

MEDICAL HISTORY
OF THE
WAR OF THE REBELLION.

WATER COLOR DRAWINGS
TO ILLUSTRATE
MEXES AND FEVERS.


SURGEON GENERAL'S OFFICE.

SURGEON GENERAL'S OFFICE

LIBRARY.

Section *Bottom Cox #54*

No. *133543*



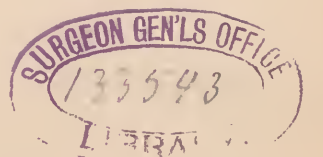
715 Surgeon's General's Office

ORIGINALS of the CHROMOS

IN THE

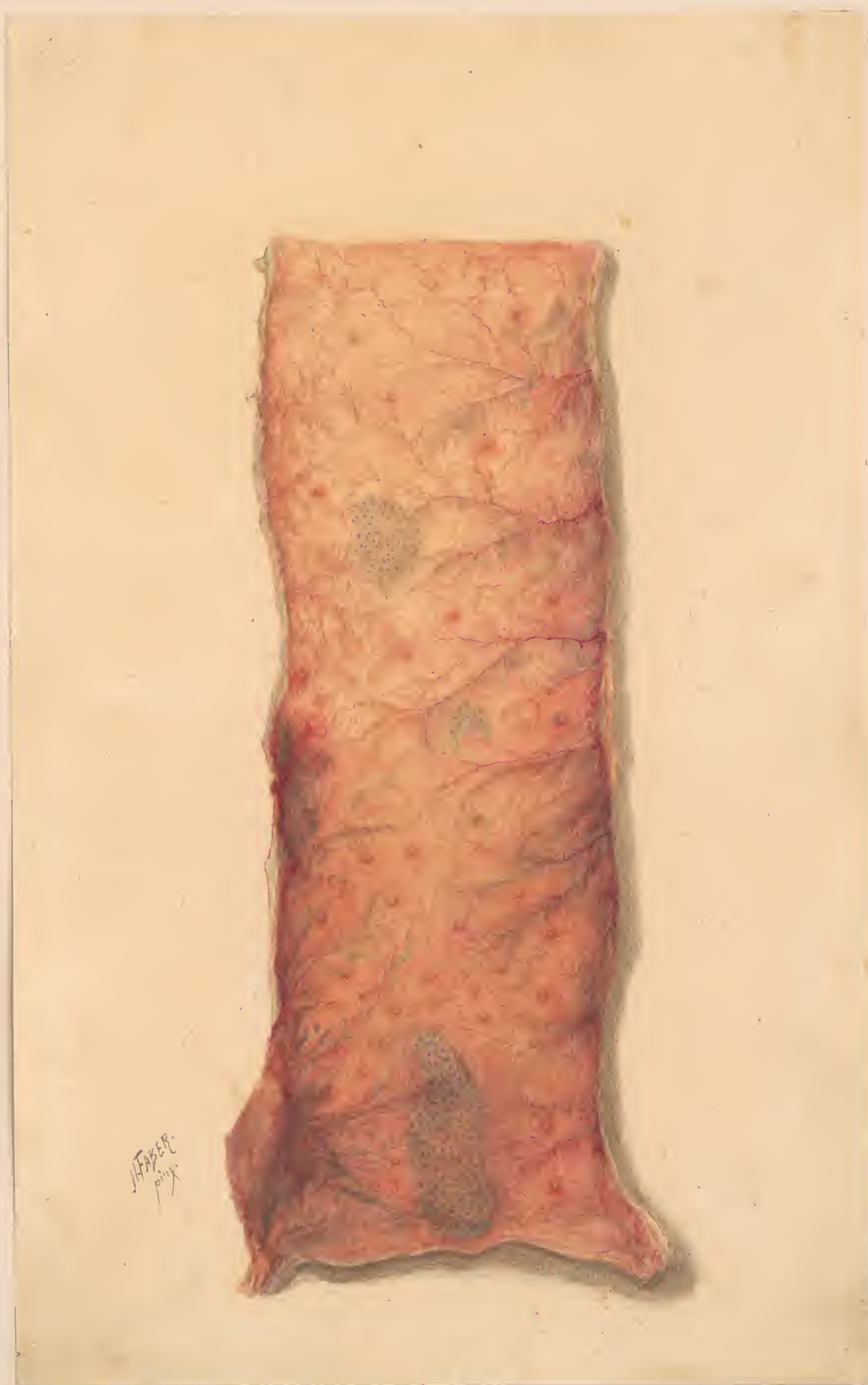Second Vol. Medical History.

W.I. P. 2



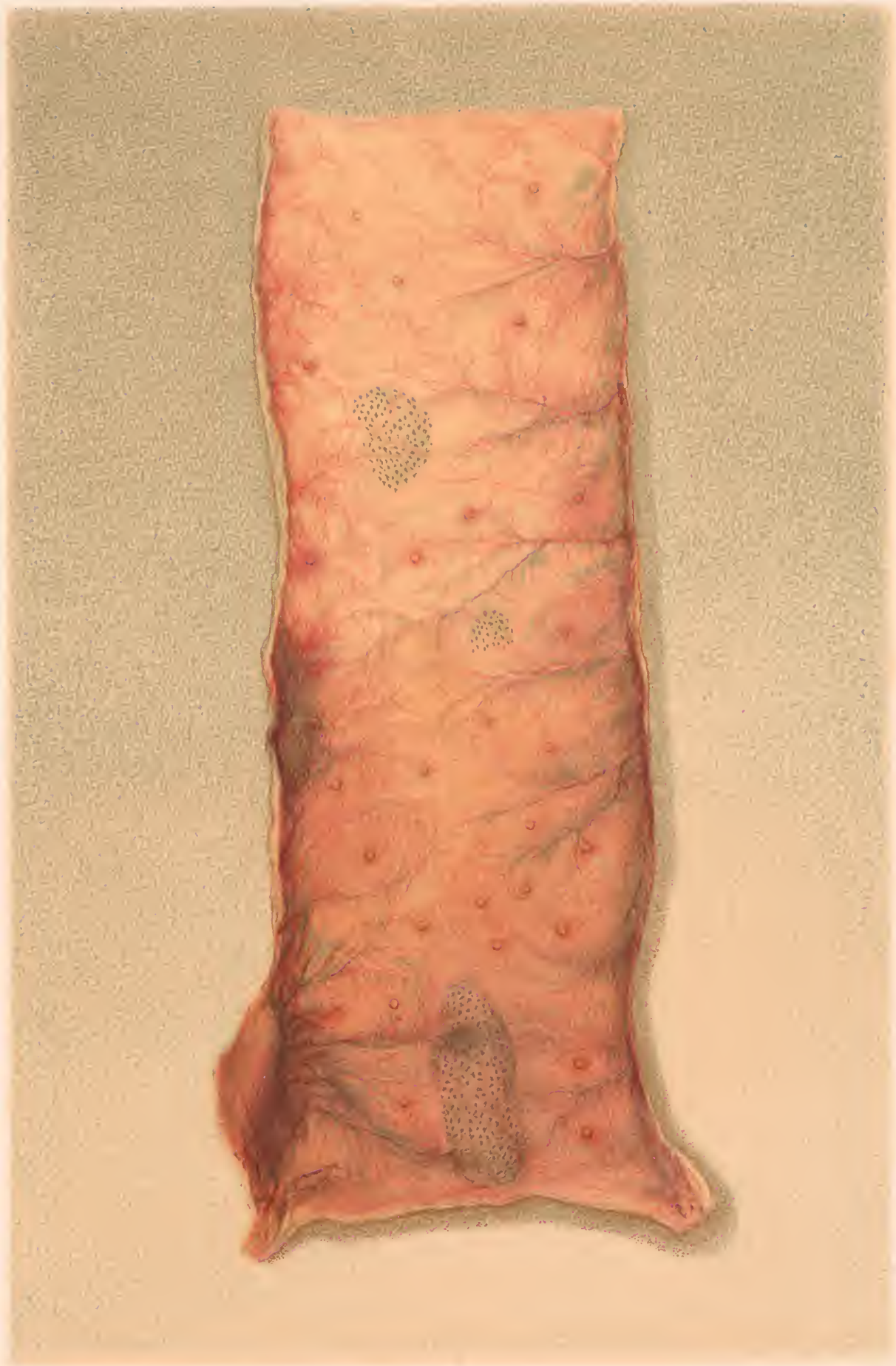Art coll.
UH
224
1861/65
FA31

NLM



HEBER
p. 11

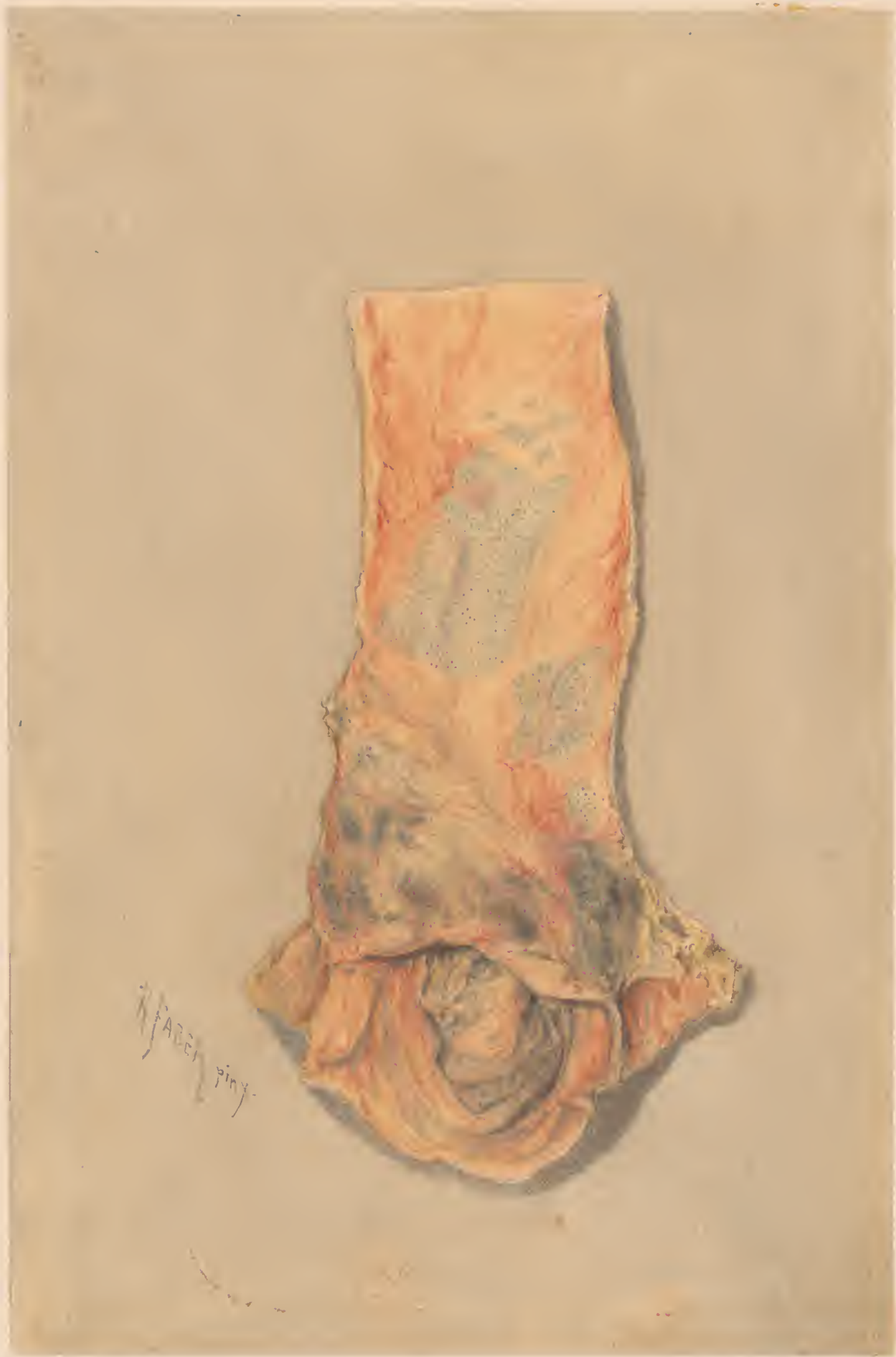1012



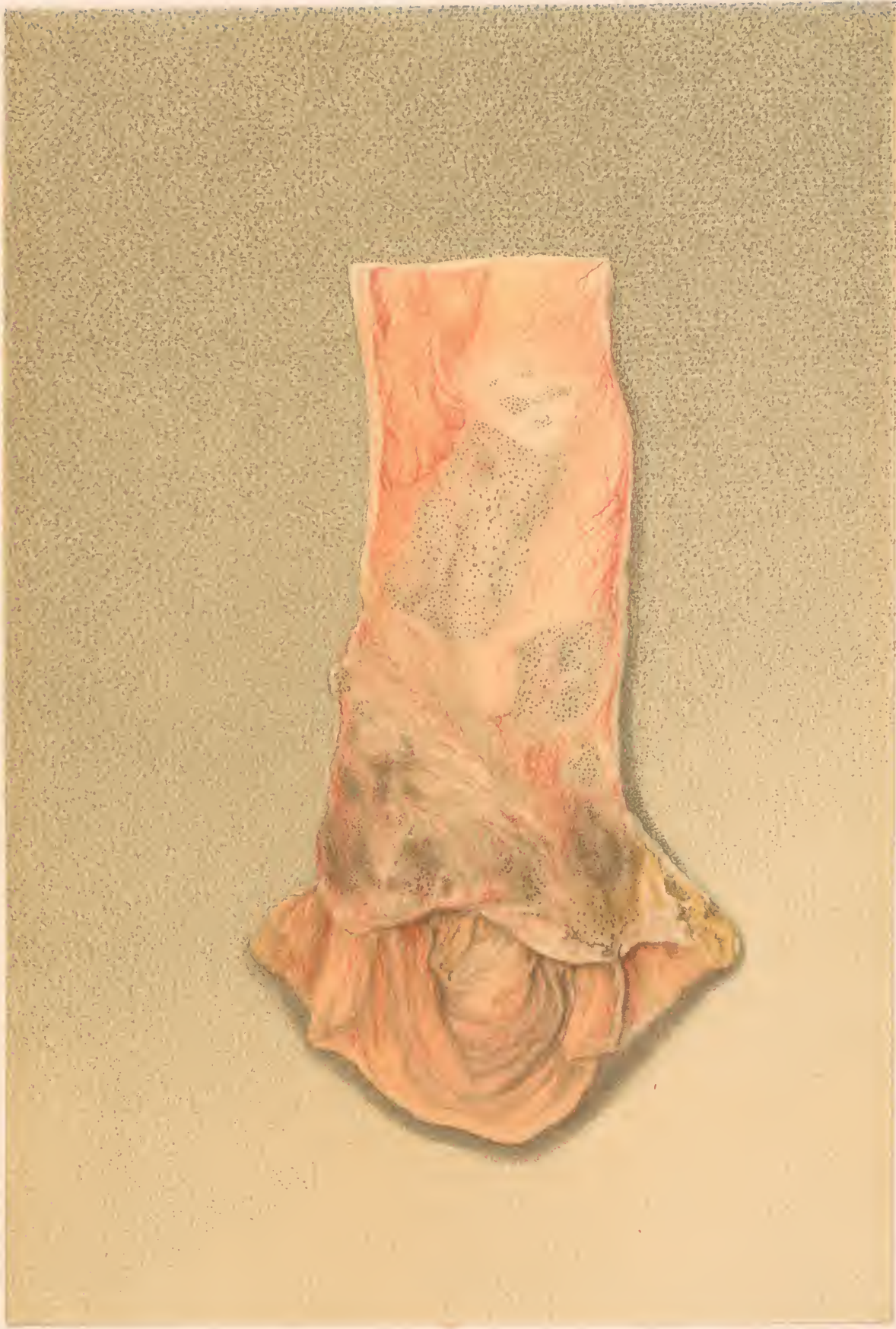
H. Faber pinx.

E. Moras chromolith. Phil.

PORTION OF ILEUM WITH INFLAMED MUCOUS MEMBRANE,
solitary follicles enlarged, and shaven beard appearance of Peyer's patches.



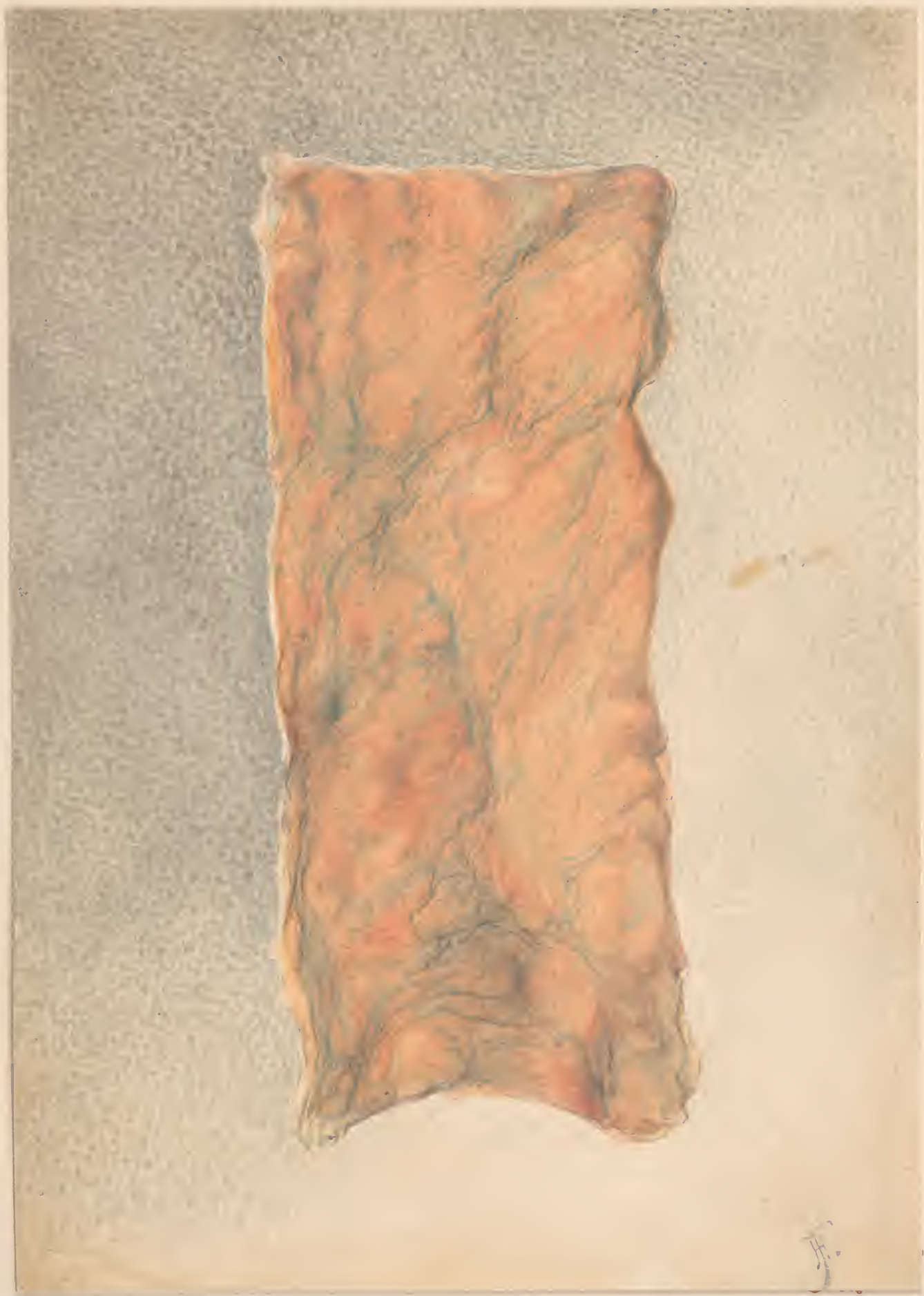2nd

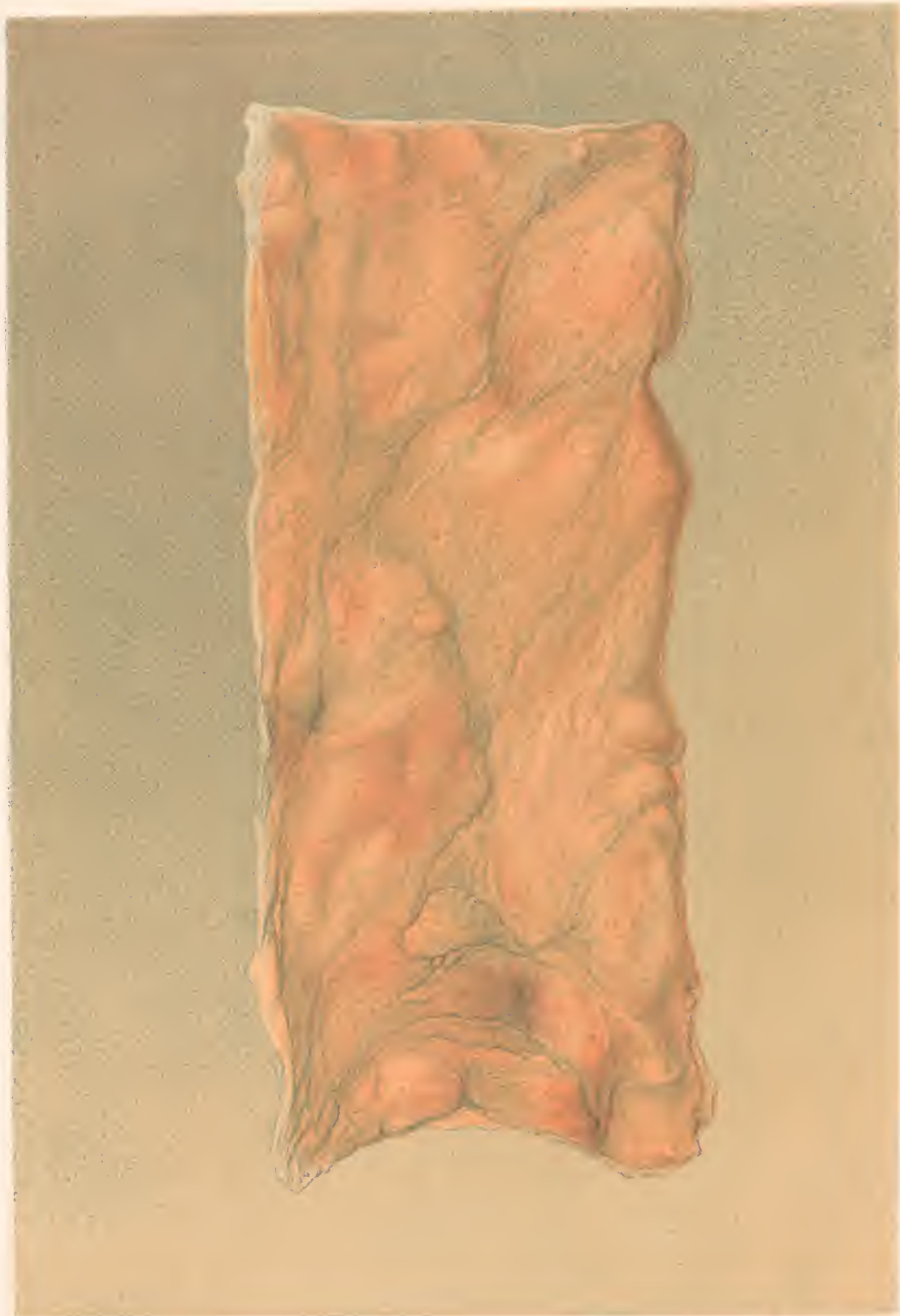


H. 10000 2000

H. 10000 2000

PIGMENT DEPOSITS IN PEYER'S PATCHES
near the ileocecal valve. Shaver lead appearance.



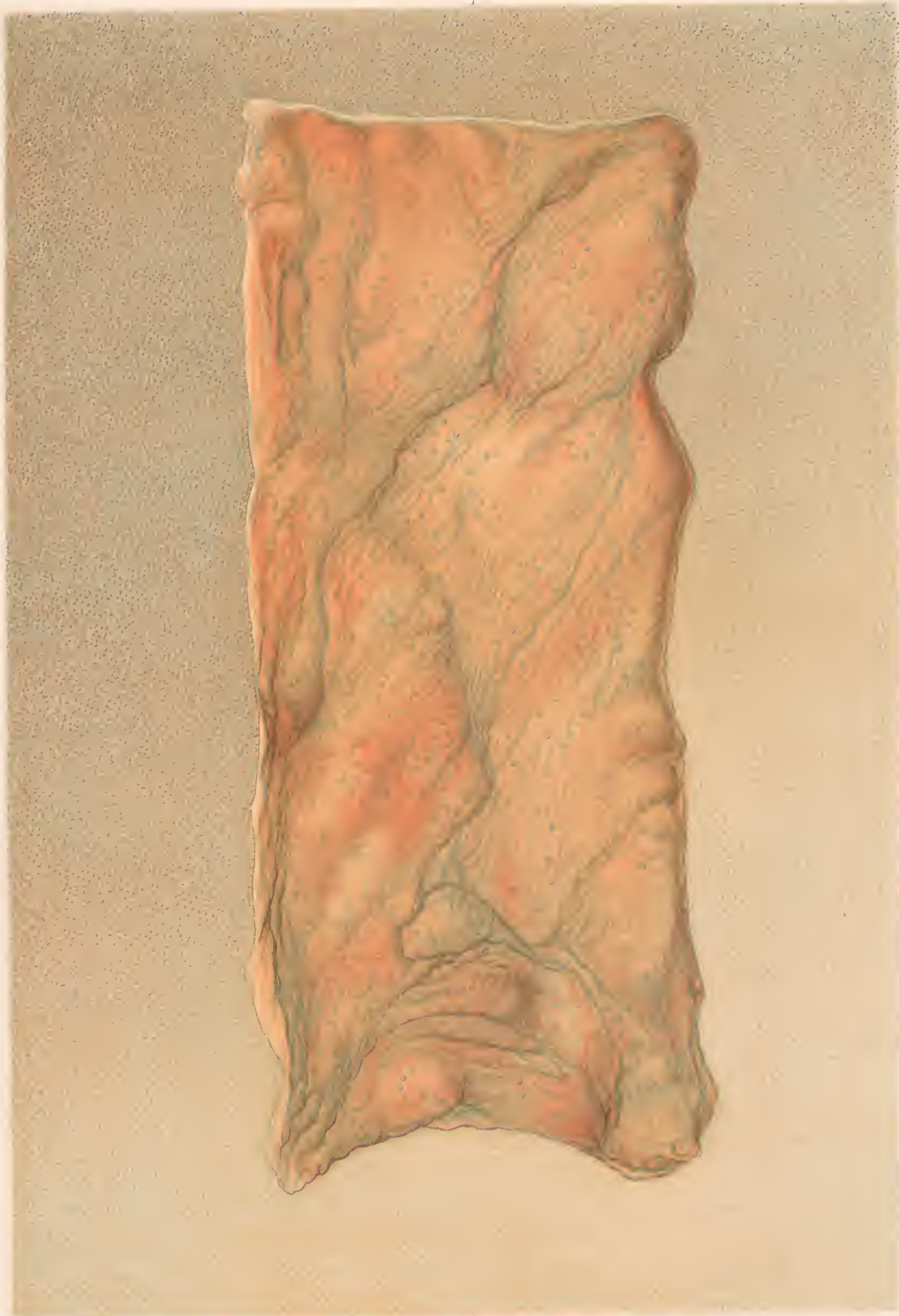

G. B. C. C. C. C. C.

F. B. C. C. C. C. C.

COLON WITH PIGMENT DEPOSITS

In and around the solitary Glands. — Dysentery

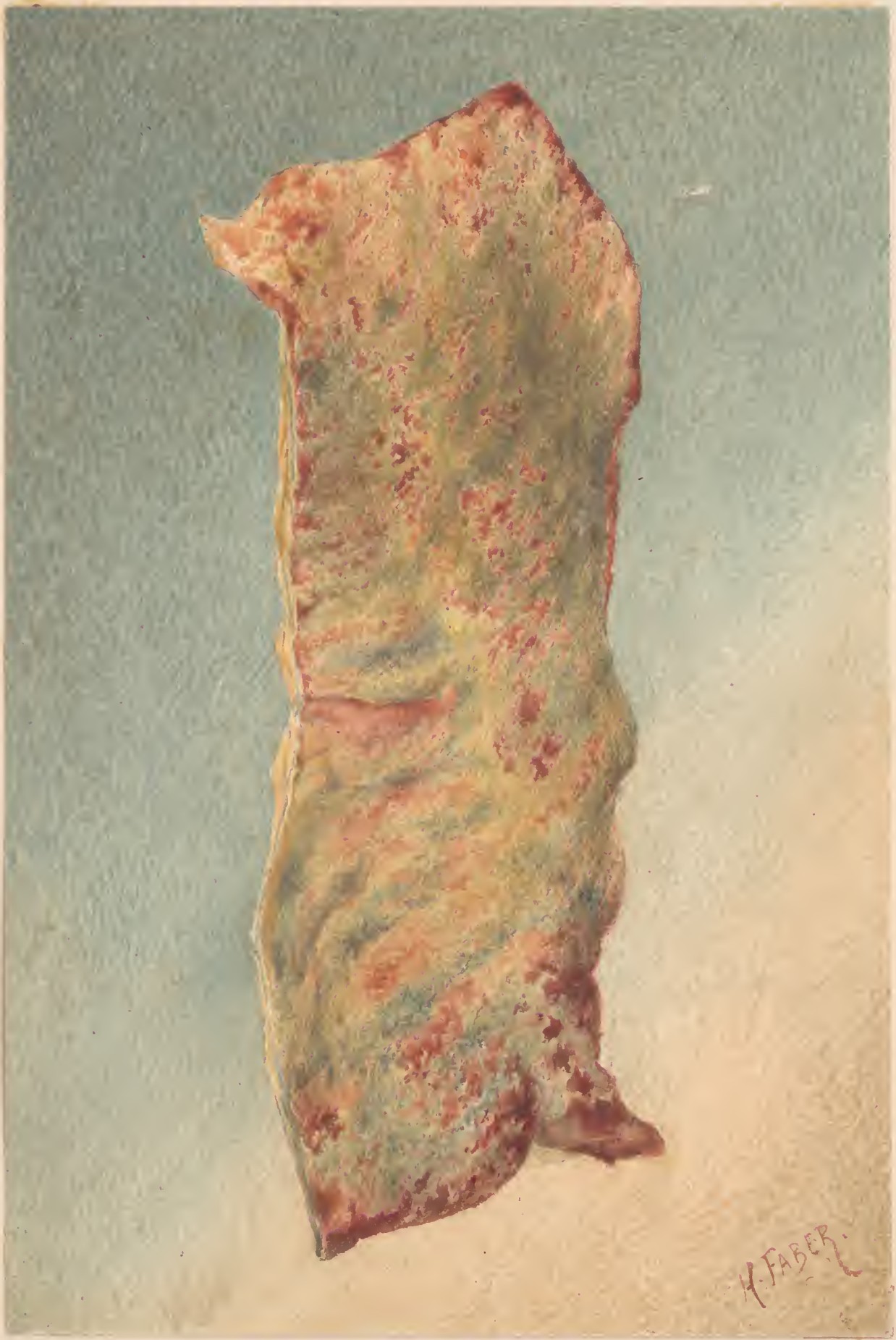

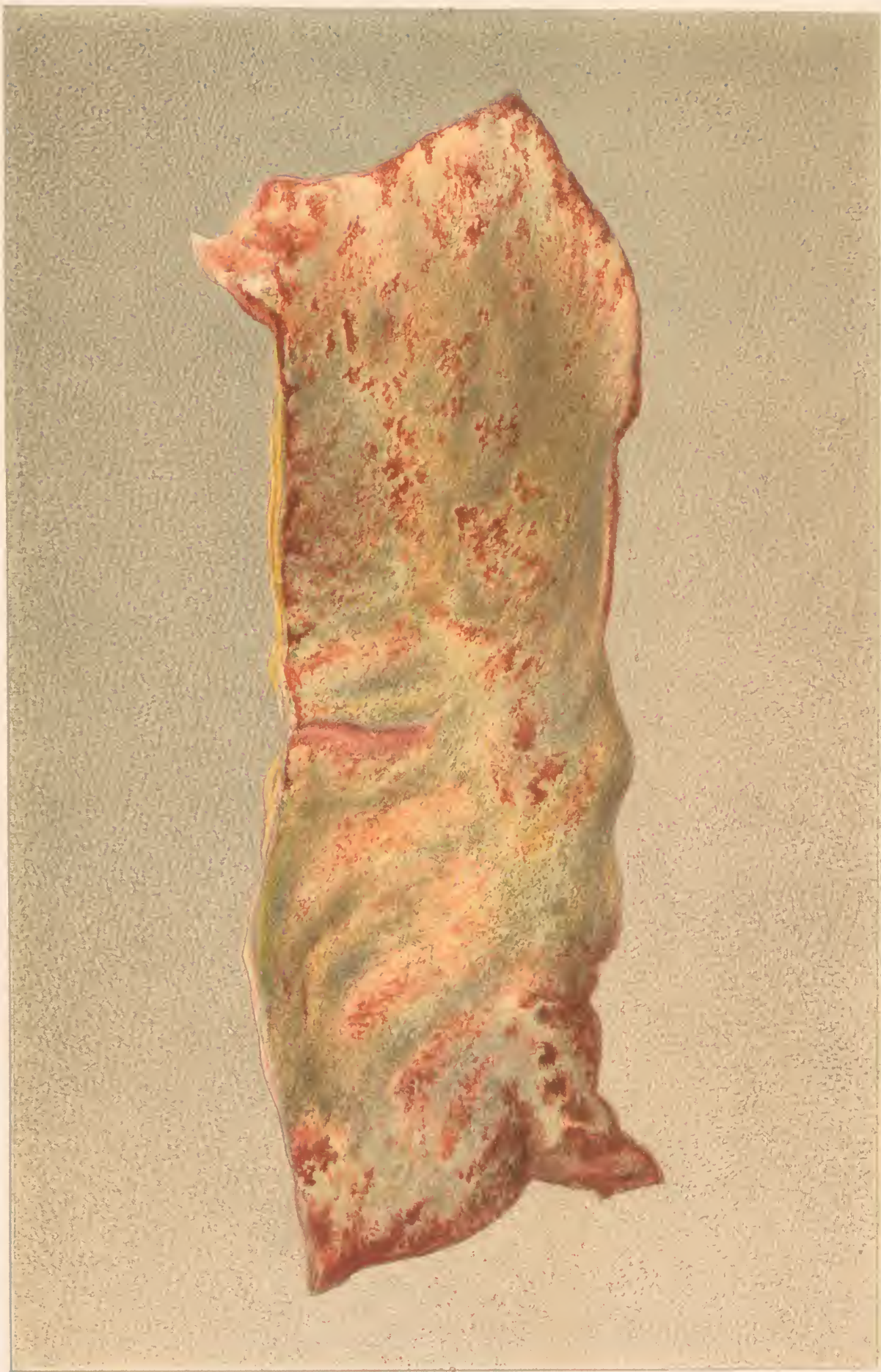From life.

By George B. Cooper.

COLON WITH PIGMENT DEPOSITS

In and around the caecal glands.



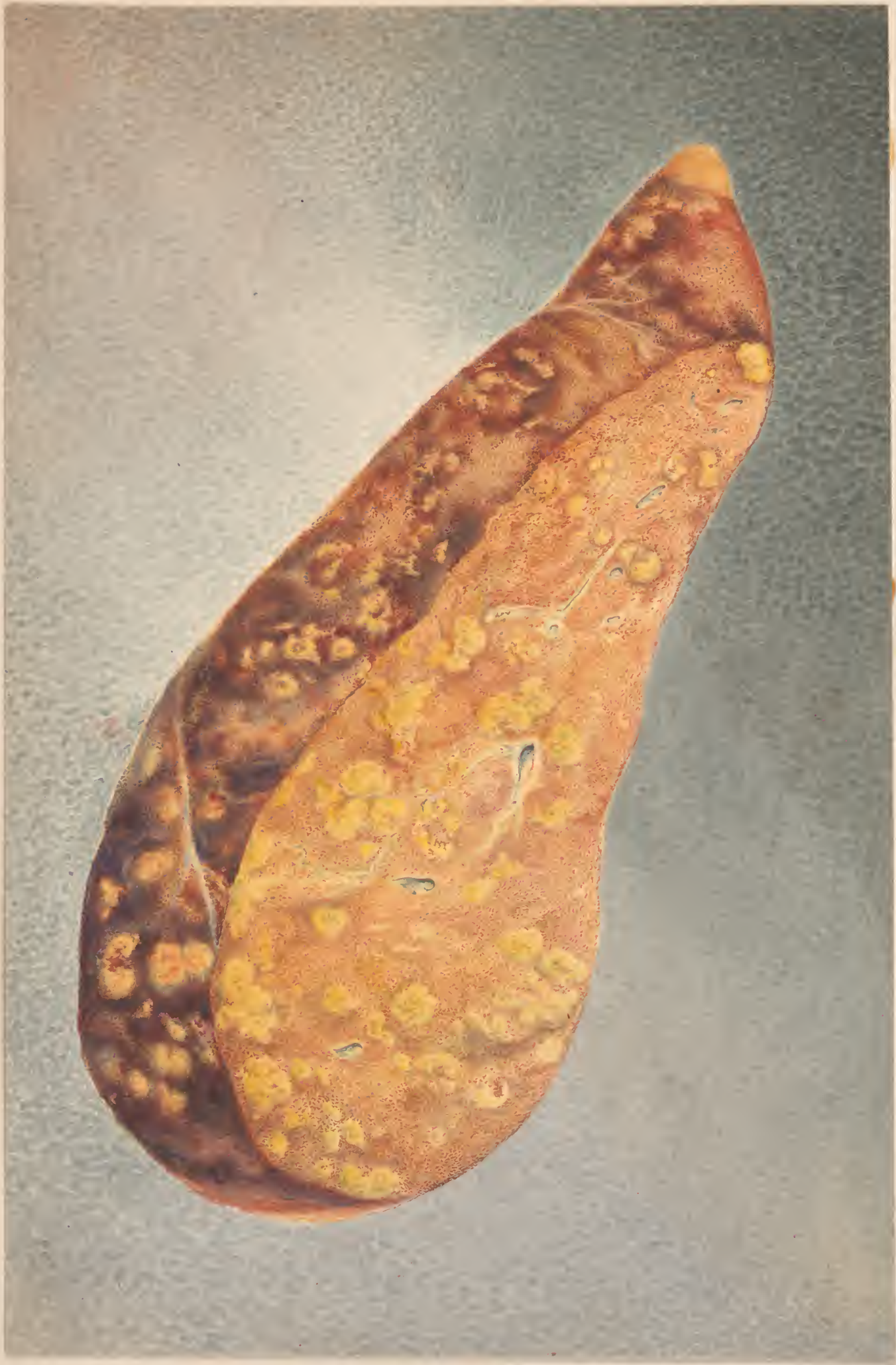

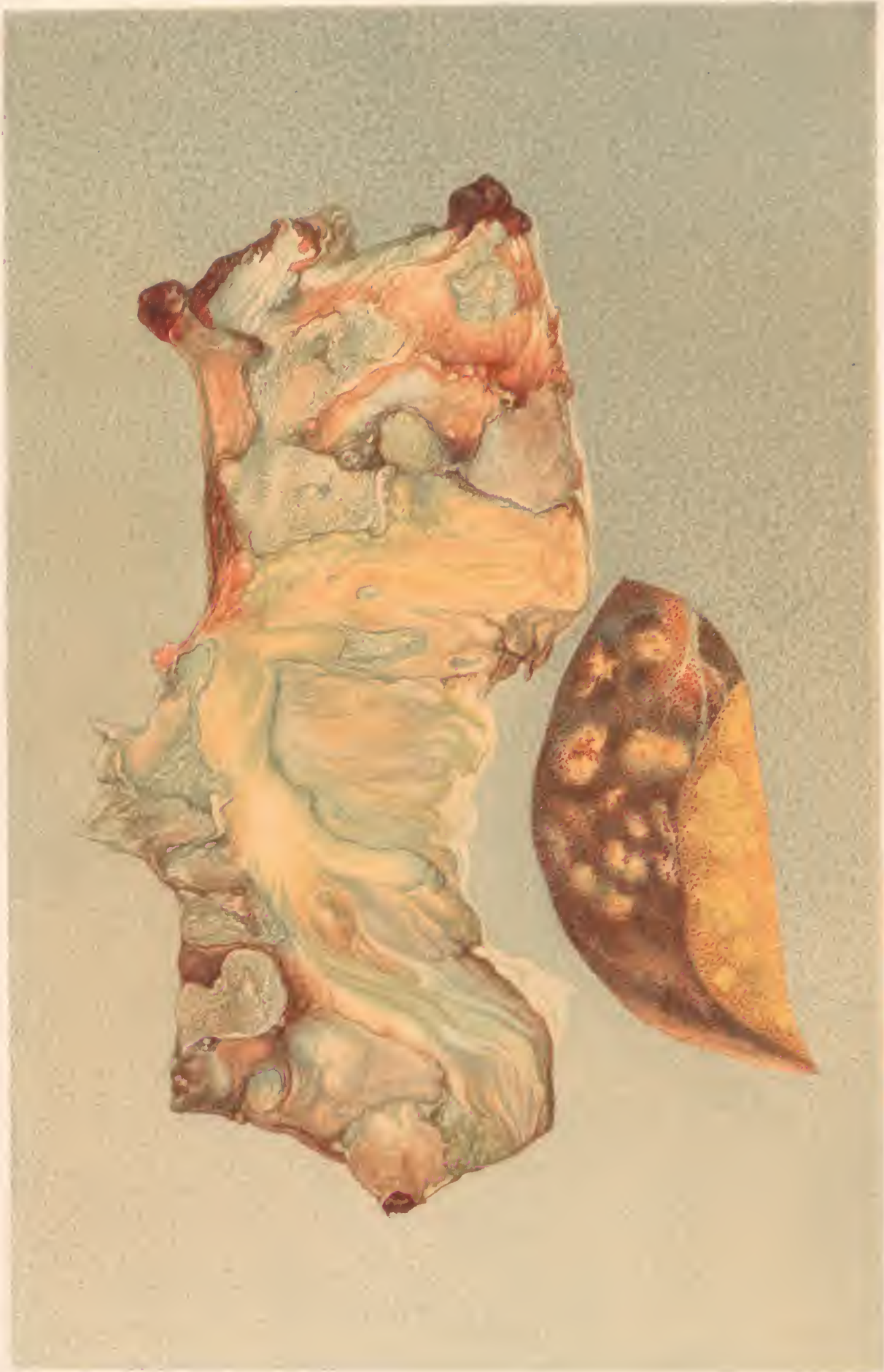H. Fäber pix

F. Moras chromolith Ph 13

PORTION OF DESCENDING COLON,
coated with pseudo-membrane.



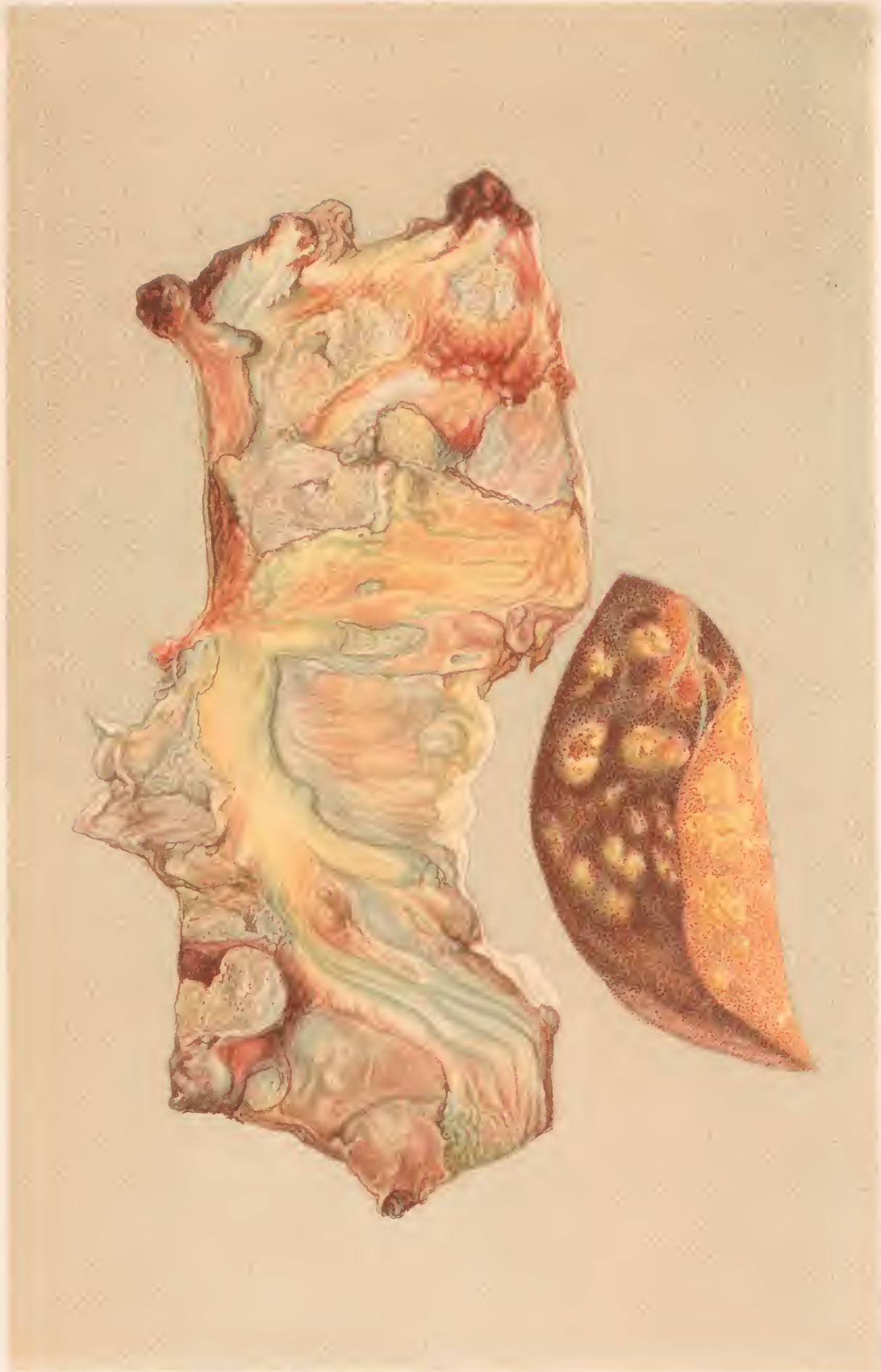



H. Fisher, 1895.

F. Moore, 1896.

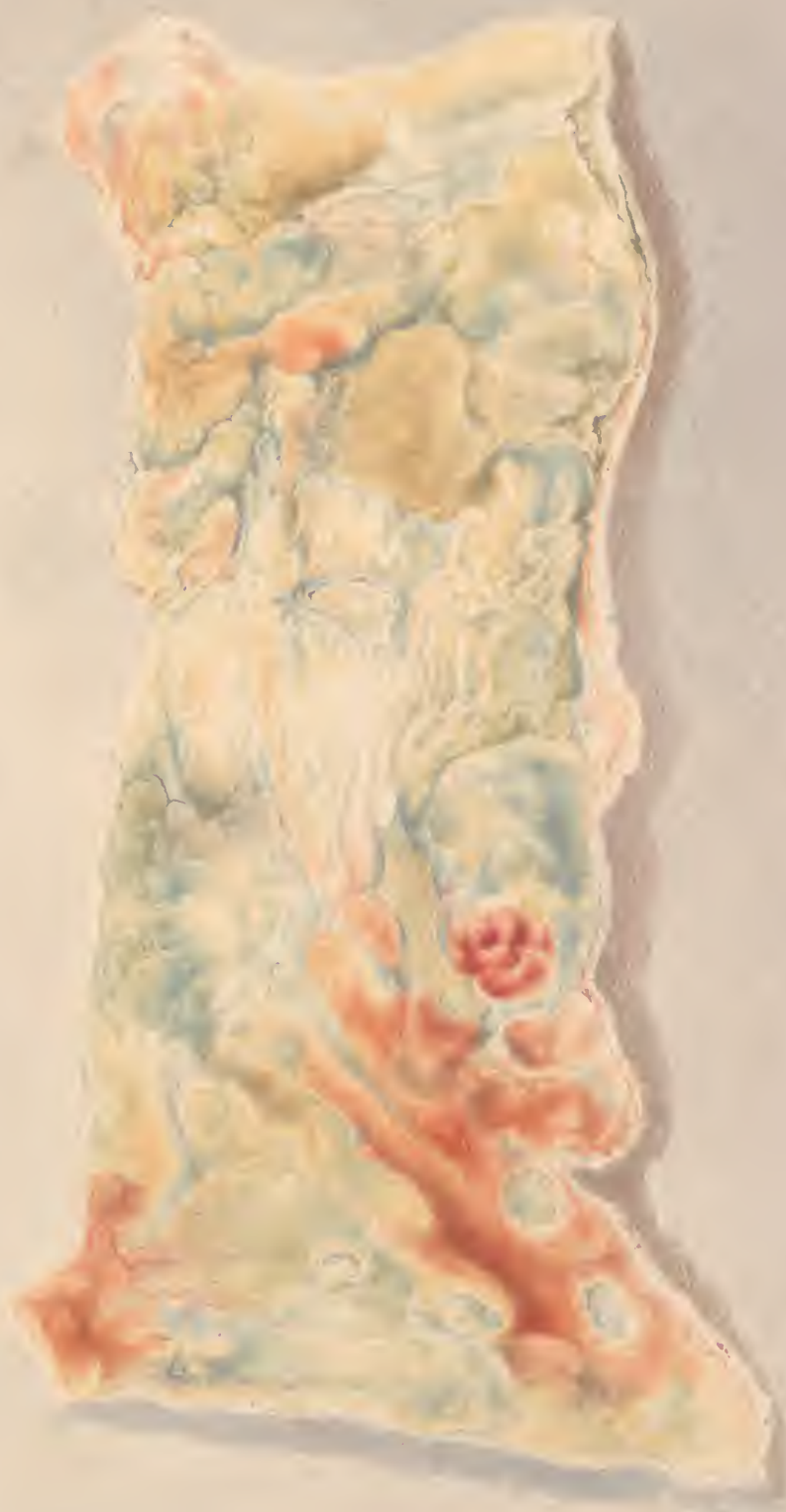EXTENSIVE ULCERATION OF COLON, CHRONIC DYSENTERY,
METASTATIC NODI OF LIVER.



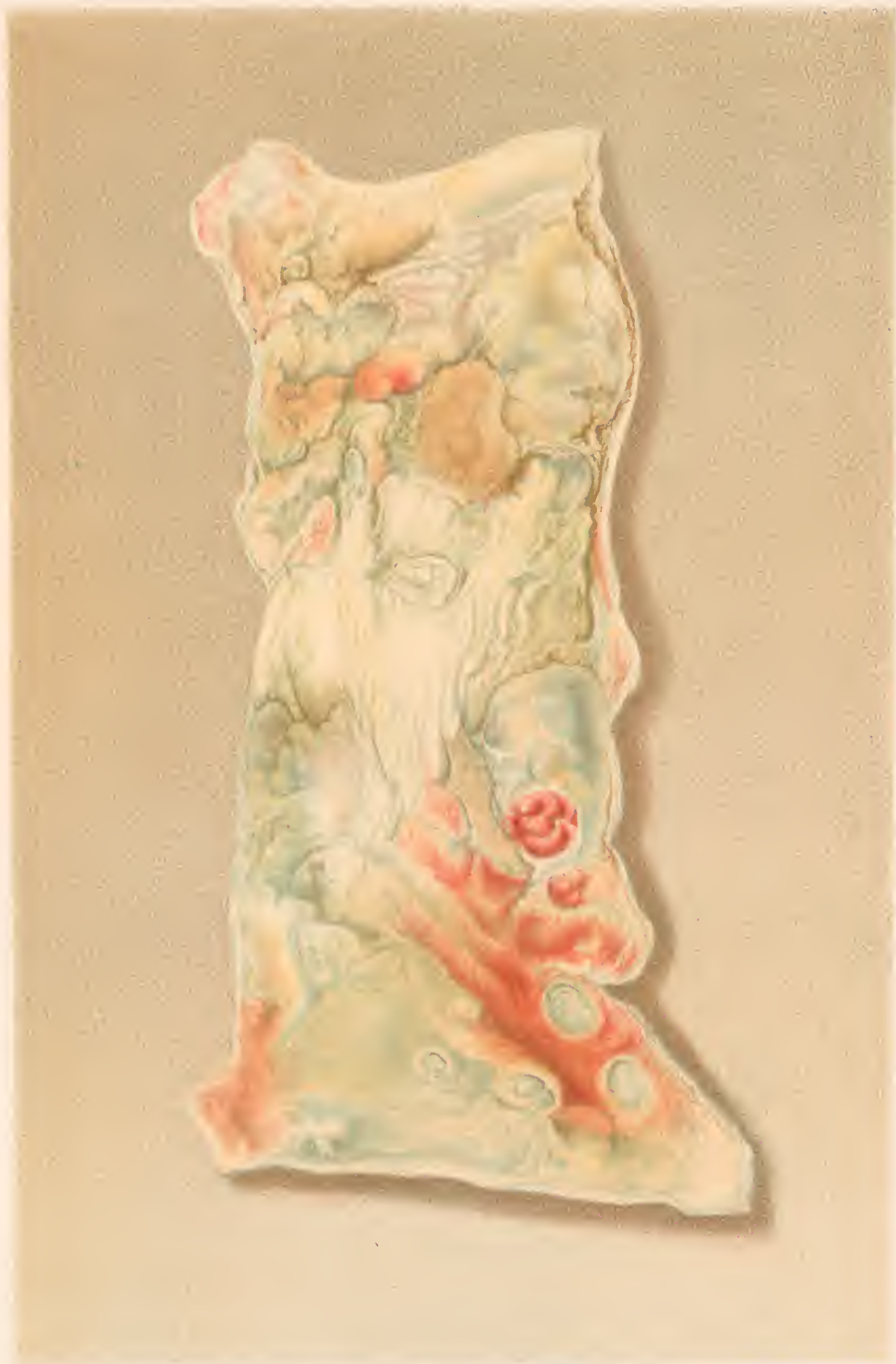H. Faber pinx'

F. Moras chromolith. 1889

EXTENSIVE ULCERATION OF COLON.-CHRONIC DYSENTERY.
METASTATIC FOCI OF LIVER.

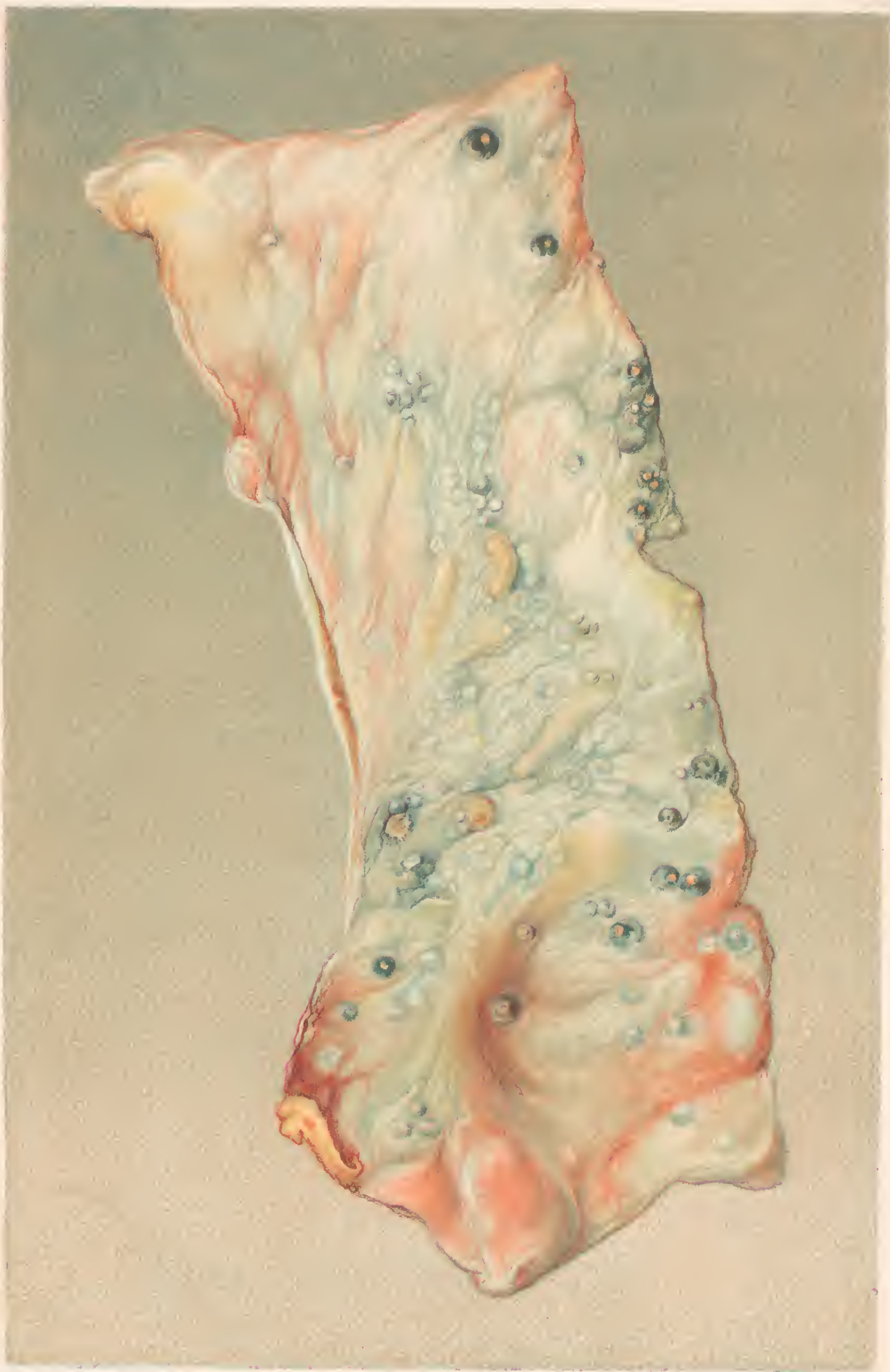

H. 1100



ULCERATION OF THE COLON.
Walls Medical Section





H. Faber pinx.

F. Mores chromolith. Philad.

SOLID CYSTS OF CHRONIC DYSENTERY.

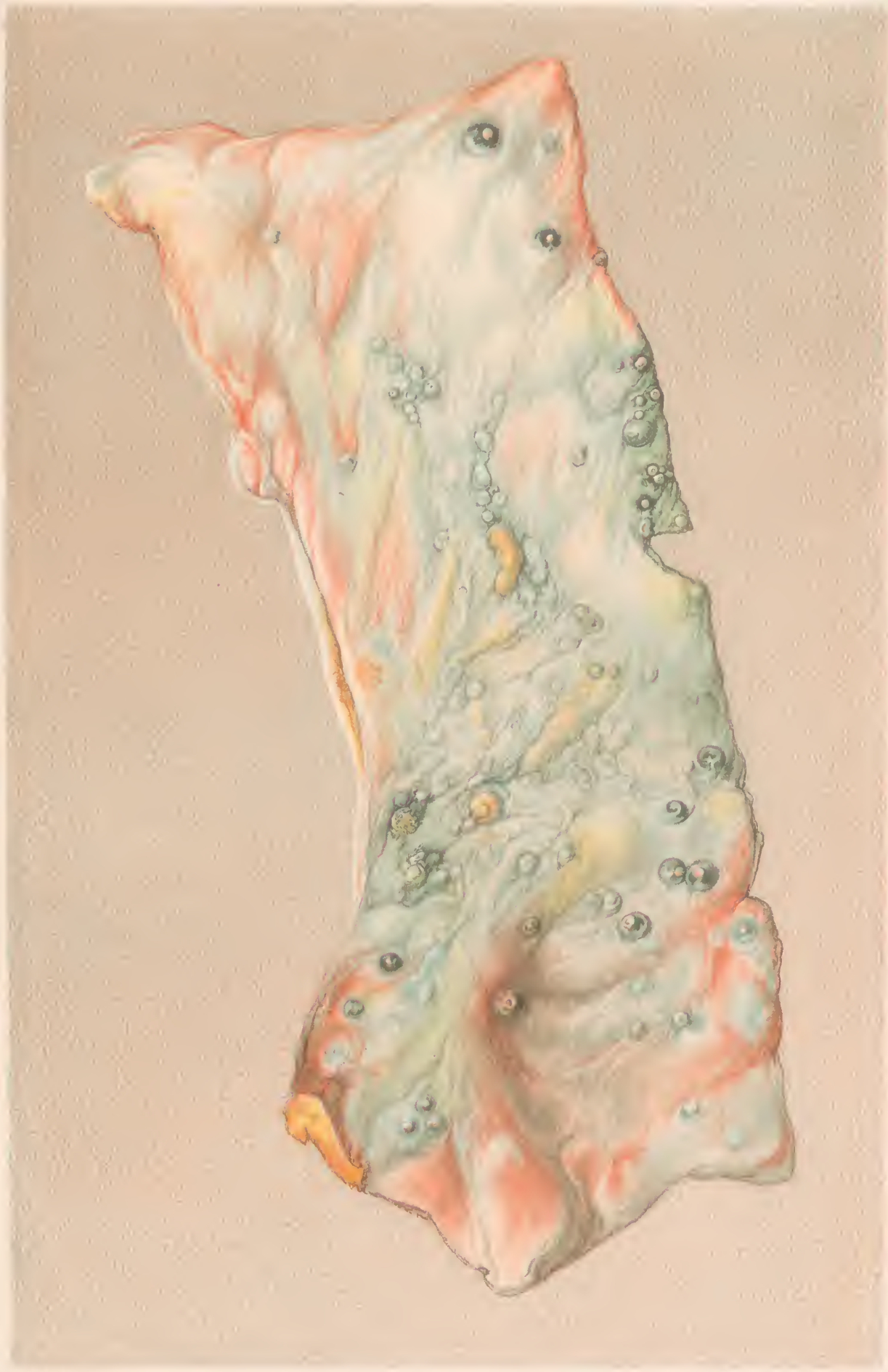

Fig. 1000.

Fig. 1000. Chronic Dysentery.

COLIC CYSTS OF COLON - CHRONIC DYSENTERY -





1880

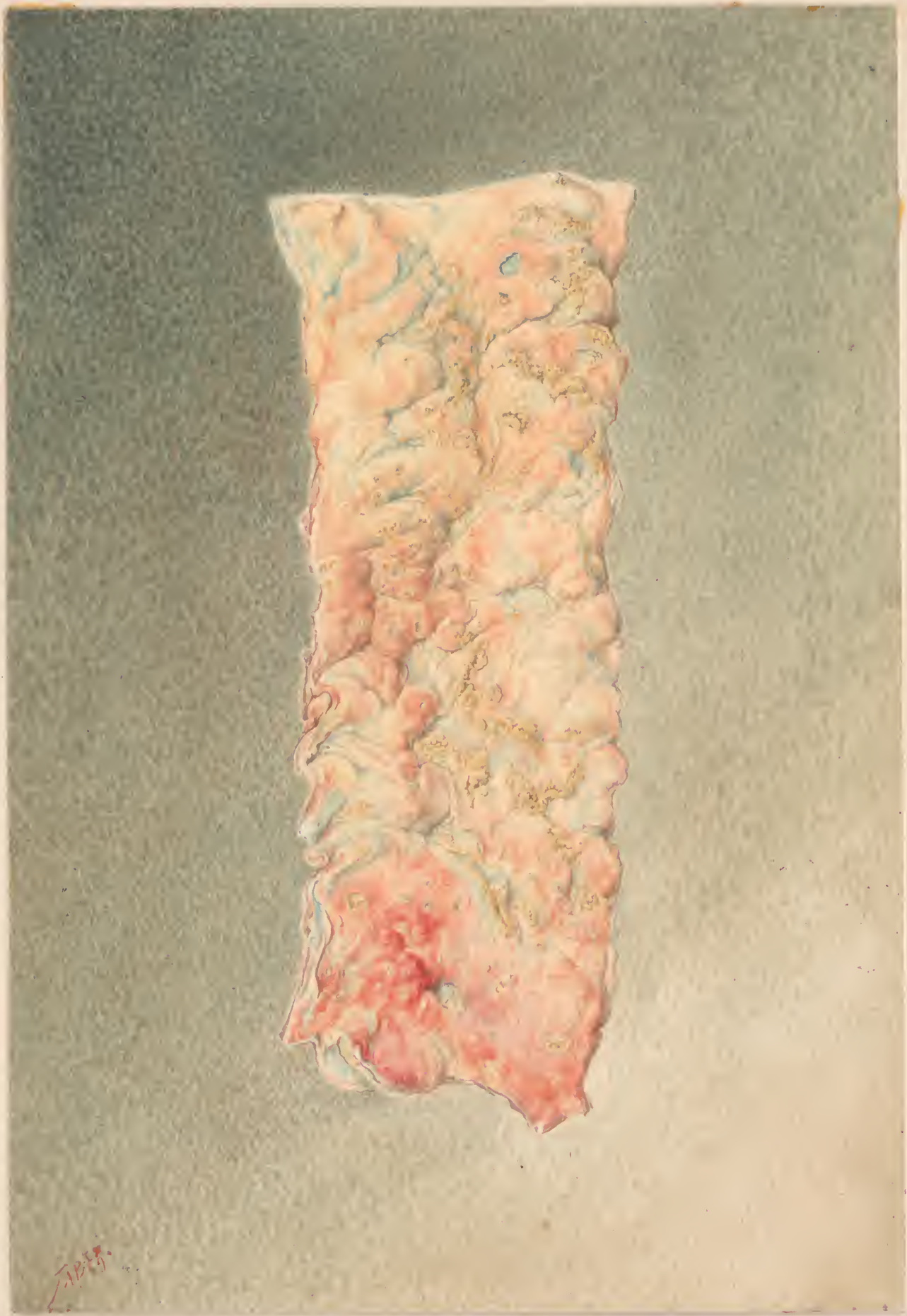120

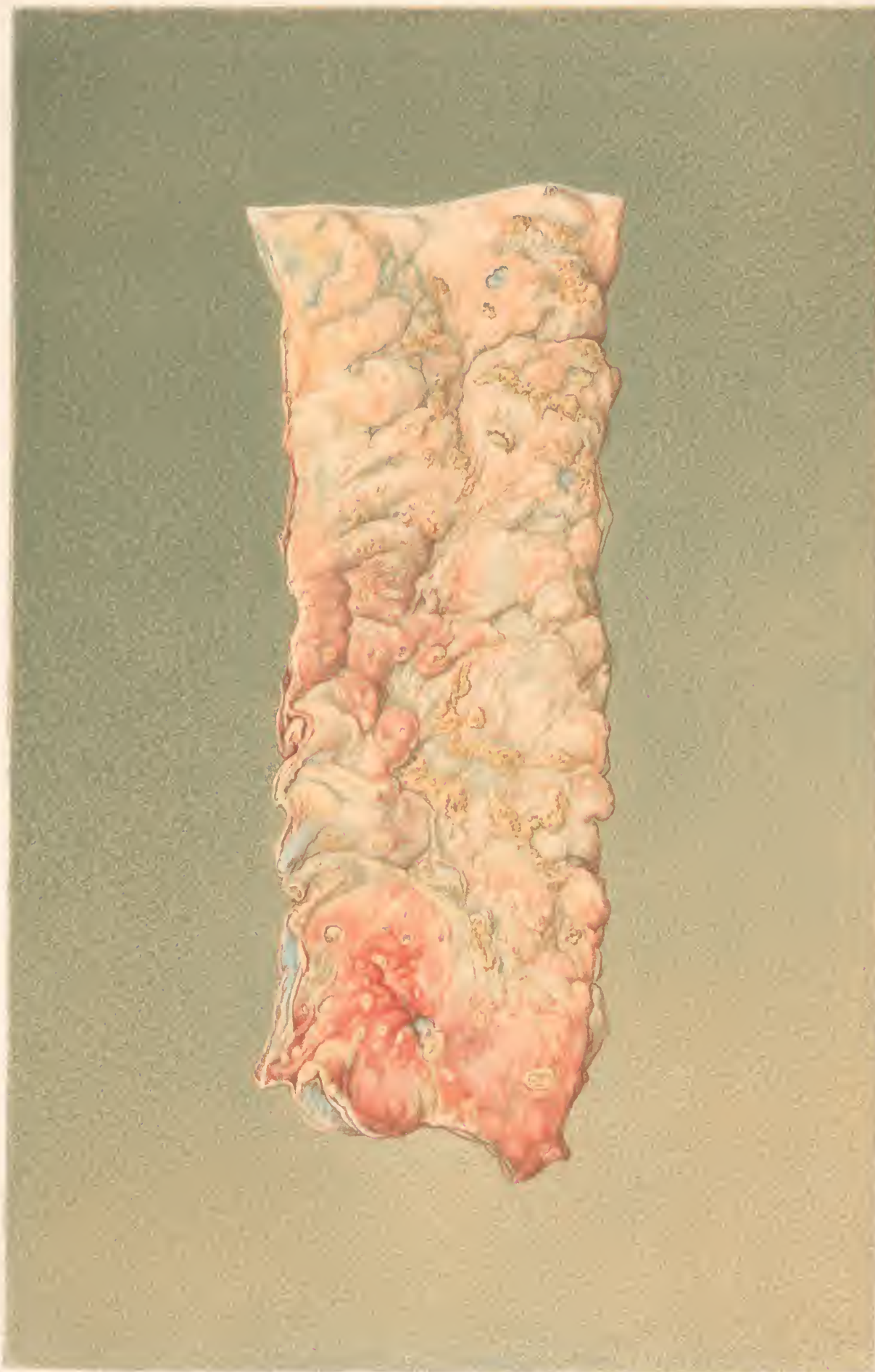COLLEGEAR MEMBRANES OF ANAEMIC-DYSENTERY

The color is thickened and anæmic



SPRINKLE 1880 LITHO BY ...
THE COLOR OF THE PAPER IS ...



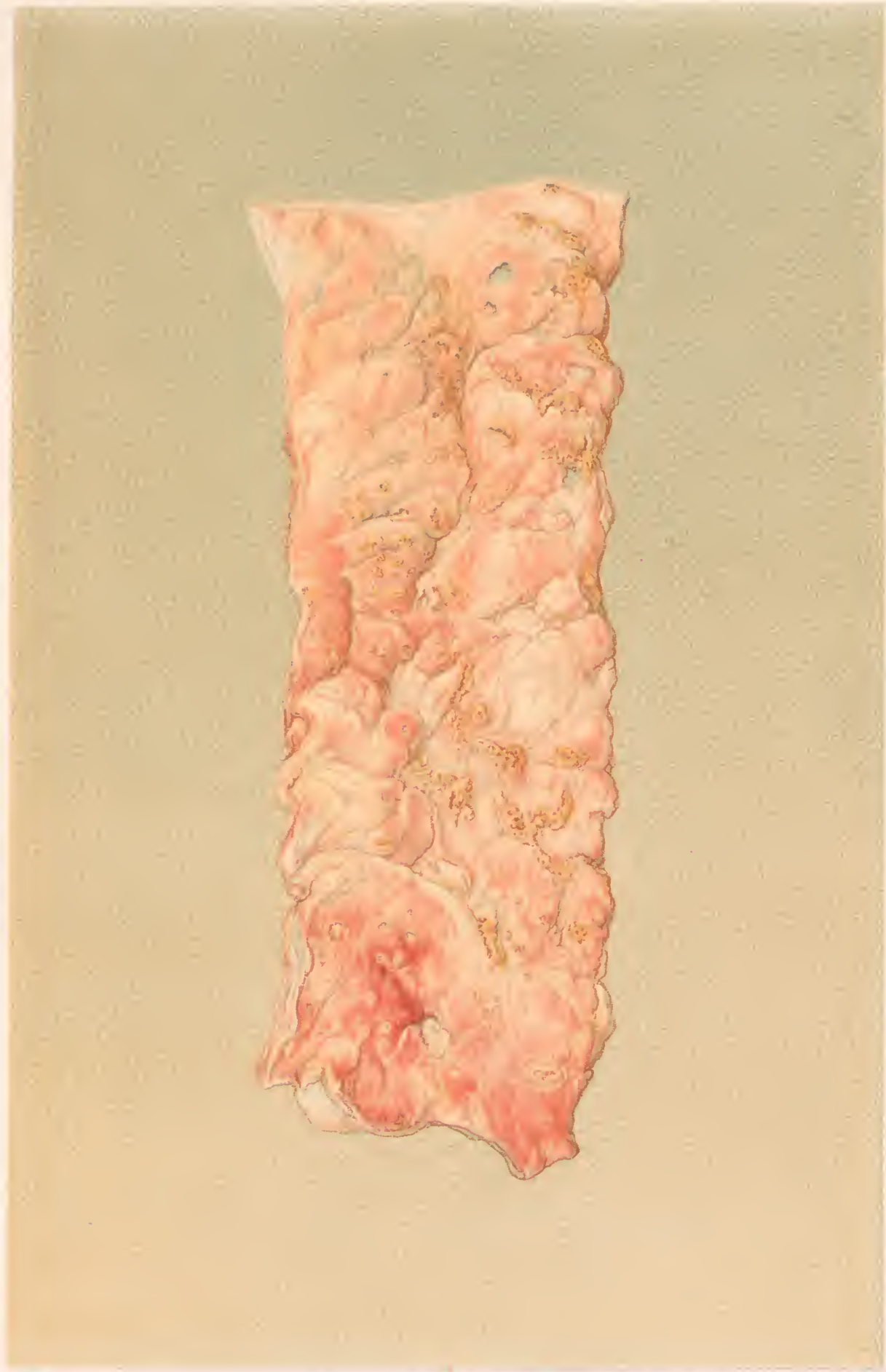


W. E. Barber, M.D.

© 1910 by W. E. Barber, M.D.

FOLLICULAR ULCERS OF COLON - CHRONIC DYSENTERY.

The edges of many of the ulcers are fringed with pseudo-membrane.

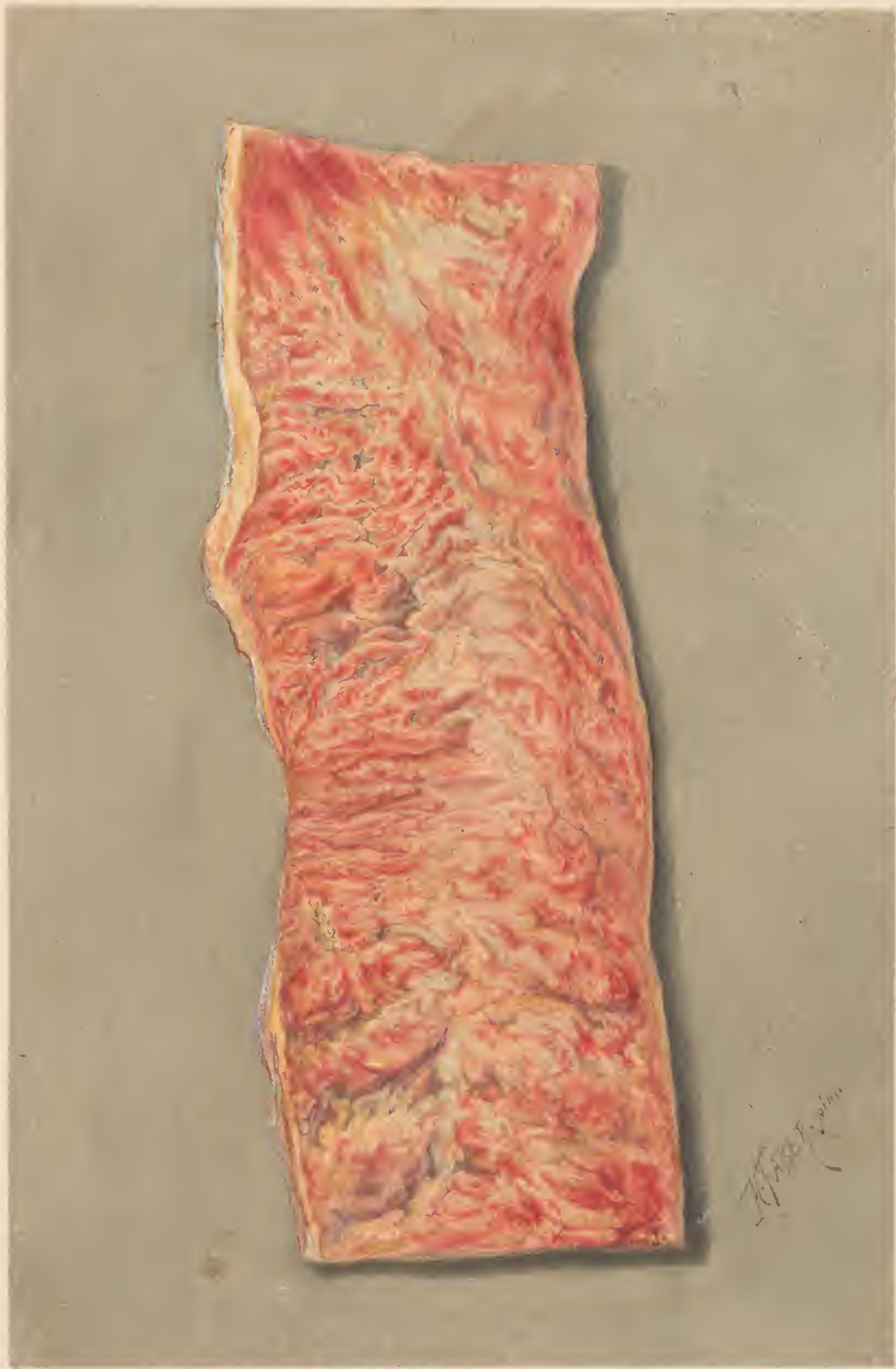

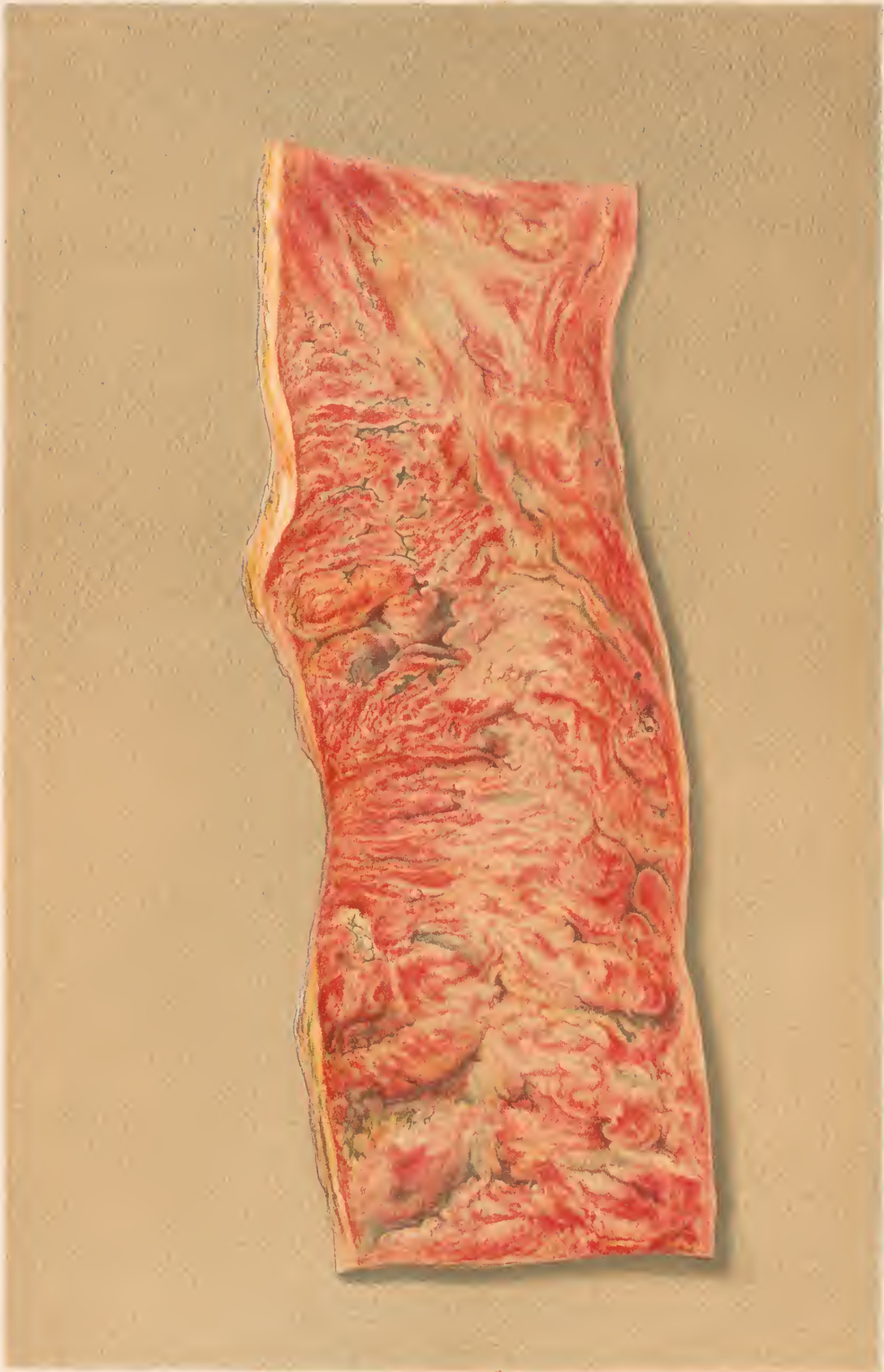Edwards

McFarlane

FOLLICULAR ULCERS OF COLON.-CHRONIC DYSENTERY.

The edges of many of the ulcers are fringed with pseudo-membrane

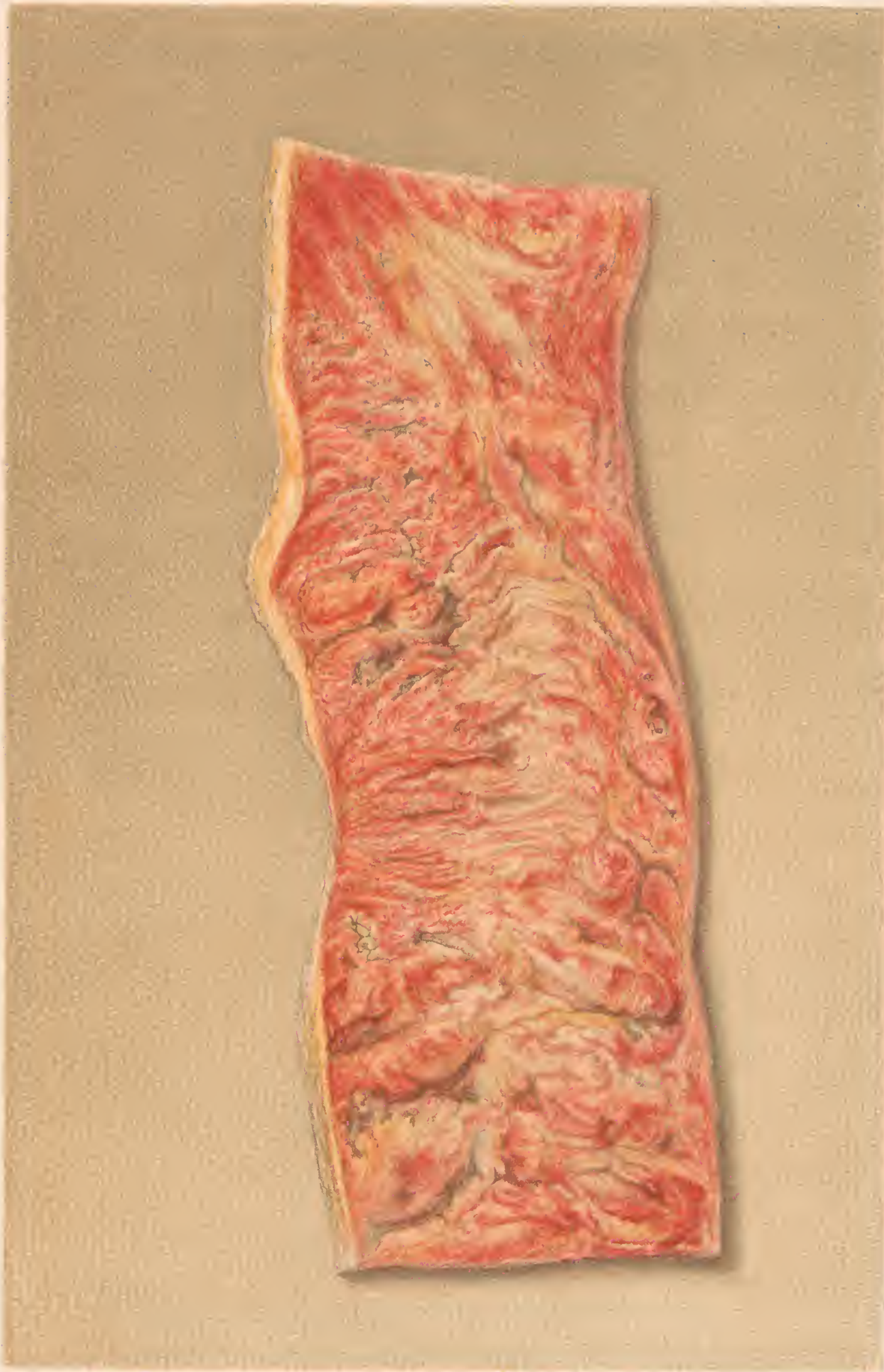



H. Faber pinxt

F. Moras chromolith Phila.

PORTION OF DESCENDING COLON
with patches of pseudo membrane, and small ulcers.



H. 1000 1/2

T. 1000 1/2

PORTION OF DESCENDING COLON
with patches of pseudo membrane, and small ulcers.

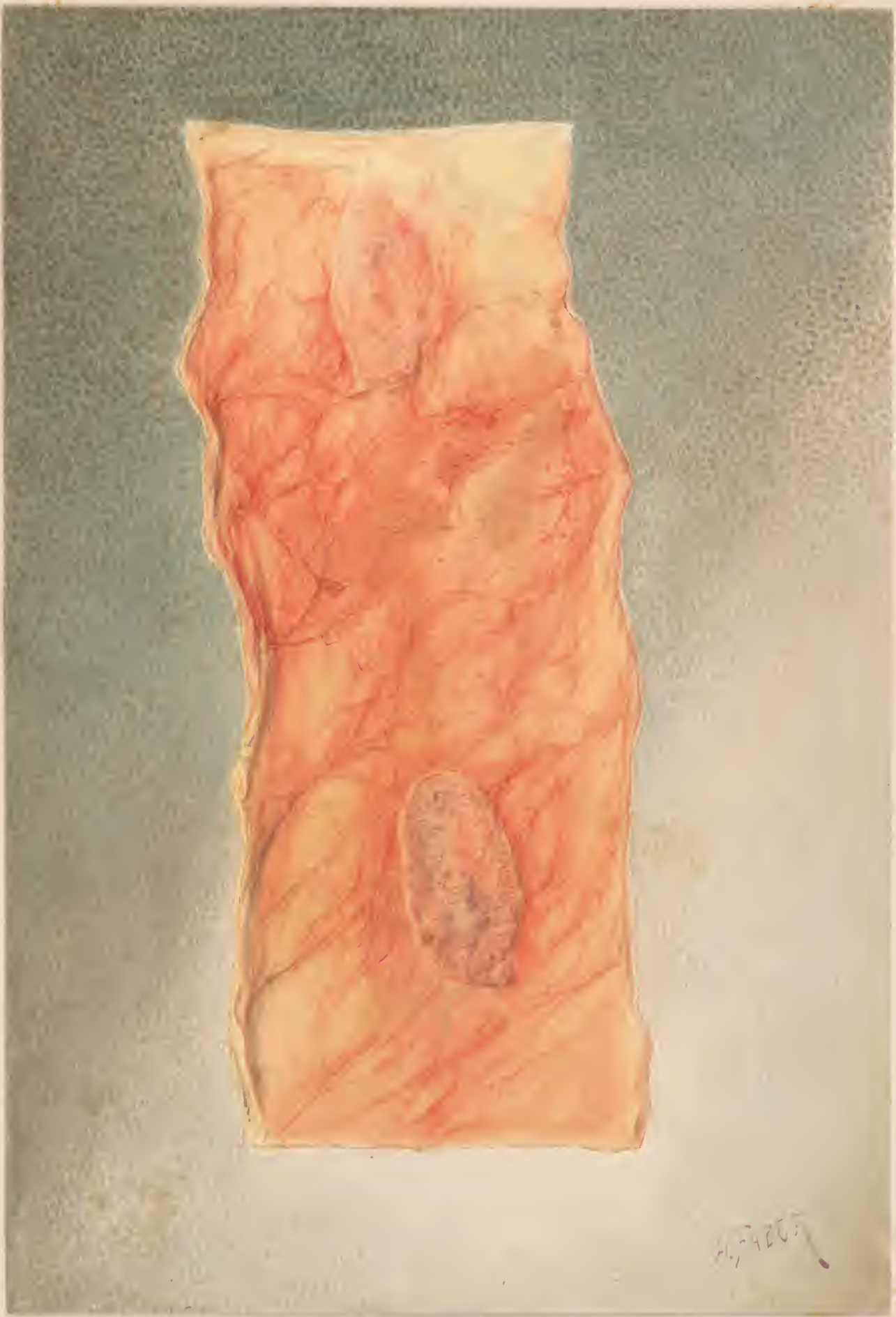
Originals

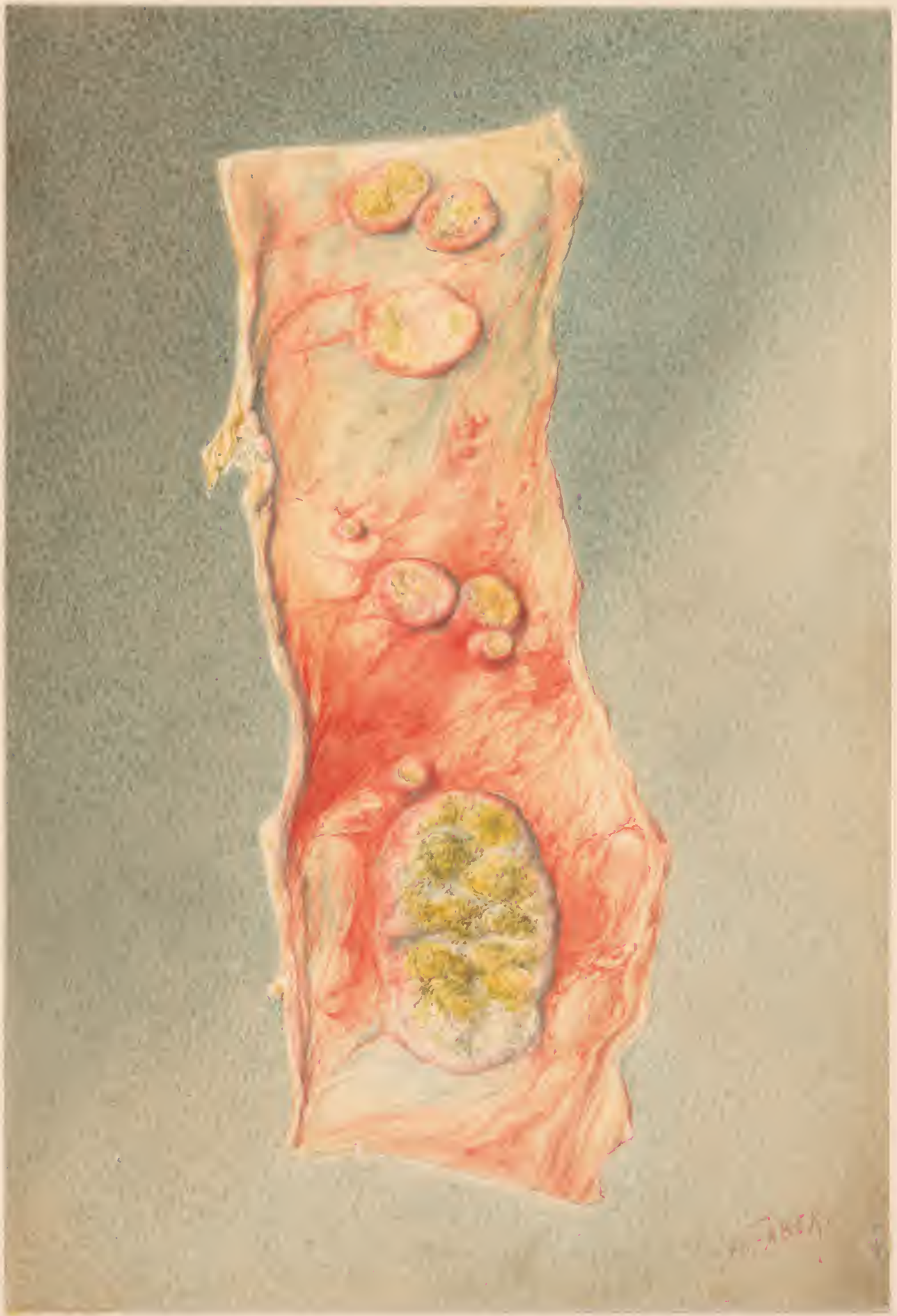
—of the—

—(in CHROMOS the)—

THIRD MEDICAL VOLUME.

v. 1 pt 3





12

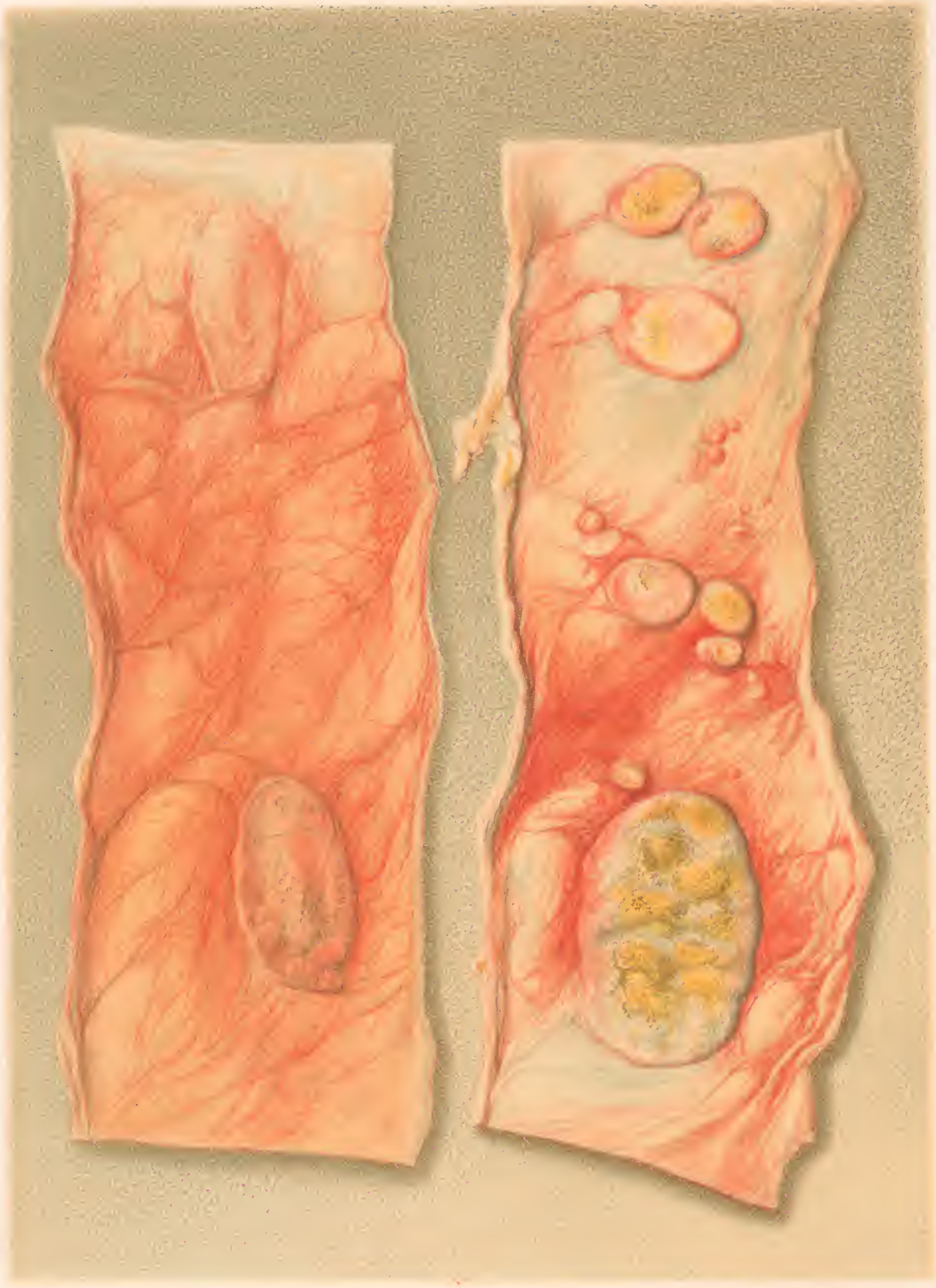
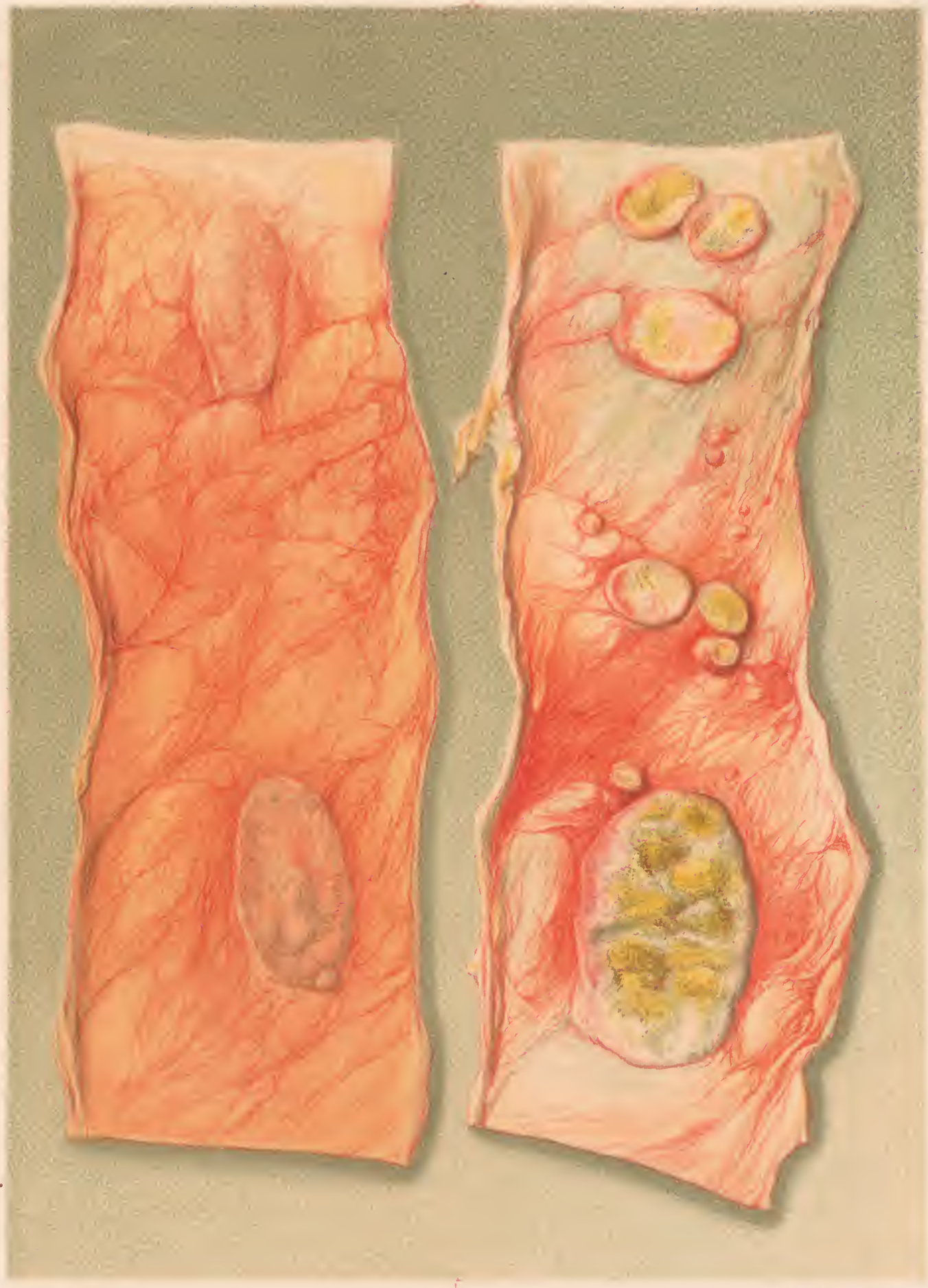


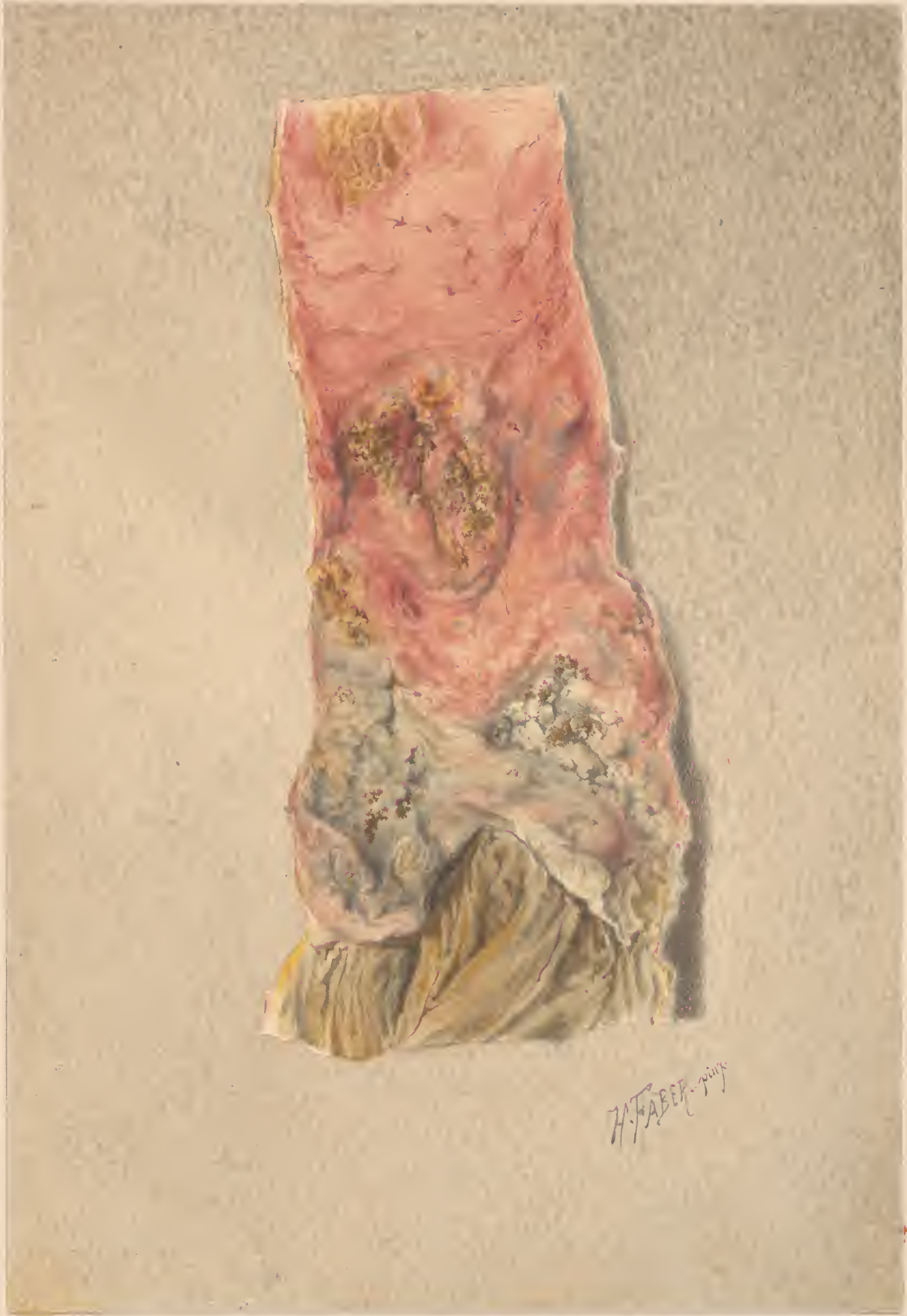FIGURE 1. SECTION OF THE STOMACH.



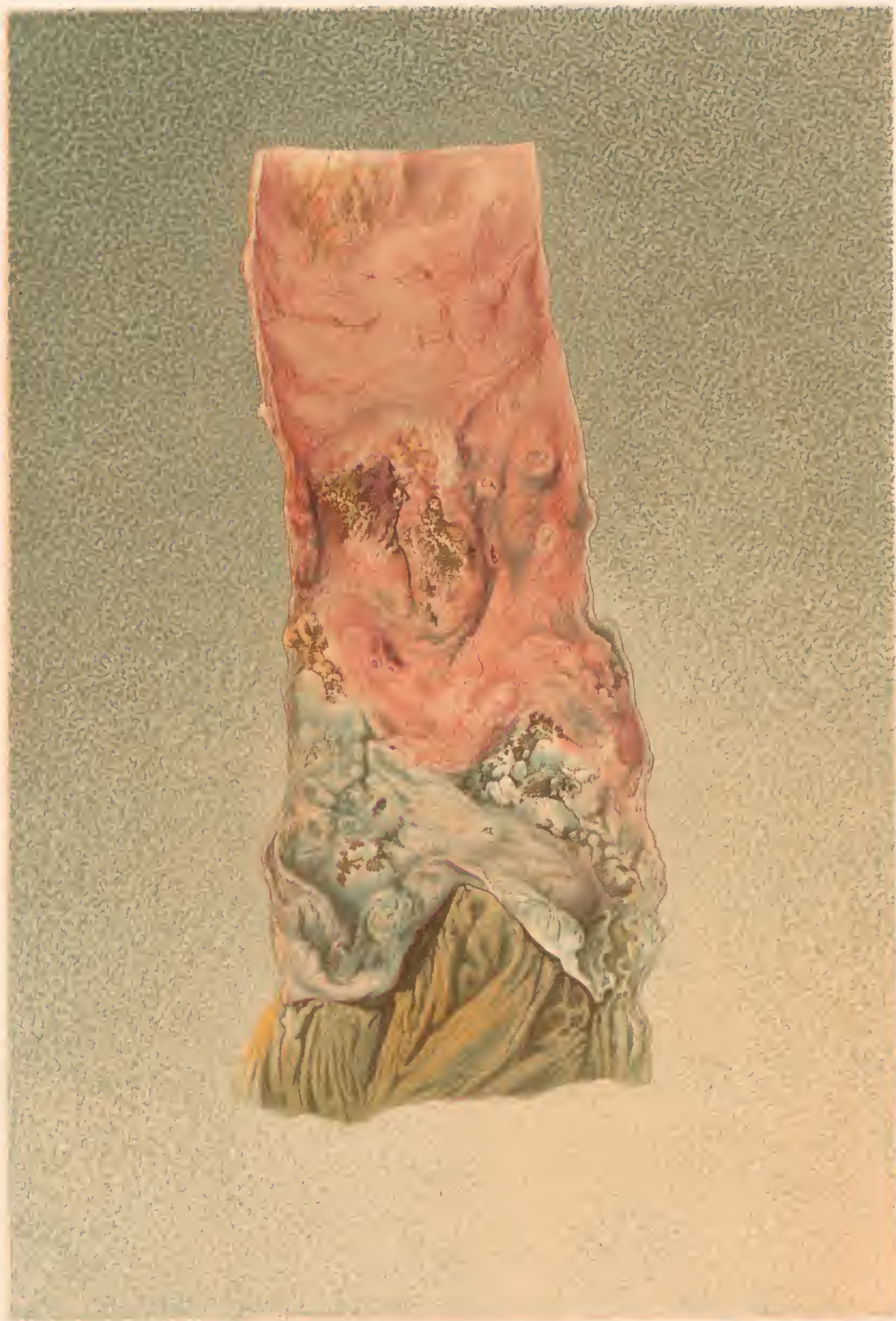H. Faber p. 114

© W. B. Saunders Co. Philadelphia, Pa.

TYPHOID THICKENING OF PEYER'S PATCHES.



H. FABER



H. Faber pinx.

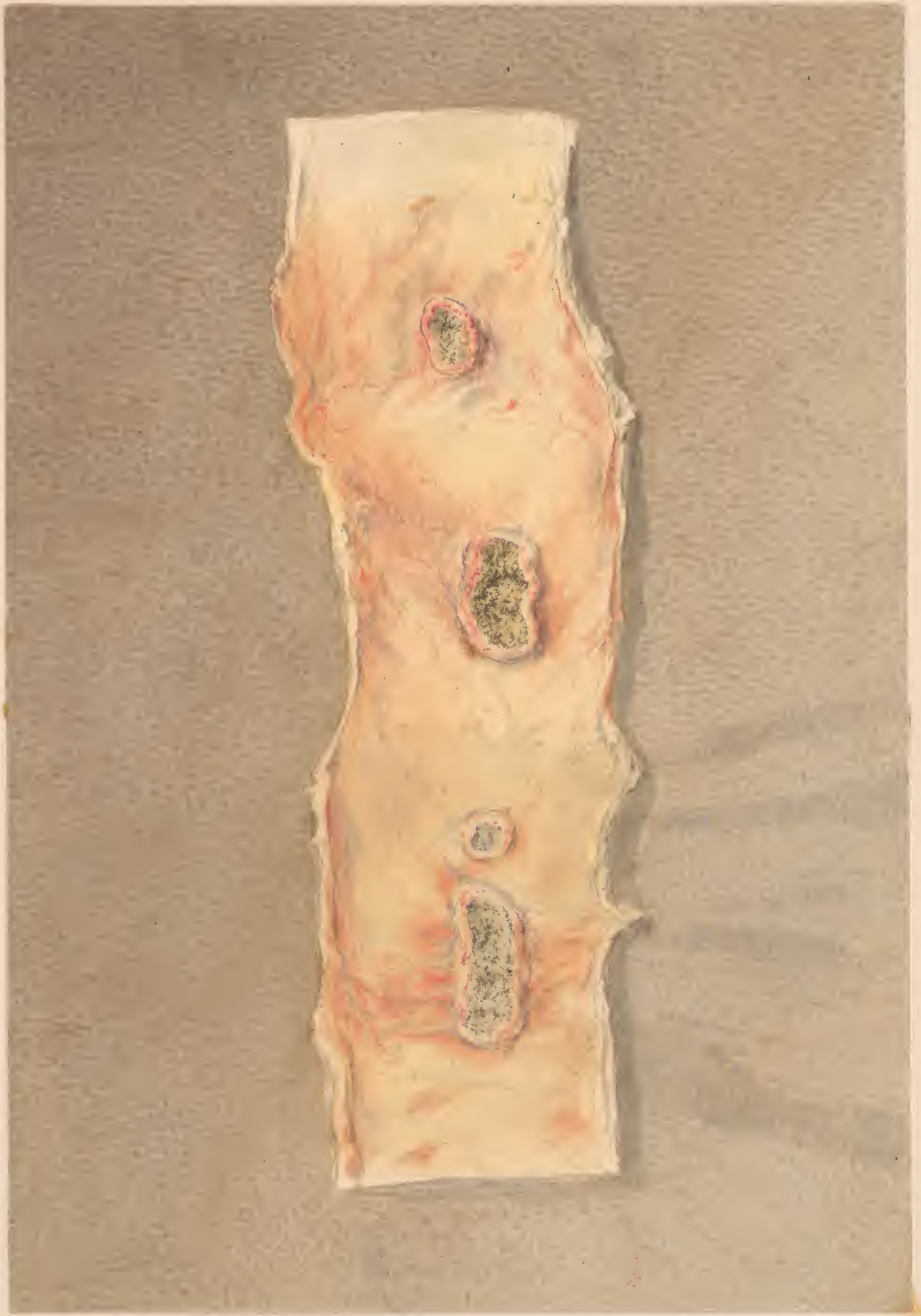J. Meiss del.

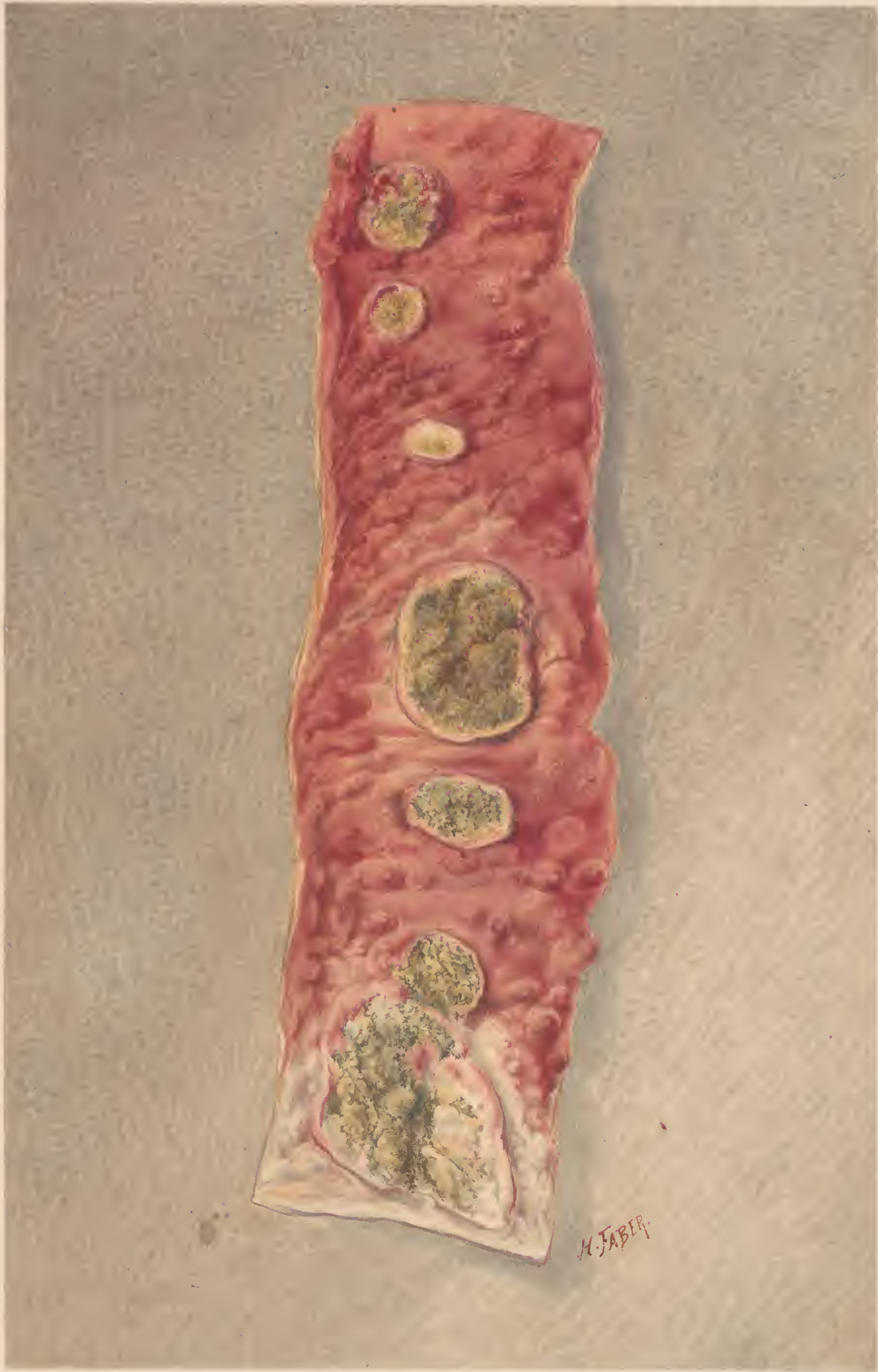ULCERATED PEYER'S PATCH. - FEVER.
taken near the Ileo Coecal valve.

7
544

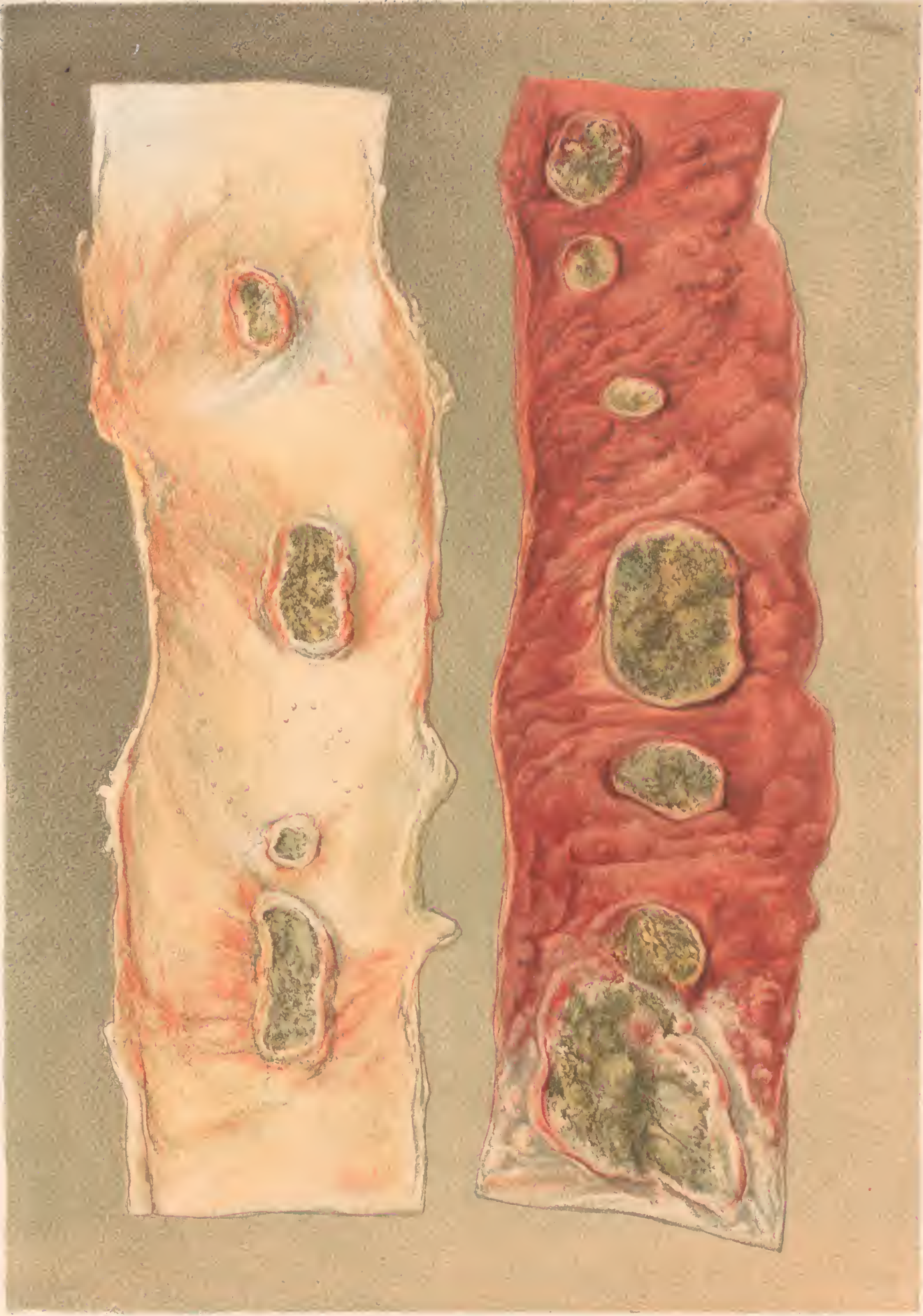


ULCERATED PEYER'S PATCH.- FEVER.
taken near the ileocecal valve.





H. FABER



H. Fisher del.

F. Moras sculp. Philad.

ULCERATED PEYER'S PATCHES.-FEVER.

The left piece from the upper, the right from the lower part of the ileum.

2" of wood 9/10/10

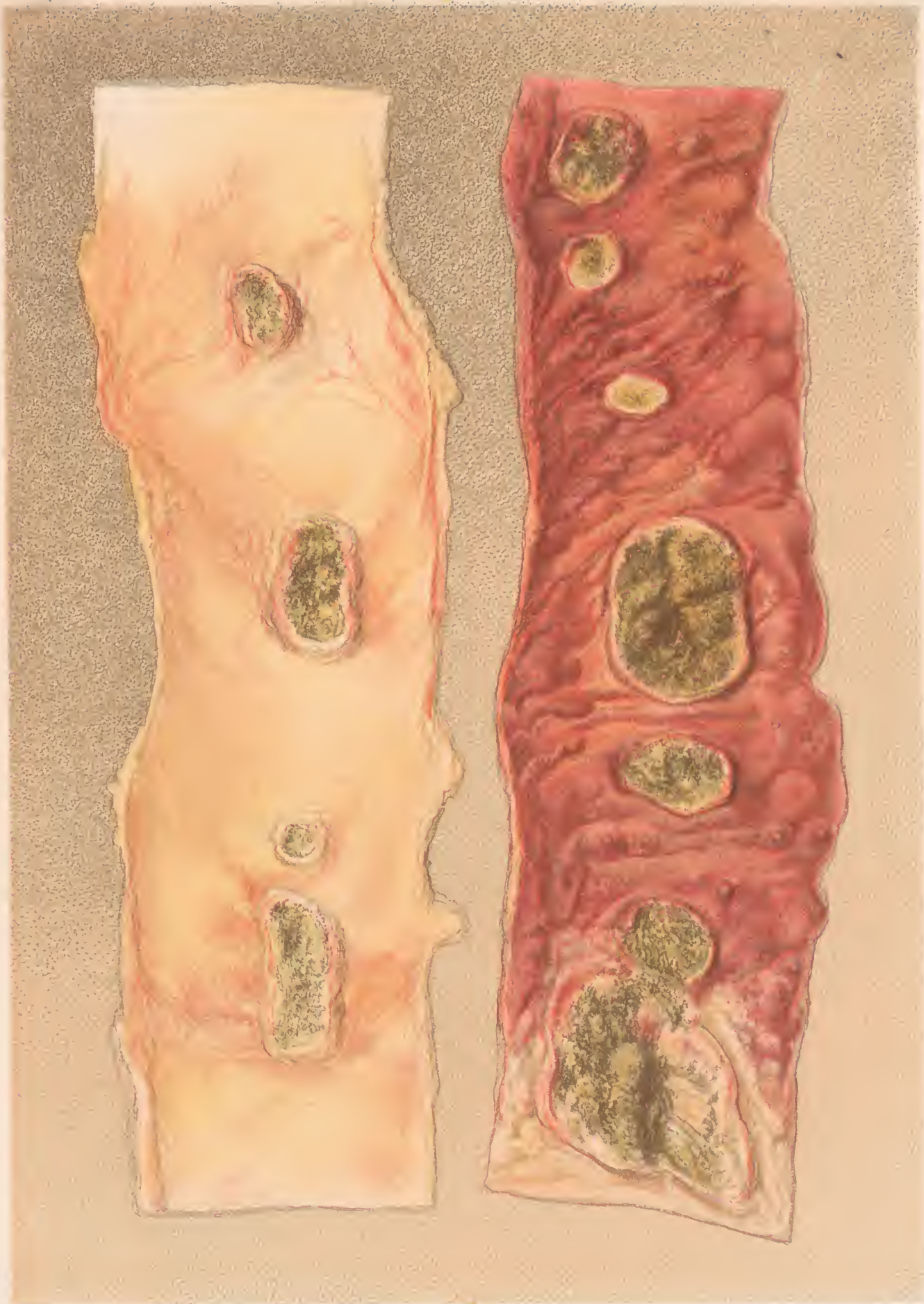
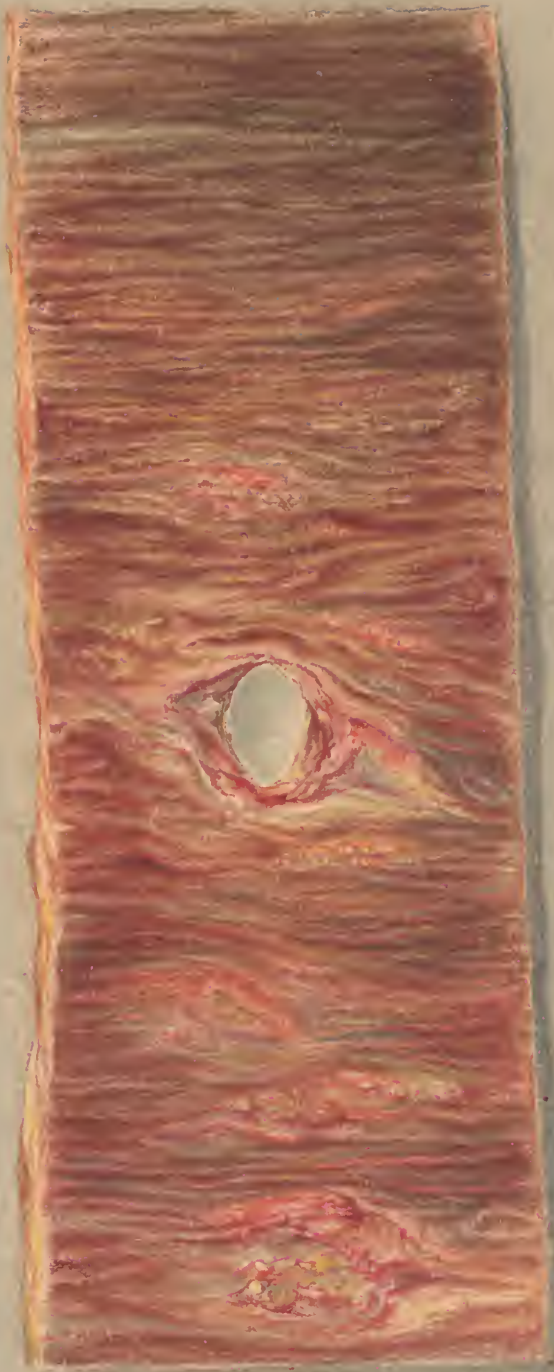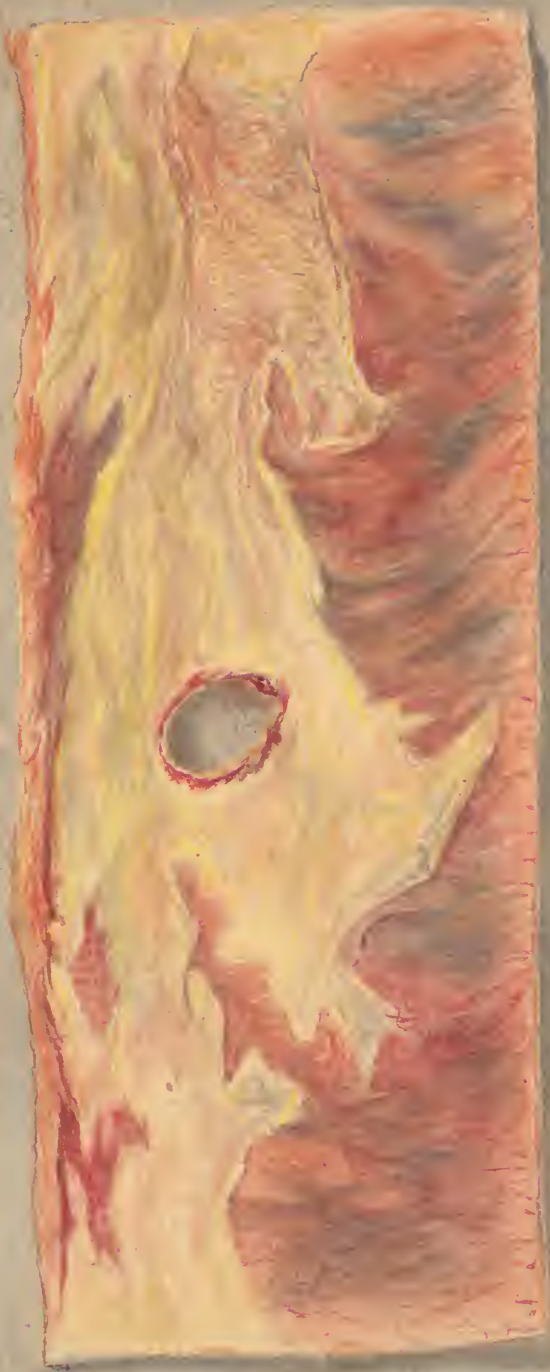


Fig. 100

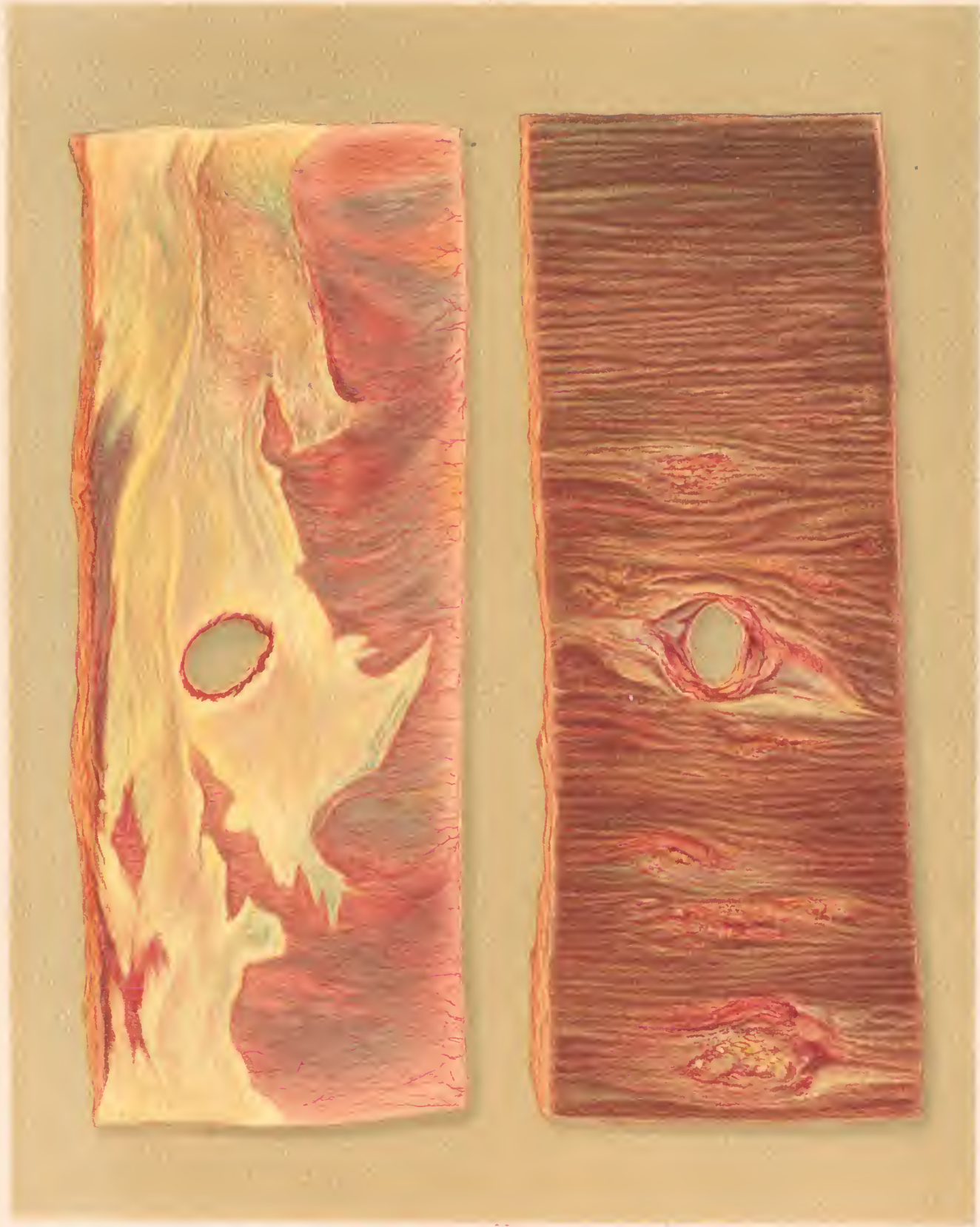Fig. 101

ULCERATED PEYER'S PATCHES IN JEJUNUM

The left piece from the upper five-sixths from the following part of the ileum



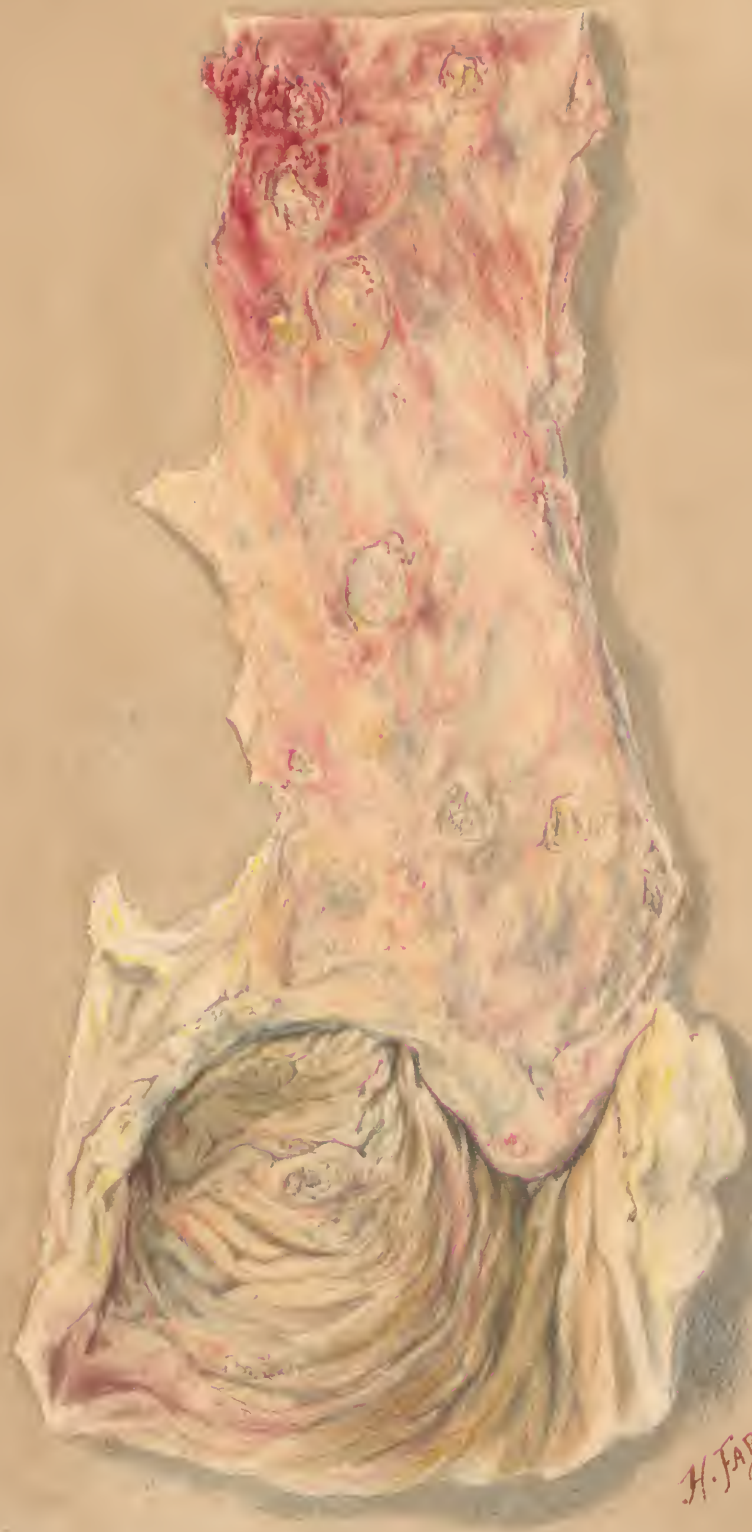11. 10. 1952



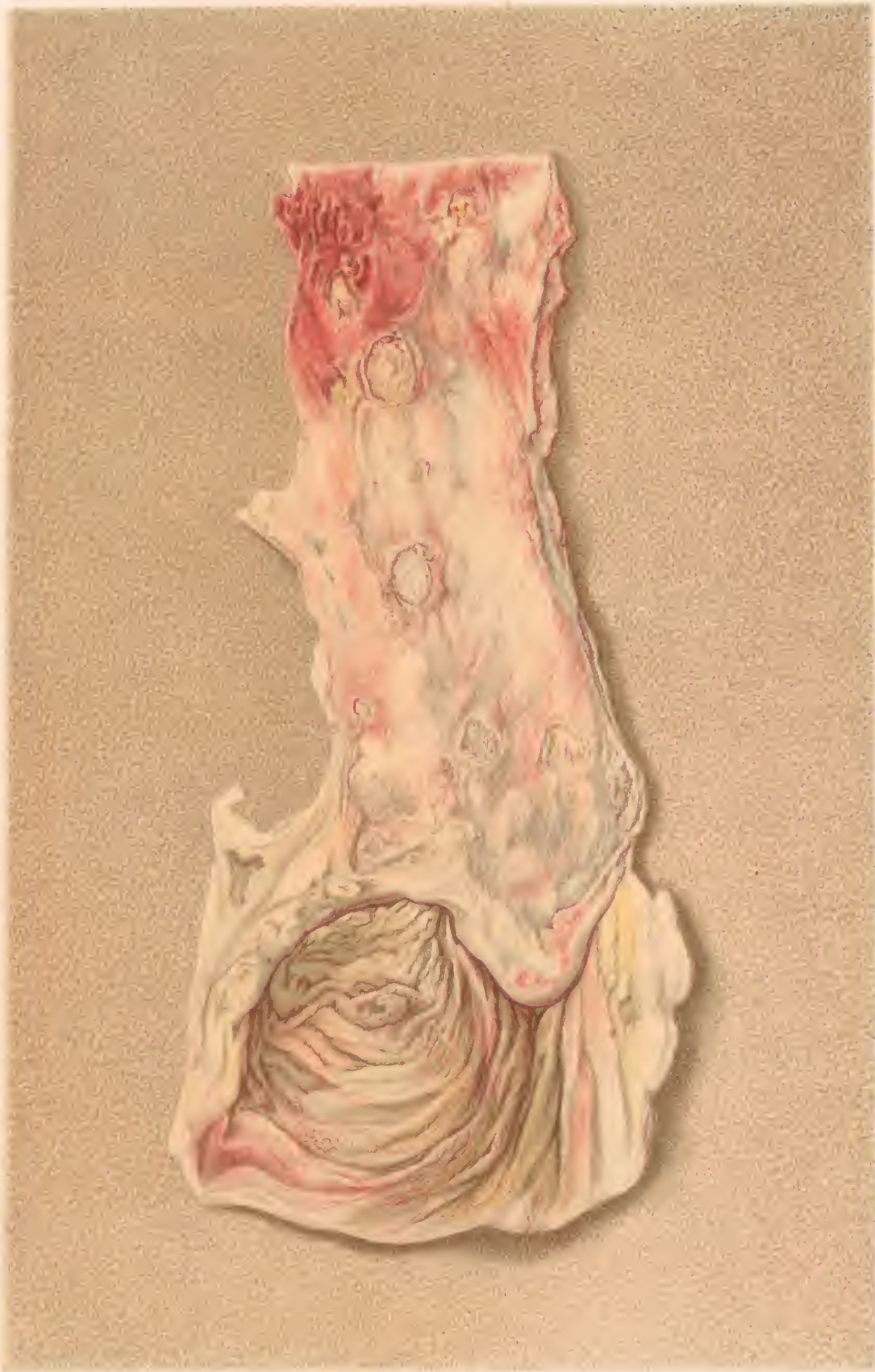H. Faber pinx.

F. Moras chromalum Ph. 3

PERFORATING ULCER OF THE ILEUM.
The right hand piece shows the mucous, the left the peritoneal surface.



H. FABER.
18



ULCERATION OF THE ILEUM AND CAECUM.

