



K. L. Duke

DUKE UNIVERSITY
MEDICAL CENTER LIBRARY
HISTORICAL COLLECTIONS

Gift of

Dr. Kenneth L. Duke

Al... ..

*Dr. Alexander Maclean
Medical College
Augusta Ga*

*... ..
... ..
... ..*

... ..

*... ..
... ..
... ..*

400

22

Mr. L. B. ...

Halcyon Lane
Pa



Erasmus Wilson
1803-1883

A SYSTEM
OF
HUMAN ANATOMY,
GENERAL AND SPECIAL.

BY ERASMUS WILSON, M.D.,

LECTURER ON ANATOMY, LONDON.

M. L. Boyd

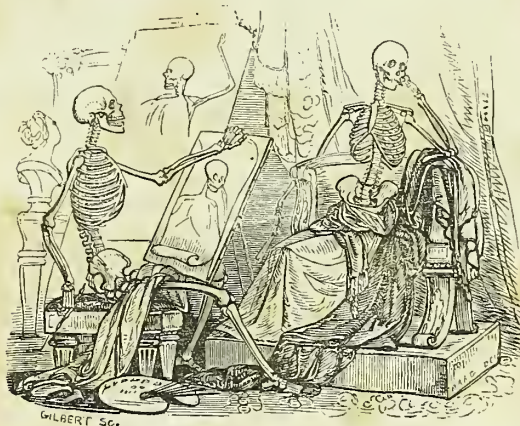
FOURTH AMERICAN

FROM THE LAST LONDON EDITION.

EDITED BY

PAUL B. GODDARD, A.M., M.D.,

PROFESSOR OF ANATOMY AND HISTOLOGY IN THE FRANKLIN MEDICAL COLLEGE
OF PHILADELPHIA.



WITH TWO HUNDRED AND FIFTY-ONE ILLUSTRATIONS
BY GILBERT.

PHILADELPHIA:
BLANCHARD AND LEA.

1852.

Entered, according to Act of Congress, in the year 1848, by

LEA AND BLANCHARD,

in the clerk's office of the District Court of the United States for the
Eastern District of Pennsylvania.

~~~~~  
PRINTED BY C. SHERMAN  
~~~~~

Wm. J. Brodie
Medical College
London

TO

SIR BENJAMIN COLLINS BRODIE, BART., F.R.S.

SERGEANT-SURGEON TO THE QUEEN,
MEMBER OF THE INSTITUTE OF FRANCE,

IN ADMIRATION OF THE HIGH ATTAINMENTS

WHICH HAVE JUSTLY PLACED HIM

W. J. Brodie
IN THE FIRST RANK OF HIS PROFESSION,

Medical College
THIS WORK

IS RESPECTFULLY INSCRIBED

W. J. Brodie
BY

THE AUTHOR.



P R E F A C E .

THE Preface to this little volume may be written in a few words. It first saw the light in the spring of 1840, and now, in the autumn of 1844, has reached its Third Edition. In this short period, less than five years, five thousand copies have been distributed among the Members of the Profession, many also taking their place in the libraries of Gentlemen, who, although not of the Profession, justly consider that some general knowledge of the structure of the body is an essential part of a liberal education. In the same period, a second edition of the work has appeared in America; and a translation, from the pen of Dr. Hollstein, has been completed in Berlin.

Thus the volume has quickly returned for review to the hands of the Author; and he trusts that an examination of the second and present editions will prove that he has not neglected this advantage. He has carefully corrected such oversights and omissions as may have occurred in the completion of a work on so extensive a subject; many parts which seemed scantily treated, he has entirely re-written; and he has endeavoured to give as full a description of every point in Anatomy, whether important or trivial, as is consistent with the limits and objects of a Practical Manual.

Two features in the Anatomist's Vade Mecum appear to the Author to deserve notice:—the first relates to the labours of his professional brethren; the second to the illustrations contained in the work. On the first of these heads the Author begs to remark, that he considers it a duty, as well to them as to his readers and himself, to quote all recent observations and discoveries in Anatomy which may have interest, and to give as complete an abstract of such discoveries as the scheme of the work will permit. By pursuing this plan, the Author trusts to distinguish his volume as the Record of the Profession at large, and not as the text-book merely of a particular school. And, in furtherance of his object, he has

to request a continuance of those communications from scientific investigators, which have hitherto so materially aided him.


The woodcut illustrations which accompany the Anatomist's Vade Mecum have been increased with each edition. Several of the new figures are illustrative of General Anatomy, and, to insure their absolute correctness, have been drawn from the microscope by the Author himself, with the aid of the camera lucida. Figures 13, 14, 15, showing the changes which occur during the development of bone; figures 63-66, the minute anatomy of cartilage; and figure 103, the structure of the ultimate muscular fibril, are examples of such drawings. The structure exhibited in the latter figure formed the subject of a paper which was read before the Royal Society during the present year.

Upper Charlotte Street, Fitzroy Square.

November, 1844.

P R E F A C E

TO THE FOURTH LONDON EDITION.



IN preparing the "ANATOMIST'S VADE MECUM," for the fourth time, for the Press, the Author has availed himself of the discoveries, in Anatomy, which have been made public since the appearance of the preceding edition; and he takes the opportunity, now afforded him, of acknowledging his obligation to the several investigators whose researches he has quoted. To one gentleman, namely, to Mr. PAGET of St. Bartholomew's Hospital, he feels particularly indebted for the assistance which he has derived from the excellent "Reports, on the chief results obtained by the use of the Microscope in the study of Human Anatomy and Physiology," published in the British and Foreign Medical Review.

In the present edition of this volume, the Wood-cut Illustrations have been augmented to two hundred; and the Author begs to observe that with very few exceptions, which have been duly acknowledged, the whole of the subjects are original; the drawings having been executed by Mr. BAGG from dissections prepared expressly for the work, or from drawings made by himself. The chief of the illustrations of General Anatomy were drawn from the microscope with the camera lucida, in order to ensure absolute correctness.

Upper Charlotte Street, Fitzroy Square,
March 1, 1847.



P R E F A C E

TO THE FOURTH AMERICAN EDITION.

~~~~~

THE Editor, in presenting this new edition of Mr. Wilson's standard work on Anatomy, has found but little to add, the author having so completely revised and brought up his last edition; while he has incorporated in the text many of the Editor's notes to former editions.

A small increase in the size of the page has enabled the Publishers to take in the additional matter, while diminishing slightly the number of pages.

The Editor has added some new matter and a large number of new cuts—among others an important series on the nerves—he has rewritten his introductory chapter on Histology; and he has taken every care to ensure, throughout, perfect correctness in the text. He thus hopes that the work will continue to hold the high character which its merits have acquired in this country, and to maintain its position as a standard TEXT BOOK for the student, which it has assumed in so many of our Colleges.

The London edition is still known by the Author's original title of "VADE MECUM;" but the publishers consider themselves sustained in the change they have made, by the fulness and completeness of the work, which amply warrant for it the title of "A SYSTEM OF HUMAN ANATOMY."

P. B. G.

Philadelphia, July, 1848.

(xi)



# CONTENTS.

## CHAPTER I.

### HISTOLOGY.

|                                   | Page |                               | Page |
|-----------------------------------|------|-------------------------------|------|
| Definition .....                  | 33   | Physical properties .....     | 39   |
| Chemistry of the tissues .....    | 33   | Vital properties .....        | 40   |
| Nitrogenized substances .....     | 35   | Development of tissues .....  | 40   |
| Non-nitrogenized substances ..... | 36   | Development of cells .....    | 41   |
| Of the tissues .....              | 37   | Multiplication of cells ..... | 41   |
| Tabular view of the tissues ..... | 37   | Transformation of cells ..... | 42   |
| Description of the tissues .....  | 38   |                               |      |

## CHAPTER II.

### OSTEOLOGY.

|                                    | Page |                                                 | Page |
|------------------------------------|------|-------------------------------------------------|------|
| Definition .....                   | 43   | Parietal bone .....                             | 61   |
| Chemical composition of bone ..... | 43   | Frontal bone .....                              | 62   |
| Division into classes .....        | 43   | Temporal bone .....                             | 64   |
| Structure of bone .....            | 44   | Sphenoid bone .....                             | 69   |
| Development of bone .....          | 46   | Ethmoid bone .....                              | 72   |
| Period of ossification .....       | 48   | Bones of the face .....                         | 74   |
| The skeleton .....                 | 49   | Nasal .....                                     | 74   |
| Vertebral column .....             | 50   | Superior maxillary .....                        | 74   |
| Cervical vertebræ .....            | 50   | Lachrymal bone .....                            | 77   |
| Dorsal vertebræ .....              | 53   | Malar bone .....                                | 77   |
| Lumbar vertebræ .....              | 53   | Palate bone .....                               | 78   |
| General considerations .....       | 54   | Inferior turbinated bone .....                  | 80   |
| Development .....                  | 55   | Vomer .....                                     | 80   |
| Attachment of muscles .....        | 56   | Inferior maxillary .....                        | 81   |
| Sacrum .....                       | 56   | Table of developments, articulations, &c. ..... | 83   |
| Coccyx .....                       | 58   | Sutures .....                                   | 83   |
| The skull .....                    | 58   | Regions of the skull .....                      | 84   |
| Bones of the cranium .....         | 58   | Base of the skull .....                         | 86   |
| Occipital bone .....               | 59   | Face .....                                      | 89   |

|                                  | Page |                                  | Page     |
|----------------------------------|------|----------------------------------|----------|
| Orbits .....                     | 90   | Carpal bones .....               | 109      |
| Nasal fossæ .....                | 90   | Metacarpal bones .....           | 112      |
| Teeth .....                      | 92   | Phalanges .....                  | 113      |
| Structure .....                  | 93   | Pelvis and lower extremity ..... | 114      |
| Development .....                | 95   | Os innominatum .....             | 114      |
| Growth .....                     | 97   | Ilium .....                      | 114      |
| Eruption .....                   | 98   | Ischium .....                    | 115      |
| Succession .....                 | 99   | Os pubis .....                   | 116      |
| Os hyoides .....                 | 99   | Pelvis — Its Divisions—Axes—Dia- |          |
| Thorax and upper extremity ..... | 100  | meters .....                     | 117, 118 |
| Sternum .....                    | 100  | Femur .....                      | 119      |
| Ribs .....                       | 101  | Patella .....                    | 121      |
| Costal cartilages .....          | 102  | Tibia .....                      | 121      |
| Clavicle .....                   | 103  | Fibula .....                     | 122      |
| Scapula .....                    | 103  | Tarsal bones .....               | 124      |
| Humerus .....                    | 105  | Metatarsal bones .....           | 127      |
| Ulna .....                       | 106  | Phalanges .....                  | 128      |
| Radius .....                     | 107  | Sesamoid bones .....             | 129      |

## CHAPTER III.

## THE LIGAMENTS.

|                                               | Page |                                                 | Page |
|-----------------------------------------------|------|-------------------------------------------------|------|
| Forms of articulation .....                   | 130  | Of the ribs with the sternum, and with          |      |
| Synarthrosis .....                            | 130  | each other .....                                | 145  |
| Amphi-artrosis .....                          | 130  | Of the sternum .....                            | 146  |
| Diarthrosis .....                             | 130  | Of the vertebral column, with the               |      |
| Movements of joints .....                     | 131  | pelvis .....                                    | 146  |
| Gliding .....                                 | 131  | Of the pelvis .....                             | 146  |
| Angular movement .....                        | 131  | LIGAMENTS OF THE UPPER EXTREMITY .....          | 149  |
| Circumduction .....                           | 131  | Sterno-clavicular articulation .....            | 149  |
| Rotation .....                                | 132  | Scapulo-clavicular articulation .....           | 151  |
| General anatomy of articular structures ..... | 132  | Ligaments of the scapula .....                  | 151  |
| Cartilage .....                               | 132  | Shoulder joint .....                            | 152  |
| True cartilage .....                          | 132  | Elbow joint .....                               | 152  |
| Reticular cartilage .....                     | 132  | Radio-ulnar articulation .....                  | 153  |
| Fibrous cartilage .....                       | 134  | Wrist joint .....                               | 155  |
| Fibrous tissue .....                          | 134  | Articulations of the carpal bones .....         | 156  |
| Ligament .....                                | 135  | Carpo-metacarpal articulation .....             | 156  |
| Tendon .....                                  | 135  | Metacarpo-phalangeal articulation .....         | 157  |
| Adipose tissue .....                          | 136  | Articulation of the phalanges .....             | 158  |
| Synovial membrane .....                       | 136  | LIGAMENTS OF THE LOWER EXTREMITY .....          | 158  |
| LIGAMENTS OF THE TRUNK—ARRANGE-               |      | Hip joint .....                                 | 158  |
| MENT .....                                    | 137  | Knee joint .....                                | 159  |
| Articulation of the vertebral column .....    | 137  | Articulation between the tibia and fibula ..... | 163  |
| Of the atlas with the occipital bone .....    | 140  | Ankle joint .....                               | 164  |
| Of the axis with the occipital bone .....     | 141  | Articulation of the tarsal bones .....          | 165  |
| Of the atlas with the axis .....              | 141  | Tarso-metatarsal articulation .....             | 167  |
| Of the lower jaw .....                        | 142  | Metatarso-phalangeal articulation .....         | 167  |
| Of the ribs of the vertebræ .....             | 144  | Articulation of the phalanges .....             | 168  |



## CHAPTER IV.

## THE MUSCLES.

|                                                   | Page     | Page                                            |          |
|---------------------------------------------------|----------|-------------------------------------------------|----------|
| General anatomy of muscle . . . . .               | 168      | Stylo-hyoideus—mylo-hyoideus . . . . .          | 189, 190 |
| Nomenclature—Structure . . . . .                  | 169      | Genio-hyoideus—Genio-hyo-glossus—               |          |
| MUSCLES OF THE HEAD AND FACE . . . . .            | 173      | Actions . . . . .                               | 190      |
| Arrangement into groups . . . . .                 | 173      | Muscles of the tongue . . . . .                 | 191      |
| Cranial group—Dissection . . . . .                | 174      | Hyo-glossus—Lingualis . . . . .                 | 191      |
| Occipito-frontalis . . . . .                      | 174      | Stylo-glossus . . . . .                         | 192      |
| Orbital group—Dissection . . . . .                | 175      | Palato-glossus—Actions . . . . .                | 192      |
| Orbicularis palpebrarum . . . . .                 | 175      | Muscles of the pharynx—Dissection . . . . .     | 192      |
| Corrugator supercillii . . . . .                  | 175      | Constrictor inferior . . . . .                  | 192      |
| Tensor tarsi—Actions . . . . .                    | 176      | Constrictor medius—Constrictor super-           |          |
| Ocular group—Dissection . . . . .                 | 176      | rior . . . . .                                  | 193      |
| Levator palpebræ—Rectus superior . . . . .        | 177      | Stylo-pharyngeus—Palato-pharyn-                 |          |
| Rectus inferior—Rectus internus—                  |          | geus—Actions . . . . .                          | 193, 194 |
| Rectus externus . . . . .                         | 177      | Muscles of the soft palate—Dissection . . . . . | 194      |
| Obliquus superior . . . . .                       | 178      | Levator palati—Tensor palati . . . . .          | 194, 195 |
| Obliquus inferior—Actions . . . . .               | 178      | Azygos uvulæ—Palato-glossus . . . . .           | 195      |
| Nasal group . . . . .                             | 179      | Palato-pharyngeus—Actions . . . . .             | 195, 196 |
| Pyramidalis nasi—Compressor nasi . . . . .        | 179      | Prævertebral muscles—Dissection . . . . .       | 196      |
| Dilatator naris—Actions . . . . .                 | 179      | Rectus anticus major—Rectus anticus             |          |
| Superior labial group . . . . .                   | 180      | minor . . . . .                                 | 196      |
| Orbicularis oris—Levator labii superi-            |          | Scalenus anticus . . . . .                      | 196      |
| oris alæque nasi . . . . .                        | 180      | Scalenus posticus—Longus colli . . . . .        | 197      |
| Levator labii superioris proprius . . . . .       | 180      | Actions . . . . .                               | 198      |
| Levator anguli oris—Zygomatichi . . . . .         | 180      | Muscles of the larynx . . . . .                 | 198      |
| Depressor labii superioris alæque nasi . . . . .  | 181      | MUSCLES OF THE TRUNK . . . . .                  | 198      |
| Actions . . . . .                                 | 181      | Muscles of the back—Arrangement . . . . .       | 198      |
| Inferior labial group—Dissection . . . . .        | 181      | First layer—Dissection . . . . .                | 199      |
| Depressor labii inferioris . . . . .              | 181      | Trapezius . . . . .                             | 199      |
| Depressor anguli oris—Levator labii               |          | Latissimus dorsi . . . . .                      | 199      |
| inferioris . . . . .                              | 181, 182 | Second layer—Dissection . . . . .               | 201      |
| Actions . . . . .                                 | 182      | Levator anguli scapulæ . . . . .                | 201      |
| Maxillary group . . . . .                         | 182      | Rhomboides minor et major . . . . .             | 201      |
| Massæter—Temporal muscle . . . . .                | 182      | Third layer—Dissection . . . . .                | 201      |
| Buccinator—External pterygoid mus-                |          | Serratus posticus superior et infe-             |          |
| cle . . . . .                                     | 183      | rior . . . . .                                  | 201, 202 |
| Internal pterygoid muscle . . . . .               | 184      | Splenius capitis et colli . . . . .             | 202      |
| Actions . . . . .                                 | 184      | Fourth layer—Dissection . . . . .               | 202      |
| Auricular group—Dissection . . . . .              | 184      | Sacro-lumbalis—Longissimus dorsi . . . . .      | 203      |
| Attollens aurem . . . . .                         | 184      | Spinalis dorsi . . . . .                        | 203      |
| Attrahens aurem . . . . .                         | 185      | Cervicalis ascendens—Transversa-                |          |
| Retrahens aurem—Actions . . . . .                 | 185      | lis colli . . . . .                             | 204      |
| MUSCLES OF THE NECK . . . . .                     | 185      | Trachelo-mastoideus—Complexus . . . . .         | 204      |
| Arrangement into groups . . . . .                 | 185      | Fifth layer—Dissection . . . . .                | 205      |
| Superficial group—Dissection . . . . .            | 186      | Semi-spinalis dorsi et colli . . . . .          | 205      |
| Platysma myoides . . . . .                        | 186      | Rectus posticus, major et minor . . . . .       | 205      |
| Sterno-cleido-mastoideus . . . . .                | 186      | Rectus lateralis—Obliquus inferior              |          |
| Actions . . . . .                                 | 187      | et superior . . . . .                           | 205      |
| Depressors of the os hyoides and larynx . . . . . | 187      | Sixth layer—Dissection . . . . .                | 205      |
| Dissection . . . . .                              | 188      | Multifidus spinæ—Levatores cos-                 |          |
| Sterno-hyoideus—Sterno-thyroideus . . . . .       | 188      | tarum . . . . .                                 | 206      |
| Thyro-hyoideus—Omo-hyoideus . . . . .             | 188      | Supra-spinalis—Inter-spinales . . . . .         | 206      |
| Actions . . . . .                                 | 189      | Inter-transversales . . . . .                   | 206      |
| Elevators of the os hyoides . . . . .             | 189      | Actions . . . . .                               | 207      |
| Dissection . . . . .                              | 189      | Table of origins and insertions of the          |          |
| Digastricus . . . . .                             | 189      | muscles of the back . . . . .                   | 208, 209 |

|                                              | Page     |                                                | Page     |
|----------------------------------------------|----------|------------------------------------------------|----------|
| Muscles of the thorax . . . . .              | 210      | Extensor carpi ulnaris—Anconeus . . . . .      | 236      |
| Intercostales externi et interni . . . . .   | 210      | Deep layer—Dissection . . . . .                | 236, 237 |
| Triangularis sterni—Actions . . . . .        | 211      | Supinator brevis . . . . .                     | 237      |
| Muscles of the abdomen . . . . .             | 211      | Extensor ossis metacarpi pollicis . . . . .    | 237      |
| Dissection . . . . .                         | 211      | Extensor primi internodii pollicis . . . . .   | 237      |
| Obliquus externus . . . . .                  | 212      | Extensor secundi internodii pollicis . . . . . | 237      |
| Obliquus internus . . . . .                  | 214      | Extensor indicis—Actions . . . . .             | 238      |
| Cremaster . . . . .                          | 214      | Muscles of the hand . . . . .                  | 238      |
| Transversalis . . . . .                      | 215      | Radial region—Dissection . . . . .             | 238      |
| Rectus . . . . .                             | 216      | Ulnar region—Dissection . . . . .              | 239, 240 |
| Pyramidalis—Quadratus lumborum . . . . .     | 216      | Palmar region . . . . .                        | 240      |
| Psoas parvus . . . . .                       | 216      | Actions . . . . .                              | 242      |
| Diaphragm . . . . .                          | 217      | MUSCLES OF THE LOWER EXTREMITY. . . . .        | 242      |
| Actions . . . . .                            | 218      | Gluteal region—Dissection . . . . .            | 243      |
| Muscles of the perineum . . . . .            | 219      | Gluteus maximus et medius . . . . .            | 244      |
| Dissection . . . . .                         | 219      | Gluteus minimus . . . . .                      | 245      |
| Acceleratores urinæ . . . . .                | 220      | Pyriformis . . . . .                           | 245      |
| Erector penis . . . . .                      | 220      | Gemellus superior—Obturator inter-             | 245      |
| Compressor urethræ . . . . .                 | 220      | nus . . . . .                                  | 245      |
| Transversus perinei . . . . .                | 221      | Gemellus inferior—Obturator exte-              | 246      |
| Sphincter ani externus et internus . . . . . | 222      | nus . . . . .                                  | 246      |
| Levator ani—Coccygeus . . . . .              | 222      | Quadratus femoris—Actions . . . . .            | 246      |
| Muscles of the female perineum . . . . .     | 222      | Anterior femoral region—Dissection . . . . .   | 246      |
| MUSCLES OF THE UPPER EXTREMITY. . . . .      | 223      | Tensor vaginæ femoris—Sartorius . . . . .      | 247      |
| Anterior thoracic region . . . . .           | 224      | Rectus—Vastus externus . . . . .               | 248      |
| Dissection . . . . .                         | 225      | Vastus internus—Crureus—Actions . . . . .      | 248      |
| Pectoralis major et minor . . . . .          | 225      | Internal femoral region—Dissection . . . . .   | 249      |
| Subclavius—Actions . . . . .                 | 226      | Iliacus internus . . . . .                     | 249      |
| Lateral thoracic region . . . . .            | 226      | Psoas magnus—Pectineus—Adduc-                  | 249, 250 |
| Serratus magnus—Actions . . . . .            | 226      | tor longus . . . . .                           | 249, 250 |
| Anterior scapular region . . . . .           | 226      | Adductor brevis—Adductor magnus                | 251      |
| Subscapularis . . . . .                      | 226      | —Gracilis . . . . .                            | 250, 251 |
| Actions . . . . .                            | 227      | Actions . . . . .                              | 251      |
| Posterior scapular region . . . . .          | 227      | Posterior femoral region—Dissection . . . . .  | 251      |
| Supra-spinatus—Infra-spinatus . . . . .      | 227      | Biceps femoris . . . . .                       | 251      |
| Teres minor—Teres major . . . . .            | 227, 228 | Semi-tendinosus—Semi-membranosus               | 251, 252 |
| Actions . . . . .                            | 228      | —Actions . . . . .                             | 251, 252 |
| Acromial region . . . . .                    | 228      | Anterior tibial region . . . . .               | 253      |
| Deltoid—Actions . . . . .                    | 228      | Dissection . . . . .                           | 253      |
| Anterior humeral region—Dissection . . . . . | 229      | Tibialis anticus . . . . .                     | 253      |
| Coraco-brachialis—Biceps . . . . .           | 229      | Extensor longus digitorum . . . . .            | 253      |
| Brachialis anticus—Actions . . . . .         | 230      | Peroneus tertius—Extensor proprius             | 254      |
| Posterior humeral region . . . . .           | 230      | pollicis . . . . .                             | 254      |
| Triceps—Actions . . . . .                    | 231      | Actions . . . . .                              | 254      |
| Anterior brachial region . . . . .           | 231      | Posterior tibial region . . . . .              | 254      |
| Superficial layer—Dissection . . . . .       | 231      | Superficial group—Dissection . . . . .         | 254      |
| Pronator radii teres . . . . .               | 231      | Gastrocnemius . . . . .                        | 255      |
| Flexor carpi radialis . . . . .              | 232      | Plantaris—Solcus—Actions . . . . .             | 255      |
| Palmaris longus . . . . .                    | 232      | Deep layer—Dissection . . . . .                | 255      |
| Flexor sublimis digitorum . . . . .          | 232      | Popliteus—Flexor longus pollicis . . . . .     | 256      |
| Flexor carpi ulnaris . . . . .               | 233      | Flexor longus digitorum . . . . .              | 256      |
| Deep layer—Dissection . . . . .              | 233      | Tibialis posticus . . . . .                    | 257      |
| Flexor profundus digitorum . . . . .         | 233      | Actions . . . . .                              | 257      |
| Flexor longus pollicis . . . . .             | 233      | Fibular region—Dissection . . . . .            | 257      |
| Pronator quadratus—Actions . . . . .         | 234      | Peroneus longus—Peroneus brevis                | 258      |
| Posterior brachial region . . . . .          | 234      | Actions . . . . .                              | 258      |
| Superficial layer—Dissection . . . . .       | 234      | Foot—Dorsal region . . . . .                   | 258      |
| Supinator longus . . . . .                   | 234      | Plantar region . . . . .                       | 259      |
| Extensor carpi radialis longior . . . . .    | 235      | First layer—Dissection . . . . .               | 259      |
| Extensor carpi radialis brevior . . . . .    | 235      | Second layer—Dissection . . . . .              | 261      |
| Extensor communis digitorum . . . . .        | 235      | Third layer—Dissection . . . . .               | 261      |
| Extensor minimi digiti . . . . .             | 236      | Fourth layer—Actions . . . . .                 | 262      |

## CHAPTER V.

## THE FASCIÆ.

|                                       | Page |                                         | Page |
|---------------------------------------|------|-----------------------------------------|------|
| General anatomy . . . . .             | 263  | Fascia iliaca . . . . .                 | 268  |
| FASCIÆ OF THE HEAD AND NECK . . . . . | 264  | Fascia pelvica . . . . .                | 268  |
| Temporal fascia . . . . .             | 264  | Obturator fascia . . . . .              | 269  |
| Cervical fascia . . . . .             | 264  | Superficial perineal fascia . . . . .   | 269  |
| FASCIÆ OF THE TRUNK . . . . .         | 265  | Deep perineal fascia . . . . .          | 269  |
| Thoracic fascia . . . . .             | 265  | FASCIÆ OF THE UPPER EXTREMITY . . . . . | 271  |
| Abdominal fascia . . . . .            | 266  | FASCIÆ OF THE LOWER EXTREMITY . . . . . | 272  |
| Fascia transversalis . . . . .        | 266  | Fascia lata . . . . .                   | 272  |
| Oblique inguinal hernia . . . . .     | 266  | Femoral hernia . . . . .                | 273  |
| Congenital hernia . . . . .           | 267  | Fascia of the leg . . . . .             | 274  |
| Encysted hernia . . . . .             | 267  | Plantar fascia . . . . .                | 274  |
| Direct inguinal hernia . . . . .      | 268  |                                         |      |

## CHAPTER VI.

## THE ARTERIES.

|                                       | Page     |                                                                     | Page |
|---------------------------------------|----------|---------------------------------------------------------------------|------|
| General anatomy of arteries . . . . . | 275      | Profundis cervicis . . . . .                                        | 299  |
| Inosculation—Structure . . . . .      | 276, 277 | Superior intercostal artery—Internal<br>mammary; branches . . . . . | 299  |
| Aorta . . . . .                       | 278      | Axillary artery . . . . .                                           | 300  |
| Table of branches . . . . .           | 281      | Table of branches . . . . .                                         | 301  |
| Coronary arteries . . . . .           | 281      | Brachial artery . . . . .                                           | 303  |
| Arteria innominata . . . . .          | 281      | Radial artery . . . . .                                             | 304  |
| Common carotid arteries . . . . .     | 282      | Ulnar artery . . . . .                                              | 306  |
| External carotid artery . . . . .     | 283      | Thoracic aorta; branches . . . . .                                  | 308  |
| Table of branches . . . . .           | 284      | Abdominal aorta; branches . . . . .                                 | 309  |
| Superior thyroid artery . . . . .     | 284      | Phrenic arteries . . . . .                                          | 309  |
| Lingual artery . . . . .              | 285      | Cœliac axis . . . . .                                               | 310  |
| Facial artery . . . . .               | 285      | Gastric artery . . . . .                                            | 310  |
| Mastoid artery . . . . .              | 287      | Hepatic artery . . . . .                                            | 310  |
| Occipital artery . . . . .            | 287      | Splenic artery . . . . .                                            | 311  |
| Posterior auricular artery . . . . .  | 287      | Superior mesenteric artery . . . . .                                | 312  |
| Ascending pharyngeal artery . . . . . | 287      | Spermatic arteries . . . . .                                        | 314  |
| Parotidean arteries . . . . .         | 287      | Inferior mesenteric artery . . . . .                                | 315  |
| Transverse facial artery . . . . .    | 287      | Renal arteries . . . . .                                            | 315  |
| Temporal artery . . . . .             | 288      | Lumbar arteries . . . . .                                           | 315  |
| Internal maxillary . . . . .          | 288      | Sacra media . . . . .                                               | 316  |
| Internal carotid artery . . . . .     | 291      | Common iliac arteries . . . . .                                     | 316  |
| Ophthalmic artery . . . . .           | 292      | Internal iliac artery . . . . .                                     | 317  |
| Anterior cerebral artery . . . . .    | 293      | Ischiatic . . . . .                                                 | 318  |
| Middle cerebral artery . . . . .      | 294      | Internal pudic artery . . . . .                                     | 318  |
| Subclavian artery . . . . .           | 294      | External iliac artery . . . . .                                     | 321  |
| Table of branches . . . . .           | 296      | Femoral artery . . . . .                                            | 323  |
| Vertebral artery . . . . .            | 296      | Popliteal artery . . . . .                                          | 326  |
| Basilar artery . . . . .              | 296      | Anterior tibial artery . . . . .                                    | 328  |
| Circle of Willis . . . . .            | 297      | Dorsalis pedis artery . . . . .                                     | 329  |
| Thyroid axis . . . . .                | 298      | Posterior tibial artery . . . . .                                   | 330  |
| Inferior thyroid artery . . . . .     | 298      | Peroneal artery . . . . .                                           | 331  |
| Supra-scapular artery . . . . .       | 298      | Plantar arteries . . . . .                                          | 332  |
| Posterior scapular . . . . .          | 299      | Pulmonary artery . . . . .                                          | 334  |
| Superficialis cervicis . . . . .      | 299      |                                                                     |      |

## CHAPTER VII.

### THE VEINS.

|                               | Page |                            | Page |
|-------------------------------|------|----------------------------|------|
| General anatomy               | 334  | Venæ innominatæ            | 345  |
| Veins of the head and neck    | 336  | Superior vena cava         | 345  |
| Veins of the diploë           | 337  | Iliac veins                | 345  |
| Cerebral and cerebellar veins | 338  | Inferior vena cava         | 346  |
| Sinuses of the dura mater     | 338  | Azygos veins               | 348  |
| Veins of the neck             | 341  | Vertebral and spinal veins | 348  |
| Veins of the upper extremity  | 342  | Cardiac veins              | 349  |
| Veins of the lower extremity  | 344  | Portal system              | 349  |
| Veins of the trunk            | 344  | Pulmonary veins            | 351  |

## CHAPTER VIII.

### THE LYMPHATICS.

|                                   | Page |                           | Page |
|-----------------------------------|------|---------------------------|------|
| General anatomy                   | 351  | Lymphatics of the viscera | 357  |
| Lymphatics of the head and neck   | 353  | Lacteals                  | 358  |
| Lymphatics of the upper extremity | 354  | Thoracic duct             | 359  |
| Lymphatics of the lower extremity | 355  | Ductus lymphaticus dexter | 360  |
| Lymphatics of the trunk           | 356  |                           |      |

## CHAPTER IX.

### THE NERVOUS SYSTEM.

|                                  | Page |                                | Page |
|----------------------------------|------|--------------------------------|------|
| General anatomy                  | 361  | Medulla oblongata              | 385  |
| The brain                        | 367  | Diverging fibres               | 386  |
| Membranes of the encephalon      | 368  | Converging fibres; commissures | 388  |
| Dura mater                       | 369  | Spinal cord                    | 389  |
| Arachnoid membrane               | 370  | Cranial nerves                 | 392  |
| Pia mater                        | 371  | Spinal nerves                  | 409  |
| Cerebrum                         | 372  | Cervical plexus                | 411  |
| Lateral ventricles               | 373  | Brachial plexus                | 414  |
| Fifth ventricle                  | 376  | Dorsal nerves                  | 420  |
| Fornix                           | 378  | Lumbar nerves                  | 422  |
| Thalami optici                   | 378  | Sacral nerves                  | 426  |
| Third ventricle                  | 378  | Sympathetic system             | 433  |
| Corpora quadrigemina             | 379  | Cranial ganglia                | 433  |
| Pineal gland                     | 379  | Cervical ganglia               | 437  |
| Fourth ventricle                 | 380  | Thoracic ganglia               | 440  |
| Lining membrane of the ventricle | 380  | Lumbar ganglia                 | 441  |
| Cerebellum                       | 381  | Sacral ganglia                 | 442  |
| Base of the brain                | 382  |                                |      |

CHAPTER X.

ORGANS OF SENSE.

|                                                | Page |                                        | Page |
|------------------------------------------------|------|----------------------------------------|------|
| Nose . . . . .                                 | 442  | Organ of hearing— <i>continued.</i>    |      |
| Nasal fossæ . . . . .                          | 444  | Tympañum . . . . .                     | 458  |
| Eyeball . . . . .                              | 445  | Ossiculi auditûs . . . . .             | 458  |
| Sclerotic coat and cornea . . . . .            | 445  | Muscles of the tympanum . . . . .      | 459  |
| Choroid coat; ciliary ligament; iris . . . . . | 447  | Internal ear . . . . .                 | 461  |
| Retina; zonula ciliaris . . . . .              | 449  | Vestibule . . . . .                    | 462  |
| Humours . . . . .                              | 451  | Semicircular canals—Cochlea . . . . .  | 463  |
| Physiological observations . . . . .           | 452  | Membranous labyrinth . . . . .         | 465  |
| Appendages of the eye . . . . .                | 453  | Organ of taste—Tongue . . . . .        | 467  |
| Lachrymal apparatus . . . . .                  | 455  | Organ of touch—Skin . . . . .          | 468  |
| Organ of hearing . . . . .                     | 456  | Appendages of the skin—Nails . . . . . | 472  |
| External ear; pinna . . . . .                  | 456  | Hairs—Sebiparous glands . . . . .      | 474  |
| Meatus auditorius . . . . .                    | 457  | Sudoriparous glands . . . . .          | 474  |

CHAPTER XI.

THE VISCERA.

|                                             | Page |                                         | Page |
|---------------------------------------------|------|-----------------------------------------|------|
| THORAX . . . . .                            | 475  | ABDOMEN— <i>continued.</i>              |      |
| Heart . . . . .                             | 475  | Liver . . . . .                         | 515  |
| Structure of the heart . . . . .            | 482  | Gall-bladder . . . . .                  | 525  |
| Organs of respiration and voice . . . . .   | 485  | Pancreas . . . . .                      | 526  |
| Larynx—Cartilages . . . . .                 | 485  | Spleen . . . . .                        | 526  |
| Ligaments . . . . .                         | 486  | Supra-renal capsules . . . . .          | 527  |
| Muscles . . . . .                           | 488  | Kidneys . . . . .                       | 528  |
| Trachea and Bronchi . . . . .               | 491  | PELVIS . . . . .                        | 532  |
| Thyroid gland . . . . .                     | 492  | Bladder . . . . .                       | 532  |
| Lungs . . . . .                             | 492  | Prostate gland . . . . .                | 534  |
| Pleuræ . . . . .                            | 495  | Vesiculæ seminales . . . . .            | 535  |
| Mediastinum . . . . .                       | 496  | MALE ORGANS OF GENERATION . . . . .     | 536  |
| ABDOMEN—Regions . . . . .                   | 496  | Penis . . . . .                         | 536  |
| Peritoneum . . . . .                        | 497  | Urethra . . . . .                       | 537  |
| Alimentary canal . . . . .                  | 501  | Testes . . . . .                        | 541  |
| Lips—Cheeks—Gums—Palate . . . . .           | 502  | FEMALE PELVIS . . . . .                 | 544  |
| Tonsils—Fauces . . . . .                    | 503  | Bladder—Urethra . . . . .               | 544  |
| Salivary glands . . . . .                   | 503  | Vagina . . . . .                        | 545  |
| Pharynx . . . . .                           | 504  | Uterus . . . . .                        | 546  |
| Stomach . . . . .                           | 505  | Fallopian tubes . . . . .               | 549  |
| Small intestine . . . . .                   | 506  | Ovaries . . . . .                       | 549  |
| Large intestine . . . . .                   | 507  | External organs of generation . . . . . | 550  |
| Structure of the intestinal canal . . . . . | 509  | MAMMARY GLANDS . . . . .                | 551  |

CHAPTER XII.

ANATOMY OF THE FŒTUS.

|                                          | Page |                                            | Page |
|------------------------------------------|------|--------------------------------------------|------|
| Osseous and ligamentous system . . . . . | 553  | Fœtal lungs . . . . .                      | 558  |
| Muscular system . . . . .                | 553  | Fœtal heart . . . . .                      | 559  |
| Vascular system . . . . .                | 553  | Viscera of the abdomen . . . . .           | 559  |
| Fœtal circulation . . . . .              | 553  | Omphalo-mesenteric vessels . . . . .       | 559  |
| Nervous system . . . . .                 | 555  | Fœtal liver . . . . .                      | 560  |
| Organs of Sense—Eye—Ear—Nose . . . . .   | 555  | Kidneys and supra-renal capsules . . . . . | 560  |
| Thyroid gland . . . . .                  | 556  | Viscera of the pelvis . . . . .            | 560  |
| Thymus gland . . . . .                   | 556  | Testes—Descent . . . . .                   | 560  |



## TABLE OF ILLUSTRATIONS.

| Figs.                                  | Page | Figs.                                              | Page |
|----------------------------------------|------|----------------------------------------------------|------|
| 1. Vegetable nucleated cells.....      | 37   | 46. Capsule of temporary incisor.....              | 97   |
| 2. Growth of cells.....                | 41   | 47. Temporary tooth with capsule of permanent..... | 98   |
| 3. Reproduction of cells.....          | 41   | 48. Os hyoides.....                                | 99   |
| 4. Implantation of cells.....          | 41   | 49. Thorax.....                                    | 101  |
| 5. Transformation of cells.....        | 42   | 50. Scapula.....                                   | 104  |
| 6. } Changes in formative ccls of      |      | 51. Humerus.....                                   | 106  |
| 7. } an animal.....                    | 42   | 52. Ulna and radius.....                           | 108  |
| 8. } .....                             |      | 53. Bones of the carpus; posterior view            | 109  |
| 9. Id. of a vegetable.....             | 42   | 54. Hand; anterior view.....                       | 111  |
| 10. Formation of fibres.....           | 42   | 55. Os innominatum.....                            | 114  |
| 11. Minute structure of bone.....      | 44   | 56. Female pelvis; anterior view...                | 117  |
| 12. Id. id. id.....                    | 45   | 57. Femur; anterior view.....                      | 119  |
| 13. Development of bone.....           | 47   | 58. Femur; posterior view.....                     | 120  |
| 14. Id. id. ....                       | 47   | 59. Tibia and fibula; anterior view...             | 122  |
| 15. Id. id. ....                       | 47   | 60. Tibia and fibula; posterior view..             | 123  |
| 16. Cervical vertebra.....             | 51   | 61. Foot; dorsal surface.....                      | 125  |
| 17. Atlas.....                         | 51   | 62. Foot; plantar surface.....                     | 128  |
| 18. Axis.....                          | 52   | 63. Articular cartilage.....                       | 132  |
| 19. Dorsal vertebra.....               | 53   | 64. Id. id. ....                                   | 132  |
| 20. Lumbar vertebra.....               | 53   | 65. Id. id. ....                                   | 133  |
| 21. Sacrum.....                        | 57   | 66. Reticular cartilage.....                       | 133  |
| 22. Occipital bone—External surface.   | 59   | 67. Fibrous cartilage.....                         | 133  |
| 23. Occipital bone—Internal surface..  | 60   | 68. White fibrous tissue.....                      | 134  |
| 24. Parietal bone—External surface..   | 61   | 69. Yellow fibrous tissue.....                     | 135  |
| 25. Parietal bone—Internal surface..   | 62   | 70. Adipose tissue.....                            | 136  |
| 26. Frontal bone—External surface..... | 63   | 71. Epithelium of serous membrane..                | 137  |
| 27. Frontal bone—Internal surface...   | 63   | 72. Ligaments of the vertebræ and ribs;            |      |
| 28. Temporal bone—External surface.    | 64   | anterior view.....                                 | 138  |
| 29. Temporal bone—Internal surface.    | 66   | 73. Posterior common ligament.....                 | 138  |
| 30. Meatus auditorius externus and in- |      | 74. Ligamenta subflava.....                        | 139  |
| ternus, and tympanic bone.....         | 66   | 75. Ligaments of the atlas, axis, and              |      |
| 31. Spheroid bone—Superior surface.    | 69   | occipital bone.....                                | 140  |
| 32. Sphenoid bone—Antero-inferior      |      | 76. Id.; posterior view.....                       | 140  |
| surface.....                           | 70   | 77. Id.; internal view.....                        | 141  |
| 33. Ethmoid bone.....                  | 73   | 78. Id.; internal view.....                        | 142  |
| 34. Superior maxillary bone.....       | 74   | 79. Ligaments of the lower jaw; ex-                |      |
| 35. Lachrymal bone.....                | 77   | ternal view.....                                   | 143  |
| 36. Palate bone—Internal surface....   | 78   | 80. Id.; internal view.....                        | 143  |
| 37. Palate bone—External surface...    | 79   | 81. Id; section.....                               | 144  |
| 38. Inferior maxillary bone.....       | 82   | 82. Ligaments of the vertebral column              |      |
| 39. Skull, anterior view.....          | 85   | and ribs.....                                      | 145  |
| 40. Base of the skull; internal view.. | 85   | 83. Ligaments of the pelvis and hip joint          | 148  |
| 41. Base of the skull; external view.. | 87   | 84. Id. id. id....                                 | 148  |
| 42. Nasal fossa with the turbinated    |      | 85. Ligaments of the sternal end of the            |      |
| bones.....                             | 91   | clavicle and costal cartilages....                 | 150  |
| 43. Permanent teeth.....               | 92   | 86. Ligaments of the scapula and                   |      |
| 44. Temporary teeth.....               | 93   | shoulder joint.....                                | 151  |
| 45. Section of molar tooth.....        | 94   |                                                    |      |

| Figs.                                                                      | Page | Figs.                                                                                                                    | Page |
|----------------------------------------------------------------------------|------|--------------------------------------------------------------------------------------------------------------------------|------|
| 87. Ligaments of the elbow; internal view.....                             | 153  | 134. Muscles of the posterior tibial region, deep layer.....                                                             | 256  |
| 88. Id.; external view.....                                                | 153  | 135. Dorsal interossii.....                                                                                              | 259  |
| 89. Id.; radio-ulnar articulation.....                                     | 154  | 136. Muscles of the sole of the foot; 1st layer.....                                                                     | 259  |
| 90. Ligaments of the wrist and hand.....                                   | 155  | 137. Muscles of the sole of the foot; 2d layer.....                                                                      | 260  |
| 91. Synovial membranes of the wrist.....                                   | 157  | 138. Deep-seated muscles.....                                                                                            | 261  |
| 92. Knee joint; anterior view.....                                         | 160  | 139. Plantar interossii.....                                                                                             | 263  |
| 93. Id.; posterior view.....                                               | 161  | 140. Section of the neck, showing the distribution of the deep cervical fascia.....                                      | 265  |
| 94. Knee joint; internal view.....                                         | 161  | 141. Transverse section of the pelvis, showing the distribution of the fasciæ.....                                       | 269  |
| 95. Id.; reflexions of the synovial membrane.....                          | 162  | 142. Deep perineal fascia.....                                                                                           | 270  |
| 96. Ankle joint; internal view.....                                        | 164  | 143. Distribution of the deep perineal fascia; side view.....                                                            | 270  |
| 97. Id.; external view.....                                                | 164  | 144. Distribution of the fasciæ at the femoral arch.....                                                                 | 273  |
| 98. Id.; posterior view.....                                               | 166  | 145. The great vessels of the chest....                                                                                  | 278  |
| 99. Ligaments of the sole of the foot.....                                 | 167  | 146. Branches of the external carotid artery.....                                                                        | 284  |
| 100. Minute structure of muscle.....                                       | 170  | 147. External carotid.....                                                                                               | 289  |
| 101. Id. id.....                                                           | 170  | 148. Branches of the subclavian artery.....                                                                              | 296  |
| 102. Id. id.....                                                           | 171  | 149. The circle of Willis.....                                                                                           | 298  |
| 103. Id. id.....                                                           | 171  | 150. Axillary and brachial arteries....                                                                                  | 301  |
| 104. Id. id.....                                                           | 172  | 151. Arteries of the fore-arm—Radial and ulnar.....                                                                      | 304  |
| 105. Muscles of the face.....                                              | 174  | 152. Branches of the abdominal aorta..                                                                                   | 310  |
| 106. Tensor tarsi.....                                                     | 176  | 153. Cœliac axis with its branches....                                                                                   | 312  |
| 107. Muscles of the orbit.....                                             | 176  | 154. The superior mesenteric artery...                                                                                   | 313  |
| 108. Pterygoid muscles.....                                                | 184  | 155. The inferior mesenteric artery....                                                                                  | 314  |
| 109. Muscles of the neck; superficial and deep.....                        | 186  | 156. The internal iliac artery with its branches.....                                                                    | 317  |
| 110. Muscles of the tongue.....                                            | 191  | 157. The arteries of the perineum....                                                                                    | 319  |
| 111. Muscles of the pharynx.....                                           | 194  | 158. The femoral artery with its branches                                                                                | 323  |
| 112. Muscles of the soft palate.....                                       | 195  | 159. The anterior tibial artery.....                                                                                     | 328  |
| 113. Muscles of the prævertebral region                                    | 197  | 160. Posterior tibial and peroneal artery                                                                                | 330  |
| 114. Muscles of the back; 1st, 2d, and 3d layer.....                       | 200  | 161. Arteries of the sole of the foot....                                                                                | 332  |
| 115. Muscles of the back; deep layer..                                     | 203  | 162. Sinuses of the dura mater.....                                                                                      | 339  |
| 116. Muscles of the anterior aspect of the trunk.....                      | 213  | 163. Sinuses of the base of the skull...                                                                                 | 340  |
| 117. Muscles of the lateral aspect of the trunk.....                       | 215  | 164. Veins and nerves of the bend of the elbow.....                                                                      | 342  |
| 118. Diaphragm.....                                                        | 218  | 165. Veins of the trunk and neck....                                                                                     | 346  |
| 119. Muscles of the perineum.....                                          | 221  | 166. The portal vein.....                                                                                                | 350  |
| 120. Muscles of the anterior humeral region.....                           | 229  | 167. The thoracic duct.....                                                                                              | 360  |
| 121. Triceps extensor eubiti.....                                          | 230  | 168. Minute structure of nerve.....                                                                                      | 363  |
| 122. Superficial layer of muscles of the anterior aspect of the fore-arm.. | 231  | 169. The centrum ovale majus and corpus callosum.....                                                                    | 373  |
| 123. Deep layer of muscles of the anterior aspect of the fore-arm.....     | 234  | 170. The lateral ventricles of the cerebrum.....                                                                         | 374  |
| 124. Superficial layer of muscles; posterior aspect of the fore-arm.....   | 235  | 171. Longitudinal section of the brain..                                                                                 | 377  |
| 125. Deep layer; posterior aspect of the fore-arm.....                     | 237  | 172. Base of the brain.....                                                                                              | 384  |
| 126. Muscles of the hand, anterior aspect                                  | 239  | 173. Distribution of the fibres of the brain                                                                             | 387  |
| 127. Palmar interossei.....                                                | 241  | 174. Sections of the spinal marrow....                                                                                   | 391  |
| 128. Dorsal interossei.....                                                | 241  | 175. Sections of the spinal cord.....                                                                                    | 392  |
| 129. Muscles of the gluteal region, deep layer.....                        | 244  | 176. The olfactory nerve.....                                                                                            | 393  |
| 130. Muscles of the anterior and internal femoral region.....              | 247  | 177. Origin of the optic and fourth nerves                                                                               | 394  |
| 131. Muscles of the gluteal and posterior femoral region.....              | 252  | 178. The isthmus encephali, showing the thalamus opticus, corpora quadrigemina, pons Varolii, and medulla oblongata..... | 394  |
| 132. Muscles of the anterior tibial region.....                            | 253  |                                                                                                                          |      |
| 133. Muscles of the posterior tibial region.....                           | 255  |                                                                                                                          |      |



| Figs.                                                                              | Page | Figs.                                                                    | Page |
|------------------------------------------------------------------------------------|------|--------------------------------------------------------------------------|------|
| 179. Third, 4th, and 5th pair of nerves                                            | 396  | 213. Anatomy of the heart, left side . .                                 | 482  |
| 180. Trifacial or fifth nerve . . . . .                                            | 397  | 214. Ligaments of the larynx . . . . .                                   | 487  |
| 181. Portio mollis of 7th pair . . . . .                                           | 401  | 215. Muscles of the larynx . . . . .                                     | 488  |
| 182. Facial and cervical nerves . . . . .                                          | 403  | 216. Id. id. . . . .                                                     | 489  |
| 183. Eighth pair of nerves . . . . .                                               | 406  | 217. Anatomy of the lungs and heart . .                                  | 493  |
| 184. Hypoglossal or ninth nerve . . . . .                                          | 408  | 218. Viscera of abdomen . . . . .                                        | 497  |
| 185. Part of the cervical portion of the<br>spinal cord . . . . .                  | 410  | 219. The peritoneum . . . . .                                            | 498  |
| 186. Axillary plexus and nerves of the<br>upper extremity . . . . .                | 414  | 220. The pharynx . . . . .                                               | 505  |
| 187. Nerves of front of fore-arm . . . . .                                         | 417  | 221. Anatomy of the stomach and duo-<br>denum . . . . .                  | 506  |
| 188. Nerves of back of fore-arm . . . . .                                          | 418  | 222. Cæcum and appendix . . . . .                                        | 508  |
| 189. Lumbar and sacral plexus, with the<br>nerves of the lower extremity . . . . . | 422  | 223. Section of anus . . . . .                                           | 510  |
| 190. Anterior crural nerve . . . . .                                               | 424  | 224. Peyer's glands . . . . .                                            | 513  |
| 191. Branches of ischiatic plexus . . . . .                                        | 427  | 225. Section of parietes of anus . . . . .                               | 514  |
| 192. id. popliteal nerve . . . . .                                                 | 430  | 226. The liver; its upper surface . . . . .                              | 516  |
| 193. Posterior tibial nerve . . . . .                                              | 430  | 227. The liver; its under surface . . . . .                              | 517  |
| 194. Nerves of sole of foot . . . . .                                              | 431  | 228. Lobules of the liver . . . . .                                      | 519  |
| 195. Anterior tibial nerve . . . . .                                               | 432  | 229. Id. id. . . . .                                                     | 519  |
| 196. The cranial ganglia of the sympa-<br>thetic nerve . . . . .                   | 434  | 230. Section of superficial lobules . . . . .                            | 520  |
| 197. Great sympathetic . . . . .                                                   | 439  | 231. Id. id. . . . .                                                     | 521  |
| 198. Fibro-cartilages of the nose . . . . .                                        | 443  | 232. Section of the kidney . . . . .                                     | 529  |
| 199. Longitudinal section of the globe<br>of the eye . . . . .                     | 446  | 233. Plan of the renal circulation . . . . .                             | 531  |
| 200. Venæ vorticossæ of choroid coat . . . . .                                     | 448  | 234. A side view of the viscera of the<br>male pelvis . . . . .          | 533  |
| 201. A transverse section of the globe of<br>the eye . . . . .                     | 449  | 235. A posterior view of the bladder and<br>vesiculæ seminales . . . . . | 535  |
| 202. Another transverse section of the<br>globe of the eye . . . . .               | 449  | 236. Anatomy of the urethra . . . . .                                    | 538  |
| 203. Auxiliary parts of eye . . . . .                                              | 453  | 237. Prostatic urethra . . . . .                                         | 539  |
| 204. A diagram of the ear . . . . .                                                | 458  | 238. Transverse section of the testicle . .                              | 541  |
| 205. Anatomy of the cochlea . . . . .                                              | 464  | 239. Anatomy of the testis . . . . .                                     | 543  |
| 206. Osseous and membranous labyrinth<br>of the ear . . . . .                      | 464  | 240. Injected testis . . . . .                                           | 544  |
| 207. Papillæ of tongue . . . . .                                                   | 467  | 241. A side view of the viscera of the<br>female pelvis . . . . .        | 545  |
| 208. Anatomy of the skin . . . . .                                                 | 469  | 242. Uterus and Fallopian tubes . . . . .                                | 546  |
| 209. Development of epidermis . . . . .                                            | 470  | 243. Section of uterus . . . . .                                         | 547  |
| 210. Anatomy of the skin . . . . .                                                 | 473  | 244. Female external organs of genera-<br>tion . . . . .                 | 550  |
| 211. The heart . . . . .                                                           | 476  | 245. Fœtal circulation . . . . .                                         | 554  |
| 212. Anatomy of the heart, right side . .                                          | 478  | 246. Section of the thymus gland . . . . .                               | 557  |
|                                                                                    |      | 247. Ducts of the thymus gland . . . . .                                 | 557  |
|                                                                                    |      | 248-9. Descent of the testis in the fœtus                                | 561  |



## SYSTEM OF HUMAN ANATOMY.

## CHAPTER I.

## INTRODUCTORY.

BY THE EDITOR.

ANATOMY (derived from *ανατεμνειν*, to dissect) is the science which teaches the structure and relation of the different parts of an organized body. Organized bodies are divided into animal and vegetable; hence we have animal and vegetable anatomy, the latter being closely allied to botany.

An organized body consists of an assemblage of parts called *organs*, which have a mutual relation to, and dependence upon each other; each doing its part to sustain the organism which they compose. The description of the form, colour and position of these organs is the province of *special anatomy*; whilst their relations to each other, and the knowledge of the number and arrangement of organs in particular parts, constitutes regional or topographical anatomy, which, when taught with reference to surgical operations, is usually designated by the title of *surgical anatomy*. When these organs are carefully examined, they are found to consist of a number of different structures which serve to build up and constitute them. These are called *tissues*, and are either *general*, existing in all the organs, or *special* and peculiar, and found only in certain of them, giving them their appropriate characters. The knowledge of tissues, their form, colours, constituents, origin and uses, constitutes *histology*; which, commencing with Bichât in 1790, has now attained such an extent and importance as to constitute almost a new science, and to correct and bring nearer to perfection the hypotheses of its sister science, *physiology*.

An animal body or organism consists of *solids*, which differ in density and hardness, in consequence of being more or less mingled with and diluted by the *fluids* which permeate them.

By the agency of *chemistry* we may separate both *solids* and *fluids* into proximate and ultimate elements, and hope by this means to obtain a more intimate acquaintance with their structure and use; but if this is done with the masses as is usual in chemical analyses, and not upon the tissues separated from each other by the aid of the microscope, it will confer upon us about as much real and useful information, as the analysis which a scientific but witty English chemist once made of a whole mouse.

The principal ultimate elements of an animal body obtained by the processes of chemical analysis are—

Oxygen, hydrogen, carbon, and nitrogen, which form almost the whole bulk of the fluids and soft *solids*; but to these must be added a number

of others, which, although they exist in smaller proportions, still form important constituents of peculiar tissues. Thus we find—

*Lime*, or its base, *calcium*, combined with the carbonic or phosphoric acids, in the bones and teeth.

*Magnesia*, in the sebaceous matter of the skin.

*Alumina*, in the enamel of the teeth ;

And *iron*, in the black pigment in various parts.

The additional elements thus brought into the organism may be enumerated as follows:

*Metallic bases of earths*.—*Calcium, magnesium, silicium, aluminium.*

*Metallic bases of alkalis*.—*Potassium, sodium.*

*Phosphorus, sulphur, chlorine, and fluorine.*

*Metals*.—*Iron, manganese, titanium, arsenic, and copper.*

Almost all of these elements exist compounded in either the binary or ternary form.

The binary compounds are—

*Water*, found universally consisting of HO.

*Carbonic acid*, found in blood, urine, sweat.

*Carbonates, or salts of carbonic acid* :—

*Carbonate of soda*, in serum, bile, mucus, sweat, saliva, tears, cartilage, &c.

*Carbonate of ammonia*, in the amniotic liquor, probably derived from the urine of the fœtus.

*Carbonate of lime*, in cartilage, bone, and the teeth.

*Carbonate of magnesia*, in the sebaceous matter of the skin.

*Salts of phosphoric acid* :—

*Phosphate of soda*, in serum, saliva, sweat, bones, muscles, &c.

*Phosphate of lime*, in bones, teeth, cartilage, and the sandy concretions of the pineal gland.

*Phosphate of soda and ammonia*, in urine and blood ; but probably only for the purpose of being excreted or thrown off as unfit to constitute a part of an animal body.

*Phosphate of iron*, in blood, gastric juice, and urine.

*Chlorine and its compounds* :—

*Hydrochloric acid*, in gastric juice, and in the fluid of the cæcum.

*Chloride of sodium*, in blood, brain, muscle, bone, cartilage, dentine, and pigment.

*Chloride of potassium*, in blood, gastric juice, milk, saliva.

*Chloride of ammonium*, in sweat, gastric juice.

*Chloride of calcium*, in gastric juice.

*Sulphuric acid and its compounds* :—

*Sulphate of potassa*, in urine, gastric juice, and cartilage.

*Sulphate of soda*, in sweat, bile, and cartilage.

*Sulphate of lime*, in bile, hair, and cuticle.

*Sulpho-cyanide of potassa*, in the saliva.

*Fluoride of calcium*, in the enamel.

*Silica and oxide of manganese*, in the hair.

*Alumina*, in the enamel.

*Oxide of iron*, in blood, black pigment, lens, and hair.

*Oxide of titanium*, in the capsulæ renales.

*Ammonia* and *cyanogen* only exist in excreted liquids, and consequently do not appear fit to form any part of an organism, one consisting of NH and the other of CH; their elements may only have united for the purpose of finding a ready exit from the body through the emunctories.

Chemistry and physiology have both failed to detect the mode in which the elements of an animal body form themselves into the ternary and quaternary compounds which are found or supposed to exist in them, and much confusion and uncertainty still prevail in regard to their composition and the part they play in the animal organization. Almost all of these compounds contain nitrogen, in addition to the carbon, oxygen and hydrogen found in them; and some of them are exactly alike in their elementary chemical constitution, although differing in a remarkable manner in their sensible characteristics. Those ternary or quaternary compounds which contain nitrogen are prone to rapid putrescence, and have received the generic name of *nitrogenized substances*.

I. NITROGENIZED SUBSTANCES.—Perhaps the best mode of explaining these compounds is to admit the existence of PROTEIN, which is described by *Mulder*, and is so called because, itself a primary substance, it originates so many dissimilar substances. It consists of  $C_{40}H_{31}N_5O_{12}$ . By imagining it to unite with small proportions of either sulphur or phosphorus, or both, it may be said to form a number of nitrogenized bodies. When in the moist state, protein is said to be gelatinous, and when dried, brittle, and of a brownish colour. It is inodorous and tasteless, insoluble in water, alcohol, or ether, but easily dissolved by all the acids in a dilute state.

The substances formed by it are—

1st. *Albumen* ( $Pr_{10} + PS_2$ ). This substance is exceedingly common in the animal economy, and a good example of it is presented in the white of an egg, which is nearly pure albumen. It forms an admirable *matrix* or *blastema* for the generation of cells, and the consequent formation of tissues. When dry, albumen is solid, brittle, and of an amber yellow colour. It is soluble in water, coagulable by heat, alcohol and acids, and forms insoluble compounds with tannin, sugar of lead, and corrosive sublimate.

Very nearly resembling albumen in many of its properties is—

2d. *Fibrin* ( $Pr_{10} + PS$ ). This, however, possesses the power of coagulating, when removed from the body of a living animal, in from three to seven minutes, into a delicate rete or net-work. It is most readily obtained from blood, where it exists in solution, by whisking it with a bundle of twigs, which hastens its coagulation, and causes it to adhere to the twigs. When well washed with running water it presents a semi-solid condition, a dull yellowish colour, and scarcely an appreciable odour. Fibrin, in a coagulated state, forms almost the whole bulk of the muscles.

3d. *Casein* ( $Pr_{10} + S$ ). This substance is abundantly found in milk, and constitutes, when dried, cheese. It is soluble in water, and coagulated by alcohol, acids, and the stomach of any of the mammalia. Be-

sides forming a constituent of milk, casein is found in blood, saliva, bile, and the lens of the eye.

4th. *Pepsin*. This substance was discovered by Schwann, and analysed by Vogel, who found it to be composed of  $C_{48} H_{32} N_8 O_{10}$ . It is so much like albumen that it is difficult to discover a distinction between them. It is found in the gastric glands.

5th. *Globulin* ( $Pr_{15} + S$ ) exists in the blood corpuscles; very like albumen.

6th. *Spermatin* is found in semen; probably fibrin, altered and filled with living forms.

7th. *Mucus* consists of globules floating in a clear fluid, the constitution of each being different.

8th. *Keratin* ( $Pr S_2$ ). The product of the analysis of hair, cuticle, &c.

9th. *Salivin*. Found only in the saliva.

Besides the protein compounds thus enumerated, we have the extractive matter, obtained by either water or alcohol from muscular flesh.

The watery extract is called *osmazome*, is highly volatile, gives the taste and odour to soups and roast meats, and is no doubt a product of the treatment of the meat, or a new combination of the animal elements occurring during the effort to procure it.

*Gelatine* is another substance obtained from portions of the animal body, and differs according to the tissue which furnishes it. Thus tendons, ligaments and bone furnish *colla*, or glue, which consists of  $C_{52} H_{40} N_8 O_{20}$ ; whilst the cartilages and the cornea furnish *chondrin*, the composition of which is  $N_{32} H_{26} N_4 O_{14}$ .

*Hematin* is found in  $C_{44} H_{22} N_3 O_6$  united with a little iron, which is not essential to its composition or existence.

A number of principles have been described as existing in the hepatic secretion or bile, but much research is yet necessary to clear up the confusion which exist in writings with regard to them. They may be enumerated:—*Bilin*, *fellinic acid*, *cholinic acid*, *taurin*, *dyslysin*, *cholepyrrhin*, *biliphain*, *biliverdin*, *bilifulvin*, *cholesterin*, *oleate*, *mangarate*, and *stearate of soda*, *chloride of sodium*, *sulphate*, *phosphate*, and *lactate of soda*, and *phosphate of lime*.

*Urea* and *uric acid*, found in the urine, should not be considered as constituent parts of an animal, but as elements combined in a particular way for the purpose of being excreted.

II. The NON-NITROGENIZED COMPOUNDS, found in the bodies or secretions of animals, are not numerous. When milk is dried, two-fifths of its solid contents consist of a peculiar sugar, called *saccharum lactis*, and composed of  $C_5 H_4 O_4 + HO$ . It crystallizes in four-sided prisms, and has a *sp. gr* of 1.543.

It also contains an acid called *lactic* ( $C_6 H_5 O_5$ ), common in all the fluids and secretions of the body, and united in them with either potash soda, ammonia, lime, or magnesia.

*Fat* consists of cells held together by areolar tissue and vessels, and is found by the chemists to contain *glycerin*, *stearic acid*, *margaric acid*, and *elaic acid*, all of which are destitute of nitrogen.

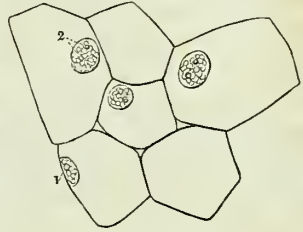
The solidity of the fat of an animal depends upon the proportion of the above ingredients; thus, when *stearic acid* preponderates, the fat is solid, and when *elaic*, fluid.

## OF THE TISSUES.

The solids of an animal body have been divided into *tissues*, any one of which presents the same characteristics, no matter in what portion of the body it is found. The tissues may be further divided into *simple* and *compound* tissues; meaning by *compound* those which consist of two or more simple or elementary tissues mixed together in a definite and regular manner. As an instance of this we may mention fibro-cartilage, which consists of a net-work of white fibrous tissue, having its meshes or interstices filled up by a cartilaginous deposit.

The simplest form of animal organism is the nucleated corpuscle or cell, which is a little vesicle or bag, containing a fluid in its early stage, and a granular body called a nucleus, attached to some portion of the cell wall. This nucleus occasionally presents one or two distinct corpuscles in its substance, which when found are called nucleoli, and which possibly are the germs of new cells.

Fig. 1.\*



Every portion of the animal organism is formed by these cells, and as the body is undergoing constant reproduction and decay, they are found in various stages of development at any time in the life of an animal.

## DIVISION OF THE TISSUES.

The animal organism may be divided into *simple*, or non-metamorphosed forms, and *compound*, or metamorphosed forms of animal matter.

They are presented in the following tabular form:

## 1. SIMPLE FORMS:—

- |                     |   |                                                               |
|---------------------|---|---------------------------------------------------------------|
| 1. Nucleated cells, | { | 1. <i>Formative</i> , producing solids ( <i>durable</i> ).    |
|                     |   | 2. <i>Secreting</i> , producing fluids ( <i>evanescent</i> ). |
| 2. Corpuscles,      | { | 1. Of the blood,                                              |
|                     |   | 2. Of the lymph,                                              |
|                     |   | 3. Of the chyle.                                              |

## 2. COMPOUND FORMS:—

Tissues produced by the metamorphosis of cells. They are divided into simple and compound tissues.

*Simple Tissues:*

- |                                                     |   |                           |
|-----------------------------------------------------|---|---------------------------|
| 1. Epithelial tissue, presenting several varieties. | { | 1. Simple membrane,       |
|                                                     |   | 2. Pigmentary membrane,   |
|                                                     |   | 3. Tesselated epithelium, |
|                                                     |   | 4. Cylindroid epithelium, |
|                                                     |   | 5. Ciliated epithelium,   |
|                                                     |   | 6. Aggregated epithelium. |
| 2. White fibrous tissue ( <i>inelastic</i> ).       |   |                           |
| 3. Yellow fibrous tissue ( <i>elastic</i> ).        |   |                           |

\* A group of vegetable cells. 1. Nucleus. 2. Nucleoli in nucleus.

4. Cartilaginous tissue.
5. Osseous tissue.
6. Petrous tissue.

*Compound Tissues :*

1. Muscular fibrous tissue, } 1. Striped muscular fibre,
2. Nerve-fibrous tissue. } 2. Unstriped muscular fibre.

*Binary Tissues, formed of two simple tissues :*

1. Areolar tissue, constituted by the white and yellow fibrous tissues intermixed.
2. Fibro-cartilage, constituted by cartilage and white fibrous tissue intermixed.

A certain difference exists between the simple corpuscles and nucleated cells. The corpuscles of the blood, for instance (in the *mammalia*), are destitute of a nucleus, and are persistent; whereas a nucleated cell is always in a state of progression, either producing a fluid or undergoing a transformation.

The 1st variety of epithelium is found where there is a necessity for transparency, as in the capsule of the lens and the posterior layer of the cornea. The membrane in this case may be produced by the development of a very large cell and the collapse of its walls, so as to cover the whole area, thus constituting a duplicate lamina.

The 2d variety is formed of hexagonal plates, adhering to each other and containing a form of carbon; it is found in the eye, in the lung, and mixed with the cuticle and hair of the negro.

The 3d variety constitutes the free surface of many membranes, as the skin, the mucous and serous; it may be found in a single lamina, forming a pavement of nucleated cells, flattened and adhering by their edges; or it may form superimposed laminae, the exterior of which is constantly peeling off, and the interior as constantly reproducing new cells to keep up the covering. This is the case in the cuticle, and in the mucous membranes of the mouth, œsophagus, rectum, &c.

The 4th variety exists in mucous membranes, and consists of conoidal nucleated cells, very firmly paved together.

The 5th variety differs only from the last in having the base furnished with vibratile ciliæ, which diffuse the secretion, moistening the surface by their constant motion. This kind of epithelium occurs in mucous and serous membranes, where the surfaces cannot come together and rub against each other, as in the ventricles of the brain, the trachea, &c.

Nails, hairs, and horny excrescences, are manifestly modifications of epithelium, and are hence included in the enumeration as constituting the sixth variety of that tissue.

The *White fibrous tissue* exists in ligaments and tendons, and constitutes the principal part of the derm or *cutis vera*. It is inelastic and inextensible.

The *Yellow fibrous tissue* is found in the *ligamenta flava* of the spine, in the middle coat of the arterial system, and in the skin, mixed with the white fibrous element.

The *Cartilaginous tissue* constitutes the cartilage of the ribs, and the



articular coverings for the ends of the bones. It is also found existing transitorily in the process of *osteo-genesis*.

The *Osseous tissue* constitutes the skeleton, and, with some modification, the ivory of the teeth or dentine.

The *Petrous tissue* presents the extreme of departure from the animal organization, consisting almost entirely of crystals, which are chiefly composed of phosphate of lime. It is found in the enamel of the teeth, in the *otoconites*, and in the concretions of the pineal gland.

The *Muscular fibrous tissue* constitutes the apparatus of motion, and is divided into two distinct varieties,—*striped*, or the muscular fibre of animal life; and *unstriped*, or the muscular fibre of organic life:—the former acting in obedience to the will, and the latter being wholly independent of it.

The *Nerve fibre* is the conducting portion of the nervous system, and is like the muscular compound, being formed of two distinct substances, the one containing and the other contained.

The *Binary tissues* are merely the intermixture or co-existence of two elementary tissues, the proportions of which vary according to the exigencies of the part of the body in which they are found.

The grey or vesicular nervous matter consists of secreting cells, which disappear and are reproduced.

Adipose tissue consists also of secreting cells, which retain their contents under certain circumstances for a great length of time, while under others they rapidly disappear.

The vascular, mucous, and serous tissues of older writers, consist of aggregations of areolar, muscular, and epithelial tissues, variously modified.

#### PROPERTIES OF THE TISSUES.

The CHEMICAL PROPERTIES have been given in the early portion of this chapter.

#### PHYSICAL PROPERTIES OF THE TISSUES.

The tissues, like other forms of matter, possess certain physical properties, such as colour, consistency, and density, which it is necessary to describe under their respective heads. One property, however, is enjoyed by every tissue, and this seems to play a most important part in the maintenance of the functions of life. I allude to the transudation of the solids by the fluids, which is known by the title of *endosmosis* and *exosmosis*, names by which the process was designated by Dutrochet, its discoverer. All the tissues contain a certain quantity of water, and in some cases this amounts to four-fifths of their weight, as may be proved by drying them; and this water is essential, not only to their vitality, but confers upon them their organic properties—pliability and elasticity. As the tissues imbibe water in certain quantity, it becomes a subject of study to discover the manner by which the quantity may be increased. It is well understood how pressure from without would produce this effect, but even this would be aided by the natural tendency to imbibe and retain an additional quantity of water under favourable circumstances, which is strongly exhibited by the softer tissues. Such a tissue saturated with water placed in contact with another tissue or a fluid having a higher affinity for water than it has, will part with its superabundance, and if not supplied from behind will

even part with a portion of that which is essential to its normal condition. If, however, it is supplied from the other side, it will continue to supply the imbibing fluid and receive more from behind. Thus a current will be established from the water on one side of the tissue to the fluid having a high affinity for it on the other; but this is not all: for the fluid alluded to, not content with absorbing all the water which the animal tissue supplies it with, in its turn transudes the tissue to get at and mix with the water on the other side, and thus a counter-current is set up in an opposite direction, which is slower, however, than the former one. These are the currents which are termed endosmotic and exosmotic, and which continue until the difference between the two liquids ceases, and they are equally saturated by each other.

#### VITAL PROPERTIES.

The most prominent vital property possessed by the tissues is the power of assimilation, or of appropriating to themselves such of the organizable substances presented to them as may suit their purposes. This power is supposed to be partly due to chemical affinity, and partly to *vital affinity*. It is most probable, however, that future researches will prove that the power of assimilating is subject to the ordinary chemical laws, but under modifying circumstances, which can only exist in a living body or tissue.

To this may be added the power of reproducing, in its appropriate place, a new portion of a tissue, when injured or destroyed.

Another property which is essentially vital is contractility—a phenomenon which is made manifest by the visible shrinking or contraction of a living tissue when irritated, either by mechanical or chemical stimuli. The muscular tissue exhibits this property in the highest degree. This contractility must be distinguished from the permanent contraction or crispation which a part suffers when exposed to a high temperature.

A third vital property is sensibility, which, however, requires that the tissues shall be united so as to form a continuous line from the part manifesting it to the brain. This property is enjoyed in very different degrees by the different tissues, and constitutes an important distinction between them, depending upon the presence and number of nerve-fibres mixed with the tissue.

#### DEVELOPMENT OF THE TISSUES.

The tissues, however diversified in form, are all developed in the following manner:

A nucleated cell attracts from the blastema in which it is formed, or from the capillary vessels contiguous to it, certain elements which combine in its interior, and either form a portion of the animal body,—in which case the remains of the cell, and particularly its nucleus, continue to exist in the part, and can be made evident by chemical agents under the microscope,—or they become filled with a fluid, and bursting when ripe, and mixing and flowing along with their former contents, are discharged into a tube or duct, and constitute a secretion or a secreted fluid. The only difference between these two kinds of cell, which we designate by the terms *formative* and *secreting*, is that the former secrete a solid or semi-solid, which remains in the body with the debris of the cell for an appreciable period of time, whilst the latter secrete a fluid which escapes from the

body with the remains of the cell which gave it birth. Each of these little bodies may be compared to a laboratory, which receives from the surrounding matter the elements which it requires, and combines them so as to produce a desired result.

The various modifications and aggregations of these cells constitute the varied forms of animal and vegetable tissues.

#### DEVELOPMENT OF CELLS.

A cell originates in a mass of soft or liquid matter, which is *organizable* or capable of being *organized*. In other words, a liquid formed of a combination of elements fitted to produce an organized structure. This substance is called "*blastema*." As an example, we may take the liquor sanguinis or the blood, excluding its globules, which in a fully formed animal is a universally diffused *blastema*.

A minute point (see Fig. 2) arises in this *blastema*, which increases in size; a transparent wall is seen to spring up like a watch-glass from one side of the granule, which swells up more and more until the granule is seen to exist in, and adhere to the side of the cell wall. When thus formed, we have

the cell wall with its fluid contents, and the granule or nucleus, which may by this time have developed several new granules or nucleoli in its interior.

Fig. 2.\*



#### MULTIPLICATION OF CELLS.

Cells are multiplied in several modes:

1st. By repetition, i. e., of the development from a *blastema*, as explained.

2d. By the development of new nuclei and cells within the parent cell-wall (see fig. 3).

Fig. 3.†

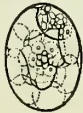
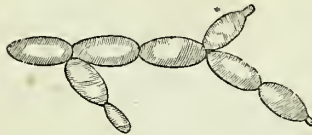
Fig. 4.‡



3d. By the development of new cells from the parietes of pre-existing ones. This is shown in fig. 4.

#### TRANSFORMATION OF CELLS.

1st. Cells may lose their fluid contents, and their walls collapsing until they come in contact and adhere, they form simple, membranous, and transparent discs.

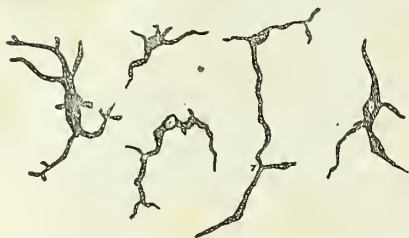\* Development of cell from blastema. On the left is seen the corpuscle which becomes the nucleus; on the right the complete nucleated cell.

† Development of new cells within the parent cell.

‡ Development of new cells from the outer wall of pre-existing cells.

2d. Cells may elongate so as to form tubes or solid rods; in the former case they adhere by their ends to neighbouring cells, and their cavities mutually open into each other, thus forming a vessel: in the latter the

Fig. 5.\*



fluid content is lost, and a rod or fibre is the result. Curious forms are produced by a modification of the same law, as exemplified in fig. 5.

3d. Solid deposits may occur within the cell wall, obliterating its cavity.

4th. The same thing may occur in the blastema, exterior to the cell walls, and thus a solid will result.

Examples of the third and fourth kind occur in the formation of cartilage, as is illustrated in the accompanying cuts.

Fig. 6.†

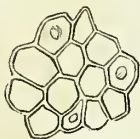

Fig. 7.†

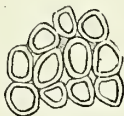


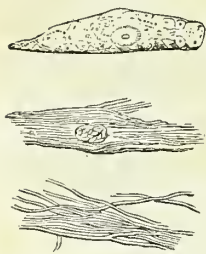
Fig. 8.†

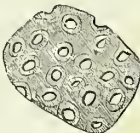

Fig. 9.‡

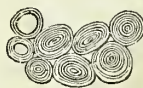

Fig. 10.§



5th. A curious modification of development occurs in the feathers of birds, where a nucleated cell elongates and becomes filled with fibres; the cell wall is rubbed off by attrition, and the fibres are thus uncovered and exposed. See fig. 10, a, b, c.

Finally, it is believed by some that the blastema may form a simple membrane or fibre without the intervention of a cell, although this is by no means proved.

\* Curious forms of cell transformation usually found in abnormal deposits.

† Development of cartilage.

‡ Deposit in layers of lignin in the interior of vegetable cells.

§ Mode of formation of the feathers of a bird in the interior of a nucleated cell.

## CHAPTER II.

## OSTEOLOGY.

THE bones are the organs of support to the animal frame; they give firmness and strength to the entire fabric, afford points of connection to the numerous muscles, and bestow individual character upon the body. In the limbs they are hollow cylinders, admirably calculated by their conformation and structure to resist violence and support weight. In the trunk and head, they are flattened and arched, to protect cavities and provide an extensive surface for attachment. In some situations they present projections of variable length, which serve as levers; and in others are grooved into smooth surfaces, which act as pulleys for the passage of tendons. Moreover, besides supplying strength and solidity, they are equally adapted, by their numerous divisions and mutual apposition, to fulfil every movement which may tend to the preservation of the creature, or be conducive to his welfare.

According to the latest analysis by Berzelius, bone is composed of about one-third of animal substance, which is almost completely reducible to gelatine by boiling, and of two-thirds of earthy and alkaline salts. The special constituents of bone are present in the following proportions:—

|                                    |              |
|------------------------------------|--------------|
| Cartilage . . . . .                | 32·17 parts. |
| Blood-vessels . . . . .            | 1·13         |
| Phosphate of lime . . . . .        | 51·04        |
| Carbonate of lime . . . . .        | 11·30        |
| Fluate of lime . . . . .           | 2·00         |
| Phosphate of magnesia . . . . .    | 1·16         |
| Soda, chloride of sodium . . . . . | 1·20         |

---

100·00

Bones are divisible into three classes:—*Long, flat, and irregular.*

The *Long* bones are found principally in the limbs, and consist of a shaft and two extremities. The shaft is cylindrical or prismoid in form, dense and hard in texture, and hollowed in the interior into a medullary canal. The extremities are broad and expanded, to articulate with adjoining bones; and cellular or cancellous in internal structure. Upon the exterior of the bone are processes and rough surfaces for the attachment of muscles, and foramina for the transmission of vessels and nerves. The character of long bones is, therefore, their general type of structure and their divisibility into a central portion and extremities, and not so much their length; for there are some long bones, as the second phalanges of the toes, which are less than a quarter of an inch in length, and almost equal, and in some instances exceed, in breadth their longitudinal axis. The long bones are, the clavicle, humerus, radius and ulna, femur, tibia and fibula, metacarpal bones, metatarsal, phalanges, and ribs.

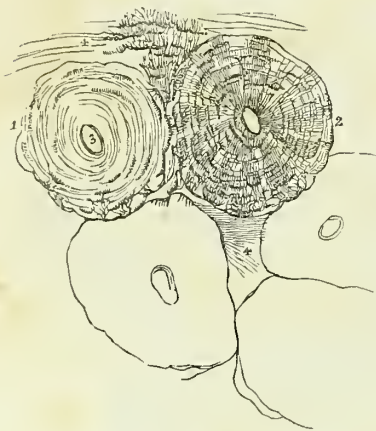*Flat* bones are composed of two layers of dense bone with an intermediate cellular structure, and are divisible into surfaces, borders, angles, and processes. They are adapted to inclose cavities; have processes upon their surface for the attachment of muscles; and are perforated by foramina, for the passage of nutrient vessels to their cells, and for the transmission

of vessels and nerves. They articulate with long bones by means of smooth surfaces plated with cartilage, and with each other either by fibrous tissue, as at the symphysis pubis; or by suture, as in the bones of the skull. The two condensed layers of the bones of the skull are named tables; and the intermediate cellular structure, *diplœ*. The flat bones are the occipital, parietal, frontal, nasal, lachrymal, vomer, sternum, scapulæ, and ossa innominata.

The *Irregular* bones include all that remain after the long and the flat bones have been selected. They are essentially irregular in their form, in some parts flat, in others short and thick. In preceding editions of this work the short and thick bones were made a separate class, under the name of *short bones*. This subdivision has been found to be disadvantageous, besides being arbitrary, and is, therefore, now omitted. Irregular bones are constructed on the same general principles with other bones; they have an exterior dense, and an interior more or less cellular: The bones of this class are, the temporal, sphenoid, ethmoid, superior maxillary, inferior maxillary, palate, inferior turbinated, hyoid, vertebræ, sacrum, coccyx, carpal and tarsal bones, and sesamoid bones, including the patellæ.

*Structure of Bone.*—Bone is a dense, compact, and homogeneous substance (basis substance) filled with minute cells (corpuscles of Purkinje), which are scattered numerously through its structure. The basis substance of bone is subfibrous and obscurely lamellated, the lamellæ being concentric in long and parallel in flat bones; it is traversed in all directions, but especially in the longitudinal axis, by branching and inosculating canals (Haversian canals), which give

Fig. 11.\*



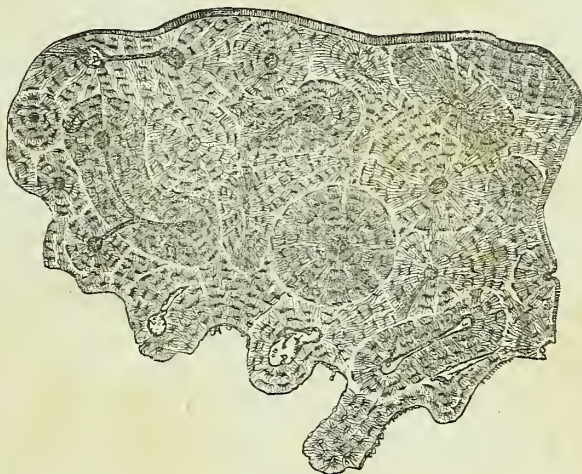
passage to vessels and nerves, and in certain situations the lamellæ separate from each other, and leave between them areolar spaces (cancelli) of various magnitude. The lamellæ have an average diameter of  $\frac{1}{600}$  of an inch, and, besides constituting the general structure of the basis substance, are collected concentrically around the Haversian canals, and form boundaries to those canals of about  $\frac{1}{250}$  of an inch in thickness. The number of lamellæ surrounding each Haversian canal is commonly ten or fifteen, and the diameters of the canals have a

medium average of  $\frac{1}{600}$  of an inch. The cancelli of bone, like its compact substance, have walls which are composed of lamellæ; and, such is the

\* Minute structure of bone, drawn with the microscope from nature, by Bagg. Magnified 300 diameters. 1. One of the Haversian canals surrounded by its concentric lamellæ. The corpuscles are seen between the lamellæ; but the calciferous tubuli are omitted. 2. An Haversian canal with its concentric lamellæ, Purkinjean corpuscles, and tubuli. 3. The area of one of the canals. 4. Direction of the lamellæ of the great medullary canal. Between the lamellæ at the upper part of the figure, several very long corpuscles with their tubuli are seen. In the lower part of the figure, the outlines of three other canals are given, in order to show their form and mode of arrangement in the entire bone.

similarity in structure of the parts of a bone, that the entire bone may be compared to an Haversian canal of which the medullary cavity is the magnified channel; and the Haversian canals may be likened to elongated and ramified cancelli. The Haversian canals are smallest near the surface of a bone, and largest near its centre, where they gradually merge into cancelli; by the frequent communications of their branches they form a coarse network in the basis substance.

Fig. 12.\*



The cells of bone, or corpuscles of Purkinje, are thickly disseminated through the basis substance; they are irregular in size and form, give off numerous minute branching tubuli, which radiate from all parts of their circumference, and in the dried state of the bone contain merely the remains of membranous cells and some calcareous salts.† In the living bone, the cells and their tubuli are probably filled with a nutritive fluid holding calcareous salts in solution. The form of the cells is oval or round, and more or less flattened, their long diameter corresponds with the long axis of the bone, and their tubuli cross the direction of the lamellæ, and constitute a very delicate network in the basis substance, by communicating with each other, and with the tubuli of neighbouring cells. The tubuli of the cells nearest the Haversian canals terminate upon the internal surface of those cavities. The size of the cells varies in extreme measurement from  $\frac{5}{1000}$  to  $\frac{8}{100}$  of an inch in their long diameter, an ordinary average being  $\frac{1}{1000}$ ; the breadth of the oval cells is about one-half or one-third their length, and their thickness one-half their breadth. They are situated between the lamellæ, to which circumstance they owe their compressed form.

\* The above cut, which I have introduced to supply the manifest deficiency of Mr. Wilson's representation, is from a section of a human femur, about its middle, and exhibits the erratic course of the Haversian canals, and their relations to each other, and at the same time the general laminated condition of a long bone. This laminated condition is well shown by polarized light, which causes the corpuscles to disappear, and the laminae to come out boldly.—G.

† Müller and Henle conceived that the bone cells and tubuli were the principal seat of the calcareous matter. Hence they have been named *calcareous* cells and tubuli.

In the fresh state, bones are invested by a dense fibrous membrane, the *periosteum*, which covers every part of their surface, with the exception of the articular extremities, the latter being coated by a thin layer of cartilage. The periosteum of the bones of the skull is termed *pericranium*; and the analogous membrane of external cartilages, *perichondrium*. Lining the interior of the medullary canal of long bones, the Haversian canals, the cells of the cancelli, and the cells of short, flat, and irregular bones, is the medullary membrane, which acts as an internal periosteum. It is through the medium of the vessels ramifying in these membranes that the changes required by nutrition occur in bones, and the secretion of medulla into their interior is effected. The medullary canal, Haversian canals, and cells of long bones, and the cells of other bones, are filled with a yellowish oily substance, the *medulla*, which is contained in a loose areolar tissue formed by the medullary membrane.

*Development of Bone.*—To explain the development of bone it is necessary to inform the student, that all organized bodies, whether belonging to the vegetable or the animal kingdom, are developed primordially from minute vesicles. These vesicles, or, as they are commonly termed, *cells*, are composed of a thin membrane containing a fluid or granular matter, and a small rounded mass, the *nucleus*, around which the cell was originally formed. Moreover, the nucleus generally contains one or more small round granules, the *nucleolus* or *nucleoli*. From cells having this structure all the tissues of the body are elaborated; the ovum itself originally presented this simple form, and the embryo at an early period is wholly composed of such nucleated cells. In their relation to each other, cells may be isolated and independent, as is exemplified in the corpuscles of the blood, chyle, and lymph; secondly, they may cohere by their surfaces and borders, as in the epiderma and epithelium; thirdly, they may be connected by an intermediate substance, which is then termed *intercellular*, as in cartilage and bone; and fourthly, they may unite with each other in rows, and upon the removal, by liquefaction, of the adherent surfaces, be converted into hollow tubuli. In the latter mode capillary vessels are formed, as also are the tubuli of nerve and muscular fibre. One of the properties of cells may also be adverted to in this place; it is that of reproducing similar cells in their interior. In this case the nucleoli become the nuclei of the secondary cells, and as the latter increase in size, the membrane of the primary or parent cell is lost.

Bone, in its earliest stage, is composed of an assemblage of these minute cells, which are soft and transparent, and are disposed within the embryo in the site of the future skeleton. From the resemblance which the soft tissue bears to jelly, this has been termed the *gelatinous stage* of osteo-genesis. As development advances, the cells, heretofore loosely collected together, become separated by the interposition of a transparent intercellular substance, which is at first fluid, but gradually becomes hard and condensed. The *cartilaginous stage* of osteo-genesis is now established, and cartilage is shown to consist of a transparent matrix, having minute cells disseminated at pretty equal distances, and without order, through its structure. Coincident with the formation of cartilage is the development of vascular canals in its substance, the canals being formed by the union of the cells in rows, and the subsequent liquefaction of the adhering surfaces. The change which next ensues in the concentration of the vascular canals towards some one point; for example, the centre



of the shaft in a long, or the mid-point of a flat bone, and here the *punctum ossificationis*, or centre of ossification, is established. What determines the vascular concentration now alluded to, is a question not easily solved, but that it takes place is certain, and the vascular punctum is the most easily demonstrable of all the phenomena of ossification.

During the formation of the *punctum ossificationis*, changes begin to be apparent in the cartilage cells. Originally they are simple nucleated cells ( $\frac{1}{5000}$  to  $\frac{1}{2000}$  of an inch in diameter), having a rounded form. As growth proceeds, they become elongated in their figure, and it is then perceived that

each cell contains two and often three nucleoli, around which smaller cells are in progress of formation. If we examine them nearer to the *punctum ossificationis*, we find that the young or secondary cells have each attained the size of the parent cell ( $\frac{1}{2000}$  of an inch), the membrane of the parent cell has disappeared, and the young cells are separated to a short distance by freshly effused intercellular substance.

Nearer still to the *punctum ossificationis* a more remarkable change has ensued, the energy of cellule reproduction has augmented with proximity to the ossifying point, and each cell in place of producing two, gives birth to four, five, or six young cells, which rapidly de-

Fig. 13.\*

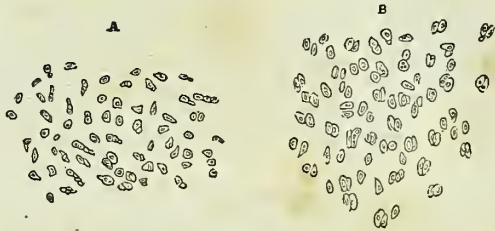


Fig. 14.†


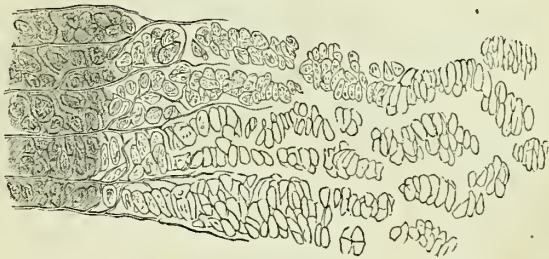


Fig. 15.‡



\* Figures illustrative of the development of bone; they are magnified 155 times, and drawn with the camera lucida. A. A portion of cartilage the farthest removed from the seat of ossification, showing simple nucleated cells, having an ordinary size of  $\frac{1}{2000}$  of an inch, long diameter. B. The same cartilage, nearer the seat of ossification; each simple cell has produced two, which are a little larger than the cells in figure A.

† The same cartilage, still nearer the seat of ossification; each single cell of A has given birth to four, five, or six cells, which form clusters. These clusters become larger towards the right of the figure, and their cells more numerous and larger,  $\frac{1}{1500}$  of an inch, long diameter.

‡ The same cartilage at the seat of ossification; the clusters of cells are arranged in columns; the intercellular spaces between the columns being  $\frac{1}{3250}$  of an inch in

stroy the parent membrane and attain a greater size ( $\frac{1}{1500}$  of an inch) than the parent cell, each cell being, as in the previous case, separated to a slight extent from its neighbour by intercellular substance. By one other repetition of the same process, each cell producing four, or five, or six young cells, a cluster is formed, containing from thirty to fifty cells. These clusters lie in immediate relation with the punctum ossificationis; they are oval in figure (about  $\frac{1}{200}$  in length by  $\frac{1}{500}$  in breadth), and placed in the direction of the longitudinal axis of the bone. The cells composing the cluster lie transversely with regard to its axis. In the first instance they are closely compressed, but by degrees are parted by a thin layer of intercellular substance, and each cluster is separated from neighbouring clusters by a broader layer ( $\frac{1}{3250}$  of an inch) of intercellular substance. Such are the changes which occur in cartilage preparatory to the formation of bone.

Ossification is accomplished by the formation of very fine and delicate fibres within the intercellular substance: this process commences at the punctum ossificationis, and extends from that point through every part of the bone, in a longitudinal direction in long, and in a radiated manner in flat bones. Starting from the punctum ossificationis, the fibres embrace each cluster of cells, and then send branches between the individual cells of each group. In this manner the network, characteristic of bone, is formed, while the cells by their conjunction constitute the permanent areolæ and Haversian canals. With a high magnifying power, the delicate ossific fibres here alluded to are seen themselves to be composed of minute cells having an elliptical form and central nuclei. These cells attract into their interior the calcareous salts of the blood, and their nuclei become developed, as I believe, into the future corpuscles of Purkinje. It is possible also that some of the cartilage cells become corpuscles of Purkinje in the fully developed bone.

During the progress of the phenomena above described, the contents of the cells undergo certain changes. At first, their contents are transparent, then they become granular, and still later opaque, from the presence of amorphous matter mingled with nuclei, nucleoli, and the remains of secondary cells. In the latter state they also contain an abundance of minute oil-globules. These latter increase in size as the ossific changes advance, and in the newly formed osseous areolæ they are very numerous and have attained the ordinary size of adipose cells.

Cartilagification is complete in the human embryo at about the sixth week; and the first point of ossification is observed in the clavicle at about the seventh week. Ossification commences at the centre, and thence proceeds towards the surface; in flat bones the osseous tissue radiates between two membranes from a central point towards the periphery, in short bones from a centre towards the circumference, and in long bones from a central portion, *diaphysis*, towards a secondary centre, *epiphysis*, situated at each extremity. Large processes, as the trochanters, are provided with a distinct centre of development, which is named *apophysis*.

breadth. To the right of the figure osseous fibres are seen occupying the intercellular spaces, at first bounding the clusters laterally, then splitting them longitudinally, and encircling each separate cell. The greater opacity of the right-hand border is due to a threefold cause, the increase of osseous fibres, the opacity of the contents of the cells, and the multiplication of oil-globules. In the lower part of the figure some attempt has been made to show the texture of the cells.

The *growth* of bone in length takes place at the extremity of the diaphysis, and in bulk by fresh deposition on the surface; while the medullary canal is formed and increased by absorption from within.

The *period of ossification* is different in different bones; the order of succession may be thus arranged:—

During the fifth week, ossification commences in the clavicle, lower jaw, and upper jaw.

During the sixth week, in the femur, humerus, tibia, radius, and ulna.

During the seventh and eighth weeks, in the fibula, frontal, occipital, sphenoid, ribs, parietal, temporal, nasal, vomer, palate, vertebræ, first three pieces of sacrum, malar, metacarpus, metatarsus, third phalanges of the hands and feet, and ilium.

During the third month, in the first and second phalanges of the hands and feet, lachrymal bone, and ischium.

During the fifth month, in the mastoid portion of the temporal, ethmoid, inferior turbinated, sternum, os pubis, and last two pieces of sacrum.

During the sixth month, in the body and odontoid process of the axis, and in the calcaneus.

During the seventh month, in the astragalus.

During the tenth month, in the cuboid bone and os hyoides.

During the first year, in the coracoid process of the scapula; first piece of the coccyx, inferior turbinated bone, last piece of the sternum, anterior arch of the atlas, os magnum, os unciforme, and external cuneiform bone.

During the third year, in the cuneiform of the carpus, internal cuneiform of the tarsus, and patella.

During the fourth year, in the middle cuneiform and scaphoid of the tarsus.

During the fifth year, in the trapezium and os semilunare.

During the seventh year, in the second piece of the coccyx.

During the eighth year, in the scaphoid of the carpus.

During the ninth year, in the os trapezoides.

During the twelfth year, in the os fisiforme and third piece of the coccyx.

During the eighteenth year, in the fourth piece of the coccyx.

The ossicula auditûs are the only bones completely ossified at birth; the vertebræ are not completed until the five-and-twentieth year.

The entire osseous framework of the body constitutes the skeleton, which in the adult man is composed of two hundred and forty-six distinct bones. They may be thus arranged:—

|                                               |    |
|-----------------------------------------------|----|
| Head . . . . .                                | 8  |
| Ossicula auditûs . . . . .                    | 6  |
| Face . . . . .                                | 14 |
| Teeth . . . . .                               | 32 |
| Vertebral column, including sacrum and coccyx | 26 |
| Os hyoides, sternum, and ribs . . . . .       | 26 |
| Upper extremities . . . . .                   | 64 |
| Lower extremities . . . . .                   | 62 |
| Sesamoid bones . . . . .                      | 8  |

The *skeleton* is divisible into: 1. The vertebral column, or central axis.  
2. The head and face, or superior development of the central axis. 3.

The hyoid arch. 4. The thoracic arch and upper extremities. 5. The pelvic arch and lower extremities.

## VERTEBRAL COLUMN.

The *vertebral column* is the first and only rudiment of internal skeleton in the lower Vertebrata, and constitutes the type of that great division of the animal kingdom. It is also the first developed portion of the skeleton in man, and the centre around which all the other parts are produced. In its earliest formation it is a simple cartilaginous cylinder, surrounding and protecting the primitive trace of the nervous system; but, as it advances in growth and organisation, it becomes divided into distinct pieces, which constitute *vertebræ*.

The *vertebræ* are divided into true and false. The true *vertebræ* are twenty-four in number, and are classified, according to the three regions of the trunk which they occupy, into cervical, dorsal, and lumbar. The false *vertebræ* consist of nine pieces united into two bones, the sacrum and coccyx. The arrangement of the *vertebræ* may be better comprehended by means of the accompanying table:—

|                         |   |             |
|-------------------------|---|-------------|
| True <i>vertebræ</i> 24 | } | 7 Cervical, |
|                         |   | 12 Dorsal,  |
|                         |   | 5 Lumbar.   |
| False <i>vertebræ</i> 9 | } | 5 Sacrum,   |
|                         |   | 4 Coccyx.   |

*Characters of a Vertebra.*—A vertebra consists of a body, two laminae, a spinous process, two transverse processes, and four articular processes. The *body* is the solid part of the vertebra; and, by its articulation with adjoining *vertebræ*, gives strength and support to the trunk. It is flattened above and below, convex in front, and slightly concave behind. Its anterior surface is constricted around the middle, and pierced by a number of small openings which give passage to nutritious vessels. Upon its posterior surface is a single irregular opening, or several, for the exit of the venæ basis *vertebræ*.

The *laminae* commence upon the sides of the posterior part of the body of the vertebra by two *pedicles*; they then expand; and, arching backwards, enclose a *foramen* which serves for the protection of the spinal cord. The upper and lower borders of the laminae are rough for the attachment of the ligamenta subflava. The concavities above and below the pedicles are the *intervertebral notches*. The *spinous process* stands backwards from the angle of union of the laminae of the vertebra. It is the succession of these projecting processes along the middle line of the back, that has given rise to the common designation of the vertebral column, the spine. The use of the spinous process is for the attachment of muscles. The *transverse processes* project one at each side from the laminae of the vertebra; they are intended for the attachment of the muscles. The *articular processes*, four in number, stand upwards and downwards from the laminae of the vertebra, to articulate with the vertebra above and below.

*Cervical Vertebra.*—In a cervical vertebra the body is smaller than in the other regions; it is thicker before than behind, broad from side to side, concave on the upper surface, and convex below; so that, when articulated, the *vertebræ* lock the one into the other. The *laminae* are

narrow and long, and the included *spinal foramen* large and triangular. The *superior intervertebral notches* are slightly deeper than the inferior; the *inferior* being the broadest. The *spinous process* is short and bifid at the extremity, increasing in length from the fourth to the seventh. The *transverse processes* are also short and bifid, and deeply grooved along the upper surface for the cervical nerves. Piercing the base of the transverse process is the vertebral foramen†, which gives passage to the vertebral artery and vein, and vertebral plexus of nerves.

The transverse processes in this region are formed by two small developments which proceed, the one from the side of the body, the other from the pedicle of the vertebra, and unite near their extremities to enclose the circular area of the vertebral foramen. The anterior of these developments is the rudiment of a cervical rib; and the posterior, the analogue of the transverse processes in the dorsal region. The extremities of these developments are the *anterior* and *posterior tubercles* of the transverse process. The *articular processes* are oblique; the superior looking upwards and backwards; and the inferior, downwards and forwards.

There are three peculiar vertebræ in the cervical region:—The first, or atlas; the second, or axis; and the seventh, or vertebra prominens.

The *Atlas* (named from supporting the head) is a simple ring of bone, without body, and composed of arches and processes. The *anterior arch* has a tubercle on its anterior surface, for the attachment of the longus colli muscle: and on its posterior aspect is a smooth surface, for the articulation of the odontoid process of the axis.

The *posterior arch* is longer and more slender than the anterior, and flattened from above downwards; at its middle is a rudimentary spinous process; and upon its upper surface, near the articular processes, a shallow groove§ at each side, which represents a superior intervertebral notch, and supports the vertebral artery previously to its passage through the dura mater, and the first cervical nerve.

\* A central cervical vertebra, seen upon its upper surface. 1. The body, concave in the middle, and rising on each side into a sharp ridge. 2. The lamina. 3. The pedicle, rendered concave by the superior intervertebral notch. 4. The bifid spinous process. 5. The bifid transverse process. The figure is placed in the concavity between the anterior and posterior tubercles, between the two processes which correspond with the rudimentary rib and the true transverse process. 6. The vertebral foramen. 7. The superior articular process, looking backwards and upwards. 8. The inferior articular process.

† Sometimes, as in a vertebra now before me, a small additional opening exists by the side of the vertebral foramen, in which case it is traversed by a second vein.

‡ The upper surface of the atlas. 1. The anterior tubercle projecting from the anterior arch. 2. The articular surface for the odontoid process upon the posterior surface of the anterior arch. 3. The posterior arch, with its rudimentary spinous process. 4. The intervertebral notch. 5. The transverse process. 6. The vertebral foramen. 7. Superior articular surface. 8. The tubercle for the attachment of the transverse ligament. The tubercle referred to is just above the head of the figure; the convexity below it is the margin of the inferior articulating process.

§ This groove is sometimes converted into a foramen.

Fig. 16.\*

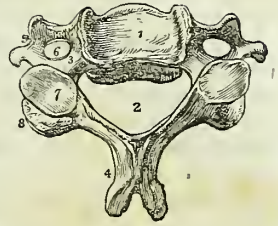
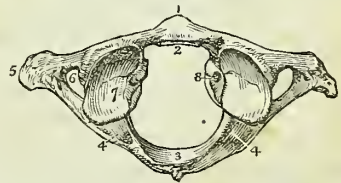


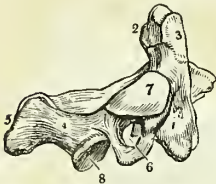
Fig. 17.‡



The intervertebral notches are peculiar, from being situated behind the articular processes, instead of before them as in the other vertebræ. The *transverse processes* are remarkably large and long, and pierced by the foramen for the vertebral artery. The *articular processes* are situated upon the most bulky and strongest part of the atlas. The superior are oval and concave, and look inwards, so as to form a kind of cup for the condyles of the occipital bone, and are adapted to the nodding movements of the head; the inferior are circular, and nearly horizontal, to permit of the rotatory movements. Upon the inner face of the *lateral mass* which supports the articular processes, is a small tubercle at each side, to which the extremities of the transverse ligament are attached, a ligament which divides the ring of the atlas into two unequal segments; the smaller for receiving the odontoid process of the axis, and the latter to give passage to the spinal cord and its membranes.

The *Axis* (vertebra dentata) is so named from having a process upon which the head turns as on a pivot. The *body* is of large size, and supports a strong process, the odontoid, which rises perpendicularly from its upper surface. The *odontoid process* presents two articulating surfaces; one on its anterior face, to articulate with the anterior arch of the atlas; the other on its posterior face, for the transverse ligament; the latter surface constricts the base of the process, which has given rise to the term *neck* applied to this part. Upon each side of its apex is a rough depression, for the attachment of the alar ligaments; and running down from its base on

Fig. 18.\*



the anterior surface of the body of the vertebra a vertical ridge, with a depression at each side for the attachment of the longus colli muscle. The *laminae* are large and strong, and unite posteriorly to form a long and bifid *spinous process*, which is concave beneath. The *transverse processes* are quite rudimentary, not bifid, and project only so far as to enclose the vertebral foramen, which is directed obliquely outwards instead of perpendicu-

larly as in the other vertebræ. The *superior articulating processes* are situated upon the body of the vertebra on each side of the odontoid process. They are circular and nearly horizontal, having a slight inclination outwards. The *inferior articulating processes* look downwards and forwards, as do the same processes in the other cervical vertebræ. The *superior intervertebral notch* is remarkably shallow, and lies behind the articular process as in the atlas. The lower surface of the body is convex, and is received into the concavity upon the upper surface of the third vertebra.

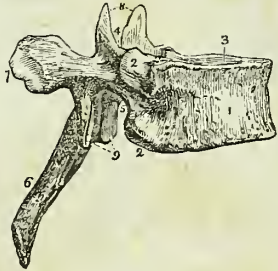
The *Vertebra prominens*, or seventh cervical, approaches in character to the upper dorsal vertebræ. It has received its designation from having a very long spinous process, which is single and terminated by a tubercle, and forms a considerable projection on the back part of the neck; to the extremity of this process the ligamentum nuchæ is attached. The transverse processes are but slightly grooved along the upper surface, have

\* A lateral view of the axis. 1. The body; the figure is placed on the depression which gives attachment to the longus colli. 2. The odontoid process. 3. The smooth facet on the anterior surface of the odontoid process which articulates with the anterior arch of the atlas; the facet for the transverse ligament is beneath No. 2, where the constriction called the neck of the odontoid process is seen; the bulk of the process between 2, 3, would represent its head. 4. The lamina. 5. The spinous process. 6. The transverse process, pierced obliquely by the vertebral foramen. 7. The superior articular surface. 8. The inferior articular process.

each a small foramen for the transmission of the vertebral vein, and present only a rudimentary bifurcation at their extremity. Sometimes the anterior tubercle represents a small but distinct rib.

*Dorsal Vertebrae.*—The *body* of a dorsal vertebra is as long from before backwards as from side to side, particularly in the middle of the dorsal region; it is thicker behind than before, and marked on each side by two half-articulating surfaces for the heads of two ribs. The *pedicles* are strong, and the *laminae* broad and thick; the spinal *foramen* small and round, and the inferior *intervertebral notch* of large size, the superior can scarcely be said to exist. The *spinous process* is long, prismoid, directed very obliquely downwards, and terminated by a tubercle. The *transverse processes* are large and strong, and directed obliquely backwards. Upon the anterior and superior aspect of their summits is a small facet for the articulation of the tubercle of a rib. The *articular processes* are vertical, the superior facing directly backwards, and the inferior directly forwards.

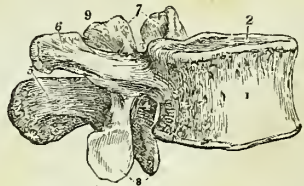
Fig. 19.\*



The peculiar vertebræ in the dorsal region are the first, ninth, tenth, eleventh, and twelfth. The *first* dorsal vertebra approaches very closely in character to the last cervical. The body is broad from side to side, and concave above. The superior articular processes are oblique, and the spinous process horizontal. It has an entire articular surface for the first rib, and a half surface for the second. The *ninth* dorsal vertebra has only one half articular surface at each side. The *tenth* has a single entire articular surface at each side. The *eleventh* and *twelfth* have each a single entire articular surface at each side; they approach in character to the lumbar vertebræ; their transverse processes are very short, trifid at their summits, and have no articulation with the corresponding ribs. The transverse processes of the twelfth dorsal vertebra are quite rudimentary, and its inferior articular processes look outwards.

*Lumbar Vertebrae.*—These are the largest pieces of the vertebral column. The *body* is broad and large, and thicker before than behind. The *pedicles* very strong; the *laminae* short, thick, and broad; the *inferior intervertebral notches* very large, and the spinal *foramen* large and oval. The *spinous process* is thick and broad. The *transverse processes* (costiform processes) are slender, pointed, and directed only slightly

Fig. 20.†



\* A lateral view of a dorsal vertebra. 1. The body. 2. Articular facets for the heads of ribs. 3. The pedicle. 4. The superior intervertebral notch. 5. The inferior intervertebral notch. 6. The spinous process. 7. The extremity of the transverse process, marked by an articular surface for the tubercle of a rib. 8. The two superior articular processes looking backwards. 9. The two inferior articular processes looking forwards.

† A lateral view of a lumbar vertebra. 1. The body. 2. The pedicle. 3. The superior intervertebral notch. 4. The inferior intervertebral notch. 5. The spinous process. 6. The transverse process. 7. The superior articular processes. 8. The inferior articular processes. 9. The posterior transverse process.

backwards. The superior *articular processes* are concave, and look backwards and inwards; the inferior convex, and look forwards and outwards. Projecting backwards and upwards from the superior articular process is a short and flattened tubercle or *posterior transverse process*, and in a strongly marked vertebra there is not unfrequently at the base of this a smaller tubercle which has a direction downwards. The last lumbar vertebra differs from the rest in having the body very much bevelled posteriorly, so as to be thick in front and thin behind, and the transverse process thick and large.

*General Considerations.*—Viewed as a whole, the vertebral column represents two pyramids applied base to base, the superior being formed by all the vertebræ from the second cervical to the last lumbar, and the inferior by the sacrum and coccyx. Examined more attentively, it will be seen to be composed of four irregular pyramids, applied to each other by their smaller extremities and by their bases. The smaller extremity of the uppermost pyramid is formed by the axis, or second cervical vertebra; and its base, by the first dorsal. The second pyramid is inverted; having its base at the first dorsal, and the smaller end at the fourth. The third pyramid commences at the fourth dorsal, and gradually enlarges to the fifth lumbar. The fourth pyramid is formed by the sacrum and coccyx.

The *bodies* of the vertebræ are broad in the cervical region; narrowed almost to an angle in the middle of the dorsal, and again broad in the lumbar region. The *arches* are broad and imbricated in the cervical and dorsal regions, the inferior border of each overlapping the superior of the next; in the lumbar region an interval is left between them. A considerable interval exists between the cranium and atlas, and another between the last lumbar vertebra and sacrum.

The *spinous processes* are horizontal in the cervical, and become gradually oblique in the upper part of the dorsal region. In the middle of the dorsal region they are nearly vertical and imbricated, and towards its lower part assume the direction of the lumbar spines, which are quite horizontal. The *transverse processes* developed in their most rudimentary form in the axis, gradually increase in length to the first dorsal vertebra. In the dorsal region they project obliquely backwards, and diminish suddenly in length in the eleventh and twelfth vertebræ where they are very small. In the lumbar region they increase to the middle transverse process, and again subside in length to the last.

The transverse processes consist essentially of two parts, the anterior of which in the dorsal region is the rib, while the posterior retains the name of the transverse process. In the cervical region these two elements are quite apparent, both by their different points of attachment to the vertebra, and by the vertebral foramen which divides them at their base. In the lumbar region the so-called transverse processes are in reality lumbar ribs, while the transverse processes will be found behind them in a rudimentary state, developed, like the true transverse processes in the cervical region, from the superior articular processes. When the anterior and posterior transverse processes are examined in relation with each other, they will be observed to converge; if they were prolonged they would unite as in the cervical region and enclose a foramen, or they would rest in contact as in the dorsal region, or become consolidated as in the formation of the sacrum. Moreover, the posterior transverse processes are



directed upwards, and if they were prolonged, they would come into contact with a small tubercle which is found at the base of the posterior transverse process (in strongly-marked vertebræ) in the vertebra above. This junction would form a posterior intervertebral foramen, as actually occurs in the sacrum. In brief, the lumbar vertebræ exhibit those transitional changes which are calculated, by an easy gradation, to convert separate vertebræ into a solid bone. The transverse processes of the eleventh and twelfth dorsal vertebræ are very interesting in a transcendental point of view, as exhibiting a tendency which exists obscurely in all the rest, namely, to trifurcate. Now, supposing these three branches to be lengthened in order to fulfil their purposes, the anterior would constitute the articulation or union with a rib, while the superior and inferior would join similar branches in the vertebra above and below, and so form the posterior intervertebral foramen.

The *intervertebral foramina* formed by the juxtaposition of the notches are smallest in the cervical region, and gradually increase to the last lumbar. On either side of the spinous processes, and extending the whole length of the column, is the *vertebral groove*, which is shallow and broad in the cervical, and deeper and narrower in the dorsal and lumbar regions. It lodges the principal muscles of the back.

Viewed from the side, the vertebral column presents several curves, the principal of which is situated in the dorsal region, the concavity looking forwards. In the cervical and lumbar regions the column is convex in front; and in the pelvis an anterior concave curve is formed by the sacrum and coccyx. Besides the antero-posterior curves, a slight lateral curve exists in the dorsal region, having its convexity towards the right side.

*Development.*—The vertebræ are developed by three primary and five secondary centres or epiphyses. The primary centres are, one for each lamella, and one for the body; the epiphyses, one for the apex of the spinous process, one for that of each transverse process, and one for the upper and under surface of the body. Exceptions to this mode of development are met with in the atlas, axis, vertebra prominens, and lumbar vertebræ. The *atlas* has four centres: one for each lateral mass, one (sometimes two) for the anterior arch, and one for the centre of the posterior arch. The *axis* has five: one (sometimes two) for the body, two for the odontoid process, appearing side by side in its base, and one for each lamella. The *vertebra prominens* has two additional centres for the anterior or costal segments of the transverse processes, and the *lumbar vertebræ* two for the posterior segments of the transverse processes.

The primary centres of the vertebræ make their appearance during the seventh or eighth week of embryonic existence, the lamella being somewhat in advance of that for the body. From the former are produced the spinous, transverse, and articular processes, and the sides of the body; they unite, to complete the arch, one year after birth, and with the body during the fifth year. The epiphyses, for the extremities of the spinous and transverse processes, make their appearance at fifteen or sixteen, and become united between twenty and twenty-five. The epiphyses of the body are somewhat later in appearance, and are consolidated between the periods of twenty-five and thirty years of age.

The ossific centres for the lateral masses of the *atlas* appear at the same time with those of the other vertebræ; they unite posteriorly at the end of the second year, by the intervention of the centre for the posterior arch.

The one or two centres of the anterior arch appear during the first year, and become consolidated with the lateral pieces during the fifth or sixth year. The *axis* develops its lateral pieces at the same time with the rest of the vertebræ; they join posteriorly soon after birth, and with the body during the fourth or fifth year. The centres for the body and odontoid process appear during the sixth month, and are consolidated during the third year. The body of the axis is more largely developed at birth than that of the other vertebræ. The costal segments of the *vertebra prominens* appear during the second month, and become united to the body at the fifth or sixth year. These processes sometimes remain permanently separate, and constitute a cervical rib. The transverse process of the *first lumbar vertebra* has sometimes a distinct centre, which may remain permanently separate, in that case forming a lumbar rib.

The ossification of the arches of the vertebræ commences from above, and proceeds gradually downwards; hence arrest of development gives rise to spina bifida, generally in the loins. Ossification of the bodies, on the contrary, commences from the centre, and proceeds from that point towards the extremities of the column; hence imperfection of the bodies occurs either in the upper or lower vertebræ.

*Attachment of Muscles.*—To the *atlas* are attached ten pairs of muscles; the longus colli, rectus anticus minor, rectus lateralis, rectus posticus minor, obliquus superior and inferior, splenius colli, levator anguli scapulæ, first interspinales, and first intertransversales.

To the *axis* are attached twelve pairs, viz.: the longus colli, intertransversales, obliquus inferior, rectus posticus major, supraspinalis, interspinales, semi-spinalis colli, multifidus spinæ, levator anguli scapulæ, splenius colli, transversalis colli, and scalenus posticus.

To the remaining *vertebræ* collectively, thirty-three pairs;—viz. *posteriorly*, the trapezius, latissimus dorsi, levator anguli scapulæ, rhomboideus minor and major, serratus posticus superior and inferior, splenius, sacrolumbalis, longissimus dorsi, spinalis dorsi, cervicalis ascendens, transversalis colli, trachelo-mastoideus, complexus, semi-spinalis dorsi and colli, multifidus spinæ, supraspinalis, interspinales, intertransversales, levatores costarum: *anteriorly*, the rectus anticus major, longus colli, scalenus anticus and posticus, psoas magnus, psoas parvus, quadratus lumborum, diaphragm, obliquus internus and transversalis.

THE SACRUM is a triangular bone, situated at the lower extremity of the vertebral column, and formed by the consolidation of five false vertebræ. It is divisible into an anterior and posterior surface, two lateral and a superior border, and an inferior extremity.

The *anterior surface* is concave, and marked by four transverse lines, which indicate its original constitution of five separate pieces. At the extremities of these lines, on each side, are the four anterior sacral foramina, which diminish in size from above downwards, and transmit the anterior sacral nerves. The projection of the superior piece is the sacro-vertebral angle or *promontory*.

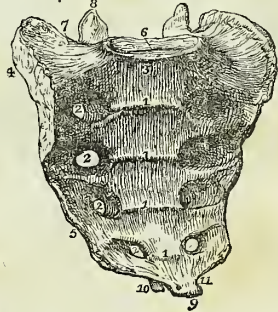
The *posterior surface* is narrower than the anterior and convex. Upon the middle line is a rough crest formed by the rudiments of four spinous processes, the fifth remaining undeveloped and exposing the lower termination of the sacral canal. Immediately external to and parallel with the median crest, is a range of five small tubercles which represent the poste-

rior transverse processes of the true vertebræ; beyond these is a shallow groove in which the four posterior sacral foramina open, and farther outwards, a range of five tubercles corresponding with the anterior or costal transverse processes of the lumbar vertebræ. The lowest pair of the posterior transverse tubercles bound on each side the termination of the sacral canal, and send each a process downwards to articulate with the coccyx. The two descending processes are the *sacral cornua*. The posterior sacral foramina are smaller than the anterior, and transmit the posterior sacral nerves. Of the anterior transverse tubercles the *first* corresponds with the angle of the superior border of the bone; the *second* is small, and enters into the formation of the sacro-iliac articulation; the *third* is large, and gives attachment to the oblique sacro-iliac ligament; the *fourth* and *fifth* are smaller, and serve for the attachment of the sacro-ischiatic ligaments. The *lateral border* of the sacrum presents superiorly a broad and ear-shaped (auricular) surface to articulate with the ilium; and inferiorly a sharp edge, to which the greater and lesser sacro-ischiatic ligaments are attached. On the *superior border*, in the middle line, is an oval articular surface, which corresponds with the under part of the body of the last lumbar vertebra; and on each side a broad triangular surface, which supports the lumbo-sacral nerve and psoas magnus muscle. Immediately behind the vertebral articular surface is the triangular entrance of the sacral canal; and on each side of this opening an articular process, which looks backwards and inwards, like the superior articular processes of the lumbar vertebræ. In front of each articular process is an intervertebral notch. The *inferior extremity* of the bone presents a small oval surface which articulates with the coccyx; and on each side a notch, which, with a corresponding notch in the upper border of the coccyx, forms the foramen for the transmission of the fifth sacral nerve.

The sacrum presents some variety in respect of curvature, and of the number of pieces which enter into its structure. The curve is often very slight, and is situated only near the lower part of the bone; while in other subjects it is considerable, and occurs at the middle of the sacrum. The sexual differences in the sacrum relate to its greater breadth, and the greater angle which it forms with the rest of the vertebral column in the female, rather than to any peculiarity in shape. It is sometimes composed of six pieces, more rarely of four, and, occasionally, the first and second pieces remain permanently separate.

*Development.*—By *twenty-one* points of ossification; five for each of the three first pieces, viz. one for the body, one for each lateral portion, and one for each lamina; and three for each of the two last, namely, one for

Fig. 21.\*



\* The sacrum seen upon its anterior surface. 1, 1'. The transverse lines marking the original constitution of the bone of four pieces. 2, 2'. The anterior sacral foramina. 3. The promontory of the sacrum. 4. The ear-shaped surface which articulates with the ilium. 5. The sharp edge to which the sacro-ischiatic ligaments are attached. 6. The vertebral articular surface. 7. The broad triangular surface which supports the psoas muscle and lumbo-sacral nerve. 8. The articular process of the right side. 9. The inferior extremity, or apex of the sacrum. 10. One of the sacral cornua. 11. The notch which is converted into a foramen by the coccyx.

the body, and one for each lateral portion. In the progress of growth, and after puberty, fourteen epiphysal centres are added, namely, two for the surfaces of each body, one for each auricular surface, and one for the thin edge of each lateral border. Ossification begins in the bodies of the sacral pieces somewhat later than in those of the true vertebræ; the first three appearing during the eighth and ninth week, and the last two at about the middle of the intra-uterine existence. Ossification of the lamellæ takes place during the interval between the sixth and the ninth month. The epiphyses for the upper and under surface of the bodies are developed during the interval between the fifteenth and eighteenth year; and for the auricular and marginal piece, after twenty. The two lower vertebral pieces, although the last to appear, are the first to be completed (between the fourth and fifth year), and to unite by their bodies. The union of the bodies takes place from below upwards, and finishes between the twenty-fifth and the thirtieth year, with the first two pieces.

*Articulations.*—With *four* bones; the last lumbar vertebra, ossa innominata, and coccyx.

*Attachment of Muscles.*—To *seven* pairs; *in front* the pyriformis, *on the side* the coccygeus, and *behind* the gluteus maximus, latissimus dorsi, longissimus dorsi, sacro-lumbalis, and multifidus spinæ.

The COCCYX (κόκκυξ cuckoo, from resembling a cuckoo's beak) is composed of four small pieces, which form the caudal termination of the vertebral column. The superior piece is broad, and expands laterally into two transverse processes; it is surmounted by an oval articular surface and two cornua, the former to articulate with the apex of the sacrum, and the latter with the sacral cornua. The lateral wings sometimes become connected with the sacrum, and convert the notches for the fifth pair of sacral nerves into foramina. The remaining three pieces diminish in size from above downwards.

*Development.*—By *four* centres; one for each piece. Ossification commences in the first piece soon after birth; in the second, between five and ten years; in the third, between ten and fifteen; and in the fourth, between fifteen and twenty. The pieces unite at an earlier period than the bodies of the sacrum, the first two pieces first, then the third and fourth, and lastly, the second and third. Between forty and sixty years, the coccyx becomes consolidated with the sacrum; this event taking place later in the female than in the male.

*Articulations.*—With the sacrum.

*Attachment of Muscles.*—To *three* pairs, and one single muscle; gluteus maximus, coccygeus, posterior fibres of the levator ani, and sphincter ani.

#### OF THE SKULL.

The skull, or superior expansion of the vertebral column, is divisible into two parts,—the cranium and the face; the former being adapted, by its form, structure, and strength, to contain and protect the brain, and the latter the chief organs of sense.

The CRANIUM is composed of eight separate bones; viz., the

|               |               |
|---------------|---------------|
| Occipital,    | Two temporal, |
| Two parietal, | Sphenoid,     |
| Frontal,      | Ethmoid.      |

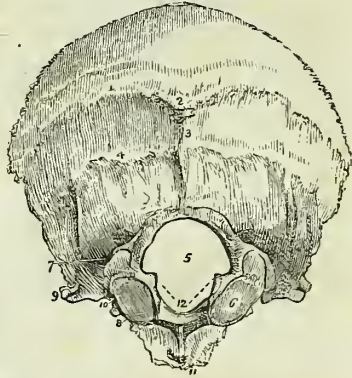
**OCCIPITAL BONE.**—This bone is situated at the posterior part and base of the cranium. It is trapezoid in figure, and divisible into two surfaces, four borders, and four angles.

*External Surface.*—Crossing the middle of the bone transversely, from one lateral angle to the other, is a prominent ridge, the *superior curved line*. In the middle of the ridge is a projection, called the *external occipital protuberance*; and descending from it a small vertical ridge, the *spine*. Above and below the superior curved line the surface is rough, for the attachment of muscles. About three-quarters of an inch below this line is another transverse ridge, the *inferior curved line*, and beneath the latter the *foramen magnum*. On each side of the foramen magnum, nearer to its anterior than its posterior segment, and encroaching somewhat upon the opening, is an oblong articular surface, the *condyle*, for articulation with the atlas. The condyles approach towards each other anteriorly, and their articular surfaces look downwards and outwards.

Directly behind each condyle is an irregular fossa, and a small opening, the *posterior condyloid foramen*, for the transmission of a vein to the lateral sinus. In front of the condyle is the *anterior condyloid foramen*, for the hypoglossal nerve; and on the outer side of each condyle a projecting ridge, the *transverse process*, excavated in front by a notch which forms part of the jugular foramen. In front of the foramen magnum is a thick square mass, the *basilar process*, and in the centre of the basilar process a small tubercle for the attachment of the superior and middle constrictor muscles of the pharynx.

*Internal Surface.*—Upon the internal surface is a crucial ridge, which divides the bone into four fossæ; the two superior or cerebral fossæ lodging the posterior lobes of the cerebrum; and the two inferior or cerebellar, the lateral lobes of the cerebellum. The superior arm of the crucial ridge is grooved for the superior longitudinal sinus, and gives attachment to the falx cerebri; the inferior arm is sharp and prominent, for the attachment of the falx cerebelli, and slightly grooved for the two occipital sinuses. The transverse ridge gives attachment to the tentorium cerebelli, and is deeply grooved for the lateral sinuses. At the point of meeting of the four arms is a projection, the *internal occipital protuberance*, which corresponds with the similar process situated upon the external surface of the bone. The convergence of the four grooves forms a slightly depressed fossa, upon which rests the torcular Herophili. In the centre of the

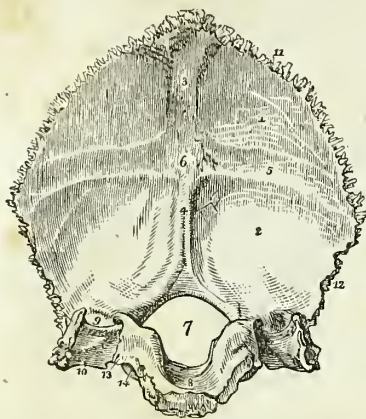
Fig. 22.\*



\* The external surface of the occipital bone. 1. The superior curved line. 2. The external occipital protuberance. 3. The spine. 4. The inferior curved line. 5. The foramen magnum. 6. The condyle of the right side. 7. The posterior condyloid fossa, in which the posterior condyloid foramen is found. 8. The anterior condyloid foramen, concealed by the margin of the condyle. 9. The transverse process; this process upon the internal surface of the bone forms the jugular eminence. 10. The notch in front of the jugular eminence which forms part of the jugular foramen. 11. The basilar process. 12, 12. The rough projections into which the odontoid ligaments are inserted.

basilar portion of the bone is the foramen magnum, oblong in form, and larger behind than before, transmitting the spinal cord, spinal accessory nerves, and vertebral arteries. Upon the lateral margins of the foramen magnum are two rough eminences, which give attachment to the odontoid ligaments, and immediately above these the openings of the anterior condyloid foramina. In front of the foramen magnum is the basilar process, grooved on its surface, for supporting the medulla oblongata, and along each lateral border, for the inferior petrosal sinuses. On each side of the foramen magnum is a groove, for the termination of the lateral sinus; a smooth surface, which forms part of the jugular fossa; and a projecting process, which divides the two, and is called the *jugular eminence*. Into the jugular

Fig. 23.\*



fossa will be seen opening the posterior condyloid foramen.

The *superior borders* are very much serrated, and assist in forming the lambdoidal suture; the *inferior* are rough, but not serrated, and articulate with the mastoid portion of the temporal bone by means of the *aditamentum suturæ lambdoidalis*. The jugular eminence and the side of the basilar process articulate with the petrous portion of the temporal bone, and the intermediate space, which is irregularly notched, forms the posterior boundary of the jugular foramen, or foramen lacerum posterius.

The *angles* of the occipital bone are the superior, inferior, and two lateral. The *superior angle* is received into the interval formed by the union of the posterior and superior angles of the parietal bones, and corresponds with that portion of the fetal head which is called the *posterior fontanelle*. The *inferior angle* is the articular extremity of the basilar process. The *lateral angles* at each side project into that interval formed by the articulation of the posterior and inferior angle of the parietal with the mastoid portion of the temporal bone.

*Development.*—By seven centres; four for the four parts of the expanded portion divided by the crucial ridge, one for each condyle, and one for the basilar process. Ossification commences in the expanded portion of the bone at a period anterior to the vertebræ; at birth the four remaining pieces are distinct; they are united at about the fifth or sixth year. After twenty the basilar process unites with the body of the sphenoid.

\* The internal surface of the occipital bone. 1. The left cerebral fossa. 2. The left cerebellar fossa. 3. The groove for the posterior part of the superior longitudinal sinus. 4. The spine for the falx cerebelli, and groove for the occipital sinuses. 5. The groove for the left lateral sinus. 6. The internal occipital protuberance, the groove on which lodges the torcular Herophili. 7. The foramen magnum. 8. The basilar process, grooved for the medulla oblongata. 9. The termination of the groove for the lateral sinus, bounded externally by the jugular eminence. 10. The jugular fossa; this fossa is completed by the petrous portion of the temporal bone. 11. The superior border. 12. The inferior border. 13. The border which articulates with the petrous portion of the temporal bone, and which is grooved by the inferior petrosal sinus. 14. The anterior condyloid foramen.

*Articulations.*—With six bones; two parietal, two temporal, sphenoid and atlas.

*Attachment of Muscles.*—To thirteen pairs: to the rough surface above the superior curved line, the occipito-frontalis; to the superior curved line, the trapezius and sterno-mastoid; to the rough space between the curved lines, complexus, and splenius capitis; to the space between the inferior curved line and the foramen magnum, the rectus posticus major and minor, and obliquus superior; to the transverse process, the rectus lateralis; and to the basilar process, the rectus anticus major and minor, and superior and middle constrictor muscles.

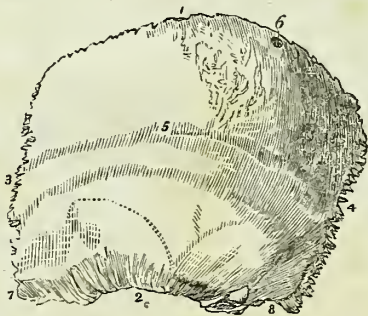**PARIETAL BONE.**—The parietal bone is situated at the side and vertex of the skull; it is quadrilateral in form, and divisible into an external and internal surface, four borders and four angles. The superior border is straight, to articulate with its fellow of the opposite side. The inferior border is arched and thin, to articulate with the temporal bone. The anterior border is concave, and the posterior somewhat convex.

*External surface.*—Crossing the bone in a longitudinal direction from the anterior to the posterior border, is an arched line, the *temporal ridge*, to which the temporal fascia is attached. In the middle of this line, and nearly in the centre of the bone, is the projection called the *parietal eminence*, which marks the centre of ossification. Above the temporal ridge the surface is rough, and covered by the aponeurosis of the occipito-frontalis; below the ridge the bone is smooth (*planum semicirculare*), for the attachment of the fleshy fibres of the temporal muscle. Near the superior border of the bone, and at about one-third from its posterior extremity, is the *parietal foramen*, which transmits a vein to the superior longitudinal sinus. This foramen is often absent.

*Internal surface.*—The internal table is smooth; it is marked by numerous furrows, which lodge the ramifications of the arteria meningea media, and by digital fossæ which correspond with the convolutions of the brain. Along the upper border is part of a shallow groove, completed by the opposite parietal bone, which serves to contain the superior longitudinal sinus. Some slight pits are also observable near this groove, which lodge the glandulæ Pacchioni.

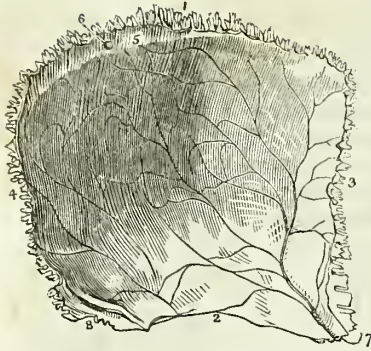The *anterior inferior angle* is thin and lengthened, and articulates with the greater wing of the sphenoid bone. Upon its inner surface it is deeply channelled by a groove for the trunk of the arteria meningea media. This groove is frequently converted into a canal. The *posterior*

Fig. 24.\*



\* The external surface of the left parietal bone. 1. The superior or sagittal border. 2. The inferior or squamous border. 3. The anterior or coronal border. 4. The posterior or lambdoidal border. 5. The temporal ridge; the figure is situated immediately in front of the parietal eminence. 6. The parietal foramen, unusually large in the bone from which this figure was drawn. 7. The anterior inferior angle. 8. The posterior inferior angle.

Fig. 25.\*



*inferior angle* is thick, and presents a broad and shallow groove for the lateral sinus.

*Development.*—By a single centre. Ossification commences at the parietal eminence at the same time with the bodies of the vertebræ.

*Articulations.*—With *five* bones; with the opposite parietal bone, the occipital, frontal, temporal, and sphenoid.

*Attachment of Muscles.*—To *one* only,—the temporal. The occipito-frontalis glides over its upper surface.

**FRONTAL BONE.**—The frontal bone bears some resemblance in form to the under valve of a scallop shell. It is situated at the anterior part of the cranium, forming the forehead, and assists in the construction of the roof of the orbits and nose. Hence it is divisible into a superior or frontal portion, and an inferior or orbito-nasal portion. Each of these portions presents for examination an external and internal surface, borders, and processes.

*External surface.*—At about the middle of each lateral half of the frontal portion is a projection, the *frontal eminence*. Below these points are the *superciliary ridges*, large towards their inner termination, and becoming gradually smaller as they arch outwards: they support the eyebrows. Beneath the superciliary ridges are the sharp and prominent arches which form the upper margin of the orbits, the *supra-orbital ridges*. Externally the supra-orbital ridge terminates in the *external angular process*, and internally in the *internal angular process*; at the inner third of this ridge is a notch, sometimes converted into a foramen, the *supra-orbital notch*, which gives passage to the supra-orbital artery, veins, and nerve. Between the two superciliary ridges is a rough projection, the *nasal tuberosity*; this portion of the bone denotes by its prominence the situation of the frontal sinuses. Extending upwards and backwards from the external angular process is a sharp ridge, the commencement of the *temporal ridge*, and beneath this a depressed surface that forms part of the *temporal fossa*.

The *orbito-nasal portion* of the bone consists of two thin processes, the *orbital plates*, which form the roof of the orbits, and of an intervening notch which lodges the ethmoid bone, and is called the *ethmoidal fissure*. The edges of the ethmoidal fissure are hollowed into cavities, which, by their union with the ethmoid bone, complete the ethmoidal cells: and, crossing these edges transversely, are two small grooves, sometimes canals, which open into the orbit by the anterior and posterior ethmoidal foramina. At the anterior termination of these edges are the irregular openings which

\* The internal surface of the left parietal bone. 1. The superior or sagittal border. 2. The inferior, or squamous border. 3. The anterior, or coronal border. 4. The posterior, or lambdoidal border. 5. Part of the groove for the superior longitudinal sinus. 6. The internal termination of the parietal foramen. 7. The anterior inferior angle of the bone, on which is seen the groove for the trunk of the arteria meningea media. 8. The posterior inferior angle, upon which is seen a portion of the groove for the latera sinus.



lead into the frontal sinuses; and between the two internal angular processes, is a rough excavation which receives the nasal bones, and a projecting process, the *nasal spine*. Upon each orbital plate, immediately beneath the external angular process, is a shallow depression which lodges the lachrymal gland; and beneath the internal angular process a small pit, sometimes a tubercle, to which the cartilaginous pulley of the superior oblique muscle is attached.

*Internal Surface.*—Along the middle line of this surface is a *grooved ridge*, the edges of the ridge giving attachment to the falx cerebri and the groove lodging the superior longitudinal sinus. At the commencement of the ridge is an opening, sometimes completed by the ethmoid bone, the *foramen cæcum*. This opening lodges a process of the dura mater, and occasionally gives passage to a small vein which communicates with the nasal veins. On each side of the vertical ridge are some slight depressions which lodge the glandulæ Pacchioni, and on the orbital plates a number of irregular pits called *digital fossæ*, which correspond with the convolutions of the anterior lobes of the cerebrum. The *superior border*

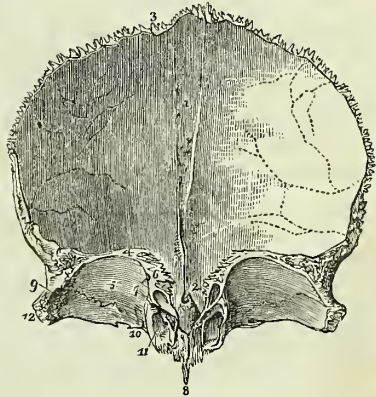
is thick and strongly serrated, bevelled at the expense of the internal table in the middle, where it rests upon the junction of the two parietal, and at the expense of the external table on each side where it receives the lateral pressure of those bones. The *inferior border* is thin, irregular, and squamous, and articulates with the sphenoid bone.

*Development.*—By *two centres*, one for each lateral half. Ossification begins in the orbital arches, somewhat before the vertebræ. The two pieces are separate at birth, and unite by suture during the first year, the suture sometimes remaining permanent

Fig. 26.\*

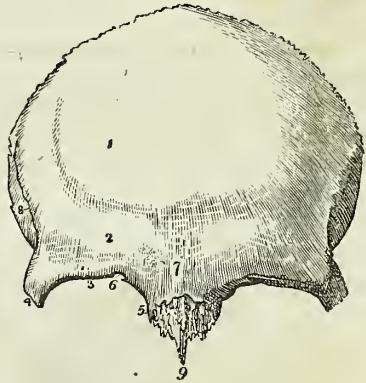

Fig. 27.†



\* The external surface of the frontal bone. 1. The situation of the frontal eminence of the right side. 2. The superciliary ridge. 3. The supra-orbital ridge. 4. The external angular process. 5. The internal angular process. 6. The supra-orbital notch for the transmission of the supra-orbital nerve and artery; in the figure it is almost converted into a foramen by a small spiculum of bone. 7. The nasal tuberosity; the swelling around this point denotes the situation of the frontal sinuses. 8. The temporal ridge, commencing from the external angular process (4). The depression in which the figure 8 is situated is a part of the temporal fossa. 9. The nasal spine.

† The internal surface of the frontal bone; the bone is raised in such a manner as to show the orbito-nasal portion. 1. The grooved ridge for the lodgment of the superior longitudinal sinus and attachment of the falx. 2. The foramen cæcum. 3. The superior

through life. The frontal sinuses make their appearance during the first year, and increase in size until old age.

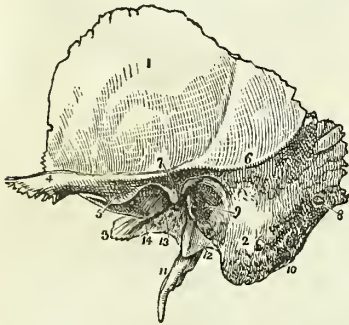
*Articulations.*—With *twelve* bones: the two parietal, the sphenoid, ethmoid, two nasal, two superior maxillary, two lachrymal, and two malar.

*Attachment of Muscles.*—To *two* pairs: corrugator supercillii, and temporal.

**TEMPORAL BONE.**—The temporal bone is situated at the side and base of the skull, and is divisible into a squamous, mastoid, and petrous portion.

The *Squamous portion*, forming the anterior part of the bone, is thin, translucent, and contains no diploë. Upon its *external surface* it is smooth, to give attachment to the fleshy fibres of the temporal muscle,

Fig. 28.



and has projecting from it an arched and lengthened process, the *zygoma*. Near the commencement of the zygoma, upon its lower border, is a projection called the *tubercle*, to which is attached the external lateral ligament of the lower jaw, and continued horizontally inwards from the tubercle, a rounded eminence, the *eminentia articularis*. The process of bone which is continued from the tubercle of the zygoma into the eminentia articularis is the *inferior root* of the zygoma. The *superior root* is continued upwards from the upper border of the zygoma,

and forms the posterior part of the temporal ridge, serving by its projection to mark the division of the squamous from the mastoid portion of the bone; and the *middle root* is continued directly backwards, and terminates abruptly at a narrow fissure, the *fissura Glaseri*. The *internal surface* of the squamous portion is marked by several shallow fossæ, which correspond with the convolutions of the cerebrum, and by a furrow for

or coronal border of the bone; the figure is situated near that part which is bevelled at the expense of the internal table. 4. The inferior border of the bone. 5. The orbital plate of the left side. 6. The cellular border of the ethmoidal fissure. The foramen cæcum (2) is seen through the ethmoidal fissure. 7. The anterior and posterior ethmoidal foramina; the anterior is seen leading into its canal. 8. The nasal spine. 9. The depression within the external angular process (12) for the lachrymal gland. 10. The depression for the pulley of the superior oblique muscle of the eye; immediately to the left of this number is the supra-orbital notch, and to its right the internal angular process. 11. The opening leading into the frontal sinuses: the leading line crosses the internal angular process. 12. The external angular process. The corresponding parts are seen on the other side of the figure.

\* The external surface of the temporal bone of the left side. 1. The squamous portion. 2. The mastoid portion. 3. The extremity of the petrous portion. 4. The zygoma. 5. Indicates the tubercle of the zygoma, and at the same time its anterior root turning inwards to form the eminentia articularis. 6. The superior root of the zygoma, forming the posterior part of the temporal ridge. 7. The middle root of the zygoma, terminating abruptly at the glenoid fissure. 8. The mastoid foramen. 9. The meatus auditorius externus, surrounded by the processus auditorius. 10. The digastric fossa, situated immediately to the inner side of (2) the mastoid process. 11. The styloid process. 12. The vaginal process. 13. The glenoid or Glaserian fissure; the leading line from this number crosses the rough posterior portion of the glenoid fossa. 14. The opening and part of the groove for the Eustachian tube.

the posterior branch of the arteria meningea media. The *superior*, or *squamous border*, is very thin, and bevelled at the expense of the inner surface, so as to overlap the lower and arched border of the parietal bone. The *inferior border* is thick, and dentated to articulate with the spinous process of the sphenoid bone.

The *Mastoid portion* forms the posterior part of the bone; it is thick, and hollowed between its tables into a loose and cellular diploë. Upon its *external surface* it is rough for the attachment of muscles, and contrasts strongly with the smooth and polished-like surface of the squamous portion: every part of this surface is pierced by small foramina, which give passage to minute arteries and veins; one of these openings, oblique in its direction, of large size, and situated near the posterior border of the bone, the *mastoid foramen*, transmits a vein to the lateral sinus. This foramen is not unfrequently situated in the occipital bone. The inferior part of this portion is round and expanded, the *mastoid process*, and excavated in its interior into numerous cells, which form a part of the organ of hearing. In front of the mastoid process, and between the superior and middle roots of the zygoma, is the large oval opening of the *meatus auditorius externus*, surrounded by a rough lip, the *processus auditorius*. Directly to the inner side of, and partly concealed by the mastoid process, is a deep groove, the *digastric fossa*; and a little more internally the *occipital groove*, which lodges the occipital artery. Upon its *internal surface* the mastoid portion presents a broad and shallow groove (*fossa sigmoidea*) for the lateral sinus, and terminating in this groove the internal opening of the mastoid foramen. The *superior border* of the mastoid portion is dentated; and its posterior border, thick and less serrated, articulates with the inferior border of the occipital bone.

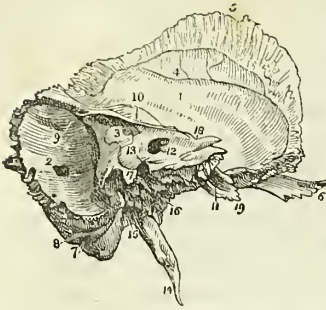The *meatus auditorius externus* is a slightly curved canal, somewhat more than half an inch in length, longer along its lower than its upper wall, and directed obliquely inwards and forwards. The canal is narrower at the middle than at each extremity, is broadest in its horizontal diameter, and terminates upon the outer wall of the tympanum by an abrupt oval border. Within the margin of this border is a groove for the insertion of the membrana tympani.

The *Petrous portion* of the temporal bone is named from its extreme hardness and density. It is a three-sided pyramid, projecting horizontally forwards into the base of the skull, the base being applied against the internal surface of the squamous and mastoid portions, and the apex being received into the triangular interval between the spinous process of the sphenoid and the basilar process of the occipital bone. For convenience of description it is divisible into three surfaces—*anterior*, *posterior*, and *basilar*; and three borders—*superior*, *anterior*, and *posterior*.

*Surfaces.*—The *anterior surface*, forming the posterior boundary of the middle fossa of the interior of the base of the skull, presents for examination from base to apex, first, an *eminence* caused by the projection of the perpendicular semicircular canal; next, a groove leading to an irregular oblique opening, the *hiatus Fallopii*, for the transmission of the petrosal branch of the Vidian nerve; thirdly, another and smaller oblique foramen, immediately beneath the preceding, for the passage of the nervus petrosus superficialis minor, a branch of Jacobson's nerve; and, lastly, a large foramen near the apex of the bone, the termination of the carotid canal.

The *posterior surface* forms the front boundary of the posterior fossa of the base of the skull; near its middle is the oblique entrance of the *meatus auditorius internus*. Above the meatus auditorius internus is a small oblique fissure, and a minute foramen; the former lodges a process of the dura mater, and the foramen gives passage to a small vein. Further outwards, towards the mastoid portion of the bone, is a small slit, almost hidden by a thin plate of bone; this is the *aquæductus vestibuli*, and transmits a small artery and vein of the vestibule and a process of dura mater. Below the meatus, and partly concealed by the margin of the posterior border of the bone, is the *aquæductus cochleæ*,

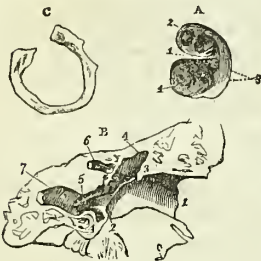
Fig. 29.\*



through which passes a vein from the cochlea to the internal jugular vein, and a process of dura mater.

The *meatus auditorius internus* is about one-third of an inch in depth, and pursues a slightly oblique course in relation to the petrous portion of the temporal bone, but a course directly outwards in relation to the cranium. At the bottom of the meatus, and upon its anterior aspect, is a reniform fossa, the concave border of which is directed towards the entrance of the meatus. The reniform fossa is divided into an upper and lower compartment by a sharp ridge, which is prolonged for some distance upon the anterior wall of the meatus, and sometimes as far as its aperture; in either case it marks the situation of the two nerves, facial and auditory, which constitute the seventh pair, and enter the meatus. Along the convexity of the reniform fossa, and arranged in a curved line from above downwards, are four or

Fig. 30.†



\* The left temporal bone, seen from within. 1. The squamous portion. 2. The mastoid portion. The number is placed immediately above the inner opening of the mastoid foramen. 3. The petrous portion. 4. The groove for the posterior branch of the arteria meningea media. 5. The bevelled edge of the squamous border of the bone. 6. The zygoma. 7. The digastric fossa immediately internal to the mastoid process. 8. The occipital groove. 9. The groove for the lateral sinus. 10. The elevation upon the anterior surface of the petrous bone marking the situation of the perpendicular semi-circular canal. 11. The opening of termination of the carotid canal. 12. The meatus auditorius internus. 13. A dotted line leads upwards from this number to the narrow fissure which lodges a process of the dura mater. Another line leads downwards to the sharp edge which conceals the opening of the aquæductus cochleæ, while the number itself is situated on the bony lamina which overlies the opening of the aquæductus vestibuli. 14. The styloid process. 15. The stylo-mastoid foramen. 16. The carotid foramen. 17. The jugular process. The deep excavation to the left of this process forms part of the jugular fossa, and that to the right is the groove for the eighth pair of nerves. 18. The notch for the fifth nerve upon the upper border of the petrous bone, near its apex. 19. The extremity of the petrous bone which gives origin to the levator palati and tensor tympani muscles.

† A. The reniform fossa of the meatus auditorius internus; right temporal bone. 1. The ridge dividing the reniform fossa into two compartments. 2. The opening of the aquæductus Fallopii. The openings following that of the aquæductus Fallopii in a curved direction require no reference. 3. The cluster of three or four oblique

five openings, the two upper ones being the largest, and occupying the superior compartment of the reniform fossa, and the two or three inferior ones, smaller than the upper, the inferior compartment. Behind the latter, at the distance of a line and a half, and on the posterior wall of the meatus, is a cluster of three or four oblique openings, two of which are minute. The inferior and larger compartment of the reniform fossa presents a well-marked spiral groove, which commences on the convex border of the fossa, immediately below the line of openings above described, and, sweeping round the convexity of the inferior compartment, and becoming deeper as it proceeds, terminates by a small round aperture in the centre of the spire. The uppermost of the openings of the reniform fossa is the aperture of the aquæductus Fallopii, and gives passage to the facial nerve. The rest are cul de sacs, pierced at the bottom by a number of minute foramina for the passage of filaments of the vestibular nerve, while the cluster of three openings on the posterior wall of the meatus are intended for single filaments of the same nerve. The spiral groove corresponds with the base of the cochlea, and being pierced by a number of minute foramina for filaments of the cochlear nerve, is named *tractus spiralis foraminulentus*. The opening in the centre of the spiral impression leads into a canal which occupies the central axis of the modiolus, and is thence called *tubulus centralis modioli*.

The *basilar surface* is rough and irregular, and enters into the formation of the under surface of the base of the skull. Projecting downwards, near its middle, is a long sharp spine, the *styloid process*, occasionally connected with the bone only by cartilage, and lost during ossification, particularly in the young subject. At the base of this process is a rough sheath-like ridge, into which the styloid process appears implanted, the *vaginal process*. In front of the vaginal process is a broad triangular depression, the *glenoid fossa*, bounded in front by the eminentia articularis, behind by the vaginal process, and externally by the rough lip of the processus auditorius.

This fossa is divided transversely by the *glenoid fissure* (fissura Glaseri), which lodges the extremity of the processus gracilis of the malleus, and transmits the laxator tympani muscle, chorda tympani nerve, and anterior tympanic artery. The surface of the fossa in front of this fissure is smooth, to articulate with the condyle of the lower jaw; and that behind the fissure is rough, for the reception of a part of the parotid gland. At the extremity of the inner angle of the glenoid fossa is the foramen of the *Eustachian tube*; and separated from it by a thin lamella of bone, called *processus cochleariformis*, a small canal for the transmission of the tensor tympani muscle. Directly behind, and at the root of the styloid process, is the *stylo-mastoid foramen*, the opening of exit of the facial nerve, and of entrance of the stylo-mastoid artery. Nearer the apex of the bone is a

openings on the posterior wall of the meatus. 4. The spirally-grooved base of the cochlea.

b. A section of the temporal bone, right side, showing the curved direction of the meatus auditorius externus. 1. The edge of the processus auditorius. 2. The groove into which the membrana tympani is inserted. The obliquity of the line from 2 to 3 indicates the oblique termination of the meatus, and the consequent oblique direction of the membrana tympani. 4, 4. The cavity of the tympanum. 5. The opening of the Eustachian tube. 6. Part of the aquæductus Fallopii. 7. Part of the carotid canal.

c. The annulus membranæ tympani or temporal bone of the fœtal skull, right side.

large oval opening, the *carotid foramen*, the commencement of the carotid canal, which lodges the internal carotid artery and the carotid plexus. And between the stylo-mastoid and carotid foramen, in the posterior border, is an irregular excavation forming part of the jugular fossa for the commencement of the internal jugular vein. The proportion of the jugular fossa formed by the petrous portion of the temporal bone is very different in different bones; but in all, the fossa presents a vertical ridge on its inner side, which cuts off a small portion from the rest. The upper part of this ridge forms a spinous projection, which is called the *jugular process*; the groove to the inner side of the ridge lodges the eighth pair of nerves, and the lower part of the ridge is the septum of division between the jugular fossa and the carotid foramen. Upon this portion of the ridge near the posterior margin of the carotid foramen is a small opening leading into a canal, which transmits the tympanic branch (Jacobson's nerve) of the glossopharyngeal nerve. Between the jugular fossa and the stylo-mastoid foramen is another small opening leading into the canal for the passage of the auricular branch of the pneumogastric nerve.

*Borders.* — The *superior border* is sharp, and gives attachment to the tentorium cerebelli. It is grooved for the superior petrosal sinus, and near its extremity is marked by a smooth notch upon which reclines the fifth nerve.

The *anterior border* is grooved for the Eustachian tube, and forms the posterior boundary of the foramen lacerum basis cranii; by its sharp extremity it gives attachment to the tensor tympani and levator palati muscles. The *posterior border* is grooved for the inferior petrosal sinus, and excavated for the jugular fossa; it forms the anterior boundary of the foramen lacerum posterius.

*Development.* — By *five centres*: one for the squamous portion, one for the mastoid process, one for the petrous portion, one for the auditory process, which in the fœtus is a mere bony ring, incomplete superiorly, and serving for the attachment of the membrana tympani, *annulus membranae tympani*; and one for the styloid process. Ossification occurs in these pieces in the following order: in the squamous portion immediately after the vertebræ, then in the petrous, tympanic, mastoid, and styloid. The tympanic ring is united by its extremities to the squamous portion during the last month of intra-uterine life; the squamous, petrous, and mastoid portions are consolidated during the first year; and the styloid some years after birth. It not unfrequently happens that the latter remains permanently separate, or is prolonged by a series of pieces to the os hyoides, and so completes the hyoid arch. The subsequent changes in the bone are the increase of size of the glenoid fossa, the growth of the meatus auditorius externus, the levelling of the surfaces of the petrous portion, and the development of mastoid cells. Traces of the union of the petrous with the squamous portion of the bone are usually perceptible in the adult.

*Articulations.* — With *five bones*: occipital, parietal, sphenoid, inferior maxillary, and malar.

*Attachment of Muscles.* — To *fourteen*: by the squamous portion, to the temporal; by the zygoma, to the masseter; by the mastoid portion, to the occipito-frontalis, splenius capitis, sterno-mastoid, trachelo-mastoid, digastricus and retrahens aurem; by the styloid process, to the stylo-pharyngeus, stylo-hyoideus, stylo-glossus, and two ligaments, the stylo-

hyoid and stylo-maxillary; and by the petrous portion, to the levator palati, tensor tympani, and stapedius.

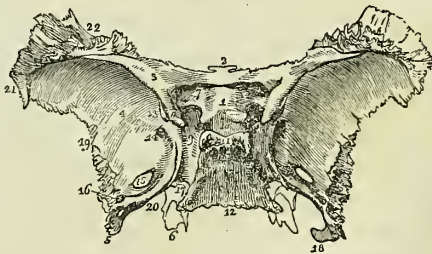
**SPHENOID BONE.** — The sphenoid ( $\sigma\phi\eta\nu$ , a wedge) is an irregular bone situated at the base of the skull, wedged between the other bones of the cranium, and entering into the formation both of the cranium and face. It bears some resemblance, in form, to a bat with its wings extended, and is divisible into body, wings, and processes.

The *body* forms the central mass of the bone, from which the wings and processes are projected. From the upper and anterior part of the body extend on each side two small triangular plates — the lesser wings; from either side and expanding laterally are the greater wings; proceeding backwards from the base of the greater wings, the spinous processes, and downwards, the pterygoid processes.

The *body* presents for examination a superior or cerebral surface, an antero-inferior surface, and a posterior surface.

*Superior Surface.* — At the anterior extremity of this surface is a small projecting plate, the *ethmoidal spine*, and spreading out on either side the lesser wings. Behind the ethmoidal spine in the middle line is a rounded elevation, the *olivary process*, which supports the commissure of the optic nerves; and on either side of the posterior margin of this process is a tubercle, the *middle clinoid process*. Passing outwards and forwards from the olivary process, are the *optic foramina*, which transmit the optic nerves and ophthalmic arteries. Behind the optic foramina are two sharp tubercles, the *anterior clinoid processes*, which are the inner terminations of the lesser wings. Beneath these processes, on the sides of the olivary process, are two depressions\* for the last turn of the internal carotid arteries. Behind the olivary process is the *sella turcica* (ephippium), the deep fossa which lodges the pituitary gland and circular sinus; behind and somewhat overhanging the sella turcica, is a broad rough plate (dorsum ephippii) bounded at each angle by a tubercle, the *posterior clinoid processes*; and behind this plate an inclining surface (clivus Blumenbachii), which is continuous with the basilar process of the occipital bone. On either side of the sella turcica is a broad groove (*carotid*) which lodges the internal carotid artery, the cavernous sinus, and the orbital nerves. Immediately external to this groove, at the junction of the greater wings with the body, are four foramina: the first is a broad interval, the *sphenoidal fissure*, which separates the greater and lesser wings, and transmits the third,

Fig. 31.†



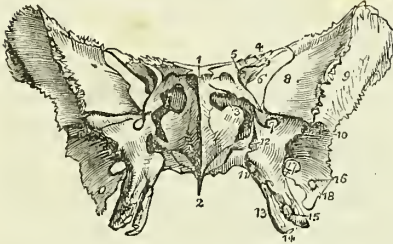
\* These depressions are occasionally, as in a skull before me, converted into foramina by the extension of a short bony pillar from the middle to the anterior clinoid process.

† The superior or cerebral surface of the sphenoid bone. 1. The processus olivaris. 2. The ethmoidal spine. 3. The lesser wing of the left side. 4. The cerebral surface of the greater wing of the same side. 5. The spinous process. 6. The extremity of the pterygoid process of the same side, projecting downwards from the under surface of the body of the bone. 7. The foramen opticum. 8. The anterior clinoid process.

fourth, the three branches of the ophthalmic division of the fifth and the sixth nerves, and the ophthalmic vein. Behind and beneath this fissure is the *foramen rotundum* for the superior maxillary nerve; and still farther back, in the base of the spinous process, the *foramen ovale* for the inferior maxillary nerve, arteria meningea parva, and nervus petrosus superficialis minor. Behind the foramen ovale, near the apex of the spinous process, is the foramen spinosum for the arteria meningea medea.

Upon the *antero-inferior surface* of the sphenoid is a long flattened spine or crest, the superior part of which, *crista sphenoidalis*, articulates with the central lamella of the ethmoid, while the inferior part longer and sharper, the *rostrum sphenoidale*, is intended to be inserted into the sheath formed by the upper border of the vomer. On either side of the crista sphenoidalis is an irregular opening leading into the sphenoidal cells. The sphenoidal cells, which are absent in the young subject, are divided by a median septum which is continuous with the crista, and are partially closed by two thin plates of bone (frequently broken away), the *sphenoidal spongy bones*. On each side of the sphenoidal cells are the outlets of the

Fig. 32.\*



(sometimes a complete canal) converted into a canal by the palate bone, the *pterygo-palatine canal* for the pterygo-palatine artery; and traversing the roots of the pterygoid processes at their union with the body of the

optic foramina, sphenoidal fissures, and foramina rotunda, the lesser and greater wings; and, below, the pterygoid processes. Upon the under surface of the body are two thin plates of bone (*processus vaginales*) proceeding from the base of the pterygoid process at each side, and intended for articulation with the borders of the vomer. On each of these plates, close to the root of the pterygoid process, is a groove

9. The groove by the side of the sella turcica; for lodging the internal carotid artery, cavernous plexus, cavernous sinus, and orbital nerves. 10. The sella turcica; the two tubercles in front of the figure are the middle clinoid processes. 11. The posterior boundary of the sella turcica; its projecting angles are the posterior clinoid processes. 12. The basilar portion of the bone. 13. Part of the sphenoidal fissure. 14. The foramen rotundum. 15. The foramen ovale. 16. The foramen spinosum. 17. The angular interval which receives the apex of the petrous portion of the temporal bone. The posterior extremity of the Vidian canal terminates at this angle. 18. The spine of the spinous process; it affords attachment to the internal lateral ligament of the lower jaw. 19. The border of the greater wing and spinous process, which articulates with the anterior part of the squamous portion of the temporal bone. 20. The internal border of the spinous process, which assists in the formation of the foramen lacerum basis cranii. 21. That portion of the greater ala which articulates with the anterior inferior angle of the parietal bone. 22. The portion of the greater ala which articulates with the orbital process of the frontal bone.

\* The antero-inferior view of the sphenoid bone. 1. The ethmoid spine. 2. The rostrum. 3. The sphenoidal spongy bone, partly closing the left opening of the sphenoidal cells. 4. The lesser wing. 5. The foramen opticum, piercing the base of the lesser wing. 6. The sphenoidal fissure. 7. The foramen rotundum. 8. The orbital surface of the greater wing. 9. Its temporal surface. 10. The pterygoid ridge. 11. The pterygo-palatine canal. 12. The foramen of entrance to the Vidian canal. 13. The internal pterygoid plate. 14. The hamular process. 15. The external pterygoid plate. 16. The foramen spinosum. 17. The foramen ovale. 18. The extremity of the spinous process of the sphenoid.



bone, are the two *pterygoid* or *Vidian* canals, which give passage to the Vidian nerve and artery at each side.

The *posterior surface* is flat and rough, and articulates with the basilar process of the occipital bone. In the adult this union is usually completed by bone; from which circumstance the sphenoid, in conjunction with the occipital, is described by Soemmering and Meckel as a single bone, under the name of *spheno-occipital*. The posterior surface is continuous on each side with the spinous process, and at the angle of union is the termination of the Vidian canal.

The *lesser wings* (processes of Ingrassias) are thin and triangular, the base being attached to the upper and anterior part of the body of the sphenoid, and the apex extended outwards, and terminating in an acute point. The anterior border is irregularly serrated, the posterior being free and rounded, and received into the fissure of Sylvius of the cerebrum. The inner extremity of this border is the anterior clinoid process, which is supported by a short pillar of bone, giving attachment to a part of the common tendon of the muscles of the orbit. The lesser wing forms the posterior part of the roof of the orbit, and its base is traversed by the optic foramen.

The *greater wings* present three surfaces; a superior or cerebral, which forms part of the middle fossa of the base of the skull, an anterior surface which assists in forming the outer wall of the orbit, and an external surface divided into two parts by the *pterygoid ridge*. The superior part of the external surface enters into the formation of the temporal fossa, and the inferior portion forms part of the zygomatic fossa. The pterygoid ridge, dividing the two, gives attachment to the upper origin of the pterygoideus externus muscle.

The *spinous processes* project backwards at each side from the base of the greater wings of the sphenoid, and are received into the angular intervals between the squamous and petrous portions of the temporal bones. Piercing the base of each process is a large oval opening, the *foramen ovale*; nearer its apex a smaller opening, the *foramen spinosum*; and extending downwards from the apex a short spine, which gives attachment to the internal lateral ligament of the lower jaw and to the laxator tympani muscle. The external border of the spinous process is rough, to articulate with the lower border of the squamous portion of the temporal bone; the internal forms the anterior boundary of the foramen lacerum basis cranii, and is somewhat grooved for the reception of the Eustachian tube.

The *pterygoid processes* descend perpendicularly from the base of the greater wings, and form in the articulated skull the lateral boundaries of the posterior nares. Each process consists of an external and internal plate, and an anterior surface. The external plate is broad and thin, giving attachment, by its external surface, to the external pterygoid muscle, and by its internal surface to the internal pterygoid. This plate is sometimes pierced by a foramen, which is not unfrequently formed by a process of communication passing between it and the spinous process. The internal pterygoid plate is long and narrow, and terminated at its extremity by a curved hook, the *hamular process*, around which plays the tendon of the tensor palati muscle. At the base of the internal pterygoid plate is a small oblong depression, the *scaphoid fossa*, from which arises the circumflexus or tensor palati muscle. The interval between the two

pterygoid plates is the *pterygoid fossa*; and the two plates are separated inferiorly by an angular notch (*palatine*), which receives the tuberosity, or *pterygoid process*, of the palate bone. The anterior surface of the pterygoid process is broad near its base, and supports Meckel's ganglion. The base of the process is pierced by the Vidian canal.

*Development.*—By *twelve* centres: four for the body, viz. two for its anterior (spheno-orbital), and two for its posterior part (spheno-temporal); four for the four wings; two for the internal pterygoid plates, and two for the sphenoidal spongy bones. Ossification commences in the various pieces of the sphenoid in the following order:—greater alæ, at about the same time with the other bones of the cranium; lesser alæ and posterior body, at the end of the second month; anterior body at the end of the third; internal pterygoid plate and spongy bones, between the period of birth and the second year. Osseous union occurs first between the centres for the posterior body, and at about the same time between each centre of the anterior body and its corresponding (lesser) ala; the third union takes place between the internal pterygoid plate and the greater ala; the fourth between the two centres of the anterior body, and at the same time between the anterior and posterior body. This is the state of union at birth, the bone consisting of five centres, one being the body and lesser alæ; one, on each side, the great ala and internal pterygoid plate; and the remaining two the sphenoidal spongy bones. The greater alæ unite with the body during the first year; the spongy bones after puberty; and the body of the sphenoid with the basilar process of the occipital bone between eighteen and twenty-five.

*Articulations.* —With *twelve* bones; that is, with all the bones of the head, and five of the face, viz. the two malar, two palate, and the vomer.

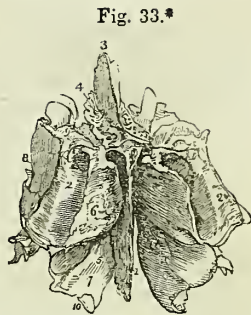
*Attachment of Muscles.*—To *twelve* pairs: temporal, external pterygoid, internal pterygoid, superior constrictor, tensor palati, laxator tympani, levator palpebræ, obliquus superior, superior rectus, internal rectus, inferior rectus, and external rectus.

**ETHMOID BONE.**—The ethmoid (*ἠθμοῖδης*, a sieve) is a square-shaped cellular bone, situated between the two orbits, at the root of the nose, and perforated upon its upper surface by a number of small openings, from which peculiarity it has received its name. It consists of a perpendicular lamella and two lateral masses.

The *perpendicular lamella* is a thin central plate, which articulates with the vomer and cartilage of the septum, and assists in forming the septum of the nose. It is surmounted superiorly by a thick and strong process, the *crista galli*, which projects into the cavity of the skull, and gives attachment to the falx cerebri. From the base of the anterior border of this process there project forward two small plates, *alar processes*, which are received into corresponding depressions in the frontal bone, and often complete posteriorly the foramen cæcum. On each side of the *crista galli*, upon the upper surface of the bone, is a thin and grooved plate perforated by a number of small openings, the *cribriform lamella*, which supports the bulb of the olfactory nerve, and gives passage to its filaments, and to the nasal branch of the ophthalmic nerve. In the middle of the groove of this lamella the foramina pierce the bone completely, but at either side they are the apertures of canals, which run for some distance in the substance of the central lamella, inner wall of the lateral mass, and spongy

bones. The opening for the nasal nerve is a narrow slit in the anterior part of the cribriform lamella, close to the crista galli. The cribriform lamella serves to connect the lateral masses with the perpendicular plate.

The *lateral masses* (labyrinthi) are divisible into an internal and external surface, and four borders, superior, inferior, anterior, and posterior. The *internal surface* is rough and slightly convex, and forms the external boundary of the upper part of the nasal fossæ. Towards the posterior border of this surface is a narrow horizontal fissure, the *superior meatus* of the nose, the upper margin of which is thin, and somewhat curled inwards; hence it is named the *superior turbinated bone* (concha superior). Below the meatus is the convex surface of another thin plate, which is curled outwards, and forms the lower border of the mass, the *middle turbinated bone* (concha media). The *external surface* is quadrilateral and smooth, hence it is named *os planum*, and, from its thinness, lamina papyracea; it enters into the formation of the inner wall of the orbit.



The *superior border* is irregular and cellular, the cells being completed by the edges of the ethmoidal fissure of the frontal bone. This border is crossed by two grooves, sometimes complete canals, opening into the orbit by the anterior and posterior ethmoidal foramina. The *inferior border* is formed internally by the lower border of the middle turbinated bone, and externally by a concave irregular fossa, the upper boundary of the middle meatus. The *anterior border*, presents a number of incomplete cells, which are closed by the superior maxillary and lachrymal bone; and the *posterior border* is regularly cellular, to articulate with the sphenoid and palate bones.

The lateral masses are composed of cells, which are divided by a thin partition into anterior and posterior ethmoidal cells. The anterior, the most numerous, communicate with the frontal sinuses, and open by means of an irregular and incomplete tubular canal, the *infundibulum*, into the middle meatus. The posterior cells, fewer in number, open into the superior meatus.

*Development.*—By three centres: one for each lateral mass, and one for the perpendicular lamella. Ossification commences in the lateral masses at about the beginning of the fifth month, appearing first in the os planum and then in the spongy bones. During the latter half of the first year after birth, the central lamella and lamina cribrosa begin to ossify, and are united to the lateral masses by the beginning of the second year. The cells of the ethmoid are developed in the course of the fourth and fifth year.

\* The ethmoid bone seen from above and behind. 1. The central lamella. 2. 2. The lateral masses; the numbers are placed on the posterior border of the lateral mass at each side. 3. The crista galli process. 4. The cribriform plate of the left side, pierced by its foramina. 5. The hollow space immediately above and to the left of this number is the superior meatus. 6. The superior turbinated bone. 7. The middle turbinated bone; the numbers 5, 6, 7, are situated upon the internal surface of the left lateral mass, near its posterior part. The interval between these parts is the superior meatus. 8. The external surface of the lateral mass, or os planum. 9. The superior or frontal border of the lateral mass, grooved by the anterior and posterior ethmoidal canals. 10. Refers to the concavity of the middle turbinated bone, which is the upper boundary of the middle meatus.

*Articulations.*—With *thirteen* bones: two of the cranium,—the frontal and sphenoid; the rest of the face, viz. the nasal, superior maxillary, lachrymal, palate, the inferior turbinated, and the vomer.

No muscles are attached to this bone.

#### BONES OF THE FACE.

The face is composed of fourteen bones; viz. the

|                         |                          |
|-------------------------|--------------------------|
| Two nasal,              | Two palate,              |
| Two superior maxillary, | Two inferior turbinated, |
| Two lachrymal,          | Vomer,                   |
| Two malar,              | Inferior maxillary.      |

**NASAL BONES.**—The nasal (fig. 39) are two small quadrangular bones, forming by their union the bridge and base of the nose. Upon the upper surface they are convex, and pierced by a foramen for a small artery; on the under surface they are somewhat concave, and marked by a groove, which lodges the nasal branch of the ophthalmic nerve. The superior border is narrow and thick, the inferior broad, thin, and irregular.

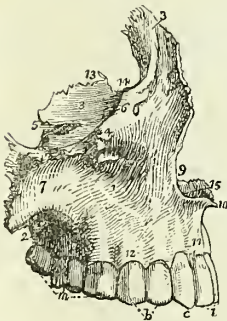
*Development.*—By a *single* centre for each bone, the first ossific deposition making its appearance at the same time as in the vertebræ.

*Articulations.*—With *four* bones: frontal, ethmoidal, nasal, and superior maxillary.

*Attachment of Muscles.*—It has in relation with it the pyramidalis nasi, and compressor nasi; but neither of these muscles is inserted into it.

**SUPERIOR MAXILLARY BONES.**—The superior maxillary are the largest bones of the face, with the exception of the lower jaw; they form, by their union, the whole of the upper jaw, and assist in the construction of the nose, the orbit, the cheek, and the palate. Each bone is divisible into a body and four processes.

Fig. 34.\*



The *body* is triangular in form, and hollowed in its interior into a large cavity, the *antrum maxillare* (antrum of Highmore). It presents for examination four surfaces, external or facial, internal or nasal, posterior or zygomatic, and superior or orbital.

The *external*, or *facial surface*, forms the anterior part of the bone; it is irregularly concave, and presents a deep depression towards its centre, the *canine fossa*, which gives attachment to two muscles, the *compressor nasi* and *levator anguli oris*. Immediately above this fossa is the *infra-orbital foramen*, the termination of the infra-orbital canal, transmitting the superior maxillary nerve and infra-orbital artery; and above the infra-orbital foramen,

\* The superior maxillary bone of the right side, as seen from the lateral aspect. 1. The external or facial surface; the depression in which the figure is placed is the canine fossa. 2. The posterior, or zygomatic surface. 3. The superior or orbital surface. 4. The infra-orbital foramen; it is situated immediately below the number. 5. The infra-orbital canal, leading to the infra-orbital foramen. 6. The inferior border of the orbit. 7. The malar process. 8. The nasal process. 9. The concavity forming the lateral boundary of the anterior nares. 10. The nasal spine. 11. The incisive, or myrtiliform fossa. 12. The alveolar process. 13. The internal border of the orbital surface, which articulates with the ethmoid and palate bone. 14. The concavity which articulates with

the lower margin of the orbit, continuous externally with the rough articular surface of the malar process, and internally with a thick ascending plate, the nasal process. Towards the middle line of the face this surface is bounded by the concave border of the opening of the nose, which is projected forwards at its inferior termination into a sharp process, forming, with a similar process of the opposite bone, the *nasal spine*. Beneath the nasal spine, and above the two superior incisor teeth, is a slight depression, the *incisive*, or *myrtiform fossa*, which gives origin to the depressor labii superioris *alæque nasi* muscle. The myrtiform fossa is divided from the canine fossa by a perpendicular ridge, corresponding with the direction of the root of the canine tooth. The inferior boundary of the facial surface is the alveolar process which contains the teeth of the upper jaw; and it is separated from the zygomatic surface by a strong projecting eminence, the malar process.

The *internal*, or *nasal surface*, presents a large irregular opening, leading into the antrum maxillare; this opening is nearly closed in the articulated skull by the ethmoid, palate, lachrymal, and inferior turbinated bones. The cavity of the antrum is somewhat triangular, corresponding in shape with the form of the body of the bone. Upon its inner wall are numerous grooves, lodging branches of the superior maxillary nerve, and projecting into its floor several conical processes, corresponding with the roots of the first and second molar teeth. In front of the opening of the antrum is the strong ascending plate of the nasal process, marked inferiorly by a rough horizontal ridge (*crista turbinalis inferior*), which gives attachment to the inferior turbinated bone. The concave depression immediately above this ridge corresponds with the middle meatus of the nose, and that below the ridge with the inferior meatus. Between the nasal process and the opening of the antrum, is a deep vertical groove (*sulcus lachrymalis*) which is converted into a canal by the lachrymal and inferior turbinated bone, and constitutes the nasal duct. The *superior border* of the nasal surface is irregularly cellular, and articulates with the lachrymal and ethmoid bone; the *posterior border* is rough, and articulates with the palate bone; the *anterior border* is sharp, and forms the free margin of the opening of the nose; and from the *inferior border* projects inwards a strong horizontal plate, the palate process.

The *posterior surface* may be called *zygomatic*, from forming part of the zygomatic fossa; it is bounded externally by the malar process, and internally by a rough and rounded border, the *tuberosity*, which is pierced by a number of small foramina (*foramina alveolaria posteriora*), giving passage to the posterior dental nerves and branches of the superior dental artery. The lower part of this tuberosity presents a rough oval surface, to articulate with the palate bone, and immediately above and to the inner side of this articular surface a smooth groove, which forms part of the posterior palatine canal. The *superior border* is smooth and rounded to form the lower boundary of the spheno-maxillary fissure, and is marked by a notch, the commencement of the infra-orbital canal. The *inferior boundary* is the alveolar process, containing the last two molar teeth.

The *orbital surface* is triangular and thin, and constitutes the floor of the orbit. It is bounded internally by an irregular edge, which articulates

the lachrymal bone, and forms the commencement of the nasal duct. 15. The *crista nasalis* of the palate process. *i*. The two incisor teeth. *c*. The canine. *b*. The two bicuspids. *m*. The three molares.

with the palate, ethmoid, and lachrymal bone; posteriorly, by the smooth border which enters into the formation of the spheno-maxillary fissure; and, anteriorly, by a convex margin, partly smooth and partly rough, the smooth portion forming part of the lower border of the orbit, and the rough articulating with the malar bone. The middle of this surface is channelled by a deep groove and canal, the infra-orbital, which terminates at the infra-orbital foramen; and near the root of the nasal process is a slight depression, marking the origin of the inferior oblique muscle of the eyeball.

The four processes of the superior maxillary bone are the nasal, malar, alveolar, and palate.

The *nasal process* ascends by the side of the nose, to which it forms the lateral boundary, and articulates with the frontal and nasal bone. By its external surface it gives attachment to the levator labii superioris aëque nasi, and to the orbicularis palpebrarum muscle. Its internal surface contributes to form the inner wall of the nares, and is marked transversely by a horizontal ridge (*crista turbinalis superior*) which divides it into two portions, one above the ridge, irregular and uneven, for giving attachment to and completing the cells of the lateral mass of the ethmoid; the other below, smooth and concave, corresponding with the middle meatus. The posterior border is thick, and hollowed into a groove for the nasal duct. The margin of the nasal process, which is continuous with the lower border of the orbit, is sharp and marked by a small *tubercle* which serves as a guide to the introduction of the knife in the operation for fistula lachrymalis.

The *malar process*, large and irregular, is situated at the angle of separation between the facial and zygomatic surfaces, and presents a triangular surface for articulation with the malar bone.

The *alveolar process* forms the lower margin of the bone; it is spongy and cellular in texture, and excavated into deep holes for the reception of eight teeth.

The *palate process* is thick and strong, and projects horizontally inwards from the inner surface of the body of the bone. Superiorly, it is concave and smooth, and forms the floor of the nares; inferiorly, it is also concave but uneven, and assists in the formation of the roof of the palate. This surface is marked by a deep groove, which lodges the posterior palatine nerve and artery. Its internal edge is raised into a ridge (*crista nasalis*), which, with a corresponding ridge in the opposite bone, forms a groove for the reception of the vomer. The prolongation of this ridge forwards beyond the level of the facial surface of the bone is the *nasal spine*. At the anterior extremity of its nasal surface is a foramen, which leads into a canal formed conjointly by the two superior maxillary bones, the anterior palatine canal. The termination of this canal is situated immediately behind the incisor teeth, hence it is also named the incisive foramen. Associated with the incisive openings and canal are two smaller canals, the naso-palatine, which transmit the naso-palatine nerves. These canals are situated in the walls of the incisive canal, and terminate inferiorly in that canal, either by separate openings or conjoined.

*Development.*—By four centres: one for the anterior part of the palate, and incisive portion of the alveolar process (the permanence of this piece constitutes the intermaxillary bone of animals); one for that portion of the bone lying internally to the infra-orbital canal and foramen; one for that

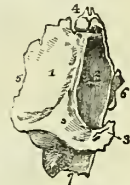portion lying externally to the infra-orbital groove and canal; and one for the palate process. The superior maxillary bone is one of the earliest to show signs of ossification, this process beginning in the alveolar process, and being associated with the early development of teeth. The early development of the alveolar process, and the consequent fusion at this point of the original pieces, explains the difficulties which have been felt by anatomists in determining the precise number of the ossifying centres of this bone.

*Articulations.*—With *nine* bones; viz. with two of the cranium, and with all the bones of the face, excepting the inferior maxillary. These are, the frontal and ethmoid; nasal, lachrymal, malar, inferior turbinated, palate, vomer, and its fellow of the opposite side.

*Attachment of Muscles.*—To *nine*; orbicularis palpebrarum, obliquus inferior oculi, levator labii superioris alæque nasi, levator labii superioris proprius, levator anguli oris, compressor nasi, depressor labii superioris alæque nasi, buccinator, masseter.

**LACHRYMAL BONES** (*os unguis*, from an imagined resemblance to a finger-nail).—The lachrymal is a thin oval-shaped plate of bone, situated at the anterior and inner angle of the orbit. It may be divided into an external and internal surface and four borders. The *external surface* is smooth and marked by a vertical ridge, the lachrymal crest, into two portions, one of which is flat and enters into the formation of the orbit, hence may be called the orbital portion; the other is concave, and lodges the lachrymal sac, hence, the lachrymal portion. The crest is expanded inferiorly into a hook-shaped process (*hamulus lachrymalis*), which forms part of the outer boundary of the fossa lachrymalis. The *internal surface* is uneven, and completes the anterior ethmoid cells; it assists also in forming the wall of the nasal fossæ and nasal duct. The four borders articulate with adjoining bones.

Fig. 35.\*



*Development.*—By a single centre, appearing in the early part of the third month.

*Articulations.*—With *four* bones: two of the cranium, frontal and ethmoid; and two of the face, superior maxillary and inferior turbinated bone.

*Attachment of Muscles.*—To *one* muscle, the tensor tarsi, and to an expansion of the tendo oculi, the former arising from the orbital surface, the other being attached to the lachrymal crest.

**MALAR BONES** (*mala*, the cheek).—The malar (fig. 39) is the strong quadrangular bone which forms the prominence of the cheek. It is divisible into an external and internal surface and four processes, the frontal, orbital, maxillary, and zygomatic. The *external surface* is smooth and convex, and pierced by several small openings which give passage to filaments of the temporo-malar nerve and minute arteries. The *internal surface* is

\* The lachrymal bone of the right side, viewed upon its external or orbital surface. 1. The orbital portion of the bone. 2. The lachrymal portion; the prominent ridge between these two portions is the crest. 3. The lower termination of the crest, the hamulus lachrymalis. 4. The superior border which articulates with the frontal bone. 5. The posterior border, which articulates with the ethmoid bone. 6. The anterior border, which articulates with the superior maxillary bone. 7. The border which articulates with the inferior turbinated bone.

concave, partly smooth and partly rough; smooth where it forms part of the temporal fossa, and rough where it articulates with the superior maxillary bone.

The *frontal process* ascends perpendicularly to form the outer border of the orbit, and to articulate with the external angular process of the frontal bone. The *orbital process* is a thick plate, which projects inwards from the frontal process, and unites with the great ala of the sphenoid to constitute the outer wall of the orbit. It is pierced by several small foramina, for the passage of the temporo-malar filaments of the superior maxillary nerve. The *maxillary process* is broad, and articulates with the superior maxillary bone. The *zygomatic process*, narrower than the rest, projects backwards to unite with the zygoma of the temporal bone.

*Development.*—By a single centre; in rare instances, by two or three. In many animals the malar bone is permanently divided into two portions, orbital and malar. Ossification commences in the malar bone soon after the vertebræ.

*Articulations.*—With *four* bones: three of the cranium, frontal, temporal, and sphenoid; and one of the face, the superior maxillary bone.

*Attachment of Muscles.*—To *five*: levator labii superioris proprius, zygomaticus minor and major, masseter, and temporal.

**PALATE BONES.**—The palate bones are situated at the posterior part of the nares, where they enter into the formation of the palate, the side of the nose, and the posterior part of the floor of the orbit; hence they might, with great propriety, be named the palato-naso-orbital bones. Each bone resembles, in general form, the letter L, and is divisible into a horizontal plate, a perpendicular plate, and a pterygoid process or tuberosity.

The *horizontal plate* is quadrilateral; and presents two surfaces, one superior, which enters into the formation of the floor of the nares, the other inferior, forming the posterior part of the hard palate. The *superior surface* is concave, and rises towards the middle line, where it unites with its fellow of the opposite side and forms part of a crest (*crista nasalis*), which articulates with the vomer. The *inferior surface* is uneven, and marked by a slight transverse ridge, to which is attached the tendinous expansion of the tensor palati muscle. Near its external border are two openings, one large and one small, the *posterior palatine foramina*; the former transmits the

Fig. 36.\*



\* A posterior view of the right palate bone in its natural position; it is slightly turned on one side, to obtain a sight of the internal surface of the perpendicular plate (2). 1. The horizontal plate of the bone; its upper or nasal surface. 2. The perpendicular plate; its internal or nasal surface. 3, 10, 11. The pterygoid process or tuberosity. 4. The thick internal border of the horizontal plate, which, articulating with the similar border of the opposite bone, forms the *crista nasalis* for the reception of the vomer. 5. The pointed process, which, with a similar process of the opposite bone, forms the palate spine. 6. The horizontal ridge which gives attachment to the inferior turbinate bone; the concavity below this ridge enters into the formation of the inferior meatus, and the concavity (7) above the ridge into that of the middle meatus. 7. The sphenopalatine notch. 8. The orbital portion. 9. The *crista turbinalis superior* for the middle turbinate bone. 10. The middle facet of the tuberosity, which enters into the formation of the pterygoid fossa. The facets 11 and 3 articulate with the two pterygoid plates, 11 with the internal, and 3 with the external.



posterior palatine nerve and artery, and the latter the middle palatine nerve. The posterior border is concave, and presents at its inner extremity a sharp point, which, with a corresponding point in the opposite bone, constitutes the *palate spine* for the attachment of the azygos uvulae muscle.

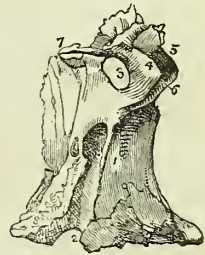
The *perpendicular plate* is also quadrilateral; and presents two surfaces, one internal or nasal, forming a part of the wall of the nares; the other external, bounding the sphenomaxillary fossa and antrum. The *internal surface* is marked near its middle by a horizontal ridge (*crista turbinalis inferior*), to which is united the inferior turbinated bone; and, at about half an inch above this is another ridge (*crista turbinalis superior*) for the attachment of the middle turbinated bone. The concave surface below the inferior ridge is the lateral boundary of the inferior meatus of the nose; that between the two ridges corresponds with the middle meatus, and the surface above the superior ridge with the superior meatus. The *external surface*, extremely irregular, is rough on each side for articulation with neighbouring bones, and smooth in the middle to constitute the inner boundary of the sphenomaxillary fossa. This smooth surface terminates inferiorly in a deep groove, which being completed by the tuberosity of the superior maxillary bone and pterygoid process of the sphenoid, forms the *posterior palatine canal*.

Near the upper part of the perpendicular plate is a large oval notch completed by the sphenoid, the *spheno-palatine foramen*, which transmits the spheno-palatine nerves and artery, and serves to divide the upper extremity of the bone into two portions, an anterior or orbital, and a posterior or sphenoidal portion. The *orbital portion* is hollow within, and presents five surfaces externally, three articular, and two free; the three articular are the anterior, which looks forward and articulates with the superior maxillary bone, the internal with the ethmoid, and the posterior with the sphenoid. The free surfaces are the superior or orbital, which forms the posterior part of the floor of the orbit, and the external, which looks into the sphenomaxillary fossa.

The *sphenoidal portion*, much smaller than the orbital, has three surfaces, two lateral and one superior. The external lateral surface enters into the formation of the sphenomaxillary fossa; the internal lateral forms part of the lateral boundary of the nares; and the superior surface articulates with the under part of the body of the sphenoid bone, and assists the sphenoidal spongy bones in closing the sphenoidal sinuses. This portion takes part in the formation of the pterygo-palatine canal.

The *pterygoid process* or *tuberosity* of the palate bone is the thick and rough process which stands backwards from the angle of union of the

Fig. 37.\*



\* The perpendicular plate of the palate bone seen upon its external or sphenomaxillary surface. 1. The rough surface of this plate, which articulates with the superior maxillary bone and bounds the antrum. 2. The posterior palatine canal, completed by the tuberosity of the superior maxillary bone and pterygoid process. The rough surface to the left of the canal (2) articulates with the internal pterygoid plate. 3. The sphenopalatine notch. 4, 5, 6. The orbital portion of the perpendicular plate. 4. The sphenomaxillary facet of this portion; 5, its orbital facet; 6, its maxillary facet, to articulate with the superior maxillary bone. 7. The sphenoidal portion of the perpendicular plate. 8. The pterygoid process or tuberosity of the bone.

horizontal with the perpendicular portion of the bone. It is received into the angular fissure, which exists between the two plates of the pterygoid process at their inferior extremity, and presents three surfaces: one concave and smooth, which forms part of the pterygoid fossa; and one at each side to articulate with the pterygoid plates. The anterior face of this process is rough, and articulates with the superior maxillary bone.

*Development.*—By a single centre, which appears in the angle of union between the horizontal and perpendicular portion, at the same time with ossification in the vertebræ.

*Articulations.*—With *six* bones: two of the cranium, the sphenoid and ethmoid; and four of the face, the superior maxillary, inferior turbinated bone, vomer, and the palate bone of the opposite side.

*Attachment of muscles.*—To *four*: the tensor palati, azygos uvulæ, internal and external pterygoid.

**INFERIOR TURBINATED BONES.**—The inferior turbinated or spongy bone, is a thin layer of light and porous bone, attached to the crista turbinalis inferior of the inner wall of the nares, and projecting inwards towards the septum narium. The inferior turbinated bone is broad in front, narrow and tapering behind, and slightly curled upon itself, so as to bear some resemblance to one valve of a bivalve shell, hence its designation *concha inferior*. The bone presents for examination a convex and a concave surface, and a superior and an inferior border. The *convex surface* looks inwards and upwards, and forms the inferior boundary of the middle meatus naris; it is marked by several longitudinal grooves for branches of the sphenopalatine nerve and artery. The *concave surface* looks downwards and outwards, and constitutes the roof of the inferior meatus. The *superior border* is irregular; it is attached to the crista turbinalis inferior of the superior maxillary bone in front, to the same crest on the palate bone behind, and between those attachments gives off two, and sometimes three, thin and laminated processes. The most anterior of these processes, *processus lachrymalis*, articulates with the lachrymal bone, and assists in completing the nasal duct. The middle process, *processus maxillaris*, descends and assists in closing the antrum maxillare; while the posterior, *processus ethmoidalis*, which is often wanting, ascends towards the ethmoid bone, and also takes part in the closure of the antrum maxillare. The *inferior border* is rounded, and thicker than the rest of the bone.

*Development.*—By a single centre, which appears at about the middle of the first year.

It affords no attachment to muscles.

*Articulations.*—With *four* bones: the ethmoid, superior maxillary, lachrymal, and palate.

**VOMER.**—The vomer is a thin, quadrilateral, plate of bone, forming the posterior and inferior part of the septum of the nares.

The *superior border* is broad and expanded, to articulate, in the middle, with the under surface of the body of the sphenoid, and on each side with the *processus vaginalis* of the pterygoid process. The anterior part of this border is hollowed into a sheath for the reception of the rostrum of the sphenoid. The *inferior border* is thin and irregular, and is received into the grooved summit of the crista nasalis. The *posterior border* is sharp and free, and forms the posterior division of the two nares. The *anterior*

*border* is more or less deeply grooved for the reception of the central lamella of the ethmoid and the cartilage of the septum. This groove is an indication of the early constitution of the bone of two lamellæ, united at the inferior border. The vomer not unfrequently presents a convexity to one or the other side, generally, it is said, to the left.

*Development.*—By a single centre, which makes its appearance at the same time with those of the vertebrae. Ossification begins from below and proceeds upwards. At birth, the vomer presents the form of a trough, in the concavity of which the cartilage of the septum nasi is placed; it is this disposition which subsequently enables the bone to embrace the rostrum of the sphenoid.

The vomer has no muscles attached to it.

*Articulations.*—With *six* bones: the sphenoid, ethmoid, two superior maxillary, and two palate bones, and with the cartilage of the septum.

**INFERIOR MAXILLARY BONE.**—The *lower* jaw is the arch of bone which contains the inferior teeth; it is divisible into a horizontal portion or body, and a perpendicular portion, the ramus, at each side.

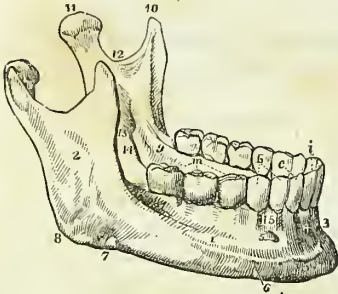
Upon the *external surface* of the *body* of the bone, at the middle line, and extending from between the two first incisor teeth to the chin, is a slight ridge, *crista mentalis*, which indicates the point of conjunction of the lateral halves of the bone in the young subject, the *symphysis*. Immediately external to this ridge is a depression which gives origin to the depressor labii inferioris muscle; and, corresponding with the root of the lateral incisor tooth, another depression, the *incisive fossa*, for the levator labii inferioris. Further outwards is an oblique opening, the *mental foramen*, for the exit of the inferior dental nerve and artery; and below this foramen is the commencement of an oblique ridge which runs upwards and outwards to the base of the coronoid process and gives attachment to the depressor anguli oris, platysma myoides, and buccinator muscle. Near the posterior part of this surface is a rough impression made by the masseter muscle; and immediately in front of this impression, a groove may occasionally be seen for the facial artery. The projecting tuberosity at the posterior extremity of the lower jaw, at the point where the body and ramus meet, is the *angle*.

Upon the *internal surface* of the *body* of the bone, at the symphysis, are two small pointed tubercles; immediately beneath these, two other tubercles, less marked and pointed; beneath them a ridge, and beneath the ridge two rough depressions of some size. These four points give attachment, from above downwards, to the genio-hyo-glossi, genio-hyoidei, part of the mylo-hyoidei, and to the digastric muscles. Running outwards into the body of the bone from the above ridge is a prominent line, the *mylo-hyoidean ridge*, which gives attachment to the mylo-hyoideus muscle, and by its extremity to the pterygo-maxillary ligament and superior constrictor muscle. Immediately above the ridge, and by the side of the symphysis, is a smooth concave surface, which corresponds with the sublingual gland; and below the ridge, and more externally, a deeper fossa for the submaxillary gland.

The *superior border* of the body of the bone is the alveolar process, furnished in the adult with alveoli for sixteen teeth. The *inferior border* or base is rounded and smooth; thick and everted in front to form the chin, and thin behind where it merges into the angle of the bone.

The *ramus* is a strong square-shaped process, differing in direction at various periods of life; thus, in the fœtus and infant, it is almost parallel with the body; in youth it is oblique, and it gradually approaches the vertical direction until manhood; in old age, after the loss of the teeth, it again declines and assumes the oblique direction. Upon its external surface it is rough, for the attachment of the masseter muscle; and at the junction of its posterior border with the body of the bone is a rough tuberosity, the *angle* of the lower jaw, which gives attachment by its inner margin to the stylo-maxillary ligament.

Fig. 38.\*



The upper extremity of the ramus presents two processes, separated by a concave sweep, the *sigmoid notch*. The anterior is the *coronoid process*; it is sharp and pointed, and gives attachment by its inner surface to the temporal muscle. The anterior border of the coronoid process is grooved at its lower part for the buccinator muscle. The posterior process is the *condyle* of the lower jaw, which is flattened from before backwards, oblique in direction, and smooth upon its upper surface, to articulate with the glenoid cavity of the temporal bone. The constriction around the base of the condyle is its *neck*, into which is inserted the external pterygoid muscle. The sigmoid notch is crossed by the masseteric artery and nerve.

The *internal surface* of the ramus is marked near its centre by a large oblique foramen, the *inferior dental*, for the entrance of the inferior dental artery and nerve into the dental canal. Bounding this opening is a sharp margin, to which is attached the internal lateral ligament, and passing downwards from the opening a narrow groove which lodges the mylo-hyoidean nerve with a small artery and vein. To the uneven surface above, and in front of the inferior dental foramen, is attached the temporal muscle, and to that below it the internal pterygoid. The internal surface of the neck of the condyle gives attachment to the external pterygoid muscle; and the angle to the stylo-maxillary ligament.

*Development.*—By two centres: one for each lateral half, the two sides meeting at the symphysis, where they become united. The lower jaw is the earliest of the bones of the skeleton to exhibit ossification, with the exception of the clavicle; ossific union of the symphysis takes place during the first year.

*Articulations.*—With the glenoid fossæ of the two temporal bones, through the medium of a fibro-cartilage.

*Attachment of Muscles.*—To fourteen pairs: by the external surface, commencing at the symphysis and proceeding outwards,—levator labii inferioris, depressor labii inferioris, depressor anguli oris, platysma myoides,

\* The lower jaw. 1. The body. 2. The ramus. 3. The symphysis. 4. The fossa for the depressor labii inferioris muscle. 5. The mental foramen. 6. The external oblique ridge. 7. The groove for the facial artery; the situation of the groove is marked by a notch in the bone a little in front of the number. 8. The angle. 9. The extremity of the mylo-hyoidean ridge. 10. The coronoid process. 11. The condyle. 12. The sigmoid notch. 13. The inferior dental foramen. 14. The mylo-hyoidean groove. 15. The alveolar process. *i.* The middle and lateral incisor tooth of one side. *z.* The canine tooth. *b.* The two bicuspides. *m.* The three molares.

buccinator, and masseter; by the internal surface, also commencing at the symphysis, the genio-hyo-glossus, genio-hyoideus, mylo-hyoideus, digastricus, superior constrictor, temporal, external pterygoid, and internal pterygoid.

Table showing the Points of Development, Articulations, and Attachment of Muscles, of the Bones of the Head.

|                     | Development. | Articulations. | Attachment of Muscles. |
|---------------------|--------------|----------------|------------------------|
| Occipital . . . . . | 7 . . . . .  | 6 . . . . .    | 13 pairs.              |
| Parietal . . . . .  | 1 . . . . .  | 5 . . . . .    | 1 muscle.              |
| Frontal . . . . .   | 2 . . . . .  | 12 . . . . .   | 2 pairs.               |
| Temporal . . . . .  | 5 . . . . .  | 5 . . . . .    | 14 muscles.            |
| Sphenoid . . . . .  | 12 . . . . . | 12 . . . . .   | 12 pairs.              |
| Ethmoid . . . . .   | 3 . . . . .  | 13 . . . . .   | none.                  |
| Nasal . . . . .     | 1 . . . . .  | 4 . . . . .    | none.                  |
| Superior maxillary  | 4 . . . . .  | 9 . . . . .    | 9 muscles.             |
| Lachrymal . . . . . | 1 . . . . .  | 4 . . . . .    | 1 ib.                  |
| Malar . . . . .     | 1 . . . . .  | 4 . . . . .    | 5 ib.                  |
| Palate . . . . .    | 1 . . . . .  | 6 . . . . .    | 4 ib.                  |
| Inferior turbinated | 1 . . . . .  | 4 . . . . .    | none.                  |
| Vomer . . . . .     | 1 . . . . .  | 6 . . . . .    | none.                  |
| Lower jaw . . . . . | 2 . . . . .  | 2 . . . . .    | 14 pairs.              |

#### SUTURES.

The bones of the cranium and face are connected with each other by means of sutures (*sutura*, a seam), of which there are four principal varieties—serrated, squamous, harmonia, and schindylesis.

The *serrated suture* is formed by the union of two borders possessing serrated edges, as in the coronal, sagittal, and lambdoid sutures. In these sutures the serrations are formed almost wholly by the external table, the edges of the internal table lying merely in apposition.

The *squamous suture* (*squama*, a scale) is formed by the overlapping of the bevelled edges of two contiguous bones, as in the articulation between the temporal and the lower border of the parietal. In this suture the approximated surfaces are roughened, so as to adhere mechanically with each other.

The *harmonia suture* (*ἁρμόσις*, to adapt) is the simple apposition of contiguous surfaces, the surfaces being more or less rough and retentive. This suture is seen in the connection between the superior maxillary bones, or of the palate processes of the palate bones with each other.

The *schindylesis suture* (*σχινδύλησις*, a fissure) is the reception of one bone into a sheath or fissure of another, as occurs in the articulation of the rostrum of the sphenoid with the vomer, or of the latter with the perpendicular lamella of the ethmoid, and with the crista nasalis of the superior maxillary and palate bones.

The serrated suture is formed by the interlocking of the radiating fibres along the edges of the flat bones of the cranium during growth. When this process is retarded in the infant by over-distension of the head, as in hydrocephalus, and sometimes without any such apparent cause, distinct ossific centres are developed in the interval between the edges; and, being surrounded by the suture, from independent pieces, which are called *ossa*

*triquetra*, or ossa Wormiana. In the lambdoid suture there is generally one or more of these bones; and in a beautiful adult hydrocephalic skeleton, in the possession of Mr. Liston, there are upwards of one hundred.

The *coronal suture* (fig. 39) extends transversely across the vertex of the skull, from the upper part of the greater wing of the sphenoid of one side to the same point on the opposite side; it connects the frontal with the parietal bones. In the formation of this suture the edges of the articulating bones are bevelled, so that the parietal rest upon the frontal at each side, and in the middle the frontal rests upon the parietal bones; they thus afford each other mutual support in the consolidation of the skull.

The *sagittal suture* (fig. 39) extends longitudinally backwards along the vertex of the skull, from the middle of the coronal to the apex of the lambdoid suture. It is very much serrated, and serves to unite the two parietal bones. In the young subject, and sometimes in the adult, this suture is continued through the middle of the frontal bone to the root of the nose, under the name of the frontal suture. Ossa triquetra are sometimes found in the sagittal suture.

The *lambdoid suture* is named from some resemblance to the Greek letter  $\Lambda$ , consisting of two branches, which diverge at an acute angle from the extremity of the sagittal suture. This suture connects the occipital with the parietal bones. At the posterior and inferior angle of the parietal bones, the lambdoid suture is continued onwards in a curved direction into the base of the skull, and serves to unite the occipital bone with the mastoid portion of the temporal, under the name of *additamentum suturæ lambdoidalis*. It is in the lambdoid suture that ossa triquetra occur most frequently.

The *squamous suture* (fig. 39) unites the squamous portion of the temporal bone with the greater ala of the sphenoid, and with the parietal, overlapping the lower border of the latter. The portion of the suture which is continued backwards from the squamous portion of the bone to the lambdoid suture, and connects the mastoid portion with the posterior inferior angle of the parietal, is the *additamentum suturæ squamosæ*.

The *additamentum suturæ lambdoidalis*, and *additamentum suturæ squamosæ*, constitute together the *mastoid suture*.

Across the upper part of the face is an irregular suture, the *transverse*, which connects the frontal bone with the nasal, superior maxillary, lachrymal, ethmoid, sphenoid, and malar bones. The remaining sutures are too unimportant to deserve particular names or description.

#### REGIONS OF THE SKULL.

The skull, considered as a whole, is divisible into four regions: a superior region, or vertex; a lateral region; an inferior region, or base; and an anterior region, the face.

The **SUPERIOR REGION**, or vertex of the skull, is bounded anteriorly by the frontal eminences; on each side by the temporal ridges and parietal eminences; and behind by the superior curved line of the occipital bone and occipital protuberance. It is crossed transversely by the coronal suture, and marked from before backwards by the sagittal, which terminates posteriorly in the lambdoid suture. Near the posterior extremity of the region, and on each side of the sagittal suture, is the parietal foramen.

Upon the *inner* or *cerebral surface* of this region is a shallow groove, extending along the middle line from before backwards, for the superior

Fig. 39.\*

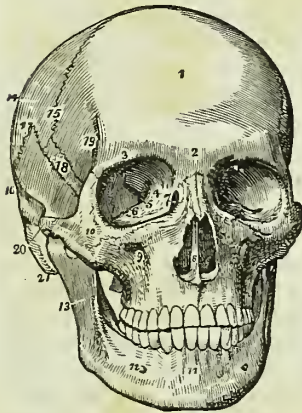
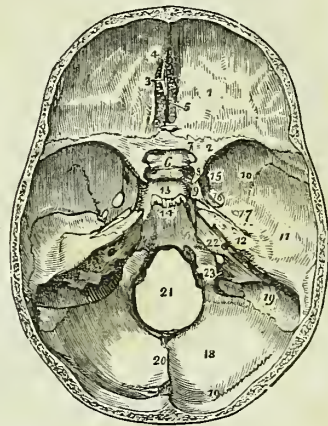


Fig. 40.†



longitudinal sinus; on either side of this groove are several small fossæ for the Pacchionian bodies, and further outwards, digital fossæ corresponding with the convexities of the convolutions, and numerous ramified markings for lodging the branches of the arteria meningea media.

The LATERAL REGION of the skull is divisible into three portions; temporal, mastoid, and zygomatic.

The *temporal portion*, or *temporal fossa*, is bounded above and behind by the temporal ridge, in front by the external angular process of the

\* A front view of the skull. 1. The frontal portion of the frontal bone. The 2, immediately over the root of the nose, refers to the nasal tuberosity; the 3, over the orbit, to the supra-orbital ridge. 4. The optic foramen. 5. The sphenoidal fissure. 6. The spheno-maxillary fissure. 7. The lachrymal fossa in the lachrymal bone, the commencement of the nasal duct. The figures 4, 5, 6, 7, are within the orbit. 8. The opening of the anterior nares, divided into two parts by the vomer; the number is placed upon the latter. 9. The infra-orbital foramen. 10. The malar bone. 11. The symphysis of the lower jaw. 12. The mental foramen. 13. The ramus of the lower jaw. 14. The parietal bone. 15. The coronal suture. 16. The temporal bone. 17. The squamous suture. 18. The upper part of the great ala of the sphenoid bone. 19. The commencement of the temporal ridge. 20. The zygoma of the temporal bone, assisting to form the zygomatic arch. 21. The mastoid process.

† The cerebral surface of the base of the skull. 1. One side of the anterior fossa; the number is placed on the roof of the orbit, formed by the orbital plate of the frontal bone. 2. The lesser wing of the sphenoid. 3. The crista galli. 4. The foramen cæcum. 5. The cribriform lamella of the ethmoid. 6. The processus olivaris. 7. The foramen opticum. 8. The anterior clinoid process. 9. The carotid groove upon the side of the sella turcica, for the internal carotid artery and cavernous sinus. 10, 11, 12. The middle fossa of the base of the skull. 10. Marks the great ala of the sphenoid. 11. The squamous portion of the temporal bone. 12. The petrous portion of the temporal. 13. The sella turcica. 14. The basilar portion of the sphenoid and occipital bone (clivus Blumenbachii). The uneven ridge between Nos. 13, 14, is the dorsum ephippii, and the prominent angles of this ridge the posterior clinoid processes. 15. The foramen rotundum. 16. The foramen ovale. 17. The foramen spinosum; the small irregular opening between 17 and 12 is the hiatus Fallopii. 18. The posterior fossa of the base of the skull. 19, 19. The groove for the lateral sinus. 20. The ridge upon the occipital bone, which gives attachment to the falx cerebelli. 21. The foramen magnum. 22. The meatus auditorius internus. 23. The jugular foramen.

frontal bone and by the malar bone, and below by the zygoma. It is formed by part of the frontal, great wing of the sphenoid, parietal, squamous portion of the temporal, malar bone, and zygoma, and lodges the temporal muscle with the deep temporal arteries and nerves.

The *mastoid portion* is rough, for the attachment of muscles. Upon its posterior part is the mastoid foramen, and below, the mastoid process. In front of the mastoid process is the external auditory foramen, surrounded by the external auditory process; and in front of this foramen the glenoid cavity, bounded above by the middle root of the zygoma and in front by its tubercle.

The *zygomatic portion* or *fossa* is the irregular cavity below the zygoma, bounded in front by the superior maxillary bone, internally by the external pterygoid plate, above by part of the great wing of the sphenoid and squamous portion of the temporal bone, and by the temporal fossa, and externally by the zygomatic arch and ramus of the lower jaw. It contains the external pterygoid, with part of the temporal and internal pterygoid muscle, and the internal maxillary artery and inferior maxillary nerve, with their branches. On the inner and upper side of the zygomatic fossa are two fissures, the spheno-maxillary and the pterygo-maxillary. The *spheno-maxillary fissure* is horizontal in direction, opens into the orbit, and is situated between the great ala of the sphenoid and the superior maxillary bone. It is completed externally by the malar bone. The *pterygo-maxillary fissure* is vertical, and descends at right angles from the extremity of the preceding. It is situated between the pterygoid process and the tuberosity of the superior maxillary bone, and transmits the internal maxillary artery. At the angle of junction of these two fissures is a small space, the *spheno-maxillary fossa*, bounded by the sphenoid, palate, and superior maxillary bone. In this space are seen the openings of five foramina,—the foramen rotundum, spheno-palatine, pterygo-palatine, posterior palatine, and Vidian. The spheno-maxillary fossa lodges Meckel's ganglion and the termination of the internal maxillary artery.

The BASE OF THE SKULL presents an internal or cerebral, and an external or basilar surface.

The *cerebral surface* is divisible into three parts, which are named the anterior, middle, and posterior fossa of the base of the cranium. The *anterior fossa* is somewhat convex on each side, where it corresponds with the roofs of the orbits; and concave in the middle, in the situation of the ethmoid bone and the anterior part of the body of the sphenoid. The latter and the lesser wings constitute its posterior boundary. It supports the anterior lobes of the cerebrum. In the middle line of this fossa, at its anterior part, is the *crista galli*; immediately in front of this process, the *foramen cæcum*; and on each side the *cribriform plate*, with its *foramina*, for the transmission of the filaments of the olfactory and nasal branch of the ophthalmic nerve. Farther back in the middle line is the *processus olivaris*, and on the sides of this process the *optic foramina*, *anterior* and *middle clinoid processes*, and vertical *grooves* for the internal carotid arteries.

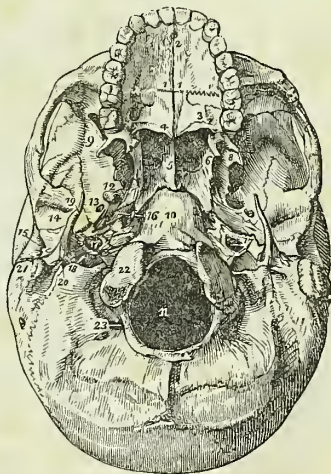
The *middle fossa* of the base, deeper than the preceding, is bounded in front by the lesser wing of the sphenoid; behind, by the petrous portion of the temporal bone; and is divided into two lateral parts by the sella turcica. It is formed by the posterior part of the body, great ala, and spinous process of the sphenoid, and by the petrous and squamous portion



of the temporal bones. In the centre of this fossa is the *sella turcica*, which lodges the pituitary gland, bounded in front by the *anterior* and *middle*, and behind by the *posterior clinoid processes*. On each side of the *sella turcica* is the *carotid groove* for the internal carotid artery, the cavernous plexus of nerves, the cavernous sinus, and the orbital nerves; and a little farther outwards the following foramina, from before backwards:—*sphenoidal fissure* (foramen lacerum anterius), for the transmission of the third, fourth, three branches of the ophthalmic division of the fifth, and the sixth nerve, and ophthalmic vein; *foramen rotundum*, for the superior maxillary nerve; *foramen ovale*, for the inferior maxillary nerve, arteria meningea parva, and nervus petrosus superficialis minor; *foramen spinosum*, for the arteria meningea media; *foramen lacerum basis cranii*, which gives passage to the internal carotid artery, carotid plexus, and petrosal branch of the Vidian nerve. On the anterior surface of the petrous portion of the temporal bone is a groove, leading to a fissured opening, the *hiatus Fallopii*, for the petrosal branch of the Vidian nerve; and, immediately beneath this, a smaller foramen, for the nervus petrosus superficialis minor. Towards the apex of the petrous portion is the notch for the fifth nerve, and below it a slight depression for the Casserian ganglion. Farther outwards is the eminence which marks the position of the perpendicular semicircular canal. Proceeding from the foramen spinosum, are two grooves which indicate the course of the trunks of the arteria meningea media. The whole fossa lodges the middle lobes of the cerebrum.

The *posterior fossa*, larger than the other two, is formed by the occipital bone, by the petrous and mastoid portion of the temporals, and by a small part of the sphenoid and parietals. It is bounded in front by the upper border of the petrous portion and dorsum ephippii, and along its posterior circumference by the groove for the lateral sinuses; it gives support to the pons Varolii, medulla oblongata, and cerebellum. In the centre of this fossa is the *foramen magnum*, bounded on each side by a rough tubercle, which gives attachment to the odontoid ligament, and by the anterior condyloid foramen. In front of the foramen magnum is the concave surface (clivus Blumenbachii) which supports the medulla oblongata and pons Varolii, and on each side the following foramina, from before backwards:—the *internal auditory foramen*, for the auditory and facial nerve and auditory artery; behind, and externally to this, is a small foramen leading

Fig. 41.\*



\* The external or basilar surface of the base of the skull. 1, 1. The hard palate. The figures are placed upon the palate processes of the superior maxillary bones. 2. The incisive, or anterior palatine foramen. 3. The palate process of the palate bone. The large opening near the figure is the posterior palatine foramen. 4. The palatine spine; the curved line upon which the number rests is the transverse ridge. 5. The vomer, dividing the openings of the posterior nares. 6. The internal pterygoid plate.

into the *aquæductus vestibuli*; and below it, partly concealed by the edge of the petrous bone, the *aquæductus cochleæ*; next, a long fissure, the *foramen lacerum posterius*, or jugular foramen, giving passage externally to the commencement of the internal jugular vein, and internally to the eighth pair of nerves. Converging towards this foramen from behind is the deep groove for the lateral sinus, and from the front the groove for the inferior petrosal sinus.

Behind the foramen magnum is a longitudinal ridge, which gives attachment to the falx cerebelli, and divides the two inferior fossæ of the occipital bone; and above the ridge is the internal occipital protuberance and the transverse groove lodging the lateral sinus.

The *external surface* of the base of the skull is extremely irregular. From before backwards it is formed by the palate processes of the superior maxillary and palate bones; the vomer; pterygoid, spinous processes, and part of the body of the sphenoid; under surface of the squamous, petrous, and mastoid portion of the temporals; and by the occipital bone. The palate processes of the superior maxillary and palate bones constitute the hard palate, which is raised above the level of the rest of the base, and is surrounded by the alveolar processes containing the teeth of the upper jaw. At the anterior extremity of the hard palate, and directly behind the front incisor teeth, is the *anterior palatine* or *incisive foramen*, the termination of the anterior palatine canal, which contains the naso-palatine ganglion, and transmits the anterior palatine nerves. At the posterior angles of the palate are the *posterior palatine foramina*, for the posterior palatine nerves and arteries. Passing inwards from these foramina are the *transverse ridges* to which are attached the aponeurotic expansions of the tensor palati muscles; and at the middle line of the posterior border, the *palate spine*, which gives origin to the azygos uvulæ. The hard palate is marked by a crucial suture, which distinguishes the four processes of which it is composed. Behind, and above the hard palate, are the *posterior nares*, separated by the vomer, and bounded on each side by the pterygoid processes. At the base of the pterygoid processes are the *pterygo-palatine canals*. The internal pterygoid plate is long and narrow, terminated at its apex by the hamular process, and at its base by the scaphoid fossa. The external plate is broad; the space between the two is the pterygoid fossa; it contains part of the internal pterygoid muscle, and the tensor palati. Externally to the external pterygoid plate is the zygomatic fossa. Behind the nasal fossæ, in the middle line, is the under surface of the body of the sphenoid, and the basilar process of the occipital bone, and, still further back, the foramen magnum. At the base of the external pterygoid plate, on each side, is the *foramen ovale*, and behind this the *foramen spinosum* with the prominent spine which gives attachment to the internal lateral ligament of the lower jaw and the laxator tympani muscle. Running outwards from the apex of the spinous process of the sphenoid

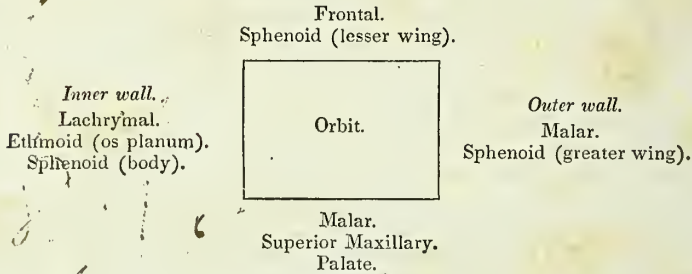
7. The scaphoid fossa. 8. The external pterygoid plate. The interval between 6 and 8 (right side of the figure) is the pterygoid fossa. 9. The zygomatic fossa. 10. The basilar process of the occipital bone. 11. The foramen magnum. 12. The foramen ovale. 13. The foramen spinosum. 14. The glenoid fossa. 15. The meatus auditorius externus. 16. The foramen lacerum anterius basis cranii. 17. The carotid foramen of the left side. 18. The foramen lacerum posterius, or jugular foramen. 19. The styloid process. 20. The stylo-mastoid foramen. 21. The mastoid process. 22. One of the condyles of the occipital bone. 23. The posterior condyloid fossa.

bone, is the fissura Glaseri, which crosses the glenoid fossa transversely, and divides it into an anterior smooth surface, bounded by the eminentia articularis, for the condyle of the lower jaw, and a posterior rough surface for a part of the parotid gland. Behind the foramen ovale and spinosum, is the irregular fissure between the spinous process of the sphenoid bone and the petrous portion of the temporal, the foramen lacerum anterius basis cranii, which lodges the internal carotid artery and Eustachian tube, and in which the carotid branch of the Vidian nerve joins the carotid plexus. Following the direction of this fissure outwards we see the foramen for the Eustachian tube, and that for the tensor tympani muscle, separated from each other by the processus cochleariformis. Behind the fissure is the pointed process of the petrous bone which gives origin to the levator palati muscle, and, externally to this process, the carotid foramen for the transmission of the internal carotid artery and the ascending branch of the superior cervical ganglion of the sympathetic; and behind the carotid foramen, the foramen lacerum posterius and jugular fossa. Externally, and somewhat in front of the latter, is the styloid process, and at its base the vaginal process. Behind and at the root of the styloid process is the stylo-mastoid foramen, for the facial nerve and stylo-mastoid artery, and further outwards the mastoid process. Upon the inner side of the root of the mastoid process is the digastric fossa; and a little farther inwards, the occipital groove. On either side of the foramen magnum, and near its anterior circumference, are the condyles of the occipital bone. In front of each condyle, and piercing its base, is the anterior condyloid foramen for the hypoglossal nerve, and directly behind the condyle the irregular fossa in which the posterior condyloid foramen is situated. Behind the foramen magnum are the two curved lines of the occipital bone, the spine, and the protuberance, with rough surfaces for the attachment of muscles.

The FACE is somewhat oval in contour, uneven in surface, and excavated for the reception of two principal organs of sense,—the eye and the nose. It is formed by part of the frontal bone and by the bones of the face. Superiorly it is bounded by the frontal eminences; beneath these are the superciliary ridges, converging towards the nasal tuberosity; beneath the superciliary ridges are the supra-orbital ridges, terminating externally in the external border of the orbit, and internally in the internal border, and presenting towards their inner third the supra-orbital notch, for the supra-orbital nerve and artery. Beneath the supra-orbital ridges are the openings of the orbits. Between the orbits is the bridge of the nose, over-arching the anterior nares; and on each side of this opening the canine fossa of the superior maxillary bone, the infra-orbital foramen, and still farther outwards the prominence of the malar bone; at the lower margin of the anterior nares is the nasal spine, and beneath this the superior alveolar arch, containing the teeth of the upper jaw. Forming the lower boundary of the face is the lower jaw, containing in its alveolar process the lower teeth, and projecting inferiorly to form the chin; on either side of the chin is the mental foramen. If a perpendicular line be drawn from the inner third of the supra-orbital ridge to the inner third of the body of the lower jaw, it will be found to intersect three openings;—the supra-orbital, infra-orbital, and mental, each giving passage to a facial branch of the fifth nerve.

## ORBITS.

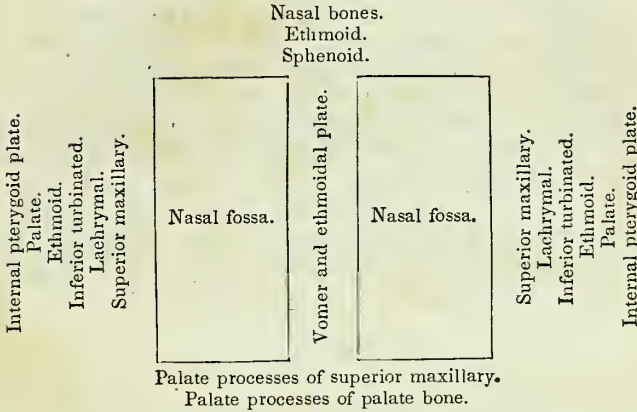
The *orbits* are two quadrilateral hollow cones, situated in the upper part of the face, and intended for the reception of the eye-balls, with their muscles, vessels, and nerves, and the lachrymal glands. The central axis of each orbit is directed outwards, so that the axis of the two, continued into the skull through the optic foramina, would intersect over the middle of the sella turcica. The *superior boundary* of the orbit is formed by the orbital plate of the frontal bone, and by part of the lesser wing of the sphenoid; the *inferior*, by part of the malar bone and by the orbital processes of the superior maxillary and palate bone; the *internal*, by the lachrymal bone, the os planum of the ethmoid, and part of the body of the sphenoid; and the *external*, by the orbital process of the malar bone and the great ala of the sphenoid. These may be expressed more clearly in a tabular form:—



There are *nine* openings communicating with the orbit: the *optic*, for the admission of the optic nerve and ophthalmic artery; the *sphenoidal fissure*, for the transmission of the third, fourth, the three branches of the ophthalmic division of the fifth nerve, the sixth nerve, and the ophthalmic vein; the *spheno-maxillary fissure*, for the passage of the superior maxillary nerve and artery to the opening of entrance of the *infra-orbital canal*; *temporo-malar foramina*—two or three small openings in the orbital process of the malar bone, for the passage of filaments of the orbital branch of the superior maxillary nerve; *anterior and posterior ethmoidal foramina* in the suture between the os planum and frontal bone, the former transmitting the nasal nerve and anterior ethmoidal artery, the latter the posterior ethmoidal artery and vein; the opening of the *nasal duct*; and the *supra-orbital notch* or foramen, for the supra-orbital nerve and artery.

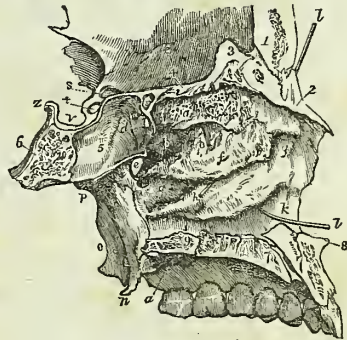
## NASAL FOSSÆ.

The nasal fossæ are two irregular cavities, situated in the middle of the face, and extending from before backwards. They are bounded *above* by the nasal bones, ethmoid, and sphenoid: *below* by the palate processes of the superior maxillary and palate bones; *externally* by the superior maxillary, lachrymal, inferior turbinated, superior and middle turbinated bones of the ethmoid, palate, and internal pterygoid plate of the sphenoid; and the two fossæ are separated by the vomer and the perpendicular lamella of the ethmoid. These may be more clearly expressed in a tabular form:—



Each nasal fossa is divided into three irregular longitudinal passages, or *meatuses*, by three processes of bone, which project from its outer wall, the superior, middle, and inferior turbinated bones; the superior and middle turbinated bones being processes of the ethmoid, and the inferior a distinct bone of the face. The *superior meatus* occupies the superior and posterior part of each fossa; it is situated between the superior and middle turbinated bones, and has opening into it three foramina, viz. the opening of the posterior ethmoid cells, the opening of the sphenoid cells, and the sphenopalatine foramen. The *middle meatus* is the space between the middle and inferior turbinated bones; it also presents three foramina, the open-

Fig. 42.\*



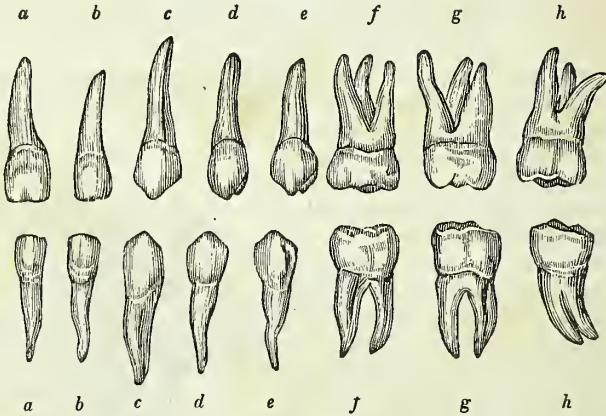
\* A longitudinal section of the nasal fossæ made immediately to the right of the middle line, and the bony septum removed in order to show the external wall of the left fossa. 1. The frontal bone. 2. The nasal bone. 3. The crista galli process of the ethmoid. The groove between 1 and 3 is the lateral boundary of the foramen cæcum. 4. The cribriform plate of the ethmoid. 5. Part of the sphenoidal cells. 6. The basilar portion of the sphenoid bone. Bones 2, 4, and 5, form the superior boundary of the nasal fossa. 7, 7. The articulating surface of the palatine process of the superior maxillary bone. The groove between 7, 7, is the lateral half of the incisive canal, and the dark aperture in the groove the inferior termination of the left naso-palatine canal. 8. The nasal spine. 9. The palatine process of the palate bone. a. The superior turbinate bone, marked by grooves and apertures for filaments of the olfactory nerve. b. The superior meatus. c. A probe passed into the posterior ethmoidal cells. d. The opening of the sphenoidal cells into the superior meatus. e. The sphenopalatine foramen. f. The middle turbinate bone. g, g. The middle meatus. h. A probe passed into the infundibular canal, leading from the frontal sinuses and anterior ethmoid cells; the triangular aperture immediately above the letter is the opening of the maxillary sinus. i. The inferior turbinate bone. k, k. The inferior meatus. l, l. A probe passed up the nasal duct, showing the direction of that canal. The anterior letters g, k, are placed on the superior maxillary bone, the posterior on the palate bone. m. The internal pterygoid plate. n. Its hamular process. o. The external pterygoid plate. p. The situation of the opening of the Eustachian tube. q. The posterior palatine foramina. r. The roof of the left orbit. s. The optic foramen. t. The groove for the last turn of the internal carotid artery converted into a foramen by the development of an osseous communication between the anterior and middle clinoid processes. v. The sella turcica. z. The posterior clinoid process.

ing of the frontal sinuses, of the anterior ethmoid cells, and of the antrum. The largest of the three passages is the *inferior meatus*, which is the space between the inferior turbinated bone and the floor of the fossa; in it there are two foramina, the termination of the nasal duct, and one opening of the anterior palatine canal. The nasal fossæ commence upon the face by a large irregular opening, the anterior nares, and terminate posteriorly in the two posterior nares.

## TEETH.

Man is provided with two successions of teeth; the first are the teeth of childhood, they are called temporary, deciduous, or milk teeth; the second continue until old age, and are named permanent.

Fig. 43.\*



The *permanent teeth* are thirty-two in number, sixteen in each jaw; they are divisible into four classes, — *incisors*, of which there are four in each jaw, two central and two lateral; *canine*, two above and two below; *bicuspid*, four above and four below; and *molars*, six above and six below.

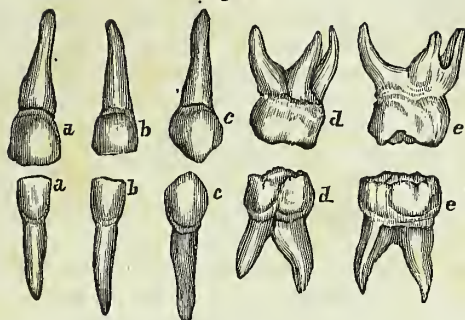
The *temporary teeth* are twenty in number (fig. 44); eight incisors, four canine, and eight molars. The temporary molars have four tubercles, and are succeeded by the permanent bicuspid, which have only two tubercles.

Each tooth is divisible into a *crown*, which is the part apparent above the gum; a constricted portion around the base of the crown, the *neck*, and a *root* or *fang*, which is contained within the alveolus. The root is invested by periosteum, which lines the alveolus, and is then reflected upon the root of the tooth as far as its neck.

The *incisor teeth* (cutting teeth) are named from presenting a sharp and cutting edge, formed at the expense of the posterior surface. The crown is flattened from before backwards, being somewhat convex in front and concave behind; the neck is considerably constricted, and the root compressed from side to side; at its apex is a small opening for the passage of the nerve and artery of the tooth.

\* Permanent teeth. *a.* Central incisor. *b.* Lateral incisor. *c.* Cuspid or canine. *d.* First bicuspid. *e.* Second bicuspid. *f.* First molar. *g.* Second molar. *h.* Third molar or *dens sapientiæ*.

Fig. 44.\*



The *canine teeth* (*cuspidati*) follow the incisors in order from before backwards; two are situated in the upper jaw, one on each side, and two in the lower. The crown is larger than that of the incisors, convex before and concave behind, and tapering to a blunted point. The root is longer than that of all the other teeth, compressed at each side, and marked by a slight groove.

The *bicuspid teeth* (*bicuspidati*, small molars), two on each side in each jaw, follow the canine, and are intermediate in size between them and the molars. The crown is compressed from before backwards, and surmounted by two tubercles, one internal, the other external; the neck is oval: the root compressed, marked on each side by a deep groove, and bifid near its apex. The teeth of the upper jaw have a greater tendency to the division of their roots than those of the lower, and the posterior than the anterior pair.

The *molar teeth* (*multicuspidati*, grinders), three on each side in each jaw, are the largest of the permanent set. The crown is quadrilateral, and surmounted by four tubercles, the neck large and round, and the root divided into several fangs. In the upper jaw the first and second molar teeth have three roots, sometimes four, which are more or less widely separated from each other, two of the roots being external, the other internal. In the lower there are but two roots, which are anterior and posterior; they are flattened from behind forwards, and grooved so as to mark a tendency to division. The third molars, or *dentes sapientiæ*, are smaller than the other two; they present three tubercles on the surface of the crown; and the root is single and grooved, appearing to be made up of four or five fangs compressed together, or partially divided. In the lower jaw the fangs are frequently separated to some distance from each other, and much curved, so as to offer considerable resistance in the operation of extraction.†

*Structure.*—The base of the crown of each tooth is hollowed in its interior into a small cavity which is continuous with a canal passing through the middle of each fang. The cavity and canal, or canals, constitute the *cavitas pulpæ*, and contain a soft cellulo-vascular organ, the *pulp*, which receives its supply of vessels and nerves through the small opening at the apex of each root. Mr. Nasmyth, to whose investigations science is so

\* Temporary teeth. a. Central incisor. b. Lateral incisor. c. Canine. d. First molar. e. Second molar.

† See an excellent practical work, "On the Structure, Economy, and Pathology of the Teeth," by Mr. Lintott.

much indebted for our present knowledge of the intimate structure and development of the teeth, has observed with regard to the pulp, that it is composed of two different tissues, *vascular* and *reticular*; the former being an intricate web of minute vessels terminating in simple capillary loops, the latter a network of nucleated cells in which calcareous salts are gradually deposited, and which by a systematic continuance of that process are gradually converted into ivory. This process naturally takes place at the surface of the pulp, and as the pulp is thus robbed of its cells, new cells are produced by the capillary plexus to supply their place, and be in their turn similarly transformed.

A tooth is composed of three distinct structures, ivory or tooth-bone

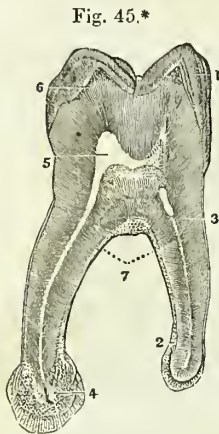


Fig. 45.\*

enamel, and a cortical substance or cementum. The *ivory* consists of very minute, tapering, and branching fibres embedded in a dense homogeneous, interfibrous substance. The fibres commence by their larger ends at the walls of the *cavitas pulpæ* and pursue a radiating and serpentine course towards the periphery of the tooth, where they terminate in ramifications of extreme minuteness. These fibres, heretofore considered to be hollow tubuli, have been shown by Mr. Nasmyth to be rows of minute opaque bodies, arranged in a linear series (baccated fibres, Nasmyth), to be, in fact, the nuclei of the ivory cells, the interfibrous substance being the rest of the cell filled with calcareous matter. In the natural state of the tooth all trace of the parietes or mode of connexion of the cells is lost, but after steeping in weak acid the

cellular network is perfectly distinct.

The *enamel* forms a crust over the whole exposed surface of the crown of the tooth to the commencement of its root; it is thickest over the upper part of the crown, and becomes gradually thinner as it approaches the neck. It is composed of minute hexagonal crystalline fibres, resting by one extremity against the surface of the ivory, and constituting by the other the free surface of the crown. The fibres examined on the face of a longitudinal section have a waving arrangement, and consist, like those of ivory, of cells connected by their surfaces and ends and filled with calcareous substance. When the latter is removed by weak acid, the enamel presents a delicate cellular net-work of animal matter.

The *cortical substance*, or *cementum*, (*substantia ostoidea*,) forms a thin coating over the root of the tooth, from the termination of the enamel to the opening in the apex of the fang. In structure it is analogous to bone, and is characterized by the presence of numerous calcigerous cells and tubuli. The cementum increases in thickness with the advance of age, and gives rise to those exostosed appearances occasionally seen in the teeth of very old persons, or in those who have taken much mercury. In old age the *cavitas pulpæ* is often found filled up and obliterated by

\* Microscopic section of a molar tooth. 1. Enamel with its columns and laminated structure. 2. Cortical substance or cementum on the outside of the fang. 3. Ivory, showing tubuli. 4. Foramen entering the dental cavity from the end of the fang. This fang has a bulbous enlargement in consequence of a hypertrophy of the cementum. 5. Dental cavity. 6. A few osseous corpuscles in the ivory just under the enamel.



osseous substance analogous to the cementum. Mr. Nasmyth has shown that this, like the other structures composing a tooth, is formed of cells having a reticular arrangement.

*Development.*—The development of the teeth in the human subject has been successfully investigated by Mr. Goodsir, to whose interesting researches I am indebted for the following narrative:—\*

The inquiries of Mr. Goodsir commenced as early as the sixth week after conception, in an embryo, which measured seven lines and a half in length and weighed fifteen grains. At this early period each upper jaw presents two semicircular folds around its circumference; the most external is the true lip; the internal, the rudiment of the palate; and between these is a deep groove, lined by the common mucous membrane of the mouth. A little later, a ridge is developed from the floor of this groove in a direction from behind forwards, this is the rudiment of the external alveolus; and the arrangement of the appearances from without inwards at this period is the following:—Most externally and forming the boundary of the mouth, is the *lip*; next we find a *deep groove*, which separates the lip from the future jaw; then comes the *external alveolar ridge*; fourthly, another groove, in which the germs of the teeth are developed, the *primitive dental groove*; fifthly, a rudiment of the *internal alveolar ridge*; and, sixthly, the rudiment of the *future palate* bounding the whole internally. At the seventh week the germ of the first deciduous molar of the upper jaw has made its appearance, in the form of a "simple, free, granular papilla" of the mucous membrane, projecting from the floor of the primitive dental groove; at the eighth week, the papilla of the canine tooth is developed; at the ninth week, the papillæ of the four incisors (the middle preceding the lateral) appear; and at the tenth week the papilla of the second molar is seen behind the anterior molar in the primitive dental groove. So that at this early period, viz. the tenth week, the papillæ or germs of the whole ten deciduous teeth of the upper jaw are quite distinct. Those of the lower jaw are a little more tardy; the papilla of the first molar is merely a slight bulging at the seventh week, and the tenth papilla is not apparent until the eleventh week.

From about the eighth week the primitive dental groove becomes contracted before and behind the first deciduous molar, and laminæ of the mucous membrane are developed around the other papillæ, which increase in growth and enclose the papillæ in follicles with open mouths. At the tenth week the follicle of the first molar is completed, then that of the canine; during the eleventh and twelfth weeks the follicles of the incisors succeed, and at the thirteenth week the follicle of the posterior deciduous molar.

During the thirteenth week the papillæ undergo an alteration of form, and assume the shape of the teeth they are intended to represent. And at the same time small membranous processes are developed from the mouths of the follicles; these processes are intended to serve the purpose of opercula to the follicles, and they correspond in shape with the form of the crowns of the appertaining teeth. To the follicles of the incisor teeth there are two opercula; to the canine, three; and to the molars a number relative to the number of their tubercles, either four or five. Dur

\* "On the Origin and Development of the Pulp and Sacs of the Human Teeth," by John Goodsir, jun., in the *Edinburgh Medical and Surgical Journal*, January, 1839.

ing the fourteenth and fifteenth weeks the opercula have completely closed the follicles, so as to convert them into *dental sacs*, and at the same time the papillæ have become *pulps*.

The deep portion of the primitive dental groove, viz. that which contains the dental sacs of the deciduous teeth, being thus closed in, the remaining portion, that which is nearer the surface of the gum, is still left open, and to this Mr. Goodsir has given the title of *secondary dental groove*; as it serves for the development of all the permanent teeth, with the exception of the anterior molars. During the fourteenth and fifteenth weeks small lunated inflexions of the mucous membrane are formed, immediately to the inner side of the closing opercula of the deciduous dental follicles, commencing behind the incisors and proceeding onwards through the rest; these are the rudiments of the follicles or *cavities of reserve* of the four permanent incisors, two permanent canines, and the four bicuspidæ. As the secondary dental groove gradually closes, these follicular inflexions of the mucous membrane are converted into closed *cavities of reserve*, which recede from the surface of the gum and lie immediately to the inner side and in close contact with the dental sacs of the deciduous teeth, being enclosed in their submucous cellular tissue. At about the fifth month the anterior of these cavities of reserve dilate at their distal extremities, and a fold or papilla projects into their fundus, constituting the rudiment of the germ of the permanent tooth; at the same time two small opercular folds are produced at their proximal or small extremities, and convert them into true dental sacs.

During the fifth month the posterior part of the primitive dental groove behind the sac of the last deciduous tooth has remained open, and in it has developed the papilla and follicle of the first permanent molar. Upon the closure of this follicle by its opercula, the secondary dental groove upon the summit of its crown forms a large cavity of reserve, lying in contact with the dental sac upon the one side and with the gum on the superficial side. At this period the deciduous teeth, and the sacs of the ten anterior permanent teeth, increase so much in size, without a corresponding lengthening of the jaws, that the first permanent molars are gradually pressed backwards and upwards into the maxillary tuberosity in the upper jaw, and into the base of the coronoid process of the lower jaw; a position which they occupy at the eighth and ninth months of foetal life. In the infant of seven or eight months the jaws have grown in length, and the first permanent molar returns to its proper position in the dental range. The cavity of reserve, which has been previously elongated by the upward movement of the first permanent molar, now dilates into the cavity which that tooth has just quitted; a papilla is developed from its fundus, the cavity becomes constricted, and the dental sac of the second molar tooth is formed, still leaving a portion of the great cavity of reserve in connexion with the superficial side of the sac. As the jaws continue to grow in length, the second permanent dental sac descends from its elevated position and advances forwards into the dental range, following the same curve with the first permanent molar. The remainder of the cavity of reserve, already lengthened backwards by the previous position of the second molar, again dilates for the last time, develops a papilla and sac in the same manner with the preceding, and forms the third permanent molar or wisdom tooth, which at the age of nineteen or twenty, upon the

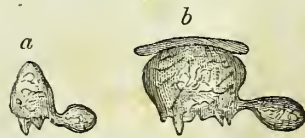increased growth of the jaw, follows the course of the first and second molars into the dental range.

From a consideration of the foregoing phenomena, Mr. Goodsir has divided the process of dentition into three natural stages:—1. follicular; 2. saccular; 3. eruptive. The first, or *follicular stage*, he makes to include all the changes which take place from the first appearance of the dental groove and papillæ to the closure of their follicles; occupying a period which extends from the sixth week to the fourth or fifth month of intra-uterine existence. The second, or *saccular stage*, comprises the period when the follicles are shut sacs, and the included papillæ pulps: it commences at the fourth and fifth months of intra-uterine existence, and terminates for the median incisors, at the seventh or eighth month of infantile life, and for the wisdom teeth at about the twenty-first year. The third, or *eruptive stage*, includes the completion of the teeth, the eruption and shedding of the temporary set, the eruption of the permanent, and the necessary changes in the alveolar processes. It extends from the seventh month till the twenty-first year.

“The *anterior permanent molar*,” says Mr. Goodsir, “is the most remarkable tooth in man, as it forms a transition between the milk and the permanent set.” If considered anatomically, *i. e.* in its development from the primitive dental groove, by a papilla and follicle, “it is decidedly a milk tooth;” if physiologically, “as the most efficient grinder in the adult mouth, we must consider it a permanent tooth.” “It is a curious circumstance, and one which will readily suggest itself to the surgeon, that laying out of view the wisdom teeth, which sometimes decay at an early period from other causes, the anterior molars are the permanent teeth which most frequently give way first, and in the most symmetrical manner and at the same time, and frequently before the milk set.”

*Growth of Teeth.*—Immediately that the dental follicles have been closed by their opercula, the pulps become moulded into the form of the future teeth: and the bases of the molars divided into two or three portions representing the future fangs. The dental sac is composed of two layers, an internal or vascular layer, which was originally a part of the mucous surface of the mouth, and a cellulo-fibrous layer, analogous to the corium of the mucous membrane. Upon the formation of this sac by the closure of the follicle, the mucous membrane resembles a serous membrane in being a shut sac, and may be considered as consisting of a tunica propria, which invests the pulp; and a tunica reflexa, which is adherent by its outer surface with the structures in the jaw, and by the inner surface is free, being separated from the pulp by an intervening cavity. As soon as the moulding of the pulp has commenced, this cavity increases and becomes filled with a gelatinous granular substance, the *enamel organ*, which is adherent to the whole internal surface of the tunica reflexa, but not to the tunica propria and pulp. At the same period, *viz.*, during the fourth or fifth month, a thin lamina of ivory is formed by the pulp, and occupies its most prominent point; if the tooth

Fig. 46.\*



\* *a.* Capsule of a temporary incisor with the rudiment of the corresponding permanent tooth attached. *b.* Capsule of a molar in the same state. A part of the gum is seen above it and in contact.

be incisor or canine, the newly-formed layer has the figure of a small hollow cone; if molar, there will be four or five small cones corresponding with the number of tubercles in its crown. These cones are united by the formation of additional layers, the pulp becomes gradually surrounded and diminishes in size, evolving fresh layers during its retreat into the jaws until the entire tooth with its fangs is completed, and the small *cavitas pulpæ* of the perfect tooth alone remains, communicating through the opening in the apex of each fang with the dental vessels and nerves. The number of roots appears to depend upon the number of nervous filaments sent to each pulp. When the formation of the ivory has commenced, the enamel organ becomes transformed into a laminated tissue, corresponding with the direction of the fibres of the enamel, and the crystalline substance of the enamel is secreted into its meshes by the vascular lining of the sac.

The *cementum* appears to be formed at a later period of life, either by a deposition of osseous substance by that portion of the dental sac, which continues to enclose the fang, and acts as its periosteum, or by the conversion of that membrane itself into bone; the former supposition is the more probable.

The formation of ivory commences in the first permanent molar previously to birth.

*Eruption.*—When the crown of the tooth has been formed and coated with enamel, and the fang has grown to the bottom of its socket by the progressive lengthening of the pulp, the formation of ivory, and the adhesion of the ivory to the contiguous portion of the sac, the pressure of the socket causes the reflected portion of the sac and the edge of the tooth to approach, and the latter to pass through the gum. The sac has thereby resumed\* its original follicular condition, and has become continuous with the mucous membrane of the mouth. The opened sac now begins to shorten more rapidly than the fang lengthens, and the tooth is quickly drawn upwards by the contraction, leaving a space between the extremity of the unfinished root and the bottom of the socket, in which the growth and completion of the fang is more speedily effected.

During the changes which have here been described as taking place among the dental sacs contained within the jaws, the septa between the sacs, which at first were composed of spongy tissue, soon became fibrous, and were afterwards formed of bone, which was developed from the surface and proceeded by degrees more deeply into the jaws, to constitute the alveoli. The sacs of the ten anterior permanent teeth, at first enclosed in the submucous cellular tissue of the deciduous dental sacs, and received

Fig. 47.†



during their growth into crypts situated behind the deciduous teeth, advanced by degrees beneath the fangs of those teeth, and became separated from them by distinct osseous alveoli. The necks of the sacs of the permanent teeth, by which they originally communicated with the mucous lining of the secondary groove, still exist, in the form of minute obliterated cords, separated from the deciduous teeth by their alveolus, but communicating through a minute osseous canal with the fibrous tissue of the palate, immediately behind the corresponding de-

\* Mr. Nasmyth is of opinion that it is "by a process of absorption, and not of disruption, that the tooth is emancipated." *Medico-chirurgical Transactions*. 1839.

† Temporary tooth with the capsule of its permanent successor attached to it by the *gubernaculum dentis*.

ciduous teeth. "These cords and foramina are not obliterated in the child," says Mr. Goodsir, "either because the cords are to become useful as '*gubernacula*' and the canals as '*itineria dentium*;' or, much more probably, in virtue of a law, which appears to be a general one in the development of animal bodies, viz. *that parts, or organs, which have once acted an important part, however atrophied they may afterwards become, yet never altogether disappear, so long as they do not interfere with other parts or functions.*"

*Succession.*—The periods of appearance of the teeth are extremely irregular; it is necessary, therefore, to have recourse to an average, which, for the temporary teeth, may be stated as follows, the teeth of the lower jaw preceding those of the upper by a short interval:—

|                                  |                               |
|----------------------------------|-------------------------------|
| 7th month, two middle incisors.  | 18th month, canine.           |
| 9th month, two lateral incisors. | 24th month, two last molares. |
| 12th month, first molares.       |                               |

The periods for the permanent teeth are,

|                                 |                                    |
|---------------------------------|------------------------------------|
| 6½ year, first molares.         | 10th year, second bicuspides.      |
| 7th year, two middle incisors.  | 11th to 12th year, canine.         |
| 8th year, two lateral incisors. | 12th to 13th year, second molares. |
| 9th year, first bicuspides.     | 17th to 21st year, last molares.   |

## OS HYOIDES.

The *os hyoides* forms the second arch developed from the cranium, and gives support to the tongue, and attachment to numerous muscles in the neck. It is named from its resemblance to the Greek letter  $\nu$ , and consists of a central portion or body, of two larger cornua, which project backwards from the body; and two lesser cornua, which ascend from the angles of union between the body and the greater cornua.

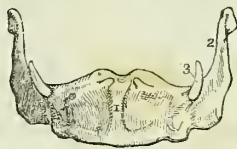The body is somewhat quadrilateral, rough and convex on its antero-superior surface, by which it gives attachment to muscles; concave and smooth on the postero-inferior surface, by which it lies in contact with the thyro-hyoidean membrane. The greater cornua are flattened from above downwards, and terminated posteriorly by a tubercle; and the lesser cornua, conical in form, give attachment to the stylo-hyoid ligaments. In early age and in the adult, the cornua are connected with the body by cartilaginous surfaces and ligamentous fibres; but in old age they become united by bone.

*Development.*—By five centres, one for the body, and one for each cornu. Ossification commences in the greater cornua during the last month of fetal life, and in the lesser cornua and body soon after birth.

*Attachment of Muscles.*—To eleven pairs; sterno-hyoid, thyro-hyoid, omo-hyoid, pulley of the digastricus, stylo-hyoid, mylo-hyoid, genio-hyoid, genio-hyo-glossus, hyo-glossus, lingualis, and middle constrictor of the pharynx. It also gives attachment to the stylo-hyoid, thyro-hyoid, and hyo-epiglottic ligaments, and to the thyro-hyoidean membrane.

\* The *os hyoides* seen from before. 1. The antero-superior, or convex side of the body. 2. The great cornu of the left side. 3. The lesser cornu of the same side. The cornua were ossified to the body of the bone in the specimen from which this figure was drawn.

Fig. 4S.\*



## THORAX AND UPPER EXTREMITY.

The bones of the thorax are the sternum and ribs; and, of the upper extremity, the clavicle, scapula, humerus, ulna and radius, bones of the carpus, metacarpus, and phalanges.

**STERNUM.**—The sternum (fig. 49) is situated in the middle line of the front of the chest, and is oblique in direction, the superior end lying within a few inches of the vertebral column, and the inferior being projected forwards so as to be placed at a considerable distance from the spine. The bone is flat or slightly concave in front, and marked by five transverse lines which indicate its original subdivision into six pieces. It is convex behind, broad and thick above, flattened and pointed below, and is divisible in the adult into three pieces, superior, middle, and inferior.

The *superior piece*, or manubrium, is nearly quadrilateral; it is broad and thick above, where it presents a concave border (*incisura semilunaris*), and narrow at its junction with the middle piece. At each superior angle is a deep articular depression (*incisura clavicularis*) for the clavicle, and on either side two notches, for the articulation of the cartilage of the first rib, and one half of the second.

The *middle piece*, or body, considerably longer than the superior, is broad in the middle, and somewhat narrower at each extremity. It presents at either side six articular notches, for the lower half of the second rib, the four next ribs, and the upper half of the seventh. This piece is sometimes perforated by an opening of various magnitude, resulting from arrest of development.

The *inferior piece* (ensiform or xiphoid cartilage) is the smallest of the three, often merely cartilaginous, and very various in appearance, being sometimes pointed, at other times broad and thin, and at other times again, perforated by a round hole, or bifid. It presents a notch at each side for the articulation of the lower half of the cartilage of the seventh rib.

*Development.*—By a variable number of centres, generally ten, namely, two for the manubrium; one (sometimes two) for the first piece of the body, two for each of the remaining pieces, and one for the ensiform cartilage. Ossification commences towards the end of the fifth month in the manubrium, the two pieces for this part being placed one above the other. At about the same time the centres for the first and second pieces of the body are apparent; the centres for the third piece of the body appear a few months later, and those for the fourth piece soon after birth. The osseous centre for the ensiform cartilage is so variable in its advent, that it may be present at any period between the third and eighteenth year. The double centres for the body of the sternum are disposed side by side in pairs, and it is the irregular union of these pairs in the last three pieces of the body that gives rise to the large aperture occasionally seen in the sternum, towards its lower part. Union of the pieces of the sternum commences from below and proceeds upwards; the fourth and the third unite at about puberty, the third and the second between twenty and twenty-five, and the second and the first between twenty-five and thirty. The ensiform appendix becomes joined to the body of the sternum at forty or fifty years; and the manubrium to the body only in very old age. Two small pisiform pieces have been described by Beclard and Breschet,

as being situated upon and somewhat behind each extremity of the *incisura semilunaris* of the upper border of the manubrium. These pre-sternal or supra-sternal pieces, which are by no means constant, appear at about the thirty-fifth year. Beclard considers them to be the analogue of the *fourchette* of birds, and Breschet as the sternal ends of the cervical rib.

*Articulations.*—With sixteen bones; viz. with the clavicle and the seven true ribs, at each side.

*Attachment of Muscles.*—To nine pairs and one single muscle; viz. to the *pectoralis major*, *sterno-mastoid*, *sterno-hyoid*, *sterno-thyroid*, *triangularis sterni*, *aponeurosis of the obliquus externus, internus, and transversalis muscles, rectus, and diaphragm.*

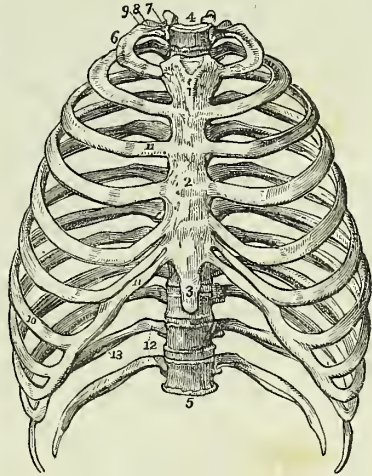
**RIBS.**—The ribs are twelve in number at each side; the first seven are connected with the sternum, and hence named *sternal* or *true ribs*; the remaining five are the *asternal* or *false ribs*; and the last two shorter than the rest, and free at their extremities, are the *floating ribs*. The ribs increase in length from the first to the eighth, whence they again diminish to the twelfth; in breadth they diminish gradually from the first to the last, and with the exception of the last two are broader at the anterior than at the posterior end. The first rib is horizontal in its direction; all the rest are oblique, so that the anterior extremity falls considerably below the posterior. Each rib presents an external and internal surface, a superior and inferior border, and two extremities; it is curved to correspond with the arch of the thorax, and twisted upon itself, so that, when laid on its side, one end is tilted up, while the other rests upon the surface.

The *external surface* is convex, and marked by the attachment of muscles; the *internal* is flat, and corresponds with the pleura; the *superior border* is rounded; and the *inferior* sharp, and grooved upon its inner side, for the attachment of the intercostal muscles.† Near its vertebral extremity, the rib is suddenly bent upon itself; and opposite the bend, upon the external surface, is a rough oblique ridge, which gives attachment to a tendon of the *sacro-lumbalis* muscle, and is called the *angle*. The distance between the vertebral extremity and the angle increases gradually, from the second to the eleventh rib. Beyond the angle is a

\* An anterior view of the thorax. 1. The superior piece of the sternum. 2. The middle piece. 3. The inferior piece, or ensiform cartilage. 4. The first dorsal vertebra. 5. The last dorsal vertebra. 6. The first rib. 7. Its head. 8. Its neck, resting against the transverse process of the first dorsal vertebra. 9. Its tubercle. 10. The seventh or last true rib. 11. The costal cartilages of the true ribs. 12. The last two false ribs or floating ribs. 13. The groove along the lower border of the rib.

† This groove is commonly described as supporting the intercostal artery, vein, and nerve, but this is not the case.

Fig. 49.\*



rough elevation, the *tubercle*; and immediately at the base and under side of the tubercle a smooth surface for articulation with the extremity of the transverse process of the corresponding vertebra. The vertebral end of the rib is somewhat expanded, and is termed the *head*, and that portion between the head and the tubercle is the *neck*. On the extremity of the head is an oval smooth surface, divided by a transverse ridge into two facets, for articulation with two contiguous vertebræ. The posterior surface of the neck is rough, for the attachment of the middle costo-transverse ligament; and upon its upper border is a crest, which gives attachment to the anterior costo-transverse ligament. The sternal extremity is flattened, and presents an oval depression, into which the costal cartilage is received.

The ribs that demand especial consideration are the first, tenth, eleventh, and twelfth.

The *first* is the shortest rib; it is broad and flat, and placed horizontally at the upper part of the thorax, the surfaces looking upwards and downwards, in place of forwards and backwards as in the other ribs. At about the anterior third of the upper surface of the bone, and near its internal border, is a tubercle which gives attachment to the scalenus anticus muscle, and immediately before and behind this tubercle, a shallow oblique groove, the former for the subclavian vein, and the latter for the subclavian artery. Near the posterior extremity of the bone is a thick and prominent tubercle, with a smooth articular surface for the transverse process of the first dorsal vertebra. There is no angle. Beyond the tuberosity is a narrow constricted neck; and at the extremity, a head, presenting a single articular surface. The second rib approaches in some of its characters to the first.

The *tenth* rib has a single articular surface on its head.

The *eleventh* and *twelfth* have each a single articular surface on the head, no neck or tubercle, and are pointed at the free extremity. The eleventh has a slight ridge, representing the angle, and a shallow groove on the lower border; the twelfth has neither.

**COSTAL CARTILAGES.**—The costal cartilages serve to prolong the ribs forwards to the anterior part of the chest, and contribute mainly to the elasticity of the thorax. They are broad at their attachment to the ribs, and taper slightly towards the opposite extremity; they diminish gradually in breadth from the first to the last; in length they increase from the first to the seventh, and then decrease to the last. The cartilages of the first two ribs are horizontal in direction, the rest incline more and more upwards. In advanced age the costal cartilages are more or less converted into bone, this change taking place earlier in the male than in the female.

The first seven cartilages articulate with the sternum; the three next with the lower border of the cartilage immediately preceding, while the last two lie free between the abdominal muscles. All the cartilages of the false ribs terminate by pointed extremities.

*Development.*—The ribs are developed by *three* centres; one for the central part, one for the head, and one for the tubercle. The last two have no centre for the tubercle. Ossification commences in the body somewhat before its appearance in the vertebræ; the epiphysal centres for the head and tubercle appear between sixteen and twenty, and are consolidated with the rest of the bone at twenty-five.



*Articulations.*—Each rib articulates with two vertebræ, and one costal cartilage, with the exception of the first, tenth, eleventh, and twelfth, which articulate each with a single vertebra only.

*Attachment of Muscles.*—To the ribs and their cartilages are attached *twenty-two* pairs, and *one* single muscle. To the *cartilages*, the subclavius, sterno-thyroid, pectoralis major, internal oblique, rectus, transversalis, diaphragm, triangularis sterni, internal and external intercostals. To the *ribs*, the intercostal muscles, scalenus anticus, scalenus posticus, pectoralis minor, serratus magnus, obliquus externus, obliquus internus, latissimus dorsi, quadratus lumborum, serratus posticus superior, serratus posticus inferior, sacro-lumbalis, longissimus dorsi, cervicalis ascendens, levatores costarum, transversalis, and diaphragm.

**CLAVICLE.**—The clavicle is a long bone shaped like the italic letter *f*, and extended across the upper part of the side of the chest from the upper piece of the sternum to the point of the shoulder, where it articulates with the scapula. In position it is very slightly oblique, the sternal end being somewhat lower and more anterior than the scapular, and the curves are so disposed that at the sternal end the convexity, and at the scapular the concavity, is directed forwards. The sternal half of the bone is rounded or irregularly quadrilateral, and terminates in a broad articular surface. The scapular half is flattened from above downwards, and broad at its extremity, the articular surface occupying only part of its extent. The upper surface is smooth and convex, and partly subcutaneous; while the under surface is rough and depressed, for the insertion of the subclavius muscle. At the sternal extremity of the under surface is a very rough prominence, which gives attachment to the rhomboid ligament; and at the other extremity a rough tubercle and ridge, for the coraco-clavicular ligament. The opening for the nutritious vessels is seen upon the under surface of the bone.

*Development.*—By *two* centres; one for the shaft and one for the sternal extremity; the former appearing before any other bone of the skeleton, the latter between fifteen and eighteen.

*Articulations.*—With the sternum and scapula.

*Attachment of Muscles.*—To *six*; the sterno-mastoid, trapezius, pectoralis major, deltoid, subclavius, and sterno-hyoid.

**SCAPULA.**—The *scapula* is a flat triangular bone, situated upon the posterior aspect and side of the thorax occupying the space from the second to the seventh rib. It is divisible into an anterior and posterior surface, superior, inferior, and posterior border, anterior, superior, and inferior angle, and processes.

The *anterior surface* or subscapular fossa, is concave and irregular, and marked by several oblique ridges which have a direction upwards and outwards. The whole concavity is occupied by the subscapularis muscle, with the exception of a small triangular portion near the superior angle. The *posterior surface* or dorsum is convex, and unequally divided into two portions by the spine; that portion above the spine is the supra-spinous fossa; and that below, the infra-spinous fossa.

The *superior border* is the shortest of the three: it is thin and concave, and terminated at one extremity by the superior angle, and at the other by the coracoid process. At its inner termination, and formed partly by the

base of the coracoid process, is the supra-scapular notch, for the transmission of the supra-scapular nerve.

The *inferior* or *axillary border* is thick, and marked by several grooves and depressions; it terminates superiorly at the glenoid cavity, and inferiorly at the inferior angle. Immediately below the glenoid cavity is a rough ridge, which gives origin to the long head of the triceps muscle. Upon the posterior surface of the border is a depression for the teres minor; and upon its anterior surface a deeper groove for the teres major; near the inferior angle is a projecting lip, which increases the surface of origin of the latter muscle.

The *posterior border*, or *base*, the longest of the three, is turned towards the vertebral column. It is intermediate in thickness between the superior and inferior, and convex, being considerably inflected outwards towards the superior angle.

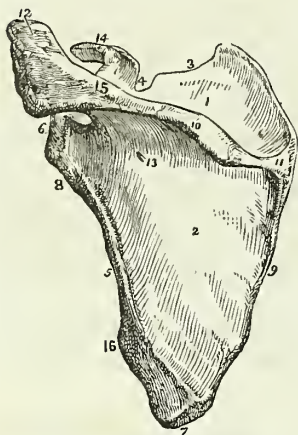
The anterior angle is the thickest part of the bone, and forms the *head* of the scapula; it is immediately surrounded by a constricted portion, the *neck*. The head presents a shallow pyriform articular surface, the *glenoid cavity*, having the pointed extremity upwards; and at its apex is a rough depression, which gives attachment to the long tendon of the biceps. The superior angle is thin and pointed. The inferior angle is thick, and smooth upon the external surface for the origin of the teres major and for a large bursa over which the upper border of the latissimus dorsi muscle plays.

The *spine* of the scapula, triangular in form, crosses the upper part of its dorsum; it commences at the posterior border by a smooth triangular surface over which the trapezius glides upon a bursa, and terminates at the point of the shoulder in the acromion process. The upper border of the spine is rough and subcutaneous, and gives attachment by two projecting lips to the trapezius and deltoid muscles; the surfaces of the spine enter into the formation of the supra and infra-spinous fossæ. The nutritious foramina of the scapula are situated in the base of the spine.

The *acromion* is somewhat triangular and flattened from above downwards; it overhangs the glenoid cavity, the upper surface being rough and subcutaneous, the lower smooth and corresponding with the shoulder-joint. Near its extremity, upon the anterior border, is an oval articular surface, for the end of the clavicle.

The *coracoid process* is a thick, round, and curved process of bone, arising from the upper part of the neck of the scapula, and over arching

Fig. 50.



\* A posterior view of the scapula. 1. The supra-spinous fossa. 2. The infra-spinous fossa. 3. The superior border. 4. The supra-scapular notch. 5. The anterior or axillary border. 6. The head of the scapula and glenoid cavity. 7. The inferior angle. 8. The neck of the scapula, the ridge opposite the number gives origin to the long head of the triceps. 9. The posterior border or base of the scapula. 10. The spine. 11. The triangular smooth surface, over which the tendon of the trapezius glides. 12. The acromion process. 13. One of the nutritious foramina. 14. The coracoid process.

the glenoid cavity. It is about two inches in length and very strong; it gives attachment to several ligaments and muscles.

*Development.*—By six centres; one for the body, one for the coracoid process, two for the acromion, one for the inferior angle, and one for the posterior border. The ossific centre for the body appears in the infra-spinous fossa at about the same time with the ossification of the vertebræ; for the coracoid process during the first year; the acromion process at puberty; the inferior angle in the fifteenth year; and the posterior border at seventeen or eighteen. Union between the coracoid process and body takes place during the fifteenth year; the bone is not complete till manhood.

*Articulations.*—With the clavicle and humerus.

*Attachment of Muscles.*—To sixteen; by its anterior surface to the subscapularis; posterior surface, supra-spinatus and infra-spinatus; superior border, omo-hyoid; posterior border, levator anguli scapulæ, rhomboideus minor, rhomboideus major, and serratus magnus; anterior border, long head of the triceps, teres minor, and teres major; upper angle of the glenoid cavity, to the long tendon of the biceps; spine and acromion to the trapezius and deltoid; coracoid process, to the pectoralis minor, short head of the biceps, and coraco-brachialis. The ligaments attached to the coracoid process are, the coracoid, coraco-clavicular, and coraco-humeral, and the costo-coracoid membrane.

HUMERUS.—The humerus is a long bone divisible into a shaft and two extremities.

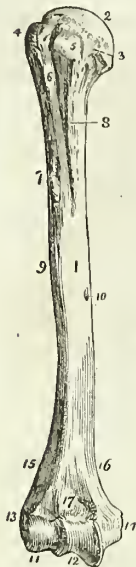The *superior extremity* presents a rounded *head*; a constriction immediately around the base of the head, the *neck*; a *greater* and a *lesser tuberosity*. The greater tuberosity is situated most externally, and is separated from the lesser by a vertical furrow, the *bicipital groove*, which lodges the long tendon of the biceps. The edges of this groove below the head of the bone are raised and rough, and are called the *anterior* and *posterior bicipital ridge*; the former serves for the insertion of the pectoralis major muscle, and the latter of the latissimus dorsi and teres major.

The constriction of the bone below the tuberosities is the surgical neck, and is so named, in contradistinction to the true neck, from being the seat of the accident called by surgical writers *fracture of the neck of the humerus*.

The *shaft* of the bone is prismoid at its upper part, and flattened from before backwards below. Upon its outer side, at about its middle, is a rough triangular eminence, which gives insertion to the deltoid; and immediately on each side of this eminence is a smooth depression, corresponding with the two heads of the brachialis anticus. Upon the inner side of the middle of the shaft is a ridge, for the attachment of the coraco-brachialis muscle; and behind, an oblique and shallow groove, which lodges the musculo-spiral nerve and superior profunda artery. The foramen for the medullary vessels is situated upon the inner surface of the shaft of the bone a little below the coraco-brachial ridge; it is directed downwards.

The *lower extremity* is flattened from before backwards, and is terminated inferiorly by a long articular surface, divided into two parts by an elevated ridge. The external portion of the articular surface is a rounded protuberance, *eminentia capitata*, which articulates with the cup-shaped

Fig. 51.\*



depression on the head of the radius; the internal portion is a concave and pulley-like surface, *trochlea*, which articulates with the ulna. Projecting beyond the articular surface on each side are the *external* and *internal condyles*, the latter being considerably the longer; and running upwards from the condyles upon the borders of the bone are the condyloid ridges, of which the external is the most prominent. Immediately in front of the trochlea is a small depression for receiving the coronoid process of the ulna during flexion of the fore-arm; and immediately behind it a large and deep fossa, for containing the olecranon process in extension.

*Development.*—By seven centres; one for the shaft, one for the head, one for the tuberosities, one for the eminentia capitata, one for the trochlea, and one for each condyle, the internal preceding the external. Ossification commences in the diaphysis of the humerus soon after the clavicle; in the head and tuberosities, during the second and third years of infantile life; in the eminentia capitata and trochlea during the third and sixth years; and in the condyles during the twelfth and fifteenth. The entire bone is consolidated at twenty.

*Articulations.*—With the glenoid cavity of the scapula, and with the ulna and radius.

*Attachment of Muscles.*—To *twenty-four*; by the greater tuberosity to the supra-spinatus, infra-spinatus, and teres minor; lesser tuberosity, subscapularis; anterior bicipital ridge, pectoralis major; posterior bicipital ridge and groove, teres major and latissimus dorsi; shaft, external and internal heads of the triceps, deltoid, coraco-brachialis, and brachialis anticus; external condyloid ridge and condyle (*condylus extensorius*), extensors and supinators of the fore-arm, viz. supinator longus, extensor carpi radialis longior, extensor carpi radialis brevior, extensor communis digitorum, extensor minimi digiti, extensor carpi ulnaris, anconeus, and supinator brevis; internal condyle (*condylus flexorius*), flexors and one pronator, viz. pronator radii teres, flexor carpi radialis, palmaris longus, flexor sublimis digitorum, and flexor carpi ulnaris.

**ULNA.**—The ulna is a long bone, divisible into a shaft and two extremities. The upper extremity is large, and forms principally the articulation of the elbow; while the lower extremity is small, and excluded from the wrist-joint by an inter-articular fibro-cartilage.

The *superior extremity* presents a semilunar concavity of large size, the *greater sigmoid notch*, for articulation with the humerus; and upon the outer side a *lesser sigmoid notch*, which articulates with the head of the radius. Bounding the greater sigmoid notch posteriorly is the *olecranon process*; and overhanging it in front, a pointed eminence with a rough

\* The humerus of the right side; its anterior surface. 1. The shaft of the bone. 2. The head. 3. The anatomical neck. 4. The greater tuberosity. 5. The lesser tuberosity. 6. The bicipital groove. 7. The anterior bicipital ridge. 8. The posterior bicipital ridge. 9. The rough surface into which the deltoid is inserted. 10. The nutritious foramen. 11. The eminentia capitata. 12. The trochlea. 13. The external condyle. 14. The internal condyle. 15. The external condyloid ridge. 16. The internal condyloid ridge. 17. The fossa for the coronoid process of the ulna.

triangular base, the *coronoid process*. Behind the lesser sigmoid notch, and extending downwards on the side of the olecranon, is a triangular uneven surface, for the anconeus muscle; and upon the posterior surface of the olecranon a smooth triangular surface, which is subcutaneous.

The *shaft* is prismoid in form, and presents three surfaces, anterior, posterior, and internal; and three borders. The *anterior surface* is occupied by the flexor profundus digitorum for the upper three-fourths of its extent; and below by a depression, for the pronator quadratus muscle. A little above its middle is the nutritious foramen, which is directed upwards. Upon the *posterior surface* at the upper part of the bone is the triangular uneven depression for the anconeus muscle, bounded inferiorly by an oblique ridge which runs downwards from the posterior extremity of the lesser sigmoid notch. Below the ridge the surface is marked into several grooves, for the attachment of the extensor ossis metacarpi, extensor secundi internodii, and extensor indicis muscle. The *internal surface* is covered in for the greater part of its extent by the flexor profundus digitorum. The *anterior border* is rounded, and gives origin by its lower fourth to the pronator quadratus; the *posterior* is more prominent, and affords attachment to the flexor carpi ulnaris and extensor carpi ulnaris. At its upper extremity it expands into the triangular subcutaneous surface of the olecranon. The *external or radial border* is sharp and prominent, for the attachment of the interosseous membrane.

The *lower extremity* terminates in a small rounded head, *capitulum ulnæ*, from the side of which projects the *styloid process*. The latter presents a deep notch at its base for the attachment of the apex of the triangular interarticular cartilage, and by its point gives attachment to the internal lateral ligament. Upon the posterior surface of the head is a groove, for the tendon of the extensor carpi ulnaris; and upon the side opposite to the styloid process a smooth surface, for articulation with the side of the radius.

*Development.*—By three centres; one for the shaft, one for the inferior extremity, and one for the olecranon. Ossification commences in the ulna shortly after the humerus and radius: the two ends of the bone are cartilaginous at birth. The centre for the lower end appears at about the fifth, and that for the olecranon about the seventh year. The bone is completed at about the twentieth year.

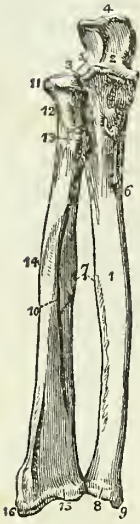*Articulations.*—With two bones; the humerus and radius; it is separated from the cuneiform bone of the carpus by the triangular interarticular cartilage.

*Attachment of Muscles.*—To twelve; by the olecranon, to the triceps extensor cubiti, one head of the flexor carpi ulnaris, and the anconeus; by the coronoid process, to the brachialis anticus, pronator radii teres, flexor sublimis digitorum, and flexor profundus digitorum; by the shaft, to the flexor profundus digitorum, flexor carpi ulnaris, pronator quadratus, anconeus, extensor carpi ulnaris, extensor ossis metacarpi pollicis, extensor secundi internodii pollicis, and extensor indicis.

**RADIUS.**—The radius is the rotatory bone of the fore-arm; it is divisible into a shaft and two extremities: unlike the ulna, its upper extremity is small, and merely accessory to the formation of the elbow-joint; while the lower extremity is large, and forms almost solely the joint of the wrist.

The *superior extremity*, presents a rounded *head*, depressed upon its

Fig. 52.\*



upper surface into a shallow cup. Around the margin of the head is a smooth articular surface, which is broad on the inner side, where it articulates with the lesser sigmoid notch of the ulna, and narrow in the rest of its circumference, to pass in the orbicular ligament. Beneath the head is a round constricted *neck*; and beneath the neck, on its internal aspect, a prominent process, the *tuberosity*. The surface of the tuberosity is partly smooth, and partly rough; rough below, where it receives the attachment of the tendon of the biceps; and smooth above, where a bursa is interposed between the tendon and the bone.

The *shaft* of the bone is prismoid, and presents three surfaces. The *anterior surface* is somewhat concave superiorly, where it lodges the flexor longus pollicis; and flat below, where it supports the pronator quadratus. At about the upper third of this surface is the nutritious foramen, which is directed upwards. The *posterior surface* is round above, where it supports the supinator brevis muscle, and marked by several shallow oblique grooves below, which afford attachment to the extensor muscles of the thumb. The *external surface* is rounded and convex, and marked by an *oblique ridge*, which extends from the tuberosity to the styloid process at the lower extremity

of the bone. Upon the inner margin of the bone is a sharp and prominent crest, which gives attachment to the interosseous membrane. The *lower extremity* of the radius is broad and triangular, and provided with two articular surfaces; one at the side of the bone, which is concave to receive the rounded head of the ulna; the other at the extremity, and marked by a slight ridge into two facets, one external and triangular, corresponding with the scaphoid; the other square, with the semilunar bone. Upon the outer side of the extremity is a strong conical projection, the *styloid process*, which gives attachment by its base to the tendon of the supinator longus, and by its apex to the external lateral ligament of the wrist joint. The inner edge of the articular surface affords attachment to the base of the inter-articular cartilage of the ulna.

Immediately in front of the styloid process is a groove, which lodges the tendons of the extensor ossis metacarpi pollicis, and extensor primi internodii; and behind the process a broader groove, for the tendons of the extensor carpi radialis longior and brevior, and extensor secundi internodii; behind this is a prominent ridge, and a deep and narrow groove, for the tendon of the extensor indicis; and still farther back, part of a broad groove, completed by the ulna, for the tendons of the extensor communis digitorum.

*Development.*—By three centres; one for the shaft, and one for each extremity. Ossification commences in the shaft soon after the humerus, and before that in the ulna. The inferior centre appears during the second

\* The two bones of the fore-arm seen from the front. 1. The shaft of the ulna. 2. The greater sigmoid notch. 3. The lesser sigmoid notch, with which the head of the radius is articulated. 4. The olecranon process. 5. The coronoid process. 6. The nutritious foramen. 7. The sharp ridges upon the two bones to which the interosseous membrane is attached. 8. The capitulum ulnæ. 9. The styloid process. 10. The shaft of the radius. 11. Its head surrounded by the smooth border for articulation with the orbicular ligament. 12. The neck of the radius. 13. Its tuberosity. 14. The oblique line 15. The lower extremity of the bone 16. Its styloid process.

year, and the superior about the seventh. The bone is perfected at twenty.

*Articulations.*—With four bones; humerus, ulna, scaphoid, and semilunar.

*Attachment of Muscles.*—To nine; by the tuberosity to the biceps; by the oblique ridge to the supinator brevis, pronator radii teres, flexor sublimis digitorum and pronator quadratus; by the anterior surface, to the flexor longus pollicis and pronator quadratus; by the posterior surface, to the extensor ossis metacarpi pollicis, and extensor primi internodii; and by the styloid process, to the supinator longus.

CARPUS.—The bones of the carpus are eight in number; they are arranged in two rows. In the first row, commencing from the radial side, are the os scaphoides, semilunare, cuneiforme, pisiforme; and in the second row, in the same order, the os trapezium, trapezoides, os magnum, and unciforme.

The SCAPHOID bone is named from bearing some resemblance to the shape of a boat, being broad at one end, and narrowed like a prow at the opposite, concave on one side, and convex upon the other. It is, however, more similar in form to a cashew nut, flattened and concave upon one side. If carefully examined, it will be found to present a convex and a concave surface, a convex and a concave border, a broad end, and a narrow and pointed extremity, the tuberosity.

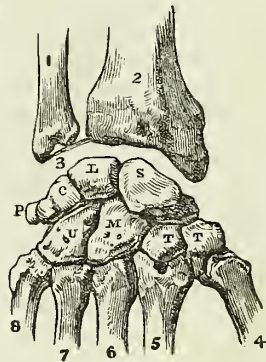
To ascertain to which hand the bone belongs, let the student hold it horizontally, so that the convex surface may look backwards (*i. e.* towards himself), and the convex border upwards: the broad extremity will indicate its appropriate hand; if it be directed to the right, the bone belongs to the right; and if to the left, to the left carpus.

*Articulations.*—With five bones; by its convex surface with the radius; by its concave surface, with the os magnum and semilunare; and by the extremity of its upper or dorsal border, with the trapezium and trapezoides.

*Attachments.*—By its tuberosity to the abductor pollicis, and anterior annular ligament.

The SEMILUNAR bone may be known by having a crescentic concavity, and a somewhat crescentic outline. It presents for examination four articular surfaces and two extremities; the *articular surfaces* are, one concave, one convex, and two lateral, one lateral surface being crescentic, the other nearly circular, and divided generally into two facets. The *extremities* are, one dorsal, which is quadrilateral, flat, and indented, for th

Fig. 53.\*



\* A diagram showing the dorsal surface of the bones of the carpus, with their articulations.—The right hand. 2. The lower end of the radius. 1. The lower extremity of the ulna. 3. The inter-articular fibro-cartilage attached to the styloid process of the ulna, and to the margin of the articular surface of the radius. S. The scaphoid bone. L. The semilunare articulating with five bones. C. The cuneiforme, articulating with three bones. P. The pisiforme, articulating with the cuneiforme only. T. The first bone of the second row,—the trapezium, articulating with four bones. T. The second bone,—the trapezoides, articulating also with four bones. M. The os magnum, articulating with seven. U. The unciforme, articulating with five.

attachment of ligaments; the other *palmar*, which is convex, rounded, and of larger size.

To determine to which hand it belongs, let the bone be held perpendicularly, so that the dorsal or flat extremity look upwards, and the convex side backwards (towards the holder). The circular lateral surface will point to the side corresponding with the hand to which the bone belongs.

*Articulations.*—With *five* bones, but occasionally with only four: by its convex surface, with the radius; by its concave surface, with the os magnum; by its crescentic lateral facet, with the scaphoid; and by the circular surface, with the cuneiform bone and with the point of the unciform. This surface is divided into two parts by a ridge when it articulates with the unciform as well as with the cuneiform bone.

The CUNEIFORM bone, although somewhat wedge-shaped in form, may be best distinguished by a circular, and isolated facet, which articulates with the pisiform bone. It presents for examination *three surfaces*, a *base*, and an *apex*. One surface is very rough and irregular; the opposite forms a concave articular surface, while the third is partly rough and partly smooth, and presents that circular facet which is characteristic of the bone. The base is an articular surface, and the apex is round and pointed.

To distinguish its appropriate hand, let the base be directed backwards and the pisiform facet upwards; the concave articular surface will point to the hand to which the bone belongs.

*Articulations.*—With *three* bones, and with the triangular fibro-cartilage. By the base, with the semilunare; by the concave surface, with the unciforme; by the circular facet, with the pisiforme; and by the superior angle of the rough surface, with the fibro-cartilage.

The PISIFORM bone may be recognised by its small size, and by possessing a singular articular facet. If it be examined carefully it will be observed to present four sides and two extremities; one side is articular, the smooth facet approaching nearer to the superior than the inferior extremity. The side opposite to this is rounded, and the remaining sides are, one slightly concave, the other slightly convex.

If the bone be held so that the articular facet shall look downwards and the extremity which overhangs the articular facet forwards, the concave side will point to the hand to which it belongs.

*Articulations.*—With the cuneiform bone only.

*Attachments.*—To *two* muscles, the flexor carpi ulnaris, and abductor minimi digiti; and to the anterior annular ligament.

The TRAPEZIUM (*os multangulum majus*) is too irregular in form to be compared to any known object; it may be distinguished by a deep groove, for the tendon of the flexor carpi radialis muscle. It is somewhat compressed, and may be divided into two surfaces which are smooth and articular, and three rough borders. One of the *articular surfaces* is *oval*, concave in one direction, and convex in the other (saddle-seat shaped); the other is marked into *three facets*. One of the *borders* presents the groove for the tendon of the flexor carpi radialis, which is surmounted by a prominent tubercle for the attachment of the annular ligament; the other two borders are rough and form the outer side of the carpus. The grooved border is narrow at one extremity and broad at the other, where it presents the groove and tubercle.

If the bone be held so that the grooved border look upwards while the apex of this border be directed forwards, and the base with the tubercle



backwards, the concavo-convex surface will point to the hand to which the bone belongs.

*Articulations.*—With *four* bones; by the concavo-convex surface, with the metacarpal bone of the thumb; and by the three facets of the other articular surface, with the scaphoid, trapezoid, and second metacarpal bone.

*Attachments.*—To *two* muscles, abductor pollicis and flexor ossis metacarpi; and by the tubercle, to the annular ligament.

The TRAPEZOIDES (os multangulum minus) is a small, oblong, and quadrilateral bone, bent near its middle upon itself (bean-shaped). It presents four articular surfaces and two extremities. One of the surfaces is *concavo-convex*, *i. e.* concave in one direction, and convex in the other; another, contiguous to the preceding, is *concave*, so as to be almost angular in the middle, and is often marked by a small rough depression, for an interosseous ligament; the two remaining sides are *flat*, and present nothing remarkable. One of the two extremities is broad and of large size, the *dorsal*; the other, or *palmar*, is small and rough.

If the bone be held perpendicularly, so that the broad extremity be upwards, and the concavo-convex surface forwards, the angular concave surface will point to the hand to which the bone belongs.

*Articulations.*—With *four* bones; by the concavo-convex surface, with the second metacarpal bone; by the angular concave surface, with the os magnum; and by the other two surfaces, with the trapezium and scaphoid.

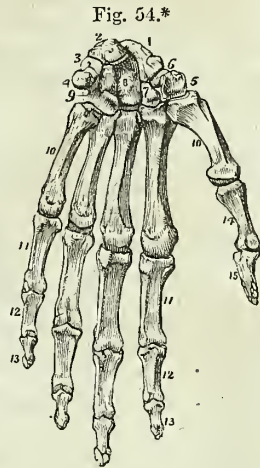
*Attachments.*—To the flexor brevis pollicis muscle.

The Os MAGNUM (capitatum) is the largest bone of the carpus, and is divisible into a body and head. The *head* is round for the greater part of its extent, but is flattened on one side. The *body* is irregularly quadrilateral, and presents four sides and a smooth extremity. Two of the sides are rough, the one being square and flat, the dorsal; the other rounded and prominent, the palmar; the other two sides are articular, the one being concave, the other convex. The extremity is a triangular articular surface, divided into three facets.

If the bone be held perpendicularly, so that the articular extremity look upwards and the broad dorsal surface backwards (towards the holder), the concave articular surface will point to the hand to which the bone belongs.

*Articulations.*—With *seven* bones; by the rounded head, with the cup formed by the scaphoid and semilunar bone; by the side of the convex surface, with the trapezoides; by the concave surface, with the unciforme; and by the extremity, with the second, third, and fourth metacarpal bones.

\* The hand viewed upon its anterior or palmar aspect. 1. The scaphoid bone. 2. The semilunare. 3. The cuneiforme. 4. The pisiforme. 5. The trapezium. 6. The groove in the trapezium that lodges the tendon of the flexor carpi radialis. 7. The trapezoides. 8. The os magnum. 9. The unciforme. 10, 10. The five metacarpal bones. 11, 11. The first row of phalanges. 12, 12. The second row. 13, 13. The third row, or ungual phalanges. 14. The first phalanx of the thumb. 15. The second and last phalanx of the thumb.



*Attachments.*—To the flexor brevis pollicis muscle.

The UNCIFORME is a triangular-shaped bone, remarkable for a long and curved process, which projects from its palmar aspect. It presents five surfaces;—three articular, and two free. One of the articular surfaces is divided by a slight ridge into two facets; the other two converge, and meet at a flattened angle.\* One of the free surfaces, the dorsal, is rough and triangular; the other, palmar, also triangular, but somewhat smaller, gives origin to the unciform process.

If the bone be held perpendicularly, so that the articular surface with two facets look upwards, and the unciform process backwards (towards the holder), the concavity of the unciform process will point to the hand to which the bone belongs.

*Articulations.*—With *five* bones; by the two facets on its base, with the fourth and fifth metacarpal bones; by the two lateral articulating surfaces, with the os magnum and cuneiforme; and by the flattened angle of its apex, with the semilunare.

*Attachments.*—To *two* muscles, abductor minimi digiti, and flexor brevis minimi digiti; and by the hook-shaped process to the annular ligament.

*Development.*—The bones of the carpus are each developed by a single centre; they are cartilaginous at birth. Ossification commences towards the end of the first year in the os magnum and unciforme; at the end of the third year in the cuneiforme; during the fifth year in the trapezium and semilunare; during the eighth, in the scaphoides; the ninth, in the trapezoides: and the twelfth in the pisiforme. The latter bone is the last in the skeleton to ossify; it is, in reality, a sesamoid bone of the tendon of the flexor carpi ulnaris.

The number of articulations which each bone of the carpus presents with surrounding bones, may be expressed in figures, which will materially facilitate their recollection; the number for the first row is 5531, and for the second 4475.

**METACARPUS.**—The bones of the metacarpus are five in number. They are long bones, divisible into a head, shaft, and base.

The *head* is rounded at the extremity, and flattened at each side, for the insertion of strong ligaments; the *shaft* is prismoid, and marked deeply on each side, for the attachment of the interossei muscles; and the *base* is irregularly quadrilateral and rough, for the insertion of tendons and ligaments. The *base* presents three articular surfaces, one at each side, for the adjoining metacarpal bones; and one at the extremity for the carpus.

The metacarpal bone of the thumb is one-third shorter than the rest, flattened and broad on its dorsal aspect, and convex on its palmar side; the articular surface of the head is not so round as that of the other metacarpal bones; and the base has a single concavo-convex surface, to articulate with the similar surface of the trapezium.

The metacarpal bones of the different fingers may be distinguished by certain obvious characters. The base of the metacarpal bone of the index finger is the largest of the four, and presents four articular surfaces. That of the middle finger may be distinguished by a rounded projecting process

\* When the unciforme does not articulate with the semilunare, this angle is sharp

upon the radial side of its base, and two small circular facets upon its ulnar lateral surface. The base of the metacarpal bone of the ring-finger is small and square, and has two small circular facets to correspond with those of the middle metacarpal. The metacarpal bone of the little finger has only one lateral articular surface.

*Development.*—By two centres; one for the shaft, and one for the digital extremity, with the exception of the metacarpal bone of the thumb, the epiphysis of which, like that of the phalanges, occupies the carpal end of the bone. Ossification of the metacarpal bones commences in the embryo between the tenth and twelfth week, that is, soon after the bones of the fore-arm. The epiphyses make their appearance at the end of the second, or early in the third year, and the bones are completed at twenty.

*Articulations.*—The first with the trapezium; second, with the trapezium, trapezoides, and os magnum, and with the middle metacarpal bone; third, or middle, with the os magnum, and adjoining metacarpal bones; fourth, with the os magnum and unciforme, and with the adjoining metacarpal bones; and, fifth, with the unciforme, and with the metacarpal bone of the ring-finger.

The figures resulting from the number of articulations which each metacarpal bone possesses, taken from the radial to the ulnar side, are 13121.

*Attachment of Muscles.*—To the metacarpal bone of the thumb, *three*, the flexor ossis metacarpi, extensor ossis metacarpi, and first dorsal interosseous; of the index finger, *five*, the extensor carpi radialis longior, flexor carpi radialis, first and second dorsal interosseous, and first palmar interosseous; of the middle finger, *four*, the extensor carpi radialis brevior, adductor pollicis, and second and third dorsal interosseous; of the ring finger, *three*, the third and fourth dorsal interosseous, and second palmar; and of the little finger, *four*, extensor carpi ulnaris, adductor minimi digiti, fourth dorsal, and third palmar interosseous.

**PHALANGES.**—The phalanges are the bones of the fingers; they are named from their arrangement in rows, and are fourteen in number, three to each finger, and two to the thumb. In conformation they are long bones, divisible into a shaft, and two extremities.

The *shaft* is compressed from before backwards, convex on its posterior surface, and flat with raised edges in front. The metacarpal extremity, or *base*, in the first row, is a simple concave articular surface, that in the other two rows a double concavity, separated by a slight ridge. The digital extremities of the first and second row present a pulley-like surface, concave in the middle, and convex on each side. The ungual extremity of the last phalanx is broad, rough, and expanded into a semi-lunar crest.

*Development.*—By two centres; one for the shaft, and one for the base. Ossification commences first in the third phalanges, then in the first, and lastly in the second. The period of commencement corresponds with that of the metacarpal bones. The epiphyses of the first row appear during the third or fourth year, those of the second row during the fourth or fifth, and of the last during the sixth or seventh. The phalanges are perfected by the twentieth year.

*Articulations.*—The first row, with the metacarpal bones and second

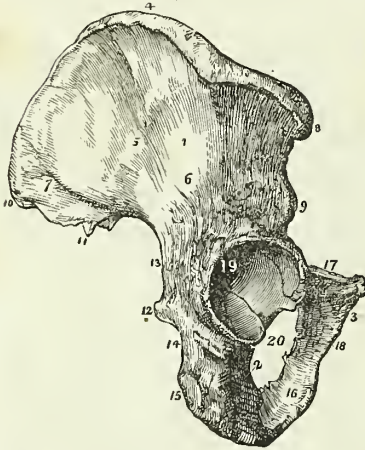
row of phalanges ; the second row, with the first and third ; and the third, with the second row.

*Attachment of Muscles.*—To the base of the *first phalanx* of the thumb four muscles, abductor pollicis, flexor brevis pollicis, adductor pollicis, and extensor primi internodii ; and to the *second phalanx, two*, the flexor longus pollicis, and extensor secundi internodii. To the *first phalanx* of the second, third, and fourth fingers, one dorsal and one palmar interosseous, and to the first phalanx of the little finger, the abductor minimi digiti, flexor brevis minimi digiti, and one palmar interosseous. To the *second phalanges*, the flexor sublimis and extensor communis digitorum ; and to the *last phalanges*, the flexor profundus and extensor communis digitorum.

PELVIS AND LOWER EXTREMITY.

The bones of the pelvis are the two ossa innominata, the sacrum, and the coccyx ; and of the lower extremity, the femur, patella, tibia and fibula, tarsus, metatarsus, and phalanges.

Fig. 55.\*



**OS INNOMINATUM.**—The os innominatum (os coxæ) is an irregular flat bone, consisting in the young subject of three parts, which meet at the acetabulum. Hence it is usually described in the adult as divisible into three portions, ilium, ischium, and pubes. The *ilium* is the superior, broad, and expanded portion which forms the prominence of the hip, and articulates with the sacrum. The *ischium* is the inferior and strong part of the bone on which we sit. The *os pubis* is that portion which forms the front of the pelvis, and gives support to the external organs of generation.

The **ILIUM** may be described as divisible into an internal and external surface, a crest, and an anterior and posterior border.

The *internal surface* is bounded above by the crest, below by a prominent line, the linea ilio-pectinea, and before and behind by the anterior and posterior borders ; it is concave and smooth for the anterior two-thirds of its extent, and lodges the iliacus muscle. The posterior third is rough, for articulation with the sacrum, and is divided by a deep groove into two parts ; an anterior or *auricular portion*, which is shaped like the pinna,

\* The os innominatum of the right side. 1. The ilium ; its external surface. 2. The ischium. 3. The os pubis. 4. The crest of the ilium. 5. The superior curved line. 6. The inferior curved line. 7. The surface for the gluteus maximus. 8. The anterior superior spinous process. 9. The anterior inferior spinous process. 10. The posterior superior spinous process. 11. The posterior inferior spinous process. 12. The spine of the ischium. 13. The great sacro-ischiatic notch. 14. The lesser sacro-ischiatic notch. 15. The tuberosity of the ischium, showing its three facets. 16. The ramus of the ischium. 17. The body of the os pubis. 18. The ramus of the pubis. 19. The acetabulum. 20. The foramen thyroideum.

and coated by cartilage in the fresh bone ; and a posterior portion, which is very rough and uneven for the attachment of interosseous ligaments.

The *external surface* is uneven, partly convex, and partly concave ; it is bounded above by the crest ; below by a prominent arch, which forms the upper segment of the acetabulum, and before and behind, by the anterior and posterior borders. Crossing this surface in an arched direction, from the anterior extremity of the crest to a notch upon the lower part of the posterior border, is a groove, which lodges the gluteal vessels and nerve, the *superior curved line* ; and below this, at a short distance, a rough ridge, the *inferior curved line*. The surface included between the superior curved line and the crest, gives origin to the gluteus medius muscle ; that between the curved lines, to the gluteus minimus ; and the rough interval between the inferior curved line and the arch of the acetabulum, to one head of the rectus. The posterior sixth of this surface is rough and raised, and gives origin to part of the gluteus maximus.

The *crest* of the ilium is arched and curved in its direction like the italic letter *f*, being bent inwards at its anterior termination, and outwards towards the posterior. It is broad for the attachment of three planes of muscles, which are connected with its external and internal borders or lips, and with the intermediate space.

The *anterior border* is marked by two projections, the *anterior superior spinous process*, which is the anterior termination of the crest, and the *anterior inferior spinous process* ; the two processes being separated by a notch for the attachment of the sartorius muscle. This border terminates inferiorly in the lip of the acetabulum. The *posterior border* also presents two projections, the *posterior superior* and the *posterior inferior spinous process*, separated by a notch. Inferiorly this border is broad and arched, and forms the upper part of the great sacro-ischiatic notch.

The ISCHIUM is divisible into a thick and solid portion, the *body*, and into a thin and ascending part, the *ramus* ; it may be considered also, for convenience of description, as presenting an external and internal surface, and three borders, posterior, inferior, and superior.

The *external surface* is rough and uneven, for the attachment of muscles ; and broad and smooth above, where it enters into the formation of the acetabulum. Below the inferior lip of the acetabulum is a notch, which lodges the obturator externus muscle in its passage outwards to the trochanteric fossa of the femur. The *internal surface* is smooth, and somewhat encroached upon at its posterior border by the spine.

The *posterior border* of the ischium presents towards its middle a remarkable projection, the *spine*. Immediately above the spine is a notch of large size, the *great sacro-ischiatic*, and below the spine the *lesser sacro-ischiatic notch* ; the former being converted into a foramen by the lesser sacro-ischiatic ligament, gives passage to the pyriformis muscle, the gluteal vessels and nerve, pudic vessels and nerve, and ischiatic vessels and nerve ; and the lesser, completed by the great sacro-ischiatic ligament, to the obturator internus muscle, and to the internal pudic vessels and nerve. The *inferior border* is thick and broad, and is called the *tuberosity*. The surface of the tuberosity is divided into three facets ; one anterior, which is rough for the origin of the semi-membranosus ; and two posterior, which are smooth, and separated by a slight ridge for the semi-tendinosus and biceps muscle. The inner margin of the tuberosity is bounded by a sharp ridge, which gives attachment to a prolongation of the great sacro-ischiatic

ligament, and the outer margin by a prominent ridge, from which the quadratus femoris muscle arises. The superior border of the ischium is thin, and forms the lower circumference of the obturator foramen. The ramus of the ischium is continuous with the ramus of the pubis, and is slightly everted.

The Os PUBIS is divided into a horizontal portion or *body* (horizontal ramus of Albinus), and a descending portion or *ramus*; it presents for examination an external and internal surface, a superior and inferior border, and symphysis.

The *external surface* is rough, for the attachment of muscles; and prominent at its outer extremity, where it forms part of the acetabulum. The *internal surface* is smooth, and enters into the formation of the cavity of the pelvis. The *superior border* is marked by a rough ridge, the *crest*, the inner termination of the crest is the *angle*; and the outer end, the *spine* or *tubercle*. Running outwards from the spine is a sharp ridge, the *pectineal line*, or *linea ilio-pectinea*, which marks the brim of the true pelvis. In front of the pectineal line is a smooth depression, which supports the femoral artery and vein, and a little more externally an elevated prominence, the *ilio-pectineal eminence*, which divides the surface for the femoral vessels, from another depression which overhangs the acetabulum, and lodges the psoas and iliacus muscles. The ilio-pectineal eminence moreover marks the junction of the pubes with the ilium. The *inferior border* is broad and deeply grooved, for the passage of the obturator vessels and nerve; and sharp upon the side of the ramus, to form part of the boundary of the obturator foramen. The *symphysis* is the inner extremity of the body of the bone; it is oval and rough, for the attachment of a ligamentous structure analogous to the intervertebral substance. The *ramus* of the pubes descends obliquely outwards, and is continuous with the ramus of the ischium. The inner border of the ramus forms with the corresponding bone the *arch of the pubes*, and at its inferior part is considerably everted, to afford attachment to the crus penis.

The *acetabulum* (*cavitas cotyloidea*) is a deep cup-shaped cavity, situated at the point of union between the ilium, ischium, and pubes; a little less than two-fifths being formed by the ilium, a little more than two-fifths by the ischium, and the remaining fifth by the pubes. It is bounded by a deep rim or lip, which is broad and strong above, where most resistance is required, and marked in front by a deep notch, which is arched over in the fresh subject by a strong ligament, and transmits the nutrient vessels into the joint. At the bottom of the cup and communicating with the notch, is a deep and circular pit (*fundus acetabuli*) which lodges a mass of fat, and gives attachment to the broad extremity of the ligamentum teres.

The *obturator* or *thyroid foramen* is a large oval interval between the ischium and pubes, bounded by a narrow rough margin, to which a ligamentous membrane is attached. The upper part of the foramen is increased in depth by the groove in the under surface of the os pubis which lodges the obturator vessels and nerve.

*Development.*—By eight centres; three principal, one for the ilium, one for the ischium, and one for the pubes; and five secondary, one, the Y-shaped piece for the interval between the primitive pieces in the acetabulum, one for the crest of the ilium, one (not constant) for the anterior and inferior spinous process of the ilium, one for the tuberosity of the ischium, and one (not constant) for the angle of the os pubis. Ossification

commences in the primitive pieces, immediately after that in the vertebræ, firstly in the ilium, then in the ischium, and lastly in the pubes; the first ossific deposits being situated near to the future acetabulum. At birth the acetabulum, the crest of the ilium, and the ramus of the pubes and ischium, are cartilaginous. The secondary centres appear at puberty, and the entire bone is not completed until the twenty-fifth year.

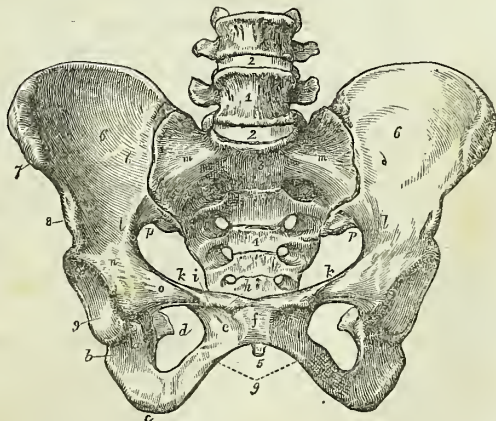
*Articulations.*—With three bones; sacrum, opposite innominatum, and femur.

*Attachments of Muscles and Ligaments.*—To *thirty-five* muscles; to the ilium, *thirteen*; by the outer lip of the crest, to the obliquus externus for two-thirds, and to the latissimus dorsi for one-third its length, and to the tensor vaginæ femoris by its anterior fourth; by the middle crest, to the internal oblique for three-fourths its length, by the remaining fourth to the erector spinæ; by the internal lip, to the transversalis for three-fourths, and to the quadratus lumborum by the posterior part of its middle third. By the external surface, to the gluteus medius, minimus and maximus, and to one head of the rectus; by the internal surface, to the iliacus; and by the anterior border to the sartorius, and the other head of the rectus. To the ischium, *sixteen*; by its external surface, the adductor magnus and obturator externus; by the internal surface, the obturator internus and levator ani; by the spine, the gemellus superior, levator ani, coccygeus, and lesser sacro-ischiatic ligament; by the tuberosity, the biceps, semi-tendinosus, semi-membranosus, gemellus inferior, quadratus femoris, erector penis, transversus perinei, and great sacro-ischiatic ligament; and by the ramus, the gracilis, accelerator urinæ, and compressor urethræ. To the os pubis, *fifteen*; by its upper border, the obliquus externus, obliquus internus, transversalis, rectus, pyramidalis, pectineus, and psoas parvus; by its external surface, the adductor longus, adductor brevis, and gracilis; by its internal surface, the levator ani, compressor urethræ, and obturator internus; and by the ramus, the adductor magnus, and accelerator urinæ.

PELVIS.

The pelvis considered as a whole is divisible into a *false* and *true* pelvis; the former is the expanded portion, bounded on each side by the ossa ilii, and separated from the true pelvis by the linea ilio-pectinea. The true pelvis is all that portion which is situated beneath the linea ilio-pectinea. This line forms the margin or *brim* of the true pelvis, while the included area is called the *inlet*. The form of the inlet is heart-shaped, obtusely pointed in front at

Fig. 56.\*



\* A female pelvis. 1. The last lumbar vertebræ. 2. 2. The intervertebral substance connecting the last lumbar vertebra with the fourth and sacrum. 3. The promontory

the symphysis pubis, expanded on each side, and encroached upon behind by a projection of the upper part of the sacrum, which is named the promontory. The cavity is somewhat encroached upon at each side by a smooth quadrangular plane of bone, corresponding with the internal surface of the acetabulum, and leading to the spine of the ischium. In front are two fossæ around the obturator foramina, for lodging the obturator internus muscle, at each side. The inferior termination of the pelvis is very irregular, and is termed the *outlet*. It is bounded in front by the convergence of the rami of the ischium and pubes, which constitute the arch of the pubes; on each side by the tuberosity of the ischium, and by two irregular fissures formed by the greater and lesser sacro-ischiatic notches; and behind by the lateral borders of the sacrum, and by the coccyx.

The pelvis is placed obliquely with regard to the trunk of the body, so that the inner surface of the ossa pubis is directed upwards, and would support the superincumbent weight of the viscera. The base of the sacrum rises nearly four inches above the level of the upper border of the symphysis pubis and the apex of the coccyx, somewhat more than half an inch above its lower border. If a line were carried through the central axis of the inlet, it would impinge by one extremity against the umbilicus, and by the other against the middle of the coccyx. The *axis of the inlet* is therefore directed *downwards and backwards*, while that of the *outlet* points *downwards and forwards*, and corresponds with a line drawn from the upper part of the sacrum, through the centre of the outlet. The axis of the cavity represents a curve, which corresponds very nearly with the curve of the sacrum, the extremities being indicated by the central points of the inlet and outlet. A knowledge of the direction of these axes is most important to the surgeon, as indicating the line in which instruments should be used in operations upon the viscera of the pelvis, and the direction of force in the removal of calculi from the bladder; and to the accoucheur, as explaining the course taken by the fœtus during parturition.

There are certain striking differences between the male and female pelvis. In the male the bones are thicker, stronger, and more solid, and the cavity deeper and narrower. In the female the bones are lighter and more delicate, the iliac fossæ are large, and the ilia expanded; the inlet, the outlet, and the cavity, are large, and the acetabula farther removed from each other; the cavity is shallow, the tuberosities widely separated, the obturator foramina triangular, and the span of the pubic arch greater. The precise diameter of the inlet and outlet, and the depth of the cavity, are important considerations to the accoucheur.

The diameters of the inlet or brim are three: 1. Antero-posterior, sacro-pubic or conjugate; 2. transverse; and 3. oblique. The *antero-posterior*

of the sacrum. 4. The anterior surface of the sacrum, on which its transverse lines and foramina are seen. 5. The tip of the coccyx. 6, 6. The iliac fossæ, forming the lateral boundaries of the false pelvis. 7. The anterior superior spinous process of the ilium; left side. 8. The anterior inferior spinous process. 9. The acetabulum. *a*. The notch of the acetabulum. *b*. The body of the ischium. *c*. Its tuberosity. *d*. The spine of the ischium seen through the obturator foramen. *e*. The os pubis. *f*. The symphysis pubis. *g*. The arch of the pubes. *h*. The angle of the os pubis. *i*. The spine of the pubes; the prominent ridge between *h* and *i* is the crest of the pubes. *k, k*. The pectineal line of the pubes. *l, l*. The ilio-pectineal line; *m, m*. the prolongation of this line to the promontory of the sacrum. The line represented by *h, i, k, k, l, l* and *m, m*. is the brim of the true pelvis. *n*. The ilio-pectineal eminence. *o*. The smooth surface which supports the femoral vessels. *p, p*. The great sacro-ischiatic notch.



extends from the symphysis pubis to the middle of the promontory of the sacrum, and measures four inches. The *transverse* extends from the middle of the brim on one side to the same point on the opposite, and measures five inches. The *oblique* extends from the sacro-iliac symphysis on one side, to the margin of the brim corresponding with the acetabulum on the opposite, and also measures five inches.

The diameters of the outlet are two, antero-posterior, and transverse. The *antero-posterior* diameter extends from the lower part of the symphysis pubis to the apex of the coccyx; and the *transverse*, from the posterior part of one tuberosity to the same point on the opposite side; they both measure four inches. The cavity of the pelvis measures in depth four inches and a half, posteriorly; three inches and a half in the middle; and one and a half at the symphysis pubis.

FEMUR.—The femur, the longest bone of the skeleton, is situated obliquely in the upper part of the lower limb, articulating by means of its head with the acetabulum, and inclining inwards as it descends, until it almost meets its fellow of the opposite side at the knee. In the female this obliquity is greater than in the male, in consequence of the greater breadth of the pelvis. The femur is divisible into a shaft, a superior, and an inferior extremity.

At the *superior extremity* is a rounded *head*, directed upwards and inwards, and marked just below its centre by an oval depression for the ligamentum teres. The head is supported by a *neck*, which varies in length and obliquity according to sex and at various periods of life, being long and oblique in the adult male, shorter and more horizontal in the female and in old age. Externally to the neck is a large process, the *trochanter major*, which presents upon its anterior surface an oval facet, for the attachment of the tendon of the gluteus minimus muscle; and above, a double facet, for the insertion of the gluteus medius. On its posterior side is a vertical ridge, the *linea quadrati*, for the attachment of the quadratus femoris muscle. Upon the inner side of the trochanter major is a deep pit, the *trochanteric* or *digital fossa*, in which are inserted the tendons of the pyriformis, gemellus superior and inferior, and obturator externus and internus muscles. Passing downwards from the trochanter major in front of the bone is an oblique ridge, which forms the inferior boundary of the neck, the *anterior intertrochanteric line*; and, behind another oblique ridge, the *posterior intertrochanteric line*, which terminates in a rounded tubercle upon the posterior and inner side of the bone, the *trochanter minor*.

Fig. 57.\*

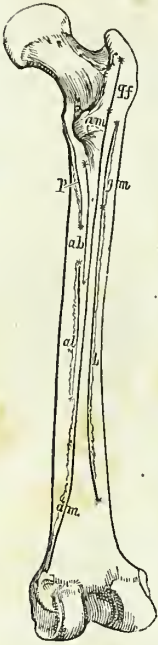

The *shaft* of the femur is convex and rounded in

\* The right femur, seen upon the anterior aspect. 1. The shaft. 2. The head. 3. The neck. 4. The great trochanter. 5. The anterior intertrochanteric line. 6. The lesser trochanter. 7. The external condyle. 8. The internal condyle. 9. The tuberosity for the attachment of the external lateral ligament. 10. The fossa for the tendon of origin of the popliteus muscle. 11. The tuberosity for the attachment of the internal lateral ligament.

front, and covered with muscles; and somewhat concave and raised into a rough prominent ridge behind, the *linea aspera*. The *linea aspera* near the upper extremity of the bone divides into three branches. The anterior branch is continued forwards in front of the lesser trochanter, and is continuous with the anterior intertrochanteric line; the middle is continued directly upwards into the *linea quadrati*; and the posterior, broad and strongly marked, ascends to the base of the trochanter major. Towards the lower extremity of the bone, the *linea aspera* divides into two ridges, which descend to the two condyles, and enclose a triangular space upon which rests the popliteal artery. The internal condyloid ridge is less marked than the external, and presents a broad and shallow groove, for the passage of the femoral artery. The nutritious foramen is situated in or near the *linea aspera*, at about one-third from its upper extremity, and is directed obliquely from below upwards.

Fig. 58.\*



The *lower extremity* of the femur is broad and porous, and divided by a smooth depression in front, and by a large fossa (*fossa intercondyloidea*) behind into two condyles.

The *external condyle* is the broadest and most prominent, and the internal the narrowest and longest; the difference in length depending upon the obliquity of the femur, in consequence of the separation of the two bones at their upper extremities by the breadth of the pelvis. The external condyle is marked upon its outer side by a prominent tuberosity, which gives attachment to the external lateral ligament; and immediately beneath this is the fossa, which lodges the tendon of origin of the popliteus. By the internal surface it gives attachment to the anterior crucial ligament of the knee-joint; and by its upper and posterior part, to the external head of the gastrocnemius and to the plantaris. The *internal condyle* projects upon its inner side into a tuberosity, to which is attached the internal lateral ligament; above this tuberosity, at the extremity of the internal condyloid ridge, is a tubercle, for the insertion of the tendon of the adductor magnus; and beneath the tubercle, upon the upper surface of the condyle, a depression, from which the internal head of the gastrocnemius arises. The outer side of the internal condyle is rough and concave, for the attachment of the posterior crucial ligament.

*Development.*—By five centres; one for the shaft, one for each extremity, and one for each trochanter. The femur is the first of the long bones to show signs of ossification. In it, ossific matter is found immediately after the maxillæ before the termination of the second month of embryonic life. The secondary deposits take place in the following order, in the

\* A diagram of the posterior aspect of the right femur, showing the lines of attachment of the muscles. The muscles attached to the inner lip are,—*p*, the pectineus; *a b*, the adductor brevis; and *a l*, the adductor longus. The middle portion is occupied for its whole extent by *a m*, the adductor magnus; and is continuous superiorly with *q f* the *linea quadrati*, into which the quadratus femoris is inserted. The outer lip is occupied by *g m*, the *gluteus maximus*; and *b*, the short head of the biceps.

condyloid extremity during the last month of fetal life,\* in the head towards the end of the first year; in the greater trochanter between the third and the fourth year; in the lesser trochanter between the thirteenth and fourteenth. The epiphyses and apophyses are joined to the diaphysis in the reverse order of their appearance, the junction commencing after puberty and not being completed for the condyloid epiphysis until after the twentieth year.

*Articulations.*—With three bones; with the os innominatum, tibia, and patella.

*Attachment of Muscles.*—To twenty-three; by the greater trochanter, to the gluteus medius and minimus, pyriformis, gemellus superior, obturator internus, gemellus inferior, obturator externus, and quadratus femoris; by the lesser trochanter, to the common tendon of the psoas and iliacus. By the linea aspera, its outer lip, to the vastus externus, gluteus maximus, and short head of the biceps; by its inner lip, to the vastus internus, pectineus, adductor brevis, and adductor longus; by its middle to the adductor magnus; by the anterior part of the bone, to the cruræus and subcruræus; by its condyles, to the gastrocnemius, plantaris, and popliteus.

**PATELLA.**—The patella is a sesamoid bone, developed in the tendon of the quadriceps extensor muscle, and usually described as a bone of the lower extremity. It is heart-shaped in figure, the broad side being directed upwards and the apex downwards, the external surface convex, and the internal divided by a ridge into two smooth surfaces, to articulate with the condyles of the femur. The external articular surface corresponding with the external condyle is the larger of the two, and serves to indicate the leg to which the bone belongs.

*Development.*—By a single centre, at about the middle of the third year.

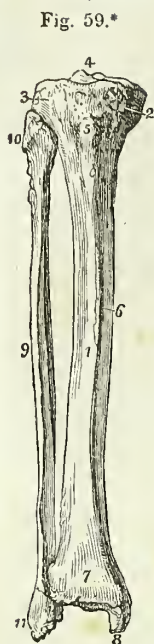
*Articulations.*—With the two condyles of the femur.

*Attachment of Muscles.*—To four; the rectus, cruræus, vastus internus, and vastus externus, and to the ligamentum patellæ.

**TIBIA.**—The tibia is the inner and larger bone of the leg; it is prismoid in form, and divisible into a shaft, an upper and lower extremity.

The *upper extremity*, or head, is large, and expanded on each side into two *tuberosities*. Upon their upper surface the tuberosities are smooth, to articulate with the condyles of the femur; the internal articular surface being oval and oblong, to correspond with the internal condyle; and the external broad and nearly circular. Between the two articular surfaces is a *spinous process*; and in front and behind the spinous process a rough depression, giving attachment to the anterior and posterior crucial ligaments. Between the two tuberosities, on the front aspect of the bone, is a prominent elevation, the *tubercle*, for the insertion of the ligamentum patellæ, and immediately above the tubercle a smooth facet, corresponding with the bursa. Upon the outer side of the external tuberosity is an articular surface, for the head of the fibula; and upon the posterior part of the internal tuberosity a depression, for the insertion of the tendon of the semimembranosus muscle.

\* Cruveilhier remarks that this centre is so constant in the last fortnight of fetal life that it may be regarded as an important proof of the fœtus having reached its full term



The *shaft* of the tibia presents three surfaces; *internal*, which is subcutaneous and superficial; *external*, which is concave and marked by a sharp ridge, for the insertion of the interosseous membrane; and *posterior*, grooved, for the attachment of muscles. Near the upper extremity of the posterior surface is an oblique ridge, the *popliteal line*, for the attachment of the fascia of the popliteus muscle; and immediately below the oblique line, the nutritious canal, which is directed downwards.

The *inferior extremity* of the bone is somewhat quadrilateral, and prolonged on its inner side into a large process, the *internal malleolus*. Behind the internal malleolus, is a broad and shallow groove, for lodging the tendons of the tibialis posticus and flexor longus digitorum; and farther outwards another groove, for the tendon of the flexor longus pollicis. Upon the outer side the surface is concave and triangular, rough above, for the attachment of the interosseous ligament; and smooth below, to articulate with the fibula. Upon the extremity of the bone is a triangular smooth surface, for articulating with the astragalus.

*Development*.—By three centres; one for the shaft, and one for each extremity. Ossification commences in the tibia, immediately after the femur; the centre for the head of the bone appears soon after birth, and that for the lower extremity during the second year; the latter is the first to join the diaphysis. The bone is not complete until near the twenty-fifth year. Two occasional centres have sometimes been found in the tibia, one in the tubercle, the other in the internal malleolus.

*Articulations*.—With three bones; femur, fibula, and astragalus.

*Attachment of Muscles*.—To ten; by the internal tuberosity, to the sartorius, gracilis, semitendinosus, and semimembranosus; by the external tuberosity, to the tibialis anticus and extensor longus digitorum; by the tubercle, to the ligamentum patellæ; by the external surface of the shaft, to the tibialis anticus; and by the posterior surface, to the popliteus, soleus, flexor longus digitorum, and tibialis posticus.

**FIBULA.**—The fibula (*περόνη*, a brooch, from its resemblance, in conjunction with the tibia, to the pin of an ancient brooch) is the outer and smaller bone of the leg; it is long and slender in figure, prismoid in shape, and, like other long bones, is divisible into a shaft and two extremities.

The *superior extremity* or head is thick and large, and depressed upon the upper part by a concave surface, which articulates with the external tuberosity of the tibia. Externally to this surface is a thick and rough prominence, for the attachment of the external lateral ligament of the knee-joint, terminated behind by a styloid process, for the insertion of the tendon of the biceps.

The *lower extremity* is flattened from without inwards, and prolonged

\* The tibia and fibula of the right leg, articulated and seen from the front. 1. The shaft of the tibia. 2. The inner tuberosity. 3. The outer tuberosity. 4. The spinous process. 5. The tubercle. 6. The internal or subcutaneous surface of the shaft. 7. The lower extremity of the tibia. 8. The internal malleolus. 9. The shaft of the fibula. 10. Its upper extremity. 11. Its lower extremity, the external malleolus. The sharp border between 1 and 6 is the crest of the tibia.

downwards beyond the articular surface of the tibia, forming the *external malleolus*. Its external side presents a rough and triangular surface, which is subcutaneous. Upon the internal surface is a smooth triangular facet, to articulate with the astragalus; and a rough depression, for the attachment of the interosseous ligament. The *anterior border* is thin and sharp; and the *posterior*, broad and grooved, for the tendons of the peronei muscles.

To place the bone in its proper position, and ascertain to which leg it belongs, let the inferior or flattened extremity be directed downwards, and the narrow border of the malleolus forwards; the triangular subcutaneous surface will then point to the side corresponding with the limb of which the bone should form a part.

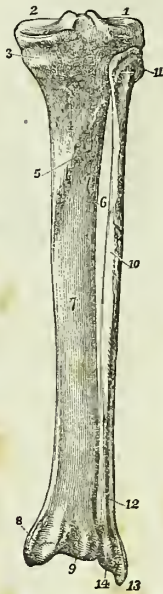The *shaft* of the fibula is prismoid, and presents three surfaces; external, internal, and posterior; and three borders. The *external surface* is the broadest of the three; it commences upon the anterior part of the bone above, and curves around it so as to terminate upon its posterior side below. This surface is completely occupied by the two peronei muscles. The *internal surface* commences on the side of the superior articular surface, and terminates below, by narrowing to a ridge, which is continuous with the anterior border of the malleolus. It is marked along its middle by the *interosseous ridge*, which is lost above and below in the inner border of the bone. The *posterior surface* is twisted like the external; it commences above on the posterior side of the bone, and terminates below on its internal side; at about the middle of this surface is the *nutritious foramen*, which is directed downwards.

The *internal border* commences superiorly in common with the interosseous ridge, and bifurcates inferiorly into two lines, which bound the triangular subcutaneous surface of the external malleolus. The *external border* begins at the base of the styloid process upon the head of the fibula, and winds around the bone, following the direction of the corresponding surface. The *posterior border* is sharp and prominent, and is lost inferiorly in the interosseous ridge.

*Development.*—By three centres; one for the shaft, and one for each extremity. Ossification commences in the shaft soon after its appearance in the tibia; at birth the extremities are cartilaginous, an ossific deposit

\* The tibia and fibula of the right leg articulated and seen from behind. 1. The articular depression for the external condyle of the femur. 2. The articular depression for the internal condyle; the prominence between the two numbers is the spinous process. 3. The fossa and groove for the insertion of the tendon of the semimembranosus muscle. 4. The popliteal plane, for the support of the popliteus muscle. 5. The popliteal line. 6. The nutritious foramen. 7. The surface of the shaft upon which the flexor longus digitorum muscle rests. 8. The broad groove on the back part of the inner malleolus, for the tendons of the flexor longus digitorum and tibialis posticus. 9. The groove for the tendon of the flexor longus pollicis. 10. The shaft of the fibula. The flexor longus pollicis muscle lies upon this surface of the bone; its superior limit being marked by the oblique line immediately above the number. 11. The styloid process on the head of the fibula for the attachment of the tendon of the biceps muscle. 12. The subcutaneous surface of the lower part of the shaft of the fibula. 13. The external malleolus formed by the lower extremity of the fibula. 14. The groove upon the posterior part of the external malleolus for the tendons of the peronei muscles.

Fig. 60.\*



taking place in the inferior epiphysis during the second year, and in the superior during the fourth or fifth. The inferior epiphysis is the first to become united with the diaphysis, but the bone is not completed until nearly the twenty-fifth year.

*Articulations.*—With the tibia and astragalus.

*Attachment of Muscles.*—To *nine*; by the head, to the tendon of the biceps and soleus; by the shaft, its external surface, to the peroneus longus and brevis; internal surface, to the extensor longus digitorum, extensor proprius pollicis, peroneus tertius, and tibialis posticus; by the posterior surface, to the popliteus and flexor longus pollicis.

**TARSUS.**—The bones of the tarsus are *seven* in number; viz. the astragalus, calcaneus, scaphoid, internal middle, and external cuneiform and cuboid.

The **ASTRAGALUS** (os tali) may be recognised by its rounded head, a broad articular facet upon its convex surface, and two articular facets, separated by a deep groove, upon its concave surface.

The bone is divisible into a superior and inferior surface, an external and internal border, and an anterior and posterior extremity. The *superior surface* is convex, and presents a large quadrilateral and smooth facet somewhat broader in front than behind, to articulate with the tibia. The *inferior surface* is concave, and divided by a deep and rough groove (sulcus tali), which lodges a strong interosseous ligament, into two facets, the posterior large and quadrangular, and the anterior smaller and elliptic, which articulate with the os calcis. The *internal border* is flat and irregular, and marked by a pyriform articular surface, for the inner malleolus. The *external* presents a large triangular articular facet, for the external malleolus, and is rough and concave in front. The *anterior extremity* presents a rounded head, surrounded by a constriction somewhat resembling a neck; and the *posterior extremity* is narrow, and marked by a deep groove, for the tendon of the flexor longus pollicis.

Hold the astragalus with the broad articular surface upwards, and the rounded head forwards; the triangular lateral articular surface will point to the side to which the bone belongs.

*Articulations.*—With *four* bones; tibia, fibula, calcaneus, and scaphoid.

The **CALCANEUS** (os calcis) may be known by its large size and oblong figure, by the large and irregular portion which forms the heel, and by two articular surfaces, separated by a broad groove upon its upper side.

The calcaneus is divisible into four surfaces, superior, interior, external, and internal; and two extremities, anterior and posterior. The *superior surface* is convex behind and irregularly concave in front, where it presents two, and sometimes three articular facets, divided by a broad and shallow groove (sulcus calcanei), for the interosseous ligament. The *inferior surface* is convex and rough, and bounded posteriorly by the two inferior tuberosities, of which the internal is broad and large, and the external smaller and prominent. The *external surface* is convex and subcutaneous, and marked towards its anterior third by two grooves, often separated by a tubercle, for the tendons of the peroneus longus and brevis. The *internal surface* is concave and grooved, for the tendons and vessels which pass into the sole of the foot. At the anterior extremity of this

surface is a projecting process (*sustentaculum tali*), which supports the anterior articulating surface of the astragalus, and serves as a pulley to the tendon of the *flexor longus digitorum*. Upon the *anterior extremity* is a flat articular surface, surmounted by a rough projection, which affords one of the guides to the surgeon in the performance of Chopart's operation. The *posterior extremity* is prominent and convex, and constitutes the *posterior tuberosity*; it is smooth for the upper half of its extent, where it corresponds with a bursa; and rough below, for the insertion of the *tendo Achillis*; the lower part of this surface is bounded by the two inferior tuberosities.

*Articulations.*—With *two* bones; the astragalus and cuboid. In their articulated state a large oblique canal is situated between the astragalus and calcaneus, being formed by the apposition of the two grooves *sulcus tali* and *calcanei*. This groove is called the *sinus tarsi*, and serves to lodge a strong interosseous ligament which binds the two bones together.

*Attachment of Muscles.*—To *nine*; by the posterior tuberosity, to the *tendo Achillis* and *plantaris*; by the inferior tuberosities and under surface, to the *abductor pollicis*, *abductor minimi digiti*, *flexor brevis digitorum*, *flexor accessorius*, and to the *plantar fascia*; and by the external surface, to the *extensor brevis digitorum*.

The SCAPHOID bone may be distinguished by its boat-like figure, concave on one side, and convex with three facets upon the other. It presents for examination an anterior and posterior surface, a superior and inferior border, and two extremities, one broad, the other pointed and thick. The *anterior surface* is convex, and divided into three facets, to articulate with the three cuneiform bones; and the *posterior* concave, to articulate with the rounded head of the astragalus. The *superior border* is convex and rough, and the *inferior* somewhat concave and irregular. The *external extremity* is broad and rough, and the *internal* pointed and prominent, so as to form a tuberosity. The external extremity sometimes presents a facet of articulation with the cuboid.

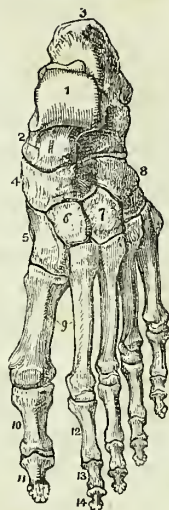If the bone be held so that the convex surface with three facets look forwards, and the convex border upwards, the broad extremity will point to the side corresponding with the foot to which the bone belongs.

*Articulations.*—With *four* bones; astragalus and three cuneiform bones, sometimes also with the cuboid.

*Attachment of Muscles.*—To the tendon of the *tibialis posticus*.

The INTERNAL CUNEIFORM may be known by its irregular wedge-shape, and by being larger than the two other bones bearing the same name. It

Fig. 61.\*



\* The dorsal surface of the left foot. 1. The astragalus; its superior quadrilateral articular surface. 2. The anterior extremity of the astragalus, which articulates with (4) the scaphoid bone. 3. The os calcis. 4. The scaphoid bone. 5. The internal cuneiform bone. 6. The middle cuneiform bone. 7. The external cuneiform bone. 8. The cuboid bone. 9. The metatarsal bones of the first and second toes. 10. The first phalanx of the great toe. 11. The second phalanx of the great toe. 12. The first phalanx of the second toe. 13. Its second phalanx. 14. Its third phalanx.

presents for examination a convex and a concave surface, a long and a short articular border, and a small and a large extremity.

Place the bone so that the small extremity may look upwards and the long articular border forwards, the concave surface will point to the side corresponding with the foot to which it belongs.

The *convex surface* is internal and free, and assists in forming the inner border of the foot; the *concave* is external, and in apposition with the middle cuneiform and second metatarsal bone; the *long border* articulates with the metatarsal bone of the great toe, and the *short border* with the scaphoid bone. The small extremity (edge) is sharp, and the larger extremity (base) rounded into a broad tuberosity.

*Articulations.*—With *four* bones; scaphoid, middle cuneiform, and first two metatarsal bones.

*Attachment of Muscles.*—To the tibialis anticus, and posticus.

The MIDDLE CUNEIFORM is the smallest of the three; it is wedge-shaped, the broad extremity being placed upwards, and the sharp end downwards in the foot. It presents for examination four articular surfaces and two extremities. The *anterior* and *posterior surfaces* have nothing worthy of remark. One of the *lateral surfaces* has a long articular facet, extending its whole length, for the internal cuneiform; the *other* has only a partial articular facet for the external cuneiform bone.

If the bone be held so that the square extremity look upwards, the broadest side of the square being towards the holder, the small and partial articular surface will point to the side to which the bone belongs.

*Articulations.*—With *four* bones; scaphoid, internal and external cuneiform, and second metatarsal bone.

*Attachment of Muscles.*—To the flexor brevis pollicis.

The EXTERNAL CUNEIFORM is intermediate in size between the two preceding, and placed, like the middle, with the broad end upwards and the sharp extremity downwards. It presents for examination five surfaces, and a superior and inferior extremity. The *upper extremity* is flat, of an oblong square form, and bevelled posteriorly, at the expense of the outer surface, into a sharp edge.

If the bone be held so that the square extremity look upwards and the sharp border backwards, the bevelled surface will point to the side corresponding with the foot to which the bone belongs.

*Articulations.*—With *six* bones; scaphoid, middle cuneiform, cuboid, and second, third, and fourth metatarsal bones.

*Attachment of Muscles.*—To the flexor brevis pollicis.

The CUBOID BONE is irregularly cuboid in form, and marked upon its under surface by a deep groove, for the tendon of the peroneus longus muscle. It presents for examination six surfaces, three articular and three non-articular. The *non-articular surfaces* are the *superior*, which is slightly convex, and assists in forming the dorsum of the foot; the *inferior*, marked by a prominent ridge, the *tuberosity*, and a deep groove for the tendon of the peroneus longus; and an *external*, the smallest of the whole, and deeply notched by the commencement of the peroneal groove. The *articular surfaces* are, the *posterior*, which is of large size, and concavo-convex, to articulate with the os calcis; *anterior*, of smaller size, divided



by a slight ridge into two facets, for the fourth and fifth metatarsal bones; and *internal*, a small oval articular facet, upon a large and quadrangular surface, for the external cuneiform bone.

If the bone be held so that the plantar surface, with the peroneal groove, look downwards, and the largest articular surface backwards, the small non-articular surface, marked by the deep notch, will point to the side corresponding with the foot to which the bone belongs.

*Articulations.*—With *four* bones; calcaneus, external cuneiform, and fourth and fifth metatarsal bones, sometimes also with the scaphoid.

*Attachment of Muscles.*—To *three*; the flexor brevis pollicis, adductor pollicis, and flexor brevis minimi digiti.

Upon a consideration of the articulations of the tarsus it will be observed, that each bone articulates with four adjoining bones, with the exception of the calcaneus, which articulates with two, and the external cuneiform with six.

*Development.*—By a single centre for each bone, with the exception of the os calcis, which has an epiphysis for its posterior tuberosity. The centres appear in the following order: calcanean, sixth month; astragalan, seventh month; cuboid, tenth month; external cuneiform, during the first year; internal cuneiform, during the third year; middle cuneiform and scaphoid, during the fourth year. The epiphysis of the calcaneus appears at the ninth year, and is united with the diaphysis at about the fifteenth.

The METATARSAL BONES, *five* in number, are long bones, and divisible therefore into a shaft and two extremities. The shaft is prismoid, and compressed from side to side; the posterior extremity, or base, is square-shaped, to articulate with the tarsal bones, and with each other; and the anterior extremity presents a rounded head, circumscribed by a neck, to articulate with the first row of phalanges.

*Peculiar Metatarsal Bones.*—The *first* is shorter and larger than the rest, and forms part of the inner border of the foot; its posterior extremity presents only one lateral articular surface, and an oval rough prominence beneath, for the insertion of the tendon of the peroneus longus. The anterior extremity has, upon its plantar surface, two grooved facets, for sesamoid bones.

The *second* is the longest and largest of the remaining metatarsal bones; it presents at its base three articular facets, for the three cuneiform bones; a large oval facet, but often no articular surface, on its inner side, to articulate with the metatarsal bone of the great toe, and two externally for the third metatarsal bone.

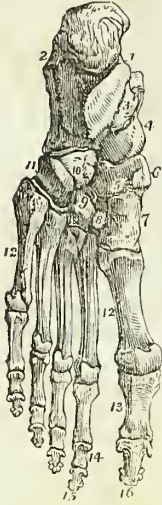The *third* may be known by two facets upon the outer side of its base, corresponding with the second, and may be distinguished by its smaller size.

The *fourth* may be distinguished by its smaller size, and by having a single articular surface on each side of the base.

The *fifth* is recognised by its broad base, and by its large tuberosity in place of an articular surface upon its outer side.

*Development.*—Each bone by *two* centres; one for the body and one for the digital extremity in the four outer metatarsal bones; and one for the body, the other for the base in the metatarsal bone of the great toe. Ossific deposition appears in these bones at the same time with the verte-

Fig. 62.\*



bræ; the epiphyses, commencing with the great toe and proceeding to the fifth, appear towards the close of the second year, consolidation being effected at eighteen.

*Articulations.*—With the tarsal bones by one extremity, and with the first row of phalanges by the other. The number of tarsal bones with which each metatarsal articulates from within outwards, is the same as between the metacarpus and carpus, one for the first, three for the second, one for the third, two for the fourth, and one for the fifth, forming the cipher 13121.

*Attachment of Muscles.*—To fourteen; to the first, the peroneus longus and first dorsal interosseous muscle; to the second, two dorsal interossei and transversus pedis; to the third, two dorsal and one plantar interosseous, adductor pollicis and transversus pedis; to the fourth, two dorsal and one plantar interosseous, adductor pollicis and transversus pedis; to the fifth, one dorsal and one plantar interosseous, peroneus brevis, peroneus tertius, abductor minimi digiti, flexor brevis minimi digiti, and transversus pedis.

**PHALANGES.**—There are two phalanges in the great toe, and three in the other toes, as in the hand. They are long bones, divisible into a central portion and extremities.

The phalanges of the first row are convex above, concave upon the under surface, and compressed from side to side. The posterior extremity has a single concave articular surface, for the head of the metatarsal bone; and the anterior extremity, a pulley-like surface for the second phalanx.

The *second phalanges* are short and diminutive, but somewhat broader than those of the first row.

The *third, or ungual phalanges*, including the second phalanx of the great toe, are flattened from above downwards, spread out laterally at the base, to articulate with the second row, and at the opposite extremity, to support the nail and the rounded extremity of the toe.

*Development.*—By two centres; one for the body and one for the metacarpal extremity. Ossification commences in these bones after that in the metatarsus, appearing first in the last phalanges, then in the first, and last of all in the middle row. The bones are completed at eighteen.

*Articulations.*—The first row with the metatarsal bones and second phalanges; the second, of the great toe with the first phalanx, and of the

\* The sole of the left foot. 1. The inner tuberosity of the os calcis. 2. The outer tuberosity. 3. The groove for the tendon of the flexor longus digitorum; this figure indicates also the sustentaculum tali. 4. The rounded head of the astragalus. 5. The scaphoid bone. 6. Its tuberosity. 7. The internal cuneiform bone; its broad extremity. 8. The middle cuneiform bone. 9. The external cuneiform bone. 10, 11. The cuboid bone. 11. Refers to the groove for the tendon of the peroneus longus: the prominence between this groove and figure 10 is the tuberosity. 12, 12. The metatarsal bones. 13, 13. The first phalanges. 14, 14. The second phalanges of the four lesser toes. 15, 15. The third, or ungual phalanges of the four lesser toes. 16. The last phalanx of the great toe.

other toes with the first and third phalanges; and the third, with the second row.

*Attachment of Muscles.*—To *twenty-three*; to the *first phalanges*; *great toe*, the innermost tendon of the extensor brevis digitorum, abductor pollicis, adductor pollicis, flexor brevis pollicis, and transversus pedis; *second toe*, first dorsal and first palmar interosseous and lumbricalis; *third toe*, second dorsal and second palmar interosseous and lumbricalis; *fourth toe*, third dorsal and third palmar interosseous and lumbricalis; *fifth toe*, fourth dorsal interosseous, abductor minimi digiti, flexor brevis minimi digiti and lumbricalis. *Second phalanges*; *great toe*, extensor longus pollicis, and flexor longus pollicis; *other toes*, one slip of the common tendon of the extensor longus and extensor brevis digitorum, and flexor brevis digitorum. *Third phalanges*; two slips of the common tendon of the extensor longus and extensor brevis digitorum, and the flexor longus digitorum.

**SESAMOID BONES.**—These are small osseous masses, developed in those tendons which exert a certain degree of force upon the surface over which they glide, or where, by continued pressure and friction, the tendon would become a source of irritation to neighbouring parts, as to joints. The best example of a sesamoid bone is the patella, developed in the common tendon of the quadriceps extensor, and resting upon the front of the knee-joint. Besides the patella, there are four pairs of sesamoid bones included in the number of pieces which compose the skeleton, two upon the metacarpo-phalangeal articulation of each thumb, and existing in the tendons of insertion of the flexor pollicis, and two upon the corresponding joint in the foot, in the tendons of the muscles inserted into the base of the first phalanx. In addition to these, there is often a sesamoid bone upon the metacarpo-phalangeal joint of the little finger; and upon the corresponding joint in the foot, in the tendons inserted into the base of the first phalanx; there is one also in the tendon of the peroneus longus muscle, where it glides through the groove in the cuboid bone; sometimes in the tendons, as they wind around the inner and outer malleolus; in the psoas and iliacus, where they glide over the body of the os pubis; and in the external head of the gastrocnemius.

The *bones of the tympanum*, as they belong to the apparatus of hearing, will be described with the anatomy of the ear.

---

### CHAPTER III.

#### ON THE LIGAMENTS.

THE bones are variously connected with each other in the construction of the skeleton, and the connexion between any two bones constitutes a joint or articulation. If the joint be immovable, the surfaces of the bones are applied in direct contact; but if motion be intended, the opposing surfaces are expanded, and coated by an elastic substance, named cartilage; a fluid secreted by a membrane closed on all sides lubricates their

surface, and they are firmly held together by means of short bands of glistening fibres, which are called ligaments (ligare, to bind). The study of the ligaments is named syndesmology (σύν together, δεσμός bond), which, with the anatomy of the articulations, forms the subject of the present chapter.

The forms of articulation met with in the human frame may be considered under three classes: Synarthrosis, Amphiarthrosis, and Diarthrosis.

**SYNARTHROSIS** (σύν, ἄρθρωσις articulation) is expressive of the fixed form of joint in which the bones are immovably connected with each other. The kinds of synarthrosis are four in number. 1. *Sutura*. 2. *Harmonia*. 3. *Schindylesis*. 4. *Gomphosis*. The characters of the three first have been sufficiently explained in the preceding chapter, p. 83. It is here only necessary to state that, in the construction of sutures, the substance of the bones is not in immediate contact, but is separated by a layer of membrane which is continuous externally with the pericranium and internally with the dura mater. It is the latter connexion which gives rise to the great difficulty sometimes experienced in tearing the calvarium from the dura mater. Cruveilhier describes this interposed membrane as the *sutural cartilage*; I never saw any structure in the sutures which could be regarded as cartilage, and the history of the formation of the cranial bones would seem to point to a different explanation. The fourth, Gomphosis (γόμφος, a nail), is expressive of the insertion of one bone into another, in the same manner that a nail is fixed into a board; this is illustrated in the articulation of the teeth with the alveoli of the maxillary bones.

**AMPHI-ARTHROSIS** (ἀμφι both, ἄρθρωσις) is a joint intermediate in aptitude for motion between the immovable synarthrosis and the movable diarthrosis. It is constituted by the approximation of surfaces partly coated with cartilage lined by synovial membrane, and partly connected by interosseous ligaments, or by the intervention of an elastic fibro-cartilage which adheres to the ends of both bones. Examples of this articulation are seen in the union between the bodies of the vertebræ, of the sacrum with the coccyx, of the pieces of the sternum, the sacro-iliac and pubic symphyses (σύν, φύειν, to grow together), and according to some, of the necks of the ribs with the transverse processes.

**DIARTHROSIS** (διὰ through, ἄρθρωσις) is a movable articulation, which constitutes by far the greater number of the joints of the body. The degree of motion in this class has given rise to a subdivision into three genera, Arthrodia, Ginglymus, and Enarthrosis.

*Arthrodia* is the movable joint in which the extent of motion is slight and limited, as in the articulation of the clavicle, of the ribs, articular processes of the vertebræ, axis with the atlas, radius with the ulna, fibula with the tibia, carpal and metacarpal, tarsal and metatarsal bones.

*Ginglymus* (γινγλυμός, a hinge), or hinge-joint; is the movement of bones upon each other in two directions only, viz. forwards and backwards; but the degree of motion may be very considerable. The instances of this form of joint are numerous; they comprehend the elbow, wrist, metacarpo-phalangeal and phalangeal joints in the upper extremity; and the knee, ankle, metatarso-phalangeal and phalangeal joints in the lower extremity. The lower jaw may also be admitted into this category, as partaking more of the character of the hinge-joint than the less movable arthrodia

The form of the ginglymoid joint is somewhat quadrilateral, and each of its four sides is provided with a ligament, which is named from its position, *anterior*, *posterior*, *internal*, or *external lateral*. The *lateral ligaments* are thick and strong, and are the chief bond of union between the bones. The *anterior* and *posterior* are thin and loose, in order to permit the required extent of movement.

*Enarthrosis* (ἐν ἰν, ἄρθρωσις) is the most extensive in its range of motion of all the movable joints. From the manner of connexion and form of the bones in this articulation, it is called the ball-and-socket-joint. There are two instances in the body, viz. the hip and the shoulder.

I have been in the habit of adding to the preceding the carpo-metacarpal articulation of the thumb, although not strictly a ball-and-socket-joint, from the great extent of motion which it enjoys, and from the nature of the ligament connecting the bones. As far as the articular surfaces are concerned, it is rather a double than a single ball-and-socket, and the whole of these considerations remove it from the simple arthro-dial and ginglymoid groups.

The ball-and-socket joint has a circular form; and in place of the four distinct ligaments of the ginglymus, is enclosed in a bag of ligamentous membrane, called a *capsular ligament*.

The kinds of articulation may probably be conveyed in a more satisfactory manner in the tabular form, thus:

|                |   |                        |                            |
|----------------|---|------------------------|----------------------------|
| Synarthrosis.  | { | Sutura - - - -         | bones of the skull.        |
|                |   | Harmonia - - -         | superior maxillary bones.  |
|                |   | Schindylesis - -       | vomer with rostrum.        |
|                |   | Gomphosis - - -        | teeth with alveoli.        |
| Amphi-artrosis | - | Bodies of the vertebræ | - Symphyses.               |
| Diarthrosis.   | { | Arthro-dia - - -       | carpal and tarsal bones.   |
|                |   | Ginglymus - - -        | elbow, wrist, knee, ankle. |
|                |   | Enarthrosis - - -      | hip, shoulder.             |

The motions permitted in joints may be referred to four heads, viz. 1. Gliding. 2. Angular movement. 3. Circumduction. 4. Rotation.

1. *Gliding* is the simple movement of one articular surface upon another, and exists to a greater or less extent in all the joints. In the least movable joints, as in the carpus and tarsus, this is the only motion which is permitted.

2. *Angular movement* may be performed in four different directions, either forwards and backwards, as in flexion and extension; or inwards and outwards, constituting adduction and abduction. Flexion and extension are illustrated in the ginglymoid joint, and exist in a large proportion of the joints of the body. Adduction and abduction conjoined with flexion and extension, are met with complete, only in the most movable joints, as in the shoulder, the hip, and the thumb. In the wrist and in the ankle adduction and abduction are only partial.

3. *Circumduction* is most strikingly exhibited in the shoulder and hip-joints; it consists in the slight degree of motion which takes place in the head of a bone against its articular cavity, while the extremity of the limb is made to describe a large circle upon a plane surface. It is also seen, but in a less degree, in the carpo-metacarpal articulation of the thumb, metacarpophalangeal articulations of the fingers and toes, and in the elbow when that joint is flexed and the end of the humerus fixed.

4. *Rotation* is the movement of a bone upon its own axis, and is illustrated in the hip and shoulder, or better in the rotation of the cup of the radius against the eminentia capitata of the humerus. Rotation is also observed in the movements of the atlas upon the axis, in which the odontoid process serves as a pivot around which the atlas turns.

The structures entering into the composition of a joint are bone, cartilage, fibrous tissue, adipose tissue, and synovial membrane. Cartilage forms a thin coating to the articular extremities of bones, sometimes presenting a smooth surface which moves on a corresponding smooth surface of the articulating bone; sometimes forming a plate smooth on both surfaces and interposed between the cartilaginous ends of two bones, *inter-articular*; and sometimes acting as the connecting medium between bones without any free surface, *interosseous*. Fibrous tissue enters into the construction of joints under the form of ligament, in one situation constituting bands of various breadth and thickness, in another a layer which extends completely around the joint, and is then called a *capsular ligament*. All the ligaments of joints are composed of that variety of fibrous tissue termed white fibrous tissue, but in some situations ligaments are found which consist of yellow fibrous tissue, for example, the ligamenta subflava of the arches of the vertebral column. Adipose tissue exists in variable quantity in relation with joints, where it performs, among other offices, that of a valve or spring, which occupies any vacant space that may be formed during the movements of the joint, and effectually prevents the occurrence of a vacuum in those cavities. This purpose of adipose tissue is exemplified in the cushion of fat at the bottom of the acetabulum, and in the similar cushion behind the ligamentum patellæ. Synovial membrane constitutes the beautiful smooth and polished lining of a joint, and contains the fluid termed synovia, by means of which the adapted surfaces are enabled to move upon each other with the perfect ease and freedom which are known to exist.

**CARTILAGE.**—In the structure of joints, cartilage serves the double purpose of a connecting and separating medium. In the former capacity possessing great strength, and in the latter smoothness and elasticity. In

Fig. 63.\*

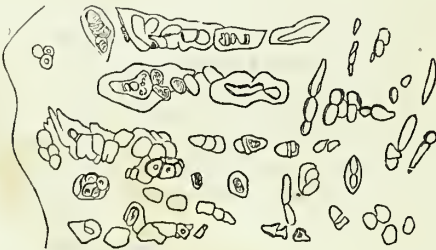
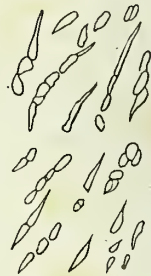

Fig. 64.†




\* A portion of articular cartilage from the head of the fibula, showing the appearance and arrangement of the cells near to the bone. The section is made vertically to the surface, and magnified 155 diameters. The irregular line to the right is the boundary of the bone

† A view of the same section, at about midway between the bone and the free-surface.

reference to its intimate structure it admits of classification into three kinds,—true cartilage, reticular cartilage, and fibrous cartilage.

*True Cartilage* is composed of a semi-transparent homogeneous substance (hyaline or vitreous substance) containing a number of minute cells (cartilage corpuscles) dispersed at short intervals through its structure. The cells are oval, oblong, or polyhedral in shape, and more or less flattened; their membranous envelope is blended with the intercellular substance, and they contain in their interior secondary cells, nuclei, nucleoli, oil-globules, and more or less of granular matter. Cartilage cells have an average measurement of  $\frac{1}{1500}$  of an inch in their long diameter; they are sometimes isolated, sometimes grouped in pairs, and sometimes disposed in a linear group of three or four. They are larger near the bone than at the surface, and in the latter situation are long and slender in form, and arranged in rows having their long axis parallel with the plane of the surface. True cartilage is pearl-white or bluish and opaline in colour, and its intercellular substance is semitransparent and structureless. These characters, however, are changed when it exhibits a tendency to ossify. In the latter case the intercellular substance becomes fibrous and more or less opaque, its colour is yellowish, and the cells are found to contain a greater number of oil-globules than in its natural state.

Fig. 65.\*



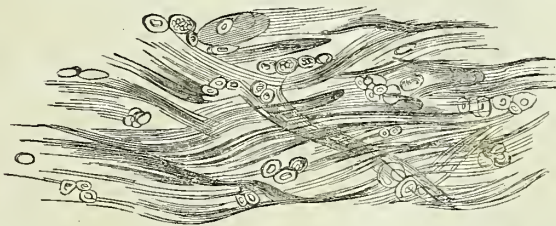
The true cartilages are, the articular, costal, ensiform, thyroid, cricoid, arytenoid, tracheal and bronchial, nasal, meatus auris, the pulley of the trochlearis muscle, and temporary cartilage or the cartilage of bone previously to ossification.†

*Reticular cartilage* is composed of cells ( $\frac{1}{1500}$  of an inch in diameter), separated from each other by an opaque, subfibrous, intercellular network, the breadth of the cells being considerably greater than that of the intercellular structure. The cells are parent cells, containing others of secondary formation, together with nuclei, nucleoli, granular matter, and oil-globules in greater number than those of true cartilage. The fibres are short, imperfect, loose in texture, and yellowish. The instances of reticular cartilage are, the pinna, epiglottis, and Eustachian tube.

Fig. 66.‡

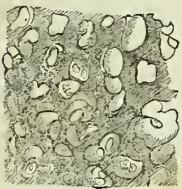

Fig. 67.§



\* A portion of articular cartilage near the synovial surface of an articulation; the line to the left is that of the synovial boundary.

† Page 47.

‡ A portion of reticular cartilage. The section is taken from the pinna, and magnified 155 diameters.

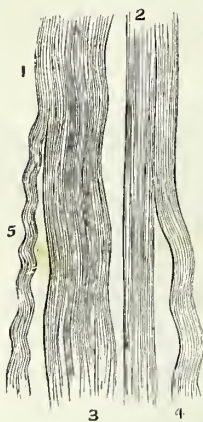
§ A portion of fibrous cartilage. The section is taken from the symphysis pubis, and magnified 155 diameters.

*Fibrous cartilage* is composed of a network of white glistening fibres, collected into fasciculi of various size, and containing in its meshes cells and a subfibrous tissue resembling that of reticular cartilage. The fibres of fibrous cartilages are identical with those of fibrous tissue, the cells are large (about  $\frac{1}{250}$ th of an inch) as in reticular cartilage, and the areolæ are variable in dimensions. It is this latter character that constitutes the difference between different fibrous cartilages, some being composed almost entirely of fibres with few and small interstices, as the interarticular cartilages, while others exhibit large spaces filled with an imperfect fibrous tissue and cells, as the intervertebral substance.

The fibrous cartilages admit of arrangement into four groups, namely, interarticular, stratiform, interosseous, and free. The instances of *interarticular fibrous cartilages* (menisci) are those of the lower jaw, sternal and acromial end of the clavicle, wrist, carpus, knee, to which may be added the fibrous cartilages of circumference, glenoid and cotyloid. The *stratiform fibrous cartilages* are such as form a thin coating to the grooves on bone through which tendons play. The *interosseous fibrous cartilages* are the intervertebral substance and symphysis pubis. The *free fibrous cartilages* are the tarsal cartilages of the eyelids.

The *development* of cartilage is the same with that of cartilage of bone (page 46), the different forms of cartilage resulting from subsequent changes in the intercellular substance and cells. Thus, for example, in articular cartilage the cells undergo the lowest degree of development, are very disproportionate to the intercellular substance, and the latter remains permanently structureless. In reticular cartilage the cells possess a more active growth, and surpass in bulk the intercellular substance, while the latter is composed also of cells, which assume a fibrous disposition. In fibrous cartilage development is most energetic in the intercellular substance; this is converted into fasciculi of fibrous tissue, while the interspaces are filled with cells and imperfect fibrous tissue in every stage of development.

Fig. 68.\*



FIBROUS TISSUE is one of the most generally distributed of all the animal tissues; it is composed of *fibres* of extreme minuteness, and presents itself under three elementary forms; namely, white fibrous tissue, yellow fibrous tissue, and red fibrous tissue.

In *white fibrous tissue* the fibres are cylindrical, exceedingly minute, (about  $\frac{1}{15000}$  of an inch in diameter), transparent and undulating; they are collected into small fasciculi (from  $\frac{1}{3000}$  to  $\frac{1}{10000}$  of an inch) and these latter form larger fasciculi, which according to their arrangement give rise to the production of thin laminae, membranes, ligamentous bands, and tendinous cords. The connecting medium of the fibres in the formation of the primitive fasciculi is a transparent structureless interfibrous substance or blastema, to which in most situations are added numerous minute dark filaments derived from nuclei and thence termed nuclear filaments.

\* White fibrous tissue:—2. Straight appearance of the tissue when stretched. 1, 3, 4, 5. Various wavy appearances which the tissue exhibits when not stretched.—Magnified 320 diameters.



The nuclear filaments are sometimes wound spirally around the fasciculi or interlace with their separate fibres, at other times they are variously twisted and run parallel with the fasciculi. The fasciculi are connected and held together in the formation of membranes and cords by loose fibres which are interwoven between them, or by mutual interlacement.

Examples of white fibrous tissue are met with in three principal forms, namely, membrane, ligament, and tendon.

The *membranous form* of white fibrous tissue is seen in the common connecting medium of the body, namely, fibro-cellular or areolar tissue, in which the membrane is extremely thin and disposed in laminæ, bands, or threads, leaving interstices of various size between them. It is seen also in the condensed covering of various organs, as the periosteum, perichondrium, capsulæ propriæ of glands, membranes of the brain, sclerotic coat of the eyeball, pericardium, fasciæ; sheaths of muscles, tendons, vessels, nerves, and ducts; sheaths of the erectile organs, and the corium of the dermic and mucous membrane.

*Ligament* is the name given to those bands of various breadth and thickness which retain the articular ends of bones in contact in the construction of joints. They are glistening and inelastic, and composed of fasciculi of fibrous tissue ranged in a parallel direction side by side, or in some situations interwoven with each other. The fasciculi are held together by separate fibres, or by areolar tissue.

*Tendon* is the collection of parallel fasciculi of fibrous tissue, by means of which muscles are attached to bones. They are constructed on the same principle with ligaments, are usually rounded in their figure, but in some instances are spread out so as to assume a membranous form. In the latter state they are called *aponeuroses*.

*Yellow fibrous tissue* is known also by the appellation *elastic tissue*, from one of its more prominent physical properties, a property which permits of its fibres being drawn out to double their length, and again returning to their original dimensions. The fibres of elastic tissue are transparent, brittle, flat or polyhedral in shape, colourless when single, but yellowish in an aggregated form, and considerably thicker ( $\frac{3}{1000}$  of an inch in diameter) than the fibres of white fibrous tissue. In the construction of their peculiar tissue they communicate with each other by means of short oblique fibres, which unite with adjoining fibres at acute or obtuse angles, without any enlargement of the fibre with which they are joined. This circumstance has given rise to the idea of these fibres giving off branches, an expression derived from the division of blood-vessels, and another term borrowed from the same source has been applied to their communication with each other, namely, *inosculation*; but both these expressions in their literal meaning are incorrect. When yellow fibrous tissue is cut or torn, the fibres in consequence of their elasticity become clubbed and curved at the extremity, a striking character of this tissue.

Fig. 69.\*

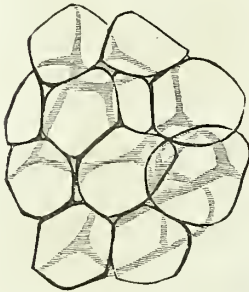


\* Yellow fibrous tissue, showing the curly and branched disposition of its fibrillæ, their definite outline, and abrupt mode of fracture. At 1, the structure is not disturbed, as in the rest of the specimen. Magnified 320 diameters.

The instances of yellow fibrous tissue are: the ligamenta subflava of the arches of the vertebræ, cordæ vocales, thyro-epiglottic ligament, crico-thyroidean membrane, the membranous layers connecting the cartilaginous rings of the trachea and bronchial tubes, the capsula propria of the spleen and the middle coat of arteries. It is also met with around some parts of the alimentary canal, as the œsophagus, cardia, and anus, around the male and female urethra, in the fascia lata, and in the corium of the skin.

*Red fibrous tissue* is also termed *contractile tissue*, from a peculiar property which it possesses, and which places it physiologically in an intermediate position between white fibrous tissue and muscular fibre. Its fibres are cylindrical, transparent, reddish in hue, and collected into fasciculi. It is met with in the corium of the skin, in the dartos, around the nipple, in the excretory ducts of glands, in the coats of blood-vessels, particularly veins, in the iris, in the intervacular spaces of the erectile tissue of the penis and clitoris, around the urethra, and around the vagina.

Fig. 70.\*



ADIPOSE TISSUE is composed of minute cells, aggregated together in clusters of various size within the areolæ of fibro-cellular tissue. The cells of adipose tissue are identical in manner of formation with other cells, being developed on nuclei and increasing in size by the formation of fluid in their interior. In adipose cells this fluid, instead of being albuminous as in other cells, is oleaginous, the oil at first appearing in separate globules, which subsequently coalesce into a single drop. The size of adipose cells at their full development is about  $\frac{1}{700}$  of an inch in diameter; when isolated they are globular in form, but are hexagonal or polyhedral when compressed. They are perfectly transparent, the cell-membrane being structureless and their nucleus disappearing as they attain their full size.

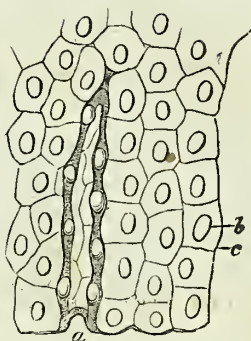
SYNOVIAL MEMBRANE is a thin membranous layer, which invests the articular cartilages of the bones, and is thence reflected upon the surfaces of the ligaments which surround and enter into the composition of a joint. It resembles the serous membranes in being a shut sac, and secretes a transparent and viscous fluid, which is named synovia. Synovia is an alkaline secretion, containing albumen, which is coagulable at a boiling temperature. The continuation of this membrane over the surface of the articular cartilage, a much-agitated question, has been decided by the interesting discoveries of Henle, who has ascertained the existence of an epithelium upon cartilage identical with that produced by the reflected portion of the membrane. In some of the joints the synovial membrane is pressed into the articular cavity by a cushion of fat: this mass was called by Havers the synovial gland, from an incorrect supposition that it was the source of the synovia; it is found in the hip and in the knee-joint. In the knee-joint, moreover, the synovial membrane forms folds, which are most improperly named ligaments, as the mucous and alar ligaments, the two latter being an appendage to the cushion of fat. Besides the

\* Fat vesicles, assuming the polyhedral form from pressure against one another. The capillary vessels are not represented. From the omentum: magnified about 300 diameters.

synovial membranes entering into the composition of joints, there are numerous smaller sacs of a similar kind interposed between surfaces which move upon each other so as to cause friction; they are often associated with the articulations. These are the *bursæ mucosæ*; they are shut sacs, analogous in structure to synovial membranes, and secreting a similar synovial fluid.

The epithelium of synovial membranes is of the kind termed tessellated; it is developed in the same manner with the epithelium of other free surfaces, and is continually reproduced from beneath, while the superficial layers are being rubbed off and lost.

Fig. 71.\*



## ARTICULATIONS.

The joints may be arranged, according to a natural division, into those of the trunk, those of the upper extremity, and those of the lower extremity.

LIGAMENTS OF THE TRUNK.—The articulations of the trunk are divisible into ten groups, viz.—

1. Of the vertebral column.
2. Of the atlas, with the occipital bone.
3. Of the axis, with the occipital bone.
4. Of the atlas, with the axis.
5. Of the lower jaw.
6. Of the ribs, with the vertebræ.
7. Of the ribs, with the sternum, and with each other.
8. Of the sternum.
9. Of the vertebral column, with the pelvis.
10. Of the pelvis.

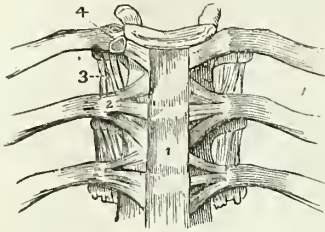
1. *Articulation of the Vertebral Column.*—The ligaments connecting together the different pieces of the vertebral column, admit of the same arrangement with that of the vertebræ themselves. Thus the ligaments

|                                       |                                                                                      |
|---------------------------------------|--------------------------------------------------------------------------------------|
| Of the <i>bodies</i> are the—         | Anterior common ligament,<br>Posterior common ligament,<br>Intervertebral substance. |
| Of the <i>arches</i> ,—               | Ligamenta subflava.                                                                  |
| Of the <i>articular processes</i> ,—  | Capsular ligaments,<br>Synovial membranes.                                           |
| Of the <i>spinous processes</i> ,—    | Inter-spinous,<br>Supra-spinous.                                                     |
| Of the <i>transverse processes</i> ,— | Inter-transverse.                                                                    |

\* Epithelium of serous membrane:—At *a*, an accidental fold is represented, the two dark edges of which exhibit the thickness of the particles, and of their nuclei. *b*. One of the oval nuclei. *c*. Line of junction between two particles. Magnified 300 diameters.

**BODIES.**—The *Anterior common ligament* is a broad and riband-like band of ligamentous fibres, extending along the front surface of the vertebral column, from the axis to the sacrum. It is intimately connected

Fig. 72.\*

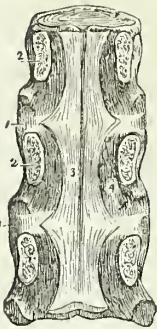


with the intervertebral substances, and less closely with the bodies of the vertebræ. In the dorsal region it is thicker than in the cervical and lumbar, and consists of a median and two lateral portions, separated from each other by a series of openings for the passage of vessels. The ligament is composed of fibres of various length closely interwoven with each other; the *deeper* and shorter crossing the intervertebral substances from one vertebra to the next;

and the *superficial* and longer fibres crossing three or four vertebræ.

The anterior common ligament is in relation by its *posterior* or *vertebral surface*, with the intervertebral substances, the bodies of the vertebræ, and with the vessels, principally veins, which separate its central from its lateral portions. By its *anterior* or *visceral surface* it is in relation in the neck, with the longus colli muscles, the pharynx and the œsophagus; in the thoracic region, with the aorta, the *venæ azygos*, and thoracic duct; and in the lumbar region with the aorta, right renal artery, right lumbar arteries, *arteria sacra media*, vena cava inferior, left lumbar veins, receptaculum chyli, the commencement of the thoracic duct, and the tendons of the lesser muscle of the diaphragm with the fibres of which the ligamentous fibres interlace.

Fig. 73.†



The *Posterior common ligament* lies upon the posterior surface of the bodies of the vertebræ, and extends from the axis to the sacrum. It is broad opposite the intervertebral substances, to which it is closely adherent; and narrow and thick over the bodies of the vertebræ, from which it is separated by the veins of the base of the vertebræ.

It is composed like the anterior ligament of shorter and longer fibres which are disposed in a similar manner.

The posterior common ligament is in relation by its *anterior surface* with the intervertebral substances, the bodies of the vertebræ, and with the *venæ basum vertebrarum*; and by its *posterior surface* with the *dura mater* of the spinal cord, some loose areolar tissue and numerous small veins being interposed.

The *intervertebral substance* is a lenticular disc of fibrous cartilage,

\* The anterior ligaments of the vertebræ, and ligaments of the ribs. 1. The anterior common ligament. 2. The anterior costo-vertebral or stellate ligament. 3. The anterior costo-transverse ligament. 4. The interarticular ligament connecting the head of the rib to the intervertebral substance, and separating the two synovial membranes of this articulation.

† A posterior view of the bodies of three dorsal vertebræ, connected by their intervertebral substance 1, 1. The laminae (2) have been sawn through near the bodies of the vertebræ, and the arches and processes removed, in order to show (3) the posterior common ligament. A part of one of the openings in the posterior surface of the vertebræ, for the transmission of the *vena basis vertebræ*, is seen at 4, by the side of the narrow and unattached portion of the ligament.

interposed between each of the vertebræ from the axis to the sacrum, and retaining them firmly in connexion with each other. It differs in thickness in different parts of the column, and varies in depth at different points of its extent; thus, it is thickest in the lumbar region, deepest in front in the cervical and lumbar regions, and behind in the dorsal region; and contributes, in a great measure, to the formation of the natural curves of the vertebral column.

When the intervertebral substance is bisected either horizontally or vertically, it is seen to be composed of a series of layers of dense fibrous tissue, separated by interstices filled with the softer kind. The central part of each intervertebral disc is wholly made up of this softer fibrous cartilage, which has the appearance of a pulp, and is so elastic as to rise above the level of the section as soon as its division is completed. When examined from the front, the layers are found to consist of fibres passing obliquely between the two vertebræ, in one layer passing from left to right, in the next from right to left, alternating in each successive layer.

ARCHES. — The *ligamenta subflava* are two thin planes, of yellow fibrous tissue, situated between the arches of each pair of vertebræ, from the axis to the sacrum. From the imbricated position of the laminae they are attached to the posterior surface of the vertebra below, and to the anterior surface of the arch of the vertebra above, and are separated from each other at the middle line by a slight interspace. They counteract by their elasticity, the efforts of the flexor muscles of the trunk; and by preserving the upright position of the spine, limit the expenditure of muscular force. They are longer in the cervical than in the other regions of the spine, and are thickest in the lumbar region.

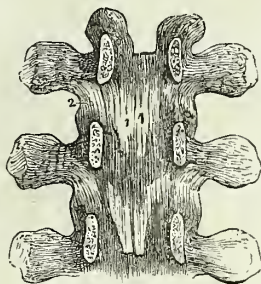
The *ligamenta subflava* are in relation by both surfaces with the meningo-rachidian veins, and internally they are separated from the dura mater of the spinal cord by those veins and some loose areolar and adipose tissue.

ARTICULAR PROCESSES. — The ligaments of the articular processes of the vertebræ are loose synovial *capsules* which surround the articulating surfaces. They are protected on their external side by a thin layer of ligamentous fibres.

SPINOUS PROCESSES. — The *inter-spinous* ligaments are thin and membranous, and are extended between the spinous processes in the dorsal and lumbar regions. They are thickest in the latter region; and are in relation with the multifidus spinæ muscle at each side.

The *Supra-spinous* ligament (fig. 82) is a strong and inelastic fibrous cord, which extends from the apex of the spinous process of the last cervical vertebra to the sacrum, being attached to each spinous process in its course; it is thickest in the lumbar region. The continuation of this ligament upwards to the tuberosity of the occipital bone, constitutes the rudimentary *ligamentum nuchæ* of man. The latter is strengthened, as in

Fig. 74.\*



\* An internal view of the arches of three vertebræ. To obtain this view the laminae have been divided through their pedicles. 1. One of the *ligamenta subflava*. 2 The capsular ligament of one side.

animals, by a thin slip from the spinous process of each of the cervical vertebræ.

**TRANSVERSE PROCESSES.** — The *inter-transverse ligaments* are thin and membranous; they are found only between the transverse processes of the lower dorsal vertebræ.

2. *Articulation of the Atlas with the Occipital bone.* — The ligaments of this articulation are *seven* in number,—

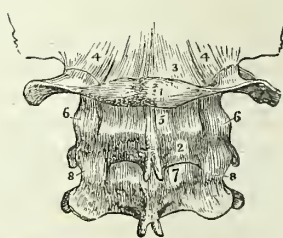
|                               |                            |
|-------------------------------|----------------------------|
| Two anterior occipito-atloid, | Posterior occipito-atloid, |
| Lateral occipito-atloid,      | Two capsular.              |

Of the two *anterior ligaments*, one is a *rounded cord*, situated in the middle line, and superficially to the other. It is attached *above*, to the basilar process of the occipital bone; and *below*, to the anterior tubercle of the atlas. The deeper ligament is a *broad* membranous layer, attached above, to the margin of the occipital foramen; and below, to the whole length of the anterior arch of the atlas. It is in relation in front with the *recti antici minores*, and behind with the *odontoid ligaments*.

Fig. 75.\*

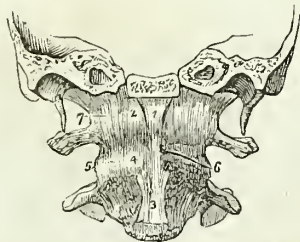

Fig. 76.†



The *posterior ligament* is thin and membranous; it is attached above, to the margin of the occipital foramen; and below, to the posterior arch of the atlas. It is closely adherent to the *dura mater*, by its inner surface; and forms a ligamentous arch at each side, for the passage of the vertebral arteries and first cervical nerves. It is in relation posteriorly with the *recti postici minores* and *obliqui superiores*.

The *lateral ligaments* are strong fasciculi of ligamentous fibres, attached below, to the base of the transverse process of the atlas at each side, and above, to the transverse process of the occipital bone. With a ligamentous expansion derived from the vaginal process of the temporal bone, these

\* An anterior view of the ligaments connecting the atlas, the axis, and the occipital bone. A transverse section has been carried through the base of the skull, dividing the basilar process of the occipital bone and the petrous portions of the temporal bones. 1. The anterior round occipito-atloid ligament. 2. The anterior broad occipito-atloid ligament. 3. The commencement of the anterior common ligament. 4. The anterior atlo-axoid ligament, which is continuous inferiorly with the commencement of the anterior common ligament. 5. One of the atlo-axoid capsular ligaments; the one on the opposite side has been removed, to show the approximated surfaces of the articular processes (6). 7. One of the occipito-atloid capsular ligaments. The most external of these fibres constitute the lateral occipito-atloid ligament.

† The posterior ligaments of the occipito-atloid, and atlo-axoid articulations. 1. The atlas. 2. The axis. 3. The posterior ligament of the occipito-atloid articulation. 4, 4. The capsular and lateral ligaments of this articulation. 5. The posterior ligament of the atlo-axoid articulation. 6, 6. Its capsular ligaments. 7. The first of the ligamentum subflava passing between the axis and the third cervical vertebra. 8, 8. The capsular ligaments of those vertebræ.

ligaments form a strong sheath around the vessels and nerves which pass through the carotid and jugular foramina.

The *capsular ligaments* are the thin and loose ligamentous capsules which surround the synovial membranes of the articulations between the condyles of the occipital bone and the superior articular processes of the atlas. The ligamentous fibres are most numerous upon the anterior and external part of the articulation.

The *movements* taking place between the cranium and atlas, are those of flexion and erection, giving rise to the forward nodding of the head. When this motion is increased to any extent the whole of the cervical region concurs in its production.

3. *Articulation of the Axis with the Occipital bone.*—The ligaments of this articulation are *three* in number,—

Occipito-axoid,

Two odontoid.

The *occipito-axoid ligament* (apparatus ligamentosus colli) is a broad band, which covers in the odontoid process and its ligaments. It is attached below to the body of the axis, where it is continuous with the posterior common ligament; superiorly it is inserted by a broad expansion, into the basilar groove of the occipital bone. It is firmly connected opposite the body of the axis, with the dura mater; and sometimes is described as consisting of a central and two lateral portions; this, however, is an unnecessary refinement.

The *odontoid ligaments* (alar) are two short and thick fasciculi of fibres, which pass outwards from the apex of the odontoid process, to the sides of the occipital foramen and condyles. A third and smaller fasciculus (ligamentum suspensorium), or middle straight ligament, proceeds from the apex of the odontoid process to the anterior margin of the foramen magnum.

These ligaments serve to limit the extent to which rotation of the head may be carried, hence they are termed *check ligaments*.

4. *Articulation of the Atlas with the Axis.*—The ligaments of this articulation are *five* in number,—

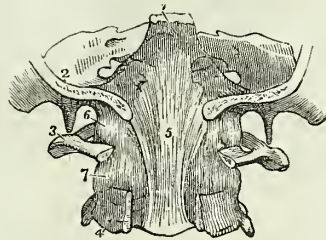
Anterior atlo-axoid,  
Posterior atlo-axoid,

Two capsular,  
Transverse.

The *anterior ligament* consists of ligamentous fibres, which pass from the anterior tubercle and arch of the atlas to the base of the odontoid process and body of the axis, where they are continuous with the commencement of the anterior common ligament.

\* The upper part of the vertebral canal, opened from behind in order to show the occipito-axoid ligament. 1. The basilar portion of the sphenoid bone. 2. Section of the occipital bone. 3. The atlas, its posterior arch removed. 4. The axis, the posterior arch also removed. 5. The occipito-axoid ligament, rendered prominent at its middle by the projection of the odontoid process. 6. Lateral and capsular ligament of the occipito-atloid articulation. 7. Capsular ligament between the articulating processes of the atlas and axis.

Fig. 77.\*

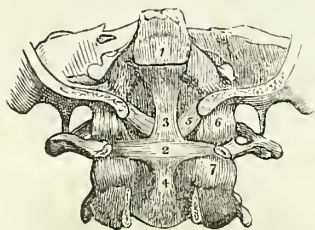


The *posterior ligament* is a thin and membranous layer, passing between the posterior arch of the atlas and the laminæ of the axis.

The *capsular ligaments* surround the articular processes of the atlas and axis; they are loose, to permit of the freedom of movement which subsists between these vertebræ. The ligamentous fibres are most numerous on the outer and anterior part of the articulation, and the synovial membrane usually communicates with the synovial cavity between the transverse ligament and the odontoid process.

The *transverse ligament* is a strong ligamentous band, which arches across the area of the ring of the atlas from a rough tubercle upon the

Fig. 78.\*



inner surface of one articular process to a similar tubercle on the other. It serves to retain the odontoid process of the axis, in connexion with the anterior arch of the atlas. As it crosses the odontoid process, some fibres are sent downwards to be attached to the body of the axis, and others pass upwards to be inserted into the basilar process of the occipital bone; hence the ligament has a cross-like appearance, derived from these appendices, and has been denominated *cruciform*. A synovial membrane is situated between the transverse ligament and the odontoid process; and another between that process and the inner surface of the anterior arch of the atlas.

*Actions.*—It is the peculiar disposition of this ligament in relation to the odontoid process, that enables the atlas, and with it the entire cranium, to rotate upon the axis; the perfect freedom of movement between these bones being insured by the two synovial membranes. The lower part of the ring, formed by the transverse ligament with the atlas, is smaller than the upper, while the summit of the odontoid process is larger than its base; so that the process is still retained in its position by the transverse ligament, when the other ligaments are cut through. The extent to which the rotation of the head upon the axis can be carried is determined by the odontoid ligaments. The odontoid process with its ligaments is covered in by the occipito-axoid ligament.

5. *Articulation of the lower jaw.*—The lower jaw has properly but one ligament, the *external lateral*; the ligaments usually described are three in number; to which may be added, as appertaining to the mechanism of the joint, an interarticular fibrous cartilage, and two synovial membranes,—

External lateral,  
Internal lateral,  
Capsular.

Interarticular fibrous-cartilage,  
Two synovial membranes,

\* A posterior view of the ligaments connecting the atlas, the axis, and the occipital bone. The posterior part of the occipital bone has been sawn away, and the arches of the atlas and axis removed. 1. The superior part of the occipito-axoid ligament, which has been cut away in order to show the ligaments beneath. 2. The transverse ligament of the atlas. 3. 4. The ascending and descending slips of the transverse ligament, which have obtained for it the title of cruciform ligament. 5. One of the odontoid ligaments; the fellow ligament is seen on the opposite side. 6. One of the occipito-axoid capsular ligaments. 7. One of the atlas-axoid capsular ligaments.



The *external lateral ligament* is a short and thick band of fibres, passing obliquely backwards from the tubercle of the zygoma, to the external surface of the neck of the lower jaw. It is in relation, externally with the integument of the face, and internally with the two synovial membranes of the articulation and the interarticular cartilage. The external lateral ligament acts conjointly with its fellow of the opposite side of the head in the movements of the jaw.

The *internal lateral ligament* has no connexion with the articulation of the lower jaw, and is incorrectly named in relation to the joint; it is a thin aponeurotic expansion extending from the extremity of the spinous process of the sphenoid bone to the margin of the dental foramen. It is pierced at its insertion, by the mylo-hyoidean nerve.

Fig. 79.\*

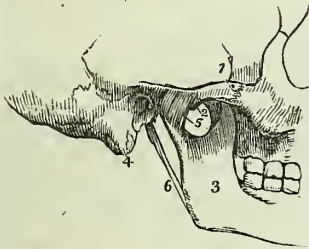
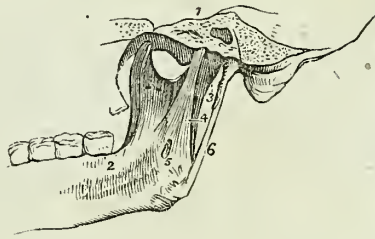


Fig. 80.†



A triangular space is left between the internal lateral ligament and the neck of the jaw, in which are situated the internal maxillary artery and auricular nerve, the inferior dental artery and nerve, and a part of the external pterygoid muscle; internally it is in relation with the internal pterygoid muscle.

The *capsular ligament* consists of a few irregular ligamentous fibres, which pass from the edge of the glenoid cavity to the neck of the lower jaw, upon the inner and posterior side of the articulation. These fibres scarcely deserve consideration as a distinct ligament.

The *interarticular fibrous cartilage* is a thin oval plate, thicker at the edges than in the centre, and placed horizontally between the head of the condyle of the lower jaw and the glenoid cavity. It is connected by its outer border with the external lateral ligament, and in front receives some fibres of the external pterygoid muscle. Occasionally it is incomplete in the centre. It divides the joint into two distinct cavities, the one being above and the other below the cartilage.

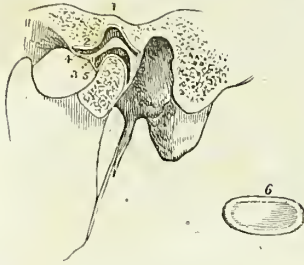
The *synovial membranes* are situated the one above, the other below, the fibrous cartilage, the former being the larger of the two. When the fibrous cartilage is perforate, the synovial membranes communicate.

\* An external view of the articulation of the lower jaw. 1. The zygomatic arch. 2. The tubercle of the zygoma. 3. The ramus of the lower jaw. 4. The mastoid portion of the temporal bone. 5. The external lateral ligament. 6. The stylo-maxillary ligament.

† An internal view of the articulation of the lower jaw. 1. A section through the petrous portion of the temporal bone and spinous process of the sphenoid. 2. An internal view of the ramus, and part of the body of the lower jaw. 3. The internal portion of the capsular ligament. 4. The internal lateral ligament. 5. A small interval at its insertion, through which the mylo-hyoidean nerve passes. 6. The stylo-maxillary ligament, a process of the deep cervical fascia.

Besides the lower jaw, there are several other joints provided with a complete interarticular cartilage, and, consequently, with two synovial membranes; they are, the *sterno-clavicular articulation*, the *acromio-clavicular* and the *articulation of the ulna with the cuneiform bone*.

Fig. 81.\*



The interarticular fibrous cartilages of the *knee-joint* are partial, and there is but one synovial membrane.

The articulations of the heads of the ribs with the vertebræ have two synovial membranes, separated by an interarticular ligament, without fibrous cartilage.

*Actions.*—The movements of the lower jaw are *depression*, by which the mouth is opened; *elevation*, by which it is closed; a *forward* and *backward* movement, and a movement from *side to side*.

In the movement of *depression*, the interarticular cartilage glides forwards on the eminentia articularis, carrying with it the condyle. If this movement be carried too far, the superior synovial membrane is ruptured, and dislocation of the fibro-cartilage with its condyle into the zygomatic fossa occurs. In *elevation*, the fibrous cartilage and condyle are returned to their original position. The *forward* and *backward* movement is a gliding of the fibro-cartilage upon the glenoid articular surface, in the antero-posterior direction; and the movement from *side to side*, in the lateral direction.

6. *Articulation of the Ribs with the Vertebræ.*—The ligaments of these articulations are so strong as to render dislocation impossible, the neck of the rib would break before displacement could occur; they are divisible into two groups:—1. Those connecting the *head of the rib* with the bodies of the *vertebræ*; and, 2. Those connecting the *neck and tubercle of the rib* with the *transverse processes*. They are—

#### 1st Group.

Anterior costo-vertebral or stellate,  
Capsular,

Interarticular ligament,  
Two synovial membranes.

#### 2d Group.

Anterior costo-transverse,  
Middle costo-transverse,  
Posterior costo-transverse.

The *anterior costo-vertebral* or *stellate ligament* (fig. 72) consists of three short bands of ligamentous fibres that radiate from the anterior part of the head of the rib. The *superior band* passes upwards, and is attached to the vertebra above: the *middle fasciculus* is attached to the intervertebral substance; and the *inferior*, to the vertebræ below.

\* In this sketch a section has been carried through the joint, in order to show the natural position of the interarticular fibro-cartilage, and the manner in which it is adapted to the difference of form of the articulating surfaces. 1. The glenoid fossa. 2. The eminentia articularis. 3. The interarticular fibro-cartilage. 4. The superior synovial cavity. 5. The inferior synovial cavity. 6. An interarticular fibro-cartilage, removed from the joint, in order to show its oval and concave form; it is seen from below

In the *first, eleventh, and twelfth* ribs, the three fasciculi are attached to the body of the corresponding vertebra.

The *capsular ligament* is a thin layer of ligamentous fibres, surrounding the joint in the interval left by the anterior ligament; it is thickest above and below the articulation, and protects the synovial membranes.

The *interarticular ligament* is a thin band which passes between the sharp crest on the head of the rib and the intervertebral substance. It divides the joint into two cavities, which are each furnished with a separate *synovial membrane*. The *first, eleventh, and twelfth* ribs have no interarticular ligament, and consequently but one synovial membrane.

The *anterior costo-transverse ligament* is a broad band composed of several fasciculi, which ascends from the crest-like ridge on the neck of the rib, to the transverse process immediately above. This ligament separates the anterior from the posterior branch of the intercostal nerves.

The *middle costo-transverse ligament* is a very strong interosseous ligament, passing directly between the posterior surface of the neck of the rib, and the transverse process against which it rests.

The *posterior costo-transverse ligament* is a small but strong fasciculus, passing obliquely from the tubercle of the rib, to the apex of the transverse process. The articulation between the tubercle of the rib and the transverse process is provided with a small synovial membrane.

There is no anterior costo-transverse ligament to the first rib; and only rudimentary posterior costo-transverse ligaments to the eleventh and twelfth ribs.

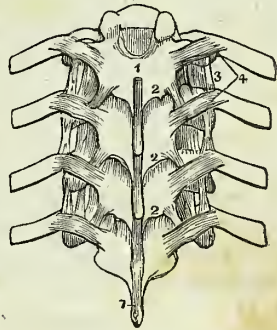
*Actions.*—The movements permitted by the articulations of the ribs, are *upwards and downwards*, and slightly *forwards and backwards*; the movement increasing in extent from the head to the extremity of the rib. The forward and backward movement is very trifling in the seven superior, but greater in the inferior ribs; the eleventh and twelfth are very movable.

7. *Articulation of the Ribs with the Sternum, and with each other.*—The ligaments of the costo-sternal articulations are,—

Anterior costo-sternal,  
Posterior costo-sternal,  
Superior costo-sternal,  
Inferior costo-sternal,  
Synovial membranes.

The *anterior costo-sternal ligament* is a thin band of ligamentous fibres, that passes in a radiated direction from the extremity of the costal cartilage to the anterior surface of the sternum, and intermingles its fibres with those of the ligament of the opposite side and with the tendinous fibres of origin of the pectoralis major muscle.

Fig. 82.\*



\* A posterior view of a part of the thoracic portion of the vertebral column, showing the ligaments connecting the vertebrae with each other, and the ribs with the vertebrae. 1, 1. The supra-spinous ligament. 2, 2. The ligamenta subflava, connecting the laminae 3. The anterior costo-transverse ligament. 4. The posterior costo-transverse ligaments.

The *posterior costo-sternal ligament* is much smaller than the anterior, and consists only of a thin fasciculus of fibres situated on the posterior surface of the articulation.

The *superior and inferior costo-sternal ligaments* are narrow fasciculi corresponding with the breadth of the cartilage, and connecting its superior and inferior border with the side of the sternum.

The *synovial membrane* is absent in the articulation of the first rib, its cartilage being usually continuous with the sternum; that of the second rib has an interarticular ligament, with two synovial membranes.

The *sixth and seventh ribs* have several fasciculi of strong ligamentous fibres, passing from the extremity of their cartilages to the anterior surface of the ensiform cartilage, which latter they are intended to support. They are named the *costo-xiphoid ligaments*.

The *six, seventh, and eighth*, and sometimes the *fifth* and the *ninth* costal cartilages, have articulations with each other, and a perfect synovial membrane. They are connected by ligamentous fibres which pass from one cartilage to the other, *external and internal ligaments*.

The *ninth and tenth* are connected at their extremities by ligamentous fibres, but have no synovial membranes.

*Actions.*—The movements of the costo-sternal articulations are very trifling; they are limited to a slight sliding motion. The first rib is the least, and the second the most movable.

8. *Articulation of the Sternum.*—The pieces of the sternum are connected by means of a thin plate of interosseous cartilage placed between each, and by an anterior and posterior ligament. The fibres of the *anterior sternal ligament* are longitudinal in direction, but so blended with the anterior costo-sternal ligaments, and the tendinous fibres of origin of the pectoral muscles, as scarcely to be distinguished as a distinct ligament. The *posterior sternal ligament* is a broad smooth plane of longitudinal fibres, placed upon the posterior surface of the bone, and extending from the manubrium to the ensiform cartilage. These ligaments contribute very materially to the strength of the sternum and to the elasticity of the front of the chest.

9. *Articulation of the Vertebral Column with the Pelvis.*—The last lumbar vertebra is connected with the sacrum by the same ligaments with which the various vertebræ are connected to each other; viz. the anterior and posterior common ligaments, intervertebral substance, ligamenta subflava, capsular ligaments, and inter and supra-spinous ligaments.

There are, however, *two* proper ligaments connecting the vertebral column with the pelvis; these are, the

Lumbo-sacral,

Lumbo-iliac.

The *lumbo-sacral ligament* is a thick triangular fasciculus of ligamentous fibres, connected above with the transverse process of the last lumbar vertebra; and below with the posterior part of the upper border of the sacrum.

The *lumbo-iliac ligament* passes from the apex of the transverse process of the last lumbar vertebra to that part of the crest of the ilium which surmounts the sacro-iliac articulation. It is triangular in form.

10. *The Articulations of the Pelvis.*—The ligaments belonging to the articulations of the pelvis are divisible into four groups. 1. Those connect-

ing the *sacrum* and *ilium*; 2. those passing between the *sacrum* and *ischium*; 3. between the *sacrum* and *coccyx*; and 4. between the *two pubic bones*.

1st, *Between the sacrum and ilium.*

Sacro-iliac anterior,  
Sacro-iliac posterior.

2d, *Between the sacrum and ischium.*

Sacro-ischiatic anterior (*short*),  
Sacro-ischiatic posterior (*long*).

3d, *Between the sacrum and coccyx.*

Sacro-coccygean anterior,  
Sacro-coccygean posterior.

4th, *Between the ossa pubis.*

Anterior pubic,  
Posterior pubic,  
Superior pubic,  
Sub-pubic,  
Interosseous fibro-cartilage.

1. *Between the Sacrum and Ilium.*—The *anterior sacro-iliac ligament* consists of numerous short ligamentous fibres, which pass from bone to bone on the anterior surface of the joint.

The *posterior sacro-iliac or interosseous ligament* is composed of numerous strong fasciculi of ligamentous fibres, which pass horizontally between the rough surfaces in the *posterior half* of the sacro-iliac articulation, and constitute the principal bond of connexion between the sacrum and the ilium. One fasciculus of this ligament, longer and larger than the rest, is distinguished, from its direction, by the name of the *oblique sacro-iliac ligament*. It is attached, by one extremity, to the posterior superior spine of the ilium; and, by the other, to the third transverse tubercle on the posterior surface of the sacrum.

The surfaces of the two bones forming the sacro-iliac articulation are partly covered with cartilage, and partly rough and connected by the interosseous ligament. The *anterior or auricular half* is coated with cartilage, which is thicker on the sacrum than on the ilium. The surface of the cartilage is irregular, and provided with a very delicate synovial membrane, which cannot be demonstrated in the adult; but is apparent in the young subject, and in the female during pregnancy.

2. *Between the Sacrum and Ischium.*—The *anterior or lesser sacro-ischiatic ligament* is thin, and triangular in form; it is attached by its apex to the spine of the ischium, and by its broad extremity to the side of the sacrum and coccyx, interlacing its fibres with the greater sacro-ischiatic ligament.

The anterior sacro-ischiatic ligament is *in relation* in front with the coccygeus muscle, and behind with the posterior ligament, with which its fibres are intermingled. By its upper border it forms a part of the lower boundary of the great sacro-ischiatic foramen, and by the lower, a part of the lesser sacro-ischiatic foramen.

The *posterior or greater sacro-ischiatric ligament*, considerably larger, thicker, and more posterior than the preceding, is narrower in the middle than at each extremity. It is attached, by its smaller end, to the inner margin of the tuberosity and ramus of the ischium, where it forms a falci-form process, which protects the internal pudic artery, and is continuous with the obturator fascia. By its larger extremity it is inserted into the side of the coccyx, sacrum, and posterior inferior spine of the ilium.

Fig. 83.\*

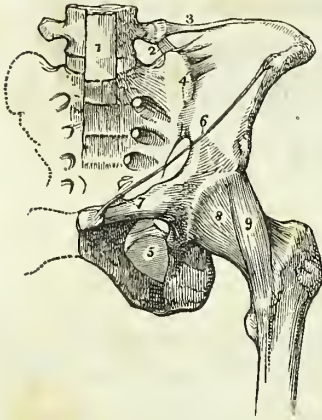
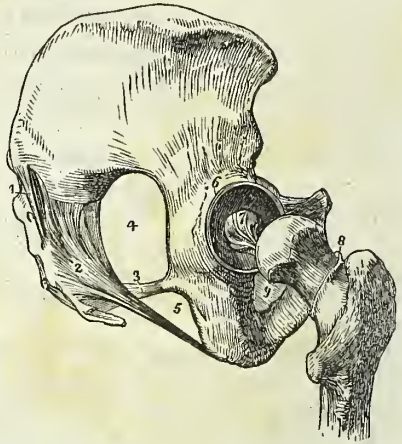


Fig. 84.†



The posterior sacro-ischiatric ligament is *in relation* in front with the anterior ligament, and behind with the *gluteus maximus*, to some of the fibres of which it gives origin. By its superior border it forms part of the lesser ischiatic foramen, and by its lower border, a part of the boundary of the perineum. It is pierced by the coccygeal branch of the ischiatic artery. The two ligaments convert the sacro-ischiatric notches into foramina.

3. *Between the Sacrum and Coccyx.*—The *anterior sacro-coccygean ligament* is a thin fasciculus passing from the anterior surface of the sacrum to the front of the coccyx.

The *posterior sacro-coccygean ligament* is a thick ligamentous layer, which completes the lower part of the sacral canal, and connects the

\* The ligaments of the pelvis and hip joint. 1. The lower part of the anterior common ligament of the vertebræ, extending downwards over the front of the sacrum. 2. The lumbo-sacral ligament. 3. The lumbo-iliac ligament. 4. The anterior sacro-iliac ligaments. 5. The obturator membrane. 6. Poupart's ligament. 7. Gimbernat's ligament. 8. The capsular ligament of the hip-joint. 9. The ilio-femoral or accessory ligament.

† Ligaments of the pelvis and hip joint. The view is taken from the side. 1. The oblique sacro-iliac ligament. The other fasciculi of the posterior sacro-iliac ligaments are not seen in this view of the pelvis. 2. The posterior sacro-ischiatric ligament. 3. The anterior sacro-ischiatric ligament. 4. The great sacro-ischiatric foramen. 5. The lesser sacro-ischiatric foramen. 6. The cotyloid ligament of the acetabulum. 7. The ligamentum teres. 8. The cut edge of the capsular ligament, showing its extent posteriorly as compared with its anterior attachment. 9. The obturator membrane only partly seen.

sacrum with the coccyx posteriorly, extending as far as the apex of the latter bone.

Between the two bones is a thin disc of soft fibrous cartilage. In females there is frequently a small synovial membrane. This articulation admits of a certain degree of movement backwards during parturition.

The ligaments connecting the different pieces of the coccyx consist of a few scattered *anterior* and *posterior* fibres, and a thin disc of interosseous cartilage: they exist only in the young subject; in the adult the pieces become ossified.

4. *Between the Ossa Pubis.* — The *anterior pubic ligament* is composed of ligamentous fibres, which pass obliquely across the union of the two bones from side to side, and form an interlacement in front of the symphysis.

The *posterior pubic ligament* consists of a few irregular fibres uniting the pubic bones posteriorly.

The *superior pubic ligament* is a thick band of fibres connecting the angles of the pubic bones superiorly, and filling the inequalities upon the surface of the bones.

The *sub-pubic ligament* is a thick arch of fibres connecting the two bones inferiorly, and forming the upper boundary of the pubic arch.

The *interosseous fibro-cartilage* unites the two surfaces of the pubic bones, in the same manner as the intervertebral substance connects the bodies of the vertebræ. It resembles the intervertebral substance, also in being composed of oblique fibres disposed in concentric layers, which are more dense towards the surface than near the centre. It is thick in front, and thin behind. A synovial membrane is sometimes found in the posterior half of the articulation.

This articulation becomes movable towards the latter term of pregnancy, and admits of a slight degree of separation of its surfaces.

The *obturator ligament or membrane* is not a ligament of articulation, but simply a tendino-fibrous membrane stretched across the obturator foramen. It gives attachment by its surfaces, to the two obturator muscles, and leaves a space in the upper part of the foramen, for the passage of the obturator vessels and nerve.

The numerous vacuities in the walls of the pelvis, and their closure by ligamentous structures, as in the case of the sacro-ischiatic fissures and obturator foramina, serve to diminish very materially the pressure on the soft parts during the passage of the head of the fœtus through the pelvis in parturition.

#### LIGAMENTS OF THE UPPER EXTREMITY.

The *Ligaments of the upper extremity* may be arranged in the order of the articulations between the different bones; they are, the

- |                                     |                                           |
|-------------------------------------|-------------------------------------------|
| 1. Sterno-clavicular articulation.  | 8. Articulation between the carpal bones. |
| 2. Scapulo-clavicular articulation. | 9. Carpo-metacarpal articulation.         |
| 3. Ligaments of the scapula.        | 10. Metacarpo-phalangeal articulation.    |
| 4. Shoulder joint.                  | 11. Articulation of the phalanges.        |
| 5. Elbow joint.                     |                                           |
| 6. Radio-ulnar articulation.        |                                           |
| 7. Wrist joint.                     |                                           |

1. *Sterno-clavicular Articulation.* — The sterno-clavicular is an arthrodial articulation; its ligaments are,

Anterior sterno-clavicular,  
 Posterior sterno-clavicular,  
 Inter-clavicular,  
 Costo-clavicular (*rhomboid*),  
 Interarticular fibro-cartilage,  
 Two synovial membranes.

The *anterior sterno-clavicular ligament* is a broad ligamentous layer, extending obliquely downwards and forwards, and covering the anterior aspect of the articulation. This ligament is *in relation* by its anterior surface with the integument and with the sternal origin of the sterno-mastoid muscle; and behind with the interarticular fibro-cartilage and synovial membranes.

The *posterior sterno-clavicular ligament* is a broad fasciculus, covering the posterior surface of the articulation. It is *in relation* by its anterior surface with the interarticular fibro-cartilage and synovial membranes, and behind with the sterno-hyoid muscle.

The two ligaments are continuous at the upper and lower part of the articulation, so as to form a complete capsule around the joint.

The *interclavicular ligament* is a cord-like band which crosses from the extremity of one clavicle to the other, and is closely connected with the upper border of the sternum. It is separated by areolar tissue from the sterno-thyroid muscles.

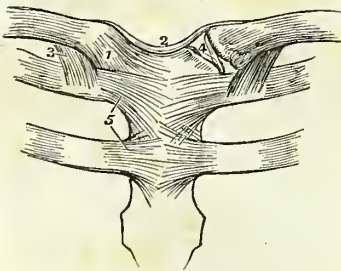
The *costo-clavicular ligament (rhomboid)* is a thick fasciculus of fibres, connecting the sternal extremity of the clavicle with the cartilage of the first rib. It is situated obliquely between the rib and the under surface of the clavicle. It is *in relation* in front with the tendon of origin of the subclavius muscle, and behind with the subclavian vein.

*Actions.* — The movements of the sterno-clavicular articulation, are a *gliding movement* of the fibro-cartilage with the clavicle upon the articular surface of the sternum in the directions forwards, backwards, upwards, and downwards; and *circumduction*. This articulation is the centre of the movements of the shoulder.

It is the rupture of the rhomboid ligament in dislocation of the sternal end of the clavicle that gives rise to the deformity peculiar to this accident.

The *interarticular fibro-cartilage* is nearly circular in form, and thicker at the edges than in the centre. It is attached above to the clavicle; below to the cartilage of the first rib; and throughout the rest of its circumference to the anterior and posterior sterno-clavicular ligaments; it divides the joint into two cavities, which are lined by distinct *synovial membranes*. This cartilage is sometimes pierced through its centre, and not unfrequently deficient, to a greater or less extent, in its lower part.

Fig. 85.\*



\* The ligaments of the sterno-clavicular and costo-sternal articulations. 1. The anterior sterno-clavicular ligament. 2. The inter-clavicular ligament. 3. The costo-clavicular or rhomboid ligament, seen on both sides. 4. The interarticular fibro-cartilage, brought into view by the removal of the anterior and posterior ligaments. 5. The anterior costo-sternal ligaments of the first and second ribs.



2. *Scapulo-clavicular Articulation*.—The ligaments of the scapular end of the clavicle are, the

- Superior acromio-clavicular,
- Inferior acromio-clavicular,
- Coraco-clavicular (*trapezoid* and *conoid*),
- Interarticular fibro-cartilage,
- Two synovial membranes.

The *superior acromio-clavicular ligament* is a moderately thick plane of superimposed fibres passing between the extremity of the clavicle and the acromion, upon the upper surface of the joint.

The *inferior acromio-clavicular ligament* is a thin plane situated upon the under surface. These two ligaments are continuous with each other in front and behind, and form a complete capsule around the joint.

The *coraco-clavicular ligament* (*trapezoid*, *conoid*) is a thick fasciculus of ligamentous fibres, passing obliquely between the base of the coracoid process and the under surface of the clavicle, and holding the end of the clavicle in firm connexion with the scapula. When seen from *before*, it has a quadrilateral form: hence it is named *trapezoid*; and examined from *behind*, it has a triangular form, the base being upwards; hence another name, *conoid*.

The *interarticular fibro-cartilage* is often indistinct, from having partial connexions with the fibro-cartilaginous surfaces of the two bones between which it is placed, and not unfrequently absent. When partial, it occupies the upper part of the articulation. The *synovial membranes* are very delicate. There is, of course, but one, when the fibro-cartilage is incomplete.

*Actions*.—The acromio-clavicular articulation admits of two movements, the *gliding* of the surfaces upon each other; and the *rotation* of the scapula upon the extremity of the clavicle.

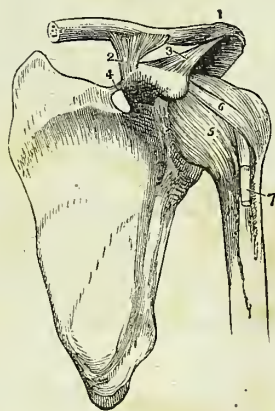
3. The *Proper ligaments of the Scapula* are the

- Coraco-acromial,
- Transverse.

The *coraco-acromial ligament* is a broad and thick triangular band, which forms a protecting arch over the shoulder joint. It is attached by its apex to the point of the acromion process, and by its base to the external border of the coracoid process its whole length. This ligament is *in relation* above with the under surface of the deltoid muscle; and below with the tendon of the supra-spinatus muscle, a bursa mucosa being usually interposed.

The *transverse* or *coracoid ligament* is a narrow but strong fasciculus which crosses

Fig. 86.\*



\* The ligaments of the scapula and shoulder joint. 1. The superior acromio-clavicular ligament. 2. The coraco-clavicular ligament; this aspect of the ligament is named trapezoid. 3. The coraco-acromial ligament. 4. The transverse ligament. 5. The capsular ligament. 6. The coraco-humeral ligament. 7. The long tendon of the biceps issuing from the capsular ligament, and entering the bicipital groove.

the notch in the upper border of the scapula, from the base of the coracoid process, and converts it into a foramen. The supra-scapular nerve passes through this foramen.

4. *Shoulder Joint*.—The scapulo-humeral articulation is an enarthrosis, or ball-and-socket joint—its ligaments are, the

Capsular,  
Coraco-humeral,  
Glenoid.

The *capsular ligament* completely encircles the articulating head of the scapula and the head of the humerus, and is attached to the neck of each bone. It is thick above, where resistance is most required, and is strengthened by the tendons of the supra-spinatus, infra-spinatus, teres minor, and subscapularis muscles: below it is thin and loose. The capsule is incomplete at the point of contact with the tendons, so that they obtain upon their inner surface a covering of synovial membrane.

The *coraco-humeral ligament* is a broad band which descends obliquely outwards from the border of the coracoid process to the greater tuberosity of the humerus, and serves to strengthen the superior and anterior part of the capsular ligament.

The *glenoid ligament* is the prismoid band of fibro-cartilage, which is attached around the margin of the glenoid cavity for the purposes of protecting its edges, and deepening its cavity. It divides superiorly into two slips which are continuous with the long tendon of the biceps; hence the ligament is frequently described as being formed by the splitting of that tendon. The cavity of the articulation is traversed by the long tendon of the biceps, which is enclosed in a sheath of synovial membrane in its passage through the joint.

The *synovial membrane* of the shoulder joint is very extensive; it communicates anteriorly through an opening in the capsular ligament with a large bursal sac, which lines the under surface of the tendon of the subscapularis muscle. Superiorly, it frequently communicates through another opening in the capsular ligament with a bursal sac belonging to the infra-spinatus muscle; and it moreover forms a sheath around that portion of the tendon of the biceps, which is included within the joint.

The muscles immediately surrounding the shoulder joint are the subscapularis, supra-spinatus, infra-spinatus, teres minor, long head of the triceps and deltoid; the long tendon of the biceps is within the capsular ligament.

*Actions*.—The shoulder joint is capable of every variety of motion, viz. of movement forwards and backwards, of abduction and adduction, of circumduction and rotation.

5. *Elbow Joint*.—The elbow is a ginglymoid articulation; its ligaments are *four* in number,—

|            |                   |
|------------|-------------------|
| Anterior,  | Internal lateral, |
| Posterior, | External lateral. |

The *anterior ligament* is a broad and thin membranous layer, descending from the anterior surface of the humerus, immediately above the joint, to the coronoid process of the ulna and orbicular ligament. On each side it is connected with the lateral ligaments. It is composed of fibres which pass in three different directions, vertical, transverse, and oblique, the lat-

ter being extended from within outwards to the orbicular ligament, into which they are attached inferiorly. This ligament is covered in by the brachialis anticus muscle.

The *posterior ligament* is a broad and loose layer passing between the posterior surface of the humerus and the anterior surface of the base of the olecranon, and connected at each side with the lateral ligaments. It is covered in by the tendon of the triceps.

The *internal lateral ligament* is a thick triangular layer, attached above, by its apex, to the internal condyle of the humerus; and below, by its expanded border, to the margin of the greater sigmoid cavity of the ulna, extending from the coronoid process to the olecranon. At its insertion it is intermingled with some transverse fibres. The internal lateral ligament is in relation posteriorly with the ulnar nerve.

The *external lateral ligament* is a strong and narrow band, which descends from the external condyle of the humerus, to be inserted into the orbicular ligament, and into the ridge on the ulna, with which the posterior part of the latter ligament is connected. This ligament is closely united with the tendon of origin of the supinator brevis muscle.

The *synovial membrane* is extensive, and is reflected from the cartilaginous surfaces of the bones upon the inner surface of the ligaments. It surrounds inferiorly the head of the radius, and forms an articulating sac between it and the lesser sigmoid notch.

The muscles immediately surrounding, and in contact with, the elbow joint, are *in front*, the brachialis anticus; to the *inner side*, the pronator radii teres, flexor sublimis digitorum, and flexor carpi ulnaris; *externally*, the extensor carpi radialis brevis, extensor communis digitorum, extensor carpi ulnaris, anconeus, and supinator brevis; and *behind*, the triceps.

*Actions*.—The movements of the elbow joint are *flexion* and *extension*, which are performed with remarkable precision. The extent to which these movements are capable of being effected, is limited in front by the coronoid process, and behind by the olecranon.

6. The *Radio-ulnar Articulation*.—The radius and ulna are firmly held together by ligaments which are connected with both extremities of the bones, and with the shaft; they are, the

Orbicular,  
Oblique,  
Interosseous,

Anterior inferior,  
Posterior inferior,  
Interarticular fibro-cartilage.

\* An internal view of the ligaments of the elbow joint. 1. The anterior ligament. 2. The internal lateral ligament. 3. The orbicular ligament. 4. The oblique ligament. 5. The interosseous ligament. 6. The internal condyle of the humerus, which conceals the posterior ligament.

† An external view of the elbow joint. 1. The humerus. 2. The ulna. 3. The ra

Fig. 87.\*

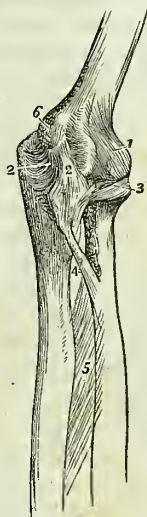

Fig. 88.†

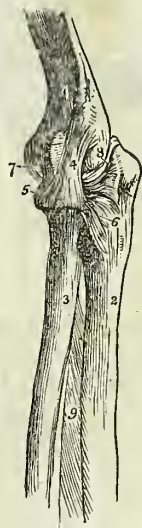
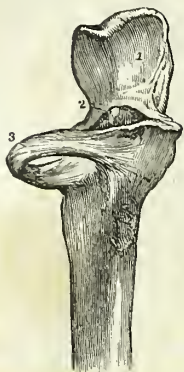
Fig. 89.\*



The *orbicular ligament* (*annular, coronary*) is a firm band several lines in breadth, which surrounds the head of the radius, and is attached by each end to the extremities of the lesser sigmoid cavity. It is strongest behind where it receives the external lateral ligament, and is lined on its inner surface by a reflection of the synovial membrane of the elbow joint.

The rupture of this ligament permits of the dislocation of the head of the radius.

The *oblique ligament* (called also *ligamentum teres* in contradistinction from the interosseous ligament) is a narrow slip of ligamentous fibres, descending obliquely from the base of the coronoid process of the ulna to the inner side of the radius, a little below its tuberosity.

The *interosseus ligament* is a broad and thin plane of aponeurotic fibres passing obliquely downwards from the sharp ridge on the radius to that on the ulna. It is deficient superiorly, is broader in the middle than at each extremity, and is perforated at its lower part for the passage of the anterior interosseous artery. The posterior interosseous artery passes backwards between the oblique ligament and the upper border of the interosseous ligament. This ligament affords an extensive surface for the attachment of muscles.

The interosseous ligament is *in relation, in front*, with the flexor profundus digitorum, the flexor longus pollicis, and pronator quadratus muscle, and with the anterior interosseous artery and nerve; and *behind* with the supinator brevis, extensor ossis metacarpi pollicis, extensor primi internodii pollicis, extensor secundi internodii pollicis, and extensor indicis muscle, and near the wrist with the anterior interosseous artery and posterior interosseous nerve.

The *anterior inferior ligament* is a thin fasciculus of fibres, passing transversely between the radius and ulna.

The *posterior inferior ligament* is also thin and loose, and has the same disposition on the posterior surface of the articulation.

The *interarticular, or triangular fibro-cartilage*, acts the part of a ligament between the lower extremities of the radius and ulna. It is attached by its apex to a depression on the inner surface of the styloid process of the ulna, and by its base to the edge of the radius. This fibro-cartilage is lined upon its upper surface by a synovial membrane, which forms a duplicature between the radius and ulna, and is called the *membrana sacciformis*. By its lower surface it enters into the articulation of the wrist joint.

*Actions.*—The movements taking place between the radius and the ulna are, the rotation of the former upon the latter; rotation forwards being termed *pronation*, and rotation backwards *supination*. In these movements the head of the radius turns upon its own axis, within the orbicular ligament and the lesser sigmoid notch of the ulna; while inferiorly the

dius. 4. The external lateral ligament inserted inferiorly into (5) the orbicular ligament. 6. The posterior extremity of the orbicular ligament, spreading out at its insertion into the ulna. 7. The anterior ligament, scarcely apparent in this view of the articulation. 8. The posterior ligament, thrown into folds by the extension of the joint.

\* 1. Articular surface of olecranon process of the ulna. 2. Coronoid process. 3. Orbicular ligament surrounding the neck of the radius.

radius presents a concavity which moves upon the rounded head of the ulna. The movements of the radius are chiefly limited by the anterior and posterior inferior ligaments, hence these are not unfrequently ruptured in great muscular efforts.

7. *Wrist Joint*.—The wrist is a ginglymoid articulation; the articular surfaces entering into its formation being the radius and under surface of the triangular fibro-cartilage above, and the rounded surfaces of the scaphoid, semilunar, and cuneiform bone below; its ligaments are *four* in number,—

Anterior,  
Posterior,

Internal lateral,  
External lateral.

The *anterior ligament* is a broad and membranous layer consisting of three fasciculi, which pass between the lower part of the radius and the scaphoid, semilunar, and cuneiform bone.

The *posterior ligament*, also thin and loose, passes between the posterior surface of the radius, and the posterior surface of the semilunar and cuneiform bone.

The *internal lateral ligament* extends from the styloid process of the ulna to the cuneiform and pisiform bone.

The *external lateral ligament* is attached by one extremity to the styloid process of the radius, and by the other to the side of the scaphoid bone. The radial artery rests on this ligament as it passes backwards to the first metacarpal space.

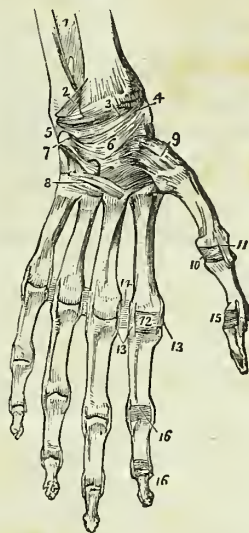
The *synovial membrane* of the wrist joint lines the under surface of the radius and inter-articular cartilage above, and the first row of bones of the carpus below.

The *relations* of the wrist joint are the flexor and extensor tendons by which it is surrounded, and the radial and ulnar artery.

*Actions*.—The movements of the wrist joint are *flexion*, *extension*, *adduction*, *abduction*, and *circumduction*. In these motions the articular surfaces glide upon each other.

\* The ligaments of the anterior aspect of the wrist and hand. 1. The lower part of the interosseous membrane. 2. The anterior inferior radio-ulnar ligament. 3. The anterior ligament of the wrist joint. 4. Its external lateral ligament. 5. Its internal lateral ligament. 6. The palmar ligaments of the carpus. 7. The pisiform bone with its ligaments. 8. The ligaments connecting the second range of carpal bones with the metacarpal and the metacarpal with each other. 9. The capsular ligament of the carpo-metacarpal articulation of the thumb. 10. Anterior ligament of the metacarpophalangeal articulation of the thumb. 11. One of the lateral ligaments of that articulation. 12. Anterior ligament of the metacarpophalangeal articulation of the index finger; this ligament has been removed in the other fingers. 13. Lateral ligaments of the same articulation; the corresponding ligaments are seen in the other articulations. 14. Transverse ligament connecting the heads of the metacarpal bones of the index and middle fingers; the same ligament is seen between the other fingers. 15. Anterior and one lateral ligament of the phalangeal articulation of the thumb. 16. Anterior and lateral ligaments of the phalangeal articulations of the index finger; the anterior ligaments are removed in the other fingers.

Fig. 90.\*



8. *Articulations between the Carpal Bones.*—These are amphiarthrodial joints, with the exception of the conjoined head of the os magnum and unciforme, which is received into a cup formed by the scaphoid, semilunar, and cuneiform bone, and constitutes an enarthrosis. The ligaments are,

|         |                               |
|---------|-------------------------------|
| Dorsal, | Interosseous fibro-cartilage, |
| Palmar, | Anterior annular.             |

The *dorsal ligaments* are ligamentous bands, that pass transversely and longitudinally from bone to bone, upon the dorsal surface of the carpus.

The *palmar ligaments* are fasciculi of the same kind, but stronger than the dorsal, having the like disposition upon the palmar surface.

The *interosseous ligaments* are fibro-cartilaginous lamellæ situated between the adjoining bones in each range: in the upper range they close the upper part of the spaces between the scaphoid, semilunar, and cuneiform bones; in the lower range they are stronger than in the upper, and connect the os magnum on the one side to the unciforme, on the other to the trapezoides, and leave intervals through which the synovial membrane is continued to the bases of the metacarpal bones.

The *anterior annular ligament* is a firm ligamentous band, which connects the bones of the two sides of the carpus. It is attached by one extremity to the trapezium and scaphoid, and by the other to the unciform process of the unciforme and the base of the pisiform bone, and forms an arch over the anterior surface of the carpus, beneath which the tendons of the long flexors and the median nerve pass into the palm of the hand.

The *articulation of the pisiform bone* with the cuneiform, is provided with a distinct synovial membrane, which is protected by fasciculi of ligamentous fibres, forming a kind of capsule around the joint; they are inserted into the cuneiforme, unciforme, and base of the metacarpal bone of the little finger.

*Synovial Membranes.*—There are *five* synovial membranes entering into the composition of the articulations of the carpus:—

The *first* is situated between the lower end of the ulna and the interarticular fibro-cartilage; it is called *sacciform*, from forming a sacculus between the lateral articulation of the ulna with the radius.

The *second* is situated between the lower surface of the radius and interarticular fibro-cartilage *above*, and the first range of bones of the carpus *below*.

The *third* is the most extensive of the synovial membranes of the wrist; it is situated between the two rows of carpal bones, and passes between the bones of the second range, to invest the carpal extremities of the four metacarpal bones of the fingers.

The *fourth* is the synovial membrane of the articulation of the metacarpal bone of the thumb with the trapezium.

The *fifth* is situated between the pisiform and cuneiform bone.

*Actions.*—Very little movement exists between the bones in each range, but more is permitted between the two ranges. The motions in the latter situation are those of flexion and extension.

9. The *Carpo-metacarpal Articulations.*—The second row of bones of the carpus articulates with the metacarpal bones of the four fingers by *dorsal* and *palmar* ligaments; and the metacarpal bone of the thumb with the trapezium by a true *capsular ligament*. There is also in the carpo-

metacarpal articulation a thin interosseous band which passes from the ulnar edge of the os magnum to the line of junction between the third and fourth metacarpal bones.

The *dorsal ligaments* are strong fasciculi which pass from the second range of carpal to the metacarpal bones.

The *palmar ligaments* are thin fasciculi arranged upon the same plan on the palmar surface.

The *synovial membrane* is a continuation of the great synovial membrane of the two rows of carpal bones.

The *capsular ligament* of the thumb is one of the three true capsular ligaments of the skeleton; the other two being the shoulder joint and hip joint. The articulation has a proper *synovial membrane*.

The *metacarpal bones* of the four fingers are firmly connected at their bases by means of dorsal and palmar ligaments, which extend transversely from one bone to the other, and by interosseous ligaments, which pass between their contiguous surfaces. Their lateral articular facets are lined by a reflection of the great synovial membrane of the two rows of carpal bones.

*Actions.*—The movements of the metacarpal on the carpal bones are restricted to a slight degree of sliding motion, with the exception of the articulation of the metacarpal bone of the thumb with the trapezium. In the latter articulation, the movements are, *flexion, extension, adduction, abduction, and circumduction.*

10. *Metacarpo-phalangeal Articulation.*—The metacarpo-phalangeal articulation is a ginglymoid joint; its ligaments are four in number,—

Anterior,                      Two lateral,                      Transverse.

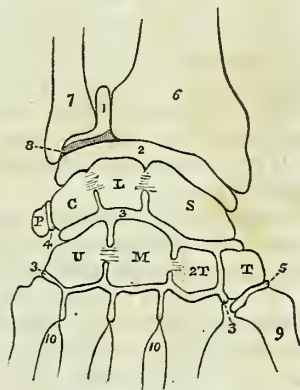
The *anterior ligaments* are thick and fibro-cartilaginous, and form part of the articulating surface of the joints. They are grooved externally for the lodgment of the flexor tendons, and by their internal aspect form part of the articular surface for the head of the metacarpal bone.

The *lateral ligaments* are strong narrow fasciculi, holding the bones together at each side.

The *transverse ligaments* are strong ligamentous bands, passing between the anterior ligaments, and connecting together the heads of the metacarpal bones of the four fingers.

\* A diagram showing the disposition of the five synovial membranes of the wrist joint. 1. The sacciform membrane. 2. The second synovial membrane. 3, 3. The third, or large synovial membrane. 4. The synovial membrane between the pisiform bone and the cuneiforme. 5. The synovial membrane of the metacarpal articulation of the thumb. 6. The lower extremity of the radius. 7. The lower extremity of the ulna. 8. The interarticular fibro-cartilage. L. The semilunare. C. The cuneiforme; the interosseous ligaments are seen passing between these three bones and separating the articulation of the wrist (2) from the articulation of the carpal bones (3). P. The pisiforme. T. The trapezium. 2T. The trapezoides. M. The os magnum. U. The unciforme; interosseous ligaments are seen connecting the os magnum with the trapezoides and unciforme. 9. The base of the metacarpal bone of the thumb. 10, 10. The bases of the other metacarpal bones.

Fig. 91.\*



The expansion of the extensor tendon over the back of the fingers takes the place of a posterior ligament.

*Actions.*—This articulation admits of movement in four different directions, viz. of *flexion*, *extension*, *adduction*, and *abduction*, the two latter being limited to a small extent. It is also capable of *circumduction*.

11. *Articulation of the Phalanges.*—These articulations are ginglymoid joints. they are formed by three ligaments.

Anterior,

Two lateral.

The *anterior ligament* is firm and fibro-cartilaginous, and forms part of the articular surface for the head of the phalanges. Externally it is grooved for the reception of the flexor tendons.

The *lateral ligaments* are very strong; they are the principal bond of connexion between the bones.

The extensor tendon takes the place and performs the office of a posterior ligament.

*Actions.*—The movements of the phalangeal joints are *flexion* and *extension*, these movements being more extensive between the first and second phalanges than between the second and third.

In connexion with the phalanges, it may be proper to examine certain fibrous bands termed *theca* or *vaginal ligaments*, which serve to retain the tendons of the flexor muscles in their position upon the flat surface of their bones. These fibrous bands are attached at each side to the lateral margins of the phalanges; they are thick in the interspaces of the joints, thin where the tendons lie upon the joints, and they are lined upon their inner surface by synovial membrane.

#### LIGAMENTS OF THE LOWER EXTREMITY.

The *ligaments of the lower extremity*, like those of the upper, may be arranged in the order of the joints to which they belong; these are, the

1. Hip joint.
2. Knee joint.
3. Articulation between the tibia and fibula.
4. Ankle joint.
5. Articulation of the tarsal bones.
6. Tarso-metatarsal articulation.
7. Metatarso-phalangeal articulation.
8. Articulation of the phalanges.

1. *Hip Joint.*—The articulation of the head of the femur with the acetabulum constitutes an enarthrosis, or ball-and-socket joint. The articular surfaces are the cup-shaped cavity of the acetabulum and the rounded head of the femur; the ligaments are *five* in number, viz.

Capsular,  
Ilio-femoral,  
Teres,

Cotyloid,  
Transverse.

The *capsular ligament* (fig. 83, 8) is a strong ligamentous capsule, embracing the acetabulum superiorly, and inferiorly the neck of the femur, and connecting the two bones firmly together. It is much thicker upon the upper part of the joint, where more resistance is required, than upon



the under part, and extends further upon the neck of the femur on the anterior and superior than on the posterior and inferior side, being attached to the intertrochanteric line in front, to the base of the great trochanter above, and to the middle of the neck of the femur behind.

The *ilio-femoral ligament* (fig. 83, 9) is an accessory and radiating band, which descends obliquely from the anterior inferior spinous process of the ilium to the anterior intertrochanteric line, and strengthens the anterior portion of the capsular ligament.

The *ligamentum teres* (fig. 84, 7), triangular in shape, is attached by a round apex to the depression just below the middle of the head of the femur, and by its base, which divides into two fasciculi, into the borders of the notch of the acetabulum. It is formed by a fasciculus of fibres, of variable size, surrounded by synovial membrane; sometimes the synovial membrane alone exists, or the ligament is wholly absent.

The *cotyloid ligament* (fig. 84, 6) is a prismoid cord of fibro-cartilage, attached around the margin of the acetabulum, and serving to deepen that cavity and protect its edges. It is much thicker upon the upper and posterior border of the acetabulum than in front, and consists of fibres which arise from the whole circumference of the brim, and interlace with each other at acute angles.

The *transverse ligament* is a strong fasciculus of ligamentous fibres, continuous with the cotyloid ligament, and extended across the notch in the acetabulum. It converts the notch into a foramen, through which the articular branches of the internal circumflex and obturator arteries enter the joint.

The fossa at the bottom of the acetabulum is filled by a mass of fat, covered by synovial membrane, which serves as an elastic cushion to the head of the bone during its movements. This was considered by Havers as the synovial gland.

The *synovial membrane* is extensive; it invests the head of the femur, and is continued around the ligamentum teres into the acetabulum, whence it is reflected upon the inner surface of the capsular ligament back to the head of the bone.

The muscles immediately surrounding and in contact with the hip joint are, *in front*, the psoas and iliacus, which are separated from the capsular ligament by a large synovial bursa; *above*, the short head of the rectus, and the gluteus minimus; *behind*, the pyriformis, gemellus superior, obturator internus, gemellus inferior, and quadratus femoris; and to the *inner side*, the obturator externus and pectineus.

*Actions*.—The movements of the hip joint are very extensive; they are *flexion, extension, adduction, abduction, circumduction, and rotation*.

2. *Knee Joint*.—The knee is a ginglymoid articulation of large size, and is provided with numerous ligaments; they are thirteen in number.

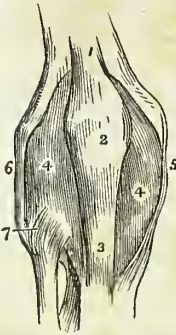
|                                  |                                      |
|----------------------------------|--------------------------------------|
| Anterior or ligamentum patellæ,  | Transverse,                          |
| Posterior or ligamentum posticum | Two coronary,                        |
| Winslowii,                       | Ligamentum mucosum, } <i>false</i> . |
| Internal lateral,                | Ligamenta alaria,                    |
| Two external lateral,            | Two semilunar fibro-cartilages,      |
| Anterior or external crucial,    | Synovial membrane.                   |
| Posterior or internal crucial,   |                                      |

The first *five* are *external* to the articulation; the next *five* are *internal*

to the articulation ; the remaining three are mere folds of synovial membrane, and have no title to the name of ligaments. In addition to the ligaments, there are two fibro-cartilages, which are sometimes very erroneously considered among the ligaments ; and a synovial membrane, which is still more improperly named the *capsular ligament*.

The *anterior ligament*, or *ligamentum patellæ*, is the prolongation of the tendon of the extensor muscles of the thigh downwards to the tubercle of the tibia. It is, therefore, no ligament ; and, as we have before stated, that the patella is simply a sesamoid bone, developed in the tendon of the extensor muscles for the defence of the front of the knee joint, the *ligamentum patellæ* has no title to consideration, either as a ligament of the knee joint or as a ligament of the patella.

Fig. 92.\*



A small *bursa mucosa* is situated between the *ligamentum patellæ*, near its insertion and the front of the tibia, and another of larger size is placed between the anterior surface of the patella and the fascia lata.

The *posterior ligament*, *ligamentum posticum Winslowii*, is a broad expansion of ligamentous fibres which covers the whole of the posterior part of the joint. It is divisible into two lateral portions which invest the condyles of the femur, and a central portion which is depressed, and formed by the interlacement of fasciculi passing in different directions. The strongest of these fasciculi is that which is derived from the tendon of the semi-membranosus, and passes obliquely upwards and outwards, from the posterior part of the inner tuberosity of the tibia to the external condyle. Other accessory fasciculi are given off by the tendon of the popliteus and by the heads of the gastrocnemius. The middle portion of the ligament supports the popliteal artery and vein, and is perforated by several openings for the passage of branches of the azygos articular artery, and for the nerves of the joint.

The *internal lateral ligament* is a broad and trapezoid layer of ligamentous fibres, attached above to the tubercle on the internal condyle of the femur, and below to the side of the inner tuberosity of the tibia. It is crossed at its lower part by the tendons of the inner hamstring, from which it is separated by a synovial bursa, and it covers in the anterior slip of the semi-membranosus tendon and the inferior internal articular artery.

*External lateral ligaments.*—The *long* external lateral ligament is a strong rounded cord, which descends from the posterior part of the tubercle upon the external condyle of the femur to the outer part of the head of the fibula. The *short* external lateral ligament is an irregular fasciculus situated behind the preceding, arising from the external condyle near the origin of the head of the gastrocnemius muscle, and inserted into the posterior part of the head of the fibula. It is firmly connected with the external semilunar fibro-cartilage, and appears principally intended to connect that cartilage with the fibula. The long external lateral ligament

\* An anterior view of the ligaments of the knee joint. 1. The tendon of the quadriceps extensor muscle of the leg. 2. The patella. 3. The anterior ligament, or *ligamentum patellæ*, near its insertion. 4, 4. The synovial membrane. 5. The internal lateral ligament. 6. The long external lateral ligament. 7. The anterior superior tibio-fibular ligament.

is covered in by the tendon of the biceps, and has passing beneath it the tendon of origin of the popliteus muscle, and the inferior external articular artery.

The true ligaments *within the joint* are the crucial, transverse, and coronary.

The *anterior*, or *external crucial ligament*, arises from the depression upon the head of the tibia in front of the spinous process, and passes upwards and backwards to be inserted into the inner surface of the outer condyle of the femur, as far as its posterior border. It is smaller than the posterior.

The *posterior*, or *internal crucial ligament*, arises from the depression upon the head of the tibia, behind the spinous process, and passes upwards and forwards to be inserted into the inner condyle of the femur. This ligament is less oblique and larger than the anterior.

The *transverse ligament* is a small slip of fibres which extends transversely from the external semilunar fibro-cartilage, near its anterior extremity, to the anterior convexity of the internal cartilage.

The *coronary ligaments* are the short fibres by which the convex borders of the semilunar cartilages are connected to the head of the tibia, and to the ligaments surrounding the joint.

The *semilunar fibro-cartilages* are two falciform plates of fibro-cartilage, situated around the margin of the head of the tibia, and serving to deepen the surface of articulation for the condyles of the femur. They are thick along their convex border, and thin and sharp along the concave edge.

The *internal semilunar fibro-cartilage* forms an oval cup for the reception of the internal condyle; it is connected by its convex border to the head of the tibia, and to the internal and posterior ligaments, by means of its coronary ligament; and by its two extremities is firmly implanted into the depressions in front and behind the spinous process. The *external semilunar fibro-cartilage* bounds a circular fossa for the external condyle: it is connected by its convex border with the head of the tibia, and to the external and posterior ligaments, by means of its coronary ligament; by its two extremities it is inserted into the depression between the two projections which constitute the spinous process of the tibia. The two extremities of the external cartilage being inserted into the same fossa form almost a complete circle,

Fig. 93.\*

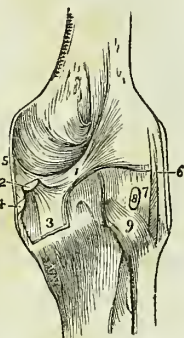
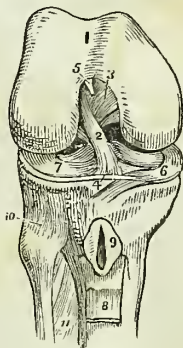


Fig. 94.†



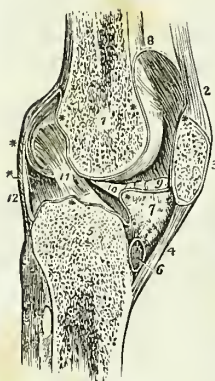
\* A posterior view of the ligaments of the knee joint. 1. The fasciculus of the ligamentum posticum Winslowii, which is derived from, 2. the tendon of the semi-membranosus muscle; the latter is cut short. 3. The process of the tendon which spreads out in the fascia of the popliteus muscle. 4. The process which is sent inwards beneath the internal lateral ligament. 5. The posterior part of the internal lateral ligament. 6. The long external lateral ligament. 7. The short external lateral ligament. 8. The tendon of the popliteus muscle cut short. 9. The posterior superior tibio-fibular ligament.

† The right knee joint laid open from the front, in order to show the internal liga

and the cartilage being somewhat broader than the internal, nearly covers the articular surface of the tibia. The external semilunar fibro-cartilage besides giving off a fasciculus from its anterior border to constitute the transverse ligament, is continuous by some of its fibres with the extremity of the anterior crucial ligament; posteriorly it divides into three slips; one, a strong cord, ascends obliquely forwards and is inserted into the anterior part of the inner condyle in front of the posterior crucial ligament; another is the fasciculus of insertion into the fossa of the spinous process; and the third, of small size, is continuous with the posterior part of the anterior crucial ligament.

The *ligamentum mucosum* is a slender conical process of synovial membrane enclosing a few ligamentous fibres which proceed from the transverse ligament. It is connected, by its apex, with the anterior part of the condyloid notch, and by its base is lost in the mass of fat which projects into the joint beneath the patella.

Fig. 95.\*



The *alar ligaments* are two fringed folds of synovial membrane, extending from the *ligamentum mucosum*, along the edges of the mass of fat to the sides of the patella.

The *synovial membrane* of the knee joint is by far the most extensive in the skeleton. It invests the cartilaginous surfaces of the condyles of the femur, of the head of the tibia, and of the inner surface of the patella; it covers both surfaces of the semilunar fibro-cartilages, and is reflected upon the crucial ligaments, and upon the inner surface of the ligaments which form the circumference of the joint. On each side of the patella, it lines the tendinous aponeuroses of the vastus internus and vastus externus muscles, and forms a pouch of considerable size between the extensor tendon and the front of the femur. It also forms

ments. 1. The cartilaginous surface of the lower extremity of the femur with its two condyles; the figure 5 rests upon the external; the figure 3 upon the internal condyle. 2. The anterior crucial ligament. 3. The posterior crucial ligament. 4. The transverse ligament. 5. The attachment of the *ligamentum mucosum*; the rest has been removed. 6. The internal semilunar fibro-cartilage. 7. The external fibro-cartilage. 8. A part of the *ligamentum patellæ* turned down. 9. The bursa, situated between the *ligamentum patellæ* and the head of the tibia; it has been laid open. 10. The anterior superior tibio-fibular ligament. 11. The upper part of the interosseous membrane; the opening above this membrane is for the passage of the anterior tibial artery.

† A longitudinal section of the left knee joint, showing the reflection of its synovial membrane. 1. The cancellous structure of the lower part of the femur. 2. The tendon of the extensor muscles of the leg. 3. The patella. 4. The *ligamentum patellæ*. 5. The cancellous structure of the head of the tibia. 6. A bursa situated between the *ligamentum patellæ* and the head of the tibia. 7. The mass of fat projecting into the cavity of the joint below the patella. \*\* The synovial membrane. 8. The pouch of synovial membrane which ascends between the tendon of the extensor muscles of the leg, and the front of the lower extremity of the femur. 9. One of the *alar ligaments*; the other has been removed with the opposite section. 10. The *ligamentum mucosum* left entire; the section being made to its inner side. 11. The anterior or external crucial ligament. 12. The posterior ligament. The scheme of the synovial membrane, which is here presented to the student, is divested of all unnecessary complications. It may be traced from the sacculus (at 8), along the inner surface of the patella; then over the adipose mass (7), from which it throws off the mucous ligament (10); then over the head of the tibia, forming a sheath to the crucial ligaments; then upwards along the posterior ligament and condyles of the femur to the sacculus, whence its examination commenced.

he folds in the interior of the joint, called "ligamentum mucosum," and "ligamenta alaria." The superior pouch of the synovial membrane is supported and raised during the movements of the limb by a small muscle, the *subcrureus*, which is inserted into it.

Between the ligamentum patellæ and the synovial membrane is a considerable mass of fat, which presses the membrane towards the interior of the joint, and occupies the fossa between the two condyles.

Besides the proper ligaments of the articulation, the joint is protected on its anterior part by the fascia lata, which is thicker upon the outer than upon the inner side, by a tendinous expansion from the vastus internus, and by some scattered ligamentous fibres which are inserted into the sides of the patella.

*Actions.*—The knee joint is one of the strongest of the articulations of the body, while at the same time it admits of the most perfect degree of movement in the directions of *flexion* and *extension*. During flexion, the articular surface of the tibia glides forward on the condyles of the femur, the lateral ligaments; the posterior, and the crucial ligaments are relaxed, while the ligamentum patellæ being put upon the stretch, serves to press the adipose mass into the vacuity formed in the front of the joint. In *extension*, all the ligaments are put upon the stretch, with the exception of the ligamentum patellæ. When the knee is semi-flexed, a partial degree of *rotation* is permitted.

3. *Articulation between the Tibia and Fibula.*—The tibia and fibula are held firmly connected by means of *seven* ligaments, viz.

|                    |                        |
|--------------------|------------------------|
| Anterior, } above. | Interosseous membrane, |
| Posterior, }       | Interosseous inferior, |
| Anterior, } below. | Transverse.            |
| Posterior, }       |                        |

The *anterior superior ligament* is a strong fasciculus of parallel fibres, passing obliquely downwards and outwards from the inner tuberosity of the tibia, to the anterior surface of the head of the fibula.

The *posterior superior ligament* is disposed in a similar manner upon the posterior surface of the joint.

Within the articulation there is a distinct *synovial membrane* which is sometimes continuous with that of the knee joint.

The *interosseous membrane* or *superior interosseous ligament* is a broad layer of aponeurotic fibres which pass obliquely downwards and outwards, from the sharp ridge on the tibia to the inner edge of the fibula, and are crossed at an acute angle by a few fibres passing in the opposite direction. The ligament is deficient above, leaving a considerable interval between the bones, through which the anterior tibial artery takes its course forwards to the anterior aspect of the leg, and near its lower third there is an opening for the anterior peroneal artery and vein.

The interosseous membrane is *in relation, in front*, with the tibialis anticus, extensor longus digitorum, and extensor proprius pollicis muscle, with the anterior tibial vessels and nerve, and with the anterior peroneal artery; and *behind*, with the tibialis posticus, and flexor longus digitorum muscle, and with the posterior peroneal artery.

The *inferior interosseous ligament* consists of short and strong fibres, which hold the bones firmly together inferiorly, where they are nearly in

contact. This articulation is so firm that the fibula is likely to be broken in the attempt to rupture the ligament.

The *anterior inferior ligament* is a broad band, consisting of two fasciuli of parallel fibres which pass obliquely across the anterior aspect of the articulation of the two bones at their inferior extremity, from the tibia to the fibula.

The *posterior inferior ligament* (fig. 98, 2) is a similar band upon the posterior surface of the articulation. Both ligaments project somewhat below the margin of the bones, and serve to deepen the cavity of articulation for the astragalus.

The *transverse ligament* (fig. 98, 3) is a narrow band of ligamentous fibres, continuous with the preceding, and passing transversely across the back of the ankle joint between the two malleoli.

The *synovial membrane* of the inferior tibio-fibular articulation, is a duplicature of the synovial membrane of the ankle joint reflected upwards for a short distance between the two bones.

*Actions.*—An obscure degree of movement exists between the tibia and fibula, which is principally calculated to enable the latter to resist injury, by yielding for a trifling extent to the pressure exerted.

4. *Ankle joint.*—The ankle is a ginglymoid articulation; the surfaces entering into its formation are the under surface of the tibia with its malleolus and the malleolus of the fibula, above, and the surface of the astragalus with its two lateral facets, below. The ligaments are three in number:

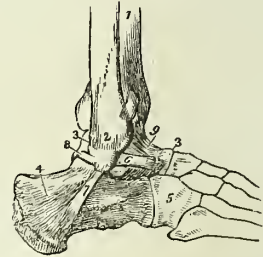
Anterior,                      Internal lateral,                      External lateral.

The *anterior ligament* is a thin membranous layer, passing from the margin of the tibia to the astragalus in front of the articular surface. It is *in relation, in front*, with the extensor tendons of the great and lesser toes, with the tendons of the tibialis anticus and peroneus tertius, and with the anterior tibial vessels and nerve. *Posteriorly* it lies in contact with the extra-synovial adipose tissue and with the synovial membrane.

Fig. 96.\*

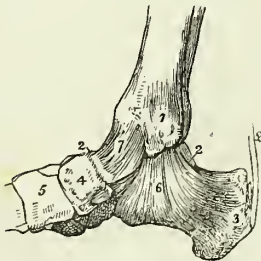

Fig. 97.†



\* An internal view of the ankle joint. 1. The internal malleolus of the tibia. 2, 2 Part of the astragalus: the rest is concealed by the ligaments. 3. The os calcis. 4. The scaphoid bone. 5. The internal cuneiform bone. 6. The internal lateral or deltoid ligament. 7. The anterior ligament. 8. The tendo Achillis; a small bursa is seen interposed between the tendon and the tuberosity of the os calcis.

† An external view of the ankle-joint. 1. The tibia. 2. The external malleolus of the fibula. 3, 3. The astragalus. 4. The os calcis. 5. The cuboid bone. 6. The anterior fasciculus of the external lateral ligament attached to the astragalus. 7. Its middle fasciculus, attached to the os calcis. 8. Its posterior fasciculus, attached to the astragalus. 9. The anterior ligament of the ankle.

The *internal lateral* or *deltoid ligament* is a triangular layer of fibres, attached superiorly by its apex to the internal malleolus, and inferiorly by an expanded base to the astragalus, os calcis, and scaphoid bone. Beneath the superficial layer of this ligament is a much stronger and thicker fasciculus, which connects the apex of the internal malleolus with the side of the astragalus.

This internal lateral ligament is covered in and partly concealed by the tendon of the tibialis posticus, and at its posterior part is in relation with the tendon of the flexor longus digitorum, and with that of the flexor longus pollicis.

The *external lateral ligament* consists of three strong fasciculi, which proceed from the inner side of the external malleolus, and diverge in three different directions. The *anterior fasciculus* passes forwards, and is attached to the astragalus; the *posterior*, backwards, and is connected with the astragalus posteriorly; and the *middle*, longer than the other two, descends to be inserted into the outer side of the os calcis.

"It is the strong union of this bone," says Sir Astley Cooper, "with the tarsal bones, by means of the external lateral ligaments, which leads to its being more frequently fractured than dislocated."

The transverse ligament of the tibia and fibula occupies the place of a posterior ligament. It is *in relation, behind*, with the posterior tibial vessels and nerve, and with the tendon of the tibialis posticus muscle; and *in front*, with the extra-synovial adipose tissue, and synovial membrane.

The *Synovial membrane* invests the cartilaginous surfaces of the tibia and fibula (sending a duplicate upwards between their lower ends), and the upper surface and two sides of the astragalus. It is then reflected upon the anterior and lateral ligaments, and upon the transverse ligament posteriorly.

*Actions.*—The movements of the ankle joint are *flexion* and *extension* only, without lateral motion.

5. *Articulations of the Tarsal Bones.*—The ligaments which connect the seven bones of the tarsus to each other are of three kinds,—

Dorsal,

Plantar,

Interosseous.

The *dorsal ligaments* are small fasciculi of parallel fibres, which pass from each bone to all the neighbouring bones with which it articulates. The only dorsal ligaments deserving of particular mention are, the *external* and *posterior calcaneo-astragaloid*, which, with the interosseous ligament, complete the articulation of the astragalus with the os calcis; the *superior* and *internal calcaneo-cuboid* ligament. The internal calcaneo-cuboid and the superior calcaneo-scaphoid ligament, which are closely united posteriorly in the deep groove which intervenes between the astragalus and os calcis, separate anteriorly to reach their respective bones; they form the principal bond of connexion between the first and second range of the bones of the foot. It is the division of this portion of these ligaments that demands the especial attention of the surgeon in performing Chopart's operation.

The *plantar ligaments* have the same disposition on the plantar surface of the foot; three of them, however, are of a large size, and have especial names, viz. the

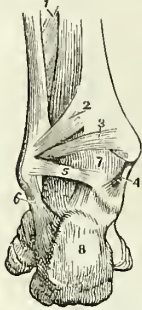
Calcaneo-scaphoid

Long calcaneo-cuboid,

Short calcaneo-cuboid.

The *inferior calcaneo-scaphoid ligament* is a broad and fibro-cartilaginous band of ligament, which passes forwards from the anterior and inner border of the os calcis and scaphoid bone. In addition to connecting the os calcis and scaphoid, it supports the astragalus, and forms part of the cavity in which the rounded head of the latter bone is received. It is lined upon its upper surface by the synovial membrane of the astragalo-scaphoid articulation.

Fig. 98.\*



The firm connexion of the os calcis with the scaphoid bone, and the feebleness of the astragalo-scaphoid articulation, are conditions favourable to the occasional dislocation of the head of the astragalus.

The *long calcaneo-cuboid ligamentum*, or *longum plantæ*, is a long band of ligamentous fibres, which proceeds from the under surface of the os calcis to the rough surface on the under part of the cuboid bone, its fibres being continued onwards to the bases of the third and fourth metatarsal bones.

This ligament forms the inferior boundary of a canal in the cuboid bone, through which the tendon of the peroneus longus passes to its insertion in the base of the metatarsal bone of the great toe.

The *short calcaneo-cuboid*, or *ligamentum breve plantæ*, is situated nearer to the bones than the long plantar ligament, from which it is separated by adipose tissue; it is broad and extensive, and ties the under surfaces of the os calcis and cuboid bone firmly together.

The *interosseous ligaments* are five in number; they are short and strong ligamentous fibres situated between adjoining bones, and firmly attached to their rough surfaces. One of these, the *calcaneo-astragaloid*, is lodged in the groove between the upper surface of the os calcis and the lower of the astragalus. It is large and very strong, consists of vertical and oblique fibres, and serves to unite the os calcis and astragalus solidly together. The second interosseous ligament, also very strong, is situated between the sides of the scaphoid and cuboid bone; while the three remaining interosseous ligaments connect strongly together the three cuneiform bones and the cuboid.

The *synovial membranes* of the tarsus are four in number; *one* for the posterior calcaneo-astragaloid articulation; *a second*, for the anterior calcaneo-astragaloid and astragalo-scaphoid articulation. Occasionally an additional small synovial membrane is found in the anterior calcaneo-astragaloid joint; *a third*, for the calcaneo-cuboid articulation; and *a fourth*, the large tarsal synovial membrane, for the articulations between the scaphoid and three cuneiform bones, the cuneiform bones with each other, the external cuneiform bone with the cuboid, and the two external cuneiform bones with the bases of the second and third metatarsal bones. The prolongation which reaches the metatarsal bones passes forwards between the internal and middle cuneiform bones. A small synovial membrane is sometimes met with between the contiguous surfaces of the scaphoid and cuboid bone.

\* A posterior view of the ankle joint. 1. The lower part of the interosseous membrane. 2. The posterior inferior ligament connecting the tibia and fibula. 3. The transverse ligament. 4. The internal lateral ligament. 5. The posterior fasciculus of the internal lateral ligament. 6. The middle fasciculus of the external lateral ligament. 7. The synovial membrane of the ankle joint. 8. The os calcis.



*Actions.*—The movements permitted by the articulation between the astragalus and os calcis, are a slight degree of gliding, in the directions *forwards* and *backwards* and *laterally* from side to side. The movements of the second range of tarsal bones is very trifling, being greater between the scaphoid and three cuneiform bones than in the other articulations. The movements occurring between the first and second range are the most considerable; they are *adduction* and *abduction*, and, in a minor degree, *flexion*, which increases the arch of the foot, and *extension*, which flattens the arch.

6. *Tarso-metatarsal Articulation.*—The ligaments of this articulation are,

Dorsal,                      Plantar,                      Interosseous.

The *dorsal ligaments* connect the metatarsal to the tarsal bones, and the metatarsal bones with each other. The precise arrangement of these ligaments is of little importance, but it may be remarked, that the base of the second metatarsal bone, articulating with the three cuneiform bones, receives a ligamentous slip from each, while the rest, articulating with a single tarsal bone, receive only a single tarsal slip.

The *plantar ligaments* have the same disposition on the plantar surface.

The *interosseous ligaments* are situated between the bases of the metatarsal bones of the four lesser toes; and also between the bases of the second and third metatarsal bones, and the internal and external cuneiform bones.

The metatarsal bone of the second toe is implanted by its base between the internal and external cuneiform bones, and is the most strongly articulated of all the metatarsal bones. This disposition must be recollected in amputation at the tarso-metatarsal articulation.

The *synovial membranes* of this articulation are three in number: one for the metatarsal bone of the great toe; one for the second and third metatarsal bones, which is continuous with the great tarsal synovial membrane; and one for the fourth and fifth metatarsal bones.

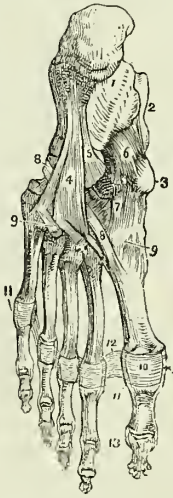
*Actions.*—The movements of the metatarsal bones upon the tarsal, and upon each other, are very slight; they are such only as contribute to the strength of the foot by permitting of a certain degree of yielding to opposing forces.

7. *Metatarsal-phalangeal Articulation.*—The ligaments of this articulation, like those of the articulation between the first phalanges and metacarpal bones of the hand, are,

Anterior or plantar,                      Two lateral,                      Transverse.

\* The ligaments of the sole of the foot. 1. The os calcis. 2. The astragalus. 3. The tuberosity of the scaphoid bone. 4. The long calcaneo-cuboid ligament. 5. Part of the short calcaneo-cuboid ligament. 6. The calcaneo-scaphoid ligament. 7. The plantar tarsal ligaments. 8, 8. The tendon of the peroneus longus muscle. 9, 9. Plantar tarso-metatarsal ligaments. 10. Plantar ligament of the metatarso-phalangeal articulation of the great toe; the same ligament is seen upon the other toes. 11. Lateral ligaments of the metatarso-phalangeal articulation. 12. Transverse ligament. 13. The lateral ligaments of the phalanges of the great toe; the same ligaments are seen upon the other toes.

Fig. 99.



The *anterior or plantar ligaments* are thick and fibro-cartilaginous, and form part of the articulating surface of the joint.

The *lateral ligaments* are short and very strong, and situated on each side of the joints.

The *transverse ligaments* are strong bands, which pass transversely between the anterior ligaments.

The expansion of the extensor tendon supplies the place of a dorsal ligament.

*Actions.*—The movements of the first phalanges upon the rounded heads of the metatarsal bones, are *flexion, extension, adduction* and *abduction*.

8. *Articulation of the Phalanges.*—The ligaments of the phalanges are the same as those of the fingers, and have the same disposition; their actions are also similar. They are,

Anterior or plantar,                      Two lateral.

## CHAPTER IV.

### ON THE MUSCLES.

MUSCLES are the moving organs of the animal frame; they constitute by their size and number the great bulk of the body, upon which they bestow form and symmetry. In the limbs they are situated around the bones, which they invest and defend, while they form to some of the joints a principal protection. In the trunk they are spread out to enclose cavities, and constitute a defensive wall capable of yielding to internal pressure, and again returning to its original position.

Their colour presents the deep red which is characteristic of flesh, and their form is variously modified, to execute the varied range of movements which they are required to effect.

Muscle is composed of a number of parallel fibres placed side by side, and supported and held together by a delicate web of areolar tissue; so that, if it were possible to remove the muscular substance, we should have remaining a beautiful reticular framework, possessing the exact form and size of the muscle without its colour and solidity. Towards the extremity of the organ the muscular fibre ceases, and the areolar structure becomes aggregated and modified, so as to constitute those glistening fibres and cords by which the muscle is tied to the surface of bone, and which are called *tendons*. Almost every muscle in the body is connected with bone, either by tendinous fibres, or by an aggregation of those fibres constituting a tendon; and the union is so firm, that, under extreme violence, the bone itself rather breaks than permits of the separation of the tendon from its attachment. In the broad muscles the tendon is spread so as to form an expansion, called *aponeurosis* (ἀπὸ, longè; νεῦρον,\* *nervus*—a nerve widely spread out).

Muscles present various modifications in the arrangement of their fibres in relation to their tendinous structure. Sometimes they are completely

\* The ancients named all the white fibres of the body *νεῦρα*; the term has since been limited to the nerves.

longitudinal, and terminate at each extremity in tendon, the entire muscle being *fusiform* in its shape; in other situations they are disposed like the rays of a fan, converging to a tendinous point, as the temporal, pectoral, glutei, &c., and constitute a *radiate* muscle. Again, they are *penniform*, converging like the plumes of a pen to one side of a tendon, which runs the whole length of the muscle as in the peronei; or *bipenniform*, converging to both sides of the tendon. In other muscles the fibres pass obliquely from the surface of a tendinous expansion spread out on one side, to that of another extended on the opposite side, as in the semi-membranosus; or, they are composed of penniform or bipenniform fasciculi as in the deltoid, and constitute a compound muscle.

The nomenclature of the muscles is defective and confused, and is generally derived from some prominent character which each muscle presents; thus, some are named from their situation, as the tibialis, peroneus; others from their uses, as the flexors, extensors, adductors, abductors, levators, tensors, &c. Some again from their form, as the trapezius, triangularis, deltoid, &c.; and others from their direction, as the rectus, obliquus, transversalis, &c. Certain muscles have received names expressive of their attachments, as the sterno-mastoid, sterno-hyoid, &c.; and others, of their divisions, as the biceps, triceps, digastricus, complexus, &c.

In the description of a muscle we express its attachment by the words "origin" and "insertion;" the term *origin* is generally applied to the more fixed or central attachment, or to the point towards which the motion is directed, while *insertion* is assigned to the more movable point, or to that most distant from the centre; but there are many exceptions to this principle, and as many muscles pull equally by both extremities, the use of such terms must be regarded as purely arbitrary.

In structure, muscle is composed of bundles of fibres of variable size called fasciculi, which are enclosed in a cellular membranous investment or sheath, and the latter is continuous with the cellular framework of the fibres. Each *fasciculus* is composed of a number of smaller bundles, and these of single fibres, which, from their minute size and independent appearance, have been distinguished by the name of ultimate fibres. The *ultimate fibre* is found by microscopic investigation to be itself a fasciculus (ultimate fasciculus), made up of a number of *ultimate fibrils* enclosed in a delicate sheath or myolemma.\* Two kinds of ultimate muscular fibre exist in the animal economy; viz., that of voluntary or animal life, and that of involuntary or organic life.

The *ultimate fibre of animal life* is known by its size, by its uniformity of calibre, and especially by the very beautiful transverse markings which occur at short and regular distances throughout its whole extent. It also presents other markings or striæ, having a longitudinal direction, which indicate the existence of fibrillæ within its myolemma. The myolemma, or investing sheath of the ultimate fibre, is thin, structureless and transparent.

\* In the summer of 1836, while engaged with Dr. Jones Quain in the examination of the animal tissues with a simple dissecting microscope, constructed by Powell, I first saw that the ultimate fibre of muscle was invested by a proper sheath, for which I proposed the term "Myolemma;" a term which was adopted by Dr. Quain in the fourth edition of his "Elements of Anatomy." We at that time believed that the transverse folding of that sheath gave rise to the appearance of transverse striæ, an opinion which subsequent examinations proved to be incorrect. Mr. Bowman employs the term "Sarcolemma," as synonymous with Myolemma.

According to Mr. Bowman\* the ultimate fibres are polygonal in shape [fig. 100] from mutual pressure. They are also variable in their size, not merely in different classes and genera of animals and different sexes, but even in the same muscle. For example, the average diameter of the ultimate fibre in the human female is  $\frac{1}{454}$ , while that of the male is  $\frac{1}{352}$ , the average of both being  $\frac{1}{403}$ . The largest fibres are met with in fishes, in which animals they average  $\frac{1}{222}$ ; the next largest are found in man, while in other classes they range in the following order:—insects  $\frac{1}{419}$ ; reptiles  $\frac{1}{84}$ ; mammalia  $\frac{1}{567}$ ; birds  $\frac{1}{807}$ .

The *ultimate fibrils* of animal life, according to Mr. Bowman, are beaded filaments consisting of a regular succession of segments and constrictions, the latter being narrower than the former, and the component substance probably less dense.

Fig. 100.†

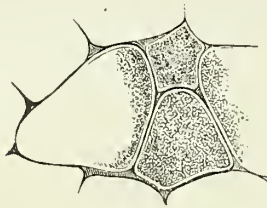
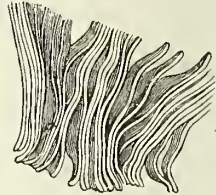


Fig. 101.‡



An ultimate fibre consists of a bundle of these fibrils, which are so disposed that all the segments and all the constrictions correspond, and in this manner give rise to the alternate light and dark lines of the transverse striæ. The fibrils are connected together with very different degrees of closeness in different animals; in man they are but slightly adherent, and distinct longitudinal lines of junction may be observed between them; they also separate very easily when macerated for some time. Besides the more usual separation of the ultimate fibre into fibrils, it breaks when stretched, into transverse sections [fig. 101,] corresponding with the dark line of the striæ, and consequently with the constrictions of the fibrillæ. When this division occurs with the greatest facility, the longitudinal lines are indistinct, or scarcely perceptible. "In fact," says Mr. Bowman, "the primitive fasciculus seems to consist of primitive component segments or particles, arranged so as to form, in one sense, fibrillæ, and in another sense, discs; and which of these two may happen to present itself to the observer, will depend on the amount of adhesion, endways or sideways, existing between the segments. Generally, in a recent fasciculus, there are transverse striæ, showing divisions into discs, and longitudinal striæ, marking its composition by fibrillæ."

Mr. Bowman has observed that in the substance of the ultimate fibre there exist minute "oval or circular discs, frequently concave on one or

\* On the Minute Structure and Movements of Voluntary Muscle. By Wm. Bowman, Esq. From the Philosophical Transactions for 1840.

† Transverse section of ultimate fibres of the biceps, copied from the illustrations to Mr. Bowman's paper. In this figure the polygonal form of the fibres is seen, and their composition of ultimate fibrils.

‡ An ultimate fibre, in which the transverse splitting into discs, in the direction of the constrictions of the ultimate fibrils is seen. From Mr. Bowman's paper.


both surfaces, and containing, somewhere near the centre, one, two, or three minute dots or granules." Occasionally they are seen to present irregularities of form, which Mr. Bowman is inclined to regard as accidental. They are situated between, and are connected with the fibrils, and are distributed in pretty equal numbers through the fibre. These corpuscles are the nuclei of the nucleated cells from which the muscular fibre was originally developed. From observing, however, that their "absolute number is far greater in the adult than in the fœtus, while their number, relatively to the bulk of the fasciculi, at these two epochs, remains nearly the same," Mr. Bowman regards it as certain, that "during development, and subsequently, a further and successive deposit of corpuscles" takes place. The corpuscles are brought into view only when the muscular fibre is acted upon by a solution of "one of the milder acids, as the citric."

According to my own investigations,† the ultimate fibril of animal life is cylindrical when isolated, and probably polygonal from pressure when forming part of an ultimate fibre or fasciculus. It measures in diameter  $\frac{1}{20000}$  of an inch, and is composed of a succession of cells connected by their flat surfaces. The cells are filled with a transparent substance, which I have termed *myoline*. The myoline differs in density in different cells, and from this circumstance bestows a peculiarity of character on certain of the cells; for example, when a fibril in its passive state is examined, there will be seen a series of dark oblong bodies separated by light spaces of equal length; now the dark bodies are each composed of a pair of cells containing the densest form of myoline, and are hence highly refractive while the transparent spaces are constituted by a pair of cells containing a more fluid myoline. When the fibrils are collected together so as to form an ultimate fibre or fasciculus, the appearance of the cell is altered; those which look dark in the single fibril, that is, the most refractive, being

Fig. 102.\*

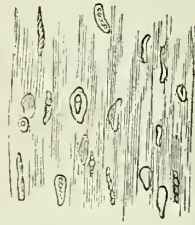

Fig. 103.‡



\* Mass of ultimate fibres from the pectoralis major of the human fœtus, at nine months. These fibres have been immersed in a solution of tartaric acid, and their "numerous corpuscles, turned in various directions, some presenting nucleoli," are shown. From Mr. Bowman's paper.

† These were made on dissections of fresh human muscle, prepared with great care by Mr. Lealand, partner of the eminent optician, Mr. Powell.

‡ Structure of the ultimate muscular fibril and fibre of animal life.

a. An ultimate muscular fibril in the state of partial contraction.

b. A similar fibril in the state of ordinary relaxation. This fibril measured  $\frac{1}{20000}$  of an inch in diameter.

c. A similar fibril put upon the stretch, and measuring  $\frac{1}{30000}$  of an inch in diameter.

d. Plan of a portion of an ultimate fibre, showing the manner in which the transverse striæ are produced by the collocation of the fibrils.

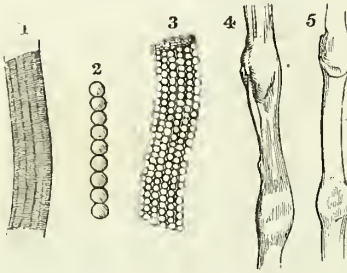
Nos. 1, 1. The pair of highly-refractive cells; they form the dark parts of the single fibrils, but the bright parts of the fibre d. In the stretched fibril c, each cell has the appearance of being double. 2, 2. The pair of less refractive cells, light in the single fibrils, but forming the shaded stria in d. The transverse septum between these cells is very conspicuous; and in c two other septa are seen to exist, making the number of transparent cells four. In d, the tier of cells immediately above the dark tier is partially illumined from the obliquity of the light.

ranged side by side, constitute the bright band; while the transparent cells of the single fibril are the shaded stria of the fibre.

When the ultimate fibril is very much stretched, the two highly-refractive cells appear each to be double, while the transparent space is evidently composed of four cells.

The *ultimate fibre of organic life* (Fig. 104, 4, 5) is a simple homogeneous filament, much smaller than the fibre of animal life, flat, and without transverse markings. Besides these characters, there may generally be seen a dark line or several dark points in its interior, and not unfrequently the entire fibre appears enlarged at irregular distances. These appearances are due to the presence of the unobliterated nuclei of cells from which the fibre was originally developed. The fibres of organic life are collected into fasciculi of various size, and are held together by dark nuclear fibres, similar to those which bind the fasciculi of fibrous tissue (p. 134.)

Fig. 104.\*



The *development of muscular fibre* is effected by means of the formation of nucleated cells out of an original blastema, and the conversion of those cells, by a process already described (p. 46), into the tubuli of ultimate fibres, while their contents; by a subsequent developmental action, are transferred into ultimate fibrils. According to this view the cell membranes constitute the myolemma, and the contents of the cell are a blastema out of which new cells are formed.

The disposition of these latter cells, in the production of fibrillæ, is probably much more simple than has hitherto been conceived. In the muscular fibre of organic life, the process would seem to stop short of the formation of fibrillæ, the cells being accumulated without apparent order. The corpuscles, observed by Mr. Bowman, in fœtal muscle (fig. 102), and the nodosities of organic fibre, are obviously undeveloped cells and nuclei.

Muscles are divided into two great classes, voluntary and involuntary, to which may be added, as an intermediate and connecting link, the muscle of the vascular system, the heart.

The *voluntary*, or *system of animal life*, is developed from the external or serous layer of the germinal membrane, and comprehends the whole of the muscles of the limbs and of the trunk. The *involuntary*, or *organic system*, is developed from the internal or mucous layer, and constitutes the thin muscular structure of the intestinal canal, bladder, and internal

\* 1. A muscular fibre of animal life enclosed in its myolemma; the transverse and longitudinal striæ are seen.

2. An ultimate fibril of muscular fibre of animal life, according to Mr. Bowman.

3. A muscular fibre of animal life, similar to 1, but more highly magnified. Its myolemma is so thin and transparent, as to permit the ultimate fibrils to be seen through. The true nature of the longitudinal striæ is seen in this fibre, as well as the mode of formation of the transverse striæ.

4. A muscular fibre of organic life, from the urinary bladder, magnified 600 times, linear measure. Two of the nuclei are seen.

5. A muscular fibre of organic life, from the stomach, magnified 600 times. The diameter of this and of the preceding fibre, midway between the nuclei, was  $\frac{1}{3750}$  of an inch.

organs of generation. At the commencement of the alimentary canal in the œsophagus, and near its termination in the rectum, the muscular coat is formed by a blending of the fibres of both classes. The heart is developed from the middle, or vascular layer of the germinal membrane; and although involuntary in its action, is composed of ultimate fibres, having the transverse striæ of the muscle of animal life.

The muscles may be arranged in conformity with the general division of the body into,—1. Those of the head and neck. 2. Those of the trunk. 3. Those of the upper extremity. 4. Those of the lower extremity.

## MUSCLES OF THE HEAD AND NECK.

The muscles of the head and neck admit of a subdivision into those of the head and face, and those of the neck.

*Muscles of the Head and Face.*—These muscles may be divided into groups, corresponding with the natural regions of the head and face; the groups are eight in number, viz.—

- |                   |                           |
|-------------------|---------------------------|
| 1. Cranial group. | 5. Superior labial group. |
| 2. Orbital group. | 6. Inferior labial group. |
| 3. Ocular group.  | 7. Maxillary group.       |
| 4. Nasal group.   | 8. Auricular group.       |

The muscles of each of these groups may be thus arranged—

1. *Cranial group.*

Occipito-frontalis.

2. *Orbital group.*

Orbicularis palpebrarum,  
Corrugator supercilii,  
Tensor tarsi.

3. *Ocular group.*

Levator palpebræ,  
Rectus superior,  
Rectus inferior,  
Rectus internus,  
Rectus externus,  
Obliquus superior,  
Obliquus inferior.

4. *Nasal group.*

Pyramidalis nasi,  
Compressor nasi,  
Dilatator naris.

5. *Superior labial group.*

(Orbicularis oris),  
Levator labii superioris alæque nasi,

Levator labii superioris proprius,  
Levator anguli oris,  
Zygomaticus major,  
Zygomaticus minor,  
Depressor labii superioris alæque nasi.

6. *Inferior labial group.*

(Orbicularis oris),\*  
Depressor labii inferioris,  
Depressor anguli oris,  
Levator labii inferioris.

7. *Maxillary group.*

Masseter,  
Temporalis,  
Buccinator,  
Pterygoideus externus,  
Pterygoideus internus.

8. *Auricular group.*

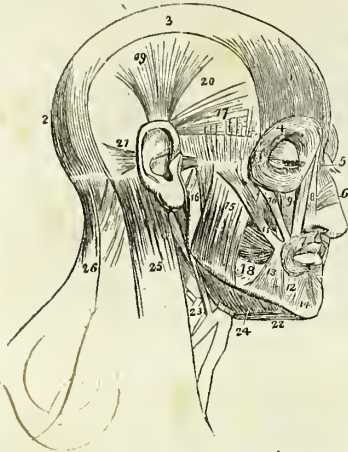Attollens aurem,  
Attrahens aurem,  
Retrahens aurem.

\* The orbicularis oris, from encircling the mouth, belongs necessarily to both the superior and inferior labial regions; it is therefore enclosed within parentheses in both.

## 1. Cranial group.—Occipito-frontalis.

*Dissction.*—The *occipito-frontalis* is to be dissected by making a longitudinal incision along the vertex of the head, from the tubercle on the occipital bone to the root of the nose; and a second incision along the forehead and around the side of the head, to join the two extremities of the preceding. Dissect the integument and superficial fascia carefully outwards, beginning at the anterior angle of the flap, where the muscular fibres are thickest, and remove it altogether. This dissection requires care; for the muscle is very thin, and, without attention, would be raised with the integument. There is no deep fascia on the face and head, nor is it required; for here the muscles are closely applied against the bones upon which they depend for support, whilst in the extremities the support is derived from the dense

Fig. 105.\*



layer of fascia by which they are invested, and which forms for each a distinct sheath.

The OCCIPITO-FRONTALIS is a broad musculo-aponeurotic layer, which covers the whole of the side of the vertex of the skull, from the occiput to the eyebrow. It *arises* by tendinous fibres from the outer two-thirds of the superior curved line of the occipital, and from the mastoid portion of the temporal bone. Its *insertion* takes place by means of the blending of the fibres of its anterior portion with those of the orbicularis palpebrarum, corrugator supercilii, levator labii superioris aëque nasi, and pyramidalis nasi. The muscle is fleshy in front over the frontal bone and behind over the occipital, the two portions being connected by a broad aponeurosis. The two muscles, together with their aponeurosis, cover the whole of the vertex of the skull, hence their designation *galca capitis*; they are loosely adherent to the pericranium, but very closely to the integument, particularly over the forehead.

*Relations.*—This muscle is in relation by its *external surface* from before backwards, with the frontal and supra-orbital vessels, the supra-orbital and facial nerve, the temporal vessels and nerve, the occipital vessels and

\* The muscles of the head and face. 1. The frontal portion of the occipito-frontalis. 2. Its occipital portion. 3. Its aponeurosis. 4. The orbicularis palpebrarum, which conceals the corrugator supercilii and tensor tarsi. 5. The pyramidalis nasi. 6. The compressor nasi. 7. The orbicularis oris. 8. The levator labii superioris aëque nasi, the adjoining fasciculus between numbers 8 and 9 is the labial portion of the muscle. 9. The levator labii superioris proprius; the lower part of the levator anguli oris is seen between the muscles 10 and 11. 10. The zygomaticus minor. 11. The zygomaticus major. 12. The depressor labii inferioris. 13. The depressor anguli oris. 14. The levator labii inferioris. 15. The superficial portion of the masseter. 16. Its deep portion. 17. The attrahens aurem. 18. The buccinator. 19. The attollens aurem. 20. The temporal fascia which covers in the temporal muscle. 21. The retrahens aurem. 22. The anterior belly of the digastricus muscle; the tendon is seen passing through its aponeurotic pulley. 23. The stylo-hyoid muscle, pierced by the posterior belly of the digastricus. 24. The mylo-hyoideus muscle. 25. The upper part of the sterno-mastoid. 26. The upper part of the trapezius. The muscle between 25 and 26 is the splenius.



nerves, and with the integument, to which it is very closely adherent. Its *under surface* is attached to the pericranium by a loose areolar tissue which admits of considerable movement.

*Actions.*—To raise the eyebrows, thereby throwing the integument of the forehead into transverse wrinkles. Some persons have the power of moving the entire scalp upon the pericranium by means of these muscles.

2. *Orbital group.*—Orbicularis palpebrarum,  
Corrugator supercilii,  
Tensor tarsi.

*Dissection.*—The dissection of the face is to be effected by continuing the longitudinal incision of the vertex of the previous dissection onwards to the tip of the nose, and thence downwards to the margin of the upper lip; then carry an incision along the margin of the lip to the angle of the mouth, and transversely across the face to the angle of the lower jaw. Lastly, divide the integument in front of the external ear upwards to the transverse incision which was made for exposing the occipito-frontalis. Dissect the integument and superficial fascia carefully from the whole of the region included by these incisions, and the present with the two following groups of muscles will be brought into view.

The ORBICULARIS PALPEBRARUM is a sphincter muscle, surrounding the orbit and eyelids. It *arises* from the internal angular process of the frontal bone, from the nasal process of the superior maxillary, and from a short tendon (*tendo oculi*) which extends between the nasal process of the superior maxillary bone, and the inner extremities of the tarsal cartilages of the eyelids. The fibres encircle the orbit and eyelids, forming a broad and thin muscular plane, which is *inserted* into the lower border of the *tendo oculi*, and into the nasal process of the superior maxillary bone. Upon the eyelids the fibres are thin and pale, and possess an involuntary action. The *tendo oculi*, in addition to its insertion into the nasal process of the superior maxillary bone, sends a process inwards which expands over the lacrimal sac, and is attached to the ridge of the lacrimal bone: this is the reflected aponeurosis of the *tendo oculi*.

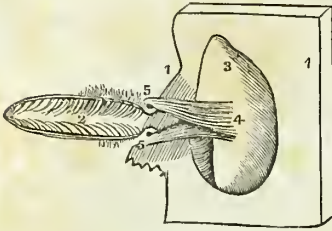
*Relations.*—By its *superficial surface* it is closely adherent to the integument from which it is separated over the eyelids by a loose areolar tissue. By its *deep surface* it lies in contact *above* with the upper border of the orbit, with the corrugator supercilii muscle, and with the frontal and supra-orbital vessels and supra-orbital nerve; *below*, with the lacrimal sac, with the origins of the levator labii superioris alæque nasi, levator labii superioris proprius, zygomaticus major and minor muscles, and malar bone; and *externally* with the temporal fascia. Upon the eyelids it is in relation with the broad tarsal ligament and tarsal cartilages, and by its upper border gives attachment to the occipito-frontalis muscle.

The CORRUGATOR SUPERCILII is a small narrow and pointed muscle, situated immediately above the orbit and beneath the upper segment of the orbicularis palpebrarum muscle. It *arises* from the inner extremity of the superciliary ridge, and is *inserted* into the under surface of the orbicularis palpebrarum at a point corresponding with the middle of the superciliary arch.

*Relations.*—By its *superficial surface* with the pyramidalis nasi, occipito-frontalis and orbicularis palpebrarum muscle; and by its *deep surface*, with the supra-orbital vessels and nerve.

The TENSOR TARSI (Horner's\* muscle) is a thin plane of muscular fibres, about three lines in breadth and six in length. It is best dissected

Fig. 106.†

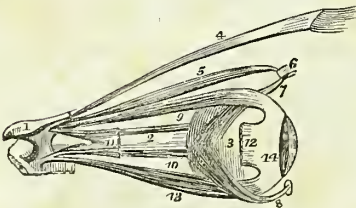


by separating the eyelids from the eye, and turning them over the nose without disturbing the tendo oculi; then dissect away the small fold of mucous membrane called plica semilunaris, and some loose cellular tissue under which the muscle is concealed. It arises from the orbital surface of the lacrimal bone, and passing across the lacrimal sac divides into two slips, which are inserted into the lacrimal canals as far as the puncta.

*Actions.*—The palpebral portion of the orbicularis acts involuntarily in closing the lids, and from the greater curve of the upper lid, upon that principally. The entire muscle acts as a sphincter, drawing at the same time, by means of its osseous attachment, the integument and lids inwards towards the nose. The corrugatores superciliorum draw the eyebrows downwards and inwards, and produce the vertical wrinkles of the forehead. The *tensor tarsi*, or lacrimal muscle, draws the extremities of the lacrimal canals inwards, so as to place the puncta in the best position for receiving the tears. It serves also to keep the lids in relation with the surface of the eye, and compresses the lacrimal sac. Dr. Horner is acquainted with two persons who have the voluntary power of drawing the lids inwards by these muscles so as to bury the puncta in the angle of the eye.

3. *Ocular group.*—Levator palpebræ,  
Rectus superior,  
Rectus inferior,  
Rectus internus,  
Rectus externus,  
Obliquus superior,  
Obliquus inferior.

Fig. 107.‡



*Dissection.*—To open the orbit (the calvarium and brain having been removed) the frontal bone must be sawn through at the inner extremity of the orbital ridge, and, externally, at its outer extremity. The roof of the orbit may then be comminuted by a few light blows with the hammer; a process easily accomplished, on account of the thinness of the orbital plate of the frontal bone and lesser wing of the

\* W. E. Horner, M. D., Professor of Anatomy in the University of Pennsylvania. The notice of this muscle is contained in a work published in Philadelphia in 1827, entitled "Lessons in Practical Anatomy."

† A view of the tensor tarsi muscle. 1, 1. Bony margins of the orbit. 2. Opening between the eyelids. 3. Internal face of the orbit. 4. Origin of the tensor tarsi. 5, 5. Insertion into the neighbourhood of the puncta lachrymalis.

‡ The muscles of the eyeball; the view is taken from the outer side of the right orbit. 1. A small fragment of the sphenoid bone around the entrance of the optic nerve into the orbit. 2. The optic nerve. 3. The globe of the eye. 4. The levator palpebre

sphenoid. The superciliary portion of the orbit may now be driven forwards by a smart blow, and the external angular process and external wall of the orbit outwards in the same manner; the broken fragments of the roof of the orbit should then be removed. By this means the periosteum will be exposed unbroken and undisturbed. Remove the periosteum from the whole of the upper surface of the exposed orbit, and examine the parts beneath.

The *LEVATOR PALPEBRÆ* is a long, thin, and triangular muscle; situated in the upper part of the orbit on the middle line; it *arises* from the upper margin of the optic foramen, and from the fibrous sheath of the optic nerve, and is *inserted* into the upper border of the superior tarsal cartilage.

*Relations.*—By its *upper surface* with the fourth nerve, the supra-orbital nerve and artery, the periosteum of the orbit, and in front with the inner surface of the broad tarsal ligament. By its *under surface* it rests upon the superior rectus muscle, and the globe of the eye; it receives its nerve and artery by this aspect, and in front is covered for a short distance by the conjunctiva.

The *RECTUS SUPERIOR* (*attollens*) *arises* from the upper margin of the optic foramen, and from the fibrous sheath of the optic nerve, and is *inserted* into the upper surface of the globe of the eye at a point somewhat more than three lines from the margin of the cornea.

*Relations.*—By its *upper surface* with the levator palpebræ muscle; by the *under surface* with the optic nerve, the ophthalmic artery and nasal nerve, from which it is separated by a layer of fascia and by the adipose tissue of the orbit, and in front with the globe of the eye, the tendon of the superior oblique muscle being interposed.

The *RECTUS INFERIOR* (*depressor*) *arises* from the inferior margin of the optic foramen by a tendon (ligament of Zinn) which is common to it, the internal and the external rectus, and from the fibrous sheath of the optic nerve; it is *inserted* into the inferior surface of the globe of the eye at a little more than two lines from the margin of the cornea.

*Relations.*—By its *upper surface* with the optic nerve, the inferior oblique branch of the third nerve, the adipose tissue of the orbit, and the under surface of the globe of the eye. By its *under surface* with the periosteum of the floor of the orbit, and with the inferior oblique muscle.

The *RECTUS INTERNUS* (*adductor*), the thickest and shortest of the straight muscles, *arises* from the common tendon, and from the fibrous sheath of the optic nerve; and is *inserted* into the inner surface of the globe of the eye at two lines from the margin of the cornea.

*Relations.*—By its *internal surface* with the optic nerve, the adipose tissue of the orbit and the eyeball. By its *outer surface* with the periosteum of the orbit; and by its *upper border* with the anterior and posterior ethmoidal vessels, the nasal and supra-trochlear nerve.

The *RECTUS EXTERNUS* (*abductor*), the longest of the straight muscles, *arises* by two distinct heads, one from the common tendon, the other with

muscle. 5. The superior oblique muscle. 6. Its cartilaginous pulley. 7. Its reflected tendon. 8. The inferior oblique muscle; the small square knob at its commencement is a piece of its bony origin broken off. 9. The superior rectus. 10. The internal rectus almost concealed by the optic nerve. 11. Part of the external rectus, showing its two heads of origin. 12. The extremity of the external rectus at its insertion; the intermediate portion of the muscle having been removed. 13. The inferior rectus. 14. The tunica albuginea, formed by the expansion of the tendons of the four recti.

the origin of the superior rectus from the margin of the optic foramen; the nasal, third and sixth nerves passing between its heads. It is *inserted* into the outer surface of the globe of the eye at a little more than two lines from the margin of the cornea.

*Relations.*—By its *internal surface* with the third, the nasal, the sixth, and the optic nerve, the ciliary ganglion and nerves, the ophthalmic artery and vein, the adipose tissue of the orbit, the inferior oblique muscle and the eyeball. By its *external surface* with the periosteum of the orbit; and by the *upper border* with the lachrymal vessels and nerve and the lachrymal gland.

The recti muscles present several characters which are common to all; thus they are thin, have each the form of an isosceles triangle, bear the same relation to the globe of the eye, and are inserted in a similar manner into the sclerotica, at about two lines from the circumference of the cornea. The points of difference relate to thickness and length; the internal rectus is the thickest and shortest, the external rectus the longest of the four, and the superior rectus the most thin. The insertion of the four recti muscles into the globe of the eye forms a tendinous expansion, which is continued as far as the margin of the cornea, and is called the tunica albuginea.

The OBLIQUUS SUPERIOR (trochlearis) is a fusiform muscle *arising* from the margin of the optic foramen, and from the fibrous sheath of the optic nerve; it passes forwards to the pulley beneath the internal angular process of the frontal bone; its tendon is then reflected beneath the superior rectus muscle, to the outer and posterior part of the globe of the eye, where it is inserted into the sclerotic coat, near the entrance of the optic nerve. The tendon is surrounded by a synovial membrane, while passing through the cartilaginous pulley.

*Relations.*—By its *superior surface* with the fourth nerve, the supra-trochlear nerve, and with the periosteum of the orbit. By the *inferior surface* with the adipose tissue of the orbit, the upper border of the internal rectus and the vessels and nerves in relation with that border.

The OBLIQUUS INFERIOR, a thin and narrow muscle, *arises* from the inner margin of the superior maxillary bone, immediately external to the lachrymal groove, and passes beneath the inferior rectus, to be *inserted* into the outer and posterior part of the eyeball, at about two lines from the entrance of the optic nerve.

*Relations.*—By its *superior surface* with the inferior rectus muscle and with the eyeball; and by the *inferior surface* with the periosteum of the floor of the orbit, and the external rectus muscle.

According to Mr. Farrall\* the muscles of the orbit are separated from the globe of the eyeball and from the structures immediately surrounding the optic nerve, by a distinct fascia, which is continuous with the broad tarsal ligament and with the tarsal cartilages. This fascia the author terms the *tunica vaginalis oculi*,† it is pierced anteriorly for the passage of the six orbital muscles, by six openings through which the tendons of the muscles play as through pulleys. The use assigned to it by Mr. Farrall is to protect the eyeball from the pressure of its muscles during their action. By means of this structure the recti muscles are enabled to impress

\* In a paper read before the Royal Society, on the 10th of June, 1841.

† This fascia was first described by Mr. Dalrymple in his work on the "Anatomy of the Human Eye." 1834.

a rotatory movement upon the eyeball; and in animals provided with a retractor muscle, they also act as antagonists to its action.

*Actions.*—The levator palpebræ raises the upper eyelid. The four recti, acting singly, pull the eyeball in the four directions; upwards, downwards, inwards, and outwards. Acting by pairs, they carry the eyeball in the diagonal of these directions, viz. upwards and inwards, upwards and outwards, downwards and inwards, or downwards and outwards. Acting all together, they directly retract the globe within the orbit. The superior oblique muscle, acting alone, rolls the globe inwards and forwards, and carries the pupil outwards and downwards to the lower and outer angle of the orbit. The inferior oblique, acting alone, rolls the globe outwards and backwards, and carries the pupil outwards and upwards to the upper and outer angle of the eye. Both muscles acting together, draw the eyeball forwards, and give the pupil that slight degree of eversion which enables it to admit the largest field of vision.

4. *Nasal Group.*—Pyramidalis nasi,  
Compressor nasi,  
Dilatator naris.

The PYRAMIDALIS NASI is a small pyramidal slip of muscular fibres sent downwards upon the bridge of the nose by the occipito-frontalis. It is inserted into the tendinous expansion of the compressores nasi.

*Relations.*—By its *upper surface* with the integument; by its *under surface* with the periosteum of the frontal and nasal bone. Its *outer border* corresponds with the edge of the orbicularis palpebrarum, and its *inner border* with its fellow, from which it is separated by a slight interval.

The COMPRESSOR NASI is a thin and triangular muscle; it *arises* by its apex from the canine fossa of the superior maxillary bone, and spreads out upon the side of the nose into a thin tendinous expansion, which is continuous across its ridge with the muscle of the opposite side.

*Relations.*—By its *superficial surface* with the levator labii superioris proprius, the levator labii superioris alæque nasi, and the integument; by its *deep surface* with the superior maxillary and nasal bone, and with the alar and lateral cartilages of the nose.

The DILATATOR NARIS is a thin and indistinct muscular apparatus expanded upon the ala of the nostril, and consisting of an anterior and a posterior slip. The anterior slip (levator proprius alæ nasi anterior) extends between the lateral and alar cartilage at about midway between the tip and the attached margin of the nose. The posterior slip (levator proprius alæ nasi posterior) is attached above to the margin of the nasal process of the superior maxillary bone, and below to the small cartilages of the ala nasi. These muscles are difficult of dissection from the close adherence of the integument to the nasal cartilages.

*Actions.*—The pyramidalis nasi, as a point of attachment of the occipito-frontalis, assists that muscle in its action: it also draws down the inner angle of the eyebrow, and by its insertion fixes the aponeurosis of the compressores nasi. The compressores nasi appear to act in expanding rather than in compressing the nares; hence probably the compressed state of the nares from paralysis of these muscles in the last moments of life, or in compression of the brain. The use of the dilatator naris is expressed in its name.

5. *Superior Labial Group*.—Orbicularis oris,  
 Levator labii superioris alæque nasi,  
 Levator labii superioris proprius,  
 Levator anguli oris,  
 Zygomaticus major,  
 Zygomaticus minor,  
 Depressor labii superioris alæque nasi.

The ORBICULARIS ORIS is a sphincter muscle, completely surrounding the mouth, and possessing consequently neither origin nor insertion. It is composed of two thick semicircular planes of fibres, which embrace the rima of the mouth, and interlace at their extremities, where they are continuous with the fibres of the buccinator, and of the other muscles connected with the angle of the mouth. The upper segment is attached by means of a small muscular fasciculus (naso-labialis) to the column of the nose; and other fasciculi connected with both segments and attached to the maxillary bones are termed "accessorii."

*Relations*.—By its *superficial surface* with the integument of the lips, with which it is closely connected. By its *deep surface* with the mucous membrane of the mouth, the labial glands and coronary arteries being interposed. By its *circumference* with the numerous muscles which move the lips, and by the inner border with the mucous membrane of the rima of the mouth.

The LEVATOR LABII SUPERIORIS ALÆQUE NASI is a thin triangular muscle: it *arises* from the upper part of the nasal process of the superior maxillary bone; and becoming broader as it descends, is *inserted* by two distinct portions into the ala of the nose and upper lip.

*Relations*.—By its *superficial surface* with part of the orbicularis palpebrarum muscle, the facial artery, and the integument. By its *deep surface* with the superior maxillary bone, compressor nasi, alar cartilage, and with a muscular fasciculus attached only to the bone, and thence called musculus anomalus.

The LEVATOR LABII SUPERIORIS PROPRIUS is a thin quadrilateral muscle: it *arises* from the lower border of the orbit, and passing obliquely downwards and inwards, is *inserted* into the integument of the upper lip; its deep fibres being blended with those of the orbicularis.

*Relations*.—By its *superficial surface* with the lower segment of the orbicularis palpebrarum, with the facial artery, and with the integument. By its *deep surface* with the origins of the compressor nasi and levator anguli oris muscle, and with the infra-orbital artery and nerve.

The LEVATOR ANGULI ORIS *arises* from the canine fossa of the superior maxillary bone, and passes outwards to be *inserted* into the angle of the mouth, intermingling its fibres with those of the orbicularis, zygomatici, and depressor anguli oris.

*Relations*.—By its *superficial surface* with the levator labii superioris proprius, the branches of the infra-orbital artery and nerve, and inferiorly with the integument. By its *deep surface* with the superior maxillary bone and buccinator muscle.

The ZYGOMATIC muscles are two slender fasciculi of fibres which *arise* from the malar bone, and are *inserted* into the angle of the mouth, where they are continuous with the other muscles attached to this part. The zygomaticus minor is situated in front of the major, and is continuous at

its insertion with the levator labii superioris proprius; it is not unfrequently wanting.

*Relations.*—The *zygomaticus major* muscle is in relation by its *superficial surface* with the lower segment of the orbicularis palpebrarum above, and the fat of the cheek and integument for the rest of its extent. By its *deep surface* with the malar bone, the masseter, and buccinator muscle, and the facial vessels. The *zygomaticus minor*, being in front of the major, has no relation with the masseter muscle, while inferiorly it rests upon the levator anguli oris.

The DEPRESSOR LABII SUPERIORIS ALÆQUE NASI (*myrtiformis*) is seen by drawing upwards the upper lip, and raising the mucous membrane. It is a small oval slip of muscle, situated on each side of the frænum, arising from the incisive fossa, and passing upwards to be inserted into the upper lip and into the ala and columna of the nose. This muscle is continuous by its outer border with the edge of the compressor nasi.

*Relations.*—By its *superficial surface* with the mucous membrane of the mouth, the orbicularis oris and levator labii superioris alæque nasi muscle; and by its *deep surface* with the superior maxillary bone.

*Actions.*—The orbicularis oris produces the direct closure of the lips by means of its continuity at the angles of the mouth with the fibres of the buccinator. When acting singly in the forcible closure of the mouth, the integument is thrown into wrinkles in consequence of its firm connexion with the surface of the muscle. The levator labii superioris alæque nasi lifts the upper lip with the ala of the nose, and expands the opening of the nares. The depressor labii superioris alæque nasi is the antagonist to this muscle, drawing the upper lip and ala of the nose downwards, and contracting the opening of the nares. The levator labii superioris proprius is the proper elevator of the upper lip; acting singly it draws the lip a little to one side. The levator anguli oris lifts the angle of the mouth and draws it inwards, while the zygomatic pull it upwards and outwards, as in laughing.

6. *Inferior Labial Group.*—Depressor labii inferioris,  
Depressor anguli oris,  
Levator labii inferioris.

*Dissection.*—To dissect the inferior labial region continue the vertical section from the margin of the lower lip to the point of the chin. Then carry an incision along the margin of the lower jaw to its angle. Dissect off the integument and superficial fascia from the whole of this surface, and the muscles of the inferior labial region will be exposed.

The DEPRESSOR LABII INFERIORIS (*quadratus menti*) arises from the oblique line by the side of the symphysis of the lower jaw, and passing upwards and inwards is inserted into the orbicularis muscle and integument of the lower lip.

*Relations.*—By its *superficial surface* with the platysma myoides, part of the depressor anguli oris, and with the integument of the chin, with which it is closely connected. By the *deep surface* with the levator labii inferioris, the labial glands and mucous membrane of the lower lip, and with the mental nerve and artery.

The DEPRESSOR ANGULI ORIS (*triangularis oris*) is a triangular plane of muscle arising by a broad base from the external oblique ridge of the

lower jaw, and *inserted* by its apex into the angle of the mouth, where it is continuous with the levator anguli oris and zygomaticus major.

*Relations.*—By its *superficial surface* with the integument; and by its *deep surface* with the depressor labii inferioris, the buccinator, and the branches of the mental nerve and artery.

The LEVATOR LABII INFERIORIS (levator menti) is a small conical slip of muscle *arising* from the incisive fossa of the lower jaw, and *inserted* into the integument of the chin. It is in relation with the mucous membrane of the mouth, with its fellow, and with the depressor labii inferioris.

*Actions.*—The depressor labii inferioris draws the lower lip directly downwards, and at the same time a little outwards. The depressor anguli oris, from the radiate direction of its fibres, will pull the angle of the mouth either downwards and inwards, or downwards and outwards, and be expressive of grief; or acting with the levator anguli oris and zygomaticus major, it will draw the angle of the mouth directly backwards. The levator labii inferioris raises and protrudes the integument of the chin.

7. *Maxillary group.*—Masseter,  
Temporalis,  
Buccinator,  
Pterygoideus externus,  
Pterygoideus internus.

*Dissection.*—The masseter has been already exposed by the preceding dissection.

The MASSETER (*μασάωμαι*, to chew,) is a short, thick, and sometimes quadrilateral muscle, composed of two planes of fibres, superficial and deep. The *superficial layer arises* by a strong aponeurosis from the tuberosity of the superior maxillary bone, the lower border of the malar bone and zygoma, and passes backwards to be *inserted* into the ramus and angle of the inferior maxilla. The *deep layer arises* from the posterior part of the zygoma, and passes forwards, to be *inserted* into the upper half of the ramus. This muscle is tendinous and muscular in its structure.

*Relations.*—By its *external surface* with the zygomaticus major and risorius Santorini muscle, the parotid gland and Stenon's duct, the transverse facial artery, the pes anserinus and the integument. By its *internal surface* with the temporal muscle, the buccinator, from which it is separated by a mass of fat, and with the ramus of the lower jaw. By its *posterior border* with the parotid gland; and by the *anterior border* with the facial artery and vein.

*Dissection.*—Make an incision along the upper border of the zygoma, for the purpose of separating the temporal fascia from its attachment. Then saw through the zygomatic process of the malar bone, and through the root of the zygoma, near to the meatus auditorius. Draw down the zygoma, and with it the origin of the masseter, and dissect the latter muscle away from the ramus and angle of the inferior maxilla. Now remove the temporal fascia from the rest of its attachment, and the whole of the temporal muscle will be exposed.

The TEMPORAL is a broad and radiating muscle occupying a considerable extent of the side of the head and filling the temporal fossa. It is covered in by a very dense fascia (temporal fascia) which is attached along



the temporal ridge on the side of the skull, extending from the external angular process of the frontal bone to the mastoid portion of the temporal; inferiorly, it is connected to the upper border of the zygoma. The muscle *arises* by tendinous fibres from the whole length of the temporal ridge, and by muscular fibres from the temporal fascia and entire surface of the temporal fossa. Its fibres converge to a strong and narrow tendon, which is *inserted* into the apex of the coronoid process, and for some way down upon its inner surface.

*Relations.* — By its *external surface* with the temporal fascia, which separates it from the attollens and attrahens aurem muscle, the temporal vessels and nerves; and with the zygoma and masseter. By its *internal surface* with the bones forming the temporal fossa, the external pterygoid muscle, a part of the buccinator, and the internal maxillary artery with its deep temporal branches.

By sawing through the coronoid process near to its base, and pulling it upwards, together with the temporal muscle, which may be dissected from the fossa, we obtain a view of the entire extent of the buccinator and of the external pterygoid muscle.

The BUCCINATOR (*buccina*, a trumpet), the trumpeter's muscle, *arises* from the alveolar process of the superior maxillary and from the external oblique line of the inferior maxillary bone, as far forward as the second bicuspid tooth, and from the pterygo-maxillary ligament. This ligament is the raphé of union between the buccinator and superior constrictor muscle, and is attached by one extremity to the hamular process of the internal pterygoid plate, and by the other to the extremity of the molar ridge. The fibres of the muscle converge towards the angle of the mouth where they cross each other, the superior being continuous with the inferior segment of the orbicularis oris, and the inferior with the superior segment. The muscle is invested externally by a thin fascia.

*Relations.* — By its *external surface*, posteriorly with a large and rounded mass of fat, which separates the muscle from the ramus of the lower jaw, the temporal, and the masseter; *anteriorly* with the risorius Santorini, the zygomatici, the levator anguli oris, and the depressor anguli oris. It is also in relation with a part of Stenon's duct, which pierces it opposite the second molar tooth of the upper jaw, with the transverse facial artery, the branches of the facial and buccal nerve, and the facial artery and vein. By its *internal surface* with the buccal glands and mucous membrane of the mouth.

The EXTERNAL PTERYGOID is a short and thick muscle, broader at its origin than at its insertion. It *arises* by two heads, *one* from the pterygoid ridge on the greater ala of the sphenoid; the *other* from the external pterygoid plate and tuberosity of the palate bone. The fibres pass backwards, to be *inserted* into the neck of the lower jaw and the interarticular fibro-cartilage. The internal maxillary artery frequently passes between the two heads of this muscle.

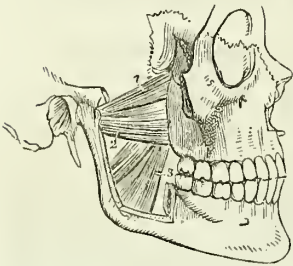
*Relations.* — By its *external surface*, with the ramus of the lower jaw, the temporal muscle, and the internal maxillary artery; by its *internal surface*, with the internal pterygoid muscle, internal lateral ligament of the lower jaw, arteria meningea media, and inferior maxillary nerve; and by its *upper border*, with the muscular branches of the inferior maxillary nerve; the internal maxillary artery passes between the two heads of this muscle, and its lower origin is pierced by the buccal nerve.

The external pterygoid muscle must now be removed, the ramus of the lower jaw sawn through its lower third, and the head of the bone dislocated from its socket and withdrawn, for the purpose of seeing the pterygoideus internus.

The INTERNAL PTERYGOID is a thick quadrangular muscle. It *arises* from the pterygoid fossa, and descends obliquely backwards, to be *inserted* into the ramus and angle of the lower jaw: it resembles the masseter in appearance and direction, and was named by Winslow the internal masseter.

*Relations.*—By its *external surface*, with the external pterygoid, the inferior maxillary nerve and its branches, the internal maxillary artery and branches, the internal lateral ligament, and the ramus of the lower jaw. By its *internal surface*, with the tensor palati, superior constrictor and fascia of the pharynx; and by its posterior border, with the parotid gland.

Fig. 108.\*



*Actions.*—The maxillary muscles are the active agents in mastication, and form an apparatus beautifully fitted for that office. The buccinator circumscribes the cavity of the mouth, and with the aid of the tongue, keeps the food under the immediate pressure of the teeth. By means of its connexion with the superior constrictor, it shortens the cavity of the pharynx from before backwards, and becomes an important auxiliary in deglutition. The temporal, the masseter, and the internal pterygoid, are the bruising muscles, drawing the lower jaw against the upper with great

force. The two latter, by the obliquity of their direction, assist the external pterygoid in grinding the food, by carrying the lower jaw forward upon the upper; the jaw being brought back again by the deep portion of the masseter and posterior fibres of the temporal. The whole of these muscles, acting in succession, produce a rotatory movement of the teeth upon each other, which, with the direct action of the lower jaw against the upper, effects the proper mastication of the food.

8. *Auricular Group.*—Attollens aurem,  
Attrahens aurem,  
Retrahens aurem.

*Dissection.*—The three small muscles of the ear may be exposed by removing a square of integument from around the auricula. This operation must be performed with care, otherwise the muscles, which are extremely thin, will be raised with the superficial fascia. They are best dissected by commencing with their tendons, and thence proceeding in the course of their radiating fibres.

> The ATTOLLENS AUREM (superior auris), the largest of the three, is a thin triangular plane of muscular fibres *arising* from the edge of the aponeurosis of the occipito-frontalis, and *inserted* into the upper part of the concha.

It is *in relation* by its external surface with the integument, and by the internal with the temporal aponeurosis.

\* The two pterygoid muscles. The zygomatic arch and the greater part of the ramus of the lower jaw have been removed, in order to bring these muscles into view. 1. The spheroid origin of the external pterygoid muscle. 2. Its pterygoid origin. 3. The internal pterygoid muscle.

7 The *ATTRAHENS AUREM* (anterior auris), also triangular, *arises* from the edge of the aponeurosis of the occipito-frontalis, and is *inserted* into the anterior part of the helix, covering in the anterior and posterior temporal arteries.

It is *in relation* by its external surface with the integument; and by the internal with the temporal aponeurosis and with the temporal artery and veins.

> The *RETRAHENS AUREM* (posterior auris), *arises* by three or four muscular slips from the mastoid process. They are *inserted* into the posterior surface of the concha.

It is *in relation* by its external surface with the integument, and by its internal surface with the mastoid portion of the temporal bone.

*Actions.*—The muscles of the auricular region possess but little action in man; they are the analogues of important muscles in brutes. Their use is sufficiently explained in their names.

## MUSCLES OF THE NECK.

The muscles of the neck may be arranged into eight groups corresponding with the natural divisions of the region; they are the—

1. Superficial group.
2. Depressors of the os hyoides and larynx.
3. Elevators of the os hyoides and larynx.
4. Lingual group.
5. Pharyngeal group.
6. Soft palate group.
7. Prævertebral group.
8. Proper muscles of the larynx.

And each of these groups consist of the following muscles:— *viz.*

- |                                                                                                                                                             |                                                                                                                                                                   |
|-------------------------------------------------------------------------------------------------------------------------------------------------------------|-------------------------------------------------------------------------------------------------------------------------------------------------------------------|
| <p>1. <i>Superficial Group.</i><br/>Platysma-myoides,<br/>Sterno-cleido-mastoideus.</p>                                                                     | <p>Stylo-glossus,<br/>Palato-glossus.</p>                                                                                                                         |
| <p>2. <i>Depressors of the os hyoides and larynx.</i><br/>Sterno-hyoideus,<br/>Sterno-thyroideus,<br/>Thyro-hyoideus,<br/>Omo-hyoideus.</p>                 | <p>5. <i>Muscles of the Pharynx.</i><br/>Constrictor inferior,<br/>Constrictor medius,<br/>Constrictor superior,<br/>Stylo-pharyngeus,<br/>Palato-pharyngeus.</p> |
| <p>3. <i>Elevators of the os hyoides and larynx.</i><br/>Digastricus,<br/>Stylo-hyoideus,<br/>Mylo-hyoideus,<br/>Genio-hyoideus,<br/>Genio-hyo-glossus.</p> | <p>6. <i>Muscles of the soft Palate.</i><br/>Levator palati,<br/>Tensor palati,<br/>Azygos uvulæ,<br/>Palato-glossus,<br/>Palato-pharyngeus.</p>                  |
| <p>4. <i>Muscles of the Tongue.</i><br/>Genio-hyo-glossus,<br/>Hyo-glossus,<br/>Lingualis,</p>                                                              | <p>7. <i>Prævertebral Group.</i><br/>Rectus anticus major,<br/>Rectus anticus minor,<br/>Scalenus anticus,<br/>Scalenus posticus,<br/>Longus colli.</p>           |

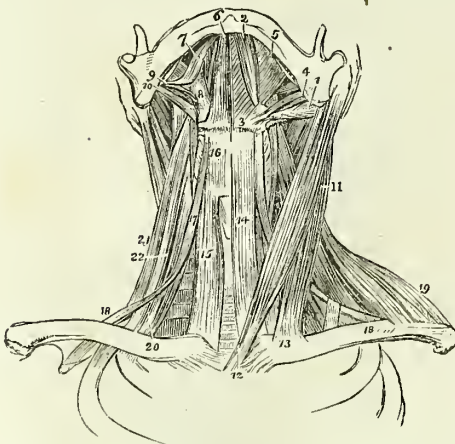
8. *Muscles of the Larynx.*  
 Crico-thyroideus,  
 Crico-arytænoideus, posticus,

Crico-arytænoideus, lateralis,  
 Thyro-arytænoideus,  
 Arytænoideus.

*Dissection.*—The dissection of the neck should be commenced by making an incision along the middle line of its fore part from the chin to the sternum, and bounding it superiorly and inferiorly by two transverse incisions; the superior one being carried along the margin of the lower jaw, and across the mastoid process to the tubercle on the occipital bone, the inferior one along the clavicle to the acromion process. The square flap of integument thus included should be turned back from the entire side of the neck, which brings into view the superficial fascia, and on the removal of a thin layer of superficial fascia the platysma myoides will be exposed.

The PLATYSMA MYOIDES (πλατύς, μῦς εἶδος, broad muscle-like lamella), is a thin plane of muscular fibres, situated between the two layers of the superficial cervical fascia; it *arises* from the integument over the pectoralis major and deltoid muscles, and passes obliquely upwards and inwards along the side of the neck to be *inserted* into the side of the chin, oblique line of the lower jaw, the angle of the mouth, and into the cellular tissue of the face. The most anterior fibres are continuous beneath the chin, with the muscle of the opposite side; the next interlace with the depressor anguli oris, and depressor labii inferioris, and the most posterior fibres are disposed in a transverse direction across the side of the face, arising in the cellular tissue covering the parotid gland, and inserted into the angle of the mouth, constituting the risorius Santorini. The entire muscle is analogous to the cutaneous muscle of brutes, the panniculus carnosus.

Fig. 109.\*



*Relations.*—By its *external surface* with the integument, with which it is closely adherent below, but loosely above. By its *internal surface*, below the clavicle, with the pectoralis major and deltoid; in the neck, with the external jugular vein and deep cervical fascia; on the face, with the parotid gland, the masseter, the facial artery and vein, the buccinator, the depressor anguli oris, and the depressor labii inferioris.

On raising the platysma throughout its whole extent, the sterno-mastoid is brought into view.

The STERNO-CLEIDO-MASTOID is the large oblique muscle of

\*The muscles of the anterior aspect of the neck; on the left side the superficial muscles are seen, and on the right the deep. 1. The posterior belly of the digastricus muscle. 2. Its anterior belly. The aponeurotic pulley, through which its tendon is seen passing, is attached to the body of the os hyoides. 3, 4. The stylo-hyoideus muscle, transfixed by the posterior belly of the digastricus. 5. The mylo-hyoideus. 6. The

the neck, and is situated between two layers of the deep cervical fascia. It *arises*, as implied in its name, from the sternum and clavicle (*κλειδίον*), and passes obliquely upwards and backwards to be *inserted* into the mastoid process and into the superior curved line of the occipital bone. The sternal portion arises by a rounded tendon, increases in breadth as it ascends, and spreads out to a considerable extent at its insertion. The clavicular portion is broad and fleshy, and separate from the sternal portion below, but becomes gradually blended with its posterior surface as it ascends.

*Relations.*—By its *superficial surface* with the integument, the platysma myoides, the external jugular vein, superficial branches of the anterior cervical plexus of nerves, and the anterior layer of the deep cervical fascia. By its *deep surface* with the deep layer of the cervical fascia; with the sterno-clavicular articulation, the sterno-hyoid, sterno-thyroid, omo-hyoid, scæleni, levator anguli scapulæ, splenii, and the posterior belly of the digastric muscle; with the phrenic nerve, and the posterior, and supra-scapular artery; with the deep lymphatic glands, the sheath of the common carotid and internal jugular vein, the descendens noni nerve, the external carotid artery and its posterior branches, the commencement of the internal carotid artery; with the cervical plexus of nerves, the pneumogastric, the spinal accessory, the hypoglossal, the sympathetic and the facial nerve, and with the parotid gland. It is pierced on this aspect by the spinal accessory nerve and by the branches of the mastoid artery. The *anterior border* of the muscle is the posterior boundary of the great anterior triangle, the other two boundaries being the middle line of the neck in front, and the lower border of the jaw above. It is the guide to the operations for the ligature of the common carotid artery and arteria innominata, and for œsophagotomy. The *posterior border* is the anterior boundary of the great posterior triangle; the other two boundaries being the anterior border of the trapezius behind, and the clavicle below.

*Actions.*—The platysma produces a muscular traction on the integument of the neck, which prevents it from falling so flaccid in old persons as would be the case if the extension of the skin were the mere result of elasticity. It draws also upon the angle of the mouth, and is one of the depressors of the lower jaw. The transverse fibres draw the angle of the mouth outwards and slightly upwards. The sterno-mastoid muscles are the great anterior muscles of connexion between the thorax and the head. Both muscles acting together bow the head directly forwards. The clavicular portions, acting more forcibly than the sternal, give stability and steadiness to the head in supporting great weights. Either muscle acting singly would draw the head towards the shoulder of the same side, and carry the face towards the opposite side.

*Second Group.—Depressors of the Os Hyoides and Larynx.*

Sterno-hyoid,  
Sterno-thyroid,

Thyro-hyoid,  
Omo-hyoid.

genio-hyoideus. 7. The tongue. 8. The hyo-glossus. 9. The stylo-glossus. 10. The stylo-pharyngeus. 11. The sterno-mastoid muscle. 12. Its sternal origin. 13. Its clavicular origin. 14. The sterno-hyoid. 15. The sterno-thyroid of the right side. 16. The thyro-hyoid. 17. The hyoid portion of the omo-hyoid. 18, 18. Its scapular portion, on the left side, the tendon of the muscle is seen to be bound down by a portion of the deep cervical fascia. 19. The clavicular portion of the trapezius. 20. The scalenus anticus of the right side. 21. The scalenus posticus.

*Dissection.*—These muscles are brought into view by removing the deep fascia from off the front of the neck between the two sterno-mastoid muscles. The omo-hyoid to be seen in its whole extent requires that the sterno-mastoid muscle should be divided from its origin and turned aside.

The STERNO-HYOIDEUS is a narrow riband-like muscle, *arising* from the posterior surface of the first bone of the sternum and inner extremity of the clavicle. It is *inserted* into the lower border and posterior surface of the body of the os hyoides. The sterno-hyoidei are separated by a considerable interval at the root of the neck, but approach each other as they ascend: they are frequently traversed by a tendinous intersection.

*Relations.*—By its *external surface* with the deep cervical fascia, the platysma myoides and sterno-mastoid muscle; by its *internal surface* with the sterno-thyroid, and thyro-hyoid muscle, and the superior thyroid artery.

The STERNO-THYROIDEUS, broader than the preceding beneath which it lies, *arises* from the posterior surface of the upper bone of the sternum, and from the cartilage of the first rib; it is *inserted* into the oblique line on the great ala of the thyroid cartilage. The inner borders of these muscles lie in contact along the middle line, and they are generally marked by a tendinous intersection at their lower part.

*Relations.*—By its *external surface* with the sterno-hyoid, omo-hyoid, and sterno-mastoid muscle; by its *internal surface*, with the trachea and inferior thyroid veins, with the thyroid gland, the lower part of the larynx, the sheath of the common carotid artery and internal jugular vein, with the subclavian vein and vena innominata, and on the right side with the arteria innominata. The middle thyroid vein lies along its inner border.

The THYRO-HYOIDEUS is the continuation upwards of the sterno-thyroid muscle. It *arises* from the oblique line on the thyroid cartilage, and is *inserted* into the lower border of the body and great cornu of the os hyoides.

*Relations.*—By its *external surface* with the sterno-hyoid and omo-hyoid muscle; by its *internal surface* with the great ala of the thyroid cartilage, the thyro-hyoidean membrane, and the superior laryngeal artery and nerve.

The OMO-HYOIDEUS (ὤμος, shoulder) is a double-bellied muscle passing obliquely across the neck from the scapula to the os hyoides: it forms an obtuse angle behind the sterno-mastoid muscle, and is retained in that position by means of a process of the deep cervical fascia which is connected to the inner border of its tendon. It *arises* from the upper border of the scapula, and from the transverse ligament of the supra-scapular notch, and is *inserted* into the lower border of the body of the os hyoides.

*Relations.*—By its *superficial surface* with the trapezius, the subclavius and clavicle, the deep cervical fascia and platysma myoides, the sterno-mastoid, and the integument. By its *deep surface* with the brachial plexus, the scaleni muscles, the phrenic nerve, the sheath of the common carotid artery and jugular vein, the descendens noni nerve, the sterno-thyroid, and thyro-hyoid muscle, and the sterno-hyoid at its insertion. The scapular portion of the muscle divides the great posterior triangle into a superior or *occipital triangle*; and an inferior or *subclavian triangle*, which contains the subclavian artery and brachial plexus of nerves; the other two boundaries of the latter being the sterno-mastoid in front and the clavicle below. The hyoid portion of the muscle divides the great anterior

triangle into an *inferior carotid triangle* situated below the muscle, and into a superior triangle which lies above the muscle and is again subdivided by the digastricus into the *submaxillary triangle* and the *superior carotid triangle*. The other two boundaries of the inferior carotid triangle, are the middle line of the neck in front and the anterior border of the sterno-mastoid behind. The other boundaries of the superior carotid triangle are the posterior belly of the digastricus muscle above and the anterior border of the sterno-mastoid behind.

*Actions.*—The four muscles of this group are the depressors of the os hyoides and larynx. The three former drawing these parts downwards in the middle line, and the two omo-hyoidei regulating their traction to the one or other side of the neck, according to the position of the head. The omo-hyoid muscles by means of their connexion with the cervical fascia are rendered tensors of that portion of the deep cervical fascia which covers in the lower part of the neck, between the two sterno-mastoid muscles.

*Third Group.—Elevators of the Os Hyoides.*

|              |                    |
|--------------|--------------------|
| Digastricus, | Genio-hyoid,       |
| Stylo-hyoid, | Genio-hyo-glossus. |
| Mylo-hyoid,  |                    |

*Dissection.*—These are best dissected by placing a high block beneath the neck, and throwing the head backwards. The integument has been already dissected away, and the removal of the cellular tissue and fat brings them clearly into view.

The DIGASTRICUS (δῖς, twice, γαστήρ, belly) is a small muscle situated immediately beneath the side of the body of the lower jaw; it is fleshy at each extremity, and tendinous in the middle. > It *arises* from the digastric fossa, upon the inner side of the mastoid process of the temporal bone, and is *inserted* into a depression on the inner side of the lower jaw, close to the symphysis. The middle tendon is held in connexion with the body of the os hyoides by an aponeurotic loop, through which it plays as through a pulley; the loop being lubricated by a synovial membrane. A thin layer of aponeurosis is given off from the tendon of the digastricus at each side, which is connected with the body of the os hyoides, and forms a strong plane of fascia between the anterior portions of the two muscles. This fascia is called the *supra-hyoidean*.

*Relations.*—By its *superficial surface* with the platysma myoides, the sterno-mastoid, the anterior fasciculus of the stylo-hyoid muscle, the parotid gland, and submaxillary gland. By its *deep surface* with the styloid muscles, the hyo-glossus, the mylo-hyoid muscle, the external carotid artery, the lingual and the facial arteries, the internal carotid artery, the jugular vein, and the hypoglossal nerve. The digastric muscle forms the two inferior boundaries of the submaxillary triangle, the superior boundary being the side of the body of the lower jaw. In the posterior half of the submaxillary triangle are situated the submaxillary gland and the facial artery.

The STYLO-HYOIDEUS is a small and slender muscle situated in immediate relation with the posterior belly of the digastricus muscle, being pierced by its tendon. It *arises* from the middle of the styloid process, and is *inserted* into the body of the os hyoides near the middle line.

*Relations.*—By its *superficial surface* with the posterior belly of the digastricus, the parotid gland and submaxillary gland; its deep relations are similar to those of the posterior belly of the digastricus.

The digastricus and stylo-hyoideus must be removed from their connexion with the lower jaw and os hyoides, and turned aside in order to see the next muscle.

The MYLO-HYOIDEUS ( $\mu\upsilon\lambda\eta$ , mola, *i. e.* attached to the molar ridge of the lower jaw) is a broad triangular plane of muscular fibres, forming, with its fellow of the opposite side, the inferior wall or floor of the mouth. It *arises* from the molar ridge on the lower jaw, and proceeds obliquely inwards to be *inserted* into the *raphé* of the two muscles and into the body of the os hyoides; the *raphé* is sometimes deficient at its anterior part.

*Relations.*—By its *superficial*, or *inferior surface*, with the platysma myoides, the digastricus, the supra-hyoidean fascia, the submaxillary gland and the submental artery. By its *deep* or *superior surface*, with the genio-hyoideus, the genio-hyo-glossus, the stylo-glossus, the gustatory nerve, the hypoglossal nerve, Wharton's duct, the sublingual gland, and the mucous membrane of the floor of the mouth.

After the mylo-hyoideus has been examined, it should be cut away from its origin and insertion, and completely removed. The view of the next muscles would also be greatly improved by dividing the lower jaw on the near side of the symphysis, and drawing it outwards, or by removing it altogether, if the ramus have been already cut across in dissecting the internal pterygoid muscle. The tongue may then be drawn out of the mouth by means of a hook.

The GENIO-HYOIDEUS ( $\gamma\epsilon\nu\epsilon\omicron\nu$ , the chin) *arises* from a small tubercle upon the inner side of the symphysis of the lower jaw, and is *inserted* into the upper part of the body of the os hyoides. It is a short and slender muscle, very closely connected with the border of the following.

*Relations.*—By its *superficial* or *inferior surface*, with the mylo-hyoideus, by the *deep* or *superior surface*, with the lower border of the genio-hyo-glossus.

The GENIO-HYO-GLOSSUS ( $\gamma\lambda\omega\sigma\sigma\alpha$ , the tongue) is a triangular muscle, narrow and pointed at its origin from the lower jaw, broad and fan-shaped at its attachment to the tongue. It *arises* from a tubercle immediately above that of the genio-hyoideus, and spreads out to be *inserted* into the whole length of the tongue, from its base to the apex, and into the body of the os hyoides.

*Relations.*—By its *inner surface* with its fellow of the opposite side. By its *outer surface* with the mylo-hyoideus, the hyo-glossus, the stylo-glossus, lingualis, the sublingual gland, the lingual artery, and the hypoglossal nerve. By its *upper border* with the mucous membrane of the floor of the mouth, in the situation of the frænum linguæ; and by the *lower border* with the genio-hyoideus.

*Actions.*—The whole of this group of muscles acts upon the os hyoides when the lower jaw is closed, and upon the lower jaw when the os hyoides is drawn downwards, and fixed by the depressors of the os hyoides and larynx. The genio-hyo-glossus is, moreover, a muscle of the tongue; its action upon that organ shall be considered with the next group.



*Fourth Group.—Muscles of the Tongue.*

Genio-hyo-glossus,  
Hyo-glossus,  
Lingualis,

Stylo-glossus,  
Palato-glossus.

These are already exposed by the preparation we have just made ; there remains, therefore, only to dissect and examine them.

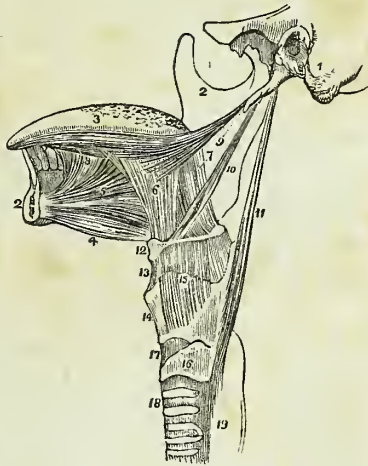
The *Genio-hyo-glossus*, the first of these muscles, has been described with the last group.

The *HYO-GLOSSUS* is a square-shaped plane of muscle, *arising* from the whole length of the great cornu and from the body of the os hyoides, and *inserted* between the stylo-glossus and lingualis into the side of the tongue. The direction of the fibres of that portion of the muscle which arises from the body is obliquely backwards ; and that from the great cornu obliquely forwards ; hence they are described by Albinus as two distinct muscles, under the names of the basio-glossus, and cerato-glossus, to which he added a third fasciculus, arising from the lesser cornu, and spreading along the side of the tongue, the chondro-glossus. The basio-glossus slightly overlaps the cerato-glossus at its upper part, and is separated from it by the transverse portion of the stylo-glossus.

*Relations.*—By its *external surface* with the digastric muscle, the stylo-hyoideus, stylo-glossus, and mylo-hyoideus, with the gustatory nerve, the hypoglossal nerve, Wharton's duct and the sublingual gland. By its *internal surface* with the middle constrictor of the pharynx, the lingualis, the genio-hyo-glossus, the lingual artery, and the glosso-pharyngeal nerve.

The *LINGUALIS*.—The fibres of this muscle may be seen towards the apex of the tongue, issuing from the interval between the hyo-glossus and genio-hyo-glossus ; it is best examined by removing the preceding muscle. It consists of a small fasciculus of fibres, running longitudinally from the base, where it is attached to the os hyoides, to the apex of the tongue. It is in relation by its under surface with the ranine artery.

Fig. 110.\*



\* The styloid muscles and the muscles of the tongue. 1. A portion of the temporal bone of the left side of the skull, including the styloid and mastoid processes, and the meatus auditorius externus. 2, 2. The right side of the lower jaw, divided at its symphysis; the left side having been removed. 3. The tongue. 4. The genio-hyoideus muscle. 5. The genio-hyo-glossus. 6. The hyo-glossus muscle, its basio-glossus portion. 7. Its cerato-glossus portion. 8. The anterior fibres of the lingualis issuing from between the hyo-glossus and genio-hyo-glossus. 9. The stylo-glossus muscle, with a small portion of the stylo-maxillary ligament. 10. The stylo-hyoid. 11. The stylo-pharyngeus muscle. 12. The os hyoides. 13. The thyro-hyoidean membrane. 14. The thyroid cartilage. 15. The thyro-hyoideus muscle arising from the oblique line on the thyroid cartilage. 16. The cricoid cartilage. 17. The crico-thyroid membrane, through which the operation of laryngotomy is performed. 18. The trachea. 19. The commencement of the œsophagus.

The *STYLO-GLOSSUS* arises from the apex of the styloid process, and from the stylo-maxillary ligament; it divides upon the side of the tongue into two portions, one transverse, which passes transversely inwards between the two portions of the hyo-glossus, and is lost among the transverse fibres of the substance of the tongue, and another longitudinal, which spreads out upon the side of the tongue as far as its tip.

*Relations.*—By its *external surface* with the internal pterygoid muscle, the gustatory nerve, the parotid gland, sublingual gland, and the mucous membrane of the floor of the tongue. By its *internal surface* with the tonsil, the superior constrictor muscle of the pharynx, and the hyo-glossus muscle.

The *PALATO-GLOSSUS* passes between the soft palate, and the side of the base of the tongue, forming a projection of the mucous membrane, which is called the anterior pillar of the soft palate. Its fibres are lost superiorly among the muscular fibres of the palato-pharyngeus, and inferiorly among the fibres of the stylo-glossus upon the side of the tongue. This muscle with its fellow constitutes the constrictor isthmi faucium.

*Actions.*—The genio-hyo-glossus muscle effects several movements of the tongue, as might be expected from its extent. When the tongue is steadied and pointed by the other muscles, the posterior fibres of the genio-hyo-glossus would dart it from the mouth, while its anterior fibres would restore it to its original position. The whole length of the muscle acting upon the tongue, would render it concave along the middle line, and form a channel for the current of fluid towards the pharynx, as in sucking. The apex of the tongue is directed to the roof of the mouth, and rendered convex from before backwards by the linguales. The hyo-glossi, by drawing down the sides of the tongue, render it convex along the middle line. It is drawn upwards at its base by the palato-glossi, and backwards or to either side by the stylo-glossi. Thus the whole of the complicated movements of the tongue may be explained, by reasoning upon the direction of the fibres of the muscles, and their probable actions. The palato-glossi muscles, assisted by the uvula, have the power of closing the fauces completely, an action which takes place in deglutition.

*Fifth Group.—Muscles of the Pharynx.*

Constrictor inferior,  
 Constrictor medius,  
 Constrictor superior,  
 Stylo-pharyngeus,  
 Palato-pharyngeus.

*Dissection.*—To dissect the pharynx, the trachea and œsophagus are to be cut through at the lower part of the neck, and drawn upwards by dividing the loose cellular tissue which connects the pharynx to the vertebral column. The saw is then to be applied behind the styloid processes, and the base of the skull sawn through. The vessels and loose structure should be removed from the preparation, and the pharynx stuffed with tow or wool for the purpose of distending it, and rendering the muscle more easy of dissection. The pharynx is invested by a proper pharyngeal fascia.

The *CONSTRICTOR INFERIOR*, the thickest of the three muscles of this class, arises from the upper rings of the trachea, the cricoid cartilage, and the oblique line of the thyroid. Its fibres spread out and are inserted into

the fibrous *raphé* of the middle of the pharynx, the inferior fibres being almost horizontal, and the superior oblique, and overlapping the middle constrictor.

*Relations.*—By its *external surface* with the anterior surface of the vertebral column, the longus colli, the sheath of the common carotid artery, the sterno-thyroid muscle, the thyroid gland, and some lymphatic glands. By its *internal surface* with the middle constrictor, the stylo-pharyngeus, the palato-pharyngeus, and the mucous membrane of the pharynx. By its *lower border*, near the cricoid cartilage, it is in relation with the recurrent nerve; and by the *upper border* with the superior laryngeal nerve. The fibres of origin of this muscle are blended with those of the sterno-hyoid, sterno-thyroid, and crico-thyroid, and it frequently forms a tendinous arch across the latter.

This muscle must be removed before the next can be examined.

The CONSTRUCTOR MEDIUS *arises* from the great cornu of the os hyoides, from the lesser cornu, and from the stylo-hyoidean ligament. It radiates from its origin upon the side of the pharynx, the lower fibres descending and being overlapped by the constrictor inferior, and the upper fibres ascending so as to cover in the constrictor superior. It is *inserted* into the *raphé* and by a fibrous aponeurosis into the basilar process of the occipital bone.

*Relations.*—By its *external surface* with the vertebral column, the longus colli, rectus anticus major, the carotid vessels, inferior constrictor, hyoglossus muscle, lingual artery, pharyngeal plexus of nerves, and some lymphatic glands. By its *internal surface*, with the superior constrictor, stylo-pharyngeus, palato-pharyngeus, and mucous membrane of the pharynx.

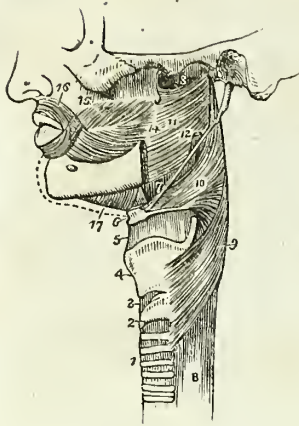
The upper portion of this muscle must be turned down, to bring the whole of the superior constrictor into view; in so doing, the stylo-pharyngeus muscle will be seen passing beneath its upper border.

The CONSTRUCTOR SUPERIOR is a thin and quadrilateral plane of muscular fibres *arising* from the extremity of the molar ridge of the lower jaw, from the pterygo-maxillary ligament, and from the lower half of the internal pterygoid plate, and *inserted* into the *raphé* and basilar process of the occipital bone. Its superior fibres are arched and leave an interval between its upper border and the basilar process, which is deficient in muscular fibres, and it is overlapped inferiorly by the middle constrictor. Between the side of the pharynx and the ramus of the lower jaw is a triangular interval, the *maxillo-pharyngeal space*, which is bounded on the *inner* side by the superior constrictor muscle; on the *outer* side by the internal pterygoid muscle; and *behind* by the rectus anticus major and vertebral column. In this space are situated the internal carotid artery, the internal jugular vein, and the glosso-pharyngeal, pneumogastric, spinal accessory, and hypo-glossal nerve.

*Relations.*—By its *external surface* with the vertebral column and its muscles, behind; with the vessels and nerves contained in the *maxillo-pharyngeal space* laterally, the middle constrictor, stylo-pharyngeus, and tensor palati muscle. By its *internal surface* with the levator palati, palato-pharyngeus, tonsil, and mucous membrane of the pharynx, the pharyngeal fascia being interposed.

The STYLO-PHARYNGEUS is a long and slender muscle *arising* from the inner side of the base of the styloid process; it descends between the

Fig. 111.\*



superior and middle constrictor muscles, and spreads out beneath the mucous membrane of the pharynx, its inferior fibres being *inserted* into the posterior border of the thyroid cartilage.

*Relations.*—By its *external surface* with the stylo-glossus muscle, external carotid artery, parotid gland, and the middle constrictor. By its *internal surface* with the internal carotid artery, internal jugular vein, superior constrictor, palato-pharyngeus, and mucous membrane. Along its lower border is seen the glosso-pharyngeal nerve which crosses it, opposite the root of the tongue, to pass between the superior and middle constrictor and behind the hyo-glossus.

The *palato-pharyngeus* is described with the muscles of the soft palate. It *arises* from the soft palate, and is *inserted* into the inner surface of the pharynx, and posterior border of the thyroid cartilage.

*Actions.*—The three constrictor muscles are important agents in deglutition; they contract upon the morsel of food as soon as it is received by the pharynx, and convey it downwards into the œsophagus. The stylo-pharyngei draw the pharynx upwards and widen it laterally. The palato-pharyngei also draw it upwards, and with the aid of the uvula close the opening of the fauces.

#### *Sixth Group.—Muscles of the Soft Palate.*

Levator palati,  
Tensor palati,  
Azygos uvulæ,  
Palato-glossus,  
Palato-pharyngeus.

*Dissection.*—To examine these muscles, the pharynx must be opened from behind, and the mucous membrane carefully removed from off the posterior surface of the soft palate.

The LEVATOR PALATI, a moderately thick muscle, *arises* from the extremity of the petrous bone and from the posterior and inferior aspect of the Eustachian tube, and passing down by the side of the posterior nares spreads out in the structure of the soft palate as far as the middle line.

*Relations.*—*Externally* with the tensor palati and superior constrictor muscle; *internally* and *posteriorly* with the mucous membrane of the pharynx and soft palate; and by its lower border with the palato-pharyngeus.

\* A side view of the muscles of the pharynx. 1. The trachea. 2. The cricoid cartilage. 3. The crico-thyroid membrane. 4. The thyroid cartilage. 5. The thyro-hyoidean membrane. 6. The os hyoides. 7. The stylo-hyoidean ligament. 8. The œsophagus. 9. The inferior constrictor. 10. The middle constrictor. 11. The superior constrictor. 12. The stylo-pharyngeus muscle passing down between the superior and middle constrictor. 13. The upper concave border of the superior constrictor; at this point the muscular fibres of the pharynx are deficient. 14. The pterygo-maxillary ligament. 15. The buccinator muscle. 16. The orbicularis oris. 17. The mylo-hyoideus.

This muscle must be turned down from its origin on one side, and removed, and the superior constrictor dissected away from its pterygoid origin, to bring the next muscle into view.

The **TENSOR PALATI** (circumflexus) is a slender and flattened muscle; it *arises* from the scaphoid fossa at the base of the internal pterygoid plate and from the anterior aspect of the Eustachian tube. It descends to the hamular process, around which it turns and expands into a tendinous aponeurosis, which is *inserted* into the transverse ridge on the horizontal portion of the palate bone, and into the *raphe*.

*Relations*.—By its *external surface* with the internal pterygoid muscle; by its *internal surface* with the levator palati, internal pterygoid plate, and superior constrictor. In the soft palate, its tendinous expansion is placed in front of the other muscles and in contact with the mucous membrane.

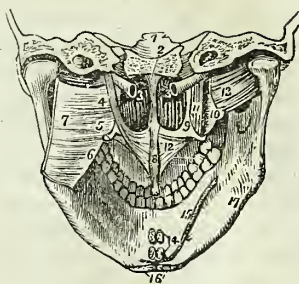
The **AZYGOS UVULÆ** is not a single muscle, as might be inferred from its name, but a pair of small muscles placed side by side in the middle line of the soft palate. They *arise* from the spine of the palate bone, and are *inserted* into the uvula. By their anterior surface they are connected with the tendinous expansion of the levatores palati, and by the posterior with the mucous membrane.

The two next muscles are brought into view throughout the whole of their extent, by raising the mucous membrane from off the pillars of the soft palate at each side.

The **PALATO-GLOSSUS** (constrictor isthmi faucium) is a small fasciculus of fibres that *arises* in the soft palate, and descends to be *inserted* into the side of the tongue. It is the projection of this small muscle, covered by mucous membrane, that forms the anterior pillar of the soft palate. It has been named constrictor isthmi faucium from a function it performs in common with the palato-pharyngeus, viz. of constricting the opening of the fauces.

The **PALATO-PHARYNGEUS** forms the posterior pillar of the fauces; it *arises* by an expanded fasciculus from the lower part of the soft palate, where its fibres are continuous with those of the muscle of the opposite

Fig. 112.\*



\* The muscles of the soft palate. 1. A transverse section through the middle of the base of the skull, dividing the basilar process of the occipital bone in the middle line, and the petrous portion of the temporal bone at each side. 2. The vomer covered by mucous membrane and separating the two posterior nares. 3, 3. The Eustachian tubes. 4. The levator palati muscle of the left side; the right has been removed. 5. The hamular process of the internal pterygoid plate of the left side, around which the aponeurosis of the tensor palati is seen turning. 6. The pterygo-maxillary ligament. 7. The superior constrictor muscle of the left side, turned aside. 8. The azygos uvulæ muscle. 9. The internal pterygoid plate. 10. The external pterygoid plate. 11. The tensor palati muscle. 12. Its aponeurosis expanding in the structure of the soft palate. 13. The external pterygoid muscle. 14. The attachments of two pairs of muscles cut short; the superior pair belong to the genio-hyo-glossi muscles; the inferior pair to the genio-hyoidei. 15. The attachment of the mylo-hyoideus of one side and part of the opposite. 16. The anterior attachments of the digastric muscles. 17. The depression on the lower jaw corresponding with the submaxillary gland. The depression above the mylo-hyoideus, on which the number 15 rests, corresponds with the situation of the sublingual gland.

side ; and is *inserted* into the posterior border of the thyroid cartilage. This muscle is broad above where it forms the whole thickness of the lower half of the soft palate, narrow in the posterior pillar, and again broad and thin in the pharynx where it spreads out previously to its insertion.

*Relations.*—In the soft palate it is in relation with the mucous membrane both by its *anterior* and *posterior* surface ; *above*, with the muscular layer formed by the levator palati, and *below* with the mucous glands situated along the margin of the arch of the palate. In the posterior pillar of the palate, it is surrounded for two-thirds of its extent by mucous membrane. In the pharynx, it is in relation by its *outer surface* with the superior and middle constrictor muscles, and by its *inner surface* with the mucous membrane of the pharynx, the pharyngeal fascia being interposed.

*Actions.*—The azygos uvulæ shortens the uvula. The levator palati raises the soft palate, while the tensor spreads it out laterally so as to form a septum between the pharynx and posterior nares. Taking its fixed point from below, the tensor palati will dilate the Eustachian tube. The palatoglossus and pharyngeus constrict the opening of the fauces, and by drawing down the soft palate they serve to press the mass of food from the dorsum of the tongue into the pharynx.

*Seventh Group.—Prævertebral Muscles.*

Rectus anticus major,  
Rectus anticus minor,  
Scalenus anticus,  
Scalenus posticus,  
Longus colli.

*Dissection.*—These muscles have already been exposed by the removal of the face from the anterior aspect of the vertebral column ; all that is further needed is the removal of the fascia by which they are invested.

The RECTUS ANTICUS MAJOR, broad and thick above, and narrow and pointed below, *arises* from the anterior tubercles of the transverse processes of the third, fourth, fifth, and sixth cervical vertebræ, and is *inserted* into the basilar process of the occipital bone.

*Relations.*—By its *anterior surface* with the pharynx, the internal carotid artery, internal jugular vein, superior cervical ganglion, sympathetic nerve, pneumogastric, and spinal accessory nerve. By its *posterior surface* with the longus colli, rectus anticus minor, and superior cervical vertebræ.

The RECTUS ANTICUS MINOR *arises* from the anterior border of the lateral mass of the atlas, and is *inserted* into the basilar process ; its fibres being directed obliquely upwards and inwards.

*Relations.*—By its *anterior surface* with the rectus anticus major, and externally with the superior cervical ganglion of the sympathetic. By its *posterior surface* with the articulation of the condyle of the occipital bone with the atlas, and with the anterior occipito-atloid ligament.

The SCALENUS ANTICUS is a triangular muscle, as its name implies, situated at the root of the neck and appearing like a continuation of the rectus anticus major ; it *arises* from the anterior tubercles of the transverse processes of the third, fourth, fifth, and sixth cervical vertebræ, and is *inserted* into the tubercle upon the inner border of the first rib.

*Relations.*—By its *anterior surface* with the sterno-mastoid and omohyoid muscle, with the cervicalis superficialis and posterior scapular artery,

with the phrenic nerve, and with the subclavian vein, by which it is separated from the subclavius muscle and clavicle. By its *posterior surface* with the nerves which go to form the brachial plexus, and below with the subclavian artery. By its *inner side* it is separated from the longus colli by the vertebral artery. Its relations with the subclavian artery and vein are very important, the vein being before and the artery behind the muscle.\*

The **SCALENUS POSTICUS** arises from the posterior tubercles of all the cervical vertebræ excepting the first. It is inserted by two fleshy fasciculi into the first and second ribs. The anterior (scalenus medius) of the two fasciculi is large, and occupies all the surface of the first rib between the groove for the subclavian artery and the tuberosity. The posterior (scalenus posticus) is small, and is attached to the second rib. Albinus and Soemmering make five scaleni.

*Relations.* — By its *anterior surface* with the brachial plexus and subclavian artery; *posteriorly* with the levator anguli scapulæ, cervicalis ascendens, transversalis colli, and sacro-lumbalis; *internally* with the first intercostal muscle, the first rib, the intertransverse muscles, and cervical vertebræ; and *externally* with the sterno-mastoid, omohyoid, supra-scapular and posterior scapular arteries.

The **LONGUS COLLI** is a long and flat muscle, consisting of two portions. The *upper* arises from the anterior tubercle of the atlas, and is inserted into the transverse processes of the third, fourth, and fifth cervical vertebræ. The *lower* portion arises from the bodies of the second and third, and transverse processes of the fourth and fifth, and passes down the neck, to be inserted into the bodies of the three lower cervical and three upper dorsal vertebræ. We should thus arrange these attachments in a tabular form :—

*Origin.*

*Insertion.*

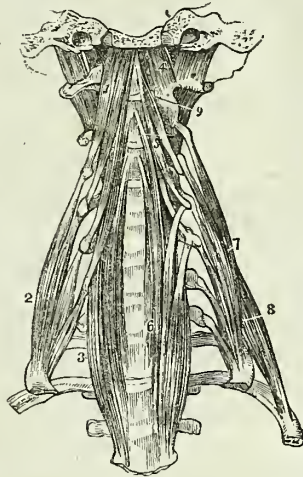
|                |                    |                                          |
|----------------|--------------------|------------------------------------------|
| Upper portion. | } Atlas - - -      | } 3d, 4th, and 5th transverse processes. |
| Lower portion. |                    |                                          |
|                | } 2d and 3d bodies | } 3 lower cervical vertebræ, bodies.     |
|                |                    |                                          |

In general terms, the muscle is attached to the bodies and transverse

\* In a subject dissected in the school of the Middlesex hospital during the winter of 1841 by Mr. Joseph Rogers, the subclavian artery of the left side was placed with the vein in front of the scalenus anticus muscle.

† The prævertebral group of muscles of the neck. 1. The rectus anticus major muscle. 2. The scalenus anticus. 3. The lower part of the longus colli of the right side; it is concealed superiorly by the rectus anticus major. 4. The rectus anticus minor. 5. The upper portion of the longus colli muscle. 6. Its lower portion; the figure rests upon the seventh cervical vertebra. 7. The scalenus posticus. 8. The rectus lateralis of the left side. 9. One of the intertransversales muscles.

Fig. 113.†



processes of the five superior cervical vertebræ above, and to the bodies of the last three cervical and first three dorsal below.

*Relations.*—By its *anterior surface*, with the pharynx, œsophagus, the sheath of the common carotid, internal jugular vein and pneumogastric nerve, the sympathetic nerve, inferior laryngeal nerve, and inferior thyroid artery. By its *posterior surface* it rests upon the cervical and upper dorsal vertebræ.

*Actions.*—The rectus anticus major and minor preserve the equilibrium of the head upon the atlas; and, acting conjointly with the longus colli, flex and rotate the head and the cervical portion of the vertebral column. The scaleni muscles, taking their fixed point from below, are flexors of the vertebral column; and, from above, elevators of the ribs, and therefore inspiratory muscles.

#### *Eighth Group.—Muscles of the Larynx.*

These muscles are described with the anatomy of the larynx, in Chapter XI.

#### MUSCLES OF THE TRUNK.

The muscles of the trunk may be subdivided into four natural groups; viz.

- |                           |                             |
|---------------------------|-----------------------------|
| 1. Muscles of the back.   | 3. Muscles of the abdomen.  |
| 2. Muscles of the thorax. | 4. Muscles of the perineum. |

1. *Muscles of the Back.*—The *region of the back*, in consequence of its extent, is common to the neck, the upper extremities, and the abdomen. The muscles of which it is composed are numerous, and may be arranged into six layers.

|                                                                                                    |                                                                                                                   |
|----------------------------------------------------------------------------------------------------|-------------------------------------------------------------------------------------------------------------------|
| <i>First Layer.</i>                                                                                | (Cervical Group.)                                                                                                 |
| Trapezius,<br>Latissimus dorsi.                                                                    | Cervicalis ascendens,<br>Transversalis colli,<br>Trachelo-mastoideus,<br>Complexus.                               |
| <i>Second Layer.</i>                                                                               | <i>Fifth Layer.</i>                                                                                               |
| Levator anguli scapulæ,<br>Rhomboideus minor,<br>Rhomboideus major.                                | (Dorsal Group.)                                                                                                   |
|                                                                                                    | Semi-spinalis dorsi,<br>Semi-spinalis colli.                                                                      |
| <i>Third Layer.</i>                                                                                | (Cervical Group.)                                                                                                 |
| Serratus posticus superior,<br>Serratus posticus inferior,<br>Splenius capitis,<br>Splenius colli. | Rectus posticus major,<br>Rectus posticus minor,<br>Rectus lateralis,<br>Obliquus inferior,<br>Obliquus superior. |
| <i>Fourth Layer.</i>                                                                               | <i>Sixth Layer.</i>                                                                                               |
| (Dorsal Group.)                                                                                    | Multifidus spinæ,<br>Levatores costarum,<br>Supra-spinales,<br>Inter-spinales,<br>Inter-transversales.            |
| Sacro-lumbalis,<br>Longissimus dorsi,<br>Spinalis dorsi.                                           |                                                                                                                   |



*First Layer.*

*Dissection.*—The muscles of this layer are to be dissected by making an incision along the middle line of the back, from the tubercle on the occipital bone to the coccyx. From the upper point of this incision carry a second along the side of the neck, to the middle of the clavicle. Inferiorly, an incision must be made from the extremity of the sacrum, along the crest of the ileum, to about its middle. For the convenience of dissection, a fourth may be carried from the middle of the spine to the acromion process. The integument and superficial fascia, together, are to be dissected off the muscles, in the course of their fibres, over the whole of this region.

The **TRAPEZIUS** muscle (trapezium, a quadrangle with unequal sides) *arises* from the superior curved line of the occipital bone, from the ligamentum nuchæ, supra-spinous ligament, and spinous processes of the last cervical and all the dorsal vertebræ. The fibres converge from these various points, and are *inserted* into the scapular third of the clavicle, the acromion process, and the whole length of the upper border of the spine of the scapula. The inferior fibres become tendinous near the scapula, and glide over the triangular surface at the posterior extremity of its spine, upon a bursa mucosa. When the trapezius is dissected on both sides, the two muscles resemble a trapezium, or diamond-shaped quadrangle, on the posterior part of the shoulders: hence the muscle was formerly named cucullaris (cucullus, a monk's cowl). The cervical and upper part of the dorsal portion of the muscle is tendinous at its origin, and forms, with the muscle of the opposite side, a kind of tendinous ellipse.

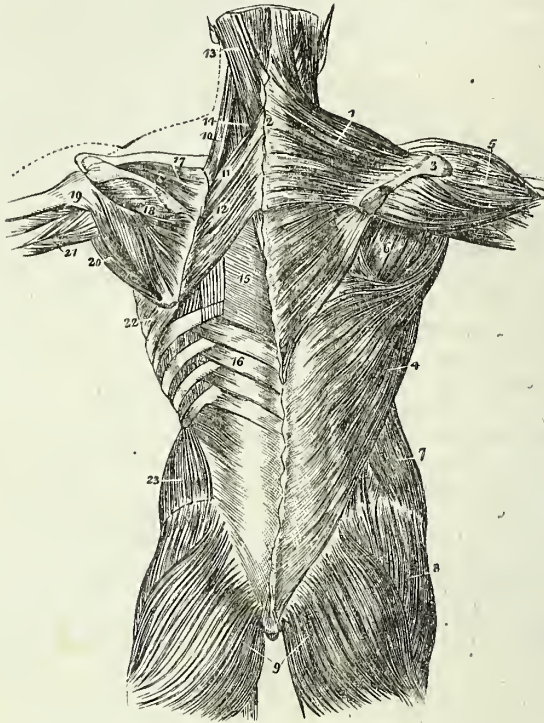
*Relations.*—By its *superficial surface*, with the integument and superficial fascia, to which it is closely adherent by its cervical portion, loosely by its dorsal portion. By its *deep surface*, from above downwards, with the complexus, splenius, levator anguli scapulæ, supra-spinatus, a small portion of the serratus posticus superior, rhomboideus minor, rhomboideus major, intervertebral aponeurosis which separates it from the erector spinæ, and with the latissimus dorsi. The *anterior border* of the cervical portion of this muscle forms the posterior boundary of the posterior triangle of the neck. The clavicular insertion of the muscle sometimes advances to the middle of the clavicle, or as far as the outer border of the sterno-mastoid, and occasionally it has been seen to overlap the latter. This is a point of much importance to be borne in mind in the operation for ligature of the subclavian artery. The spinal accessory nerve passes beneath the anterior border, near to the clavicle, previously to its distribution to the muscle.

The *ligamentum nuchæ* is a thin cellulo-fibrous layer extended from the tubercle and spine of the occipital bone, to the spinous process of the seventh cervical vertebra, where it is continuous with the supra-spinous ligament. It is connected with the spinous processes of the rest of the cervical vertebræ, with the exception of the atlas, by means of a small fibrous slip which is sent off by each. It is the analogue of an important elastic ligament in animals.

The **LATISSIMUS DORSI** muscle covers the whole of the lower part of the back and loins. It *arises* from the spinous processes of the seven inferior dorsal vertebræ, from all the lumbar and sacral spinous processes, from the posterior third of the crest of the ilium, and from the three lower ribs; the

latter origin takes place by muscular slips, which indigitate with the external oblique muscle of the abdomen. The fibres from this extensive

Fig. 114.\*



origin converge as they ascend, and cross the inferior angle of the scapula; they then curve around the lower border of the teres major muscle, and terminate in a short quadrilateral tendon, † which lies in front of the tendon of the teres, and is inserted into the bicipital groove. A synovial bursa is interposed between the muscle and the lower angle of the scapula, and

\* The first and second and part of the third layer of muscles of the back; the first layer being shown upon the right, and the second on the left side. 1. The trapezius muscle. 2. The tendinous portion which, with a corresponding portion in the opposite muscle, forms the tendinous ellipse on the back of the neck. 3. The acromion process and spine of the scapula. 4. The latissimus dorsi muscle. 5. The deltoid. 6. The muscles of the dorsum of the scapula, infra-spinatus, teres minor, and teres major. 7. The external oblique muscle. 8. The gluteus medius. 9. The gluteus maximus. 10. The levator anguli scapulae. 11. The rhomboideus minor. 12. The rhomboideus major. 13. The splenius capitis; the muscle immediately above, and overlaid by the splenius, is the complexus. 14. The splenius colli, only partially seen; the common origin of the splenius is seen attached to the spinous processes below the lower border of the rhomboideus major. 15. The vertebral aponeurosis. 16. The serratus posticus inferior. 17. The supra-spinatus muscle. 18. The infra-spinatus. 19. The teres minor muscle. 20. The teres major. 21. The long head of the triceps, passing between the teres minor and major to the upper arm. 22. The serratus magnus, proceeding forwards from its origin at the base of the scapula. 23. The internal oblique muscle.

† A small muscular fasciculus from the pectoralis major is sometimes found connected with this tendon.

another between its tendon and that of the *teres major*. The muscle frequently receives a small fasciculus from the scapula as it crosses its inferior angle.

*Relations.*—By its *superficial surface* with the integument and superficial fascia; the latter is very dense and fibrous in the lumbar region; and with the trapezius. By its *deep surface* from below upwards, with the erector spinæ, serratus posticus inferior, intercostal muscles and ribs, rhomboideus major, inferior angle of the scapula and *teres major*. The *latissimus dorsi*, with the *teres major*, forms the posterior border of the axilla.

### *Second Layer.*

*Dissection.*—This layer is brought into view by dividing the two preceding muscles near their insertion, and turning them to the opposite side.

The *LEVATOR ANGULI SCAPULÆ* arises by distinct slips, from the posterior tubercles of the transverse processes of the four upper cervical vertebræ, and is inserted into the upper angle and posterior border of the scapula, as far as the triangular smooth surface at the root of its spine.

*Relations.*—By its *superficial surface* with the trapezius, sterno-mastoid and integument. By its *deep surface* with the splenius colli, transversalis colli, cervicalis ascendens, scalenus posticus, and serratus posticus superior. The tendons of origin are interposed between the attachments of the scalenus posticus in front, and the splenius colli behind.

The *RHOMBOIDEUS MINOR* (rhombus, a parallelogram with four equal sides) is a narrow slip of muscle, detached from the rhomboideus major by a slight cellular interspace. It arises from the spinous process of the two last cervical vertebræ and ligamentum nuchæ, and is inserted into the edge of the triangular surface, on the posterior border of the scapula.

The *RHOMBOIDEUS MAJOR* arises from the spinous processes of the last cervical and four upper dorsal vertebræ and from the inter-spinous ligaments; it is inserted into the posterior border of the scapula as far as its inferior angle. The upper and middle portion of the insertion is effected by means of a tendinous band which is attached in a longitudinal direction to the posterior border of the scapula.

*Relations.*—By their *superficial surface* the two rhomboid muscles are in relation with the trapezius, and the rhomboideus major with the *latissimus dorsi* and integument. By their *deep surface* they cover in the serratus posticus superior, part of the erector spinæ, the intercostal muscles and ribs.

### *Third Layer.*

*Dissection.*—The *third layer* consists of muscles which arise from the spinous processes of the vertebral column, and pass outwards. It is brought into view by dividing the levator anguli scapulæ near its insertion, and reflecting the two rhomboid muscles upwards from their insertion into the scapula. The latter muscles should now be removed.

The *SERRATUS POSTICUS SUPERIOR* is situated at the upper part of the thorax; it arises by the ligamentum nuchæ, from the spinous processes of the three last cervical and those of the two upper dorsal vertebræ. The muscle passes obliquely downwards, and outwards, and is inserted by four

serrations into the upper border of the second, third, fourth, and fifth ribs.

*Relations.*—By its *superficial surface* with the trapezius, rhomboideus major and minor, and serratus magnus. By its *deep surface* with the splenius, the upper part of the erector spinæ, the intercostal muscles and ribs.

The SERRATUS POSTICUS INFERIOR *arises* from the processes and interspinous ligaments of the two last dorsal and three upper lumbar vertebræ, and passing obliquely upwards is *inserted* by four serrations into the lower border of the four lower ribs. Both muscles are constituted by a thin aponeurosis for about half their extent.

*Relations.*—By its *superficial surface* with the latissimus dorsi, its tendinous origin being inseparably connected with the aponeurosis of that muscle. By its *deep surface* with the aponeurosis of the obliquus internus, with which it is also closely adherent; with the erector spinæ, the intercostal muscles and lower ribs. The *upper border* is continuous with a thin tendinous layer, the vertebral aponeurosis. The *Vertebral aponeurosis* is a thin membranous expansion composed of longitudinal and transverse fibres, and extending the whole length of the thoracic region. It is attached mesially to the spinous processes of the dorsal vertebræ, and externally to the angles of the ribs; superiorly it is continued upwards beneath the serratus posticus superior, with the lower border of which it is sometimes connected. It serves to bind down the erector spinæ, and separate it from the superficial muscles.

The serratus posticus superior must be removed from its origin and turned outwards, to bring into view the whole extent of the splenius muscle.

The SPLENIUS MUSCLE is single at its origin, but divides soon after into two portions, which are destined to distinct insertions. It *arises* by the lower half of the ligamentum nuchæ, from the spinous processes of the five last cervical, and from the spinous processes and interspinous ligaments of the six upper dorsal vertebræ; it divides as it ascends the neck into the splenius capitis and colli. The *splenius capitis* is *inserted* into the rough surface of the occipital bone between the two curved lines, and into the mastoid portion of the temporal bone.

The *splenius colli* is *inserted* into the posterior tubercles of the transverse processes of the three or four upper cervical vertebræ.

*Relations.*—By its *superficial surface* with the trapezius, sterno-mastoid, levator anguli scapulæ, rhomboideus minor and major, and serratus posticus superior. By its *deep surface* with the spinalis dorsi, longissimus dorsi, semi-spinalis colli, complexus, trachelo-mastoid, and transversalis colli. The tendons of insertion of the splenius colli are interposed between the insertions of the levator anguli scapulæ in front, and the transversalis colli behind.

The splenii of opposite sides of the neck leave between them a triangular interval, in which the complexus is seen.

#### *Fourth Layer.*

*Dissection.*—The two serrati and two splenii muscles must be removed by cutting them away from their origins and insertions, to bring the fourth layer into view.

Three of these muscles, viz. sacro-lumbalis, longissimus dorsi, and

spinalis dorsi, are associated under the name of erector spinæ. They occupy the lumbar and dorsal portion of the back. The remaining four are situated in the cervical region.

The SACRO-LUMBALIS and LONGISSIMUS DORSI arise by a common origin from the posterior third of the crest of the ilium, from the posterior surface of the sacrum, and from the lumbar vertebræ; opposite the last rib a line of separation begins to be perceptible between the two muscles. The *sacro-lumbalis* is inserted by separate tendons into the angles of the six lower ribs. On turning the muscle a little outwards, a number of tendinous slips will be seen taking their origin from the ribs, and terminating in a muscular fasciculus, by which the *sacro-lumbalis* is prolonged to the upper part of the thorax. This is the *musculus accessorius ad sacro-lumbalem*: it arises from the angles of the six lower ribs, and is inserted by separate tendons into the angles of the six upper ribs.

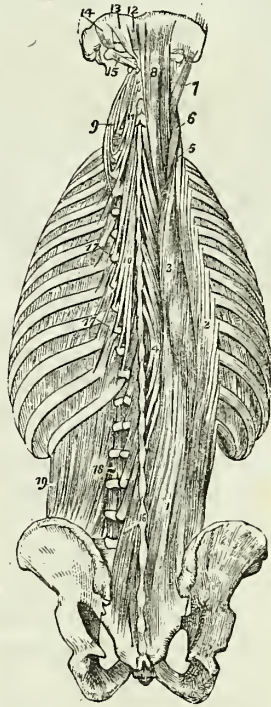
The *longissimus dorsi* is inserted into all the ribs, between their tubercles and angles.

The SPINALIS DORSI arises from the spinous processes of the two upper lumbar and three lower dorsal vertebræ, and is inserted into the spinous processes of all the upper dorsal vertebræ; the two muscles form an ellipse, which appears to enclose the spinous processes of all the dorsal vertebræ.

*Relations.* — The erector spinæ muscle is in relation by its *superficial surface* (in the lumbar region) with the conjoined aponeurosis of the transversalis and internal oblique muscle, which separates it from the aponeurosis of the serratus posticus inferior, and longissimus dorsi; (in the dorsal region) with the vertebral aponeurosis, which separates it from the latissimus dorsi, trapezius, and serratus posticus superior, and with the splenius. By its *deep surface* (in the lumbar region) with the multifidus spinæ, transverse processes of the lumbar vertebræ, and with the middle layer of the aponeurosis of the transversalis abdominis, which separates it from the quadratus lumborum; (in the dorsal region) with the multifidus spinæ, semi-spinalis dorsi, levatores costarum, intercostal muscles, and ribs as far as their angles. *Internally* or mesially with the multifidus spinæ, and semi-spinalis dorsi, which separate it from the spinous processes and arches of the vertebræ.

The two layers of aponeurosis of the transversalis abdominis, together

Fig. 115.\*



\* The fourth and fifth, and part of the sixth layer of the muscles of the back. 1. The common origin of the erector spinæ muscle. 2. The sacro-lumbalis. 3. The longissimus dorsi. 4. The spinalis dorsi. 5. The cervicalis ascendens. 6. The transversalis colli. 7. The trachelo-mastoideus. 8. The complexus. 9. The transversalis colli, showing its origin. 10. The semi-spinalis dorsi. 11. The semi-spinalis colli. 12. The rectus posticus minor. 13. The rectus posticus major. 14. The obliquus superior. 15. The obliquus inferior. 16. The multifidus spinæ. 17. The levatores costarum. 18. Intertransversales. 19. The quadratus lumborum.

with the spinal column in the lumbar region, and the vertebral aponeurosis with the ribs and spinal column in the dorsal region, form a complete osseo-aponeurotic sheath for the erector spinæ.

The CERVICALIS ASCENDENS is the continuation of the sacro-lumbalis upwards into the neck. It *arises* from the angles of the four upper ribs, and is *inserted* by slender tendons into the posterior tubercles of the transverse processes of the four lower cervical vertebræ.

*Relations.*—By its *superficial surface* with the levator anguli scapulæ; by its *deep surface* with the upper intercostal muscles and ribs, and with the intertransverse muscles; *externally* with the scalenus posticus; and *internally* with the transversalis colli. The tendons of insertion are interposed between the attachments of the scalenus posticus and transversalis colli.

The TRANSVERSALIS COLLI would appear to be the continuation upwards into the neck of the longissimus dorsi; it *arises* from the transverse processes of the five upper dorsal vertebræ, and is *inserted* into the posterior tubercles of the transverse processes of the five middle cervical vertebræ.

*Relations.*—By its *superficial surface* with the levator anguli scapulæ, splenius and longissimus dorsi. By its *deep surface* with the complexus, trachelo-mastoideus and vertebræ; *externally* with the musculus accessorius ad sacro-lumbalem, and cervicalis ascendens; *internally* with the trachelo-mastoideus and complexus. The tendons of insertion of this muscle are interposed between the tendons of insertion of the cervicalis ascendens on the outer side, and of origin of the trachelo-mastoid on the inner side.

The TRACHELO-MASTOID is likewise a continuation upwards from the longissimus dorsi. It is a very slender and delicate muscle, *arising* from the transverse processes of the four upper dorsal and four lower cervical vertebræ, and *inserted* into the mastoid process to the inner side of the digastric fossa.

*Relations.*—The same as those of the preceding muscle, excepting that it is interposed between the transversalis colli and the complexus. Its tendons of attachment are the most posterior of those which are connected with the posterior tubercles of the transverse processes of the cervical vertebræ.

The COMPLEXUS is a large muscle, and with the splenius forms the great bulk of the back of the neck. It crosses the direction of the splenius, *arising* from the transverse processes of the four upper dorsal, and from the transverse and articular processes of the four lower cervical vertebræ, and is *inserted* into the rough surface on the occipital bone between the two curved lines, near the occipital spine. A large fasciculus of the complexus is so distinct from the principal mass of the muscle as to have led to its description as a separate muscle under the name of *biventer cervicis*. This appellation is not inappropriate, for the muscle consists of a central tendon, with two fleshy bellies. The complexus is crossed in the upper part of the neck by a tendinous intersection.

*Relations.*—By its *superficial surface* with the trapezius, splenius, trachelo-mastoid, transversalis colli, and longissimus dorsi. By its *deep surface* with the semi-spinalis dorsi and colli, the recti and obliqui. It is separated from its fellow of the opposite side by the ligamentum nuchæ, and from the semi-spinalis colli by the profunda cervicis artery and prin-

ceps cervicis branch of the occipital, and by the posterior cervical plexus of nerves.

#### *Fifth Layer.*

*Dissection.*—The muscles of the preceding layer are to be removed by dividing them transversely through the middle, and turning one extremity upwards, the other downwards. In this way the whole of the muscles of the fourth layer may be got rid of, and the remaining muscles of the spine brought into a state to be examined.

The SEMI-SPINALES MUSCLES are connected with the transverse and spinous processes of the vertebræ, spanning one half of the vertebral column; hence their name semi-spinales.

The SEMI-SPINALIS DORSI *arises* from the transverse processes of the six lower dorsal vertebræ, and is *inserted* into the spinous processes of the four upper dorsal, and two lower cervical vertebræ.

The SEMI-SPINALIS COLLI *arises* from the transverse processes of the four upper dorsal vertebræ, and is *inserted* into the spinous processes of the four upper cervical vertebræ, commencing with the axis.

*Relations.*—By their *superficial surface* the semi-spinales are in relation from below upwards with the spinalis dorsi, longissimus dorsi, complexus, splenius, with the profunda cervicis and princeps cervicis artery, and posterior cervical plexus of nerves. By their *deep surface* with the multifidus spinæ muscle.

*Occipital Group.*—This group of small muscles is intended for the varied movements of the cranium on the atlas, and the atlas on the axis. They are extremely pretty in appearance.

The RECTUS POSTICUS MAJOR *arises* from the spinous process of the axis, and is *inserted* into the inferior curved line of the occipital bone.

The RECTUS POSTICUS MINOR *arises* from the spinous tubercle of the atlas, and is *inserted* into the rough surface on the occipital bone, beneath the inferior curved line.

The RECTUS LATERALIS is extended between the transverse process of the atlas and the occipital bone; it *arises* from the transverse process of the atlas, and is *inserted* into the rough surface of the occipital bone, external to the condyle.

The OBLIQUUS INFERIOR *arises* from the spinous process of the axis, and passes obliquely outwards to be *inserted* into the extremity of the transverse process of the atlas.

The OBLIQUUS SUPERIOR *arises* from the extremity of the transverse process of the atlas, and passes obliquely inwards to be *inserted* into the rough surface of the occipital bone, between the curved lines.

*Relations.*—By their *superficial surface* the recti and obliqui are in relation with a strong aponeurosis which separates them from the complexus. By their *deep surface* with the atlas and axis, and their articulations. The rectus posticus major partly covers in the rectus minor.

The rectus lateralis is in relation by its *anterior surface* with the internal jugular vein, and by its *posterior surface* with the vertebral artery.

#### *Sixth Layer.*

*Dissection.*—The semi-spinales muscles must both be removed to obtain a good view of the multifidus spinæ which lies beneath them, and fills up the concavity between the spinous and transverse processes, the whole length of the vertebral column.

The MULTIFIDUS SPINÆ\* consists of a great number of fleshy fasciculi extending between the transverse and spinous processes of the vertebræ, from the sacrum to the axis. Each fasciculus *arises* from a transverse process, and is *inserted* into the spinous process of the first or second vertebra above. Some deep fasciculi of the multifidus spinæ have recently been described by Professor Theile under the name of *rotatores spinæ*.

*Relations.*—By its *superficial surface* with the longissimus dorsi, semispinalis dorsi, and semispinalis colli. By its *deep surface* with the arches and spinous processes of the vertebral column, and in the cervical region with the ligamentum nuchæ.

The LEVATORES COSTARUM, twelve in number on each side, *arise* from the transverse processes of the dorsal vertebræ, and pass obliquely outwards and downwards to be *inserted* into the rough surface between the tubercle and angle of the rib below them. The first of these muscles arises from the transverse process of the last cervical vertebra, and the last from that of the eleventh dorsal. The levatores of the inferior ribs, besides the distribution here described, send a fasciculus downwards to the second rib below their origin, and consequently are inserted into two ribs.

*Relations.*—By their *superficial surface* with the longissimus dorsi and sacro-lumbalis. By their *deep surface* with the intercostal muscles and ribs.

The SUPRA-SPINALIS is a small and irregular muscle lying upon the spinous processes in the cervical region and composed of several fasciculi. The fasciculi *arise* from the inferior cervical and superior dorsal vertebræ, and are *inserted* into the spinous process of the axis. From its analogy to the spinalis dorsi this muscle has been named *spinalis colli*. It is sometimes wanting.

The INTERSPINALES are small muscular slips arranged in pairs and situated between the spinous processes of the vertebræ. In the *cervical region* there are six pairs of these muscles, the first being placed between the axis and third vertebra, and the sixth between the last cervical and first dorsal. In the *dorsal region*, rudiments of these muscles are occasionally met with between the upper and lower vertebræ, but are absent in the rest. In the *lumbar region* there are six pairs of interspinales, the first pair occupying the interspinous space between the last dorsal and first lumbar vertebra, and the last the space between the fifth lumbar and sacrum. They are thin and imperfectly developed. Rudimentary interspinales are occasionally met with between the lower part of the sacrum and the coccyx; these are the analogues of the caudal muscles of brutes; in man they have been named collectively the *extensor coccygis*.

The INTERTRANSVERSALES are small quadrilateral muscles situated between the transverse processes of the vertebræ. In the *cervical region* they are arranged in pairs corresponding with the double conformation of the transverse processes, the vertebral artery and anterior division of the cervical nerves lying between them. The rectus anticus minor and rectus lateralis represent the intertransversales between the atlas and cranium. In the *dorsal region* the anterior intertransversales are represented by the intercostal muscles, while the posterior are mere tendinous bands, muscular only between the first and last vertebræ. In the *lumbar region*, the

\* Professor Theile of Berlin has examined this muscle very closely, and describes a portion of it under the name of ROTATORES SPINÆ, which seems to be an unnecessary complication.—G.



anterior intertransversales are thin, and occupy only part of the space between the transverse processes. Analogues of posterior intertransversales exist in the form of small muscular fasciculi (interobliqui) extended between the rudimentary posterior transverse processes of the lumbar vertebræ.

With regard to the origin and insertion of the muscles of the back, the student should be informed, that no regularity attends their attachments. At the best, a knowledge of their exact connexions, even were it possible to retain it, would be but a barren information, if not absolutely injurious, as tending to exclude more valuable learning. I have therefore endeavoured to arrange a plan, by which they may be more easily recollected, by placing them in a tabular form (p. 208), that the student may see, at a single glance, the origin and insertion of each, and compare the natural grouping and similarity of attachments of the various layers. In this manner also their actions will be better comprehended, and learnt with greater facility.

*Actions.*—The upper fibres of the trapezius draw the shoulder upwards and backwards; the middle fibres, directly backwards; and the lower downwards and backwards. The lower fibres also act by producing rotation of the scapula upon the chest. If the shoulder be fixed the upper fibres will flex the spine towards the corresponding side. The latissimus dorsi is a muscle of the arm, drawing it backwards and downwards, and at the same time rotating it inwards; if the arm be fixed, the latissimus dorsi will draw the spine to that side, and, raising the lower ribs, be an inspiratory muscle; and if both arms be fixed, the two muscles will draw the whole trunk forwards, as in climbing or walking on crutches. The levator anguli scapulæ lifts the upper angle of the scapula, and with it the entire shoulder, and the rhomboidei carry the scapula and shoulder upwards and backwards.

In examining the following table, the student will observe the constant recurrence of the number *four* in the origin and insertion of the muscles. Sometimes the *four* occurs at the top or bottom of a region of the spine, and frequently includes a part of two regions, and takes two from each, as in the case of the serrati. Again, he will perceive that the muscles of the upper half of the table take their origin from spinous processes, and pass outwards to transverse, whereas the lower half arise mostly from transverse processes. To the student, then, we commit these reflections, and leave it to the peculiar tenor of his own mind to make such arrangements as will be best retained by his memory.

The serrati are respiratory muscles acting in opposition to each other, the *serratus posticus superior* drawing the ribs upwards, and thereby expanding the chest; and the *inferior* drawing the lower ribs downwards and diminishing the cavity of the chest. The former is an inspiratory, the latter an expiratory muscle. The splenii muscles of one side draw the vertebral column backwards and to one side, and rotate the head towards the corresponding shoulder. The muscles of opposite sides, acting together, will draw the head directly backwards. They are the natural antagonists of the sterno-mastoid muscles.

The *sacro-lumbalis* with its *accessory muscle*, the *longissimus dorsi*, and *spinalis dorsi*, are known by the general term of *erectores spinæ*, which sufficiently expresses their action. They keep the spine supported in the vertical position by their broad origin from below, and by means of their

| ORIGIN.                                 |                                                 |                                     |                      |                                                                  |
|-----------------------------------------|-------------------------------------------------|-------------------------------------|----------------------|------------------------------------------------------------------|
| Layers.                                 | Spinous Processes.                              | Transverse Processes.               | Ribs.                | Additional.                                                      |
| <i>1st Layer.</i>                       |                                                 |                                     |                      |                                                                  |
| Trapezius . . . . .                     | last cervical,<br>12 dorsal                     | . . . . .                           | . . . . .            | occipital bone and }<br>ligamentum nuchæ }<br>sacrum and ilium . |
| Latissimus dorsi . . . . .              | 6 lower dorsal,<br>5 lumbar                     | . . . . .                           | 3 lower              |                                                                  |
| <i>2d Layer.</i>                        |                                                 |                                     |                      |                                                                  |
| Levator anguli scapulae . . . . .       | . . . . .                                       | 4 upper cervical                    | . . . . .            | . . . . .                                                        |
| Rhomboideus minor . . . . .             | lig. nuchæ and<br>last cervical                 | . . . . .                           | . . . . .            | . . . . .                                                        |
| Rhomboideus major . . . . .             | 4 upper dorsal                                  | . . . . .                           | . . . . .            | . . . . .                                                        |
| <i>3d Layer.</i>                        |                                                 |                                     |                      |                                                                  |
| Serratus posticus superior . . . . .    | lig. nuchæ,<br>last cervical,<br>2 upper dorsal | . . . . .                           | . . . . .            | . . . . .                                                        |
| Serratus posticus inferior . . . . .    | 2 lower dorsal,<br>2 upper lumbar               | . . . . .                           | . . . . .            | . . . . .                                                        |
| Splenius capitis . . . . .              | lig. nuchæ,<br>last cervical,                   | . . . . .                           | . . . . .            | . . . . .                                                        |
| Splenius colli . . . . .                | 6 upper dorsal                                  | . . . . .                           | . . . . .            | . . . . .                                                        |
| <i>4th Layer.</i>                       |                                                 |                                     |                      |                                                                  |
| Sacro-lumbalis . . . . .                | . . . . .                                       | . . . . .                           | . . . . .            | sacrum and ilium .                                               |
| Accessorius ad sacro-lumbalem . . . . . | . . . . .                                       | . . . . .                           | angles of<br>6 lower | . . . . .                                                        |
| Longissimus dorsi . . . . .             | . . . . .                                       | . . . . .                           | . . . . .            | sacrum and lumbar }<br>vertebræ . . . . . }                      |
| Spinalis dorsi . . . . .                | 2 lower dorsal,<br>2 upper lumbar               | . . . . .                           | . . . . .            | . . . . .                                                        |
| Cervicalis ascendens . . . . .          | . . . . .                                       | . . . . .                           | angles of<br>4 upper | . . . . .                                                        |
| Transversalis colli . . . . .           | . . . . .                                       | 3d, 4th, 5th,<br>and 6th dorsal     | . . . . .            | . . . . .                                                        |
| Trachelo-mastoideus . . . . .           | . . . . .                                       | 4 upper dorsal,<br>4 lower cervical | . . . . .            | . . . . .                                                        |
| Complexus . . . . .                     | . . . . .                                       | 4 upper dorsal,<br>4 lower cervical | . . . . .            | . . . . .                                                        |
| <i>5th Layer.</i>                       |                                                 |                                     |                      |                                                                  |
| Semi-spinalis dorsi . . . . .           | . . . . .                                       | 6 lower dorsal                      | . . . . .            | . . . . .                                                        |
| Semi-spinalis colli . . . . .           | . . . . .                                       | 4 upper dorsal                      | . . . . .            | . . . . .                                                        |
| Rectus posticus major . . . . .         | axis . . . . .                                  | . . . . .                           | . . . . .            | . . . . .                                                        |
| Rectus posticus minor . . . . .         | atlas . . . . .                                 | . . . . .                           | . . . . .            | . . . . .                                                        |
| Rectus lateralis . . . . .              | . . . . .                                       | atlas . . . . .                     | . . . . .            | . . . . .                                                        |
| Obliquus inferior . . . . .             | axis . . . . .                                  | . . . . .                           | . . . . .            | . . . . .                                                        |
| Obliquus superior . . . . .             | . . . . .                                       | atlas . . . . .                     | . . . . .            | . . . . .                                                        |
| <i>6th Layer.</i>                       |                                                 |                                     |                      |                                                                  |
| Multifidus spinæ . . . . .              | . . . . .                                       | from sacrum to<br>3d cervical       | . . . . .            | . . . . .                                                        |
| Levatores costarum . . . . .            | . . . . .                                       | last cervical and<br>eleven dorsal  | . . . . .            | . . . . .                                                        |
| Supra-spinales . . . . .                | cervical . . . . .                              | . . . . .                           | . . . . .            | . . . . .                                                        |
| Inter-spinales . . . . .                | Cervical and<br>lumbar . . . . .                | . . . . .                           | . . . . .            | . . . . .                                                        |
| Inter-transversales . . . . .           | . . . . .                                       | cervical and<br>lumbar . . . . .    | . . . . .            | . . . . .                                                        |

INSERTION.

| Spinous Processes.                       | Transverse Processes.                  | Ribs.                                            | Additional.                                                                          |
|------------------------------------------|----------------------------------------|--------------------------------------------------|--------------------------------------------------------------------------------------|
| . . . .                                  | . . . .                                | . . . .                                          | } clavicle and spine of the scapula.<br>} posterior bicipital ridge of the humerus.  |
| . . . .                                  | . . . .                                | . . . .                                          |                                                                                      |
| . . . .                                  | . . . .                                | . . . .                                          | } angle and base of the scapula.<br>} base of the scapula.<br>} base of the scapula. |
| . . . .                                  | . . . .                                | . . . .                                          |                                                                                      |
| . . . .                                  | . . . .                                | . . . .                                          |                                                                                      |
| . . . .                                  | . . . .                                | 2d, 3d, 4th, and 5th.                            |                                                                                      |
| . . . .                                  | . . . .                                | 4 lower ribs.                                    |                                                                                      |
| . . . .                                  | 4 upper cervical                       | . . . .                                          | } occipital and mastoid portion of temporal bone.                                    |
| . . . .                                  | . . . .                                | angles of 6 lower.                               |                                                                                      |
| . . . .                                  | . . . .                                | angles of 6 upper.                               |                                                                                      |
| . . . .                                  | . . . .                                | } all the ribs between the tubercles and angles. |                                                                                      |
| 8 upper dorsal.                          | . . . .                                |                                                  |                                                                                      |
| . . . .                                  | 4 lower cervical.                      |                                                  |                                                                                      |
| . . . .                                  | 4 lower cervical.                      |                                                  |                                                                                      |
| . . . .                                  | . . . .                                | . . . .                                          | mastoid process.                                                                     |
| . . . .                                  | . . . .                                | . . . .                                          | } occipital bone between the curved lines.                                           |
| . . . .                                  | . . . .                                | . . . .                                          |                                                                                      |
| } 4 upper dorsal,<br>} 2 lower cervical. | . . . .                                | . . . .                                          | occipital bone.                                                                      |
|                                          | } 4 upper cervical,<br>} except atlas. | . . . .                                          | . . . .                                                                              |
| . . . .                                  |                                        | . . . .                                          | . . . .                                                                              |
| . . . .                                  | atlas.                                 | . . . .                                          | occipital bone.                                                                      |
| . . . .                                  | . . . .                                | . . . .                                          |                                                                                      |
| } from last lumbar to<br>} axis.         | . . . .                                | } all the ribs between the tubercles and angles. |                                                                                      |
|                                          | cervical.                              |                                                  |                                                                                      |
| cervical and lumbar.                     | . . . .                                |                                                  |                                                                                      |
| . . . .                                  | } cervical and lumbar.                 |                                                  |                                                                                      |
| . . . .                                  |                                        |                                                  |                                                                                      |

insertion, by distinct tendons, into the ribs and spinous processes. Being made up of a number of distinct fasciculi, which alternate in their actions, the spine is kept erect without fatigue, even when they have to counterbalance a corpulent abdominal development. The continuations upwards of these muscles into the neck preserve the steadiness and uprightness of that region. When the muscles of one side act alone, the neck is rotated upon its axis. The *complexus*, by being attached to the occipital bone, draws the head backwards, and counteracts the muscles on the anterior part of the neck. It assists also in the rotation of the head.

The *semi-spinales* and *multifidus spinæ* muscles act directly on the vertebræ, and contribute to the general action of supporting the vertebral column erect.

The four little muscles situated between the occiput and the two first vertebræ, effect the various movements between these bones; the *recti* producing the antero-posterior actions, and the *obliqui* the rotatory motions of the atlas on the axis.

The actions of the remaining muscles of the spine, the *supra* and *inter-spinales* and *inter-transversales*, are expressed in their names. They approximate their attachments and assist the more powerful muscles in preserving the erect position of the body.

The *levator costarum* raise the posterior parts of the ribs, and are probably more serviceable in preserving the articulation of the ribs from dislocation, than in raising them in inspiration.

#### MUSCLES OF THE THORAX.

The principal muscles situated upon the thorax belong in their actions to the upper extremity, with which they will be described. They are the pectoralis major and minor, subclavius and serratus magnus. The true thoracic muscles are few in number, and appertain exclusively to the actions of the ribs; they are, the—

Intercostales externi,  
Intercostales interni,  
Triangularis sterni.

The intercostal muscles are two planes of muscular and tendinous fibres directed obliquely between the adjacent ribs and closing the intercostal spaces. They are seen partially upon the removal of the pectoral muscles, or upon the inner surface of the chest. The triangularis sterni is within the chest, and requires the removal of the anterior part of the thorax to bring it into view.

The INTERCOSTALES EXTERNI, eleven on each side, commence posteriorly at the tubercles of the ribs, and advance forwards to the costal cartilages, where they terminate in a thin aponeurosis, which is continued onwards to the sternum. Their fibres are directed obliquely downwards and inwards, pursuing the same line with those of the external oblique muscle of the abdomen. They are thicker than the internal intercostals.

The INTERCOSTALES INTERNI, also eleven on each side, commence anteriorly at the sternum, and extend backwards as far as the angles of the ribs, whence they are prolonged to the vertebral column by a thin aponeurosis. Their fibres are directed obliquely downwards and backwards, and correspond in direction with those of the internal oblique muscle of

the abdomen. The two muscles cross each other in the direction of their fibres.

In structure the intercostal muscles consist of an admixture of muscular and tendinous fibres. They *arise* from the two lips of the lower border of the ribs, the external from the outer lip, the internal from the inner, and are *inserted* into the upper border.

*Relations.*—The external intercostals, by their *external surface*, with the muscles which immediately invest the chest, viz. the pectoralis major and minor, the serratus magnus, serratus posticus superior and inferior, scalenus posticus; sacro-lumbalis, and longissimus dorsi, with their continuations, the cervicalis ascendens and transversalis colli; the levatores costarum, and the obliquus externus abdominis. By their *internal surface* with the internal intercostals, the intercostal vessels and nerves, and a thin aponeurosis, and posteriorly with the pleura. The internal intercostals, by their *external surface* with the external intercostals, and intercostal vessels and nerves; by their *internal surface* with the pleura costalis, the triangularis sterni and diaphragm.

Connected with the internal intercostals are a variable number of muscular fasciculi, which pass from the inner surface of one rib near its middle to the next or next but one below; these are the subcostal, or more correctly the *intracostal muscles*.

The TRIANGULARIS STERNI, situated upon the inner wall of the front of the chest, *arises* by a thin aponeurosis from the side of the sternum, ensiform cartilage, and sternal extremities of the costal cartilages; and is *inserted* by fleshy digitations into the cartilages of the third, fourth, fifth and sixth ribs, and often into that of the second.

*Relations.*—By its *external surface* with the sternum, the ensiform cartilage, the costal cartilages, internal intercostal muscles, and internal mammary vessels. By its *internal surface* with the pleura costalis, the areolar tissue of the anterior mediastinum and the diaphragm. The lower fibres of the triangularis sterni are continuous with those of the diaphragm.

*Actions.*—The intercostal muscles raise the ribs when they act from above, and depress them when they take their fixed point from below. They are, therefore, both inspiratory and expiratory muscles. The triangularis sterni draws down the costal cartilages, and is, therefore, an expiratory muscle.

#### MUSCLES OF THE ABDOMEN.

The muscles of this region are, the—

Obliquus externus (descendens),  
 Obliquus internus (ascendens),  
 Cremaster,  
 Transversalis,  
 Rectus,  
 Pyramidalis,  
 Quadratus lumborum,  
 Psoas parvus,  
 Diaphragm.

*Dissection.*—The dissection of the abdominal muscles is to be commenced by making three incisions:—The first, *vertical*, in the middle line, from over the lower part of the sternum to the pubes; the second *oblique*, from

the umbilicus, upwards and outwards, to the outer side of the chest, as high as the fifth or sixth rib; and the third, *oblique*, from the umbilicus, downwards and outwards, to the middle of the crest of the ilium. The three flaps included by these incisions should then be dissected back in the direction of the fibres of the external oblique muscle, beginning at the angle of each. The integument and superficial fascia should be dissected off together so as to expose the fibres of the muscle at once.

If the external oblique muscle be dissected on both sides, a white tendinous line will be seen along the middle of the abdomen, extending from the ensiform cartilage to the os pubis; this is the *linea alba*. A little external to it, on each side, two curved lines will be observed extending from the sides of the chest to the os pubis, and bounding the recti muscles: these are the *linea semilunares*. Some transverse lines, *linea transversæ*, three or four in number, connect the *linea semilunares* with the *linea alba*.

The EXTERNAL OBLIQUE MUSCLE (*obliquus externus abdominis descendens*) is the external flat muscle of the abdomen. Its name is derived from the obliquity of its direction, and the descending course of its fibres. It arises by fleshy digitations from the external surface of the eight inferior ribs; the five upper digitations being received between corresponding processes of the serratus magnus, and the three lower of the latissimus dorsi. Soon after its origin it spreads out into a broad aponeurosis, which is inserted into the outer lip of the crest of the ilium for one half its length, the anterior superior spinous process of the ilium, spine of the os pubis, pectineal line, front of the os pubis, and *linea alba*.

The lower border of the aponeurosis, which is stretched between the anterior superior spinous process of the ilium and the spine of the os pubis, is rounded from being folded inwards, and forms *Poupart's ligament*; the insertion into the pectineal line is *Gimbernat's ligament*.

Just above the crest of the os pubis is the *external abdominal ring*, a triangular opening formed by the separation of the fibres of the aponeurosis of the external oblique. It is oblique in its direction, and corresponds with the course of the fibres of the aponeurosis. It is bounded below by the crest of the os pubis; on either side by the borders of the aponeurosis, which are called *pillars*; and above by some curved fibres (*inter-columnar*), which originate from *Poupart's ligament*, and cross the upper angle of the ring so as to give it strength. The *external pillar*, which is at the same time *inferior* from the obliquity of the opening, is inserted into the spine of the os pubis; the internal or superior pillar forms an interlacement with its fellow of the opposite side over the front of the symphysis pubis. The external abdominal ring gives passage to the spermatic cord in the male and round ligament in the female: they are both invested in their passage through it by a thin fascia derived from the edges of the ring, and called *inter-columnar fascia*, or *fascia spermatica*.

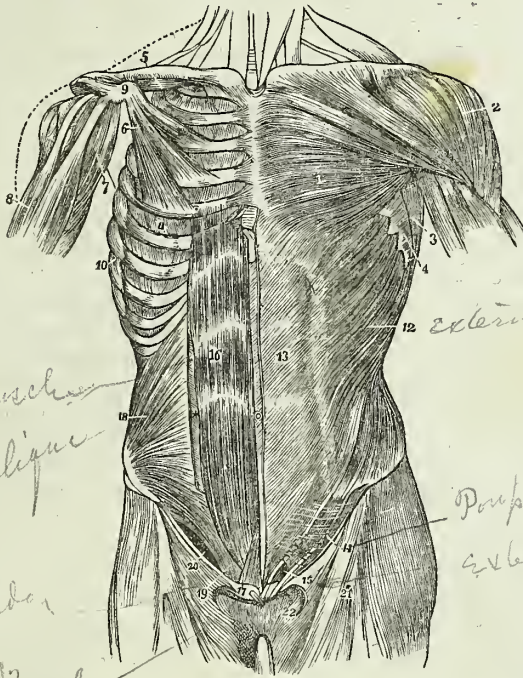
The pouch of inguinal hernia, in passing through this opening, receives the *inter-columnar fascia*, as one of its coverings.

*Relations.*—By its *external surface* with the superficial fascia and integument, and with the cutaneous vessels and nerves, particularly the superficial epigastric and superficial circumflexa ilii vessels. It is generally overlapped posteriorly by the latissimus dorsi. By its *internal surface* with the internal oblique, the lower part of the eight inferior ribs and intercostal muscles, the cremaster, the spermatic cord in the male, and the

round ligament in the female. The upper border of the external oblique is continuous with the pectoralis major.

The external oblique is now to be removed by making an incision across the ribs, just below its origin, to its posterior border; and another along Poupart's ligament and the crest of the ilium. Poupart's ligament

Fig. 116.\*



\* The muscles of the anterior aspect of the trunk; on the left side the superficial layer is seen, and on the right the deeper layer. 1. The pectoralis major muscle. 2. The deltoid; the interval between these muscles lodges the cephalic vein. 3. The anterior border of the latissimus dorsi. 4. The serrations of the serratus magnus. 5. The subclavius muscle of the right side. 6. The pectoralis minor. 7. The coracho-brachialis muscle. 8. The upper part of the biceps muscle, showing its two heads. 9. The coracoid process of the scapula. 10. The serratus magnus of the right side. 11. The external intercostal muscle of the fifth intercostal space. 12. The external oblique muscle. 13. Its aponeurosis; the median line to the right of this number is the linea alba; the flexuous line to its left is the linea semilunaris; and the transverse lines above and below the number, the lineæ transversæ. 14. Poupart's ligament. 15. The external abdominal ring; the margin above the ring is the superior or internal pillar; the margin below the ring, the inferior or external pillar; the curved intercolumnar fibres are seen proceeding upwards from Poupart's ligament to strengthen the ring. The numbers 14 and 15 are situated upon the fascia lata of the thigh; the opening immediately to the right of 15 is the saphenous opening. 16. The rectus muscle of the right side brought into view by the removal of the anterior segment of its sheath: \* the posterior segment of its sheath with the divided edge of the anterior segment. 17. The pyramidalis muscle. 18. The internal oblique muscle. 19. The conjoined tendon of the internal oblique and transversalis descending behind Poupart's ligament to the pectineal line. 20. The arch formed between the lower curved border of the internal oblique muscle and Poupart's ligament; it is beneath this arch that the spermatic cord and hernia pass.

should be left entire, as it gives attachment to the next muscles. The muscle may then be turned forwards towards the linea alba, or removed altogether.

The INTERNAL OBLIQUE MUSCLE (*obliquus internus abdominis ascendens*) is the middle flat muscle of the abdomen. It arises from the outer half of Poupart's ligament, from the middle of the crest of the ilium for two-thirds of its length, and by a thin aponeurosis from the spinous processes of the lumbar vertebræ. Its fibres diverge from their origin, so that those from Poupart's ligament curve downwards, those from the anterior part of the crest of the ilium pass transversely, and the rest ascend obliquely. The muscle is inserted into the pectineal line and crest of the os pubis, linea alba, and lower borders of the five inferior ribs.

Along the upper three-fourths of the linea semilunaris, the aponeurosis of the internal oblique separates into two lamellæ, which pass one in front and the other behind the rectus muscle to the linea alba, where they are inserted; along the lower fourth, the aponeurosis passes altogether in front of the rectus without separation. The two layers, which thus enclose the rectus, form for it a partial sheath.

The lowest fibres of the internal oblique are inserted into the pectineal line of the os pubis in common with those of the transversalis muscle. Hence the tendon of this insertion is called the *conjoined tendon of the internal oblique and transversalis*. This structure corresponds with the external abdominal ring, and forms a protection to what would otherwise be a weak point in the abdomen. Sometimes the tendon is insufficient to resist the pressure from within, and becomes forced through the external ring; it then forms the distinctive covering of *direct inguinal hernia*.

The spermatic cord passes beneath the arched border of the internal oblique muscle, between it and Poupart's ligament. During its passage some fibres are given off from the lower border of the muscle, which accompany the cord downwards to the testicle, and form loops around it: this is the cremaster muscle. In the descent of oblique inguinal hernia, which travels the same course with the spermatic cord, the cremaster muscle forms one of its coverings.

The CREMASTER, considered as a distinct muscle, arises from the middle of Poupart's ligament, and forms a series of loops upon the spermatic cord. A few of its fibres are inserted into the tunica vaginalis, the rest ascend along the inner side of the cord, to be inserted, with the conjoined tendon, into the pectineal line of the os pubis.

*Relations.*—The internal oblique is in relation, by its *external surface*, with the external oblique, latissimus dorsi, spermatic cord, and external abdominal ring. By its *internal surface*, with the transversalis muscle, the fascia transversalis, the internal abdominal ring, and spermatic cord. By its *lower and arched border*, with the spermatic cord, forming the upper boundary of the spermatic canal.

The cremaster is in relation, by its *external surface*, with the aponeurosis of the external oblique and intercolumnar fascia; and by its *internal surface*, with the fascia propria of the spermatic cord.

The internal oblique muscle is to be removed by separating it from its attachments to the ribs above, and to the crest of the ilium and Poupart's ligament below. It should be divided behind by a vertical incision, extending from the last rib to the crest of the ilium, as its lumbar attachment cannot at present be examined. The muscle is then to be turned for-



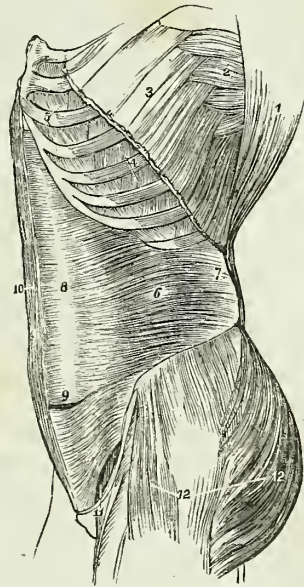
wards. Some degree of care will be required in performing this dissection, from the difficulty of distinguishing between this muscle and the one beneath. A thin layer of cellular tissue is all that separates them for the greater part of their extent. Near the crest of the ilium, the circumflexa ilii artery ascends between the two muscles, and forms a valuable guide to their separation. Just above Poupart's ligament they are so closely connected, that it is impossible to divide them.

The TRANSVERSALIS is the internal flat muscle of the abdomen; it is transverse in the direction of its fibres, as is implied in its name. It arises from the outer third of Poupart's ligament, from the internal lip of the crest of the ilium, its anterior two-thirds; from the spinous and transverse processes of the lumbar vertebræ, and from the inner surfaces of the six inferior ribs, indigitating with the diaphragm. Its lower fibres curve downwards, to be inserted, with the lower fibres of the internal oblique, into the pectineal line, and form the conjoined tendon. Throughout the rest of its extent it is inserted into the crest of the os pubis and linea alba. The lower fourth of its aponeurosis passes in front of the rectus to the linea alba; the upper three-fourths with the posterior lamella of the internal oblique, behind it.

The posterior aponeurosis of the transversalis divides into three lamellæ;—*anterior*, which is attached to the bases of the transverse processes of the lumbar vertebræ; *middle*, to the apices of the transverse processes; and *posterior*, to the apices of the spinous processes. The anterior and middle lamellæ enclose the quadratus lumborum muscle; and the middle and posterior, the erector spinæ. The union of the posterior lamella of the transversalis with the posterior aponeurosis of the internal oblique, serratus posticus inferior, and latissimus dorsi, constitutes the *lumbar fascia*.

*Relations.*—By its *external surface* with the internal oblique, the internal surfaces of the lower ribs, and internal intercostal muscles. By its *internal surface* with the transversalis fascia, which separates it from the peritoneum, with the psoas magnus, and with the lower part of the rectus and pyramidalis. The spermatic cord and oblique inguinal hernia pass beneath the *lower border*, but have no direct relation with it.

Fig. 117.\*



\* A lateral view of the trunk of the body, showing its muscles, and particularly the transversalis abdominis. 1. The costal origin of the latissimus dorsi muscle. 2. The serratus magnus. 3. The upper part of the external oblique muscle, divided in the direction best calculated to show the muscles beneath, without interfering with its indigitations with the serratus magnus. 4. Two of the external intercostal muscles. 5. Two of the internal intercostals. 6. The transversalis muscle. 7. Its posterior aponeurosis. 8. Its anterior aponeurosis, forming the most posterior layer of the sheath of the rectus. 9. The lower part of the left rectus, with the aponeurosis of the transversalis passing in front. 10. The right rectus muscle. 11. The arched opening left between the lower border of the transversalis muscle and Poupart's ligament, through which the spermatic cord and hernia pass. 12. The gluteus maximus, and medius, and tensor vaginae femoris muscles invested by fascia lata.

To dissect the *rectus muscle*, its sheath should be opened by a vertical incision extending from over the cartilages of the lower ribs to the front of the os pubis. The sheath may then be dissected off and turned to either side; this is easily done excepting at the lineæ transversæ, where a close adhesion subsists between the muscle and the external boundary of the sheath. The sheath contains the rectus and pyramidalis muscle.

The RECTUS MUSCLE *arises* by a flattened tendon from the crest of the os pubis, and is *inserted* into the cartilages of the fifth, sixth, and seventh ribs. It is traversed by several tendinous zigzag intersections, called lineæ transversæ. One of these is usually situated at the umbilicus, two above that point, and sometimes one below. They are vestiges of the abdominal ribs of reptiles, and very rarely extend completely through the muscle.

*Relations.*—By its *external surface* with the anterior lamella of the aponeurosis of the internal oblique, below with the aponeurosis of the transversalis, and pyramidalis. By its *internal surface* with the ensiform cartilages of the fifth, sixth, seventh, eighth and ninth ribs, with the posterior lamella of the internal oblique, the peritoneum, and the epigastric artery and veins.

The PYRAMIDALIS MUSCLE *arises* from the crest of the os pubis in front of the rectus, and is *inserted* into the linea alba at about midway between the umbilicus and the os pubis. It is enclosed in the same sheath with the rectus, and rests against the lower part of that muscle. This muscle is sometimes wanting.

The rectus may now be divided across the middle, and the two ends drawn aside for the purpose of examining the mode of formation of its sheath.

The *sheath of the rectus* is formed *in front* for the upper three-fourths of its extent, by the aponeurosis of the external oblique and the anterior lamella of the internal oblique, and *behind* by the posterior lamella of the internal oblique and the aponeurosis of the transversalis. At the commencement of the lower fourth, the posterior wall of the sheath terminates in a thin curved margin, the aponeurosis of the three muscles passing altogether in front of the rectus.

The next two muscles can be examined only when the viscera of the abdomen are removed. To see the quadratus lumborum, it is also necessary to divide and draw aside the psoas muscle and the anterior lamella of the aponeurosis of the transversalis.

The QUADRATUS LUMBORUM muscle is concealed from view by the anterior lamella of the aponeurosis of the transversalis muscle, which is inserted into the bases of the transverse processes of the lumbar vertebræ. When this lamella is divided, the muscle will be seen *arising* from the last rib, and from the transverse processes of the four upper lumbar vertebræ. It is *inserted* into the crest of the ilium and ilio-lumbar ligament. If the muscle be cut across or removed, the middle lamella of the transversalis will be seen attached to the apices of the transverse processes; the quadratus being enclosed between the two lamellæ as in a sheath.

*Relations.*—Enclosed in the sheath formed by the transversalis muscle, it is in relation *in front*, with the kidney, the colon, the psoas magnus and the diaphragm. *Behind*, but also separated by a sheath, with the erector spinæ.

The PSOAS PARVUS *arises* from the tendinous arches and intervertebral

substance of the last dorsal and first lumbar vertebra, and terminates in a long slender tendon which expands inferiorly and is *inserted* into the iliopectineal line and eminence. The tendon is continuous by its outer border with the iliac fascia.

*Relations.*—It rests upon the psoas magnus, and is covered in by the peritoneum; superiorly it passes beneath the ligamentum arcuatum of the diaphragm. It is occasionally wanting.

**DIAPHRAGM.**—To obtain a good view of this important inspiratory muscle, the peritoneum should be dissected from its under surface. It is the muscular septum between the thorax and abdomen, and is composed of two portions, a greater and a lesser muscle. The *greater muscle* arises from the ensiform cartilage; from the inner surfaces of the six inferior ribs, indigitating with the transversalis; and from the ligamentum arcuatum externum and internum. From these points, which form the internal circumference of the trunk, the fibres converge and are *inserted* into the central tendon.

The *ligamentum arcuatum externum* is the upper border of the anterior lamella of the aponeurosis of the transversalis: it arches across the origin of the quadratus lumborum muscle, and is attached by one extremity to the base of the transverse process of the first lumbar vertebra, and by the other to the apex and lower margin of the last rib.

The *ligamentum arcuatum internum*, or *proprium*, is a tendinous arch thrown across the psoas magnus muscle as it emerges from the chest. It is attached by one extremity to the base of the transverse process of the first lumbar vertebra, and by the other is continuous with the tendon of the lesser muscle opposite the body of the second.

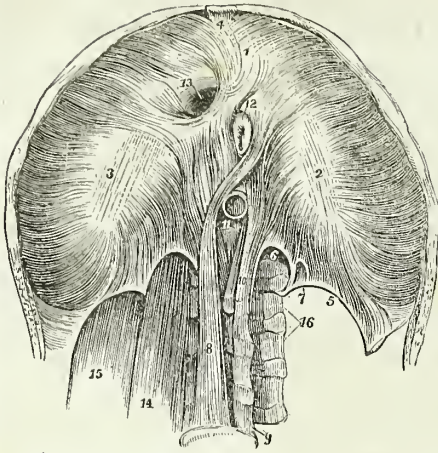
The *tendinous centre* of the diaphragm is shaped like a trefoil leaf, of which the central leaflet points to the ensiform cartilage, and is the largest; the lateral leaflets, right and left, occupy the corresponding portions of the muscle; the right being the larger and more rounded, and the left smaller and lengthened in its form.

Between the sides of the ensiform cartilage and the cartilages of the adjoining ribs, is a small triangular space where the muscular fibres of the diaphragm are deficient. This space is closed only by peritoneum on the side of the abdomen, and by pleura within the chest. It is therefore a weak point, and a portion of the contents of the abdomen might, by violent exertion, be forced through it, producing phrenic, or diaphragmatic hernia.

The *lesser muscle* of the diaphragm takes its origin from the bodies of the lumbar vertebræ by two tendons. The *right*, larger and longer than the left, arises from the anterior surface of the bodies of the second, third, and fourth vertebræ; and the *left* from the side of the second and third. The tendons form two large fleshy bellies (*crura*), which ascend to be inserted into the central tendon. The inner fasciculi of the two crura cross each other in front of the aorta, and again diverge to surround the œsophagus, so as to present the appearance of a figure of eight. The anterior fasciculus of the decussation is formed by the right crus.

The *openings in the diaphragm* are three: one, quadrilateral, in the tendinous centre, at the union of the right and middle leaflets, for the passage of the *inferior vena cava*; a muscular opening of an elliptic shape formed by the two crura, for the transmission of the *œsophagus* and *pneumogastric nerves*; and a third, the *aortic*, which is formed by a tendinous

Fig. 118.\*



arch thrown from the tendon of one crus to that of the other, beneath which pass the *aorta*, the *right vena azygos*, and *thoracic duct*. The great splanchnic nerves pass through openings in the lesser muscle on each side, and the lesser splanchnic nerves through the fibres which arise from the *ligamentum arcuatum internum*.

*Relations.*—By its *superior surface* with the pleuræ, the pericardium, the heart, and the lungs. By its *inferior surface* with the peritoneum; on the left with the stomach and spleen; on the right with

the convexity of the liver; and behind with the kidneys, the supra-renal capsules, the duodenum, and the solar plexus. By its *circumference* with the ribs and intercostal muscles, and with the vertebral column.

*Actions.*—The external oblique muscle, acting singly, would draw the thorax towards the pelvis, and twist the body to the opposite side. Both muscles, acting together, would flex the thorax directly on the pelvis. The internal oblique of one side draws the chest downwards and outwards: both together bend it directly forwards. Either transversalis muscle, acting singly, will diminish the size of the abdomen on its own side, and both together will constrict the entire cylinder of the cavity. The recti muscles, assisted by the pyramidales, flex the thorax upon the chest, and, through the medium of the *lineæ transversæ*, are enabled to act when their sheath is curved inwards by the action of the transversales. The pyramidales are tensors of the *linea alba*. The abdominal are expiratory muscles, and the chief agents of expulsion; by their action the fœtus is expelled from the uterus, the urine from the bladder, the fæces from the rectum, the bile from the gall-bladder, the ingesta from the stomach and bowels in vomiting, and the mucous and irritating substances from the bronchial tubes,

\* The under or abdominal side of the diaphragm. 1, 2, 3. The greater muscle; the figure 1 rests upon the central leaflet of the tendinous centre; the number 2 on the left or smallest leaflet; and number 3 on the right leaflet. 4. The thin fasciculus which arises from the ensiform cartilage; a small triangular space is left on either side of this fasciculus, which is closed only by the serous membranes of the abdomen and chest. 5. The *ligamentum arcuatum externum* of the left side. 6. The *ligamentum arcuatum internum*. 7. A small arched opening occasionally found, through which the lesser splanchnic nerve passes. 8. The right or larger tendon of the lesser muscle; a muscular fasciculus from this tendon curves to the left side of the greater muscle between the œsophageal and aortic openings. 9. The fourth lumbar vertebra. 10. The left or shorter tendon of the lesser muscle. 11. The aortic opening occupied by the *aorta* which is cut short off. 12. A portion of the œsophagus issuing through the œsophageal opening; in this figure the œsophageal opening is tendinous at its anterior part, a structure which is not uncommon. 13. The opening for the inferior vena cava, in the tendinous centre of the diaphragm. 14. The *psoas magnus* muscle passing beneath the *ligamentum arcuatum internum*; it has been removed on the opposite side to show the arch more distinctly. 15. The *quadratus lumborum* passing beneath the *ligamentum arcuatum externum*, this muscle has also been removed on the left side.

trachea, and nasal passages, during coughing and sneezing. To produce these efforts they all act together. Their violent and continued action produces hernia; and, acting spasmodically, they may occasion rupture of the viscera. The quadratus lumborum draws the last rib downwards, and is an expiratory muscle; it also serves to bend the vertebral column to one or the other side. The psoas parvus is a tensor of the iliac fascia, and, taking its fixed origin from below, it may assist in flexing the vertebral column forwards. The diaphragm is an inspiratory muscle, and the sole agent in tranquil inspiration. When in action, the muscle is drawn downwards, its plane being rendered oblique from the level of the ensiform cartilage, to that of the upper lumbar vertebra. During relaxation it is convex, and encroaches considerably on the cavity of the chest, particularly at the sides, where it corresponds with the lungs. It assists the abdominal muscles powerfully in expulsion, every act of that kind being preceded or accompanied by a deep inspiration. Spasmodic action of the diaphragm produces hiccough and sobbing, and its rapid alternation of contraction and relaxation, combined with laryngeal and facial movements, laughing and crying.

## MUSCLES OF THE PERINEUM.

The muscles of the perineum are situated in the outlet of the pelvis, and consist of two groups, one of which belongs especially to the organs of generation and urethra, the other to the termination of the alimentary canal. To these may be added the only pair of muscles which is proper to the pelvis, the coccygeus. The muscles of the perineal region in the male, are the

|                      |                |
|----------------------|----------------|
| Accelerator urinæ,   | Sphincter ani, |
| Erector penis,       | Levator ani,   |
| Compressor urethræ,  | Coccygeus.     |
| Transversus perinei, |                |

*Dissection.*—To dissect the perineum, the subject should be fixed in the position for lithotomy, that is, the hands should be bound to the soles of the feet, and the knees kept apart. An easier plan is the drawing of the feet upwards by means of a cord passed through a hook in the ceiling. Both of these plans of preparation have for their object the full exposure of the perineum. And as this is a dissection which demands some degree of delicacy and nice manipulation, a strong light should be thrown upon the part. Having fixed the subject, and drawn the scrotum upwards by means of a string or hook, carry an incision from the base of the scrotum along the ramus of the pubes and ischium and tuberosity of the ischium, to a point parallel with the apex of the coccyx; then describe a curve over the coccyx to the same point on the opposite side, and continue the incision onwards along the opposite tuberosity, and along the ramus of the ischium and of the pubes, to the opposite side of the scrotum, where the two extremities may be connected by a transverse incision. This incision will completely surround the perineum, following very nearly the outline of its boundaries. Now let the student dissect off the integument carefully from the whole of the included space, and he will expose the fatty cellular structure of the common superficial fascia, which exactly resembles the superficial fascia in every other situation. The common superficial

fascia is then to be removed to the same extent, exposing the superficial perineal fascia. This layer is also to be turned aside, when the muscles of the genital region of the perineum will be brought into view.

The ACCELERATORES URINÆ (bulbo-cavernosus) arise from a tendinous point in the centre of the perineum and from the fibrous raphé of the two muscles. From these origins the fibres diverge, like the plumes of a pen the posterior fibres to be inserted into the ramus of the pubes and ischium the middle to encircle the corpus spongiosum, and meet upon its upper side; and the anterior to spread out upon the corpus cavernosum on each side, and be inserted, partly into its fibrous structure, and partly into the fascia of the penis. The posterior and middle insertions of these muscles are best seen, by carefully raising one muscle from the corpus spongiosum and tracing its fibres.

*Relations.*—By their *superficial surface* with the superficial perineal fascia, the dartos, the superficial vessels and nerves of the perineum, and on each side with the erector penis. By their *deep surface* with the corpus spongiosum and bulb of the urethra.

The ERECTOR PENIS (ischio-cavernosus) arises from the ramus and tuberosity of the ischium, and curves around the root of the penis, to be inserted into the upper surface of the corpus cavernosum, where it is continuous with a strong fascia which covers the dorsum of the organ, the fascia penis.

*Relations.*—By its *superficial surface* with the superficial perineal fascia, the dartos, and the superficial perineal vessels and nerve. By its *deep surface* with the corpus cavernosum penis.

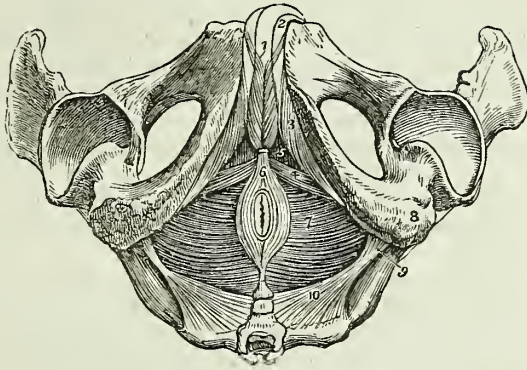
The COMPRESSOR URETHÆ (Wilson's and Guthrie's muscles), consists of two portions; one of which is *transverse* in its direction, and passes inwards, to embrace the membranous urethra; the other is *perpendicular*, and descends from the pubes. The *transverse portion*, particularly described by Mr. Guthrie, arises by a narrow tendinous point, from the upper part of the ramus of the ischium, on each side, and divides into two fasciculi, which pass inwards and slightly upwards, and embrace the membranous portion of the urethra and Cowper's glands. As they pass towards the urethra, they spread out and become fan-shaped, and are inserted into a tendinous raphé upon the upper and lower surfaces of the urethra, extending from the apex of the prostate gland, to which they are attached posteriorly, to the bulbous portion of the urethra, with which they are connected in front. When seen from above, these portions resemble two fans, connected by their expanded border along the middle line of the membranous urethra, from the prostate to the bulbous portion of the urethra. The same appearance is obtained by viewing them from below.

The *perpendicular portion*\* described by Mr. Wilson, arises by two tendinous points from the inner surface of the arch of the pubes, on each side of, and close to, the symphysis. The tendinous origins soon become muscular, and descend perpendicularly, to be inserted into the upper fasciculus of the transverse portion of the muscle; so that it is not a distinct muscle surrounding the membranous portion of the urethra, and support-

\* Mr. Tyrrell, who made many careful dissections of the muscles of the perineum, did not observe this portion of the muscle; he considers Wilson's muscle (with some other anatomists) to be the anterior fibres of the levator ani, not uniting beneath the urethra, as described by Mr. Wilson; but inserted into a portion of the pelvic fascia situated between the prostate gland and rectum, the recto-vesical fascia.

ing it as in a sling, as described by Mr. Wilson, but merely an upper origin of the transverse muscle.

Fig. 119.\*



The compressor urethræ may be considered either as two symmetrical muscles meeting at the raphé, or as a single muscle: I have adopted the latter course in the above description, as appearing to me the more consistent with the general connexions of the muscle, and with its actions.

The TRANSVERSUS PERINEI arises from the tuberosity of the ischium on each side, and is inserted into the central tendinous point of the perineum.†

*Relations.*—By its *superficial surface* with the superficial perineal fascia, and superficial perineal artery. By its *deep surface* with the deep perineal fascia, and internal pudic artery and veins. By its *posterior border* it is in relation with that portion of the superficial perineal fascia which passes back to become continuous with the deep fascia.

To dissect the *compressor urethræ*, the whole of the preceding muscles should be removed, so as to render the glistening surface of the deep perineal fascia quite apparent. The anterior layer of the fascia should then be carefully dissected away, and the corpus spongiosum penis divided through its middle, separated from the corpus cavernosum, and drawn forwards, to put the membranous portion of the urethra, upon which the muscle is spread out, on the stretch. The muscle is, however, better seen in a dissection made from within the pelvis, after having turned

\* The muscles of the perineum. 1. The accelerators urinæ muscles; the figure rests upon the corpus spongiosum penis. 2. The corpus cavernosum of one side. 3. The erector penis of one side. 4. The transversus perinei of one side. 5. The triangular space through which the deep perineal fascia is seen. 6. The sphincter ani; its anterior extremity is cut off. 7. The levator ani of the left side; the deep space between the tuberosity of the ischium (8) and the anus, is the ischio-rectal fossa; the same fossa is seen upon the opposite side. 9. The spine of the ischium. 10. The left coccygeus muscle. The boundaries of the perineum are well seen in this engraving.

† I have twice dissected a perineum in which the transversus perinei was of large size, and spread out as it approached the middle line, so as to become fan-shaped. The posterior fibres were continuous with those of the muscle of the opposite side; but the anterior were prolonged forwards upon the bulb and corpus spongiosum of the urethra, as far as the middle of the penis, forming a broad layer which usurped the place and office of the accelerator urinæ.

Down the bladder from its attachment to the os pubis, and removed a plexus of veins and the posterior layer of the deep perineal fascia.

The SPHINCTER ANI is a thin and elliptical plane of muscle closely adherent to the integument, and surrounding the opening of the anus. It *arises* posteriorly in the superficial fascia around the coccyx, and by a fibrous raphé from the apex of that bone; and is *inserted* anteriorly into the tendinous centre of the perineum, and into the raphé of the integument, nearly as far forwards as the commencement of the scrotum.

*Relations.*—By its *superficial surface* with the integument. By its *deep surface* with the internal sphincter, the levator ani, the cellular tissue and fat in the ischio-rectal fossa, and in front with the superficial perineal fascia.

The SPHINCTER ANI INTERNUS is a muscular ring embracing the extremity of the intestine, and formed by an aggregation of the circular fibres of the rectum.

Part of the levator ani may be seen during the dissection of the anal portion of the perineum, by removing the fat which surrounds the termination of the rectum in the ischio-rectal fossa. But to study the entire muscle, a lateral section of the pelvis must be made by sawing through the pubes a little to one side of the symphysis, separating the bones behind at the sacro-iliac symphysis, and turning down the bladder and rectum. The pelvic fascia is then to be carefully raised, beginning at the base of the bladder and proceeding upwards, until the whole extent of the muscle is exposed.

The LEVATOR ANI is a thin plane of muscular fibres, situated on each side of the pelvis. The muscle *arises* from the inner surface of the os pubis, from the spine of the ischium, and between those points from the angle of division between the obturator and the pelvic fascia. Its fibres descend, to be *inserted*, into the extremity of the coccyx, into a fibrous raphé in front of that bone, into the lower part of the rectum, base of the bladder, and prostate gland.

In the female, this muscle is inserted into the coccyx and fibrous raphé, lower part of the rectum and vagina.

*Relations.*—By its *external or perineal surface*, with a thin layer of fascia, by which, and by the obturator fascia, it is separated from the obturator internus muscle; with the fat in the ischio-rectal fossa, the deep perineal fascia, the levator ani, and posteriorly with the gluteus maximus. By its *internal or pelvic surface*, with the pelvic fascia, which separates it from the viscera of the pelvis and peritoneum.

The COCCYGEUS MUSCLE is a tendino-muscular layer of triangular form. It *arises* from the spine of the ischium, and is *inserted* into the side of the coccyx and lower part of the sacrum.

*Relations.*—By its *internal or pelvic surface*, with the rectum; by its *external surface*, with the lesser and greater sacro-ischiatic ligaments.

The muscles of the perineum in the female are the same as in the male, and have received analogous names. They are smaller in size, and are modified to suit the different form of the organs; they are—

Constrictor vaginæ,  
Erector clitoridis,  
Transversus perinei,  
Compressor urethræ,

Sphincter ani,  
Levator ani,  
Coccygeus.



The *Constrictor vaginae* is analogous to the *acceleratores urinæ*; it is continuous, posteriorly, with the sphincter ani, interlacing with its fibres, and is *inserted*, anteriorly, into the sides of the corpora cavernosa, and fascia of the clitoris.

The *Transversus perinei* is *inserted* into the side of the constrictor vaginae, and the levator ani into the side of the vagina.

The other muscles are precisely similar in their attachments to those in the male.

*Actions.*—The *acceleratores urinæ* being continuous at the middle line, and attached on each side to the bone, by means of their posterior fibres, will support the bulbous portion of the urethra, and acting suddenly, will propel the semen, or the last drops of urine, from the canal. The posterior and middle fibres, according to Krause,\* contribute towards the erection of the corpus spongiosum, by producing compression upon the venous structure of the bulb; and the anterior fibres, according to Tyrrell,† assist in the erection of the entire organ by compressing the vena dorsalis, by means of their insertion into the fascia penis. The erector penis becomes entitled to its name from spreading out upon the dorsum of the organ, into a membranous expansion, (*fascia penis*,) which, according to Krause, compresses the dorsal vein during the action of the muscle, and especially after the erection of the organ has commenced. The transverse muscles serve to steady the tendinous centre, that the muscles attached to it may obtain a firm point of support. According to Cruveilhier, they draw the anus backwards during the expulsion of the feces, and antagonize the levatores ani, which carry the anus forwards. The compressor urethrae, taking its fixed point from the ramus of the ischium at each side, can, says Mr. Guthrie, “compress the urethra so as to close it; I conceive completely, after the manner of a sphincter.” The transverse portion will also have a tendency to draw the urethra downwards, whilst the perpendicular portion will draw it upwards towards the os pubis. The inferior fasciculus of the transverse muscle, enclosing Cowper’s glands, will assist those bodies in evacuating their secretion. The *external sphincter*, being a cutaneous muscle, contracts the integument around the anus, and by its attachment to the tendinous centre, and to the point of the coccyx, assists the levator ani in giving support to the opening during expulsive efforts. The *internal sphincter* contracts the extremity of the cylinder of the intestine. The use of the levator ani is expressed in its name. It is the antagonist of the diaphragm and the rest of the expulsive muscles, and serves to support the rectum and vagina during their expulsive efforts. The levator ani acts in unison with the diaphragm, and rises and falls like that muscle in forcible respiration. Yielding to the propulsive action of the abdominal muscles, it enables the outlet of the pelvis to bear a greater force than a resisting structure, and on the remission of such action it restores the perineum to its original form. The coccygei muscles restore the coccyx to its natural position, after it has been pressed backwards during defæcation or during parturition.

#### MUSCLES OF THE UPPER EXTREMITY.

The muscles of the upper extremity may be arranged into groups corresponding with the different regions of the limb, thus :

\* Müller, Archiv. für Anatomie, Physiologie, &c. 1837

† Lectures in the College of Surgeons. 1839.

*Anterior Thoracic Region.*

Pectoralis major,  
Pectoralis minor,  
Subclavius.

*Anterior Scapular Region.*

Subscapularis.

*Lateral Thoracic Region.*

Serratus magnus.

*Posterior Scapular Region.*

Supra-spinatus,  
Infra-spinatus,  
Teres minor,  
Teres major.

*Acromial Region.*

Deltoid.

*Anterior Humeral Region.*

Coraco-brachialis,  
Biceps,  
Brachialis anticus.

*Posterior Humeral Region.*

Triceps.

*Anterior Brachial Region.**Superficial Layer.*

Pronator radii teres,  
Flexor carpi radialis,  
Palmaris longus,  
Flexor sublimis digitorum,  
Flexor carpi ulnaris.

*Posterior Brachial Region.**Superficial Layer.*

Supinator longus,  
Extensor carpi radialis longior,  
Extensor carpi radialis brevior,  
Extensor communis digitorum,  
Extensor minimi digiti,  
Extensor carpi ulnaris,  
Anconeus.

*Deep Layer.*

Flexor profundus digitorum,  
Flexor longus pollicis,  
Pronator quadratus.

*Deep Layer.*

Supinator brevis,  
Extensor ossis metacarpi pollicis,  
Extensor primi internodii pollicis,  
Extensor secundi internodii pollicis  
Extensor indicis.

## HAND.

*Radial Region (Thenar).*

Abductor pollicis,  
Flexor ossis metacarpi  
(opponens),  
Flexor brevis pollicis,  
Adductor pollicis.

*Ulnar Region (Hypothenar).*

Palmaris brevis,  
Abductor minimi digiti,  
Flexor brevis minimi digiti,  
Adductor minimi digiti.

*Palmar Region.*

Lumbricales,  
Interossei palmares,  
Interossei dorsales.

*Anterior Thoracic Region.*

Pectoralis major,  
Pectoralis minor,  
Subclavius.

*Dissection.* — Make an incision along the line of the clavicle, from the upper part of the sternum to the acromion process; a second along the lower border of the great pectoral muscle, from the lower end of the sternum to the insertion of its tendon into the humerus, and connect the two by a third, carried longitudinally along the middle of the sternum. The integument and superficial fascia are to be dissected together from off the fibres of the muscle, and always in the direction of their course. For this purpose the dissector, if he have the right arm, will commence with the lower angle of the flap; if the left, with the upper angle. He will thus expose the pectoralis major muscle in its whole extent.

The PECTORALIS MAJOR muscle *arises* from the sternal two-thirds of the clavicle, from one half the breadth of the sternum its whole length, from the cartilages of all the true ribs, excepting the first and last, and from the aponeurosis of the external oblique muscle of the abdomen. It is *inserted* by a broad tendon into the anterior bicipital ridge of the humerus.

That portion of the muscle which arises from the clavicle is separated from that connected with the sternum by a distinct cellular interspace; hence we speak of the *clavicular* portion and *sternal* portion of the pectoralis major. The fibres from this very extensive origin converge towards a narrow insertion, giving the muscle a radiated appearance. But there is a peculiarity about the formation of its tendon which must be carefully noted. The whole of the lower border is folded inwards upon the upper portion, so that the tendon is doubled upon itself. Another peculiarity results from this arrangement: the fibres of the upper portion of the muscle are inserted into the lower part of the bicipital ridge; and those of the lower portion, into the upper part.

*Relations.* — By its *external surface* with the fibres of origin of the platysma myoides, the mammary gland, the superficial fascia and integument. By its *internal surface*, on the thorax, with the clavicle, the sternum, the costal cartilages, intercostal muscles, subclavius, pectoralis minor, and serratus magnus; in the axilla, with the axillary vessels and glands. By its *external border* with the deltoid, from which it is separated above by a cellular interspace lodging the cephalic vein and the descending branch of the thoracico-acromialis artery. Its *lower border* forms the anterior boundary of the axillary space.

The pectoralis major is now to be removed by dividing its fibres along the lower border of the clavicle, and then carrying the incision perpendicularly downwards, parallel to the sternum, and at about three inches from its border. Divide some loose cellular tissue, and several small branches of the thoracic arteries, and reflect the muscle outwards. We thus bring into view a region of considerable interest, in the middle of which is situated the pectoralis minor.

The PECTORALIS MINOR *arises* by three digitations from the third, fourth, and fifth ribs, and is *inserted* into the anterior border of the coracoid process of the scapula by a broad tendon.

*Relations.* — By its *anterior surface* with the pectoralis major and superior thoracic vessels and nerves. By its *posterior surface* with the ribs, the intercostal muscles, serratus magnus, axillary space, and axillary vessels and nerves. Its *upper border* forms the lower boundary of a triangular space bounded above by the costo-coracoid membrane, and inter-

nally by the ribs. In this space are found the axillary vessels and nerves, and in it the subclavian artery may be tied below the clavicle.

The *SUBCLAVIUS* muscle *arises* by a round tendon from the cartilage of the first rib, and is *inserted* into the under surface of the clavicle. This muscle is concealed by the costo-coracoid membrane, an extension of the deep cervical fascia, by which it is invested.

*Relations.*—By its *upper surface* with the clavicle. By the *lower* with the subclavian artery and vein and brachial plexus, which separate it from the first rib. In *front* with the pectoralis major, the costo-coracoid membrane being interposed.

*Actions.*—The pectoralis major draws the arm against the thorax, while its upper fibres assist the upper part of the trapezius in raising the shoulder as in supporting weights. The lower fibres depress the shoulder with the aid of the latissimus dorsi. Taking its fixed point from the shoulder, the pectoralis major assists the pectoralis minor, subclavius, and serratus magnus, in drawing up and expanding the chest. The pectoralis minor, in addition to this action, draws upon the coracoid process, and assists in rotating the scapula upon the chest. The subclavius draws the clavicle downwards and forwards, and thereby assists in steadying the shoulder. All the muscles of this group are agents in forced respiration, but are incapable of acting until the shoulders are fixed.

#### *Lateral Thoracic Region.*

##### Serratus magnus.

The *SERRATUS MAGNUS* (serratus, indented like the edge of a saw), *arises* by fleshy serrations from the nine upper ribs excepting the first, and extends backwards upon the side of the chest, to be *inserted* into the whole length of the base of the scapula upon its anterior aspect. In structure the muscle is composed of three portions, a superior portion formed by two serrations attached to the second rib, and inserted into the inner surface of the superior angle of the scapula; a middle portion composed of the serrations connected with the third and fourth ribs, and inserted into the greater part of the posterior border, and an inferior portion consisting of the last five serrations which indigitate with the obliquus externus and form a thick muscular fasciculus which is inserted into the scapula near its inferior angle.

*Relations.*—By its *superficial surface* with the pectoralis major and minor, the subscapularis, and the axillary vessels and nerves. By its *deep surface* with the ribs and intercostal muscles, to which it is connected by an extremely loose cellular tissue.

*Actions.*—The serratus magnus is the great external inspiratory muscle, raising the ribs when the shoulders are fixed, and thereby increasing the cavity of the chest. Acting upon the scapula, it draws the shoulder forwards, as we see to be the case in diseased lungs, where the chest has become almost fixed from apprehension of the expanding action of the respiratory muscles.

#### *Anterior Scapular Region.*

##### Subscapularis.

The *SUBSCAPULARIS* muscle *arises* from the whole of the under surface of the scapula excepting the superior and inferior angle, and terminates by

a broad and thick tendon, which is *inserted* into the lesser tuberosity of the humerus. The substance of the muscle is traversed by several intersecting membranous layers from which muscular fibres arise, the intersections being attached to the ridges on the surface of the scapula. Its tendon forms part of the capsule of the joint, glides over a large bursa which separates it from the base of the coracoid process, and is lined by a prolongation of the synovial membrane of the articulation.

*Relations.*—By its anterior surface with the serratus magnus, coracobrachialis, and axillary vessels and nerves. By its *posterior surface* with the scapula, the subscapular vessels and nerves, and the shoulder joint.

*Action.*—It rotates the head of the humerus inwards, and is a powerful defence to the joint. When the arm is raised, it draws the humerus downwards.

#### *Posterior Scapular Region.*

Supra-spinatus,  
Infra-spinatus,

Teres minor,  
Teres major.

The SUPRA-SPINATUS muscle (*supra*, above; *spina*, the spine) *arises* from the whole of the supra-spinous fossa, and is *inserted* into the uppermost depression on the great tuberosity of the humerus. The tendon of this muscle cannot be well seen until the acromion process is removed.

*Relations.*—By its *upper surface*, with the trapezius, the clavicle, acromion, and coraco-acromion ligament. From the trapezius it is separated by a strong fascia. By its *lower surface*, with the supra-spinous fossa, the supra-scapular vessels and nerve, and the upper part of the shoulder joint, forming part of the capsular ligament.

The INFRA-SPINATUS (*infra*, beneath; *spina*, the spine) is covered in by a layer of tendinous fascia, which must be removed before the fibres of the muscle can be seen, the deltoid muscle having been previously turned down from its scapular origin. It *arises* from the whole of the infra-spinous fossa, and from the fascia above-mentioned, and is *inserted* into the middle depression upon the greater tuberosity of the humerus.

*Relations.*—By its *posterior surface*, with the deltoid, latissimus dorsi and integument. By its *anterior surface*, with the infra-spinous fossa, superior and dorsal scapular vessels, and shoulder joint; its tendon being lined by a prolongation from the synovial membrane. By its *upper border*, it is in relation with the spine of the scapula, and by the *lower*, with the teres minor, with which it is closely united.

The TERES MINOR muscle (*teres*, round) *arises* from the middle third of the inferior border of the scapula, and is *inserted* into the lower depression on the great tuberosity of the humerus. The tendons of these three muscles, with that of the subscapularis, are in immediate contact with the shoulder joint, and form part of its ligamentous capsule, thereby preserving the solidity of the articulation. They are therefore the structures most frequently ruptured in dislocation of the head of the humerus.

*Relations.*—By its *posterior surface*, with the deltoid, latissimus dorsi and integument. By its *anterior surface*, with the inferior border, and part of the dorsum of the scapula, the dorsalis scapulæ vessels, scapular head of the triceps, and shoulder joint. By its *upper border*, with the infra-spinatus; and by the *lower*, with the latissimus dorsi, teres major, and long head of the triceps.

The TERES MAJOR muscle *arises* from the lower third of the inferior border of the scapula, encroaching a little upon its dorsal aspect, and is *inserted* into the posterior bicipital ridge. Its tendon lies immediately behind that of the latissimus dorsi, from which it is separated by a synovial membrane.

*Relations.*—By its *posterior surface*, with the latissimus dorsi, scapular head of the triceps and integument. By its *anterior surface*, with the subscapularis, latissimus dorsi, coraco-brachialis, short head of the biceps, axillary vessels, and branches of the brachial plexus. By its *upper border*, it is in relation with the teres minor, from which it is separated by the scapular head of the triceps; and by the *lower*, it forms with the latissimus dorsi, the lower and posterior border of the axilla.

A large triangular space exists between the two teres muscles, which is divided into two minor spaces by the long head of the triceps.

*Actions.*—The supra-spinatus raises the arm from the side; but only feebly, from the disadvantageous direction of the force. The infra-spinatus and teres minor are rotators of the head of the humerus outwards. The most important use of these three muscles is the protection of the joint, and defence against displacement of the head of the humerus, in which action they co-operate with the subscapularis. The teres major combines, with the latissimus dorsi, in rotating the arm inwards, and at the same time carrying it towards the side, and somewhat backwards.

### *Acromial Region.*

#### Deltoid.

The convexity of the shoulder is formed by a large triangular muscle, the *deltoid* ( $\Delta$ , delta; εἶδος, resemblance), which *arises* from the outer third of the clavicle, from the acromion process, and from the whole length of the spine of the scapula. The fibres from this broad origin converge to the middle of the outer side of the humerus, where they are *inserted* into a rough triangular elevation. This muscle is remarkable for its coarse texture, and for its numerous tendinous intersections, from which muscular fibres arise. The deltoid muscle may now be cut away from its origin, and turned down, for the purpose of bringing into view the muscles and tendons placed immediately around the shoulder joint. In so doing, a large bursa will be seen between the under surface of the muscle and the head of the humerus.

*Relations.*—By its *superficial surface*, with a thin aponeurotic fascia, a few fibres of the platysma myoides, the superficial fascia and integument. By its *deep surface*, with the shoulder joint, from which it is separated by a thin tendinous fascia, and by a synovial bursa; with the coraco-acromial ligament, coracoid process, pectoralis minor, coraco-brachialis, both heads of the biceps, tendon of the pectoralis major, tendon of the supra-spinatus, infra-spinatus, teres minor, teres major, scapular and external head of the triceps, the circumflex vessels anterior and posterior, and humerus. By its *anterior border*, with the external border of the pectoralis major, from which it is separated by a cellular interspace, lodging the cephalic vein and descending branch of the thoracico-acromialis artery. Its *posterior border* is thin and tendinous above, where it is connected with the aponeurotic covering of the infra-spinatus muscle, and thick below.

*Actions.*—The deltoid is the elevator muscle of the arm in a direct

line, and by means of its extensive origin can carry the arm forwards or backwards, so as to range with the hand a considerable segment of a large circle. The arm, raised by the deltoid, is a good illustration of a lever of the third power, so common in the animal machine, by which velocity is gained at the expense of power. In this lever, the weight (hand) is at one extremity, the fulcrum (the glenoid cavity) at the opposite end, and the power (the insertion of the muscle) between the two, but nearer to the fulcrum than to the weight.

*Anterior Humeral Region.*

Coraco-brachialis,  
Biceps,  
Brachialis anticus.

*Dissection.*—These muscles are exposed, on the removal of the integument and fascia from the anterior half of the upper arm, and the clearing away of the cellular tissue.

The CORACO-BRACHIALIS, a name composed of its points of origin and insertion, *arises* from the coracoid process in common with the short head of the biceps; and is *inserted* into a rough line on the inner side of the middle of the humerus.

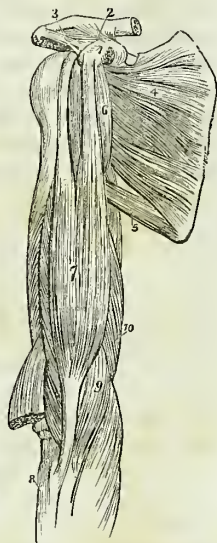
*Relations.*—By its *anterior surface* with the deltoid, and pectoralis major. By its *posterior surface*, with the shoulder joint, the humerus, subscapularis, teres major, latissimus dorsi, short head of the triceps, and anterior circumflex vessels. By its *internal border* with the axillary and brachial vessels and nerves, particularly with the median and external cutaneous nerve, by the latter of which it is pierced. By the *external border* with the short head of the biceps and brachialis anticus.

The BICEPS (*bis*—κεφαλαι, two heads) *arises* by two tendons, one the *short head*, from the coracoid process in common with the coraco-brachialis; the other the *long head*, from the upper part of the glenoid cavity. The muscle is *inserted* by a rounded tendon, into the tubercle of the radius. The long head, a long slender tendon, passes through the capsular ligament of the shoulder joint enclosed in a sheath of the synovial membrane; after leaving the cavity of the joint, it is lodged in the deep groove that separates the two tuberosities of the humerus, the bicipital groove. A small synovial bursa is interposed between the tendon of insertion, and the tubercle of the radius. *At the bend* of the elbow, the tendon of the biceps gives off from its inner side a broad tendinous band, which protects the brachial artery, and is continuous with the fascia of the fore-arm.

*Relations.*—By its *anterior surface* with the deltoid, pectoralis major, superficial and deep fascia and integument. By its *posterior surface* the

\* The muscles of the anterior aspect of the upper arm. 1. The coracoid process of the scapula. 2. The coraco-clavicular ligament (trapezoid), passing upwards to the scapular end of the clavicle. 3. The coraco-acromial ligament, passing outwards to the acromion. 4. The subscapularis muscle. 5. The teres major; the triangular space above this muscle is that through which the dorsalis scapulae vessels pass. 6. The coraco-brachialis. 7. The biceps. 8. The upper end of the radius. 9. The brachialis anticus; a portion of the muscle is seen on the outer side of the tendon of the biceps. 10. The internal head of the triceps.

Fig. 120.\*



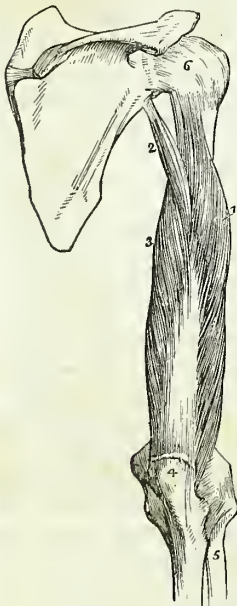
short head rests upon the subscapularis, from which it is separated by a bursa. In the rest of its extent the muscle is in relation with the humerus, the teres major, latissimus dorsi, and brachialis anticus; from the latter it is separated by the external cutaneous nerve. By its *inner border* with the coraco-brachialis, brachial artery and veins, and median nerve; the brachial vessels crossing its tendon at the bend of the elbow. By its *outer border* with the deltoid and supinator longus.

The BRACHIALIS ANTICUS is a broad muscle covering the whole of the anterior surface of the lower part of the humerus; it *arises* by two fleshy serrations from the depressions on either side of the insertion of the deltoid, from the anterior surface of the humerus, and from the intermuscular septa attached to the condyloid ridges. Its fibres converge to be *inserted* into the coronoid process of the ulna.

*Relations.*—By its *anterior surface* with the biceps, external cutaneous nerve, brachial artery and veins, and median nerve. By its *posterior surface* with the humerus, anterior ligament of the elbow joint, and intermuscular aponeurosis. The latter separates it from the triceps. By its *external border* with the supinator longus, extensor carpi radialis longior, musculo-spiral nerve, and recurrent radial artery. By its *internal border* with the intermuscular aponeurosis, which separates it from the triceps and ulnar nerve, and with the pronator radii teres.

*Actions.*—The coraco-brachialis draws the humerus inwards, and assists in flexing it upon the scapula. The biceps and brachialis anticus are flexors of the fore-arm, and the former a supinator. The brachialis anticus is a powerful protection to the elbow joint.

Fig. 121.\*



### Posterior Humeral Region.

#### Triceps extensor cubiti.

*Dissection.*—Remove the integument and fascia from the posterior aspect of the upper arm.

The TRICEPS (τρεις κεφαλαι, three heads) *arises* by three heads. Considered in relation to their length, these heads have been named long, short, and middle; and in reference to their position, internal, external, and middle; the term middle, in the former case, referring to the external head, and in the latter case to the long head. This has given rise to much confusion and misunderstanding. I shall, therefore, confine myself to the designations derived from their relations. The external head *arises* from the humerus, commencing immediately below the insertion of the teres minor, and from the intermuscular septum attached to the external condyloid ridge. The internal head (short) *arises* from the humerus, commencing immediately below the insertion of the teres major, and from the intermuscular septum attached to the internal condyloid ridge. The scapular head (long) lies between the two others, and *arises* from the upper third of the inferior border of the

\* A posterior view of the upper arm, showing the triceps muscle. 1. Its external head. 2. Its long, or scapular head. 3. Its internal, or short head. 4. The olecranon process of the ulna. 5. The radius. 6. The capsular ligament of the shoulder joint.



scapula. The three heads unite to form a broad muscle, which is *inserted* by an aponeurotic tendon into the olecranon process of the ulna; a small bursa is situated between its tendon and the upper part of the olecranon.

The scapular head of the triceps passes between the teres minor and major, and divides the triangular space between those two muscles into two smaller spaces, one of which is triangular, the other quadrangular. The *triangular space* is bounded by the teres minor, teres major, and scapular head of the triceps; it gives passage to the dorsalis scapulæ artery and veins. The *quadrangular space* is bounded on three sides by the three preceding muscles, and on the fourth by the humerus. Through this space pass the posterior circumflex artery and veins, and circumflex nerve.

A few of the deep fibres of the triceps, attached above to the humerus and below to the capsule of the elbow joint, have been named *sub-anoconeus*; they are analogous to the sub-crureus.

*Relations.*—By its *posterior surface* with the deep and superficial fascia and integument. By its *anterior surface* with the superior profunda artery, musculo-spiral nerve, humerus, intermuscular aponeuroses which separate it from the brachialis anticus, and with the elbow joint. The *scapular head* is in relation posteriorly with the deltoid and teres minor; anteriorly with the subscapularis, teres major, and latissimus dorsi; and externally with the posterior circumflex vessels and nerve.

*Actions.*—The triceps is an extensor of the fore-arm.

Fig. 122.\*

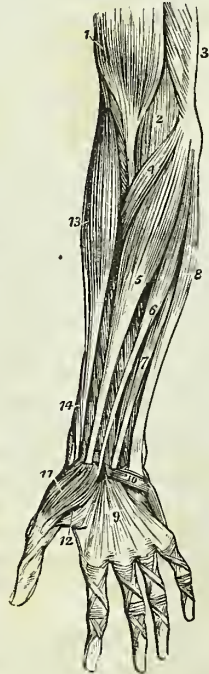
*Anterior Brachial Region.*

*Superficial Layer.*

- Pronator radii teres,
- Flexor carpi radialis,
- Palmaris longus,
- Flexor sublimis digitorum,
- Flexor carpi ulnaris.

*Dissection.*—These muscles are brought into view by making an incision through the integument along the middle line of the fore-arm, crossing each extremity by a transverse incision, and turning aside the flaps. The superficial and deep fascia are then to be removed.

The PRONATOR RADII TERES *arises* by two heads; one from the inner condyle of the humerus, fascia of the fore-arm, and intermuscular aponeurosis; the other from the coronoid process of the ulna; the median nerve passing between them. Its tendon is flat and *inserted* into the middle third of the oblique ridge of the radius. The two heads of this muscle are best examined by cutting through that which arises from the inner condyle, and turning it aside. The second head will then be seen with the median nerve lying across it.



\* Superficial layer of the muscles of the fore-arm. 1. The lower part of the biceps, with its tendon. 2. A part of the brachialis anticus, seen beneath the biceps. 3. A part of the triceps. 4. The pronator radii teres. 5. The flexor carpi radialis. 6. The pal-

*Relations.*—By its *anterior surface* with the fascia of the fore-arm, the supinator longus, extensor carpi radialis longior and brevior, radial artery and veins, and radial nerve. By its *posterior surface* with the brachialis anticus, flexor sublimis digitorum, the ulnar artery and veins, and the median nerve after it has passed between the two heads of the muscle. By its *upper border* it forms the inner boundary of the triangular space, in which the termination of the brachial artery is situated. By its *lower border* it is in relation with the flexor carpi radialis.

The FLEXOR CARPI RADIALIS arises from the inner condyle and from the intermuscular fascia. Its tendon passes through a groove formed by the scaphoid bone and trapezium, to be inserted into the base of the metacarpal bone of the index finger.

*Relations.*—By its *anterior surface* with the fascia of the fore-arm, and at the wrist with the tendinous canal through which its tendon passes. By its *posterior surface* with the flexor sublimis digitorum, flexor longus pollicis, wrist-joint, and groove in the scaphoid and trapezium bones. By its *outer border* with the pronator radii teres, and radial artery and veins. By its *inner border* with the palmaris longus. The tendon is surrounded by a synovial membrane where it plays through the tendinous canal of the wrist.

The PALMARIS LONGUS is a small muscle which arises from the inner condyle, and from the intermuscular fascia. It is inserted into the annular ligament and palmar fascia. Occasionally this muscle is wanting.

*Relations.*—By its *anterior surface* with the fascia of the fore-arm. By the *posterior surface* with the flexor sublimis digitorum: to the *external side* by the flexor carpi radialis; and to the *internal side* by the flexor carpi ulnaris.

Cut the flexor carpi radialis and palmaris longus from their origins, in order to obtain a good view of the whole extent of origin of the flexor sublimis digitorum.

The FLEXOR SUBLIMIS DIGITORUM (perforatus) arises from the inner condyle, internal lateral ligament, coronoid process of the ulna, and oblique line of the radius. The median nerve and ulnar artery pass between its origins. It divides into four tendons, which pass beneath the annular ligament into the palm of the hand, and are inserted into the base of the second phalanges of the fingers, splitting at their terminations to give passage to the tendons of the deep flexors; thence its designation, *perforates*. In the thecæ of the fingers several small tendinous fasciculi are generally found, which pass between the phalanges and the edges of the tendons; these have been termed the *vincula accessoria*.

*Relations.*—In the fore-arm. By its *anterior surface* with the pronator radii teres, flexor carpi radialis, palmaris longus, flexor carpi ulnaris, and the deep fascia. By its *posterior surface* with the flexor profundus digitorum, flexor longus pollicis, ulnar artery, veins and nerve, and median nerve. This muscle frequently sends a fasciculus to the flexor longus pollicis or flexor profundus. In the hand: its tendons, after passing be-

maris longus. 7 One of the fasciculi of the flexor sublimis digitorum; the rest of the muscle is seen beneath the tendons of the palmaris longus and flexor carpi radialis. 8. The flexor carpi ulnaris. 9. The palmar fascia. 10. The palmaris brevis muscle. 11. The abductor pollicis muscle. 12. One portion of the flexor brevis pollicis; the leading line crosses a part of the adductor pollicis. 13. The supinator longus muscle. 14. The extensor ossis metacarpi, and extensor primi internodii pollicis, curving around the lower border of the fore-arm.

neath the annular ligament, are in relation *superficially* with the superficial palmar arch, and palmar fascia; and *deeply* with the tendons of the deep flexor and lumbricales.

The FLEXOR CARPI ULNARIS arises by two heads, one from the inner condyle, the other from the olecranon and upper two-thirds of the inner border of the ulna. Its tendon is *inserted* into the pisiform bone, and base of the metacarpal bone of the little finger.

*Relations.*—By its *anterior surface* with the fascia of the fore-arm, with which it is closely united superiorly. By its *posterior surface* with the flexor sublimis digitorum, flexor profundus, pronator quadratus, and ulnar artery, veins, and nerve. By its *radial border* with the palmaris longus, and in the lower third of the fore-arm with the ulnar vessels and nerve. The ulnar nerve, and the posterior ulnar recurrent artery, pass between its two heads of origin.

*Deep layer.*

Flexor profundus digitorum,  
Flexor longus pollicis,  
Pronator quadratus.

*Dissection.*—This group is brought into view by removing the flexor sublimis, and drawing aside the pronator radii teres.

The FLEXOR PROFUNDUS DIGITORUM (perforans) arises from the upper two-thirds of the ulna and part of the interosseous membrane, and terminates in four tendons, which pass beneath the annular ligament, and between the two slips of the tendons of the flexor sublimis (hence its designation, perforans), to be *inserted* into the base of the last phalanges. The tendon of the index finger is always distinct from the rest, the other three tendons being more or less intimately connected by the cellular tissue and tendinous slips.

Four little muscular fasciculi, called *lumbricales*, are connected with the tendons of this muscle in the palm. They will be described with the muscles of the hand.

*Relations.*—In the fore-arm. By its *anterior surface* with the flexor sublimis digitorum, flexor carpi ulnaris, median nerve, and ulnar artery, veins, and nerve. By its *posterior surface* with the ulna, the interosseous membrane, the pronator quadratus, and the wrist joint. By its *radial border* with the flexor longus pollicis, the anterior interosseous artery and nerve being interposed. By its *ulnar border* with the flexor carpi ulnaris. In the hand: its tendons are in relation *superficially* with the tendons of the superficial flexor; and *deeply* with the interossei muscles, adductor pollicis, and deep palmar arch. In the fingers: the tendons of the deep flexor are interposed between the tendons of the superficial flexor and the phalanges, and give attachment to vincula accessoria.

The FLEXOR LONGUS POLLICIS arises from the upper two-thirds of the radius, and part of the interosseous membrane. Its tendon passes beneath the annular ligament, to be *inserted* into the base of the last phalanx of the thumb.

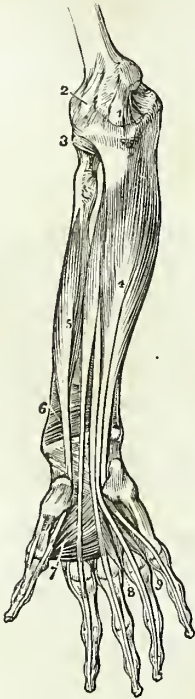
*Relations.*—By its *anterior surface* with the flexor sublimis digitorum, flexor carpi radialis, supinator longus, and radial artery and veins. By its *posterior surface* with the radius, interosseous membrane, pronator quadratus, and wrist joint. By its *ulnar border* it is separated from the flexor profundus digitorum by the anterior interosseous artery and nerve

In the hand: after passing beneath the annular ligament, it is lodged in the interspace between the two portions of the flexor brevis pollicis, and afterwards in the tendinous theca of the phalanges.

If the tendons of the last two muscles be drawn aside or divided, the third muscle of this group will be brought into view, lying across the lower part of the two bones.

The PRONATOR QUADRATUS arises from the ulna, and is inserted into the lower fourth of the oblique line, on the outer side of the radius. This muscle occupies about the lower fourth of the two bones, is broad at its origin, and narrower at its insertion.

Fig. 123.\*



*Relations.*—By its *anterior surface* with the tendons of the supinator longus, flexor carpi radialis, flexor longus pollicis, flexor profundus digitorum, and flexor carpi ulnaris, radial artery and veins, and ulnar artery, veins, and nerve. By its *posterior surface* with the radius, ulna, and interosseous membrane.

*Actions.*—The pronator radii teres and pronator quadratus muscles rotate the radius upon the ulna, and render the hand prone. The remaining muscles are flexors: two flexors of the wrist, flexor carpi radialis and ulnaris; two of the fingers, flexor sublimis and profundus, the former flexing the second phalanges, the latter the last; one flexor of the last phalanx of the thumb, flexor longus pollicis. The palmaris longus is primarily a tensor of the palmar fascia, and secondarily a flexor of the wrist and forearm.

### Posterior Brachial Region.

#### Superficial layer.

Supinator longus,  
Extensor carpi radialis longior,  
Extensor carpi radialis brevior,  
Extensor communis digitorum,  
Extensor minimi digiti,  
Extensor carpi ulnaris,  
Anconeus.

*Dissection.*—The integument is to be divided and turned aside, and the fasciæ removed in the same manner as for the anterior brachial region.

The SUPINATOR LONGUS muscle is placed along the radial border of the forearm. It arises from the external condyloid ridge of the humerus, nearly as high as the insertion of the deltoid, and is inserted into the base of the styloid process of the radius.

*Relations.*—By its *superficial surface* with the extensor ossis metacarpi pollicis, extensor primi internodii pollicis, and fascia of the forearm. By

\* The deep layer of muscles of the forearm. 1. The internal lateral ligament of the elbow joint. 2. The anterior ligament. 3. The orbicular ligament of the head of the radius. 4. The flexor profundus digitorum muscle. 5. The flexor longus pollicis. 6. The pronator quadratus. 7. The adductor pollicis muscle. 8. The dorsal interosseous muscle of the middle finger, and palmar interosseous of the ring finger. 9. The dorsal interosseous muscle of the ring finger, and palmar interosseous of the little finger.

its *deep surface* with the brachialis anticus, extensor carpi radialis longior, tendon of the biceps, supinator brevis, pronator radii teres, flexor carpi radialis, flexor sublimis digitorum; flexor longus pollicis, pronator quadratus, radius, musculo-spiral nerve, radial and posterior interosseous nerve, and radial artery and veins.

This muscle must be divided through the middle, and the two ends turned to either side to expose the next muscle.

The **EXTENSOR CARPI RADIALIS LONGIOR** arises from the external condyloid ridge below the preceding, and from the intermuscular fascia. Its tendon passes through a groove in the radius, immediately behind the styloid process, to be *inserted* into the base of the metacarpal bone of the index finger.

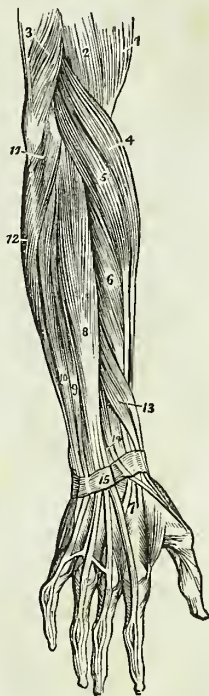
*Relations.*—By its *superficial surface*, with the supinator longus, extensor ossis metacarpi pollicis, extensor primi internodii pollicis, extensor secundi internodii pollicis, radial nerve, fascia of the forearm, and posterior annular ligament. By its *deep surface*, with the brachialis anticus, extensor carpi radialis brevior, radius and wrist joint.

The **EXTENSOR CARPI RADIALIS BREVIOR** is seen by drawing aside the former muscle. It arises from the external condyle of the humerus and intermuscular fascia, and is *inserted* into the base of the metacarpal bone of the middle finger. Its tendon is lodged in the same groove, on the radius, with the extensor carpi radialis longior.

*Relations.*—By its *superficial surface*, with the extensor carpi radialis longior, extensor ossis metacarpi pollicis, extensor primi internodii pollicis, extensor secundi internodii pollicis, fascia of the forearm, and posterior annular ligament. By its *deep surface*, with the supinator brevis, tendon of the pronator radii teres, radius and wrist joint. By its *ulnar border*, with the extensor communis digitorum.

The **EXTENSOR COMMUNIS DIGITORUM** arises from the external condyle, and intermuscular fascia; and divides into four tendons, which are *inserted* into the second and third phalanges of the fingers. At the metacarpophalangeal articulation, each tendon becomes narrow and thick, and sends a thin fasciculus upon each side of the joint. It then spreads out, and receiving the tendon of the lumbricalis, and some tendinous fasciculi from

Fig. 124.\*



\* The superficial layer of muscles of the posterior aspect of the fore-arm. 1. The lower part of the biceps. 2. Part of the brachialis anticus. 3. The lower part of the triceps, inserted into the olecranon. 4. The supinator longus. 5. The extensor carpi radialis longior. 6. The extensor carpi radialis brevior. 7. The tendons of insertion of these two muscles. 8. The extensor communis digitorum. 9. The extensor minimi digiti. 10. The extensor carpi ulnaris. 11. The anconeus. 12. Part of the flexor carpi ulnaris. 13. The extensor ossis metacarpi and extensor primi internodii muscle, lying together. 14. The extensor secundi internodii; its tendon is seen crossing the two tendons of the extensor carpi radialis longior and brevior. 15. The posterior annular ligament. The tendons of the common extensor are seen upon the back of the hand, and their mode of distribution on the dorsum of the fingers.

the interossei, forms a broad aponeurosis, which covers the whole of the posterior aspect of the finger. At the first phalangeal joint, the aponeurosis divides into three slips. The middle slip is inserted into the base of the second phalanx, and the two lateral portions are continued onwards on each side of the joint, to be inserted into the last. Little oblique tendinous slips connect the tendons of the middle, ring, and little finger, as they cross the back of the hand.

*Relations.*—By its *superficial surface*, with the fascia of the fore-arm and back of the hand, and with the posterior annular ligament. By its *deep surface*, with the supinator brevis, extensor ossis metacarpi pollicis, extensor primi internodii, extensor secundi internodii, extensor indicis, posterior interosseous artery and nerve, wrist joint, metacarpal bones and interossei muscles, and phalanges. By its *radial border*, with the extensor carpi radialis longior and brevior. By the *ulnar border*, with the extensor minimi digiti, and extensor carpi ulnaris.

The EXTENSOR MINIMI DIGITI (auricularis) is an offset from the extensor communis, with which it is connected by means of a tendinous slip. Passing down to the inferior extremity of the ulna, it traverses a distinct fibrous sheath, and at the metacarpo-phalangeal articulation unites with the tendon derived from the common extensor. The common tendon then spreads out into a broad expansion, which divides into three slips, to be *inserted*, as in the other fingers, into the last two phalanges. It is to this muscle that the little finger owes its power of separate extension; and from being called into action when the point of the finger is introduced into the meatus of the ear, for the purpose of removing unpleasant sensations or producing titillation, the muscle was called by the old writers “auricularis.”

The EXTENSOR CARPI ULNARIS *arises* from the external condyle and from the upper two-thirds of the border of the ulna. Its tendon passes through the posterior groove, in the lower extremity of the ulna, to be *inserted* into the base of the metacarpal bone of the little finger.

*Relations.*—By its *superficial surface*, with the fascia of the fore-arm, and posterior annular ligament. By its *deep surface*, with the supinator brevis, extensor ossis metacarpi pollicis, extensor secundi internodii, extensor indicis, ulna, and wrist joint. By its *radial border*, it is in relation with the extensor communis digitorum, and extensor minimi digiti: and by the *ulnar border*, with the anconeus.

The ANCONEUS is a small triangular muscle, having the appearance of being a continuation of the triceps; it *arises* from the outer condyle, and is *inserted* into the olecranon and triangular surface on the upper extremity of the ulna.

*Relations.*—By its *superficial surface* with a strong tendinous aponeurosis derived from the triceps. By its *deep surface* with the elbow joint, orbicular ligament, and slightly with the supinator brevis.

#### *Deep Layer.*

Supinator brevis,  
Extensor ossis metacarpi pollicis,  
Extensor primi internodii pollicis,  
Extensor secundi internodii pollicis,  
Extensor indicis.

*Dissection.*—The muscles of the superficial layer should be removed in order to bring the deep group completely into view.

The SUPINATOR BREVIS cannot be seen in its entire extent until the radial extensors of the carpus are divided from their origin. It arises from the external condyle, from the external lateral and orbicular ligament, and from the ulna, and winds around the upper part of the radius, to be inserted into the upper third of its oblique line. The posterior interosseous artery and nerve are seen perforating the lower border of this muscle.

*Relations.*—By its superficial surface with the pronator radii teres, supinator longus, extensor carpi radialis longior and brevior, extensor communis digitorum, extensor carpi ulnaris, anconeus, the radial artery and veins, the musculo-spiral nerve, radial and posterior interosseous nerve. By its deep surface with the elbow-joint and its ligaments, the interosseous membrane, and the radius.

The EXTENSOR OSSIS METACARPI POLLICIS is placed immediately below the supinator brevis. It arises from the ulna, interosseous membrane, and radius, and is inserted, as its name implies, into the base of the metacarpal bone of the thumb. Its tendon passes through the groove immediately in front of the styloid process of the radius.

*Relations.*—By its superficial surface with the extensor carpi ulnaris, extensor minimi digiti, extensor communis digitorum, fascia of the forearm, and annular ligament. By its deep surface with the ulna, interosseous membrane, radius, tendons of the extensor carpi radialis longior and brevior, and supinator longus, and at the wrist with the radial artery. By its upper border with the edge of the supinator brevis. By its lower border with the extensor secundi and primi internodii. The muscle is crossed by branches of the posterior interosseous artery and nerve.

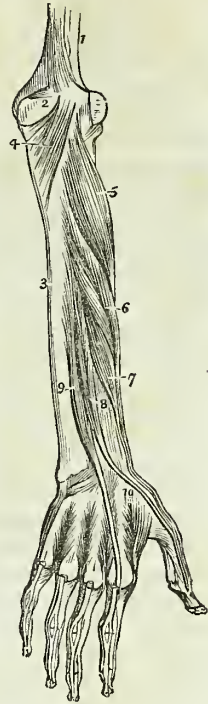
The EXTENSOR PRIMI INTERNODII POLLICIS, the smallest of the muscles in this layer, arises from the interosseous membrane and ulna, and passes through the same groove with the extensor ossis metacarpi, to be inserted into the base of the first phalanx of the thumb.

*Relations.*—The same as those of the preceding muscle with the exception of the extensor carpi ulnaris. The muscle accompanies the extensor ossis metacarpi.

The EXTENSOR SECUNDI INTERNODII POLLICIS arises from the ulna, and interosseous membrane. Its tendon passes through a distinct canal in the annular ligament, and is inserted into the base of the last phalanx of the thumb.

\* The deep layer of muscles on the posterior aspect of the forearm. 1. The lower part of the humerus. 2. The olecranon. 3. The ulna. 4. The anconeus muscle. 5. The supinator brevis muscle. 6. The extensor ossis metacarpi pollicis. 7. The extensor primi internodii pollicis. 8. The extensor secundi internodii pollicis. 9. The extensor indicis. 10. The first dorsal interosseous muscle. The other three dorsal interossei are seen between the metacarpal bones of their respective fingers.

Fig 125.\*



*Relations.*—By its *external surface* with the same relations as the extensor ossis metacarpi. By its *deep surface* with the ulna, interosseous membrane, radius, wrist joint, radial artery, and metacarpal bone of the thumb. The muscle is placed between the extensor primi internodii and extensor indicis.

The EXTENSOR INDICIS arises from the ulna, as high up as the extensor ossis metacarpi pollicis, and from the interosseous membrane. Its tendon passes through a distinct groove in the radius, and is inserted into the aponeurosis formed by the common extensor tendon of the index finger.

*Relations.*—The same as those of the preceding muscle, with the exception of the hand, where the tendon rests upon the metacarpal bone of the fore finger and second interosseous muscle, and has no relation with the radial artery.

The tendons of the extensors, as of the flexor muscles of the fore-arm, are provided with synovial bursæ as they pass beneath the annular ligaments: those of the back of the wrist have distinct sheaths, formed by the posterior annular ligament.

*Actions.*—The anconeus is associated in its action with the triceps extensor cubiti: it assists in extending the fore-arm upon the arm. The supinator longus and brevis effect the supination of the fore-arm, and antagonize the two pronators. The extensor carpi radialis longior and brevior, and ulnaris, extend the wrist in opposition to the two flexors of the carpus. The extensor communis digitorum restores the fingers to the straight position, after being flexed by the two flexors, sublimis and profundus. The extensor ossis metacarpi, primi internodii, and secundi internodii pollicis, are the especial extensors of the thumb, and serve to balance the actions of the flexor ossis metacarpi, flexor brevis, and flexor longus pollicis. The extensor indicis gives the character of extension to the index finger, and is hence named “indicator,” and the extensor minimi digiti supplies that finger with the power of exercising a distinct extension.

#### MUSCLES OF THE HAND.

##### *Radial or Thenar Region.*

|                                    |                         |
|------------------------------------|-------------------------|
| Abductor pollicis,                 | Flexor brevis pollicis, |
| Flexor ossis metacarpi (opponens), | Adductor pollicis.      |

*Dissection.*—The hand is best dissected by making an incision along the middle of the palm, from the wrist to the base of the fingers, and crossing it at each extremity by a transverse incision, then turning aside the flaps of integument. For exposing the muscles of the radial region, the removal of the integument and fascia on the radial side will be sufficient.

The ABDUCTOR POLLICIS is a small, thin muscle, which arises from the scaphoid bone and annular ligament. It is inserted into the base of the first phalanx of the thumb.

*Relations.*—By its *superficial surface*, with the external portion of the palmar fascia. By its *deep surface*, with the flexor ossis metacarpi. On its *inner side* it is separated by a narrow cellular interspace from the flexor brevis pollicis.

This muscle must be divided from its origin and turned upwards, in order to see the next.



The FLEXOR OSSIS METACARPI (opponens pollicis) arises from the trapezium and annular ligament, and is inserted into the whole length of the metacarpal bone.

*Relations.*—By its superficial surface, with the abductor pollicis. By its deep surface, with the trapezio-metacarpal articulation, and with the metacarpal bone. Internally, with the flexor brevis pollicis.

The flexor ossis metacarpi may now be divided from its origin and turned aside, in order to show the next muscle.

The FLEXOR BREVIS POLLICIS consists of two portions, between which lies the tendon of the flexor longus pollicis. The external portion arises from the trapezium and annular ligament; the internal portion, from the trapezoides and os magnum. They are both inserted into the base of the first phalanx of the thumb, having a sesamoid bone in each of their tendons, to protect the joint.

*Relations.*—By its superficial surface, with the external portion of the palmar fascia. By its deep surface, with the adductor pollicis, tendon of the flexor carpi radialis, and trapezio-metacarpal articulation. By its external surface, with the flexor ossis metacarpi and metacarpal bone. By its inner surface, with the tendons of the long flexor muscles and first lumbricalis.

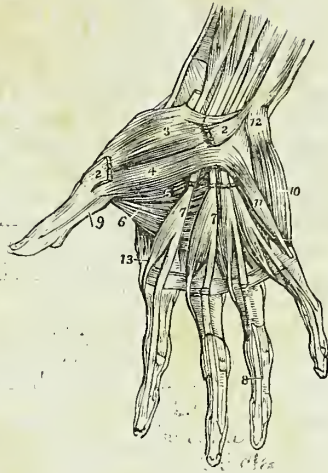
The ADDUCTOR POLLICIS is a triangular muscle; it arises from the whole length of the metacarpal bone of the middle finger; and the fibres converge to its insertion into the base of the first phalanx.

*Relations.*—By its anterior surface with the flexor brevis pollicis, tendons of the deep flexor of the fingers, lumbricales, and deep palmar arch. By its posterior surface with the metacarpal bones of the index and middle fingers, the interossei of the second interosseous space, and the abductor indicis. Its inferior border is subcutaneous.

#### Ulnar, or Hypothenar Region.

Palmaris brevis,  
Abductor minimi digiti,  
Flexor brevis minimi digiti,  
Flexor ossis metacarpi (adductor).

Fig. 126.\*



\* The muscles of the hand. 1. The annular ligament. 2, 2. The origin and insertion of the abductor pollicis muscle; the middle portion has been removed. 3. The flexor ossis metacarpi, or opponens pollicis. 4. One portion of the flexor brevis pollicis. 5. The deep portion of the flexor brevis pollicis. 6. The adductor pollicis. 7, 7. The lumbricales muscles, arising from the deep flexor tendons, upon which the numbers are placed. The tendons of the flexor sublimis have been removed from the palm of the hand. 8. One of the tendons of the deep flexor, passing between the two terminal slips of the tendon of the flexor sublimis, to reach the last phalanx. 9. The tendon of the flexor longus pollicis, passing between the two portions of the flexor brevis to the last phalanx. 10. The abductor minimi digiti. 11. The flexor brevis minimi digiti. The edge of the flexor ossis metacarpi, or adductor minimi digiti, is seen projecting beyond the inner border of the flexor brevis. 12. The prominence of the pisiform bone. 13. The first dorsal interosseous muscle.

*Dissection.*—Turn aside the ulnar flap of integument in the palm of the hand: in doing this, a subcutaneous muscle, the palmaris brevis will be exposed. After examining this muscle remove it with the deep fascia, in order to bring into view the muscles of the little finger.

The PALMARIS BREVIS is a thin plane of muscular fibres which *arises* from the annular ligament and palmar fascia, and passes transversely inwards, to be *inserted* into the integument on the inner border of the hand.

*Relations.*—By its *superficial surface* with the fat and integument of the ball of the little finger. By its *deep surface* with the internal portion of the palmar fascia, which separates it from the ulnar artery veins, and nerve, and from the muscles of the inner border of the hand.

The ABDUCTOR MINIMI DIGITI is a small tapering muscle which *arises* from the pisiform bone, and is *inserted* into the base of the first phalanx of the little finger.

*Relations.*—By its *superficial surface* with the internal portion of the deep fascia and the palmaris brevis: by its *deep surface* with the flexor ossis metacarpi and metacarpal bone. By its *inner border* with the flexor brevis minimi digiti.

The FLEXOR BREVIS MINIMI DIGITI is a small muscle *arising* from the unciform bone and annular ligament, and *inserted* into the base of the first phalanx. It is sometimes wanting.

*Relations.*—By its *superficial surface* with the internal portion of the palmar fascia, and the palmaris brevis. By its *deep surface* with the flexor ossis metacarpi, and metacarpal bone. *Externally* with the abductor minimi digiti, from which it is separated near its origin by the deep palmar branch of the ulnar nerve and communicating artery. *Internally* with the tendons of the flexor sublimis and profundus.

The FLEXOR OSSIS METACARPI (adductor, opponens) *arises* from the unciform bone and annular ligament, and is *inserted* into the whole length of the metacarpal bone of the little finger.

*Relations.*—By its *superficial surface* with the flexor brevis and abductor minimi digiti. By its *deep surface* with the interossei muscles of the last metacarpal space, the metacarpal bone, and the flexor tendons of the little finger.

#### *Palmar Region.*

Lumbricales,  
Interossei palmares,  
Interossei dorsales.

The LUMBRICALES, four in number, are accessories to the deep flexor muscle. They *arise* from the tendons of the deep flexor; the first and second from the palmar side, the third from the ulnar, and the fourth from the radial side; and are *inserted* into the aponeurotic expansion of the extensor tendons on the radial side of the fingers. The third, or that of the tendon of the ring finger, sometimes bifurcates, otherwise it is inserted wholly into the extensor tendon of the middle finger.

*Relations.*—In the palm of the hand with the flexor tendons; at their insertion, with the tendons of the interossei and the metacarpo-phalangeal articulations.

The PALMAR INTEROSSEI, three in number, are placed upon the metacarpal bones, rather than between them. They *arise* from the base of the metacarpal bone of one finger, and are *inserted* into the base of the first

Fig. 127 \*

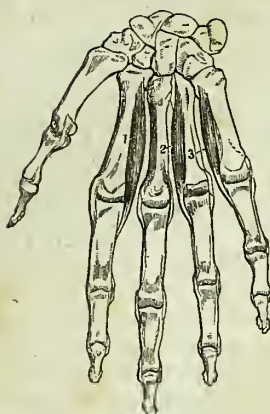
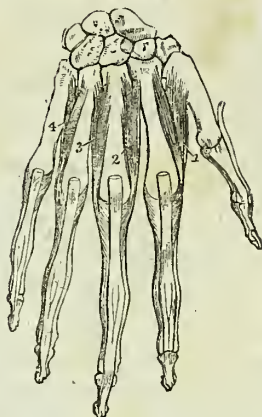


Fig. 128 †



phalanx and aponeurotic expansion of the extensor tendon of the same finger. The first belongs to the index finger; the second to the ring finger; and the third to the little finger; the middle finger being excluded.

*Relations.*—By their *palmar surface* with the flexor tendons and with the deep muscles in the palm of the hand. By their *dorsal surface* with the dorsal interossei. On one side with the metacarpal bone, on the other with the corresponding dorsal interosseous.

**DORSAL INTEROSSEI.**—On turning to the dorsum of the hand, the four *dorsal interossei* are seen in the four spaces between the metacarpal bones. They are bipenniform muscles and *arise* by two heads, from the adjoining sides of the base of the metacarpal bones. They are *inserted* into the base of the first phalanges, and aponeurosis of the extensor tendons.

The first is inserted into the index finger, and from its use is called abductor indicis, † the second and third are inserted into the middle finger compensating its exclusion from the palmar group; the fourth is attached to the ring finger; so that each finger is provided with two interossei, with the exception of the little finger, as may be shown by means of a table, thus:—

|                       |   |                                |
|-----------------------|---|--------------------------------|
| <i>Index finger,</i>  | { | one dorsal (abductor indicis), |
|                       |   | one palmar.                    |
| <i>Middle finger,</i> |   | two dorsal.                    |
| <i>Ring finger,</i>   | { | one palmar,                    |
|                       |   | one dorsal.                    |
| <i>Little finger,</i> |   | remaining palmar.              |

*Relations.*—By their *dorsal surface* with a thin aponeurosis which separates them from the tendons on the dorsum of the hand. By their *palmar*

\* Palmar interossei. 1. Adductor indicis. 2. Abductor annularis. 3. Interosseous auricularis.

† Dorsal interossei. 1. Abductor indicis. 2. Abductor medii. 3. Adductor medii. 4. Adductor annularis.

‡ Horner divides this muscle and calls one portion of it *abductor indicis* and the other *prior indicis*. Wilson's description is the best, as it makes the analogy between the foot and hand complete, whilst there is a great discrepancy in Horner's mode of describing them.—G.

*surface* with the muscles and tendons in the palm of the hand. By one side with the metacarpal bone ; by the other with the corresponding palmar interosseous. The abductor indicis is in relation by its palmar surface with the adductor pollicis, the arteria magna pollicis being interposed. The radial artery passes into the palm of the hand between the two heads of the first dorsal interosseous muscle and the perforating branches of the deep palmar arch, between the heads of the other dorsal interossei.

*Actions.*—The actions of the muscles of the hand are expressed in their names. Those of the radial region belong to the thumb, and provide for three of its movements, *abduction*, *adduction*, and *flexion*. The ulnar group, in like manner, are subservient to the same motions of the little finger, and the interossei are abductors and adductors of the several fingers. The lumbricales are accessory in their actions to the deep flexors: they were called by the earlier anatomists, *fidicini*, *i. e.* fiddlers' muscles, from an idea that they might effect the fractional movements by which the performer is enabled to produce the various notes on that instrument.

In relation to the axis of the hand, the four *dorsal* interossei are *abductors*, and the three palmar, *adductors*. It will therefore be seen that each finger is provided with its proper adductor and abductor, two flexors, and (with the exception of the middle and ring fingers) two extensors. The thumb has moreover a flexor and extensor of the metacarpal bone ; and the little finger a flexor of the metacarpal bone without an extensor.

#### MUSCLES OF THE LOWER EXTREMITY.

The muscles of the lower extremity may be arranged into groups corresponding with the regions of the hip, thigh, leg, and foot, as in the following table :—

##### HIP.

###### *Gluteal Region.*

|                    |                     |
|--------------------|---------------------|
| Gluteus maximus,   | Gluteus medius,     |
| Gluteus minimus,   | Pyriformis,         |
| Gemellus superior, | Obturator internus, |
| Gemellus inferior, | Obturator externus. |
| Quadratus femoris. |                     |

##### THIGH.

###### *Anterior Femoral Region.*

Tensor vaginæ femoris,  
Sartorius,  
Rectus,  
Vastus internus,  
Vastus externus.  
Crureus.

###### *Internal Femoral Region.*

Iliacus internus,  
Psoas magnus,  
Pectineus,  
Adductor longus,  
Adductor brevis,  
Adductor magnus,  
Gracilis.

###### *Posterior Femoral Region.*

Biceps,  
Semitendinosus,  
Semimembranosus.

## LEG.

*Anterior Tibial Region.*

Tibialis anticus,  
Extensor longus digitorum,  
Peroneus tertius,  
Extensor longus pollicis.

*Fibular Region.*

Peroneus longus,  
Peroneus brevis.

*Posterior Tibial Region.**Superficial Group.*

Gastrocnemius,  
Plantaris,  
Soleus.

*Deep [posterior] Layer.*

Popliteus,  
Flexor longus pollicis,  
Flexor longus digitorum,  
Tibialis posticus.

## FOOT.

*Dorsal Region.*

Extensor brevis digitorum,  
Interossei dorsales.

*Plantar Region.**1st Layer.*

Abductor pollicis,  
Abductor minimi digiti,  
Flexor brevis digitorum.

*2d Layer.*

Musculus accessorius,  
Lumbricales.

*3d Layer.*

Flexor brevis pollicis,  
Adductor pollicis,  
Flexor brevis minimi digiti,  
Transversus pedis.

*4th Layer.*

Interossei plantares.

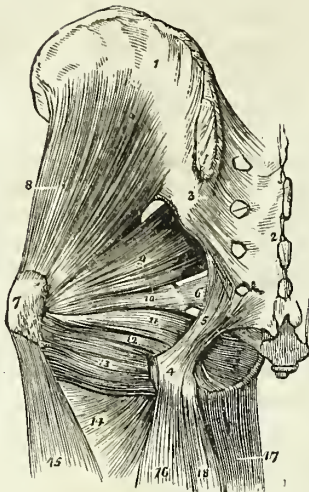
## GLUTEAL REGION.

Gluteus maximus,  
Gluteus medius,  
Gluteus minimus,  
Pyriformis,  
Gemellus superior,

Obturator internus,  
Gemellus inferior,  
Obturator externus,  
Quadratus femoris.

*Dissection.* — The subject being turned on its face, and a block placed beneath the os pubis to support the pelvis, the student commences the dissection of this region, by carrying an incision from the apex of the coccyx along the crest of the ilium to its anterior superior spinous process; or *vice versa*, if he be on the left side. He then makes an incision from the posterior fifth of the crest of the ilium, to the apex of the trochanter major, this marks the upper border of the gluteus maximus; and a third incision from the apex of the coccyx along the fleshy margin of the lower border of the gluteus maximus, to the outer side of the thigh, about four inches below the apex of the trochanter major. He then reflects the integument, superficial fascia, and deep fascia, which latter is very thin over this muscle, from the gluteus maximus, following rigidly the course of its fibres; and having exposed the muscle in its entire extent, he dissects the integument and superficial fascia from off the deep fascia which binds down the gluteus medius, the other portion of this region.

Fig. 129.\*



The **GLUTEUS MAXIMUS** ( $\gamma\lambda\omicron\upsilon\tau\omicron\varsigma$ , nates) is the thick, fleshy mass of muscle, of a quadrangular shape, which forms the convexity of the nates. In structure, it is extremely coarse, being made up of large fibres, which are collected into fasciculi, and these again into distinct muscular masses, separated by deep cellular furrows. It *arises* from the posterior fifth of the crest of the ilium, from the posterior surface of the sacrum and coccyx, and from the great sacro-ischiatic ligament. It passes obliquely outwards and downwards, to be *inserted* into the rough line leading from the trochanter major to the linea aspera, and is continuous by means of its tendon with the fascia lata covering the outer side of the thigh. A large bursa is situated between the broad tendon of this muscle and the femur.

*Relations.*—By its *superficial surface* with a thin aponeurotic fascia, which separates it from the superficial fascia and integument, and with the vastus externus, a bursa being interposed. By its *deep surface* with the gluteus medius, pyriformis, gemelli, obturator internus, quadratus femoris, sacro-ischiatic foramina, great sacro-ischiatic ligament, tuberosity of the ischium, semimembranosus, semitendinosus, biceps, and adductor magnus; the gluteal vessels and nerves, ischiatic vessels and nerves, and internal pudic vessels and nerve. By its *upper border* it overlaps the gluteus medius; and by the *lower border* forms the lower margin of the nates.

The gluteus maximus must be turned down from its origin, in order to bring the next muscle into view.

The **GLUTEUS MEDIUS** is placed in front of, rather than beneath the gluteus maximus; and is covered in by a process of the deep fascia, which is very thick and dense. It *arises* from the outer lip of the crest of the ilium for four-fifths of its length, from the surface of bone between that border and the superior curved line on the dorsum ilii, and from the dense fascia above-mentioned. Its fibres converge to the outer part of the trochanter major, into which its tendon is *inserted*.

*Relations.*—By its *superficial surface* with the tensor vaginæ femoris, gluteus maximus, and its fascia. By its *deep surface* with the gluteus minimus, and gluteal vessels and nerves. By its *lower border* with the pyriformis muscle. A bursa is interposed between its tendon and the upper part of the trochanter major.

\* The deep muscles of the gluteal region. 1. The external surface of the ilium. 2. The posterior surface of the sacrum. 3. The posterior sacro-iliac ligaments. 4. The tuberosity of the ischium. 5. The great or posterior sacro-ischiatic ligament. 6. The lesser or anterior sacro-ischiatic ligament. 7. The trochanter major. 8. The gluteus minimus. 9. The pyriformis. 10. The gemellus superior. 11. The obturator internus muscle, passing out of the lesser sacro-ischiatic foramen. 12. The gemellus inferior. 13. The quadratus femoris. 14. The upper part of the adductor magnus. 15. The vastus externus. 16. The biceps. 17. The gracilis. 18. The semitendinosus.

This muscle should now be removed from its origin and turned down, so as to expose the next, which is situated beneath it.

The *GLUTEUS MINIMUS* is a radiated muscle, *arising* from the surface of the dorsum ilii, between the superior and inferior curved lines; its fibres converge to the anterior border of the trochanter major, into which it is *inserted* by means of a rounded tendon. There is no distinct line of separation between the gluteus medius and minimus anteriorly.

*Relations.*—By its *superficial surface* with the gluteus medius, and gluteal vessels. By its *deep surface* with the surface of the ilium, the long tendon of the rectus femoris, and the capsule of the hip joint. A bursa is interposed between the tendon of the muscle and the trochanter.

The *PYRIFORMIS* muscle (pyrum, a pear, *i. e.* pear-shaped) *arises* from the anterior surface of the sacrum, by little slips that are interposed between the first and fourth anterior sacral foramina, and from the adjoining surface of the ilium. It passes out of the pelvis, through the great sacro-ischiatic foramen, and is *inserted* by a rounded tendon into the trochanteric fossa of the femur.

*Relations.*—By its *superficial or external surface* with the sacrum and gluteus maximus. By its *deep or pelvic surface* with the rectum, the sacral plexus of nerves, the branches of the internal iliac artery, the great sacro-ischiatic notch, and the capsule of the hip joint. By its *upper border* with the gluteus medius and gluteal vessels and nerves. By its *lower border* with the gemellus superior, ischiatic vessels and nerves, and internal pudic vessels and nerve.

The *GEMELLUS SUPERIOR* (gemellus, double, twin) is a small slip of muscle, situated immediately below the pyriformis; it *arises* from the spine of the ischium, and is *inserted* into the upper border of the tendon of the obturator internus, and into the trochanteric fossa of the femur. The gemellus superior is not unfrequently wanting.

*Relations.*—By its *superficial surface* with the gluteus maximus, the ischiatic vessels and nerves, and internal pudic vessels and nerve. By its *deep surface* with the pelvis, and capsule of the hip joint.

The *OBTURATOR INTERNUS* *arises* from the inner surface of the anterior wall of the pelvis, being attached to the margin of bone around the obturator foramen, and to the obturator membrane. It passes out of the pelvis through the lesser sacro-ischiatic foramen, and is *inserted* by a flattened tendon into the trochanteric fossa of the femur. The lesser sacro-ischiatic notch, over which this muscle plays as through a pulley, is faced with cartilage, and provided with a synovial bursa to facilitate its movements. The tendon of the obturator is supported on each side by the two gemelli muscles (hence their names), which are inserted into the sides of the tendon, and appear to be auxiliaries or superadded portions of the obturator internus.

*Relations.*—By its *superficial or posterior surface* with the internal pudic vessels and nerve, the obturator fascia, which separates it from the levator ani and viscera of the pelvis; the sacro-ischiatic ligaments, gluteus maximus, and ischiatic vessels and nerves. By its *deep or anterior surface* with the obturator membrane and the margin of bone surrounding it, the cartilaginous pulley of the lesser ischiatic foramen, the external surface of the pelvis, and the capsular ligament of the hip joint. By its *upper border*, within the pelvis, with the obturator vessels and nerve; externally to the

pelvis, with the gemellus superior. By its *lower border* with the gemellus inferior.

The GEMELLUS INFERIOR *arises* from the posterior point of the tuberosity of the ischium, and is *inserted* into the lower border of the tendon of the obturator internus, and into the trochanteric fossa of the femur.

*Relations.*—By its *superficial surface* with the gluteus maximus, and ischiatic vessels and nerves. By its *deep surface* with the external surface of the pelvis, and capsule of the hip joint. By its *upper border* with the tendon of the obturator internus. By its *lower border* with the tendon of the obturator externus and quadratus femoris.

In this region the tendon only of the obturator externus can be seen, situated deeply between the gemellus inferior and the upper border of the quadratus femoris. To expose this muscle fully, it is necessary to dissect it from the anterior part of the thigh, after the removal of the pectineus, adductor longus and adductor brevis muscles.

The OBTURATOR EXTERNUS muscle (obturare, to stop up) *arises* from the obturator membrane, and from the surface of bone immediately surrounding it anteriorly, viz. from the ramus of the os pubis and ischium: its tendon passes behind the neck of the femur, to be *inserted* with the external rotator muscles, into the trochanteric fossa of the femur.

*Relations.*—By its *superficial or anterior surface* with the tendon of the psoas and iliacus, pectineus, adductor brevis and magnus, the obturator vessels and nerve. By its *deep or posterior surface* with the obturator membrane and the margin of bone which surrounds it, the lower part of the capsule of the hip joint and the quadratus femoris.

The QUADRATUS FEMORIS (square-shaped) *arises* from the external border of the tuberosity of the ischium, and is *inserted* into a rough line on the posterior border of the trochanter major, which is thence named linea quadrati.

*Relations.*—By its *posterior surface* with the gluteus maximus, and ischiatic vessels and nerves. By its *anterior surface* with the tendon of the obturator externus, and trochanter minor, a synovial bursa often separating it from the latter. By its *upper border* with the gemellus inferior; and by the *lower border* with the adductor magnus.

*Actions.*—The glutei muscles are abductors of the thigh, when they take their fixed point from the pelvis. Taking their fixed point from the thigh, they steady the pelvis on the head of the femur; this action is peculiarly obvious in standing on one leg; they assist also in carrying the leg forward, in progression. The gluteus minimus being attached to the anterior border of the trochanter major, rotates the limb slightly inwards. The gluteus medius and maximus, from their insertion into the posterior aspect of the bone, rotate the limb outwards; the latter is, moreover, a tensor of the fascia of the thigh. The other muscles rotate the limb outwards, everting the knee and foot; hence they are named external rotators.

#### *Anterior Femoral Region.*

|                        |                  |
|------------------------|------------------|
| Tensor vaginæ femoris, | Vastus internus, |
| Sartorius,             | Vastus externus, |
| Rectus,                | Crurens.         |

*Dissection.*—Make an incision along the line of Poupart's ligament, from the anterior superior spinous process of the ilium to the spine of the



os pubis; and a second, from the middle of the preceding down the inner side of the thigh, and across the inner condyle of the femur, to the head of the tibia, where it may be bounded by a transverse incision. Turn back the integument from the whole of this region, and examine the superficial fascia; which is next to be removed in the same manner. After the deep fascia has been well considered, it is likewise to be removed, by dissecting it off in the course of the fibres of the muscles. As it might not be convenient to the junior student to expose so large a surface at once as ordered in this dissection, the vertical incision may be crossed by one or two transverse incisions, as may be deemed most proper.

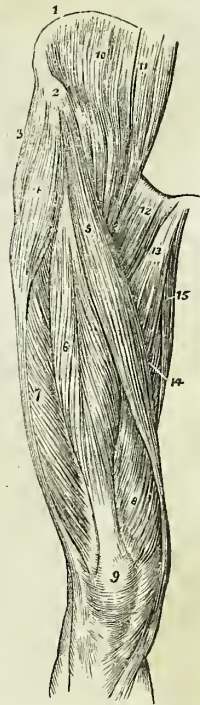
The TENSOR VAGINÆ FEMORIS (stretcher of the sheath of the thigh) is a short flat muscle, situated on the outer side of the hip. It arises from the crest of the ilium, near its anterior superior spinous process, and is inserted between two layers of the fascia lata at about one-fourth down the thigh.

*Relations.*—By its superficial surface with the fascia lata and integument. By its deep surface with the internal layer of the fascia lata, gluteus medius, rectus and vastus externus. By its inner border near its origin with the sartorius.

The SARTORIUS (tailor's muscle) is a long riband-like muscle, arising from the anterior superior spinous process of the ilium, and from the notch immediately below that process; it crosses obliquely the upper third of the thigh, descends behind the inner condyle of the femur, and is inserted by an aponeurotic expansion into the inner tuberosity of the tibia. This expansion covers in the insertion of the tendons of the gracilis and semitendinosus muscles. The inner border of the sartorius muscle is the guide to the operation for tying the femoral artery in the middle of its course.

*Relations.*—By its superficial surface with the fascia lata and some cutaneous nerves. By its deep surface with the psoas and iliacus, rectus, sheath of the femoral vessels and saphenous nerves, vastus internus, adductor longus, adductor magnus, gracilis, long saphenous nerve, internal lateral ligament of the knee joint. By its expanded insertion with the tendons of the gracilis and semi-tendinosus, a synovial bursa being interposed. At the knee joint its posterior border is in relation with the internal saphenous vein. At the upper third of the thigh the sartorius forms, with the lower border of the adductor longus, an isosceles triangle, whereof the base corresponds with Poupart's ligament, whereof the middle of the base of the apex of this triangle, immediately overlies the femoral artery with its sheath.

Fig. 130.\*



\* The muscles of the anterior femoral region: 1. The crest of the ilium. 2. Its anterior superior spinous process. 3. The gluteus medius. 4. The tensor vaginæ femoris: its insertion into the fascia lata is shown inferiorly. 5. The sartorius. 6. The rectus 7. The vastus externus. 8. The vastus internus. 9. The patella. 10. The iliacus internus. 11. The psoas magnus. 12. The pectineus. 13. The adductor longus. 14. Part of the adductor magnus. 15. The gracilis.

The **RECTUS** (straight) muscle is fusiform in its shape and bipenniform in the disposition of its fibres. It *arises* by two round tendons, one from the anterior inferior spinous process of the ilium, the other from the upper lip of the acetabulum; and is *inserted* by a broad and strong tendon, into the upper border of the patella. It is more correct to consider the patella as a sesamoid bone, developed within the tendon of the rectus; and the ligamentum patellæ as the continuation of the tendon to its insertion into the tubercle of the tibia.

*Relations.*—By its *superficial surface* with the gluteus medius, psoas and iliacus, sartorius; and, for the lower three-fourths of its extent, with the fascia lata. By its *deep surface* with the capsule of the hip joint, the external circumflex vessels, crureus, and vastus internus and externus.

The rectus must now be divided through its middle, and the two ends turned aside, to bring clearly into view the next muscles.

The three next muscles are generally considered collectively under the name of triceps extensor cruris. Adopting this view, the muscle surrounds the whole of the femur, excepting the rough line (*linea aspera*) upon its posterior aspect. Its division into three parts is not well defined; the fleshy mass upon each side being distinguished by the names of vastus internus and externus, the middle portion by that of crureus.

The **VASTUS EXTERNUS**, narrow below and broad above, *arises* from the outer border of the patella, and is *inserted* into the femur and outer side of the *linea aspera*, as high as the base of the trochanter major.

*Relations.*—By its *superficial surface* with the fascia lata, rectus, biceps, semi-membranosus and gluteus maximus, a synovial bursa being interposed between it and the latter. By its *deep surface* with the crureus and femur.

The **VASTUS INTERNUS**, broad below and narrow above, *arises* from the inner border of the patella, and is *inserted* into the femur and inner side of the *linea aspera* as high up as the anterior intertrochanteric line.

*Relations.*—By its *superficial surface* with the psoas and iliacus, rectus, sartorius, femoral artery and vein and saphenous nerves, pectineus, adductor longus, brevis, and magnus, and fascia lata. By its *deep surface* with the crureus and femur.

The **CRUREUS** (crus, the leg) *arises* from the upper border of the patella, and is *inserted* into the front aspect of the femur, as high as the anterior intertrochanteric line. When the crureus is divided from its insertion, a small muscular fasciculus is often seen upon the lower part of the femur, which is inserted into the pouch of synovial membrane, that extends upwards from the knee joint, behind the patella. This is named, from its situation, *sub-crureus*, and would seem to be intended to support the synovial membrane.

*Relations.*—By its *superficial surface* with the external circumflex vessels, the rectus, vastus internus and externus. By its *deep surface* with the femur, the sub-crureus, and synovial membrane of the knee joint.

*Actions.*—The tensor vaginæ femoris renders the fascia lata tense, and slightly inverts the limb. The sartorius flexes the leg upon the thigh, and, continuing to act, the thigh upon the pelvis, at the same time carrying the leg across that of the opposite side, into the position in which tailors sit; hence its name. Taking its fixed point from below, it assists the extensor muscles in steadying the leg, for the support of the trunk. The other four muscles have been collectively named *quadriceps extensor*, from their

similarity of action. They extend the leg upon the thigh, and obtain a great increase of power by their attachment to the patella, which acts as a fulcrum. Taking their fixed point from the tibia, they steady the femur upon the leg, and the rectus, by being attached to the pelvis, serves to balance the trunk upon the lower extremity.

*Internal Femoral Region.*

|                   |                  |
|-------------------|------------------|
| Iliacus internus, | Adductor brevis, |
| Psoas magnus,     | Adductor magnus, |
| Pectineus,        | Gracilis.        |
| Adductor longus,  |                  |

*Dissection.*—These muscles are exposed by the removal of the inner flap of integument recommended in the dissection of the anterior femoral region. The iliacus and psoas arising from within the abdomen, can only be seen in their entire extent after the removal of the viscera from that cavity.

The ILIACUS INTERNUS is a flat radiated muscle. It *arises* from the whole extent of the inner concave surface of the ilium; and, after joining with the tendon of the psoas, is *inserted* into the trochanter minor of the femur. A few fibres of this muscle are derived from the base of the sacrum, and others from the capsular ligament of the hip joint.

*Relations.*—By its *anterior surface*, within the pelvis, with the external cutaneous nerve, and with the iliac fascia, which separates the muscle from the peritoneum, on the right from the cæcum, and on the left from the sigmoid flexure of the colon; *externally* to the pelvis with the fascia lata, rectus, and sartorius. By its *posterior surface* with the iliac fossa, margin of the pelvis, and with the capsule of the hip joint, a synovial bursa of large size being interposed, which is sometimes continuous with the synovial membrane of the articulation. By its *inner border* with the psoas magnus and crural nerve.

The PSOAS MAGNUS (Ψῶα, lumbus, a loin), situated by the side of the vertebral column in the loins, is a long fusiform muscle. It *arises* from the intervertebral substances, part of the bodies and bases of the transverse processes, and from a series of tendinous arches, thrown across the constricted portion of the last dorsal and four upper lumbar vertebræ. These arches are intended to protect the lumbar arteries and sympathetic filaments of nerves from pressure, in their passage beneath the muscle. From this extensive origin, the muscle passes along the margin of the brim of the pelvis, and beneath Poupart's ligament, to its insertion. The tendon of the psoas magnus unites with that of the iliacus, and the conjoined tendon is *inserted* into the posterior part of the trochanter minor, a bursa being interposed.

*Relations.*—By its *anterior surface*, with the ligamentum arcuatum internum of the diaphragm, the kidney, the psoas parvus, genito-crural nerve, sympathetic nerve, its proper fascia, the peritoneum and colon, and along its pelvic border with the common and external iliac artery and vein. By its *posterior surface*, with the lumbar vertebræ, the lumbar arteries, quadratus lumborum, from which it is separated by the anterior layer of the aponeurosis of the transversalis, and with the crural nerve, which, near Poupart's ligament, gets to its outer side. The lumbar plexus of nerves is situated in the substance of the posterior part of the muscle

In the thigh, the muscle is in relation with the fascia lata in front; the border of the pelvis and hip joint, from which it is separated by the synovial membrane, common to it and the preceding muscle, behind; with the crural nerve and iliacus, to the outer side; and with the femoral artery, by which it is slightly overlaid, to the inner side.

The PECTINEUS is a flat and quadrangular muscle; it *arises* from the pectineal line (pecten, a crest) of the os pubis, and from the surface of bone in front of that bone. It is *inserted* into the line leading from the anterior intertrochanteric line to the linea aspera of the femur.

*Relations.*—By its *anterior surface*, with the pubic portion of the fascia lata, which separates it from the femoral artery and vein and internal saphenous vein, and lower down with the profunda artery. By its *posterior surface*, with the capsule of the hip joint, and with the obturator externus and adductor brevis, the obturator vessels being interposed. By its *external border*, with the psoas, the femoral artery resting upon the line of interval. By its *internal border*, with the outer edge of the adductor longus. Obturator hernia is situated directly behind this muscle, which forms one of its coverings.

The ADDUCTOR LONGUS (adducere, to draw to), the most superficial of the three adductors, *arises*, by a round and thick tendon, from the front surface of the os pubis, immediately below the angle; and assuming a flattened and expanded form as it descends, is *inserted* into the middle third of the linea aspera.

*Relations.*—By its *anterior surface*, with the pubic portion of the fascia lata, and near its insertion with the femoral artery and vein. By its *posterior surface*, with the adductor brevis and magnus, the anterior branches of the obturator vessels and nerves, and near its insertion with the profunda artery and vein. By its *outer border*, with the pectineus; and by the *inner border*, with the gracilis.

The pectineus must be divided near its origin and turned outwards, and the adductor longus through its middle, turning its ends to either side, to bring into view the adductor brevis.

The ADDUCTOR BREVIS, placed beneath the pectineus and adductor longus, is fleshy, and thicker than the adductor longus; it *arises* from the body and ramus of the os pubis, and is *inserted* into the upper third of the linea aspera.

*Relations.*—By its *anterior surface*, with the pectineus, adductor longus, and anterior branches of the obturator vessels and nerve. By its *posterior surface*, with the adductor magnus, and posterior branches of the obturator vessels and nerve. By its *outer border*, with the obturator externus, and conjoined tendon of the psoas and iliacus. By its *inner border*, with the gracilis and adductor magnus. The adductor brevis is pierced near its insertion by the middle perforating artery.

The adductor brevis may now be divided from its origin and turned outwards, or its inner two-thirds may be cut away entirely, when the adductor magnus muscle will be exposed in its entire extent.

The ADDUCTOR MAGNUS is a broad triangular muscle, forming a septum of division between the muscles situated on the anterior and those on the posterior aspect of the thigh. It *arises*, by fleshy fibres, from the ramus of the pubes and ischium, and from the side of the tuber ischii; and radiating in its passage outwards, is *inserted* into the whole length of the linea aspera, and inner condyle of the femur. The adductor magnus is pierced

by five openings: the three superior, for the three perforating arteries; and the fourth, for the termination of the profunda. The fifth is the large oval opening, in the tendinous portion of the muscle, that gives passage to the femoral vessels.

*Relations.*—By its *anterior surface*, with the pectineus, adductor brevis, adductor longus, femoral artery and vein, profunda artery and vein, with their branches, and with the posterior branches of the obturator vessels and nerve. By its *posterior surface*, with the semi-tendinosus, semi-membranosus, biceps, and gluteus maximus. By its *inner border*, with the gracilis and sartorius. By its *upper border*, with the obturator externus and quadratus femoris.

The GRACILIS (slender) is situated along the inner border of the thigh. It *arises* by a broad, but very thin tendon, from the body of the os pubis, along the edge of the symphysis, and from the margin of the ramus of the pubes and ischium; and is *inserted*, by a rounded tendon, into the inner tuberosity of the tibia, beneath the expansion of the sartorius.

*Relations.*—By its *inner or superficial surface*, with the fascia lata, and below, with the sartorius and internal saphenous nerve; the internal saphenous vein crosses it, lying superficially to the fascia lata. By its *outer or deep surface*, with the adductor longus, brevis, and magnus, and the internal lateral ligament of the knee joint, from which it is separated by a synovial bursa, common to the tendons of the gracilis and semi-tendinosus.

*Actions.*—The iliacus, psoas, pectineus, and adductor longus muscles bend the thigh upon the pelvis, and, at the same time, from the obliquity of their insertion into the lesser trochanter and linea aspera, rotate the entire limb outwards; the pectineus and adductors adduct the thigh powerfully; and from the manner of their insertion into the linea aspera, they assist in rotating the limb outwards. The gracilis is likewise an adductor of the thigh; but contributes also to the flexion of the leg, by its attachment to the inner tuberosity of the tibia.

#### Posterior Femoral Region.

Biceps,            Semi-tendinosus,            Semi-membranosus.

*Dissection.*—Remove the integument and fascia on the posterior part of the thigh by two flaps, as on the anterior region, and turn aside the gluteus maximus from the upper part; the muscles may then be examined.

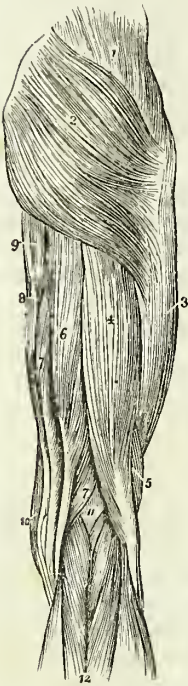
The BICEPS FEMORIS (bis, double, κεφαλή, head) *arises* by two heads, one by a common tendon with the semi-tendinosus; the other muscular and much shorter, from the lower two-thirds of the external border of the linea aspera. This muscle forms the outer hamstring, and is *inserted* by a strong tendon into the head of the fibula; a portion of the tendon is continued downwards into the fascia of the leg, and another is attached to the outer tuberosity of the tibia.

*Relations.*—By its *superficial or posterior surface* with the gluteus maximus and fascia lata. By its *deep or anterior surface* with the semi-membranosus, adductor magnus, vastus externus, the great sciatic nerve, popliteal artery and vein, and near its insertion with the external head of the gastrocnemius, and plantaris. By its *inner border* with the semi-tendinosus, and in the popliteal space with the popliteal artery and vein.

The SEMI-TENDINOSUS, remarkable for its long tendon, *arises* in common with the long head of the biceps, from the tuberosity of the ischium; the

two muscles being closely united for several inches below their origin. It is inserted into the inner tuberosity of the tibia.

Fig. 131.\*



*Relations.*—By its *superficial surface* with the gluteus maximus, fascia lata, and at its insertion with the synovial bursa which separates its tendon from the expansion of the sartorius. By its *deep surface* with the semi-membranosus, adductor magnus, internal head of the gastrocnemius, and internal lateral ligament of the knee joint, the synovial bursa common to it and the tendon of the gracilis being interposed. By its *inner border* with the gracilis; and by its *outer border* with the biceps.

These two muscles must be dissected from the tuberosity of the ischium, to bring into view the origin of the next.

The SEMI-MEMBRANOSUS, remarkable for the tendinous expansion upon its anterior and posterior surface, arises from the tuberosity of the ischium, in front of the common origin of the two preceding muscles. It is inserted into the posterior part of the inner tuberosity of the tibia; at its insertion the tendon splits into three portions, one of which is inserted in a groove on the inner side of the head of the tibia, beneath the internal lateral ligament. The second is continuous with an aponeurotic expansion that binds down the popliteus muscle, the popliteal fascia; and the third turns upwards and outwards to the external condyle of the femur, forming the middle portion of the posterior ligament of the knee joint (*ligamentum posticum Winslowii*).

The tendons of the last two muscles, viz. the semi-tendinosus and semi-membranosus, with those of the gracilis and sartorius, form the inner hamstring.

*Relations.*—By its *superficial surface* with the gluteus maximus, biceps, semi-tendinosus, fascia lata, and at its insertion with the tendinous expansion of the sartorius. By its *deep surface* with the quadratus femoris, adductor magnus, internal head of the gastrocnemius, the knee joint, from which it is separated by a synovial membrane, and the popliteal artery and vein. By its *inner border* with the gracilis. By its *outer border* with the great ischiatic nerve, and in the popliteal space with the popliteal artery and vein.

If the semi-membranosus muscle be turned down from its origin, the student will bring into view the broad and radiated expanse of the adductor magnus, upon which the three flexor muscles above described rest.

*Actions.*—These three hamstring muscles are the direct flexors of the

\* The muscles of the posterior femoral and gluteal region. 1. The gluteus medius. 2. The gluteus maximus. 3. The vastus externus, covered in by fascia lata. 4. The long head of the biceps. 5. Its short head. 6. The semi-tendinosus. 7. The semi-membranosus. 8. The gracilis. 9. A part of the inner border of the adductor magnus. 10. The edge of the sartorius. 11. The popliteal space. 12. The gastrocnemius muscle; its two heads. The tendon of the biceps forms the outer hamstring; and the sartorius with the tendons of the gracilis, semi-tendinosus, and semi-membranosus, the inner hamstring.

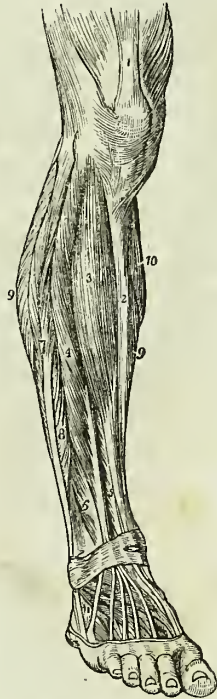
leg upon the thigh; and by taking their origin from below, they balance the pelvis on the lower extremities. The biceps, from the obliquity of its direction, everts the leg when partially flexed, and the semi-tendinosus turns the leg inwards when in the same state of flexion.

*Anterior Tibial Region.*

Fig. 132.\*

Tibialis anticus,  
Extensor longus digitorum,  
Peroneus tertius,  
Extensor proprius pollicis.

*Dissection.*—The dissection of the anterior tibial region is to be commenced by carrying an incision along the middle of the leg, midway between the tibia and the fibula, from the knee to the ankle, and bounding it inferiorly by a transverse incision extending from one malleolus to the other. And to expose the tendons on the dorsum of the foot, the longitudinal incision may be carried onwards to the outer side of the base of the great toe, and be terminated by another incision directed across the heads of the metatarsal bones.



The **TIBIALIS ANTICUS** muscle (*flexor tarsi tibialis*) arises from the upper two-thirds of the tibia, from the interosseous membrane, and from the deep fascia; its tendon passes through a distinct sheath in the annular ligament, and is inserted into the inner side of the internal cuneiform bone, and base of the metatarsal bone of the great toe.

*Relations.*—By its *anterior surface* with the deep fascia, from which many of its superior fibres arise, and with the anterior annular ligament. By its *posterior surface* with the interosseous membrane, tibia, ankle joint, and bones of the tarsus with their articulations. By its *internal surface* with the tibia. By the *external surface* with the extensor longus digitorum, extensor proprius pollicis, and the anterior tibial vessels and nerve.

The **EXTENSOR LONGUS DIGITORUM** arises from the head of the tibia, from the upper three-fourths of the fibula, from the interosseous membrane, and from the deep fascia. Below, it divides into four tendons, which pass beneath the annular ligament, to be inserted into the second and third phalanges of the four lesser toes. The mode of insertion of the extensor tendons, both in the hand and in the foot, is remarkable: each tendon spreads into a broad aponeurosis over the first phalanx; this aponeurosis divides into three slips; the middle one is inserted into the

\* The muscles of the anterior tibial region. 1. The extensor muscles inserted into the patella. 2. The subcutaneous surface of the tibia. 3. The tibialis anticus. 4. The extensor longus digitorum. 5. The extensor proprius pollicis. 6. The peroneus tertius. 7. The peroneus longus. 8. The peroneus brevis. 9, 9. The borders of the soleus muscle. 10. A part of the inner belly of the gastrocnemius. 11. The extensor brevis digitorum; the tendon in front of this number is that of the peroneus tertius; and that behind it, the tendon of the peroneus brevis.

base of the second phalanx, and the two lateral slips are continued onwards, to be inserted into the base of the third.

*Relations.*—By its *anterior surface* with the deep fascia of the leg and foot, and with the anterior annular ligament. By its *posterior surface* with the interosseous membrane, fibula, ankle joint, extensor brevis digitorum which separates its tendons from the tarsus, and with the metatarsus and phalanges. By its *inner surface* with the tibialis anticus, extensor proprius pollicis, and anterior tibial vessels. By its *outer border* with the peroneus longus and brevis.

The PERONEUS TERTIUS (flexor tarsi fibularis) arises from the lower fourth of the fibula, and is inserted into the base of the metatarsal bone of the little toe. Although apparently but a mere division or continuation of the extensor longus digitorum, this muscle may be looked upon as analogous to the flexor carpi ulnaris of the fore-arm. Sometimes it is altogether wanting.

The EXTENSOR PROPRIUS POLLICIS lies between the tibialis anticus and extensor longus digitorum. It arises from the lower two-thirds of the fibula and interosseous membrane. Its tendon passes through a distinct sheath in the annular ligament, and is inserted into the base of the last phalanx of the great toe.

*Relations.*—By its *anterior surface*, with the deep fascia of the leg and foot, and with the anterior annular ligament. By its *posterior surface*, with the interosseous membrane, the fibula, the tibia, the ankle joint, the extensor brevis digitorum, and the bones and articulations of the great toe. It is crossed upon this aspect by the anterior tibial vessels and nerve. By its *outer side*, with the extensor longus digitorum, and in the foot with the dorsalis pedis artery and veins; the outer side of its tendon upon the dorsum of the foot being the guide to those vessels. By its *inner side*, with the tibialis anticus, and with the anterior tibial vessels.

*Actions.*—The tibialis anticus and peroneus tertius are direct flexors of the tarsus upon the leg; acting in conjunction with the tibialis posticus, they direct the foot inwards, and with the peroneus longus and brevis, outwards. They assist also in preserving the flatness of the foot during progression. The extensor longus digitorum and extensor proprius pollicis, are direct extensors of the phalanges; but, continuing their action, they assist the tibialis anticus and peroneus tertius in flexing the entire foot upon the leg. Taking their origin from below, they increase the stability of the ankle joint.

### *Posterior Tibial Region.*

#### *Superficial Group.*

Gastrocnemius,  
Plantaris,  
Soleus.

*Dissection.*—Make an incision from the middle of the popliteal space, down the middle of the posterior part of the leg to the heel, bounding it inferiorly by a transverse incision, passing between the two malleoli. Turn aside the flaps of integument, and remove the fasciæ from the whole of this region; the gastrocnemius muscle will then be exposed.

The GASTROCNEMIUS (γαστροκνήμιον, the bellied part of the leg) arises by two heads, from the two condyles of the femur, the inner head being



the longest. They unite to form the beautiful muscle so characteristic of this region of the limb. It is *inserted*, by means of the tendo Achillis, into the lower part of the posterior tuberosity of the os calcis, a synovial bursa being placed between that tendon and the upper part of the tuberosity. The gastrocnemius must be removed from its origin, and turned down, in order to expose the next muscle.

*Relations.*—By its *superficial surface*, with the deep fascia of the leg, which separates it from the external saphenous vein, and with the external saphenous nerve. By its *deep surface*, with the lateral portions of the posterior ligament of the knee joint, the popliteus, plantaris, and soleus. The internal head of the muscle rests against the posterior surface of the internal condyle of the femur; the external head against the outer side of the external condyle. In the latter, a sesamoid bone is sometimes found.

The PLANTARIS (planta, the sole of the foot), an extremely diminutive muscle, situated between the gastrocnemius and soleus, *arises* from the outer condyle of the femur; and is *inserted*, by its long and delicately slender tendon, into the inner side of the posterior tuberosity of the os calcis, by the side of the tendo Achillis: having crossed obliquely between the two muscles.

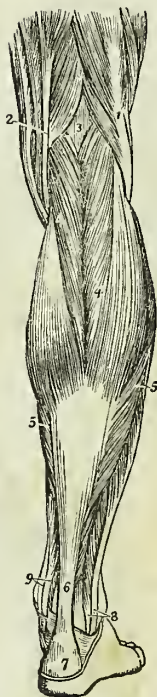The SOLEUS (solea, a sole), is the broad muscle upon which the plantaris rests. It *arises*, from the head and upper third of the fibula, from the oblique line and middle third of the tibia. Its fibres converge to the tendo Achillis, by which it is *inserted* into the posterior tuberosity of the os calcis. Between the fibular and tibial origins of this muscle is a tendinous arch, beneath which the popliteal vessels and nerve pass into the leg.

*Relations.*—By its *superficial surface*, with the gastrocnemius and plantaris. By its *deep surface*, with the intermuscular fascia, which separates it from the flexor longus digitorum, tibialis posticus, flexor longus pollicis, from the posterior tibial vessels and nerve, and from the peroneal vessels.

*Actions.*—The three muscles of the calf draw powerfully on the os calcis, and lift the heel; continuing their action, they raise the entire body. This action is attained by means of a lever of the second power, the fulcrum (the toes) being at one end, the weight (the body supported on the tibia) in the middle, and the power (these muscles) at the other extremity.

They are, therefore, the walking muscles, and perform all movements that require the support of the whole body from the ground, as dancing, leaping, &c. Taking their fixed point from below, they steady the leg upon the foot.

Fig. 133.\*



\* The superficial muscles of the posterior aspect of the leg. 1. The biceps muscle forming the outer hamstring. 2. The tendons forming the inner hamstring. 3. The popliteal space. 4. The gastrocnemius muscle. 5, 5. The soleus. 6. The tendo Achillis. 7. The posterior tuberosity of the os calcis. 8. The tendons of the peroneus longus and flexor longus digitorum passing behind the outer ankle. 9. The tendons of the tibialis posticus and flexor longus digitorum passing into the foot behind the inner ankle.

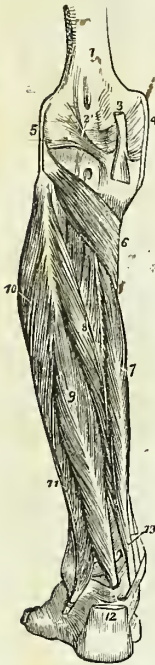*Deep Layer.*

Popliteus,  
Flexor longus pollicis,  
Flexor longus digitorum,  
Tibialis posticus.

*Dissection.*—After the removal of the soleus, the deep layer will be found bound down by an intermuscular fascia which is to be dissected away; the muscles may then be examined.

The **POPLITEUS** muscle (poples, the ham of the leg) forms the floor of the popliteal region at its lower part, and is bound tightly down by a strong fascia derived from the middle slip of the tendon of the semi-membranosus muscle. It *arises* by a rounded tendon from a deep groove on the outer

Fig. 134.\*



side of the external condyle of the femur, beneath the external lateral ligament; and spreading obliquely over the head of the tibia, is *inserted* into the surface of bone above its oblique line. This line is called, from being the limit of insertion of the popliteal muscle, the popliteal line.

*Relations.*—By its *superficial surface* with a thick fascia which separates it from the two heads of the gastrocnemius; the plantaris, and the popliteal vessels and nerve. By its *deep surface* with the synovial membrane of the knee joint and with the upper part of the tibia.

The **FLEXOR LONGUS POLLICIS** is the most superficial of the next three muscles. It *arises* from the lower two-thirds of the fibula, and passes through a groove in the astragalus and os calcis, which is converted by tendinous fibres into a distinct sheath lined by a synovial membrane, into the sole of the foot; it is *inserted* into the base of the last phalanx of the great toe.

*Relations.*—By its *superficial surface* with the intermuscular fascia, which separates it from the soleus and tendo Achillis. By its *deep surface* with the tibialis posticus, fibula, fibular vessels, interosseous membrane, and ankle joint. By its *outer border* with the peroneus longus and brevis. By its *inner border* with the flexor longus digitorum. In the foot, the tendon of the flexor longus pollicis is connected with that of the flexor longus digitorum by a short tendinous slip.

The **FLEXOR LONGUS DIGITORUM** (perforans) *arises* from the surface of the tibia, immediately below the popliteal line. Its tendon passes through a sheath common to it and the tibialis posticus behind the inner malleolus; it then passes through a second sheath which is

\* The deep layer of muscles of the posterior tibial region. 1. The lower extremity of the femur. 2. The ligamentum posticum Winslowii. 3. The tendon of the semi-membranosus muscle dividing into its three slips. 4. The internal lateral ligament of the knee joint. 5. The external lateral ligament. 6. The popliteus muscle. 7. The flexor longus digitorum. 8. The tibialis posticus. 9. The flexor longus pollicis. 10. The peroneus longus muscle. 11. The peroneus brevis. 12. The tendo Achillis divided near its insertion into the os calcis. 13. The tendons of the tibialis posticus and flexor longus digitorum muscles, just as they are about to pass beneath the internal annular ligament of the ankle; the interval between the latter tendon and the tendon of the flexor longus pollicis is occupied by the posterior tibial vessels and nerve.

connected with a groove in the astragalus and os calcis, into the sole of the foot, where it divides into four tendons, which are *inserted* into the base of the last phalanx of the four lesser toes, perforating the tendons of the flexor brevis digitorum.

*Relations.*—By its *superficial surface* with the intermuscular fascia, which separates it from the soleus, and with the posterior tibial vessels and nerve. By its *deep surface* with the tibia and tibialis posticus. In the *sole of the foot* its tendon is in relation with the abductor pollicis and flexor brevis digitorum, which lie superficially to it, and it crosses the tendon of the flexor longus pollicis. At the point of crossing it receives the tendinous slip of communication from the latter.

The flexor longus pollicis must now be removed from its origin, and the flexor longus digitorum drawn aside, to bring into view the entire extent of the tibialis posticus.

The TIBIALIS POSTICUS (extensor tarsi tibialis) lies upon the interosseous membrane, between the two bones of the leg. It *arises* by two heads from the adjacent sides of the tibia and fibula their whole length, and from the interosseous membrane. Its tendon passes inwards beneath the tendon of the flexor longus digitorum, and runs in the same sheath; it then passes through a proper sheath over the deltoid ligament, and beneath the calcaneo-scaphoid articulation to be *inserted* into the tuberosity of the scaphoid and internal cuneiform bone. While in the common sheath behind the internal malleolus, the tendon of the tibialis posticus lies internally to that of the flexor longus digitorum, from which it is separated by a thin fibrous partition. A sesamoid bone is usually met with in the tendon close to its insertion.

*Relations.*—By its *superficial surface* with the intermuscular septum, the flexor longus pollicis, flexor longus digitorum, posterior tibial vessels and nerve, peroneal vessels, and in the sole of the foot with the abductor pollicis. By its *deep surface* with the interosseous membrane, the fibula and tibia, the ankle joint, and the astragalus. The anterior tibial artery passes between the two heads of the muscle.

The student will observe that the two latter muscles change their relative position to each other in their course. Thus, in the leg, the position of the three muscles from within outwards, is, flexor longus digitorum, tibialis posticus, flexor longus pollicis. At the inner malleolus, the relation of the tendons is, tibialis posticus, flexor longus digitorum, both in the same sheath; then a broad groove, which lodges the posterior tibial artery, venæ comites, and nerve; and lastly, the flexor longus pollicis.

*Actions.*—The popliteus is a flexor of the tibia upon the thigh, carrying it at the same time inwards, so as to invert the leg. The flexor longus pollicis and flexor longus digitorum are the long flexors of the toes; their tendons are connected in the foot by a short tendinous band, hence they necessarily act together. The tibialis posticus is an extensor of the tarsus upon the leg, and an antagonist to the tibialis anticus. It combines with the tibialis anticus in adduction of the foot.

#### *Fibular Region.*

Peroneus longus,  
Peroneus brevis.

*Dissection.*—These muscles are exposed by continuing the dissection of the anterior tibial region outwards beyond the fibula, to the border of the posterior tibial region.

The PERONEUS LONGUS (*περόνη*, fibula, extensor tarsi fibularis longior) muscle *arises* from the head and upper third of the outer side of the fibula, and terminates in a long tendon, which passes behind the external malleolus, and obliquely across the sole of the foot, through the groove in the cuboid bone, to be *inserted* into the base of the metatarsal bone of the great toe. Its tendon is thickened where it glides behind the external malleolus, and a sesamoid bone is developed in that part which plays upon the cuboid bone.

*Relations.*—By its *superficial surface* with the fascia of the leg and foot. By its *deep surface* with the fibula, peroneus brevis, os calcis, and cuboid bone, and near the head of the fibula with the fibular nerve. By its *anterior border* it is separated from the extensor longus digitorum by the attachment of the fascia of the leg to the fibula; and by the *posterior border* by the same medium from the soleus and flexor longus pollicis. The peroneus longus is furnished with three tendinous sheaths and as many synovial membranes; the first is situated behind the external malleolus, and is common to this muscle and the peroneus brevis, the second on the outer side of the os calcis, and the third on the cuboid bone.

The PERONEUS BREVIS (extensor tarsi fibularis brevior) lies beneath the peroneus longus; it *arises* from the lower half of the fibula, and terminates in a tendon which passes behind the external malleolus and through a groove in the os calcis, to be *inserted* into the base of the metatarsal bone of the little toe.

*Relations.*—By its *superficial surface* with the peroneus longus and fascia of the leg and foot. By its *deep surface* with the fibula, the os calcis, and cuboid bone. The lateral relations are the same as those of the peroneus longus. The tendon of the peroneus brevis has but two tendinous sheaths and two synovial membranes, one behind the external malleolus and common to both peronei, the other upon the side of the os calcis.

*Actions.*—The peronei muscles are extensors of the foot, conjointly with the tibialis posticus. They antagonize the tibialis anticus and peroneus tertius, which are flexors of the foot. The whole of these muscles acting together, tend to maintain the flatness of the foot, so necessary to security in walking.

#### FOOT.

##### *Dorsal Region.*

Extensor brevis digitorum,

Interossei dorsales.

The EXTENSOR BREVIS DIGITORUM muscle *arises* from the outer side of the os calcis, crosses the foot obliquely, and terminates in four tendons, the innermost of which is *inserted* into the base of the first phalanx of the great toe, and the other three into the sides of the long extensor tendons of the second, third, and fourth toes.

*Relations.*—By its *upper surface* with the tendons of the extensor longus digitorum, peroneus brevis, and with the deep fascia of the foot. By its *under surface* with the tarsal and metatarsal bones. Its *inner border* is in relation with the dorsalis pedis artery, and the innermost tendon of the muscle crosses that artery just before its division.

The DORSAL INTEROSSEI muscles are placed between the metatarsal bones; they resemble the analogous muscles in the hand in *arising* by two heads from the adjacent sides of the metatarsal bones; their tendons are *inserted* into the base of the first phalanx, and into the digital expansion of the tendons of the long extensor.

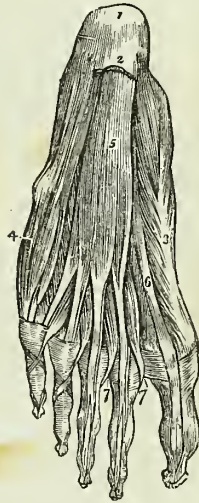
The *first dorsal interosseous* is *inserted* into the inner side of the second toe, and is therefore an *adductor*; the other three are *inserted* into the outer side of the second, third, and fourth toes, and are consequently *abductors*.

*Relations.*—By their *upper surface* with a strong fascia which separates them from the extensor tendons. By their *under surface* with the plantar interossei. Each of the muscles gives passage to a small artery (posterior perforating) which communicates with the external plantar artery. And between the heads of the first interosseous muscle the communicating artery of the *dorsalis pedis* takes its course.

Fig. 135.\*

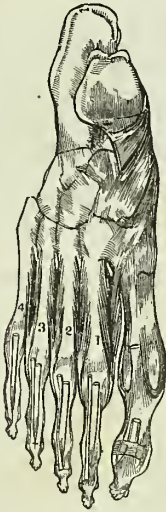

Fig. 136.†



### *Plantar Region.*

#### *First Layer.*

Abductor pollicis,  
Abductor minimi digiti,  
Flexor brevis digitorum.

*Dissection.*—The sole of the foot is best dissected by carrying an incision around the heel, and along the inner and outer borders of the foot, to

\* Dorsal interossei. 1. Abductor secundi. 2. Adductor secundi. 3. Adductor tertii. 4. Adductor quarti.

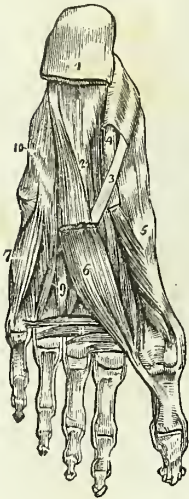
† The first layer of muscles in the sole of the foot; this layer is exposed by the removal of the plantar fascia. 1. The os calcis. 2. The posterior part of the plantar fascia divided transversely. 3. The abductor pollicis. 4. The abductor minimi digiti. 5. The flexor brevis digitorum. 6. The tendon of the flexor longus pollicis muscle. 7, 7. The lumbricales. On the second and third toes, the tendons of the flexor longus digitorum are seen passing through the bifurcation of the tendons of the flexor brevis digitorum.

the great and little toes. This incision should divide the integument and superficial fascia, and both together should be dissected from the deep fascia, as far forward as the base of the phalanges, where they may be removed from the foot altogether. The deep fascia should then be removed, and the first layer of muscles will be brought into view.

The **ABDUCTOR POLLICIS** lies along the inner border of the foot; it *arises* by two heads, between which the tendons of the long flexors, arteries, veins, and nerves enter the sole of the foot. One head *arises* from the inner tuberosity of the os calcis, the other from the internal annular ligament and plantar-fascia. *Insertion*, into the base of the first phalanx of the great toe, and into the internal sesamoid bone.

*Relations.*—By its *superficial surface* with the internal portion of the plantar fascia. By its *deep surface* with the flexor brevis pollicis, musculus accessorius, tendons of the flexor longus digitorum and flexor longus pollicis, tendons of the tibialis anticus and posticus, the plantar vessels and nerves, and the tarsal bones. On its *outer border* with the flexor brevis digitorum, from which it is separated by a vertical septum of the plantar fascia.

Fig. 137.\*



The **ABDUCTOR MINIMI DIGITI** lies along the outer border of the sole of the foot. It *arises* from the outer tuberosity of the os calcis, and from the plantar fascia, as far forward as the base of the fifth metatarsal bone, and is *inserted* into the base of the first phalanx of the little toe.

*Relations.*—By its *superficial surface* with the external portion of the plantar fascia. By its *deep surface* with the musculus accessorius, flexor brevis minimi digiti, with the tarsal bones, and with the metatarsal bone of the little toe. By its *inner side* with the flexor brevis digitorum, from which it is separated by the vertical septum of the plantar fascia.

The **FLEXOR BREVIS DIGITORUM** (*perforatus*) is placed between the two preceding muscles. It *arises* from the under surface of the os calcis, from the plantar fascia and intermuscular septa, and is *inserted* by four tendons into the base of the second phalanx of the four lesser toes. Each tendon divides, previously to its insertion, to give passage to the tendon of the long flexor; hence its cognomen *perforatus*.

*Relations.*—By its *superficial surface* with the plantar fascia. By its *deep surface* with a thin layer of fascia which separates it from the musculus accessorius, tendons of the flexor longus digitorum and flexor longus pollicis, and plantar vessels and nerves. By its *borders* with the vertical septa of the plantar fascia, which separate the muscle, on the one side from the abductor pollicis, and on the other from the abductor minimi digiti.

\* The third and a part of the second layer of muscles of the sole of the foot. 1. The divided edge of the plantar fascia. 2. The musculus accessorius. 3. The tendon of the flexor longus digitorum. 4. The tendon of the flexor longus pollicis. 5. The flexor brevis pollicis. 6. The adductor pollicis. 7. The flexor brevis minimi digiti. 8. The transversus pedis. 9. Interossei muscles, plantar and dorsal. 10. Convex ridge formed by the tendon of the peroneus longus muscle in its oblique course across the foot.

*Second Layer.*

Musculus accessorius,

Lumbricales.

*Dissection.* — The three preceding muscles must be divided from their origin, and anteriorly through their tendons, and removed, in order to bring into view the second layer.

The MUSCULUS ACCESSORIUS arises by two slips from either side of the under surface of the os calcis; the inner slip being fleshy, the outer, tendinous. The muscle is inserted into the outer side and upper surface of the tendon of the flexor longus digitorum.

*Relations.* — By its superficial surface, with the three muscles of the superficial layer, from which it is separated by their fascial sheaths, and with the external plantar vessels and nerves. By its deep surface, with the under surface of the os calcis and the long calcaneo-cuboid ligament.

The LUMBRICALES (lumbricus, an earthworm) are four little muscles, arising from the tibial side of the tendons of the flexor longus digitorum, and inserted into the expansion of the extensor tendons, and into the base of the first phalanx of the four lesser toes.

*Relations.* — By their superficial surface, with the tendons of the flexor brevis digitorum. By their deep surface, with the third layer of muscles of the sole of the foot. They pass between the digital slips of the deep fascia to reach their insertion.

*Third Layer.*

Flexor brevis pollicis,  
Adductor pollicis,  
Flexor brevis minimi digiti,  
Transversus pedis.

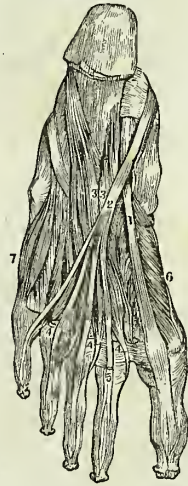
*Dissection.* — The tendons of the long flexors, and the muscles connected with them, must be removed, to see clearly the attachments of the third layer.

The FLEXOR BREVIS POLLICIS arises, by a pointed tendinous process, from the side of the cuboid, and from the external cuneiform bone; it is inserted, by two heads, into the base of the first phalanx of the great toe. Two sesamoid bones are developed in the tendons of insertion of these two heads, and the tendon of the flexor longus pollicis lies in the groove between them.

*Relations.* — By its superficial surface, with the abductor pollicis, tendon of the flexor longus pollicis, and plantar fascia. By its deep surface, with the tarsal bones and their ligaments, the metatarsal bone of the great toe, and the insertion of the tendon of the peroneus longus. By its inner border, with the abductor pollicis; and by its outer border, with the adductor pollicis; with both of these muscles it is blended near its insertion.

The ADDUCTOR POLLICIS arises from the cuboid bone, from the sheath of the tendon of the peroneus longus, and from the base of the third and

Fig. 138.\*



\* Deep-seated muscles in the sole of the foot. 1. Tendon of the flexor longus pollicis. 2. Tendon of the flexor communis digitorum pedis. 3. Flexor accessorius. 4. Lumbricales. 5. Flexor brevis digitorum. 6. Flexor brevis pollicis pedis. 7. Flexor brevis minimi digiti pedis.

fourth metatarsal bones. It is *inserted* into the base of the first phalanx of the great toe.

*Relations.* — By its *superficial surface*, with the tendons of the flexor longus and flexor brevis digitorum, the musculus accessorius, and lumbricales. By its *deep surface*, with the tarsal bones and ligaments, the external plantar artery and veins, the interossei muscles, tendon of the peroneus longus, and metatarsal bone of the great toe. By its *inner border*, with the flexor brevis pollicis; with which its fibres are blended.

The FLEXOR BREVIS MINIMI DIGITI *arises* from the base of the metatarsal bone of the little toe, and from the sheath of the tendon of the peroneus longus. It is *inserted* into the base of the first phalanx of the little toe.

*Relations.* — By its *superficial surface*, with the tendons of the flexor longus and flexor brevis digitorum, the fourth lumbricalis, abductor minimi digiti, and plantar fascia. By its *deep surface*, with the plantar interosseous muscle of the fourth metatarsal space, and the metatarsal bone.

The TRANSVERSUS PEDIS *arises*, by fleshy slips, from the heads of the metatarsal bones of the four lesser toes. Its tendon is *inserted* into the base of the first phalanx of the great toe, being blended with that of the adductor pollicis.

*Relations.* — By its *superficial surface*, with the tendons of the flexor longus and flexor brevis digitorum, and the lumbricales. By its *deep surface*, with the interossei, and heads of the metatarsal bones.

#### *Fourth Layer.*

#### Interossei plantares.

The PLANTAR INTEROSSEI muscles are three in number, and are placed *upon*, rather than between, the metatarsal bones. They *arise* from the base of the metatarsal bones of the three outer toes, and are *inserted* into the inner side of the extensor tendon and base of the first phalanx of the same toes.

*Relations.* — By their *superficial surface*, with the dorsal interossei and the metatarsal bones. By their *deep surface*, with the external plantar artery and veins, the adductor pollicis, transversus pedis, and flexor minimi digiti.

*Actions.* — All the preceding muscles act upon the toes; and the movements which they are capable of executing may be referred to four heads, viz., flexion, extension, adduction, and abduction. In these actions they are grouped in the following manner:—

| <i>Flexion.</i>                                                                                      | <i>Extension.</i>                                        |
|------------------------------------------------------------------------------------------------------|----------------------------------------------------------|
| Flexor longus digitorum,<br>Flexor brevis digitorum,<br>Flexor accessorius,<br>Flexor minimi digiti. | Extensor longus digitorum,<br>Extensor brevis digitorum. |
| <i>Adduction.</i>                                                                                    | <i>Abduction.</i>                                        |
| Interossei, { one dorsal,<br>{ three plantar.                                                        | Interossei, three dorsal,<br>Abductor minimi digiti.     |



The great toe, like the thumb in the hand, enjoys an independent action, and is provided with distinct muscles to perform its movements. These movements are precisely the same as those of the other toes, viz.:

*Flexion.*

Flexor longus pollicis,  
Flexor brevis pollicis.

*Extension.*

Extensor proprius pollicis,  
Extensor brevis digitorum.

*Adduction.*

Adductor pollicis.

*Abduction.*

Abductor pollicis.

The only muscles excluded from this table are the lumbricales, four small muscles, which, from their attachments to the tendons of the long flexor, appear to be assistants to its action; and the transversus pedis, a small muscle placed transversely in the foot across the heads of the metatarsal bones, which has for its office the drawing together of the toes.

Fig. 139.\*



## CHAPTER V.

### ON THE FASCIAE.

FASCIA (fascia, a bandage) is the name assigned to laminae of various extent and thickness, which are distributed through the different regions of the body, for the purpose of investing or protecting the softer and more delicate organs. From a consideration of their structure, these fasciæ may be arranged into two groups: cellulo-fibrous fasciæ, and aponeurotic fasciæ.

The *cellulo-fibrous fascia* is best illustrated in the common subcutaneous investment of the entire body, the superficial fascia. This structure is situated immediately beneath the integument over every part of the frame, and is the medium of connexion between that layer and the deeper parts. It is composed of cellulo-fibrous tissue containing in its areolæ an abundance of adipose cells. The fat being a bad conductor of caloric, serves to retain the warmth of the body; while it forms at the same time a yielding tissue, through which the minute vessels and nerves pass to the papillary layer of the skin, without incurring the risk of obstruction from injury or pressure upon the surface. By dissection, the superficial fascia may be separated into *two layers*, between which are found the superficial or cu-

\* Plantar interossei. 1. Abductor tertii. 2. Abductor quarti. 3. Interosseous minimi digiti.

taneous vessels and nerves; as the superficial epigastric artery, the saphe-nous veins, the radial and ulnar veins, the superficial lymphatic vessels, also the cutaneous muscles, as the platysma myoides, orbicularis palpebrarum, sphincter ani, &c. In other situations, the cellulo-fibrous fascia is found condensed into a strong and inelastic membrane, as is exemplified in the deep fascia of the neck, the thoracic, transversalis, and perineal fasciæ, and the sheaths of vessels.

The *aponeurotic fascia* is the strongest kind of investing membrane; it is composed of tendinous fibres, running parallel with each other, and connected by other fibres of the same kind passing in different directions. When freshly exposed, it is brilliant and nacreous, and is tough, inelastic, and unyielding. In the limbs it forms the deep fascia, enclosing and forming distinct sheaths to all the muscles and tendons. It is thick upon the outer and least protected side of the limb, and thinner upon its inner side. It is firmly connected to the bones, and to the prominent points of each region, as to the pelvis, knee, and ankle, in the lower, and to the clavicle, scapula, elbow, and wrist, in the upper extremity. It assists the muscles in their action, by keeping up a tonic pressure on their surface; aids materially in the circulation of the fluids in opposition to the laws of gravity; and in the palm of the hand and sole of the foot is a powerful protection to the structures which enter into the composition of these regions. In some situations its tension is regulated by muscular action, as by the tensor vaginæ femoris and gluteus maximus in the thigh, by the biceps in the leg, and by the biceps and palmaris longus in the arm; in other situations it affords an extensive surface for the origin of the fibres of muscles.

The fasciæ may be arranged like the other textures of the body into, 1. Those of the head and neck. 2. Those of the trunk. 3. Those of the upper extremity. 4. Those of the lower extremity.

#### FASCIAE OF THE HEAD AND NECK.

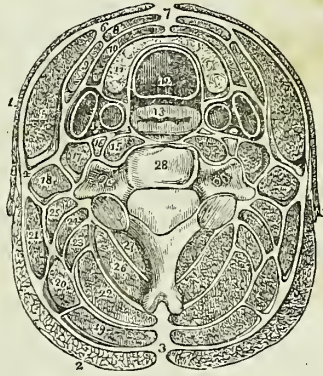
The **TEMPORAL FASCIA** is a strong aponeurotic membrane which covers in the temporal muscle at each side of the head, and gives origin by its internal surface to some of its muscular fibres. It is attached to the whole extent of the temporal ridge above, and to the zygomatic arch below; in the latter situation it is thick and divided into two layers, the external being connected to the upper border of the arch, and the internal to its inner surface. A small quantity of fat is usually found between these two layers, together with the orbital branch of the temporal artery.

**CERVICAL FASCIA.**—The fasciæ of the neck are the superficial and the deep. The *superficial cervical fascia* is a part of the common superficial fascia of the entire body, and is only interesting from containing between its layers the platysma myoides muscle.

The *deep cervical fascia* is a strong cellulo-fibrous layer which invests the muscles of the neck, and retains and supports the vessels and nerves. It commences posteriorly at the ligamentum nuchæ, and passes forwards at each side beneath the trapezius muscle to the posterior border of the sterno-mastoid; here it divides into two layers, which embrace that muscle and unite upon its anterior border to be prolonged onwards to the middle line of the neck, where it becomes continuous with the fascia of the opposite side. Besides thus constituting a sheath for the sterno-mastoid, it

also forms sheaths for the other muscles of the neck over which it passes. If the superficial layer of the sheath of the sterno-mastoid be traced upwards, it will be found to pass over the parotid gland and masseter muscle, and to be inserted into the zygomatic arch; and if it be traced downwards, it will be seen to pass in front of the clavicle, and become lost upon the pectoralis major muscle. If the deep layer of the sheath be examined superiorly, it will be found attached to the styloid process, from which it is reflected to the angle of the lower jaw, forming the stylo-maxillary ligament; and if it be followed downwards, it will be found connected with the tendon of the omo-hyoid muscle, and may thence be traced behind the clavicle, where it encloses the subclavius muscle, and, being extended from the cartilage of the first rib to the coracoid process, constitutes the costo-coracoid membrane. In front of the sterno-mastoid muscle, the deep fascia is attached to the border of the lower jaw and os hyoides, and forms a distinct sheath for the submaxillary gland. Inferiorly it divides into two layers, one of which passes in front of the sternum, while the other is attached to its superior border.

Fig. 140.\*



## FASCIÆ OF THE TRUNK.

The *thoracic fascia*† is a dense layer of cellulo-fibrous membrane, stretched horizontally across the superior opening of the thorax. It is firmly attached to the concave margin of the first rib, and to the inner surface of the sternum. In front it leaves an opening for the connexion of the cervical with the thoracic portion of the thymus gland, and behind it forms an arch across the vertebral column, to give passage to the œsophagus.

At the point where the great vessels and trachea pass through the thoracic fascia, it divides into an ascending and descending layer. The

\* A transverse section of the neck, showing the deep cervical fascia and its numerous prolongations, forming sheaths for the different muscles. As the figure is symmetrical, the figures of reference are placed only on one side. 1. The platysma myoides. 2. The trapezius. 3. The ligamentum nuchæ, from which the fascia may be traced downwards beneath the trapezius, enclosing the other muscles of the neck. 4. The point at which the fascia divides, to form a sheath for the sterno-mastoid muscle (5). 6. The point of reunion of the two layers of the sterno-mastoid sheath. 7. The point of union of the deep cervical fascia of opposite sides of the neck. 8. Section of the sterno-hyoid. 9. Omo-hyoid. 10. Sterno-thyroid. 11. The lateral lobe of the thyroid gland. 12. The trachea. 13. The œsophagus. 14. The sheath containing the common carotid artery, internal jugular vein, and pneumogastric nerve. 15. The longus colli. The nerve in front of the sheath of this muscle is the sympathetic. 16. The rectus anticus major. 17. Scalenus anticus. 18. Scalenus posticus. 19. The splenius capitis. 20. Splenius colli. 21. Levator anguli scapulæ. 22. Complexus. 23. Trachelo-mastoid. 24. Transversalis colli. 25. Cervicalis ascendens. 26. The semi-spinalis colli. 27. The multifidus spinæ. 28. A cervical vertebra. The transverse processes are seen to be traversed by the vertebral artery and vein.

† For an excellent description of this fascia, see Sir Astley Cooper's work on "Anatomy of the Thymus Gland."

*ascending layer* is attached to the trachea, and becomes continuous with the sheath of the carotid vessels, and with the deep cervical fascia; the *descending layer* descends upon the trachea to its bifurcation, surrounds the large vessels arising from the arch of the aorta, and the upper part of the arch itself, and is continuous with the fibrous layer of the pericardium. It is connected also with the venæ innominatæ and superior cava, and is attached to the cellular capsule of the thymus gland.

“The thoracic fascia,” writes Sir Astley Cooper, “performs three important offices:—

“1st. It forms the upper boundary of the chest, as the diaphragm does the lower.

“2d. It steadily preserves the relative situation of the parts which enter and quit the thoracic opening.

“3d. It attaches and supports the heart in its situation, through the medium of its connexion with the aorta and large vessels which are placed at its curvature.”

#### ABDOMINAL FASCIÆ.

The lower part of the parietes of the abdomen, and the cavity of the pelvis, are strengthened by a layer of fascia which lines their internal surface, and at the bottom of the latter cavity is reflected inwards to the sides of the bladder. This fascia is continuous throughout the whole of the above-mentioned surface; but for convenience of description is considered under the several names of transversalis fascia, iliac fascia, and pelvic fascia; the two former meet at the crest of the ilium and Poupart's ligament, and the latter is confined to the cavity of the true pelvis.

The *fascia transversalis* (Fascia Cooperi)\* is a cellulo-fibrous lamella, which lines the inner surface of the transversalis muscle. It is thick and dense below, near the lower part of the abdomen; but becomes thinner as it ascends, and is gradually lost in the subserous cellular tissue. It is attached inferiorly to the reflected margin of Poupart's ligament and to the crest of the ilium; internally, to the border of the rectus muscle; and, at the inner third of the femoral arch, is continued beneath Poupart's ligament, and forms the anterior segment of the crural canal, or sheath of the femoral vessels.

The internal abdominal ring is situated in this fascia, at about midway between the spine of the os pubis and the anterior superior spine of the ilium, and half an inch above Poupart's ligament; it is bounded upon its inner side by a well-marked falciform border, but is ill defined around its outer margin. From the circumference of this ring is given off an infundibuliform process, which surrounds the testicle and spermatic cord, constituting the fascia propria of the latter, and forms the first investment to the sac of oblique inguinal hernia. It is the strength of this fascia, in the interval between the tendon of the rectus and the internal abdominal ring, that defends this portion of the parietes from the frequent occurrence of direct inguinal hernia.

#### INGUINAL HERNIA.

Inguinal hernia is of two kinds, oblique and direct.

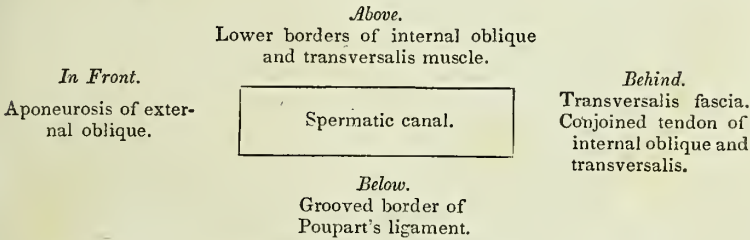
In OBLIQUE INGUINAL HERNIA the intestine escapes from the cavity of

\* Sir Astley Cooper first described this fascia in its important relation to inguinal hernia.

The abdomen into the spermatic canal, through the *internal abdominal ring*, pressing before it a pouch of peritoneum which constitutes the *hernial sac*, and distending the infundibuliform process of the transversalis fascia. After emerging through the internal abdominal ring, it passes *first* beneath the lower and arched border of the transversalis muscle; *then* beneath the lower border of the internal oblique muscle; and *finally* through the external abdominal ring in the aponeurosis of the external oblique. From the transversalis muscle it receives no investment; while passing beneath the lower border of the internal oblique it obtains the cremaster muscle; and, upon escaping at the external abdominal ring, receives the intercolumnar fascia. So that the coverings of an oblique inguinal hernia, after it has emerged through the external abdominal ring, are, from the surface to the intestine, the

- |                       |                                           |
|-----------------------|-------------------------------------------|
| Integument,           | Cremaster muscle,                         |
| Superficial fascia,   | Transversalis, or infundibuliform fascia, |
| Intercolumnar fascia, | Peritoneal sac.                           |

The spermatic canal, which, in the normal condition of the abdominal parietes serves for the passage of the spermatic cord in the male, and the round ligament with its vessels in the female, is about one inch and a half in length. It is bounded *in front* by the aponeurosis of the external oblique muscle; *behind* by the transversalis fascia, and the conjoined tendon of the internal oblique and transversalis muscle; *above* by the arched borders of the internal oblique and transversalis; *below* by the grooved border of Poupart's ligament, and at each extremity by one of the abdominal rings, the internal ring at the inner termination, the external ring at the outer extremity. These relations may be more distinctly illustrated by the following plan—



There are three varieties of oblique inguinal hernia :—common, congenital, and encysted.

*Common oblique hernia* is that which has been described above.

*Congenital hernia* results from the nonclosure of the pouch of peritoneum carried downwards into the scrotum by the testicle, during its descent in the fœtus.

The intestine at some period of life is forced into this canal, and descends through it into the tunica vaginalis where it lies in contact with the testicle; so that congenital hernia has no proper sac, but is contained within the tunica vaginalis. The other coverings are the same as those of common inguinal hernia.

*Encysted hernia* (hernia infantilis, of Hey) is that form of protrusion in which the pouch of peritoneum forming the tunica vaginalis, being only partially closed, and remaining open externally to the abdomen, admits

of the hernia passing into the scrotum, behind the tunica vaginalis. So that the surgeon in operating upon this variety, requires to divide three layers of serous membrane; the first and second layers being those of the tunica vaginalis; and the third the true sac of the hernia.

DIRECT INGUINAL HERNIA has received its name from passing *directly* through the external abdominal ring, and forcing before it the opposing parietes. This portion of the wall of the abdomen is strengthened by the conjoined tendon of the internal oblique and transversalis muscle, which is pressed before the hernia, and forms one of its investments. Its coverings are, the

|                       |                       |
|-----------------------|-----------------------|
| Integument,           | Conjoined tendon,     |
| Superficial fascia,   | Transversalis fascia, |
| Intercolumnar fascia, | Peritoneal sac.       |

Direct inguinal hernia differs from oblique in never attaining the same bulk, in consequence of the resisting nature of the conjoined tendon of the internal oblique and transversalis and of the transversalis fascia; in its direction, having a tendency to protrude from the middle line rather than towards it. Thirdly, in making for itself a new passage through the abdominal parietes, instead of following a natural channel; and fourthly, in the relation of the neck of its sac to the epigastric artery; that vessel lying to the outer side of the opening of the sac of direct hernia, and to the inner side of that of oblique hernia.

All the forms of inguinal hernia are designated *scrotal*, when they have descended into that cavity.

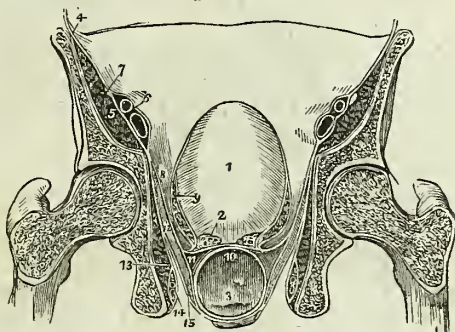
The FASCIA ILIACA is the aponeurotic investment of the psoas and iliacus muscles; and, like the fascia transversalis, is thick below, and becomes gradually thinner as it ascends. It is attached superiorly along the edge of the psoas, to the anterior lamella of the aponeurosis of the transversalis muscle, to the ligamentum arcuatum internum, and to the bodies of the lumbar vertebræ, leaving arches corresponding with the constricted portions of the vertebræ for the passage of the lumbar vessels. Lower down it passes beneath the external iliac vessels, and is attached along the margin of the true pelvis; externally, it is connected to the crest of the ilium; and, inferiorly, to the outer two-thirds of Poupart's ligament, where it is continuous with the fascia transversalis. Passing beneath Poupart's ligament, it surrounds the psoas and iliacus muscles to their termination, and beneath the inner third of the femoral arch forms the posterior segment of the sheath of the femoral vessels.

The FASCIA PELVICA is attached to the inner surface of the os pubis, and along the margin of the brim of the pelvis, where it is continuous with the iliac fascia. From this extensive origin it descends into the pelvis, and divides into two layers, the pelvic and obturator.

The *pelvic layer* or *fascia*, when traced from the internal surface of the os pubis near the symphysis, is seen to be reflected inwards to the neck of the bladder, so as to form the *anterior vesical ligaments*. Traced backwards, it passes between the sacral plexus of nerves and the internal iliac vessels, and is attached to the anterior surface of the sacrum; and followed from the sides of the pelvis, it descends to the base of the bladder and divides into three layers, one, *ascending*, is reflected upon the side of that viscus, encloses the vesical plexus of veins, and forms the lateral ligaments of the bladder. A *middle layer* passes inwards between the base

of the bladder and the upper surface of the rectum, and was named by Mr. Tyrrell the *recto-vesical fascia*; and an *inferior layer* passes behind the rectum, and, with the layer of the opposite side, completely invests that intestine.

Fig. 141.\*



The *obturator fascia* passes directly downwards from the splitting of the layers of the pelvic fascia, and covers in the obturator internus muscle and the internal pudic vessels and nerve; it is attached to the ramus of the os pubis and ischium in front, and below to the falciform margin of the great sacro-ischiatic ligament. Lying between these two layers of fascia is the levator ani muscle, which arises from their angle of separation. The levator ani is covered in inferiorly by a third layer of fascia, which is given off by the obturator fascia, and is continued downwards upon the inferior surface of the muscle to the extremity of the rectum, where it is lost. This layer may be named, from its position and inferior attachment, the *anal fascia*.

**PERINEAL FASCIÆ.**—In the perineum there are two fasciæ of much importance, the superficial and deep perineal fascia.

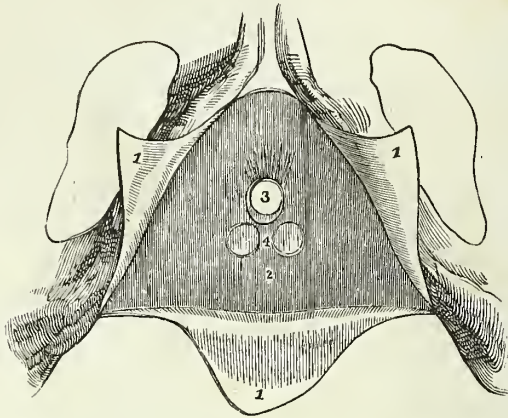
The *superficial perineal fascia* is a thin aponeurotic layer, which covers in the muscles of the genital portion of the perineum and the root of the penis. It is firmly attached at each side to the ramus of the os pubis and ischium; posteriorly it is reflected backwards beneath the transversi perinei muscles, to become connected with the deep perineal fascia; while anteriorly it is continuous with the dartos of the scrotum.

The *deep perineal fascia* (Camper's ligament, triangular ligament) is situated behind the root of the penis, and is firmly stretched across between the ramus of the os pubis and ischium of each side, so as to constitute a strong septum of defence to the outlet of the pelvis. At its infe-

\* A transverse section of the pelvis, showing the distribution of the pelvic fascia. 1. The bladder. 2. The vesicula seminalis of one side, divided across. 3. The rectum. 4. The iliac fascia, covering in the iliacus and psoas muscles (5); and forming a sheath for the external iliac vessels (6). 7. The anterior crural nerve, excluded from the sheath. 8. The pelvic fascia. 9. Its ascending layer, forming the lateral ligament of the bladder of one side, and a sheath to the vesical plexus of veins. 10. The recto-vesical fascia of Mr. Tyrrell, formed by the middle layer. 11. The inferior layer surrounding the rectum and meeting at the middle line with the fascia of the opposite side. 12. The levator ani muscle. 13. The obturator internus muscle, covered in by the obturator fascia, which also forms a sheath for the internal pudic vessels and nerve (14). 15. The layer of fascia which invests the under surface of the levator ani muscle, the *anal fascia*.

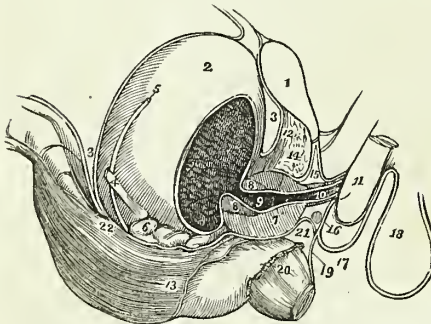
rior border it divides into two layers, one of which is continued forwards, and is continuous with the superficial perineal fascia ; while the other is

Fig. 142.\*



prolonged backwards to the rectum, and, joining with the anal fascia, assists in supporting the extremity of that intestine. The deep perineal fascia is composed of two layers, which are separated from each other by several important parts, and traversed by the membranous portion of the urethra. The anterior layer is nearly plane in its direction, and sends a sheath forwards around the anterior termination of the membranous urethra, to be attached to the posterior part of the bulb. The posterior layer is oblique, and sends a funnel-shaped process backwards, which invests

Fig. 143.†



the commencement of the membranous urethra and the prostate gland. The inferior segment of this funnel-shaped process is continued backward beneath the prostate gland and the vesiculæ seminales, and is continuous with the recto-vesical fasciæ of Tyrrell, which is attached posteriorly to the recto-vesical fold of peritoneum, and serves the important office of retaining that duplicature in its proper situation.

\* The pubic arch with the attachments of the perineal fasciæ. 1, 1, 1. The superficial perineal fascia divided by a  $\Delta$  shaped incision into three flaps ; the lateral flaps are turned over the ramus of the os pubis and ischium at each side, to which they are firmly attached ; the posterior flap is continuous with the deep perineal fascia. 2. The deep perineal fascia. 3. The opening for the passage of the membranous portion of the urethra, previously to entering the bulb. 4. Two projections of the anterior layer of the deep perineal fascia, corresponding with the position of Cowper's glands..

† A side view of the viscera of the pelvis, showing the distribution of the perineal and pelvic fasciæ. 1. The symphysis pubis. 2. The bladder. 3. The recto-vesical fold of peritoneum, passing from the anterior surface of the rectum to the posterior part of the bladder ; from the upper part of the fundus of the bladder it is reflected upon the



Between the two layers of the deep perineal fascia are situated, therefore, the whole extent of the membranous portion of the urethra, the compressor urethræ muscle, Cowper's glands, the internal pudic and bulbous arteries, and a plexus of veins. Mr. Tyrrell considers the anterior lamella alone as the deep perineal fascia, and the posterior lamella as a distinct layer of fascia, covering in a considerable plexus of veins.

## FASCIÆ OF THE UPPER EXTREMITY.

The *superficial fascia* of the upper extremity contains between its layers the superficial veins and lymphatics, and the superficial nerves.

The *deep fascia* is thin over the deltoid and pectoralis major muscles, and in the axillary space, but thick upon the dorsum of the scapula, where it binds down the infra-spinatus muscle. It is attached to the clavicle, acromion process, and spine of the scapula. In the upper arm it is somewhat stronger, and is inserted into the condyloid ridges, forming the intermuscular septa. In the fore-arm it is very strong, and at the bend of the elbow its thickness is augmented by a broad band, which is given off from the inner side of the tendon of the biceps. It is firmly attached to the olecranon process, to the ulna, and to the prominent points about the wrist. Upon the front of the wrist it is continuous with the anterior annular ligament, which is considered by some anatomists to be formed by the deep fascia, but which I am more disposed to regard as a ligament of the wrist. On the posterior aspect of this joint, it forms a strong transverse band, the *posterior annular ligament*, beneath which the tendons of the extensor muscles pass, in distinct sheaths. The attachments of the posterior annular ligament are, the radius on one side, and the ulna and pisiform bone on the opposite side of the joint.

The tendons, as they pass beneath the annular ligaments, are surrounded by synovial bursæ. The dorsum of the hand is invested by a thin fascia, which is continuous with the posterior annular ligament.

The *palmar fascia* is divided into three portions. A central portion, which occupies the middle of the palm, and two lateral portions, which spread out over the sides of the hand, and are continuous with the dorsal fascia. The central portion is strong and tendinous: it is narrow at the wrist, where it is attached to the annular ligament, and broad over the heads of the metacarpal bones, where it divides into eight slips, which are inserted into the sides of the base of the first phalanx of each finger. The

abdominal parietes. 4. The ureter. 5. The vas deferens crossing the direction of the ureter. 6. The vesicula seminalis of the right side. 7, 7. The prostate gland divided by a longitudinal section. 8, 8. The section of a ring of elastic tissue encircling the prostatic portion of the urethra at its commencement. 9. The prostatic portion of the urethra. 10. The membranous portion, enclosed by the compressor urethræ muscle. 11. The commencement of the corpus spongiosum penis, the bulb. 12. The anterior ligaments of the bladder, formed by the reflection of the pelvic fascia, from the internal surface of the os pubis to the neck of the bladder. 13. The edge of the pelvic fascia at the point where it is reflected upon the rectum. 14. An interval between the pelvic fascia and deep perineal fascia, occupied by a plexus of veins. 15. The deep perineal fascia; its two layers. 16. Cowper's gland of the right side, situated between the two layers below the membranous portion of the urethra. 17. The superficial perineal fascia, ascending in front of the root of the penis to become continuous with the dartos of the scrotum (18). 19. The layer of the deep fascia which is prolonged to the rectum. 20. The lower part of the levator ani; its fibres are concealed by the anal fascia. 21. The inferior segment of the funnel-shaped process given off from the posterior layer of the deep perineal fascia, which is continuous with the recto-vesical fascia of Tyrrell. The attachment of this fascia to the recto-vesical fold of peritoneum is seen at 22.

fascia is strengthened at its point of division into slips, by strong fasciculi of transverse fibres, and the arched interval left between the slips gives passage to the tendons of the flexor muscles. The arches between the fingers transmit the digital vessels and nerve, and lumbricales muscles.

FASCIÆ OF THE LOWER EXTREMITY.

The *superficial fascia* contains between its two layers the superficial vessels and nerves of the lower extremity. At the groin these two layers are separated from each other by the superficial lymphatic glands, and the deep layer is attached to Poupart's ligament, while the superficial layer is continuous with the superficial fascia of the abdomen.

The *deep fascia* of the thigh is named, from its great extent, the *fascia lata*; it is thick and strong upon the outer side of the limb, and thinner upon its posterior side. That portion of fascia which invests the gluteus maximus is very thin, but that which covers in the gluteus medius is excessively thick, and gives origin by its inner surface, to the superficial fibres of that muscle. The fascia lata is attached superiorly to Poupart's ligament, the crest of the ilium, sacrum, coccyx, tuberosity of the ischium, ramus of the ischium, and pubes; in the thigh it is inserted into the linea aspera, and around the knee is connected with the prominent points of that joint. It possesses also two muscular attachments, by means of the tensor vaginae femoris, which is inserted between its two layers on the outer side, and the gluteus maximus, which is attached to it behind.

In addition to the smaller openings in the fascia lata which transmit the small cutaneous vessels and nerves, there exists at the upper and inner extremity of the thigh, an oblique foramen, which gives passage to the superficial lymphatic vessels, and the large subcutaneous vein of the lower extremity, the internal saphenous vein, and is thence named the *saphenous opening*. The existence of this opening has given rise to the division of the upper part of the fascia lata into two portions, an iliac portion and a pubic portion.

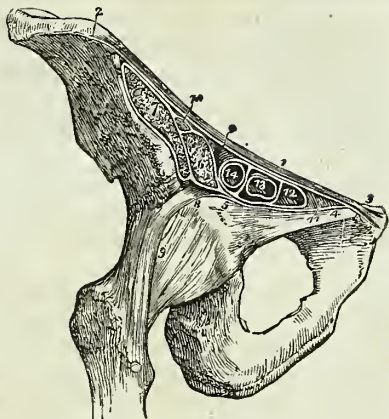
The *iliac portion* is situated upon the iliac side of the opening. It is attached to the crest of the ilium, and along Poupart's ligament to the spine of the os pubis, whence it is reflected downwards and outwards, in an arched direction, and forms a falciform border, which constitutes the outer boundary of the saphenous opening. The edge of this border immediately overlies, and is reflected upon the sheath of the femoral vessels, and the lower extremity of the curve is continuous with the pubic portion.

The *pubic portion*, occupying the pubic side of the saphenous opening, is attached to the spine of the os pubis and pectineal line; and, passing outwards behind the sheath of the femoral vessels, divides into two layers; the anterior layer is continuous with that portion of the iliac fascia which forms the sheath of the iliacus and psoas muscles, and the posterior layer is lost upon the capsule of the hip joint.

The interval between the falciform border of the iliac portion and the opposite surface of the pubic portion is closed by a fibrous layer, which is pierced by numerous openings for the passage of lymphatic vessels, and is thence named *cribriform fascia*. The cribriform fascia is connected with the sheath of the femoral vessels, and forms one of the coverings of femoral hernia. When the iliac portion of the fascia lata is removed from its attachment to Poupart's ligament and is turned aside, the sheath of the femoral vessels (the *femoral* or *crural canal*) is brought into view; and if

Poupart's ligament be carefully divided, the sheath may be isolated, and its continuation with the transversalis and iliac fascia clearly demonstrated. In this view the sheath of the femoral vessels is an infundibuliform continuation of the abdominal fasciæ, closely adherent to the vessels a little way down the thigh, but much larger than the vessels it contains at Poupart's ligament. If the sheath be opened, the artery and vein will be found lying side by side, and occupying the outer two-thirds of the sheath, leaving an infundibuliform interval between the vein and the inner wall of the sheath.

Fig. 144.\*



The superior opening of this space is named the *femoral ring*; it is bounded in front by Poupart's ligament, behind by the os pubis, internally by Gimbernat's ligament, and externally by the femoral vein. The interval itself serves for the passage of the superficial lymphatic vessels from the saphenous opening to a lymphatic gland, which generally occupies the femoral ring; and from thence they proceed into the current of the deep lymphatics. The femoral ring is closed merely by a thin layer of subserous areolar tissue,† which retains the lymphatic gland in its position, and is named *septum crurale*; and by the peritoneum. It follows from this description, that the femoral ring must be a weak point in the parietes of the abdomen, particularly in the female, where the *femoral arch*, or space included between Poupart's ligament and the border of the pelvis, is larger than in the male, while the structures which pass through it are smaller. It happens consequently, that, if violent or continued pressure be made upon the abdominal viscera, a portion of intestine may be forced through the femoral ring into the infundibuliform space in the sheath of the femoral vessels, carrying before it the peritoneum and the septum crurale,—this constitutes *femoral hernia*. If the causes which give rise to the formation of this hernia continue, the intestine, unable to extend further down the sheath, from the close connexion of the latter with the vessels, will in the next place be forced forwards through the saphenous opening in the fascia lata, carrying before it two additional coverings, the sheath of the vessels, or fascia propria, and the cribriform

\* A section of the structures which pass beneath the femoral arch. 1. Poupart's ligament. 2, 2. The iliac portion of the fascia lata, attached along the margin of the crest of the ilium, and along Poupart's ligament, as far as the spine of the os pubis (3). 4. The pubic portion of the fascia lata, continuous at 3 with the iliac portion, and passing outwards behind the sheath of the femoral vessels to its outer border at 5, where it divides into two layers; one is continuous with the sheath of the psoas (6) and iliacus (7); the other (8) is lost upon the capsule of the hip joint (9). 10. The crural nerve, enclosed in the sheath of the psoas and iliacus. 11. Gimbernat's ligament. 12. The femoral ring, within the femoral sheath. 13. The femoral vein. 14. The femoral artery; the two vessels and the ring are surrounded by the femoral sheath, and their septa are sent between the anterior and posterior wall of the sheath, dividing the artery from the vein, and the vein from the femoral ring.

† This areolar tissue is sometimes very considerably thickened by a deposit of fat within its areolæ, and forms a thick stratum over the hernial sac.

fascia; and then curving upwards over Poupart's ligament, the hernia will become placed beneath the superficial fascia and integument.

The direction which femoral hernia takes in its descent is at first *downwards*, then *forwards*, and then *upwards*; and in endeavouring to reduce it, the application of the taxis must have reference to this course, and be directed in precisely the reverse order. The coverings of femoral hernia are the

|                     |                 |
|---------------------|-----------------|
| Integument,         | Fascia propria, |
| Superficial fascia, | Septum crurale, |
| Cribriform fascia,  | Peritoneal sac. |

The FASCIA OF THE LEG is strong in the anterior tibial region, and gives origin by its inner surface to the upper part of the tibialis anticus, and extensor longus digitorum muscles.

It is firmly attached to the tibia and fibula at each side, and becomes thickened inferiorly into a narrow band, the *anterior annular ligament*, beneath which the tendons of the extensor muscles pass into the dorsum of the foot, in distinct sheaths lined by synovial bursæ. Upon the outer side it forms a distinct sheath, which envelops the peronei muscles, and ties them to the fibula. The anterior annular ligament is attached by one extremity to the outer side of the os calcis, and divides in front of the joint into two bands; one of which is inserted into the inner malleolus, while the other spreads over the inner side of the foot, and becomes continuous with the internal portion of the plantar fascia.

The *fascia of the dorsum of the foot* is a thin layer given off from the lower border of the anterior annular ligament: it is continuous at each side with the lateral portions of the plantar fascia.

The *fascia of the posterior part of the leg* is much thinner than the anterior, and consists of two layers, superficial and deep. The *superficial* layer is continuous with the posterior fascia of the thigh, and is increased in thickness upon the outer side of the leg by an expansion derived from the tendon of the biceps; it terminates inferiorly in the external and internal annular ligaments. The *deep layer* is stretched across between the tibia and fibula, and forms the *intermuscular fascia* between the superficial and deep layer of muscles. It covers in superiorly the popliteus muscle, receiving a tendinous expansion from the semi-membranosus muscle, and is attached to the oblique line of the tibia.

The *internal annular ligament* is a strong fibrous band, attached above to the internal malleolus, and below to the side of the inner tuberosity of the os calcis. It is continuous above with the posterior fascia of the leg, and below with the plantar fascia, forming sheaths for the passage of the flexor tendons and vessels into the sole of the foot.

The *external annular ligament*, shorter than the internal, extends from the extremity of the outer malleolus to the side of the os calcis, and serves to bind down the tendons of the peronei muscles in their passage beneath the external ankle.

The PLANTAR FASCIA consists of three portions, a middle and two lateral.

The *middle portion* is thick and dense, and is composed of strong aponeurotic fibres, closely interwoven with each other. It is attached posteriorly to the inner tuberosity of the os calcis, and terminates under the heads of the metatarsal bones in five fasciculi. Each of these fasciculi

divides into two slips, which are inserted one on each side into the bases of the first phalanges of the toes, leaving an interval between them for the passage of the flexor tendons. The point of division of this fascia into fasciculi and slips, is strengthened by transverse bands, which preserve the solidity of the fascia at its broadest part. The intervals between the toes give passage to the digital arteries and nerves, and to the lumbricales muscles.

The *lateral portions* are thin, and cover the sides of the sole of the foot; they are continuous behind with the internal and external annular ligaments; on the inner side with the middle portion, and externally with the dorsal fascia.

Besides constituting a strong layer of investment and defence to the soft parts situated in the sole of the foot, these three portions of fascia send processes inwards, which form sheaths for the different muscles. A strong septum is given off from each side of the middle portion of the plantar fascia, which is attached to the tarsal bones, and divides the muscles into three groups, a middle and two lateral; and transverse septa are stretched between these to separate the layers. The superficial layer of muscles derive a part of their origin from the plantar fascia.

## CHAPTER VI.

### ON THE ARTERIES.

THE arteries are the cylindrical tubes which convey the blood from the ventricles of the heart to every part of the body. They are dense in structure, and preserve for the most part the cylindrical form when emptied of their blood, which is their condition after death: hence they were considered by the ancients as the vessels for the transmission of the vital spirits,\* and were therefore named arteries (*ἀρτή* *τηρσειν*, to contain air).

The artery proceeding from the left ventricle of the heart contains the pure or arterial blood, which is distributed throughout the entire system, and constitutes, with its returning veins, the *greater* or *systemic circulation*. That which emanates from the right ventricle, conveys the impure blood to the lungs; and, with its corresponding veins, establishes the *lesser* or *pulmonary circulation*.

The whole of the arteries of the *systemic* circulation proceed from a single trunk, named the *aorta*, from which they are given off as branches, and divide and subdivide to their ultimate ramifications, constituting the great arterial tree which pervades, by its minute subdivisions, every part of the animal frame. The mode in which the division into branches takes place, is deserving of remark. From the aorta, the branches, for the most part, pass off at right angles, as if for the purpose of checking the impetus with which the blood would otherwise rush along their cylinders from the main trunk; but in the limbs a very different arrangement is adopted; the branches are given off from the principal artery at an acute angle, so

\* To Galen is due the honour of having discovered that arteries contained blood, and not air.

that no impediment may be offered to the free circulation of the vital fluid. The division of arteries is usually dichotomous, as of the aorta into the two common iliacs, common carotid into the external and internal, &c.; but in some few instances a short trunk divides suddenly into several branches, which proceed in different directions; this mode of division is termed an *axis*, as the thyroid and cœliac axis.

In the division of an artery into two branches, it is observed that the combined area of the two branches are somewhat greater than that of the single trunk; and if the combined area of all the branches at the periphery of the body were compared with that of the aorta, it would be seen that the blood, in passing from the aorta into the numerous distributing branches, was flowing through a conical space, of which the apex might be represented by the aorta, and the base by the surface of the body. The advantage of this important principle in facilitating the circulation is sufficiently obvious; for the increased channel which is thus provided for the current of the blood, serves to compensate for the retarding influence of friction, resulting from the distance of the heart and the division of the vessels.

*Communications* between arteries are very free and numerous, and increase in frequency with the diminution in size of the branches; so that, through the medium of the minute ramifications, the entire body may be considered as one uninterrupted circle of *inosculations*, or *anastomoses* (ἀνά between, στόμα mouth). This increase in the frequency of anastomosis in the smaller branches is a provision for counteracting the greater liability to impediment existing in them than in the larger branches. Where freedom of circulation is of vital importance, this communication of the arteries is very remarkable, as in the circle of Willis in the cranium, or in the distribution of the arteries of the heart. It is also strikingly seen in situations where obstruction is most likely to occur, as in the distribution to the alimentary canal, around joints, or in the hand and foot. Upon this free communication existing everywhere between arterial branches is founded the principle of cure in the ligature of large arteries; the ramifications of the branches given off from the artery above the ligature inosculate with those which proceed from the trunk of the vessel below the ligature; these anastomosing branches enlarge and constitute a *collateral circulation*, in which, as is shown in the beautiful preparations made by Sir Astley Cooper, several large branches perform the office of the single obliterated trunk.\*

The arteries do not terminate directly in veins; but in an intermediate system of vessels, which, from their minute size (about  $\frac{1}{3000}$  of an inch in diameter), are termed *capillaries* (capillus, a hair). The capillaries constitute a microscopic network, which is distributed through every part of the body, so as to render it impossible to introduce the smallest needle point beneath the skin without wounding several of these fine vessels. It is through the medium of the capillaries, that all the phenomena of nutrition and secretion are performed. They are remarkable for their uniformity of diameter, and for the constant divisions and communications which take place between them, without any alteration of size. They

\* I have a preparation, showing the collateral circulation in a dog, in which I tied the abdominal aorta; the animal died from over-feeding nearly two years after the operation

mosculate on the one hand with the terminal ramusculi of the arteries; and on the other with the minute radicles of the veins.

Arteries are composed of three coats, external, middle, and internal. The *external* or *areolo-fibrous coat* is firm and strong, and serves at the same time as the chief means of resistance of the vessel, and of connection to surrounding parts. It consists of condensed areolo-fibrous tissue, strengthened by an interlacement of glistening fibres which are partly longitudinal and partly encircle the cylinder of the tube in an oblique direction. Upon the surface the areolar tissue is loose, to permit of the movements of the artery in distention and contraction.

The *middle coat* is that upon which the thickness of the artery depends; it is yellowish in colour, and so brittle as to be cut through by the thread in the ligature of a vessel.\*

The *internal coat* is a thin serous membrane which lines the interior of the artery, and gives it the smooth polish which that surface presents. It is continuous with the lining membrane of the heart, and through the medium of the capillaries with that of the venous system.

In intimate structure an artery is more complicated than the above description would imply. The internal coat, for example, is composed of two layers, and the middle of three, so that, with the external coat, there are six layers entering into the composition of an artery. The innermost coat is a tessellated epithelium analogous to that of other serous membranes. The second coat from within is a thin, rigid membrane, pierced with a number of round or oval-shaped holes, and supporting a thin layer of flat, longitudinal fibres. From these characters it has been denominated the fenestrated or striated coat. The third layer, which is the innermost part of the middle coat, is composed of flat, longitudinal fibres, analogous to those of organic muscle. The fourth layer, the thickest of the whole, is composed of muscular fibres of organic life, arranged in a circular direction around the vessel. The fifth, or outermost part of the middle coat, is a thin layer of elastic tissue; this is present only in the large arteries. The sixth is the external or areolo-fibrous coat.

The arteries in their distribution through the body are included in a loose areolar investment which separates them from surrounding tissues, and is called a *sheath*. Around the principal vessels the sheath is an important structure; it is composed of areolo-fibrous tissue, intermingled with tendinous fibres, and is continuous with the fasciæ of the region in which the arteries are situated, as with the thoracic and cervical fasciæ in the neck, transversalis and iliac fasciæ, and fascia lata in the thigh, &c. The sheath of the arteries contains also their accompanying veins, and sometimes a nerve.

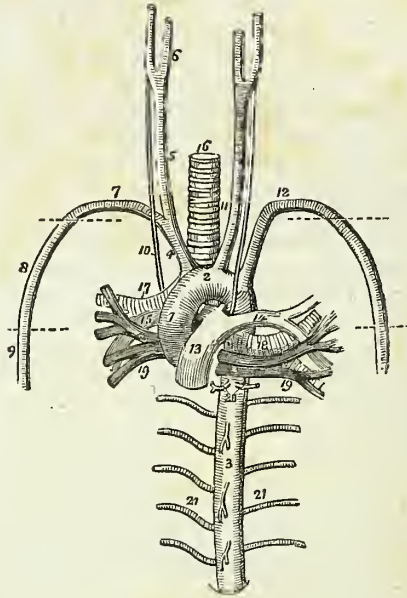
The coats of arteries are supplied with blood like other organs of the body, and the vessels which are distributed to them are named *vasa vasorum*. They are also provided with nerves; but the mode of distribution of the nerves is at present unknown.

In the consideration of the arteries, we shall first describe the aorta, and

\* The *second* or *middle coat* of the arteries has given rise to no little discussion among the continental anatomists. It will be found, however, to consist of fibres, flat, elastic, for the most part transverse, and belonging to the yellow elastic tissue. Some of the fibres are longitudinal, and some of the transverse present strong evidences of belonging to the muscular system of organic life; so that the coat may, I think, be fairly stated to be a mixed one, composed of yellow, elastic, and organic muscular fibres. It is best studied in the aorta or some large trunk.—G.

the branches of that trunk with their subdivisions, which together constitute the efferent portion of the systemic circulation; and then the pulmonary artery as the efferent trunk of the pulmonary circulation.

Fig. 145.\*



AORTA.

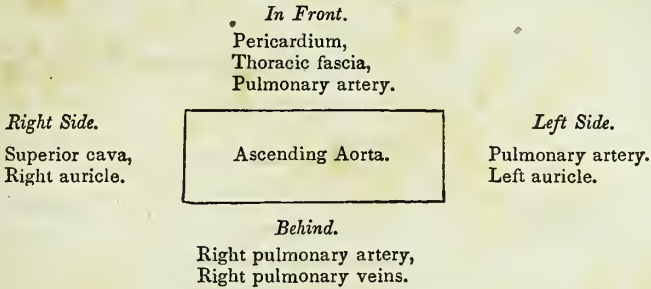
The AORTA arises from the left ventricle, at the middle of the root of the sternum, and opposite the articulation of the fourth costal cartilage with the sternum. At its commencement it presents three dilatations, called the sinus aortici, which correspond with the three semilunar valves. It ascends at first to the right, then curves backwards and to the left, and descends on the left side of the vertebral column to the fourth lumbar vertebra. Hence it is divided into—ascending—arch—and descending aorta.

\* The large vessels which proceed from the root of the heart, with their relations; the heart has been removed. 1. The ascending aorta. 2. The arch. 3. The thoracic portion of the descending aorta. 4. The arteria innominata, dividing into, 5, the right carotid, which again divides at 6, into the external and internal carotid; and 7, the right subclavian artery. 8. The axillary artery; its extent is designated by a dotted line. 9. The brachial artery. 10. The right pneumogastric nerve running by the side of the common carotid, in front of the right subclavian artery, and behind the root of the right lung. 11. The left common carotid, having to its outer side the left pneumogastric nerve, which crosses the arch of the aorta, and as it reaches its lower border is seen to give off the left recurrent nerve. 12. The left subclavian artery becoming axillary and brachial in its course, like the artery of the opposite side. 13. The trunk of the pulmonary artery connected to the concavity of the arch of the aorta by a fibrous cord, the remains of the ductus arteriosus. 14. The left pulmonary artery. 15. The right pulmonary artery. 16. The trachea. 17, 15, and 19, on the right side, and 14, 18, and 19, on the left, constitute the roots of the corresponding lungs, and the relative position of these vessels is preserved. 20. Bronchial arteries. 21, 21. Intercostal arteries; the branches from the front of the aorta above and below the number 3 are pericardiac and œsophageal branches.



*Relations.*—The *ascending aorta* has in relation with it, *in front*, the trunk of the pulmonary artery, thoracic fascia, and pericardium; *behind*, the right pulmonary veins and artery; to the *right side*, the right auricle and superior cava; and to the *left*, the left auricle and the trunk of the pulmonary artery.

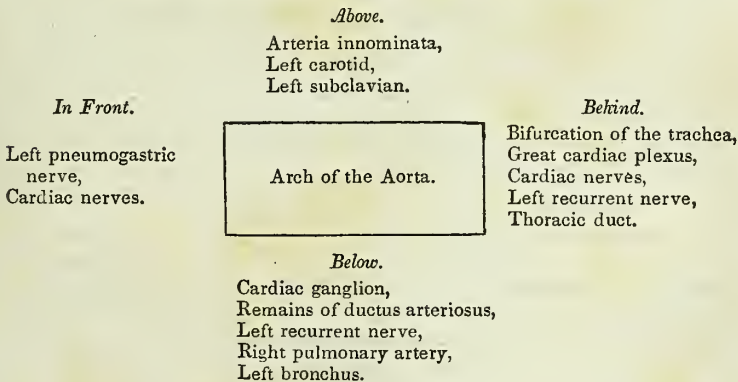
*Plan of the Relations of the Ascending Aorta.*



*Arch.*—The upper border of the arch of the aorta is parallel with the upper border of the second sterno-costal articulation of the right side in front, and the second dorsal vertebra behind, and terminates opposite the lower border of the third.

The *anterior surface* of the arch is crossed by the left pneumogastric nerve, and by the cardiac branches of that nerve and of the sympathetic. The *posterior surface* of the arch is in relation with the bifurcation of the trachea and great cardiac plexus, the cardiac nerves, left recurrent nerve, and the thoracic duct. The *superior border* gives off the three great arteries, viz. the innominata, left carotid, and left subclavian. The *inferior border*, or concavity of the arch, is in relation with the remains of the ductus arteriosus, the cardiac ganglion and left recurrent nerve, and has passing beneath it the right pulmonary artery and left bronchus.

*Plan of the Relations of the Arch of the Aorta.*

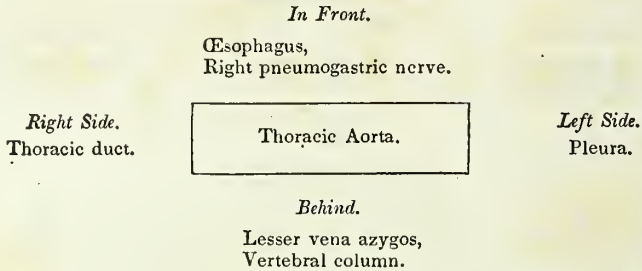


The *descending aorta* is subdivided in correspondence with the two great cavities of the trunk, into the thoracic and abdominal aorta.

The THORACIC AORTA is situated to the left side of the vertebral column, but approaches the middle line as it descends, and at the aortic opening of the diaphragm is altogether in front of the column. After entering the abdomen it again falls back to the left side.

*Relations.*—It is in relation, *behind*, with the vertebral column and lesser vena azygos; *in front*, with the œsophagus and right pneumogastric nerve; to the *left side*, with the pleura; and to the *right*, with the thoracic duct.

*Plan of the Relations of the Thoracic Aorta.*

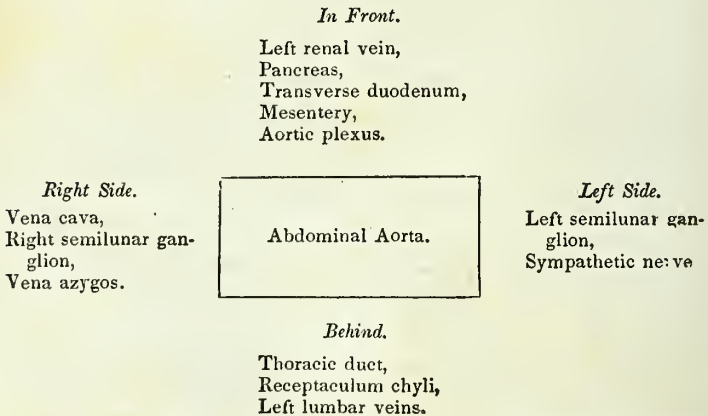


The ABDOMINAL AORTA enters the abdomen through the aortic opening of the diaphragm, and descends, lying rather to the left side of the vertebral column, to the fourth lumbar vertebra, where it divides into the two common iliac arteries.

*Relations.*—It is crossed *in front*, by the left renal vein, pancreas, transverse duodenum, and mesentery, and is embraced by the aortic plexus; *behind* it is in relation with the thoracic duct, receptaculum chyli, and left lumbar veins.

On its *left side* is the left semilunar ganglion and sympathetic nerve; and on the *right*, the vena cava, right semilunar ganglion, and the commencement of the vena azygos.

*Plan of the Relations of the Abdominal Aorta.*



*Branches.*—The branches of the aorta, arranged into a tabular form, are,—

|                                |                                                                                                                                                  |                                         |
|--------------------------------|--------------------------------------------------------------------------------------------------------------------------------------------------|-----------------------------------------|
| <i>Ascending aorta</i> . . .   | Coronary.                                                                                                                                        |                                         |
| <i>Arch of the aorta</i> . . . | { Arteria innominata,<br>{ Left carotid,<br>{ Left subclavian.                                                                                   | { Right carotid,<br>{ Right subclavian. |
| <i>Thoracic aorta</i> . . .    |                                                                                                                                                  |                                         |
| <i>Abdominal aorta</i> . . .   | { Supra-renal,<br>{ Renal,<br>{ Superior mesenteric,<br>{ Spermatic,<br>{ Inferior mesenteric,<br>{ Lumbar,<br>{ Sacramedia,<br>{ Common iliacs. |                                         |

The CORONARY ARTERIES arise from the aortic sinuses at the commencement of the ascending aorta, immediately above the free margin or the semilunar valves. The *left* or *anterior coronary*, passes forwards, between the pulmonary artery and left appendix auriculæ, and divides into two branches; one of which winds around the base of the left ventricle in the auriculo-ventricular groove, and inosculates with the right coronary, forming an arterial circle around the base of the heart; while the other passes along the line of union of the two ventricles, upon the anterior aspect of the heart, to its apex, where it anastomoses with the descending branch of the right coronary. It supplies the left auricle and the anterior surface of both ventricles.

The *right*, or *posterior coronary*, passes forwards, between the root of the pulmonary artery and the right auricle, and winds along the auriculo-ventricular groove, to the posterior median furrow, where it descends upon the posterior aspect of the heart to its apex, and inosculates with the left coronary. It is distributed to the right auricle, and to the posterior surface of both ventricles, and sends a large branch along the sharp margin of the right ventricle to the apex of the heart.

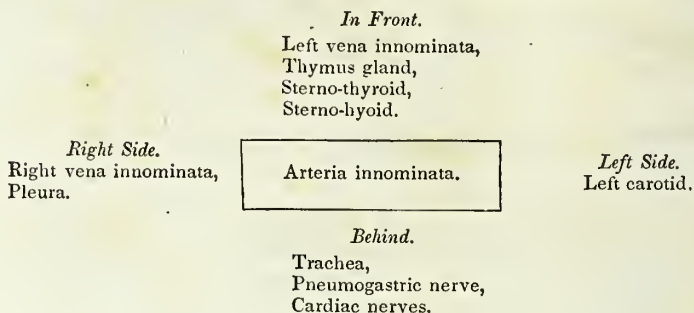
## ARTERIA INNOMINATA.

The *Arteria innominata* (fig. 145, No. 4) is the first artery given off by the arch of the aorta. It is an inch and a half in length, and ascends obliquely towards the right sterno-clavicular articulation, where it divides into the right carotid and right subclavian artery.

*Relations.*—It is in relation, *in front*, with the left vena innominata, the thymus gland, and the origins of the sterno-thyroid and sterno-hyoid muscles, which separate it from the sternum. *Behind*, with the trachea. pneu-

mogastric nerve and cardiac nerves; *externally*, with the right vena innominata and pleura; and *internally*, with the origin of the left carotid.

*Plan of the Relations of the Arteria Innominata.*



The arteria innominata occasionally gives off a small branch, which ascends along the middle of the trachea to the thyroid gland. This branch was described by Neubauer, and Dr. Harrison names it the *middle thyroid artery*. A knowledge of its existence is important in performing the operation of tracheotomy.

COMMON CAROTID ARTERIES.

The common carotid arteries (*κάρα*, the head,) arise, the *right* from the bifurcation of the arteria innominata opposite the right sterno-clavicular articulation, the *left* from the arch of the aorta. It follows, therefore, that the right carotid is shorter than the left; it is also more anterior; and, in consequence of proceeding from a branch instead of from the main trunk, it is larger than its fellow.

The *Right common carotid artery* (fig. 145, No. 5) ascends the neck perpendicularly, from the right sterno-clavicular articulation to a level with the upper border of the thyroid cartilage, where it divides into the external and internal carotid.

The *Left common carotid* (fig. 145, No. 11) passes somewhat obliquely outwards from the arch of the aorta to the side of the neck, and thence upwards to a level with the upper border of the thyroid cartilage, where it divides like the right common carotid into the external and internal carotid.

*Relations.*—The right common carotid rests, first, upon the longus colli muscle, then upon the rectus anticus major, the sympathetic nerve being interposed. The inferior thyroid artery and recurrent laryngeal nerve pass behind it at its lower part. To its *inner side* is the trachea, recurrent laryngeal nerve, and larynx; to its *outer side*, and enclosed in the same sheath, the jugular vein and pneumogastric nerve; and *in front*, the sterno-thyroid, sterno-hyoid, sterno-mastoid, omo-hyoid, and platysma muscles, and the descendens noni nerve. The left common carotid, in addition to the relations just enumerated, which are common to both, is crossed near its commencement by the left vena innominata; it lies upon the trachea; then gets to its side, and is in relation with the œsophagus and thoracic duct: to facilitate the study of these relations, I have arranged them in a tabular form.

*Plan of Relations of the Common Carotid Artery.**In Front.*

Platysma,  
 Descendens noni nerve,  
 Omo-hyoid,  
 Sterno-mastoid,  
 Sterno-hyoid,  
 Sterno-thyroid.

*Externally.*

Internal jugular vein,  
 Pneumogastric nerve.

Common Carotid Artery.

*Internally.*

Trachea,  
 Larynx,  
 Recurrent laryngeal nerve

*Behind.*

Longus colli,  
 Rectus anticus major,  
 Sympathetic,  
 Inferior thyroid artery,  
 Recurrent laryngeal nerve.

*Additional Relations of the Left Common Carotid.**In Front.*

Left vena innominata.

*Behind.*

Trachea.  
 Thoracic duct.

*Internally.*

Arteria innominata,  
 Œsophagus.

*Externally*

Pleura.

## EXTERNAL CAROTID ARTERY.

The *External carotid artery* ascends nearly perpendicularly from opposite the upper border of the thyroid cartilage, to the space between the neck of the lower jaw and the meatus auditorius, where it divides into the temporal and internal maxillary artery.

*Relations.*—*In front* it is crossed by the posterior belly of the digastricus, stylo-hyoideus, and platysma myoides muscles; by the hypoglossal nerve near its origin; higher up it is situated in the substance of the parotid gland, and is crossed by the facial nerve. *Behind*, it is separated from the internal carotid by the stylo-pharyngeus and stylo-glossus muscles, glosso-pharyngeal nerve, and part of the parotid gland.

*Plan of the Relations of the External Carotid Artery.**In Front.*

Platysma,  
 Digastricus,  
 Stylo-hyoid,  
 Hypoglossal nerve,  
 Facial nerve,  
 Parotid gland.

External Carotid Artery.

*Behind.*

Stylo-pharyngeus,  
 Stylo-glossus,  
 Glosso-pharyngeal nerve,  
 Parotid gland.

*Branches.*—The branches of the external carotid are eleven in number, and may be arranged into four groups, viz.

*Anterior.*

1. Superior thyroid,
2. Lingual,
3. Facial.

*Superior.*

7. Ascending pharyngeal,
8. Parotidean,
9. Transverse facial.

*Posterior.*

4. Mastoid,
5. Occipital,
6. Posterior auricular.

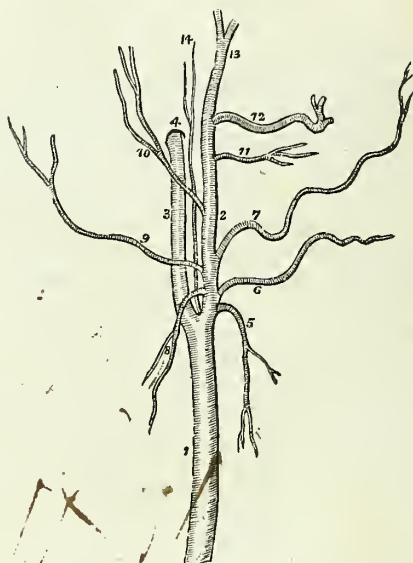
*Terminal.*

10. Temporal,
11. Internal maxillary.

The *anterior branches* arise from the commencement of the external carotid, within a short distance of each other. The lingual and facial bifurcate, not unfrequently, from a common trunk.

1. The SUPERIOR THYROID ARTERY (the first of the branches of the external carotid) curves downwards to the thyroid gland to which it is distributed, anastomosing with its fellow of the opposite side, and with the inferior thyroid arteries. In its course it passes beneath the omo-hyoid, sterno-thyroid, and sterno-hyoid muscles.

Fig. 146.\*



*Branches.*—Hyoid,  
Superior laryngeal,  
Inferior laryngeal,  
Muscular.

\* The carotid arteries, with the branches of the external carotid. 1. The common carotid. 2. The external carotid. 3. The internal carotid. 4. The carotid foramen in the petrous portion of the temporal bone. 5. The superior thyroid artery. 6. The lingual artery. 7. The facial artery. 8. The mastoid artery. 9. The occipital. 10. The posterior auricular. 11. The transverse facial artery. 12. The internal maxillary. 13. The temporal. 14. The ascending pharyngeal artery.

The *Hyoid* branch passes forwards beneath the thyro-hyoideus, and is distributed to the depressor muscles of the os hyoides near their insertion.

The *Superior laryngeal* pierces the thyro-hyoidean membrane, in company with the superior laryngeal nerve, and supplies the mucous membrane and muscles of the larynx, sending a branch upwards to the epiglottis.

The *Inferior laryngeal* is a small branch which crosses the crico-thyroidean membrane along the lower border of the thyroid cartilage. It sends branches through the membrane, to supply the mucous lining of the larynx, and inosculates with its fellow of the opposite side.

The *Muscular* branches are distributed to the depressor muscles of the os hyoides and larynx. One of these branches crosses the sheath of the common carotid to the under surface of the sterno-mastoid muscle.

2. The LINGUAL ARTERY ascends obliquely from its origin, it then passes forwards parallel with the great cornu of the os hyoides; thirdly, it ascends to the under surface of the tongue; and, fourthly, runs forward in a serpentine direction to its tip (under the name of the *ranine artery*), where it terminates by inosculating with its fellow of the opposite side.

*Relations.*—The *first* part of its course rests upon the middle constrictor muscle of the pharynx, being covered in by the tendon of the digastric and the stylo-hyoid muscle; the *second* is situated between the middle constrictor and hyo-glossus muscle, the latter separating it from the hypoglossal nerve; in the *third* part of its course it lies between the hyo-glossus and genio-hyo-glossus; and in the fourth (*ranine*) rests upon the lingualis to the tip of the tongue.

*Branches.*—Hyoid,  
Dorsalis linguæ,  
Sublingual.

The *Hyoid* branch runs along the upper border of the os hyoides, and is distributed to the elevator muscles of the os hyoides near their origin, inosculating with its fellow of the opposite side.

The *Dorsalis linguæ* ascends along the posterior border of the hyo-glossus muscle to the dorsum of the tongue, and is distributed to the tongue, the fauces, and epiglottis, anastomosing with its fellow of the opposite side.

The *Sublingual* branch, sometimes considered as a branch of bifurcation of the lingual, runs along the anterior border of the hyo-glossus, and is distributed to the sublingual gland, and to the muscles of the tongue. It is situated between the mylo-hyoideus and genio-hyo-glossus, generally accompanies Wharton's duct for a part of its course, and sends a branch to the frænum linguæ. It is the latter branch which affords the considerable hæmorrhage which sometimes follows the operation of snipping the frænum in children.

3. FACIAL ARTERY.—The *Facial artery* arises a little above the great cornu of the os hyoides, and descends obliquely to the submaxillary gland, in which it lies embedded. It then curves around the body of the lower jaw, close to the anterior inferior angle of the masseter muscle, ascends to the angle of the mouth, and thence to the angle of the eye, where it is named the *angular artery*. The facial artery is tortuous in its course

over the buccinator muscle, to accommodate itself to the movements of the jaws.

*Relations.*—Below the jaw it passes beneath the digastricus and stylo-hyoid muscles; on the body of the lower jaw it is covered by the platysma myoides, and at the angle of the mouth by the depressor anguli oris and zygomatic muscles. It rests upon the submaxillary gland, the lower jaw, buccinator, orbicularis oris, levator anguli oris, levator labii superioris proprius, and levator labii superioris alæque nasi.

Its *branches* are divided into those which are given off below the jaw and those on the face: they may be thus arranged:—

*Below the Jaw.*—Inferior palatine,  
Submaxillary,  
Submental,  
Pterygoid.

*On the Face.*—Masseteric,  
Inferior labial,  
Inferior coronary,  
Superior coronary,  
Lateralis nasi.

The *Inferior palatine* branch ascends between the stylo-glossus and stylo-pharyngeus muscles, to be distributed to the tonsil and soft palate, and anastomoses with the posterior palatine branch of the internal maxillary artery.

The *Submaxillary* are four or five branches which supply the submaxillary gland.

The *Submental* branch runs forwards upon the mylo-hyoid muscle, under cover of the body of the lower jaw, and anastomoses with branches of the sublingual and inferior dental artery.

The *Pterygoid* branch is distributed to the internal pterygoid muscle.

The *Masseteric* branches are distributed to the masseter and buccinator muscles.

The *Inferior labial* branch is distributed to the muscles and integument of the lower lip.

The *Inferior coronary* runs along the edge of the lower lip, between the mucous membrane and the orbicularis oris; it inosculates with the corresponding artery of the opposite side.

The *Superior coronary* follows the same course along the upper lip, inosculating with the opposite superior coronary artery, and at the middle of the lip it sends a branch upwards, to supply the septum of the nose and the mucous membrane.

The *Lateralis nasi* is distributed to the ala and septum of the nose.

The *Inosculations* of the facial artery are very numerous: thus, it anastomoses with the sublingual branch of the lingual, with the ascending pharyngeal and posterior palatine arteries, with the inferior dental as it escapes from the mental foramen, infra-orbital at the infra-orbital foramen, transverse facial on the side of the face, and at the angle of the eye with the nasal and frontal branches of the ophthalmic artery.

The facial artery is subject to considerable variety in its extent: it not unfrequently terminates at the angle of the nose or mouth, and is rarely symmetrical on both sides of the face.



4. The **MASTOID ARTERY** turns downwards from its origin, to be distributed to the sterno-mastoid muscle, and to the lymphatic glands of the neck; sometimes it is replaced by two small branches.

5. The **OCCIPITAL ARTERY**, smaller than the anterior branches, passes backwards beneath the posterior belly of the digastricus, the trachelo-mastoid and sterno-mastoid muscles, to the occipital groove in the mastoid portion of the temporal bone. It then ascends between the splenius and complexus muscles, and divides into two branches which are distributed upon the occiput, anastomosing with the opposite occipital, the posterior auricular, and temporal artery. The hypoglossal nerve curves around this artery near its origin from the external carotid.

*Branches.*—It gives off only two branches deserving of name, the inferior meningeal and princeps cervicis.

The *Inferior meningeal* ascends by the side of the internal jugular vein, and passes through the foramen lacerum posterius, to be distributed to the dura mater.

The *Arteria princeps cervicis* is a large and irregular branch. It descends the neck between the complexus and semi-spinalis colli, and anastomoses with the profunda cervicis of the subclavian. This branch is the means of establishing a very important collateral circulation between the branches of the carotid and subclavian, after the ligature of the common carotid artery.

6. The **POSTERIOR AURICULAR ARTERY** arises from the external carotid, above the level of the digastric and stylo-hyoid muscles, and ascends beneath the lower border of the parotid gland, and behind the concha, to be distributed by two branches to the external ear and side of the head, anastomosing with the occipital and temporal arteries; some of its branches pass through fissures in the fibro-cartilage, to be distributed to the anterior surface of the pinna. The anterior auricular arteries are branches of the temporal.

*Branches.*—The posterior auricular gives off but one named branch, the *stylo-mastoid*, which enters the stylo-mastoid foramen to be distributed to the aquæductus Fallopii and tympanum.

7. The **ASCENDING PHARYNGEAL ARTERY**, the smallest of the branches of the external carotid, arises from that trunk near its bifurcation, and ascends between the internal carotid and the side of the pharynx to the base of the skull, where it divides into two branches; *meningeal*, which enters the foramen lacerum posterius, to be distributed to the dura mater; and *pharyngeal*. It supplies the pharynx, tonsils, and Eustachian tube.

8. The **PAROTIDEAN ARTERIES** are four or five large branches which are given off from the external carotid whilst that vessel is situated in the parotid gland. They are distributed to the structure of the gland, their terminal branches reaching the integument and the side of the face.

9. The **TRANSVERSALIS FACIEI** arises from the external carotid, whilst that trunk is lodged within the parotid gland; it crosses the masseter muscle, lying parallel with and a little above Stenon's duct; and is distributed to the temporo-maxillary articulation, and to the muscles and in-

tegument of the side of the face, inosculating with the infra-orbital and facial artery. This artery is not unfrequently a branch of the temporal.

10. The TEMPORAL ARTERY is one of the two terminal branches of the external carotid. It ascends over the root of the zygoma; and, at about an inch and a half above the zygomatic arch, divides into an anterior and a posterior temporal branch. The *anterior temporal* is distributed over the front of the temple and arch of the skull, and anastomoses with the opposite anterior temporal, and with the supra-orbital and frontal artery. The *posterior temporal* curves upwards and backwards, and inosculates with its fellow of the opposite side, with the posterior auricular and occipital artery.

The trunk of the temporal artery is covered in by the parotid gland and by the *atrahens aurem* muscle, and rests on the temporal fascia.

*Branches.*—Orbital,  
Anterior auricular,  
Middle temporal.

The *Orbital artery* is a small branch, not always present, which passes forward immediately above the zygoma, between the two layers of the temporal fascia, and inosculates beneath the orbicularis palpebrarum with the palpebral arteries.

The *Anterior auricular arteries* are distributed to the anterior portion of the pinna.

The *Middle temporal branch* passes through an opening in the temporal fascia immediately above the zygoma, and supplies the temporal muscle inosculating with the deep temporal arteries.

11. The INTERNAL MAXILLARY ARTERY, the other terminal branch of the external carotid, has next to be examined.

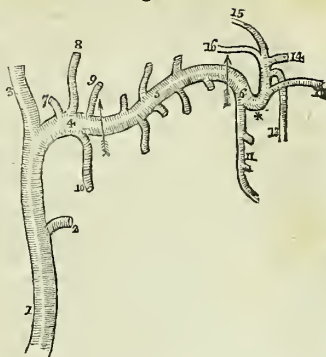
*Dissection.*—The *Internal maxillary artery* passes inwards behind the neck of the lower jaw to the deep structures in the face; we require, therefore, to remove several parts for the purpose of seeing it completely. To obtain a good view of the vessel, the zygoma should be sawn across in front of the external ear, and the malar bone near the orbit. Turn down the zygomatic arch with the masseter muscle. In doing this, a small artery and nerve will be seen crossing the sigmoid notch of the lower jaw, and entering the masseter muscle (the masseteric). Cut away the tendon of the temporal muscle from its insertion into the coronoid process, and turn it upwards towards its origin; some vessels will be seen entering its under surface; these are the *deep temporal*. Then saw the ramus of the jaw across its middle, and dislocate it from its articulation with the temporal bone. Be careful in doing this to carry the blade of the knife close to the bone, lest any branches of nerves should be injured. Next raise this portion of bone, and with it the external pterygoid muscle. The artery, together with the deep branches of the inferior maxillary nerve, will be seen lying on the pterygoid muscles. These are to be carefully freed from fat and areolar tissue, and then examined.

This artery commences in the substance of the parotid gland, opposite the meatus auditorius externus; it passes in the first instance horizontally forward behind the neck of the lower jaw; next, curves around the lower border of the external pterygoid muscle near its origin, and ascends obliquely forwards upon the outer side of that muscle; it then passes between

the two heads of the external pterygoid, and enters the pterygo-maxillary fossa. Occasionally it passes between the two pterygoid muscles, without appearing on the outer surface of the external pterygoid. In consideration of its course, this artery may be divided into three portions: maxillary, pterygoid, and spheno-maxillary.

*Relations.*—The *maxillary* portion is situated between the ramus of the jaw and the internal lateral ligament, lying parallel with the auricular nerve; the *pterygoid* portion between the external pterygoid muscle, and the masseter and temporal muscle. The *pterygo-maxillary* portion lies between the two heads of the external pterygoid muscle, and, in the spheno-maxillary fossa, is in relation with Meckel's ganglion.

Fig. 147.\*

*Branches.**Maxillary Portion.*

Tympanic,  
Inferior dental,  
Arteria meningea media,  
Arteria meningea parva.

*Pterygoid Portion.*

Deep temporal branches,  
External pterygoid,  
Internal pterygoid,  
Masseteric,  
Buccal.

*Pterygo-maxillary Portion.*

Superior dental,  
Infra-orbital,  
Pterygo-palatine,  
Spheno-palatine,  
Posterior palatine,  
Vidian.

The *Tympanic* branch is small, and not likely to be seen in an ordinary dissection; it is distributed to the temporo-maxillary articulation and meatus, and passes into the tympanum through the fissura Glaseri.

The *Inferior dental* descends to the dental foramen, and enters the canal of the lower jaw in company with the dental nerve. Opposite the bicuspid teeth it divides into two branches, one of which is continued onwards within the bone as far as the symphysis, to supply the incisor teeth,

\* 1. The external carotid artery. 2. The trunk of the transverse facial artery. 3, 4. The two terminal branches of the external carotid. 3. The temporal artery; and 4. The internal maxillary, the first or *maxillary portion* of its course; the limit of this portion is marked by an arrow. 5. The second, or *pterygoid portion*, of the artery; the limits are bounded by the arrows. 6. The third or *pterygo-maxillary portion*. The branches of the maxillary portion are, 7. A tympanic branch. 8. The arteria meningea magna. 9. The arteria meningea parva. 10. The inferior dental artery. The branches of the second portion are wholly muscular, the ascending ones being distributed to the temporal, and the descending to the four other muscles of the inter-maxillary region, viz. the two pterygoids, the masseter and buccinator. The branches of the pterygo-maxillary portion of the artery are, 11. The superior dental artery. 12. The infra-orbital artery. 13. The posterior palatine. 14. The spheno-palatine or nasal. 15. The pterygo-palatine. 16. The Vidian. \* The remarkable bend which the third portion of the artery makes as it turns inwards to enter the pterygo-maxillary fossa.

while the other escapes with the nerve at the mental foramen, and anastomoses with the inferior labial and submental branch of the facial. It supplies the teeth of the lower jaw, sending small branches along the canals in their roots.

The *Arteria meningea media* ascends behind the temporo-maxillary articulation to the foramen spinosum in the spinous process of the sphenoid bone, and entering the cranium, divides into an anterior and a posterior branch. The *anterior branch* crosses the great ala of the sphenoid to the groove or canal in the anterior inferior angle of the parietal bone, and divides into branches, which ramify upon the external surface of the dura mater, and anastomose with corresponding branches from the opposite side. The posterior branch crosses the squamous portion of the temporal bone, to the posterior part of the dura mater and cranium. The branches of the *arteria meningea media* are distributed chiefly to the bones of the skull; in the middle fossa this artery sends a small branch through the hiatus Fallopii to the facial nerve.

The *Meningea parva* is a small branch which ascends to the foramen ovale, and passes into the skull to be distributed to the Casserian ganglion and dura mater. It gives off a twig to the nasal fossæ and soft palate.

The *Muscular branches* are distributed, as their names imply, to the five muscles of the maxillary region; the *temporal branches* (*temporales profundæ*) are two in number.

The *Superior dental artery* is given off from the internal maxillary, just as that vessel is about to make its turn inwards to reach the sphenomaxillary fossa. It descends upon the tuberosity of the superior maxillary bone, and sends its branches through several small foramina to supply the posterior teeth of the upper jaw, and the antrum. The terminal branches are continued forwards upon the alveolar process, to be distributed to the gums and to the sockets of the teeth.

The *Infra-orbital* would appear, from its size, to be the proper continuation of the artery. It runs along the infra-orbital canal with the superior maxillary nerve, sending branches into the orbit and downwards, through canals in the bone, to supply the mucous lining of the antrum and the teeth of the upper jaw, and it emerges on the face at the infra-orbital foramen. The branch which supplies the incisor teeth is the *anterior dental artery*; on the face the infra-orbital inosculates with the facial and transverse facial arteries.

The *Pterygo-palatine* is a small branch which passes through the pterygo-palatine canal, and supplies the upper part of the pharynx and Eustachian tube.

The *Spheno-palatine*, or nasal, enters the superior meatus of the nose through the sphenopalatine foramen, in company with the nasal branches of Meckel's ganglion, and divides into two branches; one of which is distributed in the mucous membrane of the septum, while the other supplies the mucous membrane of the lateral wall of the nares, together with the sphenoid and ethmoid cells.

The *Posterior palatine artery* descends along the posterior palatine canal, in company with the posterior palatine branches of Meckel's ganglion, to the posterior palatine foramen; it then curves forward, lying in a groove upon the bone, and is distributed to the palate. While in the posterior palatine canal it sends a branch backwards, through the small posterior palatine foramen, to supply the soft palate, and anteriorly it dis-

tributes a branch to the anterior palatine canal, which reaches the nares, and inosculates with the branches of the sphenopalatine artery.

The *Vidian branch* passes backwards along the pterygoid canal, and is distributed to the sheath of the Vidian nerve, and to the Eustachian tube.

## INTERNAL CAROTID ARTERY.

The internal carotid artery curves slightly outwards from the bifurcation of the common carotid, and then ascends nearly perpendicularly through the maxillo-pharyngeal space\* to the carotid foramen in the petrous bone. It next passes *inwards*, along the carotid canal, *forwards* by the side of the sella turcica, and *upwards* by the anterior clinoid process, where it pierces the dura mater, and divides into three terminal branches. The course of this artery is remarkable for the number of angular curves which it forms; one or two of these flexures are sometimes seen in the cervical portion of the vessel, near the base of the skull; and by the side of the sella turcica it resembles the italic letter *s*, placed horizontally.

*Relations.*—In consideration of its connexions, the artery is divisible into a cervical, petrous, cavernous, and cerebral portion. The *Cervical portion* is in relation *posteriorly* with the rectus anticus major, sympathetic nerve, pharyngeal and laryngeal nerves, which cross behind it, and near the carotid foramen with the glosso-pharyngeal, pneumogastric, and hypoglossal nerves, and partially with the internal jugular vein. *Internally* it is in relation with the side of the pharynx, the tonsil, and the ascending pharyngeal artery. *Externally* with the internal jugular vein, glosso-pharyngeal, pneumogastric, and hypo-glossal nerves; and *in front* with the stylo-glossus, and stylo-pharyngeus muscle, glosso-pharyngeal nerve, and parotid gland.

*Plan of the Relations of the Cervical Portion of the Internal Carotid Artery.*

*In Front.*

Parotid gland,  
Stylo-glossus muscle,  
Stylo-pharyngeus muscle,  
Glosso-pharyngeal nerve.

*Internally.*

Pharynx,  
Tonsil,  
Ascending pharyngeal artery.

Internal Carotid  
Artery.

*Externally.*

Jugular vein,  
Glosso-pharyngeal,  
Pneumogastric,  
Hypo-glossal nerve.

*Behind.*

Superior cervical ganglion,  
Pneumogastric nerve,  
Glosso-pharyngeal nerve,  
Pharyngeal nerve,  
Superior laryngeal nerve,  
Sympathetic nerve,  
Rectus anticus major.

The *Petrous portion* is separated from the bony wall of the carotid canal by a lining of dura mater; it is in relation with the carotid plexus, and is covered in by the Casserian ganglion.

\* For the boundaries of this space see page 188.

The *Cavernous portion* is situated in the inner wall of the cavernous sinus, and is in relation by its outer side with the lining membrane of the sinus, the sixth nerve, and the ascending branches of the carotid plexus. The third, fourth, and ophthalmic nerves are placed in the outer wall of the cavernous sinus, and are separated from the artery by the lining membrane of the sinus.

The *Cerebral portion* of the artery is enclosed in a sheath of the arachnoid, and is in relation with the optic nerve. At its point of division it is situated in the fissure of Sylvius.

*Branches.*—The cervical portion of the internal carotid gives off no branches: from the other portions are derived the following:—

Tympanic,  
Anterior meningeal,  
Ophthalmic,  
Anterior cerebral,  
Middle cerebral,  
Posterior communicating,  
Choroidean.

The *Tympanic* is a small branch which enters the tympanum through a minute foramen in the carotid canal.

The *Anterior meningeal* is distributed to the dura mater and Casserian ganglion.

The *Ophthalmic artery* arises from the cerebral portion of the internal carotid, and enters the orbit through the foramen opticum, immediately to the outer side of the optic nerve. It then crosses the optic nerve to the inner wall of the orbit, and runs along the lower border of the superior oblique muscle, to the inner angle of the eye, where it divides into two terminal branches, the frontal and nasal.

*Branches.*—The branches of the ophthalmic artery may be arranged into two groups: first, those distributed to the orbit and surrounding parts; and, secondly, those which supply the muscles and globe of the eye. They are—

*First Group.*

Lachrymal,  
Supra-orbital,  
Posterior ethmoidal,  
Anterior ethmoidal,  
Palpebral,  
Frontal,  
Nasal.

*Second Group.*

Muscular,  
Anterior ciliary,  
Ciliary short and long,  
Centralis retinae.

The *Lachrymal* is the first branch of the ophthalmic artery, and is usually given off immediately before that artery enters the optic foramen. It follows the course of the lachrymal nerve, along the upper border of the external rectus muscle, and is distributed to the lachrymal gland. The small branches which escape from the gland supply the conjunctiva and upper eyelid. The lachrymal artery gives off a *malar branch* which passes through the malar bone into the temporal fossa and inosculates with the deep temporal arteries, while some of its branches become subcutaneous on the cheek, and anastomose with the transverse facial.

The *Supra-orbital artery* follows the course of the frontal nerve, resting on the levator palpebræ muscle; it passes through the supra-orbital foramen, and divides into a superficial and deep branch, which are distributed to the muscles and integument of the forehead, and to the pericranium. At the supra-orbital foramen it sends a branch inwards to the diploë.

The *Ethmoidal arteries*, *posterior* and *anterior*, pass through the ethmoidal foramina, and are distributed to the falx cerebri and to the ethmoidal cells and nasal fossæ. The latter accompanies the nasal nerve.

The *Palpebral arteries*, *superior* and *inferior*, are given off from the ophthalmic, near the inner angle of the orbit; they encircle the eyelids, forming a superior and an inferior arch near the borders of the lids, between the orbicularis palpebrarum and tarsal cartilage. At the outer angle of the eyelids the superior palpebral inosculates with the orbital branch of the temporal artery. The inferior palpebral artery sends a branch to the nasal duct.

The *Frontal artery*, one of the terminal branches of the ophthalmic, emerges from the orbit at its inner angle, and ascends along the middle of the forehead. It is distributed to the integument, muscles, and pericranium.

The *Nasal artery*, the other terminal branch of the ophthalmic, passes out of the orbit above the tendo oculi, and divides into two branches; one of which inosculates with the angular artery, while the other, the *dorsalis nasi*, runs along the ridge of the nose, and is distributed to the integument of that organ. The nasal artery sends a small branch to the lachrymal sac.

The *Muscular branches*, usually two in number, *superior* and *inferior*, supply the muscles of the orbit; and upon the anterior aspect of the globe of the eye give off the *anterior ciliary arteries*, which pierce the sclerotic near its margin in connection with the cornea, and are distributed to the iris. It is the congestion of these vessels that gives rise to the vascular zone around the cornea in iritis.

The *Ciliary arteries* are divisible into three groups, short, long, and anterior.

The *Short ciliary* are very numerous; they pierce the sclerotic around the entrance of the optic nerve, and supply the choroid coat and ciliary processes. The *long ciliary*, two in number, pierce the sclerotic on opposite sides of the globe of the eye, and pass forwards between it and the choroid to the iris. They form an arterial circle around the circumference of the iris by inosculating with each other, and from this circle branches are given off which ramify in the substance of the iris, and form a second circle around the pupil. The *anterior ciliary* are branches of the muscular arteries; they terminate in the great arterial circle of the iris.

The *Centralis retinæ* artery pierces the optic nerve obliquely, and passes forwards in the centre of its cylinder to the retina, where it divides into branches, which ramify in the inner layer of that membrane. It supplies the retina, hyaloid membrane, and zonula ciliaris; and, by means of a branch sent forwards through the centre of the vitreous humour in a tubular sheath of the hyaloid membrane, the capsule of the lens.

The *Anterior cerebral artery* passes forwards in the great longitudinal fissure between the two hemispheres of the brain; then curves backwards along the corpus callosum to its posterior extremity. It gives branches

to the olfactory and optic nerves, to the under surface of the anterior lobes, the third ventricle, the corpus callosum, and the inner surface of the hemispheres. The two anterior cerebral arteries are connected soon after their origin by a short anastomosing trunk, the *anterior communicating artery*.

The *Middle cerebral artery*, larger than the preceding, passes outwards along the fissure of Sylvius, and divides into three principal branches, which supply the anterior and middle lobes of the brain, and the island of Reil. Near its origin it gives off the numerous small branches which enter the substantia perforata, to be distributed to the corpus striatum.

The *Posterior Communicating artery*, very variable in size, sometimes double, and sometimes altogether absent, passes backwards and inosculates with the posterior cerebral, a branch of the basilar artery. Occasionally it is so large as to take the place of the posterior cerebral artery.

The *Choroidean* is a small branch which is given off from the internal carotid, near the origin of the posterior communicating artery, and passes beneath the edge of the middle lobe of the brain to enter the descending cornu of the lateral ventricle. It is distributed to the choroid plexus, and to the walls of the middle cornu.

#### SUBCLAVIAN ARTERY.

The *Subclavian artery*, on the right side, arises from the arteria innominata, opposite the sterno-clavicular articulation, and on the left, from the arch of the aorta. The right is consequently shorter than the left, and is situated nearer the anterior wall of the chest; it is also somewhat greater in diameter, from being a branch of a branch, in place of a division from the main trunk.

The course of the subclavian artery is divisible, for the sake of precision and surgical observation, into three portions. The first portion of the right and left arteries differs in its course and relations in correspondence with the dissimilarity of origin of the respective arteries. The other two portions are precisely alike on both sides.

The *first portion*, on the *right side*, ascends obliquely outwards to the inner border of the scalenus anticus. On the *left side* it ascends perpendicularly to the inner border of that muscle. The *second portion* curves outwards behind the scalenus anticus; and the *third portion* passes downwards and outwards beneath the clavicle, to the lower border of the first rib, where it becomes the axillary artery.

*Relations.*—The *first portion*, on the *right side*, is in relation, in *front*, with the internal jugular and subclavian vein at their point of junction, and is crossed by the pneumogastric nerve, cardiac nerves, and phrenic nerve. *Behind* and *beneath* it is invested by the pleura, is crossed by the right recurrent laryngeal nerve and vertebral vein, and is in relation with the transverse process of the seventh cervical vertebra. The *first portion* on the *left side* is in relation in *front* with the pleura, the vena innominata, the pneumogastric and phrenic nerves (which lie parallel to it), and the left carotid artery. To its *inner side* is the œsophagus; to its *outer side* the pleura; and *behind*, the thoracic duct, longus colli, and vertebral column.



*Plan of the Relations of the First Portion of the Right Subclavian Artery**In Front.*

Internal jugular vein,  
Subclavian vein,  
Pneumogastric nerve,  
Cardiac nerves,  
Phrenic nerve.

Right Subclavian Artery.

*Behind and Beneath.*

Pleura,  
Recurrent laryngeal nerve,  
Vertebral vein,  
Transverse process of the 7th cervical vertebra.

*Plan of the Relations of the First Portion of the Left Subclavian Artery.**In Front.*

Pleura,  
Vena innominata,  
Pneumogastric nerve,  
Phrenic nerve,  
Left carotid artery.

*Inner Side.*  
Œsophagus.

Left Subclavian Artery.

*Outer Side.*  
Pleura.

*Behind.*

Thoracic duct,  
Longus colli,  
Vertebral column.

The *Second portion* is situated between the two scaleni, and is supported by the margin of the first rib. The scalenus anticus separates it from the subclavian vein and phrenic nerve. Behind, it is in relation with the brachial plexus.

The *Third portion* is in relation, *in front*, with the subclavian vein and subclavius muscle; *behind*, with the brachial plexus and scalenus posticus; *below* with the first rib; and *above* with the supra-scapular artery and platysma.

*Plan of the Relations of the Third Portion of the Subclavian Artery.**Above.*

Supra-scapular artery,  
Platysma myoides.

*In Front.*  
Subclavian vein,  
Subclavius.

Subclavian artery,  
Third portion.

*Behind.*  
Brachial plexus,  
Scalenus posticus.

*Below.*

First rib.

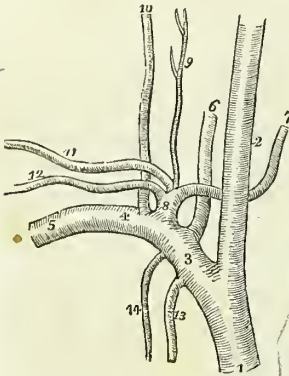
*Branches.*—The greater part of the branches of the subclavian are given off from the artery before it arrives at the margin of the first rib. The profunda cervicis and superior intercostal frequently encroach upon the second portion, and not unfrequently a branch or branches may be found proceeding from the third portion.

The primary branches are five in number, the first three being ascending, and the remaining two descending: they are the—

|                                            |                                                                                        |
|--------------------------------------------|----------------------------------------------------------------------------------------|
| Vertebral,                                 | { Inferior thyroid,<br>Supra-scapular,<br>Posterior scapular,<br>Superficial cervicis. |
| Thyroid axis,                              |                                                                                        |
| Profunda cervicis,                         |                                                                                        |
| Superior intercostal,<br>Internal mammary. |                                                                                        |

The VERTEBRAL ARTERY is the first and the largest of the branches of the subclavian artery; it ascends through the foramina in the transverse processes of all the cervical vertebræ, excepting the last; then winds backwards around the articulating process of the atlas; and, piercing the dura mater, enters the skull through the foramen magnum. The two arteries unite at the lower border of the pons Varolii, to form the *basilar artery*. In the foramina of the transverse processes of the vertebræ the artery lies in front of the cervical nerves.

Fig. 148.\*



Dr. John Davy† has observed that, when the vertebral arteries differ in size, the left is generally the larger: thus in ninety-eight cases he found the left vertebral the larger twenty-six times, and the right only eight. In the same number of cases he found a small band stretching across the cylinder of

the basilar artery, near the junction of the two vertebral arteries, seventeen times, and in a few instances a small communicating trunk between the two vertebral arteries previously to their union. I have several times seen this communicating branch, and have a preparation now before me in which it is exhibited.

The BASILAR ARTERY, so named from its position at the base of the brain, runs forwards to the anterior border of the pons Varolii, where it divides into four ultimate branches, two to either side.

*Branches.*—The branches of the vertebral and basilar arteries are the following:—

\* The branches of the right subclavian artery. 1. The arteria innominata. 2. The right carotid. 3. The first portion of the subclavian artery. 4. The second portion. 5. The third portion. 6. The vertebral artery. 7. The inferior thyroid. 8. The thyroid axis. 9. The superficialis cervicis. 10. The profunda cervicis. 11. The posterior scapular or transversalis colli. 12. The supra-scapular. 13. The internal mammary artery. 14. The superior intercostal.

† Edinburgh Medical and Surgical Journal, 1839.

|                   |   |                      |
|-------------------|---|----------------------|
| <i>Vertebral,</i> | { | Lateral spinal,      |
|                   |   | Posterior meningeal, |
|                   |   | Anterior spinal,     |
|                   |   | Posterior spinal,    |
|                   |   | Inferior cerebellar. |
| <i>Basilar,</i>   | { | Transverse,          |
|                   |   | Superior cerebellar, |
|                   |   | Posterior cerebral.  |

The *Lateral spinal* branches enter the intervertebral foramina, and are distributed to the spinal cord and to its membranes. Where the vertebral artery curves around the articular process of the atlas, it gives off several muscular branches.

The *Posterior meningeal* are one or two small branches which enter the cranium through the foramen magnum, to be distributed to the dura mater of the cerebellar fossæ, and to the falx cerebelli. One branch, described by Soemmering, passes into the cranium along the first cervical nerve.

The *Anterior spinal* is a small branch which unites with its fellow of the opposite side, on the front of the medulla oblongata. The artery formed by the union of these two vessels, descends along the anterior aspect of the spinal cord, to which it distributes branches.

The *Posterior spinal* winds around the medulla oblongata to the posterior aspect of the cord, and descends on either side, communicating very freely with the spinal branches of the intercostal and lumbar arteries. Near its commencement it sends a branch upwards to the four ventricle.

The *Inferior cerebellar* arteries wind around the upper part of the medulla oblongata to the under surface of the cerebellum, to which they are distributed. They pass between the filaments of origin of the hypoglossal nerve in their course, and anastomose with the superior cerebellar arteries.

The *Transverse* branches of the basilar artery supply the pons Varolii, and adjacent parts of the brain. One of these branches, larger than the rest, passes along the crus cerebelli, to be distributed to the anterior border of the cerebellum. This may be called the middle cerebellar artery.

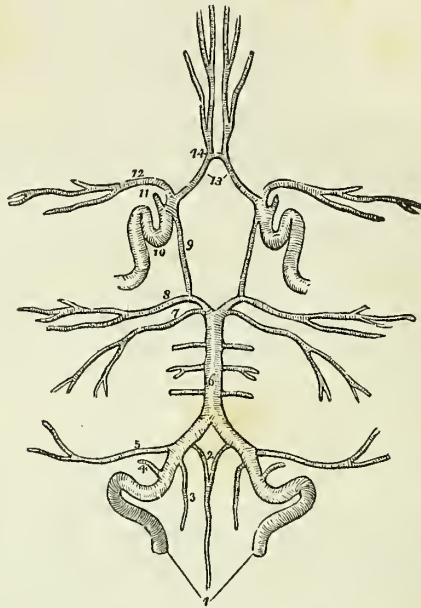
The *Superior cerebellar* arteries, two of the terminal branches of the basilar, wind around the crus cerebri on each side, lying in relation with the fourth nerve, and are distributed to the upper surface of the cerebellum, inosculating with the inferior cerebellar. This artery gives off a small branch, which accompanies the seventh pair of nerves into the meatus auditorius internus.

The *Posterior cerebral* arteries, the other two terminal branches of the basilar, wind around the crus cerebri at each side, and are distributed to the posterior lobes of the cerebrum. They are separated from the superior cerebellar arteries, near their origin, by the third pair of nerves, and are in close relation with the fourth pair, in their course around the crura cerebri. Anteriorly, near their origin, they give off a tuft of small vessels, which enter the locus perforatus, and they receive the posterior communicating arteries from the internal carotid. They also send a branch to the velum interpositum and plexus choroides.

The communications established between the anterior cerebral arteries in front, and the internal carotids and posterior cerebral arteries behind, by the communicating arteries, constitute the circle of Willis. This

remarkable communication at the base of the brain is formed by the anterior communicating branch, anterior cerebrals, and internal carotid arteries,

Fig. 149.\*



in front, and by the posterior communicating, posterior cerebrals, and basilar artery, behind.

The **THYROID AXIS** is a short trunk, which divides almost immediately after its origin into four branches, some of which are occasionally branches of the subclavian artery itself.

The **INFERIOR THYROID ARTERY** ascends obliquely in a serpentine course behind the sheath of the carotid vessels, to the inferior part of the thyroid gland, to which it is distributed; it sends branches also to the trachea, lower part of the larynx, and œsophagus. It is in relation with the middle cervical ganglion of the sympathetic, which lies in front of it.

The **SUPRA-SCAPULAR ARTERY** (transversalis humeri) passes obliquely outwards behind the clavicle, and over the ligament of the supra-scapular notch, to the supra-spinatus fossa. It crosses in its course the scalenus anticus muscle, phrenic nerve, and subclavian artery, is distributed to the

\* The circle of Willis. The arteries have references only on one side, on account of their symmetrical distribution. 1. The vertebral arteries. 2. The two anterior spinal branches uniting to form a single vessel. 3. One of the posterior spinal arteries. 4. The posterior meningeal. 5. The inferior cerebellar. 6. The basilar artery giving off its transverse branches to either side. 7. The superior cerebellar artery. 8. The posterior cerebral. 9. The posterior communicating branch of the internal carotid. 10. The internal carotid artery, showing the curvatures it makes within the skull. 11. The ophthalmic artery divided across. 12. The middle cerebral artery. 13. The anterior cerebral arteries connected by, 14. The anterior communicating artery.

muscles on the dorsum of the scapula, and inosculates with the posterior scapular, and beneath the acromion process with the dorsal branch of the subscapular artery. At the supra-scapular notch it sends a large branch to the trapezius muscle. The supra-scapular artery is not unfrequently a branch of the subclavian.

The POSTERIOR SCAPULAR ARTERY (*transversalis colli*) passes transversely across the subclavian triangle at the root of the neck, to the superior angle of the scapula. It then descends along the posterior border of that bone to its inferior angle, where it inosculates with the subscapular artery, a branch of the axillary. In its course across the neck it passes in front of the scalenus anticus, and across the brachial plexus; in the rest of its course it is covered in by the trapezius, levator anguli scapulæ, rhomboideus minor, and rhomboideus major muscles. Sometimes it passes behind the scalenus anticus, and between the nerves, which constitute the brachial plexus. This artery, which is very irregular in its origin, proceeds more frequently from the third portion of the subclavian artery than from the first.

The posterior scapular gives branches to the neck, and opposite the angle of the scapula inosculates with the profunda cervicis. It supplies the muscles along the posterior border of the scapula, and establishes an important anastomotic communication between the branches of the external carotid, subclavian, and axillary arteries.

The SUPERFICIALIS CERVICIS ARTERY (*cervicalis anterior*) is a small vessel, which ascends upon the anterior tubercles of the transverse processes of the cervical vertebræ, lying in the groove between the scalenus anticus and rectus anticus major. It is distributed to the deep muscles and glands of the neck, and sends branches through the intervertebral foramina to supply the spinal cord and its membranes.

The PROFUNDA CERVICIS (*cervicalis posterior*) passes backwards between the transverse processes of the seventh cervical and first dorsal vertebræ, and then ascends the back part of the neck, between the complexus and semi-spinalis colli muscles. It inosculates above with the princeps cervicis of the occipital artery, and below, by a descending branch, with the posterior scapular.

The SUPERIOR INTERCOSTAL ARTERY descends behind the pleura upon the necks of the first two ribs, and inosculates with the first aortic intercostal. It gives off two branches which supply the first two intercostal spaces.

The INTERNAL MAMMARY ARTERY descends by the side of the sternum, resting against the costal cartilages, to the diaphragm; it then pierces the anterior fibres of the diaphragm, and enters the sheath of the rectus, where it inosculates with the epigastric artery, a branch of the external iliac. In the upper part of its course it is crossed by the phrenic nerve, and lower down lies between the triangularis sterni and the internal intercostal muscles.

The *Branches* of the internal mammary are,—

|                       |                  |
|-----------------------|------------------|
| Anterior intercostal, | Mediastinal,     |
| Mammary,              | Pericardiac,     |
| Comes nervi phrenici, | Musculo-phrenic. |

The *Anterior intercostals* supply the intercostal muscles of the front of the chest, and inosculate with the aortic intercostal arteries. Each of the first three anterior intercostals gives off a large branch to the mammary gland, which anastomoses freely with the thoracic branches of the axillary artery; the corresponding branches from the remaining intercostals supply the integument and pectoralis major muscle. There are usually two anterior intercostal arteries in each space.

The *Comes nervi phrenici* is a long and slender branch which accompanies the phrenic nerve.

The *mediastinal* and *pericardiac* branches are small vessels distributed to the anterior mediastinum, the thymus gland, and pericardium.

The *Musculo-phrenic* artery winds along the attachment of the diaphragm to the ribs, supplying that muscle, and sending branches to the inferior intercostal spaces. "The mammary arteries," says Dr. Harrison, "are remarkable for the number of their inosculations, and for the distant parts of the arterial system which they serve to connect. They anastomose with each other, and their inosculations, with the thoracic aorta, encircle the thorax. On the parietes of this cavity their branches connect the axillary and subclavian arteries; on the diaphragm they form a link in the chain of inosculations between the subclavian artery and abdominal aorta, and in the parietes of the abdomen they form an anastomosis most remarkable for the distance between those vessels which it serves to connect; namely, the arteries of the superior and inferior extremities."

*Varieties of the subclavian Arteries.*—Varieties in these arteries are rare; that which most frequently occurs is the origin of the right subclavian, from the left extremity of the arch of the aorta, below the left subclavian artery. The vessel, in this case, curves behind the œsophagus and right carotid artery, and sometimes between the œsophagus and trachea, to the upper border of the first rib on the right side of the chest, where it assumes its ordinary course. In a case\* of subclavian aneurism on the right side, above the clavicle, which happened during the summer of 1839, Mr. Liston proceeded to perform the operation of tying the carotid and subclavian arteries at their point of division from the innominate. Upon reaching the spot where the bifurcation should have existed, he found that there was no subclavian artery. With the admirable self-possession which distinguishes this eminent surgeon in all cases of emergency, he continued his dissection more deeply, towards the vertebral column, and succeeded in securing the artery. It was ascertained after death, that the arteria innominate was extremely short, and that the subclavian was given off within the chest from the posterior aspect of its trunk, and pursued a deep course to the upper margin of the first rib. In a preparation which was shown to me in Heidelberg some years since by Professor Tiedemann, the right subclavian artery arose from the thoracic aorta, as low down as the fourth dorsal vertebra, and ascended from that point to the border of the first rib. Varieties in the branches of the subclavian are not unfrequent; the most interesting is the origin of the left vertebral from the arch of the aorta, of which I possess several preparations.

#### AXILLARY ARTERY.

The *axillary artery* forms a gentle curve through the middle of the

\* This case is recorded in the *Lancet*, vol. i. 1839-40, pp. 37 and 419.

axillary space from the lower border of the first rib to the lower border of the latissimus dorsi, where it becomes the brachial.

*Relations.*—After emerging from beneath the margin of the costo-coraoid membrane, it is in relation with the axillary vein, which lies at first to the inner side, and then in front of the artery. Near the middle of the axilla it is embraced by the two heads of the median nerve, and is covered in by the pectoral muscles. Upon the *inner or thoracic side* it is in relation, first, with the first intercostal muscle; it next rests upon the first serration of the serratus magnus; and is then separated from the chest by the brachial plexus of nerves. By its *outer or humeral side* it is at first separated from the brachial plexus by a triangular interval of areolar tissue; it next rests against the tendon of the subscapularis muscle; and thirdly, upon the coraco-brachialis muscle.

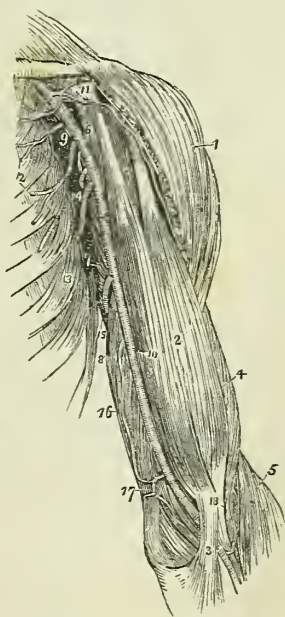
The *relations* of the axillary artery may be thus arranged :—

| <i>In Front.</i>  | <i>Inner or Thoracic Side.</i> | <i>Outer or Humeral Side.</i> |
|-------------------|--------------------------------|-------------------------------|
| Pectoralis major, | First intercostal muscle,      | Plexus of nerves,             |
| Pectoralis minor, | First serration of serra-      | Tendon of sub-                |
| Pectoralis major. | tus magnus,-                   | scapularis,                   |
|                   | Plexus of nerves.              | Coraco-brachialis.            |

*Branches.*—The branches of the *Axillary artery* are seven in number :—

- Thoracica acromialis,
- Superior thoracic,
- Inferior thoracic,
- Thoracica axillaris,
- Subscapular,
- Circumflex anterior,
- Circumflex posterior.

Fig. 150.\*



The thoracica acromialis and superior thoracic are found in the triangular space above the pectoralis minor. The inferior thoracic and thoracica axillaris, below the pectoralis minor. And the three remaining branches below the lower border of the subscapularis.

The *Thoracica acromialis* is a short trunk which ascends to the space above the pectoralis minor muscle, and divides into three branches, *thoracic*, which is distributed to the pectoral muscles and mammary gland; *acromial*, which passes outwards to the acromion, and inosculates with branches of the supra-scapular artery; and *descending*, which follows the interspace between the deltoid and pectoralis major muscles, and is in relation with the cephalic vein.

\* The axillary and brachial artery, with their branches. 1. The deltoid muscle. 2. The biceps. 3. The tendinous process given off from the tendon of the biceps, to the deep fascia of the fore-arm. It is this process which separates the median basilic vein from the brachial artery. 4. The outer border of the brachialis anticus muscle. 5. The supinator longus. 6. The coraco-brachialis. 7. The middle portion of the triceps

The *Superior thoracic* (short) frequently arises by a common trunk with the preceding; it runs along the upper border of the pectoralis minor, and is distributed to the pectoral muscles and mammary gland, inosculating with the intercostal and mammary arteries.

The *Inferior thoracic* (long external mammary) descends along the lower border of the pectoralis minor to the side of the chest. It is distributed to the pectoralis major and minor, serratus magnus, and subscapularis muscle, to the axillary glands and mammary gland; inosculating with the superior thoracic, intercostal, and mammary arteries.

The *Thoracica axillaris* is a small branch distributed to the plexus of nerves and glands in the axilla. It is frequently derived from one of the other thoracic branches.

The *Subscapular artery*, the largest of the branches of the axillary, runs along the lower border of the subscapularis muscle, to the inferior angle of the scapula, where it inosculates with the posterior scapular, a branch of the subclavian. It supplies, in its course, the muscles on the under surface and inferior border of the scapula, and the side of the chest. At about an inch and a half from the axillary, it gives off a large branch, the *dorsalis scapulae*, which passes backwards through the triangular space bounded by the teres minor, teres major, and scapular head of the triceps, and beneath the infra-spinatus to the dorsum of the scapula, where it is distributed, inosculating with the supra-scapular and posterior scapular arteries.

The *Circumflex arteries* wind around the neck of the humerus. The *anterior*, very small, passes beneath the coraco-brachialis and short head of the biceps, and sends a branch upwards along the bicipital groove to supply the shoulder joint.

The *Posterior circumflex*, of larger size, passes backwards through the quadrangular space bounded by the teres minor and major, the scapular head of the triceps and the humerus, and is distributed to the deltoid muscle and joint. Sometimes this artery is a branch of the superior profunda of the brachial. It then ascends behind the tendon of the teres major, and is distributed to the deltoid without passing through the quadrangular space. The posterior circumflex artery sends branches to the shoulder joint.

*Varieties of the Axillary artery.*—The most frequent peculiarity of this kind is the division of the vessel into two trunks of equal size: a muscular trunk, which gives off some of the ordinary axillary branches and supplies the upper arm, and a continued trunk, which represents the brachial artery. The next most frequent variety is the high division of the ulnar which passes down the arm by the side of the brachial artery, and superficially to the muscles proceeding from the inner condyle, to its ordinary distribution in the hand. In this course it lies immediately beneath the muscle. 8. Its inner head. 9. The axillary artery. 10. The brachial artery;—a dark line marks the limit between these two vessels. 11. The thoracica acromialis artery dividing into its three branches; the number rests upon the coracoid process. 12. The superior and inferior thoracic arteries. 13. The serratus magnus muscle. 14. The subscapular artery. The posterior circumflex and thoracica axillaris branches are seen in the figure between the inferior thoracic and subscapular. The anterior circumflex is observed, between the two heads of the biceps, crossing the neck of the humerus. 15. The superior profunda artery. 16. The inferior profunda. 17. The anastomotic magna inosculating inferiorly with the anterior ulnar recurrent. 18. The termination of the superior profunda, inosculating with the radial recurrent in the interspace between the brachialis anticus and supinator longus.



deep fascia of the fore-arm, and may be seen and felt pulsating beneath the integument. The high division of the radial from the axillary is rare. In one instance, I saw the axillary artery divide into three branches of nearly equal size which passed together down the arm, and at the bend of the elbow resolved themselves into radial, ulnar, and interosseous. But the most interesting variety, both in a physiological and surgical sense, is that described by Dr. Jones Quain, in his "Elements of Anatomy." "I found in the dissecting-room, a few years ago, a variety not hitherto noticed; it was at first taken for the ordinary high division of the ulnar artery. The two vessels descended from the point of division at the border of the axilla, and lay parallel with one another in their course through the arm; but instead of diverging, as is usual, at the bend of the elbow, they converged, and united so as to form a short trunk which soon divided again into the radial and ulnar arteries in the regular way." In a subject, dissected by myself, this variety existed in both arms; and I have seen several instances of a similar kind.

## BRACHIAL ARTERY.

The *Brachial artery* passes down the inner side of the arm, from the lower border of the latissimus dorsi to the bend of the elbow, where it divides into the radial and ulnar arteries.

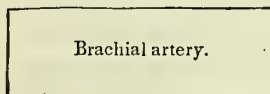
*Relations.*—In its course downwards, it rests upon the coraco-brachialis muscle, internal head of the triceps, brachialis anticus, and the tendon of the biceps. To its inner side is the ulnar nerve; to the outer side, the coraco-brachialis and biceps muscles; in front it has the basilic vein, and is crossed by the median nerve. Its relations, within its sheath, are the venæ comites.

*Plan of the Relations of the Brachial Artery.**In Front.*

Basilic vein,  
Deep fascia,  
Median nerve.

*Inner Side.*

Ulnar nerve.



Brachial artery.

*Outer Side.*

Coraco-brachialis,  
Biceps.

*Behind.*

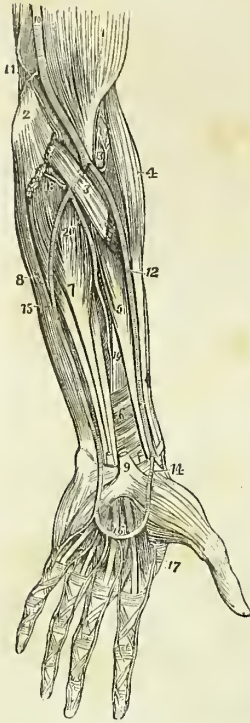
Short head of triceps,  
Coraco-brachialis,  
Brachialis anticus,  
Tendon of biceps.

The *branches* of the brachial artery are, the—

Superior profunda,  
Inferior profunda,  
Anastomotica magna,  
Muscular.

The *Superior profunda* arises opposite the lower border of the latissimus dorsi, and winds around the humerus, between the triceps and the bone, to the space between the brachialis anticus and supinator longus, where it

Fig. 151.\*



inoculates with the radial recurrent branch. It accompanies the musculo-spiral nerve. In its course it gives off the posterior articular artery, which descends to the elbow joint, and a more superficial branch which inoculates with the interosseous articular artery.

The *Inferior profunda* arises from about the middle of the brachial artery, and descends to the space between the inner condyle and olecranon in company with the ulnar nerve, where it inoculates with the posterior ulnar recurrent.

The *Anastomotica magna* is given off nearly at right angles from the brachial, at about two inches above the joint. It passes directly inwards, and divides into two branches which inoculate with the anterior and posterior ulnar recurrent arteries and with the inferior profunda.

The *Muscular branches* are distributed to the muscles in the course of the artery, viz. to the coraco-brachialis, biceps, deltoid, brachialis anticus and triceps.

*Varieties of the Brachial Artery.*—The most frequent peculiarity in the distribution of branches from this artery is the high division of the radial, which arises generally from about the upper third of the brachial artery, and descends to its normal position at the bend of the elbow. The ulnar artery sometimes arises from the brachial at about two inches above the elbow, and pursues either a superficial or deep course to the wrist;

and, in more than one instance, I have seen the interosseous artery arise from the brachial a little above the bend of the elbow. The two profunda arteries occasionally arise by a common trunk, or there may be two superior profunda.

#### RADIAL ARTERY.

The *Radial artery*, one of the divisions of the brachial, appears, from its direction, to be the continuation of that trunk. It runs along the radial side of the fore-arm, from the bend of the elbow to the wrist; it there turns around the base of the thumb, beneath its extensor tendons, and

\* The arteries of the fore-arm. 1. The lower part of the biceps muscle. 2. The inner condyle of the humerus with the humeral origin of the pronator radii teres and flexor carpi radialis divided across. 3. The deep portion of the pronator radii teres. 4. The supinator longus muscle. 5. The flexor longus pollicis. 6. The pronator quadratus. 7. The flexor profundus digitorum. 8. The flexor carpi ulnaris. 9. The annular ligament with the tendons passing beneath it into the palm of the hand; the figure is placed on the tendon of the palmaris longus muscle, divided close to its insertion. 10. The brachial artery. 11. The anastomotica magna inoculating superiorly with the inferior profunda, and inferiorly with the anterior ulna recurrent. 12. The radial artery. 13. The radial recurrent artery inoculating with the termination of the superior profunda. 14. The superficialis volæ. 15. The ulnar artery. 16. Its superficial palmar arch giving off digital branches to three fingers and a half. 17. The magna pollicis and radialis arteries. 18. The posterior ulnar recurrent. 19. The anterior interosseous artery. 20. The posterior interosseous, as it is passing through the interosseous membrane.

passes between the two heads of the first dorsal interosseous muscle, into the palm of the hand. It then crosses the metacarpal bones to the ulnar side of the hand, forming the *deep palmar arch*, and terminates by inosculating with the superficial palmar arch.

In the upper half of its course, the radial artery is situated between the supinator longus muscle, by which it is overlapped superiorly, and the pronator radii teres; in the lower half, between the tendons of the supinator longus and flexor carpi radialis. It rests in its course downwards, upon the supinator brevis, pronator radii teres, radial origin of the flexor sublimis, flexor longus pollicis, and pronator quadratus; and is covered in by the integument and fasciæ. At the wrist it is situated in contact with the dorsal carpal ligaments and beneath the extensor tendons of the thumb; and, in the palm of the hand, beneath the flexor tendons. It is accompanied by venæ comites throughout its course, and by its middle third is in close relation with the radial nerve.

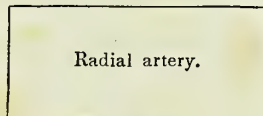
*Plan of the Relations of the Radial Artery in the Fore-arm.*

*In Front.*

Deep fascia,  
Supinator longus.

*Inner Side.*

Pronator radii teres,  
Flexor carpi radialis.



*Outer side.*

Supinator longus,  
Radial nerve (middle  
third of its course).

*Behind.*

Supinator brevis,  
Pronator radii teres,  
Flexor sublimis digitorum,  
Flexor longus pollicis.  
Pronator quadratus,  
Wrist joint.

The *Branches* of the radial artery may be arranged into three groups, corresponding with the three regions, the fore-arm, the wrist, and the hand; they are—

|                  |   |                                                                                                         |
|------------------|---|---------------------------------------------------------------------------------------------------------|
| <i>Fore-arm,</i> | { | Recurrent radial,<br>Muscular.                                                                          |
| <i>Wrist,</i>    | { | Superficialis volæ,<br>Carpalis anterior,<br>Carpalis posterior,<br>Metacarpalis,<br>Dorsales pollicis. |
| <i>Hand,</i>     | { | Princeps pollicis,<br>Radialis indicis,<br>Interosseæ,<br>Perforantes.                                  |

The *Recurrent* branch is given off immediately below the elbow; it ascends in the space between the supinator longus and brachialis anticus to supply the joint, and inosculates with the terminal branches of the superior profunda. This vessel gives off numerous muscular branches.

The *Muscular branches* are distributed to the muscles on the radial side of the fore-arm.

The *Superficialis volæ* is given off from the radial artery while at the wrist. It passes between the fibres of the abductor pollicis muscle, and inosculates with the termination of the ulnar artery, completing the superficial palmar arch. This artery is very variable in size, being sometimes as large as the continuation of the radial, and at other times a mere muscular ramusculus, or entirely wanting; when of large size it supplies the palmar side of the thumb and the radial side of the index finger.

The *Carpal* branches are intended for the supply of the wrist, the anterior carpal *in front*, and the posterior, the larger of the two, *behind*. The *carpalis posterior* crosses the carpus transversely to the ulnar border of the hand, where it inosculates with the posterior carpal branch of the ulnar artery. Superiorly it sends branches which inosculate with the termination of the anterior interosseous artery; inferiorly it gives off *posterior interosseous branches*, which anastomose with the perforating branches of the deep palmar arch, and then run forward upon the dorsal interossei muscles.

The *Metacarpal* branch runs forward on the second dorsal interosseous muscle, and inosculates with the digital branch of the superficial palmar arch, which supplies the adjoining sides of the index and middle fingers. Sometimes it is of large size, and the true continuation of the radial artery.

The *Dorsales pollicis* are two small branches which run along the sides of the dorsal aspect of the thumb.

The *Princeps pollicis* descends along the border of the metacarpal bone, between the abductor indicis and adductor pollicis to the base of the first phalanx, where it divides into two branches, which are distributed to the two sides of the palmar aspect of the thumb.

The *Radialis indicis* is also situated between the abductor indicis and the adductor pollicis, and runs along the radial side of the index finger, forming its collateral artery. This vessel is frequently a branch of the princeps pollicis.

The *Interossea*, three or four in number, are branches of the deep palmar arch; they pass forward upon the interossei muscles, and inosculate with the digital branches of the superficial arch, opposite the heads of the metacarpal bones.

The *Perforantes*, three in number, pass directly backwards between the heads of the dorsal interossei muscles, and inosculate with the posterior interosseous arteries.

#### ULNAR ARTERY.

The *Ulnar artery*, the other division of the brachial artery, crosses the arm obliquely to the commencement of its middle third; it then runs down the ulnar side of the fore-arm to the wrist, crosses the annular ligament, and forms the superficial palmar arch, which terminates by inosculating with the superficialis volæ.

*Relations.*—In the upper or oblique portion of its course, it lies upon the brachialis anticus and flexor profundus digitorum; and is covered in by the superficial layer of muscles of the fore-arm and by the median nerve. In the second part of its course, it is placed upon the flexor profundus and pronator quadratus, lying between the flexor carpi ulnaris and flexor sublimis digitorum. While crossing the annular ligament it is protected from injury by a strong tendinous arch, thrown over it from the pisiform bone;

and in the palm it rests upon the tendons of the flexor sublimis, being covered in by the palmaris brevis muscle and palmar fascia. It is accompanied in its course by the venæ comites, and is in relation with the ulnar nerve for the lower two-thirds of its extent.

*Plan of the Relations of the Ulnar Artery.*

*In Front.*

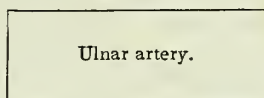
Deep fascia,  
Superficial layer of muscles,  
Median nerve.

*In the Hand.*

Tendinous arch from the pisiform bone,  
Palmaris brevis muscle,  
Palmar fascia.

*Inner Side.*

Flexor carpi ulnaris,  
Ulnar nerve (lower,  
two-thirds).



*Outer Side.*

Flexor sublimis digi-  
torum.

*Behind.*

Brachialis anticus,  
Flexor profundus digitorum,  
Pronator quadratus.

*In the Hand.*

Annular ligament,  
Tendons of the flexor sublimis digitorum.

The *Branches* of the *ulnar artery* may be arranged, like those of the radial, into three groups :—

|                  |   |                            |   |                         |
|------------------|---|----------------------------|---|-------------------------|
| <i>Fore-arm,</i> | { | Anterior ulnar recurrent,  | { | Anterior interosseous,  |
|                  |   | Posterior ulnar recurrent, |   | Posterior interosseous. |
| <i>Wrist,</i>    | { | Interosseous,              | { |                         |
|                  |   | Muscular.                  |   |                         |
| <i>Hand,</i>     | { | Carpalis anterior,         | { |                         |
|                  |   | Carpalis posterior.        |   |                         |
|                  |   | Digitales.                 |   |                         |

The *Anterior ulnar recurrent* arises immediately below the elbow, and ascends in front of the joint between the pronator radii teres and brachialis anticus, where it inosculates with the anastomotica magna and inferior profunda. The two recurrent arteries frequently arise by a common trunk.

The *Posterior ulnar recurrent*, larger than the preceding, arises immediately below the elbow joint, and passes backwards beneath the origins of the superficial layer of muscles; it then ascends between the two heads of the flexor carpi ulnaris, and beneath the ulnar nerve, and inosculates with the inferior profunda and anastomotica magna.

The *Common interosseous artery* is a short trunk which arises from the ulnar, opposite the bicipital tuberosity of the radius. It divides into two branches, the anterior and posterior interosseous arteries.

The *Anterior interosseous* passes down the fore-arm upon the interosseous membrane, between the flexor profundus digitorum and flexor longus pollicis, and behind the pronator quadratus. In the latter position it pierces the interosseous membrane, and descends to the back of the wrist, where it inosculates with the posterior carpal branches of the radial and ulnar. It is retained in connexion with the interosseous membrane by means of a thin aponeurotic arch.

The anterior interosseous artery sends a branch to the median nerve, which it accompanies into the hand. The *median* artery is sometimes of large size, and occasionally takes the place of the superficial palmar arch.

The *Posterior interosseous* artery passes backwards through an opening between the upper part of the interosseous membrane and the oblique ligament, and is distributed to the muscles on the posterior aspect of the fore-arm. It gives off a *recurrent branch*, which returns upon the elbow between the anconeus, extensor carpi ulnaris and supinator brevis muscles, and anastomoses with the posterior terminal branches of the superior profunda.

The *Muscular branches* supply the muscles situated along the ulnar border of the fore-arm.

The *Carpal branches*, *anterior* and *posterior*, are distributed to the anterior and posterior aspects of the wrist joint, where they inosculate with corresponding branches of the radial artery.

The *Digital branches* are given off from the superficial palmar arch, and are four in number. The first and smallest is distributed to the ulnar side of the little finger. The other three are short trunks, which divide between the heads of the metacarpal bones, and form the collateral branch of the radial side of the little finger, the collateral branches of the ring and middle fingers, and the collateral branch of the ulnar side of the index finger.

The *Superficial palmar arch* receives the termination of the deep palmar arch from between the abductor minimi digiti and flexor brevis minimi digiti near their origins, and terminates by inosculating with the superficialis volæ upon the ball of the thumb. The communication between the superficial and deep arch is generally described as the *communicating branch* of the ulnar artery.

The mode of distribution of the arteries to the hand is subject to frequent variety.

#### BRANCHES OF THE THORACIC AORTA.

Bronchial,  
Œsophageal,  
Intercostal.

The BRONCHIAL ARTERIES are four in number, and vary both in size and origin. They are distributed to the bronchial glands and tubes, and send branches to the œsophagus, pericardium, and left auricle of the heart. These are the nutritious vessels of the lungs.

The ŒSOPHAGEAL ARTERIES are numerous small branches; they arise from the anterior part of the aorta, are distributed to the œsophagus, and establish a chain of anastomoses along that tube: the superior inosculate with the bronchial arteries, and with œsophageal branches of the inferior

thyroid arteries; and the inferior with similar branches of the phrenic and gastric arteries.

The INTERCOSTAL, or posterior intercostal arteries, arise from the posterior part of the aorta; they are nine in number on each side, the two superior spaces being supplied by the superior intercostal artery, a branch of the subclavian. The right intercostals are longer than the left, on account of the position of the aorta. They ascend somewhat obliquely from their origin, and cross the vertebral column behind the thoracic duct, vena azygos major, and sympathetic nerve, to the intercostal spaces, the left passing beneath the superior intercostal vein, the vena azygos minor and sympathetic. In the intercostal spaces, or rather, upon the external intercostal muscles, each artery gives off a *dorsal branch*, which passes back between the transverse processes of the vertebræ, lying internally to the middle costo-transverse ligament, and divides into a spinal branch, which supplies the spinal cord and vertebræ, and a muscular branch which is distributed to the muscles and integument of the back. The artery then comes into relation with its vein and nerve, the former being above and the latter below, and divides into two branches which run along the borders of contiguous ribs between the two planes of intercostal muscles, and anastomose with the anterior intercostal arteries, branches of the internal mammary. The branch corresponding with the lower border of each rib is the larger of the two. They are protected from pressure during the action of the intercostal muscles, by little tendinous arches thrown across them and attached by each extremity to the bone.

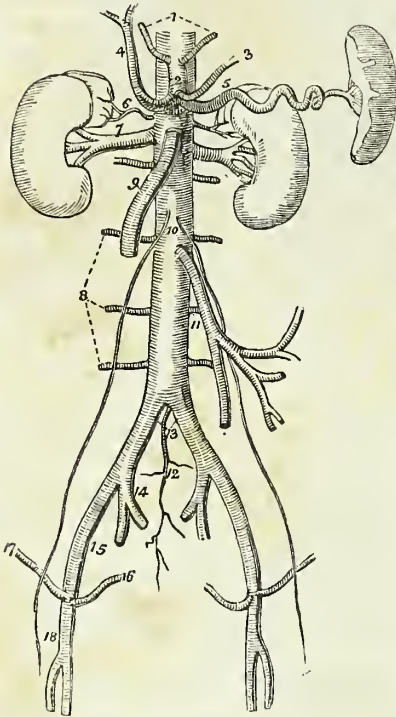
## BRANCHES OF THE ABDOMINAL AORTA.

Phrenic,  
 Coeliac axis { Gastric,  
                   { Hepatic,  
                   { Splenic.  
 Superior mesenteric,  
 Spermatic,  
 Inferior mesenteric,  
 Supra-renal,  
 Renal,  
 Lumbar,  
 Sacra media.

The PHRENIC ARTERIES are given off from the anterior part of the aorta as soon as that trunk has passed through the aortic opening. Passing obliquely outwards upon the under surface of the diaphragm, each artery divides into two branches, an *internal branch*, which runs forwards, and inosculates with its fellow of the opposite side in front of the œsophageal opening; and an *external branch*, which proceeds outwards towards the great circumference of the muscle, and sends branches to the supra-renal capsules. The phrenic arteries inosculate with branches of the internal mammary, inferior intercostal, epigastric, œsophageal, gastric, hepatic, and supra-renal arteries. They are not unfrequently derived from the cœliac axis, or from one of its divisions, and sometimes they give off the supra-renal arteries.

The CÆLIAC AXIS (*κοιλία*, *ventriculus*) is the first single trunk given off from the abdominal aorta. It arises opposite the upper border of the first lumbar vertebra, is about half an inch in length, and divides into three large branches, gastric, hepatic, and splenic.

Fig. 152.\*



*Relations.*—The trunk of the celiac axis has in relation with it, *in front*, the lesser omentum; on the *right side* the right semilunar ganglion and lobus Spigelii of the liver; on the *left side* the left semilunar ganglion and cardiac portion of the stomach; and *below*, the upper border of the pancreas and lesser curve of the stomach. It is completely surrounded by the solar plexus.

The GASTRIC ARTERY (*coronaria ventriculi*), the smallest of the three branches of the celiac axis, ascends between the two layers of the lesser omentum to the cardiac orifice of the stomach, then runs along the lesser curvature to the pylorus, and inosculates with the pyloric branch of the hepatic. It is distributed to the lower extremity of the œsophagus and lesser curve of the stomach, and anastomoses with

the œsophageal arteries and vasa brevia of the splenic artery.

The HEPATIC ARTERY curves forwards, and ascends along the right border of the lesser omentum to the liver, where it divides into two branches (right and left), which enter the transverse fissure, and are distributed along the portal canals to the right and left lobes.† It is in relation, in the right border of the lesser omentum, with the ductus communis choledochus and portal vein, and is surrounded by the hepatic plexus of nerves and numerous lymphatics. There are sometimes two hepatic arteries, in which case one is derived from the superior mesenteric artery.

\* The abdominal aorta with its branches. 1. The phrenic arteries. 2. The celiac axis. 3. The gastric artery. 4. The hepatic artery, dividing into the right and left hepatic branches. 5. The splenic artery, passing outwards to the spleen. 6. The supra-renal artery of the right side. 7. The right renal artery, which is longer than the left, passing outwards to the right kidney. 8. The lumbar arteries. 9. The superior mesenteric artery. 10. The two spermatic arteries. 11. The inferior mesenteric artery. 12. The sacra media. 13. The common iliacs. 14. The internal iliac of the right side. 15. The external iliac artery. 16. The epigastric artery. 17. The circumflexa ilii artery. 18. The femoral artery.

† For the mode of distribution of the hepatic artery within the liver, see the "Minute Anatomy" of that organ in the Chapter on the Viscera.



The *Branches* of the hepatic artery are, the

|                    |   |                                                    |
|--------------------|---|----------------------------------------------------|
| Pyloric,           | } | Gastro-epiploica dextra,<br>Pancreatico-duodenalis |
| Gastro-duodenalis, |   |                                                    |
| Cystic.            |   |                                                    |

The *Pyloric branch*, given off from the hepatic near the pylorus, is distributed to the commencement of the duodenum and to the lesser curve of the stomach, where it inosculates with the gastric artery.

The *Gastro-duodenalis artery* is a short but large trunk, which descends behind the pylorus, and divides into two branches, the gastro-epiploica dextra, and pancreatico-duodenalis. Previously to its division, it gives off some *inferior pyloric* branches to the small end of the stomach.

The *Gastro-epiploica dextra* runs along the great curve of the stomach lying between the two layers of the great omentum, and inosculates at about its middle with the gastro-epiploica sinistra, a branch of the splenic artery. It supplies the great curve of the stomach and the great omentum; hence the derivation of its name.

The *Pancreatico-duodenalis* curves along the fixed border of the duodenum, partly concealed by the attachment of the pancreas, and is distributed to the pancreas and duodenum. It inosculates inferiorly with the first jejunal, and with the pancreatic branches of the superior mesenteric artery.

The *Cystic artery*, generally a branch of the right hepatic, is of small size, and ramifies between the coats of the gall-bladder, previously to its distribution to the mucous membrane.

The **SPLENIC ARTERY**, the largest of the three branches of the cœliac axis, passes horizontally to the left along the upper border of the pancreas, and divides into five or six large branches, which enter the hilus of the spleen, and are distributed to its structure. In its course it is tortuous and serpentine, and frequently makes a complete turn upon itself. It lies in a narrow groove in the upper border of the pancreas, and is accompanied by the splenic vein, and by the splenic plexus of nerves.

The *Branches* of the splenic artery are the—

Pancreaticæ parvæ,  
Pancreatica magna,  
Vasa brevia,  
Gastro-epiploica sinistra.

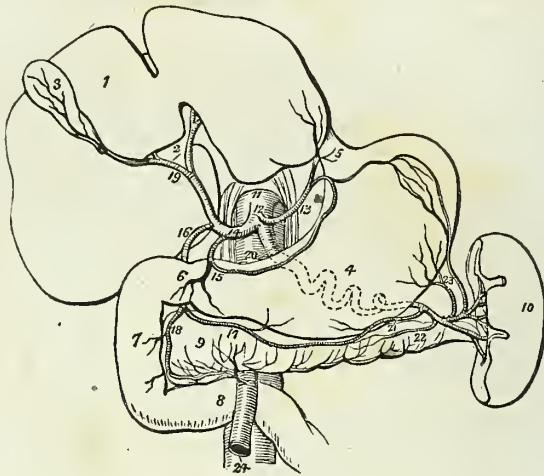The *Pancreaticæ parvæ* are numerous small branches distributed to the pancreas, as the splenic border runs along its upper border. One of these, larger than the rest, follows the course of the pancreatic duct, and is called *pancreatica magna*.

The *Vasa brevia* are five or six branches of small size which pass from the extremity of the splenic artery and its terminal branches, between the layers of the gastro-splenic omentum, to the great end of the stomach, to which they are distributed, inosculating with branches of the gastric artery and gastro-epiploica sinistra.

The *Gastro-epiploica sinistra* appears to be the continuation of the splenic artery; it passes forwards from left to right, along the great curve of the stomach, lying between the layers of the great omentum, and inos-

culates with the gastro-epiploica dextra. It is distributed to the great curve of the stomach and to the great omentum.

Fig. 153.\*



The SUPERIOR MESENTERIC ARTERY, the second of the single trunks, and next in size to the cœliac axis, arises from the aorta immediately below that vessel, and behind the pancreas. It passes forwards between the pancreas and transverse duodenum, and descends within the layers of the mesentery, to the right iliac fossa, where it terminates, very much diminished in size. It forms a curve in its course, the convexity being directed towards the left, and the concavity to the right. It is in relation near its commencement with the portal vein; and is accompanied by two veins, and the superior mesenteric plexus of nerves.

The *branches* of the superior mesenteric artery are—

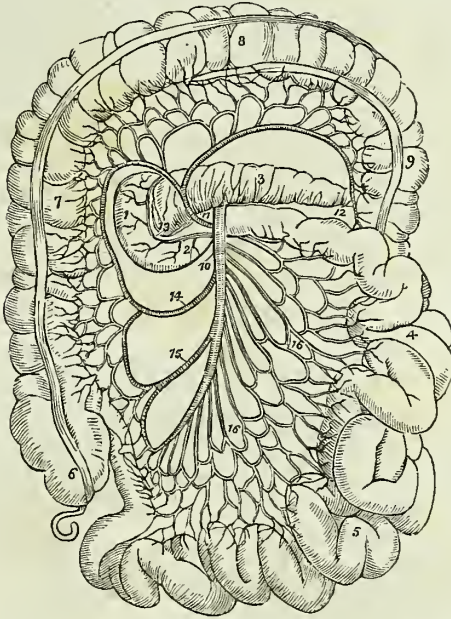
Vasa intestini tenuis,  
Ileo-colica,  
Colica dextra,  
Colica media.

The *Vasa intestini tenuis* arise from the convexity of the superior mesenteric artery. They vary from fifteen to twenty in number, and are dis-

\* The distribution of the branches of the cœliac axis. 1. The liver. 2. Its transverse fissure. 3. The gall-bladder. 4. The stomach. 5. The entrance of the œsophagus. 6. The pylorus. 7. The duodenum, its descending portion. 8. The transverse portion of the duodenum. 9. The pancreas. 10. The spleen. 11. The aorta. 12. The cœliac axis. 13. The gastric artery. 14. The hepatic artery. 15. Its pyloric branch. 16. The gastro-duodenal. 17. The gastro-epiploica dextra. 18. The pancreatico-duodenal, inosculating with a branch from the superior mesenteric artery. 19. The division of the hepatic artery into its right and left branches; the right giving off the cystic branch. 20. The splenic artery, traced by dotted lines behind the stomach to the spleen. 21. The gastro-epiploica sinistra, inosculating along the great curvature of the stomach with the gastro-epiploica dextra. 22. The pancreatica magna. 23. The vasa brevia to the great end of the stomach, inosculating with branches of the gastric artery. 24. The superior mesenteric artery, emerging from between the pancreas and transverse portion of the duodenum.

tributed to the small intestine from the duodenum to the termination of the ileum. In their course between the layers of the mesentery, they form a series of arches by the inosculation of their larger branches; from these

Fig. 154.\*



are developed secondary arches, and from the latter a third series of arches, from which the branches arise which are distributed to the coats of the intestine. From the middle branches a fourth and sometimes even a fifth series of arches is produced. By means of these arches a direct communication is established between all the branches given off from the convexity of the superior mesenteric artery; the superior branches moreover supply the pancreas and duodenum, and inosculate with the pancreatico-duodenalis; and the inferior with the ileo-colica.

The *Ileo-colic artery* is the last branch given off from the concavity of the superior mesenteric. It descends to the right iliac fossa, and divides into branches which communicate and form arches, from which branches are distributed to the termination of the ileum, the cæcum, and the commencement of the colon. This artery inosculates on the one hand with the last branches of the vasa intestini tenuis, and on the other with the last colica dextra.

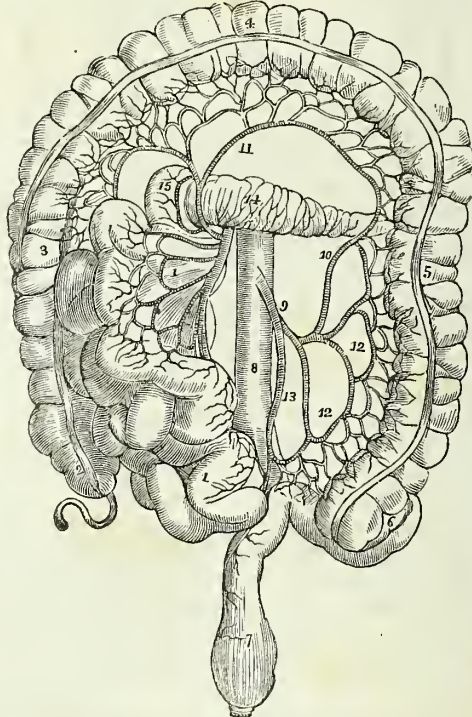
\* The course and distribution of the superior mesenteric artery. 1. The descending portion of the duodenum. 2. The transverse portion. 3. The pancreas. 4. The jejunum. 5. The ileum. 6. The cæcum, from which the appendix vermiformis is seen projecting. 7. The ascending colon. 8. The transverse colon. 9. The commencement of the descending colon. 10. The superior mesenteric artery. 11. The colica media. 12. The branch which inosculates with the colica sinistra. 13. The branch of the superior mesenteric artery, which inosculates with the pancreatico-duodenalis. 14. The colica dextra. 15. The ileo-colica. 16, 16. The branches from the convexity of the superior mesenteric to the small intestines.

The *Colica dextra* arises from about the middle of the concavity of the superior mesenteric, and divides into branches which form arches, and are distributed to the ascending colon. Its descending branches inosculate with the ileo-colica, and the ascending with the colica media.

The *Colica media* arises from the upper part of the concavity of the superior mesenteric, and passes forwards between the layers of the transverse mesocolon, where it forms arches, and is distributed to the transverse colon. It inosculates on the right with the colica dextra; and on the left with the colica sinistra, a branch of the inferior mesenteric artery.

The SPERMATIC ARTERIES are two small vessels which arise from the front of the aorta below the superior mesenteric; from this origin each artery passes obliquely outwards, and accompanies the corresponding ureter along the front of the psoas muscle to the border of the pelvis, where it is in relation with the external iliac artery. It is then directed outwards to the internal abdominal ring, and follows the course of the

Fig. 155.\*



\* The distribution and branches of the inferior mesenteric artery. 1, 1. The superior mesenteric artery, with its branches and the small intestines turned over to the right side. 2. The cæcum and appendix cæci. 3. The ascending colon. 4. The transverse colon raised upwards. 5. The descending colon. 6. Its sigmoid flexure. 7. The rectum. 8. The aorta. 9. The inferior mesenteric artery. 10. The colica sinistra, inosculating with, 11, the colica media, a branch of the superior mesenteric artery. 12, 12 Sigmoid branches. 13. The superior hæmorrhoidal artery. 14. The pancreas. 15. The descending portion of the duodenum.

spermatic cord along the spermatic canal and through the scrotum to the testicle, to which it is distributed. The right spermatic artery lies in front of the vena cava, and both vessels are accompanied by their corresponding veins and by the spermatic plexuses of nerves.

The spermatic arteries in the female descend into the pelvis and pass between the two layers of the broad ligaments of the uterus, to be distributed to the ovaries, Fallopian tubes, and round ligaments; along the latter they are continued to the inguinal canal and labium at each side.

They inosculate with the uterine arteries.

The INFERIOR MESENTERIC ARTERY, smaller than the superior, arises from the abdominal aorta, about two inches below the origin of that vessel, and descends between the layers of the left mesocolon, to the left iliac fossa, where it divides into three *branches* :

Colica sinistra,  
Sigmoideæ,  
Superior hæmorrhoidal.

The *Colica sinistra* is distributed to the descending colon, and ascends to inosculate with the colica media. This is the largest arterial inosculatión in the body.

The *Sigmoideæ* are several large branches which are distributed to the sigmoid flexure of the descending colon. They form arches, and inosculate above with the colica sinistra, and below with the superior hæmorrhoidal artery.

The *Superior hæmorrhoidal* artery is the continuation of the inferior mesenteric. It crosses the ureter and common iliac artery of the left side, and descends between the two layers of the meso-rectum as far as the middle of the rectum to which it is distributed, anastomosing with the middle and external hæmorrhoidal arteries.

The SUPRA-RENAL are two small vessels which arise from the aorta immediately above the renal arteries, and are distributed to the supra-renal capsules. They are sometimes branches of the phrenic or of the renal arteries.

The RENAL ARTERIES (emulgent) are two large trunks given off from the sides of the aorta immediately below the superior mesenteric artery; the right is longer than the left on account of the position of the aorta, and passes behind the vena cava to the kidney of that side. The left is somewhat higher than the right. They divide into several large branches previously to entering the kidney, and ramify very minutely in its vascular portion. The renal arteries supply several small branches to the supra-renal capsules.

The LUMBAR ARTERIES correspond with the intercostals in the chest; they are four or five in number on each side, and curve around the bodies of the lumbar vertebræ beneath the psoas muscles, and divide into two branches; one of which passes backwards between the transverse processes, and is distributed to the vertebræ and spinal cord and to the muscles of the back, whilst the other takes its course behind the quadratus lumborum muscle and supplies the abdominal muscles. The first lumbar

artery runs along the lower border of the last rib, and the last along the crest of the ilium. In passing between the psoas muscles and the vertebræ, they are protected by a series of tendinous arches, which defend them and the communicating branches of the sympathetic nerve from pressure during the action of the muscle.

The *SACRA MEDIA* arises from the posterior part of the aorta at its bifurcation, and descends along the middle of the anterior surface of the sacrum to the first piece of the coccyx, where it terminates by inosculating with the lateral sacral arteries. It distributes branches to the rectum and anterior sacral nerves, and inosculates on either side with the lateral sacral arteries.

*Varieties in the Branches of the Abdominal Aorta.*—The phrenic arteries are very rarely both derived from the aorta. One or both may be branches of the celiac axis; one may proceed from the gastric artery, from the renal, or from the upper lumbar artery. There are occasionally three or more phrenic arteries. The celiac artery is very variable in length, and gives off its branches irregularly. There are sometimes two or even three hepatic arteries, one of which may be derived from the gastric or even from the superior mesenteric. The colica media is sometimes derived from the hepatic artery. The spermatic arteries are very variable, both in origin and number. The right spermatic may be a branch of the renal artery, and the left a branch of the inferior mesenteric. The supra-renal arteries may be derived from the phrenic or renal arteries. The renal arteries present several varieties in number; there may be three or even four arteries on one side, and one only on the other. When there are several renal arteries on one side, one may arise from the common iliac artery, from the front of the aorta near its lower part, or from the internal iliac.

#### COMMON ILIAC ARTERIES.

The abdominal aorta divides opposite the fourth lumbar vertebra into the two common iliac arteries. Sometimes the bifurcation takes place as high as the third, and occasionally as low as the fifth lumbar vertebra. The common iliac arteries are about two inches and a half in length; they diverge from the termination of the aorta, and pass downwards and outwards on each side to the margin of the pelvis, opposite the sacro-iliac symphysis, where they divide into the internal and external iliac arteries. In old persons the common iliac arteries are more or less dilated and curved in their course.

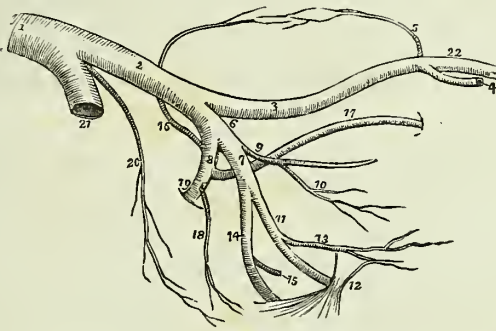
The *Right common iliac* is somewhat longer than the left, and forms a more obtuse angle with the termination of the aorta; the angle of bifurcation is greater in the female than in the male.

*Relations.*—The relations of the two arteries are different on the two sides of the body. The *right* common iliac is in relation in front with the peritoneum, and is crossed at its bifurcation by the ureter. It is in relation posteriorly with the two common iliac veins, and externally with the psoas magnus. The *left* is in relation in front with the peritoneum, and is crossed by the rectum and superior hæmorrhoidal artery, and, at its bifurcation, by the ureter. It is in relation behind with the left common iliac vein, and externally with the psoas magnus.

## INTERNAL ILIAC ARTERY.

The *Internal Iliac artery* is a short trunk, varying in length from an inch to two inches. It descends obliquely to a point opposite the upper margin of the great sacro-ischiatic foramen, where it divides into an anterior and a posterior trunk.

Fig. 156.\*



*Relations.*—This artery rests externally on the sacral plexus and on the origin of the pyriformis muscle; posteriorly it is in relation with the internal iliac vein, and anteriorly with the ureter.

*Branches.*—The branches of the anterior trunk are the—

|                      |                 |
|----------------------|-----------------|
| Umbilical,           | Ischiatic,      |
| Middle vesical,      | Internal pudic. |
| Middle hæmorrhoidal, |                 |

And in the female the—

|          |          |
|----------|----------|
| Uterine, | Vaginal. |
|----------|----------|

And of the posterior trunk, the—

|              |                 |
|--------------|-----------------|
| Ilio-lumbar, | Lateral sacral, |
| Obturator,   | Gluteal.        |

The *umbilical artery* is the commencement of the fibrous cord into which the umbilical artery of the fœtus is converted after birth. In after life, the cord remains pervious for a short distance, and constitutes the umbilical artery of the adult, from which the *superior vesical artery* is given off to the fundus and anterior aspect of the bladder. The cord may

\* The distribution and branches of the iliac arteries. 1. The aorta. 2. The left common iliac artery. 3. The external iliac. 4. The epigastric artery. 5. The circumflexa ilii. 6. The internal iliac artery. 7. Its anterior trunk. 8. Its posterior trunk. 9. The umbilical artery giving off (10) the superior vesical artery. After the origin of this branch, the umbilical artery becomes converted into a fibrous cord—the umbilical ligament. 11. The internal pudic artery passing behind the spine of the ischium (12) and lesser sacro-ischiatic ligament. 13. The middle hæmorrhoidal artery. 14. The ischiatic artery, also passing behind the anterior sacro-ischiatic ligament to escape from the pelvis. 15. Its inferior vesical branch. 16. The ilio-lumbar, the first branch of the posterior trunk (8) ascending to anastomose with the circumflexa ilii artery (5) and form an arch along the crest of the ilium. 17. The obturator artery. 18. The lateral sacral. 19. The gluteal artery escaping from the pelvis through the upper part of the great sacro-ischiatic foramen. 20. The sacra media. 21. The right common iliac artery cut short. 22. The femoral artery.

be traced forwards by the side of the fundus of the bladder to near its apex, whence it ascends by the side of the linea alba and urachus to the umbilicus.

The *Middle vesical artery* is generally a branch of the umbilical, and sometimes of the internal iliac. It is somewhat larger than the superior vesical, and is distributed to the posterior part of the body of the bladder, the vesiculæ seminales, and prostate gland.

The *Middle hæmorrhoidal artery* is as frequently derived from the ischiatic or internal pudic as from the internal iliac. It is of variable size, and is distributed to the rectum, base of the bladder, vesiculæ seminales, and prostate gland, and inosculates with the superior and external hæmorrhoidal arteries.

The ISCHIATIC ARTERY is the larger of the two terminal branches of the anterior division of the internal iliac. It passes downwards between the posterior border of the levator ani and the pyriformis, resting on the sacral plexus of nerves, and lying behind the internal pudic artery, to the lower border of the great ischiatic notch, where it escapes from the pelvis below the pyriformis muscle. It then descends in the space between the trochanter major and the tuberosity of the ischium in company with the ischiatic nerves, and divides into branches.

Its branches within the pelvis are *hæmorrhoidal*, which supply the rectum conjointly with the middle hæmorrhoidal, and sometimes take the place of that artery, and the *inferior vesical*, which is distributed to the base and neck of the bladder, the vesiculæ seminales, and prostate gland. The branches externally to the pelvis, are four in number, namely, coccygeal, inferior gluteal, comes nervi ischiatici, and muscular branches.

The *Coccygeal* branch pierces the great sacro-ischiatic ligament, and is distributed to the coccygeus and levator ani muscles, and to the integument around the anus and coccyx.

The *Inferior gluteal* branches supply the gluteus maximus muscle.

The *Comes nervi ischiatici* is a small but regular branch, which accompanies the great ischiatic nerve to the lower part of the thigh.

The *Muscular* branches supply the muscles of the posterior part of the hip and thigh, and inosculate with the internal and external circumflex arteries, with the obturator, and with the superior perforating artery.

The INTERNAL PUDIC ARTERY, the other terminal branch of the anterior trunk of the internal iliac, descends in front of the ischiatic artery to the lower border of the great ischiatic foramen. It emerges from the pelvis through the great sacro-ischiatic foramen below the pyriformis muscle, crosses the spine of the ischium, and re-enters the pelvis through the lesser sacro-ischiatic foramen; it then crosses the internal obturator muscle to the ramus of the ischium, being situated at about an inch from the margin of the tuberosity, and bound down by the obturator fascia; it next ascends the ramus of the ischium, enters between the two layers of the deep perineal fascia lying along the border of the ramus of the os pubis, and at the symphysis pierces the anterior layer of the deep perineal fascia, and, very much diminished in size, reaches the dorsum of the penis along which it runs, supplying that organ under the name of dorsalis penis.

*Branches.*—The branches of the internal pudic artery within the pelvis are several small ramuscles to the base of the bladder, the vesiculæ semi-



nales, and the prostate gland; and *hæmorrhoidal* branches which supply the middle of the rectum, and frequently take the place of the middle hæmorrhoidal branch of the internal iliac.

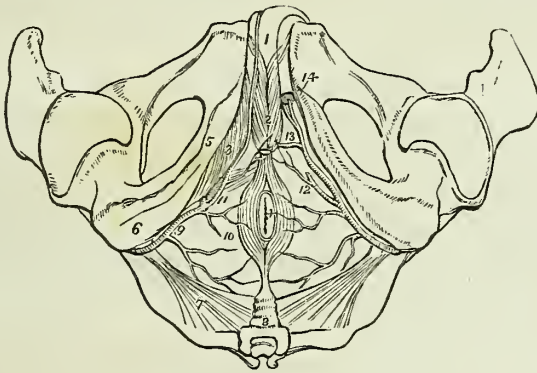
The *branches* given off externally to the pelvis, are the

External hæmorrhoidal,  
Superficialis perinei,  
Transversalis perinei,  
Arteria bulbosi,  
Arteria corporis cavernosi,  
Arteria dorsalis penis.

The *External hæmorrhoidal arteries* are three or four small branches, given off by the internal pudic while behind the tuberosity of the ischium. They are distributed to the anus, and to the muscles, the fascia, and the integument of the anal region of the perineum.

The *Superficial perineal artery* is given off near the attachment of the crus penis; it pierces the connecting layer of the superficial and deep perineal fascia, and runs forward across the transversus perinei muscle, and along the groove between the accelerator urinæ and erector penis to the septum scroti, upon which it ramifies under the name of *arteria septi*. It distributes branches to the scrotum, and to the perineum in its course forwards. One of the latter, larger than the rest, crosses the perineum,

Fig. 157.\*



\* The arteries of the perineum; on the right side the superficial arteries are seen, and on the left the deep. 1. The penis, consisting of corpus spongiosum and corpus cavernosum. The crus penis on the left side is cut through. 2. The acceleratores urinæ muscles, enclosing the bulbous portion of the corpus spongiosum. 3. The erector penis, spread out upon the crus penis of the right side. 4. The anus, surrounded by the sphincter ani muscle. 5. The ramus of the ischium and os pubis. 6. The tuberosity of the ischium. 7. The lesser sacro-ischiatic ligament, attached by its small extremity to the spine of the ischium. 8. The coccyx. 9. The internal pudic artery, crossing the spine of the ischium, and entering the perineum. 10. External hæmorrhoidal branches. 11. The superficialis perinei artery, giving off a small branch, transversalis perinei, upon the transversus perinei muscle. 12. The same artery on the left side cut off. 13. The artery of the bulb. 14. The two terminal branches of the internal pudic artery; one is seen entering the divided extremity of the crus penis, the artery of the corpus cavernosum; the other, the dorsalis penis, ascends upon the dorsum of the organ.

resting on the transversus perinei muscle, and is named the *transversalis perinei*.

The *Artery of the bulb* is given off from the pudic nearly opposite the opening for the transmission of the urethra; it passes almost transversely inwards between the two layers of the deep perineal fascia, and pierces the anterior layer to enter the corpus spongiosum at its bulbous extremity. It is distributed to the corpus spongiosum.

The *Artery of the corpus cavernosum* pierces the crus penis, and runs forward in the interior of the corpus cavernosum, by the side of the septum pectiniforme. It ramifies in the parenchyma of the venous structure of the corpus cavernosum.

The *Dorsal artery of the penis* ascends between the two crura and symphysis pubis to the dorsum penis, and runs forward, through the suspensory ligament, in the groove of the corpus cavernosum to the glans, distributing branches in its course to the body of the organ and to the integument.

The INTERNAL PUDIC artery in the female is smaller than in the male; its branches, with their distribution are, in principle, the same. The superficial perineal artery supplies the analogue of the lateral half of the scrotum, viz. the greater labium. The artery of the bulb supplies the meatus urinarius, and the vestibule; the artery of the corpus cavernosum, the cavernous body of the clitoris, and the arteria dorsalis clitoridis, the dorsum of that organ.

The UTERINE and VAGINAL arteries of the female are derived either from the internal iliac, or from the umbilical, internal pudic, or ischiatic arteries. The former are very tortuous in their course, and ascend between the layers of the broad ligament, to be distributed to the uterus. The latter ramify upon the exterior of the vagina, and supply its mucous membrane.

#### *Branches of the Posterior Trunk.*

The ILIO-LUMBAR ARTERY ascends beneath the external iliac vessels and psoas muscle, to the posterior part of the crest of the ilium; where it divides into two branches, a *lumbar branch* which supplies the psoas and iliacus muscles, and sends a ramuscle through the fifth intervertebral foramen to the spinal cord and its membranes; and an *iliac branch* which passes along the crest of the ilium, distributing branches to the iliacus and abdominal muscles, and inosculating with the lumbar and gluteal arteries, and with the circumflexa ilii.

The OBTURATOR ARTERY is exceedingly variable in point of origin; it generally proceeds from the posterior trunk of the internal iliac artery, and passes forwards a little below the brim of the pelvis to the upper border of the obturator foramen. It there escapes from the pelvis through a tendinous arch formed by the obturator membrane, and divides into two branches; an *internal branch* which curves inwards around the bony margin of the obturator foramen, between the obturator externus muscle and the ramus of the ischium, and distributes branches to the obturator muscles, the pectineus, the adductor muscles, and to the organs of generation, and inosculates with the internal circumflex artery; and an *external branch* which pursues its course along the outer margin of the obturator foramen to the space between the gemellus inferior and quadratus femoris, where it inosculates with the ischiatic artery. In its course backwards it

anastomoses with the internal circumflex, and sends a branch through the notch in the acetabulum to the hip joint. Within the pelvis the obturator artery gives off a branch to the iliacus muscle, and a small ramuscule which inosculates with the epigastric artery.

The LATERAL SACRAL ARTERIES are generally two in number on each side; superior and inferior. The *superior* passes inwards to the first sacral foramen, and is distributed to the contents of the spinal canal, from which it escapes by the posterior sacral foramen, and supplies the integument on the dorsum of the sacrum. The *inferior* passes down by the side of the anterior sacral foramina to the coccyx; it first pierces and then rests upon the origin of the pyriformis, and sends branches into the sacral canal to supply the sacral nerves. Both arteries inosculate with each other and with the sacra media.

The GLUTEAL ARTERY is the continuation of the posterior trunk of the internal iliac: it passes backwards between the lumbo-sacral and first lumbar nerve through the upper part of the great sacro-ischiatic foramen and above the pyriformis muscle, and divides into three branches, superficial, deep superior, and deep inferior.

The *Superficial branch* is directed forwards, between the gluteus maximus and medius, and divides into numerous branches, which are distributed to the upper part of the gluteus maximus and to the integument of the gluteal region.

The *Deep superior branch* passes along the superior curved line of the ilium; between the gluteus medius and minimus to the anterior superior spinous process, where it inosculates with the superficial circumflexa ilii and external circumflex artery. There are frequently two arteries which follow this course.

The *Deep inferior branches* are several large arteries which cross the gluteus minimus obliquely to the trochanter major, where they inosculate with the branches of the external circumflex artery, and send branches through the gluteus minimus to supply the capsule of the hip joint.

*Varieties in the Branches of the internal iliac.*—The most important of the varieties occurring among these branches is the origin of the dorsal artery of the penis from the internal iliac or ischiatic. The artery in this case passes forwards by the side of the prostate gland, and through the upper part of the deep perineal fascia. It would be endangered in the operation of lithotomy. The dorsal artery of the penis is sometimes derived from the obturator, and sometimes from one of the external pudic arteries. The artery of the bulb, in its normal course, passes almost transversely inwards to the corpus spongiosum. Occasionally, however, it is so oblique in its direction as to render its division in lithotomy unavoidable. The obturator artery may be very small or altogether wanting, its place being supplied by a branch from the external iliac or epigastric.

#### EXTERNAL ILIAC ARTERY.

The external iliac artery of each side passes obliquely downwards along the inner border of the psoas muscle, from opposite the sacro-iliac symphysis to the femoral arch, where it becomes the femoral artery.

*Relations.*—It is in relation *in front* with the spermatic vessels, the

peritoneum, and a thin layer of fascia, derived from the iliac fascia, which surrounds the artery and vein. At its commencement it is crossed by the ureter, and near its termination by the crural branch of the genito-crural nerve and the circumflexa ilii vein. *Externally* it lies against the psoas muscle, from which it is separated by the iliac fascia; and *posteriorly* it is in relation with the external iliac vein, which, at the femoral arch, becomes placed to its inner side. The artery is surrounded throughout the whole of its course by lymphatic vessels and glands.

*Branches.*—Besides several small branches which supply the glands surrounding the artery, the external iliac gives off two branches, the—

Epigastric,  
Circumflexa ilii.

The *Epigastric artery* arises from the external iliac near Poupart's ligament; and passing forwards between the peritoneum and transversalis fascia, ascends obliquely to the sheath of the rectus. It enters the sheath near its lower third, and passes upwards behind the rectus muscle, to which it is distributed, and in the substance of that muscle inosculates, near the ensiform cartilage, with the termination of the internal mammary artery. It lies internally to the internal abdominal ring and immediately above the femoral ring, and is crossed near its origin by the vas deferens in the male, and by the round ligament in the female.

The only branches of the epigastric artery worthy of distinct notice are the *Cremasteric*, which accompanies the spermatic cord and supplies the cremaster muscle; and the ramusculus which inosculates with the obturator artery.

The epigastric artery forms a prominence of the peritoneum which divides the iliac fossa into an internal and an external portion; it is from the former that direct inguinal hernia issues, and from the latter, oblique inguinal hernia.

The *Circumflexa ilii* arises from the outer side of the external iliac, nearly opposite the epigastric artery. It ascends obliquely along Poupart's ligament, and curving around the crest of the ilium between the attachments of the internal oblique and transversalis muscle, inosculates with the ilio-lumbar and inferior lumbar artery. Opposite the anterior superior spinous process of the ilium, it gives off a large *ascending branch* which passes upwards between the internal oblique and transversalis, and divides into numerous branches which supply the abdominal muscles, and inosculate with the inferior intercostal and with the lumbar arteries.

*Varieties in the branches of the external iliac.*—The epigastric artery not unfrequently\* gives off the obturator, which descends in contact with the external iliac vein, to the obturator foramen. In this situation the artery would lie to the outer side of the femoral ring, and would not be endangered in the operation for dividing the stricture of femoral hernia. But occasionally the obturator passes along the free margin of Gimbernat's ligament in its course to the obturator foramen, and would completely encircle the neck of the hernial sac,—a position in which it could scarcely

\* The proportion in which high division of the obturator artery from the epigastric occurs, is stated to be one in three. In two hundred and fifty subjects examined by Cloquet with a view to ascertain how frequently the high division took place, he found the obturator arising from the epigastric on both sides one hundred and fifty times; on one side twenty-eight times, and six times it arose from the femoral artery.

escape the knife of the operator. In a preparation in my anatomical collection, the branch of communication between the epigastric and obturator arteries is very much enlarged, and takes this dangerous course.

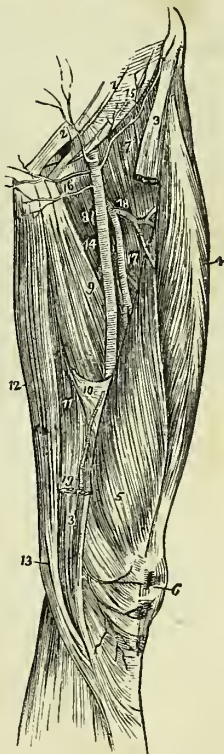
## FEMORAL ARTERY.

Emerging from beneath Poupart's ligament, the external iliac artery enters the thigh and becomes the femoral. The femoral artery passes down the inner side of the thigh, from Poupart's ligament, at a point midway between the anterior superior spinous process of the ilium and the symphysis pubis, to the opening in the adductor magnus, at the junction of the middle with the inferior third of the thigh, where it becomes the popliteal artery.

The femoral artery and vein are enclosed in a strong sheath, *femoral* or *crural canal*, which is formed for the greater part of its extent by aponeurotic and areolar tissue, and by a process of fascia sent inwards from the fascia lata. Near Poupart's ligament this sheath is much larger than the vessels it contains, and is continuous with the fascia transversalis and iliac fascia. If the sheath be opened at this point, the artery will be seen to be situated in contact with the outer wall of the sheath. The vein lies next the artery, being separated from it by a fibrous septum, and between the vein and the inner wall of the sheath, and divided from the vein by another thin fibrous septum, is a triangular interval, into which the sac is protruded in femoral hernia. This space is occupied in the normal state of the parts by loose areolar tissue, and by lymphatic vessels which pierce the inner wall of the sheath to make their way to a gland, situated in the femoral ring.

*Relations.* — The upper third of the femoral artery is superficial, being covered only by the integument, inguinal glands,

Fig. 158.\*



\* A view of the anterior and inner aspect of the thigh, showing the course and branches of the femoral artery. 1. The lower part of the aponeurosis of the external oblique muscle; its inferior margin is Poupart's ligament. 2. The external abdominal ring. 3, 3. The upper and lower part of the sartorius muscle; its middle portion having been removed. 4. The rectus. 5. The vastus internus. 6. The patella. 7. The iliacus and psoas; the latter being nearest the artery. 8. The pectineus. 9. The adductor longus. 10. The tendinous canal for the femoral artery formed by the adductor magnus, and vastus internus muscle. 11. The adductor magnus. 12. The gracilis. 13. The tendon of the semi-tendinosus. 14. The femoral artery. 15. The superficial circumflexa ilii artery taking its course along the line of Poupart's ligament, to the crest of the ilium. 16. The two external pudic arteries, superficial and deep. 17. The profunda artery, giving off 18, its external circumflex branch; and lower down the three perforantes. A small bend of the internal circumflex artery (8) is seen behind the inner margin of the femoral, just below the deep external pudic artery. 19. The anastomotic magna, descending to the knee, upon which it ramifies (6).

and by the superficial and deep fasciæ. The lower two-thirds are covered by the sartorius muscle. To its *outer side* the artery is first in relation with the psoas and iliacus, and then with the vastus internus. *Behind* it rests upon the inner border of the psoas muscle; it is next separated from the pectineus by the femoral vein, profunda vein and artery, and then lies on the adductor longus to its termination: near the lower border of the adductor longus, it is placed in an aponeurotic canal, formed by an arch of tendinous fibres, thrown from the border of the adductor longus and the border of the opening in the adductor magnus, to the side of the vastus internus. To its *inner side* it is in relation at its upper part with the femoral vein, and lower down with the pectineus, adductor longus, and sartorius.

The immediate relations of the artery are the femoral vein, and two saphenous nerves. The vein at Poupart's ligament lies to the inner side of the artery; but lower down gets altogether behind it, and inclines to its outer side. The short saphenous nerve lies to the outer side, and somewhat upon the sheath for the lower two-thirds of its extent; and the long saphenous nerve is situated within the sheath, and in front of the artery for the same extent.

*Plan of the Relations of the Femoral Artery.*

*Front.*

Fascia lata,  
Saphenous nerves,  
Sartorius,  
Arch of the tendinous canal.

*Inner Side.*

Femoral vein,  
Pectineus,  
Adductor longus,  
Sartorius.

Femoral artery.

*Outer Side.*

Psoas,  
Iliacus,  
Vastus internus.

*Behind.*

Psoas muscle,  
Femoral vein,  
Adductor longus.

*Branches.*—The branches of the Femoral Artery are the—

Superficial circumflexa ilii,  
Superficial epigastric,  
Superficial external pudic,  
Deep external pudic,  
Profunda { External circumflex,  
          { Internal circumflex,  
          { Three perforating,  
Muscular,  
Anastomotica magna.

The *Superficial circumflexa ilii* artery arises from the femoral, immediately below Poupart's ligament, pierces the fascia lata, and passes ob-

liquely outwards towards the crest of the ilium. It supplies the integument of the groin, the superficial fascia, and inguinal glands.

The *Superficial epigastric* arises from the femoral, immediately below Poupart's ligament, pierces the fascia lata, and ascends obliquely towards the umbilicus between the two layers of superficial fascia. It distributes branches to the inguinal glands and integument, and inosculates with branches of the deep epigastric and internal mammary artery.

The *Superficial external pudic* arises near the superficial epigastric artery; it pierces the fascia lata, at the saphenous opening, and passes transversely inwards, crossing the spermatic cord, to be distributed to the integument of the penis and scrotum in the male, and to the labia in the female.

The *Deep external pudic* arises from the femoral, a little lower down than the preceding: it crosses the femoral vein immediately below the termination of the internal saphenous vein, and piercing the pubic portion of the fascia lata, passes beneath that fascia to the inner border of the thigh, where it again pierces the fascia; having become superficial, it is distributed to the integument of the scrotum and perineum.

The PROFUNDA FEMORIS arises from the femoral artery at two inches below Poupart's ligament: it passes downwards and backwards and a little outwards, behind the adductor longus muscle, pierces the adductor magnus, and is distributed to the flexor muscles on the posterior part of the thigh.

*Relations.*—In its course downwards it rests successively upon the pectineus, the conjoined tendon of the psoas and iliacus, adductor brevis, and adductor magnus muscles. To its *outer side* the tendinous insertion of the vastus internus muscle intervenes between it and the femur; on its *inner side* it is in relation with the pectineus, adductor brevis, and adductor magnus; and *in front* it is separated from the femoral artery, *above* by the profunda vein and femoral vein, and *below* by the adductor longus muscle.

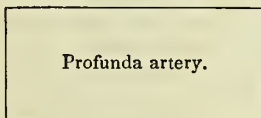
*Plan of the Relations of the Profunda Artery.*

*In Front.*

Profunda vein,  
Adductor longus.

*Inner Side.*

Pectineus,  
Adductor brevis,  
Adductor magnus.



*Outer Side.*

Psoas and iliacus,  
Vastus internus,  
Femur.

*Behind.*

Pectineus,  
Tendon of psoas and iliacus,  
Adductor brevis,  
Adductor magnus.

*Branches.*—The branches of the profunda artery are, the external circumflex, internal circumflex, and three perforating arteries.

The *External circumflex* artery passes obliquely outwards between the

divisions of the crural nerve, then between the rectus and crureus muscle, and divides into three branches; *ascending*, which inosculates with the terminal branches of the gluteal artery; *descending*, which inosculates with the superior external articular artery; and *middle*, which continues the original course of the artery around the thigh, and anastomoses with branches of the ischiatic, internal circumflex, and superior perforating artery. It supplies the muscles on the anterior and outer side of the thigh.

The *Internal circumflex* artery is larger than the external; it winds around the inner side of the neck of the femur, passing between the pectineus and psoas, and along the border of the external obturator muscle, to the space between the quadratus femoris and upper border of the adductor magnus, where it anastomoses with the ischiatic, external circumflex, and superior perforating artery. It supplies the muscles of the upper and inner side of the thigh, anastomosing with the obturator artery, and sends a small branch through the notch in the acetabulum into the hip joint.

The *Superior perforating* artery passes backwards between the pectineus and adductor brevis, pierces the adductor magnus near the femur, and is distributed to the posterior muscles of the thigh; inosculating freely with the circumflex and ischiatic arteries, and with the branches of the middle perforating artery.

The *Middle perforating* artery pierces the tendons of the adductor brevis and magnus, and is distributed like the superior; inosculating with the superior and inferior perforantes. This branch frequently gives off the nutritious artery of the femur.

The *Inferior perforating* artery is given off below the adductor brevis, and pierces the tendon of the adductor magnus, supplying it and the flexor muscles, and inosculating with the middle perforating artery above, and with the articular branches of the popliteal below. It is through the medium of these branches that the collateral circulation is maintained in the limb after ligature of the femoral artery.

The *Muscular branches* are given off by the femoral artery throughout the whole of its course. They supply the muscles in immediate proximity with the artery, particularly those of the anterior aspect of the thigh. One of these branches, larger than the rest, arises from the femoral immediately below the origin of the profunda, and passing outwards between the rectus and sartorius divides into branches which are distributed to all the muscles of the anterior aspect of the thigh. This may be named the *superior muscular artery*.

The *Anastomotica magna* arises from the femoral while in the tendinous canal formed by the adductors and vastus internus. It runs along the tendon of the adductor magnus to the inner condyle, and inosculates with the superior internal articular artery; some of its branches are distributed to the vastus internus muscle and to the crureus, and terminate by anastomosing with the branches of the external circumflex and superior external articular artery.

#### POPLITEAL ARTERY.

The popliteal artery (Fig. 160) commences from the termination of the femoral at the opening in the adductor magnus muscle, and passes obliquely outwards through the middle of the popliteal space to the lower border of the popliteus muscle, where it divides into the anterior and posterior tibial artery.



*Relations.*—In its course downwards it rests first on the femur, then on the posterior ligament of the knee joint, then on the fascia, covering the popliteus muscle. *Superficially* it is in relation with the semi-membranosus muscle, next with a quantity of fat which separates it from the deep fascia, and near its termination with the gastrocnemius plantaris, and soleus; superficial and external to it is the popliteal vein, and still more superficial and external, the popliteal nerve. By its *inner side* it is in relation with the semi-membranosus, internal condyle of the femur, and inner head of the gastrocnemius; and by its *outer side* with the biceps, external condyle of the femur, the outer head of the gastrocnemius, the plantaris and the soleus.

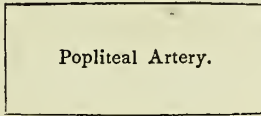
*Plan of the Relations of the Popliteal Artery.*

*Superficially.*

Semi-membranosus,  
Popliteal nerve,  
Popliteal vein,  
Gastrocnemius,  
Plantaris,  
Soleus.

*Inner Side.*

Semi-membranosus,  
Internal condyle,  
Gastrocnemius.



*Outer Side.*

Biceps,  
External condyle,  
Gastrocnemius,  
Plantaris,  
Soleus.

*Deeply.*

Femur,  
Ligamentum posticum Winslowii,  
Popliteal fascia.

*Branches.*—The branches of the popliteal artery are the

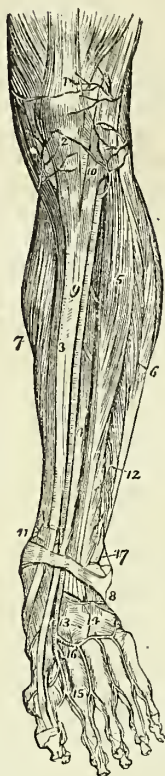
Superior external articular,  
Superior internal articular,  
Azygos articular,  
Inferior external articular,  
Inferior internal articular,  
Sural.

The *Superior articular* arteries, *external* and *internal*, wind around the femur, immediately above the condyles, to the front of the knee joint, anastomosing with each other, with the external circumflex, the anastomotica magna, the inferior articular, and the recurrent of the anterior tibial. The external passes beneath the tendon of the biceps, and the internal through an arched opening beneath the tendon of the adductor magnus. They supply the knee joint and the lower part of the femur.

The *Azygos articular* artery pierces the posterior ligament of the joint, the ligamentum posticum Winslowii, and supplies the synovial membrane in its interior. There are, frequently, several posterior articular arteries.

The *Inferior articular* arteries wind around the head of the tibia immediately below the joint, and anastomose with each other, the superior articular arteries, and the recurrent of the anterior tibial. The external passes beneath the two external lateral ligaments of the joint, and the in

Fig. 159.\*



ternal beneath the internal lateral ligament. They supply the knee joint and the heads of the tibia and fibula.

The *Sural* arteries (sura, the calf) are two large muscular branches, which are distributed to the two heads of the gastrocnemius muscle.

#### ANTERIOR TIBIAL ARTERY.

The anterior tibial artery passes forwards between the two heads of the tibialis posticus muscle, and through the opening in the upper part of the interosseous membrane, to the anterior tibial region. It then runs down the anterior aspect of the leg to the ankle joint, where it becomes the dorsalis pedis.

*Relations.*—In its course downwards upon the interosseous membrane (to which it is connected by a little tendinous arch which is thrown across it), the lower part of the tibia, and the anterior ligament of the joint. In the upper third of its course it is situated between the tibialis anticus and extensor longus digitorum, lower down between the tibialis anticus and extensor proprius pollicis; and just before it reaches the ankle it is crossed by the tendon of the extensor proprius pollicis, and becomes placed between that tendon and the tendons of the extensor longus digitorum. Its immediate relations are the venæ comites and the anterior tibial nerve, which latter lies at first to its outer side, and at about the middle of the leg becomes placed superficially to the artery.

#### *Plan of the Relations of the Anterior Tibial Artery.*

##### *Front.*

Deep fascia,  
Tibialis anticus,  
Extensor longus digitorum,  
Extensor proprius pollicis,  
Anterior tibial nerve.

##### *Inner Side.*

Tibialis anticus,  
Tendon of the ex-  
tensior proprius  
pollicis.

Anterior Tibial Artery.

##### *Outer Side.*

Anterior tibial nerve,  
Extensor longus digitorum,  
Extensor proprius pollicis,  
Tendons of the extensor  
longus digitorum.

##### *Behind.*

Interosseous membrane,  
Tibia (lower fourth),  
Ankle joint.

\* The anterior aspect of the leg and foot, showing the anterior tibial and dorsalis pedis arteries, with their branches. 1. The tendon of insertion of the quadriceps extensor muscle. 2. The insertion of the ligamentum patellæ into the lower border of the patella. 3. The tibia. 4. The extensor proprius pollicis muscle. 5. The extensor longus digitorum. 6. The peronei muscles. 7. The inner belly of the gastrocnemius and

*Branches.*—The branches of the Anterior Tibial Artery are the—

Recurrent,  
Muscular,  
External malleolar,  
Internal malleolar.

The *Recurrent* branch passes upwards beneath the origin of the tibialis anticus muscle to the front of the knee joint, upon which it is distributed, anastomosing with the articular arteries.

The *Muscular* branches are very numerous, they supply the muscles of the anterior tibial region.

The *Malleolar arteries* are distributed to the ankle joint; the *external* passing beneath the tendons of the extensor longus digitorum and peroneus tertius, inosculates with the anterior peroneal artery and with the branches of the dorsalis pedis; the *internal*, beneath the tendons of the extensor proprius pollicis and tibialis anticus, inosculates with branches of the posterior tibial and internal plantar artery. They supply branches to the ankle joint.

The DORSALIS PEDIS ARTERY is continued forward along the tibial side of the dorsum of the foot, from the ankle to the base of the metatarsal bone of the great toe, where it divides into two branches, the dorsalis hallucis and communicating.

*Relations.*—The dorsalis pedis is situated along the outer border of the tendon of the extensor proprius pollicis; on its fibular side is the innermost tendon of the extensor longus digitorum, and near its termination it is crossed by the inner tendon of the extensor brevis digitorum. It is accompanied by venæ comites, and has the continuation of the anterior tibial nerve to its outer side.

*Plan of the Relations of the Dorsalis Pedis Artery.*

*In Front.*

Integument,  
Deep fascia,  
Inner tendon of the extensor  
brevis digitorum.

*Inner Side.*

Tendon of the extensor proprius pollicis.

Dorsalis Pedis Artery.

*Outer Side.*

Tendon of the extensor longus digitorum,  
Border of the extensor brevis digitorum muscle.

*Behind.*

Bones of the tarsus, with  
their ligaments

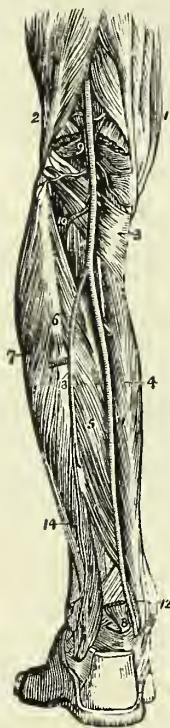
the soleus. 8. The annular ligament beneath which the extensor tendons and the anterior tibial artery pass into the dorsum of the foot. 9. The anterior tibial artery. 10. Its recurrent branch inosculating with (2) the inferior articular, and (1) the superior articular arteries, branches of the popliteal. 11. The internal malleolar artery. 17. The external malleolar inosculating with the anterior peroneal artery. 12. 13. The dorsalis pedis artery. 14. The tarsea and metatarsæ arteries; the tarsea is nearest the ankle, the metatarsæ is seen giving off the interosseæ. 15. The dorsalis hallucis artery. 16. The communicating branch.

*Branches.*—The branches of this artery are the—

Tarsæ,  
Metatarsæ,—interosseæ,  
Dorsalis hallucis,—collateral digital,  
Communicating.

The *Tarsæ* arches transversely across the tarsus, beneath the extensor brevis digitorum muscle, and supplies the articulations of the tarsal bones and the outer side of the foot; it anastomoses with the external malleolar, the peroneal arteries, and the external plantar.

Fig. 160.\*



The *Metatarsæ* forms an arch across the base of the metatarsal bones, and supplies the outer side of the foot; anastomosing with the tarsæ and with the external plantar artery. The metatarsæ gives off three branches, the *interosseæ*, which pass forward upon the dorsal interossei muscles, and divide into two collateral branches for adjoining toes. At their commencement these interosseous branches receive the posterior perforating arteries from the plantar arch, and opposite the heads of the metatarsal bones they are joined by the anterior perforating branches from the digital arteries.

The *Dorsalis hallucis* runs forward upon the first dorsal interosseous muscle, and at the base of the first phalanx divides into two branches, one of which passes inwards beneath the tendon of the extensor proprius pollicis, and is distributed to the inner border of the great toe, while the other bifurcates for the supply of the adjacent sides of the great and second toe.

The *Communicating artery* passes into the sole of the foot between the two heads of the first dorsal interosseous muscle, and inosculates with the termination of the external plantar artery.

Besides the preceding, numerous branches are distributed to the bones and articulations of the foot, particularly along the inner border of the latter.

#### POSTERIOR TIBIAL ARTERY.

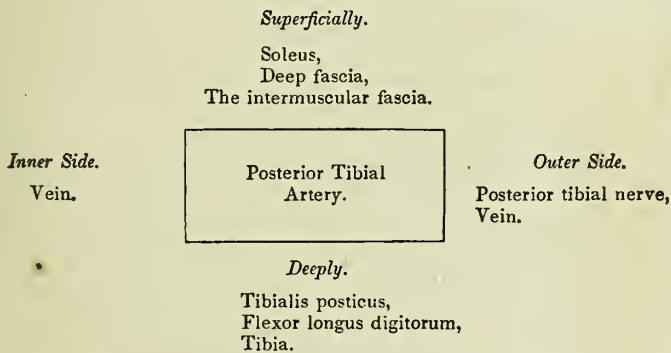
The posterior tibial artery passes obliquely downwards along the tibial side of the leg from the lower

\* A posterior view of the leg, showing the popliteal and posterior tibial artery. 1. The tendons forming the inner hamstring. 2. The tendon of the biceps forming the outer hamstring. 3. The popliteus muscle. 4. The flexor longus digitorum. 5. The tibialis posticus. 6. The fibula; immediately below the figure is the origin of the flexor longus pollicis; the muscle has been removed in order to expose the peroneal artery. 7. The peronei muscles, longus and brevis. 8. The lower part of the flexor longus pollicis muscle with its tendon. 9. The popliteal artery giving off its articular and muscular branches; the two superior articular are seen in the upper part of the popliteal space passing above the two heads of the gastrocnemius muscle, which are cut through near their origin. The two inferior are in relation with the popliteus muscle. 10. The anterior tibial artery passing through the angular interspace between the two heads of the tibialis posticus muscle. 11. The posterior tibial artery. 12. The relative position of the tendons and artery at the inner ankle from within outwards, previously to their passing beneath the internal annular ligament. 13. The peroneal artery, dividing, a little below the number, into two branches; the anterior peroneal is seen piercing the interosseous membrane. 14. The posterior peroneal

border of the popliteus muscle to the concavity of the os calcis, where it divides into the internal and external plantar artery.

*Relations.*—In its course downwards it lies first upon the tibialis posticus, next on the flexor longus digitorum, and then on the tibia; it is covered in by the intermuscular fascia which separates it above from the soleus, and below from the deep fascia of the leg and the integument. It is accompanied by its venæ comites, and by the posterior tibial nerve, which latter lies at first to its outer side, then superficially to it, and again to its outer side.

*Plan of the Relations of the Posterior Tibial Artery.*



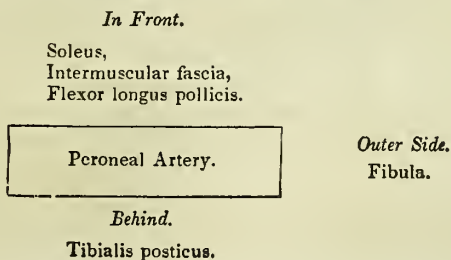
*Branches.*—The branches of the posterior tibial artery are the—

- |             |                     |
|-------------|---------------------|
| Peroneal,   | Internal calcanean, |
| Nutritious, | Internal plantar,   |
| Muscular,   | External plantar.   |

The *Peroneal artery* is given off from the posterior tibial at about two inches below the lower border of the popliteus muscle; it is nearly as large as the anterior tibial artery, and passes obliquely outwards to the fibula. It then runs downwards along the inner border of the fibula to its lower third, where it divides into the anterior and posterior peroneal artery.

*Relations.*—The peroneal artery rests upon the tibialis posticus muscle, and is covered in by the soleus, the intermuscular fascia, and the flexor longus pollicis, having the fibula to its outer side.

*Plan of the Relations of the Peroneal Artery.*



*Branches.*—The branches of the peroneal artery are, *muscular* to the neighbouring muscles, particularly to the soleus, and the two terminal branches anterior and posterior peroneal.

The *Anterior peroneal* pierces the interosseous membrane at the lower third of the leg, and is distributed on the front of the outer malleolus, anastomosing with the external malleolar and tarsal artery. This branch is very variable in size.

The *Posterior peroneal* continues onwards along the posterior aspect of the outer malleolus to the side of the os calcis, to which and to the muscles arising from it, it distributes *external calcanean* branches. It anastomoses with the anterior peroneal, tarsal, external plantar, and posterior tibial artery.

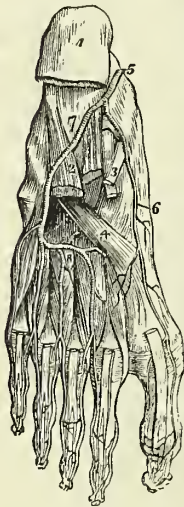The *Nutritious artery* of the tibia arises from the trunk of the tibial, frequently above the origin of the peroneal, and proceeds to the nutritious canal, which it traverses obliquely from below upwards.

The *Muscular branches* of the posterior tibial artery are distributed to the soleus and to the deep muscles on the posterior aspect of the leg. One of these branches is deserving of notice, a *recurrent branch*, which arises from the posterior tibial above the origin of the peroneal artery, pierces the soleus, and is distributed upon the inner side of the head of the tibia, anastomosing with the inferior internal articular.

The *Internal calcanean branches*, three or four in number, proceed from the posterior tibial artery immediately before its division; they are distributed to the inner side of the os calcis, to the integument, and to the muscles which arise from its inner tuberosity, and they anastomose with the external calcanean branches, and with all the neighbouring arteries.

#### PLANTAR ARTERIES.

Fig. 161.\*



The *Internal plantar artery* proceeds from the bifurcation of the posterior tibial at the inner malleolus, and passes along the inner border of the foot between the abductor pollicis and flexor brevis digitorum muscles, supplying the inner border of the foot and great toe.

The *External plantar artery*, much larger than the internal, passes obliquely outwards between the first and second layers of the plantar muscles, to the fifth metatarsal space. It then turns horizontally inwards between the second and third layers, to the first metatarsal space, where it inosculates with the communicating branch from the dorsalis pedis. The horizontal portion of the artery describes a slight curve, having the convexity forwards; this is the plantar arch.

*Branches.*—The branches of the external plantar artery are the—

- Muscular,
- Articular,
- Digital,—anterior perforating,
- Posterior perforating.

\* The arteries of the sole of the foot; the first and a part of the second layer of muscles having been removed. 1. The under and posterior part of the os calcis; to which the origins of the first layer of muscles remain attached. 2. The musculus accessorius

The *Muscular branches* are distributed to the muscles in the sole of the foot.

The *Articular branches* supply the ligaments of the articulations of the tarsus, and their synovial membranes.

The *Digital branches* are four in number: the first is distributed to the outer side of the little toe; the three others pass forwards to the cleft between the toes, and divide into collateral branches, which supply the adjacent sides of the three external toes, and the outer side of the second. At the bifurcation of the toes, a small branch is sent upwards from each digital artery, to inosculate with the interosseous branches of the metatarsæ; these are the *anterior perforating* arteries.

The *Posterior perforating* are three small branches which pass upwards between the heads of the three external dorsal interossei muscles to inosculate with the arch formed by the metatarsæ artery.

*Varieties in the Arteries of the Lower Extremity.*—The femoral artery occasionally divides at Poupart's ligament into two branches, and sometimes into three; the former is an instance of the high division of the profunda artery; and in a case of the latter kind which occurred during my dissections, the branches were the profunda, the superficial femoral, and the internal circumflex artery. Dr. Quain, in his "Elements of Anatomy," records an instance of a high division of the femoral artery, in which the two vessels became again united in the popliteal region. The point of origin of the profunda artery varies considerably in different subjects, being sometimes nearer to and sometimes farther from Poupart's ligament, but more frequently the former. The branches of the popliteal artery are very liable to variety in size; and in all these cases the compensating principle, so constant in the vascular system, is strikingly manifested. When the anterior tibial is of small size, the peroneal is large; and, in place of dividing into two terminal branches at the lower third of the leg, descends to the lower part of the interosseous membrane, and emerges upon the front of the ankle, to supply the dorsum of the foot: or the posterior tibial and plantar arteries are large, and the external plantar is continued between the heads of the first dorsal interosseous muscle, to be distributed to the dorsal surface of the foot. Sometimes the posterior tibial artery is small and thread-like; and the peroneal, after descending to the ankle, curves inwards to the inner malleolus, and divides into the two plantar arteries. If, in this case, the posterior tibial be sufficiently large to reach the ankle, it inosculates with the peroneal previously to its division. The internal plantar artery sometimes takes the distribution of the external plantar, which is short and diminutive, and the latter not unfrequently replaces a deficient dorsalis pedis.

The varieties of arteries are interesting in the practical application of a knowledge of their principal forms to surgical operations; in their transcendental anatomy, as illustrating the normal type of distribution in animals; or, in many cases, as diverticula permitted by Nature, to teach her observers two important principles:—*first*, in respect to herself, that, however in her means she may indulge in change, the end is never overlooked, and a limb is as surely supplied by a leash of arteries, various in their

3. The long flexor tendons. 4. The tendon of the peroneus longus. 5. The termination of the posterior tibial artery. 6. The internal plantar. 7. The external plantar artery. 8. The plantar arch giving off four digital branches, which pass forwards to the interosseous muscles. Three of these arteries are seen dividing, near the heads of the metatarsal bones, into collateral branches for adjoining toes.

course, as by those which we are pleased to consider normal in distribution; and, *secondly*, with regard to us, that we should ever be keenly alive to what is passing beneath our observation, and ever ready in the most serious operation to deviate from our course and avoid—or give eyes to our knife, that it may see,—the concealed dangers which it is our pride to be able to contend with and vanquish.

#### PULMONARY ARTERY.

The pulmonary artery arises from the left side of the base of the right ventricle in front of the origin of the aorta, and ascends obliquely to the under surface of the arch of the aorta, where it divides into the right and left pulmonary arteries. In its course upwards and backwards it inclines to the left side, crossing the commencement of the aorta, and is connected to the under surface of the arch by a thick and impervious cord, the remains of the ductus arteriosus.

*Relations.*—It is enclosed for one-half of its extent by the pericardium, and receives the attachment of the fibrous portion of that membrane by its upper portion. Behind, it rests against the ascending aorta; on either side is the appendix of the corresponding auricle with a coronary artery; and above, the cardiac ganglion and the remains of the ductus arteriosus.

The *Right pulmonary artery* passes beneath the arch and behind the ascending aorta, and in the root of the lungs divides into three branches for the three lobes.

The *Left pulmonary artery*, rather larger than the right, passes in front of the descending aorta, to the root of the left lung, to which it is distributed. These arteries divide and subdivide in the structure of the lungs, and terminate in capillary vessels which form a network around the air-passages and cells, and become continuous with the radicles of the pulmonary veins.

*Relations.*—In the root of the *right lung*, examined from above downwards, the pulmonary artery is situated between the bronchus and pulmonary veins, the former being above, the latter below; while in the *left lung* the artery is the highest, next the bronchus, and then the veins. On both sides, from before backwards, the artery is situated between the veins and bronchi, the former being in front, and the latter behind.

## CHAPTER VII.

### OF THE VEINS.

THE veins are the vessels which return the blood to the auricles of the heart, after it has been circulated by the arteries through the various tissues of the body. They are much thinner in structure than the arteries, so that when emptied of their blood they become flattened and collapsed. The veins of the systemic circulation convey the dark-coloured and impure or *venous blood* from the capillary system to the right auricle of the heart, and they are found after death to be more or less distended with that fluid. The veins of the pulmonary circulation resemble the arteries of the systemic circulation in containing during life the pure or arterial



blood, which they transmit from the capillaries of the lungs to the left auricle.

The veins commence by minute radicles in the capillaries which are everywhere distributed through the textures of the body, and converge to constitute larger and larger branches, till they terminate in the main trunks which convey the venous blood directly to the heart. In diameter they are larger than the arteries, and, like those vessels, their combined area would constitute an imaginary cone, whereof the apex is placed at the heart, and the base at the surface of the body. It follows from this arrangement, that the blood in returning to the heart is passing from a larger into a smaller channel, and therefore that it increases in rapidity during its course.

Veins admit of a threefold division into, superficial, deep, and sinuses.

The *Superficial veins* return the blood from the integument and superficial structures, and take their course between the layers of the superficial fascia; they then pierce the deep fascia in the most convenient and protected situations, and terminate in the deep veins. They are unaccompanied by arteries, and are the vessels usually selected for venesection.

The *Deep veins* are situated among the deeper structures of the body, and generally in relation with the arteries; in the limbs they are enclosed in the same sheath with those vessels, and they return the venous blood from the capillaries of the deep tissues. In company with all the smaller, and also with the secondary arteries, as the brachial, radial, and ulnar in the upper, and the tibial and peroneal in the lower extremity, there are two veins, placed one on each side of the artery, and named *venæ comites*. The larger arteries, as the axillary, subclavian, carotid, popliteal, femoral, &c., are accompanied by a single venous trunk. *Sinuses* differ from veins in their structure; and also in their mode of distribution, being confined to especial organs and situated within their substance. The principal venous sinuses are those of the dura mater, the diploë, the cancellous structure of bones, and the uterus.

The communications between veins are even more frequent than those of arteries, and they take place between the larger as well as among the smaller vessels; the *venæ comites* communicate with each other very frequently in their course, by means of short transverse branches which pass across from one to the other. These communications are strikingly exhibited in the frequent inosculation of the spinal veins, and in the various venous plexuses, as the spermatic plexus, vesical plexus, &c. The office of these inosculation is very apparent, as tending to obviate the obstructions to which the veins are particularly liable from the thinness of their coats, and from their inability to overcome much impediment by the force of their current.

Veins, like arteries, are composed of three coats, external or areolo-fibrous, middle or fibrous, and internal or serous. The *external coat* is firm and strong, and resembles that of arteries. The *middle coat* consists of two layers, an outer layer of contractile fibrous tissue disposed in a circular direction around the vessel, and an inner layer of organic muscular fibres arranged longitudinally. This latter resembles the inner layer of the middle coat of arteries, but is somewhat thicker; it is not unfrequently hypertrophied. The *internal coat*, as in arteries, consists of a striated or fenestrated layer, and a layer of epithelium; it is continuous with the internal coat of arteries through the medium of the lining membrane of the

heart on the one hand, and through the capillary vessels on the other. The differences in structure, therefore, between arteries and veins, relate to the difference of thickness of their component layers, and to the absence of the elastic coat in the latter. Moreover, another difference occurs in the presence of valves. The valves of veins are composed of a thin layer of fibrous membrane, lined upon its two surfaces by epithelium. The segments or flaps of the valves of veins are semilunar in form and arranged in pairs, one upon either side of the vessel; in some instances there is but a single flap, which has a spiral direction, and occasionally there are three. The free border of the valvular flaps is concave, and directed forwards, so that while the current of blood is permitted to flow freely towards the heart, the valves are distended and the current intercepted if the stream become retrograde in its course. Upon the cardiac side of each valve the vein is expanded into two *pouèhes* (sinuses), corresponding with the flaps of the valves, which give to the distended or injected vein a knotted appearance. The valves are most numerous in the veins of the extremities, particularly in the deeper veins, and they are generally absent in the very small veins, and in the veins of the viscera, as in the portal and cerebral veins: they are also absent in the large trunks, as in the *venæ cavæ*, *venæ azygos*, *innominatæ*, and *iliac veins*.

Sinuses are venous channels, excavated in the structure of an organ, and lined by the internal coat of the veins; of this structure are the sinuses of the *dura mater*, whose external covering is the fibrous tissue of the membrane, and the internal, the serous layer of the veins. The external investment of the sinuses of the uterus is the tissue of that organ; and that of the bones, the lining membrane of the cells and canals.

Veins, like arteries, are supplied with nutritious vessels, the *vasa vasorum*; and it is to be presumed that nervous filaments are distributed in their coats.

I shall describe the veins according to the primary division of the body, taking first, those of the head and neck; next, those of the upper extremity; then, those of the lower extremity; and lastly, the veins of the trunk.

#### VEINS OF THE HEAD AND NECK.

The veins of the head and neck may be arranged into three groups, viz.  
 1. Veins of the exterior of the head. 2. Veins of the *diploë* and interior of the cranium. 3. Veins of the neck.

The veins of the exterior of the head are the—

Facial,  
 Internal maxillary,  
 Temporal,  
 Temporo-maxillary,  
 Posterior auricular,  
 Occipital.

The *Facial vein* commences on the anterior part of the skull in a venous plexus, formed by the communications of the branches of the temporal, and descends along the middle line of the forehead, under the name of *frontal vein*, to the root of the nose, where it is connected with its fellow of the opposite side by a communicating trunk which constitutes the *nasal arch*. There are usually two frontal veins, which communicate by a trans-

verse anastomosis; but sometimes the vein is single and bifurcates at the root of the nose, into the two angular veins. From the nasal arch, the frontal is continued downwards by the side of the root of the nose, under the name of the *angular vein*; it then passes beneath the zygomatic muscles and becomes the facial vein, and descends along the anterior border of the masseter muscle, crossing the body of the lower jaw, by the side of the facial artery, to the submaxillary gland, and from thence to the internal jugular vein in which it terminates.

The *branches* which the facial vein receives in its course are, the *supra-orbital*, which joins the frontal vein; the *dorsal veins* of the nose which terminate in the nasal arch; the *ophthalmic*, which communicates with the angular vein; the *palpebral* and *nasal*, which open into the angular vein; a considerable trunk, the *alveolar*, which returns the blood from the sphenomaxillary fossa, from the infra-orbital, palatine, vidian, and sphenopalatine veins, and joins the facial beneath the zygomatic process of the superior maxillary bone, and the veins corresponding with the branches of the facial artery.

The *Internal maxillary vein* receives the branches from the zygomatic and pterygoid fossæ; these are so numerous and communicate so freely as to constitute a *pterygoid plexus*. Passing backwards behind the neck of the lower jaw, the internal maxillary joins with the temporal vein, and the common trunk resulting from this union constitutes the *temporo-maxillary vein*.

The *Temporal vein* commences on the vertex of the head by a plexiform network which is continuous with the frontal, the temporal, auricular, and occipital veins. The ramifications of this plexus form an anterior and a posterior branch which unite immediately above the zygoma; the trunk is here joined by another large vein, the *middle temporal*, which collects the blood from the temporal muscle, and around the outer segment of the orbit, and pierces the temporal fascia near the root of the zygoma. The temporal vein then descends between the meatus auditorius externus and the condyle of the lower jaw, and unites with the internal maxillary vein, to form the temporo-maxillary.

The *Temporo-maxillary vein* formed by the union of the temporal and internal maxillary, passes downwards in the substance of the parotid gland to its lower border, where it becomes the external jugular vein. It receives in its course the *anterior auricular*, *masseteric*, *transverse facial*, and *parotid veins*, and near its termination is joined by the posterior auricular vein.

The *Posterior auricular vein* communicates with the plexus upon the vertex of the head, and descends behind the ear to the temporo-maxillary vein, immediately before that vessel merges in the external jugular. It receives in its course the veins from the external ear and the *stylo-mastoid vein*.

The *Occipital vein* commencing posteriorly in the plexus of the vertex of the head, follows the direction of the occipital artery, and passing deeply beneath the muscles of the back part of the neck, terminates in the internal jugular vein. This vein communicates with the lateral sinus by means of a large branch which passes through the mastoid foramen, the *mastoid vein*.

## VEINS OF THE DIPLOE.

The diploë of the bones of the head is furnished in the adult with irregular sinuses, which are formed by a continuation of the internal coat of the

veins into the osseous canals in which they are lodged. At the middle period of life these sinuses are confined to the particular bones; but in old age, after the ossification of the sutures, they may be traced from one bone to the next. They receive their blood from the capillaries supplying the cellular structure of the diploë, and terminate externally in the veins of the pericranium, and internally in the veins and sinuses of the dura mater. These veins are separated from the bony walls of the canals by a thin layer of medulla.

#### CEREBRAL AND CEREBELLAR VEINS.

The cerebral veins are remarkable for the absence of valves, and for the extreme tenuity of their coats. They may be arranged into the superficial, and deep or ventricular veins.

The *Superficial cerebral veins* are situated on the surface of the hemispheres, lying in the grooves formed by the convexities of the convolutions. They are named from the position which they may chance to occupy upon the surface of this organ, either superior or inferior, internal or external, anterior or posterior.

The *Superior cerebral veins*, seven or eight in number on each side, pass obliquely forwards, and terminate in the superior longitudinal sinus, in the opposite direction to the course of the stream of blood in the sinus.

The *Deep or Ventricular veins* commence within the lateral ventricles by the veins of the corpora striata and those of the *choroid plexus*, which unite to form the two *venæ Galeni*.

The *Venæ Galeni* pass backwards in the structure of the velum interpositum; and escaping through the fissure of Bichât, terminate in the straight sinus.

The *Cerebellar veins* are disposed, like those of the cerebrum, on the surface of the lobes of the cerebellum; they are situated some upon the superior, and some upon the inferior surface, while others occupy the borders of the organ. They terminate in the lateral and petrosal sinuses.

#### SINUSES OF THE DURA MATER.

The sinuses of the dura mater are irregular channels, formed by the splitting of the layers of that membrane, and lined upon their inner surface by a continuation of the internal coat of the veins. They may be divided into two groups:—1. Those situated at the upper and back part of the skull. 2. The sinuses at the base of the skull. The former are, the

Superior longitudinal sinus,  
Inferior longitudinal sinus,  
Straight sinus,  
Occipital sinuses,  
Lateral sinuses.

The *Superior longitudinal sinus* is situated in the attached margin of the falx cerebri, and extends along the middle line of the arch of the skull, from the foramen cæcum in the frontal, to the inner tuberosity of the occipital bone, where it divides into the two lateral sinuses. It is triangular in form, is small in front, and increases gradually in size as it passes backwards; it receives the superior cerebral veins, which open into it obliquely, numerous small veins from the diploë, and near the posterior

extremity of the sagittal suture the *parietal veins*, from the pericranium and scalp. Examined in its interior, it presents numerous transverse fibrous bands (*trabeculæ*), the *chordæ Willisii*, which are stretched across its inferior angle; and some small white granular masses, the *glandulæ Pacchioni*; the oblique openings of the cerebral veins, with their valve-like margin, are also seen on the walls of the sinus.

The termination of the superior longitudinal sinus in the two lateral sinuses forms a considerable dilatation, into which the straight sinus opens from the front, and the occipital sinuses from below. This dilatation is named the *torcular Herophili*,† and is the point of communication of six sinuses, the superior longitudinal, two lateral, two occipital, and the straight.

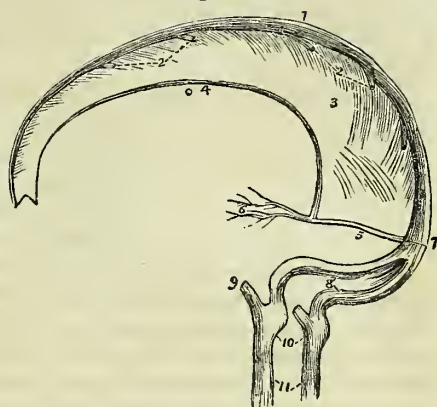
The *Inferior longitudinal sinus* is situated in the free margin of the falx cerebri; it is cylindrical in form, and extends from near the crista galli to the anterior border of the tentorium, where it terminates in the straight sinus. It receives in its course several veins from the falx.

The *Straight or fourth sinus* is the sinus of the tentorium; it is situated at the line of union of the falx with the tentorium; is prismoid in form, and extends across the tentorium, from the termination of the inferior longitudinal sinus to the torcular Herophili. It receives the *venæ Galeni*, the cerebral veins from the inferior part of the posterior lobes, and the superior cerebellar veins.

The *Occipital sinuses* are two canals of small size, situated in the attached border of the falx cerebelli; they commence by several small veins around the foramen magnum, and terminate by separate openings in the torcular Herophili. They not unfrequently communicate with the termination of the lateral sinuses.

The *Lateral sinuses*, commencing at the torcular Herophili, pass horizontally outwards, in the attached margin of the tentorium, and then curve downwards and inwards along the base of the petrous portion of the temporal bone, at each side, to the foramina lacerata posteriora, where they terminate in the internal jugular veins. Each sinus rests in its course on the transverse groove of the occipital bone, posterior inferior angle of the parietal, mastoid portion of the temporal, and again on the occipital bone. They receive the cerebral veins from the inferior surface of the posterior

Fig. 162.\*



\* The sinuses of the upper and back part of the skull. 1. The superior longitudinal sinus. 2. The cerebral veins opening into the sinus from behind forwards. 3. The falx cerebri. 4. The inferior longitudinal sinus. 5. The straight or fourth sinus. 6. The *venæ Galeni*. 7. The torcular Herophili. 8. The two lateral sinuses, with the occipital sinuses between them. 9. The termination of the inferior petrosal sinus of one side. 10. The dilatations corresponding with the jugular fossæ. 11. The internal jugular veins.

† Torcular (a press), from a supposition entertained by the older anatomists that the columns of blood, coming in different directions, compressed each other at this point

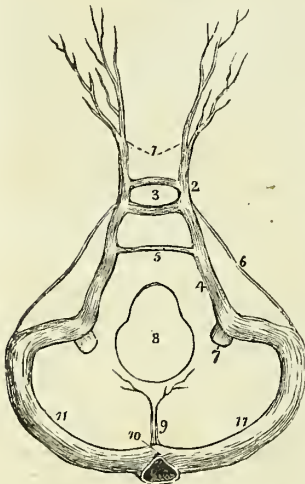
lobes, the inferior cerebellar veins, the superior petrosal sinuses, the mastoid, and posterior condyloid veins, and at their termination, the inferior petrosal sinuses. These sinuses are often unequal in size, the right being larger than the left.

The sinuses of the base of the skull are the—

Cavernous,  
Inferior petrosal,  
Circular,  
Superior petrosal,  
Transverse.

The *Cavernous sinuses* are named from presenting a structure similar to that of the corpus cavernosum penis. They are situated on each side of the sella turcica, receiving, anteriorly, the ophthalmic veins through the sphenoidal fissures, and terminating posteriorly in the inferior petrosal sinuses. In the internal wall of each cavernous sinus is the internal carotid artery, accompanied by several filaments of the carotid plexus, and crossed by the sixth nerve; and, in its external wall, the third, fourth, and ophthalmic nerves. These structures are separated from the blood flowing through the sinus, by the tubular lining membrane. The cerebral veins from the under surface of the anterior lobes open into the cavernous sinuses. They communicate by means of the ophthalmic with the facial veins, by the circular sinus with each other, and by the superior petrosal with the lateral sinuses.

Fig. 163.\*



The *Inferior petrosal sinuses* are the continuations of the cavernous sinuses backwards along the lower border of the petrous portion of the temporal bone at each side of the base of the skull, to the foramina lacerata posteriora, where they terminate with the lateral sinuses in the commencement of the internal jugular veins.

The *Circular sinus* (sinus of Ridley) is situated in the sella turcica, surrounding the pituitary gland, and communicating on each side with the cavernous sinus. The posterior segment is larger than the anterior.

The *Superior petrosal sinuses* pass obliquely backwards along the attached border of the tentorium, on the upper margin of the petrous portion of the temporal bone, and establish a communication between the cavernous and lateral sinus at each side. They receive one or two cerebral veins from the

inferior part of the middle lobes, and a cerebellar vein from the anterior border of the cerebellum. Near the extremity of the petrous bone these sinuses cross the oval aperture which transmits the fifth nerve.

\* The sinuses of the base of the skull. 1. The ophthalmic veins. 2. The cavernous sinus of one side. 3. The circular sinus; the figure occupies the position of the pituitary gland in the sella turcica. 4. The inferior petrosal sinus. 5. The transverse or anterior occipital sinus. 6. The superior petrosal sinus. 7. The internal jugular vein. 8. The foramen magnum. 9. The occipital sinuses. 10. The torcular Herophili. 11. . . The lateral sinuses.

The *Transverse sinus* (basilar, anterior occipital) passes transversely across the basilar process of the occipital bone, forming a communication between the two inferior petrosal sinuses. Sometimes there are two sinuses in this situation.

## VEINS OF THE NECK.

The veins of the neck which return the blood from the head are the—

External jugular,  
Anterior jugular,  
Internal jugular,  
Vertebral.

The *External jugular vein* is formed by the union of the posterior auricular vein with the temporo-maxillary, and commences at the lower border of the parotid gland, in front of the sterno-mastoid muscle. It descends the neck in the direction of a line drawn from the angle of the lower jaw to the middle of the clavicle, crosses the sterno-mastoid, and terminates, near the posterior and inferior attachment of that muscle, in the subclavian vein. In its course downwards it lies upon the anterior lamella of the deep cervical fascia, which separates it from the sterno-mastoid muscle, and is covered in by the platysma myoides and superficial fascia. At the root of the neck it pierces the deep cervical fascia; it is accompanied, for the upper half of its course, by the auricularis magnus nerve. The *branches* which it receives are the occipital cutaneous and posterior cervical cutaneous, and, near its termination, the supra and posterior scapular.

The external jugular vein is very variable in size, and is occasionally replaced by two veins. In the parotid gland it receives a large communicating branch from the internal jugular vein.

The *Anterior jugular vein* is a trunk of variable size, which collects the blood from the integument and superficial structures on the fore part of the neck. It passes downwards along the anterior border of the sterno-mastoid muscle, and opens into the subclavian vein, near the termination of the external jugular. The two veins communicate with each other, and with the external and internal jugular vein.

The *Internal jugular vein*, formed by the convergence of the lateral and inferior petrosal sinus, commences at the foramen lacerum posterius on each side of the base of the skull, and descends the side of the neck, lying, in the first instance, to the outer side of the internal carotid, and then upon the outer side of the common carotid artery to the root of the neck, where it unites with the subclavian, and constitutes the vena innominata. At its commencement, the internal jugular vein is posterior and external to the internal carotid artery, and the eighth and ninth pairs of nerves; lower down, the vein and artery are on the same plane, the glossopharyngeal and hypoglossal nerves passing forwards between them, the pneumogastric being between and behind in the same sheath, and the nerve accessorius crossing obliquely behind the vein.

The *Branches* which the internal jugular receives in its course are, the *facial*, the *lingual*, the *inferior pharyngeal*, the *occipital*, and the *superior* and *inferior thyroid* veins.

The *Vertebral vein* descends by the side of the vertebral artery in the canal formed by the foramina in the transverse processes of the cervical

vertebræ, and terminates at the root of the neck in the commencement of the vena innominata. In the lower part of the vertebral canal it frequently divides into two branches, one of which advances forwards, while the other passes through the foramen in the transverse process of the seventh cervical vertebra, before opening into the vena innominata.

The *Branches* which it receives in its course are the *posterior condyloid vein*, *muscular branches*, the *cervical meningo-rachidian veins*, and near its termination, the *superficial and deep cervical veins*.

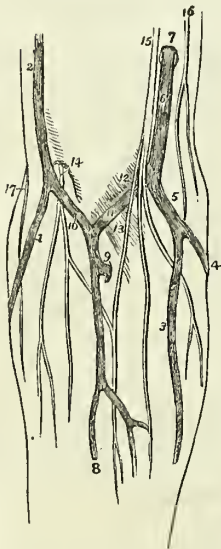
The *Inferior thyroid veins*, two, and frequently more in number, are situated one on each side of the trachea, and receive the venous blood from the thyroid gland. They communicate with each other, and with the superior thyroid veins, and form a plexus upon the front of the trachea. The right vein terminates in the right vena innominata, just at its union with the superior cava, and the left in the left vena innominata.

#### VEINS OF THE UPPER EXTREMITY.

The veins of the upper extremity are the deep and superficial. The *deep veins* accompany the branches and trunks of the arteries, and constitute their *venæ comites*. The *venæ comites* of the radial and ulnar arteries are enclosed in the same sheath with those vessels, and terminate at the bend of the elbow in the brachial veins. The brachial *venæ comites* are situated one on each side of the artery, and open into the axillary vein; the axillary becomes the subclavian, and the subclavian unites with the internal jugular to form the vena innominata.

The *Superficial veins* of the fore-arm are the—

Fig. 164.\*



Anterior ulnar vein,  
Posterior ulnar vein,  
Basilic vein,  
Radial vein,  
Cephalic vein,  
Median vein,  
Median basilic,  
Median cephalic.

The *Anterior ulnar vein* collects the venous blood from the inner border of the hand, and from the vein of the little finger, *vena salvatella*, and ascends the inner side of the fore-arm to the bend of the elbow, where it becomes the basilic vein.

The *Posterior ulnar vein*, irregular in size, and frequently absent, commences upon the inner border and posterior aspect of the hand, and ascending the fore-arm, terminates in front of the inner condyle, in the anterior ulnar vein.

The *Basilic vein* (*βασίλειος*, royal, or principal) ascends from the common ulnar vein formed by the two preceding, along the inner side of the upper arm, and near its middle pierces the fascia; it then passes upwards to the axilla, and becomes the axillary vein.

\* The veins of the fore-arm and bend of the elbow. 1. The radial vein. 2 The cephalic vein. 3. The anterior ulnar vein. 4. The posterior ulnar vein. 5. The trunk formed by their union. 6. The basilic vein, piercing the deep fascia at 7. 9. A com



The *Radial vein* commences in the large vein of the thumb, on the outer and posterior aspect of the hand, and ascends along the outer border of the fore-arm to the bend of the elbow, where it becomes the cephalic vein.

The *Cephalic vein* (κεφαλή, the head) ascends along the outer side of the arm to its upper third; it then enters the groove between the pectoralis major and deltoid muscle, where it is in relation with the descending branch of the thoracico-acromialis artery, and terminates beneath the clavicle in the subclavian vein. A large communicating branch sometimes crosses the clavicle between the external jugular and this vein, which gives it the appearance of being derived directly from the head—hence its appellation.

The *Median vein* is intermediate in position between the anterior ulnar and radial vein; it collects the blood from the anterior aspect of the forearm, communicating with the two preceding. At the bend of the elbow it receives a branch from the deep veins, and divides into two branches, the median cephalic and median basilic.

The *Median cephalic vein*, generally the smaller of the two, passes obliquely outwards, in the groove between the biceps and supinator longus, to join the cephalic vein. The branches of the external cutaneous nerve pass behind it.

The *Median basilic vein* passes obliquely inwards, in the groove between the biceps and pronator radii teres, and terminates in the basilic vein. This vein is crossed by one or two filaments of the internal cutaneous nerve, and is separated from the brachial artery by the aponeurotic slip given off by the tendon of the biceps.

#### AXILLARY VEIN.

The axillary vein is formed by the union of the venæ comites of the brachial artery with the basilic vein. It lies in front of the artery, receives numerous branches from the collateral veins of the branches of the axillary artery; and at the lower border of the first rib becomes the subclavian vein.

#### SUBCLAVIAN VEIN.

The subclavian vein crosses over the first rib and beneath the clavicle, and unites with the internal jugular vein to form the vena innominata. It lies at first in front of the subclavian artery, and then in front of the scalenus anticus, which separates it from that vessel. The phrenic and pneumogastric nerves pass between the artery and vein. The veins opening into the subclavian are the cephalic below the clavicle, and the external and anterior jugulars above; occasionally some small veins from the neighbouring parts also terminate in it.

communicating branch between the deep veins of the fore-arm and the upper part of the median vein. 10. The median cephalic vein. 11. The median basilic. 12. A slight convexity of the deep fascia, formed by the brachial artery. 13. The process of fascia, derived from the tendon of the biceps, which separates the median basilic vein from the brachial artery. 14. The external cutaneous nerve, piercing the deep fascia, and dividing into two branches, which pass behind the median cephalic vein. 15. The internal cutaneous nerve, dividing into branches, which pass in front of the median basilic vein. 16. The intercosto-humeral cutaneous nerve. 17. The spiral cutaneous nerve, a branch of the musculo-spiral.

## VEINS OF THE LOWER EXTREMITY.

The veins of the lower extremity are the deep and superficial. The *deep veins* accompany the branches of the arteries in pairs, and form the *venæ comites* of the anterior and posterior tibial and peroneal arteries. These veins unite in the popliteal region to form a single vein of large size, the popliteal, which successively becomes in its course the femoral and the external iliac vein.

## POPLITEAL VEIN.

The popliteal vein ascends through the popliteal region, lying, in the first instance, directly upon the artery, and then getting somewhat to its outer side. It receives several muscular and articular branches, and the external saphenous vein. The valves in this vein are four or five in number.

## FEMORAL VEIN.

The femoral vein, passing through the opening in the adductor magnus muscle, ascends the thigh in the sheath of the femoral artery, and entering the pelvis beneath Poupart's ligament, becomes the external iliac vein. In the lower part of its course it is situated upon the outer side of the artery; it then becomes placed behind that vessel, and, at Poupart's ligament, lies to its inner side. It receives the muscular veins, and the profunda, and, through the saphenous opening, the internal saphenous vein. The valves in this vein are four or five in number.

The *Profunda vein* is formed by the convergence of the numerous small veins which accompany the branches of the artery; it is a vein of large size, lying in front of the profunda artery, and it terminates in the femoral at about an inch and a half below Poupart's ligament.

The *Superficial veins* are the external or short, and the internal or long saphenous.

The *External saphenous vein* collects the blood from the outer side of the foot and leg. It passes behind the outer ankle, ascends along the posterior aspect of the leg, lying in the groove between the two bellies of the gastrocnemius muscle, and pierces the deep fascia in the popliteal region to join the popliteal vein. It receives several cutaneous branches in the popliteal region before passing through the deep fascia, and is accompanied in its course by the external saphenous nerve.

The *Internal saphenous vein* commences upon the dorsum and inner side of the foot. It ascends in front of the inner ankle, and along the inner side of the leg; it then passes behind the inner condyle of the femur and along the inner side of the thigh to the saphenous opening, where it pierces the sheath of the femoral vessels, and terminates in the femoral vein, at about one inch and a half below Poupart's ligament.

It receives in its course the cutaneous veins of the leg and thigh, and communicates freely with the deep veins. At the saphenous opening it is joined by the superficial epigastric and circumflexa ili veins, and by the external pudic. The situation of this vein in the thigh is not unfrequently occupied by two or even three trunks of nearly equal size.

## VEINS OF THE TRUNK.

The veins of the trunk may be divided into, 1. The superior vena cava, with its formative branches. 2. The inferior vena cava, with its formative

branches. 3. The azygos veins. 4. The vertebral and spinal veins. 5. The cardiac veins. 6. The portal vein. 7. The pulmonary veins.

SUPERIOR VENA CAVA, WITH ITS FORMATIVE  
BRANCHES.

*Venæ Innominatæ.*

The *Venæ Innominatæ* are two large trunks, formed by the union of the internal jugular and subclavian vein, at each side of the root of the neck.

The *Right vena innominata*, about an inch and a quarter in length, lies superficially and externally to the arteria innominata, and descends almost vertically to unite with its fellow of the opposite side in the formation of the superior cava. At the junction of the jugular and subclavian veins it receives from behind the ductus lymphaticus dexter, and lower down it has opening into it the *right vertebral*, *right internal mammary*, and *right inferior thyroid vein*.

The *Left vena innominata*, considerably longer than the right, extends almost horizontally across the roots of the three great arteries arising from the arch of the aorta, to the right side of the mediastinum, where it unites with the right vena innominata, to constitute the superior cava.

It is in relation in front with the left sterno-clavicular articulation and the first piece of the sternum. At its commencement it receives the thoracic duct which opens into it from behind, and in its course is joined by the *left vertebral*, *left inferior thyroid*, *left mammary*, and by the *superior intercostal vein*. It also receives some small veins from the mediastinum and thymus gland. There are no valves in the venæ innominatæ.

SUPERIOR VENA CAVA.

The superior cava is a short trunk about three inches in length, formed by the junction of the two venæ innominatæ. It descends perpendicularly on the right side of the mediastinum, and entering the pericardium terminates in the upper part of the right auricle.

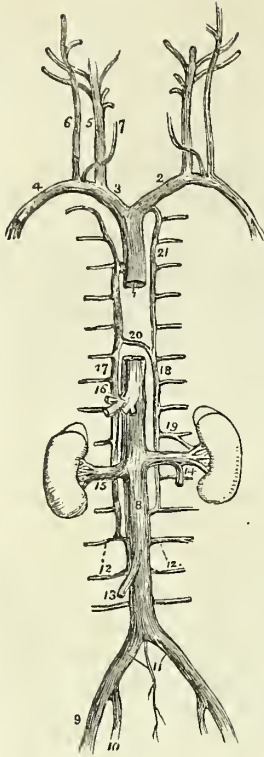
It is in relation *in front* with the thoracic fascia, which separates it from the thymus gland, and with the pericardium; *behind* with the right pulmonary artery, and right superior pulmonary vein; *internally* with the ascending aorta; *externally* with the right phrenic nerve, and right lung. Immediately before entering the pericardium it receives the vena azygos major.

INFERIOR VENA CAVA, WITH ITS FORMATIVE  
BRANCHES.

*Iliac Veins.*

The *External iliac vein* lies to the inner side of the corresponding artery at the os pubis; but gradually gets behind it as it passes upwards along the brim of the pelvis, and it terminates opposite the sacro-iliac symphysis by uniting with the internal iliac, to form the common iliac vein. Immediately above Poupart's ligament it receives the epigastric and circumflexa ilii veins; it has no valves.

Fig. 165.\*



The *Internal iliac vein* is formed by vessels which correspond with the branches of the internal iliac artery; it receives the returning blood from the gluteal, ischiatic, internal pudic, and obturator veins, externally to the pelvis; and from the vesical and uterine plexuses within the pelvis. The vein lies to the inner side of the internal iliac artery, and terminates by uniting with the external iliac vein, to form the common iliac.

The *Vesical and prostatic plexus* is an important plexus of veins which surrounds the neck and base of the bladder and prostate gland, and receives its blood from the great dorsal vein of the penis, and from the veins of the external organs of generation. It is retained in connection with the sides of the bladder by a reflexion of the pelvic fascia.

The *Uterine plexus* is situated around the vagina, and upon the sides of the uterus, between the two layers of the broad ligaments. The veins forming the vesical and uterine plexus are peculiarly subject to the production of phlebolites.

The *Common iliac veins* are formed by the union of the external and internal iliac vein on each side of the pelvis. The *right common iliac*, shorter than the left, ascends obliquely behind the corresponding artery; and upon the intervertebral substance between the fourth and fifth lumbar vertebræ, unites with the vein of the opposite side, to form the inferior cava. The *left common iliac*, longer and more oblique than the right, ascends behind, and a little internally to the corresponding artery, near its origin, to unite with the right vein in the formation of the inferior vena cava. The right common iliac vein has no branch opening into it; the left receives the vena sacra media. These veins have no valves.

#### INFERIOR VENA CAVA.

The inferior vena cava is formed by the union of the two common iliac veins, upon the intervertebral substance between the fourth and fifth lum-

\* The veins of the trunk and neck. 1. The superior vena cava. 2. The left vena innominata. 3. The right vena innominata. 4. The right subclavian vein. 5. The internal jugular vein. 6. The external jugular. 7. The anterior jugular. 8. The inferior vena cava. 9. The external iliac vein. 10. The internal iliac vein. 11. The common iliac veins; the small vein between these is the vena sacra media. 12, 12. Lumbar veins. 13. The right spermatic vein. 14. The left spermatic, opening into the left renal vein. 15. The right renal vein. 16. The trunk of the hepatic veins. 17. The greater vena azygos, commencing inferiorly in the lumbar veins. 18. The lesser vena azygos, also commencing in the lumbar veins. 19. A branch of communication with the left renal vein. 20. The termination of the lesser in the greater vena azygos. 21. The superior intercostal vein; communicating inferiorly with the lesser vena azygos, and terminating superiorly in the left vena innominata.

bar vertebra. It ascends along the front of the vertebral column, on the right side of the abdominal aorta, and passing through the fissure in the posterior border of the liver and the quadrilateral opening in the tendinous centre of the diaphragm, terminates in the inferior and posterior part of the right auricle. There are no valves in this vein.

It is in *relation* from below upwards, *in front* with the mesentery, transverse duodenum, portal vein, pancreas, and liver, which latter nearly and sometimes completely surrounds it; *behind* it rests on the vertebral column and right crus of the diaphragm, from which it is separated by the right renal and right lumbar arteries; to the *right* it has the peritoneum and sympathetic nerve; and to the *left* the aorta.

The *Branches* which the inferior cava receives in its course, are the—

Lumbar,  
Right spermatic,  
Renal,  
Supra-renal,  
Phrenic,  
Hepatic.

The *Lumbar veins*, three or four in number on each side, collect the venous blood from the muscles and integument of the loins, and from the spinal veins: the left are longer than the right on account of the position of the vena cava.

The *Right spermatic vein* is formed by the two veins which return the blood from the venous plexus situated in the spermatic cord. These veins follow the course of the spermatic artery, and unite to form the single trunk which opens into the inferior vena cava. The *left spermatic vein* terminates in the left renal vein.

The *Ovarian veins* represent the spermatic veins of the male, and collect the venous blood from the ovaries, round ligaments, and Fallopian tubes, and communicate with the uterine sinuses. They terminate as in the male.

The *Renal or emulgent veins* return the blood from the kidneys; their branches are situated in front of the divisions of the renal arteries, and the left opens into the vena cava somewhat higher than the right. The *left* is longer than the right in consequence of the position of the vena cava, and crosses the aorta immediately below the origin of the superior mesenteric artery. It receives the *left spermatic vein*, which terminates in it at right angles: hence the more frequent occurrence of varicocele on the left than on the right side.

The *Supra-renal veins* terminate partly in the renal veins, and partly in the inferior vena cava.

The *Phrenic veins* return the blood from the ramifications of the phrenic arteries; they open into the inferior cava.

The *Hepatic veins* form two principal trunks and numerous smaller veins which open into the inferior cava, while that vessel is situated in the posterior border of the liver. The hepatic veins commence in the liver by minute venules, the *intralobular veins*, in the centre of each lobule; these pour their blood into larger vessels, the *sublobular veins*; and the sublobular veins constitute, by their convergence and union, the hepatic trunks, which terminate in the inferior vena cava.

## AZYGOS VEINS.

The azygos veins (fig. 165) form a system of communication between the superior and inferior vena cava, and serve to return the blood from that part of the trunk of the body in which those vessels are deficient, on account of their connexion with the heart. This system consists of three vessels, the

Vena azygos major,  
Vena azygos minor,  
Superior intercostal vein.

The *Vena azygos major* commences in the lumbar region by a communication with the lumbar veins; sometimes it is joined by a branch directly from the inferior vena cava, or by one from the renal vein. It passes through the aortic opening in the diaphragm, and ascends along the right side of the vertebral column to the third dorsal vertebra, where it arches forwards over the right bronchus, and terminates in the superior cava. It receives all the intercostal veins of the right side, the vena azygos minor, and the bronchial veins.

The *Vena azygos minor* commences in the lumbar region, on the left side, by a communication with the lumbar or renal veins. It passes beneath the border of the diaphragm, and, ascending along the left side of the vertebral column, crosses the fifth or sixth dorsal vertebra to open into the vena azygos major. It receives the six or seven lower intercostal veins of the left side. The azygos veins have no valves.

The *Superior intercostal vein* is the trunk formed by the union of the five or six upper intercostal veins of the left side. It communicates below with the vena azygos minor, and ascends to terminate in the left vena innominata.

## VERTEBRAL AND SPINAL VEINS.

The numerous venous plexuses of the vertebral column and spinal cord may be arranged into three groups:—

Dorsi-spinal,  
Meningo-rachidian,  
Medulli-spinal,

The *Dorsi-spinal veins* form a plexus around the spinous, transverse and articular processes, and arches of the vertebræ. They receive the returning blood from the dorsal muscles and surrounding structures, and transmit it, in part to the meningo-rachidian, and in part to the vertebral, intercostal, lumbar, and sacral veins.

The *Meningo-rachidian veins* are situated between the theca vertebralis and the vertebræ. They communicate freely with each other by means of a complicated plexus. In front they form two longitudinal trunks, (*longitudinal spinal sinuses*,) which extend the whole length of the column on each side of the posterior common ligament, and are joined on the body of each vertebra by transverse trunks, which pass beneath the ligament, and receive the large basi-vertebral veins from the interior of each vertebra. The meningo-rachidian veins communicate superiorly through the anterior condyloid foramina with the internal jugulars; in the neck they pour their blood into the vertebral veins; in the thorax, into the in-

tercostals; and in the loins and pelvis into the lumbar and sacral veins. the communications being established through the intervertebral foramina.

The *Medullary-spinal veins* are situated between the pia mater and arachnoid; they communicate freely with each other to form plexuses, and they send branches through the intervertebral foramina with each of the spinal nerves, to join the veins of the trunk.

#### CARDIAC VEINS.

The veins returning the blood from the substance of the heart, are the—

Great cardiac vein,  
Posterior cardiac veins,  
Anterior cardiac veins,  
Venæ Thebesii.

The *Great cardiac vein* (coronary) commences at the apex of the heart, and ascends along the anterior ventricular groove to the base of the ventricles; it then curves around the left auriculo-ventricular groove to the posterior part of the heart, where it terminates in the right auricle. It receives in its course the left cardiac veins from the left auricle and ventricle, and the posterior cardiac veins from the posterior ventricular groove.

The *Posterior cardiac vein*, frequently two in number, commences also at the apex of the heart, and ascends along the posterior ventricular groove, to terminate in the great cardiac vein. It receives the veins from the posterior aspect of the two ventricles.

The *Anterior cardiac veins* collect the blood from the anterior surface of the right ventricle; one larger than the rest runs along the right border of the heart and joins the trunk formed by these veins, which curves around the right auriculo-ventricular groove, to terminate in the great cardiac vein near its entrance into the right auricle.

The *Venæ Thebesii* are numerous minute venules which convey the venous blood directly from the substance of the heart into its four cavities. Their existence is denied by some anatomists.

#### PORTAL SYSTEM.

The portal system is composed of four large veins which return the blood from the chylopoietic viscera; they are the—

Inferior mesenteric vein,  
Superior mesenteric vein,  
Splenic vein,  
Gastric veins.

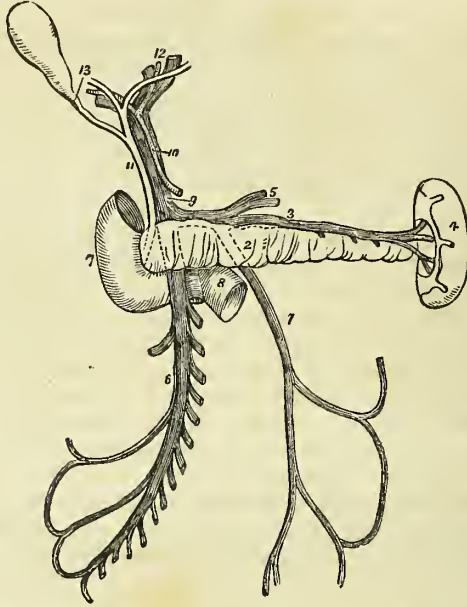
The *Inferior mesenteric vein* receives its blood from the rectum by means of the hæmorrhoidal veins, and from the sigmoid flexure and descending colon, and ascends behind the transverse duodenum and pancreas, to terminate in the splenic vein. Its hæmorrhoidal branches anastomose with branches of the internal iliac vein, and thus establish a communication between the portal and general venous system.

The *Superior mesenteric vein* is formed by branches which collect the venous blood from the capillaries of the superior mesenteric artery; they

constitute by their junction a large trunk, which ascends by the side of the corresponding artery, crosses the transverse duodenum, and unites behind the pancreas with the splenic in the formation of the portal vein.

The *Splenic vein* commences in the structure of the spleen, and quits that organ by several large veins: it is larger than the splenic artery, and

Fig. 166.\*



perfectly straight in its course. It passes horizontally inwards behind the pancreas, and terminates near its greater end by uniting with the superior mesenteric, and forming the portal vein. It receives in its course the gastric and pancreatic veins, and near its termination the inferior mesenteric vein.

The *Gastric veins* correspond with the gastric, gastro-epiploic, and vasa brevia arteries, and terminate in the splenic vein.

The *VENA PORTÆ*, formed by the union of the splenic and superior mesenteric vein behind the pancreas, ascends through the right border of the lesser omentum to the transverse fissure of the liver, where it divides into two branches, one for each lateral lobe. In the right border of the lesser omentum it is situated behind and between the hepatic artery and ductus communis choledochus, and is surrounded by the hepatic plexus of nerves and lymphatics. At the transverse fissure each primary branch divides into numerous secondary branches, which ramify through the

\* The portal vein. 1. The inferior mesenteric vein; it is traced by means of dotted lines behind the pancreas (2) to terminate in the splenic vein (3). 4. The spleen. 5. Gastric veins, opening into the splenic vein. 6. The superior mesenteric vein. 7. The descending portion of the duodenum. 8. Its transverse portion, which is crossed by the superior mesenteric vein and by a part of the trunk of the superior mesenteric artery. 9. The portal vein. 10. The hepatic artery. 11. The ductus communis choledochus. 12. The division of the duct and vessels at the transverse fissure of the liver. 13. The cystic duct leading to the gall bladder.



portal canals, and give off vaginal and interlobular veins, and the latter terminate in the lobular venous plexus of the lobules of the liver. The portal vein within the liver receives the venous blood from the capillaries of the hepatic artery.

#### PULMONARY VEINS.

The pulmonary veins, four in number, return the arterial blood from the lungs to the left auricle of the heart; they differ from the veins in general, in the area of their cylinders being very little larger than that of the corresponding arteries, and in accompanying singly each branch of the pulmonary artery. They commence in the capillaries upon the parietes of the intercellular passages and air-cells, and unite to form a single trunk for each lobe. The vein of the middle lobe of the right lung unites with the superior vein, so as to form the two trunks which open into the left auricle. Sometimes they remain separate, and then there are three pulmonary veins on the right side. The right pulmonary veins pass behind the superior vena cava to the left auricle, and the left behind the pulmonary artery; they both pierce the pericardium. Within the lung the branches of the pulmonary veins are behind the bronchial tubes, and those of the pulmonary artery in front; but at the root of the lungs the veins are in front, next the arteries, and then the bronchi. There are no valves in the pulmonary veins.

---

## CHAPTER VIII.

### ON THE LYMPHATICS.

THE lymphatic vessels, or absorbents, have received their double appellation from certain phenomena which they present; the former name being derivable from the appearance of the limpid fluid (*lympha*, water) which they convey; and the latter from their supposed property of absorbing foreign substances into the system. They are minute, delicate, and transparent vessels, remarkable for their general uniformity of size, for a knotted appearance which is due to the presence of numerous valves, for the frequent dichotomous divisions which occur in their course, and for their division into several branches immediately before entering a gland. Their office is to collect the products of digestion and the detrita of nutrition, and convey them into the venous circulation near the heart.

Lymphatic vessels commence in a delicate network which is distributed on the cutaneous surface of the body, on the various surfaces of organs and throughout their internal structure; and from this network the lymphatic vessels proceed, nearly in straight lines, in a direction towards the root of the neck. In their course they are intercepted by numerous small, spheroid, or oblong, or flattened bodies, *lymphatic glands*. The lymphatic vessels entering these glands are termed *vasa inferentia* or *afferentia*, and those which quit them, *vasa efferentia*. The *vasa inferentia* vary in number from two to six, they divide at the distance of a few lines from the gland into several smaller vessels, and enter it by one of the flattened sur-

faces.\* The vasa efferentia escape from the gland on the opposite, but not unfrequently on the same surface; they consist, like the vasa inferentia at their junction with the gland, of several small vessels which unite after a course of a few lines to form from one to three trunks, often twice as large as the vasa inferentia.

Lymphatic vessels admit of a threefold division, into superficial, deep, and lacteals. The *superficial lymphatic vessels*, on the surface of the body, follow the course of the veins, and pierce the deep fascia in convenient situations, to join the deep lymphatics. On the surface of organs they converge to the nearest lymphatic trunks. The *superficial lymphatic glands* are placed in the most protected situations of the superficial fascia, as in the hollow of the ham and groin in the lower extremity, and on the inner side of the arm in the upper extremity.

The *deep lymphatics*, fewer in number and somewhat larger than the superficial vessels, accompany the deeper veins; those from the lower parts of the body converging to the numerous glands seated around the iliac veins and inferior vena cava, and terminating in a large trunk situated on the vertebral column, the thoracic duct. From the upper part of the trunk of the body on the left side, and from the left side of the head and neck, they also proceed to the thoracic duct. Those on the right side of the head and neck, right upper extremity, and right side of the thorax, form a distinct duct which terminates at the point of junction of the subclavian with the internal jugular vein on the right side of the root of the neck.

The *lacteals* are the lymphatic vessels of the small intestines; they have received their distinctive appellation from conveying the milk-like product of digestion, the chyle, to the great centre of the lymphatic system, the thoracic duct. They are situated in the mesentery, and pass through the numerous mesenteric glands in their course.

Lymphatic vessels are very generally distributed through the animal tissues; there are, nevertheless, certain structures in which they have never been detected; for example, the brain and spinal cord, the eye, bones, cartilages, tendons, the membranes of the ovum, the umbilical cord, and the placenta. The anastomoses between these vessels are less frequent than between arteries and veins; they are effected by means of vessels of equal size with the vessels which they connect, and no increase of calibre results from their junction. The lymphatic vessels are smallest in the neck, larger in the upper extremities, and larger still in the lower limbs.

For the purpose of effecting the movement of their fluids in a proper direction, lymphatic vessels are furnished with valves, and it is to these that the appearance of constrictions around the cylinders of the vessels, at short distances, is due. Like the valves of veins, the valves of lymphatic vessels are each composed of two semilunar flaps attached by their convex border to the sides of the vessel and free by their concave border. This is the general character of the valves, but, as in veins, there are exceptions in their form and disposition; sometimes one flap is so small as to be merely rudimentary, while the other is large in proportion; sometimes the flap runs all the way round the tube, leaving a central aperture which can only be closed by a contractile power in the valve itself; and some-

\* See Mr. Lane's article on the "Lymphatic System," in the Cyclopædia of Anatomy and Physiology.

times instead of being circular the aperture is elliptical, and the arrangement of the flaps like that of the ileo-cæcal valve.\* These peculiarities are most frequently met with at and near the anastomoses of the lymphatic vessels. The valves occur most numerous near the lymphatic glands; next in frequency they are found in the neck and upper extremities, where the vessels are small, and least numerous in the lower limbs, where the lymphatics are larger. In the thoracic duct an interspace of two or three inches frequently occurs between the valves. Connected with the presence of valves in the lymphatic vessels, are two lateral dilatations or pouches, analogous to the valvular *sinuses* of veins. These sinuses are situated on the cardiac side of the valves; they receive the valves when the latter are thrown back by the current of the lymph; and when reflux occurs, they become distended with a body of fluid which makes pressure on the flaps. These pouch-like dilatations and the constrictions corresponding with the line of attachment of the convex borders of the flaps are the cause of the knotted appearance of distended lymphatic vessels.

Like arteries and veins, lymphatic vessels are composed of three coats, external, middle, and internal. The *external coat* is areolo-fibrous, like that of blood-vessels; it is thin, but very strong, and serves to connect the vessel to surrounding tissues, at the same time that it forms a protective covering. The *middle coat* is thin and elastic, and consists of a layer of longitudinal fibres analogous to those of the innermost layer of the middle coat of arteries and veins. Some few circular fibres may be seen externally to these in the larger lymphatic vessels. The *internal coat* is inelastic and more liable to rupture than the other coats. It is a serous layer continuous with the lining membrane of the veins, and invested by an epithelium. The valves are composed of a very thin layer of fibrous tissue, coated on its two surfaces by epithelium.

The lymphatic glands (conglobate, absorbent) are small oval and somewhat flattened or rounded bodies, composed of a plexus of minute lymphatic vessels, associated with a plexus of blood-vessels, and enclosed in a thin capsule of areolar tissue. When examined on the surface, they are seen to have a lobulated appearance, while the face of a section is cellular, from the division of the numberless convolutions which are formed by the lymphatic vessels within its substance. The colour of the glands is a pale pink, excepting those of the lungs, the bronchial glands, which in the adult are more or less mottled with black, and are sometimes filled with a black pigment. Lymphatic glands are larger in the young subject than in the adult, and are smallest in old age; they, as well as their vessels, are supplied with arteries, veins and nerves, like other structures.

I shall describe the lymphatic vessels and glands according to the arrangement adopted for the veins, commencing with those of the head and neck, and proceeding next to those of the upper extremity, lower extremity, and trunk.

#### LYMPHATICS OF THE HEAD AND NECK.

The *Superficial lymphatic glands of the head and face* are small, few in number, and isolated; they are, the *occipital*, which are situated near the origin of the occipito-frontalis muscle; *posterior auricular*, behind the ear; *parotid*, in the parotid gland; *zygomatic*, in the zygomatic fossa,

\* Mr. Lane, loc. cit.

*buccal*, upon the buccinator muscle; and *submaxillary*, beneath the margin of the lower jaw. There are no deep lymphatic glands within the cranium.

The *Superficial cervical lymphatic glands* are few in number and small; they are situated in the course of the external jugular vein, between the sterno-mastoid and trapezius muscles, at the root of the neck, and about the larynx.

The *Deep cervical glands* (*glandulæ concatenatæ*) are numerous and of large size; they are situated around the internal jugular vein and sheath of the carotid arteries, by the side of the pharynx, œsophagus, and trachea, and extend from the base of the skull to the root of the neck, where they are in communication with the lymphatic vessels and glands of the thorax.

The *Superficial lymphatic vessels of the head and face* are disposed in three groups; *occipital*, which take the course of the occipital vein to the occipital and deep cervical glands; *temporal*, which follow the branches of the temporal vein to the parotid and deep cervical glands; and *facial*, which accompany the facial vein to the submaxillary lymphatic glands.

The *Deep lymphatic vessels of the head* are the *meningeal* and *cerebral*, the former are situated in connexion with the meningeal veins, and escape through foramina at the base of the skull, to join the deep cervical glands. The *cerebral lymphatics*, according to Fohmann, are situated on the surface of the pia mater, none having as yet been discovered in the substance of the brain. They pass most probably through the foramina at the base of the skull, to terminate in the deep cervical glands.

The *Deep lymphatic vessels of the face* proceed from the nasal fossæ, mouth, and pharynx, and terminate in the submaxillary and deep cervical glands.

The *Superficial and deep cervical lymphatic vessels* accompany the jugular veins, passing from gland to gland, and at the root of the neck communicate with the thoracic lymphatic vessels, and terminate, on the right side, in the ductus lymphaticus dexter, and, on the left, in the thoracic duct, near its termination.

#### LYMPHATICS OF THE UPPER EXTREMITY.

The *uperficial lymphatic glands* of the arm are not more than four or five in number, and of very small size. One or two are situated near the median basilic and cephalic veins, at the bend of the elbow; and one or two near the basilic vein, on the inner side of the upper arm, immediately above the elbow.

The *Deep glands* in the fore-arm are excessively small and infrequent; two or three may generally be found in the course of the radial and ulnar vessels. In the upper arm there is a chain of small glands, accompanying the brachial artery.

The *Axillary glands* are numerous and of large size. Some are closely adherent to the vessels, others are dispersed in the loose areolar tissue of the axilla, and a small chain may be observed extending along the lower border of the pectoralis major to the mammary gland. Two or three subclavian glands are situated beneath the clavicle, and serve as the medium of communication between the axillary and deep cervical lymphatic glands.

The *Superficial lymphatic vessels* of the upper extremity commence upon the fingers and take their course along the fore-arm to the bend of the

elbow. The greater part reach their destination by passing along the dorsal surface of the fingers, wrist, and fore-arm, and then curving around the borders of the latter; but some few are met with in the palm of the hand, which take the direction of the median vein. At the bend of the elbow the lymphatics arrange themselves into two groups; an internal and larger group, which communicates with a gland situated just above the inner condyle, and then accompanies the basilic vein upwards to the axilla to enter the axillary glands; and a small group which follows the course of the cephalic vein. Several of the vessels of this group cross the biceps muscle at its upper part to enter the axillary glands, while the remainder, two or three in number, ascend with the cephalic vein in the interspace of the deltoid and pectoralis major; these latter usually join a small gland in this space, and then cross the pectoralis minor muscle to become continuous with the subclavian lymphatics.

Besides the lymphatic vessels of the arm, the axillary glands receive those from the integument of the chest, its anterior, posterior, and lateral aspect, and the lymphatics of the mammary gland.

The *Deep lymphatics* accompany the vessels of the upper extremity, and communicate occasionally with the superficial lymphatics. They enter the axillary and subclavian glands, and, at the root of the neck terminate on the left side in the thoracic duct, and on the right side in the ductus lymphaticus dexter.

#### LYMPHATICS OF THE LOWER EXTREMITY.

The *Superficial lymphatic glands* of the lower extremity are those of the groin, the *inguinal*; and one or two situated in the superficial fascia of the posterior aspect of the thigh, just above the popliteal region.

The *Inguinal glands* are divisible into two groups; a superior group of small size, situated along the course of Poupart's ligament, and receiving the lymphatic vessels from the parietes of the abdomen, gluteal region, perineum, and genital organs; and an inferior group of larger glands clustered around the internal saphenous vein near its termination, and receiving the superficial lymphatic vessels from the lower extremity.

The *Deep lymphatic glands* are the *anterior tibial*, *popliteal*, *deep inguinal*, *gluteal*, and *ischiatric*.

The *Anterior tibial* is generally a single gland, placed on the interosseous membrane, by the side of the anterior tibial artery in the upper part of its course.

The *Popliteal glands*, four or five in number and small, are embedded in the loose areolar tissue and fat of the popliteal space.

The *Deep inguinal glands*, less numerous and smaller than the superficial, are situated near the femoral vessels in the groin, beneath the fascia lata.

The *Gluteal* and *ischiatric glands* are placed near the vessels of that name, above and below the pyriformis muscle at the great ischiatic foramen.

The *Superficial lymphatic vessels* are divisible into two groups, internal and external; the *internal* and principal group, commencing on the dorsum and inner side of the foot, ascend the leg by the side of the internal saphenous vein, and passing behind the inner condyle of the femur, follow the direction of that vein to the groin, where they join the saphenous group of superficial inguinal glands. The greater part of the efferent vessels from

these glands pierce the cribriform fascia of the saphenous opening and the sheath of the femoral vessels, to join the lymphatic gland situated in the femoral ring, which serves to establish a communication between the lymphatics of the lower extremity and those of the trunk. The other efferent vessels pierce the fascia lata to join the deep glands. The vessels which pass upwards from the outer side of the dorsum of the foot, ascend along the outer side of the leg, and curve inwards just below the knee, to unite with the lymphatics of the inner side of the thigh. The *external group* consists of a few lymphatic vessels which commence on the outer side of the foot and posterior part of the ankle, and accompany the external saphenous vein to the popliteal region, where they enter the popliteal glands.

The *Deep lymphatic vessels* accompany the deep veins, and communicate with the various glands in their course. After joining the deep inguinal glands they pass beneath Poupart's ligament, to communicate with the numerous glands situated around the iliac vessels. The deep lymphatics of the gluteal region follow the course of the branches of the gluteal and ischiatic arteries. The former join the glands situated on the upper border of the pyriformis muscle, and the latter, after communicating with the lymphatics of the thigh, enter the ischiatic glands.

#### LYMPHATICS OF THE TRUNK.

The lymphatics of the trunk may be arranged under three heads, superficial, deep, and visceral.

The *Superficial lymphatic vessels* of the upper half of the trunk pass upwards and outwards on each side, and converge, some to the axillary glands, and others to the glands at the root of the neck. The lymphatics from the mammary glands follow the lower border of the pectoralis major, communicating, by means of a chain of lymphatic glands, with the axillary glands. The superficial lymphatic vessels of the lower half of the trunk, of the gluteal region, perineum, and external organs of generation, converge to the superior group of superficial inguinal glands. Some small glands are situated on each side of the dorsal vein of the penis, near the suspensory ligament; from these, as from the superficial lymphatics, the efferent vessels pass into the superior group of superficial inguinal glands.

The *Deep lymphatic glands of the thorax* are the intercostal, internal mammary, anterior mediastinal, and posterior mediastinal.

The *Intercostal glands* are of small size, and are situated on each side of the vertebral column, near the articulations of the heads of the ribs, and in the course of the intercostal arteries.

The *Internal mammary glands*, also very small, are placed in the intercostal spaces, by the side of the internal mammary arteries.

The *Anterior mediastinal glands* occupy the loose areolar tissue of the anterior mediastinum, resting some on the diaphragm, but the greater number on the large vessels at the root of the heart.

The *Posterior mediastinal glands* are situated along the course of the aorta and œsophagus in the posterior mediastinum, and communicate above with the deep cervical glands, on each side with the intercostal and below with the abdominal glands.

The *Deep lymphatic vessels of the thorax* are the intercostal, internal mammary, and diaphragmatic.

The *Intercostal* lymphatic vessels follow the course of the arteries of the same name; and reaching the vertebral column curve downwards, to terminate in the thoracic duct.

The *Internal mammary* lymphatics commence in the parieties of the abdomen, communicating with the epigastric lymphatics. They ascend by the side of the internal mammary vessels, being joined in their course by the anterior intercostals, and terminate at the root of the neck, on the right side in the tributaries of the ductus lymphaticus dexter, and on the left in the thoracic duct. The *diaphragmatic* lymphatics pursue the direction of their corresponding veins, and terminate some *in front* in the internal mammary vessels, and some *behind*, in the posterior mediastinal lymphatics.

The *Deep lymphatic glands of the abdomen* are the lumbar glands; they are very numerous, and are seated around the common iliac vessels, the aorta and vena cava.

The deep lymphatic glands of the pelvis are the external iliac, internal iliac and sacral.

The *External iliac* are placed around the external iliac vessels, being in continuation by one extremity with the femoral lymphatics, and by the other with the lumbar glands.

The *Internal iliac* glands are situated in the course of the internal iliac vessels, and the *sacral* glands are supported by the concave surface of the sacrum.

The *Deep lymphatic vessels* are continued upwards from the thigh, beneath Poupart's ligament, and along the external iliac vessels to the lumbar glands, receiving in their course the epigastric, circumflexa ilii, and ilio-lumbar lymphatic vessels. Those from the parietes of the pelvis, and from the gluteal, ischiatic, and obturator vessels, follow the course of the internal iliac arteries, and unite with the lumbar lymphatics. And the lumbar lymphatic vessels, after receiving all the lymphatics from the lower extremities, pelvis, and loins, terminate by several large trunks in the receptaculum chyli.

#### LYMPHATICS OF THE VISCERA.

The *Lymphatic vessels of the lungs* are of large size, and are distributed over every part of the surface, and through the texture of these organs; they converge to the numerous glands situated around the bifurcation of the trachea and roots of the lungs, the bronchial glands. Some of these glands of small size, may be traced in connexion with the bronchial tubes for some distance into the lungs. The efferent vessels from the bronchial glands unite with the tracheal and œsophageal glands, and terminate principally in the thoracic duct at the root of the neck, and partly in the ductus lymphaticus dexter. The *bronchial glands*, in the adult, present a variable tint of brown, and in old age a deep black colour. In infancy they have none of this pigment, and are not to be distinguished from lymphatic glands in other situations.

The *Lymphatic vessels of the heart* originate in the subserous areolar tissue of the surface, and in the deeper tissues of the organ, and follow the course of the vessels, principally, along the right border of the heart to the glands situated around the arch of the aorta and to the bronchial

glands, whence they proceed to the root of the neck, and terminate in the thoracic duct.

The *Pericardiac* and *thymic* lymphatic vessels proceed to join the anterior mediastinal and bronchial glands.

The *Lymphatic vessels of the liver* are divisible into the deep and superficial. The former take their course through the portal canals, and through the right border of the lesser omentum, to the lymphatic glands situated in the course of the hepatic artery and along the lesser curve of the stomach. The *superficial* lymphatics are situated in the areolar structure of the proper capsule, over the whole surface of the liver. Those of the convex surface are divided into two sets;—1. Those which pass from before backwards; 2. Those which advance from behind forwards. The former unite to form trunks, which enter between the folds of the lateral ligaments at the right and left extremities of the organ, and of the coronary ligament in the middle. Some of these pierce the diaphragm and join the posterior mediastinal glands; others converge to the lymphatic glands situated around the inferior cava. Those which pass from behind forwards consist of two groups: one ascends between the folds of the broad ligament, and perforates the diaphragm, to terminate in the anterior mediastinal glands; the other curves around the anterior margin of the liver to its concave surface, and from thence to the glands in the right border of the lesser omentum. The lymphatic vessels of the concave surface are variously distributed, according to their position; those from the right lobe terminate in the lumbar glands; those from the gall-bladder, which are large and form a remarkable plexus, enter the glands in the right border of the lesser omentum; and those from the left lobe converge to the lymphatic glands situated along the lesser curve of the stomach.

The *Lymphatic glands of the spleen* are situated around its hilus, and those of the *pancreas* in the course of the splenic vein. The *lymphatic vessels* of these organs pass through their respective glands, and join the aortic glands, previously to terminating in the thoracic duct.

The *Lymphatic glands of the stomach* are of small size, and are situated along the lesser and greater curves of that organ. The *lymphatic vessels*, as in other viscera, are superficial and deep, the former originating in the subserous and the latter in the submucous tissue; they pass from the stomach in four different directions: some ascend to the glands, situated along the lesser curve, others descend to those occupying the greater curve, a third set pass outwards to the splenic glands, and a fourth to the glands situated near the pylorus and to the aortic glands.

The *Lymphatic glands of the small intestine* are situated between the layers of the mesentery, in the meshes formed by the superior mesenteric artery, and are thence named *mesenteric glands*. These glands are most numerous and largest, superiorly, near the duodenum; and, inferiorly, near the termination of the ileum.

The *Lymphatic vessels* of the small intestines are of two kinds: those of the structure of the intestines, which run upon its surface previously to entering the mesenteric glands; and those which commence in the villi, in the substance of the mucous membrane, and are named lacteals.

The *Lacteals*, according to Henle, commence in the centre of each villus as a cæcal tubulus, which opens into a fine network, situated in the



sub-mucous tissue. From this areolar network the lacteal vessels proceed to the mesenteric glands, and from thence to the thoracic duct, in which they terminate.

The *Lymphatic glands of the large intestines* are situated along the attached margin of the intestine, in the meshes formed by the colic and hæmorrhoidal arteries previously to their distribution. The *lymphatic vessels* take their course in two different directions; those of the cæcum, ascending and transverse colon, after traversing their proper glands, proceed to the mesenteric, and those of the descending colon and rectum to the lumbar glands.

The *Lymphatic vessels of the kidney* follow the direction of the blood-vessels to the lumbar glands situated around the aorta and inferior vena cava; those of the supra-renal capsules, which are very large and numerous, terminate in the real lymphatics.

The *Lymphatic vessels of the viscera of the pelvis* terminate in the sacral and lumbar glands.

The *Lymphatic vessels of the testicle* take the course of the spermatic cord in which they are of large size; they terminate in the lumbar glands.

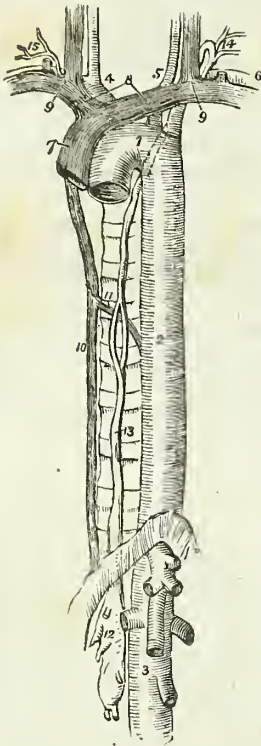
## THORACIC DUCT.

The thoracic duct\* commences in the abdomen, by a considerable and somewhat triangular dilatation, the *receptaculum chyli*, which is situated on the front of the body of the second lumbar vertebra, behind and between the aorta and inferior vena cava, and close to the tendon of the right crus of the diaphragm. From the upper part of the receptaculum chyli the thoracic duct ascends through the aortic opening of the diaphragm, and along the front of the vertebral column, lying between the thoracic aorta and vena azygos, to the fourth dorsal vertebra. It then inclines to the left side, passes behind the arch of the aorta, and ascends by the side of the œsophagus and behind the perpendicular portion of the left subclavian artery to the root of the neck opposite the seventh cervical vertebra, where it makes a sudden curve forwards and downwards, and terminates at the point of junction of the left subclavian with the left internal jugular vein.

The thoracic duct is equal in size to the diameter of a goose-quill at its commencement from the receptaculum chyli, diminishes considerably in diameter towards the middle of the posterior mediastinum, and again becomes dilated near its termination. At about the middle of the thorax it frequently divides into two branches of equal size, which reunite after a short course; and sometimes it gives off several branches, which assume a plexiform arrangement in this situation. Occasionally the thoracic duct bifurcates at the upper part of the thorax into two branches, one of which opens into the point of junction between the right subclavian and jugular veins, while the other proceeds to the normal termination of the duct on the left side. In rare instances the duct has been found to terminate in the vena azygos, which is its normal destination in some Mammalia.

\* The thoracic duct was discovered by Eustachius, in 1563, in the horse: he regarded it as a vein, and called it the vena alba thoracis. The lacteals were first seen by Asellius in 1622, in the dog; and within the next ten years by Veslingius in man.

Fig. 167.\*



The thoracic duct presents fewer valves in its course than lymphatic vessels generally; at its termination it is provided with a pair of semilunar valves, which prevent the admission of venous blood into its cylinder.

*Branches.*—The thoracic duct receives at its commencement four or five large lymphatic trunks, which unite to form the receptaculum chyli: it next receives the trunks of the lacteal vessels. Within the thorax it is joined by a large lymphatic trunk from the liver, and in its course through the posterior mediastinum, receives the lymphatic vessels both from the viscera and from the parietes of the thorax. At its curve forwards in the neck it is joined by the lymphatic trunks from the left side of the head and neck, left upper extremity, and from the upper part of the thorax, and thoracic viscera.

The *Ductus lymphaticus dexter* is a short trunk which receives the lymphatic vessels from the right side of the head and neck, right upper extremity, right side of the thorax, right lung, and one or two branches from the liver, and terminates at the junction of the right subclavian with the right internal jugular vein, at the point where these veins unite to form the right vena innominata. It is provided at its termination with a pair of semilunar valves, which prevent the entrance of blood from the veins.

\* The course and termination of the thoracic duct. 1. The arch of the aorta. 2. The thoracic aorta. 3. The abdominal aorta; showing its principal branches divided near their origin. 4. The arteria innominata, dividing into the right carotid and right subclavian arteries. 5. The left carotid. 6. The left subclavian. 7. The superior cava, formed by the union of 8, the two venæ innominatæ; and these by the junction 9, of the internal jugular and subclavian vein at each side. 10. The greater vena azygos. 11. The termination of the lesser in the greater vena azygos. 12. The receptaculum chyli; several lymphatic trunks are seen opening into it. 13. The thoracic duct, dividing opposite the middle of the dorsal vertebræ into two branches which soon reunite; the course of the duct behind the arch of the aorta and left subclavian artery is shown by a dotted line. 14. The duct, making its turn at the root of the neck and receiving several lymphatic trunks previously to terminating in the posterior aspect of the junction of the internal jugular and subclavian vein. 15. The termination of the trunk of the ductus lymphaticus dexter.

## CHAPTER IX.

## ON THE NERVOUS SYSTEM.

THE nervous system consists of a central organ, the cerebro-spinal centre or axis, and of numerous rounded and flattened white cords, the nerves, which are connected by one extremity with the cerebro-spinal centre, and by the other are distributed to all the textures of the body. The sympathetic system is an exception to this description; for in place of one it has many small centres which are called ganglia, and which communicate very freely with the cerebro-spinal axis and with its nerves.

The cerebro-spinal axis consists of two portions, the brain, an organ of large size, situated within the skull, and the spinal cord, a lengthened portion of the nervous centre continuous with the brain and occupying the canal of the vertebral column.

The most superficial examination of the brain, and spinal cord shows them to be composed of fibres, or rather fasciculi, which in some situations are ranged in a longitudinal direction, and in others are interlaced at various angles by cross fibres. The fasciculi are connected and held together by a delicate areolar web, which forms the bond of support to the entire organ. It is also observed that the cerebro-spinal axis presents two substances differing from each other in density and colour: a grey or cineritious or cortical substance, and a white or medullary substance. The *grey substance* forms a thin lamella over the entire surface of the convolutions of the cerebrum, and of the laminæ of the cerebellum: hence it has been named cortical; but the grey substance is not confined to the surface of the brain, as this term would imply; it is likewise situated in the centre of the spinal cord its entire length, and may be thence traced through the medulla oblongata, crura cerebri, thalami optici, and corpora striata; it enters also into the composition of the locus perforatus, tuber cinereum, commissura mollis, pineal gland, pituitary gland, and corpora rhomboidea.

Two kinds of grey substance are described by Rolando as existing in the spinal cord; the one (*substantia cinerea spongiosa vasculosa*) is the ordinary grey matter of the cord, and the other (*substantia cinerea gelatinosa*) forms part of the posterior cornua. The former resembles in structure the grey matter of the brain, while the latter is composed of small bodies resembling the blood corpuscles of the frog.

The fibres of the cerebro-spinal axis are arranged into two classes, *diverging* and *converging*. The diverging fibres proceed from the medulla oblongata, and diverge to every part of the surface of the brain; while the converging fibres commence at the surface and proceed inwards towards the centre, so as to connect the diverging fibres of opposite sides. In certain parts of their course the diverging fibres are separated by the grey substance, and increase in number so as to form a body of considerable size, which is called a ganglion. The position and mutual relations of these fibres and ganglia may be best explained by reference to the mode of development of the cerebro-spinal axis in animals and in man.

The centre of the nervous system, in the lowest animals possessed of a

lengthened axis, presents itself in the form of a double cord. A step higher in the animal scale, and knots or *ganglia* are developed on one extremity of this cord; such is the most rudimentary condition of the brain in the lowest forms of vertebrata. In the lowest fishes the anterior extremity of the double cord displays a succession of five pairs of ganglia. The higher fishes and amphibia appear to have a different disposition of these primitive ganglia. The first two have become fused into a single ganglion, and then follow only three pairs of symmetrical ganglia. But if the larger pair be unfolded, after being hardened in alcohol, it will then be seen that the whole number of ganglia exist, but that four have become concealed by a thin covering that has spread across them. This condition of the brain carries us upwards in the animal scale even to Mammalia, *e. g.*, in the dog or cat we find, first, a single ganglion, the cerebellum; then three pairs following each other in succession; and if we unfold the middle pair, we shall be at once convinced that it is composed of two pairs of primitive ganglia concealed by an additional development. Again, it will be observed, that the primitive ganglia of opposite sides, at first separate and disjointed, become connected by means of transverse fibres of communication (*commissures*; *commissura*, a joining). The office of these commissures is the association in function of the two symmetrical portions. Hence we arrive at the general and important conclusion, that the brain, among the lower animals, consists of *primitive cords*, *primitive ganglia* upon those cords, and *commissurés* which connect the substance of adjoining ganglia, and associate their functions.

In the development of the cerebro-spinal axis in man, the earliest indication of the spinal cord is presented under the form of a pair of minute longitudinal filaments placed side by side. Upon these, towards the anterior extremity, five pairs of minute swellings are observed, not disposed in a straight line as in fishes, but curved upon each other so as to correspond with the direction of the future cranium. The posterior pair soon become cemented on the middle line, forming a single ganglion; the second pair also unite with each other; the third and fourth pairs, at first distinct, are speedily veiled by a lateral development, which arches backwards and conceals them; the anterior pair, at first very small, decrease in size, and become almost lost in the increased development of the preceding pairs.

We see here a chain of resemblances corresponding with the progressive development observed in the lower animals; the human brain is passing through the phases of improving development, which distinguish the lowest from the lower creatures: and we are naturally led to the same conclusion with regard to the architecture of the human brain that we were led to establish as the principle of development in the inferior creatures, namely, that it is composed of *primitive cords*, *primitive ganglia* upon those cords, *commissures* to connect those ganglia, and *developments* from those ganglia.

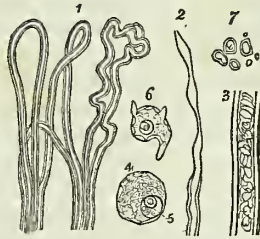
In the adult, the *primitive longitudinal cords* have become cemented together, to form the *spinal cord*. But, at the upper extremity, they separate from each other under the name of *crura cerebri*. The *first pair of ganglia*, developed from the primitive cords, have grown into the *cerebellum*; the *second pair* (the optic lobes of animals) have become the *corpora quadrigemina* of man. The *third pair*, the *optic thalami*, and the *fourth*, the *corpora striata*, are the *basis of the hemispheres*, which, the

merest lamina in the fish, have become the largest portion of the brain in man. And the *fifth pair* (olfactory lobes), so large in the lowest forms, have dwindled into the *olfactory bulbs* of man.

The microscopic elements of the nervous system, are, white nerve-fibres, grey nerve-fibres, nerve-cells, and nerve-granules.

1. WHITE NERVE FIBRES are the chief constituent of the brain, the spinal cord, and the cerebro-spinal nerves, and they also enter into the composition of the sympathetic nerve. They present some variety of size in different parts of the nervous system, measuring in the brain between  $\frac{5}{1000}$  and  $\frac{1}{14000}$  of an inch in diameter, and in the cerebro-spinal nerves between  $\frac{2}{1000}$  and  $\frac{1}{3000}$  of an inch. As a general rule, the white nerve-fibres are largest in the nerves, smaller where they enter the cerebro-spinal mass, and smallest at their termination,

Fig. 168.\*



centrally, in the grey substance of the surface of the brain, and, peripherally, in the tissues of the body. In structure, each white nerve-fibre is composed of a transparent and structureless cylindrical tubule or sheath (*vagina medullaris*), and of an axis-cylinder filled with an opalescent, colourless, oil-like fluid (*neurine*), which coagulates after death, and then resembles a white, opaque, and curd-like matter. The *vagina medullaris* possesses somewhat less than one-third the thickness of the entire fibre, and gives to the latter, when examined with the microscope, the aspect of a double cylinder,—an appearance which is characteristic of the white nerve-fibre. It is thickest in the fibres of the spinal nerves, and thinnest in those of the spinal cord, brain, and nerves of special sense. Hence in these latter, the sheath, when pressed or stretched, is apt to assume a varicose appearance, and the contained substance to accumulate in small separate masses. White nerve-fibres terminate, both at the surface of the body, in the various internal organs, and in the substance of the cerebro-spinal axis, by forming loops.

2. GREY NERVE FIBRES (fine nerve-fibres, gelatinous fibres, sympathetic fibres) are about one-half or one-third less in diameter ( $\frac{3}{750}$  to  $\frac{1}{6600}$  of an inch, Henle) than the white fibres. They are less transparent, have no appearance of being composed of a double cylinder, and their sheath is less easily distinguishable from its contents. In structure, they consist of a thin and finely granulated sheath, filled with granular substance, and, when collected into a fasciculus, have a yellowish grey tint. The grey nerve-fibres are abundant in, and are indeed the chief constituent of, the sympathetic system. They are also present in the cerebro-spinal nerves, and, most numerous, in the nerves of sensation. They take their origin from the nerve-cells of the grey substance of the brain and spinal cord,

\* Minute structure of nerve. 1. The mode of termination of white nerve-fibres in loops; three of these loops are simple, the fourth is convoluted. The latter is found in situations where an exalted degree of sensation exists. 2. A white nerve-fibre from the brain, showing the varicose appearance produced by traction or pressure. 3. A white nerve-fibre enlarged to show its structure,—namely, a tubular envelope, and a contained substance, *neurine*. 4. A nerve-cell, showing its composition of a granular-looking capsule and granular contents. 5. Its nucleus containing a nucleolus. 6. A nerve-cell from which several processes are given off. It contains, like the preceding, a nucleolated nucleus. 7. Nerve-granules.

from those of the ganglia on the posterior roots of the cerebro-spinal nerves, and from the nerve-cells of the ganglia of the sympathetic system.

3. The NERVE-CELLS are spherical or oval, or polyhedral in shape, of a reddish grey colour, and between  $\frac{1}{300}$  and  $\frac{1}{1250}$  of an inch in diameter. Each cell is composed of a capsular sheath, and contains in its interior a reddish-grey granular substance, and one or more nuclei and nucleoli, the nucleus being attached to the internal surface of the sheath. The sheath of the nerve-cell is constructed of three layers, the outermost consisting of fine granular corpuscles, the middle of nucleated cells of an oblong figure, and the internal of concentric lamellæ of delicate cylindrical filaments. Dispersed through the substance of the cell are a greater or less number of pigment-granules, some being in the interior, and some in the sheath. Nerve-cells are found in the grey substance of the brain and spinal cord, in the ganglia of the cerebro-spinal nerves, and in the sympathetic ganglia and nerves. The nerve-cells of the grey substance of the brain are often very irregular in shape, and they are also remarkable for their softness and for the thinness of their sheath. It is the pigment-granules, contained in the nerve-cells and nerve-granules, that give the peculiar tint of colour to the grey and dark substance of the cerebro-spinal axis.

In the grey substance of the brain the nerve-cells may be seen in various stages of progressive development; thus, near the periphery, they are minute, spherical or oval, nucleated cells dispersed through a matrix of granular substance; more deeply, the granular substance is collected around the cells, and forms an exterior coat; while, at a greater depth, the cells have attained the size and the laminated sheaths of the fully formed nerve-cells. Nerve-cells offer many peculiarities in respect of number and arrangement in different parts of the nervous system.

From the periphery of the nerve-cells one or more delicate thread-like processes, between  $\frac{1}{7000}$  and  $\frac{1}{10000}$  of an inch in diameter, are given off. These are the origins of the grey nerve-fibres.

4. NERVE GRANULES present the three forms of, minute homogeneous particles, aggregated particles, and nucleated corpuscles, varying in size between  $\frac{1}{5000}$  and  $\frac{1}{15000}$  of an inch in diameter. They serve as the bond of connexion between the fibres and cells of the brain and spinal cord, particularly in the grey substance; and enter also into the composition of the various ganglia. Like nerve-cells, nerve-granules contain, and have intermingled with them, a variable number of pigment-granules.

In the construction of a nerve the nerve-fibres are collected into small fasciculi, each fasciculus being invested by a distinct neurilemma. These fasciculi, again, are collected into bundles, forming larger fasciculi, which have also a separate neurilemma; and a bundle of the larger fasciculi, enclosed in a sheath or neurilemma of white fibrous tissue, constitutes a nerve. The neurilemma of the smaller fasciculi is smooth and semitransparent, and remarkable for its satiny polish,—an appearance which is due to the longitudinal arrangement of the undulating fasciculi of fibrous tissue of which it is composed. Another character which the smaller nervous fasciculi possess, is that of being crossed by oblique or transverse lines, which are produced, in all probability, by the wrinkling of the neurilemma.

In the fasciculi of grey fibres the tendency to wrinkle exists in the longitudinal direction, and the neurilemma is composed of an inner layer of circular filaments as well as an outer layer of the longitudinal filaments of fibrous tissue.

The nerve-fibres have no inosculations, but pursue an uninterrupted course from their central to their peripheral termination. In some instances they return after a short curve to the cerebro-spinal centre, as, for example, in the posterior part of the optic commissure, in the two roots of each spinal nerve, and in the loop formed between the descendens noni and the upper cervical nerves. In these cases, the fibres form a simple arch, both extremities of the arch maintaining a communication with the cerebro-spinal axis. In another instance, the direction of the curve is reversed, the centre of the arch being in the anterior part of the optic commissure, and the extremities in the retina.

The communications which take place between nerves are termed *plexuses*. These plexuses are sometimes formed by the trunks of the nerves, as, the cervical, brachial; and lumbar; and sometimes by the fasciculi, as in the terminal plexuses at the periphery of the body and at the surface of the brain. The nerve-fibres in the spinal cord and central parts of the brain also form a close and plexiform interlacement with each other. In the construction of the larger plexuses there is a free interchange of fasciculi, and in the terminal plexuses a similar interchange of smaller fasciculi and primitive fibres. It is from the terminal plexuses that the nerve-fibres pass off to form their terminal loops.

The general mode of termination of nerve-fibres is by loops. There exists, however, an exception to this rule in the instance of the Pacinian\* corpuscles. These corpuscles are minute bodies, about a line in length, of an oval, oblong, or spheroidal shape, and smooth and glistening aspect, connected with the terminal nerve-fibres of the digital branches of the nerves distributed to the hands and feet. As many as two or three hundred are met with in a single hand. They are also found, but less numerous, on the terminal fibres of other sensitive nerves, and on the fibres of the sympathetic plexuses of the mesentery, of the meso-colon, and of the pancreas. They occur singly and in groups of two or three, and are each connected with the nerve by means of a short pedicle which projects into the corpuscle, and forms a conical process in its interior. The Pacinian corpuscle and its pedicle are composed of about fifty thin and membranous tunics, which are closely adherent in the latter, but are separated in the corpuscle by an albuminous fluid, and towards the free end of the corpuscle, the tunics are connected by imperfect septa. The central tunic or capsule is also filled with fluid, and into this fluid the axis cylinder of a primitive nervous fibril, derived from the nerve and continued through the centre of the peduncle, is prolonged. According to Henle and Kölliker, this nervous fibril generally terminates in a small rounded enlargement; at other times it bifurcates and forms two rounded heads, and occasionally escapes from the corpuscle at its free end. Each of the tunics of the Pacinian body is composed of fibres which have a circular disposition on its external surface, and are arranged in a longitudinal direction within. It is these fibres which give to the corpuscle its glistening appearance. The Pacinian corpuscles are first perceptible during the sixth month of fetal life.

On certain of the nerves of the body, for example, on the posterior roots of the cranial and spinal nerves, and particularly on the sympathetic, are situated enlargements which are termed *ganglia*. Ganglia are greyish in

\* Discovered and described by Pacini in 1831; described more particularly in 1840; and by Henle and Kölliker in 1844.

colour, are invested by a smooth membranous sheath, and are composed of the three essential constituents of the nervous system, namely, nerve-cells, nerve-fibres, and nerve-granules. The *nerve-cells* of ganglia are firm in structure, and have stronger investing sheaths than those of the brain. From the exterior of their sheaths, filaments of fibrous tissue are given off, which interlace with each other, and hold the cells together; and at the same time form an investing network around the entire ganglion, the nerve-fibres passing into and out of the ganglion through the interstices of this network. Besides the sheath-filaments, certain of the nerve-cells give off grey fibres, while others are free. The *nerve-fibres* of ganglia are of the two kinds met with in the rest of the nervous system. The white-fibres are derived from the cerebro-spinal axis, and enter the sympathetic through the so-called roots of that nerve, namely, its communications with the spinal nerves. In the ganglia these white fibres separate, and either pass directly onwards between the nerve-cells (traversing fibres), or make a series of turns around them (winding fibres); in either case, they collect together after a plexiform course between the nerve-cells, and form fasciculi, which pass off as branches from the ganglion. The grey nerve-fibres originate from certain of the nerve-cells within the ganglion as finely granular threads, and pass away in the form of fasciculi, with or without association of the white fibres, to be distributed to the various organs, or to traverse other ganglia previously to their distribution. The *Nerve-granules* occupy the interstices between the nerve-cells and the nerve-fibres, as in the cerebro-spinal mass. They are also continued with the nerve-fibres, into some of the nerves given off by the ganglia. Like the interstitial substance of the brain, the granular substance (gelatinous substance) of ganglia has intermingled with it minute cells and pigment-granules.

Nerves are divisible into two great classes; those which proceed directly from the cerebro-spinal axis, the cranial and spinal nerves, and constitute the system of animal life; and those which originate from the sympathetic system, or system of organic life.

The division of nerves into cranial and spinal is purely arbitrary, and depends on the circumstance of the former passing through the foramina of the cranium, and the latter through those of the vertebral column. With respect to origin, all the cranial nerves, with the exception of the first, [olfactory,] proceed from the spinal cord, or from its immediate prolongation into the brain. The spinal nerves arise by two roots; *anterior*, which proceeds from the anterior segment of the spinal cord, and possesses a motor function; and *posterior*, which is connected with the posterior segment, and bestows the faculty of sensation. The motor nerves of the cranium are shown by dissection to be continuous with the motor portion of the cord, and form one system with the motor roots of the spinal cord; while the nerves of sensation, always excepting the olfactory, are in like manner traced to the posterior segment of the cord, and form part of the system of sensation. To these two systems a third was added by Sir Charles Bell, the respiratory system, which consists of nerves associated in the function of respiration, and arising from the side of the upper part of the spinal cord in one continuous line, which he thence named the respiratory tract. The microscope has failed in making out any structural distinction between the anterior and posterior roots of the spinal nerves; but the latter are remarkable for the possession of ;



ganglion near their attachment with the cord. This ganglion is observed upon the posterior roots of all the spinal nerves, and also upon the corresponding root of the fifth cranial nerve, which is thence considered a spinal cranial nerve. Upon others of the cranial nerves a ganglion is found, which associates them in function with the nerves of sensation, and establishes an analogy with the spinal nerves.

According to Mr. Grainger, both roots of the spinal nerves, as well as of most of the cerebral, divide into two sets of fibres upon entering the cord, one set being connected with the gray substance, while the other is continuous with the white or fibrous part of the cord. The former he considers to be the agents of the excito-motory system of Dr. Marshall Hall; and the latter, the communication with the brain and the medium for the transmission of sensation and volition. He has not been able to trace the fibres which enter the gray substance to their termination; but he thinks it probable that the ultimate fibres of the posterior root join those of the anterior root; or, in the words of Dr. Marshall Hall's system, that the incident fibres (sensitive) are continuous with the reflex (motor).

The connexion of a nerve with the cerebro-spinal axis is called, for convenience of description, its *origin*: this term must not, however, be taken literally, for each nerve is developed in the precise situation which it occupies in the body, and with the same relations that it possesses in after life. Indeed, we not unfrequently meet with instances, in anencephalous fœtuses, where the nerves are beautifully and completely formed, while the brain and spinal cord are wanting. The word "origin" must therefore be considered as a relict of the darkness of preceding ages, when the cerebro-spinal axis was looked upon as the tree from which the nerves pushed forth as branches. In their *distribution*, the spinal nerves for the most part follow the course of the arteries, particularly in the limbs, where they lie almost constantly to the outer side and superficially to the vessels, as if for the purpose of receiving the first intimation of danger and of communicating it to the muscles, that the latter may instantly remove the arteries from impending injury.

The *Sympathetic system* consists of numerous ganglia, of communicating branches passing between the ganglia, of others passing between the ganglia and the cerebro-spinal axis, and of branches of distribution which are remarkable for their frequent and plexiform communications. The sympathetic nerves also differ from other nerves in their colour, which is of a grayish pearly tint.

The *capillary vessels* of nerves are very minute. They run parallel with the nervous fasciculi, and every here and there are connected by transverse communications, so as to give rise to a net-work composed of oblong meshes very similar to the capillary system of muscles.

The nervous system may be divided for convenience of description into 1. The brain. 2. The spinal cord. 3. The cranial nerves. 4. The spinal nerves. 5. The sympathetic system.

#### THE BRAIN.

The brain is a collective term which signifies those parts of the nervous system, exclusive of the nerves themselves, which are contained within the cranium; they are the cerebrum, cerebellum, and medulla oblongata.\*

\* The weight of the human brain, according to Semmering, is 2℔. 5½℥. to 3℔. 1℥. 7℥.

These are invested and protected by the membranes of the brain, and the whole together constitute the encephalon (ἐν κεφαλήν, within the head).

## MEMBRANES OF THE ENCEPHALON.

*Dissection.*—To examine the encephalon with its membranes, the upper part of the skull must be removed, by sawing through the external table and breaking the internal table with the chisel and hammer. After the calvarium has been loosened all round, it will require a considerable degree of force to tear the bone away from the dura mater. This adhesion is particularly firm at the sutures, where the dura mater is continuous with a membranous layer interposed between the edges of the bones; in other situations, the connexion results from numerous vessels which permeate the inner table of the skull. The adhesion subsisting between the dura mater and bone is greater in the young subject and in old persons than in the adult. On being torn away, the internal table will present numerous deeply grooved and ramified channels, corresponding with the branches of the arteria meningea media. Along the middle line will be seen a groove corresponding with the superior longitudinal sinus, and on either side may be frequently observed some small fossæ, corresponding with the Pacchionian bodies.

The membranes of the encephalon are the *dura mater*, *arachnoid membrane*, and *pia mater*.

The DURA MATER\* is the firm, whitish or greyish layer which is brought into view when the calvarium is removed. It is a strong fibrous membrane, somewhat laminated in texture, and composed of white fibrous tissue. Lining the interior of the cranium, it serves as the internal periosteum of that cavity; it is prolonged also into the spinal column, under the name of theca vertebralis, but is not adherent to the bones in that canal as in the cranium. From the internal surface of the dura mater, processes are directed inwards for the support and protection of parts of the brain; while from its exterior, other processes are prolonged outwards to form sheaths for the nerves as they quit the skull and spinal column. Its external surface is rough and fibrous, and corresponds with the internal table of the skull. The internal surface is smooth, and lined by the thin varnish-like lamella of the arachnoid membrane. The latter is a serous membrane. Hence the dura mater becomes a *fibro-serous* membrane, being composed of its own proper fibrous structure, and the serous layer derived from the arachnoid. There are two other instances of fibro-serous membrane in the body, formed in the same way, namely, the pericardium and tunica albuginea of the testicle.

On the external surface of the dura mater the branches of the middle meningeal artery may be seen ramifying; and in the middle line is a depressed groove, formed by the subsidence of the upper wall of the superior longitudinal sinus. If the sinus be opened along its course, it will be found to be a triangular channel, crossed at its lower angle by numerous white bands, called chordæ Willisii; † granular bodies are also occasionally seen in its interior, these are glandulæ Pacchioni.

\* So named from a supposition that it was the source of all the fibrous membranes of the body.

† Willis lived in the seventeenth century; he was a great defender of the opinions of Harvey.

The *Glandulæ Pacchioni*\* are small, round, whitish granulations, occurring singly or in clusters, and forming small groups of various size along the margin of the longitudinal fissure of the cerebrum, and more particularly near the summit of the latter. These bodies would seem to be of morbid origin; they are absent in infancy, increase in numbers in adult life, and are abundant in the aged. They are generally associated with opacity of the arachnoid around their bases, but in some instances are wanting even in the adult. They have their point of attachment in the pia mater, from which they seem to spring, carrying with them the arachnoid membrane, and then, in proportion to their size, producing various effects upon contiguous parts. For example, when small, they remain free or constitute a bond of adhesion between the visceral and parietal layer of the arachnoid; when of larger size they produce absorption of the dura mater, and as the degree of absorption is greater or less, they protrude through that membrane, and form depressions on the inner surface of the cranium, or simply render the dura mater thin and cribriform. Sometimes they cause absorption of the wall of the longitudinal sinus, and projecting into its cavity, give rise to the granulations described in connexion with that channel.

If the student cut through one side of the dura mater, in the direction of his incision through the skull, and turn it upwards towards the middle line, he will observe the smooth internal surface of this membrane. He will perceive also the large veins of the hemispheres filled with dark blood, and passing from behind forwards to open into the superior longitudinal sinus; and the firm connexion, by means of these veins and Pacchionian bodies, between the opposed surfaces of the arachnoid membrane. If he separate these adhesions with his scalpel, he will see a vertical layer of dura mater descending between the hemispheres; and if he draw one side of the brain a little outwards, he will be enabled to perceive the extent of the process of membrane, which is called the *falx cerebri*.

The processes of dura mater which are sent inwards towards the interior of the skull, are the *falx cerebri*, *tentorium cerebelli*, and *falx cerebelli*.

The *Falx cerebri* (falx, a sickle), so named from its sickle-like appearance, narrow in front, broad behind, and forming a sharp curved edge below, is attached in front to the crista galli process of the ethmoid bone, and behind to the tentorium cerebelli.

The *Tentorium cerebelli* (tentorium, a tent) is a roof of dura mater, thrown across the cerebellum and attached at each side to the margin of the petrous portion of the temporal bone; behind, to the transverse ridge of the occipital bone, which lodges the lateral sinuses; and to the clinoid processes in front. It supports the posterior lobes of the cerebrum and prevents their pressure† on the cerebellum, leaving only a small opening anteriorly, for the transmission of the *crura cerebri*.

The *Falx cerebelli* is a small process, generally double, attached to the vertical ridge of the occipital bone beneath the lateral sinus, and to the tentorium. It is received into the indentation between the two hemispheres of the cerebellum.

The layers of the dura mater separate in several situations, so as to form

\* These bodies are incorrectly described as conglobate glands by Pacchioni, in an epistolatory dissertation, "De Glandulis conglobatis Duræ Meningis indeque ortis Lymphaticis ad Piam Matrem productis," published at Rome, in 1705.

† In leaping animals, as the feline and canine genera, the tentorium forms a bony tent

irregular channels which receive the venous blood. These are the *sinuses* of the dura mater, which have been described at page 338.

The student cannot see the tentorium and falx cerebelli until the brain is removed; but he should consider the attachments of the former on the dried skull, for he will have to incise it in the removal of the brain. He should now proceed to that operation, for which purpose the dura mater is to be incised all round, on a level with the section through the skull, and the scissors are to be carried deeply between the hemispheres of the brain in front, to cut through the anterior part of the falx; then draw the dura mater backwards, and leave it hanging by its attachment to the tentorium. Raise the anterior lobes of the brain carefully with the hand, and lift the olfactory bulbs from the cribriform fossæ with the handle of the scalpel. Then cut across the two optic nerves and internal carotid arteries. Next divide the infundibulum and third nerves, and carry the knife along the margin of the petrous bone at each side, so as to divide the tentorium near its attachment. Cut across the fourth, fifth, sixth, seventh, and eighth nerves in succession with a sharp knife, and pass the scalpel as far down as possible into the vertebral canal, to sever the spinal cord, cutting first to one side and then to the other, in order to divide the vertebral arteries and first cervical nerves. Then let him press the cerebellum gently upwards with the fingers of the right hand, the hemispheres being supported with the left, and the brain will roll into his hand.

The *Arteries* of the dura mater are the *anterior meningeal* from the ethmoidal, ophthalmic, and internal carotid. The *middle meningeal* and *meningea parva* from the internal maxillary. The *inferior meningeal* from the ascending pharyngeal and occipital arteries; and the *posterior meningeal* from the vertebral.

Its *Nerves* are derived from the *nervi molles* and vertebral plexus of the sympathetic, from the Casserian ganglion, the ophthalmic nerve, and sometimes from the fourth. The branches from the two latter are given off while those nerves are situated by the side of the sella turcica; they are recurrent, and pass backwards between the layers of the tentorium, to the lining membrane of the lateral sinus. Purkinje describes a sympathetic plexus of considerable size, as being situated around the vena Galeni at its entrance into the fourth sinus. The filaments from this plexus are distributed to the tentorium.

#### *Arachnoid Membrane.*

The *Arachnoid* (*ἀράχνη εἶδος*, like a spider's web), so named from its extreme tenuity, is the serous membrane of the cerebro-spinal centre; and, like other serous membranes, a shut sac. It envelopes the brain and spinal cord (visceral layer) and is reflected upon the inner surface of the dura mater (parietal layer), giving to that membrane its serous investment.

On the upper surface of the hemispheres the arachnoid is transparent, but may be demonstrated as it passes across the sulci from one convolution to another by injecting, with a blow-pipe, a stream of air beneath it. At the base of the brain the membrane is opalescent and thicker than in other situations, and more easily demonstrable from the circumstance of stretching across the interval between the middle lobes of the hemispheres. The space which is included between this layer of membrane and those parts of the base of the brain which are bounded by the optic commissure

and fissures of Sylvius in front, and the pons Varolii behind, is termed the *anterior sub-arachnoidean space*. Another space formed in a similar manner, between the under part of the cerebellum and the medulla oblongata, is the *posterior sub-arachnoidean space*; and a third space, situated over the corpora quadrigemina, may be termed the *superior sub-arachnoidean space*. These spaces communicate freely with each other, the anterior and posterior across the crura cerebelli, the anterior and the superior around the crura cerebri, and the latter and the posterior across the cerebellum in the course of the vermiform processes. They communicate also with a still larger space formed by the loose disposition of the arachnoid around the spinal cord, the *spinal sub-arachnoidean space*. The whole of these spaces, with the lesser spaces between the convolutions of the hemispheres, constitute one large and continuous cavity which is filled with a limpid, serous secretion, the *sub-arachnoidean fluid*,\* a fluid which is necessary to the maintenance and protection of the cerebro-spinal mass. The quantity of the sub-arachnoidean fluid is determined by the relative size of the cerebro-spinal axis and that of the containing cavity, and is consequently very variable. It is smaller in youth than in old age, and in the adult has been estimated at about two ounces. The visceral layer of the arachnoid is connected to the pia mater by a delicate areolar tissue, which in the sub-arachnoidean spaces is loose and filamentous. The serous secretion of the true cavity of the arachnoid is very small in quantity as compared with the sub-arachnoidean fluid.

The arachnoid does not enter into the ventricles of the brain, as imagined by Bichât, but is reflected inwards upon the venæ Galeni for a short distance only, and returns upon those vessels to the dura mater of the tentorium. It surrounds the nerves as they originate from the brain, and forms a sheath around them to their point of exit from the skull. It is then reflected back upon the inner surface of the dura mater.

According to Mr. Rainey,† *vessels* of considerable size, but few in number; and branches of cranial *nerves* are found in the arachnoid. He also describes, in this membrane, numberless plexuses and ganglia, which he considers to be analogous to those of the sympathetic nerve. The fibres proceeding from this source are distributed on the arteries and nerves of the cerebro-spinal axis, but particularly on the former.

### *Pia Mater.*

The *Pia mater* is a vascular membrane composed of innumerable vessels held together by a thin layer of areolar tissue. It invests the whole surface of the brain, dipping into the sulci between the convolutions, and forming a fold in its interior called *velum interpositum*. It also forms folds in other situations, as in the third and fourth ventricles, and in the longitudinal fissures of the spinal cord.

This membrane differs very strikingly in its structure in different parts of the cerebro-spinal axis. Thus, on the surface of the cerebrum, in contact with the soft grey matter of the brain, it is extremely vascular, forming remarkable loops of anastomoses in the interspaces of the convolutions, and

\* The presence of a serous fluid beneath the arachnoid has given rise to the conjecture that a sub-arachnoid serous membrane may exist in that situation. Such a supposition is quite unnecessary to explain the production of the secretion, since the pia mater is fully adequate to that function.

† Medico-Chirurgical Transactions, vol. 29.

distributing multitudes of minute straight vessels to the grey substance. In the *substantia perforata*, again, and *locus perforatus*, it gives off tufts of small arteries, which pierce the white matter to reach the grey substance in the interior. But upon the *crura cerebri*, *pons Varolii*, and spinal cord, its vascular character seems almost lost. It has become a *dense fibrous membrane*; difficult to tear off, and forming the proper sheath of the spinal cord.

The *pia mater* is the nutrient membrane of the brain, and derives its blood from the internal carotid and vertebral arteries.

Its *Nerves* are the minute filaments of the sympathetic, which accompany the branches of the arteries.

## CEREBRUM.

The *Cerebrum* presents on its surface a number of slightly convex elevations, the convolutions, (*gyri*) which are separated from each other by *sulci* of various depth.\* It is divided superiorly into two hemispheres by the great longitudinal fissure, which lodges the *falx cerebri*, and marks the original development of the brain by two symmetrical halves.

Each hemisphere, upon its under surface, admits of a division into three lobes, anterior, middle, and posterior. The *anterior lobe* rests upon the roof of the orbit, and is separated from the middle by the fissure of Sylvius.† The *middle lobe* is received into the middle fossæ of the base of the skull, and is separated from the posterior by a slight impression produced by the ridge of the petrous bone. The *posterior lobe* is supported by the tentorium.

If the upper part of one hemisphere, at about one-third from its summit, be removed with a scalpel, a centre of white substance will be observed, surrounded by a narrow border of grey, which follows the line of the sulci and convolutions, and presents a zigzag form. This section from exhibiting the largest surface of medullary substance demonstrable in a single hemisphere is called *centrum ovale minus*; it is spotted by numerous small red points (*puncta vasculosa*) which are produced by the escape of blood from the cut ends of minute arteries and veins.

Now separate carefully the two hemispheres of the cerebrum, and a broad band of white substance (*corpus callosum*) will be seen to connect them; it will be seen also that the surface of the hemisphere where it comes in contact with the *corpus callosum* is bounded by a large convolution (*gyrus fornicatus*) which lies horizontally on that body, and may be traced forwards and backwards to the base of the brain, terminating by each extremity at the fissure of Sylvius. The sulcus between this convolution and the *corpus callosum* has been termed, very improperly, the “ventricle of the *corpus callosum*,” and some longitudinal fibres (*strix longitudinales laterales*), which are brought into view when the convolution is raised, were called by Reil the “covered band.” If, now, the upper part of each hemisphere be removed to a level with the *corpus callosum*, a large expanse of medullary matter, surrounded by a zigzag line of grey substance corresponding with the convolutions and sulci of the two hemispheres, will be seen; this is the *centrum ovale majus* of Vieussens.

\* In estimating the surface of the brain, which, according to Baillarger, averages in round numbers, 670 square inches, these convolutions and the laminæ of the cerebellum are supposed to be unfolded.

† James Dubois, a celebrated professor of anatomy in Paris, where he succeeded Vi dius in 1550, although known much earlier by his works and discoveries, but particularly by his violence in the defence of Galen. His name was latinised to *Jacobus Sylvius*.

The *Corpus callosum* (callosus, hard) is a thick layer of medullary fibres passing transversely between the two hemispheres, and constituting their *great commissure*. It is situated in the middle line of the *centrum ovale majus*, but nearer the anterior than the posterior part of the brain, and terminates anteriorly in a rounded border (genu), which may be traced downwards to the base of the brain in front of the commissure of the optic nerves. Posteriorly it forms a thick rounded fold (splenium), which is continuous with the fornix. The length of the corpus callosum is about four inches.

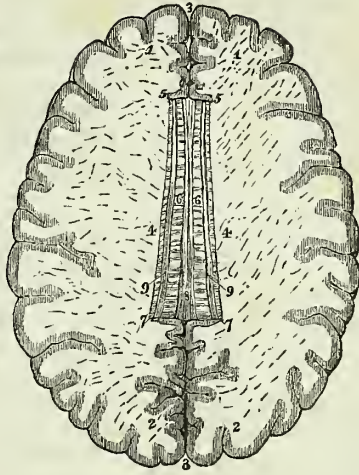
Beneath the posterior rounded border of the corpus callosum is the *transverse fissure* of the cerebrum, which extends between the hemispheres and *crura cerebri* from near the fissure of Sylvius on one side, to the same point on the opposite side of the brain. It is through this fissure that the pia mater communicates with the *velum interpositum*. And it was here that Bichât conceived the arachnoid to enter the ventricles; hence it is also named the *fissure of Bichât*.

Along the middle line of the corpus callosum is the *raphé*, a linear depression between two slightly elevated longitudinal bands (*chordæ longitudinales, Lancisii*); and, on either side of the *raphé*, may be seen the *lineæ transversæ*, which mark the direction of the fibres of which the corpus callosum is composed. These fibres may be traced into the hemispheres on either side, and they will be seen to be crossed at about an inch from the *raphé* by the longitudinal fibres of the covered band of Reil. Anteriorly and posteriorly the fibres of the corpus callosum curve into their corresponding lobes.

If, now, a superficial incision be made through the corpus callosum on either side of the *raphé*, two irregular cavities will be opened, which extend from one extremity of the hemispheres to the other: these are the *lateral ventricles*. To expose them completely, their upper boundary should be removed with the scissors. In making this dissection the thin and diaphanous membrane of the ventricles may frequently be seen.

LATERAL VENTRICLES.—Each lateral ventricle is divided into a *central cavity*, and three smaller cavities called *cornua*. The *anterior cornu* curves forwards and outwards in the anterior lobe; the *middle cornu* descends into the middle lobe; and the *posterior cornu* passes backwards in the posterior lobe, converging towards its fellow of the opposite side. The central cavity is triangular in form, being bounded above (*roof*) by the corpus callosum; internally by the *septum lucidum*, which separates

Fig. 169.\*

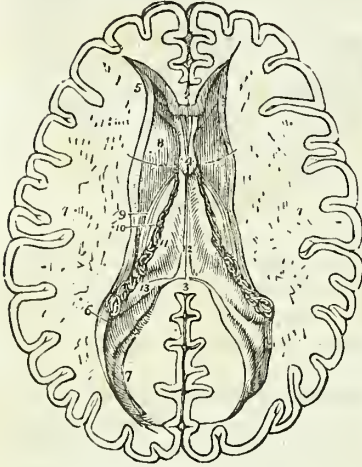


\* A section of the brain showing the *centrum ovale majus* and corpus callosum. 1, 1. The anterior lobes of the brain. 2, 2. The posterior lobes. 3, 3. The longitudinal fissure for the reception of the *falx cerebri*. 4, 4. The roof of the lateral ventricles. 5, 5. The genu of the corpus callosum. 6. Its body, upon which the *lineæ transversæ* are seen. 7, 7. The *splenium corporis callosi*. 8. The *raphé*. 9, 9. The *striæ longitudinales laterales*, or covered bands of Reil.

it from the opposite ventricle ; and below (*floor*) by the following parts, taken in their order of position from before backwards :—

Corpus striatum,  
Tenia semicircularis,  
Thalamus opticus,  
Choroid plexus,  
Corpus fimbriatum,  
Fornix.

Fig. 170.\*



terminates in the vena Galeni of its own side. The vein is formed by small vessels from the corpus striatum and thalamus opticus, and is overlaid by a yellowish band, a thickening of the lining membrane of the ventricle. This was first noticed and described by Tarinus, under the name of the *horny band*. We may therefore term it *tenia Tarini*.†

The *Thalamus opticus* (thalamus, a bed) is an oblong body, having a

\* The lateral ventricles of the cerebrum. 1, 1. The two hemispheres cut down to a level with the corpus callosum so as to constitute the centrum ovale majus. The surface is seen to be studded with the small vascular points—*puncta vasculosa*; and surrounded by a narrow margin which represents the grey substance. 2. A small portion of the anterior extremity (genu) of the corpus callosum. 3. Its posterior boundary (splenium); the intermediate portion forming the roof of the lateral ventricles has been removed so as to expose completely those cavities. 4. A part of the septum lucidum, showing an interspace between its layers—the fifth ventricle. 5. The anterior cornu of one side. 6. The commencement of the middle cornu. 7. The posterior cornu. 8. The corpus striatum of one ventricle. 9. The tenia semicircularis covered by the vena corporis striati and tenia Tarini. 10. A small part of the thalamus opticus. 11. The dark fringe-like body to the left of the numeral is the choroid plexus. This plexus communicates with that of the opposite ventricle through the foramen of Monro, or foramen commune anterius; a bristle is passed through this opening (under figure 4), and its extremities are seen resting on the corpus striatum at each side. The figure 11 rests upon the edge of the fornix, on that part of it which is called the corpus fimbriatum. 12. The fornix. 13. The commencement of the hippocampus major descending into the middle cornu. The rounded oblong body in the posterior cornu of the lateral ventricle, directly behind the figure 13, is the hippocampus minor.

† Peter Tarin, a French anatomist; his work, entitled "*Adversaria Anatomica*," was published in 1750.



tain coating of white substance on its surface; it has received its name from giving origin to one root of the optic nerve. It is the inferior ganglion of the cerebrum. Part only of the thalamus is seen in the floor of the lateral ventricle; we must, therefore, defer its further description until we can examine it in its entire extent.

The *Choroid plexus* (χόριον, εἶδος, resembling the chorion\*) is a vascular fringe extending obliquely across the floor of the lateral ventricle, and sinking into the middle cornu. Anteriorly, it is small and tapering, and communicates with the choroid plexus of the opposite ventricle, through a large oval opening, the *foramen of Monro*, or foramen commune anterius. This foramen may be distinctly seen by pulling slightly on the plexus, and pressing aside the septum lucidum with the handle of the knife. It is situated between the under surface of the fornix, and the anterior extremities of the thalami optici, and forms a communication transversely between the lateral ventricles, and perpendicularly with the third ventricle.

The choroid plexus presents upon its surface a number of minute vascular processes, which are termed *villi*. They are invested by a very delicate epithelium, surmounted by cilia, which have been seen in active movement in the embryo. In their interior the plexuses not unfrequently contain particles of calcareous matter, and they are sometimes covered by small clusters of serous cysts.

The *Corpus fimbriatum* is a narrow white band, which is situated immediately behind the choroid plexus, and extends with it into the descending cornu of the lateral ventricle. It is, in fact, the lateral thin edge of the fornix, and being attached to the hippocampus major in the descending horn of the lateral ventricle, it is also termed, *tenia hippocampi*.

The *Fornix* is a white layer of medullary substance, of which a portion only is seen in this view of the ventricle.

The *Anterior cornu* is triangular in its form, sweeping outwards, and terminating by a point in the anterior lobe of the brain, at a short distance from its surface.

The *Posterior cornu* or *digital cavity* curves inwards, as it extends back into the posterior lobe of the brain, and likewise terminates near the surface. An elevation corresponding with a deep sulcus between two convolutions projects into the area of this cornu, and is called the *hippocampus minor*.

The *Middle* or *descending cornu*, in descending into the middle lobe of the brain, forms a very considerable curve, and alters its direction several times as it proceeds. Hence it is described as passing backwards and outwards and downwards, and then turning forwards and inwards. This complex expression of a very simple curve has given origin to a symbol formed by the primary letters of these various terms; and by means of this the student recollects with ease the course of the cornu, BODFI. It is the largest of the three cornua, and terminates close to the fissure of Sylvius, after having curved around the crus cerebri.

The middle cornu should now be laid open, by inserting the little finger into its cavity, and making it serve as a director for the scalpel in cutting away the side of the hemisphere, so as to expose it completely.

The *Superior boundary* of the middle cornu is formed by the under sur-

\* See the note appended to the description of the choroid coat of the eye-ball

face of the thalamus opticus, upon which are the two projections called corpus geniculatum internum and externum; and the *inferior wall* by the various parts which are sometimes spoken of as the contents of the middle cornu: these are the—

Hippocampus major,  
 Pes hippocampi,  
 Pes accessorius,  
 Corpus fimbriatum,  
 Choroid plexus,  
 Fascia dentata,  
 Transverse fissure.

The *Hippocampus major* or *cornu Ammonis*, so called from its resemblance to a ram's horn, the famous crest of Jupiter Ammon, is a considerable projection from the inferior wall, and extends the whole length of the middle cornu. Its extremity is likened to the foot of an animal, from its presenting a number of knuckle-like elevations upon the surface, and is named *pes hippocampi*. The hippocampus major is the internal surface of the convolution (*gyrus fornicatus*) of the lateral edge of the hemisphere, the convolution which has been previously described as lying upon the corpus callosum and extending downwards to the base of the brain to terminate at the fissure of Sylvius. If it be cut across, the section will be seen to resemble the extremity of a convoluted scroll, consisting of alternate layers of white and grey substance. The hippocampus major is continuous superiorly with the fornix and corpus callosum, deriving from the latter its medullary layer.

The *Pes accessorius* is a swelling somewhat resembling the hippocampus major, but smaller in size; it is situated on the outer wall of the cornu, and is frequently absent.

The *Corpus fimbriatum* (*tenia hippocampi*) is the narrow white band which is prolonged from the central cavity of the ventricle, and is attached along the inner border of the hippocampus major. It is lost inferiorly on the hippocampus.

*Fascia dentata*:—if the corpus fimbriatum be carefully raised, a narrow serrated band of grey substance, the margin of the grey substance of the middle lobe, will be seen beneath it; this is the fascia dentata. Beneath the corpus fimbriatum will be likewise seen the *transverse fissure* of the brain, which has been before described as extending from near the fissure of Sylvius on one side, across to the same point on the opposite side of the brain. It is through this fissure that the pia mater communicates with the *choroid plexus*, and the latter obtains its supply of blood. The fissure is bounded on one side by the corpus fimbriatum, and on the other by the under surface of the thalamus opticus.

The internal boundary of the lateral ventricle is the *septum lucidum*. This septum is thin and semi-transparent, and consists of two laminae of cerebral substance attached above to the under surface of the corpus callosum at its anterior part, and below to the fornix. Between the two layers is a narrow space, the *fifth ventricle*, which is lined by a proper membrane. The *fifth ventricle* may be shown, by snipping through the septum lucidum transversely with the scissors.

The corpus callosum should now be cut across towards its anterior ex-

treinity, and the two ends carefully dissected away. The anterior portion will be retained only by the septum lucidum, but the posterior will be found incorporated with the white layer beneath, which is the fornix.

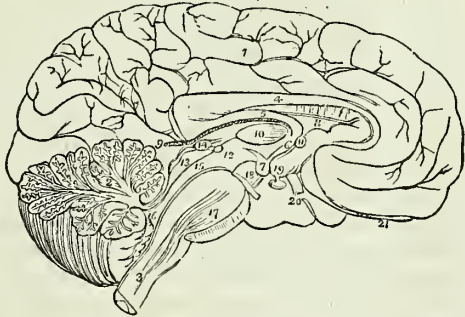
FORNIX. — The fornix (arch) is a triangular lamina of white substance, broad behind, and extending into each lateral ventricle: narrow in front, where it terminates in two crura, which arch downwards to the base of the brain. The two crura descend in a curved direction to the base of the brain, embedded in grey substance, in the lateral walls of the third ventricle, and lying directly behind the anterior commissure. At the base of the brain they make a sudden curve upon themselves and constitute the corpora albicantia, from which they may be traced upwards to their origin in the thalami optici. Opening transversely beneath these two crura, just as they are about to arch downwards, is the foramen of communication between the lateral and the third ventricles, the *foramen of Monro*; or *foramen commune anterius*. The choroid plexuses communicate, and the veins of the corpora striata pass through this opening.

The lateral thin edges of the fornix are continuous *posteriorly* with the concave border of the hippocampus major at each side, and form the narrow white band called *corpus fimbriatum* (posterior crus of the fornix). In the middle line the fornix is continuous with the corpus callosum, and at each side with the hippocampus major and minor. Upon the under surface of the fornix towards its posterior part, some transverse lines are seen passing between the diverging corpora fimbriata: this appearance is termed the *lyra* (corpus psaloides), from a fancied resemblance to the strings of a harp.

The fornix may now be removed by dividing it across anteriorly, and turning it backwards, at the same time separating its lateral connexions with the hippocampi. If the student examine its under surface, he will perceive the lyra above described.

Beneath the fornix is the *velum interpositum*, a duplication of pia mater introduced into the interior of the brain, through the transverse fissure. The velum is continuous at each side with the choroid plexus, and contains in its inferior layer two large veins (the *venæ Galeni*) which re-

Fig. 171.\*



\* The mesial surface of a longitudinal section of the brain. The incision has been carried along the middle line; between the two hemispheres of the cerebrum, and through the middle of the cerebellum and medulla oblongata. 1. The inner surface of the left hemisphere. 2. The divided surface of the cerebellum, showing the arbor vitae. 3. The medulla oblongata. 4. The corpus callosum curving downwards in front to terminate at the base of the brain, and rounded behind to become continuous with 5, the fornix. 6. One of the crura of the fornix descending to 7, one of the corpora albicantia. 8. The septum lucidum. 9. The velum interpositum, communicating with the pia mater of the convolutions through the fissure of Bichat. 10. Section of the middle commissure situated at the base of the brain. 11. Section of the anterior commissure. 12. Section of the posterior commissure; the commissure is somewhat above and to the left of the numeral. The interspace between 10 and 11 is the foramen commune anterius, in which the crus of the fornix (6) is situated. The interspace between 10 and 12 is the

ceive the blood from the corpora striata and choroid plexuses, and terminate posteriorly, after uniting into a single trunk, in the straight sinus. Upon the under surface of the velum interpositum are two fringe-like bodies, which project into the third ventricle. These are the *choroid plexuses* of the *third ventricle*; posteriorly these fringes enclose the pineal gland.

If the velum interpositum be raised and turned back, an operation which must be conducted with care, particularly at its posterior part, where it invests the pineal gland, the thalami optici and the cavity of the third ventricle will be brought into view.

**THALAMI OPTICI.**—The thalami optici are two oblong, square-shaped bodies, of a white colour superficially, inserted between the two diverging portions of the corpora striata. In the middle line a fissure exists between them, which is called the *third ventricle*. Posteriorly and inferiorly, they form the superior wall of the descending cornu, and present two rounded elevations called *corpus geniculatum externum* and *internum*. The *corpus geniculatum externum* is the larger of the two, and of a greyish colour; it is the principal origin of the optic nerve. Anteriorly, the thalami are connected with the corpora albicantia by means of two white bands, which appear to originate in the white substance uniting the thalami to the corpora striata. Externally they are in relation with the corpora striata and hemispheres. In their interior the thalami are composed of white fibres mixed with grey substance. They are essentially the *inferior ganglia of the cerebrum*.

**THIRD VENTRICLE.**—The third ventricle is the fissure between the two thalami optici. It is bounded above by the under surface of the velum interpositum, from which are suspended the choroid plexuses of the third ventricle. Its *floor* is formed by the grey substance of the anterior termination of the corpus callosum, called lamina cinerea, the tuber cinereum, corpora albicantia, and locus perforatus. *Laterally* it is bounded by the thalami optici; *anteriorly* by the anterior commissure and crura of the fornix; and *posteriorly* by the posterior commissure and the iter a tertio ad quartum ventriculum. The third ventricle is crossed by three commissures, anterior, middle, and posterior; and between these are two spaces, called foramen commune anterius and foramen commune posterius.

The *Anterior commissure* is a small rounded white cord, which enters the corpus striatum at either side, and spreads out in the substance of the hemispheres; the *middle*, or *soft commissure* consists of grey matter, which is continuous with the grey lining of the ventricle, it connects the adjacent sides of the thalami optici; the *posterior commissure*, smaller than the anterior, is a rounded white cord, connecting the two thalami optici posteriorly.

The space between the anterior and middle commissure is called the *foramen commune anterius*, and is that to which Monro has given his name (foramen of Monro). It is the medium of communication between

foramen commune posterius. 13. The corpora quadrigemina, upon which is seen resting the pineal gland, 14. 15. The iter a tertio ad quartum ventriculum, or aqueduct of Sylvius. 16. The fourth ventricle. 17. The pons Varolii, through which are seen passing the diverging fibres of the corpora pyramidalia. 18. The crus cerebri of the left side, with the third nerve arising from it. 19. The tuber cinereum, from which projects the infundibulum, having the pituitary gland appended to its extremity. 20. One of the optic nerves. 21. The left olfactory nerve terminating anteriorly in a rounded bulb.

the lateral and third ventricles, and it transmits superiorly the choroid plexus and the venæ corporum striatorum. The foramen commune anterior is also termed, *iter ad infundibulum*, from leading downwards to the funnel-shaped cavity of the infundibulum. The crura of the fornix are embedded in the lateral walls of the foramen commune, and are concealed from view in this situation by the layer of grey substance which lines the interior of the third ventricle. If the crura be slightly separated, the anterior commissure will be seen immediately in front of them, crossing from one corpus striatum to the other. The space between the middle and posterior commissure is the *foramen commune posterius*; it is much shallower than the preceding, and is the origin of a canal, the aqueduct of Sylvius or *iter a tertio ad quartum ventriculum*, which leads backwards beneath the posterior commissure and through the base of the corpora quadrigemina to the upper part of the fourth ventricle.

**CORPORA QUADRIGEMINA.**—The corpora quadrigemina, or optic lobes, are situated immediately behind the third ventricle and posterior commissure; and beneath the posterior border of the corpus callosum. They form, indeed, at this point, the inferior boundary of the transverse fissure of the hemispheres, the fissure of Bichât. The anterior pair of these bodies are grey in colour, and are named *nates*: the posterior pair are white and much smaller than the anterior; they are termed *testes*. From the nates on each side may be traced a rounded process (brachium anterior) which passes obliquely outwards into the thalamus opticus; and from the testis a similar but smaller process (brachium posterius) which has the same destination. The corpus geniculatum internum lies in the interval of these two processes where they enter the thalamus, and behind the brachium posterius is a prominent band (laqueus) which marks the course of the superior division of the fasciculus olivaris. The corpora quadrigemina are perforated longitudinally through their base by the aqueduct of Sylvius; they are covered in partly by the pia mater and partly by the velum interpositum, and the nates form the base of support of the pineal gland.

**PINEAL GLAND.**—The pineal gland is a small reddish grey body of a conical form (hence its synonym *conarium*), situated on the anterior part of the nates and invested by a duplicature of pia mater derived from the under part of the velum interpositum. The pineal gland, when pressed between the fingers is found to contain a gritty matter (acervulus) composed chemically of phosphate and carbonate of lime, and is sometimes hollow in the interior. It is connected to the brain by means of two medullary cords called *peduncles* and a thin lamina derived from the posterior commissure; the peduncles of the pineal gland are attached to the thalami optici, and may be traced along the upper and inner margin of those bodies to the crura of the fornix with which they become blended. From the close connexion subsisting between the pia mater and the pineal gland, and the softness of texture of the latter, the gland is liable to be torn away in the removal of the pia mater.

Behind the corpora quadrigemina is the cerebellum, and beneath the cerebellum the fourth ventricle. The student must therefore divide the cerebellum down to the fourth ventricle, and turn its lobes aside to examine that cavity.

**FOURTH VENTRICLE.**—The fourth ventricle (sinus rhomboidalis) is the ventricle of the medulla oblongata, upon the posterior surface of which, and of the pons Varolii, it is placed. It is a lozenge-shaped cavity,

bounded on each side by a thick cord passing between the cerebellum and corpora quadrigemina, called the *processus e cerebello ad testes*, and by the *corpus restiforme*. It is covered in behind by the cerebellum, and by a thin lamella of medullary substance, stretched between the two *processus e cerebello ad testes*, termed the *valve of Vieussens*.\*

That portion of the cerebellum which forms the posterior boundary of the fourth ventricle; presents four small prominences or lobules, and a thin layer of medullary substance, the *velum medullare posterius*. Of the lobules two are placed in the middle line, the *nodulus* and *uvula*, the former being before the latter; the remaining two are named *amygdalæ*, or tonsils, and are situated one on either side of the uvula. They all project into the cavity of the fourth ventricle, and the *velum medullare posterius* is situated in front of them. The *valve of Vieussens*, or *velum medullare anterius*, is an extremely thin lamella of medullary substance, prolonged from the white matter of the cerebellum to the testes, and attached on each side to the *processus e cerebello ad testes*. This lamella is overlaid for a short distance by a thin, transversely-grooved lobule of grey substance (*linguetta laminosa*) derived from the anterior border of the cerebellum, and its junction with the testes is strengthened by a narrow slip given off by the commissure of those bodies, the *frænulum veli medullaris anterioris*. The *anterior wall*, or *floor* of the fourth ventricle is formed by two slightly convex bodies, *processus teretes* or posterior pyramids, separated by a longitudinal groove which is continuous inferiorly with the *fissura longitudinalis posterior* of the spinal cord. The *processus teretes* are crossed transversely by several white and grey fasciculi (*lineæ transversæ*) the origin of the auditory nerves. And upon the lower part of the floor of this ventricle is an impression resembling the point of a pen, and hence named *calamus scriptorius*; the lateral boundaries of the calamus are the *processus clavati* of the posterior median columns of the spinal cord. Above, the fourth ventricle is bounded by the corpora quadrigemina and aqueduct of Sylvius; and below by a layer of pia mater and arachnoid, called the valve of the arachnoid. It is by rupture of this latter that a communication is established between the ventricles of the brain and the sub-arachnoidean space. Within the fourth ventricle and lying against the uvula and tonsils are two small vascular fringes formed by the pia mater, the *choroid plexuses* of the fourth ventricle. The fourth ventricle is lined by grey matter derived from the interior of the spinal cord, the grey matter being partly concealed by a thin expansion of white substance.

#### LINING MEMBRANE OF THE VENTRICLES.

The lining membrane of the ventricles is a serous layer distinct from the arachnoid; it lines the whole of the interior of the lateral ventricles, and is connected above and below with the attached border of the choroid plexus, so as to exclude all communication between the ventricles and the exterior of the brain. From the lateral ventricles it is reflected through the foramen of Monro on each side, into the third ventricle, which it invests throughout. From the third it is conducted into the fourth ventricle, through the *iter a tertio ad quartum ventriculū*, and lines its interior, to-

\* Raymond Vieussens, a great discoverer in the anatomy of the brain and nervous system. His "*Neurographia Universalis*" was published at Lyons, in 1685.

gether with a layer of pia mater which forms its inferior boundary. In this manner a perfect communication is established between all the ventricles, with the exception of the fifth, which has its own proper membrane. It is this membrane which gives them their polished surface, and transudes the secretion which moistens their interior. When the fluid accumulates to an unnatural degree, it may then break down this layer and the layer of pia mater at the bottom of the fourth ventricle, and thus make its way into the sub-arachnoidean space; but in the normal condition it is doubtful whether a communication exists between the interior of the ventricles and the serous cavity of the sub-arachnoidean space.

## CEREBELLUM.

The *Cerebellum* (figs. 171, 172, 173), seven times smaller than the cerebrum, is situated beneath the posterior lobes of the latter, being lodged in the posterior fossa of the base of the cranium, and protected from the superincumbent pressure of the cerebrum by the tentorium cerebelli. Like the cerebrum, it is composed of grey and white substance, the former occupying the surface, the latter the interior, and its surface is formed of parallel lamellæ separated by sulci, and here and there by deeper sulci. In form, the cerebellum is oblong and flattened, its greater diameter being from side to side, its two surfaces looking upwards and downwards, and its borders being anterior, posterior, and lateral. In consideration of its shape the cerebellum admits of a division into two hemispheres, into certain prominences termed processes and lobules, and into certain divisions of its substance called lobes, formed upon the hemispheres by the deeper sulci above referred to. The two hemispheres are separated from each other on the upper surface of the cerebellum by a longitudinal ridge which is termed the *superior vermiform process*, and which forms a commissure between them. On the anterior border of the organ there is a semilunar notch, *incisura cerebelli anterior*, which encircles the corpora quadrigemina posteriorly. On the posterior border there is another notch, *incisura cerebelli posterior*, which receives the upper part of the falx cerebelli; and on the under surface of the cerebellum is a deep fissure corresponding with the medulla oblongata, and termed the vallecule (valley).

Each hemisphere of the cerebellum is divided by means of a fissure (sulcus horizontalis) which runs along its free border, into an upper and a lower portion, and upon each of these portions certain lobes are marked out. Thus on the upper portion there are two such lobes separated by a sulcus, somewhat more strongly marked than the rest, and extending deeper into the substance of the cerebellum; they are the *lobus superior anterior* and *lobus superior posterior*. Upon the under portion of the hemisphere there are three such lobes, namely, *lobus inferior anterior*, *medius*, and *posterior*, and two additional ones of peculiar form, the *lobus inferior internus* or *tonsil*, and the *flocculus*. The tonsil (amygdala) is situated on the side of the vallecule, and projects into the fourth ventricle. The flocculus or pneumogastric lobule, long and slender, extends from the side of the vallecule around the corpus restiforme to the crus cerebelli, lying behind the filaments of the eighth pair of nerves.

The commissure between the two hemispheres is termed the *worm* (vermis), that portion of the worm which occupies the upper surface of the cerebellum as far back as the horizontal fissure being the processus

vermiformis superior, and that which is lodged within the vallecule being the processus vermiformis inferior. The *superior vermiform process* is a prominent longitudinal ridge, extending from the incisura anterior to the incisura posterior cerebelli. In imitation of the hemispheres, it is divided into lobes, of which three have received names, namely, the *lobulus centralis*, which is a small lobe situated in the incisura anterior; the *monticulus cerebelli*, a longer lobe, having its peak and declivity; and a small lobe near the incisura posterior, the *commissura simplex*. The lobes of the *inferior vermiform process* are four in number, namely,—the *commissura brevis*, situated in the incisura posterior, below the horizontal fissure; the *pyramid*, a small, obtusely-pointed eminence; a larger prominence, the *uvula*, situated between the tonsils, and connected with them by means of a commissure; and in front of the uvula, the *nodulus*. In front of the nodulus is a thin lamina of medullary substance, consisting of a central and two lateral portions, the *velum medullare posterius* (valvula Tarini), and between this velum in front, and the nodulus and uvula behind, is a deep fossa which is known as the *swallow's nest* (nidus hirundinis). The *velum medullare anterius* is the valve of Vieussens, described with the fourth ventricle; both these vela proceed from the same point in the roof of that ventricle, and separate from each other at an angle, the one passing obliquely forwards, the other obliquely backwards.

When a vertical incision is made into the cerebellum, that appearance is seen which has been denominated *arbor vita cerebelli*; the white substance in the centre of such a section resembles the trunk of a tree, from which branches are given off, and from the branches branchlets and leaves, the two latter being coated by a moderately thick and uniform layer of grey substance. If the incision be made somewhat nearer the commissure than to the lateral border of the organ, a yellowish grey dentated line, enclosing medullary substance traversed by the openings of numerous vessels, will be seen in the centre of the white substance. This is the ganglion of the cerebellum, the *corpus rhomboideum* or dentatum, from which the peduncles of the cerebellum proceed. The grey line is dense and horny in structure, and is the cut edge of a thin capsule, open towards the medulla oblongata.

The cerebellum is associated with the rest of the encephalon by means of three pairs of rounded cords or peduncles, superior, middle, and inferior. The superior peduncles, or *processus e cerebello ad testes*, proceed from the cerebellum forwards and upwards to the testes, in which they are lost. They form the anterior part of the lateral boundaries of the fourth ventricle, and give attachment by their inner borders to the valve of Vieussens, which is stretched between them. At their junction with the testes they are crossed by the fourth pair of nerves. The middle peduncles, or *crura cerebelli ad pontem*, the largest of the three, issue from the cerebellum through the anterior extremity of the sulcus horizontalis, and are lost in the pons Varolii. The inferior peduncles, or *crura ad medullam oblongatam*, are the corpora restiformia which descend to the posterior part of the medulla oblongata, and form the inferior portion of the lateral boundaries of the fourth ventricle.

The student should now prepare to study the base of the brain: for this purpose the organ should be turned upon its incised surface; and if the



dissection have hitherto been conducted with care, he will find the base perfectly uninjured. The arachnoid membrane, some parts of the pia mater, and the circle of Willis, must be carefully cleared away, in order to expose all the parts to be examined. These he will find arranged in the following order from before backwards:—

|                            |                     |
|----------------------------|---------------------|
| Longitudinal fissure,      | Infundibulum,       |
| Olfactory nerves,          | Corpora albicantia, |
| Fissure of Sylvius,        | Locus perforatus,   |
| Substantia perforata,      | Crura cerebri,      |
| Commencement of the trans- | Pons Varolii,       |
| verse fissure,             | Crura cerebelli,    |
| Optic commissure,          | Medulla oblongata.  |
| Tuber cinereum,            |                     |

The *Longitudinal* fissure is the space separating the two hemispheres: it is continued downwards to the base of the brain, and divides the two anterior lobes. In this fissure the anterior cerebral arteries ascend towards the corpus callosum; and, if the two lobes be slightly drawn asunder, the anterior border (genu) of the corpus callosum will be seen descending to the base of the brain. Arrived at the base of the brain, the corpus callosum terminates by a concave border, which is prolonged to the commissure of the optic nerves by a thin layer of grey substance, the *lamina cinerea*. The lamina cinerea is the anterior part of the inferior boundary of the third ventricle. On each side of the lamina cinerea the corpus callosum is continued into the substantia perforata and crura cerebri, and upon the latter forms a narrow medullary band lying externally to, and slightly overlapping the optic tract, the *medulla innominata*.

Upon the under surface of each anterior lobe, on either side of the longitudinal fissure, is the *olfactory nerve*, with its bulb.

The *Fissure of Sylvius* bounds the anterior lobe posteriorly, and separates it from the middle lobe; it lodges the middle cerebral artery. If this fissure be followed outwards, a small isolated cluster of five or six convolutions will be observed; these constitute the *island of Reil*. The island of Reil, together with the substantia perforata, form the base of the corpus striatum.

The *Substantia perforata* is a triangular plane of white substance, situated at the inner extremity of the fissure of Sylvius. It is named *perforata* from being pierced by a number of openings for small arteries, which enter the brain in this situation to supply the grey substance of the corpus striatum.

Passing backwards on each side beneath the edge of the middle lobe, is the commencement of the *great transverse fissure*, which extends beneath the hemisphere of one side to the same point on the opposite side. A probe passed into this fissure between the crus cerebri and middle lobe would enter the middle cornu of the lateral ventricle.

The *Optic commissure* is situated on the middle line; it is the point of communication between the two optic nerves.

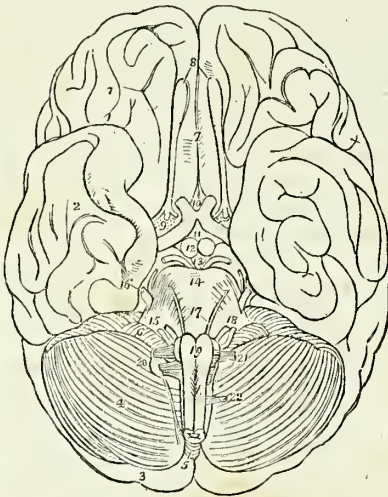
The *Tuber cinereum* is an eminence of grey substance situated immediately behind the optic commissure, and in front of the corpora mammillaria. From its centre there projects a small conical body of grey substance, apparently a prolongation of the tuber cinereum, the *infundibulum*. The infundibulum is hollow in its interior, enclosing a short cæcal canal

which communicates with the cavity of the third ventricle; and below the termination of the canal, the conical process becomes connected with the pituitary gland. The infundibulum and tuber cinereum form part of the floor of the third ventricle.

The *Pituitary gland* (hypophysis cerebri), is a small, flattened, reddish-grey body situated in the sella turcica, and closely retained in that situation by the dura mater and arachnoid. It consists of two lobes, closely pressed together, the anterior lobe being the larger of the two, and oblong in shape, the posterior round. Both lobes are connected with the infundibulum, but the latter is so soft in texture as to be generally torn through in the removal of the brain. Indeed, for the purposes of the student, it is better to effect this separation with the knife, and leave the pituitary body in situ, to be examined with the base of the cranium.

The *Corpora albicantia* (mammillaria, pisiformia, bulbi fornicis) are two white convex bodies, having the shape and size of peas, situated behind the tuber cinereum, and between the crura cerebri. They are a part of the crura of the fornix, which, after their origin from the thalami optici, descend to the base of the brain, and making a sudden curve upon themselves previously to their ascent to the lateral ventricles, constitute the corpora albicantia. When divided by section, these bodies will be found to be composed of a capsule of white substance, containing grey matter, the grey matter of the two corpora being connected by means of a commissure.

Fig. 172.\*



The *Locus perforatus* is a layer of whitish-grey substance, connected in front with the corpora albicantia, behind with the pons Varolii, and on each side with the crura cerebri, between which it is situated. It is perforated by several thick tufts of arteries, which are distributed to the thalami optici and third ventricle, of which latter it assists in forming the floor. It is sometimes called the pons Tarini.

The *Crura cerebri* are two thick white cords, which issue from the anterior border of the pons Varolii, and diverge to each side to enter the thalami optici. By their outer side the crura cerebri are continuous with the corpora quadrigemina, and, above, they constitute the lower boundary of the aqueduct of

\* The under surface or base of the brain. 1. The anterior lobe of one hemisphere of the cerebrum. 2. The middle lobe. 3. The posterior lobe almost concealed by (4) the hemisphere of the cerebellum. 5. The pyramidal lobe of the inferior vermiform process of the cerebellum. 6. The pneumogastric lobule. 7. The longitudinal fissure. 8. The olfactory nerves, with their bulbous expansions. 9. The substantia perforata at the inner termination of the fissure of Sylvius; the three roots of the olfactory nerve are seen upon the substantia perforata. The commencement of the transverse fissure on each side is concealed by the inner border of the middle lobe. 10. The commissure of the optic nerves; the numeral is placed between the optic nerves as they diverge from the commissure, and rests upon the lamina cinerea of the corpus callosum. 11. The

Sylvius. In their interior they contain grey matter, which has a semilunar shape when the crus is divided transversely, and has been termed the *locus niger*. The third nerve will be observed to arise from the inner side of each, and the fourth nerves wind around their outer border from above.

The *Pons Varolii*\* (protuberantia annularis, nodus encephali), is the broad transverse band of white fibres which arches like a bridge across the upper part of the medulla oblongata; and, contracting on each side into a thick rounded cord, enters the substance of the cerebellum under the name of crus cerebelli. There is a groove along its middle which lodges the basilar artery. The pons Varolii is the commissure of the cerebellum, and associates the two lateral lobes in their common function. Resting against the pons, near its posterior border, is the sixth pair of nerves. On the anterior border of the crus cerebelli, at each side, is the thick bundle of filaments belonging to the fifth nerve, and, lying against its posterior border, the seventh pair of nerves. The upper surface of the pons forms a part of the floor of the fourth ventricle.

## MEDULLA OBLONGATA.

The medulla oblongata (bulbus rachidicus), is the upper enlarged portion of the spinal cord. It is somewhat conical in shape, and a little more than an inch in length, extending from the pons Varolii to a point corresponding with the upper border of the atlas. On the middle line, in front and behind, the medulla oblongata is marked by two vertical fissures, the *fissura longitudinalis anterior* and *posterior*, which divide it superficially into two symmetrical lateral cords or columns; whilst each lateral column is subdivided by minor grooves into three smaller cords, namely, the *corpora pyramidalia*, *corpora olivaria*, and *corpora restiformia*.

The *Corpora pyramidalia* are two narrow convex cords, tapering slightly from above downwards, and situated one on either side of the *fissura longitudinalis anterior*. At about an inch below the pons the *corpora pyramidalia* communicate very freely across the fissure by a decussation of their fibres, and at their point of entrance into the pons they are constricted into round cords. The *fissura longitudinalis* is somewhat enlarged by this constriction, and the enlarged space has received the name of *foramen cæcum* of the medulla oblongata.

The *Corpora olivaria* (named from some resemblance to the shape of an olive), are two oblong, oval-shaped, convex bodies, of about the same breadth with the *corpora pyramidalia*, about half an inch in length, and

tuber cinereum, from which the infundibulum is seen projecting. 12. The *corpora albicantia*. 13. The *locus perforatus*, bounded on each side by the *crura cerebri*, and by the third nerve. 14. The pons Varolii. 15. The crus cerebelli of one side. 16. The fifth nerve emerging from the anterior border of the crus cerebelli; the small nerve by its side is the fourth. 17. The sixth pair of nerves. 18. The seventh pair of nerves consisting of the auditory and facial. 19. The *corpora pyramidalia* of the medulla oblongata; the corpus olivare and part of the corpus restiforme are seen at each side. Just below the numeral is the decussation of the fibres of the *corpora pyramidalia*. 20. The eighth pair of nerves. 21. The ninth or hypoglossal nerve. 22. The anterior root of the first cervical spinal nerve.

\* Constant Varolius, Professor of Anatomy in Bologna: died in 1578. He dissected the brain in the course of its fibres, beginning from the medulla oblongata; a plan which has since been perfected by Vieussens, and by Gall and Spurzheim. The work containing his mode of dissection, "*De Resolutione Corporis Humani*," was published after his death, in 1591.

somewhat larger above than below. The corpus olivare is situated immediately external to the corpus pyramidale, from which, and from the corpus restiforme, it is separated by a well-marked groove. In this groove some longitudinal fibres are seen which enclose the base of the corpus olivare, and have been named *funiculi siliquæ*, those which lie to its inner side being the funiculus internus, and those to its outer side the funiculus externus. Besides these there are other fibres which cross the corpus olivare obliquely, these are the *fibræ arciformes*. When examined by section (Fig. 175), the corpus olivare is found to be a ganglion deeply embedded in the medulla oblongata, and meeting its fellow at the middle line behind the corpus pyramidale. The ganglion of the corpus olivare (corpus dentatum, nucleus olivæ), like that of the cerebellum, is a yellowish-grey dentated capsule, open behind, and containing medullary substance from which a fasciculus of fibres proceeds upwards to the corpora quadrigemina and thalami optici. The nervous filaments which spring from the groove on the anterior border of the corpus olivare, are those of the hypoglossal nerve; and those on its posterior border are the glosso-pharyngeal and pneumogastric.

The *Corpora restiformia* (restis, a rope), comprehend the whole of the posterior half of each lateral column of the medulla oblongata. They are separated from the corpora olivaria by the grooves already spoken of; posteriorly they are divided from each other by the fissura longitudinalis posterior and by the fourth ventricle, and superiorly they diverge and curve backwards to enter the cerebellum, and constitute its inferior peduncles. Along the posterior border of each corpus restiforme, and marked off from that body by a groove, is a narrow white cord, separated from its fellow by the fissura longitudinalis posterior. This pair of narrow cords are termed the *posterior median columns* or fasciculi (*funiculi graciles*). Each fasciculus forms an enlargement (*processus clavatus*) at its upper end, and is then lost in the corresponding corpus restiforme. The *processus clavati* are the lateral boundaries of the nib of the calamus scriptorius. The corpus restiforme is crossed near its entrance into the cerebellum, by the auditory nerve, the choroid plexus of the fourth ventricle, and the pneumogastric lobule.

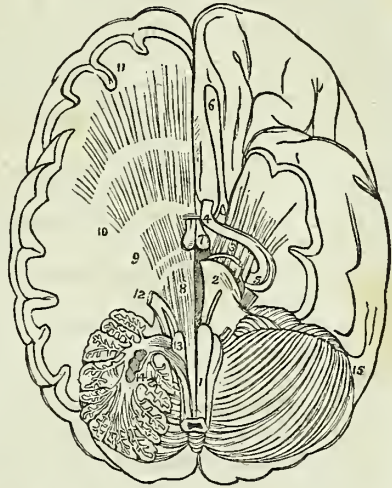
The remaining portion of the medulla oblongata visible from the exterior, are the two slightly convex columns which enter into the formation of the floor of the fourth ventricle. These columns are the *funiculi teretes* or posterior pyramids.

**DIVERGING FIBRES.**—The fibres composing the columns of the medulla oblongata have a special arrangement on reaching the upper part of that body, those of the corpora pyramidalia and olivaria enter the pons Varolii, and are thence prolonged through the crura cerebri, thalami optici, and corpora striata to the cerebral hemispheres; but those of the corpora restiformia are reflected backwards into the cerebellum and form its inferior peduncles.

From pursuing this course, and spreading out as they advance, these fibres have been termed by Gall the *diverging fibres*. While situated within the pons, the fibres of the *corpus pyramidale* and *olivare* separate and spread out, and have grey substance interposed between them; and they quit the pons much increased in number and bulk, so as to form the *crus cerebri*. The fibres of the *crus cerebri* again are separated in the thalamus opticus, and are intermingled with grey matter, and they also

quit that body greatly increased in number and bulk. Precisely the same change takes place in the corpus striatum, and the fibres are now so extraordinarily multiplied as to be capable of forming a large proportion of the hemispheres.

Fig. 173.\*



Observing this remarkable increase in the white fibres, apparently from the admixture of grey substance, Gall and Spurzheim considered the latter as the material of increase or formative substance to the white fibres, and they are borne out in this conclusion by several collateral facts, among the most prominent of which is the great vascularity of the grey substance; and the larger proportion of the nutrient fluid circulating through it is fully capable of effecting the increased growth and nutrition of the structures by which it is surrounded. For a like reason, the bodies in which this grey

substance occurs, are called by the same physiologists "*ganglia of increase*," and by other authors simply ganglia. Thus the thalami optici and corpora striata are the ganglia of the cerebrum; or, in other words, the *formative ganglia* of the hemispheres.

The fibres of the corpora pyramidalia are not all of them destined to the course above described; several fasciculi curve outwards to reach the corpora restiformia, some passing in front and some behind the corpus olivare on each side. These are the *arciform fibres*, and they are distinguished by Mr. Solly into the *superficial* and *deep cerebellar fibres*. In the pons Varolii the continued or cerebral fibres (Solly) of the corpus pyramidalia are placed between the superficial and deep layers of transverse fibres, and escaping from the pons, constitute the inferior and inner segment of the crus cerebri. From the crus cerebri they pass for the most part beneath the thalami optici into the corpora striata.

\* The base of the brain, upon which several sections have been made, showing the distribution of the diverging fibres. 1. The medulla oblongata. 2. One half of the pons Varolii. 3. The crus cerebri crossed by the optic nerve (4) and spreading out into the hemisphere to form the corona radiata. 5. The optic nerve near its origin; the nerves about the crus cerebri and cerebelli are the same as in the preceding figure. 6. The olfactory nerve. 7. The corpora albicantia. On the right side a portion of the brain may be removed to show the distribution of the diverging fibres. 8. The fibres of the corpus pyramidale passing through the substance of the pons Varolii. 9. The fibres passing through the thalamus opticus. 10. The fibres passing through the corpus striatum. 11. Their distribution to the hemisphere. 12. The fifth nerve; its two roots may be traced, the one forwards to the fibres of the corpus pyramidale, the other backwards to the fasciculi teretes. 13. The fibres of the corpus pyramidale which pass outwards with the corpus restiforme into the substance of the cerebellum; these are the arciform fibres of Solly. The fibres referred to are those below the numeral, the numeral itself rests upon the corpus olivare. 14. A section through one of the hemispheres of the cerebellum, showing the corpus rhomboideum in the centre of its white substance; the arbor vitae is also seen. 15. The opposite hemisphere of the cerebellum

The fibres which enclose the corpus olivare, under the name of fasciculi siliquæ, are separated by that body into two bands; the innermost of the two bands, *funiculus siliquæ internus*, accompanies the fibres of the corpus pyramidale into the crus cerebri. The *funiculus siliquæ externus* unites with a fasciculus proceeding from the nucleus olivæ, and the combined column ascending behind the crus cerebelli divides into a superior and an inferior band. The inferior band proceeds with a fasciculus presently to be described, the fasciculus innominatus, into the upper segment of the crus cerebri. The superior band (laqueus) ascends by the side of the processus e cerebello ad testes, and, crossing the latter obliquely, enters the corpora quadrigemina, in which many of its fibres are distributed, while the rest are continued onwards into the thalamus opticus.

The corpora restiformia derive their fibres from the anterior as well as from the posterior columns of the medulla oblongata; they diverge as they approach the cerebellum, and leaving behind them the cavity of the fourth ventricle, enter the substance of the cerebellum, under the form of two rounded cords. These cords envelope the corpora rhomboidea, or ganglia of increase, and then expand on all sides so as to constitute the cerebellum.

Besides the fibres here described, there are, in the interior of the medulla oblongata, behind the corpora olivaria, and more or less apparent between these bodies and the corpora restiformia, two large bundles of fibres, the *fasciculi innominata*. These fasciculi ascend behind the deep transverse fibres of the pons Varolii, and become apparent in the floor of the fourth ventricle, under the name of fasciculi teretes, or posterior pyramids. From this point they are prolonged upwards beneath the corpora quadrigemina into the crura cerebri, of which they form the upper and outer segment, and are thence continued through the thalami optici and corpora striata into the hemispheres. The locus niger of the crus cerebri is a septum of grey matter interposed between these fasciculi and those of the corpora pyramidalia.

CONVERGING FIBRES.—In addition to the diverging fibres which are thus shown to constitute both the cerebrum and cerebellum, by their increase and development, another set of fibres are found to exist, which have for their office the association of the symmetrical halves and distant parts of the same hemispheres.

These are called, from their direction, *converging fibres*, and from their office, *commissures*. The commissures of the cerebrum and cerebellum are the—

Corpus callosum,  
Fornix,  
Septum lucidum,  
Anterior commissure,  
Middle commissure,  
Posterior commissure,  
Peduncles of the pineal gland,  
Pons Varolii.

The *Corpus callosum* is the commissure of the hemispheres. It is therefore of moderate thickness in the middle, where its fibres pass directly from one hemisphere to the other; thicker in front (genu), where the anterior lobes are connected; and thickest behind (splenium), where

the fibres from the posterior lobes are assembled. The fibres which curve backwards into the posterior lobes from the splenium of the corpus callosum have been termed *forceps*, those which pass directly outwards into the middle lobes from the same point, *tapetum*, and those which curve forwards and inwards from the genu to the anterior lobes, *forceps anterior*.

The *Fornix* is an antero-posterior commissure, and serves to connect a number of parts. Below, it is associated with the thalami optici; on each side, by means of the corpora fimbriata, with the middle lobes of the brain; and, above, with the corpus callosum, and consequently with the hemispheres.

The *Septum lucidum* is a perpendicular commissure between the fornix and corpus callosum.

The *Anterior commissure* traverses the corpus striatum, and connects the anterior and middle lobes of opposite hemispheres.

The *Middle commissure* is a layer of grey substance, uniting the thalami optici.

The *Posterior commissure* is a white rounded cord, connecting the thalami optici.

The *Peduncles of the pineal gland* must also be regarded as commissures, assisted in their function by the grey substance of the gland.

The *Pons Varolii* is the commissure to the two hemispheres of the cerebellum. It consists of transverse fibres, which are split into two layers by the passage of the fasciculi of the corpora pyramidalia and corpora olivaria. These two layers, the superior and inferior, are collected together on each side, in the formation of the crura cerebelli.

## SPINAL CORD.

The dissection of the spinal cord requires that the spinal column should be opened through its entire length by sawing through the laminæ of the vertebræ, close to the roots of the transverse processes, and raising the arches with a chisel; the muscles of the back having been removed as a preliminary step.

The *Spinal column* contains the *spinal cord*, or medulla spinalis; the *roots of the spinal nerves*; and the membranes of the cord, viz. the *dura mater*, *arachnoid*, *pia mater*, and *membrana dentata*.

The *Dura mater spinalis* (*theca vertebralis*) is a cylindrical sheath of fibrous membrane, identical in structure with the dura mater of the skull, and continuous with that membrane. At the margin of the occipital foramen it is closely adherent to the bone; by its anterior surface it is attached to the posterior common ligament, and below, by means of its pointed extremity, to the coccyx. In the rest of its extent it is comparatively free, being connected, by a very loose areolar tissue only, to the walls of the spinal canal. In this areolar tissue there exists a quantity of reddish, oily, adipose substance, somewhat analogous to the marrow of long bones. On either side and below, the dura mater forms a sheath for each of the spinal nerves, to which it is closely adherent. Upon its inner surface it is smooth, being lined by the arachnoid; and on its sides may be seen double openings for the two roots of each of the spinal nerves.

The *Arachnoid* is a continuation of the serous membrane of the brain. It encloses the cord very loosely, being connected to it only by long

slender filaments\* of areolar tissue, and by a longitudinal lamella which is attached to the posterior aspect of the cord. The areolar tissue is most abundant in the cervical region, and diminishes in quantity from above downwards; and the longitudinal lamella is complete only in the dorsal region. The arachnoid passes off from the cord on either side with the spinal nerves, to which it forms a sheath; and is then reflected on the dura mater, to constitute its serous surface. A connexion exists in several situations between the arachnoid of the cord and that of the dura mater. The space between the arachnoid and the spinal cord is identical with that already described as existing between the same parts in the brain, the *sub-arachnoidean space*. It is occupied by a serous fluid, sufficient in quantity to expand the arachnoid, and fill completely the cavity of the theca vertebralis. The *sub-arachnoidean fluid* keeps up a constant and gentle pressure on the entire surface of the brain and spinal cord, and yields with the greatest facility to the various movements of the cord, giving to those delicate structures the advantage of the principles so usefully occupied by Dr. Arnott in the hydrostatic bed.

The *Pia mater* is the immediate investment of the cord; and, like the other membranes, is continuous with that of the brain. It is not, however, like the pia mater cerebri, a vascular membrane; but is dense and fibrous in structure, and contains but few vessels. It invests the cord closely, and sends a duplicature into the fissura longitudinalis anterior, and another, extremely delicate, into the fissura longitudinalis posterior. It forms a sheath for each of the filaments of the nerves, and for the nerves themselves; and, inferiorly, at the conical termination of the cord, is prolonged downwards as a slender ligament (*filum terminale*), which descends through the centre of the cauda equina, and is attached to the dura mater lining the canal of the coccyx. This attachment is a rudiment of the original extension of the spinal cord into the canal of the sacrum and coccyx. The pia mater has, distributed to it, a number of nervous plexuses derived from the sympathetic.

The *Membrana dentata* (ligamentum dentatum) is a thin process of pia mater sent off from each side of the cord throughout its entire length, and separating the anterior from the posterior roots of the spinal nerves. The number of serrations on each side is about twenty, the first being situated on a level with the occipital foramen, and having the vertebral artery and hypoglossal nerve passing in front and the spinal accessory nerve behind it, and the last opposite the first or second lumbar vertebra. Below this point, the membrana dentata is lost in the filum terminale of the pia mater. The use of this membrane is to maintain the position of the spinal cord in the midst of the fluid by which it is surrounded.

The *Spinal cord* of the adult extends from the pons Varolii to opposite the first or second lumbar vertebra, where it terminates in a rounded point; in the child, at birth, it reaches to the middle of the third lumbar vertebra, and in the embryo is prolonged as far as the coccyx. It presents a difference of diameter in different parts of its extent, and exhibits three enlargements. The uppermost of these is the *medulla oblongata*; the next corresponds with the origin of the nerves destined to the upper extremities; and the lower enlargement is situated near its termination,

\* According to Mr. Rainey, these filaments are nervous fasciculi, having their origin in the arachnoid, and passing to the arteries of the cord. See page 371.



and corresponds with the attachment of the nerves which are intended for the supply of the lower limb.

In form, the spinal cord is a flattened cylinder, and presents on its anterior surface a fissure, which extends into the cord to the depth of one-third of its diameter. This is the *fissura longitudinalis anterior*. If the sides of the fissure be gently separated, they will be seen to be connected at the bottom by a layer of medullary substance, the anterior commissure.

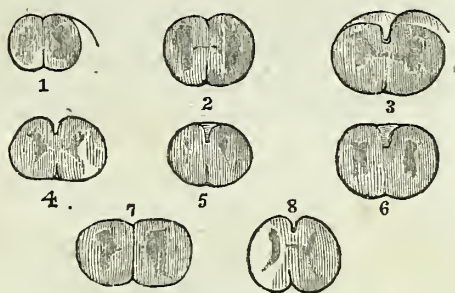
On the posterior surface another fissure exists, which is so narrow between the second cervical and second lumbar nerve, as to be hardly perceptible. This is the *fissura longitudinalis posterior*. It extends more deeply into the cord than the anterior fissure, and terminates in the grey substance of the interior. These two fissures divide the medulla spinalis into two lateral cords, which are connected to each other by the white commissure which forms the bottom of the anterior longitudinal fissure, and by a commissure of grey matter situated behind the former. On either side of the *fissura longitudinalis posterior* is a slight line which bounds on each side the posterior median columns. These columns are most apparent at the upper part of the cord, near the fourth ventricle, where they are separated by the point of the calamus scriptorius, and where they form the bulbous enlargement at each side, called *processus clavatus*.

Two other lines are observed on the medulla, the anterior and posterior lateral sulci, corresponding with the attachment of the anterior and posterior roots of the spinal nerves. The *anterior lateral sulcus* is a mere trace, marked only by the attachment of the filaments of the anterior roots. The *posterior lateral sulcus* is more evident, and is a narrow greyish line derived from the grey substance of the interior.

Although these fissures and sulci indicate a division of the spinal cord into three pairs of columns, namely, anterior, lateral, and posterior, the posterior median columns being regarded as a part of the posterior columns, it is customary to consider each half of the spinal cord as consisting of two columns only, the antero-lateral and the posterior. The *antero-lateral columns* are the columns of motion, and comprehend all that part of the cord situated between the *fissura longitudinalis anterior* and the posterior lateral sulcus, the grey line of origin of the posterior roots of the spinal nerves. The *posterior columns* are the columns of sensation.

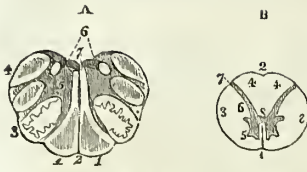
If a transverse section of the spinal cord be made, its internal structure may be seen and examined. It will then appear to be composed of two hollow cylinders of white matter, placed side by side, and connected by a narrow white commissure. Each cylinder is filled with grey substance,

Fig. 174.\*



\* Sections of the spinal marrow in different portions of its length. 1. Opposite the 11th dorsal vertebra. 2. Opposite the 10th dorsal. 3. Opposite the 8th dorsal. 4. Opposite the 5th dorsal. 5. Opposite the 7th cervical. 6. Opposite the 4th cervical. 7. Opposite the 3d cervical. 8. Section of medulla oblongata through the corpora olivaria.

Fig. 175.\*



which is connected by a commissure of the same matter. The form of the grey substance, as observed in the section, is that of two irregularly curved lines joined by a transverse band. The extremities of the curved lines correspond to the sulci of origin of the anterior and posterior roots of the nerves. The anterior extremities, larger than the posterior, do not quite reach this surface; but the posterior appear upon the surface, and form a narrow grey line, the sulcus lateralis posterior.

The white substance of the spinal cord is composed of parallel fibres, which are collected into longitudinal laminae and extend throughout the entire length of the cord. These laminae are various in breadth, and are arranged in a radiated manner; one border being thick and corresponding with the surface of the cord, while the other is thin and lies in contact with the grey substance of the interior. According to Rolando the white substance constitutes a simple nervous membrane, which is folded into longitudinal plaits, having the radiated disposition above described. The anterior commissure, according to his description, is merely the continuation of this nervous membrane from one lateral cord across the middle line to the other. Moreover, Rolando considers that a thin lamina of pia mater is received between each of the folds from the exterior, while a layer of the grey substance is prolonged between them from within. Cruveilhier is of opinion that each lamella is completely independent of its neighbours, and he believes this statement to be confirmed by pathology, which shows that a single lamella may be injured or atrophied, and at the same time be surrounded by others perfectly sound.

#### CRANIAL NERVES.

There are *nine pairs* of cranial nerves. Taken in their order from before, backwards, they are as follows:

- 1st. Olfactory.
- 2d. Optic.
- 3d. Motores oculorum.
- 4th. Pathetici (trochleares).
- 5th. Trifacial (trigemini).
- 6th. Abducentes.
- 7th. { Facial (portio dura,  
Auditory (portio mollis).

\* Sections of the spinal cord. After Arnold. A. A section made across the lower part of the corpora olivaria. 1, 1. Corpora pyramidalia. 2. Fissura longitudinalis anterior. 3. The corpus olivare; in the section of which the zig-zag outline of the corpus dentatum is seen. 4. The corpus restiforme. 5. The grey substance of the corpus restiforme. 6. The corpora pyramidalia posteriora. 7. The floor of the fourth ventricle.

B. A section made between the third and fourth cervical nerves. 1. The fissura longitudinalis anterior. 2. An indentation corresponding in situation with the fissura longitudinalis posterior, which latter is not distinguishable at this part of the spinal cord. 3, 3. The antero-lateral columns of the spinal cord. 4, 4. The posterior columns. 5. The anterior cornu of grey matter. 6. Its posterior cornu, terminating at 7, the sulcus lateralis posterior. 8. The isthmus connecting the grey matter of the two sides of the cord.

- 8th. { Glosso-pharyngeal,  
Pneumogastric (vagus, par vagum).  
Spinal accessory.  
9th. Hypoglossal (lingual).

Functionally or physiologically the cranial nerves admit of division into three groups, namely, nerves of special sense, nerves of motion, and compound nerves, that is, nerves which contain fibres both of sensation and motion. The nerves belonging to these groups are the following :

|                         |                                                                                                     |
|-------------------------|-----------------------------------------------------------------------------------------------------|
| Special sense . . . . . | { 1st. Olfactory.<br>2d. Optic.<br>7th. Auditory.                                                   |
| Motion . . . . .        | { 3d. Motores oculorum.<br>4th. Pathetici.<br>6th. Abducentes.<br>7th. Facial.<br>9th. Hypoglossal. |
| Compound . . . . .      | { 5th. Trifacial.<br>8th. Glosso-pharyngeal.<br>Pneumogastric.<br>Spinal accessory.                 |

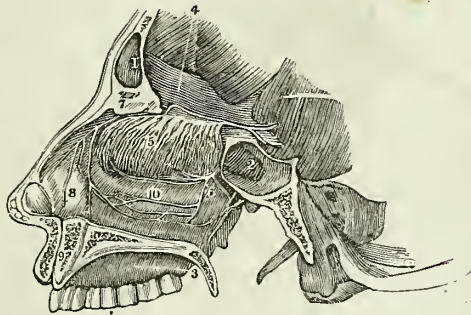
The fourth, facial, and eighth nerves were considered by Sir Charles Bell to form a system apart from the rest, and to be allied in the functions of expression and respiration. In consonance with this view he termed them *respiratory nerves*, and he gave to that part of the medulla oblongata from which they arise the name of *respiratory tract*.

FIRST PAIR. OLFACTORY.

—The olfactory nerve arises by three roots ; an *inner root* from the substantia perforata, a *middle root* from a papilla of grey matter (caruncula mammillaris), embedded in the anterior lobe, and an *external root*, which may be traced as a white streak along the fissure of Sylvius into the corpus striatum, where it is continuous with some of the fibres of the anterior commissure. The nervous cord

formed by the union of these three roots is soft in texture, prismoid in shape, and embedded in a sulcus between two convolutions on the under surface of each anterior lobe of the brain, lying between the pia mater and the arachnoid. As it passes forwards it increases in breadth and swells at its extremity,

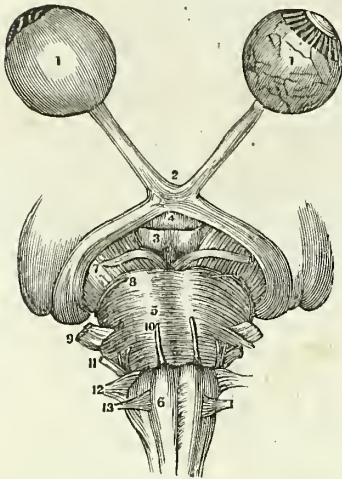
Fig. 176.\*



\* A view of the 1st pair or olfactory, with the nasal branches of the 5th. 1. Frontal sinus. 2. Sphenoidal sinus. 3. Hard palate. 4. Bulb of the olfactory nerve. 5. Branches of the olfactory on the superior and middle turbinated bones. 6. Spheno-palatine nerves from the 2d of the 5th. 7. Internal nasal nerve from the 1st of the 5th. 8. Branches of 7, to Schneiderian membrane. 9. Ganglion of Cloquet in the *foramen incisivum*. 10. Anastomosis on the inferior turbinated bone of the branches of the 5th pair

into an oblong mass of grey and white substance, the *bulbus olfactorius*, which rests upon the cribriform lamella of the ethmoid bone. From the

Fig. 177.\*

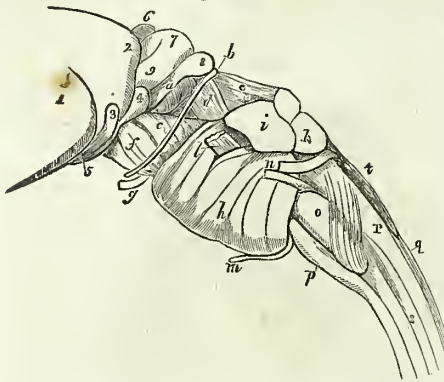


under surface of the bulbous olfactories are given off the nerves which pass through the cribriform foramina and supply the mucous membrane of the nares; they are arranged into two groups, an inner group, reddish in colour and soft, which spread out upon the septum narium, and an outer group, whiter and more firm, which descend through the bony canals in the outer wall of the nares, and are distributed upon the superior and middle turbinated bones.

**SECOND PAIR. OPTIC.**—The optic nerve, a nerve of large size, arises from the corpora geniculata on the posterior and inferior aspect of the thalamus opticus and from the nates. Proceeding from this origin it winds around the crus cerebri as a flattened

band, under the name of *tractus opticus*, and joins with its fellow in front of the tuber cinereum to form the *optic commissure* (chiasma). The tractus opticus is united with the crus cerebri and tuber cinereum, and is covered in by the pia mater; the commissure is also connected with the tuber cinereum, from which it receives fibres, and the nerve beyond the commissure diverges from its fellow, becomes rounded in form, and is enclosed in a sheath derived from the arachnoid. In passing through the optic foramen the optic nerve receives a sheath from the dura mater, which splits at this point into two layers; one, which becomes the periosteum of the

Fig. 178.†



\* A view of the 2d pair or optic, and the origins of seven other pairs. 1. 1. Globe of the eye, the one on the left hand is perfect, but that on the right has the sclerotic and choroid removed to show the retina. 2. The chiasm of the optic nerves. 3. The corpora albicantia. 4. The infundibulum. 5. The pons Varolii. 6. The medulla oblongata. The figure is on the right corpus pyramidale. 7. The 3d pair, motores oculi. 8. 4th pair, pathetici. 9. 5th pair, trigemini. 10th. 6th pair, abducentes. 11. 7th pair, auditory and facial. 12th. 8th pair, pneumogastric, spinal accessory, and glosso-pharyngeal. 13. 9th pair, hypoglossal.

† The isthmus encephali, showing the thalamus opticus, corpora quadrigemina, pons Varolii, and medulla oblongata, as viewed from the side. 1. The thalamus opticus. 2. The posterior prominence of this body, tuberculum superius posterius or pulvinar. 3. The corpus geniculatum externum. 4. The corpus geniculatum internum. 5. The commencement of the tractus opticus. 6. The pincal gland. 7. The nates. 8. The

orbit; the other, the one in question, which forms a sheath for the nerve, and is lost in the sclerotic coat of the eyeball. After a short course within the orbit the optic nerve pierces the sclerotic and choroid coats and expands into the nervous membrane of the eyeball, the retina. Near the globe, the nerve is pierced by a small artery, the *arteria centralis retinae*, which runs through the central axis of the nerve and reaches the internal surface of the retina, to which it distributes branches.

The commissure rests upon the *processus olivaris* of the sphenoid bone; it is bounded by the *lamina cinerea* of the *corpus callosum* in front, by the *substantia perforata* on each side, and by the *tuber cinereum* behind. Within the commissure the innermost fibres of the optic nerves cross each other to pass to opposite eyes, while the outer fibres continue their course uninterruptedly to the eye of the corresponding side. The *neurilemma* of the commissure, as well as that of the nerves, is formed by the *pia mater*.

**THIRD PAIR. MOTORES OCULORUM.**—The *motor oculi*, a nerve of moderate size, arises from the inner side of the *crus cerebri*, close to the *pons Varolii*, and passes forward between the posterior cerebral and superior cerebellar artery. It pierces the *dura mater* immediately in front of the posterior clinoid process; descends obliquely along the external wall of the cavernous sinus; and divides into two branches which enter the orbit between the two heads of the external rectus muscle. The *superior* branch ascends, and supplies the superior rectus and levator palpebræ. The *inferior* sends a branch beneath the optic nerve to the internal rectus, another to the inferior rectus, and a long branch to the inferior oblique muscle. From the latter a short thick branch is given off to the ciliary ganglion, forming its inferior root.

The fibres of origin of this nerve may be traced into the grey substance of the *crus cerebri*,\* into the motor tract,† and as far as the superior fibres of the *crus cerebri*.‡ In the cavernous sinus it receives one or two filaments from the cavernous plexus, and one from the ophthalmic nerve.

**FOURTH PAIR. PATHETICI (trochlearis).**—The fourth is the smallest cerebral nerve; it arises from the valve of *Viessens* close to the testis, and winding around the *crus cerebri* to the extremity of the petrous portion of the temporal bone, pierces the *dura mater* near the oval opening for the

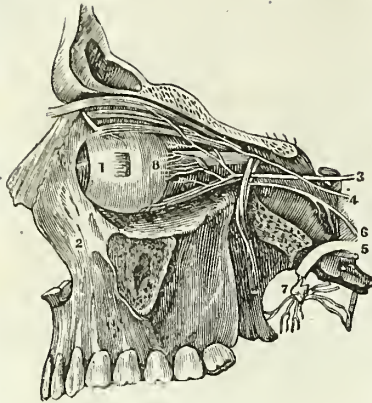testis of one side. 9. The *brachium anterius* of the *corpora quadrigemina*. a. The *brachium posterius*. b. The origin of the fourth nerve, which may be seen descending over the *crus cerebri*. c. The *processus e cerebello ad testem*, or superior peduncle of the cerebellum. d. The band of fibres termed *laqueus*, the superior division of the *fasciculus olivaris* crossing the superior peduncle of the cerebellum to enter the *corpora quadrigemina*. Through the small triangular space in front of this band, crossed by the fourth nerve, some of the fibres of the superior peduncle of the cerebellum may be seen. e. The superior portion of the *crus cerebri*, termed *tegmentum*. f. Its inferior portion. g. The third nerve. h. The *pons Varolii*. i. The *crus cerebelli*, or middle peduncle of the cerebellum. k. The inferior peduncle derived from the *corpus restiforme*. The mass lying in the angular interval upon these is the superior peduncle. l. The fifth nerve issuing from between the transverse fasciculi of the *pons Varolii*. m. The sixth nerve. n. The seventh nerve; the inferior and smaller cord is the facial nerve, the superior and larger the auditory. o. The *corpus olivare* crossed inferiorly by the superficial arciform fibres. p. The *corpus pyramidale*. q. The median posterior fasciculi of the *medulla oblongata*. r. The *corpus restiforme*. s. The spinal cord. t. The fourth ventricle.

\* Mayo.

† Solly.

‡ Grainger.

Fig. 179.\*



fifth nerve, and passes along the outer wall of the cavernous sinus to the sphenoidal fissure. In its course through the sinus it is situated at first below the motor oculi, but afterwards ascends and becomes the highest of the nerves which enter the orbit through the sphenoidal fissure. Upon entering the orbit the nerve crosses the levator palpebræ muscle near its origin, and is distributed upon the orbital surface of the superior oblique or trochlearis muscle; hence its synonym *trochlearis*.

*Branches.*—While in the cavernous sinus the fourth nerve gives off a recurrent branch, some filaments of communication to the ophthalmic nerve, and a branch to assist in forming the lachrymal nerve; the *recurrent branch*, which consists of sympathetic filaments derived from the carotid plexus, passes backwards between the layers of the tentorium, and divides into two or three filaments, which are distributed to the lining membrane of the lateral sinus. This nerve is sometimes a branch of the ophthalmic, and occasionally proceeds directly from the carotid plexus.

**FIFTH PAIR. TRIFACIAL (trigeminus).**—The fifth nerve, the great sensitive nerve of the head and face, and the largest cranial nerve, is analogous to the spinal nerves in its origin by two roots, from the anterior and posterior columns of the spinal cord, and in the existence of a ganglion on the posterior columns of the spinal cord, and in the existence of a ganglion on the posterior root. It arises† from a tract of yellowish-white matter situated in front of the floor of the fourth ventricle and the origin of the auditory nerve, and behind the crus cerebelli. This tract divides inferiorly into two fasciculi which may be traced downwards into the spinal cord, one being continuous with the fibres of the anterior column, the other with the posterior column. Proceeding from this origin the two roots of the nerve pass forward, and issue from the brain upon the anterior part of the crus cerebelli, where they are separated by a slight interval. The anterior is much smaller than the posterior, and the two together constitute the fifth nerve, which in this situation consists of seventy to a hundred filaments held together by pia mater. The nerve then passes through an oval opening in the border of the tentorium, near the extremity of the petrous bone, and spreads out into a large semilunar ganglion, the Casserian. If the ganglion be turned over, it will be seen that the anterior root lies against its under

\* A view of the 3d, 4th, and 6th pairs of nerves. 1. Ball of the eye, the rectus externus muscle being cut and hanging down from its origin. 2. The superior maxilla. 3. The third pair or motor oculi distributed to all the muscles of the eye except the superior oblique and external rectus. 4. The 4th pair or patheticus going to the superior oblique muscle. 5. One of the branches of the 5th. 6. The 6th pair or motor externus distributed to the external rectus muscle. 7. Spheno-palatine ganglion and branches. 8. Ciliary nerves from the lenticular ganglion, the short root of which is seen to connect it with the 3d pair.

† I have adopted the origin of this nerve, given by Dr. Alcock, of Dublin, as the result of his dissections, in the Cyclopædia of Anatomy and Physiology. Mr. Mayo also traces the anterior root of the nerve to a similar origin.

surface without having any connexion with it, and may be followed onwards to the inferior maxillary nerve. The Casserian ganglion divides into three branches, the ophthalmic, superior maxillary, and inferior maxillary.

The OPTHALMIC NERVE is a short trunk, being not more than three quarters of an inch in length; it arises from the upper angle of the Casserian ganglion, beneath the dura mater, and passes forwards through the outer wall of the cavernous sinus, lying externally to the other nerves; it divides into three branches. Previously to its division it receives several filaments from the carotid plexus, and gives off a small *recurrent nerve*, that passes backwards with the recurrent branch of the fourth nerve between the two layers of the tentorium to the lining membrane of the lateral sinus.

The *Branches* of the ophthalmic nerve are, the—

Frontal,

Lachrymal,

Nasal.

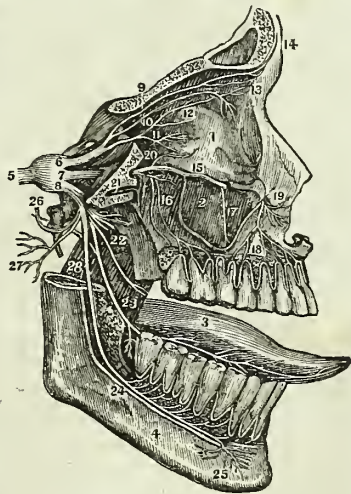
The *Frontal* nerve mounts above the levator palpebræ, and runs forward, resting upon that muscle, to the supra-orbital foramen, through which it escapes upon the forehead, with the supra-orbital artery. It supplies the conjunctiva and upper eyelid, and the integument of the cranium as far as the vertex.

The frontal nerve gives off but one small branch, the *supra-trochlear*, which passes inwards above the pulley of the superior oblique muscle, and ascends along the middle line of the forehead, distributing filaments to the integument, to the inner angle of the eye and root of the nose, and to the conjunctiva.

The *Lachrymal* nerve, the smallest of the three branches of the ophthalmic, receives a filament from the fourth nerve in the cavernous sinus, and passes outwards along the upper border of the external rectus muscle, and in company with the lachrymal artery, to the lachrymal gland, where it divides into two branches. The superior branch passes along the upper surface of the gland and through a foramen in the malar bone, and is distributed upon the temple and cheek, communicating with the subcutaneous malæ and facial nerves. The inferior branch supplies the lower surface of the gland and conjunctiva, and terminates in the integument of the upper lid communicating with the facial nerve.

The *Nasal* nerve (naso-ciliaris) passes forwards between the two heads of the external rectus muscle, crosses the optic nerve in company with the ophthalmic artery, and enters the anterior ethmoidal foramen immediately above the internal rectus. It then traverses the upper part of the ethmoid bone to the cribriform plate, and passes downwards through the slit-like opening by the side of the

Fig. 180.\*



\* A view of the distribution of the trifacial or 5th pair.—1. Orbit. 2. Antrum of Highmore. 3. Tongue. 4. Lower maxilla. 5. Root of 5th pair forming the ganglion of Casser. 6. 1st branch, Ophthalmic. 7. 2d branch, Superior maxillary. 8. 3d branch,

crista galli into the nose, where it divides into two branches—an *internal branch* supplying the mucous membrane, near the anterior openings of the nares; and an *external branch* which passes between the fibro-cartilages, and is distributed to the integument at the extremity of the nose.

The *Branches* of the nasal nerve within the orbit are, the ganglionic, ciliary, and infra-trochlear; in the nose it gives off one or two filaments to the anterior ethmoidal cells and frontal sinus. The *ganglionic branch* passes obliquely forwards to the superior angle of the ciliary ganglion, forming its superior long root. The *ciliary branches* are two or three filaments which are given off by the nasal as it crosses the optic nerve. They pierce the posterior part of the sclerotic, and pass between that tunic and the choroid to be distributed to the iris. The *infra-trochlear* is given off just as the nerve is about to enter the anterior ethmoidal foramen. It passes along the superior border of the internal rectus to the inner angle of the eye, where it communicates with the supra-trochlear nerve, and supplies the lachrymal sac, caruncula lachrymalis, conjunctiva, and inner angle of the orbit.

The SUPERIOR MAXILLARY NERVE, larger than the preceding, proceeds from the middle of the Casserian ganglion; it passes forwards through the foramen rotundum, crosses the spheno-maxillary fossa, and enters the canal in the floor of the orbit, along which it runs to the infra-orbital foramen. Emerging on the face, beneath the levator labii superioris muscle, it divides into a number of branches, which are distributed to the lower eyelid and conjunctiva, and to the muscles and integument of the upper lip, nose, and cheek, forming a plexus with the facial nerve.

The *Branches* of the superior maxillary nerve are divisible into three groups:—1. Those which are given off in the spheno-maxillary fossa. 2. Those in the infra-orbital canal; and 3. Those on the face. They may be thus arranged:

|                                |                                                                |
|--------------------------------|----------------------------------------------------------------|
| <i>Spheno-maxillary fossa,</i> | { Orbital,<br>Two from Meckel's ganglion,<br>Posterior dental. |
| <i>Infra-orbital canal,</i>    | { Middle dental,<br>Anterior dental.                           |
| <i>On the face,</i>            | { Muscular,<br>Cutaneous.                                      |

The *Orbital* branch (n. subcutaneus malæ) enters the orbit through the spheno-maxillary fissure, and divides into two branches, temporal and malar; the *temporal branch* ascends along the outer wall of the orbit, and, after receiving a branch from the lachrymal nerve, passes through a canal

Inferior maxillary. 9. Frontal branch, dividing into external and internal frontal at 14. 10. Lachrymal branch, dividing before entering the lachrymal gland. 11. Nasal branch. Just under the figure is the long root of the lenticular or ciliary ganglion, and a few of the ciliary nerves. 12. Internal nasal, disappearing through the anterior ethmoidal foramen. 13. External nasal. 14. External and internal frontal. 15. Infra-orbital nerve. 16. Posterior dental branches. 17. Middle dental branch. 18. Anterior dental nerve. 19. Terminating branches of infra-orbital, called labial and palpebral. 20. Subcutaneous malæ or orbitar branch. 21. Pterygoid or recurrent, from Meckel's ganglion. 22. Five anterior branches of 3d of 5th, being nerves of motion, and called masseter, temporal, pterygoid and buccal. 23. Lingual branch joined at an acute angle by the chorda tympani. 24. Inferior dental nerve terminating in, 25. Mental branches. 26. Superficial temporal nerve. 27. Auricular branches. 28. Mylo-hyoid branch.



in the malar bone and enters the temporal fossa; it then pierces the temporal muscle and fascia and is distributed to the integument of the temple and side of the forehead, communicating with the facial and anterior auricular nerve. In the temporal fossa it communicates with the deep temporal nerves. The *malar*, or inferior branch, takes its course along the lower angle of the outer wall of the orbit, and emerges upon the cheek through an opening in the malar bone, passing between the fibres of the orbicularis palpebrarum muscle. It communicates with branches of the infra-orbital and facial nerves.

The *Two branches* from Meckel's ganglion ascend from that body to join the nerve, as it crosses the sphenomaxillary fossa.

The *Posterior dental* branches pass through small foramina, in the posterior surface of the superior maxillary bone, and running forwards in the base of the alveolus, supply the posterior teeth and gums.

The *Middle* and *anterior dental* branches descend to the corresponding teeth and gums; the former beneath the lining membrane of the antrum, the latter through distinct canals in the walls of the bone. Previously to their distribution, the dental nerves form a plexus (superior maxillary plexus) in the outer wall of the superior maxillary bone immediately above the alveolus. From this plexus the filaments are given off which supply the pulps of the teeth, the gums, the mucous membrane of the floor of the nares, and the palate. Some gangliform masses have been described in connexion with this plexus, one being placed over the canine, and another over the second molar tooth.

The *Muscular* and *cutaneous branches* are the terminating filaments of the nerve; they supply the muscles, integument, and mucous membrane of the cheek, nose, and lip, and form an intricate plexus with branches of the facial nerve.

The INFERIOR MAXILLARY NERVE proceeds from the inferior angle of the Casserian ganglion; it is the largest of the three divisions of the fifth nerve, and is augmented in size by the anterior or motor root, which passes behind the ganglion, and unites with the inferior maxillary as it escapes through the foramen ovale. Emerging at the foramen ovale the nerve divides into two trunks, external and internal, which are separated from each other by the external pterygoid muscle.

The *External trunk*, into which may be traced nearly the whole of the motor root, immediately divides into five branches which are distributed to the muscles of the temporo-maxillary region; they are—

The *Masseteric*, which crosses the sigmoid notch with the masseteric artery to the masseter muscle. It sends a small branch to the temporal muscle, and a filament to the temporo-maxillary articulation.

*Temporal*; two branches passing between the upper border of the external pterygoid muscle and the temporal bone to the temporal muscle. Two or three filaments from these nerves pierce the temporal fascia, and communicate with the lachrymal, subcutaneous malæ, auricular and facial nerve.

*Buccal*; a large branch which pierces the fibres of the external pterygoid, to reach the buccinator muscle. This nerve sends filaments to the temporal and external pterygoid muscle, to the mucous membrane and integument of the cheek, and communicates with the facial nerve.

*Internal pterygoid*; a long and slender branch, which passes inwards to the internal pterygoid muscle, and gives filaments in its course to the tensor palati and tensor tympani. This nerve is remarkable from its connexion with the otic ganglion, to which it is attached.

The *Internal trunk* divides into three branches—

Gustatory,  
Inferior dental,  
Anterior auricular.

The GUSTATORY NERVE descends between the two pterygoid muscles to the side of the tongue, where it becomes flattened, and divides into numerous filaments, which are distributed to the papillæ and mucous membrane.

*Relations.*—It lies at first between the external pterygoid muscle and the pharynx, next between the two pterygoid muscles, then between the internal pterygoid and ramus of the jaw, and between the stylo-glossus muscle and the submaxillary gland; lastly, it runs along the side of the tongue, resting upon the hyo-glossus muscle, and covered in by the mylo-hyoideus and mucous membrane.

The gustatory nerve, while between the two pterygoid muscles, receives a branch from the inferior dental; lower down it is joined at an acute angle by the chorda tympani which passes downwards in the sheath of the gustatory to the submaxillary gland, where it unites with the submaxillary ganglion. On the hyo-glossus muscle some branches of communication are sent to the hypoglossal, and in the course of the nerve several small branches to the mucous membrane of the fauces, to the tonsils, submaxillary gland, Wharton's duct, and sublingual gland.

The INFERIOR DENTAL NERVE passes downwards with the inferior dental artery, at first between the two pterygoid muscles, and then between the internal lateral ligament and the ramus of the lower jaw, to the dental foramen. It then runs along the canal in the inferior maxillary bone, distributing branches (inferior maxillary plexus) to the teeth and gums, and divides into two terminal branches, incisive and mental. The *incisive* branch passes forwards, to supply the incisive teeth: the *mental* branch escapes through the mental foramen, to be distributed to the muscles and integument of the chin and lower lip, and to the mucous membrane of the latter, communicating with the facial nerve.

The inferior dental nerve gives off but one branch, the *mylo-hyoidean*, which leaves the nerve just as it is about to enter the dental foramen. This branch pierces the insertion of the internal lateral ligament, and descends along a groove in the bone to the inferior surface of the mylo-hyoid muscle, to which, and to the anterior belly of the digastricus, it is distributed.

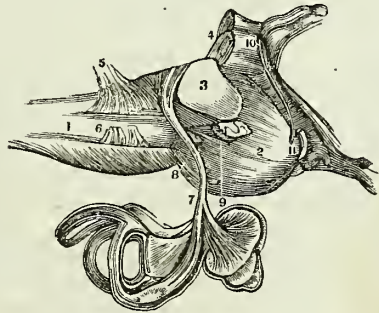
The ANTERIOR AURICULAR NERVE originates by two roots, between which the arteria meningeæ media takes its course, and passes directly backwards behind the articulation of the lower jaw, against which it rests. In this situation it divides into two branches, which reunite, and form a kind of plexus. From the plexus two branches are given off—ascending and descending. The *ascending* or *temporal branch* sends one or two considerable branches of communication to the facial nerve, and then ascends in front of the ear to the temporal region, upon which it is distri-

buted in company with the branches of the temporal artery. In its course it sends filaments to the temporo-maxillary articulation, to the pinna and meatus of the ear, and to the integument in the temporal region. It communicates on the temple with branches of the facial, supra-orbital, lachrymal, and subcutaneus malæ nerve. The *descending branch* enters the parotid gland, to which it sends numerous branches; it communicates with the inferior dental and auricularis magnus nerve, and supplies the external ear, the meatus auditorius, and the temporo-maxillary articulation, and sends one or two filaments into the tympanum.

**SIXTH PAIR. ABDUCENTES.**—The abducens nerve, about half the size of the motor oculi, arises by several filaments from the upper constricted part of the corpus pyramidale close to the pons Varolii. Proceeding forwards from this origin it lies parallel with the basilar artery, and, piercing the dura mater upon the clivus Blumenbachii of the sphenoid bone, ascends beneath that membrane to the cavernous sinus. It then runs forwards along the inner wall of the sinus below the other nerves, and, resting against the internal carotid artery, passes between the two heads of the external rectus, and is distributed to that muscle. As it enters the orbit, it lies upon the ophthalmic vein, from which it is separated by a lamina of dura mater. In the cavernous sinus it is joined by several filaments from the carotid plexus, by one from Meckel's ganglion, and one from the ophthalmic nerve. Mr. Mayo traced the origin of this nerve between the fasciculi of the corpora pyramidalia to the posterior part of the medulla oblongata; and Mr. Grainger pointed out its connexion with the grey substance of the spinal cord.

**SEVENTH PAIR.**—The seventh pair consists of two nerves which lie side by side on the posterior border of the crus cerebelli. The smaller and most internal of these, and, at the same time, the most dense in texture, is the facial nerve or portio dura. The external nerve, which is soft and pulpy, and often grooved by contact with the preceding, is the auditory nerve or portio mollis of the seventh pair. Soemmering makes the auditory nerve the eighth pair; but, retaining the classification of Willis, we regard it as a part of the seventh with the facial.

Fig. 181.\*



**FACIAL NERVE (portio dura).**—The facial nerve arises from the upper part of the groove between the corpus olivare and corpus restiforme, close to the pons Varolii, from which point its fibres may be traced deeply into the corpus restiforme. The nerve then passes forwards, resting upon the

\* A view of the origin and distribution of the portio mollis of the 7th pair or auditory nerve. 1. The medulla oblongata. 2. The pons Varolii. 3 and 4. The crura cerebelli of the right side. 5. 8th pair. 6. 9th pair. 7. The auditory nerve distributed to the cochlea and labyrinth. 8. The 6th pair. 9. The portio dura of the 7th pair. 10. The 4th pair. 11. The 3d pair.

crus cerebelli, and comes into relation with the auditory nerve, with which it enters the meatus auditorius internus, lying at first to the inner side of, and then upon that nerve. At the bottom of the meatus it enters the canal expressly intended for it, the aqueductus Fallopii, and directs its course forwards towards the hiatus Fallopii, where it forms a gangliform swelling (intumescencia gangliformis), and receives the petrosal branch of the Vidian nerve. It then curves backwards towards the tympanum, and descends along the inner wall of that cavity to the stylo-mastoid foramen. Emerging at the stylo-mastoid foramen it passes forwards within the parotid gland, crossing the external jugular vein and external carotid artery, and at the ramus of the lower jaw divides into two trunks, *temporo-facial* and *cervico-facial*. These trunks at once split into numerous branches, which, after forming a number of looped communications (pes anserinus) with each other over the masseter muscle, spread out upon the side of the face, from the temple to the neck, to be distributed to the muscles of this extensive region. The communications which the facial nerve maintains in its course are the following: in the meatus auditorius, it sends one or two filaments to the auditory nerve; the intumescencia gangliformis receives the nervus petrosus superficialis major and minor, and sends a twig back to the auditory nerve; behind the tympanum the nerve receives one or two twigs from the auricular branch of the pneumogastric; at its exit from the stylo-mastoid foramen it receives a twig from the glosso-pharyngeal, and in the parotid gland one or two large branches from the anterior auricular nerve. Besides these, the facial nerve has numerous peripheral communications, with the branches of the fifth nerve on the face, and of the cervical nerves in the parotid gland and neck. The numerous communications of the facial nerve obtained for it the designation of *nervus sympatheticus minor*.

The *Branches* of the facial nerve are—

|                                              |                                                      |
|----------------------------------------------|------------------------------------------------------|
| Within the aqueductus Fallopii,              | { Tympanic,<br>Chorda tympani.                       |
| After emerging at the stylo-mastoid foramen, | { Posterior auricular,<br>Stylo-hyoid,<br>Digastric. |
| On the face,                                 | { Temporo-facial,<br>Cervico-facial.                 |

The *Tympanic* branch is a small filament distributed to the stapedius muscle.

The *Chorda tympani* quits the facial just before that nerve emerges from the stylo-mastoid foramen, and ascends by a distinct canal to the upper part of the posterior wall of the tympanum, where it enters that cavity through an opening situated between the base of the pyramid and the attachment of the membrana tympani, and becomes invested by mucous membrane. It then crosses the tympanum between the handle of the malleus and long process of the incus to the anterior inferior angle of the cavity, and escapes through a distinct opening in the fissura Glaseri, and joins the gustatory nerve at an acute angle between the two pterygoid muscles. Enclosed in the sheath of the gustatory nerve, it descends to the submaxillary gland, where it unites with the submaxillary ganglion.

The *Posterior auricular* nerve ascends behind the ear, between the

meatus and mastoid process, and divides into an anterior and a posterior branch. The *anterior* branch receives a filament of communication from the auricular branch of the pneumogastric nerve, and distributes filaments to the retrahens and attollens aurem muscles and to the pinna. The *posterior* branch communicates with the auricularis magnus and occipitalis minor, and is distributed to the posterior belly of the occipito-frontalis.

The *Stylo-hyoid* branch is distributed to the stylo-hyoid muscle.

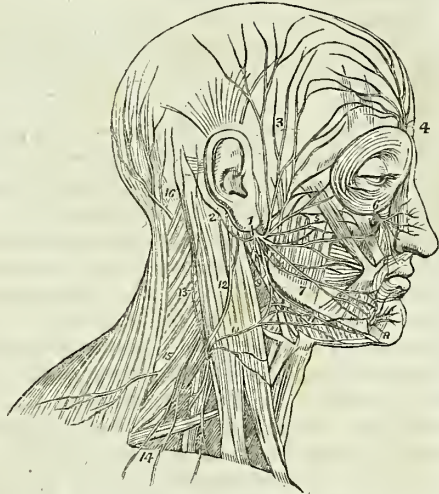
The *Digastric* branch supplies the posterior belly of the digastricus muscle, and communicates with the glosso-pharyngeal and pneumogastric nerve.

The *Temporo-facial* gives off a number of branches, which are distributed over the temple and upper half of the face, supplying the muscles of this region, and communicating with the branches of the auricular, the subcutaneous malæ, and the supra-orbital nerve. The inferior branches, which accompany Stenon's duct, and form a plexus with the terminal branches of the infra-orbital nerve.

The *Cervico-facial* divides into a number of branches that are distributed to muscles on the lower half of the face and upper part of the neck. The cervical branches form a plexus with the superficialis colli nerve over the submaxillary gland, and are distributed to the platysma myoides.

**AUDITORY NERVE (portio mollis).**—The auditory nerve takes its origin in the linæ transversæ (striæ medullares) of the anterior wall or floor of the fourth ventricle, and winds around the corpus restiforme, from which it receives fibres, to the posterior border of the crus cerebelli. It then passes forwards upon the crus cerebelli in company with the facial nerve, which lies in a groove on its superior surface, and enters the meatus

Fig. 182.\*



\* The distribution of the facial nerve and the branches of the cervical plexus. 1. The facial nerve, escaping from the stylo-mastoid foramen, and crossing the ramus of the lower jaw; the parotid gland has been removed in order to see the nerve more distinctly. 2. The posterior auricular branch; the digastric and stylo-mastoid filaments are seen near the origin of this branch. 3. Temporal branches, communicating with (4) the branches of the frontal nerve. 5. Facial branches, communicating with (6) the infra-orbital nerve. 7. Facial branches, communicating with (8) the mental nerve. 9. Cervico-facial branches, communicating with (10) the superficialis colli nerve, and forming a plexus (11) over the submaxillary gland. The distribution of the branches of the facial in a radiated direction over the side of the face and their looped communications constitute the pes anserinus. 12. The auricularis magnus nerve, one of the ascending branches of the cervical plexus. 13. The occipitalis minor, ascending along the posterior border of the sterno-mastoid muscle. 14. The superficial and deep descending branches of the cervical plexus. 15. The spinal accessory nerve, giving off a branch to the external surface of the trapezius muscle. 16. The occipitalis major nerve, the posterior branch of the second cervical nerve.

auditorius internus, and at the bottom of the meatus it divides into two branches, *cochlear* and *vestibular*. The auditory nerve is soft and pulpy in texture, and receives in the meatus auditorius several filaments from the facial nerve.

**EIGHTH PAIR.**—The eighth pair consists of three nerves, glosso-pharyngeal, pneumogastric, and spinal accessory; these are the ninth, tenth, and eleventh pairs of Soemmering.

**GLOSSO-PHARYNGEAL NERVE.**—The glosso-pharyngeal nerve arises by five or six filaments from the groove between the corpus olivare and restiforme, and escapes from the skull at the innermost extremity of the jugular foramen through a distinct opening in the dura mater, lying anteriorly to the sheath of the pneumogastric and spinal accessory nerves, and internally to the jugular vein. It then passes forwards between the jugular vein and internal carotid artery, to the stylo-pharyngeus muscle, and descends along the inferior border of that muscle to the hyo-glossus, beneath which it curves to be distributed to the mucous membrane of the base of the tongue and fauces, to the mucous glands of the mouth, and to the tonsils. While situated in the jugular fossa, the nerve presents two gangliform swellings; one *superior* (ganglion jugulare of Müller) of small size, and involving only the posterior fibres of the nerve; the other *inferior*, nearly half an inch below the preceding, of larger size and occupying the whole diameter of the nerve, the ganglion of Andersch\* (ganglion petrosum).

\* The fibres of origin of this nerve may be traced through the fasciculi of the corpus restiforme to the grey substance in the floor of the fourth ventricle.

The *Branches* of the glosso-pharyngeal nerve are—

|                                                                   |                                                                                                |
|-------------------------------------------------------------------|------------------------------------------------------------------------------------------------|
| Tympanic,<br>Muscular,<br>Pharyngeal,<br>Lingual,<br>Tonsillitic. | Communicating branches with the Facial,<br>Pneumogastric,<br>Spinal accessory,<br>Sympathetic. |
|-------------------------------------------------------------------|------------------------------------------------------------------------------------------------|

The *Branches of communication* proceed from the ganglion and from the upper part of the trunk of the nerve, and are common to the facial, eighth pair, and sympathetic; they form a complicated plexus at the base of the skull.

The *Tympanic* branch (Jacobson's nerve) proceeds from the ganglion of Andersch, or from the trunk of the nerve immediately above the ganglion: it enters a small bony canal in the jugular fossa (page 68) and divides into six branches, which are distributed upon the inner wall of the tympanum, and establish a plexiform communication (tympanic plexus) with the sympathetic and fifth pair of nerves. The *branches* of distribution supply the fenestra rotunda, fenestra ovalis, and Eustachian tube: those of communication join the carotid plexus, the petrosal branch of the Vidian nerve, and the otic ganglion.

\* Charles Samuel Andersch. "Tractatus Anatomico-Physiologicus de Nervis Corporis Humani Aliquibus. 1797."

The *Muscular* branch divides into filaments, which are distributed to the stylo-pharyngeus and to the posterior belly of the digastricus and stylo-hyoideus muscle.

The *Pharyngeal* branches are two or three filaments which are distributed to the pharynx and unite with the pharyngeal branches of the pneumogastric and sympathetic nerve to form the pharyngeal plexus.

The *Lingual* branches enter the substance of the tongue beneath the hyo-glossus and stylo-glossus muscle, and are distributed to the mucous membrane of the side and base of the tongue, and to the epiglottis and fauces.

The *Tonsillitic* branches proceed from the glosso-pharyngeal nerve near its termination; they form a plexus (circulus tonsillaris) around the base of the tonsil, from which numerous filaments are given off to the mucous membrane of the fauces and soft palate, communicating with the posterior palatine branches of Meckel's ganglion.

**PNEUMOGASTRIC NERVE (vagus).**—The pneumogastric nerve arises by ten or fifteen filaments from the groove between the corpus olivare and corpus restiforme, immediately below the glosso-pharyngeal, and passes out of the skull through the inner extremity of the jugular foramen in a distinct canal of the dura mater. While situated in this canal it presents a small rounded ganglion (ganglion jugulare); and having escaped from the skull, a gangliform swelling (plexus gangliformis), nearly an inch in length, and surrounded by an irregular plexus of white nerves, which communicate with each other, with the other divisions of the eighth pair, and with the trunk of the pneumogastric below the ganglion. The plexus gangliformis (ganglion of the superior laryngeal branch, of Sir Astley Cooper,) is situated, at first, behind the internal carotid artery, and then between that vessel and the internal jugular vein. The pneumogastric nerve then descends the neck within the sheath of the carotid vessels, lying behind and between the artery and vein, to the root of the neck. Here the course of the nerve at opposite sides becomes different.

On the *right* side it passes between the subclavian artery and vein to the posterior mediastinum, then behind the root of the lung to the œsophagus, which it accompanies to the stomach, lying on its posterior aspect.

On the *left* it enters the chest parallel with the left subclavian artery, crosses the arch of the aorta, and descends behind the root of the lung, and along the anterior surface of the œsophagus, to the stomach.

The fibres of origin of the pneumogastric nerve, like those of the glosso-pharyngeal, may be traced through the fasciculi of the corpus restiforme into the grey substance of the floor of the fourth ventricle.

The *Branches* of the pneumogastric nerve are the following:—

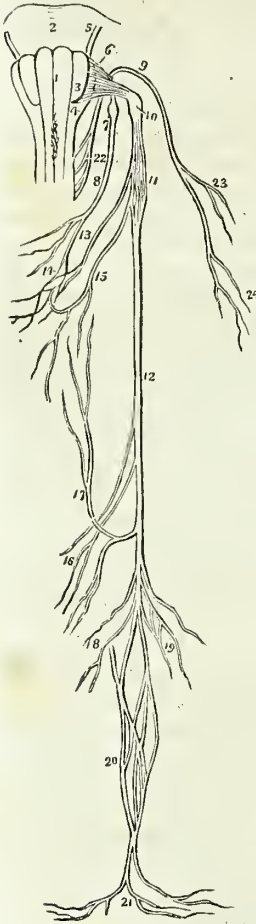
Communicating branches with the Facial,  
Glosso-pharyngeal,  
Spinal accessory,  
Hypo-glossal,  
Sympathetic.

Auricular,  
Pharyngeal,  
Superior laryngeal,

Cardiac,  
 Inferior or recurrent laryngeal,  
 Pulmonary anterior,  
 Pulmonary posterior,  
 Oesophageal,  
 Gastric.

The *Branches of communication* form part of the complicated plexus at the base of the skull. The branches to the ganglion of Andersch are given off by the superior ganglion in the jugular fossa.

Fig. 183.\*



The *Auricular* nerve is given off from the lower part of the jugular ganglion, or from the trunk of the nerve immediately below, and receives immediately after its origin a small branch of communication from the glosso-pharyngeal. It then passes outwards behind the jugular vein, and on the outer side of that vessel enters a small canal (page 68) in the petrous portion of the temporal bone near the stylo-mastoid foramen. Guided by this canal it reaches the descending part of the aqueductus Fallopii and joins the facial nerve. In the aqueductus Fallopii the auricular nerve gives off two small filaments, one of which communicates with the posterior auricular branch of the facial, while the other is distributed to the pinna.

The *Pharyngeal* nerve arises from the pneumogastric, immediately above the gangliform plexus, and descends behind the internal carotid artery to the upper border of the middle constrictor, upon which it forms the *pharyngeal plexus* assisted by branches from the glosso-pharyngeal, superior laryngeal, and sympathetic. The pharyngeal plexus is distributed to the muscles and mucous membrane of the pharynx.

The *Superior laryngeal* nerve arises from the gangliform plexus of the pneumogastric, of which it appears to be almost a continuation; hence this plexus was named by Sir Astley Cooper the "*ganglion of the superior laryngeal branch.*" The nerve descends behind the internal carotid artery to the opening in the thyro-hyoidean membrane, through which it passes with the superior laryngeal artery, and is distributed to the mucous membrane of the larynx and arytenoideus muscle. On the latter, and behind the cricoid cartilage,

\* Origin and distribution of the eighth pair of nerves. 1, 3, 4. The medulla oblongata. 1 Is the corpus pyramidale of one side. 3. The corpus olivare. 4. The corpus restiforme. 2. The pons Varolii. 5. The facial nerve. 6. The origin of the glosso-pharyngeal nerve. 7. The ganglion of Andersch. 8. The trunk of the nerve. 9. The spinal accessory nerve. 10. The ganglion of the pneumogastric nerve. 11. Its plexiform gan-



it communicates with the recurrent laryngeal nerve. Behind the internal carotid it gives off the *external laryngeal branch*, which sends a twig to the pharyngeal plexus, and then descends to supply the inferior constrictor and crico-thyroid muscles and thyroid gland. This branch communicates inferiorly with the recurrent laryngeal and sympathetic nerve.

Mr. Hilton of Guy's Hospital, concludes from his dissections\* that the superior laryngeal nerve is the *nerve of sensation* to the larynx, being distributed solely (with the exception of its external laryngeal branch and a twig to the arytenoideus) to the mucous membrane. If this fact be taken in connexion with the observations of Sir Astley Cooper, and the dissections of the origin of the nerve by Mr. Edward Cock, we shall have ample evidence, both in the ganglionic origin of the nerve and in its distribution, of its sensitive function. The recurrent, or inferior laryngeal nerve, is the proper motor nerve of the larynx, and is distributed to its muscles.

The *Cardiac* branches, two or three in number, arise from the pneumogastric in the lower part of the neck, and cross the lower part of the common carotid, to communicate with the cardiac branches of the sympathetic, and with the great cardiac plexus.

The *Recurrent laryngeal*, or inferior laryngeal nerve, curves around the subclavian artery on the right, and the arch of the aorta on the left side. It ascends in the groove between the trachea and œsophagus, and piercing the lower fibres of the inferior constrictor muscle enters the larynx close to the articulation of the inferior cornu of the thyroid with the cricoid cartilage. It is distributed to all the muscles of the larynx with the exception of the crico-thyroid, and communicates on the arytenoideus muscle with the superior laryngeal nerve. As it curves around the subclavian artery and aorta it gives branches to the heart and root of the lungs; and as it ascends the neck it distributes filaments to the œsophagus and trachea, and communicates with the external laryngeal nerve and sympathetic.

The *Anterior pulmonary* branches are distributed upon the anterior aspect of the root of the lungs, forming, with branches from the great cardiac plexus, the *anterior pulmonary plexus*.

The *Posterior pulmonary* branches, more numerous than the anterior, are distributed upon the posterior aspect of the root of the lungs, and are joined by branches from the great cardiac plexus, forming the *posterior pulmonary plexus*.

Upon the œsophagus the two nerves divide into numerous branches, which communicate with each other and constitute the *œsophageal plexus* which completely surrounds the cylinder of the œsophagus, and accompanies it to the cardiac orifice of the stomach.

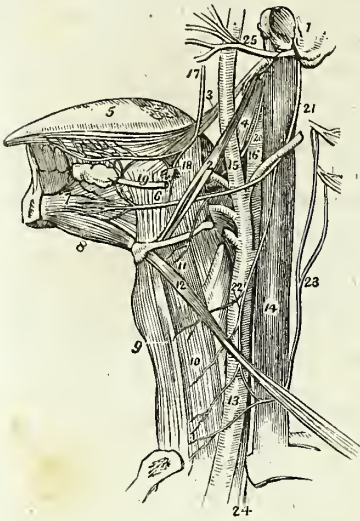
The *Gastric* branches are the terminal filaments of the two pneumogastric nerves; they are spread out upon the anterior and posterior surfaces of the stomach, and are likewise distributed to the omentum, spleen, pancreas, liver, and gall-bladder, and communicate, particularly the right nerve, with the solar plexus.

gion. 12. Its trunk. 13. Its pharyngeal branch forming the pharyngeal plexus (14), assisted by a branch from the glosso-pharyngeal (8), and one from the superior laryngeal nerve (15). 16. Cardiac branches. 17. Recurrent laryngeal branch. 18. Anterior pulmonary branches. 19. Posterior pulmonary branches. 20. Œsophageal plexus. 21. Gastric branches. 22. Origin of the spinal accessory nerve. 23. Its branches distributed to the sterno-mastoid muscle. 24. Its branches to the trapezius muscle.

\* Guy's Hospital Reports, vol. ii.

**SPINAL ACCESSORY NERVE.**—The spinal accessory nerve arises by several filaments from the side of the spinal cord as low down as the fourth or fifth cervical nerve, and ascends behind the ligamentum denticulatum, and between the anterior and posterior roots of the spinal nerves, to the foramen lacerum posterius. It communicates in its course with the posterior root of the first cervical nerve, and entering the foramen lacerum becomes applied against the posterior aspect of the ganglion jugulare of the pneumogastric, being contained in the same sheath of dura mater. In the jugular fossa it divides into two branches; the smaller joins the pneumogastric immediately below the jugular ganglion, and contributes to the formation of the pharyngeal nerve; the larger or true continuation of the nerve passes backwards behind the internal jugular vein, and descends obliquely to the upper part of the sterno-mastoid muscle. It pierces the sterno-mastoid, and then passes obliquely across the neck, communicating with the second, third, and fourth cervical nerves, and is distributed to the trapezius. The spinal accessory sends numerous twigs to the sterno-mastoid in its passage through that muscle, and in the trapezius the nervous filaments may be traced downwards to its lower border.

Fig. 184.\*



lar vein, and descends obliquely to the upper part of the sterno-mastoid muscle. It pierces the sterno-mastoid, and then passes obliquely across the neck, communicating with the second, third, and fourth cervical nerves, and is distributed to the trapezius. The spinal accessory sends numerous twigs to the sterno-mastoid in its passage through that muscle, and in the trapezius the nervous filaments may be traced downwards to its lower border.

The pneumogastric and spinal accessory nerves together (*nervus vagus cum accessorio*) resemble a spinal nerve, of which the former with its ganglion is the posterior and sensitive root, the latter the anterior and motor root.

**NINTH PAIR.† HYPOGLOSSAL NERVE (lingual).** The hypoglossal nerve arises from the groove between the corpus pyramidale and corpus olivare

\* The anatomy of the side of the neck, showing the nerves of the tongue. 1. A fragment of the temporal bone containing the meatus auditorius externus, mastoid, and styloid process. 2. The stylo-hyoid muscle. 3. The stylo-glossus. 4. The stylo-pharynx. 5. The tongue. 6. The hyo-glossus muscle; its two portions. 7. The genio-hyoglossus muscle. 8. The genio-hyoideus; they both arise from the inner surface of the symphysis of the lower jaw. 9. The sterno-hyoid muscle. 10. The sterno-thyroid. 11. The thyro-hyoid, upon which the thyro-hyoidean branch of the hypoglossal nerve is seen ramifying. 12. The omo-hyoid crossing the common carotid artery (13), and in the internal jugular vein (14). 15. The external carotid giving off its branches. 16. The internal carotid. 18. The gustatory nerve giving off a branch to the submaxillary ganglion (18), and communicating a little further on with the hypoglossal nerve. 19. The submaxillary, or Wharton's duct, passing forwards to the sublingual gland. 20. The glosso-pharyngeal nerve, passing in behind the hyo-glossus muscle. 21. The hypoglossal nerve curving around the occipital artery. 22. The descendens noni nerve, forming a loop with (23) the communicans noni, which is seen to be arising by filaments from the upper cervical nerves. 24. The pneumogastric nerve, emerging from between the internal jugular vein and common carotid artery, and entering the chest. 25. The facial nerve, emerging from the stylo-mastoid foramen, and crossing the external carotid artery.

† The twelfth pair according to the arrangement of Soemmering.

by ten or fifteen filaments, which being collected into two bundles, escape from the cranium through the anterior condyloid foramen. The nerve then passes forwards between the internal carotid artery and internal jugular vein, and descends along the anterior and inner side of the vein to a point parallel with the angle of the lower jaw. It next curves inwards around the occipital artery, with which it forms a loop, and crossing the lower part of the hyo-glossus muscle to the genio-hyo-glossus, sends filaments onwards with the anterior fibres of that muscle as far as the tip of the tongue. It is distributed to the muscles of the tongue, and principally to the genio-hyo-glossus. While resting on the hyo-glossus muscle it is flattened, and beneath the mylo-hyoideus it communicates with the gustatory nerve.

At its origin the hypoglossal nerve sometimes communicates with the posterior root of the first cervical nerve.

The *Branches* of the hypoglossal nerve are :

Communicating branches with the Pneumogastric,  
Spinal accessory,  
First and second cervical nerves,  
Sympathetic.

Descendens noni,  
Thyro-hyoidean branch,  
Communicating filaments with the gustatory nerve.

The *Communications* with the pneumogastric and spinal accessory take place through the medium of a plexiform interlacement of branches at the base of the skull, behind the internal jugular vein. The communications with the sympathetic nerve are derived from the superior cervical ganglion.

The *Descendens noni* is a long and slender twig, which quits the hypoglossal just as that nerve is about to form its arch around the occipital artery, and descends upon the sheath of the carotid vessels. Just below the middle of the neck it forms a loop with a long branch (communicans noni) from the second and third cervical nerves. From the convexity of this loop branches are sent to the sterno-hyoideus, sterno-thyroideus, and both bellies of the omo-hyoideus ; sometimes also a twig is given off to the cardiac plexus, and occasionally one to the phrenic nerve. If the descendens noni be traced to its origin it will be found to be formed by a branch from the hypoglossal, and one from the first and second cervical nerves ; occasionally it receives also a filament from the pneumogastric.

The *Thyro-hyoidean* nerve is a small branch, distributed to the thyro-hyoideus muscle. It is given off from the trunk of the hypoglossal near the posterior border of the hyoglossus muscle, and descends obliquely over the great cornu of the os hyoides.

The *Communicating filaments*, with the gustatory nerve, are several small twigs, which ascend upon the hyoglossus muscle near its anterior border, and form a kind of plexus with filaments sent down by the gustatory nerve.

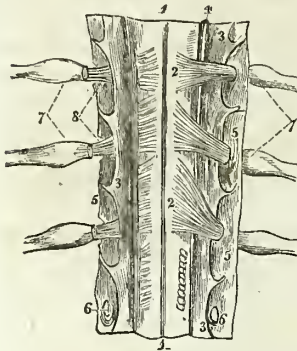
#### SPINAL NERVES.

There are thirty-one pairs of spinal nerves, each arising by two roots, an anterior or motor root, and a posterior or sensitive root.

The anterior roots proceed from a narrow white line, anterior lateral

sulcus, on the antero-lateral column of the spinal cord, and gradually approach towards the anterior longitudinal fissure as they descend.

Fig. 185.\*



The posterior roots, more regular than the anterior, proceed from the posterior lateral sulcus, a narrow grey stria, formed by the internal grey substance of the cord. They are larger, and the filaments of origin more numerous than those of the anterior roots. In the intervertebral foramina there is a ganglion on each of the posterior roots. The first cervical nerve forms an exception to these characters; its posterior root is smaller than the anterior; it often joins in whole or in part with the spinal accessory nerve and sometimes with the hypoglossal: there is frequently no ganglion upon it, and when the ganglion exists it is often situated within the dura

mater, the latter being the usual position of the ganglia of the last two pairs of spinal nerves.

After the formation of a ganglion, the two roots unite and constitute a spinal nerve, which escapes through the intervertebral foramen and divides into an anterior branch for the supply of the front aspect of the body, and a posterior branch for the posterior aspect. In the first cervical and two last sacral nerves this division takes place within the dura mater and in the upper four sacral nerves externally to that cavity, but within the sacral canal. The anterior branches, with the exception of the first two cervical nerves, are larger than the posterior; an arrangement which is proportioned to the larger extent of surface they are required to supply.

The *Spinal nerves* are divided into—

|          |           |          |
|----------|-----------|----------|
| Cervical | . . . . . | 8 pairs. |
| Dorsal   | . . . . . | 12       |
| Lumbar   | . . . . . | 5        |
| Sacral   | . . . . . | 6        |

The cervical nerves pass off transversely from the spinal cord; the dorsal are oblique in their direction; and the lumbar and sacral vertical; the latter form the large assemblage of nerves at the termination of the cord called *cauda equina*.

CERVICAL NERVES.

The cervical nerves increase in size from above downwards; the first (sub-occipital) passes out of the spinal canal between the occipital bone and the atlas; and the last, between the last cervical and first dorsal ver-

\* Part of the cervical portion of the spinal cord, viewed on its posterior aspect; and showing its membranes and the posterior roots of the spinal nerves. 1, 1. The fissura longitudinalis posterior. 2, 2. The posterior roots of the cervical nerves; on the opposite side the corresponding roots are cut through near their origin. 3, 3. The membrana dentata. 4. The nervus accessorius, ascending between the posterior roots and the membrana dentata; on the opposite side this nerve has been removed. 5, 5. The dura mater or theca vertebralis. 6, 6. Openings in the dura mater for the passage of the roots of the nerves. 7, 7. The ganglia on the posterior roots of the spinal nerves. 8. The anterior roots of the spinal nerves. The posterior roots have been cut away in order to show each anterior root, proceeding to join the nerve beyond the ganglion.

tebra. Each nerve, at its escape from the intervertebral foramen, divides into an anterior and a posterior branch. The anterior branches of the four upper cervical nerves form the *cervical plexus*; the posterior branches, the *posterior cervical plexus*. The anterior branches of the four inferior cervical, together with the first dorsal, form the brachial plexus.

**ANTERIOR CERVICAL NERVES.**—The anterior branch of the *first cervical nerve* escapes from the vertebral canal through the groove upon the posterior arch of the atlas which supports the vertebral artery, beneath which it lies. It then descends in front of the transverse process of the atlas, sends several twigs to the rectus lateralis and recti antici, and forms an anastomotic loop by communicating with an ascending branch of the second nerve.

The anterior branch of the *second cervical nerve* at its exit from the intervertebral foramen between the atlas and the axis, gives twigs to the rectus anticus major, scalenus posticus and levator anguli scapulæ muscles, and divides into three branches, viz. an ascending branch, which completes the arch of communication with the first nerve; and two descending branches, which communicate with the third nerve.

The anterior branch of the *third cervical nerve*, double the size of the preceding, divides at its exit from the intervertebral foramen into numerous branches, some of which are distributed to the rectus major, longus colli, and scalenus posticus muscles, while others communicate and form loops and anastomoses with the second and fourth nerve.

The anterior branch of the *fourth cervical nerve*, of the same size with the preceding, sends twigs to the rectus major, longus colli, and levator anguli scapulæ, communicates by anastomosis with the third, and sends a small branch downwards to the fifth nerve. Its principal branches pass downwards and outwards across the posterior triangle of the neck, towards the clavicle and acromion.

The anterior branches of the *fifth, sixth, seventh, and eighth cervical nerves* will be described with the brachial plexus, of which they form a part.

## CERVICAL PLEXUS.

The cervical plexus is constituted by the loops of communication, and by the anastomoses which take place between the anterior branches of the four first cervical nerves. The plexus rests upon the levator anguli scapulæ, posterior scalenus, and splenius muscle, and is covered in by the sterno-mastoid and platysma.

The *Branches* of the cervical plexus may be arranged into three groups, superficial ascending, superficial descending; and deep—

|             |                                                                                            |                                                                                                                                                                                     |
|-------------|--------------------------------------------------------------------------------------------|-------------------------------------------------------------------------------------------------------------------------------------------------------------------------------------|
| Superficial | $\left\{ \begin{array}{l} \textit{Ascending}, \\ \textit{Descending}, \end{array} \right.$ | $\left\{ \begin{array}{l} \text{Superficialis colli,} \\ \text{Auricularis magnus,} \\ \text{Occipitalis minor.} \\ \text{Acromiales,} \\ \text{Claviculares.} \end{array} \right.$ |
|             |                                                                                            |                                                                                                                                                                                     |
| Deep        |                                                                                            |                                                                                                                                                                                     |

The *Superficialis colli* is formed by communicating branches from the second and third cervical nerves; it curves around the posterior border of the sterno-mastoid and crosses obliquely behind the external jugular vein to the anterior border of that muscle, where it divides into an ascending and a descending branch; the *descending branch* is distributed to the integument on the side and front of the neck, as low down as the clavicle; the *ascending branch* passes upwards to the submaxillary region, and divides into four or five filaments, some of which pierce the platysma myoides and supply the integument as high up as the chin and lower part of the face, while others form a plexus with the descending branches of the facial nerve beneath the platysma. One or two filaments from this nerve accompany the external jugular vein.

The *Auricularis magnus*, the largest of the three ascending branches of the cervical plexus, also proceeds from the second and third cervical nerve; it curves around the posterior border of the sterno-mastoid, and ascends upon that muscle, lying parallel with the external jugular vein, to the parotid gland, where it divides into an anterior and a posterior branch. The *anterior* branch is distributed to the integument over the parotid gland, to the gland itself, communicating with the facial nerve, and to the external ear. The *posterior* branch pierces the parotid gland and crosses the mastoid process, where it divides into branches which supply the posterior part of the pinna and the integument of the side of the head, and communicate with the posterior auricular branch of the facial and with the occipitalis minor. Previously to its division the auricularis magnus nerve sends off several facial branches which are distributed to the cheek.

The *Occipitalis minor* arises from the second cervical nerve; it curves around the posterior border of the sterno-mastoid above the preceding, and ascends upon that muscle, parallel with its posterior border, to the lateral and posterior side of the head. It is distributed to the integument and to the muscles of this region, namely, to the occipito-frontalis, attollens and attrahens aurem, and communicates with the occipitalis major, auricularis magnus and posterior auricular branch of the facial.

The *Acromiales* and *Claviculares* are two or three large nerves which proceed from the fourth cervical nerve, and divide into numerous branches which pass downwards over the clavicle, and are distributed to the integument of the upper and anterior part of the chest from the sternum to the shoulder.

The *Communicating branches* are filaments which arise from the loop between the first and second cervical nerve, and pass inwards to communicate with the sympathetic, the pneumogastric, and the hypo-glossal nerve. The three first cervical nerves send branches to the first cervical ganglion; the fourth sends a branch to the trunk of the sympathetic, or to the middle cervical ganglion. From the second cervical nerve a large branch is given off which goes to join the spinal accessory nerve.

The *Muscular branches* proceed from the third and fourth cervical nerves; they are distributed to the trapezius, levator anguli scapulæ, and rhomboidei muscles.

The *Communicans noni* is a long slender branch formed by filaments from the first, second, and third cervical nerves; it descends upon the outer side of the internal jugular vein, and forms a loop with the descendens noni over the sheath of the carotid vessels.

The *Phrenic nerve* (internal respiratory of Bell) is formed by filaments from the third, fourth, and fifth cervical nerves, receiving also a branch from the sympathetic. It descends to the root of the neck, resting upon the scalenus anticus muscle, then crosses the first portion of the subclavian artery, and enters the chest between it and the subclavian vein. Within the chest it passes through the middle mediastinum, between the pleura and pericardium, and in front of the root of the lung to the diaphragm to which it is distributed, some of its filaments reaching the abdomen through the openings for the œsophagus and vena cava, and communicating with the phrenic and solar plexus, and on the right side with the hepatic plexus. The left phrenic nerve is rather longer than the right, from the inclination of the heart to the left side.

POSTERIOR CERVICAL NERVES.—The posterior division of the *first cervical nerve* (sub-occipital), larger than the anterior, escapes from the vertebral canal through the opening for the vertebral artery, lying posteriorly to that vessel, and emerges into the triangular space formed by the rectus posticus major, obliquus superior, and obliquus inferior. It is distributed to the recti and obliqui muscles, and sends one or two filaments downwards to communicate with the second cervical nerve. The posterior branch of the *second cervical nerve* is three or four times greater than the anterior branch, and is larger than the other posterior cervical nerves. The posterior branch of the *third cervical nerve* is smaller than the preceding, but larger than the fourth; and the other posterior cervical nerves go on progressively decreasing to the seventh. The posterior branches of the fourth, fifth, sixth, seventh and eighth nerves pass inwards between the muscles of the back in the cervical and upper part of the dorsal region, and reaching the surface near the middle line, are reflected outwards, to be distributed to the integument. The fourth and fifth are nearly transverse in their course, and lie between the semispinalis colli and complexus. The sixth, seventh, and eighth are directed nearly vertically downwards; they pierce the aponeurosis of origin of the splenius and trapezius.

POSTERIOR CERVICAL PLEXUS.—This plexus is constituted by the succession of anastomosing loops and communications which pass between the posterior branches of the first, second, and third cervical nerves. It is situated between the complexus and semispinalis colli, and its branches are the—

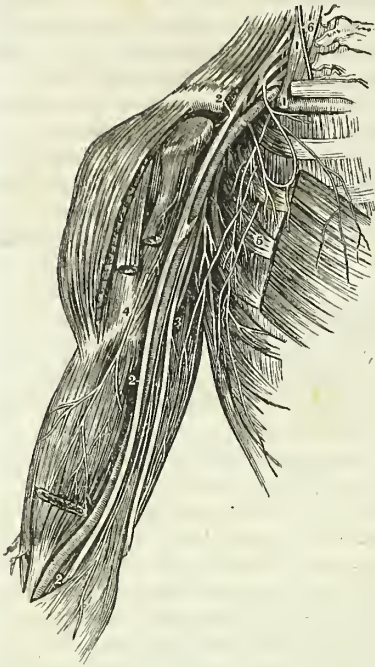
Musculo-cutaneous,

Occipitalis major.

The *Musculo-cutaneous* branches pass inwards between the complexus and semispinalis colli to the ligamentum nuchæ, distributing muscular filaments in their course. They then pierce the aponeurosis of the trapezius and become subcutaneous, sending branches outwards to supply the integument of the posterior aspect of the neck, and upwards to the posterior region of the scalp.

The *Occipitalis major* is the direct continuation of the second cervical nerve; it ascends obliquely inwards, between the obliquus inferior and complexus, pierces the complexus and trapezius after passing for a short distance between them, and ascends upon the posterior aspect of the head between the integument and occipito-frontalis, in company with the occi-

Fig. 186.\*



pital artery. The occipitalis major sends numerous branches to the muscles of the neck, and is distributed to the integument of the scalp, as far forwards as the middle of the vertex of the head. Its branches communicate with those of the occipitalis minor.

#### BRACHIAL PLEXUS.

The *Brachial* or *axillary plexus* of nerves is formed by communications between the anterior branches of the four last cervical and first dorsal nerve. These nerves are all similar in size, and their mode of disposition in the formation of the plexus is the following: the fifth and sixth nerves unite to form a common trunk, which soon divides into two branches; the last cervical and first dorsal also unite immediately upon their exit from the intervertebral foramina, and the common trunk resulting from their union after a short course also divides into two branches; the seventh nerve passes outwards between the

common trunks of the two preceding, and opposite the clavicle divides into a superior branch which unites with the inferior division of the superior trunk, and an inferior branch which communicates with the superior division of the inferior trunk: from these divisions and communications the brachial plexus results. The brachial plexus communicates with the cervical plexus by means of a branch sent down from the fourth to the fifth nerve, and by the inferior branch of origin of the phrenic nerve, and also sends filaments of communication to the sympathetic. The plexus is broad in the neck, narrows as it descends into the axilla, and again enlarges at its lower part where it divides into its six terminal branches.

*Relations.*—The brachial plexus is in relation in the neck with the two scaleni muscles, between which its nerves issue; lower down it is placed between the clavicle and subclavius muscle above, and the first rib and first serration of the serratus magnus muscle below. In the axilla, it is situated at first to the outer side and then behind the axillary artery, resting by its outer border against the tendon of the subscapularis muscle. At this point it completely surrounds the artery by means of the two cords which are sent off to form the median nerve.

Its *Branches* may be arranged into two groups, humeral and descending,—

\* A view of the brachial plexus of nerves and branches of arm. 1, 1. The scalenus anticus muscle, in front of which are the roots of the plexus. 2, 2. The median nerve. 3. The ulnar nerve. 4. The branch to the biceps muscle. 5. The nerves of Wrisberg. 6. The phrenic nerve from the 3d and 4th cervical.



*Humeral Branches.*

Superior muscular,  
 Short thoracic,  
 Long thoracic,  
 Supra-scapular,  
 Subscapular,  
 Inferior muscular.

*Descending Branches.*

External cutaneous,  
 Internal cutaneous,  
 Lesser internal cutaneous,  
 Median,  
 Ulnar,  
 Musculo-spiral,  
 Circumflex.

The superior *Muscular nerves* are several large branches which are given off by the fifth cervical nerve above the clavicle; they are, a *subclavian branch* to the subclavius muscle, which usually sends a communicating filament to the phrenic nerve: a *rhomboid branch* to the rhomboidei muscles; and frequently an *angular branch* to the levator anguli scapulæ.

The *Short thoracic nerves* (anterior) are two in number; they arise from the brachial plexus at a point parallel with the clavicle, and are divisible into an anterior and a posterior branch. The *anterior branch* passes forwards between the subclavius muscle and the subclavian vein, and is distributed to the pectoralis major muscle, entering it by its costal surface. In its course it sends one or two twigs to the deltoid muscle and gives off a branch which forms a loop of communication with the posterior branch. The *posterior branch* passes forward beneath the axillary artery and unites with the communicating branch of the preceding to form a loop, from which numerous branches are given off to the pectoralis major and pectoralis minor.

The *Long thoracic nerve* (posterior thoracic, external respiratory of Bell) is a long and remarkable branch arising from the fourth and fifth cervical nerves, immediately after their escape from the intervertebral foramina. It passes down behind the plexus and axillary vessels, resting on the scalenus posticus muscle; it then descends along the side of the chest upon the serratus magnus muscle to its lowest serration. It sends numerous filaments to this muscle in its course.

The *Supra-scapular nerve* arises above the clavicle from the fifth cervical nerve and descends obliquely outwards to the supra-scapular notch; it then passes through the notch, crosses the supra-spinous fossa beneath the supra-spinatus muscle, and passing in front of the concave margin of the spine of the scapula enters the infra-spinous fossa. It is distributed to the supra-spinatus and infra-spinatus muscle.

The *Subscapular nerves* are two in number; of which one arises from the brachial plexus above the clavicle, the other from the posterior aspect of the plexus within the axilla. They are distributed to the subscapularis muscle.

The *Inferior muscular nerves* are two or three branches which proceed from the lower and back part of the brachial plexus, and are distributed to the latissimus dorsi and teres major. The former of these is the longer, and follows the course of the subscapular artery.

The terminal branches of the plexus are arranged in the following order: the external cutaneous, and one head of the median to the outer side of the artery; the other head of the median, internal cutaneous, lesser internal cutaneous, and ulnar, upon its inner side; and the circumflex and musculo-spiral behind.

The **EXTERNAL CUTANEOUS NERVE** (musculo-cutaneous, perforans Caserii) arises from the brachial plexus in common with the external head of the median; it pierces the coraco-brachialis muscle and passes between the biceps and brachialis anticus, to the outer side of the bend of the elbow, where it perforates the fascia, and divides into an external and internal branch. The branches pass behind the median cephalic vein, the *external*, the larger of the two, taking the course of the radial vein and communicating with the branches of the radial nerve on the back of the hand; the *internal* and smaller following the direction of the supinator longus, communicating with the internal cutaneous, and at the lower third of the fore-arm sending off a twig, which accompanies the radial artery to the wrist, and distributes filaments to the synovial membranes of the joint.

The external cutaneous nerve supplies the coraco-brachialis, biceps and brachialis anticus in the upper arm, and the integument of the outer side of the fore-arm as far as the wrist and hand.

The **INTERNAL CUTANEOUS NERVE** is one of the internal and smaller of the branches of the axillary plexus; it arises from the plexus in common with the ulnar and internal head of the median, and passes down the inner side of the arm in company with the basilic vein, giving off several cutaneous filaments in its course. At about the middle of the upper arm it pierces the deep fascia by the side of the basilic vein and divides into two branches, anterior and posterior. The *anterior* branch, the larger of the two, divides into several branches which pass in front of, and sometimes behind, the median basilic vein at the bend of the elbow, and descends in the course of the palmaris longus muscle to the wrist, distributing filaments to the integument in their course and communicating with the anterior branch of the external cutaneous on the outer side, and its own posterior branch on the inner side of the fore-arm. The *posterior* branch sends off several twigs to the integument over the inner condyle and olecranon, and then descends the fore-arm in the course of the ulnar vein as far as the wrist, supplying the integument on the inner side of the fore-arm and communicating with the anterior branch of the same nerve in front, and the dorsal branch of the ulnar nerve on the wrist.

The **LESSER INTERNAL CUTANEOUS NERVE**, or *nerve of Wrisberg*, the smallest of the branches of the brachial plexus, is very irregular in point of origin. It is a long and slender nerve, and usually arises from the common trunk of the last cervical and first dorsal nerve. Passing downwards into the axillary space it communicates with the external branch of the first intercosto-humeral nerve, and descends on the inner side of the internal cutaneous nerve, to the middle of the posterior aspect of the upper arm, where it pierces the fascia and is distributed to the integument of the elbow, communicating with filaments of the posterior branch of the internal cutaneous and with the spiral cutaneous. In its course it gives off two or three cutaneous filaments to the integument of the inner and anterior aspect of the upper arm.

The **MEDIAN NERVE** has received its name from taking a course along the middle of the fore-arm to the palm of the hand; it is, therefore, intermediate in position between the radial and ulnar nerves. It commences by two heads, which embrace the axillary artery; lies at first to the outer side of the brachial artery, which it crosses at its middle; and descends

on its inner side to the bend of the elbow. It then passes between the two heads of the pronator radii teres and flexor sublimis digitorum muscles, and runs down the fore-arm, between the flexor sublimis and profundus, and beneath the annular ligament, into the palm of the hand.

The *Branches* of the median nerve are,—

Muscular,  
Anterior interosseous,  
Superficial palmar,  
Digital.

The *Muscular branches* are given off by the nerve at the bend of the elbow; they are distributed to all the muscles on the anterior aspect of the fore-arm, with the exception of the flexor carpi ulnaris, and to the periosteum. The branch to the pronator radii teres sends off reflected branches to the elbow joint.

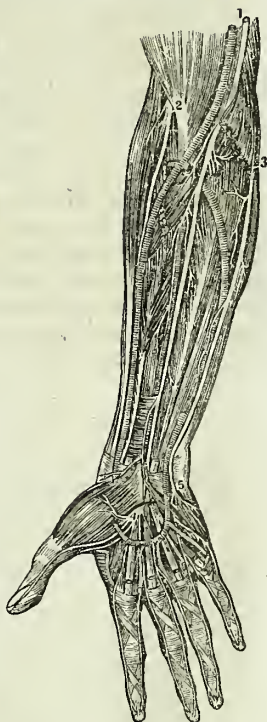The *Anterior interosseous* is a large branch accompanying the anterior interosseous artery, and supplying the deep layer of muscles in the fore-arm. It passes beneath the pronator quadratus muscle, and pierces the interosseous membrane near the wrist. On reaching the posterior aspect of the wrist it joins a large and remarkable ganglion which gives off a number of branches for the supply of the joint.

The *Superficial palmar branch* arises from the median nerve at about the lower fourth of the fore-arm: it crosses the annular ligament, and is distributed to the integument over the ball of the thumb and in the palm of the hand.

The median nerve at its termination in the palm of the hand is spread out and flattened, and divides into six branches, one muscular and five digital. The *muscular* branch is distributed to the muscles of the ball of the thumb. The *digital branches* send twigs to the lumbricales muscles and are thus arranged: two pass outwards to the thumb to supply its borders; one to the radial side of the index finger; one subdivides for the supply of the adjoining sides of the index and middle fingers; and the remaining one, for the supply of the adjoining sides of the middle and ring fingers. The digital nerves in their course along the fingers are situated to the inner side of the digital arteries. Opposite the base of the first phalanx each nerve gives off a *dorsal branch* which runs along the border of the dorsum of the finger. Near the extremity of the finger the digital nerve divides into a *palmar* and a *dorsal* branch; the former supplying the sentient extremity of the finger, and the latter the structures around and beneath the nail. The digital nerve maintains no communication with its fellow of the opposite side.

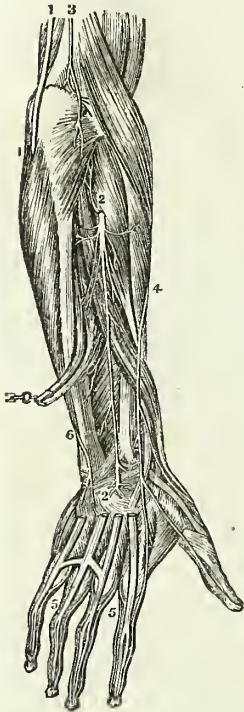
\* Nerves of front of fore-arm. 1. Median nerve. 2. Anterior branch of musculo spiral or radial nerve. 3. Ulnar nerve. 4. Division of median nerve in the palm to the thumb, 1st, 2d, and radial side of 3d finger. 5. Division of ulnar nerve to ulnar side of 3d and both sides of 4th finger.

Fig. 187.\*



The **ULNAR NERVE** is somewhat smaller than the median, behind which it lies, gradually diverging from it in its course. It arises from the brachial plexus in common with the internal head of the median and the internal cutaneous nerve, and runs down the inner side of the arm, to the groove between the internal condyle and olecranon, resting upon the internal head of the triceps, and accompanied by the inferior profunda artery. At the elbow it is superficial, and supported by the inner condyle, against which it is easily compressed, giving rise to the thrilling sensation along the inner side of the fore-arm and little finger, ascribed to striking the "funny bone." It then passes between the two heads of the flexor carpi ulnaris and descends along the inner side of the fore-arm, crosses the annular ligament, and divides into two branches, superficial and deep palmar. At the commencement of the middle third of the fore-arm, it becomes applied against the artery, and lies to its ulnar side, as far as the hand.

Fig. 188.\*



The *Branches* of the ulnar nerve are—

Muscular in the upper arm,  
 Articular,  
 Muscular in the fore-arm,  
 Anastomotic,  
 Dorsal branch,  
 Superficial palmar,  
 Deep palmar.

The *Muscular branches* in the upper arm are a few filaments distributed to the triceps.

The *Articular branches* are several filaments to the elbow joint, which are given off from the nerve as it lies in the groove between the inner condyle and the olecranon.

The *Muscular branches* in the fore-arm are distributed to the flexor carpi ulnaris and flexor profundus digitorum muscle.

The *Anastomotic branch* (n. cutaneus palmaris ulnaris) is a small nerve which arises from the ulnar at about the middle of the fore-arm, and divides into a deep and a superficial branch; the former accompanies the ulnar artery, the latter pierces the deep fascia, and is distributed to the integument, communicating with the posterior branch of the internal cutaneous nerve.

The *Dorsal branch* passes backwards beneath the tendon of the flexor carpi ulnaris, at the lower third of the fore-arm, and divides into branches, which supply the integument and two fingers and a half on the posterior aspect of the hand, communicating with the internal cutaneous and radial nerve.

The *Superficial palmar branch* divides into three filaments, which are

\* A view of the nerves on the dorsal aspect of the fore-arm and hand. 1, 1. The ulnar nerve. 2, 2. The posterior interosseous nerve. 3. Termination of the nervus cutaneus humeri. 4. The dorsalis carpi, a branch of the radial nerve. 5, 5. A back view of the digital nerves. 6. Dorsal branch of the ulnar nerve.

distributed, *one* to the ulnar side of the little finger, *one* to the adjoining borders of the little and ring fingers, and a communicating branch to join the median nerve.

The *Deep palmar branch* passes between the abductor and flexor minimi digiti, to the deep palmar arch, supplying the muscles of the little finger, and the interossei and other deep structures in the palm of the hand.

The MUSCULO-SPIRAL NERVE, the largest branch of the brachial plexus, arises from the posterior part of the plexus by a common trunk with the circumflex nerve. It passes downwards from its origin in front of the tendons of the latissimus dorsi and teres major muscle, and winds around the humerus in the spiral groove, accompanied by the superior profunda artery, to the space between the brachialis anticus and supinator longus, and thence onwards to the bend of the elbow, where it divides into two branches, the posterior interosseous and radial nerve.

The *Branches* of the musculo-spiral nerve are—

Muscular,  
Radial,

Spiral cutaneous,  
Posterior interosseous.

The *Muscular branches* are distributed to the triceps, to the supinator longus, and to the extensor carpi radialis longior.

The *Spiral cutaneous nerve* pierces the deep fascia immediately below the insertion of the deltoid muscle, and passes down the outer side of the fore-arm as far as the wrist. It is distributed to the integument.

The *Radial nerve* runs along the radial side of the fore-arm to the commencement of its lower third; it then passes beneath the tendon of the supinator longus, and at about two inches above the wrist joint pierces the deep fascia, and divides into an external and an internal branch. The *external branch*, the smaller of the two, is distributed to the outer border of the hand and thumb, and communicates with the posterior branch of the external cutaneous nerve. The *internal branch* crosses the direction of the extensor tendons of the thumb, and divides into several filaments for the supply of the ulnar border of the thumb, the radial border of the index finger, and the adjoining borders of the index and middle fingers. It communicates on the back of the hand with the dorsal branch of the ulnar nerve.

In the upper third of the fore-arm the radial nerve lies beneath the border of the supinator longus muscle. In the middle third it is in relation with the radial artery lying to its outer side. It then quits the artery, and passes beneath the tendon of the supinator longus, to reach the back of the hand.

The *Posterior interosseous nerve*, somewhat larger than the radial, separates from the latter at the bend of the elbow, pierces the supinator brevis muscle, and emerges from its lower border on the posterior aspect of the fore-arm, where it divides into branches which supply the whole of the muscles on the posterior aspect of the fore-arm. One branch, longer than the rest, descends to the posterior part of the wrist, and forms a large gangliform swelling (the common character of nerves which supply joints), from which numerous branches are distributed to the wrist joint.

The *CIRCUMFLEX NERVE* arises from the posterior part of the brachial plexus by a common trunk with the musculo-spiral nerve. It passes downwards over the border of the subscapularis muscle, winds around the neck of the humerus with the posterior circumflex artery, and terminates by dividing into numerous branches, which supply the deltoid muscle.

The *Branches* of the circumflex nerve are muscular and cutaneous. The *Muscular* branches are distributed to the subscapularis, teres minor, teres major, latissimus dorsi, and deltoid. The *Cutaneous* branches pierce the deltoid muscle, and are distributed to the integument of the shoulder. One of these cutaneous branches (cutaneus brachii superior), larger than the rest, winds around the posterior border of the deltoid, and divides into filaments which pass in a radiating direction across the shoulder, and are distributed to the integument.

#### DORSAL NERVES.

The dorsal nerves are twelve in number on each side; the first appears between the first and second dorsal vertebræ, and the last between the twelfth dorsal and first lumbar. They are smaller than the lower cervical nerves, and diminish gradually in size from the first to the tenth, and then increase to the twelfth. Each nerve, as soon as it has escaped from the intervertebral foramen, divides into two branches; a dorsal branch and the true intercostal nerve.

The *Dorsal branches* pass directly backwards between the transverse processes of the vertebræ, lying internally to the anterior costo-transverse ligament, where each nerve divides into an anterior or muscular and a posterior or musculo-cutaneous branch. The *muscular branch* enters the substance of the muscles in the direction of a line corresponding with the interval of separation between the longissimus dorsi and sacro-lumbalis, and is distributed to the muscles of the back, its terminal filaments reaching to the integument. The *musculo-cutaneous* branch passes inwards, crossing the semispinalis dorsi to the spinous processes of the dorsal vertebræ, giving off muscular branches in its course; it then pierces the aponeurosis of origin of the trapezius and latissimus dorsi, and divides into branches which are inclined outwards beneath the integument to which they are distributed.

The dorsal branch of the *first dorsal nerve* resembles in its mode of distribution the dorsal branches of the last cervical. The dorsal branches of the *last four dorsal nerves* pass obliquely downwards and outwards into the substance of the erector spinæ in the situation of the interspace between the sacro-lumbalis and longissimus dorsi. After supplying the erector spinæ and communicating freely with each other they approach the surface along the outer border of the sacro-lumbalis, where they pierce the aponeuroses of the transversalis, internal oblique, serratus posticus inferior, and latissimus dorsi, and divide into *internal branches* which supply the integument in the lumbar region upon the middle line, and *external branches* which are distributed to the integument upon the side of the lumbar and in the gluteal region.

**INTERCOSTAL NERVES.**—The *Intercostal nerves* receive one or two filaments from the adjoining ganglia of the sympathetic, and pass forwards in

the intercostal space with the intercostal vessels, lying below the veins and artery, and supplying the intercostal muscles in their course. At the termination of the intercostal spaces near the sternum, the nerves pierce the intercostal and pectoral muscles, and incline downwards and outwards to be distributed to the integument of the mamma and front of the chest. Those which are situated between the false ribs pass behind the costal cartilages, and between the transversalis and obliquus internus muscles, and supply the rectus and the integument on the front of the abdomen. The first and last dorsal nerves are exceptions to this distribution. The anterior branch of the first dorsal nerve divides into two branches; a smaller, which takes its course along the under surface of the first rib to the sternal extremity of the first intercostal space; and a larger, which crosses obliquely the neck of the first rib to join the brachial plexus. The last dorsal nerve, next in size to the first, sends a branch of communication to the first lumbar nerve, to assist in forming the lumbar plexus.

The *Branches* of each intercostal nerve are, a *muscular* twig to the intercostal and neighbouring muscles, and a *cutaneous* branch which is given off at about the middle of the arch of the rib. The first intercostal nerve has no cutaneous branch. The cutaneous branches of the second and third intercostal nerves are named, from their origin and distribution, *intercosto-humeral*.

The **FIRST INTERCOSTO-HUMERAL NERVE** is of large size; it pierces the external intercostal muscle of the second intercostal space, and divides into an internal and an external branch. The *internal branch* is distributed to the integument of the inner side of the arm. The *external branch* communicates with the nerve of Wrisberg, and divides into filaments which supply the integument upon the inner and posterior aspect of the arm as far as the elbow. This nerve sometimes takes the place of the nerve of Wrisberg.

The **SECOND INTERCOSTO-HUMERAL NERVE** is much smaller than the preceding; it emerges from the external intercostal muscle of the third intercostal space between the serrations of the serratus magnus muscle, and divides into filaments which are distributed to the integument of the shoulder. One of these filaments may be traced inwards to the integument of the mamma. The two intercosto-humeral nerves not unfrequently communicate previously to their distribution.

The cutaneous branches of the *fourth* and *fifth* intercostal nerve send anterior twigs to the integument of the mammary gland and posterior filaments to the scapular region of the back. The *cutaneous branches* of the remaining intercostal nerves reach the surface between the serrations of the serratus magnus muscle above and the external oblique below, and each nerve divides into an *anterior* and a *posterior* branch; the former being distributed to the integument of the antero-lateral, and the latter to that of the lateral part of the trunk.

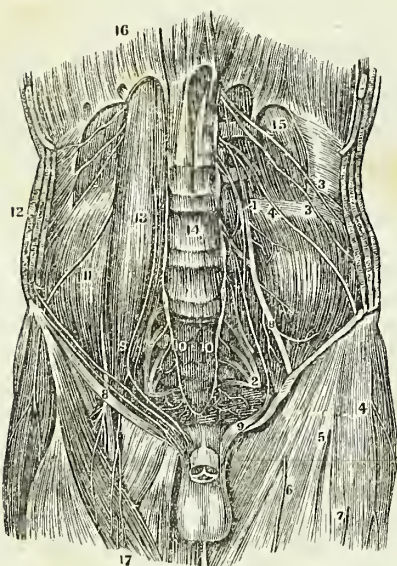
The cutaneous branch of the *last dorsal nerve* is remarkable for its size (n. clunium superior anticus); it pierces the internal and external oblique muscles, crosses the anterior part of the crest of the ilium, and is distributed to the integument of the gluteal region as low down as the trochanter major.

## LUMBAR NERVES.

There are five pairs of lumbar nerves, of which the first makes its appearance between the first and second lumbar vertebræ, and the last between the fifth lumbar and the base of the sacrum. The *anterior* branches increase in size from above downwards. They communicate at their origin with the lumbar ganglia of the sympathetic, and pass obliquely outwards behind the psoas magnus or between its fasciculi, sending twigs to that muscle and to the quadratus lumborum. In this situation each nerve divides into two branches, a superior branch which ascends to form a loop of communication with the nerve above, and an inferior branch which descends to join in like manner the nerve below, the communications and anastomoses which are thus established constituting the lumbar plexus.

The *posterior* branches diminish in size from above downwards; they pass backwards between the transverse processes of the corresponding vertebræ, and each nerve divides into an internal and an external branch. The *internal* branch, the smaller of the two, passes inwards to be distributed to the multifidus spinæ and interspinales, and becoming cutaneous supplies the integument of the lumbar region on the middle line. The *external* branches communicate with each other by several loops, and after supplying the deeper muscles, pierce the sacro-lumbalis to reach the integument to which they are distributed. The external branches of the three lower lumbar nerves (nervi clunium superiores postici) descend over the superior part of the crest of the ilium, and are distributed to the integument of the gluteal region.

Fig. 189.\*



## LUMBAR PLEXUS.

The *Lumbar plexus* is formed by the communications and anastomoses which take place between the anterior branches of the five lumbar nerves, and between the latter and the last dorsal. It is narrow above and increases in breadth inferiorly, and is situated between the transverse processes of the lumbar vertebræ and the quadratus lumborum behind, and the psoas magnus muscle in front.

\* A view of the lumbar and ischiatic plexus and the branches of the former. 14. The bodies of the lumbar vertebræ. 13. The psoas magnus muscle. 11. The iliacus internus muscle. 15. The quadratus lumborum muscle. 16. The diaphragm. 12. The three broad muscles of the abdomen. 17. The sartorius. 1. The lumbar plexus. 2. The ischiatic plexus. 3, 3. Abdomino-crural nerves. 4. External cutaneous nerve (inguino-cutaneous). 5, 6, 7. Cutaneous branches from (8) The anterior crural nerve. 9. The genito-crural nerve or spermaticus externus. 10, 10. The lower termination of the great sympathetic.



The *Branches* of the *lumbar plexus* are the—

|                     |               |
|---------------------|---------------|
| Musculo-cutaneous,  | Crural,       |
| External-cutaneous, | Obturator,    |
| Genito-crural,      | Lumbo-sacral. |

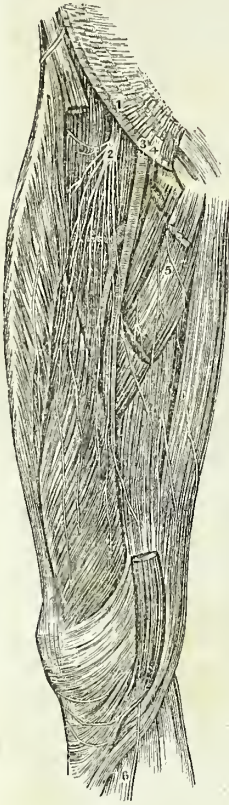
The **MUSCULO-CUTANEOUS NERVES**, two in number, superior and inferior, proceed from the first lumbar nerve. The *superior musculo-cutaneous nerve* (ilio-scrotal, ilio-hypogastricus), passes outwards between the posterior fibres of the psoas magnus, and crossing obliquely the quadratus lumborum to the middle of the crest of the ilium, pierces the transversalis muscle, and gives off a cutaneous branch. It then winds along the crest of the ilium between the transversalis and internal oblique, and divides into two branches, abdominal and scrotal. The *abdominal branch* is continued forwards parallel with the last intercostal nerve to near the rectus muscle, to which it sends branches and perforates the aponeuroses of the internal and external oblique to be distributed to the integument of the mons pubis and groin. The *scrotal branch*, opposite the anterior superior spinous process of the ilium, communicates with the inferior musculo-cutaneous nerve, and passes forward to the external abdominal ring. It then pierces the cremaster muscle and accompanies the spermatic cord in the male, and the round ligament in the female, to be distributed to the integument of the scrotum or external labium. The *inferior musculo-cutaneous nerve* (ilio-inguinal) also arises from the first lumbar nerve. It is much smaller than the preceding, crosses the quadratus lumborum below it, and curves along the crest of the ilium to the anterior superior spinous process, resting in its course upon the iliac fascia. It there pierces the transversalis fascia and muscle, communicates with the scrotal branch of the ilio-scrotal nerve, and passes along the spermatic canal with the spermatic cord to be similarly distributed.

The **EXTERNAL CUTANEOUS NERVE** (inguino-cutaneous) proceeds from the second lumbar nerve. It pierces the posterior fibres of the psoas muscle; and crossing the iliacus obliquely, lying upon the iliac fascia, to the anterior superior spinous process of the ilium, passes into the thigh beneath Poupart's ligament. It then pierces the fascia lata at about two inches below the anterior superior spine of the ilium, and divides into two branches, anterior and posterior. The *posterior branch* crosses the tensor vaginae femoris muscle to the outer and posterior side of the thigh, and supplies the integument in that region. The *anterior nerve* divides into two branches which are distributed to the integument upon the outer border of the thigh, and to the articulation of the knee.

The **GENITO-CRURAL** proceeds also from the second lumbar nerve. It traverses the psoas magnus from behind forwards, and runs down on the anterior surface of that muscle and beneath its fascia to near Poupart's ligament, where it divides into a genital and a crural branch. The *genital branch* (n. spermaticus seu pudendus externus) crosses the external iliac artery to the internal abdominal ring and descends along the spermatic canal, lying behind the cord to the scrotum, where it divides into branches which supply the spermatic cord and cremaster in the male, and the round ligament and external labium in the female. At the internal abdominal ring this nerve sends off a branch which after supplying the lower border

of the internal oblique and transversalis, is distributed to the integument of the groin. The *crural branch* (lumbo-inguinalis), the most external of the two, descends along the outer border of the external iliac artery, and, crossing the origin of the circumflex ilii artery, enters the sheath of the femoral vessels in front of the femoral artery. It pierces the sheath below Poupart's ligament, and is distributed to the integument of the anterior aspect of the thigh as far as its middle. This nerve is often very small, and sometimes communicates with one of the cutaneous branches of the crural nerve.

Fig. 190.\*



The CRURAL, or FEMORAL NERVE, is the largest of the divisions of the lumbar plexus; it is formed by the union of branches from the second, third, and fourth lumbar nerves, and, emerging from beneath the psoas muscle, passes downwards in the groove between it and the iliacus, and beneath Poupart's ligament into the thigh, where it spreads out and divides into numerous branches. At Poupart's ligament it is separated from the femoral artery by the breadth of the psoas muscle, which at this point is scarcely more than half an inch in diameter, and by the iliac fascia, beneath which it lies.

*Branches.*—While situated within the pelvis the crural nerve gives off several muscular branches to the iliacus, and one to the psoas. On emerging from beneath Poupart's ligament the nerve becomes flattened and divides into numerous branches, which may be arranged into,—

Cutaneous,  
Muscular,  
Branch to the femoral sheath,  
Short saphenous nerve,  
Long saphenous nerve.

The *Cutaneous nerves* (middle cutaneous) two in number, proceed from the anterior part of the crural, and after perforating the sartorius muscle to which they give filaments, pierce the fascia lata and are distributed to the integument of the middle and lower part of the thigh and of the knee. The most *external* of these nerves perforates the upper part of the sartorius, communicates with the crural branch of the genito-crural, divides into two branches at about the middle of the thigh, and gives off numerous filaments to the anterior and outer aspect of the limb as far as the patella. The *internal* nerve perforates the muscle at about its middle, pierces the fascia lata at the lower third of the thigh, descends to the inner condyle, and curves forward to the front of the knee, supplying the integument by many filaments. Besides these another cutaneous branch derived from the muscular branch

\* A view of the anterior crural nerve and branches. 1. Place of emergence of the nerve under Poupart's ligament. 2. Division of the nerve into branches. 3. Femoral artery 4. Femoral vein. 5. Branches of obturator nerve. 6. Nervus saphenus

to the vastus externus is found on the outer side of the lower third of the thigh.

The *Muscular branches* are several large twigs which are distributed to the muscles of the anterior aspect of the thigh. One of these is sent to the rectus; one to the vastus externus, which gives off a cutaneous twig to the outer aspect of the thigh; one to the cruræus, and one large and long branch to the vastus internus. From the two latter, filaments are distributed to the periosteum and knee joint. The sartorius receives its supply of nerves from the cutaneous nerves by which it is perforated.

The *Branch to the femoral sheath* is a small nerve which passes inwards to the sheath of the femoral vessels at the upper part of the thigh, and divides into several filaments which surround the femoral and profunda vessels. Two of these filaments, one from the front, and the other from the posterior part of the sheath, unite to form a small nerve which escapes from the saphenous opening and passes downwards with the saphenous vein. Other filaments are distributed to the adductor muscles, and communicate with the long saphenous nerve.

The *Short saphenous nerve* (n. cutaneus internus) inclines inwards to the sheath of the femoral vessels, and divides into a superficial and a deep branch. The *superficial* branch passes downwards along the inner border of the sartorius muscle to the lower third of the thigh; it then pierces the fascia lata, joins the internal saphenous vein, and accompanies that vessel to the knee joint, where it terminates by communicating with the long saphenous nerve. The *deep branch* descends on the outer side of the sheath of the femoral vessels, and crosses the sheath at its lower part to a point opposite the termination of the femoral artery, where it divides into several filaments which constitute a *plexus* by their communication with other nerves. One of these filaments communicates with the descending branch of the obturator nerve, another with the long saphenous nerve, and two or three are distributed to the integument upon the internal and posterior aspect of the thigh.

The *Long saphenous nerve* (n. cutaneus internus longus) inclines inwards to the sheath of the femoral vessels, and entering the sheath accompanies the femoral artery to the aponeurotic canal formed by the adductor longus and vastus internus muscles. It then quits the artery, and, passing between the tendons of the sartorius and gracilis, descends along the inner side of the leg with the internal saphenous vein, crosses in front of the inner ankle, and is distributed to the integument on the inner side of the foot as far as the great toe.

The internal saphenous nerve receives from the obturator nerve two branches of communication, one near its upper part, which passes through the angle of division of the femoral artery, and the other at the internal condyle. The branches which it gives off in its course are, a *femoral cutaneous branch*, at about the middle of the thigh, distributed to the integument of the inner and posterior aspect of the limb, and communicating with other cutaneous filaments from the saphenous below the knee; a *tibial cutaneous branch* proceeding from the nerve a little above the internal condyle, passing between the sartorius and gracilis and descending the inner aspect of the leg to the ankle; an *articular branch* of small size, proceeding from the nerve while in the aponeurotic canal of the femoral artery, and passing directly to the knee joint to supply the synovial membrane; an *anterior cutaneous branch* proceeding from the saphenous at the

inner condyle, perforating the sartorius, and dividing into a number of filaments which supply the integument over the patella and around the joint, and the integument of the front and outer aspect of the leg as far as the ankle; lastly, cutaneous filaments below the knee to supply the inner side and front of the leg and foot, and articular branches to the ankle joint.

The OBTURATOR NERVE is formed by a branch from the third, and another from the fourth lumbar nerve. It passes downwards among the fibres of the psoas muscle, through the angle of bifurcation of the common iliac vessels, and along the inner border of the brim of the pelvis, to the obturator foramen, where it joins the obturator artery. Having escaped from the pelvis it gives off two small twigs to the obturator externus muscle and divides into four branches, *three anterior*, which pass in front of the adductor brevis, supplying that muscle, the pectineus, the adductor longus, and the gracilis; and a *posterior* branch which passes downwards behind the adductor brevis, and ramifies in the adductor magnus.

From the branch which supplies the adductor brevis, a *communicating filament* passes outwards through the angle of bifurcation of the femoral vessels to unite with the long saphenous nerve. From the branch to the adductor longus a long *cutaneous nerve* proceeds, which issues from beneath the inferior border of that muscle, sends filaments of communication to the plexus of the short saphenous nerve, and descends to the inner side of the knee, where it pierces the fascia and communicates with the long saphenous nerve. It is distributed to the integument upon the inner side of the leg. From the posterior branch an *articular branch* is given off which pierces the adductor magnus muscle, accompanies the popliteal artery, and is distributed to the synovial membrane of the knee joint on its posterior aspect.

The LUMBO-SACRAL NERVE.—The anterior division of the fifth lumbar nerve, conjoined with a branch from the fourth, constitutes the lumbo-sacral nerve, which descends over the base of the sacrum into the pelvis, and assists in forming the sacral plexus.

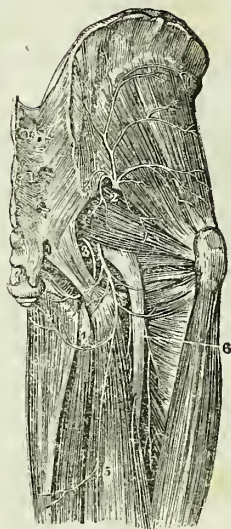
#### SACRAL NERVES.

There are six pairs of sacral nerves; the first escape from the vertebral canal through the first sacral foramina, and the two last between the sacrum and coccyx. The *posterior sacral nerves* are very small, and diminish in size from above downwards; they communicate with each other immediately after their escape from the posterior sacral foramina, and divide into external and internal branches. The external branches pierce the gluteus maximus, to which they give filaments, and are distributed to the integument of the posterior part of the gluteal region (n. cutanei clunium posteriores). The internal supply the integument over the sacrum and coccyx.

The *anterior sacral nerves* diminish in size from above downwards; the *first* is large and unites with the lumbo-sacral nerve; the *second*, of equal size, unites with the preceding; the *third*, which is scarcely one-fourth so large as the second, also joins with the preceding nerves in the formation of the sacral plexus. The *fourth* anterior sacral nerve is about one-third the size of the preceding sacral nerve; it divides into several branches, one of which is sent to the sacral plexus, a second to join the fifth sacral

nerve, a third to the viscera of the pelvis communicating with the hypogastric plexus, and a fourth to the coccygeus muscle, and to the integument around the anus. The *fifth* anterior sacral nerve presents about half the size of the fourth; it divides into two branches, one of which communicates with the fourth, the other with the sixth. The *sixth* sacral nerve (coccygeal) is exceedingly small; it gives off an ascending filament which is continuous with the communicating branch of the fifth; and a descending filament which passes downwards by the side of the coccyx and traverses the fibres of the great sacro-ischiatic ligament to be distributed to the gluteus maximus and to the integument. All the anterior sacral nerves receive branches from the sacral ganglia of the sympathetic at their emergence from the sacral foramina.

Fig. 191.\*



## SACRAL PLEXUS.

The *Sacral plexus* is formed by the lumbo-sacral and by the anterior branches of the four upper sacral nerves. The plexus is triangular in form, the base corresponding with the whole length of the sacrum, and the apex with the lower part of the great ischiatic foramen. It is in relation behind with the pyriformis muscle, and in front with the pelvic fascia, which latter separates it from the branches of the internal iliac artery, and from the viscera of the pelvis.

The *Branches* of the sacral plexus are divisible into the *internal* and the *external*; they may be thus arranged:—

*Internal.*

Visceral,  
Muscular.

*External.*

Muscular,  
Gluteal,  
Internal pudic,  
Lesser ischiatic,  
Greater ischiatic.

The *Visceral nerves* are three or four large branches which are derived from the fourth and fifth sacral nerves: they ascend upon the side of the rectum and bladder; in the female upon the side of the rectum, the vagina and the bladder; and interlace with the branches of the hypogastric plexus, sending in their course numerous filaments to those viscera.

The *Muscular branches* given off within the pelvis are one or two twigs to the levator ani; an obturator branch; which curves around the spine of the ischium to reach the internal surface of the obturator internus muscle; a coccygeal branch; and an hæmorrhoidal nerve which passes through the two ischiatic openings and descends to the termination of the rectum to supply the sphincter and the integument.

\* A view of the branches of the ischiatic plexus to the hip and back of the thigh. 1, 1. Posterior sacral nerves. 2. Nervi glutei. 3. The internal pudic nerve (nervus pudendalis longus superior). 4. The lesser ischiatic nerve, giving off the perineal cutaneous (pudendalis longus inferior), and 5. The ramus femoralis cutaneus posterior. The reference to the great ischiatic has been omitted. It is seen to the right of 3.

The *Muscular branches* supplied by the sacral plexus externally to the pelvis are, a branch to the pyramidalis; a branch to the gemellus superior; and a branch of moderate size which descends between the gemelli muscles and the ischium, and is distributed to the gemellus inferior, the quadratus femoris, and the capsule of the hip joint.

The **GLUTEAL NERVE** (superior gluteal) is a branch of the lumbo-sacral; it passes out of the pelvis with the gluteal artery, through the great sacro-ischiatic foramen, and divides into a superior and an inferior branch. The *superior* branch follows the direction of the superior curved line of the ilium, accompanying the deep superior branch of the gluteal artery, and sending filaments to the gluteus medius and minimus. The *inferior* passes obliquely downwards and forwards between the gluteus medius and minimus, distributing numerous filaments to both, and terminates in the tensor vaginæ femoris muscle.

The **INTERNAL PUDIC NERVE** arises from the lower part of the sacral plexus, passes out of the pelvis through the great sacro-ischiatic foramen below the pyriformis muscle, and takes the course of the internal pudic artery. While situated beneath the obturator fascia it lies below that vessel and divides into a superior and an inferior branch.

The *Superior nerve* (dorsalis penis) ascends upon the posterior surface of the ramus of the ischium, pierces the deep perineal fascia and accompanies the arteria dorsalis penis to the glans, to which it is distributed. At the root of the penis this nerve gives off a cutaneous branch which runs along the side of the organ, gives filaments to the corpus cavernosum, and with its fellow of the opposite side supplies the integument of the upper two-thirds of the penis and prepuce.

The *Inferior or perineal nerve* pursues the course of the internal pudic artery in the perineum and sends off three principal branches, an *external perineal branch*, which ascends upon the outer side of the crus penis; and supplies the scrotum; a *superficial perineal branch*, which accompanies the artery of that name and distributes filaments to the scrotum, to the integument of the under part of the penis and to the prepuce; and, thirdly, the *bulbo-urethral branch*, which sends twigs to the sphincter ani, transversus perinei, and accelerator urinæ, and terminates by ramifying in the corpus spongiosum.

In the female the internal pudic nerve is distributed to the parts analogous to those of the male. The *superior branch* supplies the clitoris; and the *inferior* the vulva and parts in the perineum.

The **LESSER ISCHIATIC NERVE** passes out of the pelvis through the great sacro-ischiatic foramen below the pyriformis muscle, and divides into muscular and cutaneous branches. The muscular branches, *inferior gluteal*, are distributed to the gluteus maximus; some ascending in the substance of that muscle to its upper border, and others descending. The cutaneous branches are, several ascending filaments to the integument over the gluteus maximus (n. cutanei clunium inferiores), perineal cutaneous, and middle posterior cutaneous.

The *Perineal cutaneous nerve* (pudendalis longus inferior), curves around the tuberosity of the ischium and ascends in a direction parallel to the ramus of the ischium and os pubis to the scrotum, where it communicates

with the superficial perineal nerve, and divides into an internal and an external branch. The internal branch passes down upon the inner side of the testis to the scrotum; the external branch to its outer side, and both terminate in the integument of the under border of the penis.

The *Middle posterior cutaneous nerve* crosses the tuberosity of the ischium and pierces the deep fascia at the lower border of the gluteus maximus. It then passes downwards along the middle of the posterior aspect of the thigh and of the popliteal region, and is distributed to the integument as far as the middle of the calf of the leg. In its course the nerve gives off several cutaneous branches to the integument of the inner and outer side of the thigh, and in the popliteal region a communicating branch which pierces the fascia of the leg and unites with the external saphenous nerve.

The **GREAT ISCHIATIC NERVE** is the largest nervous cord in the body; it is formed by the sacral plexus, or rather is a prolongation of the plexus, and at its exit from the great sacro-ischiatic foramen beneath the pyriformis muscle measures three quarters of an inch in breadth. It descends through the middle of the space between the trochanter major and tuberosity of the ischium, and along the posterior part of the thigh to about its lower third, where it divides into two large terminal branches, popliteal and peroneal. This division sometimes takes place at the plexus, and the two nerves descend together side by side; occasionally they are separated at their commencement by a part or the whole of the pyriformis muscle. The nerve in its course down the thigh rests upon the gemellus superior, tendon of the obturator internus, gemellus inferior, quadratus femoris, and adductor magnus muscle, and is covered in by the gluteus maximus, biceps, semi-tendinosus, and semi-membranosus.

The *Branches* of the great ischiatic nerve, previously to its division, are muscular and articular. The *muscular* branches are given off from the upper part of the nerve, and supply both heads of the biceps, the semi-tendinosus, semi-membranosus, and adductor magnus. The *articular* branch descends to the upper part of the external condyle of the femur, and divides into filaments which are distributed to the fibrous capsule and to the synovial membrane of the knee joint.

The **POPLITEAL NERVE** passes through the middle of the popliteal space, from the division of the great ischiatic nerve to the lower border of the popliteus muscle, accompanies the artery beneath the arch of the soleus, and becomes the posterior tibial nerve. It is superficial in the whole of its course, and lies externally to the vein and artery.

The *Branches* of the popliteal nerve are muscular or sural, and articular, and a cutaneous branch, the *communicans poplitei*.

The *Muscular branches*, of considerable size, and four or five in number, are distributed to the two heads of the gastrocnemius, to the soleus, plantaris, and popliteus.

The *Articular nerve* pierces the ligamentum posticum Winslowii, and supplies the interior of the knee joint. It usually sends a twig to the popliteus muscle.

The *Communicans poplitei* (*communicans tibialis*) is a large nerve which arises from the popliteal at about the middle of its course, and descends between the two heads of the gastrocnemius, and along the groove

formed by the two bellies of that muscle; at a variable distance below the articulation of the knee it receives a large branch, the *communicans peronei*, from the peroneal nerve, and the two together constitute the external saphenous nerve.

The *External saphenous nerve* pierces the deep fascia below the fleshy part of the *gastrocnemius* muscle, and continues its course down the leg, lying along the outer border of the *tendo Achillis* and by the side of the external saphenous vein, which it accompanies to the foot. At the lower part of the leg it winds around the outer malleolus, and is distributed to the outer side of the foot and little toe, communicating with the external peroneal cutaneous nerve, and sending numerous filaments to the integument of the heel and sole of the foot.

Fig. 192.\*

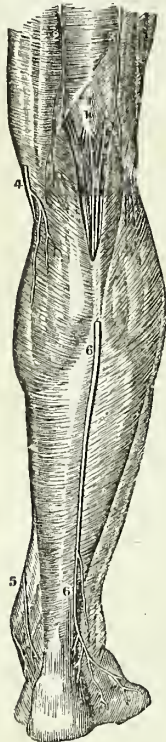


Fig. 193.†



The POSTERIOR TIBIAL NERVE is continued along the posterior aspect of the leg from the lower border of the *popliteus* muscle to the posterior part of the inner ankle, where it divides into the internal and external plantar nerve. In the upper part of its course it lies to the outer side of

\* A view of some of the branches of the popliteal nerve. 1. The popliteal nerve. 2, 3. The terminations of the *ramus femoralis cutaneus posterior*. 4, 5. The saphenous nerve. 6, 6. The external saphenous or *communicans tibialis*.

† A view of the posterior tibial nerve in the back of the leg. 1 and 2, indicate its course; the upper part of the peroneal nerve being seen to the right.



the posterior tibial artery; it then becomes placed superficially to that vessel, and at the ankle is again situated to its outer side; in the lower third of the leg it lies parallel with the inner border of the tendo Achillis.

The *Branches* of the posterior tibial nerve are three or four *muscular* twigs to the deep muscles of the posterior aspect of the leg, the branch to the flexor longus pollicis accompanies the fibular artery; one or two filaments which entwine around the artery and then terminate in the integument;\* and two or three *plantar cutaneous* branches which pass downwards upon the inner side of the os calcis, and are distributed to the integument of the heel.

The **INTERNAL PLANTAR NERVE**, larger than the external, crosses the posterior tibial vessels to enter the sole of the foot, where it lies in the interspace between the abductor pollicis and flexor brevis digitorum; it then enters the sheath of the latter muscle, and divides opposite the bases of the metatarsal bones into three digital branches; *one* to supply the adjoining sides of the great and second toe; the *second* the adjoining sides of the second and third toe; and the *third* the corresponding sides of the third and fourth toes. This distribution is precisely similar to that of the digital branches of the median nerve.

In its course the internal plantar nerve gives off *cutaneous branches* to the integument of the inner side and sole of the foot; *muscular branches* to the muscles forming the inner and middle group of the sole; a *digital branch* to the inner border of the great toe; and *articular branches* to the articulations of the tarsal and metatarsal bones.

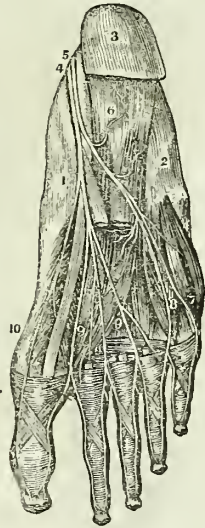
The **EXTERNAL PLANTAR NERVE**, the smaller of the two, follows the course of the external plantar artery to the outer border of the musculus accessorius, beneath which it sends several large muscular branches to supply the adductor pollicis and the articulations of the tarsal and metatarsal bones. It then gives branches to the integument of the outer border and sole of the foot, and sends forward two digital branches to supply the little toe and one half the next.

The **PERONEAL NERVE** is one-half smaller than the popliteal; it passes downwards by the side of the tendon of the biceps, crossing the inner head of the gastrocnemius and the origin of the soleus, to the neck of the

\* It is extremely interesting, in a physiological point of view, to observe the mode of distribution of these filaments. I have traced them in relation with several, and I have no doubt that they exist in connexion with all the superficial arteries. They seem to be the direct *monitors* to the artery of the presence or approach of danger!

† A view of the termination of the posterior tibial nerve in the sole of the foot. 1. Inside of the foot. 2. Outer side. 3. Heel. 4. Internal plantar nerve. 5. External plantar nerve. 6. Branch to flexor brevis. 7. Branch to outside of little toe. 8. Branch to space between 4th and 5th toes. 9, 9, 9. Digital branches to remaining spaces. 10. Branch to internal side of great toe.

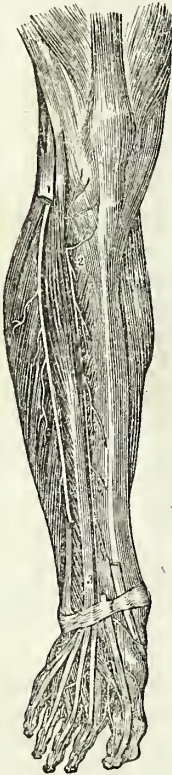Fig. 194.†



fibula, where it pierces the origin of the peroneus longus muscle, and divides into two branches, the anterior tibial and musculo-cutaneous.

The *Branches* of the peroneal nerve previously to its division are, the *communicans peronei*, cutaneous, articular, and muscular. The *communicans peronei*, much smaller than the *communicans poplitei*, crosses the external head of the gastrocnemius to the middle of the leg. It there sends a large branch to join the *communicans poplitei* and constitute the external saphenous nerve, and descends very much reduced in size with the external saphenous vein to the side of the external ankle, to which and to the integument of the heel it distributes filaments. The *cutaneous* branch passes down the outer side of the leg, supplying the integument. The *articular* is a small branch distributed to the knee joint. The *muscular* branches are twigs to the short head of the biceps, peroneus longus, and tibialis anticus.

Fig. 195.\*



The ANTERIOR TIBIAL NERVE commences at the bifurcation of the peroneal, upon the head of the fibula, and passes beneath the upper part of the extensor longus digitorum, to reach the outer side of the anterior tibial artery, just as that vessel has emerged through the opening in the interosseous membrane. It descends the anterior aspect of the leg with the artery; lying at first to its outer side, and then in front of it, and near the ankle becomes again placed to its outer side. Reaching the ankle, it passes beneath the annular ligament; accompanies the dorsalis pedis artery, supplies the adjoining sides of the great and second toes, and communicates with the internal peroneal cutaneous nerve.

The *Branches* given off by the anterior tibial nerve are, *muscular* to the muscles in its course, and on the foot a *tarsal* branch which passes beneath the extensor brevis digitorum, and distributes filaments to the interossei muscles and to the articulations of the tarsus and metatarsus.

The MUSCULO-CUTANEOUS NERVE passes downwards in the direction of the fibula, in the substance of the peroneus longus; it then passes forwards to get between the peroneus longus and brevis, and at the lower third of the leg pierces the deep fascia, and divides into two peroneal cutaneous branches. In its course it gives off several branches to the peronei muscles.

The *Peroneal cutaneous* nerves pass in front of the ankle joint, and are distributed to the integument of the foot and toes; the external supplying three toes and a half, and the internal one and a half. They communicate with the saphenous and anterior tibial nerves. The external saphenous nerve frequently supplies the fifth toe and the adjoining side of the fourth.

\* A view of the anterior tibial nerve. 1. The peroneal nerve. 2, 3. The anterior tibial nerve accompanying the artery of the same name.

## SYMPATHETIC NERVES.

The *Sympathetic system* consists of a series of ganglia, extending along each side of the vertebral column from the head to the coccyx, communicating with all the other nerves of the body, and distributing branches to all the internal organs and viscera.

It communicates with the other nerves immediately at their exit from the cranium and vertebral canal. The fourth and sixth nerves, however, form an exception to this rule; for with these it unites in the cavernous sinus; and with the olfactory, optic, and auditory, at their ultimate expansions.

The branches of distribution accompany the arteries which supply the different organs, and form communications around them, which are called *plexuses*, and take the name of the artery with which they are associated: thus we have the mesenteric plexus, hepatic plexus, splenic plexus, &c. All the *internal organs* of the head, neck, and trunk are supplied with branches from the sympathetic, and some of them exclusively; hence it is considered a nerve of *organic life*.

It is called the *ganglionic nerve* from the circumstance of being formed by a number of *ganglia*; and from the constant disposition which it evinces in its distribution, to communicate and form small knots or ganglia.

There are five sympathetic ganglia in the head; viz. the ganglion of Ribes; the *ciliary* or lenticular; the spheno-palatine, or Meckel's; the otic, or Arnold's; and the submaxillary: three in the neck; superior, middle, and inferior: twelve in the dorsal region; four in the lumbar region; and four or five in the sacral region.

Each ganglion may be considered as a *distinct centre* giving off branches in four different directions, viz., *superior* or *ascending*, to communicate with the ganglion above; *inferior* or *descending*, to communicate with the ganglion below; *external*, to communicate with the spinal nerves; and *internal*, to communicate with the sympathetic filaments of the opposite side, and to be distributed to the viscera.

## CRANIAL GANGLIA.

Ganglion of Ribes,  
Ciliary, or lenticular ganglion,  
Spheno-palatine, or Meckel's ganglion,  
Otic, or Arnold's ganglion,  
Submaxillary ganglion.

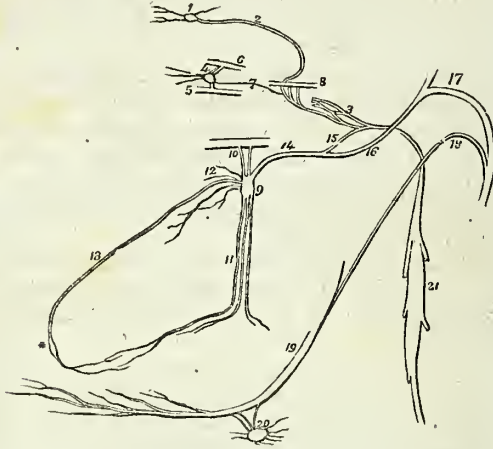
The **GANGLION OF RIBES** is a small ganglion situated upon the anterior communicating artery, and formed by the union of the sympathetic filaments which accompany the ramifications of the two anterior cerebral arteries. These filaments are derived from the carotid plexus at each side; and through their intervention, the ganglion of Ribes is brought into connexion with the carotid plexus, and with the other ganglia of the sympathetic. This ganglion, though of very small size, is interesting, as being the superior point of union between the sympathetic chains of opposite sides of the body.

The **CILIARY GANGLION** (*lenticular*) is a small quadrangular and flattened

ganglion situated within the orbit, between the optic nerve and the external rectus muscle; it is in close contact with the optic nerve, and is surrounded by adipose tissue, which renders its dissection somewhat difficult.

Its *branches of distribution* are the *ciliary*, which arise from its anterior angles by two groups: the upper group, consisting of about four filaments; and the lower, of five or six. They accompany the ciliary arteries in a

Fig. 196.\*



waving course, and divide into a number of filaments which pierce the sclerotic around the optic nerve, and supply the tunics of the eyeball. A small filament is said by Tiedemann, to accompany the arteria centralis retinae into the centre of the globe of the eye.

Its *branches of communication* are three, one, the *long root*, which proceeds from the posterior superior angle to the *nasal* branch of the ophthalmic nerve; a short thick branch, the *short root*, from the posterior inferior angle to the inferior division of the third nerve; and a slender filament, the *sympathetic root*, which passes backwards to the cavernous sinus, and communicates with the carotid plexus. Occasionally the ciliary ganglion

\* The cranial ganglia of the sympathetic nerve. 1. The ganglion of Ribes. 2. The filament by which it communicates with the carotid plexus (3). 4. The ciliary or lenticular ganglion, giving off ciliary branches for the supply of the globe of the eye. 5. Part of the inferior division of the third nerve, receiving a short thick branch (the short root) from the ganglion. 6. Part of the nasal nerve, receiving a longer branch (the long root) from the ganglion. 7. A slender filament (the sympathetic root) sent directly backwards from the ganglion to the carotid plexus. 8. Part of the sixth nerve in the cavernous sinus, receiving two branches from the carotid plexus. 9. Meckel's ganglion (spheno-palatine). 10. Its ascending branches, communicating with the superior maxillary nerve. 11. Its descending or palatine branches. 12. Its internal branches, sphenopalatine or nasal. 13. The nasopalatine branch, one of the nasal branches. \* The nasopalatine ganglion. 14. The posterior branch of the ganglion, the Vidian nerve. 15. Its carotid branch (n. petrosus profundus) communicating with the carotid plexus. 16. Its petrosal branch (n. petrosus superficialis minor), joining the intumescencia gangli-formis of the facial nerve. 17. The facial nerve. 18. The chorda tympani nerve, which descends to join the gustatory nerve. 19. The gustatory nerve. 20. The submaxillary ganglion, receiving the chorda tympani, and other filaments from the gustatory. 21. The superior cervical ganglion of the sympathetic.

receives also a filament of communication (middle root) from the sphenopalatine ganglion; and it sometimes sends a twig to the abducens nerve.

The SPHENO-PALATINE GANGLION (Meckel's) the largest of the cranial ganglia of the sympathetic, is very variable in its dimensions. It is situated in the sphenomaxillary fossa.

Its branches are divisible into four groups; ascending, descending, internal, and posterior.

The *branches of distribution* are the internal and the descending. The *internal* branches are the nasal and the naso-palatine. The *nasal* or *sphenopalatine nerves*, four or five in number, enter the nasal fossa through the sphenopalatine foramen, and are distributed to the mucous membrane of the superior meatus, and superior and middle spongy bones. Besides these, several branches issue through small openings in the palate and sphenoid bone, and supply the mucous membrane of the upper part of the pharynx and the Eustachian tube.

The *naso-palatine nerve* (Scarpa) enters the nasal fossa with the nasal nerves, and crosses the roof of the nares to reach the septum, to which it gives several filaments. It then curves downwards and forwards to the naso-palatine canal, and enters the anterior palatine canal, where it joins with its fellow of the opposite side, and receives filaments from the anterior dental and palatine nerves. By this junction an enlargement is formed, the *naso-palatine ganglion* (Cloquet's), which distributes filaments to the mucous membrane of the palate, immediately behind the incisor teeth.

The *descending* branches are the three palatine nerves, anterior, middle, and posterior.

The *anterior palatine nerve*, the largest of the three, descends from the ganglion through the posterior palatine canal, and emerges at the posterior palatine foramen. It then passes forwards in the substance of the hard palate to which it is distributed, and communicates with the naso-palatine ganglion and with its branches. While in the posterior palatine canal this nerve gives off several branches, which enter the nose through openings in the palate bone, and are distributed to the middle and inferior meatus, the inferior spongy bone, and the antrum.

The *middle palatine nerve* descends through the same canal to the posterior palatine foramen, and distributes branches to the tonsil, soft palate, and uvula.

The *posterior palatine nerve*, the smallest of the three, quits the other nerves to enter a distinct canal, from which it emerges by a separate opening behind the posterior palatine foramen. It is distributed to the hard palate and gums near the point of its emergence, and to the tonsil and soft palate.

The *branches of communication* are the ascending and the posterior. The *ascending* branches are, one or two to join the superior maxillary nerve; one to the abducens nerve; one to the ciliary ganglion constituting its middle root; and occasionally two filaments to the optic nerve within the orbit. The *posterior* branch is the Vidian or pterygoid nerve.

The *Vidian\* nerve* passes directly backwards from the sphenopalatine

\* Guido Guidi, latinized into Vidus Vidius, was professor of anatomy and medicine in the College of France in 1542. His work is posthumous, and was published in 1611.

ganglion, through the pterygoid or Vidian canal, to the foramen lacerum basis cranii, where it divides into two branches, the *carotid* and *petrosal*. The *carotid branch* (n. petrosus profundus) crosses the foramen lacerum, surrounded by the ligamentous substance which closes that opening and enters the carotid canal by several filaments to join the carotid plexus. The *petrosal branch* (n. petrosus superficialis major) enters the cranium through the foramen lacerum basis cranii, piercing the ligamentous substance of the latter, and passes backwards beneath the Casserian ganglion and dura mater, embedded in a groove upon the anterior surface of the petrous bone, to the hiatus Fallopii. In the hiatus Fallopii the petrosal branch of the Vidian receives a twig from Jacobson's nerve, and terminates in the intumescentia gangliformis of the facial nerve.

While in the pterygoid canal the Vidian nerve sends off a minute branch which passes through an opening in the sphenoid bone and joins the otic ganglion.

The OTIC GANGLION (Arnold's)\* is a small oval-shaped and flattened ganglion, resting against the inner surface of the inferior maxillary nerve, immediately below the foramen ovale; it is in *relation externally* with the trunk of the inferior maxillary nerve, just at the point of union of the motor root; *internally* it rests against the cartilage of the Eustachian tube and tensor palati muscle; and *posteriorly* it is in contact with the arteria meningea media. It is closely adherent to the internal pterygoid nerve, and appears like a swelling upon that branch.

The branches of the otic ganglion are seven in number; two of distribution, and five of communication.

The *branches of distribution* are, a small filament to the tensor tympani muscle, and one to the tensor palati muscle; the latter is usually derived from the internal pterygoid nerve, at the point where that nerve is enclosed by the ganglion.

The *branches of communication* are, two or three filaments to the outer portion of the inferior maxillary nerve; one or two filaments to the auricular nerve; a filament to the chorda tympani; filaments to the arteria meningea media to communicate with the nervi molles; a filament which enters the cranium through the foramen spinosum with the arteria meningea media, and accompanies the nervus petrosus superficialis minor to the hiatus Fallopii, where it joins the intumescentia gangliformis of the facial nerve; a filament which enters the cranium through a small canal behind the foramen rotundum to join the Casserian ganglion; a filament which enters a small canal near the foramen ovale to communicate with the Vidian nerve; and the *nervus petrosus superficialis minor*. The latter nerve ascends from the ganglion to a small canal situated between the foramen ovale and foramen spinosum, and passes backwards on the petrous bone to the hiatus Fallopii, where it divides into two filaments. One of these filaments enters the hiatus and joins the intumescentia gangliformis of the facial; the other passes to a minute foramen nearer the base of the petrous bone and enters the tympanum, where it communicates with a branch of Jacobson's nerve.

The SUBMAXILLARY GANGLION is a small round or triangular ganglion,

\* Frederick Arnold, "Dissertatio Inauguralis de Parte Cephalica Nervi Sympathetici," Heidelberg, 1826; and "Ueber den Oliknoten," 1828

situated upon the submaxillary gland, in close relation with the gustatory nerve and near the posterior border of the mylo-hyoideus muscle.

Its *branches of distribution*, six or eight in number, divide into many filaments, which supply the substance of the submaxillary gland and Wharton's duct.

Its *branches of communication* are, two or three from and to the gustatory nerve; one from the chorda tympani; and one or two filaments which pass to the facial artery and communicate with the *nervi molles* from the cervical portion of the sympathetic.

**CAROTID PLEXUS.**—The ascending branch of the superior cervical ganglion enters the carotid canal with the internal carotid artery, and divides into two branches, which form several loops of communication with each other around the artery. These branches, together with those derived from the petrosal branch of the Vidian, constitute the *carotid plexus*. They also form frequently a small gangliform swelling upon the under part of the artery, which is called the *carotid ganglion*. The latter, however, is not constant. The continuation of the carotid plexus onwards with the artery by the side of the sella turcica, is called the *cavernous plexus*.

The carotid plexus is the centre of communication between all the cranial ganglia; and being derived from the superior cervical ganglion, between the cranial ganglia and those of the trunk, it also communicates with the greater part of the cerebral nerves, and distributes filaments with each of the branches of the internal carotid, which accompany those branches in all their ramifications.

Thus, the *Ganglion of Ribes* is formed by the union of the filaments which accompany the anterior cerebral arteries, and which meet on the anterior communicating artery. The *ciliary ganglion* communicates with the plexus by means of the long branch which is sent back to join it in the cavernous sinus. The *spheno-palatine*, and with it the *naso-palatine ganglion*, joins the plexus by means of the carotid branch of the Vidian. The *submaxillary ganglion* is brought into connexion with it by means of the otic ganglion, and the *otic ganglion* by means of the tympanic nerve and the Vidian.

It communicates with the third nerve in the cavernous sinus, and through the ciliary ganglion; frequently with the fourth in the formation of the nerve of the tentorium; with the Casserian ganglion; with the *ophthalmic* division of the fifth in the cavernous sinus, and by means of the ciliary ganglion; with the superior maxillary, through the spheno-palatine ganglion; and with the inferior maxillary, through the otic ganglion. It sends two branches directly to the sixth nerve, which unite\* with it as it crosses the cavernous sinus; it communicates with the facial and auditory nerves, through the medium of the petrosal branch of the Vidian; and with the glosso-pharyngeal by means of two filaments to the tympanic nerve.

#### CERVICAL GANGLIA.

The *Superior cervical ganglion* is long and fusiform, of a greyish colour, smooth, and of considerable thickness, extending from within an inch of

\* Panizza, in his "Experimental Researches on the Nerves," denies this communication, and states very vaguely that "they are merely lost and entwined around it"—*Edinburgh Medical and Surgical Journal*, January 1836.

the carotid foramen in the petrous bone to opposite the lower border of the third cervical vertebra. It is in relation in front with the sheath of the internal carotid artery and internal jugular vein; and behind with the rectus anticus major muscle.

Its *branches*, like those of all the sympathetic ganglia in the trunk, are divisible into *superior*, *inferior*, *external*, and *internal*; to which may be added, as proper to this ganglion, *anterior*.

The *superior* (carotid nerve) is a single branch which ascends by the side of the internal carotid, and divides into two branches; one lying to the outer side, the other to the inner side of that vessel. The two branches enter the carotid canal, and by their communications with each other and with the petrosal branch of the Vidian, constitute the *carotid plexus*.

The *inferior* or descending branch, sometimes two, is the cord of communication with the middle cervical ganglion.

The *external branches* are numerous, and may be divided into two sets: those which communicate with the glosso-pharyngeal, pneumogastric, and hypoglossal nerves; and those which communicate with the three first cervical nerves.

The *internal branches* are three in number: *pharyngeal*, to assist in forming the pharyngeal plexus; *laryngeal*, to join the superior laryngeal nerve and its branches; and the *superior cardiac nerve*, or *nervus superficialis cordis*.

The *anterior branches* accompany the carotid artery with its branches, around which they form intricate plexuses, and here and there small ganglia; they are called, from the softness of their texture, *nervi molles*, and from their reddish hue, *nervi subrufi*.

The *Middle cervical ganglion* (thyroid ganglion) is of small size, and sometimes altogether wanting. It is situated opposite the fifth cervical vertebra, and rests upon the inferior thyroid artery. This relation is so constant, as to have induced Haller to name it the "thyroid ganglion."

Its *superior branch*, or branches, ascend to communicate with the superior cervical ganglion.

Its *inferior branches* descend to join the inferior cervical ganglion; one of these frequently passes in front of the subclavian artery, the other behind it.

Its *external branches* communicate with the third, fourth, and fifth cervical nerves.

Its *internal branches* are, filaments which accompany the inferior thyroid artery, the inferior thyroid plexus; and the *middle cardiac nerve*, *nervus cardiacus magnus*.

The **INFERIOR CERVICAL GANGLION** (vertebral ganglion) is much larger than the preceding, and is constant in its existence. It is of a semilunar form, and is situated upon the base of the transverse process of the seventh cervical vertebra, immediately behind the vertebral artery: hence its title to the designation "*vertebral ganglion*."

Its *superior branches* communicate with the middle cervical ganglion.

The *inferior branches* pass some before and some behind the subclavian artery, to join the first thoracic ganglion.

The *external branches* consist of two sets; one which communicates with the sixth, seventh, and eighth cervical and first dorsal nerve; and



one which accompanies the vertebral artery along the vertebral canal, forming the *vertebral plexus*. This plexus sends filaments to all the branches given off by the artery, and communicates in the cranium with the filaments of the carotid plexus accompanying the branches of the internal carotid artery.

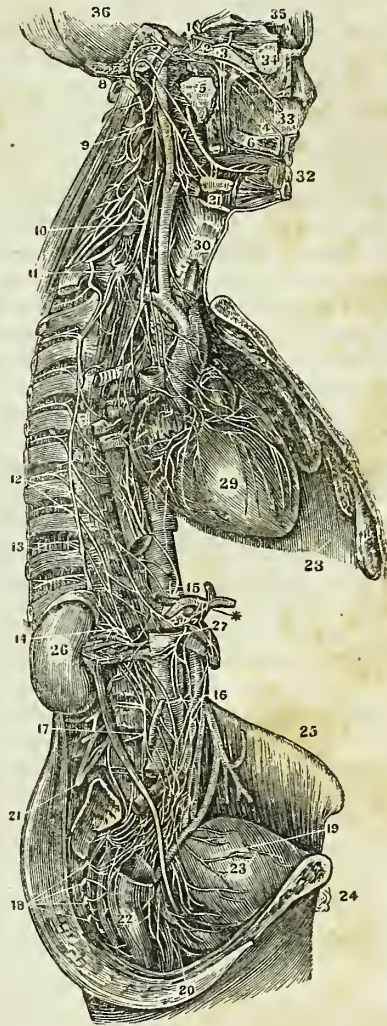
The *internal branch* is the *inferior cardiac nerve*, *nervus cardiacus minor*.

**CARDIAC NERVES.\***—The *superior cardiac nerve* (*nervus superficialis cordis*) arises from the lower part of the superior cervical ganglion; it then descends the neck behind the common carotid artery and parallel with the trachea, crosses the inferior thyroid artery, and running by the side of the recurrent laryngeal nerve for a short distance, passes behind the *arteria innominata* to the concavity of the arch of the aorta, where it joins the *cardiac ganglion*.

In its course it receives branches from the pneumogastric nerve, and sends filaments to the thyroid gland and trachea.

The *Middle cardiac nerve* (*nervus cardiacus magnus*) proceeds from the middle cardiac ganglion, or, in its absence, from the cord of communication between the superior and inferior. It is the largest of the three nerves, and lies nearly parallel with the recurrent

Fig. 197.†



\* There is no constancy with regard to the origin and course of these nerves; therefore the student must not be disappointed in finding the description in discord with *his* dissection.

† A view of the great sympathetic nerve. 36. The cavity of the cranium. 34. The globe of the eye. 33. The septum of the nose. 32. The incisor teeth. 31. The submaxillary gland. 30. The larynx. 29. The heart. 28. The left lung. \* The cœliac axis. 27. The ascending vena cava. 26. The kidney. 25. The crista of the ilium. 23. The bladder. 22. The rectum. 24. The pubes. 1. Plexus on the carotid artery in the carotid foramen. 2. Sixth nerve, (motor externus.) 3. 1st of the fifth or ophthalmic nerve. 4. Branch on the septum narium, connecting Meckel's ganglion with Clouquet's in the incisive foramen. 5. Immediately above the figure is the recurrent branch or Vidian nerve, dividing into the carotid and petrosal branches. 6. Posterior palatine branches. 7. Lingual nerve joined by the chorda tympani. 8. The portio dura of the seventh pair or facial nerve. 9. The superior cervical ganglion. 10. The middle cer

laryngeal. At the root of the neck it divides into several branches, which pass some before and some behind the subclavian artery; it communicates with the superior and inferior cardiac, and with the pneumogastric and recurrent nerves, and descends to the bifurcation of the trachea, to the *great cardiac plexus*.

The *Inferior cardiac nerve* (*nervus cardiacus minor*) arises from the inferior cervical ganglion, communicates freely with the recurrent laryngeal and middle cardiac nerves, and descends to the front of the bifurcation of the trachea, to join the *great cardiac plexus*.

The *Cardiac ganglion* is a ganglionic enlargement of variable size, situated beneath the arch of the aorta, to the right side of the ligament of the ductus arteriosus. It receives the superior cardiac nerves of opposite sides of the neck and a branch from the pneumogastric, and gives off numerous branches to the cardiac plexuses.

The *Great cardiac plexus* is situated upon the bifurcation of the trachea, above the right pulmonary artery, and behind the arch of the aorta. It is formed by the convergence of the middle and inferior cardiac nerves, and by branches from the pneumogastric and descendens noni nerve, and first thoracic ganglion.

The *Anterior cardiac plexus* is situated in front of the ascending aorta, near its origin. It is formed by the communications of filaments that proceed from three different sources, namely, from the superior cardiac nerves, crossing the arch of the aorta; from the cardiac ganglion beneath the arch; and from the great cardiac plexus, passing between the ascending aorta and the right auricle. The anterior cardiac plexus supplies the anterior aspect of the heart, distributing numerous filaments with the left coronary artery, which form the *anterior coronary plexus*.

The *Posterior cardiac plexus* is formed by numerous branches from the great cardiac plexus, and is situated upon the posterior part of the ascending aorta, near its origin. It divides into two sets of branches: one set accompanying the right coronary artery in the auriculo-ventricular sulcus; the other set joining the artery on the posterior aspect of the heart. They both together constitute the *posterior coronary plexus*.

The great cardiac plexus likewise gives branches to the *auricles* of the heart, and others to assist in forming the *anterior* and *posterior pulmonary plexuses*.

#### THORACIC GANGLIA.

The *Thoracic ganglia* are twelve in number on each side. They are flattened and triangular, or irregular in form, and present the peculiar grey colour and pearly lustre of the other sympathetic ganglia; they rest upon the heads of the ribs, and are covered in by the pleura costalis. The two first ganglia and the last are usually the largest.

Their *branches* are superior, inferior, external, and internal.

The *superior* and *inferior* are prolongations of the substance of the ganglia rather than branches; the *former* to communicate with the ganglion above, the *latter* with that below.

vical ganglion. 11. The inferior cervical ganglion. 12. The roots of the great splanchnic nerve, arising from the dorsal ganglia. 13. The lesser splanchnic nerve. 14. The renal plexus. 15. The solar plexus. 16. The mesenteric plexus. 17. The lumbar ganglia. 18. The sacral ganglia. 19. The vesical plexus. 20. The rectal plexus. 21. The lumbar plexus, (cerebro-spinal.)

The *external branches*, two or three in number, communicate with both roots of each of the spinal nerves.

The *internal branches* of the five upper ganglia are *pulmonary* to join the pulmonary plexuses; *œsophageal* to the œsophageal plexus and *aortic* to the thoracic aorta and its branches; the first thoracic ganglion moreover sends branches to the cardiac plexuses. The branches of the lower ganglia are aortic, and several large cords which unite to form the two *splanchnic nerves*.

The *Great splanchnic nerve* arises from the sixth dorsal ganglion, and receives branches from the seventh, eighth, ninth, and tenth, which augment it to a nerve of considerable size. It descends in front of the vertebral column, within the posterior mediastinum, pierces the diaphragm immediately to the outer side of each crus, and terminates in the *semilunar ganglion*.

The *Lesser splanchnic nerve (renal)* is formed by filaments from the tenth, eleventh, and sometimes from the twelfth dorsal ganglion. It pierces the diaphragm, and descends to join the *renal plexus*.

The *Semilunar ganglion* is a large, irregular, gangliform body, pierced by numerous openings, and appearing like the aggregation of a number of smaller ganglia, having spaces between them. It is situated by the side of the cœlic axis, and communicates with the ganglion of the opposite side, both above and below that trunk, so as to form a gangliform circle, from which branches pass off in all directions, like rays from a centre. Hence the entire circle has been named the *solar plexus*.

The *Solar plexus* receives the great splanchnic nerves; part of the lesser splanchnic nerves; the termination of the right pneumogastric nerve; some branches from the right phrenic nerve; and sometimes one or two filaments from the left. It sends numerous filaments, which accompany, under the name of *plexuses*, all the branches given off by the abdominal aorta. Thus, we have derived from the solar plexus the—

|                       |                             |
|-----------------------|-----------------------------|
| Phrenic plexuses,     | Renal plexuses,             |
| Gastric plexus,       | Superior mesenteric plexus, |
| Hepatic plexus,       | Spermatic plexuses,         |
| Splenic plexus,       | Inferior mesenteric plexus. |
| Supra-renal plexuses, |                             |

The *Renal plexus* is formed chiefly by the lesser splanchnic nerve, but receives many filaments from the solar plexus.

The *Spermatic plexus* is formed principally by the renal plexus.

The *Inferior mesenteric plexus* receives filaments from the aortic plexus.

#### LUMBAR GANGLIA.

The *Lumbar ganglia* are four in number on each side, of the peculiar pearly grey colour, fusiform, and situated upon the anterior part of the bodies of the lumbar vertebræ.

The *superior* and *inferior branches* of the lumbar ganglia are branches of communication with the ganglion above and below, as in the dorsal region.

The *external branches*, two or three in number, communicate with the lumbar nerves.

The *internal branches* consist of two sets; of which the upper pass inwards in front of the abdominal aorta, and form around that trunk a plex

iform interlacement, which constitutes the *lumbar aortic plexus*; the lower branches cross the common iliac arteries, and unite over the promontory of the sacrum, to form the hypogastric plexus.

The *Lumbar aortic plexus* is formed by branches from the lumbar ganglia, and receives filaments from the solar and superior mesenteric plexuses. It sends filaments to the inferior mesenteric plexus, and terminates in the hypogastric plexus.

The *Hypogastric plexus* is formed by the termination of the aortic plexus, and by the union of branches from the lower lumbar ganglia. It is situated over the promontory of the sacrum, between the two common iliac arteries, and bifurcates inferiorly into two lateral portions, which communicate with branches from the fourth and fifth sacral nerves. It distributes branches to all the viscera of the pelvis, and sends filaments which accompany the branches of the internal iliac artery.

#### SACRAL GANGLIA.

The *Sacral ganglia* are four or five in number on each side. They are situated upon the sacrum, close to the anterior sacral foramina, and resemble the lumbar ganglia in form and mode of connexion, although much smaller in size.

The *superior and inferior branches* communicate with the ganglia above and below.

The *external branches* communicate with the sacral nerves.

The *internal branches* communicate very freely with the lateral divisions of the hypogastric plexus, and are distributed to the pelvic viscera. The last pair of sacral ganglia give off branches which join a small ganglion, situated on the first bone of the coccyx, called the *ganglion impar*, or *azygos*. This ganglion resembles in its position and function the ganglion of Ribes, serving to connect the inferior extremity of the sympathetic system, as does the former ganglion its upper extremity. It gives off a few small branches to the coccyx and rectum.

## CHAPTER X.

### ORGANS OF SENSE.

THE organs of sense, the instruments by which the animal frame is brought into relation with surrounding nature, are five in number. Four of these organs are situated within the head: viz. the apparatus of smell, sight, hearing, and taste; and the remaining organ, of touch, is resident in the skin, and distributed over the surface of the body.

#### THE NOSE AND NASAL FOSSÆ.

The organ of smell consists essentially of two parts: one external, the *nose*; the other internal, the *nasal fossæ*.

The nose is the triangular pyramid which projects from the centre of the face, immediately above the upper lip. Superiorly it is connected

with the forehead by means of a narrow bridge; inferiorly, it presents two openings, the *nostrils*, which overhang the mouth, and are so constructed that the odour of all substances must be received by the nose before they can be introduced within the lips. The septum between the openings of the nostrils is called the *columnna*. Their entrance is guarded by a number of stiff hairs (*vibrissæ*) which project across the openings, and act as a filter in preventing the introduction of foreign substances, such as dust or insects, with the current of air intended for respiration.

The anatomical elements of which the nose is composed, are—1. Integument. 2. Muscles. 3. Bones. 4. Fibro-cartilages. 5. Mucous membrane. 6. Vessels and nerves.

1. The *Integument* forming the tip (*lobulus*) and wings (*alæ*) of the nose is extremely thick and dense, so as to be with difficulty separated from the fibro-cartilage. It is furnished with an abundance of *sebiparous follicles*, which, by their oily secretion, protect the extremity of the nose in excessive alternations of temperature. The sebaceous matter of these follicles becomes of a dark colour upon the surface, from the attraction of the carbonaceous matter floating in the atmosphere; hence the spotted appearance which the tip of the nose presents in large cities. When the integument is firmly compressed, the inspissated sebaceous secretion is squeezed out from the follicles, and taking the cylindrical form of their excretory ducts, has the appearance of small white maggots with black heads.

2. The *Muscles* are brought into view by reflecting the integument: they are the *pyramidalis nasi*, *compressor nasi*, *dilatator naris*, *levator labii superioris alæque nasi*, and *depressor labii superioris alæque nasi*. They have been already described with the muscles of the face.

3. The *Bones* of the nose are, the nasal, and nasal processes of the superior maxillary.

4. The *Fibro-cartilages* give form and stability to the outwork of the nose, providing, at the same time, by their elasticity, against injuries. They are five in number, namely, the—

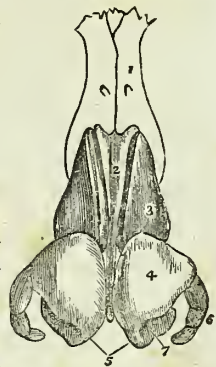
Fibro-cartilage of the septum,  
Two lateral fibro-cartilages,  
Two alar fibro-cartilages.

The *Fibro-cartilage of the septum*, somewhat triangular in form, divides the nose into its two nostrils. It is connected above with the nasal bones and lateral fibro-cartilages; behind, with the ethmoidal septum and vomer; and below, with the palate processes of the superior maxillary bones. The alar fibro-cartilages and *columnna* move freely upon the fibro-cartilage of the septum, being but loosely connected with it by perichondrium.

The *Lateral fibro-cartilages* are also triangular: they are connected, *in front*, with the fibro-cartilage of the septum; *above*, with the nasal bones;

\* The fibro-cartilages of the nose. 1. One of the nasal bones. 2. The fibro-cartilage of the septum. 3. The lateral fibro-cartilage. 4. The alar fibro-cartilage. 5. The central portions of the alar fibro-cartilages which constitute the *columnna*. 6. The appendix of the alar fibro-cartilage. 7. The nostril.

Fig. 198.\*



behind, with the nasal processes of the superior maxillary bones; and *below* with the alar fibro-cartilages.

*Alar fibro-cartilages.*—Each of these cartilages is curved in such a manner as to correspond with the opening of the nostril, to which it forms a kind of rim. The inner portion is loosely connected with the same part of the opposite cartilage, so as to form the *columna*. It is expanded and thickened at the point of the nose to constitute the *lobe*; and on the side forms a curve corresponding with the form of the ala. This curve is prolonged downwards and forwards in the direction of the posterior border of the ala by three or four small fibro-cartilaginous plates, which are appendages of the alar fibro-cartilage.

The whole of these fibro-cartilages are connected with each other and to the bones, by perichondrium, which, from its membranous structure, permits of the freedom of motion existing between them.

5. The *Mucous membrane*, lining the interior of the nose, is continuous with the skin externally, and with the pituitary membrane of the nasal fossæ within. Around the entrance of the nostrils it is provided with numerous *vibrissæ*.

6. *Vessels and Nerves.*—The *Arteries* of the nose are the *lateralis nasi* from the facial, and the *nasalis septi* from the superior coronary.

Its *Nerves* are, the facial, infra-orbital, and nasal branch of the ophthalmic.

#### NASAL FOSSÆ.

To obtain a good view of the *nasal fossæ*, the face must be divided through the nose by a vertical incision, a little to one side of the middle line.

The *Nasal fossæ* are two irregular compressed cavities, extending backwards from the nose to the pharynx. They are bounded *superiorly* by the lateral cartilage of the nose, and by the nasal, sphenoid, and ethmoid bones; *inferiorly* by the hard palate; and, in the *middle* line, they are separated from each other by a bony and fibro-cartilaginous septum. A plan of the boundaries of the nasal fossæ will be found at page 91.

Upon the outer wall of each fossa, in the dried skull, are three projecting processes, termed spongy bones. The two superior belong to the ethmoid, the inferior is a separate bone. In the fresh fossæ these are covered with mucous membrane, and serve to increase the surface of that membrane by their prominence and convoluted form. The space intervening between the superior and middle spongy bone is the *superior meatus*; the space between the middle and inferior the *middle meatus*; and that between the inferior and the floor of the fossa the *inferior meatus*.

These *meatuses* are passages which extend from before backwards, and it is in rushing through and amongst these that the atmosphere deposits its odorant particles upon the mucous membrane. There are several *openings* into the nasal fossæ: thus, in the *superior meatus* are the openings of the sphenoidal and posterior ethmoidal cells; in the *middle* the anterior ethmoidal cells, the frontal sinuses, and the antrum maxillare; and, in the inferior meatus, the termination of the nasal duct. In the dried bone there are two additional openings, the sphenopalatine and the anterior palatine foramen; the former being situated in the superior, and the latter in the inferior meatus.

The *Mucous membrane* of the nasal fossæ is called *pituitary*, or *Schneiderian*.\* The former name being derived from the nature of its secretion, the latter from Schneider, who was the first to show that the secretion of the nose proceeded from the mucous membrane, and not from the brain, as was formerly imagined. It is continuous with the general gastro-pulmonary mucous membrane, and may be traced through the openings in the meatuses, into the sphenoidal and ethmoidal cells; into the frontal sinuses; into the antrum maxillare; through the nasal duct to the surface of the eye, where it is continuous with the conjunctiva; along the Eustachian tubes into the tympanum and mastoid cells, to which it forms the lining membrane; and through the posterior nares into the pharynx and mouth, and thence through the lungs and alimentary canal.

The surface of this membrane is furnished with a columnar epithelium supporting innumerable vibratile cilia.

*Vessels and Nerves.*—The *Arteries* of the nasal fossæ are the anterior and posterior ethmoidal, from the ophthalmic artery; and the sphenopalatine and pterygo-palatine from the internal maxillary.

The *Nerves* are, the olfactory, the sphenopalatine branches from Meckel's ganglion, and the nasal branch of the ophthalmic. The ultimate filaments of the olfactory nerve terminate in papillæ.

#### THE EYE, WITH ITS APPENDAGES.

The form of the eyeball is that of a sphere, of about one inch in diameter, having the segment of a smaller sphere engrafted upon its anterior surface, which increases its antero-posterior diameter. The axes of the two eyeballs are parallel with each other, but do not correspond with the axes of the orbits, which are directed outwards. The optic nerves follow the direction of the orbits, and therefore enter the eyeballs to their nasal side.

The *Globe of the Eye* is composed of *tunics*, and of refracting media called *humours*. The *tunics* are three in number, the

1. Sclerotic and Cornea,
2. Choroid, Iris, and Ciliary processes,
3. Retina and Zonula ciliaris.

The *humours* are also three—

- Aqueous;
- Crystalline (lens),
- Vitreous.

**FIRST TUNIC.**—The Sclerotic and Cornea form the external tunic of the eyeball, and give it its peculiar form. Four-fifths of the globe are invested by the sclerotic, the remaining fifth by the cornea.

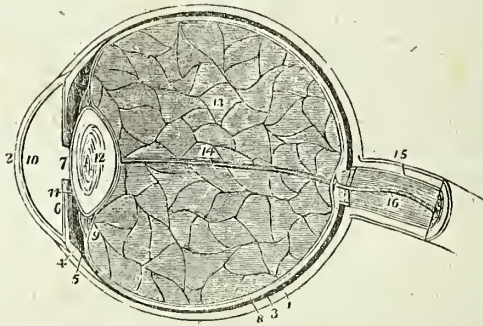
The *Sclerotic* (*σκληρός*, hard) is a dense fibrous membrane, thicker behind than in front. It is continuous, posteriorly, with the sheath of the optic nerve, which is derived from the dura mater, and is pierced by that nerve as well as by the ciliary nerves and arteries. Anteriorly it presents a bevelled edge which receives the cornea in the same way that a watch-

\* Conrad Victor Schneider, professor of medicine at Wittenberg. His work, entitled *De Catarrhis*, &c was published in 1761.

glass is received by the groove in its case. Its anterior surface is covered by a thin tendinous layer, the *tunica albuginea*, derived from the expansion of the tendons of the four recti muscles. By its posterior surface it gives attachment to the two oblique muscles. The *tunica albuginea* is covered, for a part of its extent, by the mucous membrane of the front of the eye; the conjunctiva; and, by reason of the brilliancy of its whiteness, gives occasion to the common expression, "the white of the eye."

At the entrance of the optic nerve, the sclerotic forms a thin *cribriform lamella* (*lamina cribrosa*), which is pierced by a number of minute openings for the passage of the nervous filaments. One of these openings, larger than the rest, and situated in the centre of the lamella, is the *porus opticus* through which the *arteria centralis retinae* enters the eyeball.

Fig. 199.\*



The *Cornea* (*corneus*, horny) is the transparent projecting layer that constitutes the anterior fifth of the globe of the eye. In its form it is circular, concavo-convex, and resembles a watch-glass. It is received by its edge, which is sharp and thin, within the bevelled border of the sclerotic, to which it is very firmly attached, and it is somewhat thicker than the anterior portion of that tunic. When examined from the exterior, its vertical diameter is seen to be about one-sixteenth shorter than the transverse, in consequence of the overlapping above and below, of the margin of the sclerotica; on the interior, however, its outline is perfectly circular.

The cornea is composed of four layers: namely, of the conjunctiva; of the cornea proper, which consists of several thin lamellæ connected together by an extremely fine areolar tissue; of the cornea elastica, a "fine, elastic, and exquisitely transparent membrane, exactly applied to the inner surface

\* A longitudinal section of the globe of the eye. 1. The sclerotic, thicker behind than in front. 2. The cornea, received within the anterior margin of the sclerotic, and connected with it by means of a bevelled edge. 3. The choroid, connected anteriorly with (4) the ciliary ligament, and (5) the ciliary processes. 6. The iris. 7. The pupil. 8. The third layer of the eye, the retina, terminating anteriorly by an abrupt border at the commencement of the ciliary processes. 9. The canal of Petit, which encircles the lens (12); the thin layer in front of this canal is the zonula ciliaris, a prolongation of the vascular layer of the retina to the lens. 10. The anterior chamber of the eye, containing the aqueous humour: the lining membrane by which the humour is secreted is represented in the diagram. 11. The posterior chamber. 12. The lens, more convex behind than before, and enclosed in its proper capsule. 13. The vitreous humour enclosed in the hyaloid membrane, and in cells formed in its interior by that membrane. 14. A tubular sheath of the hyaloid membrane, which serves for the passage of the artery of the capsule of the lens. 15. The neurilemma of the optic nerve. 16. The *arteria centralis retinae*, embedded in the centre of the optic nerve.



of the cornea proper," and of the lining membrane of the anterior chamber of the eyeball. The cornea elastica is remarkable for its perfect transparency, even when submitted for many days to the action of water or alcohol; while the cornea proper is rendered opaque by the same immersion. To expose this membrane, Dr. Jacob suggests that the eye should be placed in water for six or eight days, and, then, that all the opaque cornea should be removed layer after layer. Another character of the cornea elastica is its great elasticity, which causes it to roll up when divided or torn, in the same manner as the capsule of the lens. The use of this layer, according to Dr. Jacob, is to "preserve the requisite permanent correct curvature of the flaccid cornea proper."

The opacity of the cornea, produced by pressure on the globe, results from the infiltration of fluid into the areolar tissue connecting its layers. This appearance cannot be produced in a sound living eye.

*Dissection.*—The sclerotic and cornea are now to be dissected away from the second tunic; this, with care, may be easily performed, the only connexions subsisting between them being at the circumference of the iris, the entrance of the optic nerve, and the perforation of the ciliary nerves and arteries. Pinch up a fold of the sclerotic near its anterior circumference, and make a small opening into it, then raise the edge of the tunic, and with a pair of fine scissors, having a probe point, divide the entire circumference of the sclerotic, and cut it away bit by bit. Then separate it from its attachment around the circumference of the iris by a gentle pressure with the edge of the knife. The dissection of the eye must be conducted under water.

In the course of this dissection the *ciliary nerves* and *long ciliary arteries* will be seen passing forwards between the sclerotic and choroid to be distributed to the iris.

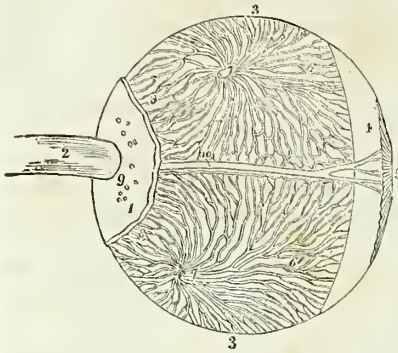
**SECOND TUNIC.**—The second tunic of the eyeball is formed by the *choroid*, *ciliary ligament*, and *iris*, the *ciliary processes* being an appendage developed from its inner surface.

The *Choroid*\* is a vascular membrane of a rich chocolate-brown colour upon its external surface, and of a deep black colour within. It is connected to the sclerotic, externally, by an extremely fine areolar tissue, and by nerves and vessels. Internally it is in simple contact with the third tunic of the eye, the retina. It is pierced posteriorly for the passage of the optic nerve, and is connected anteriorly with the iris, ciliary processes, and with the line of junction of the cornea and sclerotic, by a dense white structure, the *ciliary ligament*, which surrounds the circumference of the iris like a ring.

The choroid membrane is composed of three layers:—an *external* or *venous* layer, which consists principally of veins arranged in a peculiar manner: hence they have been named *venæ vorticosæ*. The marking on

\* The word *choroid* has been very much abused in anatomical language; it was originally applied to the membrane of the fœtus called chorion from the Greek word *χόριον*, domicilium, that membrane being, as it were, the abode or receptacle of the fœtus. *Χόριον* comes from *χωρέω*, to take or receive. Now it so happens that the chorion in the ovum is a vascular membrane of peculiar structure. Hence the term choroid, *χόριον είδος*, like the chorion, has been used indiscriminately to signify vascular structures, as in the choroid membrane of the eye, the choroid plexus, &c., and we find Cruveilhier in his work on *Anatomy*, vol. iii. p. 463, saying in a note, "*Choroide est synonyme de vasculense.*"

Fig. 200.\*



cells, which contain the granules of pigmentum nigrum, and are arranged so as to resemble a tessellated pavement.

In animals, the pigmentum nigrum, on the posterior wall of the eyeball, is replaced by a layer of considerable extent, and of metallic brilliancy, called the tapetum.

The *Ciliary ligament*, or circle, is the bond of union between the external and middle tunics of the eyeball, and serves to connect the cornea and sclerotic, at their line of junction, with the iris and external layer of the choroid. It is also the point to which the ciliary nerves and vessels proceed previously to their distribution, and it receives the anterior ciliary arteries through the anterior margin of the sclerotic. A minute vascular canal is situated within the ciliary ligament, called the ciliary canal, or the canal of Fontana, ‡ from its discoverer.

The *Iris* (iris, a rainbow,) is so named from its variety of colour in different individuals: it forms a septum between the anterior and posterior chambers of the eye, and is pierced somewhat to the nasal side of its centre by a circular opening, which is called the *pupil*. By its periphery it is connected with the ciliary ligament, and by its inner circumference forms the margin of the pupil; its anterior surface looks towards the cornea, and the posterior towards the ciliary processes and lens.

The iris is composed of two layers, an *anterior* or *muscular*, consisting of *radiating* fibres which converge from the circumference towards the centre, and have the power of dilating the pupil; and *circular*, which surround the pupil like a sphincter, and by their action produce contraction

\* A dissection of the eyeball, showing its second tunic, and the mode of distribution of the venæ vorticosæ of the choroid. After Arnold. 1. Part of the sclerotic coat. 2. The optic nerve. 3, 3. The choroid coat. 4. The ciliary ligament. 5. The iris. 6, 6. The venæ vorticosæ. 7, 7. The trunks of the venæ vorticosæ at the point where they have pierced the sclerotica. 8, 8. The posterior ciliary veins, which enter the eyeball in company with the posterior ciliary arteries, by piercing the sclerotic at 9. 10. One of the long ciliary nerves, accompanied by a long ciliary vein.

† Ruysch was born at the Hague in 1638, and was appointed professor of Anatomy at Amsterdam in 1665. His whole life was employed in making injected preparations, for which he is justly celebrated, and he died at the advanced age of ninety-three years. He came to the conclusion that the body was entirely made up of vessels.

‡ Felix Fontana, an anatomist of Tuscany. His "Description of a New Canal in the Eye" was published in 1778, in a Letter to the Professor of Anatomy in Upsal.

of its area. The posterior layer is of a deep purple tint, and is thence named *uvea*, from its resemblance in colour to a ripe grape.

The *Ciliary processes* may be seen in two ways, either by removing the iris from its attachment to the ciliary ligament, when a front view of the processes will be obtained, or by making a transverse section through the globe of the eye, when they may be examined from behind, as in fig. 201.

The ciliary processes consist of a number of triangular folds, formed apparently by the plaiting of the middle and internal layer of the choroid. According to Zinn, they are about sixty in number, and may be divided into large and small, the latter being situated in the spaces between the former. Their periphery is connected with the ciliary ligament, and is continuous with the middle and internal layer of the choroid. The central border is free, and rests against the circumference of the lens. The anterior surface corresponds with the uvea; the posterior receives the folds of the zonula ciliaris between its processes, and thus establishes a connexion between the choroid and the third tunic of the eye. The ciliary processes are covered with a thick layer of pigmentum nigrum, which is more abundant upon them, and upon the anterior part of the choroid, than upon the posterior part. When the pigment is washed off, the processes are of a whitish colour.

Fig. 201.\*

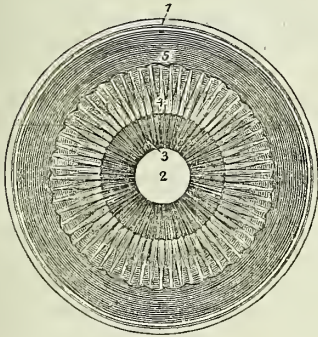
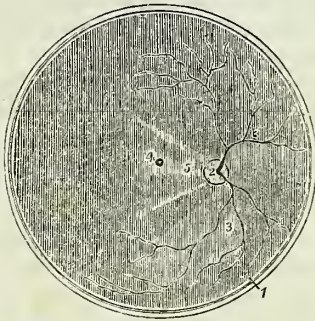


Fig. 202.†



**THIRD TUNIC.**—The third tunic of the eye is the *retina*, which is prolonged forwards to the lens by the *zonula ciliaris*.

*Dissection.*—If, after the preceding dissection, the choroid membrane be carefully raised and removed, the eye being kept under water, the retina may be seen very distinctly.

\* The anterior segment of a transverse section of the globe of the eye, seen from within. 1. The divided edge of the three tunics; sclerotic, choroid (the dark layer), and retina. 2. The pupil. 3. The iris, the surface presented to view in this section being the uvea. 4. The ciliary processes. 5. The scalloped anterior border of the retina.

† The posterior segment of a transverse section of the globe of the eye, seen from within. 1. The divided edge of the three tunics. The membrane covering the whole internal surface is the retina. 2. The entrance of the optic nerve with the arteria centralis retinae piercing its centre. 3, 3. The ramifications of the arteria centralis. 4. The foramen of Soemmering, in the centre of the axis of the eye; the shade from the sides of the section obscures the limbus luteus which surrounds it. 5. A fold of the retina, which generally obscures the foramen of Soemmering after the eye has been opened.

The *Retina* is composed of three layers:—

|                   |                      |
|-------------------|----------------------|
| <i>External</i> , | or Jacob's membrane, |
| <i>Middle</i> ,   | Nervous membrane,    |
| <i>Internal</i> , | Vascular membrane.   |

*Jacob's membrane* is extremely thin, and is seen as a mere film when the freshly dissected eye is suspended in water. Examined by the microscope, it is found to be composed of cells having a tessellated arrangement. Dr. Jacob considers it to be a serous membrane.

The *Nervous membrane* is the expansion of the optic nerve, and forms a thin semi-transparent bluish-white layer, which envelopes the vitreous humour, and extends forwards to the commencement of the ciliary processes, where it terminates by an abrupt scalloped margin. According to Treviranus, this layer is composed of cylindrical fibres, which proceed from the optic nerve, and, near their termination, bend abruptly inwards, to form the internal papillary layer, which lies in contact with the hyaloid membrane; each fibre constituting by its extremity a distinct papilla.

The *Vascular membrane* consists of the ramifications of a minute artery, the *arteria centralis retinae*, and its accompanying vein; the artery pierces the optic nerve, and enters the globe of the eye through the *porus opticus*, in the centre of the *lamina cribrosa*. This artery may be seen very distinctly by making a transverse section of the eyeball. Its branches are continued anteriorly into the *zonula ciliaris*. The vascular layer forms distinct sheaths for the nervous papillæ, which constitute the inner surface of the retina.

In the centre of the posterior part of the globe of the eye the retina presents a circular spot, which is called the *foramen of Soemmering*;\* it is surrounded by a yellow halo, the *limbus luteus*, and is frequently obscured by an elliptical fold of the retina, which has been regarded as a normal condition of the membrane. The term *foramen* is misapplied to this spot, for the vascular layer and the *membrana Jacobi* are continued across it; the nervous substance alone appearing to be deficient. It exists only in animals having the axes of the eyeballs parallel with each other, as man, quadrupeds, and some saurian reptiles, and is said to give passage to a small lymphatic vessel.

The *Zonula ciliaris* (*zonula of Zinn*)† is a thin vascular layer, which connects the anterior margin of the retina with the anterior surface of the lens near its circumference. It presents upon its surface a number of small folds corresponding with the ciliary processes, between which they are received. These processes are arranged in the form of rays around the lens, and the spaces between them are stained by the *pigmentum nigrum* of the ciliary processes. They derive their vessels from the vascular layer of the retina. The under surface of the *zonula* is in contact with the hyaloid membrane, and around the lens forms the anterior fluted wall of the *canal of Petit*.

\* Samuel Thomas Soemmering is celebrated for the beautiful and accurate plates which accompany his works. The account "*De Foramine Centrali Retinae Humanæ, Limbo Luteo cincto*," was published in 1779, in the *Commentationes Soc. Reg. Scient. Gottingensis*.

† John Gottfried Zinn, professor of Anatomy in Göttingen; his "*Descriptio Anatomica Oculi Humani*" was published in 1755, with excellent plates. It was republished by Wrisberg in 1780.

The connexion between these folds and the ciliary processes may be very easily demonstrated by dividing an eye transversely into two portions, then raising the anterior half, and allowing the vitreous humour to separate from its attachment by its own weight. The folds of the zonula will then be seen to be drawn out from between the folds of the ciliary processes.

**HUMOURS.**—The *Aqueous humour* is situated in the anterior and posterior chambers of the eye; it is a weakly albuminous fluid, having an alkaline reaction, and a specific gravity very little greater than that of distilled water. According to Petit, it scarcely exceeds four or five grains in weight.

The *anterior chamber* is the space intervening between the cornea in front, and the iris and pupil behind. The *posterior chamber* is the narrow space, less than half a line in depth,\* bounded by the posterior surface of the iris and pupil in front, and by the ciliary processes, zonula ciliaris, and lens behind. The two chambers are lined by a thin layer, the *secreting membrane of the aqueous humour*.

The *Vitreous humour* forms the principal bulk of the globe of the eye. It is an albuminous and highly transparent fluid, enclosed in a delicate membrane, the *hyaloid*. From the inner surface of this membrane, numerous thin lamellæ are directed inwards, and form compartments in which the fluid is contained. According to Hannover, these lamellæ have a radiated arrangement, like those on the transverse section of an orange, and are about 180 in number. In the centre of the vitreous humour is a tubular canal, through which a minute artery is conducted from the *arteria centralis retinæ* to the capsule of the lens. This vessel is injected without difficulty in the fœtus.

The *Crystalline humour* or *lens* is situated immediately behind the pupil, and is surrounded by the ciliary processes, which slightly overlap its margin. It is more convex on the posterior than on the anterior surface, and is embedded in the anterior part of the vitreous humour, from which it is separated by the hyaloid membrane. It is invested by a peculiarly transparent and elastic membrane, the capsule of the lens, which contains a small quantity of fluid, called *liquor Morgagni*,† and is retained in its place by the attachment of the zonula ciliaris. Dr. Jacob is of opinion that the lens is connected to its capsule by means of areolar tissue, and that the liquor Morgagni is the result of a cadaveric change.

The lens consists of concentric layers, of which the external are soft, the next firmer, and the central form a hardened nucleus. These layers are best demonstrated by boiling, or by immersion in alcohol, when they separate easily from each other. Another division of the lens takes place at the same time: it splits into three triangular segments, which have the sharp edge directed towards the centre, and the base towards the circumference. The concentric lamellæ are composed of minute parallel fibres, which are united with each other by means of scalloped borders, the con-

\* Winslow and Lieutaud thought the iris to be in contact with the lens; it frequently adheres to the capsule of the latter in iritis. The depth of the posterior chamber is greater in old than in young persons.

† John Baptist Morgagni was born in 1682. He was appointed Professor of Medicine in Bologna, and published the first part of his "*Adversaria Anatomica*" in 1706. He died in 1771.

7exity on the one border fitting accurately the concave scallop upon the other.

Immediately around the circumference of the lens is a triangular canal, the *canal of Petit*,\* about a line and a half in breadth. It is bounded, in front, by the flutings of the zonula ciliaris; behind, by the hyaloid membrane; and, within, by the border of the lens.

The *Vessels* of the globe of the eye are the long and short, and anterior ciliary arteries, and the arteria centralis retinæ. The *long ciliary arteries*, two in number, pierce the posterior part of the sclerotic, and pass forward on each side, between that membrane and the choroid, to the ciliary ligament, where they divide into two branches, which are distributed to the iris. The *short ciliary arteries* pierce the posterior part of the sclerotic coat, and are distributed to the middle layer of the choroid membrane. The *anterior ciliary* are branches of the muscular arteries. They enter the eye through the anterior part of the sclerotic, and are distributed to the iris. It is the increased number of these latter arteries, in iritis, that gives rise to the peculiar red zone around the circumference of the cornea which accompanies that disease.

The *arteria centralis retinæ* enters the optic nerve at about half an inch from the globe of the eye, and passing through the porus opticus is distributed upon the inner surface of the retina, forming its vascular layer; one branch pierces the centre of the vitreous humour, and supplies the capsule of the lens.

The *Nerves* of the eyeball are, the optic, two ciliary nerves from the nasal branch of the ophthalmic, and the ciliary nerves from the ciliary ganglion.

*Observations.*—The sclerotic is a tunic of protection, and the cornea a medium for the transmission of light. The choroid supports the vessels destined for the nutrition of the eye, and by its pigmentum nigrum absorbs all loose and scattered rays that might confuse the image impressed upon the retina. The iris, by means of its powers of expansion and contraction, regulates the quantity of light admitted through the pupil. If the iris be thin, and the rays of light pass through its substance, they are immediately absorbed by the uvea; and if that layer be insufficient, they are taken up by the black pigment of the ciliary processes. In Albinoes, where there is an absence of pigmentum nigrum, the rays of light traverse the iris, and even the sclerotic, and so overwhelm the eye with light, that sight is destroyed, except in the dimness of evening or at night. In the manufacture of optical instruments care is taken to colour their interior black with the same object, the absorption of scattered rays.

The transparent lamellated cornea and the humours of the eye have for their office the refraction of the rays in such proportion as to direct the image in the most favourable manner upon the retina. Where the refracting medium is too great, as in over convexity of the cornea and lens, the image falls short of the retina (*myopia*, near-sightedness); and where it is too little, the image is thrown beyond the nervous membrane (*presbyopia*, far-sightedness). These conditions are rectified by the use of spectacles, which provide a differently refracting medium externally to the eye, and thereby correct the transmission of light.

\* John Louis Petit, a celebrated French surgeon: he published several surgical and anatomical Essays, in the early part of the 18th century. He died in 1750.

## APPENDAGES OF THE EYE.

The *Appendages of the Eye* (*tutamina oculi*) are, the eyebrows, eyelids, eyelashes, conjunctiva, caruncula lachrymalis, and the lachrymal apparatus.

The *Eyebrows* (*supercilia*) are two projecting arches of integument covered with short thick hairs, which form the upper boundary of the orbits. They are connected beneath with the orbiculares, occipito-frontales, and corrugatores superciliarum muscles; their use is to shade the eyes from too vivid a light, or protect them from particles of dust and moisture floating over the forehead.

The *Eyelids* (*palpebræ*) are two valvular layers placed in front of the eye, serving to defend it from injury by their closure. When drawn open, they leave between them an elliptical space, the angles of which are called *canthi*. The outer canthus is formed by the meeting of the two lids at an acute angle. The inner canthus is prolonged for a short distance inwards towards the nose, and a triangular space is left between the lids in this situation, which is called the *lacus lachrymalis*. At the commencement of the lacus lachrymalis upon each of the two lids is a small angular projection, the *lachrymal papilla* or *tubercle*; and at the apex of each papilla a small orifice (*punctum lachrymale*), the commencement of the lachrymal canal.

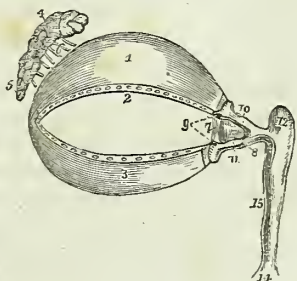
The eyelids have, entering into their structure, *integument*, *orbicularis muscle*, *tarsal cartilages*, *Meibomian glands*, and *conjunctiva*.

The tegumentary areolar tissue of the eyelids is remarkable for its looseness and for the absence of adipose substance; it is particularly liable to serous infiltration. The fibres of the orbicularis muscle covering the eyelids, are extremely thin and pale.

The *Tarsal cartilages* are two thin lamellæ of fibro-cartilage about an inch in length, which give form and support to the eyelids. The *superior* is of a semilunar form, about one-third of an inch in breadth at its middle, and tapering to each extremity. Its lower border is broad and flat, its upper is thin, and gives attachment to the levator palpebræ and to the fibrous membrane of the lids.

The *Inferior fibro-cartilage* is an elliptical band, narrower than the superior, and situated in the substance of the lower lid. Its upper border is flat, and corresponds with the flat edge of the upper cartilage. The lower is held in its place by the fibrous membrane. Near the inner canthus the tarsal cartilages terminate, at the commencement of the lacus lach-

Fig. 203.\*



\* The appendages of the eye. 1. The superior tarsal cartilage. 2. The lower border of the cartilage on which are seen the openings of the Meibomian glands. 3. The inferior tarsal cartilage; along the upper border of this cartilage the openings of the Meibomian glands are likewise seen. 4. The lachrymal gland; its superior or orbital portion. 5. Its inferior or palpebral portion. 6. The lachrymal ducts. 7. The plica semilunaris. 8. The caruncula lachrymalis. 9. The puncta lachrymalia of the lachrymal canals. 10. The superior lachrymal canal. 11. The inferior lachrymal canal. 12. The lachrymal sac. 14. The dilatation of the nasal duct, where it opens into the inferior meatus of the nose. 15. The nasal duct.

rymalis, and are attached to the margin of the orbit by the *tendo oculi*. At their outer extremity they terminate at a short distance from the angle of the canthus, and are retained in their position by means of a decussation of the fibrous structure of the broad tarsal ligament, called the *external palpebral ligament*.

The *Fibrous membrane* of the lids is firmly attached to the periosteum, around the margin of the orbit, by its circumference, and to the tarsal cartilages by its central margin. It is thick and dense on the outer half of the orbit, but becomes thin to its inner side. Its use is to retain the tarsal cartilages in their place, and give support to the lids; hence it has been named the *broad tarsal ligament*.

The *Meibomian glands*\* are embedded in the internal surface of the cartilages, and are very distinctly seen on examining the inner aspect of the lids. They have the appearance of parallel strings of pearls, about thirty in number in the upper cartilage, and somewhat fewer in the lower; and open by minute foramina on the edges of the lids. They correspond in length with the breadth of the cartilage, and are consequently longer in the upper than in the lower lid.

Each gland consists of a single lengthened follicle or tube, into which a number of small clustered follicles open; the latter are so numerous as almost to conceal the tube by which the secretion is poured out upon the margin of the lids. Occasionally an arch is formed between two of them, and produces a very graceful appearance.

The edges of the eyelids are furnished with a triple row of long thick hairs, which curve upwards from the upper lid, and downwards from the lower, so that they may not interlace with each other in the closure of the eyelids, and prove an impediment to the opening of the eyes. These are the *eyelashes (cilia)*, important organs of defence to the sensitive surface of so delicate an organ as the eye.

The *Conjunctiva* is the mucous membrane of the eye. It covers the whole of its anterior surface, and is then reflected upon the lids so as to form their internal layer. The duplicatures formed between the globe of the eye and the lids are called the *superior* and *inferior palpebral sinuses*, of which the former is much deeper than the inferior. Where it covers the cornea the conjunctiva is very thin and closely adherent, and no vessels can be traced into it. Upon the sclerotica it is thicker and less adherent, but upon the inner surface of the lids is very closely connected, and exceedingly vascular. It is continuous with the general gastro-pulmonary mucous membrane and sympathises in its affections, as may be observed in various diseases. From the surface of the eye it may be traced through the lachrymal ducts into the lachrymal gland; along the edges of the lids it is continuous with the mucous lining of the Meibomian glands, and at the inner angle of the eye may be followed through the lachrymal canals into the lachrymal sac, and thence downwards through the nasal duct into the inferior meatus of the nose.

The *Caruncula lachrymalis* is the small reddish body which occupies the lacus lachrymalis at the inner canthus of the eye. In health it presents a bright pink tint; in sickness it loses its colour and becomes pale. It consists of an assemblage of follicles similar to the Meibomian glands, embedded in a fibro-cartilaginous tissue, and is the source of the whitish secretion which so constantly forms at the inner angle of the eye. It is

\* Henry Meibomius, "de Vasis Palpebrarum Novis," 1666.



covered with minute hairs which are sometimes so long as to be distinctly visible to the naked eye.

Immediately to the outer side of the caruncula is a slight duplicature of the conjunctiva, called *plica semilunaris*, which contains a minute plate of cartilage, and is the rudiment of the third lid of animals, the *membrana nictitans* of birds.

*Vessels and Nerves.*—The palpebræ are supplied internally with *arteries* from the ophthalmic, and externally from the facial and transverse facial. Their *nerves* are branches of the fifth and of the facial.

#### LACHRYMAL APPARATUS.

The *Lachrymal apparatus* consists of the lachrymal gland with its excretory ducts; the puncta lachrymalia, and lachrymal canals; the lachrymal sac and nasal duct.

The *Lachrymal gland* is situated at the upper and outer angle of the orbit, and consists of two portions, orbital and palpebral. The *orbital portion*, about three-quarters of an inch in length, is flattened and oval in shape, and occupies the lachrymal fossa in the orbital plate of the frontal bone. It is in contact superiorly with the periosteum, with which it is closely connected by its upper and convex surface; by its inferior or concave surface it is in relation with the globe of the eye, and the superior and external rectus; and by its anterior border with the broad tarsal ligament. By its posterior border it receives its vessels and nerves. The *palpebral portion*, smaller than the preceding, is situated in the upper eyelid, extending downwards to the superior margin of the tarsal cartilage. It is continuous with the orbital portion above, and is enclosed in an investment of dense fibrous membrane. The secretion of the lachrymal gland is conveyed away by from eight to twelve small ducts, which run for a short distance beneath the conjunctiva, and open upon its surface by a series of pores about one-twentieth of an inch apart, situated in a curved line a little above the upper border of the tarsal cartilage.

*Lachrymal Canals.*—The lachrymal canals commence at the minute openings, puncta lachrymalia, seen upon the lachrymal papillæ of the lids at the outer extremity of the lacus lachrymalis, and proceed inwards to the lachrymal sac, where they terminate beneath a valvular semilunar fold of the lining membrane of the sac. The *superior duct* at first ascends, and then turns suddenly inwards towards the sac, forming an abrupt angle. The inferior duct forms the same kind of angle, by descending at first, and then turning abruptly inwards. They are dense and elastic in structure, and remain constantly open, so that they act like capillary tubes in absorbing the tears from the surface of the eye. The two fasciculi of the tensor tarsi muscle are inserted into these ducts, and serve to draw them inwards.

The *Lachrymal sac* is the upper extremity of the nasal duct, and is scarcely more dilated than the rest of the canal. It is lodged in the groove of the lachrymal bone, and is often distinguished, internally, from the nasal duct, by a semilunar or circular valve. The sac consists of mucous membrane, but is covered in and retained in its place by a fibrous expansion, derived from the tendon of the orbicularis, which is inserted into the ridge on the lachrymal bone; it is also covered by the tensor tarsi

muscle, which arises from the same ridge, and in its action upon the lachrymal canals may serve to compress the lachrymal sac.

The *Nasal duct* is a short canal about three-quarters of an inch in length, directed downwards, backwards, and a little outwards to the inferior meatus of the nose, where it terminates by an expanded orifice. It is lined by mucous membrane, which is continuous with the conjunctiva above, and with the pituitary membrane of the nose below. Obstruction, from inflammation and suppuration of this duct, constitutes the disease called fistula lachrymalis.

*Vessels and Nerves.*—The lachrymal gland is supplied with blood by the lachrymal branch of the ophthalmic artery, and with nerves by the lachrymal branch of the ophthalmic and orbital branch of the superior maxillary.

#### THE ORGAN OF HEARING.

The apparatus of hearing is composed of three parts; the external ear, middle ear or tympanum, and internal ear or labyrinth.

The EXTERNAL EAR consists of two portions, the *pinna* and *meatus*; the former representing a kind of funnel which collects the vibrations of the atmosphere, producing sounds, and the latter a tube which conveys the vibrations to the tympanum.

The PINNA presents a number of holes and hollows upon its surface, which have different names assigned to them. Thus, the external folded margin is called the *helix* (ἑλῆξ, a fold). The elevation parallel to and in front of the helix is called *antihelix* (ἀντι, opposite). The pointed process, projecting like a valve over the opening of the ear from the face, is called the *tragus* (τράγος, a goat), probably from being sometimes covered with bristly hair like that of a goat; and a tubercle opposite to this is the *anti-tragus*. The lower dependent and fleshy portion of the pinna is the *lobulus*. The space between the helix and antihelix is named the *fossa innominata*. Another depression is observed at the upper extremity of the antihelix, which bifurcates and leaves a triangular space between its branches, called the *scaphoid fossa*; and the large central space, to which all the channels converge, is the *concha*, which opens directly into the *meatus*.

The pinna is composed of *integument*, *fibro-cartilage*, *ligaments*, and *muscles*.

The *Integument* is thin, contains an abundance of sebiparous glands, and is closely connected with the fibro-cartilage.

The *Fibro-cartilage* gives form to the pinna, and is folded so as to produce the various convexities and grooves which have been described upon its surface. The *helix* commences in the concha, and partially divides that cavity into two parts; on its anterior border is a tubercle for the attachment of the *atrahens aurem* muscle, and a little above this a small vertical fissure, the *fissure of the helix*. The termination of the helix and antihelix forms a lengthened process, the *processus caudatus*, which is separated from the concha by an extensive fissure. Upon the anterior surface of the tragus is another fissure, the *fissure of the tragus*, and in the lobulus the fibro-cartilage is wholly deficient. The fibro-cartilage of the meatus, at the upper and anterior part of the cylinder, is divided from

the concha by a fissure which is closed in the entire ear by ligamentous fibres; it is firmly attached at its termination to the processus auditorius.

The *Ligaments* of the external ear are those which attach the pinna to the side of the head, viz. the anterior, posterior, and ligament of the tragus; and those of the fibro-cartilage, which serve to preserve its folds and connect the opposite margins of the fissures. The latter are two in number, the ligament between the concha and the processus caudatus, and the broad ligament which extends from the upper margin of the fibro-cartilage of the tragus to the helix, and completes the meatus.

The proper *Muscles* of the pinna are the—

Major heliçis,  
Minor heliçis,  
Tragicus,  
Antitragicus,  
Transversus auriculæ.

The *Major heliçis* is a narrow band of muscular fibres situated upon the anterior border of the helix, just above the tragus.

The *Minor heliçis* is placed upon the posterior border of the helix, at its commencement in the fossa of the concha.

The *Tragicus* is a thin quadrilateral layer of muscular fibres, situated upon the tragus.

The *Antitragicus* arises from the antitragus, and is inserted into the posterior extremity, or processus caudatus of the helix.

The *Transversus auriculæ*, partly tendinous and partly muscular, extends transversely from the convexity of the concha to that of the helix, on the posterior surface of the pinna.

These muscles are rudimentary in the human ear, and deserve only the title of muscles in the ears of animals. Two other muscles are described by Mr. Tod,\* the *obliquus auris* and *contractor meatûs*, or *trago-helicus*.

The MEATUS AUDITORIUS is a canal, partly cartilaginous and partly osseous, about an inch in length, which extends inwards and a little forwards from the concha to the tympanum. It is narrower in the middle than at each extremity, forms an oval cylinder, the long diameter being vertical, and is slightly curved upon itself, the concavity looking downwards.

It is lined by an extremely thin pouch of epithelium, which, when withdrawn after maceration, preserves the form of the meatus. Some stiff short hairs are also found in its interior, which stretch across the tube, and prevent the ingress of insects and dust. In the substance of its lining membrane are a number of *ceruminous glands*, which secrete the wax of the ear.

*Vessels and Nerves.*—The pinna is plentifully supplied with *arteries*; by the anterior auricular from the temporal, and by the posterior auricular from the external carotid.

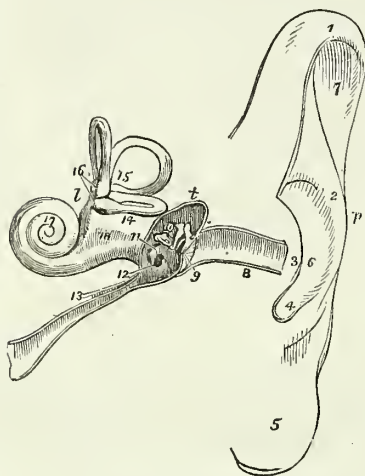
Its *Nerves* are derived from the anterior auricular of the fifth, the posterior auricular of the facial, and the auricularis magnus of the cervical plexus.

\* "The Anatomy and Physiology of the Organ of Hearing," by David Tod, 1832.

## MIDDLE EAR OR TYMPANUM.

The tympanum is an irregular bony cavity, compressed from without inwards, and situated within the petrous bone. It is bounded, *externally*, by the meatus and membrana tympani; *internally*, by the base of the petrous bone; *behind*, by the mastoid cells; and, throughout the rest of its circumference, by the thin osseous layer which connects the petrous with the squamous portion of the temporal bone.

Fig. 204.\*



The *Membrana tympani* is a thin and semi-transparent membrane of an oval shape, its long diameter being vertical. It is inserted into a groove situated around the circumference of the meatus, near its termination, and is placed obliquely across the area of that tube, the direction of the obliquity being downwards and inwards. It is concave towards the meatus, and convex towards the tympanum, and is composed of *three layers*, an *external*, epidermal; *middle*, fibrous and muscular; and, *internal*, mucous, derived from the mucous lining of the tympanum.

The tympanum contains three small bones, *ossicula auditus*, viz., the malleus, incus, and stapes.

The *Malleus* (*hammer*) consists of a head, neck, handle (*manubrium*), and two processes, *long* (*processus gracilis*), and *short* (*processus brevis*). The manubrium is connected with the membrana tympani by its whole length, extending below the central point of that membrane. It lies beneath the mucous layer of the membrane, and serves as a point of attachment to which the radiating fibres of the fibrous layer converge. The long process descends to a groove near the fissura Glaseri, and gives attachment to the laxator tympani muscle. Into the short process is inserted the tendon of the tensor tympani, and the head of the bone articulates with the incus.

The *Incus* (*anvil*) is named from an imagined resemblance to an anvil. It has also been likened to a bicuspid tooth, having one root longer than.

\* A diagram of the ear. *p.* The pinna. *t.* The tympanum. *l.* The labyrinth. 1. The upper part of the helix. 2. The antihelix. 3. The tragus. 4. The antitragus. 5. The lobulus. 6. The concha. 7. The upper part of the fossa innominata. 8. The meatus. 9. The membrana tympani, divided by the section. 10. The three little bones, crossing the area of the tympanum, malleus, incus, and stapes; the foot of the stapes blocks up the fenestra ovalis upon the inner wall of the tympanum. 11. The promontory. 12. The fenestra rotunda; the dark opening above the ossicula leads into the mastoid cells. 13. The Eustachian tube; the little canal upon this tube contains the tensor tympani muscle in its passage to the tympanum. 14. The vestibule. 15. The three semi-circular canals, horizontal, perpendicular, and oblique. 16. The ampullæ upon the perpendicular and horizontal canals. 17. The cochlea. 18. A depression between the convexities of the two tubuli which communicate with the tympanum and vestibule: the one is the scala tympani, terminating at 12; the other is the scala vestibuli.

and widely separated from, the other. It consists of two processes, which unite nearly at right angles, and at their junction form a flattened body, which articulates with the head of the malleus. The short process is attached to the margin of the opening of the mastoid cells by means of a ligament; the long process descends nearly parallel with the handle of the malleus, and curves inwards, near its termination. At its extremity is a small globular projection the *os orbiculare*, which in the fœtus is a distinct bone, but becomes ankylosed to the long process of the incus in the adult; this process articulates with the head of the stapes.

The *Stapes* is shaped like a stirrup, to which it bears a close resemblance. Its head articulates with the *os orbiculare*, and the two branches are connected by their extremities with a flat, oval-shaped plate, representing the foot of the stirrup. The foot of the stirrup is received into the fenestra ovalis, to the margin of which it is connected by means of a circular ligament; it is in contact, by its surface, with the *membrana vestibuli*, and is covered in by the mucous lining of the tympanum. The neck of the stapes gives attachment to the stapedius muscle.

The ossicula auditûs are retained in their position and moved upon themselves by means of ligaments and muscles.

The *Ligaments* are three in number; the ligament of the head of the malleus, which is attached to the upper wall of the tympanum; the ligament of the incus, a short and thick band, which serves to attach the extremity of the short process of that bone to the margin of the opening of the mastoid cells; and the circular ligament which connects the margin of the foot of the stapes with the circumference of the fenestra ovalis. These ligaments have been described as muscles, by Mr. Tod, under the names of superior capitis mallei, obliquus incudis externus posterior, and musculus vel structura stapedii inferior.

The *Muscles of the tympanum* are four in number, the—

Tensor tympani,  
Laxator tympani,  
Laxator tympani minor,  
Stapedius.

The *Tensor tympani* (*musculus internus mallei*) arises from the spinous process of the sphenoid, from the petrous portion of the temporal bone, and from the Eustachian tube, and passes forwards in a distinct canal, separated from the tube by the *processus cochleariformis*, to be inserted into the handle of the malleus, immediately below the commencement of the *processus gracilis*.

The *Laxator tympani* (*musculus externus mallei*) arises from the spinous process of the sphenoid bone, and passes through an opening in the *fissura Glaseri*, to be inserted into the long process of the malleus. This is regarded as a ligament by some anatomists.

The *Laxator tympani minor* arises from the upper margin of the meatus, and is inserted into the handle of the malleus, near the *processus brevis*. This is regarded as a ligament by some anatomists.

The *Stapedius* arises from the interior of the pyramid, and escapes from its summit to be inserted into the neck of the stapes.

*Foramina.*—The openings in the tympanum are ten in number, *five large and five small*; they are—

*Large Openings.*

Meatus auditorius,  
Fenestra ovalis,  
Fenestra rotunda,  
Mastoid cells,  
Eustachian tube.

*Small Openings.*

Entrance of the chorda tympani,  
Exit of the chorda tympani,  
For the laxator tympani,  
For the tensor tympani,  
For the stapedius.

The opening of the *meatus auditorius* has been already described.

The *Fenestra ovalis* (fenestra vestibuli), is a reniform opening, situated at the bottom of a small oval fossa (the pelvis ovalis), in the upper part of the inner wall of the tympanum, directly opposite the meatus. The long diameter of the fenestra is directed horizontally, and its convex borders upwards. It is the opening of communication between the tympanum and vestibule, and is closed by the foot of the stapes and by the lining membranes of both cavities.

The *Fenestra rotunda* (fenestra cochleæ) is somewhat triangular in its form, and situated in the inner wall of the tympanum, below and rather posteriorly to the fenestra ovalis, from which it is separated by a bony elevation, called the *promontory*. It serves to establish a communication between the tympanum and the cochlea. In the fresh subject it is closed by a proper membrane (m. tympani secundaria,) as well as by the lining of both cavities.

The *Mastoid cells* are numerous, and occupy the whole of the interior of the mastoid process and part of the petrous bone. They communicate by a large irregular opening with the upper and posterior circumference of the tympanum.

The *Eustachian tube* is a canal of communication extending obliquely between the pharynx and the anterior circumference of the tympanum. In structure it is partly fibro-cartilaginous and partly osseous, is broad and expanded at its pharyngeal extremity, and narrow and compressed at the tympanum.

The *smaller openings* serve for the transmission of the chorda tympani nerve, and three of the muscles of the tympanum.

The *opening* by which the *chorda tympani* enters the tympanum, is at about the middle of its *posterior wall*, and near the root of the pyramid.

The *opening of exit* for the *chorda tympani* is at the fissura Glaseri in the *anterior wall* of the tympanum.

The *opening for the laxator tympani muscle* is also situated in the fissura Glaseri, in the *anterior wall* of the tympanum.

The *opening for the tensor tympani muscle* is in the *inner wall*, immediately above the opening of the Eustachian tube.

The *opening for the stapedius muscle* is at the apex of a conical bony eminence, called the pyramid, which is situated on the *posterior wall* of the tympanum, immediately behind the fenestra ovalis.

Directly *above* the fenestra ovalis is a *rounded ridge* formed by the projection of the *aquæductus Fallopii*.

*Beneath* the fenestra ovalis and separating it from the fenestra rotunda is the *promontory*, a rounded prominence formed by the projection of the

first turn of the cochlea. It is channelled upon its surface by three small grooves, which lodge the three tympanic branches of Jacobson's nerve.

The *Foramina* and *processes of the tympanum* may be arranged, according to their situation, into four groups.

1. In the *External wall* is the *meatus auditorius*, closed by the *membrana tympani*.

2. In the *Inner wall*, from above downwards, are the—

Opening for the tensor tympani,  
Ridge of the aquæductus Fallopii,  
Fenestra ovalis,  
Promontory,  
Grooves for Jacobson's nerve,  
Fenestra rotunda.

3. In the *Posterior wall* are the—

Opening of the mastoid cells,  
Pyramid,  
Opening for the stapedius,  
Opening for Jacobson's nerve,  
Apertura chordæ (entrance).

4. In the *Anterior wall* are the—

Eustachian tube,  
Fissura Glaseri,  
Opening for the laxator tympani,  
Apertura chordæ (exit).

The tympanum is lined by a *vascular mucous membrane*, which invests the ossicula and chorda tympani, and forms the internal layer of the *membrana tympani*. From the tympanum it is reflected into the mastoid cells, which it lines throughout, and it passes through the Eustachian tube to become continuous with the mucous membrane of the pharynx.

*Vessels and Nerves.*—The *Arteries* of the tympanum are derived from the internal maxillary, internal carotid, and posterior auricular.

Its *Nerves* are,—1. Minute branches from the *facial*, which are distributed to the stapedius muscle. 2. The *chorda tympani*, which leaves the facial nerve near the stylo-mastoid foramen, and arches upwards to enter the tympanum at the root of the pyramid; it then passes forwards between the handle of the malleus and long process of the incus, to its proper opening in the fissura Glaseri. 3. The *tympanic branches of Jacobson's nerve*, which are distributed to the membranes of the fenestra ovalis and fenestra rotunda, and to the Eustachian tube, and form a plexus by communicating with the carotid plexus, otic ganglion, and Vidian nerve. 4. A filament from the otic ganglion to the tensor tympani muscle.

#### INTERNAL EAR.

The *Internal ear* is called *labyrinth*, from the complexity of its communications; it consists of a membranous and an osseous portion. The

osseous labyrinth presents a series of cavities, which are channelled through the substance of the petrous bone, and is situated between the cavity of the tympanum and the meatus auditorius internus. It is divisible into the—

Vestibule,  
Semicircular canals,  
Cochlea.

The **VESTIBULE** is a small three-cornered cavity, compressed from without inwards, and situated immediately within the inner wall of the tympanum. The three corners, which are named ventricles or cornua, are placed, one anteriorly, one superiorly, and one posteriorly.

The anterior ventricle receives the oval aperture of the *scala vestibuli*; the superior, the ampullary openings of the superior and horizontal semicircular canals; the posterior, the ampullary opening of the oblique semicircular canal, the common aperture of the oblique and perpendicular canals, the termination of the horizontal canal, and the aperture of the *aquæductus vestibuli*. In the *anterior ventricle* is a small depression, which corresponds with the posterior segment of the *cul de sac* of the meatus auditorius internus; it is called the *fovea hemispherica*, and is pierced by a cluster of small openings, the *macula cribrosa*. In the *superior ventricle* of the vestibule is another small depression, the *fovea elliptica*, which is separated from the *fovea hemispherica* by a projecting crest, the *eminentia pyramidalis*. The latter is pierced by numerous minute openings for the passage of nervous filaments. The *posterior ventricle* presents a third small depression, the *fovea sulciformis*, which leads upwards to the ostium *aquæductus vestibuli*. The *internal wall* of the vestibule corresponds with the bottom of the *cul de sac* of the meatus auditorius internus, and is pierced by numerous small openings for the transmission of nervous filaments. In the *external or tympanic wall* is the reniform opening of the *fenestra ovalis* (*fenestra vestibuli*), the margin of which presents a prominent rim towards the cavity of the vestibule.

The openings of the vestibule may be arranged, like those of the tympanum, into *large* and *small*.

The *Large openings* are seven in number: viz. the—

Fenestra ovalis,  
Scala vestibuli,  
Five openings of the three semicircular canals.

The *Small openings* are the—

Aquæductus vestibuli,  
Openings for small arteries,  
Openings for branches of the auditory nerve.

The *Fenestra ovalis* has already been described; it is the opening from the tympanum.

The opening of the *scala vestibuli* is the oval termination of the vestibular canal of the cochlea.

The *Aquæductus vestibuli* (canal of Cotunnus) is the commencement of the small canal which opens under the osseous scale upon the posterior surface of the petrous bone. It gives passage to a process of membrane



(which is continuous internally with the lining membrane of the vestibule, and externally with the dura mater), and to a small vein.

The *Openings* for *arteries* and *nerves* are situated in the internal wall of the vestibule, and correspond with the termination of the meatus auditorius internus.

The SEMICIRCULAR CANALS are three bony passages communicating with the vestibule, into which they open by both extremities. Near one extremity of each of the canals is a remarkable dilatation of its cavity, which is called the ampulla (sinus ampullaceus). The *superior*, or perpendicular canal (canalis semicircularis verticalis superior), is directed transversely across the petrous bone, forming a projection on the anterior face of the latter. It commences, by means of an ampulla, in the superior ventricle of the vestibule, and terminates posteriorly by joining with the oblique, and forming a common canal, which opens into the upper part of the posterior ventricle. The *middle* or *oblique* canal (canalis semicircularis verticalis posterior) corresponds with the posterior part of the petrous portion of the temporal bone: it commences by an ampullary dilatation in the posterior ventricle, and curves nearly perpendicularly upwards to terminate in the common canal. In the ampulla of this canal are numerous minute openings for nervous filaments. The *inferior* or *horizontal* canal (canalis semicircularis horizontalis) is directed outwards towards the base of the petrous bone, and is shorter than the two preceding. It commences by an ampullary dilatation in the superior ventricle, and terminates in the posterior ventricle.

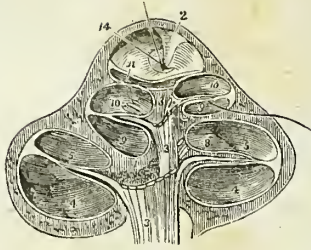
The COCHLEA (*snail-shell*) forms the anterior portion of the labyrinth, corresponding by its apex with the anterior wall of the petrous bone, and by its base with the anterior depression at the bottom of the cul de sac of the meatus auditorius internus. It consists of an osseous and gradually tapering canal, about one inch and a half in length, which makes two turns and a half spirally around a central axis, called the modiolus.

The central axis, or *modiolus*, is large near its base, where it corresponds with the first turn of the cochlea, and diminishes in diameter towards its extremity. At its base, it is pierced by numerous minute openings, which transmit the filaments of the cochlear nerve. These openings are disposed in a spiral manner: hence they have received, from Cotunnus,\* the name of tractus spiralis foraminulentus. The modiolus is everywhere traversed, in the direction of its length, by minute canals, which proceed from the tractus spiralis foraminulentus, and terminate upon the sides of the modiolus, by opening into the canal of the cochlea or upon the surface of its lamina spiralis. The central canal of the tractus spiralis foraminulentus is larger than the rest, and is named the tubulus centralis modioli; it is continued onwards to the extremity of the modiolus, and transmits a nerve and small artery (arteria centralis modioli).

The interior of the canal of the cochlea is partially divided into two passages (*scalæ*) by means of a thin and porous lamina of bone (*zonula ossea laminæ spiralis*), which is wound spirally around the modiolus in the direction of the canal. This bony septum extends for about two-thirds across the diameter of the canal, and in the fresh subject, is pro-

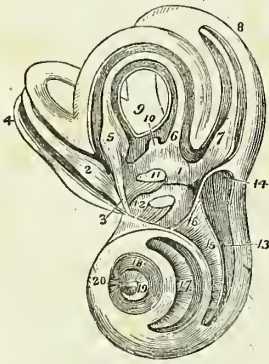
\* Dominico Cotunnus, an Italian physician; his dissertation "De Aquæductibus Auris Humanæ Internæ" was published at Naples in 1761.

Fig. 205.\*



rated throughout their length in the living ear, communicate superiorly, over the hamulus laminae spiralis, by means of an opening common to

Fig. 206.†



longed to the opposite wall by means of a membranous layer, so as to constitute a complete partition, the *lamina spiralis*. The osseous lamina spiralis consists of two thin lamellæ of bone, between which, and through the perforations on their surfaces, the filaments of the cochlear nerve reach the membrane of the cochlea. At the apex of the cochlea the lamina spiralis terminates by a pointed, hook-shaped process, the hamulus laminae spiralis. The two scalæ of the cochlea, which are completely separated throughout their length, communicate superiorly, over the hamulus laminae spiralis, by means of an opening common to both, which has been termed by Breschet *helicotrema* (ἑλιξ, ἐλίσσω volvere—τρήμα). Inferiorly, one of the two scalæ, the scala vestibuli, terminates by means of an oval aperture in the anterior ventricle of the vestibule; while the other, the scala tympani, becomes somewhat expanded, and opens into the tympanum through the fenestra rotunda (fenestra cochleæ). Near the termination of the scala tympani is the small opening of the aquæductus cochleæ.

The internal surface of the osseous labyrinth is lined by a *fibro-serous membrane*, which is analogous to the dura mater in performing the office of a periosteum by its exterior, whilst it fulfils the purpose of a serous membrane by its internal layer, secreting a limpid fluid, the aqua

\* The cochlea divided parallel with its axis, through the centre of the modiolus. After Breschet. 1. The modiolus. 2. The infundibulum in which the modiolus terminates. 3, 3. The cochlear nerve, sending its filaments through the centre of the modiolus. 4, 4. The scala tympani of the first turn of the cochlea. 5, 5. The scala vestibuli of the first turn; the septum between 4 and 5 is the lamina spiralis; a filament of the cochlear nerve is seen passing between the layers of the lamina to be distributed upon the membrane which invests the lamina. 8. Loops formed by the filaments of the cochlear nerve on the lamina spiralis. 9, 9. Scala tympani of the second turn of the cochlea. 10, 10. Scala vestibuli of the second turn; the septum between the two is the lamina spiralis. 11. The remaining half turn of the scala vestibuli; the dome placed over this half turn is the cupola; a line leads from the numeral to the remaining half turn of the scala tympani. The lamina of bone which forms the floor of the scala vestibuli curves spirally round to constitute the infundibulum (2). 14. The helicotrema through which a bristle is passed; its lower extremity issues from the scala tympani of the middle turn of the cochlea. The hamulus laminae spiralis is seen in front of the bristle.

† The labyrinth of the left ear, laid open, in order to show its cavities and the membranous labyrinth. After Breschet. 1. The cavity of the vestibule, opened from its anterior aspect in order to show the three-cornered form of its interior, and the membranous labyrinth which it contains. The figure rests upon the common saccule of the membranous labyrinth,—the sacculus communis. 2. The ampulla of the superior or perpendicular semicircular canal, receiving a nervous fasciculus from the superior branch of the vestibular nerve. 3. 4. The superior or perpendicular canal with its contained membranous canal. 5. The ampulla of the inferior or horizontal semicircular canal, receiving a nervous fasciculus from the superior branch of the vestibular nerve. 6. The termination of the membranous canal of the horizontal semicircular canal in the sacculus communis. 7. The ampulla of the middle or oblique semicircular canal,

labyrinthi (liquor Cotunnii), and sending a reflection inwards upon the nerves distributed to the membranous labyrinth. In the cochlea the membrane of the labyrinth invests the two surfaces of the bony lamina spiralis, and being continued from its border across the diameter of the canal to its outer wall, forms the membranous lamina spiralis, and completes the separation between the scala tympani and scala vestibuli. The fenestra ovalis and fenestra rotunda are closed by an extension of this membrane across them, assisted by the membrane of the tympanum and a proper intermediate layer. Besides lining the interior of the osseous cavity, the membrane of the labyrinth sends two delicate processes along the aqueducts of the vestibule and cochlea to the internal surface of the dura mater, with which they are continuous. These processes are the remains of a communication originally subsisting between the dura mater and the cavity of the labyrinth.\*

The MEMBRANOUS LABYRINTH is smaller in size, but a perfect counterpart with respect to form, of the vestibule and semicircular canals. It consists of a small elongated sac, *sacculus communis* (*utriculus communis*); of three semicircular membranous canals, which correspond with the osseous canals, and communicate with the *sacculus communis*; and of a small round sac (*sacculus proprius*), which occupies the anterior ventricle of the vestibule, and lies in close contact with the external surface of the *sacculus communis*. The membranous semicircular canals are two-thirds smaller in diameter than the osseous canals.

The membranous labyrinth is retained in its position by means of the numerous nervous filaments which are distributed to it from the openings in the inner wall of the vestibule, and is separated from the lining membrane of the labyrinth by the *aqua labyrinthi*. In structure it is composed

receiving a nervous fasciculus from the inferior branch of the vestibular nerve. 8. The oblique semicircular canal with its membranous canal. 9. The common canal, resulting from the union of the perpendicular with the oblique semicircular canal. 10. The membranous common canal terminating in the *sacculus communis*. 11. The otoconite of the *sacculus communis* seen through the membranous parietes of that sac. A nervous fasciculus from the inferior branch of the vestibular nerve is seen to be distributed to the *sacculus communis* near the otoconite. The extremity of the *sacculus* above the otoconite is lodged in the superior ventricle of the vestibule, and that below it in the inferior ventricle. 12. The *sacculus proprius* situated in the anterior ventricle; its otoconite is seen through its membranous parietes, and a nervous fasciculus derived from the middle branch of the vestibular nerve is distributed to it. The spaces around the membranous labyrinth are occupied by the *aqua labyrinthi*. 13. The first turn of the cochlea; the figure points to the *scala tympani*. 14. The extremity of the *scala tympani* corresponding with the *fenestra rotunda*. 15. The *lamina spiralis*; the figure is situated in the *scala vestibuli*. 16. The opening of the *scala vestibuli* into the vestibule. 17. The second turn of the cochlea; the figure is placed upon the *lamina spiralis*, and therefore in the *scala vestibuli*, the *scala tympani* being beneath the *lamina*. 18. The remaining half turn of the cochlea; the figure is placed in the *scala tympani*. 19. The *lamina spiralis* terminating in its falciform extremity. The dark space included within the falciform curve of the extremity of the *lamina spiralis* is the *helicotrema*. 20. The *fundibulum*.

\* Cotunnus regarded these processes as tubular canals, through which the superabundant *aqua labyrinthi* might be expelled into the cavity of the cranium. Mr. Wharton Jones, in the article "Organ of Hearing," in the *Cyclopædia of Anatomy and Physiology*, also describes them as tubular canals which terminate beneath the dura mater of the petrous bone in a small dilated pouch. In the ear of a man, deaf and dumb from birth, he found the termination of the aqueduct of the vestibule of unusually large size in consequence of irregular development.

of four layers; an external or serous layer, derived from the lining membrane of the labyrinth; a vascular layer, in which an abundance of minute vessels are distributed; a nervous layer, formed by the expansion of the filaments of the vestibular nerve; and an internal and serous membrane, by which the limpid fluid which fills its interior is secreted. Some patches of pigment have been observed by Mr. Wharton Jones in the tissue of the membranous labyrinth of man. Among animals such spots are constant.

The membranous labyrinth is filled with a limpid fluid, first well described by Scarpa, and thence named liquor Scarpæ (endolymph,\* vitreous humour of the ear), and contains two small calcareous masses, called otoconites. The *otoconites* (ὄττις, ὠτὸς, κότις, the ear-dust) consist of an assemblage of minute, crystalline particles of carbonate and phosphate of lime, held together by animal substance, and probably retained in form by a reflection of the lining membrane of the membranous labyrinth. They are found suspended in the liquor Scarpæ; one in the sacculus communis, the other in the sacculus proprius, from that part of each sac with which the nerves are connected.

The AUDITORY NERVE divides into two branches at the bottom of the cul de sac of the meatus auditorius internus; a vestibular nerve and a cochlear nerve. The *vestibular nerve*, the most posterior of the two, divides into three branches, superior, middle, and inferior. The superior vestibular branch gives off a number of filaments which pass through the minute openings of the eminentia pyramidalis and superior ventricle of the vestibule, and are distributed to the sacculus communis and ampullæ of the perpendicular and horizontal semicircular canals. The middle vestibular branch sends off numerous filaments, which pass through the openings of the macula cribrosa in the anterior ventricle of the vestibule, and are distributed to the sacculus proprius. The inferior and smallest branch takes its course backwards to the posterior wall of the vestibule, and gives off filaments which pierce the wall of the ampullary dilatation of the oblique canal to be distributed upon its ampulla. According to Stiefensand there is in the situation of the point of entrance of the nervous filaments into the ampulla a deep depression upon the exterior of the membrane, and upon the interior a corresponding projection, which forms a kind of transverse septum, partially dividing the cavity of the ampulla into two chambers. In the substance of the sacculi and ampullæ, the nervous filaments radiate in all directions, anastomosing with each other and forming interlacements and loops, and they terminate upon the inner surface of the membrane in minute papillæ, resembling those of the retina.

The *Cochlear nerve* divides into numerous filaments which enter the foramina of the tractus spiralis foraminulentus in the base of the cochlea, and passing upwards in the canals of the modiolus, bend outwards at right angles, to be distributed in the tissue of the lamina spiralis. The central portion of the nerve passes through the tubulus centralis of the modiolus, and supplies the apical portion of the lamina spiralis. In the lamina spiralis the nervous filaments lying side by side on an even plane form numerous anastomosing loops, and spread out into a nervous membrane.

\* Antonio Scarpa is celebrated for several beautiful surgical and anatomical monographs; as, for example, his work on "Aneurism," "De Auditu et Olfactu," &c. An account of the aqua labyrinthi will be found in his anatomical observations "De Structurâ Fenestræ Rotundæ, et de Tympano Secundario."

According to Treviranus and Gottsche, the ultimate terminations of the filaments assume the form of papillæ.

The *Arteries* of the labyrinth are derived principally from the auditory branch of the superior cerebellar artery.

#### ORGAN OF TASTE.

The *Tongue* is composed of muscular fibres, which are distributed in layers arranged in various directions: thus, some are disposed *longitudinally*; others *transversely*; others, again, *obliquely* and *vertically*. Between the muscular fibres is a considerable quantity of adipose substance.

The tongue is *connected*, posteriorly, with the os hyoides by muscular attachment; and to the epiglottis by mucous membrane, which forms the three folds called *fræna epiglottidis*. On either side it is held in connexion with the lower jaw by mucous membrane, and in front a fold of that membrane, which is named *frænum linguæ*, is formed beneath its under surface.

The surface of the tongue is covered by a dense layer analogous to the corium of the skin, which gives support to papillæ. A *raphé* marks the middle line of the organ, and divides it into symmetrical halves.

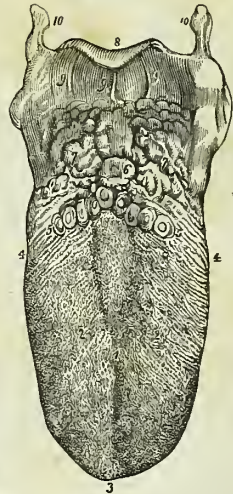
The *Papillæ* of the *tongue* are the—

Papillæ circumvallatæ,  
Papillæ conicæ,  
Papillæ filiformes,  
Papillæ fungiformes.

The *Papillæ circumvallatæ* (p. lenticulares) are of large size, and from fifteen to twenty in number. They are situated on the dorsum of the tongue, near its root, and form a row on each side, which meets its fellow at the middle line, like the two branches of the letter A. Each papilla resembles a cone, attached by its apex to the bottom of a cup-shaped depression: hence they are also named papillæ *calyciformes*. This cup-shaped cavity forms a kind of fossa around the papilla, whence their name *circumvallatæ*. At the meeting of the two rows of these papillæ upon the middle of the root of the tongue, is a deep mucous follicle called *foramen cæcum*.

The *Papillæ conicæ* and *filiformes* cover the whole surface of the tongue in front of the circumvallatæ, but are most abundant towards its anterior part. They are conical and filiform in shape, and many of them are pierced at the extremity by a minute aperture. Hence, they may be regarded as

Fig. 207.\*



\* The tongue with its papillæ. 1. The raphé, which in some tongues bifurcates on the dorsum of the organ, as in the figure. 2, 2. The lobes of the tongue. The rounded eminences on this part of the organ, and near its tip are the papillæ fungiformes. The smaller papillæ, among which the former are dispersed, are the papillæ conicæ and filiformes. 3. The tip of the tongue. 4, 4. Its sides, on which are seen the lamellated and fringed papillæ. 5, 5. The A-shaped row of papillæ circumvallatæ. 6. The foramen cæcum. 7. The mucous glands of the root of the tongue. 8. The epiglottis. 9, 9. The fræna epiglottidis. 10, 10. The greater cornua of the os hyoides.

follicles rather than sentient organs; the true sentient papillæ being extremely minute and occupying their surface, as they do that of the other papillæ of the tongue.

The *Papillæ fungiformes* (p. capitata) are irregularly dispersed over the dorsum of the tongue, and are easily recognised among the other papillæ by their rounded heads and larger size. A number of these papillæ will generally be observed at the tip of the tongue.

Behind the papillæ circumvallatæ, at the root of the tongue, are a number of *mucous glands*, which open upon the surface. They have been improperly described as papillæ by some authors.

*Vessels and Nerves.*—The tongue is abundantly supplied with blood by the lingual arteries.

The *Nerves* are three in number, and of large size: The *gustatory* branch of the fifth, which is distributed to the papillæ, and is the nerve of common sensation and taste. The *glosso-pharyngeal*, which is distributed to the mucous membrane, follicles, and glands of the tongue, is a nerve of sensation and motion; it also serves to associate the tongue with the pharynx and larynx. The *hypoglossal* is the motor nerve of the tongue, and is distributed to the muscles. To these may be added the chorda tympani, which conveys a motor influence from the facial nerve to the lingualis muscle.

The *Mucous membrane* which invests the tongue, is continuous with the derma along the margin of the lips. On either side of the frænum linguæ it may be traced through the sublingual ducts into the sublingual glands, and along Wharton's\* ducts into the submaxillary glands: from the sides of the cheeks it passes through the openings of Stenon's† ducts to the parotid glands: in the fauces, it forms the assemblage of follicles called tonsils, and may thence be traced downwards into the larynx and pharynx, where it is continuous with the general gastro-pulmonary mucous membrane.

Beneath the mucous membrane of the mouth are a number of small *glandular granules*, which pour their secretion upon the surface. A considerable number of them are situated within the lips, in the palate, and in the floor of the mouth. They are named from the position which they may chance to occupy, *labial, palatal glands, &c.*

#### ORGAN OF TOUCH.

The *Skin* is the exterior investment of the body, which it serves to cover and protect. It is continuous at the apertures of the internal cavities with the lining membrane of those cavities, the internal skin or mucous membrane, and is composed essentially of two layers, *derma* and *epiderma*.

The *DERMA* or cutis is chiefly composed of areolo-fibrous tissue, besides which it has entering into its structure elastic and contractile fibrous tissue, together with blood-vessels, lymphatic vessels and nerves. The areolo-fibrous tissue exists in greatest abundance in the deeper stratum of the derma, which is consequently dense, white, and coarse; the superficial

\* Thomas Wharton, an English physician, devoted considerable attention to the anatomy of the various glands; his work, entitled "Adenographia," &c., was published in 1656.

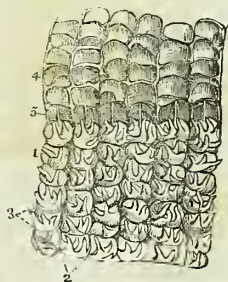† Nicholas Stenon, a Danish anatomist: he was made professor in Copenhagen in 1672.

stratum, on the other hand, is fine in texture, reddish in colour, soft, raised into minute papillæ, and highly vascular and sensitive. These differences in structure have given rise to a division of the derma into the deep stratum, or *corium*, and the superficial, or *papillary* layer.

In the *Corium* the areolo-fibrous tissue is collected into fasciculi, which are small and closely interwoven in the superficial strata, large and coarse in the deep strata; in the latter forming an areolar network with large areolæ, which are occupied by adipose tissue. These areolæ are the channels by which the branches of vessels and nerves find a safe passage to the papillary layer, in which and in the superficial strata of the corium they are principally distributed. The yellow elastic tissue is found chiefly in the superficial strata, the red contractile tissue in the deep. It is to the latter that the nipples and scrotum owe their contractile powers, and the general surface of the skin the contraction which is known by the name of *cutis anserina*. The corium presents some variety in thickness in different parts of the body. Thus in the more exposed regions, as the back, the outer sides of the limbs, the palms, and the soles, it is remarkable for its thickness; while on protected parts it is comparatively thin. On the eyelids, the penis, and the scrotum, it is peculiarly delicate. It is connected by its under surface with the common superficial fascia of the body.

The *Papillary* layer of the derma is raised in the form of conical prominences or papillæ. On the general surface of the body the papillæ are short and exceedingly minute; but in other situations, as the palmar surface of the hands and fingers, and the plantar surface of the feet and toes, they are long and of large size. They also differ in arrangement; for, on the general surface they are distributed at equal distances and without order; whereas, on the palms and soles, and on the corresponding surfaces of the fingers and toes, they are collected into little square clumps containing from ten to twenty papillæ; and these little clumps are disposed in parallel rows. It is this arrangement in rows that gives rise to the characteristic parallel ridges and furrows which are met with on the hands and feet. The papillæ in these little square clumps are for the most part uniform in size and length, but every here and there one papilla may be observed which is longer than the rest. The largest

Fig. 208.\*



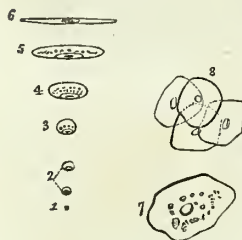
\* Anatomy of a portion of skin taken from the palm of the hand. 1. The papillary layer, in which the longitudinal furrows (2) marking the arrangement of the papillæ into ridges is shown. Each ridge is moreover divided by transverse furrows (3) into small quadrangular clumps. The quadrangular clumps consist of a tuft of minute conical papillæ, of which one or two are frequently longer and larger than the rest. In this figure the long papillæ are alone seen, the rest being too numerous to introduce into a wood-engraving. 4. The rete mucosum raised from the papillary layer and turned back; the under surface of this stratum presents an accurate impression of the papillary layer; on which are seen longitudinal ridges corresponding with the longitudinal furrows, transverse ridges corresponding with the transverse furrows, and quadrangular depressions corresponding with the quadrangular clumps of papillæ. Moreover, whenever one of the long papillæ exists, a distinct conical sheath will be found in the rete mucosum 5, 5. Perspiratory ducts drawn out straight by the separation of the rete mucosum from the papillary layer; the point at which each perspiratory duct issues from the papillary layer, and pierces the rete mucosum, is the middle of the transverse furrow between the quadrangular masses.

papillæ of the derma are those which produce the nail; in the dermal follicle of the nail they are long and filiform, while beneath its concave surface they form longitudinal and parallel plications which extend for nearly the entire length of that organ. In structure each papilla is composed of a more or less convoluted capillary and a more or less convoluted nervous loop.

The EPIDERMA or cuticle (scarf-skin) is a product of the derma, which it serves to envelope and defend. That surface of the epiderma which is exposed to the influence of the atmosphere and exterior sources of injury is hard and horny in texture, while that which lies in contact with the papillary layer is soft and cellular. Hence the epiderma, like the derma, is divisible into two layers, external and internal, the latter being termed the *rete mucosum*. Moreover, the epiderma is laminated in structure, and the laminæ present a progressively increasing tenuity and density as they advance from the inner to the outer surface. This difference of density is dependent on the mode of growth of the epiderma, for as the external surface is constantly subjected to destruction from attrition and chemical action, so the membrane is continually reproduced on its internal surface; new layers being successively formed on the derma to take the place of the old.

The theory of growth of the epiderma, deduced from the observations of Schwann, is as follows:—A stratum of plastic lymph (liquor sanguinis) is poured out upon the surface of the derma. This fluid, by virtue of the vital force inherent in itself, and communicated to it by contact with a living tissue, is converted into granules, which are termed cell-germs, or *cyto-blasts*. By endosmosis, these cyto-blasts imbibe serum from the plastic lymph and adjacent tissues, and the outermost layer or pellicle of the cyto-blast becomes gradually distended by the imbibed fluid. The cyto-blast has now become a cell, and the solid portion of the cyto-blast, which always remains adherent to some one point of the internal surface

Fig. 209.\*



of the cell-membrane, is the *nucleus* of the cell. Moreover, within the nucleus one or several nuclei are formed which are termed *nucleoli*. By a continuance of the process of imbibition, the cell becomes more or less spherical; so that, after a time, every part of the surface of the papillary layer of the derma is coated by a thin and membranous stratum, consisting of spherical cells lying closely pressed together, and corresponding with every irregularity which the papillæ present. But, as this production of cells is a function constantly in operation, a new layer is formed before the first is

completed, and the latter is separated by subsequent formations farther and farther from the surface of the papillary layer. As a consequence of loss of contact with the derma, the vital force is progressively dimi-

\* A diagram illustrative of the development of the epiderma, and of epithelia in general, according to the theory of Schwann. 1. A granule or cyto-blast. 2. The cell seen rising on the cyto-blast; the latter is now a nucleus, and a nucleolus may be detected in its interior. 3. The spheroidal cell. 4. The oval cell. 5. The elliptical cell. 6. The flattened cell; which, by contact of its walls, is speedily converted into a scale in which the nucleus is lost. 7. A nucleated scale as seen upon its flat surface. 8. A cluster of such scales.



nished; the cell becomes subject to the influence of physical laws, and evaporation of its fluid slowly ensues. In consequence of this evaporation, the cell becomes collapsed and flattened, and assumes an elliptical form; the latter is by degrees converted into the flat cell with parallel and contiguous layers, and an included nucleolated nucleus; and lastly, the flattened cell desiccates into a thin membranous scale, in which the nucleus is no longer apparent.

My own investigations\* have shown that, after the original granules of the liquor sanguinis have become aggregated into a granular nucleus, other granules are formed in successive circles, around the circumference of the nucleus, until the entire breadth of the epidermal scale is attained; that the cell never acquires a greater thickness than that of the original nucleus, and, that the formation of the scale results from the desiccation of the cell, as it is gradually pushed outwards from the derma towards the surface. Consequently, the cell never possesses any other than the flattened form; all its phases of growth are perfected in the deepest layer of the epiderma; and, in its internal structure, it is a parent cell containing secondary and tertiary cells and granules, its growth being the result of the growth of these secondary formations.

The under surface of the epiderma is accurately modelled on the papillary layer of the derma, each papilla having its appropriate sheath in the newly-formed epiderma or rete mucosum, and each irregularity of surface of the former having its representative in the soft tissue of the latter. On the external surface, this character is lost; the minute elevations corresponding with the papillæ, are, as it were, polished down, and the surface is rendered smooth and uniform. The palmar and plantar surfaces of the hands and feet are, however, an exception to this rule; for here, in consequence of the large size of the papillæ and their peculiar arrangement in rows, ridges corresponding with the papillæ are strongly marked on the superficial surface of the epiderma. The epiderma is remarkable for its thickness in situations where the papillæ are large, as in the palms and soles. In other situations, it assumes a character which is also due to the nature of the surface of the derma; namely, that of being marked by a network of linear furrows, which trace out the surface into small polygonal and lozenge-shaped areas. These lines correspond with the folds of the derma produced by its movements, and are most numerous where those movements are the greatest, as in the flexures and on the convexities of joints.

The dark colour of the skin among the natives of the South is due to the coloration of the primitive granules of which the cell is composed, especially the nucleus. As the cells desiccate, the colour of the granules is gradually lost; hence the deeper hue of the rete mucosum.

The *pores* of the epiderma are the openings of the perspiratory ducts, hair follicles, and sebiparous glands.

*Vessels and Nerves.*—The *Arteries* of the derma which enter its structure through the areolæ of the under surface of the corium, divide into innumerable intermediate vessels, which form a rich capillary plexus in the superficial strata of the skin and in its papillary layer. In the papillæ of some parts of the derma, as in the longitudinal plications beneath the nail, the capillary vessels form simple loops, but in other papillæ they are convoluted to a greater or less degree in proportion to the size and importance

\* Diseases of the Skin, 2d edition, p. 5.

of the papillæ. The *Lymphatic* vessels probably form, in the superficial strata of the derma, a plexus, the meshes of which are interwoven with those of the capillary and nervous plexus. No lymphatics have as yet been discovered in the papillæ.

The *Nerves* of the derma, after entering the areolæ of the deeper part of the corium, divide into minute fasciculi, which form a terminal plexus in the upper strata of the corium. From this plexus the primitive fibres pass off to their distribution, as loops, in the papillæ. In the less sensitive parts of the skin the loops are simple and more or less acute in their bend, in conformity with the figure of the papilla. In the sensitive parts, however, and especially in the tactile papillæ of the pulps of the fingers, the loop is convoluted to a greater or less extent, and acts as a multiplier of sensation.

#### APPENDAGES OF THE SKIN.

The appendages of the skin are the nails, hairs, sebiparous glands, and perspiratory glands and ducts.

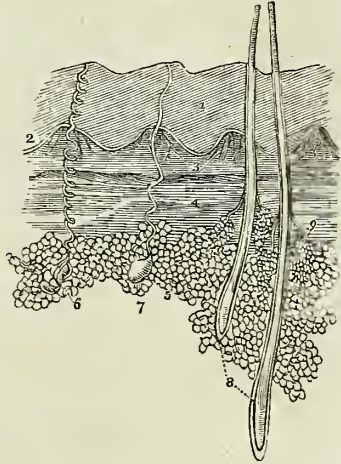
The **NAILS** are horny appendages of the skin, identical in formation with the epiderma, of which they are a part. A nail is convex on its external surface, concave within, and implanted by means of a thin margin or root in a fold of the derma (matrix), which is nearly two lines in depth, and acts the part of a follicle to the nail. At the bottom of the groove of the follicle are a number of filiform papillæ, which produce the margin of the root, and, by the successive formation of new cells, push the nail onwards in its growth. The concave surface of the nail is in contact with the derma, and the latter is covered by papillæ, which perform the double office of retaining the nail in its place, and giving it increased thickness by the addition of newly-formed cells to its under surface. It is this constant change occurring in the under surface of the nail, co-operating with the continual reproduction taking place along the margin of the root, which ensures the growth of the nail in the proper direction. The nail derives a peculiarity of appearance from the disposition and form of the papillæ on the unguis surface of the derma. Thus, beneath the root, and for a short distance onwards towards its middle, the derma is covered by papillæ which are more minute, and consequently less vascular than the papillæ somewhat farther on. This patch of papillæ is bounded by a semilunar line, and that part of the nail covering it being lighter in colour than the rest, has been termed *lunula*. Beyond the lunula the papillæ are raised into longitudinal plaits, which are exceedingly vascular, and give a deeper tint of redness to the nail. These plait-like papillæ of the derma are well calculated by their form to offer an extensive surface both for the adhesion and formation of the nail. The granules and cells are developed on every part of their surface, both in the grooves between the plaits and on their sides, and a horny lamina is formed between each pair of plaits. When the under surface of a nail is examined, these longitudinal laminæ, corresponding with the longitudinal papillæ of the unguis portion of the derma, are distinctly apparent, and if the nail be forcibly detached, the laminæ may be seen in the act of parting from the grooves of the papillæ. It is this structure that gives rise to the ribbed appearance of the nail. The papillary surface of the derma which produces the nail is continuous around the circumference of the attached part of that organ with the derma of the sur-

rounding skin, and the horny structure of the nail is consequently continuous with that of the epiderma.

HAIRS are horny appendages of the skin produced by the involution and subsequent evolution of the epiderma; the involution constituting the follicle in which the hair is enclosed, and the evolution the shaft of the hair. Hairs vary much in size and length in different parts of the body; in some they are so short as not to appear beyond the follicle; in others they grow to a great length, as on the scalp; while along the margins of the eyelids and in the whiskers and beard, they are remarkable for their thickness. Hairs are generally more or less flattened in form, and when the extremity of a transverse section is examined it is found to possess an elliptical or reniform outline. This examination also demonstrates that the centre of the hair is porous and loose in texture, while its periphery is dense; thus affording ground for its division into a cortical and a medullary portion. The free extremity of a hair is generally pointed, and sometimes split into two or three filaments. Its attached extremity is implanted deeply in the integument extending through the derma into the sub-cutaneous areolar tissue, where it is surrounded by adipose cells. The central extremity of a hair is larger than its shaft, and is called the root or bulb. It is usually conical in its shape.

The process of formation of a hair by its follicle is identical with that of the formation of the epiderma by the papillary layer of the derma. Plastic lymph is in the first instance exuded by the capillary plexus of the follicle, the lymph undergoes conversion, first into granules, then into cells, and the latter are elongated into fibres. The cells which are destined to form the surface of the hair go through a different process. They are converted into flat scales, which enclose the fibrous structure of the interior. These scales, as they are successively produced, overlap those which precede and give rise to the prominent and waving lines which may be seen around the circumference of a hair. It is this overlapping line that is the cause of the roughness which we experience in drawing a hair, from its point to its bulb, between the fingers. The bulb is the newly formed portion of the hair; its expanded form is due to the greater bulk of the fresh cells compared with the fibres and scales into which they are subsequently converted in the shaft.

Fig. 210.\*



\* The anatomy of the skin. 1. The epiderma. 2. The rete mucosum or deep layer of the epiderma. 3. Two of the quadrilateral papillary clumps, such as are seen in the palm of the hand or sole of the foot; they are composed of minute conical papillæ. 4. The deep layer of the derma, the corium. 5. Adipose cells. 6. A sudoriparous gland with its spiral duct, such as is seen in the palm of the hand or sole of the foot. 7. Another sudoriparous gland with a straighter duct, such as is seen in the scalp. 8. Two hairs from the scalp, enclosed in their follicles; their relative depth in the skin is preserved. 9. A pair of sebiparous glands, opening by short ducts into the follicle of the hair.

The colour of the hair, like that of the epiderma, is due to the coloration of the primitive granules of the cells.

The SEBIPAROUS GLANDS are sacculated glandular organs embedded in the substance of the derma, and presenting every variety of complexity, from the simplest pouch-like follicle to the sacculated and lobulated gland. In some situations, the excretory ducts of these glands open independently on the surface of the epiderma; while in others, and the most numerous, they terminate in the follicles of the hairs. The sebiparous glands associated with the hairs are racemiform and lobulated in structure, consisting of sacculi which open by short pedunculated tubuli into a common excretory duct, and the latter, after a short course, terminates in the hair-follicle. In the scalp there are two of these glands to each hair-follicle. On the nose and face the glands are of large size, distinctly lobulated, and constantly associated with small hair-follicles. In the meatus auditorius the sebiparous (ceruminous) glands are also large and lobulated, but the largest are those of the eyelids, the Meibomian glands. The excretory ducts of sebiparous glands offer some diversity in different parts of the body: thus, in many situations they are short and straight, while in others, as in the palms of the hands and soles of the feet, where the epiderma is thick, they assume a spiral arrangement. The sebiferous ducts are lined by an inversion of the epiderma, which forms a thick and funnel-shaped cone at its commencement, but soon becomes uniform and soft. Sebiparous glands are met with in all parts of the body, but are most abundant in the skin of the face, and in those situations which are naturally exposed to the influence of friction.

The sebaceous substance, when it collects in inordinate quantities within the excretory ducts, becomes the habitat of a very remarkable parasitic animal, the *steatozoon folliculorum*.

The SUDORIPAROUS GLANDS are situated deeply in the corium and also in the subcutaneous areolar tissue, where they are surrounded by adipose cells. They are small, oblong bodies, composed of one or more convoluted tubuli, or of a congeries of globular sacs, which open into a common efferent duct. The latter ascends from the gland through the derma and epiderma, and terminates on the surface by a funnel-shaped and oblique aperture or pore. The efferent duct presents some variety in its course upwards; thus within the derma it is curved and serpentine, and if the epiderma be thin, it proceeds more or less directly to the excreting pore. Sometimes it is spirally curved within the derma, and having passed the latter, is regularly and beautifully spiral in its passage through the epiderma, the last turn forming an oblique and valvular opening on the surface. The spiral course of the duct is especially remarkable in the thick epiderma of the palm of the hand and sole of the foot. On those parts of the skin where the papillæ are irregularly distributed, the efferent ducts of the sudoriparous glands open on the surface also irregularly, while on the palmar and plantar surfaces of the hands and feet, the pores are situated at regular distances along the ridges, at points corresponding with the intervals of the small, square-shaped, clumps of papillæ. Indeed, the apertures of the pores, seen upon the surface of the epidermal ridges, give rise to the appearance of small transverse furrows, which intersect the ridges from point to point.

The efferent duct and the component sacs and tubuli of the sudoriparous gland are lined by an inflection of the epiderma. This inflection is thick

and infundibuliform in the upper stratum of the derma, but soon becomes uniform and soft. The infundibuliform projection is drawn out from the duct when the epiderma is removed, and may be perceived on the under surface of the latter as a nipple-shaped cone. A good view of the sudoriferous ducts is obtained by gently separating the epiderma of a portion of decomposing skin; or they may be better seen by scalding a piece of skin, and then withdrawing the epiderma from the derma. In both cases it is the lining sheath of epiderma which is drawn out from the duct.

---

## CHAPTER XI.

### OF THE VISCERA.

THAT part of the science of anatomy which treats of the viscera is named splanchnology, from the Greek words *σπλάγχνον*, viscus, and *λόγος*. The viscera of the human body are situated in the three great internal cavities: cranio-spinal, thorax, and abdomen. The viscera of the cranio-spinal cavity, namely, the brain and spinal cord, with the principal organs of sense, have been already described, in conjunction with the nervous system. The viscera of the chest are: the central organ of circulation, the heart; the organs of respiration, the lungs; and the thymus gland. The abdominal viscera admit of a subdivision into those which properly belong to that cavity, viz., the alimentary canal, liver, pancreas, spleen, kidneys, and supra-renal capsules; and those of the pelvis; the bladder and internal organs of generation.

#### THORAX.

The thorax is the conical cavity, situated at the upper part of the trunk of the body; it is narrow above and broad below, and is bounded by the sternum, six superior costal cartilages, ribs, and intercostal muscles *in front*; *laterally*, by the ribs and intercostal muscles; and, *behind*, by the same structures, and by the vertebral column, as low down as the upper border of the last rib and the first lumbar vertebra; *superiorly*, by the thoracic fascia and first rib; and *inferiorly*, by the diaphragm. This cavity is much deeper on the posterior than on the anterior wall, in consequence of the obliquity of the diaphragm, and contains the heart enclosed in its pericardium, with the great vessels; the lungs, with their serous coverings, the pleuræ; the œsophagus; some important nerves; and, in the fœtus, the thymus gland.

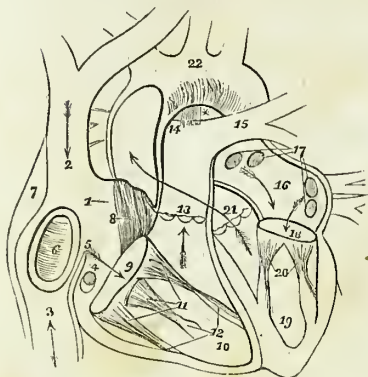
#### THE HEART.

The central organ of circulation, the heart, is situated between the two layers of pleura which constitute the mediastinum, and is enclosed in a proper membrane, the pericardium.

*Pericardium.*—The pericardium is a fibro-serous membrane like the dura mater, and resembles that membrane in deriving its serous layer from the reflected serous membrane of the viscus which it encloses. It consists, therefore, of two layers, an external fibrous and an internal serous. The

*fibrous* layer is attached, above, to the great vessels at the root of the heart, where it is continuous with the thoracic fascia; and below, to the tendinous portion of the diaphragm. The serous membrane invests the heart with the commencement of its great vessels, and is then reflected upon the internal surface of the fibrous layer.

Fig. 211.\*



The HEART is placed obliquely in the chest, the *base* being directed upwards and backwards towards the right shoulder; the *apex* forwards and to the left, pointing to the space between the fifth and sixth ribs, at about two or three inches from the sternum. Its *under side* is flattened, and rests upon the tendinous portion of the diaphragm; its *upper side* is rounded and convex, and formed principally by the right ventricle, and partly by the left. Surmounting the ventricles are the corresponding auricles, whose auricular appendages are directed forwards, and slightly overlap the root of the pulmonary artery. The pulmonary artery is the large anterior vessel at the root of the heart; it crosses obliquely the commencement of the aorta. The heart consists of two auricles and two ventricles, which are respectively named, from their position, right and left. The right is the venous side of the heart; it receives into its auricle the venous blood from every part of the body, by the superior and inferior cava and coronary vein. From the auricle the blood passes into the ventricle, and from the ventricle through the pulmonary artery, to the capillaries of the lungs. From these it is returned as arterial blood to the left auricle; from the left auricle it passes into the left ventricle; and

\* The anatomy of the heart. 1. The right auricle. 2. The entrance of the superior vena cava. 3. The entrance of the inferior cava. 4. The opening of the coronary vein, half closed by the coronary valve. 5. The Eustachian valve. 6. The fossa ovalis, surrounded by the annulus ovalis. 7. The tuberculum Loweri. 8. The muscoli pectinati in the appendix auriculæ. 9. The auriculo-ventricular opening. 10. The cavity of the right ventricle. 11. The tricuspid valve, attached by the chordæ tendinæ to the carniæ columnæ (12). 13. The pulmonary artery, guarded at its commencement by three semilunar valves. 14. The right pulmonary artery, passing beneath the arch and behind the ascending aorta. 15. The left pulmonary artery, crossing in front of the descending aorta. \* The remains of the ductus arteriosus, acting as a ligament between the pulmonary artery and arch of the aorta. The arrows mark the course of the venous blood through the right side of the heart. Entering the auricle by the superior and inferior cavæ, it passes through the auriculo-ventricular opening into the ventricle, and thence through the pulmonary artery to the lungs. 16. The left auricle. 17. The openings of the fourth pulmonary veins. 18. The auriculo-ventricular opening. 19. The left ventricle. 20. The mitral valve, attached by its chordæ tendinæ to two large columnæ carniæ, which project from the walls of the ventricle. 21. The commencement and course of the ascending aorta behind the pulmonary artery, marked by an arrow. The course of the vessel is guarded by three semilunar valves. 22. The arch of the aorta. The comparative thickness of the two ventricles is shown in the diagram. The course of the pure blood through the left side of the heart is marked by arrows. The blood is brought from the lungs by the four pulmonary veins into the left auricle, and passes through the auriculo-ventricular opening into the left ventricle, whence it is conveyed by the aorta to every part of the body.

from the left ventricle is carried through the aorta, to be distributed to every part of the body, and again returned to the heart by the veins. This constitutes the course of the *adult circulation*.

The heart is best studied *in situ*. If, however, it be removed from the body, it should be placed in the position indicated in the above description of its situation. A transverse incision should then be made along the ventricular margin of the right auricle, from the appendix to its right border, and crossed by a perpendicular incision, carried from the side of the superior to the inferior cava. The blood must then be removed. Some fine specimens of white fibrin are frequently found with the coagula; occasionally they are yellow and gelatinous. This appearance deceived the older anatomists, who called these substances "polypus of the heart;" they are also frequently found in the right ventricle, and sometimes in the left cavities.

The RIGHT AURICLE is larger than the left, and is divided into a principal cavity or sinus, and an appendix auriculæ. The interior of the sinus presents for examination five openings; two valves; two relicts of fetal structure; and two peculiarities in the proper structure of the auricle. They may be thus arranged:—

|                            |   |                                                                                                           |
|----------------------------|---|-----------------------------------------------------------------------------------------------------------|
| Openings . . . . .         | { | Superior cava,<br>Inferior cava,<br>Coronary vein,<br>Foramina Thebesii,<br>Auriculo-ventricular opening. |
| Valves . . . . .           | { | Eustachian valve,<br>Coronary valve.                                                                      |
| Relicts of fetal structure | { | Annulus ovalis,<br>Fossa ovalis.                                                                          |
| Structure of the auricle . | { | Tuberculum Loweri,<br>Musculi pectinati.                                                                  |

The *Superior cava* returns the blood from the upper half of the body, and opens into the upper and front part of the auricle.

The *Inferior cava* returns the blood from the lower half of the body, and opens through the lower and posterior wall, close to the partition between the auricles (septum auricularum). The direction of these two vessels is such, that a stream forced through the superior cava would be directed towards the auriculo-ventricular opening. In like manner, a stream rushing upwards by the inferior cava would force its current against the septum auricularum; this is the proper direction of the two currents during fetal life.

The *Coronary vein* returns the venous blood from the substance of the heart; it opens into the auricle between the inferior cava and the auriculo-ventricular opening, under cover of the coronary valve.

The *Foramina Thebesii*\* are minute pore-like openings, by which the venous blood exudes directly from the muscular structure of the heart into the auricle, without entering the venous current. These openings are also found in the left auricle, and in the right and left ventricles.

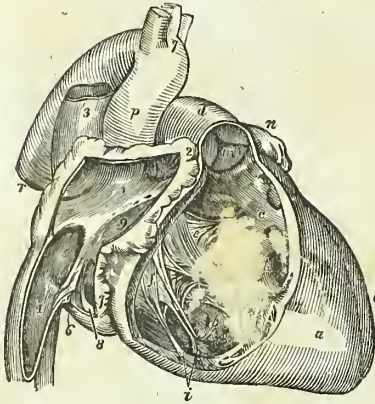
\* Adam Christian Thebesius. His discovery of the openings now known by his name is contained in his "Dissertatio Medica de Circulo Sanguinis in Corde," 1708.

The *Auriculo-ventricular opening* is the large opening of communication between the auricle and ventricle.

The *Eustachian\* valve* is a part of the apparatus of foetal circulation, and serves to direct the placental blood from the inferior cava, though the foramen ovale into the left auricle. In the adult it is a mere vestige and imperfect, though sometimes it remains of large size. It is formed by a fold of the lining membrane of the auricle, containing some muscular fibres, is situated between the opening of the inferior cava and the auriculo-ventricular opening, and is generally connected with the coronary valve.

The *Coronary valve* is a semilunar fold of the lining membrane, stretching across the mouth of the coronary vein, and preventing the reflux of the blood in the vein during the contraction of the auricle.

Fig. 212.†



The *Annulus ovalis* is situated on the septum auricularum, opposite the termination of the inferior cava. It is the rounded margin of the septum, which occupies the place of the foramen ovale of the fœtus.

The *Fossa ovalis* is an oval depression corresponding with the foramen ovale in the fœtus. This opening is closed at birth by a thin valvular layer, which is continuous with the left margin of the annulus, and is frequently imperfect at its upper part. The depression or fossa in the right auricle results from this arrangement. There is no fossa ovalis in the left auricle.

The *Tuberculum Loweri‡* is the portion of auricle intervening between the openings of the superior and inferior cava. Being thicker than the walls of the veins, it forms a projec-

\* Bartholomew Eustachius, born at San Severino, in Naples, was Professor of Medicine in Rome, where he died in 1570. He was one of the founders of modern anatomy, and the first who illustrated his works with good engravings on copper.

† The anatomy of the heart; the organ is viewed upon the right side. 1. The cavity of the right auricle. 2. The appendix auriculæ, in the cavity of which the musculi pectinati are seen. 3. The superior vena cava, opening into the upper part of the right auricle. 4. The inferior vena cava. 5. The fossa ovalis; the prominent ridge surrounding it is the annulus ovalis. 6. The Eustachian valve. 7. The opening of the coronary vein. 8. The coronary valve. 9. The entrance of the auriculo-ventricular opening. Between the numbers 1 and 9, two or three of the foramina Thebesii are seen. a. The right ventricle. b. c. The cavity of the right ventricle, on the walls of which the columnæ carneæ are seen; c is placed in the channel leading upwards to the pulmonary artery, d. e. f. The tricuspid valve; e is placed on the anterior curtain, and f, on the right curtain. g. The long columnæ carneæ, to the apex of which the anterior and right curtains of the tricuspid valve are connected by the chordæ tendineæ. h. The "long moderator band." i. The two columnæ carneæ of the right curtain. k. The attachment by chordæ tendineæ of the left limb of the anterior curtain. l, l. Chordæ tendineæ of the "fixed curtain" of the valve. m. The valve of the pulmonary artery. The letter of reference is placed on the inferior semilunar segment. n. The apex of the right appendix auriculæ. o. The left ventricle. p. The ascending aorta. q. Its arch, with the three arterial trunks which arise from the arch. r. The descending aorta.

‡ Richard Lower, M. D. "Tractatus de Corde; item de Motu et Colore Sanguinis," 1669. His dissections were made upon quadrupeds, and his observations relate rather to animals than to man.



tion, which was supposed by Lower to direct the blood from the superior cava into the auriculo-ventricular opening.

The *Musculi pectinati* are small muscular columns situated in the appendix auriculæ. They are numerous, and are arranged parallel with each other; hence their cognomen, "*pectinati*," like the teeth of a comb.

The RIGHT VENTRICLE is triangular and prismoid in form. Its anterior side is convex, and forms the larger proportion of the front of the heart. The posterior side, which is also inferior, is flat, and rests upon the diaphragm; the inner side corresponds with the partition between the two ventricles, septum ventriculorum.

The right ventricle is to be laid open by making an incision parallel with, and a little to the right of, the middle line, from the pulmonary artery in front, to the apex of the heart, and thence by the side of the middle line behind to the auriculo-ventricular opening.

It contains, to be examined, two openings, the auriculo-ventricular and that of the pulmonary artery; two apparatus of valves, the tricuspid and semilunar; and a muscular and tendinous apparatus belonging to the tricuspid valves. They may be thus arranged:—

Auriculo-ventricular opening,  
Opening of the pulmonary artery.  
Tricuspid valves,  
Semilunar valves.  
Chordæ tendineæ,  
Carneæ columnæ.

The *Auriculo-ventricular opening* is surrounded by a fibrous ring, covered by the lining membrane of the heart. It is the opening of communication between the right auricle and ventricle.

The *Opening of the pulmonary artery* is situated close to the septum ventriculorum, on the left side of the right ventricle, and upon the anterior aspect of the heart.

The *Tricuspid valves* are three triangular folds of the lining membrane, strengthened by a thin layer of fibrous tissue. They are connected by their base around the auriculo-ventricular opening; and by their sides and apices, which are thickened, they give attachment to a number of slender tendinous cords, called chordæ tendineæ. The *chordæ tendineæ* are the tendons of the thick muscular columns (*columnæ carneæ*) which stand out from the walls of the ventricle, and serve as muscles to the valves. A number of these tendinous cords converge to a single muscular attachment. The tricuspid valves prevent the regurgitation of blood into the auricle during the contraction of the ventricle, and they are prevented from being themselves driven back by the chordæ tendineæ and their muscular attachments.

This connexion of the muscular columns of the heart to the valves has caused their division into active and passive. The *active* valves are the tricuspid and mitral; the *passive*, the semilunar and coronary.

The valves consist, according to Mr. King,\* of *curtains*, *cords*, and

\* "Essay on the Safety Valve Function in the Right Ventricle of the Human Heart," by T. W. King. Guy's Hospital Reports, vol. ii.

*columns.* The *anterior valve* or *curtain* is the largest, and is so placed as to prevent the filling of the pulmonary artery during the distension of the ventricle. The *right valve* or *curtain* is of smaller size, and is situated on the right side of the auriculo-ventricular opening. The third valve, or "*fixed curtain*," is connected by its cords to the septum ventriculorum. The *cords* (*chordæ tendineæ*) of the anterior curtain are attached, principally, to a long *column* (*columna carnea*), which is connected with the "right or thin and *yielding wall* of the ventricle." From the lower part of this column a transverse muscular band, the "*long moderator band*," is stretched to the septum ventriculorum, or "*solid wall*" of the ventricle. The right curtain is connected, by means of its *cords*, partly with the long column, and partly with its own proper column, the *second column*, which is also attached to the "*yielding wall*" of the ventricle. A third and smaller column is generally connected with the right curtain. The "*fixed curtain*" is so named from its attachment to the "*solid wall*" of the ventricle, by means of cords only, without fleshy columns.

From this arrangement of the valves, it follows, that if the right ventricle be over distended, the thin or "*yielding wall*" will give way, and carry with it the columns of the anterior and right valves. The cords connected with these columns will draw down the edges of the corresponding valves, and produce an opening between the curtains, through which the superabundant blood may escape into the auricle, and the ventricle be relieved from over-pressure. This mechanism is therefore adapted to fulfil the "*function of a safety valve*."

The *Columnæ carneæ* (fleshy columns) is a name expressive of the appearance of the internal walls of the ventricles, which seem formed of muscular columns interlacing in almost every direction. They are divided, according to the manner of their connexion, into three sets. 1. The greater number are attached by the whole of one side, and merely form convexities into the cavity of the ventricle. 2. Others are connected by both extremities, being free in the middle. 3. A few (*columnæ papillares*) are attached by one extremity to the walls of the heart, and by the other give insertion to the *chordæ tendineæ*.

The *Semilunar valves*, three in number, are situated around the commencement of the pulmonary artery, being formed by a folding of its lining membrane, strengthened by a thin layer of fibrous tissue. They are attached by their convex borders, and free by the concave, which are directed upwards in the course of the vessel, so that, during the current of the blood along the artery, they are pressed against the sides of the cylinder; but if any attempt at regurgitation ensue, they are immediately expanded, and effectually close the entrance of the tube. The margins of the valves are thicker than the rest of their extent, and each valve presents in the centre of this margin a small fibro-cartilaginous tubercle, called *corpus Arantii*,\* which locks in with the other two during the closure of the valves, and secures the triangular space that would otherwise be left by the approximation of three semilunar folds.

Between the semilunar valves and the cylinder of the artery are three pouches, called the *pulmonary sinuses* (sinuses of Valsalva). Similar

\* Julius Cæsar Arantius, Professor of Medicine in Bologna. He was a disciple of Vesalius, one of the founders of modern anatomy. His treatise "*De Humano Fœtu*" was published at Rome, in 1564.

sinuses are situated behind the valves at the commencement of the aorta, and are larger and more capacious than those of the pulmonary artery.

The *Pulmonary artery* commences by a scalloped border, corresponding with the three valves which are attached along its edge. It is connected to the ventricle by muscular fibres, and by the lining membrane of the heart.

The **LEFT AURICLE** is somewhat smaller, but thicker, than the right; of a cuboid form, and situated more posteriorly. The *appendix auriculæ* is constricted at its junction with the auricle, and has a foliated appearance; it is directed forwards towards the root of the pulmonary artery, to which the auriculæ of both sides appear to converge.

The left auricle is to be laid open by a + shaped incision, the horizontal section being made along the border, which is attached to the base of the ventricle. It presents for examination five openings, and the muscular structure of the appendix; these are—

Four pulmonary veins,  
Auriculo-ventricular opening,  
Musculi pectinati.

The *Pulmonary veins*, two from the right and two from the left lung, open into the corresponding sides of the auricle. The two left pulmonary veins terminate frequently by a common opening.

The *auriculo-ventricular opening* is the aperture of communication between the auricle and ventricle.

The *Musculi pectinati* are fewer in number than in the right auricle, and are situated only in the appendix auriculæ.

**LEFT VENTRICLE.** — The left ventricle is to be opened by making an incision a little to the left of the septum ventriculorum, and continuing it around the apex of the heart to the auriculo-ventricular opening behind.

The left ventricle is conical, both in external figure and in the form of its internal cavity. It forms the apex of the heart, by projecting beyond the right ventricle, while the latter has the advantage in length towards the base. Its walls are about seven lines in thickness, those of the right ventricle being about two lines and a half.

It presents for examination, in its interior, two openings, two valves, and the tendinous cords and muscular columns; they may be thus arranged:

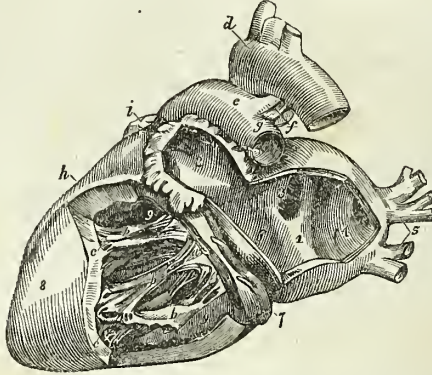
Auriculo-ventricular opening,  
Aortic opening.  
Mitral valves,  
Semilunar valves.  
Chordæ tendineæ,  
Columnæ carneæ.

The *Auriculo-ventricular opening* is a dense fibrous ring, covered by the lining membrane of the heart, but smaller in size than that of the right side.

The *Mitral valves* are attached around the auriculo-ventricular opening, as are the tricuspid in the right ventricle. They are thicker than the tricuspid, and consist of only two segments, of which the larger is placed

between the auriculo-ventricular opening and the commencement of the aorta, and acts the part of a valve to that foramen during the filling of the ventricle. The difference in size of the two valves, both being triangular, and the space between them, has given rise to the idea of a "bishop's

Fig. 213.\*



mitre," after which they were named. These valves, like the tricuspid, are furnished with an apparatus of tendinous cords, *chordæ tendineæ*, which are attached to two very large *columnæ carneæ*.

The *Columnæ carneæ* admit of the same arrangement into three kinds, as on the right side. Those which are free by one extremity, the *columnæ papillares*, are two in number, and larger than those on the opposite side; one being placed on the left wall of the ventricle, and the other at the junction of the septum ventriculorum with the posterior wall.

The *Semilunar valves* are placed around the commencement of the aorta, like those of the pulmonary artery; they are similar in structure, and are attached to the scalloped border by which the aorta is connected with the ventricle. The tubercle in the centre of each fold is larger than those in the pulmonary valves, and it was these that Arantius particularly described; but the term "*corpora Arantii*" is now applied indiscriminately to both. The fossæ between the semilunar valves and the cylinder of the artery are larger than those of the pulmonary artery; they are called the "*sinus aortici*" (sinuses of Valsalva).

#### STRUCTURE OF THE HEART.

The arrangement of the fibres of the heart has been made the subject of careful investigation by Mr. Searle, to whose article, "Fibres of the Heart,"

\* The anatomy of the heart; the organ is viewed on its left side. 1. The cavity of the left auricle. The number is placed on that portion of the septum auricularum corresponding with the centre of the fossa ovalis. 2. The cavity of the appendix auriculæ, near the apex of which are seen the musculi pectinati. 3. The opening of the two right pulmonary veins. 4. The sinus, into which the left pulmonary veins open. 5. The left pulmonary veins. 6. The auriculo-ventricular opening. 7. The coronary vein, lying in the auriculo-ventricular groove. 8. The left ventricle. 9, 9. The cavity of the left ventricle; the numbers rest on the septum ventriculorum. *a*. The mitral valve; its flaps are connected by chordæ tendineæ to *b*, *b*. The columnæ carneæ. *c*, *c*. Fixed columnæ carneæ, forming part of the internal surface of the ventricle. *d*. The arch of the aorta, from the summit of which the three arterial trunks of the head and upper extremities are seen arising. *e*. The pulmonary artery. *f*. The obliterated ductus arte-

in the Cyclopædia of Anatomy and Physiology, I am indebted for the following summary of their distribution:—

For the sake of clearness of description the fibres of the ventricles have been divided into three layers, superficial, middle, and internal, all of which are disposed in a spiral direction around the cavities of the ventricles. The mode of formation of these three layers will be best understood by adopting the plan pursued by Mr. Searle in tracing the course of the fibres from the centre of the heart towards its periphery.

The left surface of the septum ventriculorum is formed by a broad and thick layer of fibres, which proceed backwards in a spiral direction around the posterior aspect of the left ventricle, and become augmented on the left side of that ventricle by other fibres derived from the bases of the two columnæ papillares. The broad and thick band formed by the fibres from these two sources, curves around the apex and lower third of the left ventricle to the anterior border of the septum, where it divides into two bands, a short or apical band, and a long or basal band.

The *Short or apical band* is increased in thickness at this point by receiving a layer of fibres (derived from the root of the aorta and carneæ columnæ) upon its internal surface, from the right surface of the septum ventriculorum; it is then continued onwards in a spiral direction from left to right, around the lower third of the anterior surface, and the middle third of the posterior surface of the right ventricle to the posterior border of the septum. From the latter point the short band is prolonged around the posterior and outer border of the left ventricle to the anterior surface of the base of that ventricle, and is inserted into the anterior border of the left auriculo-ventricular ring, and the anterior part of the root of the aorta and pulmonary artery.

The *Long or basal band*, at the anterior border of the septum, passes directly backwards through the septum, (forming its middle layer,) to the posterior ventricular groove, where it becomes joined by fibres derived from the root of the pulmonary artery. It then winds spirally around the middle and upper third of the left ventricle to the anterior border of the septum, where it is connected by means of its internal surface with the superior fibres derived from the aorta, which form part of the right wall of the septum. From this point it is continued around the upper third of the anterior and posterior surface of the right ventricle to the posterior border of the septum, where it is connected with the fibres constituting the right surface of the septum ventriculorum. At the latter point the fibres of this band begin to be twisted upon themselves, like the strands of a rope, the direction of the twist being from below upwards. This arrangement of fibres is called by Mr. Searle "the rope;" it is continued spirally upwards, forming the brim of the left ventricle, to the anterior surface of the base of that ventricle, where the twisting of the fibres ceases. The long band then curves inwards towards the septum, and spreads out upon the left surface of the septum into the broad and thick layer of fibres with which this description commenced.

The most inferior of the fibres of the left surface of the septum ventriculorum, after winding spirally around the internal surface of the apex of the left ventricle, so as to close its extremity, form a small fasciculus,

rius; the letter is placed in the cleft formed by the bifurcation of the pulmonary artery. *g.* The left pulmonary artery. *h.* The right ventricle. *i.* The point of the appendix of the right auricle.

which is excluded from the interior of the ventricle, and expands in a radiated manner over the surface of the heart, constituting its superficial layer of fibres. The direction of these fibres is, for the most part, oblique, passing from left to right on the anterior and from right to left on the posterior surface of the heart, becoming more longitudinal near its base, and terminating by being inserted into the fibrous rings of the auriculo-ventricular openings, and of the pulmonary artery and aorta. Over the right ventricle the superficial fibres are increased in number by the addition of accessory fibres from the right surface of the septum, which pierce the middle layer, and take the same direction with the superficial fibres from the apex of the left ventricle, and of other accessory fibres from the surface of both ventricles.

From this description it will be perceived, that the *superficial layer* of fibres is very scanty, and is pretty equally distributed over the surface of both ventricles. The *middle layer* of both ventricles is formed by the two bands, short and long. But the *internal layer* of the two ventricles is very differently constituted: that of the left is formed by the spiral expansion of the fibres of the rope, and of the two columnæ papillares; that of the right remains to be described. The septum ventriculorum also consists of three layers, a *left layer*, the radiated expansion of the rope and carneæ columnæ; a *middle layer*, the long band; and a *right layer*, belonging to the proper wall of the right ventricle, and continuous both in front and behind with the long band, and in front also with the short band, and with the superficial layer of the right ventricle.

The *Internal layer* of the *right ventricle* is formed by fasciculi of fibres which arise from the right segment of the root of the aorta, from the entire circumference of the root of the pulmonary artery, and from the bases of the columnæ papillares. The fibres from the root of the aorta, associated with some from the carneæ columnæ, constitute a layer which passes obliquely forwards upon the right side of the septum. The superior fibres coming directly from the aorta join the internal surface of the long band at the anterior border of the septum, while the lower two-thirds of the layer are continuous with the internal surface of the short band, some of its fibres piercing that band to augment the number of superficial fibres. The fibres derived from the root of the pulmonary artery, conjoined with those from the base of one of the columnæ papillares, curve forwards from their origin, and wind obliquely downwards and backwards around the internal surface of the wall of the ventricle to the posterior border of the septum, where they become continuous with the long band, directly that it has passed backwards through the septum.

*Fibres of the Auricles.*—The fibres of the auricles are disposed in two layers, external and internal. The *internal layer* is formed of fasciculi which arise from the fibrous rings of the auriculo-ventricular openings and proceed upwards to enlace with each other, and constitute the appendices auricularum. These fasciculi are parallel in their arrangement, and in the appendices form projections and give rise to the appearance which is denominated muscoli pectinati. In their course they give off branches which connect adjoining fasciculi, and form a columnar interlacement between them.

*External Layer.*—The fibres of the right auricle having completed the appendix, wind from left to right around the right border of this auricle, and along its anterior aspect, beneath the appendix, to the anterior surface

of the septum. From the septum they are continued to the anterior surface of the left auricle, where they separate into three bands, superior, anterior, and posterior. The *superior band* proceeds onwards to the appendix, and encircles the apex of the auricle. The *anterior band* passes to the left, beneath the appendix, and winds as a broad layer completely around the base of the auricle, and through the septum to the root of the aorta, to which it is partly attached, and from this point is continued onwards to the appendix, where its fibres terminate by interlacing with the *musculi pectinati*. The *posterior band* crosses the left auricle obliquely to its posterior part, and winds from left to right around its base, encircling the openings of the pulmonary veins; some of its fibres are lost on the surface of the auricle, others are continued onwards to the base of the aorta; and a third set, forming a small band, are prolonged along the anterior edge of the appendix to its apex, where they are continuous with the *superior band*. The septum auricularum has four sets of fibres entering into its formation; 1. The fibres arising from the auriculo-ventricular rings at each side; 2. Fibres arising from the root of the aorta, which pass upwards to the transverse band, and to the root of the superior cava; 3. Those fibres of the anterior band that pass through the lower part of the septum in their course around the left auricle; and, 4. A slender fasciculus, which crosses through the septum from the posterior part of the right auriculo-ventricular ring to the left auricle.

It will be remarked, from this description, that the left auricle is considerably thicker and more muscular than the right.

*Vessels and Nerves.*—The *Arteries* supplying the heart are the anterior and posterior coronary. The *Veins* accompany the arteries, and empty themselves by the common coronary vein into the right auricle. The *lymphatics* terminate in the glands about the root of the heart. The *nerves* of the heart are derived from the cardiac plexuses, which are formed by communicating filaments from the sympathetic and pneumogastric.

## ORGANS OF RESPIRATION AND VOICE.

The organs of respiration are the two lungs, with their air-tube, the trachea, to the upper part of which is adapted an apparatus of cartilages, constituting the organ of voice, or larynx.

### THE LARÝNX.

The *Larynx* is situated at the fore part of the neck, between the trachea and the base of the tongue. It is a short tube, having an hour-glass form, and is composed of *cartilages, ligaments, muscles, vessels, nerves, and mucous membrane*.

The *Cartilages* are the—

|                |                |
|----------------|----------------|
| Thyroid,       | Two cuneiform, |
| Cricoid,       | Epiglottis.    |
| Two arytenoid, |                |

The *Thyroid* (θυρεός—είδος, like a shield) is the largest cartilage of the larynx: it consists of two lateral portions, or *alæ*, which meet at an angle in front, and form the projection which is known by the name of *pomum Adami*. In the male, after puberty, the angle of union of the two *alæ* is

acute; in the female, and before puberty in the male, it is obtuse. Where the pomum Adami is prominent, a bursa mucosa is often found between it and the skin.

Each ala is quadrilateral in shape, and forms a rounded border posteriorly, which terminates above, in the *superior cornu*, and below, in the *inferior cornu*. Upon the side of the ala is an *oblique line*, or *ridge*, directed downwards and forwards, and bounded at each extremity by a tubercle. Into this line the sterno-thyroid muscle is inserted; and from it the thyro-hyoid and inferior constrictor take their origin. In the *receding angle*, formed by the meeting of the two alæ upon the inner side of the cartilage, and near its lower border, are attached the epiglottis, the chordæ vocales, the thyro-arytenoid, and thyro-epiglottidean muscles.

The *Cricoid* (κρίκος—εἶδος, like a ring) is a ring of cartilage, narrow in front, and broad behind, where it is surmounted by *two rounded surfaces*, which articulate with the arytenoid cartilages. At the middle line, posteriorly, is a *vertical ridge* which gives attachment to the œsophagus, and on each side of the ridge are the depressions which lodge the crico-arytenoidei postici muscles. On either side of the ring is a *glenoid cavity*, which articulates with the inferior cornu of the thyroid cartilage.

The *Arytenoid cartilages* (ἀρυσταίνα,\* a pitcher), two in number, are triangular and prismoid in form. They are broad and thick below where they articulate with the upper border of the cricoid cartilage; pointed above, and prolonged by two small pyriform cartilages, *cornicula laryngis* (capitula Santorini), which are curved inwards and backwards, and they each present three surfaces, anterior, posterior, and internal. The posterior surface is concave, and lodges part of the arytenoideus muscle; the internal surface is smooth, and forms part of the lateral wall of the larynx; the anterior or external surface is rough and irregular, and gives attachment to the chorda vocalis, thyro-arytenoideus, crico-arytenoideus lateralis and posticus, and, above these, to the base of the cuneiform cartilage.

The *Cuneiform cartilages* are two small cylinders of fibro-cartilage, about seven lines in length, and enlarged at each extremity. By the lower end, or base, the cartilage is attached to the middle of the external surface of the arytenoid, and by its upper extremity forms a prominence in the border of the aryteno-epiglottidean fold of membrane. They are sometimes wanting.

In the male, the cartilages of the larynx are more or less ossified, particularly in old age.

The *Epiglottis* (ἐπιγλωττις, upon the tongue) is a fibro-cartilage of a yellowish colour, studded with a number of small mucous glands, which are lodged in shallow pits upon its surface. It is shaped like a cordate leaf, and is placed immediately in front of the opening of the larynx, which it closes completely when the larynx is drawn up beneath the base of the tongue. It is attached by its point to the *receding angle*, between the two alæ of the thyroid cartilage.

*Ligaments.*—The *Ligaments* of the larynx are numerous, and may be arranged into four groups: 1. Those which articulate the thyroid with the os hyoides. 2. Those which connect it with the cricoid. 3. Ligaments of the arytenoid cartilages. 4. Ligaments of the epiglottis.

\* This derivation has reference to the appearance of both cartilages taken together and covered by mucous membrane. In animals, which were the principal subjects of dissection among the ancients, the opening of the larynx with the arytenoid cartilages bears a striking resemblance to the mouth of a pitcher having a large spout.



1. The ligaments which connect the thyroid cartilage with the os hyoides are three in number:—

The two *Thyro-hyoidean ligaments* pass between the superior cornua of the thyroid and the extremities of the greater cornua of the os hyoides: a sesamoid bone or cartilage is found in each.

The *Thyro-hyoidean membrane* is a broad membranous layer, occupying the entire space between the upper border of the thyroid cartilage and the upper border of the os hyoides. It is pierced by the superior laryngeal nerve and artery.

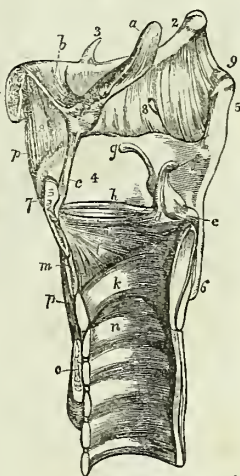
2. The ligaments connecting the thyroid to the cricoid cartilage are also three in number:—

Two *Capsular ligaments*, with their synovial membranes, which form the articulation between the inferior cornua of the thyroid and the sides of the cricoid; and the crico-thyroidean membrane. The *crico-thyroidean membrane* is a fan-shaped layer of elastic tissue, thick in front (middle crico-thyroidean ligament) and thinner at each side (lateral crico-thyroidean ligament). It is attached by its apex to the lower border and receding angle of the thyroid cartilage, and by its expanded margin to the upper border of the cricoid and base of the arytenoid cartilage. Superiorly it is continuous with the inferior margin of the chorda vocalis. The front of the crico-thyroidean membrane is crossed by a small artery, the inferior laryngeal, and is the spot selected for the operation of laryngotomy. Laterally it is covered in by the crico-thyroidei and crico-arytenoidei laterales muscles.

3. The ligaments of the arytenoid cartilages are six in number:—

Two *Capsular ligaments*, with synovial membranes, which articulate the arytenoid cartilages with the cricoid; and the superior and inferior thyro-arytenoid ligaments. The *superior thyro-arytenoid ligaments* are two thin bands of elastic tissue which are attached in front to the receding angle of the thyroid cartilage, and behind to the anterior and inner border of each arytenoid cartilage. The lower border of this ligament constitutes the upper boundary of the ventricle of the larynx. The *inferior thyro-*

Fig. 214.\*

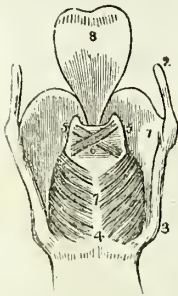


\* A vertical section of the larynx, showing its ligaments. 1. The body of the os hyoides. 2. Its great cornu. 3. Its lesser cornu. 4. The ala of the thyroid cartilage. 5. The superior cornu. 6. Its inferior cornu. 7. The pomum Adami. 8, 8. The thyro-hyoidean membrane; the opening in the membrane immediately above the most posterior of the numerals is for the passage of the superior laryngeal nerve and artery. 9. The thyro-hyoidean ligament; the numeral is placed immediately above the sesamoid bone or cartilage which exists in this ligament. a. The epiglottis. b. The hyo-epiglottic ligament. c. The thyro-epiglottic ligament. d. The arytenoid cartilage; its inner surface. e. The outer angle of the base of the arytenoid cartilage. f. The corniculum laryngis. g. The cuneiform cartilage. h. The superior thyro-arytenoid ligament. i. The inferior thyro-arytenoid ligament, or chorda vocalis; the elliptical space between the two thyro-arytenoid ligaments is that of the ventricle of the larynx. k. The cricoid cartilage. l. The lateral portion of the crico-thyroidean membrane. m. The central portion of the same membrane. n. The upper ring of the trachea, which is received within the ring of the cricoid cartilage. o. Section of the isthmus of the thyroid gland. p, p. The levator glandulae thyroideae.

*arytenoid ligaments*, or *chordæ vocales*, are thicker than the superior, and like them composed of elastic tissue. Each ligament is attached in front to the receding angle of the thyroid cartilage, and behind to the anterior angle of the base of the arytenoid. The inferior border of the *chordæ vocalis* is continuous with the lateral expansion of the crico-thyroid ligament. The superior border forms the lower boundary of the ventricle of the larynx. The space between the two *chordæ vocales* is the glottis or rima glottidis.

4. The ligaments of the epiglottis are five in number, namely, three glosso-epiglottic, hyo-epiglottic, and thyro-epiglottic.

Fig. 215.\*



The *glosso-epiglottic* ligaments (*fræna epiglottidis*) are three folds of mucous membrane, which connect the anterior surface of the epiglottis with the root of the tongue. The middle of these contains elastic tissue. The *hyo-epiglottic* ligament is a band of elastic tissue passing between the anterior aspect of the epiglottis near its apex, and the upper margin of the body of the os hyoides. The *thyro-epiglottic* ligament is a long and slender fasciculus of elastic tissue, which embraces the apex of the epiglottis, and is inserted into the receding angle of the thyroid cartilage immediately below the anterior fissure and above the attachment of the *chordæ vocales*.

*Muscles.*—The muscles of the larynx are eight in number: the five larger are the muscles of the *chordæ vocales* and rima glottidis; the three smaller are muscles of the epiglottis.

The five muscles of the *chordæ vocales* and rima glottidis are the—

Crico-thyroid,  
Crico-arytenoideus posticus,  
Crico-arytenoideus lateralis,  
Thyro-arytenoideus,  
Arytenoideus.

The *Crico-thyroid* muscle arises from the anterior surface of the cricoid cartilage, and passes obliquely outwards and backwards to be inserted into the lower and inner border of the ala of the thyroid as far back as its inferior cornu.

The *Crico-arytenoideus posticus* arises from the depression on the posterior surface of the cricoid cartilage, and passes upwards and outwards to be inserted into the outer angle of the base of the arytenoid.

The *Crico-arytenoideus lateralis* arises from the upper border of the side of the cricoid, and passes upwards and backwards to be inserted into the outer angle of the base of the arytenoid cartilage.

The *Thyro-arytenoideus* arises from the receding angle of the thyroid cartilage, close to the outer side of the *chordæ vocalis*, and passes backwards parallel with the cord, to be inserted into the base and outer surface of the arytenoid cartilage.

\* A posterior view of the larynx. 1. The thyroid cartilage, its right ala. 2. One of its ascending cornua. 3. One of the descending cornua. 4, 7. The cricoid cartilage. 5, 5. The arytenoid cartilages. 6. The arytenoideus muscle, consisting of oblique and transverse fasciculi. 7. The crico-arytenoidei postici muscles. 8. The epiglottis

The *Arytenoideus* muscle occupies the posterior concave surface of the arytenoid cartilages, between which it is stretched. It consists of three planes of transverse and oblique fibres; hence it was formerly considered as several muscles, under the names of *transversi* and *obliqui*.

The three muscles of the epiglottis are the—

Thyro-epiglottideus,  
Aryteno-epiglottideus superior,  
Aryteno-epiglottideus inferior.

The *Thyro-epiglottideus* appears to be formed by the upper fibres of the thyro-arytenoideus muscle: they spread out upon the external surface of the sacculus laryngis and in the aryteno-epiglottidean fold of mucous membrane, in which they are lost; a few of the anterior fibres being continued onwards to the side of the epiglottis.

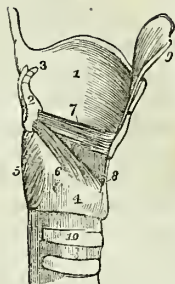
The *Aryteno-epiglottideus superior* consists of a few scattered fibres, which pass forwards in the fold of mucous membrane forming the lateral boundary of the entrance into the larynx, from the apex of the arytenoid cartilage to the side of the epiglottis.

The *Aryteno-epiglottideus inferior*.—This muscle, described by Mr. Hilton, and closely connected with the sacculus laryngis, may be found by raising the mucous membrane immediately above the ventricle of the larynx. It arises by a narrow and fibrous origin from the arytenoid cartilage, just above the attachment of the chorda vocalis; and passing forwards, and a little upwards, expands over the upper half, or two-thirds of the sacculus laryngis, and is inserted by a broad attachment into the side of the epiglottis.

*Actions*.—From a careful examination of the muscles of the larynx, Mr. Bishop† concludes, that the crico-arytenoidei postici open the glottis, while all the rest close it. The arytenoideus approximates the arytenoid cartilages posteriorly, and the crico-arytenoidei laterales and thyro-arytenoidei anteriorly; the latter, moreover, close the glottis mesially. The crico-thyroidei are tensors of the chordæ vocales, and these muscles, together with the thyro-arytenoidei, regulate the tension, position, and vibrating length of the vocal cords.

The crico-thyroid muscles effect the tension of the chordæ vocales by rotating the cricoid on the inferior cornua of the thyroid; by this action the anterior portion is drawn upwards and made to approximate the inferior border of the thyroid, while the posterior and superior border of the cricoid, together with the arytenoid cartilages, is carried backwards. The crico-arytenoidei postici separate the chordæ vocales by drawing the arytenoid cartilages outwards and downwards. The crico-arytenoidei laterales, by drawing the outer angles of the arytenoid cartilages forwards, approximate the anterior angles to which the chordæ vocales are attached. The thyro-arytenoidei draw the arytenoid cartilages forwards, and, by their

Fig. 216.\*



\* A side view of the larynx, one ala of the thyroid cartilage has been removed. 1. The remaining ala of the thyroid cartilage. 2. One of the arytenoid cartilages. 3. One of the cornicula laryngis. 4. The cricoid cartilage. 5. The crico-arytenoideus posticus muscle. 6. The crico-arytenoideus lateralis. 7. The thyro-arytenoideus. 8. The crico-thyroidean membrane. 9. One half of the epiglottis. 10. The upper part of the trachea

† Cyclopædia of Anatomy and Physiology, art. Larynx

connexion with the chordæ vocales, act upon the whole length of those cords.

The thyro-epiglottideus acts principally by compressing the glands of the sacculus laryngis and the sac itself: by its attachment to the epiglottis it would act feebly upon that valve. The aryteno-epiglottideus superior serves to keep the mucous membrane of the sides of the opening of the glottis tense, when the larynx is drawn upwards and the opening closed by the epiglottis. Of the aryteno-epiglottideus, the "functions appear to be," writes Mr. Hilton, "to compress the subjacent glands which open into the pouch; to diminish the capacity of that cavity, and change its form; and to approximate the epiglottis and the arytenoid cartilage."

*Mucous Membrane.*—The aperture of the larynx is a triangular or cordiform opening, broad in front and narrow behind; bounded anteriorly by the epiglottis, posteriorly by the arytenoideus muscle, and on either side by a fold of mucous membrane stretched between the side of the epiglottis and the apex of the arytenoid cartilage. On the margin of this *aryteno-epiglottidean* fold the cuneiform cartilage forms a prominence more or less distinct. The cavity of the larynx is divided into two parts by an oblong constriction produced by the prominence of the chordæ vocales. That portion of the cavity which lies above the constriction is broad and triangular above, and narrow below; that which is below it, is narrow above and broad and cylindrical below, the circumference of the cylinder corresponding with the ring of the cricoid; while the space included by the constriction is a narrow, triangular fissure, the *glottis* or *rima glottidis*. The form of the glottis is that of an isosceles triangle, bounded on the sides by the chordæ vocales and inner surface of the arytenoid cartilages, and behind by the arytenoideus muscle. Its length is greater in the male than in the female, and in the former measures somewhat less than an inch. Immediately above the prominence caused by the chorda vocalis, and extending nearly its entire length on each side of the cavity of the larynx, is an elliptical fossa, the *ventricle of the larynx*. This fossa is bounded below by the chorda vocalis, which it serves to isolate, and above by a border of mucous membrane folded upon the lower edge of the superior thyro-arytenoid ligament. The whole of the cavity of the larynx, with its prominences and depressions, is lined by mucous membrane, which is continuous superiorly with that of the mouth and pharynx, and inferiorly is prolonged through the trachea and bronchial tubes into the lungs. In the ventricles of the larynx the mucous membrane forms a cæcal pouch of variable size, termed by Mr. Hilton the *sacculus laryngis*.\* The sacculus

\* This sac was described by Mr. Hilton before he was aware that it had already been pointed out by the older anatomists. I myself made a dissection, which I still possess, of the same sac in an enlarged state, during the month of August, 1837, without any knowledge either of Mr. Hilton's labours or Morgagni's account. The sac projected considerably above the upper border of the thyroid cartilage, and the extremity had been snipped off on one side in the removal of the muscles. The larynx was presented to me by Dr. George Moore of Camberwell; he had obtained it from a child who died of bronchial disease; and he conceived that this peculiar disposition of the mucous membrane might possibly explain some of the symptoms by which the case was accompanied. Cruveilhier made the same observation in equal ignorance of Morgagni's description, for we read in a note at page 677, vol. ii. of his *Anatomie Descriptive*.—"J'ai vu pour la première fois cette arrière cavité chez un individu affecté de phthisie laryngée, où elle était très-développée. Je fis des recherches sur le larynx d'autres individus, et je trouvai que cette disposition était constante. Je ne savais pas alors que Morgagni

laryngis is directed upwards, sometimes extending as high as the upper border of the thyroid cartilage, and occasionally above that border. When dissected from the interior of the larynx it is found covered by the aryteno-epiglottideus muscle and a fibrous membrane, which latter is attached to the superior thyro-arytenoid ligament below; to the epiglottis in front; and to the upper border of the thyroid cartilage above. If examined from the exterior of the larynx, it will be seen to be covered by the thyro-epiglottideus muscle. On the surface of its mucous membrane are the openings of sixty or seventy small follicular glands, which are situated in the submucous tissue, and give to its external surface a rough and ill-dissected appearance. The secretion from these glands is intended for the lubrication of the chordæ vocales, and is directed upon them by two small valvular folds of mucous membrane, which are situated at the entrance of the sacculus.

*Glands.*—The bodies known as the glands of the larynx, namely, the epiglottic and the arytenoid, are very improperly named. The former is a mass of areolo-fibrous and adipose tissue, situated in the triangular space between the front surface of the apex of the epiglottis, the hyo-epiglottidean and the thyro-hyoidean ligament. The latter is the body which forms a prominence in the aryteno-epiglottidean fold of mucous membrane, and has been described among the cartilages as the cuneiform cartilage.

*Vessels and Nerves.*—The *Arteries* of the larynx are derived from the superior and inferior thyroid. The *Nerves* are the superior laryngeal and recurrent laryngeal; both branches of the pneumogastric. The two nerves communicate with each other freely; but the superior laryngeal is distributed principally to the mucous membrane at the entrance of the larynx; the recurrent, to the muscles.

#### THE TRACHEA.

The TRACHEA extends from opposite the fifth cervical vertebra to opposite the third dorsal, where it divides into the two bronchi. The *right bronchus*, larger than the left, passes off nearly at *right angles* to the upper part of the corresponding lung. The *left* descends *obliquely*, and passes beneath the arch of the aorta, to reach the left lung.

The *Trachea* is composed of—

Fibro-cartilaginous rings,  
Fibrous membrane,  
Mucous membrane,  
Longitudinal elastic fibres,  
Muscular fibres,  
Glands.

The *Fibro-cartilaginous rings* are from fifteen to twenty in number, and extend for two-thirds around the cylinder of the trachea. They are deficient at the posterior part, where the tube is completed by fibrous membrane. The last ring has usually a triangular form in front. The rings

avait indiqué et faire présenter la même disposition." Cruveilhier compares its form very aptly to a "*Phrygian casque*," and Morgagni's figure, *Advers. 1. Epist. Anat. 3. plate 2. fig. 4.*, has the same appearance. But neither of these anatomists notice the follicular glands described by Mr. Hilton.

are connected to each other by a membrane of *yellow elastic fibrous tissue*, which in the space between the extremities of the cartilages, posteriorly, forms a distinct layer.

The *Longitudinal elastic fibres* are situated immediately beneath the mucous membrane on the posterior part of the trachea, and enclose the entire cylinder of the bronchial tubes to their terminations.

The *Muscular fibres* form a thin layer, extending transversely between the extremities of the cartilages. On the posterior surface they are covered in by an areolo-fibrous lamella, in which are lodged the *tracheal glands*. These are small flattened ovoid bodies, situated in great number between the fibrous and muscular layers of the membranous portion of the trachea, and also between the two layers of elastic fibrous tissue connecting the rings. They pour their secretion upon the mucous membrane.

### *Thyroid Gland.*

The thyroid gland or body is one of those organs which it is difficult to classify from the absence of any positive knowledge with regard to its function. It is situated upon the trachea, and in an anatomical arrangement may therefore be considered in this place, although bearing no part in the function of respiration.

This gland consists of two lobes, which are placed one on each side of the trachea, and are connected with each other by means of an *isthmus*, which crosses its upper rings. There is considerable variety in the situation and breadth of the isthmus, which should be recollected in the performance of operations upon the trachea. In structure it is composed, according to Mr. Simon,\* of a dense aggregation of minute and independent membranous cavities enclosed by a plexus of capillary vessels, and connected together by areolo-fibrous tissue. The cavities are filled with fluid, in which are found cyto-blasts and cells; the latter measuring  $\frac{1}{1400}$  of an inch in diameter. In young animals the cyto-blasts lie in contact with the internal wall of the cavities, and constitute a kind of tessellated epithelium. The gland is larger in young subjects and in females, than in the adult and males. It is the seat of an enlargement called bronchocele, goitre, or the Derbyshire neck.

A muscle is occasionally found connected with its upper border or with its isthmus; and attached, superiorly, to the body of the os hyoides, or to the thyroid cartilage. It was named by Soemmering the "*levator glandulae thyroideae*;" fig. 214, p. 487.

*Vessels and Nerves.*—It is abundantly supplied with blood by the superior and inferior thyroid arteries. Sometimes an additional artery is derived from the arteria innominata, and ascends upon the front of the trachea, to be distributed to the gland. The wounding of the latter vessel, in tracheotomy, might be fatal to the patient. The *nerves* are derived from the superior laryngeal and sympathetic.

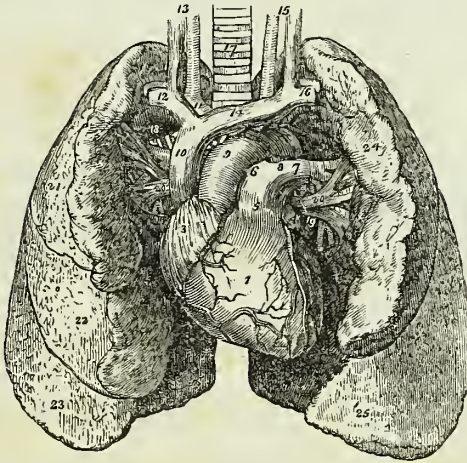
### THE LUNGS.

The lungs are two conical organs, situated one on each side of the chest, embracing the heart, and separated from each other by that organ

\* The Comparative Anatomy of the Thyroid Gland. Philosophical Transactions, 1844.

and by a membranous partition, the mediastinum. On the external or thoracic side they are convex, and correspond with the form of the cavity of the chest; internally they are concave, to receive the convexity of the heart. Superiorly they terminate in a tapering cone, which extends above the level of the first rib, and inferiorly they are broad and concave, and rest upon the convex surface of the diaphragm. Their posterior border is rounded and broad, the anterior sharp, and marked by one or two deep fissures, and the inferior border which surrounds the base is also sharp. The colour of the lungs is pinkish-grey, mottled, and variously marked with black. The surface is figured with irregularly polyhedral outlines, which represent the lobules of the organ, and the area of each of these polyhedral spaces is crossed by lighter lines.

Fig. 217.\*



Each lung is divided into two lobes, by a long and deep fissure, which extends from the posterior surface of the upper part of the organ, downwards and forwards to near the anterior angle of its base. In the right lung the upper lobe is subdivided by a second fissure, which extends obliquely forwards from the middle of the preceding to the anterior border of the organ, and marks off a small triangular lobe.

The right lung is larger than the left, in consequence of the inclination of the heart to the left side. It is also shorter, from the great convexity

\* Anatomy of the heart and lungs. 1. The right ventricle; the vessels to the left of the number are the middle coronary artery and veins; and those to its right, the anterior coronary artery and veins. 2. The left ventricle. 3. The right auricle. 4. The left auricle. 5. The pulmonary artery. 6. The right pulmonary artery. 7. The left pulmonary artery. 8. The remains of the ductus arteriosus. 9. The arch of the aorta. 10. The superior vena cava. 11. The arteria innominata, and in front of it the right vena innominata. 12. The right subclavian vein, and, behind it, its corresponding artery. 13. The right common carotid artery and vein. 14. The left vena innominata. 15. The left carotid artery and vein. 16. The left subclavian vein and artery. 17. The trachea. 18. The right bronchus. 19. The left bronchus. 20, 20. The pulmonary veins; 13, 20, form the root of the right lung; and 7, 19, 20, the root of the left. 21. The superior lobe of the right lung. 22. Its middle lobe. 23. Its inferior lobe. 24. The superior lobe of the left lung. 25. Its inferior lobe.

of the liver, which presses the diaphragm upwards upon the right side of the chest considerably above the level of the left; and has three lobes. The left lung is smaller, has but two lobes, but is longer than the right.

Each lung is retained in its place by its *root*, which is formed by the pulmonary artery, pulmonary veins and bronchial tubes, together with the bronchial vessels and pulmonary plexuses of nerves. The large vessels of the root of each lung are arranged in a similar order from before, backwards, on both sides, viz.

Pulmonary veins,  
Pulmonary artery,  
Bronchus.

From above, downwards, on the *right* side, this order is exactly reversed; but on the *left* side, the bronchus has to stoop beneath the arch of the aorta, which alters its position to the vessels. They are thus disposed on the two sides:—

| <i>Right.</i>                  | <i>Left.</i>                   |
|--------------------------------|--------------------------------|
| Bronchus,<br>Artery,<br>Veins. | Artery,<br>Bronchus,<br>Veins. |

*Structure.*—The lungs are composed of the ramifications of the bronchial tubes which terminate in intercellular passages and air-cells, of the ramifications of the pulmonary artery and veins, bronchial arteries and veins, lymphatics and nerves; the whole of these structures, being held together by areolo-fibrous tissue, constitute the *parenchyma*. The parenchyma of the lungs, when examined on the surface or by means of a section, is seen to consist of small polyhedral divisions, or lobules, which are connected to each other by an inter-lobular areolar tissue. These lobules again consist of smaller lobules, and the latter are formed by a cluster of air-cells, in the parietes of which the capillaries of the pulmonary artery and pulmonary veins are distributed.

*Bronchial Tubes.*—The two bronchi proceed from the bifurcation of the trachea to their corresponding lungs. The right takes its course nearly at right angles with the trachea, and enters the upper part of the right lung; while the left, longer and smaller than the right, passes obliquely beneath the arch of the aorta, and enters the lung at about the middle of its root. Upon entering the lungs they divide into two branches, and each of these divides and subdivides dichotomously to their ultimate termination in the intercellular passages and air-cells.

According to Mr. Rainey,\* the bronchial tubes continue to diminish in size until they attain a diameter of  $\frac{1}{50}$  to  $\frac{1}{30}$  of an inch, and arrive within  $\frac{1}{4}$  of an inch of the surface of the lung. They then become changed in structure, and are continued onwards in the midst of air-cells, under the name of *intercellular passages*. Lastly, the intercellular passages, after several bifurcations, terminate, each by a cæcal extremity or air-cell. The intercellular passages are at first cylindrical like the bronchial tubes, but soon become irregular in shape from the great number of air-cells which open into them on all sides. The *air-cells* are small, irregular in shape, and, most frequently, four-sided cavities, separated by thin septa, and communicating freely with the intercellular passages, and sparingly with

\* Medico-Chirurgical Transactions, vol. xxviii.



the bronchial tubes. The air-cells composing a lobule also communicate freely with each other.

The bronchial tubes, after the cessation of the fibro-cartilaginous plates, are composed of fibrous membrane (constructed of longitudinal and circular fibres) and mucous membrane, the latter being invested by a ciliated columnar epithelium. At the termination of these tubes the mucous membrane and epithelium cease abruptly, and the fibrous membrane, very thin and transparent, is continued onwards through the intercellular passages and air-cells. The same change takes place in the structure of the parietes, where the air-cells open directly into the bronchial tubes.

The capillaries of the lungs form plexuses which occupy the walls and septa of the air-cells and the walls of the intercellular passages, but are not continued into the bronchial tubes. The septa between the cells consist of a single layer of the capillary plexus enclosed in a fold of the fibrous lining membrane. The cells of the central parts of the lung are most vascular, and at the same time smallest, while those of the periphery are less vascular and larger.

The pigmentary matter of the lungs is contained in the air-cells, as well as in the areolo-fibrous tissue of the inter-lobular spaces and of the blood-vessels.

The *Pulmonary artery*, conveying the dark and impure venous blood to the lungs, terminates in capillary vessels, which form a minute network in the parietes of the intercellular passages and air-cells, and then converge to form the pulmonary veins, by which the arterial blood, purified in its passage through the capillaries, is returned to the left auricle of the heart.

The *Bronchial arteries*, branches of the thoracic aorta, ramify on the parietes of the bronchial tubes, while the venous blood is returned by the bronchial veins to the vena cava.

The *Lymphatics*, commencing on the surface and in the substance of the lungs, terminate in the bronchial glands. These glands, very numerous and often of large size, are placed at the roots of the lungs, around the bronchi, and at the bifurcation of the trachea. In early life they resemble lymphatic glands in other situations; but in old age, and often in the adult, are quite black, and filled with carbonaceous matter, and occasionally with calcareous deposits.

The *Nerves* are derived from the pneumogastric and sympathetic. They form two plexuses: *anterior pulmonary plexus*, situated upon the front of the root of the lungs, and composed chiefly of filaments from the great cardiac plexus; and *posterior pulmonary plexus*, on the posterior aspect of the root of the lungs, composed principally of branches from the pneumogastric. The branches from these plexuses follow the course of the bronchial tubes, and are distributed to the intercellular passages and air-cells.

#### PLEURÆ.

Each lung is enclosed, and its structure maintained, by a serous membrane, the pleura, which invests it as far as the root, and is then reflected upon the parietes of the chest. That portion of the membrane which is in relation with the lung is called *pleura pulmonalis*, and that in contact with the parietes, *pleura costalis*. The reflected portion, besides forming the internal lining to the ribs and intercostal muscles, also covers the diaphragm and the thoracic surface of the vessels at the root of the neck.

The pleura must be dissected from off the root of the lung, to see the vessels by which it is formed, and the pulmonary plexuses.

#### MEDIASTINUM.

The approximation of the two reflected pleuræ in the middle line of the thorax forms a septum, which divides the chest into the two pulmonary cavities. This is the mediastinum. The two pleuræ are not, however, in contact with each other at the middle line in the formation of the mediastinum, but have a space between them which contains all the viscera of the chest with the exception of the lungs. The mediastinum is divided into the *anterior*, *middle*, and *posterior*.

The *Anterior mediastinum* is a triangular space, bounded in front by the sternum, and on each side by the pleura. It contains a quantity of loose areolar tissue, in which are found some lymphatic vessels passing upwards from the liver, the remains of the thymus gland, the origins of the sterno-hyoid, sterno-thyroid, and triangularis sterni muscles, and the internal mammary vessels of the left side.

The *Middle mediastinum* contains the heart enclosed in its pericardium; the ascending aorta; the superior vena cava; the bifurcation of the trachea; the pulmonary arteries and veins; and the phrenic nerves.

The *Posterior mediastinum* is bounded behind by the vertebral column, in front by the pericardium, and on each side by the pleura. It contains the descending aorta; the greater and lesser azygos veins; the superior intercostal vein; the thoracic duct; the œsophagus and pneumogastric nerves, and the great splanchnic nerves.

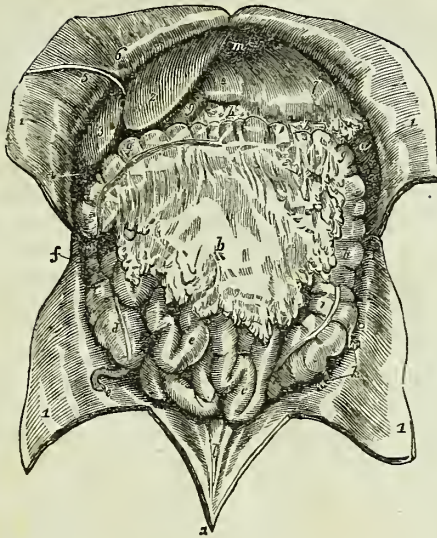
#### ABDOMEN.

The abdomen is the inferior cavity of the trunk of the body; it is *bounded in front* and *at the sides* by the lower ribs and abdominal muscles; *behind*, by the vertebral column and abdominal muscles; *above*, by the diaphragm; and, *below*, by the pelvis: and contains the alimentary canal, the organs subservient to digestion, viz. the liver, pancreas, and spleen; and the organs of excretion, the kidneys, with the supra-renal capsules.

*Regions.*—For convenience of description of the viscera, and of reference to the morbid affections of this cavity, the abdomen is divided into certain districts or regions. Thus, if two transverse lines be carried around the body, the one parallel with the inferior convexities of the ribs, the other with the highest points of the crests of the ilia, the abdomen will be divided into three zones. Again, if a perpendicular line be drawn at each side, from the cartilage of the eighth rib to the middle of Poupart's ligament, the three primary zones will each be subdivided into three compartments or regions, a middle and two lateral.

The middle region of the upper zone being immediately over the superior end of the stomach, is called *epigastric* (ἐπί γαστήρ, over the stomach). The two lateral regions being under the cartilages of the ribs are called *hypochondriac* (ὑπὸ χόνδρῳ, under the cartilages). The middle region of the middle zone is the *umbilical*; the two lateral, the *lumbar*. The middle region of the inferior zone is the *hypogastric* (ὑπὸ γαστήρ, below the stomach); and the two lateral, the *iliac*. In addition to these divisions we

Fig. 218.\*



employ the term *inguinal region*, in reference to the vicinity of Poupart's ligament.

*Position of the Viscera.*—In the *upper zone* will be seen the liver, extending across from the right to the left side; the stomach and spleen on the left, and the pancreas and duodenum behind. In the *middle zone* is the transverse portion of the colon, with the upper part of the ascending and descending colon, omentum, small intestines, mesentery, and, behind, the kidneys and supra-renal capsules. In the *inferior zone* is the lower part of the omentum and small intestines, the cæcum, ascending and descending colon with the sigmoid flexure, and ureters.

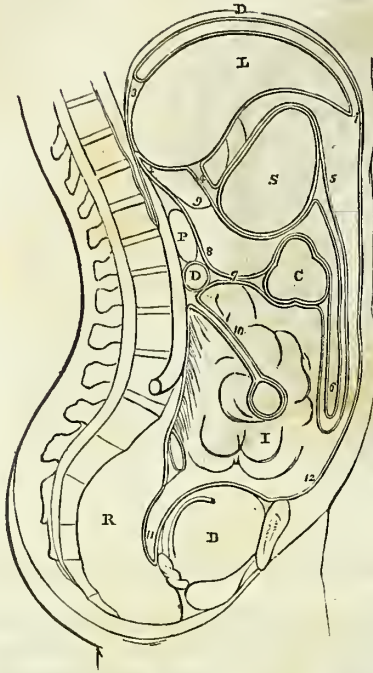
The smooth and polished surface, which the viscera and parietes of the abdomen present, is due to the peritoneum, which should in the next place be studied.

PERITONEUM.

The *Peritoneum* (*περιτρίβειν*, to extend around) is a serous membrane, and therefore a shut sac: a single exception exists in the human subject to this character, viz. in the female, where the peritoneum is perforated by the open extremities of the Fallopian tubes, and is continuous with their mucous lining.

\* The viscera of the abdomen in situ. 1, 1. The flaps of the abdominal parietes turned aside. 2. The liver, its left lobe. 3. Its right lobe. 4. The fundus of the gall-bladder. 5. The round ligament of the liver, issuing from the cleft of the longitudinal fissure, and passing along the parietes of the abdomen to the umbilicus. 6. Part of the broad ligament of the liver. 7. The stomach. 8. Its pyloric end. 9. The commencement of the duodenum. *a*. The lower extremity of the spleen. *b, b*. The greater omentum. *c, c*. The small intestines. *d*. The cæcum. *e*. The appendix cæci. *f*. The ascending colon. *g, g*. The transverse colon. *h*. The descending colon. *i*. The sigmoid flexure of the colon. *k*. Appendices epiploicæ connected with the sigmoid flexure. *l*. Three ridges, representing the cords of the urachus and the umbilical arteries ascending to the umbilicus. *m*. Part of the under surface of the diaphragm.

Fig. 219.\*



The simplest idea that can be given of a serous membrane, which may apply equally to all, is, that it invests the viscus or viscera, and is then reflected upon the parietes of the containing cavity. If the cavity contain only a single viscus, the consideration of the serous membrane is extremely simple. But in the abdomen, where there are a number of viscera, the serous membrane passes from one to the other until it has invested the whole, before it is reflected on the parietes. Hence its reflexions are a little more complicated.

In tracing the reflexions of the peritoneum in the middle line, we commence with the diaphragm, which is lined by two layers, one from the parietes in front, *anterior*, and one from the parietes behind, *posterior*. These two layers of the same membrane, at the posterior part of the diaphragm, descend to the upper surface of the liver, forming the *coronary* and *lateral ligaments* of the liver. They then surround the liver, one going in front, the other behind that viscus, and, meeting at its under surface, pass to the stomach, forming the *lesser omentum*. They then, in the same manner, surround the stomach, and, meeting at its lower border, descend for some distance in front of the intestines, and return to the transverse colon, forming the *great omentum*; they then surround the transverse colon, and pass directly backwards to the vertebral column, forming the *transverse meso-colon*. Here the two layers separate; the *posterior* ascends in front of the pancreas and aorta, and returns to the posterior part of the diaphragm, where it becomes the posterior layer with which we commenced. The *anterior* descends, invests all the small intestines, and returning to the vertebral column, forms the *mesentery*. It then descends into the pelvis in front of the

\* The reflexions of the peritoneum. D. The diaphragm. S. The stomach. C. The transverse colon. D. The transverse duodenum. P. The pancreas. I. The small intestines. R. The rectum. B. The urinary bladder. 1. The anterior layer of the peritoneum, lining the under surface of the diaphragm. 2. The posterior layer. 3. The coronary ligament, formed by the passage of these two layers to the posterior border of the liver. 4. The lesser omentum; the two layers passing from the under surface of the liver to the lesser curve of the stomach. 5. The two layers meeting at the greater curve, then passing downwards and returning upon themselves, forming (6) the greater omentum. 7. The transverse meso-colon. 8. The posterior layer traced upwards in front of D, the transverse duodenum, and P, the pancreas, to become continuous with the posterior layer (2). 9. The foramen of Winslow; the dotted line bounding this foramen inferiorly marks the course of the hepatic artery forwards, to enter between the layers of the lesser omentum. 10. The mesentery encircling the small intestine. 11. The recto-vesical fold, formed by the descending anterior layer. 12. The anterior layer traced upwards upon the internal surface of the abdominal parietes to the layer (1), with which the examination commenced.

rectum, which it holds in its place by means of a fold called *meso-rectum*, forms a pouch, the *recto-vesical fold*, between the rectum and bladder, ascends upon the posterior surface of the bladder, forming its false ligaments, and returns upon the anterior parietes of the abdomen to the diaphragm, whence we first traced it.

In the female, after descending into the pelvis in front of the rectum, it is reflected upon the posterior surface of the vagina and uterus. It then descends on the anterior surface of the uterus, and forms at either side the broad ligaments of that organ. From the uterus it ascends upon the posterior surface of the bladder and anterior parietes of the abdomen, and is continued, as in the male, to the diaphragm.

In this way the continuity of the peritoneum, as a whole, is distinctly shown, and it matters not where the examination commence or where it terminate, still the same continuity of surface will be discernible throughout. If we trace it from side to side of the abdomen, we may commence at the umbilicus; we then follow it outwards lining the inner side of the parietes to the ascending colon; it surrounds that intestine; it then surrounds the small intestine, and returning on itself forms the mesentery. It then invests the descending colon, and reaches the parietes on the opposite side of the abdomen, whence it may be traced to the exact point from which we started.

The viscera, which are thus shown to be invested by the peritoneum in its course from above downwards, are the—

|                   |                   |
|-------------------|-------------------|
| Liver,            | Small intestines, |
| Stomach,          | Pelvic viscera.   |
| Transverse colon, |                   |

The folds, formed between these and between the diaphragm and the liver, are—

(Diaphragm.)

Broad, coronary, and lateral ligaments.

(Liver.)

Lesser omentum.

(Stomach.)

Greater omentum.

(Transverse colon.)

Transverse meso-colon.

Mesentery,

Meso-rectum,

Recto-vesical fold,

False ligaments of the bladder.

And in the female, the—

Broad ligaments of the uterus.

The ligaments of the liver will be described with that organ.

The *Lesser omentum* is the duplicature which passes between the liver and the upper border of the stomach. It is extremely thin, excepting at its right border, where it is free, and contains between its layers, the—

Hepatic artery,  
 Ductus communis choledochus,  
 Portal vein,

Hepatic plexus of nerves,  
 Lymphatics.

These structures are enclosed in a loose areolar tissue, called *Glisson's capsule*.\* The relative position of the three vessels is, the artery to the left, the duct to the right, and the vein between and behind.

If the finger be introduced behind this right border of the lesser omentum, it will be situated in an opening called the *foramen of Winslow*.† In front of the finger will lie the right border of the lesser omentum; behind it the diaphragm, covered by the ascending or posterior layer of the peritoneum; below, the hepatic artery, curving forwards from the cœliac axis; and above, the lobus Spigelii. These, therefore, are the boundaries of the *foramen of Winslow*, which is nothing more than a constriction of the general cavity of the peritoneum at this point, arising out of the necessity for the hepatic and gastric arteries to pass forwards from the cœliac axis to reach their respective viscera.

If air be blown through the foramen of Winslow, it will descend behind the lesser omentum and stomach to the space between the descending and ascending pair of layers, forming the great omentum. This is sometimes called the lesser cavity of the peritoneum, and that external to the foramen the greater cavity; in which case the foramen is considered as the means of communication between the two. There is a great objection to this division, as it might lead the inexperienced to believe that there were really two cavities. There is but one only, the foramen of Winslow being merely a constriction of that one, to facilitate the communication between the nutrient arteries and the viscera of the upper part of the abdomen.

The *Great omentum* consists of *four layers of peritoneum*, the two which descend from the stomach, and the same two, returning upon themselves to the transverse colon. A quantity of adipose substance is deposited around the vessels which ramify through its structure. It would appear to perform a double function in the economy. 1st. Protecting the intestines from cold; and, 2dly. Facilitating the movement of the intestines upon each other during their vermicular action.

The *Transverse meso-colon* (μέσος, middle, being attached to the middle of the cylinder of the intestine) is the medium of connexion between the transverse colon and the posterior wall of the abdomen. It also affords to the nutrient arteries a passage to reach the intestine, and encloses between its layers, at the posterior part, the transverse portion of the duodenum.

The *Mesentery* (μέσον ἐντέρον, being connected to the middle of the cylinder of the small intestine) is the medium of connexion between the small intestines and the posterior wall of the abdomen. It is oblique in its direction, being attached to the posterior wall, from the left side of the second lumbar vertebra to the right iliac fossa. It retains the small intestines in their places, and gives passage to the mesenteric arteries, veins, nerves, and lymphatics.

The *Meso-rectum*, in like manner, retains the rectum in connexion with the front of the sacrum. Besides this, there are some minor folds in the

\* Francis Glisson, Professor of Medicine in the University of Cambridge. His work, "De Anatomia Hepatis," was published in 1654.

† Jacob Benignus Winslow: his "Exposition Anatomique de la Structure du Corps Humain" was published in Paris in 1732.

pelvis, as the *recto-vesical* fold, the *false ligaments of the bladder*, and the *broad ligaments of the uterus*.

The *Appendices epiploicæ* are small irregular pouches of the peritoneum, filled with fat, and situated like fringes upon the large intestine.

Three other duplicatures of the peritoneum are situated in the sides of the abdomen; they are the *gastro-phrenic ligament*, the *gastro-splenic omentum*, the *ascending and descending meso-colon*. The *gastro-phrenic ligament* is a small duplicature of the peritoneum, which descends from the diaphragm to the extremity of the œsophagus, and lesser curve of the stomach. The *gastro-splenic omentum* is the duplicature which connects the spleen to the stomach. The *ascending meso-colon* is the fold which connects the upper part of the ascending colon with the posterior wall of the abdomen; and the *descending meso-colon*, that which retains the sigmoid flexure in connexion with the abdominal wall.

*Structure of Serous Membrane.*—Serous membrane consists of two layers, an external or areolo-fibrous layer, and an internal layer or epithelium. The *areolo-fibrous layer* upon its outer surface is rough and vascular, and adherent to surrounding structures; but on its inner or free surface is dense and smooth, and deficient of vessels. The smooth and brilliant surface of serous membrane is due to a distinct epithelium, composed of laminæ of cells, and flattened polyhedral scales with central nuclei, like the epiderma and epithelium of mucous membrane. Henle has also observed this structure, which may be demonstrated with a good microscope, on the surface of all the serous membranes of the body, upon the surface of the lining membrane of arteries and veins, and on synovial membranes.

The general characters of a serous membrane are its resemblance to a shut sac, and its secretion of a peculiar fluid, resembling the serum of the blood; but the former of these characters is not absolutely essential to the identity of a serous membrane; for, as we have shown above, the peritoneum in the female is perforated by the extremities of the Fallopian tubes; while in some aquatic reptiles there is a direct communication between its cavity and the medium in which they live.

From the variable nature of the secretion of these membranes, they have been divided into two classes, the true serous membranes, viz. the arachnoid, pericardium, pleuræ, peritoneum, and tunicæ vaginales, which pour out a secretion containing but a small portion of albumen; and the synovial membranes and bursæ, which secrete a fluid containing a larger quantity of albumen.

## ALIMENTARY CANAL.

The *Alimentary canal* is a musculo-membranous tube, extending from the mouth to the anus. It is variously named in the different parts of its course; hence it is divided into the

|                 |             |
|-----------------|-------------|
| Mouth,          |             |
| Pharynx,        |             |
| Œsophagus,      |             |
| Stomach,        |             |
| Small intestine | { Duodenum, |
|                 | { Jejunum,  |
|                 | { Ileum.    |

|                 |   |                             |
|-----------------|---|-----------------------------|
| Large intestine | } | Cæcum,<br>Colon,<br>Rectum. |
|-----------------|---|-----------------------------|

The *Mouth* is the irregular cavity which contains the organs of taste and the principal instruments of mastication. It is bounded *in front* by the lips; on either *side* by the internal surface of the cheeks; *above* by the hard palate and teeth of the upper jaw; *below* by the tongue, by the mucous membrane stretched between the arch of the lower jaw and the under surface of the tongue, and by the teeth of the inferior maxilla; and *behind* by the soft palate and fauces.

The *Lips* are two fleshy folds formed externally by common integument, and internally by mucous membrane, and containing between these two layers the muscles of the lips, a quantity of fat, and numerous small labial glands. They are attached to the surface of the upper and lower jaw, and each lip is connected to the gum in the middle line by a fold of mucous membrane, the *frænum labii superioris* and *frænum labii inferioris*, the former being the larger.

The *Cheeks* (*buccæ*) are continuous on either hand with the lips, and form the sides of the face; they are composed of integument, a large quantity of fat, muscles, mucous membrane, and buccal glands.

The mucous membrane lining the cheeks is reflected above and below upon the sides of the jaws, and is attached posteriorly to the anterior margin of the ramus of the lower jaw. At about its middle, opposite the second molar tooth of the upper jaw, is a papilla, upon which may be observed a small opening, the aperture of the duct of the parotid gland.

The *Hard palate* is a dense structure, composed of mucous membrane, palatal glands, fibrous tissue, vessels, and nerves, and firmly connected to the palate processes of the superior maxillary and palate bones. It is bounded in front and on each side by the alveolar processes and gums, and is continuous behind with the soft palate. Along the middle line it is marked by an elevated raphé, and presents upon each side of the raphé a number of transverse ridges and grooves. Near its anterior extremity, and immediately behind the middle incisor teeth, is a papilla which corresponds with the termination of the naso-palatine canal, and has been supposed to be endowed with a peculiar sensibility.

The *Gums* are composed of a thick and dense mucous membrane, which is closely adherent to the periosteum of the alveolar processes, and embraces the necks of the teeth. They are remarkable for their hardness and insensibility; and for their close contact, without adhesion, to the surface of the tooth. From the neck of the tooth they are reflected into the alveolus, and become continuous with the periosteal (peridental) membrane of that cavity.

The *Tongue* has been already described as an organ of sense; it is invested by mucous membrane, which is reflected from its under part upon the inner surface of the lower jaw, and constitutes with the muscles beneath, the floor of the mouth. Upon the under surface of the tongue, near its anterior part, the mucous membrane forms a considerable fold, which is called the *frænum linguæ*; and on each side of the *frænum* is a large papilla, the commencement of the duct of the submaxillary gland, and several smaller openings, the apertures of the ducts of the sublingual gland.



The *Soft palate* (velum pendulum palati) is a fold of mucous membrane situated at the posterior part of the mouth. It is continuous, superiorly, with the hard palate, and is composed of mucous membrane, palatal glands, and muscles. Hanging from the middle of its inferior border is a small rounded process, the *uvula*; and passing outwards from the uvula on each side are two curved folds of the mucous membrane, the arches, or pillars of the palate. The *anterior pillar* is continued downwards to the side of the base of the tongue, and is formed by the prominence of the palato-glossus muscle. The *posterior pillar* is prolonged downwards and backwards into the pharynx, and is formed by the convexity of the palato-pharyngeus muscle. These two pillars, closely united above, are separated below by a triangular interval or niche, in which the tonsil is lodged.

The *Tonsils* (amygdalæ) are two glandular organs, shaped like almonds, and situated between the anterior and posterior pillar of the soft palate, on each side of the fauces. They are composed of an assemblage of mucous follicles, which open upon the surface of the gland. Externally, they are invested by the pharyngeal fascia, which separates them from the superior constrictor muscle and internal carotid artery, and prevents an abscess from opening in that direction. In relation to surrounding parts, they correspond with the angle of the lower jaw.

The space included between the soft palate and the root of the tongue is the *isthmus of the fauces*. It is bounded *above* by the soft palate; on each *side* by the pillars of the soft palate and tonsils; and *below* by the root of the tongue. It is the opening between the mouth and pharynx.

#### SALIVARY GLANDS.

Communicating with the mouth are the excretory ducts of three pairs of salivary glands, the parotid, submaxillary, and sublingual.

The *Parotid gland*, (*παρά*, near, *οἴς*, *ᾠτος*, the ear,) the largest of the three, is situated immediately in front of the external ear, and extends superficially for a short distance over the masseter muscle, and deeply behind the ramus of the lower jaw. It reaches inferiorly to below the level of the angle of the lower jaw, and posteriorly to the mastoid process, slightly overlapping the insertion of the sterno-mastoid muscle. Embedded in its substance are the external carotid artery, temporo-maxillary vein, and facial nerve; emerging from its anterior border, the transverse facial artery and branches of the pes anserinus; and above, the temporal artery.

The duct of the parotid gland (Stenon's\* duct) commences at the papilla upon the internal surface of the cheek, opposite the second molar tooth of the upper jaw; and, piercing the buccinator muscle, crosses the masseter to the anterior border of the gland, where it divides into several branches, which subdivide and ramify through its structure, to terminate in the small cæcal pouches of which the gland is composed. A small branch is generally given off from the duct while crossing the masseter muscle, which forms, by its ramifications and terminal dilatations, a small glandular appendage, the *socia parotidis*. Stenon's duct is remarkably dense and of considerable thickness, while the area of its canal is extremely small.

The *Submaxillary gland* is situated in the posterior angle of the sub-

\* Nicholas Stenon, an anatomist of great research. He discovered the parotid duct while in Paris. He was appointed Professor of Medicine in Copenhagen in 1672. His work, "De Musculis et Glandulis Observationes," was published in 1664

maxillary triangle of the neck. It rests upon the hyo-glossus and mylo-hyoideus muscles, and is covered in by the body of the lower jaw and by the deep cervical fascia. It is separated from the parotid gland by the stylo-maxillary ligament, and from the sublingual by the mylo-hyoideus muscle. Embedded among its lobules are the facial artery and submaxillary ganglion.

The excretory duct (Wharton's) of the submaxillary gland commences upon the papilla, by the side of the frænum linguæ, and passes backwards beneath the mylo-hyoideus and resting upon the hyo-glossus muscle, to the middle of the gland, where it divides into numerous branches, which ramify through the structure of the gland, and terminate by cæcal extremities. It lies in its course against the mucous membrane forming the floor of the mouth, and causes a prominence of that membrane.

The *Sublingual* is an elongated and flattened gland, situated beneath the mucous membrane of the floor of the mouth, on each side of the frænum linguæ. It is in relation, *above*, with the mucous membrane; *in front*, with the depression by the side of the symphysis of the lower jaw; *externally*, with the mylo-hyoideus muscle; and, *internally*, with the hypoglossal nerve and genio-hyo-glossus muscle.

It pours its secretion into the mouth by seven or eight small ducts, which open by small apertures on each side of the frænum linguæ.

*Structure.*—The salivary are conglomerate glands, consisting of lobes, which are made up of polyhedral lobules, and these of smaller lobules.

The smallest lobule is apparently composed of granules, which are minute cæcal pouches, formed by the dilatation of the extreme ramifications of the ducts. These minute ducts unite to form lobular ducts, and the lobular ducts constitute by their union a single excretory duct. The cæcal pouches are connected by areolo-fibrous tissue, so as to form a minute lobule; the lobules are held together by a more condensed areolar layer; and the larger lobes are enveloped by a dense areolo-fibrous capsule, which is firmly attached to the deep cervical fascia.

*Vessels and Nerves.*—The parotid gland is abundantly supplied with *arteries* by the external carotid; the submaxillary by the facial; and the sublingual by the sublingual branch of the lingual artery.

The *Nerves* of the parotid gland are derived from the auricular branch of the inferior maxillary, from the auricularis magnus, and from the nervi molles accompanying the external carotid artery. The submaxillary gland is supplied by the branches of the submaxillary ganglion, and by filaments from the mylo-hyoidean nerve; and the sublingual by filaments from the submaxillary ganglion and gustatory nerve.

#### PHARYNX.

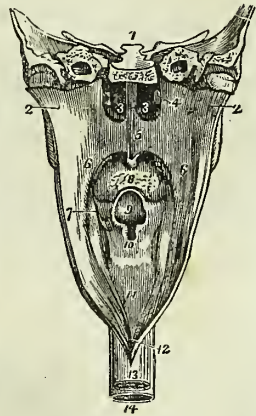
The pharynx (φάρυγξ, the throat) is a musculo-membranous sac, situated upon the cervical portion of the vertebral column, and extending from the base of the skull to a point corresponding with the cricoid cartilage in front, and the fifth cervical vertebra behind. It is composed of mucous membrane, muscles, vessels, and nerves, and is invested by a strong fascia, situated between the mucous membrane and muscles, which serves to connect it with the basilar process of the occipital bone and with the petrous portions of the temporal bones. Upon its anterior part it is incomplete, and has opening into it seven foramina, viz.—

Posterior nares, two,  
Eustachian tubes, two,  
Mouth,  
Larynx,  
Œsophagus.

The *Posterior nares* are the two large openings at the upper and front part of the pharynx. On each side of these openings, and slightly above the posterior termination of the inferior turbinated bone, is the irregular depression in the mucous membrane, marking the entrance of the *Eustachian tube*. Beneath the posterior nares is the large opening into the *mouth*, partly veiled by the soft palate; and, beneath the root of the tongue, the cordiform opening of the larynx. The *œsophageal* opening is the lower constricted portion of the pharynx.

*Œsophagus*.—The œsophagus (ἀΐειν, to bear, φαγεῖν, to eat) is a slightly flexuous canal, inclining to the left in the neck, to the right in the upper part of the thorax,† and again to the left in its course through the posterior mediastinum; it commences at the termination of the pharynx, opposite the lower border of the cricoid cartilage and fifth cervical vertebra, and descends the neck behind and rather to the left of the trachea. It then passes behind the arch of the aorta, and along the posterior mediastinum, lying in front of the thoracic aorta, to the œsophageal opening in the diaphragm, where it enters the abdomen, and terminates at the cardiac orifice of the stomach at a point about opposite the tenth dorsal vertebra. The œsophagus is flattened and narrow in the cervical region, and cylindrical in the rest of its course; its largest diameter is met with near the lower part of its course.

Fig. 220.\*



## THE STOMACH.

The stomach is an expansion of the alimentary canal, situated in the left hypochondriac, and extending into the epigastric region. It is directed somewhat obliquely from above downwards, from left to right, and from before backwards; and in the female, where the injurious system of tight-lacing has been pursued, is longer than in the male. On account of the peculiarity of its form, it is divided into a *greater* or *splenic*, and a *lesser* or *pyloric*, end; a *lesser curvature* above, and a *greater curvature* below; an *anterior* and a *posterior surface*; a *cardiac orifice*, and a *pyloric orifice*. The great end is not only of large size, but expands beyond the

\* The pharynx laid open from behind. 1. A section carried transversely through the base of the skull. 2, 2. The walls of the pharynx drawn to each side. 3, 3. The posterior nares, separated by the vomer. 4. The extremity of the Eustachian tube of one side. 5. The soft palate. 6. The posterior pillar of the soft palate. 7. Its anterior pillar; the tonsil is seen in the niche between the two pillars. 8. The root of the tongue, partly concealed by the uvula. 9. The epiglottis, overhanging (10) the cordiform opening of the larynx. 11. The posterior part of the larynx. 12. The opening into the œsophagus. 13. The external surface of the œsophagus. 14. The trachea.

† Cruveilhier remarks that this inflexion explains the obstruction which a *louis* sometimes meets with, in its passage along the œsophagus, opposite the first rib.

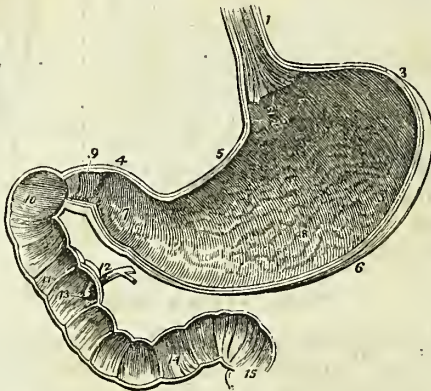
point of entrance of the œsophagus, and is embraced by the concave surface of the spleen. The pylorus is the small and contracted extremity of the organ; near its extremity is a small dilatation which was called by Willis the antrum of the pylorus. The two curvatures give attachment to the peritoneum; the upper curve to the lesser omentum, and the lower to the greater omentum. The anterior surface looks upwards and forwards, and is in relation with the diaphragm, (which separates it from the viscera of the thorax and from the six lower ribs,) with the left lobe of the liver, and in the epigastric region with the abdominal parietes. The posterior surface looks downwards and backwards, and is in relation with the diaphragm, the pancreas, the third portion of the duodenum, the transverse meso-colon, the left kidney, and left supra-renal capsule; this surface forms the anterior boundary of that cul-de-sac of the peritoneum which is situated behind the lesser omentum and extends into the greater omentum.

## SMALL INTESTINE.

The small intestine is about twenty-five feet in length, and is divisible into three portions, *duodenum*, *jejunum*, and *ileum*.

The *Duodenum* (called *δωδεκάδακτυλον* by Herophilus) is somewhat larger than the rest of the small intestines, and has received its name from being

Fig. 221.\*



about equal in length to the breadth of twelve fingers. Commencing at the pylorus, it ascends *obliquely* backwards to the under surface of the liver; it next descends *perpendicularly* in front of the right kidney, and

\* A vertical and longitudinal section of the stomach and duodenum, made in such a direction as to include the two orifices of the stomach. 1. The œsophagus; upon its internal surface the plicated arrangement of the cuticular epithelium is shown. 2. The cardiac orifice of the stomach, around which the fringed border of the cuticular epithelium is seen. 3. The great end of the stomach. 4. Its lesser or pyloric end. 5. The lesser curve. 6. The greater curve. 7. The dilatation at the lesser end of the stomach, which has received from Willis the name of antrum of the pylorus. This may be regarded as the rudiment of a second stomach. 8. The rugæ of the stomach, formed by the mucous membrane: their longitudinal direction is shown. 9. The pylorus. 10. The oblique portion of the duodenum. 11. The descending portion. 12. The pancreatic duct and the ductus communis choledochus close to their termination. 13. The papilla upon which the ducts open. 14. The transverse portion of the duodenum. 15. The commencement of the jejunum. In the interior of the duodenum and jejunum the *valvulæ conniventes* are seen.

then passes nearly *transversely* across the third lumbar vertebra; terminating in the jejunum on the left side of the second lumbar vertebra, where it is crossed by the superior mesenteric artery and vein. The *first* or *oblique portion* of its course, between two and three inches in length, is completely enclosed by the peritoneum: it is in relation, *above* with the liver and neck of the gall-bladder; *in front* with the great omentum and abdominal parietes; and *behind* with the right border of the lesser omentum and its vessels. The *second* or *perpendicular portion* is situated altogether behind the peritoneum; it is in relation by its *anterior surface* with the commencement of the arch of the colon; by its *posterior surface* with the concave margin of the right kidney, the inferior vena cava, and the ductus communis choledochus; by its *right border* with the ascending colon; and by its *left border* with the pancreas. The ductus communis choledochus and pancreatic duct open into the internal and posterior side of the perpendicular portion, a little below its middle. The *third* or *transverse portion* of the duodenum lies between the diverging layers of the transverse meso-colon, with which and with the stomach it is in relation *in front*; *above*, it is in contact with the lower border of the pancreas, the superior mesenteric artery and vein being interposed; and, *behind*, it rests upon the inferior vena cava and aorta.

The *Jejunum* (jejunus, empty) is named from being generally found empty. It forms the upper two-fifths of the small intestine; commencing at the duodenum, on the left side of the second lumbar vertebra, and terminating in the ileum. It is thicker to the touch than the rest of the intestine, and has a pinkish tinge from containing more mucous membrane than the ileum.

The *Ileum* (ἑιλῆιν, to twist, to convolute) includes the remaining three-fifths of the small intestine. It is somewhat smaller in calibre, thinner in texture, and paler than the jejunum; but there is no mark by which to distinguish the termination of the one or the commencement of the other. It terminates in the right iliac fossa, by opening at an obtuse angle into the colon.

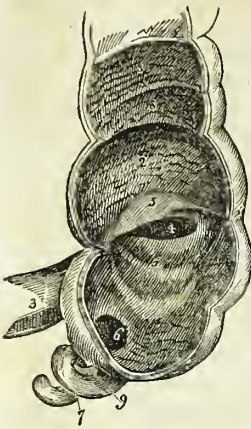
The jejunum and ileum are surrounded, above and at the sides, by the colon; in front, they are in relation with the omentum and abdominal parietes; they are retained in their position by the mesentery, which connects them with the posterior wall of the abdomen; and below they descend into the cavity of the pelvis. At about the lower third of the ileum a pouch-like process or diverticulum of the intestine is occasionally seen. This is a vestige of embryonic structure, and is formed by the obliteration of the vitelline duct at a short distance from the cylinder of the intestine.

## LARGE INTESTINE.

The large intestine, about five feet in length, is sacculated in appearance, and is divided into the *cæcum*, *colon*, and *rectum*.

The *Cæcum* (cæcus, blind) is the blind pouch, or cul-de-sac, at the commencement of the large intestine. It is situated in the right iliac fossa, and is retained in its place by the peritoneum which passes over its anterior surface; its posterior surface is connected by loose areolar tissue with the iliac fascia. Attached to its extremity is the appendix vermiformis, a long worm-shaped tube, the rudiment of the lengthened cæcum found in all mammiferous animals except man and the higher quadrumana. The

Fig. 222.\*



appendix varies in length from one to five or six inches; it is about equal in diameter to a goose-quill, and is connected with the posterior and left aspect of the cæcum near the extremity of the ileum. It is usually more or less coiled upon itself, and retained in that coil by a falciform duplicature of peritoneum. Its canal is extremely small, and the orifice by which it opens into the cæcum not unfrequently provided with an incomplete valve. Occasionally the peritoneum invests the cæcum so completely as to constitute a meso-cæcum, which permits of an unusual degree of movement in this portion of the intestine, and serves to explain the occurrence of hernia of the cæcum upon the right side. The cæcum is the most dilated portion of the large intestine.

The *Colon* is divided into *ascending*, *transverse*, and *descending*. The *ascending colon* passes upwards from the right iliac fossa, through the right lumbar region, to the under surface of the liver. It then bends inwards and crosses the upper part of the umbilical region under the name of *transverse colon*, and, on the left side, descends (*descending colon*) through the left lumbar region to the left iliac fossa, where it makes a remarkable curve upon itself, which is called the *sigmoid flexure*.

The *ascending colon*, the most dilated portion of the large intestine, next to the cæcum, is retained in its position in the abdomen either by the peritoneum passing simply in front of it or by a narrow meso-colon. It is in relation *in front* with the small intestine and abdominal parietes; *behind* with the quadratus lumborum muscle and right kidney; *internally* with the small intestine and the perpendicular portion of the duodenum; and by its *upper extremity* with the under surface of the liver and gall-bladder. The *transverse colon*, the longest portion of the large intestine, forms a curve across the cavity of the abdomen, the convexity of which looks forwards and sometimes downwards. It is in relation, by its *upper surface*, with the liver, gall-bladder, stomach; and lower extremity of the spleen; by its *lower surface*, with the small intestine; by its *anterior surface*, with the anterior layers of the great omentum and the abdominal parietes; and, by its *posterior surface*, with the transverse meso-colon. The *descending colon* is smaller in calibre, and is situated more deeply than the ascending colon. Its relations are precisely similar. The *sigmoid flexure* is the narrowest part of the colon; it curves in the first place upwards and then downwards, and to one or the other side, and is retained in its place by a meso-colon. It is in relation, *in front*, with the small intestine and abdominal parietes; *behind*, with the iliac fossa, and, on either *side*, with the small intestine.

The *Rectum* is the termination of the large intestine. It has received its name, not so much from the direction of its course, as from the straightness of its form in comparison with the colon. It descends, from opposite

\* The cæcum, showing its appendix, the entrance of the ileum, and the ileo-cæcal valve. 1. The cæcum. 2. The commencement of the colon. 3. The ileum. 4. The aperture of entrance of the ileum into the cæcum. 5, 5. The ileo-cæcal valve. 6. The aperture of the appendix vermiformis cæci. 7. The appendix vermiformis. 8, 8. Sacculi of the colon, separated by valvular septa. 9. The falciform frænum of the appendix vermiformis.

the left sacro-iliac symphysis, in front of the sacrum, forming a gentle curve to the right side, and then returning to the middle line; near the extremity of the coccyx it curves backwards to terminate at the anus at about an inch in front of the apex of that bone. The rectum, therefore, forms a double flexure in its course, the one being directed from side to side, the other from before backwards. It is smaller in calibre at its upper part than the sigmoid flexure, but becomes gradually larger as it descends, and its lower extremity, previously to its termination at the anus, forms a dilatation of considerable but variable magnitude.

With reference to its relations, the rectum is divided into three portions; the *first*, including half its length, extends to about the middle of the sacrum, is completely surrounded by peritoneum, and connected to the sacrum by means of the meso-rectum. It is in relation, above, with the left sacro-iliac symphysis; and, below, with the branches of the internal iliac artery, and with the sacral plexus of nerves; one or two convolutions of the small intestine are interposed between the front of the rectum and the bladder, in the male; and between the rectum and the uterus with its appendages, in the female. The *second portion*, about three inches in length, is closely attached to the surface of the sacrum, and covered by peritoneum only in front; it is in relation by its lower part with the base of the bladder, vesiculæ seminales, and prostate gland, and in the female with the vagina. The *third portion* curves backwards from opposite the prostate gland to terminate at the anus; it is embraced by the levatores ani, and is about one inch and a half in length. It is separated from the membranous portion of the urethra by a triangular space; in the female this space intervenes between the vagina and the rectum, and constitutes by its base the perineum.

The *Anus* is situated at a little more than an inch in front of the extremity of the coccyx. The integument around it is covered with hairs, and is thrown into numerous radiated plaits which are obliterated during the passage of fæces. The margin of the anus is provided with an abundance of sebiparous glands, and the epiderma may be seen terminating by a fringed and scalloped border, at a few lines above the extremity of the opening.

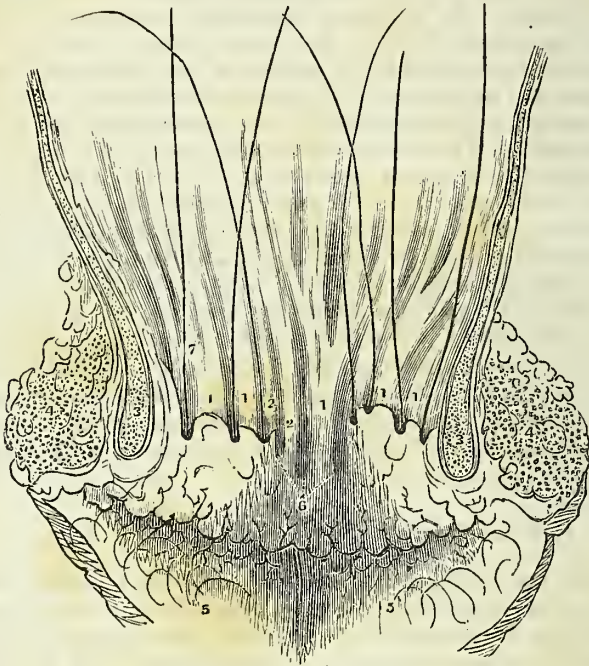
#### STRUCTURE OF THE INTESTINAL CANAL.

The pharynx has three coats; a mucous coat, a fibrous coat derived from the pharyngeal fascia, and a muscular layer. The œsophagus has but two coats, the mucous and muscular. The stomach and intestines have three, *mucous* and *muscular*, and an external *serous* investment, derived from the peritoneum.

**MUCOUS COAT.**—The mucous membrane of the mouth invests the whole internal surface of that cavity, and is reflected along the parotid, submaxillary, and sublingual ducts, into the corresponding glands. It terminates anteriorly upon the outer margin of the red border of the lips, and posteriorly is continuous with the mucous lining of the pharynx. The mucous membrane of the pharynx is continuous with the mucous lining of the Eustachian tubes, the nares, the mouth, and the larynx. In the œsophagus it is thick, very loosely connected with the muscular coat, and disposed in *longitudinal plicæ*. In the stomach the mucous membrane is thin and

vascular at the great extremity, and becomes thicker and lighter in colour towards the pyloric extremity. It is formed into plaits or *rugæ*, which are disposed for the most part in a longitudinal direction. The *rugæ* are most numerous towards the lesser end of the stomach; while around the cardiac orifice they assume a radiated arrangement. At the pylorus the mucous membrane forms a circular or spiral fold which constitutes a part of the apparatus of the *pyloric valve*. In the lower half of the duodenum, the whole length of the jejunum, and the upper part of the ileum, it forms valvular folds called *valvula conniventes*, which are several lines in breadth in the lower part of the duodenum and upper portion of the jejunum, and diminish gradually in size towards each extremity. These folds do not entirely surround the cylinder of the intestine, but extend for about one-half or three-fourths of its circumference. In the lower half of the ileum the mucous lining is without folds; hence the thinness of the coats of this

Fig. 223.\*



intestine as compared with the jejunum and duodenum. At the termination of the ileum in the cæcum, the mucous membrane forms two folds, which are strengthened by the muscular coat, and project into the cæcum. These are the *ileo-cæcal valve* (*valvula Bauhini*). In the cæcum and colon the mucous membrane is raised into crescentic folds, which correspond

\* A vertical section of the anterior parietes of the anus, with the whole canal displayed so as to show the relations of the sacculi of the middle region, and their relations to the surrounding parts, their orifices being marked with bristles. 1, 1. Columns of the rectum. 2, 2. Rudiments of columns. 3. Internal sphincter. 4. External sphincter. 6. Rudimentary or imperfect sacculi. 5, 5. Radiated folds of the skin, terminating on the surface of the nates. 7. A bristle in one of the sacs.—G.



with the sharp edges of the sacculi; and, in the rectum, it forms three valvular folds,\* one of which is situated near the commencement of the intestine; the second, extending from the side of the tube, is placed opposite the middle of the sacrum; and the third, which is the largest and most constant, projects from the anterior wall of the intestine opposite the base of the bladder. Besides these folds, the membrane in the empty state of the intestine is thrown into longitudinal plaits, somewhat similar to those of the œsophagus; these have been named the *columns* of the rectum. The mucous membrane of the rectum is connected to the muscular coat by a very loose areolar tissue, as in the œsophagus.†

*Structure of Mucous Membrane.*—Mucous membrane is analogous to the cutaneous covering of the exterior of the body, and resembles that tissue very closely in its structure. It is composed of three layers, an *epithelium*, a *proper mucous*, and a *fibrous layer*.

The *Epithelium* is the epiderma of the mucous membrane. Throughout the pharynx and œsophagus it resembles the epiderma, both in appearance and character. It is continuous with the epiderma of the skin at the margin of the lips, and terminates by an irregular border at the cardiac orifice of the stomach. At the opposite extremity of the canal it terminates by a scalloped border just within the verge of the anus. In the mouth it is composed of laminæ of cytoblasts, cells, and polyhedral scales (fig. 209). Each cell and each scale possesses a central nucleus, and within the nucleus are one or more nucleus-corpuscles. According to Mr. Nasmyth,‡ the deepest lamina of the epithelium appears to consist of nuclei (cytoblasts) only; in the next the investing vesicle or cell is developed; the cells by degrees enlarge and become flattened, and in the superficial laminæ are converted into thin scales. The nuclei, the cells, and the scales are connected together by a glutinous fluid of the consistence of jelly, which contains an abundance of minute opaque granules. The scales of the superficial layer overlap each other by their margins. During the natural functions of the mucous membrane the superficial scales exfoliate continually and give place to the deeper layers. In the stomach and intestines these bodies are pyriform in shape, and have a columnar arrangement, the apices being applied to the papillary surface of the membrane, and the bases forming, by their approximation, the free intestinal surface. Each column is provided with a central nucleus and nucleus-corpuscle, which gives its middle a swollen appearance; and, from the transparency of its structure, the nucleus may be seen through the base of the column, when examined from the surface. Around the circular villi, the columns, from being placed perpendicularly to the surface, have a radiated arrangement. The columnar epithelium is produced, in the same manner with the laminated epithelium, in cytoblasts, cells, and columns, and the latter are continually thrown off to give place to successive layers.

\* Mr. Houston, "On the Mucous Membrane of the Rectum." Dublin Hospital Reports, vol. v.

† The spaces between the columns of the rectum become closed at the anus so as to form a series of pouches represented in the accompanying cut. These pouches are sometimes dilated and produce a disease first described by Dr. Physick. (See Gibson's Surgery.) The mucous membrane of the rectum is connected to the muscular coat by a very loose cellular tissue, as in the œsophagus.—G.

‡ Investigations into the structure of the Epithelium, presented to the medical section of the British Medical Association, in 1839, published in a work entitled "Three Memoirs on the Development of the teeth and epithelium," 1841.

The *Proper mucous*, or *Papillary layer* is analogous to the papillary layer of the skin, and, like it, is the formative structure by which the epithelium is produced. Its surface presents several varieties of appearance when examined in different parts of its extent. In the stomach it forms polyhedral cells, into the floor of which the gastric follicles open. In the small intestine it presents numerous minute, projecting papillæ, called villi. The villi are of two kinds, *cylindrical* and *laminated*, and so abundant, as to give to the entire surface a beautiful velvety appearance. In the large intestine the surface is composed of a fine network of minute polyhedral cells, more numerous than those of the stomach, but resembling them in receiving the secretion from numerous perpendicular follicles into their floors.

The *Fibrous layer* (sub-mucous, nervous) is the membrane of support to the mucous membrane, as is the corium to the papillary layer of the skin. It gives to the mucous membrane its strength and resistance, is but loosely connected with the mucous layer, but is firmly adherent to the muscular stratum, and is called, in the older works on anatomy, the "*nervous coat*."

*Glands*.—In the loose areolar tissue connecting the mucous with the fibrous layer, are situated the glands and follicles belonging to the mucous membrane: these are the—

Pharyngeal glands,  
Œsophageal glands,  
Gastric follicles,  
Duodenal glands (Brunner's),  
Glandulæ solitariæ,  
Glandulæ aggregatæ (Peyer's),  
Simple follicles (Lieberkühn's).

The *Pharyngeal glands* are situated in considerable numbers beneath the mucous membrane of the pharynx, particularly around the posterior nares. Two of these glands, of larger size than the rest, and lobulated in structure, occupy the margin of the opening of the Eustachian tube.

The *Œsophageal glands* are small lobulated bodies, situated in the sub-mucous tissue, and opening upon the surface of the œsophagus by a long excretory duct, which passes obliquely through the mucous membrane.

The *Gastric follicles* are long tubular follicular glands, situated perpendicularly side by side in every part of the mucous membrane of the stomach. At their terminations they are dilated into small lateral pouches, which give them a clustered appearance. This character is more clearly exhibited at the pyloric than at the cardiac end of the stomach. They are intended, very probably, for the secretion of the gastric fluid.

The *Duodenal*, or *Brunner's*\* *glands*, are small flattened granular bodies, compared collectively by Von Brunn to a second pancreas. They resemble in structure the small salivary glands, so abundant beneath the mucous membrane of the mouth and lips; and, like them, they open upon the surface by minute excretory ducts. They are limited to the duodenum.

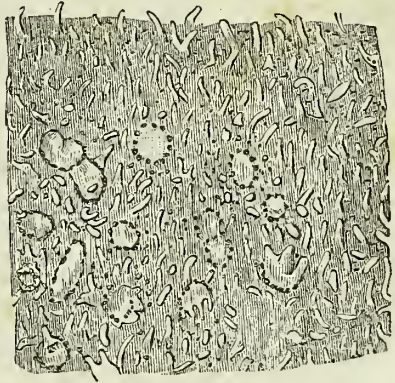
The *Solitary glands* are of two kinds, those of the small and those of the large intestine. The former are small circular patches, surrounded

\* John Conrad von Brunn: "Glandulæ Duodeni seu Pancreas Secundarium," 1715.

by a zone or wreath of simple follicles. When opened, they are seen to consist of a small flattened saccular cavity, containing a mucous secretion, but having no excretory duct. They are chiefly found in the lower part of the ileum. The solitary glands of the large intestine are most abundant in the cæcum and appendix cæci; they are small circular prominences, flattened upon the surface, and perforated in the centre by a minute excretory opening.

The *Aggregate*, or *Peyer's\* glands*, are situated near the lower end of the ileum, and occupy that portion of the intestine which is opposite the attachment of the mesentery. To the naked eye they present the appearance of oval disks, covered with small irregular fissures; but with the aid of the microscope they are seen to be composed of numerous small circular patches, surrounded by simple follicles, like the solitary glands of the small intestine. Each patch corresponds with a flattened and closed sac, situated beneath the membrane, but having no excretory opening, and the interspace between the patches is occupied by flattened villi.

Fig. 224.†



The *Simple follicles*, or follicles of Lieberkühn, are small pouches of the mucous layer, dispersed in immense numbers over every part of the mucous membrane.

**MUSCULAR COAT.**—The muscular coat of the pharynx consists of five pairs of muscles, which have been already described. The muscular coat of the rest of the alimentary canal is composed of two planes of fibres, an external *longitudinal*, and an internal *circular*.

The *Œsophagus* is very muscular; its longitudinal fibres are continuous above with the pharynx, and are attached in front to the vertical ridge on the posterior surface of the cricoid cartilage; the uppermost circular fibres are also attached to the cricoid cartilage. Below, both sets of fibres are continued upon the stomach.

Besides the fibres possessed by the *œsophagus* in common with the rest of the alimentary canal, two special muscles have been described by Hyrtl under the names of *Broncho-œsophageal* and *Pleuro-œsophageal*. The *Broncho-œsophageal* muscle arises as a broad fasciculus from the posterior surface of the left bronchus, and is lost, after a course of two or three inches in length, among the longitudinal fibres of the left side of the *œsophagus*. The *Pleuro-œsophageal* muscle arises from the left wall of the posterior mediastinum behind the commencement of the descending aorta, and curves around that vessel to mingle its fibres with the longitudinal fibres of the *œsophagus*.

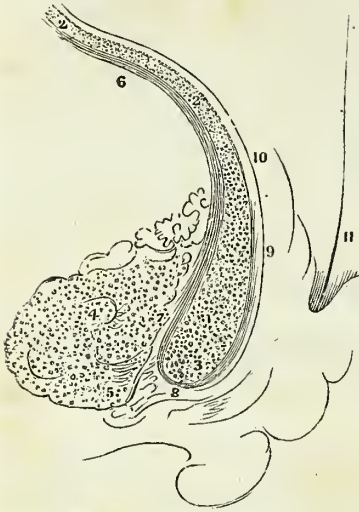
\* John Conrad Peyer, an anatomist of Schaffhausen, in Switzerland. His essay, "De Glandulis Intestinalium," was published in 1677.

† Portion of one of the patches of Peyer's glands from the end of the ileum: highly magnified. The villi are also shown.—(Boehm.)

On the *Stomach* the longitudinal fibres are most apparent along the lesser curve, and the circular at the smaller end. At the pylorus the latter are aggregated into a thick circular ring, which, with the spiral fold of mucous membrane found in this situation, constitutes the *pyloric valve*. At the great end of the stomach a new order of fibres is introduced, having for their object to strengthen and compress that extremity of the organ. They are directed more or less horizontally from the great end towards the lesser end, and are generally lost upon the sides of the stomach at about its middle; these are the oblique fibres.

The *Small intestine* is provided with both layers of fibres, equally distributed over the entire surface. At the termination of the ileum the circular fibres are continued into the two folds of the ileo-cæcal valve, while the longitudinal fibres pass onwards to the large intestine. In the *large intestine* the longitudinal fibres commence at the appendix vermiformis and are collected into three bands, an anterior, broad, and two posterior and narrower bands. These bands are nearly one-half shorter than the intestine, and serve to maintain the sacculated structure which is characteristic of the cæcum and colon. In the *descending colon* the posterior bands usually unite and form a single band. From this point the bands are continued downwards upon the sigmoid flexure to the rectum, around which they spread out and form a thick and very muscular longitudinal layer. The circular fibres in the cæcum and colon are exceedingly thin; in the rectum they are

Fig. 225.\*



thicker, and at its lower extremity they are aggregated into the thick muscular ring which is known as the internal sphincter ani. Between the latter and the mucous membrane are several narrow fasciculi of longitudinal muscular fibres, somewhat more than an inch in length, which have been described by Horner of Philadelphia.

**SEROUS COAT.**—The pharynx and œsophagus have no covering of serous membrane. The alimentary canal within the abdomen has a serous layer, derived from the peritoneum.

\* A vertical section of the parietes of the anus, passing through the middle line of one of the columns of the rectum, and the neighbouring parts. 1. The internal sphincter, with its arched fibres transversely divided. 2, 2. The plane of arched fibres of the muscular coat, similarly divided. 3. The point of greatest contraction of the internal sphincter. 4. The external sphincter. 5. The point of greatest contraction of the same muscle. 6. The plane of longitudinal fibres of the muscular coat, longitudinally divided. 7. Some of these fibres terminating in the internal sphincter. 8. Others, terminating in the external sphincter. 9. The remaining longitudinal fibres, collected into a semitendinous fasciculus, passing over the lower margin of the internal sphincter, to be reverted upward within the duplicature of the column. 10. These reverted fibres again becoming muscular, and terminating in the mucous coat. 11. The mucous coat. 12. A bristle in one of the sacs.—G.

The *Stomach* is completely surrounded by peritoneum, excepting along the line of junction of the great and lesser omentum. The *first* or *oblique portion of the duodenum* is also completely included by the serous membrane, with the exception of the points of attachment of the omenta. The *descending portion* has merely a partial covering on its anterior surface. The *transverse portion* is also behind the peritoneum, being situated between the two layers of the transverse meso-colon, and has but a partial covering. The rest of the *small intestine* is completely invested by it, excepting along the concave border to which the mesentery is attached. The *cæcum* is more or less invested by the peritoneum, the more frequent disposition being that in which the intestine is surrounded for three-fourths only of its circumference. The *ascending* and the *descending colon* are covered by the serous membrane only in front. The *transverse colon* is invested completely, with the exception of the lines of attachment of the greater omentum and transverse meso-colon. And the *sigmoid flexure* is entirely surrounded, with the exception of the part corresponding with the junction of the left meso-colon. The upper third of the rectum is completely enclosed by the peritoneum; the middle third has an anterior covering only, and the inferior third none whatsoever.

*Vessels and Nerves.*—The *Arteries* of the alimentary canal, as they supply the tube from above downwards, are the pterygo-palatine, ascending pharyngeal, superior thyroid, and inferior thyroid, in the neck; œsophageal, in the thorax; gastric, hepatic, splenic, superior and inferior mesenteric, in the abdomen; and inferior mesenteric, iliac, and internal pudic, in the pelvis. The *veins* from the abdominal alimentary canal unite to form the vena portæ. The *lymphatics* and *lacteals* open into the thoracic duct.

The *Nerves* of the pharynx and œsophagus are derived from the glosso-pharyngeal, pneumogastric, and sympathetic. The nerves of the stomach are the pneumogastric, and sympathetic branches from the solar plexus; and those of the intestinal canal are the superior and inferior mesenteric and hypogastric plexuses. The extremity of the rectum is supplied by the inferior sacral nerves from the spinal cord.

#### THE LIVER.

THE liver is a conglomerate gland of large size, appended to the alimentary canal, and performing the double office of separating impurities from the venous blood of the chylo-poietic viscera previously to its return into the general venous circulation, and of secreting a fluid necessary to chylification, the bile. It is the largest organ in the body, weighing about four pounds, and measuring through its longest diameter about twelve inches. It is situated in the right hypochondriac region, and extends across the epigastrium into the left hypochondriac, frequently reaching, by its left extremity, the upper end of the spleen. It is placed obliquely in the abdomen; its convex surface looking upwards and forwards, and the concave downwards and backwards. The anterior border is sharp and free, and marked by a deep notch, and the posterior rounded and broad. It is in relation, superiorly and posteriorly, with the diaphragm; and inferiorly, with the stomach, ascending portion of the duodenum, transverse colon, right supra-renal capsule, and right kidney; and corresponds, by its free border, with the lower margin of the ribs.

*Ligaments.*—The liver is retained in its place by five ligaments; four of which are duplicatures of the peritoneum, and are situated on the convex surface of the organ; the fifth is a fibrous cord which passes through a fissure in its under surface, from the umbilicus to the inferior vena cava: They are the—

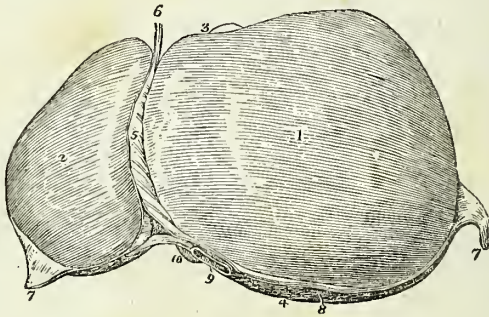
Longitudinal,  
Two lateral,

Coronary,  
Round.

The *Longitudinal ligament* (broad, *ligamentum suspensorium hepatis* is an antero-posterior fold of peritoneum, extending from the notch on the anterior margin of the liver to its posterior border. Between its two layers in the anterior and free margin, is the round ligament.

The *Lateral ligaments* are formed by the two layers of peritoneum, which pass from the under surface of the diaphragm to the posterior border of the liver; they correspond with its lateral lobes.

Fig. 226.\*



The *Coronary ligament* is formed by the separation of the two layers forming the lateral ligaments near their point of convergence. The posterior layer is continued unbroken from one lateral ligament into the other; but the anterior quits the posterior at each side, and is continuous with the corresponding layer of the longitudinal ligament. In this way a large oval surface on the posterior border of the liver is left uncovered by peritoneum, and is connected to the diaphragm by areolo-fibrous tissue. This space is formed principally by the right lateral ligament, and is pierced near its left extremity by the inferior vena cava, previously to the passage of that vessel through the tendinous opening in the diaphragm.

The *Round ligament* is a fibrous cord resulting from the obliteration of the umbilical vein, and situated between the two layers of peritoneum in the anterior border of the longitudinal ligament. It may be traced from the umbilicus, along the longitudinal fissure of the under surface of the liver to the inferior vena cava, to which it is connected.

*Fissures.*—The under surface of the liver is marked by five fissures,

\* The upper surface of the liver. 1. The right lobe. 2. The left lobe. 3. The anterior or free border. 4. The posterior or rounded border. 5. The broad ligament. 6. The round ligament. 7, 7. The two lateral ligaments. 8. The space left uncovered by the peritoneum, and surrounded by the coronary ligament. 9. The inferior vena cava. 10. The point of the lobus Spigelii. 3. The fundus of the gall-bladder seen projecting beyond the anterior border of the right lobe.

which divide its surface into five compartments or lobes, two principal and three minor lobes; they are the—

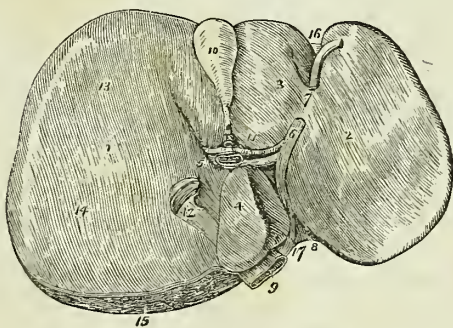
| <i>Fissures.</i>               | <i>Lobes.</i>    |
|--------------------------------|------------------|
| Longitudinal fissure,          | Right lobe,      |
| Fissure of the ductus venosus, | Left lobe,       |
| Transverse fissure,            | Lobus quadratus, |
| Fissure for the gall-bladder,  | Lobus Spigelii,  |
| Fissure for the vena cava.     | Lobus caudatus.  |

The *Longitudinal fissure* is a deep groove running from the notch upon the anterior margin of the liver, to the posterior border of the organ. At about one-third from its posterior extremity it is joined by a short but deep fissure, the transverse, which meets it transversely from the under part of the right lobe.

The longitudinal fissure in front of this junction lodges the fibrous cord of the umbilical vein, and is generally crossed by a band of hepatic substance called the *pons hepatis*.

The *Fissure for the ductus venosus* is the shorter portion of the longitudinal fissure, extending from the junctional termination of the transverse fissure to the posterior border of the liver, and containing a small fibrous cord, the remains of the ductus venosus. This fissure is therefore but a part of the longitudinal fissure.

Fig. 227.\*



The *Transverse fissure* is the short and deep fissure, about two inches in length, through which the hepatic ducts, hepatic artery, and portal vein enter the liver. Hence this fissure was considered by the older anatomists as the gate (*porta*) of the liver; and the large vein entering the organ at

\* The under surface of the liver. 1. The right lobe. 2. The left lobe. 3. The lobus quadratus. 4. The lobus Spigelii. 5. The lobus caudatus. 6. The longitudinal fissure; the numeral is placed on the rounded cord, the remains of the umbilical vein. 7. The *pons hepatis*. 8. The fissure for the ductus venosus; the obliterated cord of the ductus is seen passing backwards to be attached to the coats of the inferior vena cava (9). 10. The gall-bladder lodged in its fossa. 11. The transverse fissure, containing, from before backwards, the hepatic duct, hepatic artery, and portal vein. 12. The vena cava. 13. A depression corresponding with the curve of the colon. 14. A double depression produced by the right kidney and its supra-renal capsule. 15. The rough surface on the posterior border of the liver left uncovered by peritoneum; the cut edge of peritoneum surrounding this surface forms part of the coronary ligament. 16. The notch on the anterior border, separating the two lobes. 17. The notch on the posterior border, corresponding with the vertebral column.

this point, the portal vein. At their entrance into the transverse fissure the branches of the hepatic duct are the most anterior, next those of the artery, and most posteriorly the portal vein.

The *Fissure for the gall-bladder* is a shallow fossa extending forwards, parallel with the longitudinal fissure, from the right extremity of the transverse fissure to the free border of the liver, where it frequently forms a notch.

The *Fissure for the vena cava* is a deep and short fissure, occasionally a circular tunnel, which proceeds from a little behind the right extremity of the transverse fissure to the posterior border of the liver, and lodges the inferior vena cava.

These five fissures taken collectively resemble an inverted  $\nabla$ , the base corresponding with the free margin of the liver, and the apex with its posterior border. Viewing them in this way, the two anterior branches represent the longitudinal fissure on the left, and the fissure for the gall-bladder on the right side; the two posterior, the fissure for the ductus venosus on the left, and the fissure for the vena cava on the right side; and the connecting bar, the transverse fissure.

*Lobes.*—The *Right lobe* is four or six times larger than the left, from which it is separated, on the concave surface, by the longitudinal fissure, and, on the convex, by the longitudinal ligament. It is marked upon its under surface by the transverse fissure, and by the fissures for the gall-bladder and vena cava; and presents three depressions, one, in front, for the curve of the ascending colon, and two, behind, for the right suprarenal capsule and kidney.

The *Left lobe* is small and flattened, convex upon its upper surface, and concave below, where it lies in contact with the anterior surface of the stomach. It is sometimes in contact by its extremity with the upper end of the spleen, and is in relation, by its posterior border, with the cardiac orifice of the stomach and left pneumogastric nerve.

The *Lobus quadratus* is a quadrilateral lobe situated on the under surface of the right lobe; it is bounded, *in front*, by the free border of the liver; *behind*, by the transverse fissure; to the *right*, by the gall-bladder; and to the *left*, by the longitudinal fissure.

The *Lobus Spigelii*\* is a small triangular lobe, also situated on the under surface of the right lobe: it is bounded, *in front*, by the transverse fissure; and, *on the sides*, by the fissures for the ductus venosus and vena cava.

The *Lobus caudatus* is a small tail-like appendage of the lobus Spigelii, from which it runs outwards like a crest into the right lobe, and serves to separate the right extremity of the transverse fissure from the commencement of the fissure for the vena cava. In some persons this lobe is well marked, in others it is small and ill-defined.

Reverting to the comparison of the fissures with an inverted  $\nabla$ , it will be observed, that the quadrilateral interval, in front of the transverse bar, represents the lobus quadratus; the triangular space behind the bar, the lobus Spigelii; and the apex of the letter, the point of union between the inferior vena cava and the remains of the ductus venosus.

*Vessels and Nerves.*—The vessels entering into the structure of the liver are also *five* in number; they are the

\* Adrian Spigel, a Belgian physician, professor at Padua after Casserius in 1616. He assigned considerable importance to this little lobe, but it had been described by Sylvius full sixty years before his time.



Hepatic artery,  
Portal vein,  
Hepatic veins,

Hepatic ducts,  
Lymphatics.

The *Hepatic artery*, *portal vein*, and *hepatic duct* enter the liver at the transverse fissure, and ramify through portal canals to every part of the organ; so that their general direction is from below upwards, and from the centre towards the circumference.

The *Hepatic veins* commence at the circumference, and proceed from before backwards, to open into the vena cava, on the posterior border of the liver. Hence the branches of the two veins cross each other in their course.

The portal vein, hepatic artery, and hepatic duct are moreover enveloped in a loose areolar tissue, the capsule of Glisson, which permits them to contract upon themselves when emptied of their contents; the hepatic veins, on the contrary, are closely adherent by their parietes to the surface of the canals in which they run, and are unable to contract. By these characters the anatomist is enabled, in any section of the liver, to distinguish at once the most minute branch of the portal vein from an hepatic vein: the former will be found more or less collapsed, and always accompanied by an artery and duct, and the latter widely open and solitary.

The *Lymphatics* of the liver are described in the Chapter dedicated to those vessels.

The *Nerves* of the liver are derived from the systems both of animal and organic life; the former proceed from the right phrenic and pneumogastric nerves, and the latter from the hepatic plexus.

#### *Structure and Minute Anatomy of the Liver.*

The *Liver* is composed of *lobules*, of a connecting medium called *Glisson's capsule*, of the ramifications of the *portal vein*, *hepatic duct*, *hepatic artery*, *hepatic veins*, *lymphatics*, and *nerves*, and is enclosed and retained in its situation by the peritoneum.

The *Lobules* are small granular bodies, of about the size of a millet seed, of an irregular form, and presenting a number of rounded promi-

Fig. 228.\*

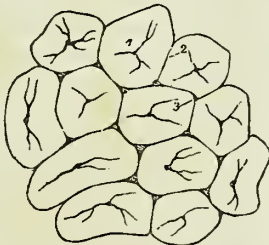
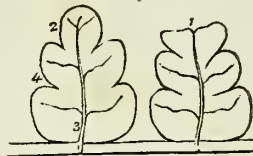


Fig. 229.†



\* The lobules of the liver. The lobules as they are seen upon the surface of the liver, or when divided transversely. 1. The intralobular vein in the centre of each lobule. 2. The interlobular fissure. 3. The interlobular space.

† A longitudinal section of two lobules. 1. A superficial lobule, terminating abruptly, and resembling a section at its extremity. 2. A deep lobule, showing the foliated appearance of its section. 3. The interlobular vein, with its converging venules; the vein terminates in a sublobular vein. 4. The external, or capsular surface of the lobule

nences on their surface. When divided longitudinally, they have a foliated appearance, and transversely, a polygonal outline, with sharp or rounded angles, according to the smaller or greater quantity of Glisson's capsule contained in the liver. Each lobule is divided upon its exterior into a base and a capsular surface. The *base* corresponds with one extremity of the lobule, is flattened, and rests upon an hepatic vein, which is thence named *sublobular*. The *capsular surface* includes the rest of the periphery of the lobule, and has received its designation from being enclosed in an areolar capsule derived from the capsule of Glisson. In the centre of each lobule is a small vein, the *intralobular*, which is formed by the convergence of six or eight minute venules from the rounded prominences of the periphery. The intralobular vein thus constituted takes its course through the centre of the longitudinal axis of the lobule, pierces the middle of its base, and opens into the sublobular vein. The periphery of the lobule, with the exception of its base, which is always closely attached to a sublobular vein, is connected by means of its areolar capsule with the capsular surfaces of surrounding lobules. The interval between the lobules is the *interlobular fissure*, and the angular interstices formed by the apposition of several lobules are the *interlobular spaces*.

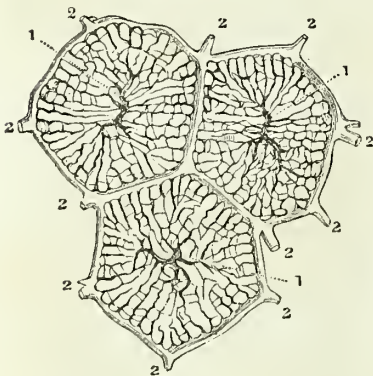
The lobules of the centre of the liver are angular, and somewhat smaller than those of the surface; from the greater compression to which they are submitted. The superficial lobules are incomplete, and give to the surface of the organ the appearance and all the advantages resulting from an examination of a transverse section.

“Each lobule is *composed* of a plexus of biliary ducts, of a venous plexus, formed by branches of the portal vein, of a branch (intralobular), of an hepatic vein, and of minute arteries; nerves and absorbents, it is to be presumed, also enter into their formation, but cannot be traced into them.” “Examined with the microscope, a lobule is apparently composed of numerous minute bodies of a yellowish colour and of various forms, connected with each other by vessels. These minute bodies are the *acini* of Malpighi.”

“If an uninjected lobule be examined and contrasted with an injected lobule, it will be found that the acini of Malpighi in the former are identical with the injected lobular biliary plexus in the latter, and the blood-vessels in both will be easily distinguished from the ducts.”†

*Glisson's capsule* is the areolar fibrous tissue which envelopes the hepatic artery, portal vein, and hepatic duct, during their passage through the right border of the lesser omentum, and which continues to surround them to their ultimate distribution in the substance of the lobules. It forms for

Fig. 230.\*



\* Horizontal section of three superficial lobules, showing the two principal systems of blood-vessels.—(Kiernan.)

† The Anatomy and Physiology of the Liver, by Mr. Kiernan, Phil. Trans. 1833, from which this and the other paragraphs within inverted commas, on the structure of the liver, are quoted

each lobule a distinct capsule, which invests it on all sides with the exception of its base, connects all the lobules together, and constitutes the proper capsule of the entire organ. But Glisson's capsule is not mere areolar tissue; "it is to the liver what the pia mater is to the brain; it is a cellulo-vascular membrane, in which the vessels divide and subdivide to an extreme degree of minuteness; which lines the portal canals, forming sheaths for the larger vessels contained in them, and a web in which the smaller vessels ramify; which enters the interlobular fissures, and with the vessels forms the capsules of the lobules; and which finally enters the lobules, and with the blood-vessels expands itself over the secreting biliary ducts." Hence arises a natural division of the capsule into three portions, a *vaginal*, an *interlobular*, and a *lobular portion*.

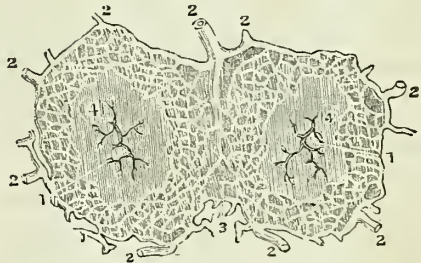
The *vaginal portion* is that which invests the hepatic artery, hepatic duct, and portal vein, in the portal canals; in the larger canals it completely surrounds these vessels, but in the smaller is situated only on that side which is occupied by the artery and duct. The *interlobular portion* occupies the interlobular fissures and spaces, and the *lobular portion* forms the supporting tissue to the substance of the lobules.

The *Portal vein*, entering the liver at the transverse fissure, ramifies through its structure in canals, which resemble, by their surfaces, the external superficies of the liver, and are formed by the capsular surfaces of the lobules. These are the portal canals, and contain, besides the portal vein with its ramifications, the artery and duct with their branches.

In the larger canals, the vessels are separated from the parietes by a web of Glisson's capsule; but, in the smaller, the portal vein is in contact with the surface of the canal for about two-thirds of its cylinder, the opposite third being in relation with the artery and duct and their investing capsule. If, therefore, the portal vein were laid open by a longitudinal incision in one of these smaller canals, the coats being transparent, the outline of the lobules, bounded by their interlobular fissures, would be as distinctly seen as upon the external surface of the liver, and the smaller venous branches would be observed entering the interlobular spaces.

The branches of the portal vein are, the *vaginal*, *interlobular*, and *lobular*. The *vaginal branches* are those which, being given off in the portal canals, have to pass through the sheath (*vagina*) of Glisson's capsule, previously to entering the interlobular spaces. In this course they form an intricate plexus, the *vaginal plexus*, which, depending for its existence on the capsule of Glisson, necessarily surrounds the vessels, as does that capsule in the larger canals, and occupies the capsular side only in the smaller canals. The *interlobular branches* are given off from the *vaginal portal plexus* where it exists, and directly from the portal veins, in that part of the smaller canals where the coats of the vein are in contact with the walls of the canal. They then enter the interlobular

Fig. 231.\*



\* Horizontal section of two superficial lobules, showing interlobular plexus of biliary ducts.—(Kiernan.)

spaces and divide into branches, which cover with their ramifications every part of the surface of the lobules, with the exception of their bases and those extremities of the superficial lobules which appear upon the surfaces of the liver. The interlobular veins communicate freely with each other, and with the corresponding veins of adjoining fissures, and establish a general portal anastomosis throughout the entire liver. The *lobular branches* are derived from the interlobular veins; they form a plexus within each lobule, and converge from the circumference towards the centre, where they terminate in the minute radicles of the intralobular vein. "This plexus, interposed between the interlobular portal veins and the intralobular hepatic vein, constitutes the venous part of the lobule, and may be called the *lobular venous plexus*." The irregular islets of the substance of the lobules, seen between the meshes of this plexus by means of the microscope, are the acini of Malpighi, and are portions of the lobular biliary plexus.

The portal vein returns the venous blood from the chylopoietic viscera, to be circulated through the lobules; it also receives the venous blood which results from the distribution of the hepatic artery.

The *Hepatic duct*, entering the liver at the transverse fissure, divides into branches, which ramify through the portal canals, with the portal vein and hepatic artery, to terminate in the substance of the lobules. Its branches, like those of the portal vein, are vaginal, interlobular, and lobular.

The *Vaginal branches* ramify through the capsule of Glisson, and form a *vaginal biliary plexus*, which, like the vaginal portal plexus, surrounds the vessels in the large canals, but is deficient on that side of the smaller canals near which the duct is placed. The branches given off by the vaginal biliary plexus are interlobular and lobular. The *interlobular branches* proceed from the vaginal biliary plexus where it exists, and directly from the hepatic duct on that side of the smaller canals against which the duct is placed. They enter the interlobular spaces, and ramify upon the capsular surface of the lobules in the interlobular fissures, where they communicate freely with each other. The *lobular ducts* are derived chiefly from the interlobular; but to those lobules forming the walls of the portal canals, they pass directly from the vaginal plexus. They enter the lobule, and form a plexus in its interior, the *lobular biliary plexus*, which constitutes the principal part of the substance of the lobule. The ducts terminate either in loops or in caecal extremities.

The coats of the ducts are very vascular, and are supplied with a number of mucous follicles, which are distributed irregularly in the larger, but are arranged in two parallel longitudinal rows in the smaller ducts.

The *Hepatic artery* enters the liver with the portal vein and hepatic duct, and ramifies with those vessels through the portal canals. Its branches are the vaginal, interlobular, and lobular. The *vaginal branches*, like those of the portal vein and hepatic duct, form a *vaginal plexus*, which exists throughout the whole extent of the portal canals, with the exception of that side of the smaller canals which corresponds with the artery. The *interlobular branches*, arising from the vaginal plexus and from the parietal side of the artery (in the smaller canals), ramify through the interlobular fissures, and are principally distributed to the coats of the interlobular ducts.

"From the superficial interlobular fissures small arteries emerge, and

ramify in the *proper capsule*, on the convex and concave surface of the liver, and in the ligaments. These are the *capsular arteries*." Where the capsule is well developed, "these vessels cover the surfaces of the liver with a beautiful plexus," and "anastomose with branches of the phrenic, internal mammary, and supra-renal arteries," and with the epigastric.

The *Lobular branches*, extremely minute and few in number, are the nutrient vessels of the lobules, and terminate in the lobular venous plexus.

All the venous blood resulting from the distribution of the hepatic artery, even that from the vasa vasorum of the hepatic veins, is returned into the portal vein.

The *Hepatic veins* commence in the substance of each lobule by minute venules, which receive the blood from the lobular venous plexus, and converge to form the intralobular vein. The *intralobular vein* passes through the central axis of the lobule, and through the middle of its base, to terminate in a sublobular vein; and the union of the sublobular veins constitutes the hepatic trunks, which open into the inferior vena cava. The hepatic venous system consists, therefore, of three sets of vessels; intralobular veins, sublobular veins, and hepatic trunks.

The *Sublobular veins* are contained in canals formed solely by the bases of the lobules, with which, from the absence of Glisson's capsule, they are in immediate contact. Their coats are thin and transparent; and, if they be laid open by a longitudinal incision, the bases of the lobules will be distinctly seen, separated by interlobular fissures, and perforated through the centre by the opening of the intralobular vein.

The *Hepatic trunks* are formed by the union of the sublobular veins; they are contained in canals (hepatic-venous) similar in structure to the portal canals, and lined by a prolongation of the proper capsule. They proceed from before backwards, and terminate, by two large openings (corresponding to the right and left lobe of the liver) and several smaller apertures, in the inferior vena cava.

*Summary.*—The liver has been shown to be composed of *lobules*; the lobules (excepting at their bases) are invested and connected together, the vessels supported, and the whole organ enclosed, by *Glisson's capsule*, and they are so arranged, that the base of every lobule in the liver is in contact with an hepatic vein (sublobular).

The *Portal vein* distributes its numberless branches through portal canals, which are channeled through every part of the organ; it brings the returning blood from the chylopoietic viscera; it collects also the venous blood from the ultimate ramifications of the hepatic artery in the liver itself. It gives off branches in the canals, which are called *vaginal*, and form a venous *vaginal plexus*; these give off *interlobular branches*, and the latter enter the lobules and form *lobular venous plexuses*, from the blood circulating in which the bile is secreted.

The *Bile* in the lobule is received by a network of minute ducts, the *lobular biliary plexus*; it is conveyed from the lobule into the *interlobular ducts*; it is thence poured into the biliary *vaginal plexus* of the portal canals, and thence into the excreting ducts, by which it is carried to the duodenum and gall-bladder, after being mingled in its course with the mucous secretion from the numberless muciparous follicles in the walls of the ducts.

The *Hepatic artery* distributes branches through every portal canal;

gives off *vaginal branches* which form a vaginal hepatic plexus, from which the *interlobular branches* arise, and these latter terminate ultimately in the lobular venous plexuses of the portal vein. The artery ramifies abundantly in the coats of the hepatic ducts, enabling them to provide their mucous secretion; and supplies the vasa vasorum of the portal and hepatic veins, and the nutrient vessels of the entire organ.

The *Hepatic veins* commence in the centre of each lobule by minute radicles, which collect the impure blood from the lobular venous plexus and convey it into the *intralobular veins*; these open into the *sublobular veins*, and the sublobular veins unite to form the large hepatic trunks by which the blood is conveyed into the vena cava.

*Physiological and Pathological Deductions.*—The physiological deduction arising out of this anatomical arrangement is, that the *bile is wholly secreted from venous blood*, and not from a mixed venous and arterial blood, as stated by Müller; for although the portal vein receives its blood from two sources, viz. from the chylopoietic viscera and from the capillaries of the hepatic artery, yet the very fact of the blood of the latter vessel having passed through its capillaries into the portal vein, or in extremely small quantity into the capillary network of the lobular venous plexus, is sufficient to establish its venous character.\*

The pathological deductions depend upon the following facts:—Each lobule is a perfect gland; of uniform structure, of uniform colour, and possessing the same degree of vascularity throughout. It is the seat of a double venous circulation, the vessels of the one (*hepatic*) being situated in the centre of the lobule, and those of the other (*portal*) in the circumference. Now the colour of the lobule, as of the entire liver, depends chiefly upon the proportion of blood contained within these two sets of vessels; and so long as the circulation is natural, the colour will be uniform. But the instant that any cause is developed which shall interfere with the free circulation of either, there will be an immediate diversity in the colour of the lobule.

Thus, if there be any impediment to the free circulation of the venous blood through the heart or lungs, the circulation in the hepatic veins will be retarded, and the sublobular and the intralobular veins will become congested, giving rise to a more or less extensive redness in the centre of each of the lobules, while the marginal or non-congested portion presents a distinct border of a yellowish white, yellow, or green colour, according to the quantity and quality of the bile it may contain. "This is '*passive congestion*' of the liver, the usual and natural state of the organ after death;" and, as it commences with the hepatic vein, it may be called the first stage of *hepatic-venous congestion*.

But if the causes which produced this state of congestion continue, or be from the beginning of a more active kind, the congestion will extend through the lobular venous plexuses "into those branches of the portal vein situated in the *interlobular fissures*, but not to those in the *spaces*, which being larger, and giving origin to those in the fissures, are the last to be congested." In this second stage the liver has a mottled appearance, the non-congested substance is arranged in isolated, circular, and ramose patches, in the centres of which the spaces and parts of the fissures are seen. This is an extended degree of *hepatic-venous congestion*; it is

\* For arguments on this contested question, see the article "Liver," in the "Cyclo pædia of Anatomy and Physiology," edited by Dr. Todd.

“*active congestion*” of the liver, and very commonly attends disease of the heart and lungs.

These are instances of *partial congestion*, but there is sometimes *general congestion* of the organ. “In general congestion the whole liver is of a red colour, but the central portions of the lobules are usually of a deeper hue than the marginal portions.”

## GALL-BLADDER.

The Gall-bladder (fig. 166) is the reservoir of the bile; it is a pyriform sac, situated in a fossa on the under surface of the right lobe of the liver, and extending from the right extremity of the transverse fissure to the free margin. It is divided into a body, fundus, and neck: the fundus or broad extremity in the natural position of the liver is placed downwards, and frequently projects beyond the free margin of the liver, while the neck, small and constricted, is directed upwards. This sac is composed of three coats, serous, fibrous, and mucous. The *serous coat* is partial, is derived from the peritoneum, and covers that side only which is unattached to the liver. The *middle* or *fibrous coat* is a thin but strong fibrous layer, connected on one side to the liver, and on the other to the peritoneum. The *internal* or *mucous coat* is but loosely attached to the fibrous layer; it is everywhere raised into minute rugæ, which give it a beautifully reticulated appearance, and forms, at the neck of the sac, a spiral valve. It is continuous through the hepatic duct with the mucous membrane lining all the ducts of the liver, and through the ductus communis choledochus, with the mucous membrane of the alimentary canal.

The *Biliary ducts* are, the ductus communis choledochus, the cystic, and the hepatic duct.

The *Ductus communis choledochus* (χολή bilis, δέχομαι recipio) is the common excretory duct of the liver and gall-bladder; it is about three inches in length, and commences at the papilla situated on the inner side of the cylinder of the perpendicular portion of the duodenum. Passing obliquely between the mucous and muscular coat, it ascends behind the duodenum, and through the right border of the lesser omentum; and divides into two branches, the cystic duct and the hepatic duct. It is constricted at its commencement in the duodenum, and becomes dilated in its progress upwards.

The *Cystic duct*, about an inch in length, passes outwards from the preceding to the neck of the gall-bladder, with which it is continuous.

The *Hepatic duct* continues onwards to the transverse fissure of the liver, and divides into two branches, which ramify through the portal canals to every part of the liver.

The coats of the hepatic ducts are an external or fibrous, and an internal or mucous coat. The *external coat* is composed of a contractile fibrous tissue, which is probably muscular; but its muscularity has not yet been demonstrated in the human subject. The *mucous coat* is continuous on the one hand with the lining membrane of the hepatic ducts and gall bladder, and on the other with that of the duodenum.

*Vessels and Nerves.* — The gall-bladder is supplied with blood by the cystic artery, a branch of the hepatic. Its veins return their blood into the portal vein. The nerves are derived from the hepatic plexus.

## THE PANCREAS.

The pancreas is a long, flattened, conglomerate gland, analogous to the salivary glands. It is about six inches in length, and between three and four ounces in weight; is situated transversely across the posterior wall of the abdomen, behind the stomach, and resting on the aorta, vena portæ, inferior vena cava, the origin of the superior mesenteric artery, and the left kidney and supra-renal capsule; opposite the first and second lumbar vertebræ. It is divided into a body, a greater and a smaller extremity: the great end or head is placed towards the right, and is surrounded by the curve of the duodenum; the lesser end extends to the left as far as the spleen. The anterior surface of the body of the pancreas is covered by the ascending posterior layer of peritoneum, and is in relation with the stomach, the first portion of the duodenum, and the commencement of the transverse arch of the colon. The posterior surface is grooved for the splenic vein, and tunnelled by a complete canal for the superior mesenteric and portal vein, and superior mesenteric artery. The upper border presents a deep groove, sometimes a canal, for the splenic artery and vein, and is in relation with the oblique portion of the duodenum, the lobus Spigelii, and cœliac axis. And the lower border is separated from the transverse portion of the duodenum by the superior mesenteric artery and vein. Upon the posterior part of the head of the pancreas is a lobular fold of the gland which completes the canal of the superior mesenteric vessels, and is called the *lesser pancreas*.

In structure, the pancreas is composed of reddish-yellow polyhedral lobules; these consist of smaller lobules, and the latter are made up of the arborescent ramifications of minute ducts, terminating in cæcal pouches.

The pancreatic duct commences at the papilla on the inner and posterior surface of the perpendicular portion of the duodenum by a small dilatation which is common to it and the ductus communis choledochus, and, passing obliquely between the mucous and muscular coats, runs from right to left through the middle of the gland, lying nearer its anterior than its posterior surface. At about the commencement of the apical third of its course it divides into two parallel terminal branches. The duct gives off numerous small branches, which are distributed through the lobules, and constitute, with the latter, the substance of the gland. The duct which receives the secretion from the lesser pancreas is called the *ductus pancreaticus minor*; it opens in the principal duct near the duodenum, and sometimes passes separately into that intestine. As a variety, two pancreatic ducts are occasionally met with.

*Vessels and Nerves.*—The arteries of the pancreas are branches of the splenic, hepatic, and superior mesenteric; the *veins* open into the splenic vein; the *lymphatics* terminate in the lumbar glands. The *nerves* are filaments of the splenic plexus.

## THE SPLEEN.

The spleen is an oblong flattened organ, of a dark bluish-red colour, situated in the left hypochondriac region. It is variable in size and weight, spongy and vascular in texture, and exceedingly friable. The external surface is convex, the internal slightly concave, indented along the middle line, and pierced by several large and irregular openings for the entrance



and exit of vessels; this is the *hilus lienis*. The upper extremity is somewhat larger than the lower, and rounded; the inferior is flattened: the posterior border is obtuse, the anterior is sharp, and marked by several notches. The spleen is in relation by its external or *convex* surface with the diaphragm, which separates it from the ninth, tenth, and eleventh ribs; by its *concave* surface, with the great end of the stomach, the extremity of the pancreas, the gastro-splenic omentum and its vessels, the left kidney and supra-renal capsule, and the left crus of the diaphragm; by its *upper end* with the diaphragm, and sometimes with the extremity of the left lobe of the liver; and, by its *lower end*, with the left extremity of the transverse arch of the colon. It is connected to the stomach by the gastro-splenic omentum, and by the vessels contained in that duplicature. A second spleen (*lien succenturiatus*) is sometimes found appended to one of the branches of the splenic artery, near the great end of the stomach; when it exists, it is round and of small size, rarely larger than a hazel-nut. I have seen two, and even three, of these bodies. The spleen is invested by the peritoneum and by a *tunica propria* of yellow elastic tissue, which enables it to yield to the greater or less distension of its vessels. The elastic tunic forms sheaths for the vessels in their ramifications through the organ, and from these sheaths small fibrous bands are given off in all directions, which become attached to the internal surface of the elastic tunic, and constitute the areolar framework of the spleen. The substance occupying the interspaces of this tissue is soft, granular, and of a bright red colour; and frequently interspersed with small, white, soft corpuscles (Malpighian bodies). These corpuscles, according to the researches of Oesterlen and Mr. Simon, are aggregations of cyto-blasts enclosed in a kind of capsule of capillary vessels. There are, besides, separate cyto-blasts scattered through the red substance.

*Vessels and Nerves.*—The *Splenic artery* is of very large size in proportion to the bulk of the spleen; it is a division of the *coeliac axis*. The branches which enter the spleen are distributed to distinct sections of the organ, and anastomose very sparingly with each other. The *veins* by their numerous dilatations constitute the principal part of the bulk of the spleen; they pour their blood into the splenic vein, which is one of the two great formative trunks of the portal vein. The *lymphatics* are remarkable for their number and large size; they terminate in the lumbar glands. The *nerves* are, the splenic plexus, derived from the solar plexus.

#### THE SUPRA-RENAL CAPSULES.

The supra-renal capsules are two small yellowish and flattened bodies surmounting the kidneys, and inclining inwards towards the vertebral column. The right is somewhat three-cornered in shape, the left semilunar; they are connected to the kidneys by the common investing areolar tissue, and each capsule is marked on its anterior surface by a fissure which appears to divide it into two lobes. The right supra-renal capsule is closely adherent to the posterior and under surface of the liver, and the left lies in contact with the pancreas. Both capsules rest against the crura of the diaphragm on a level with the tenth dorsal vertebra, and, by their inner border, are in relation with the great splanchnic nerve and semilunar ganglion. They are larger in the *foetus* than in the adult, and appear to

perform some office connected with embryonic life. The anatomy of these organs in the fœtus will be found in the succeeding chapter.

In structure they are composed of two substances, cortical and medullary. The cortical substance is of a yellowish colour, and consists of straight parallel columns placed perpendicularly side by side. The medullary substance is generally of a dark brown colour, double the quantity of the yellow substance, soft and spongy in texture, and contains within its centre the trunk of a large vein, the vena supra-renal. It is the large size of this vein that gives to the fresh supra-renal capsule the appearance of a central cavity: the dark-coloured pulpy or fluid contents of the capsule, at a certain period after death, are produced by softening of the medullary substance. Dr. Nagel\* has shown, by his injections and microscopic examinations, that the appearance of columns in the cortical substance is caused by the direction of a plexus of capillary vessels. Of the numerous minute arteries, supplying the supra-renal capsule, he says, the greater number enter the cortical substance at every point of its surface, and, after proceeding for scarcely half a line, divide into a plexus of straight capillary vessels. Some few of the small arteries traverse the cortical layer, and give off, in the medullary substance, several branches which proceed in different directions, and re-enter the cortical layer to divide into a capillary plexus in a similar manner with the first described. From the capillary plexus, composing the cortical layer, the blood is received by numerous small veins which form a venous plexus in the medullary substance, and terminate at acute angles in the large central vein.

According to the more recent researches of Oesterlen and Mr. Simon, the appearance of columns is due to groups of small corpuscles or cyto-blasts associated with elementary granules and fat-cells collected together in the form of parallel cylinders or cones, each group being enclosed in a tube of delicate membrane (limitary membrane). The medullary substance and intercolumnar spaces contain cyto-blasts uniformly scattered and interspersed with granules and fat-cells. Oesterlen found also, occasionally, in the medullary substance elongated spaces, without lining membrane, containing a thick greyish-white fluid.

*Vessels and Nerves.*—The supra-renal arteries are derived from the aorta, from the renal, and from the phrenic arteries; they are remarkable for the innumerable minute twigs into which they divide previously to entering the capsule. The *supra-renal vein* collecting the blood from the medullary venous plexus, and receiving several branches which pierce the cortical layer, opens directly into the vena cava on the right side, and into the renal vein on the left.

The *Lymphatics* are large and very numerous; they terminate in the lumbar glands. The *nerves* are derived from the renal and from the phrenic plexus.

#### THE KIDNEYS.

The kidneys, the secreting organs of the urine, are situated in the lumbar regions, behind the peritoneum, and on each side of the vertebral column, which latter they approach by their upper extremities. Each kidney is between four and five inches in length, about two inches and a half in breadth, somewhat more than one inch in thickness, and weighs between three and five ounces. The kidneys are usually enclosed in a

\* Müller's Archiv. 1826.

quantity of fat; they rest on the diaphragm, on the anterior lamella of the transversalis muscle, which separates them from the quadratus lumborum, and on the psoas magnus. The *right kidney* is somewhat lower than the left, from the position of the liver; it is in relation, by its anterior surface, with the liver and descending portion of the duodenum, which rest against it; and it is covered in by the ascending colon and by its flexure. The *left kidney*, higher than the right, is covered, in front, by the great end of the stomach, by the spleen, descending colon with its flexure, and by a portion of the small intestines. The anterior surface of the kidney is convex, while the posterior is flat; the superior extremity is in relation with the supra-renal capsule; the convex border is turned outwards towards the parietes of the abdomen; the concave border looks inwards towards the vertebral column, and is excavated by a deep fissure, the *hilus renalis*, in which are situated the vessels and nerves and pelvis of the kidney; the renal vein being the most anterior, next the renal artery, and lastly the pelvis.

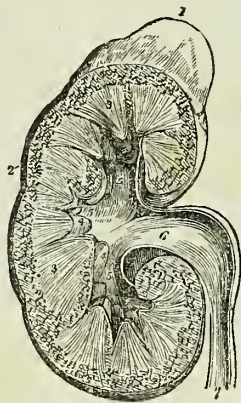
The kidney is dense and fragile in texture, and is invested by a proper fibrous capsule, which is easily torn from its surface. When divided by a longitudinal incision, carried from the convex to the concave border, it is found to present in its interior two structures, an external or vascular (cortical), and an internal or tubular (medullary) substance. The *tubular portion* is formed of pale reddish-coloured conical masses, corresponding by their bases with the vascular structure, and by their apices with the hilus of the organ; these bodies are named cones (pyramids of Malpighi), and are from eight to fifteen in number. The *vascular portion* is composed of blood-vessels and of the plexiform convolutions of uriferous tubuli, and not only constitutes the surface of the kidney, but dips between the cones and surrounds them nearly to their apices.

The cones or pyramids of the tubular portion of the kidney are composed of minute straight tubuli uriniferi, of about the diameter of a fine hair. The tubuli commence at the apices of the cones, and pursue a parallel course towards the periphery of the organ, bifurcating from point to point, and separated only by minute straight blood-vessels, and a small quantity of parenchymatous substance. At the bases of the pyramids the tubuli collect into smaller conical fasciculi, which are prolonged into the substance of the cortical portion of the kidney, and have interposed between them processes of the vascular structure. In the smaller pyramids the fasciculi separate into their component tubules, which, after a course marked by "tortuosities, plexuses, convolutions, and dilatations," terminate, according to Mr. Bowman,† in small round bodies, the corpora

\* A section of the kidney, surmounted by the supra-renal capsule; the swellings on the surface mark the original constitution of the organ of distinct lobes. 1. The supra-renal capsule. 2. The vascular portion of the kidney. 3, 3. Its tubular portion, consisting of cones. 4, 4. Two of the papillæ projecting into their corresponding calices. 5, 5, 5. The three infundibula; the middle 5 is situated in the mouth of a calyx. 6. The pelvis. 7. The ureter.

† On the Structure and Use of the Malpighian Bodies of the Kidney. Philosophical Transactions, 1842.

Fig. 232.\*



Malpighiana, or, according to Krause and the recent investigations of Mr. Toynbee,\* by anastomoses and cæcal extremities. The average diameter of the tubuli uriniferi in the cortical portion of the kidney is the  $\frac{1}{480}$  of an inch, of which about two-thirds are occupied by a nucleated epithelium, the remaining third representing the area of the tube. According to Mr. Bowman, the epithelium is ciliated in that part of the tubule which is near the Malpighian body, and which, according to the same authority, is very much constricted.

In the cortical portion of the kidney are contained a multitude of minute, red, globular bodies, the corpora Malpighiana, or glomeruli. Each Malpighian body, about  $\frac{1}{100}$  of an inch in diameter, is composed of a plexus of capillary vessels, and, in addition, according to Mr. Toynbee, of a coil of an uriniferous tubule; the tuft of capillaries and the coil of the tubule both being enclosed in a thin, membranous capsule. According to Mr. Bowman, the capsule of the Malpighian body is the origin of the uriniferous tubule expanded into a globular form for the reception of the capillary tuft. The capillary vessels of the vascular tuft are arranged in loops closely packed together, and surrounded by an epithelium which is continuous with a similar structure lining the inner surface of the capsule. They are derived from a small artery, which, after piercing the capsule, immediately divides in a radiated manner into several branches. From the interior of this little vascular ball a vein proceeds, smaller than the corresponding artery, and pierces the capsule close by the artery, to communicate with the efferent vessels of other Malpighian bodies and constitute a venous plexus.

The cones or mamillary processes of the interior of the kidney are invested by mucous membrane, which is continuous at their apices with the uriniferous tubuli, and is reflected from their sides so as to form around each a cup-like pouch, or *calyx*. The calices communicate with a common cavity of larger size, situated at each extremity, and in the middle of the organ; and these three cavities, the *infundibula*, constitute by their union the large membranous sac, which occupies the hilus renalis, the *pelvis* of the kidney.

The kidney in the embryo and fœtus consists of lobules. See the anatomy of the fœtus in the succeeding Chapter.

The *Ureter*, ( $\alpha\tilde{\nu}\rho\omega\nu$ , urine,  $\tau\acute{\eta}\rho\epsilon\iota\nu$ , to keep,) the excretory duct of the kidney, is a membranous tube of about the diameter of a goose-quill, and nearly eighteen inches in length; it is continuous superiorly with the pelvis of the kidney, and is constricted inferiorly, where it lies in an oblique direction between the muscular and mucous coats of the base of the bladder, and opens upon its mucous surface. Lying along the posterior wall of the abdomen, it is situated behind the peritoneum, and is crossed by the spermatic vessels; in its course downwards it rests against the anterior surface of the psoas, and crosses the common iliac artery and vein, and then the external iliac vessels. Within the pelvis it crosses the umbilical artery and the vas deferens in the male, and the upper part of the vagina in the female. There are sometimes two ureters to one kidney. The ureter, the pelvis, the infundibula, and the calices are composed of two coats, an external or fibrous coat, the tunica propria; and an internal mucous coat, which is continuous with the mucous membrane of the

\* On the intimate Structure of the Human Kidney, &c. Medico-Chirurgical Transactions, vol. xxix., 1846.

bladder inferiorly, and with that of the tubuli uriniferi above.

*Vessels and Nerves.*—The renal artery is derived from the aorta; it divides into several large branches before entering the hilus, and within the organ ramifies in an arborescent manner, terminating in nutrient twigs, and in the small inferent vessels of the corpora Malpighiana. In the Malpighian bodies the inferent vessels divide into several primary twigs, which subdivide into capillaries, and the capillaries, after forming loops, converge to the efferent vein, which is generally smaller than the corresponding artery. The efferent veins proceed to and form a capillary venous plexus, which surrounds the tortuous tubuli uriniferi, and from this venous plexus the blood is conveyed, by converging branches, into the renal vein.

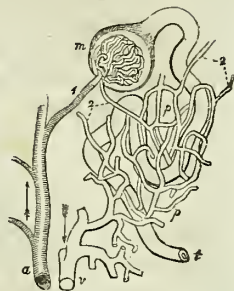


Fig. 233.\*

“Thus,” remarks Mr. Bowman, “there are in the kidney two perfectly distinct systems of capillary vessels, through both of which the blood passes in its course from the arteries into the veins: the first, that” which forms the vascular tuft in the Malpighian bodies, and is “in immediate connexion with the arteries; the second, that enveloping the convolutions of the tubes and communicating directly with the veins. The efferent vessels of the Malpighian bodies, that carry the blood between these two systems, may collectively be termed the portal system of the kidney.” The inferences drawn by Mr. Bowman from his investigations are interesting; they are, that the capillary tufts of the Malpighian bodies are the part of the kidney specially acted on by diuretics; that they are the medium by which water, certain salts, and other substances, pass out of the system; that they are, moreover, the means of escape of certain morbid products, such as sugar, albumen, and the red particles of the blood. Respecting the capillary venous plexus, we have proof that the principal proximate constituents of urine, such as urea, lithic acid, &c., are, like the bile, derived from venous (portal) blood.

The *Veins* of the kidney commence at the surface by minute converging venules, the *stellated vessels*, and proceed inwards, receiving in their course the veins of the cortical and tubular portions of the organ. On arriving at the pelvis, they unite to form the branches of the renal vein, which terminates in the vena cava by a single large trunk on each side; the left renal vein receiving the left spermatic vein. Injections thrown into the renal artery, and returning by the tubuli uriniferi, make their way into those tubes by rupture. The *lymphatic vessels* terminate in the lumbar glands.

The *Nerves* are derived from the renal plexus, which is formed partly by the solar plexus, and partly by the lesser splanchnic nerve. The renal plexus gives branches to the spermatic plexus, and branches which accom-

\* Plan of the renal circulation; copied from Mr. Bowman's paper. *a*. A branch of the renal artery giving off several Malpighian twigs. 1. An efferent twig to the capillary tuft contained in the Malpighian body, *m*; from the Malpighian body the uriniferous tube is seen taking its tortuous course to *t*. 2, 2. Efferent veins; that which proceeds from the Malpighian body is seen to be smaller than the corresponding artery. *v*, *p*. The capillary venous plexus, ramifying upon the uriniferous tube. This plexus receives its blood from the efferent veins, 2, 2, and transmits it to the branch of the renal vein, *v*.

pany the ureters: hence the morbid sympathies which exist between the kidney, the ureter, and the testicle: and by the communications with the solar plexus, with the stomach and diaphragm, and indeed with the whole system. In the intimate structure of the kidney, the nerve-fibres are, according to Mr. Toynbee, continuous with the nucleated cells of the parenchyma of that organ.

#### PELVIS.

The cavity of the pelvis is that portion of the great abdominal cavity which is included within the bones of the pelvis, below the level of the linea-ilio-pectinea and the promontory of the sacrum. It is bounded by the cavity of the abdomen above, and by the perineum below; its internal parietes are formed, in front, below, and at the sides, by the peritoneum, pelvic fascia, levatores ani muscles, obturator fasciæ, and muscles; and behind, by the sacrum and sacral plexus of nerves.

The *Viscera of the pelvis* in the male are, the urinary bladder, the prostate gland, vesiculæ seminales, and the rectum.

#### BLADDER.

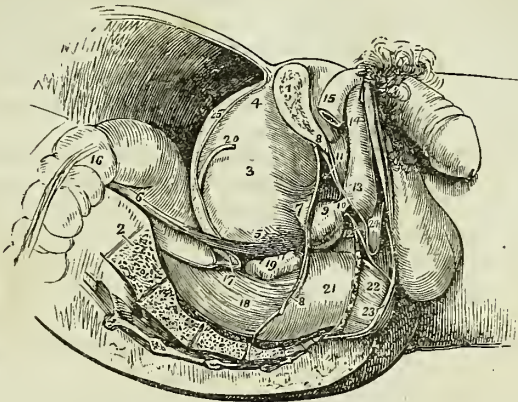
The *Bladder* is an oblong membranous viscus of an ovoid shape, situated behind the ossa pubis and in front of the rectum. It is larger in its vertical diameter than from side to side; and its long axis is directed from above, obliquely downwards and backwards. It is divided into, body, fundus, base, and neck. The *body* comprehends the middle zone of the organ; the *fundus*, its upper segment; the *base*, the lower broad extremity which rests on the rectum; and the *neck*, the narrow constricted portion which is applied against the prostate gland.

This organ is retained in its place by ligaments, which are divided into true and false; the true ligaments are seven in number, two anterior, two lateral, two umbilical, and the urachus; the false ligaments are folds of the peritoneum, and are four in number, two anterior and two posterior. The *anterior ligaments* are formed by the pelvic fascia, which passes from the inner surface of the os pubis, on each side of the symphysis, to the front of the bladder. The *lateral ligaments* are formed by the reflexion of the pelvic fascia from the levatores ani muscles, upon the sides of the base of the bladder. The *umbilical ligaments* are the fibrous cords, which result from the obliteration of the umbilical arteries of the fœtus; they pass forwards on each side of the fundus of the bladder, and ascend beneath the peritoneum to the umbilicus. The *urachus* is a small fibrous cord formed by the obliteration of a tubular canal existing in the embryo: it is attached to the apex of the bladder, and thence ascends to the umbilicus. The *false ligaments* are folds of peritoneum; the two lateral correspond with the passage of the vasa deferentia from the sides of the bladder to the internal abdominal rings, and the two posterior with the course of the umbilical arteries, to the fundus of the organ.

The bladder is composed of three coats, an external or serous coat, a muscular, and a mucous coat. The *serous coat* is partial, and derived from the peritoneum, which invests the posterior surface and sides of the bladder, from about opposite the point of termination of the two ureters

to its summit, whence it is guided to the anterior wall of the abdomen by the umbilical ligaments and urachus. The *muscular coat* consists of two

Fig. 234.\*



layers, an external layer composed of longitudinal fibres, the *detrusor urinæ*; and an internal layer of oblique and transverse fibres irregularly distributed. The anterior longitudinal fibres commence by four tendons (the tendons of the bladder or of the *detrusor urinæ*), two superior from the *ossa pubis*, and two inferior from the rami of the *ischia*, and spread out as they ascend upon the anterior surface of the bladder to its fundus; they then converge upon the posterior surface of the organ, and descend to its neck, where they are inserted into the isthmus of the prostate gland, and into a ring of muscular tissue, which surrounds the commencement of the prostatic portion of the urethra. Some of the anterior fibres are also attached to this ring. The lateral fibres commence at the prostate gland and the muscular ring of the urethra on one side, and spread out as they ascend upon the side of the bladder to descend upon the opposite side, and be inserted into the prostate and opposite segment of the same ring. Two bands of oblique fibres are described by Sir Charles Bell, as

\* A side view of the viscera of the male pelvis, in situ. The right side of the pelvis has been removed by a vertical section made through the *os pubis* near the symphysis; and another through the middle of the sacrum. 1. The divided surface of the *os pubis*. 2. The divided surface of the sacrum. 3. The body of the bladder. 4. Its fundus; from the apex is seen passing upwards the *urachus*. 5. The base of the bladder. 6. The ureter. 7. The neck of the bladder. 8, 8. The pelvic fascia; the fibres immediately above 7 are given off from the pelvic fascia, and represent the anterior ligaments of the bladder. 9. The prostate gland. 10. The membranous portion of the urethra, between the two layers of the deep perineal fascia. 11. The deep perineal fascia formed of two layers. 12. One of Cowper's glands between the two layers of deep perineal fascia, and beneath the membranous portion of the urethra. 13. The bulb of the *corpus spongiosum*. 14. The body of the *corpus spongiosum*. 15. The right *crus penis*. 16. The upper part of the first portion of the rectum. 17. The recto-vesical fold of peritoneum. 18. The second portion of the rectum. 19. The right *vesicula seminalis*. 20. The *vas deferens*. 21. The rectum covered by the descending layer of the pelvic fascia, just as it is making its bend backwards to constitute the third portion. 22. A part of the *levator ani* muscle investing the lower part of the rectum. 23. The external sphincter ani. 24. The interval between the deep and superficial perineal fascia: they are seen to be continuous beneath the number.

originating at the terminations of the ureters, and converging to the neck of the bladder: the existence of these muscles is not well established. The fibres corresponding with the trigonum vesicæ are transverse.

It has been shown by Mr. Guthrie,\* that there are no fibres at the neck of the bladder capable of forming a sphincter vesicæ; but Mr. Lane† has described a fasciculus of muscular fibres which surround the commencement of the urethra, and perform such an office. These fibres form a narrow bundle above the urethra, but spread out below behind the prostate gland: they are brought into view by dissecting off the mucous membrane from around the orifice of the urethra.

Sir Astley Cooper has described around the urethra, within the prostate gland, a ring of elastic tissue, or, rather, according to Mr. Lane, of muscular fibres, which has for its object the closure of the urethra against the involuntary passage of the urine. It is into this ring that the longitudinal fibres of the detrusor urinæ are inserted, so that the muscle, taking a fixed point at the os pubis, will not only compress the bladder, and thereby tend to force its contents along the urethra, but will at the same time, by means of its attachment to the ring, dilate the entrance of the urethra, and afford a free egress to the contents of the bladder.

The *Mucous coat* is thin and smooth, and exactly moulded upon the muscular coat, to which it is connected by a somewhat thick layer of submucous tissue, called by some anatomists the nervous coat; its papillæ are very minute, and there is scarcely a trace of mucous follicles. This mucous membrane is continuous, through the ureters, with the lining membrane of the uriniferous ducts, and, through the urethra, with that of the prostatic ducts, tubuli seminiferi, and Cowper's glands.

Upon the internal surface of the base of the bladder is a triangular smooth plane of a paler colour than the rest of the mucous membrane, the trigonum vesicæ, or *trigone vesicale*, (fig. 237.) This is the most sensitive part of the bladder, and the pressure of calculi upon it gives rise to great suffering. It is bounded on each side by the raised ridge, corresponding with the muscles of the ureters, at each posterior angle by the openings of the ureters, and, in front, by a slight elevation of the mucous membrane at the entrance of the urethra, called *wvula vesicæ*.

The external surface of the base of the bladder corresponding with the trigonum, is also triangular, and is separated from the rectum merely by a thin layer of fibrous membrane, the recto-vesical fascia. It is bounded behind by the recto-vesical fold of peritoneum; and on each side by the vas deferens and vesicula seminalis, which converge almost to a point at the base of the prostate gland. It is through this space that the opening is made in the recto-vesical operation for puncture of the bladder.

#### PROSTATE GLAND.

The prostate gland (πρῶσιςτημι præponere) is situated in front of the neck of the bladder, behind the deep perineal fascia, and upon the rectum, through which latter it may be felt with the finger. It surrounds the commencement of the urethra for a little more than an inch of its extent, and resembles a Spanish chestnut both in size and form; the base being directed backwards towards the neck of the bladder, the apex forwards,

\* "On the Anatomy and Diseases of the Neck of the Bladder and of the Urethra."

† *Lancet*, vol. i. 1842-43, p. 670.

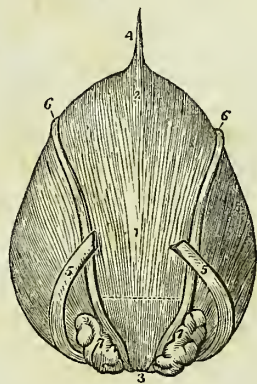


and the convex side towards the rectum. It is retained firmly in its position by the two superior and two inferior tendons of the bladder, by the attachments of the pelvic fascia, and by a process of the internal layer of the deep perineal fascia, which forms a sheath around the membranous urethra, and is inserted into the apex of the gland. It consists of three lobes, two lateral and a middle lobe or isthmus; the lateral lobes are distinguished by an indentation upon the base of the gland, and by a slight furrow upon its upper and lower surface. The third lobe or isthmus is a small transverse band which passes between the two lateral lobes at the base of the organ. In structure the prostate gland is composed of ramified ducts, terminating in lobules of follicular pouches, which are so closely compressed as to give to a thin section of the gland a cellular appearance. It is pale in colour and hard in texture, splits easily in the course of its ducts, and is surrounded by a plexus of veins which are enclosed by the strong fibrous membrane with which it is invested. Its secretion is poured into the prostatic portion of the urethra by fifteen or twenty excretory ducts. The urethra in passing through the prostate lies one-third nearer its upper than its lower surface.

## VESICULÆ SEMINALES.

On the under surface of the base of the bladder, and converging towards the base of the prostate gland, are two lobulated and somewhat pyriform bodies, about two inches in length, the vesiculæ seminales. Their upper surface is in contact with the base of the bladder; the under side rests on the rectum, separated only by the recto-vesical fascia; the larger extremities are directed backwards and outwards, and the smaller ends almost meet at the base of the prostate. They enclose between them a triangular space, which is bounded posteriorly by the recto-vesical fold of peritoneum, and which corresponds with the trigonum vesicæ on the interior of the bladder. Each vesicula is formed by the convolutions of a single tube, which gives off several irregular cæcal branches. It is enclosed in a dense fibrous membrane, derived from the pelvic fascia, and is constricted beneath the isthmus of the prostate gland into a small excretory duct. The vas deferens, somewhat enlarged and convoluted, lies along the inner border of each vesicula, and is included in its fibrous investment. It communicates with the duct of the vesicula, beneath the isthmus of the prostate, and forms† the ejaculatory duct. The ejacula-

Fig. 235.\*



\* The posterior aspect of the male bladder; the serous covering is removed in order to show the muscular coat. 1. The body of the bladder. 2. Its fundus. 3. Its inferior fundus or base. 4. The urachus. 5, 5. The ureters. 6, 6. The vasa deferentia. 7, 7. The vesiculæ seminales. The triangular area, bounded by the vasa deferentia and vesiculæ seminales on either side, a dotted line above and the numeral 3 below, is the space corresponding with the trigonum vesicæ. It is this part of the bladder which is pierced, in puncturing the bladder through the rectum. The dotted line, forming the base of this triangular area, marks the extent of the recto-vesical fold of the peritoneum.

† It has been customary hitherto, in works on anatomy, to describe the course of excretory ducts as proceeding from the gland, and passing thence to the point at which

tory duct is about three quarters of an inch in length, and running forwards, first between the base of the prostate and the isthmus, and then through the tissue of the veru montanum, opens upon the mucous membrane of the urethra, near its fellow of the opposite side, at the anterior extremity of that process.

#### MALE ORGANS OF GENERATION.

The organs of generation in the male are, the penis and the testes, with their appendages.

#### PENIS.

The *Penis* is divisible into a body, root, and extremity. The *body* is surrounded by a thin integument, which is remarkable for the looseness of its areolar connexion with the deeper parts of the organ, and for containing no adipose tissue. The *root* is broad, and firmly adherent to the rami of the ossa pubis and ischia by means of two strong processes, the *crura*, and is connected to the symphysis pubis by a fibrous membrane, the *ligamentum suspensorium*. The *extremity*, or *glans penis*, resembles an obtuse cone, somewhat compressed from above downwards, and of a deeper red colour than the surrounding skin. At its apex is a small vertical slit, the *meatus urinarius*, which is bounded by two, more or less protuberant, labia; and, extending backwards from the meatus, is a depressed raphé, to which is attached a loose fold of mucous membrane, the *frænum præputii*. The base of the glans is marked by a projecting collar, the *corona glandis*, upon which are seen a number of small papillary elevations, the *glandulæ Tysoni* (*odoriferæ*). Behind the corona is a deep fossa, bounded by a circular fold of integument, the *præputium*, which, in the quiescent state of the organ, may be drawn over the glans, but, in its distended state, is obliterated, and serves to facilitate its enlargement. The internal surface of the prepuce is lined by mucous membrane, covered by a thin epithelium; this membrane, on reaching the base of the glans, is reflected over the glans penis, and, at the meatus urinarius, is continuous with the mucous lining of the urethra.

The penis is composed of the corpus cavernosum and corpus spongiosum, and contains in its interior the longest portion of the urethra.

The *Corpus cavernosum* is distinguished into two lateral portions (*corpora cavernosa*) by an imperfect septum and by a superior and inferior groove, and is divided posteriorly into two *crura*. It is firmly adherent, by means of its *crura*, to the rami of the ossa pubis and ischia. It forms, anteriorly, a single rounded extremity, which is received into a fossa in the base of the glans penis; the superior groove lodges the dorsal vessels of the organ, and the inferior receives the corpus spongiosum. Its fibrous tunic is thick, elastic, and extremely firm, and sends a number of fibrous bands and cords (*trabeculæ*) inwards from its inferior groove, which cross its interior in a radiating direction, and are inserted into the inner walls of the tunic. These *trabeculæ* are most abundant on the middle line, where

the secretion is poured out. In the description of the vas deferens, with its connexion with the duct of the vesicula seminalis, I have adopted this plan, that I might not too far depart from established habit. But as it is more correct and consistent with the present state of science to consider the gland as a development of the duct, I have pursued the latter principle in the description of most of the other glandular organs of the body.

they are ranged vertically, side by side, somewhat like the teeth of a comb, and constitute the imperfect partition of the corpus cavernosum, called *septum pectiniforme*. This septum is more complete at its posterior than towards its anterior part.

The tunic of the corpus cavernosum consists of strong longitudinal fibrous fasciculi, closely interwoven with each other. Its internal structure is composed of erectile tissue.

The *Corpus spongiosum* is situated along the under surface of the corpus cavernosum, in its inferior groove. It commences by its posterior extremity between and beneath the crura penis, where it forms a considerable enlargement, the *bulb*, and terminates anteriorly by another expansion, the *glans penis*. Its middle portion, or body, is nearly cylindrical, and tapers gradually from its posterior towards its anterior extremity. The bulb is adherent to the deep perineal fascia by means of the tubular prolongation of the anterior layer, which surrounds the membranous portion of the urethra; in the rest of its extent the corpus spongiosum is attached to the corpus cavernosum by areolar tissue, and by veins which wind around that body to reach the dorsal vein. It is composed of erectile tissue, enclosed by a dense fibrous layer, much thinner than that of the corpus cavernosum, and contains in its interior the spongy portion of the urethra, which lies nearer its upper than its lower wall.

Erectile tissue is a peculiar cellulo-vascular structure, entering in considerable proportion into the composition of the organs of generation. It consists essentially of a plexus of veins so closely convoluted and interwoven with each other, as to give rise to a cellular appearance when examined by means of a section. The veins forming this plexus are smaller in the glans penis, corpus spongiosum, and circumference of the corpus cavernosum, than in the central part of the latter, where they are large and dilated. They have no other coat than the internal lining prolonged from the neighbouring veins; and the interstices of the plexus are occupied by a peculiar reddish fibrous tissue. They receive their blood from the capillaries of the arteries in the same manner with veins generally, and not by means of vessels having a peculiar form and distribution, as described by Müller. The helicine arteries of that physiologist have no existence.

*Vessels and Nerves.*—The arteries of the penis are derived from the internal pudic; they are, the arteries of the bulb, arteries of the corpus cavernosum, and dorsales penis. Its *veins* are superficial and deep. The deep veins run by the side of the deep arteries, and terminate in the internal pudic veins. The superficial veins escape in considerable number from the base of the glans, and converge on the dorsum penis, to form a large dorsal vein, which receives other veins from the corpus cavernosum and spongiosum in its course, and passes backwards between two layers of the ligamentum suspensorium, and through the deep fascia beneath the arch of the os pubis, to terminate in the prostatic and vesical plexuses.

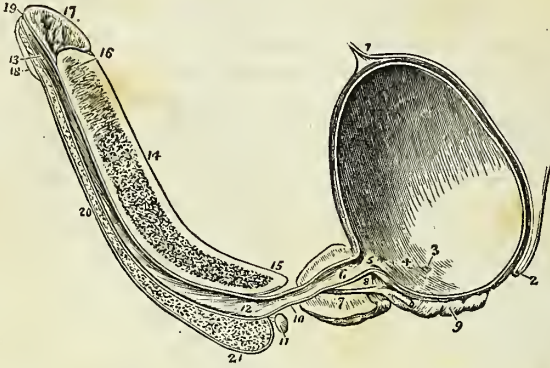
The *Lymphatics* terminate in the inguinal glands. The *Nerves* are derived from the internal pudic nerve, from the sacral plexus, and, as shown by Professor Müller, in his beautiful monograph, from the hypogastric plexus.

#### URETHRA.

The urethra is the membranous canal extending from the neck of the bladder to the meatus urinarius. It is curved in its course, and is com-

posed of two layers, a mucous coat and an elastic fibrous coat. The mucous coat is thin and smooth; it is continuous, internally, with the mucous membrane of the bladder; externally, with the investing membrane of the glans; and at certain points of its extent, with the lining membrane of the numerous ducts which open into the urethra, namely, those of Cowper's

Fig. 236.\*



glands, the prostate gland, vasa deferentia, and vesiculæ seminales. The elastic fibrous coat varies in thickness in the different parts of the course of the urethra: it is thick in the prostate gland, forms a firm investment for the membranous portion of the canal, and is thin in the spongy portion, where it serves as a bond of connexion between the mucous membrane and the corpus spongiosum. The urethra is about nine inches in length, and is divided into a prostatic, membranous, and spongy portion.

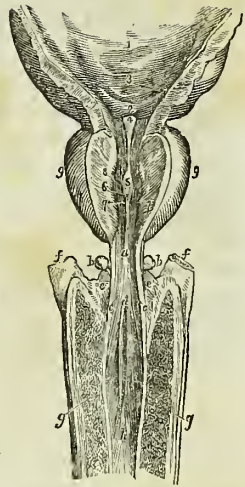
The *Prostatic portion*, a little more than an inch in length, is situated in the prostate gland, about one-third nearer its upper than its lower surface, and extending from its base to its apex. Upon its lower circum-

\* A longitudinal section of the bladder, prostate gland, and penis, showing the urethra.

1. The urachus attached to the upper part of the fundus of the bladder. 2. The rectovesical fold of peritoneum, at its point of reflexion from the base of the bladder, upon the anterior surface of the rectum. 3. The opening of the right ureter. 4. A slight ridge, formed by the muscle of the ureter, and extending from the termination of the ureter to the commencement of the urethra. This ridge forms the lateral boundary of the trigonum vesicæ. 5. The commencement of the urethra; the elevation of mucous membrane immediately below the number is the uvula vesicæ. The constriction of the bladder at this point is the neck of the bladder. 6. The prostatic portion of the urethra. 7. The prostate gland; the difference of thickness of the gland, above and below the urethra, is shown. 8. The isthmus, or third lobe of the prostate; immediately beneath which the ejaculatory duct is seen passing. 9. The right vesicula seminalis; the vas deferens is seen to be cut short off, close to its junction with the ejaculatory duct. 10. The membranous portion of the urethra. 11. Cowper's gland of the right side, with its duct. 12. The bulbous portion of the urethra; throughout the whole length of the urethra of the corpus spongiosum, numerous lacunæ are seen. 13. The fossa navicularis. 14. The corpus cavernosum, cut somewhat obliquely to the right side, near its lower part. The character of the venous cellular texture is well shown. 15. The right crus penis. 16. Near the upper part of the corpus cavernosum, the section has fallen a little to the left of the middle line; a portion of the septum pectiniforme is consequently seen. This figure also indicates the thickness of the fibrous investment of the corpus cavernosum, and its abrupt termination at the base of (17) the glans penis. 8. The lower segment of the glans. 19. The meatus urinarius. 20. The corpus spongiosum. 21. The bulb of the corpus spongiosum.

ference or floor is a longitudinal fold of mucous membrane, the *veru montanum*, or *caput gallinæ*, and on each side of the veru, a depressed fossa, the *prostatic sinus*, in which are seen the numerous openings of the prostatic ducts. At the anterior extremity of the veru montanum are the openings of the two ejaculatory ducts, and between them a third opening, which leads backwards into a small cæcal sac, the *sinus peculiaris*. The prostatic portion of the urethra, when distended, is the most dilated part of the canal; but, excepting during the passage of urine, is completely closed by means of a ring of muscular tissue which encircles the urethra as far as the anterior extremity of the veru montanum. In the contracted state of the urethra, the veru montanum acts as a valve, being pressed upwards against the upper wall of the canal; but, during the action of the detrusor muscle of the bladder, the whole ring is expanded by the longitudinal muscular fibres which are inserted into it; and the veru is especially drawn down by two delicate tendons, which have been traced by Mr. Tyrrell from the posterior fibres of the detrusor into the tissue of this process.

Fig. 237.\*



The *Membranous portion*, the narrowest part of the canal, is somewhat less than an inch in length. It is situated between the two layers of the deep perineal fascia, and is surrounded by the fan-like expansions of the upper and lower segments of the compressor urethræ muscle, which meet at the *raphé* along its upper and lower surface. It is continuous posteriorly with the prostatic urethra, and anteriorly with the spongy portion of the canal. Its coverings are, the mucous membrane, elastic fibrous layer, compressor urethræ muscle, and a partial sheath from the deep perineal fascia.

The *Spongy portion* forms the rest of the extent of the canal, and is lodged in the corpus spongiosum from its commencement at the deep perineal fascia to the meatus urinarius. It is narrowest in the body, and becomes dilated at either extremity, posteriorly in the bulb, where it is named the bulbous portion, and anteriorly in the glans penis, where it forms the fossa navicularis. The meatus urinarius is the most constricted part of the canal; so that a catheter, which will enter that opening, may be passed freely through the whole extent of a normal urethra. Opening into the bulbous portion are two small excretory ducts about three-quarters of an inch in length, which may be traced backwards, between the coats of the urethra and the bulb, to the interval between the two layers

\* The bulbous, membranous, and prostatic urethra, with part of the bladder. 1. Part of the urinary bladder; its internal surface. 2. The trigonum vesicæ. 3. The openings of the ureters. 4. The avula vesicæ. 5. The veru montanum. 6. The opening of the sinus peculiaris. 7, 7. The apertures of the ejaculatory ducts. 8, 8. The openings of the prostatic ducts. The numbers 7, 7, and 8, 8, are placed on the cut surface of the supra-urethral portion of the prostate gland. 9, 9. The lateral lobes of the prostate gland. a. The membranous portion of the urethra. b, b. Cowper's glands. c, c. The apertures of the excretory ducts of Cowper's glands. d. The commencement of the bulbous portion of the urethra. e, e. The upper surface of the bulb of the corpus spongiosum. f, f. The crura penis. g, g. The corpus cavernosum. h. The spongy portion of the urethra.

of the deep perineal fascia, where they ramify in two small lobulated and somewhat compressed glands, of about the size of peas. These are Cowper's glands; they are situated immediately beneath the membranous portion of the urethra, and are enclosed by the lower segment of the compressor urethræ muscle, so as to be subject to muscular compression. Upon the whole of the internal surface of the spongy portion of the urethra, particularly along its upper wall, are numerous small openings or lacunæ, which are the apertures of mucous glands situated in the submucous areolar tissue. The openings of these lacunæ are directed forwards, and are liable occasionally to intercept the point of a small catheter in its passage into the bladder. At about an inch and a half from the opening of the meatus, one of these lacunæ is generally found much larger than the rest, and is named the *lacuna magna*. In a preparation of this lacuna, made by Sir Astley Cooper, the extremity of the canal presents several large primary ramifications.

#### TESTES.

The testes are two small glandular organs suspended from the abdomen by the spermatic cords, and enclosed in an external tegumentary covering, the scrotum.

The SCROTUM is distinguished into two lateral halves or hemispheres by a *raphé*, which is continued anteriorly along the under surface of the penis, and posteriorly along the middle line of the perineum to the anus. Of these two lateral portions the left is somewhat longer than the right, and corresponds with the greater length of the spermatic cord on the left side.

The scrotum is composed of two layers, the integument and a proper covering, the dartos; the integument is extremely thin, transparent, and abundant, and beset by a number of hairs which issue obliquely from the skin, and have prominent roots. The dartos is a thin layer of contractile fibrous tissue, intermediate in properties between muscular fibre and elastic tissue; it forms the proper tunic of the scrotum, and sends inwards a distinct septum (*septum scroti*), which divides it into two cavities for the two testes. The dartos is continuous around the base of the scrotum with the common superficial fascia of the abdomen and perineum.

The SPERMATIC CORD is the medium of communication between the testes and the interior of the abdomen; it is composed of arteries, veins, lymphatics, nerves, the excretory duct of the testicle, and investing tunics. It commences at the internal abdominal ring, where the vessels of which it is composed converge, and passes obliquely along the spermatic canal; the cord then escapes at the external abdominal ring, and descends through the scrotum to the posterior border of the testicle. The left cord is somewhat longer than the right, and permits the left testicle to reach a lower level than its fellow.

The *Arteries* of the spermatic cord are, the spermatic artery from the aorta; the deferential artery, accompanying the vas deferens, from the superior vesical; and the cremasteric branch from the epigastric artery. The *spermatic veins* form a plexus, which constitutes the chief bulk of the cord; they are provided with valves at short intervals, and the smaller veins have a peculiar tendril-like arrangement which has obtained for them the name of *vasa pampiniformia*. The *lymphatics* are of large size, and terminate in the lumbar glands. The *nerves* are the spermatic plexus,

which is derived from the aortic and renal plexus, the genital branch of the genito-crural nerve, and the scrotal branch of the ilio-scrotal.

The *Vas deferens*, the excretory duct of the testicle, is situated along the posterior border of the cord, where it may easily be distinguished by the hard and cordy sensation which it communicates to the fingers. Its parietes are very thick and tough, and its canal extremely small, and lined by the mucous membrane continued from the urethra.

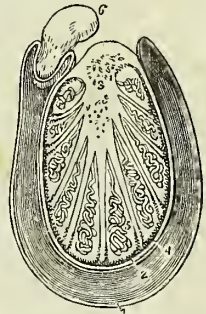
The *Coverings of the spermatic cord* are, the spermatic fascia, cremaster muscle, and fascia propria. The spermatic fascia is a prolongation of the intercolumnar fascia, derived from the borders of the external abdominal ring during the descent of the testicle in the fœtus. The cremasteric covering (erythroid) is the thin muscular expansion formed by the spreading out of the fibres of the cremaster, which is likewise carried down by the testis during its descent. The fascia propria is a continuation of the infundibuliform process from the transversalis fascia, which immediately invests the vessels of the cord, and is also obtained during the descent of the testis.

## TESTES.

The **TESTIS** (testicle) is a small oblong and rounded gland, somewhat compressed upon the sides and behind, and suspended in the cavity of the scrotum by the spermatic cord.

Its position in the scrotum is oblique; so that the upper extremity is directed upwards and forwards, and a little outwards; the lower, downwards and backwards, and a little inwards; the convex border looks forwards and downwards, and the flattened border, to which the cord is attached, backwards and upwards. Lying against its outer and posterior body is a flattened body which follows the course of the testicle, and extends from its upper to its lower extremity; this body is named, from its relation to the testis, *epididymis* (ἐπί, upon, δίδυμος, the testicle); it is divided into a central part or body, an upper extremity or globus major, and a lower extremity, globus minor (cauda) epididymis. The globus major is situated against the upper end of the testicle, to which it is closely adherent; the globus minor is placed at its lower end, is attached to the testis by areolar tissue, and curves upwards, to become continuous with the vas deferens. The testis is invested by three tunics, tunica vaginalis, tunica albuginea, and tunica vasculosa, and is connected to the inner surface of the dartos by a large quantity of extremely loose areolar tissue,

Fig. 238.\*



\* A transverse section of the testicle. 1. The cavity of the tunica vaginalis; the most external layer is the tunica vaginalis reflexa; and that in contact with the organ, the tunica vaginalis propria. 2. The tunica albuginea. 3. The mediastinum testis, giving off numerous fibrous cords in a radiated direction to the internal surface of the tunica albuginea. The cut extremities of the vessels below the number belong to the rete testis; and those above, to the arteries and veins of the organ. 4. The tunica vasculosa, or pia mater testis. 5. One of the lobules, consisting of the convolutions of the tubuli seminiferi, and terminating by a single duct, the vas rectum. Corresponding lobules are seen between the other fibrous cords of the mediastinum. 6. Section of the epididymis.

in which fat is never deposited, but which is very susceptible of serous infiltration.

The *Tunica vaginalis* is a pouch of serous membrane derived from the peritoneum in the descent of the testis, and afterwards obliterated from the abdomen to within a short distance of the gland. Like other serous coverings, it is a shut sac, investing the organ, and thence reflected so as to form a bag around its circumference: hence it is divided, into the *tunica vaginalis propria*, and *tunica vaginalis reflexa*. The *tunica vaginalis propria* covers the surface of the tunica albuginea, and surrounds the epididymis, connecting it to the testis by means of a distinct duplicature. The *tunica vaginalis reflexa* is attached by its external surface, through the medium of a quantity of loose areolar tissue, to the inner surface of the dartos. Between the two layers is the smooth surface of the shut sac, moistened by its proper secretion.

The *Tunica albuginea* (*dura mater testis*) is a thick fibrous membrane, of a bluish white colour, and the proper tunic of the testicle. It is adherent externally to the *tunica vaginalis propria*, and from the union of a serous with a fibrous membrane is considered to be a fibro-serous membrane, like the *dura mater* and pericardium. After surrounding the testicle, the *tunica albuginea* is reflected from its posterior border into the interior of the gland, and forms a projecting longitudinal ridge, which is called the *mediastinum testis* (*corpus Highmorianum\**), from which numerous fibrous cords (*trabeculae*, *septula*) are given off, to be inserted into the inner surface of the tunic. The *mediastinum* serves to contain the vessels and ducts of the testicle in their passage into the substance of the organ, and the fibrous cords are admirably fitted, as has been shown by Sir Astley Cooper, to prevent compression of the gland. If a transverse section be made of the testis, and the surface of the *mediastinum* examined, it will be observed that the blood-vessels of the substance of the organ are situated near the posterior border of the *mediastinum*, while the divided ducts of the *rete testis* occupy a place nearer the free margin.

The *Tunica vasculosa* (*pia mater testis*) is the nutrient membrane of the testis; it is situated immediately within the *tunica albuginea*, and encloses the substance of the gland, sending processes inwards between the lobules, in the same manner that the *pia mater* is reflected between the convolutions of the brain.

The substance of the testis consists of numerous conical flattened *lobules* (*lobuli testis*), the bases being directed towards the surface of the organ, and the apices towards the *mediastinum*. Krause found between four and five hundred of these lobules in a single testis. Each lobule is invested by a distinct sheath, formed of two layers, one being derived from the *tunica vasculosa*, the other from the *tunica albuginea*. The lobule is composed of one or several minute tubuli, *tubuli seminiferi*,† exceedingly convoluted, anastomosing frequently with each other near their extremities, terminating in loops or in free cæcal ends, and of the same diameter ( $\frac{1}{770}$

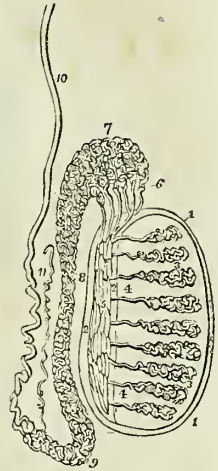
\* Nathaniel Highmore, a physician of Oxford, in his "Corporis Humani Disquisitio Anatomica," published in 1651, considers the *corpus Highmorianum* as a duct formed by the convergence of the fibrous cords, which he mistakes for smaller ducts.

† Lauth estimates the whole number of *tubuli seminiferi* in each testis at 840, and their average length at 2 feet 3 inches. According to this calculation, the whole length of the *tubuli seminiferi* would be 1890 feet.



of an inch, Lauth) throughout. The tubuli seminiferi are of a bright yellow colour; they become less convoluted in the apices of the lobules, and terminate by forming between twenty and thirty small straight ducts of about twice the diameter of the tubuli seminiferi, the *vasa recta*. The vasa recta enter the substance of the mediastinum, and terminate in from seven to thirteen ducts, smaller in diameter than the vasa recta. These ducts pursue a waving course from below upwards through the fibrous tissue of the mediastinum; they communicate freely with each other, and constitute the *rete testis*. At the upper extremity of the mediastinum, the ducts of the rete testis terminate in from nine to thirty small ducts, the *vasa efferentia*,† which form by their convolutions a series of conical masses, the *coni vasculosi*; from the bases of these cones tubes of larger size proceed, which constitute, by their complex convolutions, the body of the epididymis. The tubes become gradually larger towards the lower end of the epididymis, and terminate in a single large and convoluted duct, the vas deferens.

Fig. 239.\*



The *Epididymis* is formed by the convolutions of the excretory seminal ducts, externally to the testis, and previously to their termination in the vas deferens. The more numerous convolutions and the aggregation of the *coni vasculosi* at the upper end of the organ constitute the globus major; the continuation of the convolutions downwards is the body; and the smaller number of convolutions of the single tube at the lower extremity, the globus minor. The tubuli are connected together by a very delicate areolar tissue, and are enclosed by the tunica vaginalis.

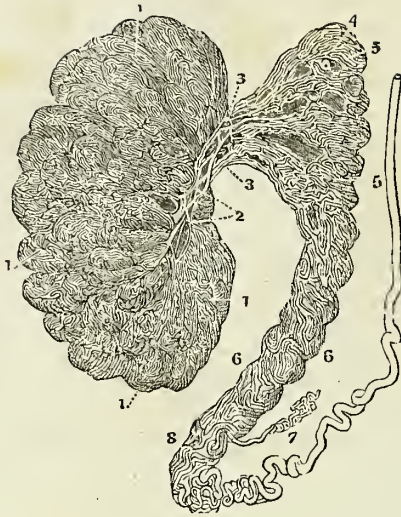A small convoluted duct, of variable length, is generally connected with the duct of the epididymis immediately before the commencement of the vas deferens. This is the vasculum aberrans of Haller; it is attached to the epididymis by the areolar tissue in which that body is enveloped. Sometimes it becomes dilated towards its extremity, but more frequently retains the same diameter throughout.

The *Vas deferens* may be traced upwards in the course of the seminal fluid, from the globus minor of the epididymis along the posterior part of the spermatic cord, and along the spermatic canal to the internal abdominal ring. From the ring it is reflected inwards to the side of the fundus of the bladder, and descends along its posterior surface, crossing the direction of the ureter, to the inner border of the vesicula seminalis. In this situation it becomes somewhat larger in size and convoluted, and terminates at the base of the prostate gland, by uniting with the duct of the vesicula seminalis and constituting the ejaculatory duct. The ejaculatory

\* Anatomy of the testis. 1, 1. The tunica albuginea. 2, 2. The mediastinum testis. 3, 3. The lobuli testis. 4, 4. The vasa recta. 5. The rete testis. 6. The vasa efferentia, of which six only are represented in this diagram. 7. The coni vasculosi constituting the globus major of the epididymis. 8. The body of the epididymis. 9. The globus minor of the epididymis. 10. The vas deferens. 11. The vasculum aberrans.

† Each vas efferens with its cone measures, according to Lauth, about 8 inches. The entire length of the tubes composing the epididymis, according to the same authority, is about 21 feet.

Fig. 240.\*



duct, which is thus formed by the junction of the duct of the vesicula seminalis with the vas deferens, passes forwards to the anterior extremity of the veru montanum, where it terminates by opening into the prostatic urethra.

#### FEMALE PELVIS.

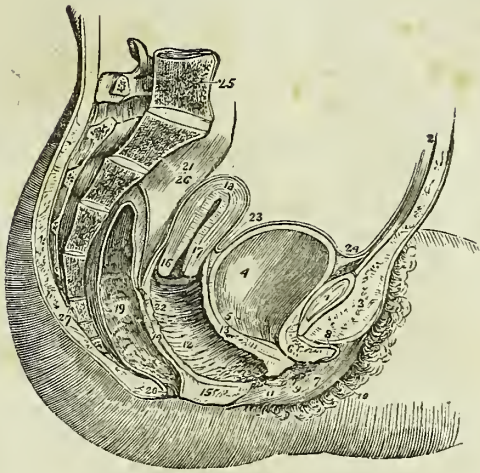
The peculiarities in form of the female pelvis have already been examined with the anatomy of the bones (p. 118). Its lining boundaries are the same with those of the male. The contents are, the bladder, vagina, uterus with its appendages, and the rectum. Some portion of the small intestines also occupies the upper part of its cavity.

The *Bladder* is in relation with the ossa pubis in front, with the uterus behind, from which it is usually separated by a convolution of small intestine, and with the neck of the uterus and vagina beneath. The form of the female bladder corresponds with that of the pelvis, being broad from side to side, and often bulging more on one side than on the other. This is particularly evident after frequent parturition. The *coats* of the bladder are the same as those of the male.

The *Urethra* is about an inch and a half in length, and is lodged in the upper wall of the vagina, in its course downwards and forwards, beneath the arch of the os pubis, to the meatus urinarius. It is lined by mucous membrane, which is disposed in longitudinal folds, and is continuous internally with that of the bladder, and externally with that of the vulva, the mucous membrane is surrounded by a proper coat of elastic tissue, to which the muscular fibres of the detrusor urinæ are attached. It is to the elastic tissue that is due the remarkable dilatibility of the female urethra,

\* Human testis injected with mercury. 1, 1. Lobules formed of seminiferous tubes. 2. Rete testis. 3. Vasa efferentia. 4. Plexuses of the efferent vessels passing into the head of the epididymis. 5, 5. 6. Body of the epididymis. 7. Its appendix; its tail or cauda. 8. Vas deferens.—(Lauth.)

Fig. 241.\*



and its speedy return to its original diameter. The meatus is encircled by a ring of fibrous tissue, which prevents it from distending with the same facility as the rest of the canal; hence it is sometimes advantageous in performing this operation to divide the margin of the meatus slightly with the knife.

## VAGINA.

The *Vagina* is a membranous canal, leading from the vulva to the uterus, and corresponding in direction with the axis of the outlet of the pelvis. It is constricted at its commencement, but near the uterus becomes dilated; and is closed by the contact of the anterior with the posterior wall. Its length is variable; but it is always longer upon the posterior than upon the anterior wall, the former being usually about five or six inches in length, and the latter four or five. It is attached to the cervix of the uterus, which latter projects into the upper extremity of the canal.

In *Structure* the vagina is composed of a *mucous lining*, a layer of *erectile tissue*; and an external tunic of *contractile fibrous tissue*, resembling the dartos of the scrotum. The upper fourth of the posterior wall of the

\* A side view of the viscera of the female pelvis. 1. The symphysis pubis; to the upper part of which the tendon of the rectus muscle is attached. 2. The abdominal parietes. 3. The collection of fat, forming the prominence of the mons Veneris. 4. The urinary bladder. 5. The entrance of the left ureter. 6. The canal of the urethra, converted into a mere fissure by the contraction of its walls. 7. The meatus urinarius. 8. The clitoris, with its præputium, divided through the middle. 9. The left nymphæ. 10. The left labium majus. 11. The meatus of the vagina, narrowed by the contraction of its sphincter. 12. 22. The canal of the vagina, upon which the transverse rugæ are apparent. 13. The thick wall of separation between the base of the bladder and the vagina. 14. The wall of separation between the vagina and rectum. 15. The perineum. 16. The os uteri. 17. Its cervix. 18. The fundus uteri. The cavitas uteri is seen along the centre of the organ. 19. The rectum, showing the disposition of its mucous membrane. 20. The anus. 21. The upper part of the rectum, invested by the peritoneum. 23. The utero-vesical fold of peritoneum. The recto-uterine fold is seen between the rectum and the posterior wall of the vagina. 24. The reflexion of the peritoneum, from the apex of the bladder upon the urachus to the internal surface of the abdominal parietes. 25. The last lumbar vertebra. 26. The sacrum. 27. The coccyx.

vagina is covered, on its pelvic surface, by the peritoneum ; while in front the peritoneum is reflected from the upper part of the cervix of the uterus to the posterior surface of the bladder. On each side it gives attachment, superiorly, to the broad ligaments of the uterus ; and, inferiorly, to the pelvic fascia and levatores ani.

The *Mucous membrane* presents a number of *transverse papillæ* or *rugæ* upon the upper and lower surfaces of the canal, the *rugæ* extending outwards on each side from a middle *raphé*. The transverse papillæ and *raphé* are more apparent upon the upper than upon the lower surface, and the two *raphé* are called the *columns of the vagina*. The mucous membrane is covered by a thin cuticular epithelium, which is continued from the labia, and terminates by a fringed border at about the middle of the cervix uteri.

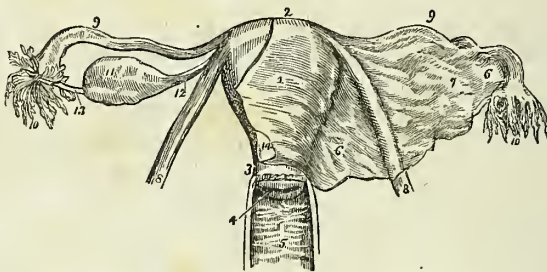
The *Middle* or *erectile layer* consists of erectile tissue enclosed between two layers of fibrous membrane ; this layer is thickest near the commencement of the vagina, and becomes gradually thinner as it approaches the uterus.

The *External*, or *dartoid layer* of the vagina, serves to connect it to the surrounding viscera. Thus, it is very closely adherent to the under surface of the bladder, and drags that organ down with it in prolapsus uteri. To the rectum it is less closely connected, and that intestine is therefore less frequently affected in prolapsus.

#### UTERUS.

The *Uterus* is a flattened organ of a pyriform shape, having the base directed upwards and forwards, and the apex downwards and backwards in the line of the axis of the inlet of the pelvis, and forming a considerable angle with the course of the vagina. It is convex on its posterior surface, and somewhat flattened upon its anterior aspect. In the unimpregnated state it is about three inches in length, two in breadth across its broadest

Fig. 242.\*



\* The uterus with its appendages viewed on their anterior aspect. 1. The body of the uterus. 2. Its fundus. 3. Its cervix. 4. The os uteri. 5. The vagina ; the number is placed on the posterior *raphé* or column, from which the transverse *rugæ* are seen passing off at each side. 6, 6. The broad ligament of the uterus. 7. A convexity of the broad ligament formed by the ovary. 8, 8. The round ligaments of the uterus. 9, 9. The Fallopian tubes. 10, 10. The fimbriated extremities of the Fallopian tubes ; on the left side the mouth of the tube is turned forwards in order to show its ostium abdominale. 11. The ovary. 12. The utero-ovarian ligament. 13. The Fallopian-ovarian ligament, upon which some small fimbriæ are continued for a short distance. 14. The peritoneum of the anterior surface of the uterus. This membrane is removed on the left side, but on the right is continuous with the anterior layer of the broad ligament.

part, and one in thickness, and is divisible into fundus, body, cervix, and os uteri. At the period of puberty the uterus weighs about one ounce and a half; after parturition from two to three ounces; and at the ninth month of utero-gestation from two to four pounds.

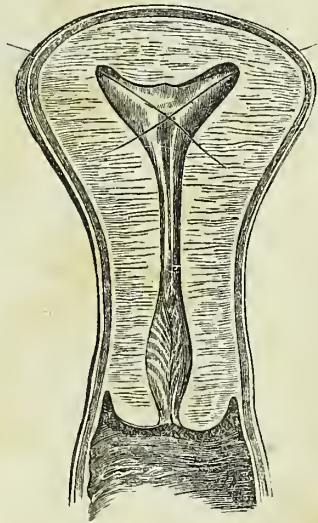
The *Fundus* and *body* are enclosed in a duplicature of peritoneum, which is connected with the sides of the pelvis, and forms a transverse septum between the bladder and rectum. The folds formed by this duplicature of peritoneum on either side of the organ are the *broad ligaments* of the uterus. The *cervix* is the lower portion of the organ; it is distinguished from the body by a well-marked constriction; around its circumference is attached the upper end of the vagina, and at its extremity is an opening which is nearly round in the virgin, and transverse after parturition, the *os uteri*, bounded before and behind by two labia; the anterior labium being the most thick, and the posterior somewhat the longest. The opening of the *os uteri* is of considerable size, and is named the *orificium uteri externum*; the canal then becomes narrowed, and at the upper end of the cervix is constricted into a smaller opening, the *orificium internum*.\* At this point the canal of the cervix expands into the shallow triangular cavity of the uterus, the inferior angle corresponding with the *orificium internum*, and the two superior angles, which are funnel-shaped, and represent the original bicornute condition of the organ, with the commencement of the Fallopian tubes. In the canal of the cervix uteri are two or three longitudinal folds, to which numerous oblique folds converge so as to give the idea of branches from the stem of a tree; hence this appearance has been denominated the *arbor vitæ uterina*. Between these folds, and around the *os uteri*, are numerous mucous follicles. It is the closure of the mouth of one of these follicles, and the subsequent distention of the follicle with its proper secretion, that occasions those vesicular appearances, so often noticed within the mouth and cervix of the uterus, called the *ovula of Naboth*.

*Structure.*—The uterus is composed of three tunics: of an *external* or *serous coat*, derived from the peritoneum, which constitutes the duplicatures on each side of the organ called the broad ligaments; of a *middle* or *muscular coat*, which gives thickness and bulk to the uterus; and of an *internal* or *mucous membrane*, which lines its interior, and is continuous on the one hand with the mucous lining of the Fallopian tubes, and on the other with that of the vagina. In the unimpregnated state the muscular coat is exceedingly condensed in texture, offers resistance to section with the scalpel,

\* The *orificium internum* is not unfrequently obliterated in old persons. Indeed, this obliteration is so common, as to have induced Mayer to regard it as normal.

† Section of the uterus (transverse). The two bristles are introduced into the orifices of the Fallopian tubes.

Fig. 243.†



and appears to be composed of whitish fibres inextricably interlaced and mingled with blood-vessels. In the impregnated uterus the fibres are of large size, and distinct, and are disposed in two layers, superficial and deep. The *superficial layer* consists of fibres which pursue a vertical direction, some being longitudinal, and others oblique. The longitudinal fibres are found principally on the middle line, forming a thin plane upon the anterior and posterior face of the organ and upon its fundus. The oblique fibres occupy chiefly the sides and the fundus. At the angles of the uterus the fibres of the superficial layer are continued outwards upon the Fallopian tubes, and into the round ligaments and ligaments of the ovaries. The *deep layer* consists of two hollow cones of circular fibres having their apex at the openings of the Fallopian tubes, and intermingling with each other by their bases on the body of the organ. These fibres are continuous with the deep muscular layer of the Fallopian tubes, and indicate the primitive formation of the uterus by the blending of these two canals. Around the cervix uteri the muscular fibres assume a circular form interlacing with and crossing each other at acute angles. The *mucous membrane* is provided with a columnar ciliated epithelium, which extends from the middle of the cervix uteri to the extremities of the Fallopian tubes.

*Vessels and Nerves.*—The *Arteries* of the uterus are the uterine from the internal iliac, and the spermatic from the aorta. The *Veins* are large and remarkable; in the impregnated uterus they are called sinuses, and consist of canals channeled through the substance of the organ, being merely lined by the internal membrane of the veins. They terminate on each side of the uterus in the uterine plexuses. The *lymphatics* terminate in the lumbar glands.

The *Nerves* of the uterus are derived from the hypogastric and spermatic plexuses, and from the sacral plexus. They have been made the subject of special investigation by Dr. Robert Lee, who has successfully repaired the omission made by Dr. William Hunter, in this part of the anatomy of the organ. In his numerous dissections of the uterus, both in the unimpregnated and gravid state, Dr. Lee has made the discovery of several large nervous ganglia and plexuses. The principal of these, situated on each side of the cervix uteri, immediately behind the ureter, he terms the *hypogastric ganglion*; it receives the greater number of the nerves from the hypogastric and sacral plexus, and distributes branches to the uterus, vagina, bladder, and rectum. Of the branches to the uterus, a large fasciculus proceeds upwards by the side of the organ towards its angle, where they communicate with branches of the spermatic plexus, and form another large ganglion; which he designates the *spermatic ganglion*, and which supplies the fundus uteri. Besides these, Dr. Lee describes *vesical* and *vaginal ganglia*, and anterior and posterior *subperitoneal ganglia* and *plexuses*, which communicate with the preceding, and constitute an extensive nervous network over the entire uterus. Dr. Lee concludes his observations by remarking:—"These dissections prove that the human uterus possesses a great system of nerves, which enlarges with the coats, blood-vessels, and absorbents, during pregnancy, and which returns after parturition to its original condition before conception takes place. It is chiefly by the influence of these nerves that the uterus performs the varied functions of menstruation, conception, and parturition, and it is solely by their means that the whole fabric of the nervous system sympa-

unises with the different morbid affections of the uterus. If these nerves of the uterus could not be demonstrated, its physiology and pathology would be completely inexplicable.”\*

## APPENDAGES OF THE UTERUS.

The *Appendages of the uterus* are enclosed by the lateral duplicatures of peritoneum, called the broad ligaments. They are the *Fallopian tubes* and *ovaries*.

The FALLOPIAN† TUBES or oviducts, the uterine trumpets of the French writers, are situated in the upper border of the broad ligaments, and are connected with the superior angles of the uterus. They are somewhat trumpet-shaped, being smaller at the uterine than at the free extremity, and narrower in the middle than at either end. Each tube is about four or five inches in length, and more or less flexuous in its course. The canal of the Fallopian tube is exceedingly minute; its inner extremity opens by means of the *ostium uterinum* into the upper angle of the cavity of the uterus, and the opposite end into the cavity of the peritoneum. The free or expanded extremity of the Fallopian tube presents a double and sometimes a triple series of small processes or fringes, which surround the margin of the trumpet or funnel-shaped opening, the *ostium abdominale*. This fringe-like appendage to the end of the tube has gained for it the appellation of the fimbriated extremity; and the remarkable manner in which this circular fringe applies itself to the surface of the ovary during sexual excitement, the additional title of *morsus diaboli*. A short ligamentous cord proceeds from the fimbriated extremity to be attached to the distal end of the ovary, and serves to guide the tube in its seizure of that organ.

The Fallopian tube is composed of three tunics, an external and loose investment derived from the peritoneum; a middle or muscular coat, consisting of circular [internal] and longitudinal [external] fibres, continuous with those of the uterus; and an internal or lining mucous membrane, which is continuous on the one hand with the mucous membrane of the uterus, and at the opposite extremity with the peritoneum. In the minute canal of the tube the mucous membrane is thrown into longitudinal folds or rugæ, which indicate the adaptation of the tube for dilatation.

The OVARIES are two oblong flattened and oval bodies of a whitish colour, situated in the posterior layer of peritoneum of the broad ligaments. They are connected to the upper angles of the uterus at each side by means of a rounded cord, consisting chiefly of muscular fibres derived from the uterus, the *ligament of the ovary*. By the opposite extremity they are connected by another and a shorter ligament to the fimbriated aperture of the Fallopian tube.

In *structure* the ovary is composed of a cellulo-fibrous parenchyma or stroma, traversed by blood-vessels, and enclosed in a capsule consisting of three layers: a vascular layer, which is situated most internally, and sends processes inwards to the interior of the organ; a middle or fibrous layer of considerable density, and an external investment of peritoneum.

\* Philosophical Transactions for 1842.

† Gabriel Fallopius, a nobleman of Modena, was one of the founders of modern anatomy. He was Professor at Ferrara, then at Pisa, and afterwards succeeded Vesalius at Padua. His principal observations are collected in a work, "Observationes Anatomicae," which he published in 1561.

In the cells of the stroma of the ovary the small vesicles or ovisacs of the future ova, the Graafian vesicles, as they have been termed, are developed. There are usually about fifteen fully formed Graafian vesicles in each ovary; and Dr. Martin Barry has shown that countless numbers of microscopic ovisacs exist in the parenchyma of the organ, and that very few out of these are perfected so as to produce ova.

After conception, a yellow spot, the *corpus luteum*, is found in one or both ovaries. The corpus luteum is a globular mass of yellow, spongy tissue, traversed by white areolar bands, and containing in its centre a small cavity, more or less obliterated, which was originally occupied by the ovum. The interior of the cavity is lined by a puckered membrane, the remains of the ovisac. In recent corpora lutea, the opening by which the ovum escaped from the ovisac through the capsule of the ovary is distinctly visible; when closed, a small cicatrix may be seen on the surface of the ovary in the situation of the opening. A similar appearance to the preceding, but of smaller size, and without a central cavity, is sometimes met with in the ovaries of the virgin; this is a *false corpus luteum*.

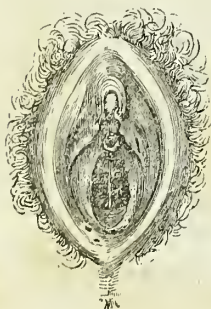*Vessels and Nerves.*—The *Arteries* of the ovaries are the spermatic; their *nerves* are derived from the spermatic plexus.

The **ROUND LIGAMENTS** are two muscular and fibrous cords situated between the layers of the broad ligaments, and extending from the upper angles of the uterus, and along the spermatic canals to the labia majora, in which they are lost. They are accompanied by a small artery, by several filaments of the spermatic plexus of nerves, and by a plexus of veins. The latter occasionally become varicose, and form a small tumour at the external abdominal ring, which has been mistaken for inguinal hernia. The round ligaments serve to retain the uterus in its proper position in the pelvis, and, during utero-gestation, to draw the anterior surface of the organ against the abdominal parietes.

#### EXTERNAL ORGANS OF GENERATION.

The female organs of generation are divisible into the internal and external: the internal are contained within the pelvis, and have been already described; they are the vagina, uterus, ovaries, and Fallopian tubes. The external organs are the mons Veneris, labia majora, labia minora, clitoris, meatus urinarius, and the opening of the vagina.

Fig. 244.



The *Mons Veneris* is the eminence of integument, situated upon the front of the ossa pubis. Its areolar tissue is loaded with adipose substance, and the surface covered with hairs.

The *Labia majora* are two large longitudinal folds of integument, consisting of fat and loose areolar tissue. They enclose an elliptical fissure, the common urino-sexual opening, or *vulva*. The vulva receives the inferior opening of the urethra and vagina, and is bounded anteriorly by the commissura superior, and posteriorly by the commissura inferior. Stretching across the posterior commissure is a small transverse fold, the *frenulum labiorum* or fourchette, which is ruptured during parturition; and immediately within this fold is a small cavity, the *fossa*



*navicularis*. The length of the perineum is measured from the posterior commissure to the margin of the anus, and is usually not more than an inch. The external surface of the labia is covered with hairs; the inner surface is smooth, and lined by mucous membrane, which contains a number of sebiparous follicles, and is covered by a thin cuticular epithelium. The use of the labia majora is to favour the extension of the vulva during parturition; for, in the passage of the head of the fœtus, the labia are unfolded and completely effaced.

The *Labia minora*, or *nymphæ*, are two smaller folds, situated within the labia majora. Superiorly they are divided into two processes, which surround the glans clitoridis, the superior fold forming the præputium clitoridis, and the inferior its frænulum. Inferiorly, they diminish gradually in size, and are lost on the sides of the opening of the vagina. The nymphæ consist of mucous membrane, covered by a thin cuticular epithelium. They are provided with a number of sebiparous follicles, and contain, in their interior, a layer of erectile tissue.

The *Clitoris* is a small elongated organ situated in front of the ossa pubis, and supported by a suspensory ligament. It is formed by a small body, which is analogous to the corpus cavernosum of the penis, and, like it, arises from the ramus of the os pubis and ischium on each side, by two *crura*. The extremity of the clitoris is called its *glans*. It is composed of erectile tissue, enclosed in a dense layer of fibrous membrane, and is susceptible of erection. Like the penis, it is provided with two small muscles, the *erectores clitoridis*.

At about an inch behind the clitoris is the *entrance of the vagina*, an elliptical opening, marked by a prominent margin. The entrance to the vagina is closed in the virgin by a membrane of a semilunar form, which is stretched across the opening; this is the *hymen*. Sometimes the membrane forms a complete septum, and gives rise to great inconvenience by preventing the escape of the menstrual effusion. It is then called an *imperforate hymen*. The *hymen* must not be considered a necessary accompaniment of virginity, for its existence is very uncertain. When present, it assumes a variety of appearances: it may be a membranous fringe, with a round opening in the centre, or a semilunar fold, leaving an opening in front; or a transverse septum, having an opening both in front and behind; or a vertical band with an opening at either side.

The rupture of the hymen, or its rudimentary existence, gives rise to the appearance of a fringe of papillæ around the opening of the vagina; these are called *carunculae myrtiformes*.

The triangular smooth surface between the clitoris and the entrance of the vagina, which is bounded on each side by the upper portions of the nymphæ, is the *vestibule*.

At the upper angle of the vagina is an elevation formed by the prominence of the upper wall of the canal, and analogous to the bulb of the urethra of the male; and immediately in front of this tubercle, and surrounded by it, is the opening of the urethra, the *meatus urinarius*.

## MAMMARY GLANDS.

The *Mammæ* are situated in the pectoral region, and are separated from the pectoralis major muscle by a thin layer of superficial fascia. They exist in the male as well as in the female, but in a rudimentary state,

unless excited into growth by some peculiar action, such as the loss or atrophy of the testes.

Their base is somewhat elliptical, the long diameter corresponding with the direction of the fibres of the pectoralis major muscle; and the left mamma is generally a little larger than the right.

Near the centre of the convexity of each mamma is a small prominence of the integument, called the *nipple*, which is surrounded by an areola having a coloured tint. In the female before impregnation, the colour of the areola is a delicate pink; after impregnation, it assumes a brownish hue, which deepens in colour as pregnancy advances; and after the birth of a child, the brownish tint continues through life.

The areola is furnished with a considerable number of *sebiparous follicles*, which secrete a peculiar fatty substance for the protection of the delicate integument around the nipple. During suckling these follicles are increased in size, and have the appearance of small pimples, projecting from the skin. At this period they serve by their increased secretion to defend the nipple and areola from the excoriating action of the saliva of the infant.

In *Structure*, the mamma is a conglomerate gland, and consists of lobes, which are held together by a dense and firm areolar tissue; the lobes are composed of lobules, and the lobules of minute cæcal vesicles, the ultimate terminations of the excretory ducts.

The excretory ducts (*tubuli lactiferi*), from ten to fifteen in number, commence by small openings at the apex of the nipple, and pass inwards, parallel with each other, towards the central part of the gland, where they form dilatations (*ampullæ*), and give off numerous branches to ramify through the gland to their ultimate terminations in the minute lobules.

The ducts and cæcal vesicles are lined, throughout, by a mucous membrane, which is continuous at the apex of the nipple with the integument.

In the nipple the excretory ducts are surrounded by a tissue analogous to the dartos of the scrotum, to which the power of erectility of the nipple seems due. There is no appearance of any structure resembling erectile tissue.

*Vessels and Nerves.*—The mammæ are supplied with *arteries* from the thoracic branches of the axillary, from the intercostals, and from the internal mammary.

The *Lymphatics* follow the border of the pectoralis major to the axillary glands.

The *Nerves* are derived from the thoracic and intercostals.

## CHAPTER XII.

### ANATOMY OF THE FŒTUS.

THE medium weight of a child of the full period, at birth, is seven pounds, and its length seventeen inches; the extremes of weight are four pounds and three quarters, and ten pounds; and the extremes of measurement fifteen and twenty inches. The head is of large size, and lengthened

from before backwards; the face small. The upper extremities are greatly developed, and the thorax expanded and full. The upper part of the abdomen is large, from the great size of the liver; the lower part is small and conical. And the lower extremities are very small in proportion to the rest of the body. The external genital organs are very large, and fully developed, and the attachment of the umbilicus is one inch farther from the vertex of the head than from the soles of the feet; and one inch farther from the ensiform cartilage than from the symphysis pubis.

**OSSEOUS SYSTEM.**—The development of the osseous system has been treated of in the first chapter. The ligamentous system presents no peculiarity deserving of remark.

**MUSCULAR SYSTEM.**—The muscles of the fœtus at birth are large and fully formed. They are of a lighter colour than those of the adult, and of softer texture. The transverse striæ on the fibres of animal life are not distinguishable until the sixth month of fœtal life.

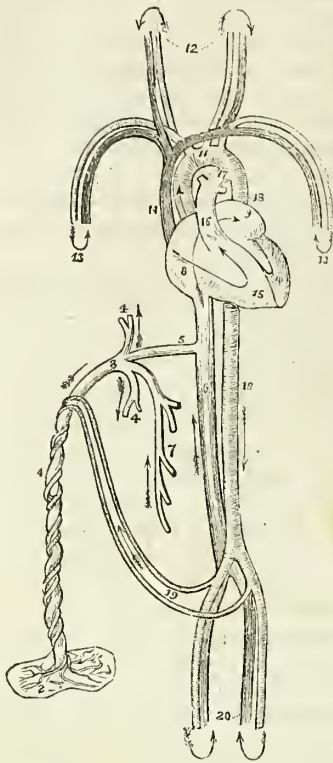
**VASCULAR SYSTEM.**—The circulating system presents several peculiarities: 1stly, In the heart; there is a communication between the two auricles by means of the *foramen ovale*. 2dly, In the arterial system; there is a communication between the pulmonary artery and descending aorta, by means of a large trunk, the *ductus arteriosus*. 3dly, Also in the arterial system; the internal iliac arteries, under the name of hypogastric and *umbilical*, are continued from the fœtus to the placenta, to which they return the blood which has circulated in the system of the fœtus. 4thly, In the venous system; there is a communication between the umbilical vein and the inferior vena cava, called the *ductus venosus*.

#### FETAL CIRCULATION.

The pure blood is brought from the placenta by the *umbilical vein*. The umbilical vein passes through the umbilicus, and enters the liver, where it divides into several branches, which may be arranged under three heads:—1stly, Two or three, which are distributed to the left lobe. 2dly, A single branch, which communicates with the portal vein in the transverse fissure, and supplies the right lobe. 3dly, A large branch, the *ductus venosus*, which passes directly backwards, and joins the inferior cava. In the inferior cava the pure blood becomes mixed with that which is returning from the lower extremities and abdominal viscera, and is carried through the right auricle, (guided by the Eustachian valve) and through the *foramen ovale*, into the left auricle. From the left auricle it passes into the left ventricle, and from the left ventricle into the aorta, whence it is distributed, by means of the carotid and subclavian arteries, principally to the head and upper extremities. From the head and upper extremities, the impure blood is returned by the superior vena cava to the right auricle; from the right auricle, it is propelled into the right ventricle; and from the right ventricle into the pulmonary artery. In the adult, the blood would now be circulated through the lungs, and oxygenated; but in the fœtus the lungs are solid, and almost impervious. Only a small quantity of the blood passes therefore into the lungs; the greater part rushes through the *ductus arteriosus*, into the commencement of the descending aorta, where it becomes mingled with that portion of the pure blood which is not sent through the carotid and subclavian arteries.

Passing along the aorta, a small quantity of this mixed blood is distri-

Fig. 245.\*



same cavity without admixture. 2. That the inferior cava opens almost directly into the left auricle. 3. That by the aid of the Eustachian valve, the current in the inferior cava will be almost entirely excluded from the right ventricle.

3dly. That the blood which circulates through the arch of the aorta comes directly from the placenta; and, although mixed with the impure

\* The fetal circulation. 1. The umbilical cord, consisting of the umbilical vein and two umbilical arteries; proceeding from the placenta (2). 3. The umbilical vein dividing into three branches; two (4, 4), to be distributed to the liver; and one (5), the ductus venosus, which enters the inferior vena cava (6). 7. The portal vein, returning the blood from the intestines, and uniting with the right hepatic branch. 8. The right auricle; the course of the blood is denoted by the arrow, proceeding from 8, to 9, the left auricle. 10. The left ventricle; the blood following the arrow to the arch of the aorta (11), to be distributed through the branches given off by the arch to the head and upper extremities. The arrows 12 and 13, represent the return of the blood from the head and upper extremities through the jugular and subclavian veins, to the superior vena cava (14), to the right auricle (8), and in the course of the arrow through the right ventricle (15), to the pulmonary artery (16). 17. The ductus arteriosus, which appears to be a proper continuation of the pulmonary artery, the offsets at each side are the right and left pulmonary artery cut off; these are of extremely small size as compared with the ductus arteriosus. The ductus arteriosus joins the descending aorta (18, 18), which divides into the common iliacs, and these into the internal iliacs, which become the hypogastric arteries (19), and return the blood along the umbilical cord to the placenta; while the other divisions, the external iliacs (20), are continued into the lower extremities. The arrows at the terminations of these vessels mark the return of the venous blood by the veins to the inferior vena cava.

buted by the external iliac arteries to the lower extremities; the greater portion is conveyed by the internal iliac, hypogastric, and umbilical arteries to the placenta; the hypogastric arteries proceeding from the internal iliacs, and passing by the side of the fundus of the bladder, and upwards along the anterior wall of the abdomen to the umbilicus, where they become the umbilical arteries.

From a careful consideration of this circulation, we perceive—1st. That the pure blood from the placenta is distributed in considerable quantity to the liver, before entering the general circulation. Hence arises the abundant nutrition of that organ, and its enormous size in comparison with other viscera.

2dly. That the right auricle is the scene of meeting of a double current; the one coming from the inferior cava, the other from the superior, and that they must cross each other in their respective course. How this crossing is effected the theorist will wonder; not so the practical anatomist; for a cursory examination of the fetal heart will show,

1. That the direction of entrance of the two vessels is so opposite, that they may discharge their currents through the

blood of the inferior cava, yet is propelled in so great abundance to the head and upper extremities, as to provide for the increased nutrition of those important parts, and prepare them, by their greater size and development, for the functions which they are required to perform at the instant of birth.

4thly. That the blood circulating in the descending aorta is very impure, being obtained principally from the returning current in the superior cava; a small quantity only being derived from the left ventricle. Yet is it from this impure blood that the nutrition of the lower extremities is provided. Hence we are not surprised at their insignificant development at birth; while we admire the providence of nature, that directs the nutrient current, in abundance, to the organs of sense, prehension, and deglutition, organs so necessary, even at the instant of birth, to the safety and welfare of the creature.

After birth, the *foramen ovale* becomes gradually closed by a membranous layer, which is developed from the margins of the opening from below upwards, and completely separates the two auricles. The situation of the foramen is seen in the adult heart, upon the septum auricularum, and is called the *fossa ovalis*; the prominent margin of the opening is the *annulus ovalis*.

As soon as the lungs have become inflated by the first act of inspiration, the blood of the pulmonary artery rushes through its right and left branches into the lungs, to be returned to the left auricle by the pulmonary veins. Thus the pulmonary circulation is established. Then the *ductus arteriosus* contracts, and degenerates into an impervious fibrous cord, serving in after life simply as a bond of union between the left pulmonary artery and the concavity of the arch of the aorta.

The current through the umbilical cord being arrested, the *umbilical arteries* likewise contract and become impervious, and degenerate into the *umbilical ligaments* of the bladder.

The *umbilical vein* and *ductus venosus*, also deprived of their circulating current, become reduced to fibrous cords, the former being the *round ligament* of the liver, and the latter a fibrous band which may be traced along the fissure for the ductus venosus to the inferior vena cava.

NERVOUS SYSTEM.—The brain is very soft, almost pulpy, and has a reddish tint throughout; its weight at birth, relatively to the entire body, is as one to six, and the difference between the white and grey substance is not well marked. The nerves are firm and well developed.

#### ORGANS OF SENSE.

*Eye*.—The eyeballs are of large size and well developed at birth. The pupil is closed by a vascular membrane called the *membrana pupillaris*, which disappears at about the seventh month. Sometimes it remains permanently, and produces blindness. It consists of two thin membranous layers, between which the ciliary arteries are prolonged from the edge of the iris, and form arches and loops by returning to it again, without anastomosing with those of the opposite side.

The removal of the membrane takes place by the contraction of these arches and loops towards the edge of the pupil. The capsule of the lens is extremely vascular.

*Ear*.—The ear is remarkable for its early development; the labyrinth

and ossicula auditûs are ossified at an early period, and the latter are completely formed before birth. The only parts remaining incomplete are the mastoid cells, and the meatus auditorius. The membrana tympani in the fœtal head is very oblique, occupying almost the basilar surface of the skull; hence probably arises a deficient acuteness in the perception of sound. It is also extremely vascular.

*Nose.*—The sense of smell is imperfect in the infant, as may be inferred from the small capacity of the nasal fossæ, and the non-development of the ethmoid, sphenoid, frontal, and maxillary sinuses.

#### THYROID GLAND.

The *Thyroid gland* is of large size in the fœtus, and is developed by two lateral halves, which approach and become connected at the middle line so as to constitute a single gland. It is doubtful whether it performs any special function in fetal life.

#### THYMUS GLAND.

The *Thymus gland*\* consists “of a thoracic and a cervical portion on each side. The former is situated in the anterior mediastinum, and the latter is placed in the neck just above the first bone of the sternum, and behind the sterno-hyoidei and sterno-thyroidei muscles.” It extends upwards from the fourth rib as high as the thyroid gland, resting against the pericardium, and separated from the arch of the aorta and great vessels by the thoracic fascia in the chest, and lying on each side of the trachea in the neck.

Although described usually as a single gland, it consists actually of two lateral, almost symmetrical glands, connected with each other by areolar tissue only, and having no structural communication: they may therefore be “properly called, a right and left thymus gland.”

Between the second and third months of embryonic existence, the thymus is so small as to be only “just perceptible;” and continues gradually increasing with the growth of the fœtus until the seventh. At the eighth month it is large; but, during the ninth, it undergoes a sudden change, assumes a greatly increased size, and at birth weighs 240 grains. After birth it continues to enlarge until the expiration of the first year, when it ceases to grow, and gradually diminishes, until at puberty it has almost disappeared.

The thymus is a conglomerate gland, being composed of lobules disposed in a spiral form around a central cavity. The lobules are held together by a firm areolar tissue (“reticulated”), and the entire gland is enclosed in a coarse areolo-fibrous capsule.

The *Lobules* are very numerous, and vary in size from that of the head of a pin to a moderate-sized pea. Each lobule contains in its interior a small cavity, or “*secretory cell*,” and several of these cells open into a small “*pouch*” which is situated at their base, and leads to the central cavity, the “*reservoir of the thymus*.”

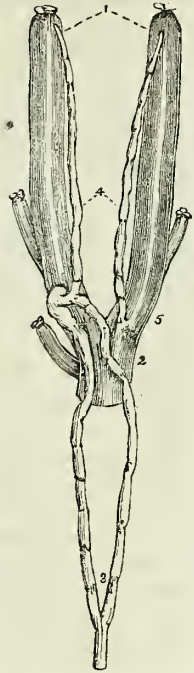
The *Reservoir* is lined in its interior by a vascular mucous membrane, which is raised into ridges by a layer of ligamentous bands situated be-

\* In the description of this gland I have adhered closely to the history of it given by Sir Astley Cooper, in his beautiful monograph “On the Anatomy of the Thymus Gland,” 1832.

Fig. 246.\*

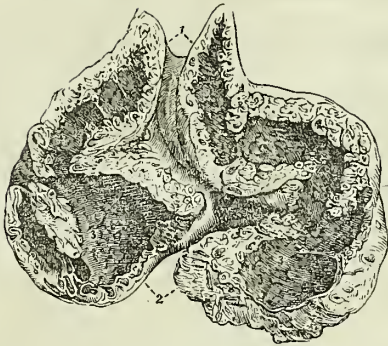

Fig. 247.†



beneath it. The ligamentous bands proceed in various directions, and encircle the open mouths (*pores*) of the secretory cells and pouches. This ligamentous layer serves to keep the lobules together, and prevent the injurious distension of the cavity.

When either gland is carefully unravelled by removing the areolar capsule and vessels, and dissecting away the reticulated areolar tissue which retains the lobules in contact, the reservoir, from being folded in a serpentine manner upon itself, admits of being drawn out into a lengthened tubular *cord*,‡ around which the lobules are clustered in a spiral manner, and resemble knots upon a cord, or a string of beads.

The reservoir, pouches, and cells, contain a white fluid “like chyle,” or “like cream, but with a small admixture of red globules.”

In an examination of the thymic fluid which I lately (1840) made, with a Powell microscope magnifying 600 times linear measure, I observed that the corpuscles were very numerous, smaller than the blood particles, globular and oval in form, irregular in outline, variable in size, and provided with a small central nucleus.

In the human fœtus this fluid has been found by Sir Astley Cooper in too small proportion to be submitted to chemical analysis. But the thymic fluid of the fœtal calf, which exists in great abundance, gave the fol-

\* A section of the thymus gland at the eighth month, showing its anatomy. This figure, and the succeeding, were drawn from two of Sir Astley Cooper's beautiful preparations, with the kind permission of their possessor. The references were made by Sir Astley's own hand. 1. The cervical portions of the gland; the independence of the two lateral glands is well marked. 2. Secretory cells seen on the cut surface of the section; these are observed in all parts of the section. 3, 3. The pores or openings of the secretory cells and pouches; they are seen dispersed upon the whole internal surface of the great central cavity or reservoir. The continuity of the reservoir in the lower or thoracic portion of the gland, with the cervical portion, is seen in the figure.

† The course and termination of the “absorbent ducts” of the thymus of the calf; from one of Sir Astley Cooper's preparations. 1. The two internal jugular veins. 2. The superior vena cava. 3. The thoracic duct, dividing into two branches, which reunite previously to their termination in the root of the left jugular vein. 4. The two thymic ducts; that on the left side opens into the thoracic duct, and that on the right into the root of the right jugular vein.

‡ See the beautiful plates in Sir Astley Cooper's work.

lowing analytical\* results: one hundred parts of the fluid contained sixteen parts of solid matter, which consisted of,

Incipient fibrine,  
Albumen,  
Mucus, and muco-extractive matter,  
Muriate and phosphate of potass  
Phosphate of soda,  
Phosphoric acid, a trace.

According to the researches of Mr. Simon† and Oesterlen the thymus is composed of polygonal and mutually flattened membranous cells, measuring from half a line to two lines in diameter and arranged in conical masses around a central cavity. Each cell is surrounded by a capillary plexus and connected to neighbouring cells by areolar tissue intermingled with elastic fibres. The corpuscles found in the fluid of the thymus are dotted nuclei measuring  $\frac{1}{3830}$  of an inch in diameter; and are subject to conversion into nucleated cells and fat-cells.

The *Arteries* of the thymus gland are derived from the internal mammary, and from the superior and inferior thyroid.

The *Veins* terminate in the left vena innominata, and some small branches in the thyroid veins.

The *Nerves* are very minute, and are derived chiefly, through the internal mammary plexus, from the superior thoracic ganglion of the sympathetic. Sir Astley Cooper has also seen a branch from the junction of the pneumogastric and sympathetic pass to the side of the gland.

The *Lymphatics* terminate in the general union of the lymphatic vessels at the junction of the internal jugular and subclavian veins. Sir Astley Cooper has injected them only once in the human fœtus, but in the calf he finds two large lymphatic ducts, which commence in the upper extremities of the glands, and pass downwards, to terminate at the junction of the jugular and subclavian vein at each side. These vessels he considers to be the "*absorbent ducts* of the glands; '*thymic ducts*;' they are the carriers of the fluid from the thymus into the veins."

Sir Astley Cooper concludes his anatomical description of this gland with the following observations:—

"As the thymus secretes all the parts of the blood, viz. albumen, fibrine, and particles, is it not probable that the gland is designed to prepare a fluid well fitted for the fœtal growth and nourishment from the blood of the mother, before the birth of the fœtus, and, consequently, before chyle is formed from food?—and this process continues for a short time after birth, the quantity of fluid secreted from the thymus gradually declining as that of chylification becomes perfectly established."

#### FŒTAL LUNGS.

The *Lungs*, previously to the act of inspiration, are dense and solid in structure, and of a deep red colour. Their specific gravity is greater than water, in which they sink to the bottom; whereas lung which has respired will float upon that fluid. The specific gravity is, however, no test of the

\* This analysis was conducted by Dr. Dowler of Richmond.

† "A Physiological Essay on the Thymus Gland," 4to. 1845.



real weight of the lung, the respired lung being actually heavier than the foetal. Thus the weight of the foetal lung, at about the middle period of uterine life, is to the weight of the body as 1 to 60.\* But, after respiration, the relative weight of the lung to the entire body is as 1 to 30.

## FŒTAL HEART.

The *Heart* of the foetus is large in proportion to the size of the body; it is also developed very early, representing at first a simple vessel, and undergoing various degrees of complication until it arrives at the compound character which it presents after birth. The two ventricles form, at one period, a single cavity, which is afterwards divided into two by the septum ventriculorum. The two auricles communicate up to the moment of birth, the septum being incomplete, and leaving a large opening between them, the *foramen ovale* (foramen of Botal†).

The *Ductus arteriosus* is another peculiarity of the foetus connected with the heart; it is a communication between the pulmonary artery and the aorta. It degenerates into a fibrous cord after birth, from the double cause, of a diversion in the current of the blood towards the lungs, and from the pressure of the left bronchus, caused by its distension with air.

## VISCERA OF THE ABDOMEN.

At an early period of uterine life, and sometimes at the period of birth, as I have twice observed in the imperfectly developed foetus, two minute fibrous threads may be seen passing from the umbilicus to the mesentery. These are the remains of the omphalo-mesenteric vessels.

The *Omphalo-mesenteric* are the first developed vessels of the germ: they ramify upon the vesicula umbilicalis, or yolk-bag, and supply the newly formed alimentary canal of the embryo. From them, as from a centre, the general circulating system is produced. After the establishment of the placental circulation they cease to carry blood, and dwindle to the size of mere threads, which may be easily demonstrated in the early periods of uterine life; but are completely removed, excepting under peculiar circumstances, at a later period.

The *Stomach* is of small size, and the great extremity but little developed. It is also more vertical in direction the earlier it is examined, a position that would seem due to the enormous magnitude of the liver, and particularly of its left lobe.

The *Appendix vermiformis cæci* is long and of large size, and is continued directly from the central part of the cul-de-sac of the cæcum, of which it appears to be a constricted continuation. This is the character of the appendix cæci in the higher quadrumana.

The large intestines are filled with a dark green viscous secretion, called *meconium* (μῆκων, poppy), from its resemblance to the inspissated juice of the poppy.

The *Pancreas* is comparatively larger in the foetus than in the adult.

The *Spleen* is comparatively smaller in the foetus than in the adult.

\* Cruveilhier, Anatomie Descriptive, vol. ii. p. 621.

† Leonard Botal, of Piedmont, was the first of the moderns who gave an account of this opening in a work published in 1565. His description is very imperfect. The foramen was well known to Galen.

## FOETAL LIVER.

The *Liver* is the first formed organ in the embryo. It is developed from the alimentary canal, and at about the third week, fills the whole abdomen, and is one-half the weight of the entire embryo. At the fourth month the liver is of immense size in proportion to the bulk of the fœtus. At birth it is of very large size, and occupies the whole upper part of the abdomen. The left lobe is as large as the right, and the falciform ligament corresponds with the middle line of the body. The liver diminishes rapidly after birth, probably from obliteration of the umbilical vein.

## KIDNEYS AND SUPRA-RENAL CAPSULES.

The *Kidneys* present a lobulated appearance in the fœtus, which is their permanent type amongst some animals, as the bear, the otter, and cetacea.

The *Supra-renal capsules* are organs which appear, from their early and considerable development, to belong especially to the economy of the fœtus. They are distinctly formed at the second month of embryonic life, and are greater in size and weight than the kidneys. At the third or fourth month, they are equalled in bulk by the kidneys; and at birth, they are about one-third less than those organs.

## VISCERA OF THE PELVIS.

The *Bladder* in the fœtus is long and conical, and is situated altogether above the upper border of the ossa pubis, which are as yet small and undeveloped. It is, indeed, an abdominal viscus, and is connected superiorly with a fibrous cord, called the *urachus*, of which it appears to be an expansion.

The *Urachus* is continued upwards to the umbilicus, and becomes connected with the umbilical cord. In animals it is a pervious duct, and is continuous with one of the membranes of the embryo, the *allantois*. It has been found pervious in the human fœtus, and the urine has been passed through the umbilicus. Calculous concretions have also been found in its course.

The *Uterus*, in the early periods of embryonic existence, appears bifid, from the large size of the Fallopian tubes, and the small development of the body of the organ. At the end of the fourth month, the body assumes a larger bulk, and the bifid appearance is lost. The cervix uteri in the fœtus is larger than the body of the organ.

The *Ovaries* are situated, like the testicles, in the lumbar region, near the kidneys, and descend from thence, gradually, into the pelvis.

## TESTES.

The *Testicles* in the embryo are situated in the lumbar regions, immediately in front of and somewhat below the kidneys. They have, connected with them inferiorly, a peculiar structure, which assists in their descent, and is called the gubernaculum testis.

The *Gubernaculum* is a soft and conical cord composed of areolar tissue containing in its areolæ a gelatiniform fluid. In the abdomen it lies in front of the psoas muscle, and passes along the spermatic canal, which it

serves to distend for the passage of the testis. It is attached by its superior and larger extremity to the lower end of the testis and epididymis, and by the inferior extremity to the bottom of the scrotum. The gubernaculum is surrounded by a thin layer of muscular fibres, the cremaster, which pass upwards upon this body to be attached to the testis. Inferiorly, the muscular fibres divide into three processes, which, according to Mr. Curling,\* are thus attached: "The external and broadest is connected to Poupart's ligament in the inguinal canal; the middle forms a lengthened band, which escapes at the external abdominal ring, and descends to the bottom of the scrotum, where it joins the dartos; the internal passes in the direction inwards, and has a firm attachment to the os pubis and sheath of the rectus muscle. Besides these, a number of muscular fibres are reflected from the internal oblique on the front of the gubernaculum."

The *Descent of the testicle* is gradual and progressive. Between the fifth and sixth months it has reached the lower part of the psoas muscle, and during the seventh it makes its way through the spermatic canal, and descends into the scrotum.

While situated in the lumbar region, the testis and gubernaculum are placed behind the peritoneum, by which they are invested upon their anterior surface and sides. As they descend, the investing peritoneum is carried downwards with the testis into the scrotum, forming a lengthened

Fig. 248.†

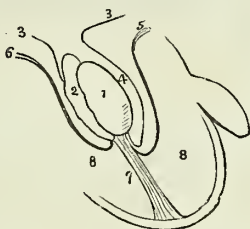
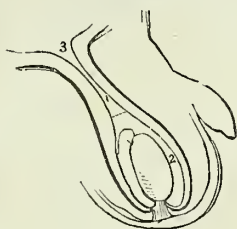


Fig. 249.‡



pouch, which by its upper extremity opens into the cavity of the peritoneum. The upper part of this pouch, being compressed by the spermatic canal, is gradually obliterated, the obliteration extending downwards along the spermatic cord nearly to the testis. That portion of the peritoneum which immediately surrounds the testis is, by the above process, cut off from its continuity with the peritoneum, and is termed the tunica

\* See an excellent paper "On the Structure of the Gubernaculum," &c., by Mr. Curling, Lecturer on Morbid Anatomy in the London Hospital, in the *Lancet*, vol. ii. 1840-41, p. 70.

† A diagram illustrating the descent of the testis. 1. The testis. 2. The epididymis. 3, 3. The peritoneum. 4. The pouch formed around the testis by the peritoneum, the future cavity of the tunica vaginalis. 5. The pubic portion of the cremaster attached to the lower part of the testis. 6. The portion of the cremaster attached to Poupart's ligament. The mode of eversion of the cremaster is shown by these lines. 7. The gubernaculum, attached to the bottom of the scrotum, and becoming shortened by the contraction of the muscular fibres which surround it. 8, 8. The cavity of the scrotum.

‡ In this figure the testis has completed its descent. The gubernaculum is shortened to its utmost, and the cremaster completely everted. The pouch of peritoneum above the testis is compressed so as to form a tubular canal; 1. A dotted line marks the point at which the tunica vaginalis will terminate superiorly; and the number 2 its cavity. 3. The peritoneal cavity.

vaginalis ; and as this membrane must be obviously a shut sac, one portion of it investing the testis, and the other being reflected so as to form a loose bag around it, its two portions have received the appellations of tunica vaginalis propria, and tunica vaginalis reflexa.

The descent of the testis is effected by means of the traction of the muscle of the gubernaculum (cremaster). "The fibres," writes Mr. Curling,\* "proceeding from Poupart's ligament and the obliquus internus, tend to guide the gland into the inguinal canal ; those attached to the os pubis, to draw it below the abdominal ring ; and the process descending to the scrotum, to direct it to its final destination." During the descent, "the muscle of the testis is gradually everted, until, when the transition is completed, it forms a muscular envelope external to the process of peritoneum, which surrounds the gland and the front of the cord." "The mass composing the central part of the gubernaculum, which is so soft, lax, and yielding as in every way to facilitate these changes, becomes gradually diffused, and, after the arrival of the testicle in the scrotum, contributes to form the loose cellular tissue which afterwards exists so abundantly in this part." The attachment of the gubernaculum to the bottom of the scrotum is indicated throughout life by distinct traces.

\* Loc. cit.

# INDEX.

## A.

Abdomen, 496  
 Abdominal regions, 496  
 Abdominal ring, 212, 266  
 Abductor oculi, 177  
 Acetabulum, 116  
 Acini, 519  
 Adductor oculi, 177  
 Adipose tissue, 136  
 Air-cells, 494  
 Albino, 452  
 Alcock, Dr., researches of, 396  
 Alimentary canal, 501  
 Allantois, 560  
 Amphiarthrosis, 130  
 Ampulla, 459  
 Amygdalæ, 503  
   cerebri, 380  
 Andersch, notice of, 404  
 Annulus ovalis, 478  
 Antihelix, 456  
 Antitragus, 456  
 Antrum of Highmore, 74  
   pylori, 506  
 Anus, 509-514  
 Aorta, abdominal, 280  
   arch, 279  
   ascending, 279  
   thoracic, 280  
 Aortic sinuses, 278  
 Aponeurosis, 168  
 Apophysis, 48  
 Apparatus ligamentosus colli, 141  
 Appendices epiploicæ, 501  
 Appendix vermiformis, 507  
 Aqua labyrinthi, 463  
 Aqueductus cochleæ, 463  
   vestibuli, 462  
 Aqueduct of Sylvius, 379  
 Aqueous humour, 451  
 Arachnoid membrane, 370  
 Arantius, notice of, 480  
 Arbor vitæ, 382  
   uterina, 547  
 Arch, femoral, 273  
   palmar, superficial; 308  
 Arciform fibres, 386  
 Areola, 552  
 Areolar tissue, 136  
 Arnold, Frederick, researches, 435  
 ARTERIES.  
   General anatomy, 275  
   structure, 277  
   anastomotica, femor, 326  
     brachial, 304

## ARTERIES—continued.

angular, 285  
 aorta, 278  
 articulares genû, 327  
 auricula anterior, 288  
   posterior, 287  
 axillary, 300  
 basilar, 296  
 brachial, 303  
 bronchial, 308  
 bulbosi, 320  
 calcanean, 332  
 carotid, common, 282  
   external, 283  
   internal, 291  
 carpal ulnar, 308  
   radial, 306  
 cavernosi, 320  
 centralis retinæ, 293, 452  
 cerebellar inferior, 297  
   superior, 297  
 cerebral, 293, 294  
 cervicalis anterior, 299  
   posterior, 299  
 choroidean, 294  
 ciliary, 293  
 circumflex anterior, 302  
   external, 325  
 circumflex ili, 322, 324  
   internal, 326  
   posterior, 302  
 coccygeal, 318  
 cœliac, 310  
 colic, 314, 315  
 comes nervi ischiatici, 318  
   phrenici, 300  
 communicans cerebri, 294  
   pedis, 330  
 coronaria cordis, 281  
   dextra, 281  
   labii, 286  
   sinistra, 281  
   ventriculi, 310  
 corporis bulbosi, 320  
   cavernosi, 320  
 cremasteric, 322  
 cystic, 311  
 dental, 289  
 digitales manûs, 308  
   pedis, 333  
 dorsales pollicis, 306  
 dorsalis linguæ, 285  
   carpi, 306  
   hallucis, 330  
   nasi, 293  
   pedis, 333

ARTERIES—*continued.*

- penis, 320
- scapulæ, 302
- emulgent, 315
- epigastric, 322
  - superficial, 325
- ethmoidal, 293
- facial, 285
- femoral, 323
- frontal, 293
- gastric, 310
- gastro-duodenalis 311
  - epiploica dextra, 311
  - sinistra, 311
- gluteal, 321
  - inferior, 318
- hæmorrhoidal, external, 319
  - middle, 318
  - superior, 315
  - inferior, 318
- hepatic, 310
- ileo-colic, 313
- iliac, common, 316
  - external, 321
  - internal, 317
- ileo-lumbar, 320
- infra-orbital, 290
- innominata, 281
- intercostal, 309
  - anterior, 300
  - superior, 299
- inter-osseous, 307, 308
- intestini tenuis, 312
- ischiatric, 318
- labial, 286
- lachrymal, 292
- laryngeal, 285
- lateralis nasi, 286
- lingual, 285
- lumbar, 315
- malleolar, 329
- mammary, internal, 299
- masseteric, 286
- mastoid, 287
- maxillary, internal, 288
- mediastinal, 300
- meningeæ, anterior, 292
  - inferior, 287
  - media, 290
  - parva, 290
  - posterior, 297
- mesenteric, 312
  - inferior, 315
- metacarpal, 306
- metatarsal, 330
- musculo-phrenic, 300
- nasal, 293
- obturator, 320
- occipital, 287
- œsophageal, 308
- ophthalmic, 292
- orbital, 288
- palatine, inferior, 286
  - posterior, 290
- palpebral, 293
- pancreatica magna, 311
- pancreaticæ parvæ, 311
- pancreatico-duodenalis, 311
- parotidean, 287
- perforantes, femoral, 326
  - palmares, 306
  - plantares, 332
- pericardiac, 300
- perineal, superficial, 319

ARTERIES—*continued.*

- peroneal, 331
- pharyngea ascendens, 287
- phrenic, 309
- plantar, external, 332
  - internal, 332
- popliteal, 326
- princeps cervicis, 287
  - pollicis, 306
- profunda cervicis, 299
  - femoris, 325
  - inferior, 304
  - superior, 303
- pterygoid, 286
- pterygo-palatine, 290
- pubic, external, 325
  - internal, 318
- pulmonary, 334
- pyloric, 311
- radial, 304
- radialis indicis, 306
- ranine, 285
- recurrens interosseous, 308
  - radialis, 305
  - tibialis, 329
  - ulnaris, 307
- renal, 315
- sacra media, 316
  - lateralis, 321
- scapular, posterior, 299
- sigmoid, 315
- spermatic, 314
- spheno-palatine, 290
- spinal, 297
- splenic, 311
- stylo-mastoid, 287
- subclavian, 294
- sublingual, 285
- submaxillary, 286
- submental, 286
- subscapular, 302
- superficialis cervicis, 299
  - volæ, 306
- supra-orbital, 293
- supra-renal, 315
  - scapular, 298
- sural, 328
- tarsea, 330
- temporal, 288
- temporales profundæ, 290
- thoracic, 302
- thyroidea inferior, 238
  - media, 282
  - superior, 284
- tibialis antica, 328
  - postica, 330
- transversalis colli, 299
  - faciei, 287
  - humeri, 298
  - perinei, 320
- tympanic, 289
- ulnar, 306
- umbilical, 317
- uterine, 320
- vaginal, 320
- vasa brevia, 311
  - intestini tenuis, 312
- vertebral, 296
- vesical, 318
- Vidian, 291
- Arthrodia, 130
- Articulations, 137
- Arytenoid cartilages, 486
- Arytenoid glands, 491

Auricles of the heart, 477, 481  
Auriculo-ventricular openings, 478, 481

## B.

Barry, Dr., researches of, 550  
Base of the brain, 382  
Bauhini, valvula, 510  
Bell, Sir C., researches of, 366  
Berzelius, analysis of bone, 43  
Biliary ducts, 525  
Bladder, 532  
BONES, chemical composition, 43  
    development, 46  
    general anatomy, 43  
    structure, 44  
astragalus, 124  
atlas, 51  
axis, 52  
calcis, 124  
carpus, 109  
clavicula, 103  
coccyx, 58  
costæ, 102  
cuboides, 126  
cuneiforme carpi, 110  
    externum tarsi, 125  
    internum, 126  
    medium, 128  
ethmoides, 72  
femur, 119  
fibula, 122  
frontale, 62  
humerus, 105  
hyoides, 99  
ilium, 114  
innominatum, 114  
ischium, 115  
lachrymale, 77  
magnum, 111  
malare, 77  
maxillare superius, 74  
maxillare inferius, 81  
metacarpus, 112  
metatarsus, 127  
nasi, 74  
naviculare, 125  
occipitale, 59  
palati, 77  
parietale, 61  
patella, 121  
phalanges manus, 113  
    pedis, 128  
pisiforme, 110  
pubis, 116  
radius, 107  
sacrum, 56  
scaphoides carpi, 109  
    tarsi, 125  
scapula, 103  
    semilunare, 109  
sesamoidea manus, 129  
    pedis, 129  
sphenoides, 69  
sternum, 100  
tarsus, 124  
temporal, 64  
tibia, 121  
trapezoides, 111  
trapezium, 110  
triquetra, 84  
turbatum inferius, 80  
    superius, 73  
ulna, 106

BONES—*continued.*

unciforme, 113  
unguis, 77  
vertebra prominens, 52  
vertebra dentata, 52  
vertebræ, cervical, 50  
    dorsal, 53  
    lumbar, 53  
vomer, 80  
Wormiana, 84  
Botal, foramen of, 559  
    notice of, 559  
Bowman, Mr., researches of, 170, 529  
Brain, 367  
Bronchi, 494  
Bronchial cells, 494  
    tubes, 494  
Bronchocele, 392  
Brunn, Von, notice of, 512  
Brunner's glands, 512  
Bulb, corpus spongiosum, 537  
Bulbi fornicis, 384  
Bulbous part of the urethra, 539  
Bulbus olfactorius, 394  
Bursæ mucosæ, 137

## C.

Cæcum, 507  
Calamus scriptorius, 380  
Calyces, 530  
Camper's ligament, 269  
Canal of Fontana, 447  
    Petit, 452  
    Sylvius, 379  
Canals of Havers, 44  
Canthi, 453  
Capillaries, 276  
Capitula Santorini, 486  
Capsule of Glisson, 521  
Capsules supra-renal, 527  
Caput gallinaginis, 539  
Cardia, 505  
Carpus, 109  
Cartilage, 46, 132  
CARTILAGES.  
    inter-articular of the clavicle, 150  
    inter-articular of the jaw, 144  
    inter-articular of the wrist, 155  
    semilunar, 161  
Cartilagification, 132  
Caruncula lachrymalis, 454  
    mammillaris, 384  
Carunculæ myrtiformes, 551  
Casserian ganglion, 391  
Cauda equina, 390  
Cava, vena, 346  
Cementum, 94  
Centrum ovale majus, 373  
    minus, 374  
Cerebellum, 381  
Cerebro-spinal axis, 367  
Cerebrum, 372  
Ceruminous follicles, 457  
Cervical ganglia, 437  
Chambers of the eye, 451  
Cheeks, 502  
Chiasma nerv. opt. 394  
Chorda tympani, 402  
Chordæ longitudinales, 390  
    tendineæ, 479, 482  
    vocales, 488  
    Willisii, 368  
Choroid membrane, 448

- Choroid plexus, 375  
 Cilia, 453  
 Ciliary canal, 448  
   ligament, 448  
   processes, 448  
 Circle of Willis, 298  
 Circulation, adult, 276  
   fœtal, 585  
 Circulus tonsillar, 287  
 Clitoris, 551  
 Clivus Blumenbachii, 69  
 Cochlea, 463  
 Cock, Mr., researches of, 407  
 Cœliac axis, 310  
 Colon, 508  
 Columna nasi, 443  
 Columnæ carnae, 479, 482  
 Commissures, 362, 378  
   great, 373  
 Conarium, 379  
 Concha, 456  
 Congestion of the liver, 523  
 Coni renales, 529  
   vasculosi, 543  
 Conjunctiva, 454  
 Converging fibres, 388  
 Cooper, Sir Astley, researches of, 557  
 Corium, 469  
 Cornea, 446  
 Cornicula laryngis, 486  
 Cornu Ammonis, 376  
 Cornua of the ventricles, 373, 375  
 Corona glandis, 536  
 Coronary valve, 478  
 Corpora albicantia, 384  
   Arantii, 480  
   cavernosa, 536  
   geniculata, 378  
     Malpighiana, 530  
     mamillaria, 384  
     olivaria, 385  
     pisiformia, 384  
     pyramidalia, 385  
     quadrigenina, 379  
     restiformia, 386  
     striata, 374  
 Corpus callosum, 37  
   cavernosum, 536  
   dentatum, 382  
   fimbriatum, 376  
   geniculatum externum, 378  
     internum, 378  
   Highmorianum, 542  
   luteum, 550  
   psalloides, 398  
   rhomboideum, 382  
   spongiosum, 537  
   striatum, 374  
 Costal cartilages, 102  
 Cotunnus, notice of, 463  
 Cowper's glands, 540  
 Cranial nerves, 392  
 Cribriform fascia, 272  
 Cricoid cartilage, 486  
 Crico-thyroid membrane, 487  
 Crura cerebelli, 382  
   cerebri, 378  
   penis, 536  
 Crural canal, 272  
   ring, 273  
 Crystalline lens, 451  
 Cuneiform cartilages, 486  
 Cupola, 464  
 Curling, Mr., researches of, 561, 562  
 Cuticle, 470  
 Cutis, 468  
 Cystic duct, 525  
 Cyto-blast, 470
- D.
- Dartos, 540  
 Davy, Dr., researches of, 296  
 Derbyshire neck, 392  
 Dermis, 468  
 Detrusor urinæ, 533  
 Diaphragm, 217  
 Diaphysis, 48  
 Diarthrosis, 130  
 Digital cavity, 375  
 Diverging fibres, 386  
 Dorsi-spinal veins, 348  
 Ductus ad nasum, 456  
   arteriosus, 553  
   comm. choledochus, 525  
   cysticus, 525  
   ejaculatorius, 537  
   hepaticus, 525  
   lymphaticus dexter, 360  
   pancreaticus, 526  
   prostaticus, 535  
   thoracicus, 360  
   venosus, 553  
 Duodenum, 506  
 Dura mater, 368
- E.
- Ear, 456  
 Ejaculatory duct, 537  
 Elastic tissue, 135  
 Enamel, 94  
 Enarthrosis, 131  
 Encephalon, 367  
 Endolymph, 462  
 Ensiform cartilage, 100  
 Entozoon folliculorum, 474  
 Epidermis, 470  
 Epididymis, 543  
 Epigastric region, 496  
 Epiglottic gland, 491  
 Epiglottis, 486  
 Epiglottico-hyoidean ligament, 488  
 Epiphysis, 48  
 Epithelium, 511  
 Erectile tissue, 537  
 Eustachian tube, 460  
   valve, 478  
 Eustachius, notice of, 478  
 Eye, 445  
   brows, 453  
   globe, 445  
   lashes, 453  
   lids, 453
- F.
- Falciform process, 273  
 Fallopian tubes, 549  
 Fallopius, notice of, 549  
 Falx cerebelli, 369  
   cerebri, 369  
 FASCIA.  
   general anatomy of, 263  
   cervical, deep, 264  
     superficial, 264  
   cribriform, 272  
   dentata, 376



FASCIA—*continued.*

- iliaca, 268  
 inter-columnar, 212  
 lata, 272  
 lumbar, 215  
 obturator, 269  
 palmar, 271  
 pelvica, 268  
 perineal, 269  
 plantar, 274  
 propria, 274  
 recto-vesical, 269  
 spermatica, 212  
 temporal, 264  
 thoracic, 265  
 transversalis, 266
- Fasciculi innominati, 387  
 siliquæ, 388  
 teretes, 389
- Fauces, 502
- Femoral arch, 273  
 canal, 273  
 hernia, 273  
 ring, 273
- Fenestra ovalis, 460  
 rotunda, 460
- Fibres of the heart, 483
- Fibro-cartilage, 133  
 inter-articular of the clavicle, 150  
 jaw, 144  
 knee, 161  
 wrist, 155  
 cellular tissue, 136
- Fibrous tissue, 135
- Filum terminale, 390
- Fimbriæ, Fallopianæ, 549
- Fissure of Bichat, 361  
 Sylvius, 372
- Fissures of the liver, 517
- Flocculus, 381
- Fœtal circulation, 553
- Fœtus, anatomy of, 552
- Follicles of Lieberkuhn, 543
- Fontana, notice of, 449
- Foramen of Botal, 478  
 cæcum, 467  
 commune anterius, 381  
 posterius, 381  
 Monro, of, 378  
 ovale, 553  
 saphenum, 273  
 Sæmmering, of, 449  
 Winslow, of, 500
- Foramina Thebesii, 477
- Fornix, 377
- Fossa innominata, 456  
 navicularis urethræ, 537  
 pudendi, 551  
 ovalis, 478  
 scaphoides, 456
- Fourchette, 550
- Fræna epiglottidis, 467, 488
- Frænulum labiorum, 550  
 veli medull., 380
- Frænulum labii, 468  
 linguæ, 467  
 præputii, 536
- Funiculi siliquæ, 386  
 graciles, 386
- G.**
- Galea capitis, 174
- Galen, 275
- Gall-bladder, 525
- Ganglia, cervical, 437  
 of increase, 361  
 lumbar, 441  
 sacral, 442  
 semilunar, 441  
 structure of, 361  
 thoracic, 440
- Ganglion of Andersch, 404  
 Arnold's, 436  
 azygos, 442  
 cardiac, 440  
 carotid, 439  
 Casserian, 396  
 ciliary, 433  
 Cloquet's, 435  
 impar, 442  
 jugular, 403  
 lenticular, 433  
 Meckel's, 435  
 naso-palatine, 435  
 otic, 436  
 petrous, 403  
 plexiforme, 404  
 Ribes, of, 433  
 spheno-palatine, 435  
 submaxillary, 436  
 thyroid, 438  
 vertebral, 438
- Gimbernat's ligament, 216
- Ginglymus, 130
- Gland, epiglottic, 491  
 lachrymal, 455  
 parotid, 503  
 pineal, 379  
 pituitary, 384  
 prostate, 534  
 thymus, 556  
 thyroid, 492
- Glands, aggregate, 513  
 arytenoid, 491  
 Brunner's, 512  
 concatenated, 354  
 Cowper's, 540  
 duodenal, 512  
 gastric, 512  
 inguinal, 355  
 lachrymal, 455  
 Lieberkuhn's, 513  
 lymphatic, 358  
 mammary, 583  
 mesenteric, 361  
 Meibomian, 454  
 œsophageal, 512  
 Pacchionian, 369  
 Peyer's, 513  
 pharyngeal, 512  
 salivary, 503  
 sebaceous, 474  
 solitary, 513  
 sublingual, 504  
 submaxillary, 503  
 sudoriparous, 474  
 tracheal, 492
- Glandulæ odoriferæ, 556  
 Pacchioni, 369  
 Tysoni, 536
- Glans clitoridis, 551  
 penis, 536
- Glisson, notice of, 500
- Glisson's capsule, 519
- Globus major-epididymis, 543  
 minor-epididymis, 543
- Glottis, 490

Goodsir, Mr., researches of, 95  
 Goitre, 392  
 Gomphosis, 130  
 Graafian vesicles, 550  
 Grainger, Mr., researches of, 367  
 Gubernaculum testis, 560  
 Gums, 502  
 Guthrie, Mr., researches of, 534  
 Guthrie's muscle, 220  
 Gyrus fornicatus, 376

## H.

Hair, 473  
 Hall, Dr. Marshall, researches of, 367  
 Harmonia, 130  
 Haversian canals, 44  
 Heart, 475  
 Helicine arteries, 537  
 Helico-trema, 464  
 Helix, 456  
 Hepatic duct, 525  
 Hernia, congenital, 267  
   diaphragmatic, 217  
   direct, 268  
   encysted, 267  
   femoral, 273  
   infantilis, 267  
   inguinal, 266  
   scrotal, 268  
 Highmore, notice of, 542  
 Hilton's muscle, 484  
 Hilus lienis, 557  
   renalis, 529  
 Hippocampus major, 376  
   minor, 376  
 Horner's muscle, 176  
 Horner, W. E., observations of, 514  
 Houston, Mr., researches of, 511  
 Humours of the eye, 451  
 Hyaloid membrane, 451  
 Hymen, 551  
 Hyoid bone, 99  
 Hypochondriac regions, 496  
 Hypogastric region, 496  
 Hypophysis cerebri, 384

## I.

Ileo-cæcal valve, 510  
 Ileum, 507  
 Iliac regions, 496  
 Incus, 458  
 Infundibula, 530  
 Infundibulum, 383  
 Inguinal region, 496  
 Inter-articular cartilages of the clavicle, 150  
   jaw, 144  
   wrist, 155  
 Inter-columnar fibres, 212  
 Inter-vertebral substance, 138  
 Intestinal canal, 501  
 Intumescencia gangliformis, 401  
 Iris, 448  
 Isthmus of the fauces, 502  
 Iter ad infundibulum, 379  
   a tertio ad quartum ventriculum, 379

## J.

Jacob's membrane, 450  
 Jejunum, 507  
 Joint, ankle, 165  
   elbow, 152

Joint, hip, 158  
   lower jaw, 145  
   knee, 160  
   shoulder, 152  
   wrist, 155  
 Jones, Mr., researches of, 464

## K.

Kidneys, 528  
 Kiernan, Mr., researches of, 520  
 King, Mr. T. W., researches of, 479  
 Krause, researches of, 222

## L.

Labia majora, 550  
   minora, 550  
 Labyrinth, 461  
 Lachrymal canals, 455  
   gland, 455  
   papillæ, 455  
   puncta, 455  
   sac, 456  
   tubercles, 453  
 Lacteals, 358  
 Lacunæ, 540  
 Lacus lachrymalis, 455  
 Lamina cinerea, 382  
   cribrosa, 446  
   spiralis, 464  
 Laqueus, 388  
 Laryngotomy, 487  
 Larynx, 485  
 Lateral ventricles, 378  
 Lauth, researches of, 542  
 Lee, Dr., researches of, 548  
 Lens, 451  
 Lenticular ganglion, 433  
 Lieberkuhn's follicles, 513  
 Lien succenturiatus, 528  
 Ligament, 135  
 LIGAMENTS, 129  
   acromio-clavicular, 151  
   alar, 141, 162  
   ankle, of the, 164  
   annular, of the ankle, 274  
     radius, 153  
     wrist, anterior, 155  
     posterior, 271  
   arcuatum externum, 217  
     internum, 217  
   atlo-axoid, 141  
   bladder, of, 532  
   breve plantæ, 166  
   calcaneo-astragaloid, 165  
     cuboid, 165  
     scaphoid, 166  
   capsular of the hip, 158  
     jaw, 143  
     rib, 145  
     shoulder, 152  
     thumb, 157  
   carpal, 156  
   carpo-metacarpal, 156  
   common anterior, 138  
     posterior, 138  
   conoid, 151  
   coracoid, 151  
   coraco-acromial, 151  
     clavicular, 151  
     humeral, 152  
   coronary, 154  
   of the knee, 161

LIGAMENTS—*continued.*

costo-clavicular, 150  
 sternal, 145  
 transverse, 145  
 vertebral, 144  
 xiphoid, 146  
 cotyloid, 159  
 crico-thyroidean, 487  
 crucial, 161  
 cruciform, 142  
 dentatum, 382  
 deltoid, 165  
 elbow, of the, 152  
 epiglott-hyoidean, 488  
 glenoid, 152  
 hip joint, of the, 158  
 hyo-epiglottic, 487  
 ilio-femoral, 159  
 inter-articular, of ribs, 145  
 inter-clavicular, 150  
 inter-osseous, 163, 166  
   calcaneo-astragal., 166  
   peroneo-tibial, 163  
 radio-ulnar, 153  
 inter-spinous, 139  
 inter-transverse, 140  
 inter-vertebral, 138  
 knee, of the, 160  
 lateral of the ankle, 165  
   elbow, 153  
   jaw, 143  
   knee, 160  
   phalanges, foot, 168  
   phalanges, hand, 157  
   wrist, 155  
 liver, of the, 516  
 longum plantæ, 166  
 lumbo-iliac, 146  
 lumbo-sacral, 146  
 metacarpo-phalangeal, 157  
 metatarsal-phalangeal, 167  
 mucosum, 162  
 nuchæ, 199  
 oblique, 154  
 obturator, 149  
 occipito-atloid, 140  
   axoid, 141  
 odontoid, 141  
 orbicular, 154  
 palpebral, 453  
 patellæ, 160  
 peroneo-tibial, 163  
 phalanges of the foot, 167  
   of the hand, 157  
 plantar, long, 166  
 plantar, short, 166  
 posticum Winslowii, 160  
 pterygo-maxillary, 142  
 pubic, 149  
 radio-ulnar, 153  
 rhomboid, 150  
 rotundum, hepatis, 516  
 sacro-coccygean, 148  
 sacro-iliac, 147  
 sacro-ischiatic, anterior, 147  
   posterior, 148  
 stellate, 144  
 sternal, 145, 146  
 sterno-clavicular, 149  
 stylo-maxillary, 265  
 sub-flava, 139  
 sub-pubic, 149  
 supra-spinous, 139  
 suspensorium hepatis, 516

LIGAMENTS—*continued.*

suspensorium penis, 536  
 tarsal, 165  
 tarso-metatarsal, 167  
 teres, 159  
 thyro-arytenoid, 487  
 thyro-hyoidean, 487  
 tibio-fibular, 163  
 transverse, 164  
   of the acetabulum, 159  
   of the ankle, 164  
   of the atlas, 141  
   of the knee, 159  
   of the metacarpus, 157  
   of the metatarsus, 167  
   of the scapula, 151  
   of the semilunar cartilages, 161  
 trapezoid, 151  
 tympanum, of the, 468  
 umbilical, 532  
 wrist, of the, 155  
 Zinn, of, 177  
 Ligamentum nuchæ, 199  
 Limbus luteus, 449  
 Linea alba, 212  
 Lineæ semi-lunares, 212  
   transversæ, 212, 373  
 Linguetta laminosa, 380  
 Lips, 502  
 Liquor Cotunnii, 465  
   Morgagni, 451  
   Scarpa, of, 466  
 Liver, 515  
 Lobules of the liver, 519  
 Lobuli testis, 542  
 Lobulus auris, 456  
   pneumogastricus, 381  
 Lobus caudatus, 518  
   quadratus, 518  
   Spigelii, 518  
 Locus niger, 383  
   perforatus, 383  
 Lower, notice of, 478  
 Lumbar fascia, 215  
   regions, 496  
 Lungs, 492  
 Lunula, 472  
 Lymphatic glands and vessels, 351  
   axillary, 354  
   bronchial, 357  
   cardiac, 358  
   cervical, 354  
   head and neck, 353  
   heart, 357  
   iliac, 357  
   inguinal, 355  
   intestines, 358, 359  
   kidney, 359  
   lacteals, 358  
   liver, 358  
   lower extremity, 355  
   lungs, 357  
   mediastinal, 356  
   mesenteric, 358  
   pelvic viscera, 359  
   popliteal, 355  
   spleen, 358  
   stomach, 358  
   testicle, 359  
   trunk, 356  
   upper extremity, 354  
   viscera, 357  
 Lyra, 377

## M.

Malleus, 458  
 Malpighian bodies, 528, 530  
 Mammæ, 551  
 Mammary gland, 552  
 Mastoid cells, 460  
 Matrix, 546  
 Maxillo-pharyngeal space, 192  
 Mayo, Mr., researches of, 395  
 Meatus, auditorius, 457  
   urinaris, female, 545  
   male, 536  
 Meatuses of the nares, 444  
 Meckel's ganglion, 435  
 Meconium, 559  
 Mediastinum, 496  
   testis, 542  
 Medulla of bones, 44  
   innominata, 383  
   oblongata, 385  
 Meibomian glands, 454  
 Meibomius, notice of, 454  
 Membrana dentata, 390  
   nictitans, 455  
   pigmenti, 448  
   pupillaris, 555  
   sacciformis, 153  
   tympani, 458  
 Membrane, choroid, 448  
   hyaloid, 451  
   Jacob's, 450  
   of the ventricles, 380  
 Membranous urethra, 539  
 Meniscus, 133  
 Mesenteric glands, 358  
 Mesentery, 498  
 Meso-colon, 498  
 Meso-rectum, 499  
 Metacarpus, 112  
 Metatarsus, 127  
 Mitral valves, 482  
 Modiolus, 463  
 Mons Veneris, 550  
 Monticulus cerebelli, 382  
 Morgagni, notice of, 451  
 Morsus diaboli, 549  
 Motor tract, 391  
 Mouth, 502  
 Mucous membrane, structure, 511  
 Müller, researches of, 45  
 MUSCLES, 168  
   general anatomy of, 168  
   development of, 172  
   structure, 169  
   abductor min. digiti, 240  
   abduc. min. dig. pedis, 260  
     indicis, 241  
     oculi, 177  
     pollicis, 238  
       pedis, 260  
   accelerator urinæ, 220  
   accessorius, 261  
   adductor brevis, 250  
     longus, 250  
     magnus, 250  
     min. digiti, 260  
     oculi, 177  
     pollicis, 239  
       pedis, 261  
   anconeus, 236  
   anterior auris, 185  
   anti-tragicus, 457  
   arytenoideus, 489

## MUSCLES—continued.

aryteno-epiglot. inf., 489  
   superior, 489  
 attollens aurem, 184  
   oculum, 177  
 attrahens aurem, 185  
 auricularus, 236  
 azygos uvulæ, 195  
 basio-glossus, 191  
 biceps flexor cruris, 251  
 cubiti, 229  
 biventer cervicis, 204  
 brachialis anticus, 230  
 buccinator, 183  
 bulbo-cavernosus, 220  
 cerato-glossus, 191  
 cervicalis ascendens, 204  
 circumflexus palati, 195  
 coccygeus, 222  
 complexus, 204  
 compressor nasi, 179  
   urethræ, 220  
 constrictor inferior, 192  
   isth. faucium, 192, 195  
   medius, 193  
   pharyngis, 192  
   superior, 193  
   vaginæ, 223  
 coraco-brachialis, 229  
 corrugator superciliî, 175  
 cremaster, 214  
 crico-arytenoid lat., 488  
   posticus, 488  
   thyroideus, 488  
 crureus, 248  
 cucullaris, 199  
 deltoid, 228  
 depressor ang. oris, 181  
   labii inferioris, 181  
   labii sup. alæque nasi, 181  
 depressor oculi, 177  
 detrusor urinæ, 532  
 diaphragm, 217  
 dilatator naris, 179  
 digastricus, 189  
 erector clitoridis, 551  
   penis, 220  
   spinæ, 203  
 extensor carpi rad. brev. 235  
 carpi rad. long., 235  
 carpi ulnaris, 236  
 coccygis, 206  
 digiti minimi, 236  
 digitor. brevis, 258  
 digitor. com., 235  
 digitor. longus, 253  
 indicis, 238  
 ossis metacarpi, 237  
 pollicis proprius, 254  
 primi internodii, 237  
 sec. internodii, 237  
 flexor accessorius, 261  
   brevis digiti minimi, 240  
   digiti minimi pedis, 262  
 carpi radialis, 232  
   ulnaris, 233  
 digitorum brevis, 260  
   profundus, 233  
   sublimis, 232  
 longus digit. pedis, 256  
 longus pollicis manus, 233  
   pedis, 256  
 ossis metacarpi, 239, 240  
 pollicis brevis, 239

MUSCLES—*continued.*

- pedis, 261
- longus, 256
- gastrocnemius, 254
- gemellus inferior, 246
- superior, 245
- genio-hyo-glossus, 190
- hyoideus, 190
- gluteus maximus, 244
- medius, 244
- minimus, 245
- gracilis, 251
- helicis major, 457
- minor, 457
- hyo-glossus, 190
- iliacus, 249
- indicator, 238
- infra-spinatus, 227
- inter-costales externi, 210
- interni, 210
- interossei manus, 241
- pedis, 259
- inter-spinales, 205
- inter-transversales, 205
- intra-costales, 210
- ischio-cavernosus, 220
- larynx, of the, 488
- latissimus dorsi, 199
- laxator tympani, 459
- levator anguli oris, 180
- scapulæ, 201
- ani, 222
- glandulæ thyroïd., 212
- labii inferioris, 182
- superioris, 180
- sup. alæq. nasi, 183
- menti, 182
- palati, 194
- palpebræ, 177
- levatores costarum, 203
- lingualis, 191
- longissimus dorsi, 203'
- longus colli, 197
- lumbricales manus, 240
- pedis, 261
- mallei externus, 459
- internus, 459
- masseter, 182
- multifidus spinæ, 206
- mylo-hyoideus, 190
- myrtiformis, 181
- naso-labialis, 180
- obliquus abdom. ext., 212
- abdom. int., 214
- capitis inferior, 205
- superior, 205
- oculi inferior, 178
- superior, 178
- obturator externus, 246
- internus, 245
- occipito-frontalis, 174
- omo-hyoideus, 188
- opponens digit. min., 240
- pollicis, 239
- orbicularis oris, 180
- palpebrarum, 175
- palato-glossus, 192, 195
- pharyngeus, 195
- palmaris brevis, 240
- longus, 232
- pectineus, 250
- pectoralis major, 225
- minor, 225
- peroneus brevis, 258

MUSCLES—*continued.*

- longus, 258
- tertius, 254
- plantaris, 255
- platysma-myoides, 186
- popliteus, 256
- posterior auris, 185
- pronator quadratus, 234
- radii teres, 231
- psoas magnus, 249
- parvus, 216
- pterygoideus ext., 183
- int., 184
- pyramidalis abdom., 216
- nasi, 179
- pyriformis, 245
- quadratus femoris, 246
- lumborum, 216
- menti, 181
- rectus abdominis, 216
- capitis ant. maj., 196
- min., 196
- lateralis, 205
- post. maj., 205
- min., 205
- femoris, 248
- oculi externus, 177
- inferior, 177
- internus, 177
- superior, 177
- retrahens aurem, 185
- rhomboideus major, 201
- minor, 201
- risorius Santorini, 186
- sacro-lumbalis, 203
- sartorius, 247
- scalenus anticus, 196
- posticus, 197
- semi-spinalis colli, 205
- dorsi, 205
- semi-membranosus, 252
- semi-tendinosus, 251
- serratus magnus, 226
- posticus inf., 202
- sup., 201
- soleus, 255
- sphincter ani, 222
- internus, 222
- spinalis dorsi, 203
- splenius capitis, 202
- colli, 202
- stapedius, 459
- sterno-hyoideus, 188
- mastoideus, 186
- thyroideus, 188
- stylo-glossus, 192
- hyoideus, 189
- pharyngeus, 193
- subclavius, 226
- subcreureus, 248
- subscapularis, 226
- superior auris, 184
- supinator brevis, 237
- longus, 234
- supra-spinalis, 206
- supra-spinatus, 227
- temporal, 182
- tensor palati, 195
- tarsi, 176
- tympani, 459
- vaginæ fem., 247
- teres major, 228
- minor, 227
- thyro-arytenoideus, 488

MUSCLES—*continued.*

- epiglottideus, 489
  - hyoideus, 188
  - ibialis anticus, 253
  - posticus, 257
  - trachelo-mastoideus, 204
  - tragicus, 457
  - transversalis abdom., 215
  - colli, 204
  - transversus auris, 457
  - pedis, 262
  - perinei, 221, 223
  - trapezius, 199
  - triangularis oris, 181
  - sterni, 211
  - triceps extens. cruris, 248
  - cubiti, 230
  - trochlearis, 178
  - ureters, of the, 533
  - vastus externus, 248
  - internus, 248
  - zygomatikus major, 181
  - minor, 181
- Muscular fibre, 169
- Musculi pectinati, 479
- Myolemma, 169
- Myoline, 171
- Myopia, 452

## N.

- Naboth, ovula of, 547
- Nagel, Mr., researches of, 528
- Nails, 472
- Nares, 444
- Nasal duct, 456
- fossæ, 442
- Nasmyth, Mr., researches of, 94, 511
- Nates cerebri, 379

## NERVES.

- general anatomy, 361
- abducentes, 401
- accessorius, 404
- acromiales, 412
- auditory, 403
- auricularis anterior, 400
- magnus, 412
- posterior, 402
- brachial, 414
- buccal, 399
- cardiac, 407
- cardiacus inferior, 438
- magnus, 439
- medius, 438
- minor, 439
- superior, 438
- cervical, 410
- cervico-facial, 403
- chorda tympani, 402
- ciliary, 398
- circumflex, 420
- claviculares, 412
- coccygeal, 426
- cochlear, 404
- communicans noni, 412
- peronei, 428
- poplitei, 429
- cranial, 393
- crural, 424
- cutaneous ext. brach., 416
- ext. femoralis, 423
- int. brachialis, 416
- minor, 416
- med femoralis, 424

NERVES—*continued.*

- post. femoralis, 429
- spiralis, 419
- dental anterior, 399
- inferior, 400
- posterior, 399
- descendens noni, 409
- digastric, 402
- dorsal, 420
- eighth pair, 404
- facial, 401
- femoral, 424
- fifth pair, 396
- first pair, 393
- fourth pair, 395
- frontal, 397
- gastric, 407
- genito-crural, 423
- glosso-pharyngeal, 404
- gluteal, 428
- inferior, 428
- gustatory, 400
- hypo-glossal, 408
- ilio-scrotal, 423
- inferior maxillary, 399
- infra-trochlear, 396
- inguino-cutaneous, 423
- intercostal, 420
- intercosto-humeral, 421
- interosseous anterior, 417
- posterior, 419
- ischiatricus major, 429
- minor, 428
- Jacobson's, 404
- lachrymal, 397
- laryngeal inferior, 407
- superior, 406
- lingual, 396
- lumbar, 422
- lumbo-sacral, 426
- masseteric, 399
- maxillaris inferior, 399
- superior, 396
- median, 416
- molles, 438
- motores oculorum, 395
- musculo-cutan., arm, 416
- leg, 432
- musculo-spiral, 419
- mylo-hyoidean, 397
- nasal, 397
- naso-ciliaris, 397
- palatine, 435
- ninth pair, 408
- obturator, 426
- occipitalis major, 413
- minor, 412
- olfactory, 393
- ophthalmic, 397
- optic, 394
- orbital, 398
- palatine anterior, 435
- posterior, 435
- palmar, deep, 417
- superficial, 417
- pathetici, 395
- perforans Casserii, 416
- perineal, 428
- peroneo-cutaneous, 428
- peroneal, 431
- petrosal, 434
- petrosus minor, 436
- pharyngeal, 405, 406
- phrenic, 413

NERVES—*continued.*

- plantar, external, 431
  - internal, 431
  - pneumogastric, 405
  - popliteal, 429
  - vortio dura, 401
  - mollis, 403
  - pterygoid, 399
  - pudendalis, 429
  - pudic, internal, 428
  - pulmonary, 407
  - radial, 419
  - recurrent, 407
  - respiratory, external, 415
  - sacral, 426
  - saphenous, external, 430
  - long, 425
  - short, 425
  - second pair, 394
  - seventh pair, 401
  - sixth pair, 401
  - spheno-palatine, 435
  - spinal, 409
  - spinal accessory, 408
  - splanchnicus major, 441
  - minor, 441
  - stylo-hyoid, 403
  - subcutaneous malæ, 398
  - sub-occipital, 403
  - subruñ, 438
  - subscapular, 415
  - superficialis colli, 412
  - cordis, 438
  - superior maxillary, 398
  - supra-orbital, 396
  - scapular, 415
  - trochlear, 395
  - sympatheticus major, 433
  - temporal, 399
  - temporo-facial, 403
  - malar, 400
  - third pair, 395
  - thoracic, long, 415
  - short, 415
  - thyro-hyoidean, 409
  - tibialis anticus, 432
  - posticus, 430
  - trifacial, 396
  - trigeminus, 396
  - trochlearis, 395
  - tympanic, 402
  - ulnar, 418
  - vagus, 404
  - vestibular, 404
  - Vidian, 435
  - Wrisberg, of, 416
  - Neurilemma, 361
  - Nipple, 552
  - Nodulus, 382
  - Nodus encephali, 385
  - Nose, 442
  - Nucleus Olivæ, 386
  - Nymphæ, 550
- O.
- Œsophagus, 505
  - Omentum, gastro-splenic, 498
  - great, 498
  - lesser, 498
  - Omphalo-mesenteric vessels, 559
  - Optic commissure, 393
  - thalami, 378
  - Orbicular, os, 459

- Orbits, 90
  - Ossicula auditus, 458
  - Ossification, 49
  - Ostium abdominale, 549
  - uterinum, 549
  - Otoconites, 466
  - Ovaries, 549
  - Ovula Graafiana, 550
  - Naboth, of, 547
- P.
- Pachionian glands, 371
  - Palate, 502
  - Palmar arch, 306
  - Palpebræ, 453
  - Palpebral ligaments, 454
  - sinuses, 454
  - Pancreas, 526
  - Panizza, researches of, 437
  - Papillæ of the nail, 472
  - of the skin, 469
  - of the tongue, 467
  - calyciformes, 467
  - circumvallatæ, 467
  - conicæ, 467
  - filiformes, 467
  - fungiformes, 468
  - Parotid gland, 503
  - Pelvis, 117
  - viscera of, 532
  - Penis, 536
  - Pericardium, 475
  - Perichondrium, 46
  - Pericranium, 46
  - Periosteum, 46
  - Peritoneum, 497
  - Perspiratory ducts, 474
  - Pes accessorius, 37
  - anserinus, 401
  - hippocampi, 376
  - Petit, notice of, 452
  - Peyer, notice of, 513
  - Peyer's glands, 513
  - Phalanges, 113, 128
  - Pharynx, 504
  - Pia mater, 371
  - Pigmentum nigrum, 448
  - Pillars of the palate, 503
  - Pineal gland, 379
  - Pinna, 456
  - Pituitary gland, 384
  - membrane, 445
  - Pleuræ, 495
  - Plexus, aortic, 441
  - axillary, 414
  - brachial, 414
  - cardiac, 440
  - carotid, 436
  - cavernosus, 436
  - cervical, anterior, 411
  - posterior, 413
  - choroid, 375
  - cœliac, 440
  - coronary, 439
  - gangliformis, 401
  - gastric, 440
  - hepatic, 440
  - hypogastric, 442
  - lumbar, 419
  - mesenteric, inferior, 441
  - superior, 441
  - œsophageal, 404
  - pharyngeal, 402

PLEXUS—*continued.*

- phrenic, 441
- prostatic, 340
- pterygoid, 330
- pulmonary, 403, 439
- renal, 441
- sacral, 424
- solar, 441
- spermatic, 441
- splenic, 441
- submaxillary, 397
- supra-renal, 441
- uterine, 341
- vertebral, 437
- vesical, 341
- Plicæ semilunaris, 455
- Plicæ longitudinales, 509
- Pneumogastric lobule, 382
- Polypus of the heart, 476
- Pomum Adami, 485
- Pons Tarini, 385
  - Varolii, 385, 389
- Pores, 471
- Portal vein, 349
- Portio dura, 401
  - mollis, 403
- Porus opticus, 446
- Poupart's ligament, 212
- Prepuce, 536
- Presbyopia, 452
- Processus e cerebello ad testes, 382
  - clavatus, 386
  - vermiformes, 384
- Promontory, 460
- Prostate gland, 534
- Prostatic urethra, 538
- Protuberantia annularis, 385
- Pulmonary artery, 494
  - plexuses, 494
  - sinuses, 480
  - veins, 351
- Puncta lachrymalia, 455
  - vasculosa, 373
- Pupil, 448
- Purkinje, corpuscles of, 45
- Pylorus, 506
- Pyramid, 460
- Pyramids, anterior, 386
  - posterior, 380
  - of Wistar, 72

## R.

- Raphe, corporis callosi, 373
- Receptaculum chyli, 359
- Rectum, 513
- Regions, abdominal, 496
- Reil, island of, 383
- Respiratory nerves, 495
  - tract, 388
- Recte mucosum, 471
  - testis, 543
- Retina, 449
- Ribs, 101
- Ribes, ganglion of, 433
- Rima glottidis, 488
- Ring, external abdominal, 212
  - femoral, 278
  - internal abdominal, 271
- Rugæ, 510, 546
- Ruysch, notice of, 449

## S.

- Sacculus communis, 465

- Sacculus laryngis, 490
  - proprius, 465
- Salivary glands, 503
- Saphenous opening, 273
  - veins, 344
- Scala tympani, 463
  - vestibuli, 463
- Scarf-skin, 430
- Scarpa, notice of, 466
- Schindylesis, 83
- Schneider, notice of, 445
- Schneiderian membrane, 445
- Sclerotic coat, 445
- Serotum, 540
- Searle, Mr., researches of, 482
- Sebaceous glands, 470
- Semicircular canals, 452
- Semilunar fibro-cartilages, 161
  - valves, 480
- Septum auricularum, 478
  - crurale, 273
  - lucidum, 376, 389
  - pectiniforme, 537
  - scroti, 540
- Serous membrane, structure, 501
- Sesamoid bones, 129
- Sheath of the rectus, 216
- Sigmoid valves, 480
- Sinuses, structure, 337
- Sinus, aortic, 480
  - basilar, 340
  - cavernous, 340
  - circular, 340
  - fourth, 339
  - lateral, 339
  - longitudinal, inferior, 339
    - superior, 338
  - occipital, anterior, 339
    - posterior, 339
  - petrosal; inferior, 340
    - superior, 340
  - pocularis, 539
  - prostatic, 539
  - pulmonary, 480
  - rectus or straight, 339
  - rhomboidalis, 379
  - transverse, 341
  - Valsalva, of, 480
- Skeleton, 49
- Skin, 468
- Skull, 58
- Socia parotidis, 503
- Scemmering, notice of, 450
- Soft palate, 502
- Spermatic canal, 271
  - cord, 540
- Spheno-palatine ganglion, 435
- Spigel, notice of, 518
- Spinal cord, 389
  - nerves, 409
  - veins, 348
- Spleen, 526
- Spongy part of the urethra, 539
- Stapes, 458
- Stenon, notice of, 503
- Stenon's duct, 503
- Stomach, 505
- Striæ, medullares, 376
  - muscular, 169
- Sub-arachnoidean fluid, 371
  - space, 371
  - tissue, 372
- Sublingual gland, 504
- Submaxillary gland, 503



Substantia, cinerea, 372  
 perforata, 383  
 Sudoriferous ducts, 471  
 Sudoriparous glands, 471  
 Sulcus hepatis, 518  
 longitudinal cordæ spinal., 391  
 Supercilia, 453  
 Superficial fascia, 264  
 Supra-renal capsules, 527  
 Suspensory ligament, liver, 516  
 penis, 536  
 Sutures, 83  
 Sylvius, notice of, 372  
 Sympathetic nerve, 438  
 Symphysis, 130  
 Synarthrosis, 130  
 Synovia, 137  
 Synovial membrane, 136

## T.

Tapetum, 449  
 Tarin, Peter, notice of, 374  
 Tarsal cartilages, 453  
 Tarsus, 124  
 Teeth, 92  
 Tendo Achillis, 254  
 oculi, 175  
 Tendon, 169  
 Tenia hippocampi, 376  
 semicircularis, 374  
 Tarini, 374  
 Tentorium cerebelli, 369  
 Testes cerebri, 379  
 Testicles, 540  
 descent, 561  
 Thalami optici, 378  
 Thebesius, notice of, 417  
 Theca vertebralis, 389  
 Thoracic duct, 359  
 Thorax, 475  
 Thymus gland, 556  
 Thyro-hyoid membrane, 487  
 Thyroid axis, 298  
 cartilage, 485  
 gland, 492  
 Tod, Mr., researches of, 457  
 Tongue, 467  
 Tonsils, 503  
 cerebelli, 381  
 Torcular Herophili, 339  
 Toynee, Mr., researches of, 530  
 Trachea, 491  
 Tractus motorius, 391  
 opticus, 390  
 spiralis, 463  
 Tragus, 456  
 Triangles of the neck, 188  
 Tricuspid valves, 479  
 Trigone vesicale, 534  
 Trochlearis, 178  
 Tuber cinereum, 385  
 Tubercula quadrigemina, 380  
 Tuberculum Loweri, 478  
 Tubuli lactiferi, 552  
 seminiferi, 542  
 uriniferi, 529  
 Tunica albuginea oculi, 445  
 testis, 542  
 erythroides, 541  
 nervea, 446  
 Ruyschiana, 449  
 vaginalis, 542  
 oculi, 445

Tunica vasculosa testis, 542  
 Tutamina oculi, 453  
 Tympanum, 458  
 Tyrrell, Mr., researches of, 268  
 Tyson's glands, 536

## U.

Umbilical region, 496  
 Uraclius, 532  
 Ureter, 530  
 Urethra, female, 544  
 male, 537  
 Uterus, 546  
 Utriculus communis, 465  
 Uvea, 447  
 Uvula cerebelli, 382  
 palati, 503  
 vesicæ, 534

## V.

Vagina, 545  
 Vallecule, 371  
 Valsalva, sinuses of, 480  
 Valve, arachnoid, 370  
 Bauhini, 510  
 coronary, 478  
 Eustachian, 478  
 ileo-cæcal, 510  
 mitral, 481  
 pyloric, 510  
 rectum, of the, 511  
 semilunar, 480  
 Tarin, of, 372  
 tricuspid, 478  
 Vicussens, of, 370  
 Valvula conniventes, 510  
 Varolius, notice of, 385  
 Vasa efferentia, 543  
 lactea, 358  
 lymphatica, 357  
 pompiniformia, 543  
 recta, 543  
 vasorum, 281  
 Vasculum, aberrans, 543  
 Vas deferens, 540  
 VEINS, 334  
 structure, 335  
 angular, 337  
 auricular, 337  
 axillary, 343  
 nzygos major, 348  
 minor, 348  
 basilic, 342  
 cardiac, 349  
 cava, inferior, 346  
 superior, 345  
 cephalic, 343  
 cerebellar, 338  
 cerebral, 338  
 coronary, 349  
 corpora striata, 374  
 diploe, 337  
 dorsalis penis, 346  
 dorsi-spinal, 348  
 emulgent, 347  
 facial, 336  
 femoral, 344  
 frontal, 336  
 Galeni, 338, 377  
 gastric, 350  
 hepatic, 348  
 iliac, 345

VEINS—*continued.*

- innominata, 345
  - intercostal, superior, 348
  - jugular, 341
  - lumbar, 347
  - mastoid, 337
  - maxillary, internal, 337
  - median, 343
    - basilic, 343
    - cephalic, 343
  - medulli-spinal, 349
  - meningo-rachidian, 342, 348
  - mesenteric, inferior, 349
    - superior, 349
  - occipital, 337
  - ovarian, 347
  - parietal, 339
  - popliteal, 344
  - portal, 349
  - profunda femoris, 344
  - prostatic, 346
  - pulmonary, 351, 495
  - radial, 343
  - renal, 347
  - salvatella, 342
  - saphenous, external, 344
    - internal, 344
  - spermatic, 347
  - spinal, 348
  - splenic, 350
  - subclavian, 343
  - temporal, 337
  - temporo-maxillary, 337
  - Thebesii, 349
  - thyroid, 342
  - ulnar, 342
  - uterine, 346
  - vertebral, 341, 348
  - vesical, 346
- Volun interpositum, 377
- medullare, 380
  - pendulum palati, 502

- Venæ comites, 339
  - Galenii, 378
  - vorticosa, 448
- Ventricle of Arantius, 380
- Ventricles of the brain, 378
  - fifth, 376
  - fourth, 379
  - lateral, 373
  - third, 377
    - of the heart, 479, 481
    - of the larynx, 490
- Vermiform process, 382
- Vertebral aponeurosis, 200
  - column, 50
- Veru montanum, 539
- Vesiculæ seminales, 535
- Vestibule, 462
- Vestibulum vaginæ, 551
- Vibrissæ, 453
- Vidius, Vidus, notice of, 435
- Vieussens, notice of, 380
- Villi, 512
- Vitreous humour, 451
- Vulva, 550

## W.

- Wharton, notice of, 468
- Wharton's duct, 504
- Willis, notice of, 368
- Wilson's muscles, 220
- Winslow, notice of, 500
- Wistar, pyramids of, 73
- Wrisberg, nerve of, 416

## Z.

- Zinn, notice of, 450
- Zonula ciliaris, 450
  - of Zinn, 450
- Zygoma, 64

---

MARCH, 1853.

---

CATALOGUE

OF

MEDICAL AND SURGICAL WORKS,

PUBLISHED BY

BLANCHARD & LEA,

PHILADELPHIA,

AND

FOR SALE BY ALL BOOKSELLERS.

---

**ILLUSTRATED MEDICAL CATALOGUE.**

BLANCHARD & LEA have now ready a Catalogue of their Medical and Surgical Publications, containing descriptions of the works, with Notices of the Press and specimens of the Illustrations, making a pamphlet of forty-eight large octavo pages. It has been prepared with great care, and without regard to expense, forming one of the most beautiful specimens of typographical execution as yet issued in this country. Copies sent by mail, free of postage, to Physicians, on application to the Publishers.

## TO THE MEDICAL PROFESSION.

The Subscribers subjoin a list of their publications in medical and other sciences, to which they would invite the attention of the Profession, with the full confidence that they will be found to correspond in every respect with the description. They are to be had of all the principal booksellers throughout the Union, from whom, or from the publishers particulars respecting price, &c., may be had on application.

*Philadelphæ, March, 1853.*

BLANCHARD & LEA.

### DICTIONARIES, JOURNALS, &c.

- American Journal of the Medical Sciences, quarterly, at \$5 a year.  
 Cyclopædia of Practical Medicine, by Forbes, Tweedie, &c., edited by Dunglison, in 4 super royal volumes, 3154 double-columned pages.  
 Dunglison's Medical Dictionary, 9th ed., 1 vol. imp. 8vo., 928 large pages.  
 Hoblyn's Dictionary of Medical Terms, by Hays, 1 vol. large 12mo., 402 pages, double columns.  
 Neill and Smith's Compend of the Medical Sciences, 2d ed., enlarged, 1 vol., large 12mo., 1000 pp., 350 cuts.  
 Medical News and Library, monthly, at \$1 a year.

### ANATOMY.

- Anatomical Atlas, by Smith and Horner, large imp. 8vo., 650 figures. New and cheaper ed.  
 Horner's Special Anatomy and Histology, new edition, 2 vols. 8vo., many cuts.  
 Horner's United States Dissector, 1 vol. large royal 12mo., many cuts, 444 pages.  
 Macleise's Surgical Anatomy, now complete in 1 large imp. 4to. vol., strongly bound, with 68 magnificent colored plates.  
 Sibson's Medical Anatomy, imp. 4to., with col'd pl's, to match "Macleise." Part I, (preparing.)  
 Sharpey and Quain's Anatomy, by Leidy, 2 vols. 8vo., 1300 pages, 511 wood-cuts.  
 Wilson's Human Anatomy, by Goddard, 4th edition, 1 vol. 8vo., 252 wood-cuts, 580 pp.  
 Wilson's Dissector, by Goddard. New edition, with cuts, 1 vol. 12mo., 458 pages.

### PHYSIOLOGY.

- Carpenter's Principles of Human Physiology. By F. G. Smith. 1 large vol. 8vo., many illustrations, new and improved edition, (Now ready.)  
 Carpenter's Elements, or Manual of Physiology, new and improved ed., 1 vol. 8vo., 566 pp.  
 Carpenter's General and Comparative Physiology, 1 vol. 8vo., (new edition, preparing.)  
 Carpenter on the Varieties of Mankind, 1 vol. royal 12mo., with illustrations, (preparing.)  
 Dunglison's Human Physiology, 7th edition, 2 vols. 8vo., 1428 pages, and 472 wood-cuts.  
 Harrison on the Nerves, 1 vol. 8vo., 292 pages.  
 Kirkes and Paget's Physiology, 1 vol. 12mo., many cuts, 550 pages.  
 Longet's Physiology. Translated by F. G. Smith. 2 vols. 8vo., many cuts, (preparing.)  
 Matteucci on the Physical Phenomena of Living Beings, 1 vol. 12mo., 358 pp., cuts.  
 Solly on the Brain, 1 vol. 8vo., 496 pp., 118 cuts.  
 Todd and Bowman's Physiology. Parts I, II, and III., 1 vol. 8vo., 156 cuts. Part IV, (publishing in the Med. News and Library for 1853.)

### PATHOLOGY.

- Abererombie on the Brain, 1 vol. 8vo., 324 pp.  
 Blakiston on Diseases of the Chest, 1 vol., 384 pp.  
 Blood and Urine Manuals, by Reese, Griffith, and Markwick, 1 vol. 12mo., with plates.  
 Budd on the Liver, 1 vol. 8vo., 392 pages, plates and cuts, new and improved ed., (just ready.)  
 Burrows on Cerebral Circulation, 1 vol. 8vo., 216 pages, with 6 colored plates.  
 Billing's Principles, new and improved edition, 1 vol. 8vo., 250 pages, (just issued.)  
 Bird on Urinary Deposits, 12mo., new and improved edition, (just issued.)  
 Copland on Palsy and Apoplexy, 12mo., 236 pp.  
 Frick on Renal Affections, 1 vol. 12mo., cuts.  
 Gluge's Pathological Histology, 1 vol. imp. 4to., with colored plates, (now ready.)  
 Hasse's Pathological Anatomy, 8vo., 379 pages.

- Hope on the Heart, new ed., pl's, 1 vol. 8vo., 572 p.  
 Philips on Scrofula, 1 vol. 8vo., 350 pages.  
 Ricord on Venereal, new ed., 1 vol. 8vo., 340 pp.  
 Rokitsansky's Pathological Anatomy, 2 vols. 8vo., (preparing.)  
 Stanley on the Bones, 1 vol. 8vo., 286 pages.  
 Simon's General Pathology, 1 vol. 8vo.  
 Whitehead on Sterility and Abortion, 1 vol. 8vo., 368 pages.  
 Williams' Principles of Medicine, by Clymer, 2d edition, 440 pages, 1 vol. 8vo.  
 Williams on the Respiratory Organs, by Clymer, 1 vol. 8vo., 500 pages.

### PRACTICE OF MEDICINE.

- Ashwell on Females, 2d ed., 1 vol. 8vo., 520 pp.  
 Barlow's Practice of Medicine, (preparing.)  
 Bennet on the Uterus, 3d edition, 1 vol. 8vo., 356 pages, (now ready.)  
 Bartlett on Fevers, 3d edition, 600 pages.  
 Benedict's Compendium of Chapman's Lectures, 1 vol. 8vo., 258 pages.  
 Chapman on Fevers, Gout, Dropsy, &c. &c., 1 vol. 8vo., 450 pages.  
 Colombat de L'Isère on Females, by Meigs, 1 vol. 8vo., 720 pages, cuts. New edition.  
 Condie on the Diseases of Children, 3d edition, 1 vol. 8vo.  
 Churchill on the Diseases of Infancy and Childhood, 1 vol. 8vo.  
 Churchill on the Diseases of Females, new ed., rev'd by the author, 1 vol. 8vo., (now ready.)  
 Churchill's Monographs of the Diseases of Females, 1 vol. 8vo., now ready, 450 pages.  
 Clymer on Fevers, in 1 vol. 8vo., 600 pages.  
 Day on Old Age, 1 vol. 8vo., 226 pages.  
 Dewees on Children, 9th ed., 1 vol. 8vo., 548 pp.  
 Dewees on Females, 9th ed., 1 vol. 8vo., 532 p. pls.  
 Dunglison's Practice of Medicine, 3d edition, 2 vols. 8vo., 1500 pages.  
 Meigs' Letters on Diseases of Females, 1 vol. 8vo., 690 pp., 2d ed., improved.  
 Meigs on Diseases of Infancy, 1 vol. 8vo., 216 pp.  
 Neligan on Diseases of the Skin, 1 vol. royal 12mo., (now ready.)  
 Thomson on the Sick Room, 12mo., 360 pages.  
 Wilson on the Skin, 1 vol. 8vo., 3d ed., 480 pp. Same work, with fifteen plates.  
 Wilson on Syphilis, 1 vol. 8vo., with beautiful colored plates, (now ready.)  
 Watson's Principles and Practice of Physic, 3d edition by Condie, 1 vol. 8vo., 1060 large pages.  
 West's Lectures on the Diseases of Infancy and Childhood. 1 vol. 8vo., 452 pp.  
 Walshe on the Heart and Lungs. A new work, now ready, 1 vol. royal 12mo., 512 pp.  
 What to Observe at the Bed-side.—A Clinical Manual, 1 vol. royal 12mo., (now ready.)

### SURGERY.

- Brodie on Urinary Organs, 1 vol. 8vo., 214 pages.  
 Brodie on the Joints, 1 vol. 8vo., 216 pages.  
 Brodie's Lectures on Surgery, 1 vol. 8vo., 350 pp.  
 Brodie's Select Surgical Works, 780 pp. 1 vol. 8vo.  
 Chelius' System of Surgery, by South and Norris, in 3 large 8vo. vols., near 2200 pages.  
 Cooper's (Bransby B.) Lectures on Principles and Practice of Surgery, 1 large vol. 8vo., 750 pp.  
 Cooper on Dislocations and Fractures, 1 vol. 8vo., 500 pages, many cuts, (new edition.)  
 Cooper on Hernia, 1 vol. imp. 8vo., many plates  
 Cooper on the Testis and Thymus Gland, 1 vol. imperial 8vo., many plates.  
 Cooper on the Anatomy and Diseases of the Breast, Surgical Papers, &c. &c., 1 vol. imp. 8vo., pl't's.

Druitt's Principles and Practice of Modern Surgery, 1 vol. 8vo., 576 pages, 193 cuts, 4th ed.  
 Dufton on the Ear, 1 vol. 12mo., 120 pages.  
 Durlacher on Corns, Bunions, &c., 12mo., 134 pp.  
 Ear, Diseases of, a new work, (preparing.)  
 Fergusson's Practical Surgery, 1 vol. 8vo., 4th edition, 620 pages, 393 cuts, (now ready.)  
 Guthrie on the Bladder, 8vo., 150 pages.  
 Gross on Injuries and Diseases of Urinary Organs, 1 large vol. 8vo., 726 pp., many cuts.  
 Jones' Ophthalmic Medicine and Surgery, by Hays, 1 vol. 12mo., 529 pp., cuts and plates.  
 Liston's Lectures on Surgery, by Mütter, 1 vol. 8vo., 566 pages, many cuts.  
 Lawrence on the Eye, by Hays, 3d ed. much improved, many cuts, (nearly ready.)  
 Lawrence on Ruptures, 1 vol. 8vo., 480 pages.  
 Miller's Principles of Surgery, 3d ed., by Sargent, much enlarged, 1 vol. 8vo., with beautiful cuts, (now ready.)  
 Miller's Practice of Surgery, 1 vol. 8vo., 496 pp.  
 Malgaigne's Operative Surgery, by Brittan, with cuts, one 8vo. vol., 600 pages.  
 Maury's Dental Surgery, 1 vol. 8vo., 286 pages, many plates and cuts.  
 Pirrie's Principles and Practice of Surgery, edited by Neill, 1 vol. 8vo., 316 cuts, (now ready.)  
 Skey's Operative Surgery, 1 vol. large 8vo., many cuts, 662 pages, a new work.  
 Sargent's Minor Surgery, 12mo., 380 pp. 128 cuts.  
 Smith on Fractures, 1 vol. 8vo., 200 cuts, 314 pp.

#### MATERIA MEDICA AND THERAPEUTICS.

Bird's (Golding) Therapeutics, (preparing.)  
 Christison's and Griffith's Dispensatory, 1 large vol. 8vo., 216 cuts, over 1000 pages.  
 Carpenter on Alcoholic Liquors in Health and Disease, 1 vol. 12mo.  
 Carson's Synopsis of Lectures on Materia Medica and Pharmacy, 1 vol. 8vo., 208 pp.  
 Dunglison's Materia Medica and Therapeutics, 4th ed., much improved, 182 cuts, 2 vols. 8vo.  
 Dunglison on New Remedies, 6th ed., much improved, 1 vol. 8vo., 750 pages.  
 De Jongh on Cod-Liver Oil, 12mo.  
 Ellis' Medical Formulary, 9th ed., much improved, 1 vol. 8vo., 268 pages.  
 Griffith's Universal Formulary, 1 vol. 8vo., 560 pp.  
 Griffith's Medical Botany, a new work, 1 large vol. 8vo., 704 pp., with over 350 illustrations.  
 Mayne's Dispensatory, 1 vol. 12mo., 330 pages.  
 Mohr, Redwood, and Procter's Pharmacy, 1 vol. 8vo., 550 pages, 506 cuts.  
 Pereira's Materia Medica, by Carson, 3d ed., 2 vols. 8vo., much improved and enlarged, with 400 wood-cuts. Vol. I, ready. Vol. II, in press.  
 Royle's Materia Medica and Therapeutics, by Carson, 1 vol. 8vo., 689 pages, many cuts.

#### OBSTETRICS.

Churchill's Theory and Practice of Midwifery, a new and improved ed., by Condie, 1 vol. 8vo., 510 pp., many cuts.  
 Dewees' Midwifery, 11th ed., 1 vol. 8vo., 660 pp., plates.  
 Lee's Clinical Midwifery, 12mo., 238 pages.  
 Meigs' Obstetrics, 2d ed., enlarged, 1 vol. 8vo., 752 pp.,  
 Ramsbotham on Parturition, with many plates, 1 large vol., imperial 8vo., 520 pp. 6th edition.  
 Rigby's Midwifery, new ed., 1 vol. 8vo., 422 pp.  
 Smith (Tyler) on Parturition, 1 vol. 12mo., 400 pp.

#### CHEMISTRY AND HYGIENE.

Bowman's Practical Chemistry, 1 vol. 12mo., 97 cuts, 350 pages.  
 Brigham on Excitement, &c., 1 vol. 12mo., 204 pp.  
 Beale on Health of Mind and Body, 1 vol. 12mo.

Bowman's Medical Chemistry, 1 vol. 12mo., many cuts, 288 pages.  
 Dunglison on Human Health, 2d ed., 8vo., 464 pp.  
 Fowne's Elementary Chemistry, 3d ed., 1 vol. 12mo., much improved, many cuts.  
 Graham's Chemistry, by Bridges, new and improved edition. Part 1, 432 pp., 185 cuts, (now ready.)  
 Gardner's Medical Chemistry, 1 vol. 12mo. 400 pp.  
 Griffith's Chemistry of the Four Seasons, 1 vol. royal 12mo., 451 pages, many cuts.  
 Lehman's Physiological Chemistry, translated by Day, 1 vol. large 8vo., (preparing.)  
 Knapp's Chemical Technology, by Johnson, 2 vols. 8vo., 936 pp., 460 large cuts.

#### MEDICAL JURISPRUDENCE, EDUCATION, &c.

Bartlett's Philosophy of Medicine, 1 vol. 8vo.  
 Bartlett on Certainty in Medicine, 1 vol. 12mo.  
 Dickson's Essays on Life, Pain, Sleep, &c., in 1 vol. royal 12mo., 300 pages.  
 Taylor's Medical Jurisprudence, by Griffith, 1 vol. 8vo., new edition, 670 pp.  
 Taylor on Poisons, by Griffith, 1 vol. 8vo., 688 pp.

#### NATURAL SCIENCE, &c.

Arnott's Physics, 1 vol. 8vo., 484 pp., many cuts.  
 Ansted's Ancient World, 12mo., cuts, 382 pp.  
 Bird's Natural Philosophy, 1 vol. royal 12mo., 402 pages and 372 wood-cuts.  
 Brewster's Optics, 1 vol. 12mo. 423 pp. many cuts.  
 Broderip's Zoological Recreations, 12mo., 376 p.  
 Coleridge's Idea of Life, 12mo., 94 pages.  
 Carpenter's General and Comparative Physiology, 1 large 8vo. vol., many wood-cuts.  
 Dana on Zoophytes, being vol. 8 of Ex. Expedition, royal 4to., extra cloth.  
 Atlas to "Dana on Zoophytes," im. fol., col. pl's.  
 Gregory on Animal Magnetism, royal 12mo.  
 De la Beche's Geological Observer, 1 large 8vo. vol., many wood-cuts.  
 Hale's Ethnography and Philology of the U. S. Exploring Expedition, in 1 large imp. 4to. vol.  
 Herschel's Treatise on Astronomy, 1 vol. 12mo., 417 pages, numerous plates and cuts.  
 Herschel's Outlines of Astronomy, 1 vol. small 8vo., plates and cuts, new edition, (now ready.)  
 Humboldt's Aspects of Nature, 1 vol. 12mo., new edition.  
 Johnston's Physical Atlas, 1 vol. imp. 4to., half bound, 25 colored maps.  
 Knox on Races of Men, 1 vol. 12mo.  
 Lardner's Handbooks of Natural Philosophy, First Course, 1 vol. royal 12mo., with 426 cuts. Second Course, 1 vol. royal 12mo., 250 cuts, (now ready.) Third Course (Astronomy) preparing.  
 Müller's Physics and Meteorology, 1 vol. 8vo., 636 pp., with 540 wood-cuts and 2 col'd plates.  
 Small Books on Great Subjects, 12 parts, done up in 3 handsome 12mo. volumes.  
 Schoedler and Medlock's Book of Nature, 1 vol. crown 8vo., 600 wood-cuts, (nearly ready.)  
 Somerville's Physical Geography, 1 vol. 12mo., cloth, 540 pages, enlarged edition.  
 Weisbach's Mechanics applied to Machinery and Engineering, Vol. I. 8vo., 486 pp. 550 wood-cuts. Vol. II., 8vo., 400 pp., 340 cuts.

#### VETERINARY MEDICINE.

Clater and Skinner's Farrier, 1 vol. 12mo., 220 pp.  
 Youatt's Great Work on the Horse, by Skinner, 1 vol. 8vo., 448 pages, many cuts.  
 Youatt and Clater's Cattle Doctor, 1 vol. 12mo., 282 pages, cuts.  
 Youatt on the Dog, by Lewis, 1 vol. demy 8vo., 403 pages, beautiful plates.  
 Youatt on the Pig, 12mo., illustrated.

Other new and important works are in preparation.

Two Medical Periodicals, free of postage, for Five Dollars.

# THE AMERICAN JOURNAL OF THE MEDICAL SCIENCES,

EDITED BY ISAAC HAYS, M. D.,

IS PUBLISHED QUARTERLY, ON THE FIRST OF JANUARY, APRIL, JULY, AND OCTOBER,

*By BLANCHARD & LEA, Philadelphia.*

Each Number contains about Two Hundred and Eighty Large Octavo Pages,  
Appropriately Illustrated with Engravings on Copper, Wood, Stone, &c.

## THE MEDICAL NEWS AND LIBRARY

Is Published Monthly, and consists of

THIRTY-TWO VERY LARGE OCTAVO PAGES,

Containing the Medical Information of the day, as well as a Treatise of high character on some prominent department of Medicine.

In this manner its subscribers have been supplied with

WATSON'S LECTURES ON THE PRACTICE OF MEDICINE,

BRODIE'S CLINICAL LECTURES ON SURGERY,

TODD & BOWMAN'S PHYSIOLOGY,

WEST ON THE DISEASES OF INFANCY AND CHILDHOOD,

**AND MALGAIGNE'S OPERATIVE SURGERY.**

SIMON'S LECTURES ON GENERAL PATHOLOGY.

And the work at present appearing in its columns is

TODD & BOWMAN'S PHYSIOLOGY, Part IV. (See Advertisement, p. 15.)

### TERMS.

THE SUBSCRIPTION TO THE

AMERICAN JOURNAL OF THE MEDICAL SCIENCES

**IS FIVE DOLLARS PER ANNUM.**

When this amount is paid in advance, the subscriber thereby becomes entitled to the

**MEDICAL NEWS AND LIBRARY FOR ONE YEAR, GRATIS.**

When ordered separately, the price of the "News" is ONE DOLLAR per annum, invariably in advance.

## THE MEDICAL JOURNAL free of Postage.

Under the new Post-Office law of the first of October, 1852, the publishers have the privilege of prepaying the postage on Journals sent by mail to subscribers. They therefore avail themselves of it by offering to pay the postage on the AMERICAN MEDICAL JOURNAL, and MEDICAL NEWS AND LIBRARY sent to advance-paying subscribers.

Gentlemen, therefore, who remit their annual subscriptions for the year in advance, will receive, for the small sum of Five Dollars,

**THE AMERICAN JOURNAL OF THE MEDICAL SCIENCES**

AND

**THE MEDICAL NEWS AND LIBRARY,**

Embracing about Fifteen Hundred large octavo pages, mailed to any part of the United States, free of postage.

Those who remit during January and February, will be considered as entitled to the News, and will receive, free of postage, all the numbers of both periodicals which have not been mailed previous to their remittance; the publishers thus agreeing to prepay everything for which they have been paid in advance.

The advantages of a remittance before the opening of any year will thus be apparent.

Address

BLANCHARD & LEA, Philadelphia.

NEW AND ENLARGED EDITION OF  
**NEILL & SMITH'S COMPENDIUM—(NOW READY.)**  
**AN ANALYTICAL COMPENDIUM**  
 OF THE VARIOUS BRANCHES OF MEDICAL SCIENCE,  
 FOR THE USE AND EXAMINATION OF STUDENTS.

BY JOHN NEILL, M. D.,

Demonstrator of Anatomy in the University of Pennsylvania; Surgeon to the Pennsylvania Hospital:

AND

FRANCIS GURNEY SMITH, M. D.,

Professor of Institutes of Medicine in the Pennsylvania Medical College, &c.

*Second Edition, Revised and Improved.*

*In one very large and handsomely printed volume, royal 12mo., of over 1000 large pages, with about 350 illustrations, strongly bound in leather, with raised bands.*

PREFACE TO THE NEW EDITION.

The speedy sale of a large impression of this work has afforded to the authors gratifying evidence of the correctness of the views which actuated them in its preparation. In meeting the demand for a second edition, they have therefore been desirous to render it more worthy of the favor with which it has been received. To accomplish this, they have spared neither time nor labor in embodying in it such discoveries and improvements as have been made since its first appearance, and such alterations as have been suggested by its practical use in the class and examination-room. Considerable modifications have thus been introduced throughout all the departments treated of in the volume, but more especially in the portion devoted to the "Practice of Medicine," which has been entirely rearranged and rewritten. The authors therefore again submit their work to the profession, with the hope that their efforts may tend, however humbly, to advance the great cause of medical education.

Notwithstanding the increased size and improved execution of this work, the price has not been increased, and it is confidently presented as one of the cheapest volumes now before the profession.

**COOPER'S SURGICAL LECTURES—(Just Issued.)**

LECTURES ON THE  
**PRINCIPLES AND PRACTICE OF SURGERY.**

BY BRANSBY B. COOPER, F. R. S.,

Senior Surgeon to Guy's Hospital.

In one very large octavo volume, of seven hundred and fifty pages.

For twenty-five years Mr. Bransby Cooper has been surgeon to Guy's Hospital; and the volume before us may be said to consist of an account of the results of his surgical experience during that long period.

We cordially recommend Mr. Bransby Cooper's Lectures as a most valuable addition to our surgical literature, and one which cannot fail to be of service both to students and to those who are actively engaged in the practice of their profession.—*The Lancet*.

A good book by a good man is always welcome; and Mr. Bransby Cooper's book does no discredit to its paternity. It has reminded us, in its easy style and copious detail, more of Watson's Lectures, than any book we have seen lately, and we should not be surprised to see it occupy a similar position to that well-known work in professional estimation. It consists of seventy-five lectures on the most important surgical diseases. To analyze such a work is impossible, while so interesting is every lecture, that we feel ourselves really at a loss what to select for quotation.

The work is one which cannot fail to become a favorite with the profession; and it promises to supply an hiatus which the student of surgery has often to deplore.—*Medical Times*.

**MALGAIGNE'S SURGERY.—(Just Published.)**

**OPERATIVE SURGERY,**  
 BASED ON NORMAL AND PATHOLOGICAL ANATOMY.

BY J. F. MALGAIGNE.

TRANSLATED FROM THE FRENCH,

BY FREDERICK BRITTON, A. B., M. D., M. R. C. S. L.

WITH NUMEROUS ILLUSTRATIONS ON WOOD.

In one handsome octavo volume of nearly 600 pages.

This work has, during its passage through the columns of the "Medical News and Library" in 1850 and 1851, received the unanimous approbation of the profession, and in presenting it in a complete form the publishers confidently anticipate for it an extended circulation.

Certainly one of the best books published on operative surgery.—*Edinburgh Med. Journal*.

We can strongly recommend it both to practitioners and students, not only as a safe guide in the dissecting-room or operating-theatre, but also as a concise work of reference for all that relates to operative surgery.—*Forbes's Review*.

Dr. Britton has performed his task of translator and editor with much judgment. The descriptions are perfectly clear and explicit; and the author's occasional omissions of important operations proposed by British surgeons are judiciously supplied in brief notes.—*Medical Gazette*.

**GROSS ON URINARY ORGANS—(Lately Issued.)****A PRACTICAL TREATISE ON THE  
DISEASES AND INJURIES OF THE URINARY ORGANS.**

BY S. D. GROSS, M. D., &amp;c.,

Professor of Surgery in the New York University.

In one large and beautifully printed octavo volume, of over seven hundred pages.

With numerous Illustrations.

The author of this work has devoted several years to its preparation, and has endeavored to render it complete and thorough on all points connected with the important subject to which it is devoted. It contains a large number of original illustrations, presenting the natural and pathological anatomy of the parts under consideration, instruments, modes of operation, &c. &c., and in mechanical execution it is one of the handsomest volumes yet issued from the American press.

Dr. Gross has brought all his learning, experience, tact, and judgment to the task, and has produced a work worthy of his high reputation. We feel perfectly safe in recommending it to our readers as a monograph unequalled in interest and practical value by any other on the subject in our language; and we cannot help saying that we esteem it a matter of just pride, that another work so creditable to our country has been contributed to our medical literature by a Western physician.—*The Western Journal of Medicine and Surgery*

We regret that our limits preclude such a notice as this valuable contribution to our American medical literature merits. We have only room to say that the author deserves the thanks of the profession for this elaborate production; which cannot fail to augment the exalted reputation acquired by his former works, for which he has been honored at home and abroad.—*N. Y. Med. Gazette.*

**COOPER ON DISLOCATIONS.—New Edition—(Just Issued.)**

A TREATISE ON

**DISLOCATIONS AND FRACTURES OF THE JOINTS.**

BY SIR ASTLEY P. COOPER, BART., F. R. S., &amp;c.

EDITED BY BRANSBY B. COOPER, F. R. S., &amp;c.

WITH ADDITIONAL OBSERVATIONS BY PROF. J. C. WARREN.

A NEW AMERICAN EDITION,

In one handsome octavo volume, with numerous illustrations on wood.

After the fiat of the profession, it would be absurd in us to eulogize Sir Astley Cooper's work on Dislocations. It is a national one, and will probably subsist as long as English Surgery.—*Medico-Chirurg. Review.*

**WORKS BY THE SAME AUTHOR.**

COOPER (SIR ASTLEY) ON THE ANATOMY AND TREATMENT OF ABDOMINAL HERNIA.

1 large vol., imp. 8vo., with over 130 lithographic figures.

COOPER ON THE STRUCTURE AND DISEASES OF THE TESTIS, AND ON THE THYMUS

GLAND. 1 vol., imp. 8vo., with 177 figures on 29 plates.

COOPER ON THE ANATOMY AND DISEASES OF THE BREAST, WITH TWENTY-FIVE

MISCELLANEOUS AND SURGICAL PAPERS. 1 large vol., imp. 8vo., with 252 figures on 36 plates.

These three volumes complete the surgical writings of Sir Astley Cooper. They are very handsomely printed, with a large number of lithographic plates, executed in the best style, and are presented at exceedingly low prices.

**LISTON & MUTTER'S SURGERY.****LECTURES ON THE OPERATIONS OF SURGERY,  
AND ON DISEASES AND ACCIDENTS REQUIRING OPERATIONS.**

BY ROBERT LISTON, Esq., F. R. S., &amp;c.

EDITED, WITH NUMEROUS ADDITIONS AND ALTERATIONS,

BY T. D. MUTTER, M. D.,

Professor of Surgery in the Jefferson Medical College of Philadelphia.

In one large and handsome octavo volume of 566 pages, with 216 wood-cuts.

STANLEY ON THE BONES.—A Treatise on Diseases of the Bones. In one vol. 8vo., extra cloth. 286 pp.

BRODIE'S SURGICAL LECTURES.—Clinical Lectures on Surgery. 1 vol. 8vo., cloth. 350 pp.

BRODIE ON THE JOINTS.—Pathological and Surgical Observations on the Diseases of the Joints. 1 vol.

8vo., cloth. 216 pp.

BRODIE ON URINARY ORGANS.—Lectures on the Diseases of the Urinary Organs. 1 vol. 8vo., cloth.

214 pp.

\*\*\* These three works may be had neatly bound together, forming a large volume of "Brodie's Surgical Works." 750 pp.

RICORD ON VENEREAL.—A Practical Treatise on Venereal Diseases. With a Therapeutical Summary and Special Formulary. Translated by Sidney Doane, M. D. Fourth edition. 1 vol. 8vo. 340 pp.

DURLACHER ON CORNS, BUNIONS, &amp;c.—A Treatise on Corns, Bunions, the Diseases of Nails, and the General Management of the Feet. In one 12mo. volume, cloth. 134 pp.

GUTHRIE ON THE BLADDER, &amp;c.—The Anatomy of the Bladder and Urethra, and the Treatment of the Obstructions to which those Passages are liable. In one vol. 8vo. 150 pp.

LA WRENCE ON RUPTURES.—A Treatise on Ruptures, from the fifth London Edition. In one 8vo. vol. sheep. 450 pp.



A NEW TEXT-BOOK ON SURGERY—(Now Ready.)

**THE PRINCIPLES AND PRACTICE OF SURGERY.**

BY WILLIAM PIRRIE, F. R. S. E.,

Regius Professor of Surgery in the University of Aberdeen.

EDITED, BY JOHN NEILL, M. D.,

Demonstrator of Anatomy in the University of Pennsylvania, Lecturer on Anatomy in the Medical Institute of Philadelphia, &amp;c.

In one very handsome octavo volume, of 780 pages, with 316 illustrations.

The object of the author, in the preparation of this volume, has been to present to the student a complete text-book of surgery, embracing both the principles and the practice in their mutual relations, according to the latest state of scientific development. In accomplishing this, his aim has been to combine simplicity of arrangement, and conciseness and clearness of description, with the elucidation of sound principles and the modes of practice which his own experience and the teachings of the best authorities have shown to be the most successful. The Editor has, therefore, found but little to add respecting European surgery, and his efforts consequently have been directed towards introducing such improvements as have been pointed out by the practitioners of the United States, and such further information as may be requisite for the guidance of the student in this country.—Of the very numerous illustrations, the greater portion are from preparations in the author's museum, or from patients under his care. These have been reproduced with great care, and the whole is presented as an original and highly practical work, and at the same time as a handsome specimen of typographical execution.

However well it may be adapted for a text-book (and in this respect it may compete with the best of the kind) of this much our reading has convinced us, that as a systematic treatise, it is carefully and ably written, and can hardly fail to command a prominent position in the library of practitioners; though not complete in the fullest sense of the word, it nevertheless furnishes the student and practitioner with as chaste and concise a work as exists in our language. The additions to the volume by Dr. Neill, are judicious; and while they render it more complete, greatly enhance its practical value, as a work for practitioners and students.—*N. Y. Journal of Medicine.*

We know of no other surgical book of a reasonable size, wherein there is so much theory and practice, or where subjects are more soundly or clearly taught.—*The Stethoscope.*

Our impression is, that as a manual for students, Pirrie's is the best work extant.—*Western Med. and Surg. Journal.*

LIBRARY OF SURGICAL KNOWLEDGE.

**A SYSTEM OF SURGERY.**

BY J. M. CHELIUS.

TRANSLATED FROM THE GERMAN,  
AND ACCOMPANIED WITH ADDITIONAL NOTES AND REFERENCES,  
BY JOHN F. SOUTH.

Complete in three very large octavo volumes of nearly 2200 pages, strongly bound, with raised bands and double titles.

We do not hesitate to pronounce it the best and most comprehensive system of modern surgery with which we are acquainted.—*Medico-Chirurgical Review.*

The fullest and ablest digest extant of all that relates to the present advanced state of Surgical Pathology.—*American Medical Journal.*

If we were confined to a single work on Surgery, that work should be Chelius's.—*St. Louis Med. Journal.*

As complete as any system of Surgery can well be.—*Southern Medical and Surgical Journal.*

The most finished system of Surgery in the English language.—*Western Lancet.*

The most learned and complete systematic treatise now extant.—*Edinburgh Medical Journal.*

No work in the English language comprises so large an amount of information relative to operative medicine and surgical pathology.—*Medical Gazette.*

A complete encyclopedia of surgical science—a very complete surgical library—by far the most complete and scientific system of surgery in the English language.—*N. Y. Journal of Medicine.*

One of the most complete treatises on Surgery in the English language.—*Monthly Journal of Med. Science.*

The most extensive and comprehensive account of the art and science of Surgery in our language.—*Lancet.*

JONES ON THE EYE.

**THE PRINCIPLES AND PRACTICE  
OF OPHTHALMIC MEDICINE AND SURGERY.**

BY T. WHARTON JONES, F. R. S., &amp;c. &amp;c.

EDITED BY ISAAC HAYS, M. D., &amp;c.

In one very neat volume, large royal 12mo. of 529 pages, with four plates, plain or colored, and ninety-eight well executed wood-cuts.

MAURY'S DENTAL SURGERY.—A Treatise on the Dental Art, founded on Actual Experience. Illustrated by 241 lithographic figures and 54 wood-cuts. Translated by J. B. Savier. In 1 8vo. vol., sheep. 286 pp.

DUFTON ON THE EAR.—The Nature and Treatment of Deafness and Diseases of the Ear; and the Treatment of the Deaf and Dumb. One small 12mo. volume. 120 pp.

SMITH ON FRACTURES.—A Treatise on Fractures in the vicinity of Joints, and on Dislocations. One vol. 8vo., with 200 beautiful wood-cuts.

NEW AND MUCH IMPROVED EDITION—(Now Ready.)

**A SYSTEM OF PRACTICAL SURGERY.**BY WILLIAM FERGUSSON, F. R. S.,  
Professor of Surgery in King's College, London, &c. &c.

FOURTH AMERICAN, FROM THE THIRD AND ENLARGED LONDON EDITION.

In one large and beautifully printed octavo volume of about seven hundred pages, with three hundred and ninety-three wood engravings.

The present edition of this favorite work will be found far superior to its predecessors, the author having used every exertion, not only to bring it thoroughly up to the day with all the most recent observations and improvements, but also to supply by additional chapters, whatever deficiencies may have formerly existed. To avoid increasing unduly the bulk of the volume, while accommodating these additions, and the large number of new and beautiful illustrations, the size of the page has been increased, and the work is still kept at its former very moderate price, notwithstanding a marked improvement in its mechanical execution, which renders it one of the handsomest volumes as yet presented.

The most important subjects in connection with practical surgery which have been more recently brought under the notice of, and discussed by, the surgeons of Great Britain, are fully and dispassionately considered by Mr. Fergusson, and that which was before wanting has now been supplied, so that we can now look upon it as a work on practical surgery instead of one on operative surgery alone, which many have hitherto considered it to be. And we think the author has shown a wise discretion in making the additions on surgical disease which are to be found in the present volume, and has very much enhanced its value; for, besides two excellent chapters on the diseases of bones and joints, which were wanting before, he has headed each chief section of the work by a general description of the surgical disease and injury of that region of the body which is treated of in each, prior to entering into the consideration of the more special morbid conditions and their treatment. There is also, as in former editions, a sketch of the anatomy of particular regions.

We have now pointed out some of the principal additions in this work. There was some ground formerly for the complaint before alluded to, that it dwelt too exclusively on operative surgery; but this defect is now removed, and the book is more than ever adapted for the purposes of the practitioner, whether he confines himself more strictly to the operative department, or follows surgery on a more comprehensive scale.—*Medical Times and Gazette.*

NEW AND IMPORTANT WORK ON PRACTICAL SURGERY.—(JUST ISSUED.)

**OPERATIVE SURGERY.**

BY FREDERICK C. SKEY, F. R. S., &amp;c.

In one very handsome octavo volume of over 650 pages, with about one hundred wood-cuts.

The treatise is, indeed, one on operative surgery, but it is one in which the author throughout shows that he is most anxious to place operative surgery in its just position. He has acted as a judicious, but not partial friend; and while he shows throughout that he is able and ready to perform any operation which the exigencies and casualties of the human frame may require, he is most cautious in specifying the circumstances which in each case indicate and contraindicate operation. It is indeed gratifying to perceive the sound and correct views which Mr. Skey entertains on the subject of operations in general, and the gentlemanly tone in which he impresses on readers the lessons which he is desirous to inculcate. His work is a perfect model for the operating surgeon, who will learn from it not only when and how to operate, but some more noble and exalted lessons which cannot fail to improve him as a moral and social agent.—*Edinburgh Medical and Surgical Journal.*

THE STUDENT'S TEXT-BOOK.

**THE PRINCIPLES AND PRACTICE OF MODERN SURGERY.**

BY ROBERT DRUITT, Fellow of the Royal College of Surgeons.

A New American, from the last and improved London Edition.

EDITED BY F. W. SARGENT, M. D., Author of "Minor Surgery," &amp;c.

ILLUSTRATED WITH ONE HUNDRED AND NINETY-THREE WOOD ENGRAVINGS.

*In one very handsomely printed octavo volume of 576 large pages.**From Professor Brainard, of Chicago, Illinois.*

I think it the best work of its size, on that subject, in the language.

*From Professor Rivers, of Providence, Rhode Island.*

I have been acquainted with it since its first republication in this country, and the universal praise it has received I think well merited.

*From Professor May, of Washington, D. C.*

Permit me to express my satisfaction at the republication in so improved a form of this most valuable work. I believe it to be one of the very best text-books ever issued.

*From Professor McCook, of Baltimore.*

I cannot withhold my approval of its merits, or the expression that no work is better suited to the wants of the student. I shall commend it to my class, and make it my chief text-book.

A NEW MINOR SURGERY.

**ON BANDAGING AND OTHER POINTS OF MINOR SURGERY.**

BY F. W. SARGENT, M. D.

In one handsome royal 12mo. volume of nearly 400 pages, with 123 wood-cuts.

*From Professor Gilbert, Philadelphia.*

Embracing the smaller details of surgery, which are illustrated by very accurate engravings, the work becomes one of very great importance to the practitioner in the performance of his daily duties, since such information is rarely found in the general works on surgery now in use.

The great Atlas of Surgical Anatomy—(Now Complete.)

# SURGICAL ANATOMY.

BY JOSEPH MACLISE, SURGEON.

IN ONE VOLUME, VERY LARGE IMPERIAL QUARTO,

With Sixty-eight large and splendid Plates, drawn in the best style, and beautifully colored,

Containing one hundred and ninety Figures, many of them the size of life.

TOGETHER WITH COPIOUS EXPLANATORY LETTER-PRESS.

Strongly and handsomely bound in extra cloth, being one of the best executed and cheapest surgical works as yet issued in the country.

This great work being now concluded, the publishers confidently present it to the attention of the profession as worthy in every respect of their approbation and patronage. No complete work of the kind has yet been published in the English language, and it therefore will supply a want long felt in this country of an accurate and comprehensive Atlas of Surgical Anatomy to which the student and practitioner can at all times refer, to ascertain the exact relative position of the various portions of the human frame towards each other and to the surface, as well as their abnormal deviations. The importance of such a work to the student in the absence of anatomical material, and to the practitioner when about attempting an operation, is evident, while the price of the book, notwithstanding the large size, beauty, and finish of the very numerous illustrations, is so low as to place it within the reach of every member of the profession. The publishers therefore confidently anticipate a very extended circulation for this magnificent work.

Notwithstanding the short time in which this work has been before the profession, it has received the unanimous approbation of all who have examined it. From among a very large number of commendatory notices with which they have been favored, the publishers select the following:—

*From Prof. D. Gilbert, Philadelphia.*

Allow me to say, gentlemen, that the thanks of the profession at large, in this country are due to you for the republication of this admirable work of Maclise. The precise relationship of the organs in the regions displayed is so perfect, that even those who have daily access to the dissecting-room may, by consulting this work, enliven and confirm their anatomical knowledge prior to an operation. But it is to the thousands of practitioners of our country who cannot enjoy these advantages that the perusal of those plates, with their concise and accurate descriptions, will prove of infinite value. These have supplied a desideratum, which will enable them to refresh their knowledge of the important structures involved in their surgical cases, thus establishing their self-confidence, and enabling them to undertake operative procedures with every assurance of success. And as all the practical departments in medicine rest upon the same basis, and are enriched from the same sources, I need hardly add that this work should be found in the library of every practitioner in the land.

*From Prof. Gibson, Richmond, Va.*

Excellent as are the previous numbers, the present one far surpasses them, and indeed is superior to anything of the kind I have ever seen. The plates illustrating the anatomy of the Urethra and Bladder are superb.

*From Prof. McClintock, Philadelphia.*

I regard it as the best book on the subject ever published in this country. I have recommended it to the gentlemen of our classes, many of whom, after procuring it, have thanked me for the advice.

*From Prof. Bethune, Trinity College, Toronto.*

The work is exceedingly well brought out, and reflects the highest credit upon your establishment. It will afford me great pleasure to recommend it to all my professional friends and pupils.

*From Prof. Kimball, Pittsfield, Mass.*

I have examined these numbers with the greatest satisfaction, and feel bound to say that they are altogether the most perfect and satisfactory plates of the kind that I have ever seen.

*From Prof. Richardson, University of Toronto.*

No commendation is necessary from me to secure for it a wide circulation, for it has obtained, both in Britain and America, the most marked approbation; and upon examination it will commend itself to all for the clearness, fidelity, and beauty of the plates, and the able descriptions of the letter-press.

*From Prof. Brainard, Chicago, Ill.*

The work is extremely well adapted to the use both of students and practitioners, being sufficiently extensive for practical purposes, without being so expensive as to place it beyond their reach. Such a work was a desideratum in this country, and I shall not fail to recommend it to those within the sphere of my acquaintance.

*From Prof. P. F. Eve, Augusta, Ga.*

I consider this work a great acquisition to my library, and shall take pleasure in recommending it on all suitable occasions.

*From Prof. Peaslee, Brunswick, Me.*

The second part more than fulfils the promise held out by the first, so far as the beauty of the illustrations is concerned; and, respecting my opinion of the value of the work, so far as it has advanced, I need add nothing to what I have previously expressed to you.

*From Prof. Gunn, Ann Arbor, Mich.*

The plates in your edition of Maclise answer, in an eminent degree, the purpose for which they are intended. I shall take pleasure in exhibiting it and recommending it to my class.

*From Prof. Rivers, Providence, R. I.*

The plates illustrative of Hernia are the most satisfactory I have ever met with.

*From Prof. S. D. Gross, Louisville, Ky.*

The work, as far as it has progressed, is most admirable, and cannot fail, when completed, to form a most valuable contribution to the literature of our profession. It will afford me great pleasure to recommend it to the pupils of the University of Louisville.

## Maclise's Surgical Anatomy—(Continued.)

From Prof. R. L. Howard, Columbus Ohio.

In all respects, the first number is the beginning of a most excellent work, filling completely what might be considered hitherto a vacuum in surgical literature. For myself, in behalf of the medical profession, I wish to express to you my thanks for this truly elegant and meritorious work. I am confident that it will meet with a ready and extensive sale. I have spoken of it in the highest terms to my class and my professional brethren.

From Prof. Granville S. Pattison, N. Y.

The profession, in my opinion, owe you many thanks for the publication of this beautiful work—a work which, in the correctness of its exhibitions of Surgical Anatomy, is not surpassed by any with which I am acquainted; and the admirable manner in which the lithographic plates have been executed and colored is alike honorable to your house and to the arts in the United States.

From Prof. J. F. May, Washington, D. C.

Having examined the work I am pleased to add my testimony to its correctness, and to its value as a work of reference by the surgeon.

From Prof. Alden Marsh, Albany, N. Y.

From what I have seen of it, I think the design and execution of the work admirable, and, at the proper time in my course of lectures, I shall exhibit it to the class, and give it a recommendation worthy of its great merit.

From H. H. Smith, M. D., Philadelphia.

Permit me to express my gratification at the execution of Maclise's Surgical Anatomy. The plates are, in my opinion, the best lithographs that I have seen of a medical character, and the coloring of this number cannot, I think, be improved. Estimating highly the contents of the work, I shall continue to recommend it to my class as I have heretofore done.

From Prof. J. M. Bush, Lexington, Ky.

I am delighted with both the plan and execution of the work, and shall take all occasions to recommend it to my private pupils and public classes.

This is by far the ablest work on Surgical Anatomy that has come under our observation. We know of no other work that would justify a student, in any degree, for neglect of actual dissection. A careful study of these plates, and of the commentaries on them, would almost make an anatomist of a diligent student. And to one who has studied anatomy by dissection, this work is invaluable as a perpetual remembrancer, in matters of knowledge that may slip from the memory. The practitioner can scarcely consider himself equipped for the duties of his profession without such a work as this, and this has no rival, in his library. In those sudden emergencies that so often arise, and which require the instantaneous command of minute anatomical knowledge, a work of this kind keeps the details of the dissecting-room perpetually fresh in the memory. We appeal to our readers, whether any one can justifiably undertake the practice of medicine who is not prepared to give all needful assistance, in all matters demanding immediate relief. We repeat that no medical library, however large, can be complete without Maclise's Surgical Anatomy. The American edition is well entitled to the confidence of the profession, and should command, among them, an extensive sale. The investment of the amount of the cost of this work will prove to be a very profitable one, and if practitioners would qualify themselves thoroughly with such important knowledge as is contained in works of this kind, there would be fewer of them sighing for employment. The medical profession should spring towards such an opportunity as is presented in this republication, to encourage frequent repetitions of American enterprise of this kind.—*The Western Journal of Medicine and Surgery.*

One of the greatest artistic triumphs of the age in Surgical Anatomy.—*British American Medical Journal.*

One of the most useful and elegant practical works on anatomy ever published.—*London Lancet.*

Too much cannot be said in its praise; indeed, we have not language to do it justice.—*Ohio Medical and Surgical Journal.*

The most admirable surgical atlas we have seen. To the practitioner deprived of demonstrative dissections upon the human subject, it is an invaluable companion.—*N. J. Medical Reporter.*

The most accurately engraved and beautifully colored plates we have ever seen in an American book—one of the best and cheapest surgical works ever published.—*Buffalo Medical Journal.*

It is very rare that so elegantly printed, so well illustrated, and so useful a work, is offered at so moderate a price.—*Charleston Medical Journal.*

Its plates can boast a superiority which places them almost beyond the reach of competition.—*Medical Examiner.*

Every practitioner, we think, should have a work of this kind within reach.—*Southern Medical and Surgical Journal.*

No such lithographic illustrations of surgical regions have hitherto, we think, been given.—*Boston Medical and Surgical Journal.*

As a surgical anatomist, Mr. Maclise has probably no superior.—*British and Foreign Medico-Chirurgical Review.*

Of great value to the student engaged in dissecting, and to the surgeon at a distance from the means of keeping up his anatomical knowledge.—*Medical Times.*

All that can be desired or expected.—*American Medical Journal.*

The mechanical execution cannot be excelled.—*Transylvania Medical Journal.*

A work which has no parallel in point of accuracy and cheapness in the English language.—*N. Y. Journal of Medicine.*

To all engaged in the study or practice of their profession, such a work is almost indispensable.—*Dublin Quarterly Medical Journal.*

No practitioner whose means will admit should fail to possess it.—*Ranking's Abstract.*

Country practitioners will find these plates of immense value.—*N. Y. Medical Gazette.*

We are extremely gratified to announce to the profession the completion of this truly magnificent work, which, as a whole, certainly stands unrivalled, both for accuracy of drawing, beauty of coloring, and all the requisite explanations of the subject in hand. To the publishers, the profession in America is deeply indebted for placing such a valuable, such a useful work, at its disposal, and at such a moderate price. It is one of the most finished and complete pictures of Surgical Anatomy ever offered to the profession of America. With these plates before them, the student and practitioner can never be at a loss, under the most desperate circumstances. We do not intend these for commonplace compliments. We are sincere; because we know the work will be found invaluable to the young, no less than the old, surgeon. We have not space to point out its beauties, and its merits; but we speak of it *en masse*, as a whole, and strongly urge—especially those, who, from their position, may be debarred the privilege and opportunity of inspecting the fresh subject, to furnish themselves with the entire work.—*The New Orleans Medical and Surgical Journal.*

NEW AND ENLARGED EDITION, MUCH IMPROVED.

# PRINCIPLES OF SURGERY.

BY JAMES MILLER, F. R. S. E.,  
Professor of Surgery in the University of Edinburgh.

Third American, from the Second and Revised Edinburgh Edition.

REVISED, WITH ADDITIONS, BY F. W. SARGENT, M. D.,

Author of "Minor Surgery," &c.

In one large and very beautiful octavo volume, of seven hundred and fifty-two pages,  
WITH TWO HUNDRED AND FORTY EXQUISITE ILLUSTRATIONS ON WOOD.

The publishers have endeavored to render the present edition of this work, in every point of mechanical execution, worthy of its very high reputation, and they confidently present it to the profession as one of the handsomest volumes as yet issued in this country.

This edition is far superior, both in the abundance and quality of its material, to any of the preceding. We hope it will be extensively read, and the sound principles which are herein taught treasured up for future application. The work takes rank with Watson's Practice of Physic; it certainly does not fall behind that great work in soundness of principle or depth of reasoning and research. No physician who values his reputation, or seeks the interests of his clients, can acquit himself before his God and the world without making himself familiar with the sound and philosophical views developed in the foregoing book.—*New Orleans Medical and Surgical Journal.*

Without doubt the ablest exposition of the principles of that branch of the healing art in any language. This opinion, deliberately formed after a careful study of the first edition, we have had no cause to change on examining the second. This edition has undergone thorough revision by the author; many expressions have been modified, and a mass of new matter introduced. The book is got up in the finest style, and is an evidence of the progress of typography in our country.—*Charleston Medical Journal and Review.*

We recommend it to both student and practitioner, feeling assured that as it now comes to us, it presents the most satisfactory exposition of the modern doctrines of the principles of surgery to be found in any volume in any language.—*N. Y. Journal of Medicine.*

BY THE SAME AUTHOR.

## THE PRACTICE OF SURGERY.

In one octavo volume, of 496 pages.

NEW AND MUCH IMPROVED EDITION—(Nearly Ready.)  
LAWRENCE'S GREAT WORK ON THE EYE.

## A TREATISE ON DISEASES OF THE EYE.

BY W. LAWRENCE, F. R. S.

Third American Edition, greatly enlarged, with over 200 Illustrations.

BY ISAAC HAYS, M. D.

Surgeon to Wills Hospital, Philadelphia, &c.

In one very large and handsome octavo volume.

This work, by far the largest and most comprehensive on the subject within reach of the profession in this country, will receive an entire revision on the part of the editor. Brought up in this manner to the most advanced state of science, and presenting an equal improvement over its predecessors as regards mechanical execution, it is confidently presented as worthy of the extended reputation which it has hitherto enjoyed.

A NEW WORK ON THE EAR—(Just Ready.)

## A PRACTICAL TREATISE ON THE DISEASES OF THE EAR.

BY W. R. WILDE,

Surgeon to St. Mark's Ophthalmic and Aural Hospital, Dublin.

In one handsome royal 12mo. volume, with illustrations.

So little is generally known in this country concerning the causes, symptoms, and treatment of aural affections, that a practical and scientific work on that subject, from a practitioner of Mr. Wilde's great experience, cannot fail to be productive of much benefit, by attracting attention to this obscure class of diseases, which too frequently escape attention until past relief. The immense number of cases which have come under Mr. Wilde's observation for many years, have afforded him opportunities rarely enjoyed for investigating this branch of medical science, and his work may therefore be regarded as of the highest authority.

**SHARPEY AND QUAIN'S ANATOMY.—(Lately Issued.)**

# HUMAN ANATOMY.

BY JONES QUAIN, M. D.

FROM THE FIFTH LONDON EDITION.

EDITED BY

RICHARD QUAIN, F. R. S., AND WILLIAM SHARPEY, M. D., F. R. S.,  
Professors of Anatomy and Physiology in University College, London.

**REVISED, WITH NOTES AND ADDITIONS,**

BY JOSEPH LEIDY, M. D.

Complete in Two large Octavo Volumes, of about Thirteen Hundred Pages.

**Beautifully Illustrated with over Five Hundred Engravings on Wood.**

We have here one of the best expositions of the present state of anatomical science extant. There is not probably a work to be found in the English language which contains so complete an account of the progress and present state of general and special anatomy as this. By the anatomist this work must be eagerly sought for, and no student's library can be complete without it.—*The N. Y. Journal of Medicine.*

We know of no work which we would sooner see in the hands of every student of this branch of medical science than Sharpey and Quain's Anatomy.—*The Western Journal of Medicine and Surgery.*

It may now be regarded as the most complete and best posted up work on anatomy in the language. It will be found particularly rich in general anatomy.—*The Charleston Medical Journal.*

We believe we express the opinion of all who have examined these volumes, that there is no work superior to them on the subject which they so ably describe.—*Southern Medical and Surgical Journal.*

It is one of the most comprehensive and best works upon anatomy in the English language. It is equally valuable to the teacher, practitioner, and student in medicine, and to the surgeon in particular.—*The Ohio Medical and Surgical Journal.*

To those who wish an extensive treatise on Anatomy, we recommend these handsome volumes as the best that have ever issued from the English or American Press.—*The N. W. Medical and Surgical Journal.*

We believe that any country might safely be challenged to produce a treatise on anatomy so readable, so clear, and so full upon all-important topics.—*British and Foreign Medico-Chirurgical Review.*

It is indeed a work calculated to make an era in anatomical study, by placing before the student every department of his science, with a view to the relative importance of each; and so skillfully have the different parts been interwoven, that no one who makes this work the basis of his studies will hereafter have any excuse for neglecting or undervaluing any important particulars connected with the structure of the human frame; and whether the bias of his mind lead him in a more especial manner to surgery, physic, or physiology, he will find here a work at once so comprehensive and practical as to defend him from exclusiveness on the one hand, and pedantry on the other.—*Monthly Journal and Retrospect of the Medical Sciences.*

We have no hesitation in recommending this treatise on anatomy as the most complete on that subject in the English language; and the only one, perhaps, in any language, which brings the state of knowledge forward to the most recent discoveries.—*The Edinburgh Medical and Surgical Journal.*

Admirably calculated to fulfil the object for which it is intended.—*Provincial Medical Journal.*

The most complete Treatise on Anatomy in the English language.—*Edinburgh Medical Journal.*

There is no work in the English language to be preferred to Dr. Quain's Elements of Anatomy.—*London Journal of Medicine.*

THE STUDENT'S TEXT-BOOK OF ANATOMY.

NEW AND IMPROVED EDITION—(JUST ISSUED.)

# A SYSTEM OF HUMAN ANATOMY, GENERAL AND SPECIAL.

BY ERASMUS WILSON, M. D.

FOURTH AMERICAN FROM THE LAST ENGLISH EDITION.

EDITED BY PAUL B. GODDARD, A. M., M. D.

WITH TWO HUNDRED AND FIFTY ILLUSTRATIONS.

Beautifully printed, in one large octavo volume of nearly six hundred pages.

In many, if not all the Colleges of the Union, it has become a standard text-book. This, of itself, is sufficiently expressive of its value. A work very desirable to the student; one, the possession of which will greatly facilitate his progress in the study of Practical Anatomy.—*New York Journal of Medicine.*

Its author ranks with the highest on Anatomy.—*Southern Medical and Surgical Journal.*

It offers to the student all the assistance that can be expected from such a work.—*Medical Examiner.*

The most complete and convenient manual for the student we possess.—*American Journal of Med. Science.*

In every respect this work, as an anatomical guide for the student and practitioner, merits our warmest and most decided praise.—*London Medical Gazette.*

CARPENTER'S COMPARATIVE PHYSIOLOGY.

# PRINCIPLES OF PHYSIOLOGY,

GENERAL AND COMPARATIVE.

BY WILLIAM B. CARPENTER, M. D.,

NEW AND IMPROVED EDITION.—(PREPARING.)

In one very handsome octavo volume, with several hundred beautiful wood-cuts.

A truly magnificent work. In itself a perfect physiological study.—*Ranking's Abstract.*

**HORNER'S ANATOMY.****MUCH IMPROVED AND ENLARGED EDITION:—(Just Issued.)****SPECIAL ANATOMY AND HISTOLOGY.**BY WILLIAM E. HORNER, M. D.,  
Professor of Anatomy in the University of Pennsylvania, &c.

EIGHTH EDITION.

EXTENSIVELY REVISED AND MODIFIED TO 1851.

In two large octavo volumes, handsomely printed, with several hundred illustrations.

This work has enjoyed a thorough and laborious revision on the part of the author, with the view of bringing it fully up to the existing state of knowledge on the subject of general and special anatomy. To adapt it more perfectly to the wants of the student, he has introduced a large number of additional wood-engravings, illustrative of the objects described, while the publishers have endeavored to render the mechanical execution of the work worthy of the extended reputation which it has acquired. The demand which has carried it to an EIGHTH EDITION is a sufficient evidence of the value of the work, and of its adaptation to the wants of the student and professional reader.

NEW AND CHEAPER EDITION.

**AN ANATOMICAL ATLAS,  
ILLUSTRATIVE OF THE STRUCTURE OF THE HUMAN BODY.**

BY HENRY H. SMITH, M. D., &amp;c.

UNDER THE SUPERVISION OF

WILLIAM E. HORNER, M. D.,  
Professor of Anatomy in the University of Pennsylvania.

In one volume, large imperial octavo, with about six hundred and fifty beautiful figures.

With the view of extending the sale of this beautifully executed and complete "Anatomical Atlas," the publishers have prepared a new edition, printed on both sides of the page, thus materially reducing its cost, and enabling them to present it at a price about forty per cent. lower than former editions, while, at the same time, the execution of each plate is in no respect deteriorated, and not a single figure is omitted.

These figures are well selected, and present a complete and accurate representation of that wonderful fabric, the human body. The plan of this Atlas, which renders it so peculiarly convenient for the student, and its superb artistic execution, have been already pointed out. We must congratulate the student upon the completion of this Atlas, as it is the most convenient work of the kind that has yet appeared; and we must add, the very beautiful manner in which it is "got up" is so creditable to the country as to be flattering to our national pride.—*American Medical Journal.*

TODD &amp; BOWMAN'S PHYSIOLOGY.

**THE PHYSIOLOGICAL ANATOMY  
AND PHYSIOLOGY OF MAN.**

BY R. B. TODD AND W. BOWMAN.

Parts I. II. and III., in 1 vol. 8vo. of 552 pages, with 153 wood cuts.

The distinguishing peculiarity of this work is, that the authors investigate for themselves every fact asserted; and it is the immense labor consequent upon the vast number of observations requisite to carry out this plan, which has so long delayed the appearance of its completion. Part IV., with numerous original illustrations, is now appearing in the Medical News and Library for 1853. Those who have subscribed since the appearance of the preceding portion of the work can obtain it by mail, on remittance of \$2 50 to the publishers.

WILSON'S DISSECTOR, New Edition—(Just Issued.)

**THE DISSECTOR;  
OR, PRACTICAL AND SURGICAL ANATOMY.**

BY ERASMUS WILSON.

MODIFIED AND RE-ARRANGED BY

PAUL BECK GODDARD, M. D.

A NEW EDITION, WITH REVISIONS AND ADDITIONS.

In one large and handsome volume, royal 12mo., with one hundred and fifteen illustrations.

In passing this work again through the press, the editor has made such additions and improvements as the advance of anatomical knowledge has rendered necessary to maintain the work in the high reputation which it has acquired in the schools of the United States as a complete and faithful guide to the student of practical anatomy. A number of new illustrations have been added, especially in the portion relating to the complicated anatomy of Hernia. In mechanical execution the work will be found superior to former editions.

WORKS BY W. B. CARPENTER, M. D.

NEW AND ENLARGED EDITION—(Now Ready.)

## PRINCIPLES OF HUMAN PHYSIOLOGY;

WITH THEIR CHIEF APPLICATIONS TO

PSYCHOLOGY, PATHOLOGY, THERAPEUTICS, HYGIENE,  
AND FORENSIC MEDICINE.

Fifth American, from the Fourth and Enlarged London Edition.

WITH THREE HUNDRED AND FOURTEEN ILLUSTRATIONS.

EDITED, WITH ADDITIONS, BY FRANCIS GURNEY SMITH, M. D.,  
Professor of the Institutes of Medicine in the Pennsylvania Medical College, &c.

In one very large and beautiful octavo volume, of nearly eleven hundred pages, handsomely printed, and strongly bound in leather, with raised bands.

*From the Author's Preface to the present Edition.*

“When the author, on the completion of his ‘Principles of General and Comparative Physiology,’ applied himself to the preparation of his ‘Principles of Human Physiology,’ for the press, he found that nothing short of an *entire remodelling* of the preceding edition would in any degree satisfy his notions of what such a treatise ought to be. For although no fundamental change had taken place during the interval in the fabric of Physiological Science, yet a large number of less important modifications had been effected, which had combined to produce a very considerable alteration in its aspect. Moreover, the progressive maturation of his own views, and his increased experience as a teacher, had not only rendered him more keenly alive to the imperfections which were inherent in its original plan, but had caused him to look upon many topics in a light very different from that under which he had previously regarded them; and, in particular, he felt a strong desire to give to his work as *practical* a character as possible, without foregoing the position which (he trusts he may say without presumption) he had succeeded in gaining for it, as a *philosophical* exposition of one important department of Physiological Science. He was led, therefore, to the determination of, in reality, producing a *new treatise*, in which only those parts of the old should be retained, which might express the existing state of knowledge, and of his own opinions, on the points to which they relate.”

The American edit'ion has been printed from sheets prepared for the purpose by the author, who has introduced nearly one hundred illustrations not in the London edition; while it has also enjoyed the advantage of a careful superintendence on the part of the editor, who has added notices of such more recent investigations as had escaped the author's attention. Neither care nor expense has been spared in the mechanical execution of the work to render it superior to former editions, and it is confidently presented as in every way one of the handsomest volumes as yet placed before the medical profession in this country.

CARPENTER'S MANUAL OF PHYSIOLOGY.

NEW AND IMPROVED EDITION—(JUST ISSUED.)

## ELEMENTS OF PHYSIOLOGY,

INCLUDING PHYSIOLOGICAL ANATOMY.

SECOND AMERICAN, FROM A NEW AND REVISED LONDON EDITION.

With One Hundred and Ninety Illustrations. In one very handsome octavo volume.

In publishing the first edition of this work, its title was altered from that of the London volume by the substitution of the word “Elements” for that of “Manual,” and, with the author's sanction, the title of “Elements” is still retained, as being more expressive of the scope of the treatise. A comparison of the present edition with the former one will show a material improvement, the author having revised it thoroughly, with the view of rendering it completely on a level with the most advanced state of the science. By condensing the less important portions, these numerous additions have been introduced without materially increasing the bulk of the volume, and while numerous illustrations have been added, and the general execution of the work improved, it has been kept at its former very moderate price.

To say that it is the best manual of Physiology now before the public, would not do sufficient justice to the author.—*Buffalo Med. Journal.*

In his former works it would seem that he had exhausted the subject of Physiology. In the present, he gives the essence, as it were, of the whole.—*N. Y. Journal of Medicine.*

The best and most complete exposé of modern physiology, in one volume, extant in the English language.—*St. Louis Med. Journal.*

Those who have occasion for an elementary treatise on physiology, cannot do better than to possess themselves of the manual of Dr. Carpenter.—*Medical Examiner.*



## DUNGLISON'S PHYSIOLOGY.

New and much Improved Edition.—(Just Issued.)

## HUMAN PHYSIOLOGY.

BY ROBLEY DUNGLISON, M. D.,

Professor of the Institutes of Medicine in the Jefferson Medical College, Philadelphia, etc. etc.

SEVENTH EDITION.

Thoroughly revised and extensively modified and enlarged,

*With nearly Five Hundred Illustrations.*

In two large and handsomely printed octavo volumes, containing nearly 1450 pages.

On no previous revision of this work has the author bestowed more care than on the present, it having been subjected to an entire scrutiny, not only as regards the important matters of which it treats, but also the language in which they are conveyed; and on no former occasion has he felt as satisfied with his endeavors to have the work on a level with the existing state of the science. Perhaps at no time in the history of physiology have observers been more numerous, energetic, and discriminating than within the last few years. Many modifications of fact and inference have consequently taken place, which it has been necessary for the author to record, and to express his views in relation thereto. On the whole subject of physiology proper, as it applies to the functions executed by the different organs, the present edition, the author flatters himself, will therefore be found to contain the views of the most distinguished physiologists of all periods.

The amount of additional matter contained in this edition may be estimated from the fact that the mere list of authors referred to in its preparation alone extends over nine large and closely printed pages. The number of illustrations has been largely increased, the present edition containing four hundred and seventy-four, while the last had but three hundred and sixty-eight; while, in addition to this, many new and superior wood-cuts have been substituted for those which were not deemed sufficiently accurate or satisfactory. The mechanical execution of the work has also been improved in every respect, and the whole is confidently presented as worthy the great and continued favor which it has so long received from the profession.

NEW AND IMPROVED EDITION.—(Now Ready.)

## A MANUAL OF PHYSIOLOGY,

BY WILLIAM SENHOUSE KIRKES, M. D.,

Demonstrator of Morbid Anatomy at St. Bartholomew's Hospital.

ASSISTED BY JAMES PAGET, F. R. S.,

Lecturer on General Anatomy and Physiology at St. Bartholomew's Hospital.

Second American, from the Second London Edition.

WITH ONE HUNDRED AND SIXTY-FIVE ILLUSTRATIONS.

In one large and handsome royal 12mo. volume, strongly bound.

The new London edition of this work having been thoroughly brought up to the present state of physiological knowledge, little remained to be done in preparing the present volume. An occasional note has, however, been added, and a number of new illustrations have been introduced, wherever the subject appeared to require them. Care has, however, been exercised to maintain the character which the work has acquired of a clear and intelligible manual for students, unincumbered with unnecessary minutiae and details.

An excellent work, and for students one of the best within reach.—*Boston Medical and Surgical Journal.*

One of the best little books on Physiology which we possess.—*Braithwaite's Retrospect.*

Particularly adapted to those who desire to possess a concise digest of the facts of Human Physiology.—*British and Foreign Med.-Chirurg. Review.*

One of the best treatises which can be put into the hands of the student.—*London Medical Gazette.*

We conscientiously recommend it as an admirable "Handbook of Physiology."—*London Jour. of Medicine.*

HARRISON ON THE NERVES.—An Essay towards a correct theory of the Nervous System. In one octavo volume, 292 pages.

MATEUCCI ON LIVING BEINGS.—Lectures on the Physical Phenomena of Living Beings. Edited by Pereira. In one neat royal 12mo. volume, extra cloth, with cuts—386 pages.

ROGET'S PHYSIOLOGY.—A Treatise on Animal and Vegetable Physiology, with over 400 illustrations on wood. In two octavo volumes, cloth.

ROGET'S OUTLINES.—Outlines of Physiology and Phrenology. In one octavo volume, cloth—516 pages.

ON THE CONNECTION BETWEEN PHYSIOLOGY AND INTELLECTUAL SCIENCE. In one 12mo. volume, paper, price 25 cents.

SOILY ON THE BRAIN.—The Human Brain; its Structure, Physiology, and Diseases. In one handsome octavo volume, with over one hundred illustrations.

NOW READY.

**AN ATLAS OF PATHOLOGICAL HISTOLOGY.**

BY GOTTLIEB GLUGE, M. D.,

Professor of Physiology and Pathological Anatomy in the University of Brussels.

TRANSLATED, WITH NOTES AND ADDITIONS, BY JOSEPH LEIDY, M. D.

In one volume, very large imperial quarto,

WITH THREE HUNDRED AND TWENTY FIGURES, PLAIN AND COLORED, ON TWELVE PLATES.

*From the Translator's Preface.*

No apology can be necessary for presenting to the medical profession in the United States the translation of a work upon a subject relatively so new to the science of medicine as pathological histology. Its importance to pathological anatomy is of the same character as normal histology is to normal anatomy, and this cannot be better represented than by referring to the great and permanent advance which physiology has made in its relation to the physical structure of the organs of the living body. Pathological anatomy also is beyond doubt of the highest value in medicine, for a scientific treatment of disease must of necessity depend to a very considerable extent upon our knowledge of material changes which are so frequently the source of those symptoms which indicate its existence.

The present volume of Gluge, originally appended to his great work on pathological anatomy, besides illustrating the various subjects of pathological histology, accompanied by copious references, will be found of particular interest from the light which is thrown upon the inflammatory process and its various attendant and accessory phenomena.

**WILLIAMS' PRINCIPLES—New and Enlarged Edition.****PRINCIPLES OF MEDICINE,**

Comprising General Pathology and Therapeutics, and a brief general view of Etiology, Nosology, Semeiology, Diagnosis, Prognosis, and Hygienics. By Charles J. B. Williams, M. D., F. R. S. Edited, with Additions, by Meredith Clymer, M. D. Third American, from the second and enlarged London edition. In one octavo volume, of 440 pages.

**SIMON'S PATHOLOGY—(Now Ready.)****GENERAL PATHOLOGY,**

As conducive to The Establishment of Rational Principles for the Diagnosis and Treatment of Disease; a Course of Lectures, delivered at St. Thomas's Hospital, during the summer session of 1850. By John Simon, F. R. S., one of the Surgical Staff of that Hospital, and Officer of Health to the City of London. In one neat octavo volume, extra cloth.

**MANUALS ON THE BLOOD AND URINE,**

In one handsome volume royal 12mo., extra cloth, of 460 large pages, with numerous illustrations,

CONTAINING

- I. A Practical Manual on the Blood and Secretions of the Human Body. BY JOHN WILLIAM GRIFFITH, M. D., &c.
- II. On the Analysis of the Blood and Urine in health and disease, and on the treatment of Urinary diseases. BY G. OWEN REESE, M. D., F. R. S., &c. &c.
- III. A Guide to the Examination of the Urine in health and disease. BY ALFRED MARKWICK.

NEW EDITION—(JUST ISSUED.)

**URINARY DEPOSITS;****THEIR DIAGNOSIS, PATHOLOGY, AND THERAPEUTICAL INDICATIONS.**

BY GOLDING BIRD, A. M., M. D., &amp;c.

A NEW AMERICAN, FROM THE THIRD AND IMPROVED LONDON EDITION.

In one very neat volume, royal 12mo., with over sixty illustrations.

Though the present edition of this well-known work is but little increased in size, it will be found essentially modified throughout, and fully up to the present state of knowledge on its subject. The unanimous testimony of the medical press warrants the publishers in presenting it as a complete and reliable manual for the student of this interesting and important branch of medical science.

**BURROWS ON CEREBRAL CIRCULATION.**—On Disorders of the Cerebral Circulation, and on the Connection between Affections of the Brain and Diseases of the Heart. In 1 Svo. vol., with col'd pl's, pp. 216.

**BLAKISTON ON THE CHEST.**—Practical Observations on certain Diseases of the Chest, and on the Principles of Auscultation. In one volume, 8vo., pp. 354.

**HASSE'S PATHOLOGICAL ANATOMY.**—An Anatomical Description of the Diseases of Respiration and Circulation. Translated and Edited by Swaine. In one volume, 8vo., pp. 379.

**FRICK ON THE URINE.**—Renal Affections, their Diagnosis and Pathology. In one handsome volume, royal 12mo., with illustrations.

**COPLAND ON PALSY.**—Of the Causes, Nature, and Treatment of Palsy and Apoplexy. In one volume, royal 12mo. (Just Issued.)

**BILLING'S PRINCIPLES.**—The Principles of Medicine. Second American, from the Fifth and Improved London Edition. In one octavo volume, extra cloth, 250 pages.

**THE PRACTICE OF MEDICINE.**

A TREATISE ON  
SPECIAL PATHOLOGY AND THERAPEUTICS.  
THIRD EDITION.

BY ROBLEY DUNGLISON, M. D.,

Professor of the Institutes of Medicine in the Jefferson Medical College; Lecturer on Clinical Medicine, &c.

In two large octavo volumes, of fifteen hundred pages.

The student of medicine will find, in these two elegant volumes, a mine of facts, a gathering of precepts and advice from the world of experience, that will nerve him with courage, and faithfully direct him in his efforts to relieve the physical sufferings of the race.—*Boston Medical and Surgical Journal.*

Upon every topic embraced in the work the latest information will be found carefully posted up.  
*Medical Examiner.*

It is certainly the most complete treatise of which we have any knowledge. There is scarcely a disease which the student will not find noticed.—*Western Journal of Medicine and Surgery.*

One of the most elaborate treatises of the kind we have.—*Southern Medical and Surg. Journal.*

**NEW AND IMPROVED EDITION—(Now Ready.)**

THE HISTORY, DIAGNOSIS, AND TREATMENT OF THE  
**FEVERS OF THE UNITED STATES.**

BY ELISHA BARTLETT, M. D.,

Professor of Materia Medica and Medical Jurisprudence in the College of Physicians and Surgeons, N. Y.

*Third Edition, Revised and Improved.*

In one very neat octavo volume, of six hundred pages.

In preparing a new edition of this standard work, the author has availed himself of such observations and investigations as have appeared since the publication of his last revision, and he has endeavored in every way to render it worthy of a continuance of the very marked favor with which it has been hitherto received.

The masterly and elegant treatise by Dr. Bartlett is invaluable to the American student and practitioner.—*Dr. Holmes's Report to the Nat. Med. Association.*

We regard it, from the examination we have made of it, the best work on fever extant, in our language, and as such cordially recommend it to the medical public.—*St. Louis Med. and Surg. Journal.*

**DISEASES OF THE HEART, LUNGS, AND APPENDAGES;  
THEIR SYMPTOMS AND TREATMENT.**

BY W. H. WALSHE, M. D.,

Professor of the Principles and Practice of Medicine in University College, London, &c.

In one handsome volume, large royal 12mo. of 512 pages.

**THE CYCLOPEDIA OF PRACTICAL MEDICINE;**

COMPRISING

Treatises on the Nature and Treatment of Diseases, Materia Medica, and Therapeutics, Diseases of Women and Children, Medical Jurisprudence, &c. &c.

EDITED BY

JOHN FORBES, M. D., F. R. S., ALEXANDER TWEEDIE, M. D., F. R. S.,

AND JOHN CONOLLY, M. D.

Revised, with Additions,

BY ROBLEY DUNGLISON, M. D.

THIS WORK IS NOW COMPLETE, AND FORMS FOUR LARGE SUPER-ROYAL OCTAVO VOLUMES, Containing Thirty-two Hundred and Fifty-four unusually large Pages in Double Columns, Printed on Good Paper, with a new and clear type.

THE WHOLE WELL AND STRONGLY BOUND, WITH RAISED BANDS AND DOUBLE TITLES.

This work contains no less than FOUR HUNDRED AND EIGHTEEN DISTINCT TREATISES,

By Sixty-eight distinguished Physicians.

The most complete work on Practical Medicine extant; or, at least, in our language.—*Buffalo Medical and Surgical Journal.*

For reference, it is above all price to every practitioner.—*Western Lancet.*

One of the most valuable medical publications of the day—as a work of reference it is invaluable.—*Western Journal of Medicine and Surgery.*

It has been to us, both as learner and teacher, a work for ready and frequent reference, one in which modern English medicine is exhibited in the most advantageous light.—*Medical Examiner.*

We rejoice that this work is to be placed within the reach of the profession in this country, it being unquestionably one of very great value to the practitioner. This estimate of it has not been formed from a hasty examination, but after an intimate acquaintance derived from frequent consultation of it during the past nine or ten years. The editors are practitioners of established reputation, and the list of contributors embraces many of the most eminent professors and teachers of London, Edinburgh, Dublin, and Glasgow. It is, indeed, the great merit of this work that the principal articles have been furnished by practitioners who have not only devoted especial attention to the diseases about which they have written, but have also enjoyed opportunities for an extensive practical acquaintance with them—and whose reputation carries the assurance of their competency justly to appreciate the opinions of others, while it stamps their own doctrines with high and just authority.—*American Medical Journal.*

WATSON'S PRACTICE OF MEDICINE—(New Edition.)

LECTURES ON THE  
PRINCIPLES AND PRACTICE OF PHYSIC.

BY THOMAS WATSON, M. D., &amp;c. &amp;c.

Third American, from the last London Edition.

REVISED, WITH ADDITIONS, BY D. FRANCIS CONDIE, M. D.,

Author of "A Treatise on the Diseases of Children," &amp;c.

IN ONE OCTAVO VOLUME,

Of nearly ELEVEN HUNDRED LARGE PAGES, strongly bound with raised bands.

To say that it is the very best work on the subject now extant, is but to echo the sentiment of the medical press throughout the country.—*N. O. Medical Journal.*

Regarded on all hands as one of the very best, if not the very best, systematic treatise on practical medicine extant.—*St. Louis Med. Journal.*

As a text-book it has no equal; as a compendium of pathology and practice no superior.—*N. Y. Annalist.*

We know of no work better calculated for being placed in the hands of the student, and for a text-book; on every important point the author seems to have posted up his knowledge to the day.—*Amer. Med. Journal.*

One of the most practically useful books that ever was presented to the student.—*N. Y. Med. Journal.*

We are free to state that a careful examination of this volume has satisfied us that it merits all the commendation bestowed on it in this country and at home. It is a work adapted to the wants of young practitioners, combining, as it does, sound principles and substantial practice. It is not too much to say, that it is a representative of the actual state of medicine as taught and practised by the most eminent physicians of the present day, and as such we would advise every one about embarking in the practice of physic to provide himself with a copy of it.—*Western Journal of Medicine and Surgery.*

For our parts, we are not only willing that our characters as scientific physicians and skilful practitioners may be deduced from doctrines contained in this volume, but we hesitate not to express our belief, that for sound, trustworthy principles, and good substantial practice, it cannot be paralleled by any similar work in any other country. We would advise no one to set himself down in practice unprovided with a copy;—*British and Foreign Medical Review.*

NEW AND IMPROVED EDITION—(Now Ready.)

## ON DISEASES OF THE SKIN.

BY ERASMUS WILSON, F. R. S.,

Author of "Human Anatomy," &amp;c.

THIRD AMERICAN FROM THE THIRD LONDON EDITION.

In one neat octavo volume, extra cloth, 480 pages.

Also, to be had with fifteen beautiful steel plates, embracing 165 figures, plain and colored, representing the Normal Anatomy and Pathology of the Skin.

ALSO, THE PLATES SOLD SEPARATE, IN BOARDS.

This edition will be found in every respect much improved over the last. Considerable additions have been made, the arrangement altered, and the whole revised so as to make it fully on a level with the existing state of knowledge on the subjects treated.

As a practical guide to the classification, diagnosis, and treatment of the diseases of the skin, the book is complete. We know nothing, considered in this aspect, better in our language; it is a safe authority on all the ordinary matters which, in this range of diseases, engage the practitioner's attention, and possesses the high quality—unknown, we believe, to every older manual—of being on a level with science's high-water mark—a sound book of practice.—*London Medical Times.*

WILSON ON SYPHILIS—(Now Ready.)

ON CONSTITUTIONAL AND HEREDITARY SYPHILIS;  
AND ON SYPHILITIC ERUPTIONS.

BY ERASMUS WILSON, F. R. S.,

Author of "Human Anatomy," "Diseases of the Skin," &amp;c.

In one very handsome volume, small 8vo., with four beautiful colored plates,

Presenting accurate representations of more than thirty varieties of Syphilitic Diseases of the Skin.

This work is the result of extensive practical experience in the treatment of this disease, and presents some new views on this difficult and important subject, illustrated by numerous cases.

BENEDICT'S CHAPMAN.—Compendium of Chapman's Lectures on the Practice of Medicine. One neat volume, 8vo., pp. 258.

BUDD ON THE LIVER.—On Diseases of the Liver. In one very neat 8vo. vol., with colored plates and wood-cuts, pp. 392.

CHAPMAN'S LECTURES.—Lectures on Fevers, Dropsy, Gout, Rheumatism, &c. &c. In one neat 8vo. volume, pp. 450.

THOMSON ON THE SICK ROOM.—Domestic management of the sick Room, necessary in aid of Medical Treatment for the cure of Diseases. Edited by R. E. Griffith, M. D. In one large royal 12mo. volume, with wood-cuts, pp. 360.

HOPE ON THE HEART.—A Treatise on the Diseases of the Heart and Great Vessels. Edited by Pen-  
nock. In one volume, 8vo., with plates, pp. 572.

PHILIPS ON SCROFULA.—Scrofula: its Nature, its Prevalence, its Causes, and the Principles of its Treatment. In one volume, 8vo., with a plate, pp. 350.

NEW AND MUCH IMPROVED EDITION—JUST READY.

BUDD ON THE LIVER.

## ON DISEASES OF THE LIVER.

BY GEORGE BUDD, M. D., F. R. S.,

Professor of Medicine in King's College, London; and Fellow of Caius College, Cambridge.

Second American, from the Second and Improved London Edition.

In one very handsome octavo volume.

WITH FOUR BEAUTIFULLY COLORED PLATES, AND NUMEROUS WOOD-CUTS.

The reputation which this work has obtained as a full and practical treatise on an important class of diseases will not be diminished by this improved and enlarged edition. It has been carefully and thoroughly revised by the author; the number of plates has been increased, and the style of its mechanical execution will be found materially improved.

The full digest we have given of the new matter introduced into the present volume, is evidence of the value we place on it. The fact that the profession has required a second edition of a monograph such as that before us, bears honorable testimony to its usefulness. For many years, Dr. Budd's work must be the authority of the great mass of British practitioners on the hepatic diseases; and it is satisfactory that the subject has been taken up by so able and experienced a physician.—*British and Foreign Medico-Chirurgical Review.*

We cannot too strongly recommend the diligent study of this volume. The work cannot fail to rank the name of its author among the most enlightened pathologists and soundest practitioners of the day.—*Medico-Chirurgical Review.*

We feel bound to say that Dr. Budd's treatise is greatly in advance of its predecessors. It is the first work in which the results of microscopical anatomy and the discoveries of modern chemistry have been brought fully to bear upon the pathology and treatment of diseases of the liver; and it is the only work in which a method of studying diseases of this organ, founded upon strictly inductive principles, is developed.—*Dublin Medical Press.*

Having thus attempted to give a brief summary of the more important contents of this work, we would, in conclusion, recommend it to every practitioner and student as well worthy of a careful and patient perusal.—*The New Orleans Medical and Surgical Journal.*

A CLINICAL MANUAL—(Now Ready.)

WHAT TO OBSERVE AT THE BEDSIDE AND AFTER DEATH,  
IN MEDICAL CASES.

Published under the authority of the London Society for Medical Observation.

In one very handsome volume, royal 12mo., extra cloth.

Did not the perusal of the work justify the high opinion we have of it, the names of Dr. Walshe, the originator, and of Dr. Ballard, as the editor of the volume, would almost of itself have satisfied us that it abounds in minute clinical accuracy. Few, besides those more immediately connected with the progress of the book, are aware of how much the value of the work is dependent upon the care and great labor bestowed upon it by Dr. Ballard, who, we happen to know, was engaged for a length of time after it had passed from the hands of the Committee, in perfecting its details and in arranging it for the press. We need not say that the execution of the whole reflects the highest credit not only upon the gentlemen mentioned, but upon all those engaged upon its production. In conclusion, we are convinced that the possession of the work will be almost necessary to every member of the profession—that it will be found indispensable to the practical physician, the pathologist, the medical jurist, and above all to the medical student.—*London Medical Times*, Dec. 11, 1852.

A NEW WORK ON THE SKIN—(Now Ready.)

## A PRACTICAL TREATISE ON DISEASES OF THE SKIN.

BY J. MOORE NELIGAN, M. D., M. R. I. A.,

Author of "Medicines, their Uses and Modes of Administration," &amp;c.

In one neat volume, royal 12mo.

We must say he bears off the palm for clearness, conciseness, and rigid plainness of expression. This style enables him to compress much in a single sentence without in any degree injuring the sense, but, on the contrary, making it more comprehensible and impressive. His simplification of the divisions is a striking feature in his descriptions, and yet, by introducing the accumulated subdivisions of other authors as varieties merely, we lose nothing of any real importance. His diagnosis is as it should be, clear and definite, and the broad lines of demarcation are prominently distinguished; so that, rising even from his shortest descriptions, you do not feel at all the want of plates or illustrations, the very severest test that can be given to try the effectiveness of cutaneous definitions. By far the largest proportion of the volume is devoted to therapeutic considerations. Not merely are full details of treatment and formulæ given at the close of each section, but an entire chapter is devoted to "those general points in therapeutics which are specially applicable to this class of affections." The present work forms a favorable contrast to the voluminous and disputed details of many of its predecessors, and will, we feel assured, be admirably conducive to facilitating the study of the student, and improving the practice of the practitioner.—*Dublin Quarterly Journ. of Med. Science.*

WHITEHEAD ON ABORTION, &c.—The Causes and Treatment of Abortion and Sterility; being the Result of an Extended Practical Inquiry into the Physiological and Morbid Conditions of the Uterus. In one volume, 8vo., pp. 368.

WILLIAMS ON RESPIRATORY ORGANS.—A Practical Treatise on Diseases of the Respiratory Organs; including Diseases of the Larynx, Trachea, Lungs, and Pleuræ. With numerous Additions and Notes by M. Clymer, M. D. With wood-cuts. In one octavo volume, pp. 508.

DAY ON OLD AGE.—A Practical Treatise on the Domestic Management and more important Diseases of Advanced Life. With an Appendix on a new and successful mode of treating Lumbago and other forms of Chronic Rheumatism. 1 vol. 8vo., pp. 226.

CLYMER ON FEVERS.—Fever, their Diagnosis, Pathology, and Treatment. Prepared, with large Additions, from "Tweedie's Library of Practical Medicine." In one vol 8vo., pp. 604.

**MEIGS ON FEMALES, New and Improved Edition—(Lately Issued.)**  
**WOMAN; HER DISEASES AND THEIR REMEDIES;**  
**A SERIES OF LETTERS TO HIS CLASS.**

BY C. D. MEIGS, M. D.,

Professor of Midwifery and Diseases of Women and Children in the Jefferson Medical College of Philadelphia, &c. &c.

In one large and beautifully printed octavo volume, of nearly seven hundred large pages.

"I am happy to offer to my Class an enlarged and amended edition of my Letters on the Diseases of Women; and I avail myself of this occasion to return my heartfelt thanks to them, and to our brethren generally, for the flattering manner in which they have accepted this fruit of my labor."—PREFACE.

The value attached to this work by the profession is sufficiently proved by the rapid exhaustion of the first edition, and consequent demand for a second. In preparing this, the author has availed himself of the opportunity thoroughly to revise and greatly to improve it. The work will therefore be found completely brought up to the day, and in every way worthy of the reputation which it has so immediately obtained.

Professor Meigs has enlarged and amended this great work, for such it unquestionably is, having passed the ordeal of criticism at home and abroad, but been improved thereby; for in this new edition the author has introduced real improvements, and increased the value and utility of the book immeasurably. It presents so many novel, bright and sparkling thoughts; such an exuberance of new ideas on almost every page, that we confess ourselves to have become enamored with the book and its author; and cannot withhold our congratulations from our Philadelphia confreres, that such a teacher is in their service. We regret that our limits will not allow of a more extended notice of this work, but must content ourselves with thus commending it as worthy of diligent perusal by physicians as well as students, who are seeking to be thoroughly instructed in the important practical subjects of which it treats.—*N. Y. Med. Gazette.*

It contains a vast amount of practical knowledge, by one who has accurately observed and retained the experience of many years, and who tells the result in a free, familiar, and pleasant manner.—*Dublin Quarterly Journal.*

There is an off-hand fervor, a glow and a warm-heartedness infecting the effort of Dr. Meigs, which is entirely captivating, and which absolutely hurries the reader through from beginning to end. Besides, the book teems with solid instruction, and it shows the very highest evidence of ability, viz., the clearness with which the information is presented. We know of no better test of one's understanding a subject than the evidence of the power of lucidly explaining it. The most elementary, as well as the obscurest subjects, under the pencil of Prof. Meigs, are isolated and made to stand out in such bold relief, as to produce distinct impressions upon the mind and memory of the reader.—*The Charleston Medical Journal.*

The merits of the first edition of this work were so generally appreciated, and with such a high degree of favor by the medical profession throughout the Union, that we are not surprised in seeing a second edition of it. It is a standard work on the diseases of females, and in many respects is one of the very best of its kind in the English language. Upon the appearance of the first edition, we gave the work a cordial reception, and spoke of it in the warmest terms of commendation. Time has not changed the favorable estimate we placed upon it, but has rather increased our convictions of its superlative merits. But we do not now deem it necessary to say more than to commend this work, on the diseases of women, and the remedies for them, to the attention of those practitioners who have not supplied themselves with it. The most select library would be imperfect without it.—*The Western Journal of Medicine and Surgery.*

He is a bold thinker, and possesses more originality of thought and style than almost any American writer on medical subjects. If he is not an elegant writer, there is at least a freshness—a raciness in his mode of expressing himself—that cannot fail to draw the reader after him, even to the close of his work: you cannot nod over his pages; he stimulates rather than narcotises your senses, and the reader cannot lay aside these letters when once he enters into their merits. This, the second edition, is much amended and enlarged, and affords abundant evidence of the author's talents and industry.—*N. O. Medical and Surgical Journal.*

The practical writings of Dr. Meigs are second to none.—*The N. Y. Journal of Medicine.*

The excellent practical directions contained in this volume give it great utility, which we trust will not be lost upon our older colleagues; with some condensation, indeed, we should think it well adapted for translation into German.—*Zeitschrift für die Gesamte Medicin.*

NEW AND IMPROVED EDITION—(Lately Issued.)

**A TREATISE ON THE DISEASES OF FEMALES,**  
**AND ON THE SPECIAL HYGIENE OF THEIR SEX.**  
**BY COLOMBAT DE L'ISERE, M. D.**

TRANSLATED, WITH MANY NOTES AND ADDITIONS, BY C. D. MEIGS, M. D.

SECOND EDITION, REVISED AND IMPROVED.

In one large volume, octavo, of seven hundred and twenty pages, with numerous wood-cuts.

We are satisfied it is destined to take the front rank in this department of medical science. It is in fact a complete exposition of the opinions and practical methods of all the celebrated practitioners of ancient and modern times.—*New York Journ. of Medicine.*

**ASHWELL ON THE DISEASES OF FEMALES.**

**A PRACTICAL TREATISE ON THE DISEASES PECULIAR TO WOMEN.**

ILLUSTRATED BY CASES DERIVED FROM HOSPITAL AND PRIVATE PRACTICE.  
 BY SAMUEL ASHWELL, M. D. WITH ADDITIONS BY PAUL BECK GODDARD, M. D.

Second American edition. In one octavo volume, of 520 pages.

One of the very best works ever issued from the press on the Diseases of Females.—*Western Lancet.*

**ON THE CAUSES AND TREATMENT OF ABORTION AND STERILITY.** By James Whitehead, M. D., &c. In one volume octavo, of about three hundred and seventy-five pages.

NEW AND IMPROVED EDITION.

## ON THE DISEASES OF WOMEN. INCLUDING THOSE OF PREGNANCY AND CHILD-BED.

BY FLEETWOOD CHURCHILL, M. D., M. R. I. A.,  
Author of "Theory and Practice of Midwifery," "Diseases of Females," &c.

A New American Edition, Revised by the Author.

WITH NOTES AND ADDITIONS, BY D. FRANCIS CONDIE, M. D.

In one large and handsome octavo volume of 684 pages, with wood-cuts.

To indulge in panegyric, when announcing the fifth edition of any acknowledged medical authority, were to attempt to "gild refined gold." The work announced above, has too long been honored with the term "classical" to leave any doubt as to its true worth, and we content ourselves with remarking, that the author has carefully retained the notes of Dr. Huston, who edited the former American edition, thus really enhancing the value of the work, and paying a well-merited compliment. All who wish to be "posted up" on all that relates to the diseases peculiar to the wife, the mother, or the maid, will hasten to secure a copy of this most admirable treatise.—*The Ohio Medical and Surgical Journal.*

We know of no author who deserves that approbation, on "the diseases of females," to the same extent that Dr. Churchill does. His, indeed, is the only thorough treatise we know of on the subject, and it may be commended to practitioners and students as a masterpiece in its particular department. The former editions of this work have been commended strongly in this journal, and they have won their way to an extended, and a well-deserved popularity. This fifth edition, before us, is well calculated to maintain Dr. Churchill's high reputation. It was revised and enlarged by the author, for his American publishers, and it seems to us that there is scarcely any species of desirable information on its subjects, that may not be found in this work.—*The Western Journal of Medicine and Surgery.*

We are gratified to announce a new and revised edition of Dr. Churchill's valuable work on the diseases of females. We have ever regarded it as one of the very best works on the subjects embraced within its scope, in the English language; and the present edition, enlarged and revised by the author, renders it still more entitled to the confidence of the profession. The valuable notes of Prof. Huston have been retained, and contribute, in no small degree, to enhance the value of the work. It is a source of congratulation that the publishers have permitted the author to be, in this instance, his own editor, thus securing all the revision which an author alone is capable of making.—*The Western Lancet.*

As a comprehensive manual for students, or a work of reference for practitioners, we only speak with common justice when we say that it surpasses any other that has ever issued on the same subject from the British press.—*The Dublin Quarterly Journal.*

Churchill's Monographs on Females—(Lately Issued.)

### ESSAYS ON THE PUERPERAL FEVER, AND OTHER DISEASES PECULIAR TO WOMEN.

SELECTED FROM THE WRITINGS OF BRITISH AUTHORS PREVIOUS TO THE CLOSE OF  
THE EIGHTEENTH CENTURY.

Edited by FLEETWOOD CHURCHILL, M. D., M. R. I. A.,  
Author of "Treatise on the Diseases of Females," &c.

In one neat octavo volume, of about four hundred and fifty pages.

To these papers Dr. Churchill has appended notes, embodying whatever information has been laid before the profession since their authors' time. He has also prefixed to the essays on puerperal fever, which occupy the larger portion of the volume, an interesting historical sketch of the principal epidemics of that disease. The whole forms a very valuable collection of papers by professional writers of eminence, on some of the most important accidents to which the puerperal female is liable.—*American Journal of Medical Sciences.*

BENNETT ON THE UTERUS—(New Edition, Now Ready.)

### A PRACTICAL TREATISE ON INFLAMMATION OF THE UTERUS AND ITS APPENDAGES, AND ON ULCERATION AND INDURATION OF THE NECK OF THE UTERUS.

BY HENRY BENNETT, M. D.,  
Obstetric Physician to the Western Dispensary.

Third American Edition.

In one neat octavo volume of 350 pages, with wood-cuts.

Few works issue from the medical press which are at once original and sound in doctrine; but such, we feel assured, is the admirable treatise now before us. The important practical precepts which the author inculcates are all rigidly deduced from facts. . . . Every page of the book is good, and eminently practical. So far as we know and believe, it is the best work on the subject on which it treats.—*Monthly Journal of Medical Science.*

### A TREATISE ON THE DISEASES OF FEMALES.

BY W. P. DEWEES, M. D.

NINTH EDITION.

In one volume, octavo. 532 pages, with plates.

## MEIGS ON CHILDREN—(Just Issued.)

OBSERVATIONS ON  
CERTAIN OF THE DISEASES OF YOUNG CHILDREN.

BY CHARLES D. MEIGS, M. D.,

Professor of Midwifery and of the Diseases of Women and Children in the Jefferson  
Medical College of Philadelphia, &c. &c.

In one handsome octavo volume of 214 pages.

While this work is not presented to the profession as a systematic and complete treatise on Infantile disorders, the importance of the subjects treated of, and the interest attaching to the views and opinions of the distinguished author must command for it the attention of all who are called upon to treat this interesting class of diseases.

It puts forth no claims as a systematic work, but contains an amount of valuable and useful matter, scarcely to be found in the same space in our home literature. It cannot but prove an acceptable offering to the profession at large.—*N. Y. Journal of Medicine.*

The work before us is undoubtedly a valuable addition to the fund of information which has already been treasured up on the subjects in question. It is practical, and therefore eminently adapted to the general practitioner. Dr. Meigs' works have the same fascination which belongs to himself.—*Medical Examiner.*

This is a most excellent work on the obscure diseases of childhood, and will afford the practitioner and student of medicine much aid in their diagnosis and treatment.—*The Boston Medical and Surgical Journal.*

We take much pleasure in recommending this excellent little work to the attention of medical practitioners. It deserves their attention, and after they commence its perusal, they will not willingly abandon it, until they have mastered its contents. We read the work while suffering from a carbuncle, and its fascinating pages often beguiled us into forgetfulness of agonizing pain. May it teach others to relieve the afflictions of the young.—*The Western Journal of Medicine and Surgery.*

All of which topics are treated with Dr. Meigs' acknowledged ability and original diction. The work is neither a systematic nor a complete treatise upon the diseases of children, but a fragment which may be consulted with much advantage.—*Southern Medical and Surgical Journal.*

## NEW WORK BY DR. CHURCHILL.

## ON THE

## DISEASES OF INFANTS AND CHILDREN.

BY FLEETWOOD CHURCHILL, M. D., M. R. I. A.,

Author of "Theory and Practice of Midwifery," "Diseases of Females," &amp;c.

In one large and handsome octavo volume of over 600 pages.

From Dr. Churchill's known ability and industry, we were led to form high expectations of this work; nor were we deceived. Its learned author seems to have set no bounds to his researches in collecting information which, with his usual systematic address, he has disposed of in the most clear and concise manner, so as to lay before the reader every opinion of importance bearing upon the subject under consideration.

We regard this volume as possessing more claims to completeness than any other of the kind with which we are acquainted. Most cordially and earnestly, therefore, do we commend it to our professional brethren, and we feel assured that the stamp of their approbation will in due time be impressed upon it.

After an attentive perusal of its contents, we hesitate not to say, that it is one of the most comprehensive ever written upon the diseases of children, and that, for copiousness of reference, extent of research, and perspicuity of detail, it is scarcely to be equalled, and not to be excelled in any language.—*Dublin Quarterly Journal.*

The present volume will sustain the reputation acquired by the author from his previous works. The reader will find in it full and judicious directions for the management of infants at birth, and a compendious, but clear, account of the diseases to which children are liable, and the most successful mode of treating them. We must not close this notice without calling attention to the author's style, which is perspicuous and polished to a degree, we regret to say, not generally characteristic of medical works. We recommend the work of Dr. Churchill most cordially, both to students and practitioners, as a valuable and reliable guide in the treatment of the diseases of children.—*Am. Journ. of the Med. Sciences.*

After this meagre, and we know, very imperfect notice, of Dr. Churchill's work, we shall conclude by saying, that it is one that cannot fail from its copiousness, extensive research, and general accuracy, to exalt still higher the reputation of the author in this country. The American reader will be particularly pleased to find that Dr. Churchill has done full justice throughout his work, to the various American authors on this subject. The names of Dewees, Eberle, Condie, and Stewart, occur on nearly every page, and these authors are constantly referred to by the author in terms of the highest praise, and with the most liberal courtesy.—*The Medical Examiner.*

We know of no work on this department of Practical Medicine which presents so candid and unprejudiced a statement or posting up of our actual knowledge as this.—*N. Y. Journal of Medicine.*

Its claims to merit, both as a scientific and practical work, are of the highest order. Whilst we would not elevate it above every other treatise on the same subject, we certainly believe that very few are equal to it, and none superior.—*Southern Med. and Surg. Journal.*



New and Improved Edition.

# A PRACTICAL TREATISE ON THE DISEASES OF CHILDREN.

BY D. FRANCIS CONDIE, M. D.,  
Fellow of the College of Physicians, &c. &c.

Third edition, revised and augmented. In one large volume, 8vo., of over 700 pages.

In the preparation of a third edition of the present treatise, every portion of it has been subjected to a careful revision. A new chapter has been added on Epidemic Meningitis, a disease which, although not confined to children, occurs far more frequently in them, than in adults. In the other chapters of the work, all the more important facts that have been developed since the appearance of the last edition, in reference to the nature, diagnosis, and treatment of the several diseases of which they treat, have been incorporated. The great object of the author has been to present, in each succeeding edition, as full and connected a view as possible of the actual state of the pathology and therapeutics of those affections which most usually occur between birth and puberty.

To the present edition there is appended a list of the several works and essays quoted or referred to in the body of the work, or which have been consulted in its preparation or revision.

Every important fact that has been verified or developed since the publication of the previous edition, either in relation to the nature, diagnosis, or treatment of the diseases of children, have been arranged and incorporated into the body of the work: thus posing up to date, to use a counting-house phrase, all the valuable facts and useful information on the subject. To the American practitioner, Dr. Condie's remarks on the diseases of children will be invaluable, and we accordingly advise those who have failed to read this work to procure a copy, and make themselves familiar with its sound principles.—*The New Orleans Medical and Surgical Journal.*

We feel persuaded that the American Medical profession will soon regard it, not only as a very good, but as the VERY BEST "Practical Treatise on the Diseases of Children."—*American Medical Journal.*

We pronounced the first edition to be the best work on the Diseases of Children in the English language, and, notwithstanding all that has been published, we still regard it in that light.—*Medical Examiner.*

*From Professor Wm. P. Johnston, Washington, D. C.*

I make use of it as a text-book, and place it invariably in the hands of my private pupils.

*From Professor D. Humphreys Storer, of Boston.*

I consider it to be the best work on the Diseases of Children we have access to, and as such recommend it to all who ever refer to the subject.

*From Professor M. M. Pallen, of St. Louis.*

I consider it the best treatise on the Diseases of Children that we possess, and as such have been in the habit of recommending it to my classes.

Dr. Condie's scholarship, acumen, industry, and practical sense are manifested in this, as in all his numerous contributions to science.—*Dr. Hobbes's Report to the American Medical Association.*

Taken as a whole, in our judgment, Dr. Condie's Treatise is the one from the perusal of which the practitioner in this country will rise with the greatest satisfaction.—*Western Journal of Medicine and Surgery.*

One of the best works upon the Diseases of Children in the English language.—*Western Lancet.*

We feel assured from actual experience that no physician's library can be complete without a copy of this work.—*N. Y. Journal of Medicine.*

Perhaps the most full and complete work now before the profession of the United States; indeed, we may say in the English language. It is vastly superior to most of its predecessors.—*Transylvania Med Journal.*

A veritable pædiatric encyclopædia, and an honor to American medical literature.—*Ohio Medical and Surgical Journal.*

## WEST ON DISEASES OF CHILDREN.

### LECTURES ON THE

# DISEASES OF INFANCY AND CHILDHOOD.

BY CHARLES WEST, M. D.,  
Senior Physician to the Royal Infirmary for Children, &c. &c.

In one volume, octavo.

Every portion of these lectures is marked by a general accuracy of description, and by the soundness of the views set forth in relation to the pathology and therapeutics of the several maladies treated of. The lectures on the diseases of the respiratory apparatus, about one-third of the whole number, are particularly excellent, forming one of the fullest and most able accounts of these affections, as they present themselves during infancy and childhood, in the English language. The history of the several forms of phthisis during these periods of existence, with their management, will be read by all with deep interest.—*The American Journal of the Medical Sciences.*

The Lectures of Dr. West, originally published in the London Medical Gazette, form a most valuable addition to this branch of practical medicine. For many years physician to the Children's Infirmary, his opportunities for observing their diseases have been most extensive, no less than 14,000 children having been brought under his notice during the past nine years. These have evidently been studied with great care, and the result has been the production of the very best work in our language, so far as it goes, on the diseases of this class of our patients. The symptomatology and pathology of their diseases are especially exhibited most clearly; and we are convinced that no one can read with care these lectures without deriving from them instruction of the most important kind.—*Charleston Med. Journal.*

A TREATISE  
ON THE PHYSICAL AND MEDICAL TREATMENT OF CHILDREN.

BY W. P. DEWEES, M. D.  
Ninth edition. In one volume, octavo, of 548 pages.

NEW AND IMPROVED EDITION—(Just Issued.)

# OBSTETRICS:

## THE SCIENCE AND THE ART.

BY CHARLES D. MEIGS, M. D.,

Professor of Midwifery and the Diseases of Women and Children in the Jefferson Medical College, Philadelphia, &amp;c. &amp;c.

Second Edition, Revised and Improved, with 131 Illustrations.

In one beautifully printed octavo volume, of seven hundred and fifty-two large pages.

The rapid demand for a second edition of this work is a sufficient evidence that it has supplied a desideratum of the profession, notwithstanding the numerous treatises on the same subject which have appeared within the last few years. Adopting a system of his own, the author has combined the leading principles of his interesting and difficult subject, with a thorough exposition of its rules of practice, presenting the results of long and extensive experience and of familiar acquaintance with all the modern writers on this department of medicine. As an American treatise on Midwifery, which has at once assumed the position of a classic, it possesses peculiar claims to the attention and study of the practitioner and student, while the numerous alterations and revisions which it has undergone in the present edition are shown by the great enlargement of the work, which is not only increased as to the size of the page, but also in the number. Among other additions may be mentioned

## A NEW AND IMPORTANT CHAPTER ON "CHILD-BED FEVER."

As an elementary treatise—concise, but, withal, clear and comprehensive—we know of no one better adapted for the use of the student; while the young practitioner will find in it a body of sound doctrine, and a series of excellent practical directions, adapted to all the conditions of the various forms of labor and their results, which he will be induced, we are persuaded, again and again to consult, and always with profit.

It has seldom been our lot to peruse a work upon the subject, from which we have received greater satisfaction, and which we believe to be better calculated to communicate to the student correct and definite views upon the several topics embraced within the scope of its teachings.—*American Journal of the Medical Sciences.*

We are acquainted with no work on midwifery of greater practical value.—*Boston Medical and Surgical Journal.*

Worthy the reputation of its distinguished author.—*Medical Examiner.*

We most sincerely recommend it, both to the student and practitioner, as a more complete and valuable work on the Science and Art of Midwifery, than any of the numerous reprints and American editions of European works on the same subject.—*N. Y. Annalist.*

We have, therefore, great satisfaction in bringing under our reader's notice the matured views of the highest American authority in the department to which he has devoted his life and talents.—*London Medical Gazette.*

An author of established merit, a professor of Midwifery, and a practitioner of high reputation and immense experience—we may assuredly regard his work now before us as representing the most advanced state of obstetric science in America up to the time at which he writes. We consider Dr. Meigs' book as a valuable acquisition to obstetric literature, and one that will very much assist the practitioner under many circumstances of doubt and perplexity.—*The Dublin Quarterly Journal.*

These various heads are subdivided so well, so lucidly explained, that a good memory is all that is necessary in order to put the reader in possession of a thorough knowledge of this important subject. Dr. Meigs has conferred a great benefit on the profession in publishing this excellent work.—*St. Louis Medical and Surgical Journal.*

## TYLER SMITH ON PARTURITION.

## ON PARTURITION, AND THE PRINCIPLES AND PRACTICE OF OBSTETRICS.

BY W. TYLER SMITH, M. D.,

Lecturer on Obstetrics in the Hunterian School of Medicine, &amp;c. &amp;c.

In one large duodecimo volume, of 400 pages.

The work will recommend itself by its intrinsic merit to every member of the profession.—*Lancet.*

We can imagine the pleasure with which William Hunter or Denman would have welcomed the present work; certainly the most valuable contribution to obstetrics that has been made since their own day. For ourselves, we consider its appearance as the dawn of a new era in this department of medicine. We do most cordially recommend the work as one absolutely necessary to be studied by every accoucheur. It will, we may add, prove equally interesting and instructive to the student, the general practitioner, and pure obstetrician. It was a bold undertaking to reclaim parturition for Reflex Physiology, and it has been well performed.—*London Journal of Medicine.*

## LEE'S CLINICAL MIDWIFERY.

## CLINICAL MIDWIFERY,

COMPRISING THE HISTORIES OF FIVE HUNDRED AND FORTY-FIVE CASES OF DIFFICULT, PRETERNATURAL, AND COMPLICATED LABOR, WITH COMMENTARIES.

BY ROBERT LEE, M. D., F. R. S., &amp;c.

From the 2d London Edition.

In one royal 12mo. volume, extra cloth, of 238 pages.

More instructive to the juvenile practitioner than a score of systematic works.—*Lancet.*

An invaluable record for the practitioner.—*N. Y. Annalist.*

A storehouse of valuable facts and precedents.—*American Journal of the Medical Sciences.*

CHURCHILL'S MIDWIFERY, BY CONDIE, NEW AND IMPROVED EDITION—(Just Issued.)

ON THE  
**THEORY AND PRACTICE OF MIDWIFERY.**

BY FLEETWOOD CHURCHILL, M. D., &c.

A NEW AMERICAN FROM THE LAST AND IMPROVED ENGLISH EDITION.

EDITED, WITH NOTES AND ADDITIONS,

BY D. FRANCIS CONDIE, M. D.,

Author of a "Practical Treatise on the Diseases of Children," &c.

**WITH ONE HUNDRED AND THIRTY-NINE ILLUSTRATIONS.**

In one very handsome octavo volume.

In the preparation of the last English edition, from which this is printed, the author has spared no pains, with the desire of bringing it thoroughly up to the present state of obstetric science. The labors of the editor have thus been light, but he has endeavored to supply whatever he has thought necessary to the work, either as respects obstetrical practice in this country, or its progress in Europe since the appearance of Dr. Churchill's last edition. Most of the notes of the former editor, Dr. Huston, have been retained by him, where they have not been embodied by the author in his text. The present edition of this favorite text-book is therefore presented to the profession in the full confidence of its meriting a continuance of the great reputation which it has acquired as a work equally well fitted for the student and practitioner.

To bestow praise on a book that has received such marked approbation would be superfluous. We need only say, therefore, that if the first edition was thought worthy of a favorable reception by the medical public, we can confidently affirm that this will be found much more so. The lecturer, the practitioner, and the student, may all have recourse to its pages, and derive from their perusal much interest and instruction in every thing relating to theoretical and practical midwifery.—*Dublin Quarterly Journal of Medical Science.*

A work of very great merit, and such as we can confidently recommend to the study of every obstetric practitioner.—*London Medical Gazette.*

This is certainly the most perfect system extant. It is the best adapted for the purposes of a text-book, and that which he whose necessities confine him to one book, should select in preference to all others.—*Southern Medical and Surgical Journal.*

The most popular work on Midwifery ever issued from the American press.—*Charleston Medical Journal.* Certainly, in our opinion, the very best work on the subject which exists.—*N. Y. Annalist.*

Were we reduced to the necessity of having but one work on Midwifery, and permitted to choose, we would unhesitatingly take Churchill.—*Western Medical and Surgical Journal.*

It is impossible to conceive a more useful and elegant Manual than Dr. Churchill's Practice of Midwifery.—*Provincial Medical Journal.*

No work holds a higher position, or is more deserving of being placed in the hands of the tyro, the advanced student, or the practitioner.—*Medical Examiner.*

**NEW EDITION OF RAMSBOTHAM ON PARTURITION.**

**THE PRINCIPLES AND PRACTICE OF  
OBSTETRIC MEDICINE AND SURGERY,**

In reference to the Process of Parturition.

BY FRANCIS H. RAMSBOTHAM, M. D.,

Physician to the Royal Maternity Charity, &c. &c.

SIXTH AMERICAN, FROM THE LAST LONDON EDITION.

Illustrated with One Hundred and Forty-eight Figures on Fifty-five Lithographic Plates.

In one large and handsomely printed volume, imperial octavo, with 520 pages.

In this edition the plates have all been redrawn, and the text carefully read and corrected. It is therefore presented as in every way worthy the favor with which it has so long been received.

From Professor Hodge, of the University of Pennsylvania.

To the American public, it is most valuable, from its intrinsic undoubted excellence, and as being the best authorized exponent of British Midwifery. Its circulation will, I trust, be extensive throughout our country.

We recommend the student, who desires to master this difficult subject with the least possible trouble, to possess himself at once of a copy of this work.—*American Journal of the Medical Sciences.*

It stands at the head of the long list of excellent obstetric works published in the last few years in Great Britain, Ireland, and the Continent of Europe. We consider this book indispensable to the library of every physician engaged in the practice of Midwifery.—*Southern Medical and Surgical Journal.*

When the whole profession is thus unanimous in placing such a work in the very first rank as regards the extent and correctness of all the details of the theory and practice of so important a branch of learning, our commendation or condemnation would be of little consequence; but, regarding it as the most useful of all works of the kind, we think it but an act of justice to urge its claims upon the profession.—*N. O. Med. Journal.*

**DEWEES'S MIDWIFERY.**

**A COMPREHENSIVE SYSTEM OF MIDWIFERY.**

ILLUSTRATED BY OCCASIONAL CASES AND MANY ENGRAVINGS.

BY WILLIAM P. DEWEES, M. D.

Tenth Edition, with the Author's last Improvements and Corrections. In one octavo volume, of 600 pages.

**PEREIRA'S MATERIA MEDICA—Vol. I.—(Now Ready.)**  
**NEW EDITION, GREATLY IMPROVED AND ENLARGED.**

**THE ELEMENTS OF**  
**MATERIA MEDICA AND THERAPEUTICS.**

BY JONATHAN PEREIRA, M. D., F. R. S. AND L. S.

THIRD AMERICAN EDITION,

ENLARGED AND IMPROVED BY THE AUTHOR, INCLUDING NOTICES OF MOST OF THE MEDICINAL SUBSTANCES IN USE IN THE CIVILIZED WORLD, AND FORMING AN ENCYCLOPEDIA OF MATERIA MEDICA.

EDITED BY JOSEPH CARSON, M. D.,

Professor of Materia Medica and Pharmacy in the University of Pennsylvania.

In two very large volumes, on small type, with about four hundred illustrations.

The demand for this new edition of "PEREIRA'S MATERIA MEDICA" has induced the publishers to issue the First Volume separately. The Second Volume, now at press, and receiving important corrections and revisions from both author and editor, may be shortly expected for publication.

The third London edition of this work received very extensive alterations by the author. Many portions of it were entirely rewritten, some curtailed, others enlarged, and much new matter introduced in every part. The edition, however, now presented to the American profession, in addition to this, not only enjoys the advantages of a thorough and accurate superintendence by the editor, but also embodies the additions and alterations suggested by a further careful revision by the author, expressly for this country, embracing the most recent investigations, and the result of several new Pharmacopœias which have appeared since the publication of the London edition of Volume I. The notes of the American editor have been prepared with reference to the new edition of the U. S. Pharmacopœia, and contain such matter generally as is requisite to adapt it fully to the wants of the profession in this country, as well as such recent discoveries as have escaped the attention of the author. In this manner the size of the work has been materially enlarged, and the number of illustrations much increased, while its mechanical execution has been greatly improved in every respect. The profession may therefore rely on being able to procure a work which, in every point of view, will not only maintain, but greatly advance the very high reputation which it has everywhere acquired.

The work, in its present shape, and so far as can be judged from the portion before the public, forms the most comprehensive and complete treatise on materia medica extant in the English language. Dr. Pereira has been at great pains to introduce into his work, not only all the information on the natural, chemical, and commercial history of medicines, which might be serviceable to the physician and surgeon, but whatever might enable his readers to understand thoroughly the mode of preparing and manufacturing various articles employed either for preparing medicines, or for certain purposes in the arts connected with materia medica and the practice of medicine. The accounts of the physiological and therapeutic effects of remedies are given with great clearness and accuracy, and in a manner calculated to interest as well as instruct the reader.—*The Edinburgh Medical and Surgical Journal.*

**ROYLE'S MATERIA MEDICA.**

**MATERIA MEDICA AND THERAPEUTICS;**

INCLUDING THE

Preparations of the Pharmacopœias of London, Edinburgh, Dublin, and of the United States,  
 WITH MANY NEW MEDICINES.

BY J. FORBES ROYLE, M. D., F. R. S.,

Professor of Materia Medica and Therapeutics, King's College, London, &c. &c.

EDITED BY JOSEPH CARSON, M. D.,

Professor of Materia Medica and Pharmacy in the University of Pennsylvania.

WITH NINETY-EIGHT ILLUSTRATIONS.

In one large octavo volume, of about seven hundred pages.

Being one of the most beautiful Medical works published in this country.

This work is, indeed, a most valuable one, and will fill up an important vacancy that existed between Dr. Pereira's most learned and complete system of Materia Medica, and the class of productions on the other extreme, which are necessarily imperfect from their small extent.—*British and Foreign Medical Review.*

**POCKET DISPENSATORY AND FORMULARY.**

A DISPENSATORY AND THERAPEUTICAL REMEMBRANCER. Comprising the entire lists of Materia Medica, with every Practical Formula contained in the three British Pharmacopœias. With relative Tables subjoined, illustrating by upwards of six hundred and sixty examples, the Extemporaneous Forms and Combinations suitable for the different Medicines. By JOHN MAYNE, M. D., L. R. C. S., EDIN., &c. &c. Edited, with the addition of the formulæ of the United States Pharmacopœia, by R. EGLESFELD GRIFFITH, M. D. In one 12mo. volume, of over three hundred large pages.

The neat typography, convenient size, and low price of this volume, recommend it especially to physicians, apothecaries, and students in want of a pocket manual.

NEW UNIVERSAL FORMULARY.—(Lately Issued.)

**A UNIVERSAL FORMULARY,**

CONTAINING THE

**METHODS OF PREPARING AND ADMINISTERING  
OFFICINAL AND OTHER MEDICINES.**

THE WHOLE ADAPTED TO PHYSICIANS AND PHARMACEUTISTS.

BY R. EGLESFELD GRIFFITH, M. D.,

Author of "American Medical Botany," &amp;c.

In one large octavo volume of 568 pages, double columns.

A valuable acquisition to the medical practitioner, and a useful book of reference to the apothecary on numerous occasions.—*American Journal of Pharmacy.*Dr. Griffith's Formulary is worthy of recommendation, not only on account of the care which has been bestowed on it by its estimable author, but for its general accuracy, and the richness of its details.—*Medical Examiner.*Most cordially we recommend this Universal Formulary, not forgetting its adaptation to druggists and apothecaries, who would find themselves vastly improved by a familiar acquaintance with this every-day book of medicine.—*The Boston Medical and Surgical Journal.*

Pre-eminent among the best and most useful compilations of the present day will be found the work before us, which can have been produced only at a very great cost of thought and labor. A short description will suffice to show that we do not put too high an estimate on this work. We are not cognizant of the existence of a parallel work. Its value will be apparent to our readers from the sketch of its contents above given.

We strongly recommend it to all who are engaged either in practical medicine, or more exclusively with its literature.—*London Medical Gazette.*A very useful work, and a most complete compendium on the subject of materia medica. We know of no work in our language, or any other, so comprehensive in all its details.—*London Lancet.*

The vast collection of formulae which is offered by the compiler of this volume, contains a large number which will be new to English practitioners, some of them from the novelty of their ingredients, and others from the unaccustomed mode in which they are combined; and we doubt not that several of these might be advantageously brought into use. The authority for every formula is given, and the list includes a very numerous assemblage of Continental, as well as of British and American writers of repute. It is, therefore, a work to which every practitioner may advantageously resort for hints to increase his stock of remedies and of forms of prescription.

The other indices facilitate reference to every article in the "Formulary;" and they appear to have been drawn up with the same care as that which the author has evidently bestowed on every part of the work.—*The British and Foreign Medico-Chirurgical Review.*

CHRISTISON &amp; GRIFFITH'S DISPENSATORY.—(A New Work.)

**A DISPENSATORY,**

OR, COMMENTARY ON THE PHARMACOPEIAS OF GREAT BRITAIN AND THE UNITED STATES: COMPRISING THE NATURAL HISTORY, DESCRIPTION, CHEMISTRY, PHARMACY, ACTIONS, USES, AND DOSES OF THE ARTICLES OF THE MATERIA MEDICA.

BY ROBERT CHRISTISON, M. D., V. P. R. S. E.,

President of the Royal College of Physicians of Edinburgh; Professor of Materia Medica in the University of Edinburgh, etc.

Second Edition, Revised and Improved,

WITH A SUPPLEMENT CONTAINING THE MOST IMPORTANT NEW REMEDIES.

WITH COPIOUS ADDITIONS,  
AND TWO HUNDRED AND THIRTEEN LARGE WOOD ENGRAVINGS.

BY R. EGLESFELD GRIFFITH, M. D.,

Author of "A Medical Botany," etc.

In one very large and handsome octavo volume, of over one thousand closely-printed pages, with numerous wood-cuts, beautifully printed on fine white paper, presenting an immense quantity of matter at an unusually low price.

It is enough to say that it appears to us as perfect as a Dispensatory, in the present state of pharmaceutical science, could be made.—*The Western Journal of Medicine and Surgery.*

CARSON'S SYNOPSIS.—(Just Issued.)

**SYNOPSIS OF THE  
COURSE OF LECTURES ON MATERIA MEDICA AND PHARMACY,**

Delivered in the University of Pennsylvania.

BY JOSEPH CARSON, M. D.,

Professor of Materia Medica and Pharmacy in the University of Pennsylvania.

In one very neat octavo volume of 208 pages.

**THE THREE KINDS OF COD-LIVER OIL,**

Comparatively considered, with their Chemical and Therapeutic Properties, by L. J. DE JONGH, M. D. Translated, with an Appendix and Cases, by EDWARD CAREY, M. D. To which is added an article on the subject from "Dunglison on New Remedies." In one small 12mo. volume, extra cloth.

**DUNGLISON'S THERAPEUTICS.**  
**NEW AND IMPROVED EDITION.—(Lately Issued.)**

**GENERAL THERAPEUTICS AND MATERIA MEDICA;**

ADAPTED FOR A MEDICAL TEXT-BOOK,

BY **ROBLEY DUNGLISON, M. D.,**

Professor of Institutes of Medicine, &c., in Jefferson Medical College; Late Professor of *Materia Medica*, &c.  
 in the Universities of Maryland and Virginia, and in Jefferson Medical College.

FOURTH EDITION, MUCH IMPROVED.

**With One Hundred and Eighty-two Illustrations.**

In two large and handsomely printed octavo volumes.

The present edition of this standard work has been subjected to a thorough revision both as regards style and matter, and has thus been rendered a more complete exponent than heretofore of the existing state of knowledge on the important subjects of which it treats. The favor with which the former editions have everywhere been received seemed to demand that the present should be rendered still more worthy of the patronage of the profession, and of the medical student in particular, for whose use more especially it is proposed; while the number of impressions through which it has passed has enabled the author so to improve it as to enable him to present it with some degree of confidence as well adapted to the purposes for which it is intended. In the present edition, the remedial agents of recent introduction have been inserted in their appropriate places; the number of illustrations has been greatly increased, and a copious index of diseases and remedies has been appended, improvements which can scarcely fail to add to the value of the work to the therapeutical inquirer.

The publishers, therefore, confidently present the work as it now stands to the notice of the practitioner as a trustworthy book of reference, and to the student, for whom it was more especially prepared, as a full and reliable text-book on General Therapeutics and *Materia Medica*.

Notwithstanding the increase in size and number of illustrations, and the improvements in the mechanical execution of the work, its price has not been increased.

In this work of Dr. Dunglison, we recognize the same untiring industry in the collection and embodying of facts on the several subjects of which he treats, that has heretofore distinguished him, and we cheerfully point to these volumes, as two of the most interesting that we know of. In noticing the additions to this, the fourth edition, there is very little in the periodical or annual literature of the profession, published in the interval which has elapsed since the issue of the first, that has escaped the careful search of the author. As a book for reference, it is invaluable.—*Charleston Med. Journal and Review.*

It may be said to be the work now upon the subjects upon which it treats.—*Western Lancet.*

As a text book for students, for whom it is particularly designed, we know of none superior to it.—*St. Louis Medical and Surgical Journal.*

It purports to be a new edition, but it is rather a new book, so greatly has it been improved both in the amount and quality of the matter which it contains.—*N. O. Medical and Surgical Journal.*

We bespeak for this edition from the profession an increase of patronage over any of its former ones, on account of its increased merit.—*N. Y. Journal of Medicine.*

We consider this work unequalled.—*Boston Med. and Surg. Journal.*

**NEW AND MUCH IMPROVED EDITION.**

**NEW REMEDIES,**

**WITH FORMULÆ FOR THEIR ADMINISTRATION.**

BY **ROBLEY DUNGLISON, M. D.,**

PROFESSOR OF THE INSTITUTES OF MEDICINE, ETC. IN THE JEFFERSON MEDICAL COLLEGE OF PHILADELPHIA.

**Sixth Edition, with extensive Additions.**

In one very large octavo volume, of over seven hundred and fifty pages.

The fact that this work has rapidly passed to a **SIXTH EDITION** is sufficient proof that it has supplied a desideratum to the profession in presenting them with a clear and succinct account of all new and important additions to the *materia medica*, and novel applications of old remedial agents. In the preparation of the present edition, the author has shrunk from no labor to render the volume worthy of a continuance of the favor with which it has been received, as is sufficiently shown by the increase of about one hundred pages in the size of the work. The necessity of such large additions arises from the fact that the last few years have been rich in valuable gifts to Therapeutics; and amongst these, ether, chloroform, and other so-called anæsthetics, are worthy of special attention. They have been introduced since the appearance of the last edition of the "**NEW REMEDIES.**" Other articles have been proposed for the first time, and the experience of observers has added numerous interesting facts to our knowledge of the virtues of remedial agents previously employed.

The therapeutical agents now first admitted into this work, some of which have been newly introduced into pharmacology, and the old agents brought prominently forward with novel applications, and which may consequently be regarded as *New Remedies*, are the following:—*Adansonia digitata*, Benzoate of Ammonia, Valerianate of Bismuth, Sulphate of Cadmium, Chloroform, Collodion, Cautharidal Collodion, *Cotyledon Umbilicus*, Sulphuric Ether, Stroug Chloric Ether, Compound Ether, *Hura Braziliensis*, *Iberis Amara*, Iodic Acid, Iodide of Chloride of Mercury, Powdered Iron, Citrate of Magnetic Oxide of Iron, Citrate of Iron and Magnesia, Sulphate of Iron and Alumina, Tannate of Iron, Valerianate of Iron, Nitrate of Lead, Lemon Juice, Citrate of Magnesia, Salts of Manganese, Oleum Cadinum, Arsenite of Quinia, Hydriodate of Iron and Quinia, *Sanicula Marilandica*, and Sumbul.

MOHR, REDWOOD, AND PROCTER'S PHARMACY.—(Lately Issued.)

**PRACTICAL PHARMACY.**

COMPRISING THE ARRANGEMENTS, APPARATUS, AND MANIPULATIONS OF THE PHARMACEUTICAL SHOP AND LABORATORY.

BY FRANCIS MOHR, Ph. D.,  
Assessor Pharmacicæ of the Royal Prussian College of Medicine, Cohlentz;  
AND THEOPHILUS REDWOOD,  
Professor of Pharmacy in the Pharmaceutical Society of Great Britain.EDITED, WITH EXTENSIVE ADDITIONS, BY PROFESSOR WILLIAM PROCTER,  
Of the Philadelphia College of Pharmacy.

In one handsomely printed octavo volume, of 570 pages, with over 500 engravings on wood.

To physicians in the country, and those at a distance from competent pharmacists, as well as to apothecaries, this work will be found of great value, as embodying much important information which is to be met with in no other American publication.

After a pretty thorough examination, we can recommend it as a highly useful book, which should be in the hands of every apothecary. Although no instruction of this kind will enable the beginner to acquire that practical skill and readiness which experience only can confer, we believe that this work will much facilitate their acquisition, by indicating means for the removal of difficulties as they occur, and suggesting methods of operation in conducting pharmaceutical processes which the experimenter would only hit upon after many unsuccessful trials; while there are few pharmacists, of however extensive experience, who will not find in it valuable hints that they can turn to use in conducting the affairs of the shop and laboratory. The mechanical execution of the work is in a style of unusual excellence. It contains about five hundred and seventy large octavo pages, handsomely printed on good paper, and illustrated by over five hundred remarkably well-executed wood-cuts of chemical and pharmaceutical apparatus. It comprises the whole of Mohr and Redwood's book, as published in London, rearranged and classified by the American editor, who has added much valuable new matter, which has increased the size of the book more than one-fourth, including about one hundred additional wood-cuts.—*The American Journ. of Pharmacy.*

It is a book, however, which will be in the hands of almost every one who is much interested in pharmaceutical operations, as we know of no other publication so well calculated to fill a void long felt.—*The Medical Examiner.*

The country practitioner who is obliged to dispense his own medicines, will find it a most valuable assistant.—*Monthly Journal and Retrospect.*

The book is strictly practical, and describes only manipulations or methods of performing the numerous processes the pharmacist has to go through, in the preparation and manufacture of medicines, together with all the apparatus and fixtures necessary thereto. On these matters, this work is very full and complete, and details, in a style uncommonly clear and lucid, not only the more complicated and difficult processes, but those not less important ones, the most simple and common. The volume is an octavo of five hundred and seventy-six pages. It is elegantly illustrated with a multitude of neat wood engravings, and is unexceptionable in its whole typographical appearance and execution. We take great satisfaction in commending this so much needed treatise, not only to those for whom it is more specially designed, but to the medical profession generally—to every one, who, in his practice, has occasion to prepare, as well as administer medical agents.—*Buffalo Medical Journal.*

**NEW AND COMPLETE MEDICAL BOTANY.****MEDICAL BOTANY;**

OR, A DESCRIPTION OF ALL THE MORE IMPORTANT PLANTS USED IN MEDICINE, AND OF THEIR PROPERTIES, USES, AND MODES OF ADMINISTRATION.

BY R. EGLESFELD GRIFFITH, M. D., &amp;c. &amp;c.

In one large 8vo. vol. of 704 pages, handsomely printed, with nearly 350 illustrations on wood.

One of the greatest acquisitions to American medical literature. It should by all means be introduced, at the very earliest period, into our medical schools, and occupy a place in the library of every physician in the land.—*Southwestern Medical Advocate.*

Admirably calculated for the physician and student—we have seen no work which promises greater advantages to the profession.—*N. O. Medical and Surgical Journal.*

One of the few books which supply a positive deficiency in our medical literature.—*Western Lancet.*

We hope the day is not distant when this work will not only be a text-book in every medical school and college in the Union, but find a place in the library of every private practitioner.—*N. Y. Journ. of Medicine.*

**ELLIS'S MEDICAL FORMULARY.—(Improved Edition.)****THE MEDICAL FORMULARY:**

BEING A COLLECTION OF PRESCRIPTIONS, DERIVED FROM THE WRITINGS AND PRACTICE OF MANY OF THE MOST EMINENT PHYSICIANS OF AMERICA AND EUROPE.

To which is added an Appendix, containing the usual Dietetic Preparations and Antidotes for Poisons.

THE WHOLE ACCOMPANIED WITH A FEW BRIEF PHARMACEUTIC AND MEDICAL OBSERVATIONS.

BY BENJAMIN ELLIS, M. D.

NINTH EDITION, CORRECTED AND EXTENDED, BY SAMUEL GEORGE MORTON M. D.

In one neat octavo volume of 268 pages.

**CARPENTER ON ALCOHOLIC LIQUORS.—(A New Work.)**

A Prize Essay on the Use of Alcoholic Liquors in Health and Disease. By William B. Carpenter, M. D., author of "Principles of Human Physiology," &amp;c. In one 12mo. volume.

**NEW EDITION OF GRAHAM'S CHEMISTRY—(Now Ready.)**

## ELEMENTS OF CHEMISTRY;

INCLUDING THE APPLICATIONS OF THE SCIENCE IN THE ARTS.

BY THOMAS GRAHAM, F. R. S., &c.

Second American, from the entirely Revised, and greatly Enlarged, Second London Edition.

WITH NOTES AND ADDITIONS BY ROBERT BRIDGES, M. D.

*To be complete in one very large octavo volume, with several hundred beautiful illustrations.*

PART I, now ready, of about 450 large pages, with 185 illustrations.

PART II, completing the work, preparing for early publication.

The great changes which the science of chemistry has undergone within the last few years, render a new edition of a treatise like the present almost a new work. The author has devoted several years to the revision of his treatise, and has endeavored to embody in it every fact and inference of importance which has been observed and recorded by the great body of chemical investigators, who are so rapidly changing the face of the science. In this manner the work has been greatly increased in size, and the number of illustrations doubled; while the labors of the editor have been directed towards the introduction of such matters as have escaped the attention of the author, or as have arisen since the publication of the first portion of this edition in London, in 1850. Printed in handsome style, and at a very low price, it is therefore confidently presented to the profession and the student as a very complete and thorough text-book of this important subject

**NEW AND IMPROVED EDITION—(Lately Issued.)**

## ELEMENTARY CHEMISTRY,

THEORETICAL AND PRACTICAL.

BY GEORGE FOWNES, PH. D.,

Chemical Lecturer in the Middlesex Hospital Medical School, &c. &c.

WITH NUMEROUS ILLUSTRATIONS.

THIRD AMERICAN, FROM A LATE LONDON EDITION. EDITED, WITH ADDITIONS,

BY ROBERT BRIDGES, M. D.,

Professor of General and Pharmaceutical Chemistry in the Philadelphia College of Pharmacy, &c. &c.

In one large royal 12mo. vol., of over 500 pages, with about 180 wood-cuts, sheep or extra cloth.

The work of Dr. Fownes has long been before the public, and its merits have been fully appreciated as the best text-book on Chemistry now in existence. We do not, of course, place it in a rank superior to the works of Braude, Graham, Turner, Gregory, or Gmelin, but we say that, as a work for students, it is preferable to any of them.—*London Journal of Medicine.*

The rapid sale of this Manual evinces its adaptation to the wants of the student of chemistry, whilst the well-known merits of its lamented author have constituted a guarantee for its value, as a faithful exposition of the general principles and most important facts of the science to which it professes to be an introduction.—*The British and Foreign Medico-Chirurgical Review.*

A work well adapted to the wants of the student. It is an excellent exposition of the chief doctrines and facts of modern chemistry, originally intended as a guide to the lectures of the author, corrected by his own hand shortly before his death in 1849, and recently revised by Dr. Bence Jones, who has made some additions to the chapter on animal chemistry. Although not intended to supersede the more extended treatises on chemistry, Professor Fownes' Manual may, we think, be often used as a work of reference, even by those advanced in the study, who may be desirous of refreshing their memory on some forgotten point. The size of the work, and still more the condensed yet perspicuous style in which it is written, absolve it from the charges very properly urged against most manuals termed popular, viz., of omitting details of indispensable importance, of avoiding technical difficulties, instead of explaining them, and of treating subjects of high scientific interest in an unscientific way.—*Edinburgh Monthly Journal of Medical Science.*

**BOWMAN'S MEDICAL CHEMISTRY—(Lately Issued.)**

## PRACTICAL HANDBOOK OF MEDICAL CHEMISTRY.

BY JOHN E. BOWMAN, M. D.

In one neat volume, royal 12mo., with numerous illustrations.

Mr. Bowman has succeeded in supplying a desideratum in medical literature. In the little volume before us, he has given a concise but comprehensive account of all matters in chemistry which the man in practice may desire to know.—*Lancet.*

**BY THE SAME AUTHOR—(Lately Issued.)**

## INTRODUCTION TO PRACTICAL CHEMISTRY, Including Analysis.

With Numerous Illustrations. In one neat volume, royal 12mo.

**GARDNER'S MEDICAL CHEMISTRY.**

## MEDICAL CHEMISTRY,

FOR THE USE OF STUDENTS AND THE PROFESSION;

BEING A MANUAL OF THE SCIENCE, WITH ITS APPLICATIONS TO TOXICOLOGY, PHYSIOLOGY, THERAPEUTICS, HYGIENE, &c.

BY D. PEREIRA GARDNER, M. D.

In one handsome royal 12mo. volume, with illustrations.



**TAYLOR'S MEDICAL JURISPRUDENCE.**  
**MEDICAL JURISPRUDENCE.**

BY ALFRED S. TAYLOR,

SECOND AMERICAN, FROM THE THIRD AND ENLARGED LONDON EDITION.

With numerous Notes and Additions, and References to American Practice and Law.

BY R. E. GRIFFITH, M. D.

In one large octavo volume.

This work has been much enlarged by the author, and may now be considered as the standard authority on the subject, both in England and this country. It has been thoroughly revised, in this edition, and completely brought up to the day with reference to the most recent investigations and decisions. No further evidence of its popularity is needed than the fact of its having, in the short time that has elapsed since it originally appeared, passed to three editions in England, and two in the United States.

We recommend Mr. Taylor's work as the ablest, most comprehensive, and, above all, the most practically useful book which exists on the subject of legal medicine. Any man of sound judgment, who has mastered the contents of Taylor's "Medical Jurisprudence," may go into a court of law with the most perfect confidence of being able to acquit himself creditably.—*Medico-Chirurgical Review*.

The most elaborate and complete work that has yet appeared. It contains an immense quantity of cases lately tried, which entitle it to be considered what Beck was in its day.—*Dublin Medical Journal*.

**TAYLOR ON POISONS.**

**ON POISONS,**

**IN RELATION TO MEDICAL JURISPRUDENCE AND MEDICINE.**

BY ALFRED S. TAYLOR, F. R. S., &c.

EDITED, WITH NOTES AND ADDITIONS, BY R. E. GRIFFITH, M. D.

In one large octavo volume, of 688 pages.

The most elaborate work on the subject that our literature possesses.—*Brit. and For. Medico-Chirur. Review*.

One of the most practical and trustworthy works on Poisons in our language.—*Western Journal of Med.*

It contains a vast body of facts, which embrace all that is important in toxicology, all that is necessary to the guidance of the medical jurist, and all that can be desired by the lawyer.—*Medico-Chirurgical Review*.

It is, so far as our knowledge extends, incomparably the best upon the subject; in the highest degree creditable to the author, entirely trustworthy, and indispensable to the student and practitioner.—*N. Y. Annalist*.

**LARDNER ON HEAT, ELECTRICITY, &c.**—(Now Ready.)

**HANDBOOK OF**

**HEAT, MAGNETISM, COMMON ELECTRICITY, AND  
 VOLTAIC ELECTRICITY.**

BY DIONYSIUS LARDNER, LL. D., &c.

In one very neat volume, royal 12mo., with 250 illustrations, strongly bound in leather.

A good manual of the existing state of knowledge on these interesting and important subjects has long been a desideratum. This want the author has endeavored to supply in the present volume, and his name is a sufficient guarantee for its accuracy, fulness, and clearness. The additions of the editor have been mostly confined to the portion devoted to Heat, which may be considered as the most complete treatise on that subject accessible to the student in this country. It forms the second Course of Lardner's Handbooks of Natural Philosophy and Astronomy.

Just Issued—**FIRST COURSE**, containing Mechanics, Hydrostatics, Hydraulics, Pneumatics, Sound, and Optics, in one very large royal 12mo. volume, with 424 illustrations.

The **THIRD COURSE**, constituting a complete Treatise on Astronomy and Meteorology, is in preparation for early publication.

**SCHOEDLER AND MEDLOCK'S BOOK OF NATURE**—(Nearly Ready.)

**THE BOOK OF NATURE;**

AN ELEMENTARY INTRODUCTION TO THE SCIENCES OF

Physics, Astronomy, Chemistry, Mineralogy, Geology, Botany, Zoology, and Physiology

BY FREDERICK SCHOEDLER, PH. D.,

Professor of the Natural Sciences at Worms.

PREPARED BY HENRY MEDLOCK, F. C. S., &c.

WITH ALTERATIONS AND ADDITIONS BY THE AMERICAN EDITOR.

In one thick volume, small octavo, with over six hundred illustrations on wood.

**DUNGLISON ON HUMAN HEALTH**—**HUMAN HEALTH**, or the Influence of Atmosphere and Locality, Change of Air and Climate, Seasons, Food, Clothing, Bathing, Exercise, Sleep, &c. &c. &c., on healthy man; constituting Elements of Hygiene. Second edition, with many modifications and additions. By Robley Dunglison, M. D., &c. &c. In one octavo volume of 464 pages.

**BARFLETT ON CERTAINTY IN MEDICINE**.—An Inquiry into the Degree of Certainty in Medicine, and into the Nature and Extent of its Power over Disease. In one vol. royal 12mo. 84 pp.

**BEALE ON HEALTH**.—The Laws of Health in Relation to Mind and Body. 1 vol. royal 12mo.

**GREGORY ON ANIMAL MAGNETISM**.—Letters to a Candid Enquirer on Animal Magnetism. 1 vol royal 12mo.

**DICKSON'S ESSAYS**.—On Life, Sleep, Pain, Intellection, Hygiene, and Death. 1 vol. royal 12mo.

## THE GREAT AMERICAN MEDICAL DICTIONARY.

New and Enlarged Edition—(Now Ready.)

**MEDICAL LEXICON;****A DICTIONARY OF MEDICAL SCIENCE,**

Containing a Concise Explanation of the various Subjects and Terms of

PHYSIOLOGY, PATHOLOGY, HYGIENE, THERAPEUTICS, PHARMACOLOGY,  
OBSTETRICS, MEDICAL JURISPRUDENCE, &c.**WITH THE FRENCH AND OTHER SYNONYMS.**

NOTICES OF CLIMATE AND OF CELEBRATED MINERAL WATERS;

Formulæ for various Official, Empirical, and Dietetic Preparations, &amp;c.

**BY ROBLEY DUNGLISON, M. D.,**

Professor of Institutes of Medicine, &amp;c. in Jefferson Medical College, Philadelphia, &amp;c.

**NINTH EDITION, REVISED.**

In one very thick 8vo. vol., of 927 large double-columned pages, strongly bound, with raised bands.

Every successive edition of this work bears the marks of the industry of the author, and of his determination to keep it fully on a level with the most advanced state of medical science. Thus the last two editions contained about NINE THOUSAND SUBJECTS AND TERMS not comprised in the one immediately preceding, and the present has not less than FOUR THOUSAND not in any former edition. As a complete Medical Dictionary, therefore, embracing over FIFTY THOUSAND definitions, in all the branches of the science, it is presented as meriting a continuance of the great favor and popularity which have carried it, within no very long space of time, to an eighth edition.

Every precaution has been taken in the preparation of the present volume, to render its mechanical execution and typographical accuracy worthy of its extended reputation and universal use. The very extensive additions have been accommodated, without materially increasing the bulk of the volume, by the employment of a small but exceedingly clear type, cast for this purpose. The press has been watched with great care, and every effort used to insure the verbal accuracy so necessary to a work of this nature. The whole is printed on fine white paper; and while thus exhibiting in every respect so great an improvement over former issues, it is presented at the original exceedingly low price.

On the appearance of the last edition of this valuable work, we directed the attention of our readers to its peculiar merits; and we need do little more than state, in reference to the present re-issue, that notwithstanding the large additions previously made to it, no fewer than four thousand terms, not to be found in the preceding edition, are contained in the volume before us. Whilst it is a wonderful monument of its author's erudition and industry, it is also a work of great practical utility, as we can testify from our own experience; for we keep it constantly within our reach, and make very frequent reference to it, nearly always finding in it the information we seek.—*British and Foreign Medico-Chirurgical Review*, April, 1852.

Dr. Dunglison's Lexicon has the rare merit that it certainly has no rival in the English language for accuracy and extent of references. The terms generally include short physiological and pathological descriptions, so that, as the author justly observes, the reader does not possess in this work a mere dictionary, but a book, which, while it instructs him in medical etymology, furnishes him with a large amount of useful information. That we are not over-estimating the merits of this publication, is proved by the fact that we have now before us the seventh edition. This, at any rate, shows that the author's labors have been properly appreciated by his own countrymen; and we can only confirm their judgment, by recommending this most useful volume to the notice of our cisatlantic readers. No medical library will be complete without it.—*The London Med. Gazette*.

It is certainly more complete and comprehensive than any with which we are acquainted in the English language. Few, in fact, could be found better qualified than Dr. Dunglison for the production of such a work. Learned, industrious, persevering, and accurate, he brings to the task all the peculiar talents necessary for its successful performance: while, at the same time, his familiarity with the writings of the ancient and modern "masters of our art," renders him skillful to note the exact usage of the several terms of science, and the various modifications which medical terminology has undergone with the change of theories or the progress of improvement.—*American Journal of the Medical Sciences*.

One of the most complete and copious known to the cultivators of medical science.—*Boston Med. Journal*.  
This most complete Medical Lexicon—certainly one of the best works of the kind in the language.—*Charleston Medical Journal*.

The most complete Medical Dictionary in the English language.—*Western Lancet*.

Dr. Dunglison's Dictionary has not its superior, if indeed its equal, in the English language.—*St. Louis Med. and Surg. Journal*.

Familiar with nearly all the medical dictionaries now in print, we consider the one before us the most complete, and an indispensable adjunct to every medical library.—*British American Medical Journal*.

We repeat our former declaration that this is the best Medical Dictionary in the English language.—*Western Lancet*.

We have no hesitation to pronounce it the very best Medical Dictionary now extant.—*Southern Medical and Surgical Journal*.

The most comprehensive and best English Dictionary of medical terms extant.—*Buffalo Med. Journal*.

**HOBLYN'S MEDICAL DICTIONARY.****A DICTIONARY OF THE TERMS USED IN MEDICINE**

AND THE COLLATERAL SCIENCES.

**BY RICHARD D. HOBLYN, A. M., OXON.**

REVISED, WITH NUMEROUS ADDITIONS, FROM THE SECOND LONDON EDITION,

BY ISAAC HAYS, M. D., &amp;c. In one large royal 12mo. volume of 402 pages, double columns.

We cannot too strongly recommend this small and cheap volume to the library of every student and practitioner.—*Medico-Chirurgical Review*.

M. L. Page

Kaleyon Hill  
# 3 4 5 6 7 8 9 10 11 12 13 14 15 16 17 18 19 20 21 22 23 24 25 26 27 28 29 30 31 32 33 34 35 36 37 38 39 40 41 42 43 44 45 46 47 48 49 50 51 52 53 54 55 56 57 58 59 60 61 62 63 64 65 66 67 68 69 70 71 72 73 74 75 76 77 78 79 80 81 82 83 84 85 86 87 88 89 90 91 92 93 94 95 96 97 98 99 100

Kaleyon Hill  
Tenn. Co. Tenn.

