







BOSTONIENSIS

SERVAT ET DOCEI

BIBLIOTHECA

MEDICINAE

FVNDATA


EX DONO

MDCCLXXI









Digitized by the Internet Archive  
in 2011 with funding from  
Open Knowledge Commons and Harvard Medical School

# ANATOMY

DESCRIPTIVE AND SURGICAL

BY

HENRY GRAY, F.R.S.

FELLOW OF THE ROYAL COLLEGE OF SURGEONS  
LECTURER ON ANATOMY AT ST GEORGE'S HOSPITAL MEDICAL SCHOOL

THE DRAWINGS BY H. V. CARTER, M.D.

LATE DEMONSTRATOR OF ANATOMY AT ST GEORGE'S HOSPITAL

WITH ADDITIONAL DRAWINGS IN LATER EDITIONS

FOURTEENTH EDITION

EDITED BY

T. PICKERING PICK

SENIOR SURGEON TO ST GEORGE'S HOSPITAL; SENIOR SURGEON VICTORIA HOSPITAL FOR CHILDREN  
H.M. INSPECTOR OF ANATOMY IN ENGLAND AND WALES

LONGMANS, GREEN, AND CO.

39 PATERNOSTER ROW, LONDON

AND BOMBAY

1897





2229

9789.

TO

SIR BENJAMIN COLLINS BRODIE, BART.

F.R.S., D.C.L.

SERJEANT-SURGEON TO THE QUEEN

CORRESPONDING MEMBER OF THE INSTITUTE OF FRANCE

THIS WORK IS DEDICATED

IN ADMIRATION OF

HIS GREAT TALENTS

AND IN REMEMBRANCE OF

MANY ACTS OF KINDNESS SHOWN TO THE AUTHOR

FROM AN

EARLY PERIOD OF HIS PROFESSIONAL CAREER



# PREFACE

TO

THE FOURTEENTH EDITION

---

**I**N this edition the whole work has undergone a careful revision, and in some parts sections have been almost entirely re-written. Many new illustrations have been added, and in some places old illustrations have been eliminated and have been replaced by others.

In connection with the Peritoneum, it was thought that the description of its complex folds would be rendered more intelligible by studying its simple primitive type in the embryo and by describing its development. The Editor has therefore availed himself of the pen of Dr. FRED. T. BROCKWAY, Assistant Demonstrator of Anatomy, College of Physicians and Surgeons, (Columbia University) New York, who has written a very clear and concise account of the Development of the Peritoneum, which was published in the last issue of the American edition of this work. This the Editor, by the kind permission of Messrs. LEA BROTHERS & Co., of Philadelphia, has introduced into the present edition.

It is hoped that this edition will maintain the reputation which the work has for so many years enjoyed.



# CONTENTS



## GENERAL ANATOMY

	PAGE		PAGE
The Blood . . . . .	1	The Sympathetic Nerve . . . . .	46
The Lymph and Chyle . . . . .	6	Origin and Termination of Nerves . . . . .	47
The Animal Cell . . . . .	7	The Ganglia . . . . .	50
Epithelium . . . . .	12	The Vascular System . . . . .	51
Connective Tissues . . . . .	15	The Arteries . . . . .	52
Adipose Tissue . . . . .	20	The Capillaries . . . . .	54
Pigment . . . . .	21	The Veins . . . . .	55
Cartilage . . . . .	21	The Lymphatics . . . . .	57
White Fibro-cartilage . . . . .	23	The Lymphatic Glands . . . . .	58
Yellow or Reticular, Elastic Car- tilage . . . . .	24	The Skin and its Appendages . . . . .	61
Bone . . . . .	25	The Nails . . . . .	64
Development of Bone . . . . .	30	The Hair . . . . .	64
Muscular Tissue . . . . .	35	The Sebaceous Glands . . . . .	66
Striped Muscle . . . . .	36	The Sudoriferous Glands . . . . .	66
Unstriped Muscle . . . . .	39	Serous Membranes . . . . .	68
Nervous Tissue . . . . .	40	Synovial Membranes . . . . .	69
The Brain . . . . .	44	Mucous Membranes . . . . .	69
The Nerves . . . . .	45	Secreting Glands . . . . .	70

## DEVELOPMENT

Origin and Development of the Body . . . . .	72	The Ear . . . . .	99
The Ovum . . . . .	72	The Nose . . . . .	100
Fertilisation of . . . . .	74	The Skin, Glands, and Soft Parts . . . . .	100
Segmentation of . . . . .	74	The Limbs . . . . .	100
Blastodermic Membrane . . . . .	76	The Muscles . . . . .	101
First Rudiments of the Embryo . . . . .	79	The Blood-vascular System . . . . .	101
Formation of Membranes . . . . .	84	Vitelline Circulation . . . . .	101
The Amnion . . . . .	84	Placental Circulation . . . . .	103
The Chorion . . . . .	85	The Alimentary Canal and its Appen- dages . . . . .	108
The Allantois . . . . .	85	The Respiratory Organs . . . . .	110
The Decidua . . . . .	86	The Urinary Organs . . . . .	110
The Placenta . . . . .	87	The Generative Organs . . . . .	112
Development of the Embryo . . . . .	88	Ovary . . . . .	113
The Spine . . . . .	88	Testicle . . . . .	113
The Ribs and Sternum . . . . .	90	External Organs . . . . .	115
The Cranium and Face . . . . .	90	Chronological Tables of the Develop- ment of the Fœtus . . . . .	117
The Nervous Centres . . . . .	93		
The Nerves . . . . .	96		
The Eye . . . . .	97		

## THE SKELETON

The Skeleton . . . . .	119	Characters of the Dorsal Vertebræ . . . . .	125
Number of the Bones . . . . .	119	Peculiar Dorsal Vertebræ . . . . .	127
Form of Bones . . . . .	119	Characters of the Lumbar Vertebræ . . . . .	127
<i>The Spine</i>		Structure of the Vertebræ . . . . .	129
General Characters of a Vertebra . . . . .	120	Development of the Vertebræ . . . . .	129
Characters of the Cervical Vertebræ . . . . .	121	Atlas . . . . .	130
Atlas . . . . .	122	Axis . . . . .	130
Axis . . . . .	124	Seventh Cervical . . . . .	131
Seventh Cervical . . . . .	125	Lumbar Vertebræ . . . . .	131
		Progress of Ossification in the Spine . . . . .	131



	PAGE		PAGE
Sacral and Coccygeal Vertebrae . . . . .	131	The Scapula . . . . .	225
Sacrum . . . . .	132	Surface form . . . . .	230
Coccyx . . . . .	136	Surgical Anatomy . . . . .	231
Of the Spine in general . . . . .	137	The Humerus . . . . .	231
Surface form of Spine . . . . .	139	Surface form . . . . .	236
Surgical Anatomy of Spine . . . . .	140	Surgical Anatomy . . . . .	237
<i>The Skull</i>			
Bones of the Cranium . . . . .	141	The Ulna . . . . .	238
Occipital Bone . . . . .	141	Surface form . . . . .	242
Parietal Bones . . . . .	145	The Radius . . . . .	243
Frontal Bone . . . . .	148	Surface form . . . . .	245
Temporal Bones . . . . .	151	Surgical Anatomy of Bones of Forearm . . . . .	245
Sphenoid Bone . . . . .	158	The Hand . . . . .	246
Ethmoid Bone . . . . .	163	The Carpus . . . . .	246
Development of the Cranium . . . . .	166	Bones of the Upper Row . . . . .	246
The Fontanelles . . . . .	166	Bones of the Lower Row . . . . .	251
Wormian Bones . . . . .	167	The Metacarpus . . . . .	253
Congenital Fissures and Gaps . . . . .	167	Peculiar Characters of the Metacarpal Bones . . . . .	254
Bones of the Face :		Phalanges . . . . .	256
Nasal Bones . . . . .	167	Surface form of Bones of Hand . . . . .	257
Superior Maxillary Bones . . . . .	169	Surgical Anatomy of Bones of Hand . . . . .	258
Changes produced in Upper Jaw by age . . . . .	174	Development of the Bones of the Hand . . . . .	258
Lachrymal Bones . . . . .	174	<i>The Lower Extremity</i>	
Malar Bones . . . . .	175	Os Innominatum . . . . .	259
Palate Bones . . . . .	177	Ilium . . . . .	259
Inferior Turbinated Bones . . . . .	180	Ischium . . . . .	262
Vomer . . . . .	181	Os Pubis . . . . .	264
Inferior Maxillary Bone . . . . .	183	Development of the Os Innominatum . . . . .	265
Changes produced in the Lower Jaw by age . . . . .	186	The Pelvis . . . . .	267
Sutures of the Skull . . . . .	186	Differences between the Male and Female Pelvis . . . . .	270
Vertex of the Skull . . . . .	189	Surface form of Bones of Pelvis . . . . .	270
Base of the Skull, Internal Surface . . . . .	190	Surgical Anatomy of Bones of Pelvis . . . . .	271
Anterior Fossa . . . . .	190	The Femur . . . . .	271
Middle Fossa . . . . .	191	Surface form . . . . .	278
Posterior Fossa . . . . .	192	Surgical Anatomy . . . . .	278
Base of Skull, External Surface . . . . .	193	The Leg . . . . .	279
Lateral Region of the Skull . . . . .	196	Patella . . . . .	279
Temporal Fossa . . . . .	197	Surface form . . . . .	280
Mastoid Portion . . . . .	197	Surgical Anatomy . . . . .	280
Zygomatic Fossa . . . . .	197	Tibia . . . . .	280
Spheno-maxillary Fossa . . . . .	198	Surface form . . . . .	284
Anterior Region of the Skull . . . . .	199	Fibula . . . . .	285
Orbits . . . . .	199	Surface form . . . . .	287
Nasal Fossæ . . . . .	201	Surgical Anatomy of Bones of Leg . . . . .	287
Surface form of Skull . . . . .	204	The Foot . . . . .	287
Surgical Anatomy of Skull . . . . .	206	Tarsus . . . . .	287
Os Hyoides . . . . .	209	Os Calcis . . . . .	287
<i>The Thorax</i>			
The Sternum . . . . .	211	Astragalus . . . . .	291
The Ribs . . . . .	214	Cuboid . . . . .	293
Peculiar Ribs . . . . .	217	Navicular . . . . .	294
Costal Cartilages . . . . .	218	Internal Cuneiform . . . . .	294
Surface form of Chest . . . . .	219	Middle Cuneiform . . . . .	295
Surgical Anatomy of Chest . . . . .	220	External Cuneiform . . . . .	296
<i>The Upper Extremity</i>			
The Shoulder and Pelvic Girdles . . . . .	221	Metatarsal Bones . . . . .	297
The Clavicle . . . . .	222	Phalanges . . . . .	300
Surface form . . . . .	224	Development of the Bones of the Foot . . . . .	300
Surgical Anatomy . . . . .	224	Construction of the Foot as a whole . . . . .	301
		Surface form of Foot . . . . .	302
		Surgical Anatomy of Foot . . . . .	302
		Sesamoid Bones . . . . .	304

THE ARTICULATIONS

Structures composing the Joints . . . . .	305	Bursæ . . . . .	306
Articular Lamella of Bone . . . . .	305	Synovia . . . . .	306
Ligaments . . . . .	305	Forms of Articulation :	
Synovial Membrane . . . . .	305	Synarthrosis . . . . .	306

	PAGE
Amphiarthrosis . . . . .	307
Diarthrosis . . . . .	307
Movements of Joints . . . . .	308
<i>Articulations of the Trunk</i>	
Articulations of the Vertebral Column	311
Atlas with the Axis	315
Spine with the Cranium . . . . .	317
Atlas with the Occipital Bone . . . . .	317
Articulations of the Axis with the Occipital Bone . . . . .	318
Surgical Anatomy of Articulations of Spine . . . . .	319
Temporo-maxillary Articulation . . . . .	320
Surface form . . . . .	322
Surgical Anatomy . . . . .	322
Articulations of the Ribs with the Vertebrae:	
Costo-central . . . . .	323
Costo-transverse . . . . .	324
Articulations of the Cartilages of the Ribs with the Sternum and Ensiform Cartilage . . . . .	326
Interchondral Articulations . . . . .	328
Ligaments of the Sternum . . . . .	328
Articulation of the Pelvis with the Spine . . . . .	329
Articulations of the Pelvis:	
Articulation of the Sacrum and Ilium . . . . .	330
Ligament between the Sacrum and Ischium . . . . .	331
Articulation of the Sacrum and Coecyx . . . . .	332
Articulation of the Ossa Pubis . . . . .	333
<i>Articulations of the Upper Extremity</i>	
Sterno-clavicular . . . . .	334
Surface form . . . . .	336
Surgical Anatomy . . . . .	336
Acromio-clavicular . . . . .	336
Surface form . . . . .	338
Surgical Anatomy . . . . .	338
Proper Ligaments of the Scapula . . . . .	338
Shoulder-joint . . . . .	339
Surface form . . . . .	342
Surgical Anatomy . . . . .	342
Elbow-joint . . . . .	343
Surface form . . . . .	346
Surgical Anatomy . . . . .	346
Superior Radio-ulnar Articulation . . . . .	347
Surface form . . . . .	348

	PAGE
Middle Radio-ulnar Articulation . . . . .	348
Inferior Radio-ulnar Articulation . . . . .	349
Surface form . . . . .	350
Wrist-joint . . . . .	350
Surface form . . . . .	352
Surgical Anatomy . . . . .	352
Articulations of the Carpus . . . . .	352
of the first row of Carpal Bones	352
of the second row of Carpal Bones . . . . .	353
of the two rows of Carpal Bones	353
Carpometacarpal Articulations . . . . .	354
of the Metacarpal Bone of Thumb and Trapezium . . . . .	354
of the four inner Metacarpal Bones and Carpus . . . . .	355
Articulations of the Metacarpal Bones	356
Metacarpophalangeal Articulations . . . . .	356
Surface form . . . . .	357
Articulations of the Phalanges . . . . .	357

*Articulations of the Lower Extremity*

Hip-joint . . . . .	357
Surface form . . . . .	361
Surgical Anatomy . . . . .	361
Knee-joint . . . . .	363
Surface form . . . . .	370
Surgical Anatomy . . . . .	370
Articulations between the Tibia and Fibula . . . . .	371
Superior Tibio-fibular Articulation	371
Middle Tibio-fibular Articulation . . . . .	372
Inferior Tibio-fibular Articulation	372
Ankle-joint . . . . .	373
Surface form . . . . .	376
Surgical Anatomy . . . . .	376
Articulations of the Tarsus . . . . .	376
of the Os Calcis and Astragalus	376
of the Os Calcis and Cuboid . . . . .	377
of the Os Calcis and Navicular . . . . .	378
Surgical Anatomy . . . . .	378
of the Astragalus and Navicular	378
of the Navicular and Cuneiform	379
of the Navicular and Cuboid . . . . .	379
of the Cuneiform with each other	379
of the External Cuneiform and Cuboid . . . . .	380
Tarso-metatarsal Articulations . . . . .	380
Articulations of the Metatarsal Bones . . . . .	381
Synovial Membranes in Tarsal and Metatarsal Joints . . . . .	381
Metatarso-phalangeal Articulations . . . . .	382
Articulations of the Phalanges . . . . .	383
Surface form . . . . .	383

MUSCLES AND FASCLE

General Description of Muscle . . . . .	384
Tendons . . . . .	385
Aponeuroses . . . . .	385
Fascia . . . . .	385

MUSCLES AND FASCLE OF THE CRANIUM AND FACE

Subdivision into Groups . . . . .	386
<i>Cranial Region</i>	
Dissection . . . . .	387
Occipito-frontalis . . . . .	388

*Auricular Region*

Dissection . . . . .	389
Attrahens Aurem . . . . .	390
Attollens Aurem . . . . .	390
Retrahens Aurem . . . . .	390
Actions . . . . .	390

*Palpebral Region*

Dissection . . . . .	390
Orbicularis Palpebrarum . . . . .	390
Corrugator Supercilii . . . . .	391
Tensor Tarsi . . . . .	392
Actions . . . . .	392

	PAGE		PAGE
<i>Orbital Region</i>		<i>Infra-hyoid Region</i>	
Dissection . . . . .	392	Dissection . . . . .	409
Levator Palpebræ . . . . .	392	Sterno-hyoid . . . . .	409
Rectus Superior, Inferior, Internal, and		Sterno-thyroid . . . . .	409
External Recti . . . . .	393	Thyro-hyoid . . . . .	410
Superior Oblique . . . . .	393	Omo-hyoid . . . . .	410
Inferior Oblique . . . . .	394	Actions . . . . .	411
Actions . . . . .	394		
Surgical Anatomy . . . . .	395	<i>Supra-hyoid Region</i>	
<i>Nasal Region</i>		Dissection . . . . .	411
Pyramidalis Nasi . . . . .	395	Digastric . . . . .	411
Levator Labii Superioris Alæque Nasi	396	Stylo-hyoid . . . . .	412
Dilatator Naris, Anterior and Posterior	396	Stylo-hyoid Ligament . . . . .	412
Compressor Nasi . . . . .	396	Mylo-hyoid . . . . .	412
Compressor Narium Minor . . . . .	396	Genio-hyoid . . . . .	412
Depressor Alæ Nasi . . . . .	396	Actions . . . . .	413
Actions . . . . .	396		
<i>Superior Maxillary Region</i>		<i>Lingual Region</i>	
Levator Labii Superioris Proprius . . . . .	396	Dissection . . . . .	413
Levator Anguli Oris . . . . .	397	Genio-hyo-glossus . . . . .	413
Zygomatici . . . . .	397	Hyo-glossus . . . . .	413
Actions . . . . .	397	Chondro-glossus . . . . .	414
		Stylo-glossus . . . . .	414
<i>Inferior Maxillary Region</i>		Palato-glossus . . . . .	415
Dissection . . . . .	397	Muscular Substance of Tongue . . . . .	415
Levator Labii Inferioris . . . . .	397	Superior Lingualis . . . . .	416
Depressor Labii Inferioris . . . . .	397	Transverse Lingualis . . . . .	416
Depressor Anguli Oris . . . . .	398	Vertical Lingualis . . . . .	416
		Inferior Lingualis . . . . .	417
		Surgical Anatomy . . . . .	417
		Actions . . . . .	417
<i>Intermaxillary Region</i>		<i>Pharyngeal Region</i>	
Dissection . . . . .	398	Dissection . . . . .	418
Orbicularis Oris . . . . .	398	Inferior Constrictor . . . . .	418
Buccinator . . . . .	399	Middle Constrictor . . . . .	418
Risorius . . . . .	399	Superior Constrictor . . . . .	419
Actions . . . . .	399	Stylo-pharyngeus . . . . .	419
		Actions . . . . .	419
<i>Temporo-Maxillary Region</i>		<i>Palatal Region</i>	
Maseteric Fascia . . . . .	400	Dissection . . . . .	420
Maseter . . . . .	400	Levator Palati . . . . .	420
Temporal Fascia . . . . .	400	Tensor Palati . . . . .	421
Dissection . . . . .	400	Azygos Uvulæ . . . . .	421
Temporal . . . . .	400	Palato-glossus . . . . .	421
		Palato-pharyngeus . . . . .	421
<i>Pterygo-Maxillary Region</i>		Salpingo-pharyngeus . . . . .	421
Dissection . . . . .	401	Actions . . . . .	422
External Pterygoid . . . . .	401	Surgical Anatomy . . . . .	422
Internal Pterygoid . . . . .	402		
Actions . . . . .	402	<i>Vertebral Region (Anterior)</i>	
Surface form of Muscles of Head and		Rectus Capitis Anticus Major . . . . .	423
Face . . . . .	403	Rectus Capitis Anticus Minor . . . . .	423
		Rectus Lateralis . . . . .	424
		Longus Colli . . . . .	424
MUSCLES AND FASCLE OF THE NECK		<i>Vertebral Region (Lateral)</i>	
Subdivision into Groups . . . . .	403	Scalenus Anticus . . . . .	424
		Scalenus Medius . . . . .	424
<i>Superficial Region</i>		Scalenus Posticus . . . . .	425
Dissection . . . . .	404	Actions . . . . .	425
Superficial Cervical Fascia . . . . .	404	Surface form of Muscles of Neck . . . . .	426
Platysma Myoides . . . . .	404		
Deep Cervical Fascia . . . . .	405	MUSCLES AND FASCLE OF THE TRUNK	
Surgical Anatomy . . . . .	406	Subdivision into Groups . . . . .	426
Sterno-mastoid . . . . .	407		
Boundaries of the Triangles of the		<i>Muscles of the Back</i>	
Neck . . . . .	407	Subdivision into Layers . . . . .	426
Actions . . . . .	408		
Surface form . . . . .	409		
Surgical Anatomy . . . . .	409		



	PAGE
<i>First Layer</i>	
Dissection . . . . .	427
Superficial and Deep Fasciæ . . . . .	427
Trapezius . . . . .	427
Ligamentum Nuchæ . . . . .	429
Latissimus Dorsi . . . . .	429
<i>Second Layer</i>	
Dissection . . . . .	430
Levator Anguli Scapulæ . . . . .	430
Rhomboideus Minor . . . . .	430
Rhomboideus Major . . . . .	431
Actions . . . . .	431
<i>Third Layer</i>	
Dissection . . . . .	431
Serratus Posticus Superior . . . . .	431
Serratus Posticus Inferior . . . . .	432
Vertebral Aponeurosis . . . . .	432
Lumbar Fascia . . . . .	432
Splenius . . . . .	432
Actions . . . . .	434
<i>Fourth Layer</i>	
Dissection . . . . .	434
Erector Spinæ . . . . .	434
Ilio-costalis . . . . .	435
Musculus Accessorius ad Ilio-costalem . . . . .	435
Cervicalis Ascendens . . . . .	435
Longissimus Dorsi . . . . .	435
Transversalis Colli . . . . .	435
Trachelo-mastoid . . . . .	435
Spinalis Dorsi . . . . .	436
Spinalis Colli . . . . .	436
Complexus . . . . .	436
Biventer Cervicis . . . . .	436
<i>Fifth Layer</i>	
Dissection . . . . .	437
Semispinalis Dorsi et Colli . . . . .	437
Multifidus Spinæ . . . . .	437
Rotatores Spinæ . . . . .	437
Supraspinales . . . . .	438
Interspinales . . . . .	438
Extensor Coccygis . . . . .	438
Intertransversales . . . . .	438
Rectus Capitis Posticus Major . . . . .	438
Rectus Capitis Posticus Minor . . . . .	438
Obliquus Capitis Inferior . . . . .	439
Obliquus Capitis Superior . . . . .	439
Suboccipital triangle . . . . .	439
Actions . . . . .	439
Surface form of Muscles of Back . . . . .	440
MUSCLES AND FASCIAE OF THE THORAX	
Intercostal Fasciæ . . . . .	441
External and Internal Intercostals . . . . .	441
Infracostales (subcostales) . . . . .	442
Triangularis Sterni . . . . .	442
Levatores Costarum . . . . .	443
Diaphragm . . . . .	443
Actions . . . . .	445
Muscles of Inspiration and Expiration . . . . .	446
<i>Superficial Muscles of the Abdomen</i>	
Dissection . . . . .	447
Obliquus Externus . . . . .	448
External Abdominal Ring . . . . .	449
The Intercolumnar Fibres . . . . .	450

	PAGE
The Intercolumnar Fascia . . . . .	450
Poupart's Ligament . . . . .	450
Gimbernat's Ligament . . . . .	450
Triangular Fascia . . . . .	451
Obliquus Internus . . . . .	451
Cremaster . . . . .	452
Transversalis . . . . .	453
Rectus . . . . .	453
Pyramidalis . . . . .	455
Linea Alba . . . . .	456
Lineæ Semilunares, Lineæ Transversæ . . . . .	456
Actions . . . . .	456
Fascia Transversalis . . . . .	456
Internal Abdominal Ring . . . . .	457
Inguinal Canal . . . . .	457
Surface form of Muscles of Abdomen . . . . .	457
<i>Deep Muscles of the Abdomen</i>	
Quadratus Lumborum . . . . .	458
<i>Muscles of the Pelvic Outlet</i>	
Corrugator Cutis Ani . . . . .	459
External Sphincter Ani . . . . .	459
Internal Sphincter Ani . . . . .	459
Levator Ani . . . . .	459
Coccygeus . . . . .	460
<i>Muscles of the Perinæum in the Male</i>	
Superficial Perineal Fascia . . . . .	461
Transversus Perinæi . . . . .	462
Accelerator Urinæ . . . . .	463
Erector Penis . . . . .	464
Triangular Ligament . . . . .	464
Compressor Urethræ . . . . .	465
<i>Muscles of the Perinæum in the Female</i>	
Transversus Perinæi . . . . .	465
Sphincter Vaginæ . . . . .	465
Erector Clitoridis . . . . .	466
Triangular Ligament . . . . .	466
Compressor Urethræ . . . . .	467
MUSCLES AND FASCIAE OF THE UPPER EXTREMITY	
Subdivision into Groups . . . . .	467
Dissection of Pectoral Region and Axilla . . . . .	467
Fasciæ of the Thorax . . . . .	468
<i>Anterior Thoracic Region</i>	
Pectoralis Major . . . . .	468
Costo-coracoid Membrane . . . . .	470
Pectoralis Minor . . . . .	470
Subclavius . . . . .	471
Actions . . . . .	471
<i>Lateral Thoracic Region</i>	
Serratus Magnus . . . . .	472
Actions . . . . .	473
<i>Acromial Region</i>	
Deltoid . . . . .	473
Actions . . . . .	474
<i>Anterior Scapular Region</i>	
Subscapular Fascia . . . . .	474
Subscapularis . . . . .	474
Actions . . . . .	475

	PAGE		PAGE
<i>Posterior Scapular Region</i>		<i>Muscles of the Hand</i>	
Dissection . . . . .	475	Radial Group . . . . .	495
Supraspinous Fascia . . . . .	475	Abductor Pollicis . . . . .	495
Supraspinatus . . . . .	475	Opponens Pollicis . . . . .	495
Infraspinous Fascia . . . . .	475	Flexor Brevis Pollicis . . . . .	496
Infraspinatus . . . . .	476	Adductor Obliquus Pollicis . . . . .	496
Teres Minor . . . . .	476	Adductor Transversus Pollicis . . . . .	497
Teres Major . . . . .	477	Actions . . . . .	497
Actions . . . . .	477	Ulnar Group . . . . .	497
<i>Anterior Humeral Region</i>		Palmaris Brevis . . . . .	497
Deep Fascia of Arm . . . . .	477	Abductor Minimi Digiti . . . . .	498
Coraco-brachialis . . . . .	478	Flexor Brevis Minimi Digiti . . . . .	499
Biceps . . . . .	478	Opponens Minimi Digiti . . . . .	499
Brachialis Anticus . . . . .	479	Actions . . . . .	499
Actions . . . . .	479	Middle Palmar Group . . . . .	499
<i>Posterior Humeral Region</i>		Lumbricales . . . . .	499
Triceps . . . . .	480	Interossei Dorsales . . . . .	499
Subanconeus . . . . .	480	Interossei Palmares . . . . .	500
Actions . . . . .	481	Actions . . . . .	500
<i>Muscles of Forearm</i>		Surface form of Muscles of Upper Ex- tremity . . . . .	501
Deep Fascia of Forearm . . . . .	481	<i>Surgical Anatomy of the Muscles of the Upper Extremity</i>	
<i>Anterior Radio-Ulnar Region, Superficial Layer</i>		Fractures of the Clavicle . . . . .	503
Pronator Radii Teres . . . . .	482	Acromion Process . . . . .	503
Flexor Carpi Radialis . . . . .	482	Coracoid Process . . . . .	503
Palmaris Longus . . . . .	482	Humerus . . . . .	504
Flexor Carpi Ulnaris . . . . .	482	Olecranon . . . . .	505
Flexor Digitorum Sublimis . . . . .	483	Radius . . . . .	505
<i>Anterior Brachial Region, Deep Layer</i>		Ulna . . . . .	505
Flexor Profundus Digitorum . . . . .	484	Radius and Ulna . . . . .	506
Flexor Longus Pollicis . . . . .	485	Lower end of Radius . . . . .	506
Pronator Quadratus . . . . .	485	MUSCLES AND FASCLE OF THE LOWER EXTREMITY	
Actions . . . . .	486	Subdivision into Groups . . . . .	506
<i>Radial Region</i>		<i>Iliac Region</i>	
Dissection . . . . .	486	Dissection . . . . .	507
Supinator Longus . . . . .	486	Iliac Fascia . . . . .	507
Extensor Carpi Radialis Longior . . . . .	487	Psoas Magnus . . . . .	508
Extensor Carpi Radialis Brevior . . . . .	487	Psoas Parvus . . . . .	508
<i>Posterior Radio-Ulnar Region, Superficial Layer</i>		Iliacus . . . . .	508
Extensor Communis Digitorum . . . . .	488	Actions . . . . .	509
Extensor Minimi Digiti . . . . .	488	Surgical Anatomy . . . . .	509
Extensor Carpi Ulnaris . . . . .	489	<i>Anterior Femoral Region</i>	
Anconeus . . . . .	489	Dissection . . . . .	509
<i>Posterior Brachial Region, Deep Layer</i>		Fasciæ of the Thigh: Superficial Fascia . . . . .	510
Supinator Brevis . . . . .	489	Deep Fascia (Fas- cia Lata) . . . . .	510
Extensor Ossis Metacarpi Pollicis . . . . .	489	Saphenous Open- ing . . . . .	512
Extensor Brevis Pollicis . . . . .	491	Iliac and Pubic portions of Fas- cia Lata . . . . .	512
Extensor Longus Pollicis . . . . .	491	Tensor Vaginæ Femoris . . . . .	512
Extensor Indicis . . . . .	491	Sartorius . . . . .	512
Actions . . . . .	491	Quadriceps Extensor . . . . .	513
<i>Muscles and Fasciæ of the Hand</i>		Rectus Femoris . . . . .	513
Dissection . . . . .	492	Vastus Externus . . . . .	514
Anterior Annular Ligament . . . . .	492	Vastus Internus and Crureus . . . . .	514
Synovial Membranes of the Flexor Tendons at the Wrist . . . . .	493	Subcrureus . . . . .	515
Posterior Annular Ligament . . . . .	493	Actions . . . . .	515
Deep Palmar Fascia . . . . .	494	Surgical Anatomy . . . . .	515
Superficial Transverse Ligament of the Fingers . . . . .	495	<i>Internal Femoral Region</i>	
		Dissection . . . . .	515
		Gracilis . . . . .	515

	PAGE
Pectineus . . . . .	516
Adductor Longus . . . . .	516
Adductor Brevis . . . . .	517
Adductor Magnus . . . . .	517
Actions . . . . .	518
Surgical Anatomy . . . . .	518

*Gluteal Region*

Dissection . . . . .	518
Gluteus Maximus . . . . .	518
Gluteus Medius . . . . .	519
Gluteus Minimus . . . . .	520
Pyriformis . . . . .	520
Obturator Membrane . . . . .	521
Obturator Internus . . . . .	521
Gemelli . . . . .	522
Quadratus Femoris . . . . .	522
Obturator Externus . . . . .	522
Actions . . . . .	523

*Posterior Femoral Region*

Dissection . . . . .	524
Biceps . . . . .	524
Semitendinosus . . . . .	524
Semimembranosus . . . . .	525
Actions . . . . .	525
Surgical Anatomy of Hamstring Tendons . . . . .	525

*Muscles and Fasciæ of the Leg*

Dissection of Front of Leg . . . . .	526
Deep Fascia of the Leg . . . . .	526

*Anterior Tibio-fibular Region*

Tibialis Anticus . . . . .	527
Extensor Proprius Hallucis . . . . .	527
Extensor Longus Digitorum . . . . .	527
Peroneus Tertius . . . . .	528
Actions . . . . .	528

*Posterior Tibio-fibular Region, Superficial Layer*

Dissection . . . . .	528
Gastrocnemius . . . . .	528
Soleus . . . . .	529
Tendo Achillis . . . . .	529
Plantaris . . . . .	530
Actions . . . . .	530

*Posterior Tibio-fibular Region, Deep Layer*

Deep Transverse Fascia of Leg . . . . .	530
Popliteus . . . . .	531

	PAGE
Flexor Longus Hallucis . . . . .	531
Flexor Longus Digitorum . . . . .	532
Tibialis Posticus . . . . .	532
Actions . . . . .	532

*Fibular Region*

Peroneus Longus . . . . .	533
Peroneus Brevis . . . . .	533
Actions . . . . .	534
Surgical Anatomy of Tendons around Ankle . . . . .	534

*Muscles and Fasciæ of the Foot*

Anterior Annular Ligament . . . . .	534
Internal Annular Ligament . . . . .	535
External Annular Ligament . . . . .	535
Plantar Fascia . . . . .	535

*Muscles of the Foot, Dorsal Region*

Extensor Brevis Digitorum . . . . .	536
-------------------------------------	-----

*Plantar Region*

Subdivision into Groups . . . . .	536
Subdivision into Layers . . . . .	536

First Layer—

Abductor Hallucis . . . . .	537
Flexor Brevis Digitorum . . . . .	537
Fibrous Sheaths of Flexor Tendons . . . . .	538
Abductor Minimi Digiti . . . . .	538

Second Layer—

Flexor Accessorius . . . . .	538
Lumbricales . . . . .	539

Third Layer—

Flexor Brevis Hallucis . . . . .	539
Adductor Obliquus Hallucis . . . . .	539
Flexor Brevis Minimi Digiti . . . . .	540
Adductor Transversus Hallucis . . . . .	540

Fourth Layer—

Interossei . . . . .	541
Surface form of Muscles of Lower Extremity . . . . .	542

*Surgical Anatomy of the Muscles of the Lower Extremity*

Fracture of the Neck of the Femur . . . . .	543
the Femur below Trochanter Minor . . . . .	544
the Femur above the Condyles . . . . .	544
the Patella . . . . .	545
the Tibia . . . . .	545
the Fibula, with Dislocation of the Foot outwards . . . . .	545

THE ARTERIES

*General Anatomy*

Subdivision into Pulmonary and Systemic . . . . .	546
Distribution of—Where found . . . . .	546
Mode of Division—Anastomoses . . . . .	546

PULMONARY ARTERY . . . . .	547
----------------------------	-----

THE AORTA

Divisions . . . . .	548
Ascending Aorta . . . . .	549
Coronary Arteries . . . . .	549
Arch of Aorta . . . . .	550

Peculiarities . . . . .	551
Surgical Anatomy . . . . .	551
Branches . . . . .	552
Peculiarities of Branches . . . . .	552

*Arteria Innominata*

Relations . . . . .	553
Peculiarities . . . . .	553
Surgical Anatomy . . . . .	554

*Common Carotid Arteries*

Course and Relations . . . . .	554
Peculiarities . . . . .	557



	PAGE		PAGE
Surface Marking . . . . .	557	<i>Cerebral Branches of Internal</i>	
Surgical Anatomy . . . . .	557	<i>Carotid</i> . . . . .	581
		The Blood-vessels of the Brain . . . . .	583
<i>External Carotid Artery</i>			
Course and Relations . . . . .	559		
Surface Marking . . . . .	559	ARTERIES OF UPPER EXTREMITY	
Surgical Anatomy . . . . .	559	<i>Subclavian Arteries</i>	
Branches . . . . .	560	First Part of Right Subclavian Artery . . . . .	585
<i>Superior Thyroid Artery</i>		First Part of Left Subclavian Artery . . . . .	586
Course and Relations . . . . .	560	Second Part of Subclavian Artery . . . . .	587
Branches . . . . .	560	Third Part of Subclavian Artery . . . . .	587
Surgical Anatomy . . . . .	561	Peculiarities . . . . .	588
<i>Lingual Artery</i>		Surface Marking . . . . .	589
Course and Relations . . . . .	561	Surgical Anatomy . . . . .	589
Branches . . . . .	561	Branches . . . . .	591
Surgical Anatomy . . . . .	562	<i>Vertebral Artery</i> . . . . .	591
<i>Facial Artery</i>		<i>Basilar Artery</i> . . . . .	593
Course and Relations . . . . .	562	<i>Circle of Willis</i> . . . . .	594
Branches . . . . .	563	<i>Thyroid Axis</i> . . . . .	594
Peculiarities . . . . .	564	<i>Inferior Thyroid</i>	594
Surgical Anatomy . . . . .	565	<i>Suprascapular Artery</i>	595
<i>Occipital Artery</i>		<i>Transversalis Colli</i> . . . . .	595
Course and Relations . . . . .	565	<i>Internal Mammary</i> . . . . .	596
Branches . . . . .	565	<i>Superior Intercostal</i> . . . . .	598
<i>Posterior Auricular Artery</i>		THE AXILLA . . . . .	598
Course and Relations . . . . .	566	Surgical Anatomy of the Axilla . . . . .	600
Branches . . . . .	566		
<i>Ascending Pharyngeal Artery</i>		<i>Axillary Artery</i>	
Course and Relations . . . . .	566	First Portion . . . . .	601
Branches . . . . .	566	Second Portion . . . . .	601
Surgical Anatomy . . . . .	567	Third Portion . . . . .	601
<i>Superficial Temporal Artery</i>		Peculiarities . . . . .	602
Course and Relations . . . . .	567	Surface Marking . . . . .	602
Branches . . . . .	567	Surgical Anatomy . . . . .	602
Surgical Anatomy . . . . .	567	Branches . . . . .	603
<i>Internal Maxillary Artery</i>		<i>Brachial Artery</i>	
Course and Relations . . . . .	568	Relations . . . . .	605
Branches from First Portion . . . . .	569	Bend of the Elbow . . . . .	605
Second Portion . . . . .	570	Peculiarities of Brachial Artery . . . . .	605
Third Portion . . . . .	570	Surface Form . . . . .	607
		Surgical Anatomy . . . . .	607
		Branches . . . . .	608
		<i>Radial Artery</i>	
		Relations . . . . .	610
		Deep Palmar Arch . . . . .	610
		Peculiarities . . . . .	610
		Surface Marking . . . . .	611
		Surgical Anatomy . . . . .	611
		Branches . . . . .	611
		<i>Ulnar Artery</i>	
		Relations . . . . .	613
		Peculiarities of Ulnar Artery . . . . .	613
		Surface Marking . . . . .	614
		Surgical Anatomy . . . . .	614
		Branches . . . . .	614
		Superficial Palmar Arch . . . . .	616
		ARTERIES OF THE TRUNK	
		DESCENDING AORTA . . . . .	617
		THORACIC AORTA	
		Course and Relations . . . . .	617
		Surgical Anatomy . . . . .	618
		Branches . . . . .	618

SURGICAL ANATOMY OF THE TRIANGLES  
OF THE NECK

*Anterior Triangular Space*

Inferior Carotid Triangle . . . . .	572
Superior Carotid Triangle . . . . .	572
Submaxillary Triangle . . . . .	573

*Posterior Triangular Space*

Occipital Triangle . . . . .	574
Subclavian Triangle . . . . .	574

*Internal Carotid Artery*

Cervical Portion . . . . .	575
Petrous Portion . . . . .	575
Cavernous Portion . . . . .	575
Cerebral Portion . . . . .	576
Peculiarities . . . . .	576
Surgical Anatomy . . . . .	577
Branches . . . . .	577
<i>Ophthalmic Artery</i> . . . . .	577

	PAGE
<b>ABDOMINAL AORTA</b>	
Course and Relations . . . . .	620
Surface Marking . . . . .	621
Surgical Anatomy . . . . .	621
Branches . . . . .	622
<i>Cœliac Axis, Gastric Artery</i> . . . . .	622
<i>Hepatic Artery</i> . . . . .	623
<i>Splenic Artery</i> . . . . .	625
<i>Superior Mesenteric Artery</i> . . . . .	625
<i>Inferior Mesenteric Artery</i> . . . . .	627
<i>Suprarenal Arteries</i> . . . . .	628
<i>Renal Arteries</i> . . . . .	628
<i>Spermatic Arteries</i> . . . . .	629
<i>Phrenic Arteries</i> . . . . .	629
<i>Lumbar Arteries</i> . . . . .	629
<i>Middle Sacral Artery</i> . . . . .	630
<i>Luschka's Gland</i> . . . . .	630

<b>COMMON ILIAC ARTERIES</b>	
Course and Relations . . . . .	631
Branches . . . . .	631
Peculiarities . . . . .	631
Surface Marking . . . . .	632
Surgical Anatomy . . . . .	632

<i>Internal Iliac Artery</i>	
Course and Relations . . . . .	633
Peculiarities . . . . .	634
Surgical Anatomy . . . . .	634
Branches . . . . .	635
<i>Vesical Arteries</i> . . . . .	635
<i>Hæmorrhoidal Arteries</i> . . . . .	636
<i>Uterine Arteries</i> . . . . .	636
<i>Vaginal Arteries</i> . . . . .	636
<i>Obturator Artery</i> . . . . .	636
Peculiarities . . . . .	637
<i>Internal Pudic Artery</i> . . . . .	637
In the Male . . . . .	637
Peculiarities . . . . .	638
Surgical Anatomy . . . . .	638
Branches . . . . .	638
In the Female . . . . .	639
<i>Sciatic Artery</i> . . . . .	639
<i>Ilio-lumbar Artery</i> . . . . .	640
<i>Lateral Sacral Artery</i> . . . . .	641
<i>Gluteal Artery</i> . . . . .	641
Surface Marking of Branches of Internal Iliac . . . . .	641
Surgical Anatomy of Branches of Internal Iliac . . . . .	641

<i>External Iliac Artery</i>	
Course and Relations . . . . .	642
Surgical Anatomy . . . . .	642

<i>Deep Epigastric Artery</i> . . . . .	643
<i>Deep Circumflex Iliac Artery</i> . . . . .	644

<b>ARTERIES OF THE LOWER EXTREMITY</b>	
<i>Femoral Artery</i>	
Course and Relations . . . . .	644
Scarpa's Triangle . . . . .	644
Hunter's Canal . . . . .	645
Common Femoral . . . . .	646
Superficial Femoral . . . . .	646
Peculiarities . . . . .	647
Surface Marking . . . . .	647
Surgical Anatomy . . . . .	647
Branches . . . . .	649
Deep Femoral . . . . .	650
Branches . . . . .	651

<i>Popliteal Artery</i>	
POPLITEAL SPACE . . . . .	652
Course and Relations . . . . .	654
Peculiarities . . . . .	654
Surface Marking . . . . .	655
Surgical Anatomy . . . . .	655
Branches . . . . .	655

<i>Anterior Tibial Artery</i>	
Course and Relations . . . . .	657
Peculiarities . . . . .	658
Surface Marking . . . . .	658
Surgical Anatomy . . . . .	658
Branches . . . . .	658

<i>Dorsalis Pedis Artery</i>	
Course and Relations . . . . .	659
Peculiarities . . . . .	660
Surface Marking . . . . .	660
Surgical Anatomy . . . . .	660
Branches . . . . .	660

<i>Posterior Tibial Artery</i>	
Course and Relations . . . . .	660
Peculiarities . . . . .	661
Surface Marking . . . . .	661
Surgical Anatomy . . . . .	661
Branches . . . . .	662

<i>Peroneal Artery</i>	
Course and Relations . . . . .	662
Peculiarities . . . . .	662
<i>Plantar Arteries</i> . . . . .	663
Surface Marking . . . . .	664
Surgical Anatomy . . . . .	664

THE VEINS

<i>General Anatomy</i>	
Subdivision into Pulmonary, Systemic, and Portal . . . . .	666
Anastomoses of Veins . . . . .	666
Superficial Veins . . . . .	666
Deep Veins, Venæ Comites . . . . .	667
Sinuses . . . . .	667
PULMONARY VEINS . . . . .	667
SYSTEMIC VEINS . . . . .	667

<b>VEINS OF THE HEAD AND NECK</b>	
Frontal Vein . . . . .	668
Facial Vein . . . . .	669

Surgical Anatomy . . . . .	669
Temporal Vein . . . . .	669
Internal Maxillary Vein . . . . .	670
Temporo-Maxillary Vein . . . . .	670
Posterior Auricular Vein . . . . .	670
Occipital Vein . . . . .	670

<i>Veins of the Neck</i>	
External Jugular Vein . . . . .	670
Surgical Anatomy . . . . .	671
Posterior External Jugular Vein . . . . .	671
Anterior Jugular Vein . . . . .	671
Internal Jugular Vein . . . . .	671

	PAGE		PAGE
Surgical Anatomy . . . . .	672	Inferior Thyroid Veins . . . . .	684
Lingual Vein . . . . .	672	Superior Intercostal Veins . . . . .	684
Pharyngeal Vein . . . . .	672	Superior Vena Cava . . . . .	684
Thyroid Veins . . . . .	672	Azygos Veins . . . . .	685
Vertebral Veins . . . . .	672	Bronchial Veins . . . . .	686
<i>Veins of the Diploë</i> . . . . .	673	<i>Spinal Veins</i> . . . . .	686
<i>Cerebral Veins</i>			
Superficial Cerebral Veins . . . . .	674	VEINS OF THE LOWER EXTREMITY— ABDOMEN AND PELVIS	
Deep Cerebral Veins . . . . .	674	Internal Saphenous Vein . . . . .	688
Cerebellar Veins . . . . .	674	External Saphenous Vein . . . . .	689
<i>Sinuses of the Dura Mater</i>			
Superior Longitudinal Sinus . . . . .	675	Popliteal Vein . . . . .	689
Inferior Longitudinal, Straight Sinuses . . . . .	676	Femoral Vein . . . . .	689
Lateral Sinus . . . . .	676	External Iliac Vein . . . . .	690
Occipital Sinuses . . . . .	676	Internal Iliac Vein . . . . .	690
Cavernous Sinuses . . . . .	676	Common Iliac Veins . . . . .	691
Surgical Anatomy . . . . .	677	Inferior Vena Cava . . . . .	691
Circular Sinus . . . . .	677	Peculiarities . . . . .	692
Superior Petrosal Sinus . . . . .	677	Lumbar Veins . . . . .	692
Inferior Petrosal Sinus . . . . .	677	Spermatic Veins . . . . .	692
Transverse Sinuses . . . . .	678	Surgical Anatomy . . . . .	692
Emissary Veins . . . . .	678	Ovarian Veins . . . . .	692
VEINS OF THE UPPER EXTREMITY AND THORAX			
Superficial Veins . . . . .	679	Renal and Suprarenal Veins . . . . .	693
Deep Veins . . . . .	680	Phrenic Veins . . . . .	693
Axillary Vein . . . . .	682	Hepatic Veins . . . . .	693
Surgical Anatomy . . . . .	682	PORTAL SYSTEM OF VEINS	
Subclavian Vein . . . . .	682	Superior Mesenteric Vein . . . . .	693
Innominate Veins . . . . .	683	Splenic Vein . . . . .	693
Peculiarities of . . . . .	684	Inferior Mesenteric Vein . . . . .	693
Internal Mammary Veins . . . . .	684	Gastric Veins . . . . .	694
		Portal Vein . . . . .	695
		CARDIAC VEINS . . . . . 695	
		Coronary Sinus . . . . .	695

## THE LYMPHATICS

<i>General Anatomy</i>		Deep Inguinal Glands . . . . .	704
Subdivision into Deep and Superficial . . . . .	697	Gluteal and Ischiatic Glands . . . . .	704
Lymphatic or Conglobate Glands . . . . .	697	Superficial Lymphatics of Lower Ex- tremity . . . . .	705
Thoracic Duct . . . . .	698	Internal Group . . . . .	705
Right Lymphatic Duct . . . . .	699	External Group . . . . .	705
<i>Lymphatics of Head, Face, and Neck</i>		Deep Lymphatics of Lower Extremity . . . . .	705
Lymphatic Glands of Head . . . . .	699	<i>Lymphatics of Pelvis and Abdomen</i>	
Lymphatics of the Head . . . . .	699	Deep Lymphatic Glands of Pelvis . . . . .	706
Superficial Lymphatics of the Face . . . . .	700	External Iliac Glands . . . . .	706
Deep Lymphatics of the Face . . . . .	700	Internal Iliac Glands . . . . .	707
Lymphatics of the Cranium . . . . .	701	Sacral Glands . . . . .	707
Superficial Cervical Glands . . . . .	701	Lumbar Glands . . . . .	707
Deep Cervical Glands . . . . .	702	Superficial Lymphatics of Wall of Abdomen . . . . .	707
Superficial and Deep Cervical Lym- phatics . . . . .	702	of Gluteal Region . . . . .	707
<i>Lymphatics of the Upper Extremity</i>		of Scrotum and Perinæum . . . . .	707
Superficial Lymphatic Glands . . . . .	702	of Penis . . . . .	707
Deep Lymphatic Glands . . . . .	702	of Labia, Nymphæ, and Clitoris . . . . .	707
Axillary Glands . . . . .	702	Deep Lymphatics of Pelvis and Abdo- men . . . . .	707
Superficial Lymphatics of Upper Ex- tremity . . . . .	703	Lymphatics of Bladder . . . . .	708
Deep Lymphatics of Upper Extremity . . . . .	704	of Rectum . . . . .	708
<i>Lymphatics of the Lower Extremity</i>		of Uterus . . . . .	708
Superficial Inguinal Glands . . . . .	704	of Testicle . . . . .	708
Deep Lymphatic Glands . . . . .	704	of Kidney . . . . .	708
Anterior Tibial Glands . . . . .	704	of Liver . . . . .	708
Deep Popliteal Glands . . . . .	704	Lymphatic Glands of Stomach . . . . .	709
		Lymphatics of Stomach . . . . .	709



	PAGE		PAGE
Lymphatic Glands of Spleen . . . . .	709	Internal Mammary Glands . . . . .	709
Lymphatics of Spleen . . . . .	709	Anterior Mediastinal Glands . . . . .	710
<i>Lymphatic System of the Intestines</i>			
Lymphatic Glands of Small Intestine (Mesenteric Glands) . . . . .	709	Posterior Mediastinal Glands . . . . .	710
Lymphatic Glands of Large Intes- tine . . . . .	709	Superficial Lymphatics on front of Thorax . . . . .	710
Lymphatics of Small Intestine (Lac- teals) . . . . .	709	Deep Lymphatics of Thorax . . . . .	710
of Large Intestine . . . . .	709	Intercostal Lymphatics . . . . .	710
<i>Lymphatics of Thorax</i>			
Deep Lymphatic Glands of Thorax . . . . .	709	Internal Mammary Lymphatics . . . . .	710
Intercostal Glands . . . . .	709	Lymphatics of Diaphragm . . . . .	710
		Bronchial Glands . . . . .	710
		Lymphatics of Lung . . . . .	710
		Cardiac Lymphatics . . . . .	710
		Thymic Lymphatics . . . . .	711
		Thyroid Lymphatics . . . . .	711
		Lymphatics of Œsophagus . . . . .	711

NERVOUS SYSTEM

*General Anatomy*

Subdivision into Cerebro-spinal Axis, Ganglia, and Nerves . . . . .	712
--	-----

*The Spinal Cord and its Membranes*

Dissection . . . . .	712
Membranes of the Cord . . . . .	712
Dura Mater . . . . .	712
Arachnoid . . . . .	713
Pia Mater . . . . .	713
Ligamentum Denticulatum . . . . .	714
Spinal Cord . . . . .	714
Fissures of Cord . . . . .	715
Columns of Cord . . . . .	716
Structure of the Cord . . . . .	716
Commissure of the Cord . . . . .	716
Minute Anatomy of the Cord . . . . .	718
Neuroglia . . . . .	718
White Substance . . . . .	718
Grey Substance . . . . .	720

*The Brain and its Membranes*

Membranes of the Brain . . . . .	723
----------------------------------	-----

*Dura Mater*

Structure . . . . .	723
Arteries, Veins, Nerves . . . . .	723
Processes of the Dura Mater . . . . .	724
Falx Cerebri . . . . .	724
Tentorium Cerebelli . . . . .	724
Falx Cerebelli . . . . .	724
Glandulæ Pacchioni . . . . .	724

*Arachnoid Membrane*

Subarachnoid Space . . . . .	725
Cerebro-spinal Fluid . . . . .	726
Pia Mater . . . . .	726

THE BRAIN

Subdivision into Cerebrum, Cerebellum, Pons Varolii, Medulla Oblongata . . . . .	726
Weight of Brain . . . . .	727

MEDULLA OBLONGATA

Pyramids . . . . .	728
Lateral Tract, and Olivary Body . . . . .	729
Funiculus of Rolando . . . . .	729
Funiculus Cuneatus . . . . .	729
Restiform Bodies . . . . .	729
Funiculus Gracilis . . . . .	730
Posterior Surface of Medulla Oblongata	730

Structure of Medulla Oblongata . . . . .	730
of Pyramid . . . . .	730
of Olivary Body . . . . .	731
of Lateral Tract . . . . .	731
of Funiculus of Rolando . . . . .	731
of Funiculus Cuneatus . . . . .	731
of Funiculus Gracilis . . . . .	731
of Restiform Body . . . . .	731
Arciform Fibres of Medulla . . . . .	732
Raphé . . . . .	732
Formatio Reticularis . . . . .	733
Grey Matter of Medulla . . . . .	733

PONS VAROLII

Structure . . . . .	734
Microscopic Anatomy of Pons . . . . .	734
Septum . . . . .	735

CEREBRUM

Upper Surface of Cerebrum . . . . .	736
Convolutions . . . . .	737
Structure of the Convolutions . . . . .	737
Lobes and Fissures of the Brain . . . . .	738
Fissure of Sylvius . . . . .	738
Fissure of Rolando . . . . .	738
Parieto-occipital Fissure . . . . .	738
Frontal Lobe . . . . .	738
Parietal Lobe . . . . .	739
Occipital Lobe . . . . .	741
Temporo-sphenoidal Lobe . . . . .	741
Central Lobe . . . . .	742
Calloso-marginal Fissure . . . . .	742
Parieto-occipital Fissure . . . . .	743
Calcarine Fissure . . . . .	743
Collateral Fissure . . . . .	743
Dentate Fissure . . . . .	744
Gyrus Fornicatus . . . . .	744
Marginal Convolution . . . . .	744
Quadrate Lobe . . . . .	744
Cuneate Lobe . . . . .	744
Uncinate Gyrus or Internal Occi- pito-temporal Convolution . . . . .	744
External Occipito-temporal Con- volution . . . . .	744

CEREBRAL LOCALISATION AND TOPO-  
GRAPHY

Base of the Brain . . . . .	747
General Arrangement of the Parts composing the Cerebrum . . . . .	750
Interior of the Cerebrum . . . . .	751
Corpus Callosum . . . . .	751
Lateral Ventricle . . . . .	752

	PAGE		PAGE
Corpus Striatum . . . . .	753	Abducens Nerve . . . . .	795
Tenia Semicircularis . . . . .	755	Relations of the Orbital Nerves . . . . .	795
Choroid Plexus . . . . .	755	in the Cavernous Sinus . . . . .	795
Corpus Fibriatum . . . . .	755	in the Sphenoidal Fissure . . . . .	796
Hippocampus Major . . . . .	756	in the Orbit . . . . .	796
Transverse Fissure . . . . .	756	Surgical Anatomy . . . . .	796
Septum Lucidum . . . . .	757	Facial Nerve . . . . .	796
Fifth Ventricle . . . . .	757	Branches of Facial Nerve . . . . .	798
Fornix . . . . .	757	Surgical Anatomy . . . . .	801
Velum Interpositum . . . . .	758	Auditory Nerve . . . . .	801
Thalamus Opticus . . . . .	759	Surgical Anatomy . . . . .	802
Third Ventricle . . . . .	759	Glosso-pharyngeal Nerve . . . . .	802
Commissure of Third Ven-		Pneumogastric (Vagus) Nerve . . . . .	803
tricles . . . . .	760	Surgical Anatomy . . . . .	808
Foramen of Monro . . . . .	761	Spinal Accessory Nerve . . . . .	809
Pineal Gland . . . . .	761	Surgical Anatomy . . . . .	809
Corpora Quadrigemina . . . . .	762	Hypoglossal Nerve . . . . .	809
Corpora Geniculata . . . . .	763	Surgical Anatomy . . . . .	812
Structure of Cerebrum . . . . .	763		
White Matter of the Cerebrum . . . . .	763	SPINAL NERVES	
Diverging Fibres . . . . .	763	Roots of the Spinal Nerves . . . . .	812
Commissural Fibres . . . . .	764	Origin of Anterior Roots . . . . .	812
Grey Matter of the Cortex . . . . .	765	of Posterior Roots . . . . .	812
Grey Matter of the Basal Ganglia . . . . .	767	Ganglia of the Spinal Nerves . . . . .	813
Central Grey Matter of the Cerebrum . . . . .	768	Posterior Divisions of the Spinal Nerves . . . . .	813
		Anterior Divisions of the Spinal Nerves . . . . .	813
CEREBELLUM		Points of emergence of Spinal Nerves . . . . .	813
Its Position, Size, Weight, &c. . . . .	768		
Lobes of the Cerebellum . . . . .	768	CERVICAL NERVES	
Cerebellum, Upper Surface . . . . .	769	Roots of the Cervical Nerves . . . . .	814
Under Surface . . . . .	770	Posterior Divisions of the Cervical	
Inferior Vermiform Process . . . . .	770	Nerves . . . . .	814
Internal Structure of the Cerebellum . . . . .	771	Anterior Divisions of the Cervical	
White Matter of Cerebellum . . . . .	771	Nerves . . . . .	816
Valve of Vieussens . . . . .	772		
Peduncles of Cerebellum . . . . .	772	CERVICAL PLEXUS	
Grey Matter of Cerebellum . . . . .	772	Superficial Branches of the Cervical	
Microscopical Appearance of Cortex . . . . .	772	Plexus . . . . .	818
Fourth Ventricle . . . . .	774	Deep Branches of the Cervical Plexus . . . . .	819
Lining Membrane . . . . .	776		
Choroid Plexus . . . . .	776	BRACHIAL PLEXUS	
		<i>Branches above the Clavicle</i>	
CRANIAL NERVES		Posterior Thoracic, Suprascapular . . . . .	821
Enumeration . . . . .	776	<i>Branches below the Clavicle</i>	
Olfactory Nerve . . . . .	777	Anterior Thoracic . . . . .	823
Surgical Anatomy . . . . .	778	Subscapular Nerves . . . . .	823
Optic Nerve . . . . .	778	Circumflex Nerve . . . . .	823
Tracts . . . . .	778	Musculo-cutaneous Nerve . . . . .	823
Commissure . . . . .	778	Internal Cutaneous Nerve . . . . .	826
Surgical Anatomy . . . . .	779	Lesser Internal Cutaneous Nerve . . . . .	826
Motor Oculi Nerve . . . . .	779	Median Nerve . . . . .	827
Surgical Anatomy . . . . .	781	Ulnar Nerve . . . . .	828
Pathetic Nerve . . . . .	781	Musculo-spiral Nerve . . . . .	830
Surgical Anatomy . . . . .	781	Radial Nerve . . . . .	830
Trifacial Nerve . . . . .	782	Posterior Interosseous Nerve . . . . .	831
Gasserian Ganglion . . . . .	782	Surgical Anatomy of Brachial Plexus . . . . .	831
Ophthalmic Nerve . . . . .	782		
Lachrymal, Frontal, and Nasal		DORSAL NERVES	
Branches . . . . .	783	Roots of the Dorsal Nerves . . . . .	832
Ophthalmic Ganglion . . . . .	784	Posterior Divisions of the Dorsal	
Superior Maxillary Nerve . . . . .	786	Nerves . . . . .	832
Spheno-palatine Ganglion . . . . .	788	Anterior Divisions of the Dorsal	
Inferior Maxillary Nerve . . . . .	790	Nerves . . . . .	834
Auriculo-temporal Branch . . . . .	791	First Dorsal Nerve . . . . .	834
Lingual Branch . . . . .	792	Upper Dorsal Nerves . . . . .	834
Inferior Dental Branch . . . . .	792	Lower Dorsal Nerves . . . . .	835
Otic Ganglion . . . . .	793	Last Dorsal Nerve . . . . .	835
Submaxillary Ganglion . . . . .	794		
Surgical Anatomy of Fifth Nerve . . . . .	794		

	PAGE
LUMBAR NERVES	
Root of Lumbar Nerves . . . . .	836
Posterior Divisions of Lumbar Nerves	836
Anterior Divisions of Lumbar Nerves .	837
LUMBAR PLEXUS	
Branches of Lumbar Plexus . . . . .	838
Ilio-hypogastric Nerve . . . . .	838
Ilio-inguinal Nerve . . . . .	839
Genito-crural Nerve . . . . .	839
External Cutaneous Nerve . . . . .	839
Obturator Nerve . . . . .	839
Accessory Obturator Nerve . . . . .	841
Anterior Crural Nerve . . . . .	841
Branches of Anterior Crural . . . . .	842
<i>Middle Cutaneous</i> . . . . .	842
<i>Internal Cutaneous</i> . . . . .	842
<i>Long Saphenous</i> . . . . .	842
<i>Muscular and Articular Branches</i>	843
SACRAL AND COCCYGEAL NERVES	
Roots of, Origin of . . . . .	843
Posterior Divisions of Sacral Nerves .	844
Coccygeal Nerve . . . . .	844
Anterior Divisions of Sacral Nerves .	844
SACRAL PLEXUS	
Superior Gluteal Nerve . . . . .	846
Inferior Gluteal Nerve . . . . .	847
Small Sciatic Nerve . . . . .	847
Pudic Nerve . . . . .	847
Great Sciatic Nerve . . . . .	849
Internal Popliteal Nerve . . . . .	849
External Saphenous Nerve . . . . .	850
Posterior Tibial Nerve . . . . .	850
Plantar Nerves . . . . .	850
External Popliteal or Peroneal Nerve .	851
Anterior Tibial Nerve . . . . .	852
Musculo-cutaneous Nerve . . . . .	852
Surgical Anatomy of Lumbar and Sacral	
Plexus . . . . .	852
SYMPATHETIC NERVE	
Subdivision of, into Parts . . . . .	854

	PAGE
Branches of the Ganglia, General De-	
scription of . . . . .	854
CERVICAL PORTION OF THE GANGLIATED	
CORD . . . . .	856
<i>Superior Cervical Ganglion</i> . . . . .	856
Carotid Plexus . . . . .	856
Cavernous Plexus . . . . .	858
<i>Middle Cervical Ganglion</i> . . . . .	859
<i>Inferior Cervical Ganglion</i> . . . . .	859
THORACIC PART OF THE GANGLIATED	
CORD . . . . .	860
Great Splanchnic Nerve . . . . .	860
Lesser Splanchnic Nerve . . . . .	860
Smallest Splanchnic Nerve . . . . .	860
LUMBAR PORTION OF THE GANGLIATED	
CORD . . . . .	860
PELVIC PORTION OF THE GANGLIATED	
CORD . . . . .	861
THE GREAT PLEXUSES OF THE SYMPATHETIC	
Cardiac Plexuses . . . . .	861
Great Cardiac Plexus . . . . .	861
Superficial Cardiac Plexus . . . . .	862
Coronary Plexuses . . . . .	862
Epigastric, or Solar Plexus . . . . .	862
Phrenic Plexus . . . . .	863
Suprarenal Plexus . . . . .	864
Renal Plexus . . . . .	864
Spermatic Plexus . . . . .	864
Cœliac Plexus . . . . .	864
Superior Mesenteric Plexus . . . . .	864
Aortic Plexus . . . . .	865
Inferior Mesenteric Plexus . . . . .	865
Hypogastric Plexus . . . . .	865
Pelvic Plexus . . . . .	865
Inferior Hæmorrhoidal Plexus . . . . .	865
Vesical Plexus . . . . .	865
Prostatic Plexus . . . . .	865
Vaginal Plexus . . . . .	865
Uterine Plexus . . . . .	866

ORGANS OF SENSE

TONGUE	
Structure of . . . . .	868
Papillæ of . . . . .	868
Glands of . . . . .	870
Fibrous Septum of . . . . .	871
Hyo-glossal Membrane . . . . .	871
Arteries and Nerves of . . . . .	872
Muscles of . . . . .	872
Nerves of . . . . .	872
Surgical Anatomy of . . . . .	872
NOSE	
Cartilages of . . . . .	874
Muscles of . . . . .	875
Skin . . . . .	875
Mucous Membrane . . . . .	875
Arteries, Veins, and Nerves . . . . .	875
<i>Nasal Fossæ</i>	
Mucous Membrane of . . . . .	875
Superior, Middle, and Inferior Meatuses	876

Arteries, Veins, and Nerves of Nasal	
Fossæ . . . . .	877
Surgical Anatomy of Nose and Nasal	
Fossæ . . . . .	878
EYE	
Situation, Form of . . . . .	879
Capsule of Tenon . . . . .	879
Tunics of, Sclerotic . . . . .	880
Cornea . . . . .	880
Choroid . . . . .	883
Ciliary Processes . . . . .	884
Iris . . . . .	885
Membrana Pupillaris . . . . .	887
Ciliary Muscle . . . . .	887
Retina . . . . .	887
Structure of Retina . . . . .	888
Structure of Retina at Yellow Spot . . . . .	891
Arteria Centralis Retinæ . . . . .	892



	PAGE		PAGE
<i>Humours of the Eye</i>		Arteries, Veins, and Nerves of the Pinna	903
Aqueous Humour . . . . .	892	Auditory Canal . . . . .	904
Anterior Chamber . . . . .	892	Surface Form . . . . .	905
Posterior Chamber . . . . .	892	<i>Middle Ear, or Tympanum</i>	
Vitreous Body . . . . .	892	Cavity of Tympanum . . . . .	905
Crystalline Lens and its Capsule . . . . .	893	Eustachian Tube . . . . .	908
Changes produced in the Lens by Age . . . . .	894	Membrana Tympani . . . . .	908
Suspensory Ligament of Lens . . . . .	894	Structure of . . . . .	908
Canal of Petit . . . . .	894	Ossicles of the Tympanum . . . . .	909
Vessels of the Globe of the Eye . . . . .	894	Ligaments of the Ossicula . . . . .	909
Nerves of Eyeball . . . . .	895	Muscles of the Tympanum . . . . .	910
Surgical Anatomy of Eye . . . . .	895	Mucous Membrane of Tympanum . . . . .	910
APPENDAGES OF THE EYE		Arteries of Tympanum . . . . .	910
Eyebrows . . . . .	896	Veins and Nerves of Tympanum . . . . .	910
Eyelids . . . . .	896	<i>Internal Ear, or Labyrinth</i>	
Eyelashes . . . . .	897	Osseous Labyrinth . . . . .	911
Structure of the Eyelids . . . . .	897	Vestibule . . . . .	911
Tarsal Plates . . . . .	897	Semicircular Canals—	
Meibomian Glands . . . . .	897	Superior Semicircular Canal . . . . .	912
Conjunctiva . . . . .	898	Posterior Semicircular Canal . . . . .	913
Carunculæ Lachrymales . . . . .	899	External Semicircular Canal . . . . .	913
LACHRYMAL APPARATUS		Cochlea—	
Lachrymal Gland . . . . .	899	Central Axis of, or Modiolus . . . . .	913
Canals . . . . .	899	Spiral Canal of . . . . .	913
Sac . . . . .	900	Osseous Lamina Spiralis . . . . .	914
Nasal Duct . . . . .	900	Membranous Labyrinth . . . . .	914
Front of Eye . . . . .	900	Utricule and Sacculæ . . . . .	914
Surgical Anatomy . . . . .	901	Semicircular Canals . . . . .	915
EAR		Cochlea . . . . .	915
<i>External Ear</i>		Scala Tympani, Scala Vestibuli and Scala Media . . . . .	916
Pinna, or Auricle . . . . .	902	Organ of Corti . . . . .	916
Structure of Auricle . . . . .	902	Vessels of the Labyrinth . . . . .	918
Ligaments of the Pinna . . . . .	903	Auditory Nerve, Vestibular Nerve . . . . .	918
Muscles of the Pinna . . . . .	903	Cochlear Nerve . . . . .	919
ORGANS OF DIGESTION		Surgical Anatomy . . . . .	919
Subdivisions of the Alimentary Canal . . . . .		<i>Tonsils</i>	
The Mouth . . . . .	921	Arteries . . . . .	935
The Lips . . . . .	921	Veins, and Nerves of Tonsils . . . . .	935
The Cheeks . . . . .	922	SALIVARY GLANDS	
The Gums . . . . .	922	<i>Parotid Gland</i>	
TEETH		Situation and Relations . . . . .	935
General Characters of . . . . .	923	Stenson's Duct . . . . .	936
Permanent Teeth . . . . .	923	Vessels and Nerves of Parotid Gland . . . . .	937
Incisors . . . . .	923	<i>Submaxillary Gland</i>	
Canine and Bicuspid . . . . .	924	Situation and Relations . . . . .	937
Molars . . . . .	925	Wharton's Duct . . . . .	937
Temporary or Milk Teeth . . . . .	926	Vessels and Nerves of Submaxillary Gland . . . . .	937
Structure of the Teeth . . . . .	926	<i>Sublingual Gland</i>	
Ivory or Dentine . . . . .	927	Situation and Relations . . . . .	937
Enamel . . . . .	928	Vessels and Nerves of . . . . .	938
Cortical Substance . . . . .	928	Structure of Salivary Glands . . . . .	938
Development of the Teeth . . . . .	929	Surface Form of Mouth . . . . .	940
of the Permanent Teeth . . . . .	932	PHARYNX AND ŒSOPHAGUS	
Eruption of the Teeth . . . . .	933	Situation and Relations . . . . .	941
PALATE		Structure of Pharynx . . . . .	941
Hard Palate . . . . .	934		
Soft Palate . . . . .	934		
Uvula, Pillars of the Soft Palate . . . . .	934		
Mucous Membrane, and Aponeurosis of Soft Palate . . . . .	934		
Muscles of Soft Palate . . . . .	935		

	PAGE
Surgical Anatomy . . . . .	942
Relations of (Esophagus) . . . . .	943
Structure . . . . .	943
Vessels and Nerves of . . . . .	944
Surgical Anatomy . . . . .	944

ABDOMEN

Boundaries . . . . .	945
Apertures of . . . . .	945
Regions . . . . .	945

*Peritoneum*

Development of the Peritoneum . . . . .	948
Reflections traced . . . . .	958
Foramen of Winslow . . . . .	963
Ligaments formed by Peritoneum . . . . .	964
Omenta . . . . .	964
Lesser Omentum . . . . .	964
Great Omentum . . . . .	965
Gastro-splenic Omentum . . . . .	965
Mesenteries . . . . .	965
Meso-cæcum . . . . .	965
Meso-colon, Meso-rectum, Appen- dices Epiploicæ . . . . .	965

*Stomach*

Situation . . . . .	967
Splenic End, Pyloric End . . . . .	967
Cardiac and Pyloric Orifices . . . . .	967
Greater and Lesser Curvatures . . . . .	967
Surfaces . . . . .	968
Ligaments of . . . . .	968
Alterations in Position . . . . .	968
Pylorus . . . . .	968
Structure of Stomach . . . . .	968
Serous Coat . . . . .	968
Muscular Coat and Mucous Membrane . . . . .	969
Gastric Follicles . . . . .	970
Vessels and Nerves of Stomach . . . . .	971
Surface Marking . . . . .	972
Surgical Anatomy . . . . .	972

*Small Intestines*

Duodenum . . . . .	973
First or Superior Portion . . . . .	973
Second or Descending Portion . . . . .	975
Third or Transverse Portion . . . . .	975
Fourth or Ascending Portion . . . . .	975
Vessels and Nerves of Duodenum . . . . .	975
Jejunum . . . . .	975
Ileum . . . . .	975
Meckel's Diverticulum . . . . .	976
Structure of Small Intestines . . . . .	976
Serous and Muscular Coats . . . . .	976
Mucous Membrane and Epithelium . . . . .	976
Valvule Conniventes . . . . .	976
Villi—their Structure . . . . .	977
Simple Follicles . . . . .	979
Duodenal Glands . . . . .	979
Solitary Glands . . . . .	979
Peyer's Glands . . . . .	980

*Large Intestine*

Cæcum . . . . .	982
Appendix Cæci Vermiformis . . . . .	983
Fossæ in neighbourhood of Cæ- cum . . . . .	983
Ileo-cæcal Valve . . . . .	983

Colon . . . . .	984
Ascending . . . . .	984
Transverse . . . . .	984
Descending . . . . .	984
Sigmoid Flexure . . . . .	986
Rectum . . . . .	987
Upper Portion . . . . .	987
Middle Portion . . . . .	987
Lower Portion . . . . .	988
Structure of Large Intestine . . . . .	988
Serous Coat . . . . .	988
Muscular Coat . . . . .	988
Areolar and Mucous Coats . . . . .	989
Simple Follicles . . . . .	989
Solitary Glands . . . . .	989
Surface Form . . . . .	990
Surgical Anatomy . . . . .	990

LIVER

Size, Weight, Position of . . . . .	993
Its Surfaces and Borders . . . . .	994

*Ligaments*

Longitudinal . . . . .	995
Lateral and Coronary . . . . .	995
Round Ligament . . . . .	996

*Fissures*

Longitudinal . . . . .	996
Fissure of Ductus Venosus . . . . .	996
Portal Fissure . . . . .	996
Fissures for Gall Bladder and Vena Cava . . . . .	996

*Lobes*

Right . . . . .	997
Left . . . . .	997
Quadratus . . . . .	997
Spigelii . . . . .	997
Caudatus . . . . .	997
Vessels of Liver . . . . .	998
Nerves of Liver . . . . .	998
Structure of Liver . . . . .	998
Serous Coat . . . . .	998
Fibrous Coat . . . . .	998
Lobules . . . . .	998
Hepatic Cells . . . . .	999
Hepatic Artery . . . . .	1000
Portal Vein . . . . .	1000
Hepatic Veins . . . . .	1000
Biliary Ducts . . . . .	1001

GALL BLADDER

Relations . . . . .	1002
Structure . . . . .	1002
Biliary Ducts . . . . .	1002
Hepatic Duct . . . . .	1002
Cystic Duct . . . . .	1002
Common Cholealic Duct . . . . .	1003
Structure of Biliary Ducts . . . . .	1003
Surface Marking of Liver . . . . .	1003
Surgical Anatomy . . . . .	1004

PANCREAS

Dissection . . . . .	1005
Relations . . . . .	1005
Duct . . . . .	1006
Structure . . . . .	1006
Vessels and Nerves . . . . .	1007
Surface Marking . . . . .	1007
Surgical Anatomy . . . . .	1007

	PAGE		PAGE
SPLEEN		Valves . . . . .	1020
Relations . . . . .	1008	Relics of Fœtal Structure . . . . .	1020
Size and Weight . . . . .	1009	Musculi Pectinati . . . . .	1020
Structure of Serous and Fibrous Coats	1009	<i>Right Ventricle</i>	
Proper Substance . . . . .	1010	Infundibulum . . . . .	1020
Splenic Artery, Distribution . . . . .	1010	Openings . . . . .	1021
Malpighian Bodies . . . . .	1011	Tricuspid Valve . . . . .	1021
Capillaries of Spleen . . . . .	1012	Semilunar . . . . .	1022
Veins of Spleen . . . . .	1012	Chordæ Tendinæ and Columnæ	
Lymphatics and Nerves . . . . .	1013	Carneæ . . . . .	1022
Surface Marking of Spleen . . . . .	1013	<i>Left Auricle</i>	
Surgical Anatomy . . . . .	1013	Sinus . . . . .	1023
THORAX		Appendix . . . . .	1023
Cavity of . . . . .	1014	Openings, Musculi Pectinati . . . . .	1023
Upper Opening . . . . .	1014	<i>Left Ventricle</i>	
Lower Opening . . . . .	1014	Openings . . . . .	1024
PERICARDIUM		Mitral and Semilunar Valves . . . . .	1024
Structure . . . . .	1014	Endocardium . . . . .	1025
Fibrous Layer . . . . .	1015	<i>Structure of Heart</i>	
Serous Layer . . . . .	1016	Fibrous Rings . . . . .	1025
HEART		Muscular Structure . . . . .	1026
Position . . . . .	1018	Muscular Structure of Auricles . . . . .	1026
Size . . . . .	1018	Muscular Structure of Ventricles . . . . .	1026
Subdivision into Four Cavities . . . . .	1018	Vessels and Nerves of Heart . . . . .	1027
Circulation of Blood in Adult . . . . .	1018	Surface Marking of Heart . . . . .	1027
Auriculo-ventricular and Ventricular		Peculiarities in Vascular System of	
Grooves . . . . .	1018	Fœtus . . . . .	1028
<i>Right Auricle</i>		Foramen Ovale, Eustachian Valve . . . . .	1028
Sinus . . . . .	1018	Ductus Arteriosus . . . . .	1028
Appendix . . . . .	1019	Umbilical or Hypogastric Arteries . . . . .	1028
Openings . . . . .	1019	Fœtal Circulation . . . . .	1029
		Changes in Vascular System at Birth . . . . .	1031

## ORGANS OF VOICE AND RESPIRATION

<i>The Larynx</i>		Aryteno-epiglottideus, superior . . . . .	1039
Cartilages of the Larynx . . . . .	1032	inferior . . . . .	1039
Thyroid Cartilage . . . . .	1032	Actions of Muscles of Larynx . . . . .	1039
Cricoid . . . . .	1033	Mucous Membrane of Larynx . . . . .	1040
Arytenoid Cartilages, Cartilages of		Glands, Vessels, and Nerves of Larynx . . . . .	1040
Santorini and Wisberg . . . . .	1034	<i>The Trachea</i>	
Epiglottis . . . . .	1034	Relations . . . . .	1041
Ligaments of the Larynx . . . . .	1035	Bronchi . . . . .	1042
Ligaments connecting the Thyroid		Structure of Trachea . . . . .	1042
Cartilage with the Hyoid Bone . . . . .	1035	Surface Form . . . . .	1044
Ligaments connecting the Thyroid		Surgical Anatomy of Laryngo-tracheal	
Cartilages with the Cricoid . . . . .	1035	Region . . . . .	1044
Ligaments connecting the Arytenoid		<i>The Pleura</i>	
Cartilages to the Cricoid . . . . .	1035	Reflections . . . . .	1046
Ligaments of the Epiglottis . . . . .	1036	Vessels and Nerves . . . . .	1047
Cavity of the Larynx . . . . .	1036	Surgical Anatomy . . . . .	1047
Superior Aperture of the Larynx . . . . .	1036	<i>Mediastina</i>	
Rima Glottidis . . . . .	1036	Superior Mediastinum . . . . .	1048
False Vocal Cords . . . . .	1037	Anterior Mediastinum . . . . .	1049
True Vocal Cords . . . . .	1037	Middle Mediastinum . . . . .	1049
Ventricle of Larynx, Sacculus Laryngis	1037	Posterior Mediastinum . . . . .	1049
Muscles of Larynx . . . . .	1038	<i>The Lungs</i>	
Crico-thyroid . . . . .	1038	Surfaces . . . . .	1049
Crico-arytenoideus posticus . . . . .	1038	Borders and Lobes . . . . .	1049
lateralis . . . . .	1038	Root of Lung . . . . .	1050
Arytenoideus . . . . .	1038		
Thyro-arytenoideus . . . . .	1039		
Muscles of the Epiglottis . . . . .	1039		
Thyro-epiglottideus . . . . .	1039		

	PAGE		PAGE
Weight, Colour, and Properties of Substance of Lung . . . . .	1050	Surface Form of Lungs . . . . .	1054
Structure of Lung . . . . .	1051	Surface Anatomy . . . . .	1055
Serous Coat and Subserous Areolar Tissue . . . . .	1051	<i>Thyroid Gland</i>	
Parenchyma and Lobules of Lung . . . . .	1051	Surfaces and Relations . . . . .	1055
Bronchi, Arrangement of, in Substance of Lung . . . . .	1052	Structure . . . . .	1056
Structure of Smaller Bronchial Tubes . . . . .	1052	Vessels and Nerves . . . . .	1056
The Air-Cells . . . . .	1052	Surgical Anatomy . . . . .	1057
Pulmonary Artery . . . . .	1052	<i>Thymus Gland</i>	
Pulmonary Capillaries and Veins . . . . .	1052	Relations . . . . .	1057
Bronchial Arteries and Veins . . . . .	1054	Structure . . . . .	1058
Lymphatics and Nerves of Lung . . . . .	1054	Vessels and Nerves . . . . .	1059

THE URINARY ORGANS

<i>Kidneys</i>		<i>Suprarenal Capsules</i>	
Relations . . . . .	1060	Relations . . . . .	1071
Dimensions, Weight . . . . .	1060	Structure . . . . .	1072
General Structure . . . . .	1061	Vessels and Nerves . . . . .	1073
Cortical Substance . . . . .	1062	THE PELVIS	
Medullary Substance . . . . .	1062	Boundaries . . . . .	1073
Minute Structure . . . . .	1062	Contents . . . . .	1073
Malpighian Bodies . . . . .	1063	<i>Bladder</i>	
Tufts . . . . .	1063	Shape, Position, Relations . . . . .	1073
Capsule . . . . .	1063	Surfaces . . . . .	1074
Tubuli Uriniferi, Course . . . . .	1063	Urachus . . . . .	1074
Structure . . . . .	1064	Ligaments . . . . .	1076
Renal Blood-vessels . . . . .	1066	Structure . . . . .	1077
Renal Veins . . . . .	1067	Interior of Bladder . . . . .	1078
Venæ Rectæ . . . . .	1067	Vessels and Nerves . . . . .	1079
Lymphatics and Nerves . . . . .	1068	Surface Form . . . . .	1079
Surface Form . . . . .	1068	Surgical Anatomy . . . . .	1079
Surgical Anatomy . . . . .	1069	<i>Male Urethra</i>	
<i>Ureters</i>		Divisions . . . . .	1080
Situation . . . . .	1069	Structure . . . . .	1081
Calices . . . . .	1069	Surgical Anatomy . . . . .	1081
Course . . . . .	1070		
Relations . . . . .	1070		
Structure . . . . .	1070		

MALE GENERATIVE ORGANS

Prostate Gland . . . . .	1083	Vessels and Nerves of the Coverings of the Testis . . . . .	1090
Structure . . . . .	1084	<i>Spermatic Cord</i>	
Vessels and Nerves . . . . .	1084	Its Composition . . . . .	1090
Surgical Anatomy . . . . .	1085	Relations of, in Inguinal Canal . . . . .	1090
Cowper's Glands . . . . .	1085	Arteries of the Cord . . . . .	1090
<i>Penis</i>		Veins of the Cord . . . . .	1091
Root . . . . .	1085	Lymphatics and Nerves of the Cord . . . . .	1091
Glans Penis . . . . .	1085	Surgical Anatomy . . . . .	1091
Body . . . . .	1086	<i>Testes</i>	
Corpora Caverosa . . . . .	1086	Form and Situation . . . . .	1091
Erectile Tissue . . . . .	1087	Size and Weight . . . . .	1092
Arteries of the Penis . . . . .	1087	Coverings . . . . .	1092
Corpus Spongiosum . . . . .	1087	Tunica Vaginalis . . . . .	1092
The Bulb . . . . .	1088	Tunica Albuginea . . . . .	1092
Structure of Corpus Spongiosum . . . . .	1088	Mediastinum Testis . . . . .	1093
Lymphatics of the Penis . . . . .	1088	Tunica Vasculosa . . . . .	1093
Nerves of the Penis . . . . .	1088	Structure of the Testis . . . . .	1093
Surgical Anatomy . . . . .	1088	Lobules of the Testis . . . . .	1093
<i>The Testes and their Coverings</i>		Tubuli Seminiferi . . . . .	1093
Scrotum . . . . .	1089	Arrangement in Lobuli . . . . .	1093
Coverings of the Testis . . . . .	1089		



	PAGE		PAGE
in Mediastinum Testis . . . . .	1094	Relations . . . . .	1095
in Epididymis . . . . .	1094	Structure . . . . .	1096
Vas Deferens, Course, Relations . . . . .	1094	Ejaculatory Ducts . . . . .	1096
Structure . . . . .	1095		
Vas Aberrans . . . . .	1095		
Surgical Anatomy . . . . .	1095		
		<i>Descent of the Testes</i>	
<i>Vesiculæ Seminales</i>		Gubernaculum Testis . . . . .	1097
Form and Size . . . . .	1095	Canal of Nuck . . . . .	1097

## FEMALE ORGANS OF GENERATION

Mons Veneris, Labia Majora . . . . .	1099	during Menstruation . . . . .	1108
Labia Minora . . . . .	1100	during Pregnancy . . . . .	1108
Clitoris, Meatus Urinarius . . . . .	1100	after Parturition . . . . .	1108
Hymen, Glands of Bartholin . . . . .	1101	in Old Age . . . . .	1108
Female Urethra . . . . .	1101		
Female Rectum . . . . .	1102		
		<i>Appendages of the Uterus</i>	
<i>Vagina</i>		Fallopian Tubes . . . . .	1108
Relations . . . . .	1102	Structure . . . . .	1108
Structure . . . . .	1103	Ovaries . . . . .	1109
		Structure . . . . .	1110
<i>Uterus</i>		Graafian Vesicles . . . . .	1110
Situation, Form, Dimensions . . . . .	1103	Discharge of the Ovum . . . . .	1111
Fundus, Body, and Cervix . . . . .	1103	Ligament of the Ovary . . . . .	1112
Ligaments . . . . .	1104	Round Ligaments . . . . .	1112
Cavity of the Uterus . . . . .	1105	Vessels and Nerves of Appendages . . . . .	1112
Cavity of the Cervix . . . . .	1106		
Structure . . . . .	1106		
Vessels and Nerves . . . . .	1107	<i>Mammary Glands</i>	
Its Form, Size, and Situation in the		Situation and Size . . . . .	1112
Fœtus . . . . .	1107	Nipple . . . . .	1112
at Puberty . . . . .	1107	Structure of Mamma . . . . .	1113
		Vessels and Nerves . . . . .	1114

## SURGICAL ANATOMY OF INGUINAL HERNIA

<i>Coverings of Inguinal Hernia</i>		Deep Epigastric Artery . . . . .	1121
Dissection . . . . .	1115	Peritoneum . . . . .	1121
Superficial Fascia . . . . .	1115		
Superficial Vessels and Nerves . . . . .	1115	<i>Inguinal Hernia</i>	
Deep Layer of Superficial Fascia . . . . .	1116	Oblique Inguinal Hernia . . . . .	1123
Aponeurosis of External Oblique . . . . .	1117	Course and Coverings of Oblique Hernia . . . . .	1123
External Abdominal Ring . . . . .	1117	Seat of Stricture . . . . .	1123
Pillars of the Ring . . . . .	1117	Serotal Hernia . . . . .	1124
Intercolumnar Fibres . . . . .	1117	Bubonocele . . . . .	1124
Fascia . . . . .	1117	Congenital Hernia . . . . .	1126
Poupart's Ligament . . . . .	1118	Infantile and Encysted Hernia . . . . .	1126
Gimbernat's Ligament . . . . .	1118	Hernia into the Funicular Process . . . . .	1126
Triangular Ligament . . . . .	1119		
Internal Oblique Muscle . . . . .	1119	<i>Direct Inguinal Hernia</i>	
Cremaster . . . . .	1119	Course and Coverings of the Hernia . . . . .	1126
Transversalis Muscle . . . . .	1120	Seat of Stricture . . . . .	1127
Spermatic Canal . . . . .	1120	Incomplete Direct Hernia . . . . .	1127
Fascia Transversalis . . . . .	1121	Comparative Frequency of Oblique and Direct Hernia . . . . .	1127
Internal Abdominal Ring . . . . .	1121	Division of Stricture in Inguinal Hernia . . . . .	1127
Subserous Areolar Tissue . . . . .	1121		

## SURGICAL ANATOMY OF FEMORAL HERNIA

Dissection . . . . .	1128	Deep Layer of Superficial Fascia . . . . .	1130
Superficial Fascia . . . . .	1128	Cribriform Fascia . . . . .	1130
Cutaneous Vessels . . . . .	1128	Fascia Lata . . . . .	1130
Internal Saphenous Vein . . . . .	1128	Iliac Portion . . . . .	1131
Superficial Inguinal Glands . . . . .	1129	Pubic Portion . . . . .	1131
Cutaneous Nerves . . . . .	1129	Saphenous Opening . . . . .	1131

	PAGE		PAGE
Crural Arch . . . . .	1131	Position of Parts around the Ring . . . . .	1134
Gimbernat's Ligament . . . . .	1132	Septum Crurale . . . . .	1135
Crural Sheath . . . . .	1133	Descent of Femoral Hernia . . . . .	1136
Deep Crural Arch . . . . .	1134	Coverings of Femoral Hernia . . . . .	1136
Crural Canal . . . . .	1134	Varieties of Femoral Hernia . . . . .	1136
Femoral or Crural Ring . . . . .	1134	Seat of Stricture . . . . .	1136

SURGICAL ANATOMY OF PERINÆUM AND  
ISCHIO-RECTAL REGION

*Ischio-Rectal Region*

Dissection of . . . . .	1137
Boundaries of . . . . .	1137
Superficial Fascia . . . . .	1138
Ischio-rectal Fossa . . . . .	1138
Position of parts contained in . . . . .	1138

*Male Perinæum*

Boundaries and extent . . . . .	1139
Deep Layer of Superficial Fascia . . . . .	1139
Course taken by the Urine in Rupture of the Urethra . . . . .	1139
Muscles of the Perinæum (Male) . . . . .	1139
Deep Perineal Fascia . . . . .	1140
Superficial Layer . . . . .	1140
Deep Layer . . . . .	1141
Parts between the Two Layers . . . . .	1141
Compressor Urethræ . . . . .	1142

Cowper's Glands . . . . .	1142
Pudic Vessels and Nerves . . . . .	1142
Artery of the Bulb . . . . .	1142
Position of Viscera at Outlet of Pelvis . . . . .	1142
Prostate Gland . . . . .	1142
Surgical Anatomy of Lithotomy . . . . .	1143
Parts divided in the Operation . . . . .	1144
Parts to be avoided in the Operation . . . . .	1144
Abnormal Course of Arteries in the Perinæum . . . . .	1144

*Female Perinæum*

Superficial Fascia . . . . .	1144
Deep Fascia . . . . .	1144
Compressor Urethræ . . . . .	1145
Perineal Body . . . . .	1145
Pelvic Fascia . . . . .	1145
Obturator Fascia . . . . .	1146
Recto-vesical Fascia . . . . .	1146

INDEX . . . . .	1147
-----------------	------

# LIST OF ILLUSTRATIONS

The illustrations, when copied from any other work, have the author's name affixed. When no such acknowledgment is made the drawing is to be considered original.

## GENERAL ANATOMY

FIG.	PAGE
1. Human Blood Corpuscles . . . . .	<i>Kölliker</i> 3
2. Varieties of Leucocytes in Human Blood . . . . .	3
3. Changes in Shape of Colourless Corpuscles . . . . .	<i>Kirkes</i> 4
4. Blood Crystals . . . . .	<i>Harley</i> 6
5. Chyle from the Lacteals . . . . .	<i>do.</i> 7
6. Karyokinesis . . . . .	9
7. Pavement Epithelium . . . . .	13
8. Columnar Epithelium . . . . .	<i>Kölliker</i> 13
9. Goblet Cells . . . . .	<i>Klein and Noble Smith</i> 13
10. Spheroidal Epithelium . . . . .	<i>Harley</i> 14
11. Ciliated Epithelium. . . . .	<i>Kölliker</i> 14
12. Epithelial Cells from the oral cavity of man . . . . .	<i>Harley</i> 14
13. Transitional Epithelium . . . . .	13
14. White Fibrous Tissue . . . . .	<i>Harley</i> 15
15. Connective Tissue . . . . .	<i>Klein and Noble Smith</i> 16
16. Tendon Cells . . . . .	<i>Schäfer</i> 16
17. Yellow Elastic Tissue . . . . .	<i>Harley</i> 17
18. Connective-tissue Corpuscles . . . . .	<i>Klein and Noble Smith</i> 18
19. Mucoid or Gelatinous Tissue . . . . .	19
20. Retiform Connective Tissue . . . . .	<i>Klein</i> 19
21. Adipose Tissue . . . . .	<i>Harley</i> 20
22. Development of Fat . . . . .	<i>Klein and Noble Smith</i> 20
23. Pigment Cells of Retina . . . . .	21
24. Human Cartilage Cells . . . . .	<i>Kölliker</i> 22
25. Costal Cartilage in Old Age . . . . .	<i>Harley</i> 23
26. White Fibro-Cartilage . . . . .	<i>do.</i> 23
27. Yellow Cartilage . . . . .	<i>do.</i> 24
28. Transverse Section of Bone . . . . .	<i>Kölliker</i> 27
29. Transverse Section of Bone . . . . .	<i>Sharpey</i> 28
30. Nucleated Bone Cells . . . . .	<i>Klein and Noble Smith</i> 28
31. Longitudinal Section of Bone . . . . .	<i>Kölliker</i> 29
32. Section of Bone after removal of Earthy Portion . . . . .	<i>Harley</i> 29
33. Ossification of Fœtal Cartilage . . . . .	<i>Rollett</i> 31
34. Ossification of Limb Bone of Cat . . . . .	<i>Schäfer</i> 32
35. Ossification of Limb Bone of Rabbit . . . . .	<i>Klein and Noble Smith</i> 32
36. Transverse Section of Fœtal Femur . . . . .	<i>Frey</i> 33
37. Ossification of Fœtal Cartilage . . . . .	<i>do.</i> 34
38. Intra-membranous Ossification . . . . .	<i>do.</i> 35
39. Transverse Section of Muscle . . . . .	<i>Kölliker</i> 36
40. Human Muscular Fibre . . . . .	<i>do.</i> 37
41. Structure of Muscular Fibre . . . . .	<i>Todd and Bowman</i> 37
42. Structure of Muscular Fibre . . . . .	<i>Quain</i> 38
43. Krause's Membrane . . . . .	<i>Klein and Noble Smith</i> 38
44. Non-striated Muscular Fibre . . . . .	<i>Harley</i> 39
45. Muscular Fibre Cells . . . . .	<i>Kölliker</i> 40
46. Muscular Fibres of the Heart . . . . .	<i>Schweigger-Seidel</i> 40
47. Nerve Vesicles from Gasserian Ganglion . . . . .	<i>Todd and Bowman</i> 41

FIG.		PAGE
48.	Nerve Vesicles from Brain . . . . .	<i>Harley</i> 42
49.	Human Nerve Tubes . . . . .	<i>Kölliker</i> 42
50.	Node of Ranvier . . . . .	<i>Klein and Noble Smith</i> 43
51.	Nerve Tubes of Eel . . . . .	<i>Todd and Bowman</i> 43
52.	Nervous Branch from Sympathetic . . . . .	<i>Frey</i> 43
53.	Section of Nerve . . . . .	<i>Klein and Noble Smith</i> 45
54.	End Bulb of Krause . . . . .	<i>Klein</i> 48
55.	Tactile Corpuscles . . . . .	<i>Kölliker</i> 48
56.	Pacinian Corpuseles . . . . .	<i>Todd and Bowman</i> 49
57.	Motorial End-plates . . . . .	<i>Kühne</i> 50
58.	Section through a Microscopic Ganglion . . . . .	<i>Klein and Noble Smith</i> 51
59.	Section of Artery and Vein . . . . .	<i>do.</i> 52
60.	Longitudinal Section of Artery and Vein . . . . .	<i>Kölliker</i> 53
61.	Capillary Vessels . . . . .	<i>Frey</i> 55
62.	Capillary Vessels . . . . .	<i>Kölliker</i> 55
63.	Section of Thoracic Duct . . . . .	<i>do.</i> 57
64.	Stomata of Serous Membrane . . . . .	<i>Frey</i> 58
65.	Section of Lymphatic Gland . . . . .	<i>do.</i> 59
66.	Follicle from Lymphatic Gland . . . . .	<i>Frey</i> 59
67.	Medullary Structure from Lymphatic Gland . . . . .	<i>do.</i> 59
68.	Minute Structure of Lymphatic Gland . . . . .	<i>do.</i> 60
69.	Sectional View of the Skin and its Appendages . . . . .	<i>Kölliker</i> 61
70.	Section of Skin . . . . .	<i>do.</i> 62
71.	Transverse Section of Hair Follicle . . . . .	<i>Biesiadecki</i> 65
72.	Sweat Gland . . . . .	<i>Klein and Noble Smith</i> 67
73.	Endothelium with Stomata . . . . .	<i>Klein</i> 68
74.	Varieties of Secreting Glands . . . . .	<i>do.</i> 70
75.	Ovum of Sow . . . . .	<i>M. Barry</i> 72
76.	Human Ovum . . . . .	<i>Kölliker</i> 72
77.	Fertilisation of Ovum . . . . .	<i>Selenka</i> 74
78.	Diagram of the Division of the Yolk . . . . .	<i>Allen Thomson</i> 75
79.	Vitelline Spheres . . . . .	<i>Von Beneden</i> 75
80.	Diagram of the Division of the Blastodermic Membrane . . . . .	<i>Bischoff</i> 76
81.	Section across Medullary Groove of an Early Embryo . . . . .	<i>Schäfer</i> 76
82.	Diagrams of the Development of the Three Layers of the Blastodermic Membrane, Transverse Sections . . . . .	<i>Beauvais and Bouchard</i> 77
83.	Similar Diagrams, Antero-Posterior Sections . . . . .	<i>do.</i> 78
84.	Embryonic Area of the Ovum of a Rabbit . . . . .	<i>Kölliker</i> 80
85.	Transverse Section through Embryo Chick . . . . .	<i>Foster and Balfour</i> 80
86.	Diagrammatic Section through Ovum . . . . .	<i>Quain</i> 81
87.	Transverse Diagrammatic Section of Embryo . . . . .	<i>do.</i> 82
88.	Human Embryo of Four Weeks . . . . .	<i>Quain</i> 83
89.	Transverse Section of Mammalian Embryo . . . . .	<i>Schäfer</i> 84
90.	Diagram of Membranes of the Ovum . . . . .	<i>Wagner</i> 87
91.	Transverse Section through Embryo Chick . . . . .	<i>Foster and Balfour</i> 89
92.	Primitive Vertebral Column of Embryo . . . . .	<i>Kölliker</i> 89
93.	Longitudinal Section of Head of Embryo . . . . .	<i>do.</i> 90
94.	Vertical Section of Head of Embryo . . . . .	<i>Mihalkovics</i> 91
95.	Face of an Embryo . . . . .	<i>Coste</i> 92
96.	Profile View of Brain of Human Embryo at Different Stages . . . . .	<i>His</i> 95
97.	Section of the Medulla . . . . .	<i>Kölliker</i> 96
98.	Diagram of Development of Lens . . . . .	<i>Remak</i> 98
99.	Diagrammatic Section through Fœtal Eyeball . . . . .	<i>Quain</i> 98
100.	Development of Blood-vessels . . . . .	<i>Klein</i> 102
101.	Heart of Embryo, Fifth Week . . . . .	<i>Baer</i> 102
102.	Diagram of Formation of Aortic Arches and Large Arteries . . . . .	<i>Kölliker</i> 105
103.	Diagram of Arterial Arches . . . . .	<i>Quain</i> 105
104.	Primitive Veins . . . . .	<i>Dalton</i> 106
105.	Diagram of the Formation of the Main Systemic Veins . . . . .	<i>Kölliker</i> 107
106.	Development of Alimentary Canal . . . . .	<i>Thompson</i> 108
107.	Early Form of Alimentary Canal . . . . .	<i>Kölliker</i> 108
108.	Wolfian Body in the Asexual Stage of Embryo . . . . .	<i>Farre</i> 111



FIG.	PAGE
244. Tibia and Fibula, anterior surface . . . . .	281
245. Tibia and Fibula, posterior surface . . . . .	282
246. Plan of the Development of the Tibia . . . . .	284
247. Plan of the Development of the Fibula . . . . .	286
248. Bones of the Right Foot, dorsal surface . . . . .	288
249. Bones of the Right Foot, plantar surface . . . . .	289
250. Left Os Calcis . . . . .	290
251. Left Astragalus . . . . .	292
252. Left Cuboid . . . . .	293
253. Left Navicular . . . . .	294
254. Left Internal Cuneiform . . . . .	295
255. Left Middle Cuneiform . . . . .	295
256. Left External Cuneiform . . . . .	296
257. First Metatarsal . . . . .	297
258. Second Metatarsal . . . . .	298
259. Third Metatarsal . . . . .	298
260. Fourth Metatarsal . . . . .	299
261. Fifth Metatarsal . . . . .	299
262. Plan of the Development of the Foot . . . . .	301

## ARTICULATIONS

263. Vertical section of two Vertebræ and their Ligaments, front view . . . . .	312
264. Occipito-atlantal and Atlanto-axial Ligaments, front view . . . . .	316
265. Occipito-atlantal and Atlanto-axial Ligaments, posterior view . . . . .	317
266. Articulation between Odontoid Process and Atlas . . . . . <i>Arnold</i>	318
267. Occipito-axial and Atlanto-axial Ligaments . . . . .	319
268. Temporo-maxillary Articulation, external view . . . . .	320
269. Temporo-maxillary Articulation, internal view . . . . .	321
270. Temporo-maxillary Articulation, vertical section . . . . .	321
271. Costo-vertebral, and Costo-transverse Articulations, anterior view . . . . .	323
272. Costo-transverse Articulation . . . . . <i>Arnold</i>	324
273. Diagrams showing the Axis of Rotation of the Ribs in the movements of Respiration . . . . . <i>Kirke</i>	325
274. Chondro-sternal, Chondro-xiphoid, and Inter-chondral Articulations, anterior view . . . . .	327
275. Articulations of Pelvis and Hip, anterior view . . . . .	329
276. Articulations of Pelvis and Hip, posterior view . . . . .	330
277. Side View of Pelvis, showing greater and lesser Sacro-sciatic Ligaments . . . . .	331
278. Vertical Section of the Symphysis Pubis . . . . .	333
279. Sterno-clavicular Articulation . . . . .	335
280. Shoulder-Joint, Scapulo-clavicular Articulations, and proper Ligaments of Scapula . . . . .	337
281. Vertical Section through the Shoulder-Joint . . . . . <i>Henle</i>	340
282. Left Elbow-Joint, showing anterior and internal Ligaments . . . . .	344
283. Left Elbow-Joint, showing posterior and external Ligaments . . . . .	344
284. Sagittal Section of the Right Elbow-Joint . . . . . <i>Braune</i>	345
285. Ligaments of Wrist and Hand, anterior view . . . . . <i>Arnold</i>	349
286. Ligaments of Wrist and Hand, posterior view . . . . . <i>do.</i>	350
287. Longitudinal Section of Forearm and Hand . . . . . <i>Braune</i>	351
288. Vertical Section of Wrist, showing the Synovial Membranes . . . . .	355
289. Articulations of the Phalanges . . . . .	356
290. Left Hip-Joint, laid open . . . . .	358
291. Ilio-femoral Ligament . . . . . <i>Bigelow</i>	359
292. Vertical Section through Hip-Joint . . . . . <i>Henle</i>	359
293. Muscles in relation with Hip . . . . .	360
294. Right Knee-Joint, anterior view . . . . .	364
295. Right Knee-Joint, posterior view . . . . .	364
296. Right Knee-Joint, showing internal ligaments . . . . .	365
297. Head of Tibia, with Semilunar Cartilages, seen from above . . . . .	366
298. Longitudinal Section through Knee-Joint . . . . . <i>Braune</i>	367
299. Posterior Surface of the Patella . . . . .	369

FIG.		PAGE
300.	Ankle-Joint, Tarsal and Tarso-metatarsal Articulations, internal view . . . . .	373
301.	Ankle-Joint, Tarsal and Tarso-metatarsal Articulations, external view . . . . .	374
302.	Section of Right Foot . . . . .	<i>Braune</i> 375
303.	Ligaments of Plantar Surface of the Foot . . . . .	378
304.	Synovial Membranes of the Tarsus and Metatarsus . . . . .	<i>Arnold</i> 382

## MUSCLES AND FASCIÆ

305.	Plan of Dissection of the Head, Face, and Neck . . . . .	387
306.	Muscles of the Head, Face, and Neck . . . . .	388
307.	Horner's Muscle . . . . .	391
308.	Muscles of the Right Orbit . . . . .	393
309.	The relative position and attachment of the Muscles of the Left Eyeball . . . . .	394
310.	The Temporal Muscle . . . . .	401
311.	The Pterygoid Muscles . . . . .	402
312.	Cervical Fascia . . . . .	405
313.	Muscles of the Neck, and Boundaries of the Triangles . . . . .	408
314.	Muscles of the Neck, anterior view . . . . .	<i>Quain</i> 410
315.	Muscles of the Tongue, left side . . . . .	414
316.	Muscles of the Tongue, from below . . . . .	415
317.	Muscles on the Dorsum of the Tongue . . . . .	415
318.	Coronal Section of Tongue . . . . .	<i>Altered from Krause</i> 416
319.	Muscles of the Pharynx, external view . . . . .	418
320.	Muscles of the Soft Palate . . . . .	420
321.	The Prevertebral Muscles . . . . .	<i>Quain</i> 423
322.	Muscles of the Neck . . . . .	425
323.	Plan of Dissection of the Muscles of the Back . . . . .	427
324.	Muscles of the Back—first, second, and part of the third layer . . . . .	<i>Quain</i> 428
325.	Muscles of the back—deep layers . . . . .	433
326.	Posterior Surface of Sternum and Costal Cartilages . . . . .	442
327.	The Diaphragm, under surface . . . . .	443
328.	Plan of Dissection of Abdomen . . . . .	447
329.	The External Oblique Muscle . . . . .	448
330.	The Internal Oblique Muscle . . . . .	451
331.	The Transversalis, Rectus, and Pyramidalis . . . . .	454
332.	Transverse Section of Abdomen in Lumbar Region . . . . .	<i>Quain</i> 455
333.	Side View of Pelvis, showing Levator Ani . . . . .	460
334.	The Perinæum . . . . .	461
335.	The Muscles attached to the front of the Pelvis . . . . .	462
336.	Superficial Muscles and Vessels of the Perinæum . . . . .	463
337.	Triangular Ligament or Deep Perineal Fascia . . . . .	464
338.	Muscles of Female Perinæum . . . . .	466
339.	Plan of Dissection of Upper Extremity . . . . .	468
340.	Muscles of the Chest and Front of the Arm, superficial view . . . . .	469
341.	Muscles of the Chest and Front of the Arm, with the boundaries of the Axilla . . . . .	471
342.	Serratus Magnus . . . . .	472
343.	Muscles on the Dorsum of the Scapula and the Triceps . . . . .	476
344.	Front of the Left Forearm, superficial muscles . . . . .	483
345.	Front of the Left Forearm, deep muscles . . . . .	484
346.	Posterior Surface of Forearm, superficial muscles . . . . .	487
347.	Supinator Brevis . . . . .	490
348.	Posterior Surface of Forearm, deep muscles . . . . .	490
349.	Transverse Section through the Wrist, showing the Annular Ligaments and the Canals for the passage of the Tendons . . . . .	492
350.	Transverse Section through Carpus . . . . .	<i>Henle</i> 493
351.	Diagram showing the arrangement of the Synovial Sheaths of the Palm and Fingers . . . . .	493
352.	Palmar Fascia . . . . .	494
353.	Muscles of Thumb . . . . .	496
354.	Muscles of the Left Hand, palmar surface . . . . .	498
355.	Dorsal Interossei of Left Hand . . . . .	500

FIG.	PAGE
356. Palmar Interossei of Left Hand . . . . .	500
357. Fracture of the Middle of the Clavicle . . . . .	<i>Hind</i> 503
358. Fracture of the Surgical Neck of the Humerus . . . . .	<i>do.</i> 504
359. Fracture of the Humerus above the Condyles . . . . .	<i>do.</i> 504
360. Fracture of the Olecranon . . . . .	<i>do.</i> 505
361. Fracture of Shaft of the Radius . . . . .	<i>do.</i> 505
362. Fracture of the Lower End of the Radius . . . . .	<i>do.</i> 506
363. Plan of Dissection of Lower Extremity, front view . . . . .	510
364. Muscles of the Iliac and Anterior Femoral Regions . . . . .	511
365. Muscles of the Internal Femoral Region . . . . .	<i>Quain</i> 516
366. Plan of Dissection of Lower Extremity, posterior view . . . . .	519
367. Muscles of the Hip and Thigh . . . . .	520
368. Obturator Externus Muscle . . . . .	523
369. Muscles of the Front of the Leg . . . . .	526
370. Muscles of the Back of the Leg, superficial layer . . . . .	529
371. Muscles of the Back of the Leg, deep layer . . . . .	531
372. Muscles of the Sole of the Foot, first layer . . . . .	537
373. Muscles of the Sole of the Foot, second layer . . . . .	538
374. Muscles of the Sole of the Foot, third layer . . . . .	539
375. Dorsal Interossei . . . . .	540
376. The Plantar Interossei . . . . .	540
377. Fracture of the Neck of the Femur within the Capsular Ligament . . . . .	<i>Hind</i> 543
378. Fracture of the Femur below the Trochanters . . . . .	<i>do.</i> 544
379. Fracture of the Femur above the Condyles . . . . .	<i>do.</i> 544
380. Fracture of the Patella . . . . .	<i>do.</i> 544
381. Oblique Fracture of the Shaft of the Tibia . . . . .	<i>do.</i> 544
382. Fracture of the Fibula with Dislocation of the Foot outward (Pott's fracture) <i>do.</i>	545

## ARTERIES

383. The Arch of the Aorta and its Branches . . . . .	548
384. Plan of the Branches of the Arch of the Aorta . . . . .	548
385. Relations of Great Vessels at Base of Heart . . . . .	551
386. Superficial Dissection of the Right Side of the Neck, showing the Carotid and Subclavian Arteries . . . . .	556
387. Plan of the Branches of the External Carotid . . . . .	556
388. The Arteries of the Face and Scalp . . . . .	563
389. The Internal Maxillary Artery and its Branches . . . . .	568
390. Plan of the Branches of the Internal Maxillary Artery . . . . .	568
391. The Internal Carotid and Vertebral Arteries . . . . .	576
392. The Ophthalmic Artery and its Branches . . . . .	578
393. The Arteries of the Base of the Brain . . . . .	579
394. Vascular Area of the Internal Surface of the Cerebrum . . . . .	<i>Charcot</i> 580
395. Distribution of Middle Cerebral Artery . . . . .	<i>do.</i> 582
396. Diagram of the Arterial Circulation at the Base of the Brain . . . . .	<i>do.</i> 583
397. Distribution of the Cortical Arteries . . . . .	<i>do.</i> 584
398. The Subclavian Artery, showing its relations . . . . .	588
399. Plan of the Branches of the Right Subclavian Artery . . . . .	591
400. The Scapula and Circumflex Arteries . . . . .	595
401. Internal Mammary Artery and its Branches . . . . .	597
402. The Axillary Artery and its Branches . . . . .	599
403. The Brachial Artery . . . . .	606
404. The Radial and Ulnar Arteries . . . . .	609
405. Ulnar and Radial Arteries, deep view . . . . .	612
406. Arteries of the Back of the Forearm and Hand . . . . .	615
407. The Abdominal Aorta and its Branches . . . . .	620
408. The Cœliac Axis and its Branches, the Liver having been raised, and the Lesser Omentum removed . . . . .	623
409. The Cœliac Axis and its Branches, the Stomach having been raised, and the Transverse Mesocolon removed . . . . .	624
410. The Superior Mesenteric Artery and its Branches . . . . .	626



FIG.		PAGE
411.	The Inferior Mesenteric Artery and its Branches . . . . .	628
412.	Arteries of the Pelvis . . . . .	632
413.	Arteries of Internal Organs of Generation in the Female . . . . .	635
414.	Variations in Origin and Course of Obturator Artery . . . . .	636
415.	The Internal Pudic Artery and its Branches in the Male . . . . .	637
416.	The Arteries of the Gluteal and Posterior Femoral Regions . . . . .	640
417.	The Femoral Artery . . . . .	645
418.	Femoral Artery and its Branches . . . . .	650
419.	Side View of Popliteal Artery . . . . .	653
420.	The Popliteal, Posterior Tibial, and Peroneal Arteries . . . . .	656
421.	Surgical Anatomy of the Anterior Tibial and Dorsalis Pedis Arteries . . . . .	656
422.	The Plantar Arteries, superficial view . . . . .	664
423.	The Plantar Arteries, deep view . . . . .	664

## VEINS

424.	Veins of the Head and Neck . . . . .	668
425.	Veins of the Diploë, as displayed by the removal of the outer table of the Skull	} <i>Breschet</i> 673
426.	Vertical Section of the Skull, showing the Sinuses of the Dura Mater . . . . .	675
427.	Plan showing Relation of Structures in Cavernous Sinus . . . . .	677
428.	The Sinuses at the Base of the Skull . . . . .	678
429.	Relation of Structure passing through the Jugular Foramen . . . . .	679
430.	The Superficial Veins of the Upper Extremity . . . . .	680
431.	The Venæ Cavæ and Azygos Veins, with their Formative Branches . . . . .	683
432.	Transverse Section of a Dorsal Vertebra, showing the Spinal Veins	} <i>Breschet</i> 686
433.	Vertical Section of two Dorsal Vertebrae, showing the Spinal Veins	} <i>do.</i> 687
434.	The Internal, or Long Saphenous Vein and its Branches . . . . .	688
435.	The External, or Short Saphenous Vein . . . . .	688
436.	The Portal Vein and its Branches . . . . .	} <i>Quain</i> 694

## LYMPHATICS

437.	The Thoracic and Right Lymphatic Ducts . . . . .	698
438.	The Superficial Lymphatics and Glands of the Head, Face, and Neck	} <i>Mascagni</i> 700
439.	The Deep Lymphatics and Glands of the Neck and Thorax . . . . .	} <i>do.</i> 701
440.	The Superficial Lymphatics and Glands of the Upper Extremity . . . . .	} <i>do.</i> 703
441.	The Superficial Lymphatics and Glands of the Lower Extremity . . . . .	} <i>do.</i> 705
442.	The Deep Lymphatic Vessels and Glands of the Abdomen and Pelvis . . . . .	} <i>do.</i> 706

## NERVOUS SYSTEM

443.	The Spinal Cord and its Membranes . . . . .	713
444.	Transverse Section of the Spinal Cord and its Membranes . . . . .	} <i>Arnold</i> 713
445.	Spinal Cord, side view. Plan of the Fissures and Columns . . . . .	} <i>Quain</i> 715
446.	Transverse Sections of the Cord . . . . .	} <i>Arnold</i> 716
447.	Transverse Section of the Spinal Cord . . . . .	} <i>Klein and Noble Smith</i> 716
448.	Transverse Section through Spinal Cord . . . . .	} <i>do.</i> 717
449.	Columns of the Cord . . . . .	719
450.	Transverse Section of Grey Matter of Cord . . . . .	} <i>J. L. Clarke</i> 720
451.	Transverse Section of Grey Matter of Cord . . . . .	} <i>do.</i> 721
452.	Longitudinal Section of Cord . . . . .	} <i>do.</i> 722
453.	Transverse Section through the White Matter of the Cord	} <i>Klein and Noble Smith</i> 722
454.	Medulla Oblongata and Pons Varolii, anterior surface . . . . .	728
455.	Posterior Surface of Medulla Oblongata . . . . .	730
456.	Section of the Medulla Oblongata . . . . .	} <i>Schwalbe</i> 732
457.	Superficial Dissection of the Medulla and Pons . . . . .	} <i>Ellis</i> 735
458.	Upper Surface of the Brain, the Arachnoid having been removed . . . . .	736
459.	Convolution on the Outer Surface of the Cerebral Hemisphere . . . . .	737
460.	Convolution of the Orbital Lobe . . . . .	740

FIG.		PAGE
461.	Convulsions on the Inner Surface of the Cerebral Hemisphere . . . . .	741
462.	Side View of the Brain, showing the localisation of the various functions <i>Ferrier</i>	742
463.	Top view of the Brain, showing the localisation of the various functions <i>do.</i>	743
464.	Cranio-cerebral topography . . . . . <i>Macalister</i>	745
465.	Cranio-cerebral topography . . . . . <i>Reid</i>	746
466.	Base of the Brain . . . . .	747
467.	Section of the Brain, made on a level with the Corpus Callosum . . . . .	752
468.	The Lateral Ventricles of the Brain . . . . .	753
469.	Horizontal Section through Cerebrum . . . . . <i>Ellis</i>	754
470.	Transverse Vertical Section of the Brain . . . . . <i>After Hirschfeld and Leveillé</i>	755
471.	Transverse Section of the Middle Horn of the Lateral Ventricle . . . . .	756
472.	The Fornix, Velum Interpositum, and middle or descending Cornu of the Lateral Ventricle . . . . .	758
473.	The Third and Fourth Ventricles . . . . .	760
474.	Vertical Median Section of Encephalon, showing the parts in } <i>After Sappey</i>	761
	the middle line	
475.	Grey Matter of the Cerebral Cortex . . . . . <i>Meynert</i>	765
476.	Upper Surface of the Cerebellum . . . . .	769
477.	Under Surface of the Cerebellum . . . . .	770
478.	Vertical Section of the Cerebellum . . . . . <i>Arnold</i>	771
479.	Vertical Section through Grey Matter of Cerebellum <i>Klein and Noble Smith</i>	773
480.	A Corpusele of Purkinje . . . . . <i>do.</i>	774
481.	Floor of the Fourth Ventricle . . . . .	775

## CRANIAL NERVES

482.	The Optic Nerves and Optic Tract . . . . .	778
483.	Course of the Fibres in the Optic Commissure . . . . . <i>Bowman</i>	778
484.	Nerves of the Orbit, seen from above . . . . . <i>After Arnold</i>	780
485.	Plan of the Motor Oculi Nerve . . . . . <i>After Flower</i>	780
486.	Nerves of the Orbit and Ophthalmic Ganglion, side view . . . . . <i>After Arnold</i>	783
487.	Plan of the Fifth Cranial Nerve . . . . . <i>After Flower</i>	785
488.	Distribution of the Second and Third Divisions of the Fifth } <i>After Arnold</i>	787
	Nerve and Submaxillary Ganglion	
489.	The Spheno-Palatine Ganglion and its Branches . . . . .	789
490.	The Otic Ganglion and its Branches . . . . . <i>After Arnold</i>	793
491.	Relation of Structures passing through Sphenoidal Fissure . . . . .	796
492.	The Course and Connections of the Facial Nerve in the } <i>After Bidder</i>	797
	Temporal Bone	
493.	Plan of the Facial Nerve . . . . . <i>After Flower</i>	799
494.	The Nerves of the Scalp, Face, and Side of the Neck . . . . .	800
495.	Origin of the Glosso-pharyngeal, Pneumogastric, and Spinal } <i>do.</i>	802
	Accessory Nerves, their Ganglia and Communications	
496.	Plan of the Glosso-pharyngeal, Pneumogastric and Spinal } <i>After Flower</i>	804
	Accessory Nerves	
497.	Course and Distribution of the Glosso-pharyngeal, Pneumo- } <i>do.</i>	805
	gastric, and Spinal Accessory Nerves	
498.	Plan of the Hypoglossal Nerve . . . . . <i>After Flower</i>	810
499.	Hypoglossal Nerve, Cervical Plexus, and their Branches . . . . .	811

## SPINAL NERVES

500.	Posterior Divisions of the Upper Cervical Nerves . . . . .	815
501.	Plan of the Cervical Plexus . . . . .	817
502.	Plan of the Brachial Plexus . . . . .	821
503.	Cutaneous Nerves of Right Upper Extremity, anterior view . . . . .	824
504.	Cutaneous Nerves of Right Upper Extremity, posterior view . . . . .	824
505.	Nerves of the Left Upper Extremity, front view . . . . .	825
506.	The Suprascapular, Circumflex, and Musculo-spiral Nerves . . . . .	829
507.	The Posterior Branches of the Spinal Nerves <i>After Hirschfeld and Leveillé</i>	833

FIG.		PAGE
508.	Plan of the Lumbar Plexus . . . . .	837
509.	The Lumbar Plexus and its Branches . . . . . <i>Altered from Quain</i>	838
510.	Cutaneous Nerves of the Lower Extremity, front view . . . . .	840
511.	Nerves of the Lower Extremity, front view . . . . .	840
512.	The Posterior Sacral Nerves . . . . . <i>Altered from Ellis</i>	844
513.	The Sacral Plexus and its Branches . . . . .	846
514.	Cutaneous Nerves of the Lower Extremity, posterior view . . . . .	848
515.	Nerves of the Lower Extremity, posterior view . . . . .	848
516.	The Plantar Nerves . . . . .	851
517.	The Sympathetic Nerve . . . . .	855
518.	Plan of the Cervical Portion of the Sympathetic . . . . . <i>Flower</i>	857
519.	Lumbar Portion of Sympathetic . . . . . <i>Henle</i>	863

## ORGANS OF SENSE

520.	Upper Surface of the Tongue . . . . .	867
521.	The three kinds of Papillæ of the Tongue, magnified . . . . . <i>Bowman</i>	868
522.	Circumvallate Papillæ . . . . . <i>Stohr</i>	869
523.	Minute Structure of Taste Goblet . . . . .	870
524.	Under Surface of Tongue, showing Glands of Blandin and Nuhn . . . . .	870
525.	Under Surface of Tongue, showing Distribution of Nerves . . . . .	871
526, 527.	Cartilages of the Nose . . . . . <i>Arnold</i>	874
528.	Bones and Cartilages of Septum of Nose, right side . . . . . <i>do.</i>	875
529.	Transverse Vertical Section of Nasal Fossæ . . . . . <i>Henle</i>	876
530.	Nerves of Septum of Nose, right side . . . . . <i>Arnold</i>	877
531.	A Horizontal Section of the Eyeball . . . . . <i>Allen</i>	881
532.	The Choroid and Iris, enlarged . . . . . <i>Altered from Zinn</i>	883
533.	The Veins of the Choroid, enlarged . . . . . <i>Arnold</i>	884
534.	The Arteries of the Choroid and Iris, the Sclerotic having been } mostly removed, enlarged . . . . . <i>Arnold</i>	885
535.	Section of the Ciliary Region of the Eye . . . . . <i>Waldeyer</i>	886
536.	The Arteria Centralis Retinæ, Yellow Spot, &c., the anterior half of the Eyeball having been removed, enlarged . . . . .	888
537, 538.	Vertical Sections of the Human Retina . . . . . <i>Frey</i>	889
539.	Layers of the Retina . . . . . <i>Altered from Schultze</i>	891
540.	The Crystalline Lens hardened and divided, enlarged . . . . . <i>Arnold</i>	893
541.	The Meibomian Glands, &c., seen from the inner surface of the Eyelids <i>do.</i>	898
542.	The Lachrymal Apparatus, right side . . . . .	899
543.	The Pinna, or Auricle, outer surface . . . . .	902
544.	The Muscles of the Pinna . . . . . <i>Arnold</i>	903
545.	A Front View of the Organ of Hearing, right side . . . . . <i>Scarpa</i>	904
546.	View of Inner Wall of Tympanum, enlarged . . . . .	906
547.	The Small Bones of the Ear, seen from the outside, enlarged . . . . . <i>Arnold</i>	908
548.	The Osseous Labyrinth, laid open, enlarged . . . . . <i>Sömmerring</i>	912
549.	The Cochlea, laid open, enlarged . . . . . <i>Arnold</i>	914
550.	The Membranous Labyrinth . . . . . <i>C. Stewart</i>	915
551.	Floor of Scala Media, showing the organ of Corti, &c. . . . . <i>do.</i>	916
552.	Longitudinal section of the Cochlea . . . . . <i>do.</i>	917

## ORGANS OF DIGESTION AND THEIR APPENDAGES

553.	Sectional View of the Nose, Mouth, Pharynx, &c. . . . .	922
554.	The Permanent Teeth, external view . . . . . <i>From the American Edition</i>	924
555.	The Temporary, or Milk Teeth, external view <i>do. do.</i>	924
556.	Front and Side Views of the Teeth and Jaws . . . . . <i>do. do.</i>	925
557.	Vertical Section of a Tooth <i>in situ</i> . . . . . <i>do. do.</i>	926
558.	Vertical Section of a Molar Tooth . . . . .	926
559.	Vertical Section of a Bicuspid Tooth, magnified . . . . . <i>After Retzius</i>	927
560.	Transverse Section of the Root of a Tooth . . . . . <i>Waldeyer</i>	927
561.	Vertical Section of the Lower Jaw of an early Human Fœtus . . . . . <i>do.</i>	930
562.	Dental Sac of a Human Embryo at an advanced stage of development <i>Frey</i>	931



FIG.		PAGE
563.	The Salivary Glands . . . . .	936
564.	Section of Submaxillary Gland . . . . .	<i>Kölliker</i> 938
565.	Termination of Nerves in Salivary Cells . . . . .	<i>Pflüger</i> 939
566.	Accessory Muscular Fibres of (Esophagus . . . . .	944
567.	Topography of Thoracic and Abdominal Viscera . . . . .	946
568.	The Regions of the Abdomen and their contents (edge of Costal Cartilages in dotted outline) . . . . .	947
569.	Longitudinal Section of a Mammalian Embryo . . . . .	<i>From the American Edition</i> 949
570.	Schematic Median Section of Embryo . . . . .	<i>do. do.</i> 949
571.	Schematic Median Section of Embryo (4th week) . . . . .	<i>do. do.</i> 950
572.	Schematic Median Section of Embryo (6th week) . . . . .	<i>do. do.</i> 950
573.	Fig. 570 with Mesenteries added . . . . .	<i>do. do.</i> 951
574.	Diagram showing the original positions of the Liver, Stomach, Duodenum, &c. . . . .	<i>From the American Edition</i> 951
575.	Cross Section in Duodenal Region . . . . .	<i>do. do.</i> 952
576.	Schematic Representation of Mesentery . . . . .	<i>do. do.</i> 952
577.	Torsion of Umbilical Loop. Initial Position . . . . .	<i>do. do.</i> 953
578.	Torsion of Umbilical Loop. Acquired Position . . . . .	<i>do. do.</i> 953
579.	Development of Alimentary Canal. Early Stage . . . . .	<i>do. do.</i> 953
580.	Development of Alimentary Canal. Later Stage . . . . .	<i>do. do.</i> 953
581.	Final Disposition of the Intestines . . . . .	<i>do. do.</i> 954
582.	Stomach and Mesogastrium . . . . .	<i>do. do.</i> 954
583.	Formation of Cavity of Great Omentum . . . . .	<i>do. do.</i> 954
584.	Cross Section through Embryo . . . . .	<i>do. do.</i> 955
585.	Same Section as Fig. 584. Later . . . . .	<i>do. do.</i> 955
586.	Development of Lesser Sac of Peritoneum . . . . .	<i>do. do.</i> 956
587.	Development of Bursa Omentalis . . . . .	<i>do. do.</i> 956
588.	Cross Section of Alimentary Canal of Fig. 580 . . . . .	<i>do. do.</i> 957
589.	Schematic Drawing of a Cross Section of a Serous Cavity . . . . .	<i>do. do.</i> 957
590.	The Reflections of the Peritoneum, as seen in a Vertical Section of the Abdomen . . . . .	} <i>Altered from Quain</i> 959
591.	Plan of the Peritoneum . . . . .	961
592.	The Reflection of the Peritoneum, as seen in a Transverse Section of the Abdomen . . . . .	963
593.	Diagram to show the lines along which the Peritoneum leaves the Wall of the Abdomen to invest the Viscera . . . . .	966
594.	Diagrammatic Outline of the Stomach . . . . .	967
595.	The Mucous Membrane of the Stomach and Duodenum, with the Bile Ducts . . . . .	969
596.	The Muscular Coat of the Stomach . . . . .	970
597.	Pyloric Gland . . . . .	971
598.	Cardiac Gland . . . . .	971
599.	Relations of the Duodenum, Pancreas and Spleen . . . . .	974
600.	Diagrammatic Section of a Villus . . . . .	977
601.	Villi of Small Intestine . . . . .	<i>Cadiat</i> 978
602.	Transverse Section of Crypts of Lieberkühn . . . . .	<i>Klein and Noble Smith</i> 979
603.	Longitudinal Section of Crypts of Lieberkühn . . . . .	<i>do.</i> 979
604.	Transverse Section through three of Peyer's Follicles, from the Rabbit . . . . .	<i>Frey</i> 980
605.	Patch of Peyer's Glands, from the lower part of the Ileum . . . . .	980
606.	A portion of the above, magnified . . . . .	<i>Boehm</i> 980
607.	Vertical Section of one of Peyer's Patches, from Man, injected through its Lymphatic Canals . . . . .	<i>Frey</i> 981
608.	Meissner's Plexus . . . . .	<i>Klein and Noble Smith</i> 981
609.	The Cæcum and Colon laid open, to show the Ileo-cæcal Valve . . . . .	982
610.	Diagram of the Relations of the Large Intestine and Kidneys, from behind . . . . .	985
611.	The Relations of the Viscera and large vessels of the Abdomen, from behind . . . . .	986
612.	Coronal Section through the Anal Canal . . . . .	<i>From the American Edition</i> 987
613.	Minute Structure of Large Intestine . . . . .	<i>C. Stewart</i> 989
614.	The Liver, upper surface . . . . .	<i>From the American Edition</i> 991
615.	The Liver, under surface . . . . .	<i>do. do.</i> 994
616.	The Under Surface of the Liver . . . . .	<i>Ellis</i> 997
617.	Longitudinal Section of an Hepatic Vein . . . . .	<i>Kiernan</i> 999
618.	Longitudinal Section of a small Portal Vein and Canal . . . . .	<i>do.</i> 999

FIG.		PAGE
619.	Vessels of Lobules of Liver . . . . .	<i>Klein</i> 1000
620.	Origin of Bile Ducts . . . . .	<i>Herring</i> 1001
621.	A Transverse Section of a small Portal Canal and its vessels . . . . .	<i>Kiernan</i> 1001
622.	The Pancreas and its relations . . . . .	1005
623.	Transverse Section through the first Lumbar Vertebra, showing relations of Pancreas . . . . .	<i>Braune</i> 1007
624.	Transverse Section of the Spleen, showing the Trabecular Tissue, and the Splenic Vein and its Branches . . . . .	1009
625.	Transverse Section of the Human Spleen, showing the distribution of the Splenic Artery and its Branches . . . . .	1011
626.	Part of Malpighian Capsule of Spleen . . . . .	<i>Klein and Noble Smith</i> 1012
627.	Minute Structure of Spleen . . . . .	1012

## ORGANS OF CIRCULATION

628.	Pericardium, from in front . . . . .	1015
629.	Pericardium, from behind . . . . .	1016
630.	Front View of the Thorax, showing the relation of the Thoracic Viscera to the Walls of the Chest . . . . .	1017
631.	The Right Auricle and Ventricle laid open, the anterior walls of both being removed . . . . .	1019
632.	The Left Auricle and Ventricle laid open, the posterior walls of both being removed . . . . .	1023
633.	Section of Heart, showing Interventricular Septum . . . . .	1025
634.	Plan of the Fœtal Circulation . . . . .	1029

## ORGANS OF VOICE AND RESPIRATION

635.	Side View of the Thyroid and Cricoid Cartilages . . . . .	1032
636.	The Cartilages of the Larynx, posterior view . . . . .	1033
637.	The Larynx and adjacent parts, seen from above . . . . .	1036
638.	Vertical Section of the Larynx and upper part of the Trachea . . . . .	1037
639.	Muscles of Larynx, side view, right Ala of Thyroid Cartilage removed . . . . .	1038
640.	Interior of the Larynx, seen from above, enlarged . . . . .	<i>Willis</i> 1039
641.	Front View of Cartilages of Larynx: the Trachea and Bronchi . . . . .	1041
642.	Transverse Section of the Trachea, just above its Bifurcation, with a bird's-eye view of the interior . . . . .	1042
643.	Surgical Anatomy of the Laryngo-tracheal Region . . . . .	1043
644.	A Transverse Section of the Thorax, showing the relative positions of the Viscera, and the reflections of the Pleuræ . . . . .	1046
645.	The Posterior Mediastinum . . . . .	1048
646.	Transverse Section through the Third Dorsal Vertebra . . . . .	<i>Braune</i> 1050
647.	Front View of the Heart and Lungs . . . . .	1051
648.	The Roots of the Lungs and Posterior Pulmonary Plexus, seen from behind . . . . .	1053
649.	Structure of Thyroid Gland . . . . .	<i>Frey</i> 1056
650.	Minute Structure of Thyroid Gland . . . . .	<i>Baber</i> 1057
651.	Minute Structure of Thymus Gland . . . . .	<i>Frey</i> 1058
652.	Minute Structure of Thymus Gland . . . . .	1059

## THE URINARY AND GENERATIVE ORGANS

653.	Vertical Section of Kidney . . . . .	1061
654.	Uriniferous Tubes . . . . .	1062
655.	Minute Structure of Kidney . . . . .	1063
656.	Malpighian Body . . . . .	1063
657.	A Uriniferous Tube . . . . .	1065
658.	Descending Limb of Uriniferous Tube . . . . .	<i>Klein</i> 1066
659.	Straight Tube . . . . .	<i>do.</i> 1066
660.	Transverse Section of Kidney . . . . .	<i>do.</i> 1067
661.	Diagrammatic Sketch of Kidney . . . . .	1067



FIG.		PAGE
662.	A Portion of Fig. 593 enlarged . . . . .	1067
663.	Diagrammatic Representation of the Blood-vessels of the Cortex of the Kidney	} <i>Ludwig</i> 1068
664.	Vertical Section of Suprarenal Capsule . . . . .	<i>Elberth</i> 1071
665.	Cortical Portion of Suprarenal Capsule . . . . .	<i>Frey</i> 1071
666.	Transverse Section through the Cortical Substance of the Suprarenal Capsule	} <i>do.</i> 1071
667.	Vertical Section of Bladder, Penis, and Urethra . . . . .	1074
668.	Frontal Section of the lower part of the Abdomen . . . . .	<i>Braune</i> 1075
669.	Vertical Median Section of the Male Pelvis . . . . .	<i>Henle</i> 1076
670.	Superficial Layer of Epithelium of Bladder . . . . .	<i>Klein and Noble Smith</i> 1077
671.	Deep Layers of Epithelium of Bladder . . . . .	<i>do.</i> 1077
672.	The Bladder and Urethra laid open . . . . .	1078
673.	Transverse Section of the Prostate Gland . . . . .	1083
674.	Structure of the Corpus Cavernosum . . . . .	<i>Langer</i> 1087
675.	Transverse Section through the Left Side of the Scrotum and the Left Testicle	1089
676.	The Testis <i>in situ</i> . . . . .	1092
677.	Vertical Section of the Testis . . . . .	1094
678.	Base of the Bladder . . . . .	<i>Haller</i> 1096
679.	The Vulva . . . . .	1099
680.	Vertical Median Section of Female Pelvis . . . . .	1100
681.	Douglas's Pouch . . . . .	1104
682.	Side View of Female Pelvic Organs . . . . .	1105
683.	Arteries of the Internal Organs of Generation of the Female . . . . .	1107
684.	The Uterine Appendages . . . . .	<i>Henle</i> 1108
685.	The Uterus and its Appendages . . . . .	1109
686.	Section of an Ovary . . . . .	<i>Schrön</i> 1110
687.	Section of a Graafian Vesicle . . . . .	<i>Von Baer</i> 1110
688.	Dissection of Lower Half of Female Breast . . . . .	<i>Luschka</i> 1113

SURGICAL ANATOMY OF HERNIA

689.	Inguinal Hernia, superficial dissection . . . . .	1116
690.	Inguinal Hernia, showing the Internal Oblique, Cremaster, and Spermatic Canal	1118
691.	Inguinal Hernia, showing the Transversalis Muscle, the Transversalis Fascia, and the Internal Abdominal Ring . . . . .	1120
692.	Posterior Surface of Anterior Abdominal Wall <i>From the American Edition</i>	1122
693.	Oblique Inguinal Hernia, showing its coverings . . . . .	1124
694.	Varieties of Oblique Inguinal Hernia . . . . .	1125
695.	Femoral Hernia, superficial dissection . . . . .	1129
696.	Femoral Hernia, showing Fascia Lata and Saphenous Opening . . . . .	1130
697.	Femoral Hernia, showing Femoral Canal . . . . .	1132
698.	Structures which pass beneath Crural Arch . . . . .	1133
699.	Hernia. The Relations of the Femoral and Internal Abdominal Rings . . . . .	1135

SURGICAL ANATOMY OF PERINÆUM AND ISCHIO-RECTAL REGION

700.	Dissection of Perinæum and Ischio-rectal Region . . . . .	1138
701.	The Superficial Muscles and Vessels of the Perinæum . . . . .	1140
702.	Deep Perineal Fascia . . . . .	1141
703.	A View of the Position of the Viscera at the Outlet of the Pelvis . . . . .	1142
704.	A Transverse Section of the Pelvis, showing the Pelvic Fascia from behind	} <i>After Wilson</i> 1143
705.	Side View of the Pelvic Viscera of the Male Subject, showing the Pelvic and Perineal Fasciæ . . . . .	1145

# GENERAL ANATOMY



**T**HE fluids of the body, which are intended for its nutrition, are the lymph, the chyle, and the blood. There are other fluids also which partially subserve the same purpose, as the saliva, the gastric juice, the bile, the intestinal secretion; and others which are purely excrementitious, as the urine. But there is no need to describe the rest in this place, since they are the secretions of special organs, and are described, as far as is judged necessary for the purposes of this work, in subsequent pages. We shall here speak first of the blood, and next of the lymph and chyle.

## THE BLOOD

The blood is a thickish, opaque fluid, of a bright red or scarlet colour when it flows from the arteries, of a dark red or purple colour when it flows from the veins. It is viscid, and has a somewhat clammy feeling; it is salt to the taste, and has a peculiar faint odour. It has an alkaline reaction; its alkalinity varies in degree; it is greatest after a meal and least after severe muscular exertion. Its specific gravity at 60° F. is about 1.055, and its temperature is generally about 100° F., though varying slightly in different parts of the body.

**General Composition of the Blood.**—When blood is drawn from the body and allowed to stand, it solidifies in the course of a very few minutes into a jelly-like mass, which has the same appearance and volume as the fluid blood, and, like it, looks quite uniform. Soon, however, drops of a transparent yellowish fluid begin to ooze from the surface of this mass and to collect around it. Coincidentally with this the clot begins to contract, so that, in the course of about twenty-four hours, the original mass of coagulated blood has become separated into two parts: a 'clot' or 'coagulum,' considerably smaller and firmer than the first-formed jelly-like mass, and a large quantity of yellowish fluid, the *serum*, in which the clot floats.

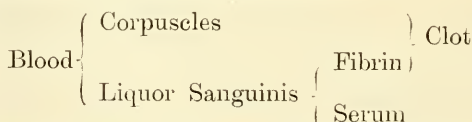
The clot thus formed consists of a solid, colourless material, called *fibrin*, and a large number of minute cells or corpuscles, called *blood-corpuscles*, which are entangled and enclosed in the fibrin. The fibrin is formed during the act of solidification. In the fluid blood in the living body there are two substances, named *fibrinogen* and *paraglobulin* or *serum globulin*, which may be termed fibrin-factors. These two materials, when withdrawn from the body, become acted upon by a third material, also contained in the blood, and named a *fibrin-ferment*, and unite together, forming a solid substance, *fibrin*. This latter in its process of solidification encloses and entangles the blood-corpuscles, and thus the clot is formed.

It must be stated, however, that recent observations have shown that, in the act of clotting outside the body, solutions of fibrinogen, on addition of fibrin-ferment, clot firmly, provided that the solution has a trace of a calcium salt. Consequently paraglobulin would not appear to be necessary for this process; it

merely plays an accessory part, leading to the formation of a firmer and more abundant fibrin. The act of clotting outside the body, which is evidence of the death of the blood, is a process dissimilar to that which occurs inside the body. In the former case a body, fibrinogen, is acted upon by the fibrin-ferment, which appears only after the death of the white corpuscles. In the latter, intravascular clotting can be produced in two ways: (1) by directly stimulating living blood, as by the transfixion of an artery by a needle; or (2) by injection of proteid bodies, which contain lecithin, and which, when injected into the blood, kill in a few minutes by producing intravascular clotting. Further, injection of fibrin-ferment into the blood has negative results; and, again, addition of proteid and lecithin to blood, removed from the body, does not in any way affect the ordinary coagulation process.

We may now consider the constituents of the blood in another way. If a drop of blood is placed in a thin layer on a glass slide and examined under the microscope, it will be seen to consist of a number of minute bodies or corpuscles floating in a clear fluid; and, on more minute examination, it will be found that these corpuscles are of several kinds. Some, greatly preponderating in point of numbers, are termed *coloured corpuscles*; others, fewer in number and less conspicuous, are termed *colourless corpuscles*. From this we learn that blood is a fluid holding a large number of corpuscles of different varieties in suspension. The fluid is named *liquor sanguinis* or *plasma*, and must not be confused with the serum spoken of above in connection with the coagulation of the blood; for it differs from it in this important particular that it contains fibrinogen, while serum contains no fibrinogen.

The relation of these various constituents of blood to each other will be easily understood by a reference to the subjoined plan.



The **Blood-corpuscles**.—The bodies suspended in blood plasma are of three kinds: (1) Erythroblasts, (2) Chromocytes, (3) Leucocytes.

1. *Erythroblasts* are nucleated corpuscles, variable in size and containing hæmoglobin. They occur in the embryo, and in the adult are found in the spleen and red marrow, also in blood after excessive hæmorrhage.

2. *Chromocytes* comprise the ordinary non-nucleated red discs. They develop from erythroblasts, which lose their nuclei either by extrusion from the protoplasm or by solution in this substance. Blood-plates are minute chromocytes destitute of a nucleus in mammals, but possessing one in birds, fish, and amphibia.

3. *Leucocytes*. These are the colourless corpuscles. They multiply by division of the nucleus. The daughter cells are lymphocytes.

**Coloured corpuscles** (*chromocytes*) when examined under the microscope and viewed on the flat are seen to be circular, like a coin, and present a slight central depression, which sometimes appears as a dark centre surrounded by a light ring; but on altering the focus appears as a light centre surrounded by a dark ring. When viewed in profile, each corpuscle is seen to be cupped on both surfaces, presenting the appearance of a dumbbell. Hence, they may be described as biconcave discs (fig. 1). When examined singly by transmitted light, their colour appears to be of a faint reddish-yellow when derived from arterial blood, and greenish-yellow in venous blood. It is to their aggregation that blood owes its red hue. Their size varies slightly even in the same drop of blood, but it may be stated that their average diameter is about  $\frac{1}{3200}$  of an inch, their thickness about  $\frac{1}{12000}$ , or nearly one-quarter of their diameter. Besides these, especially in some anæmic and diseased conditions, certain corpuscles are found of a much smaller size (*microcytes*), about one-third or

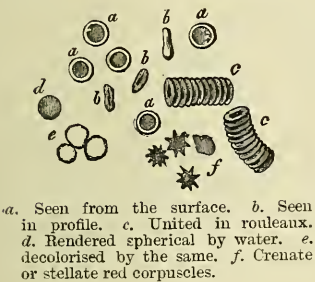


half the size of the ordinary one. These, however, are very scarce in normal blood. The number of red corpuscles in the blood is enormous; between 4,000,000 and 5,000,000 are contained in a cubic millimetre. Power states that the red corpuscles of an adult would present an aggregate surface of about 3,000 square yards. Human blood-discs present no trace of a nucleus. They consist of two parts: a colourless stroma, which is composed largely of fatty material, *lecithin* and *cholesterine*; and a coloured fluid contents, which is a solution of a substance named *hæmoglobin*. *Hæmoglobin* resembles a proteid in chemical constitution, but differs from it in containing iron in addition to the ordinary proteid constituents. It has a great affinity for oxygen, and when removed from the body crystallises readily under certain circumstances. It is readily soluble in water, and the addition of this fluid to a drop of blood speedily dissolves out hæmoglobin from the corpuscle.

If the web of a frog's foot is spread out and examined under the microscope, the blood is seen to flow in a continuous stream through the vessels, and the corpuscles show no tendency to adhere to each other or to the wall of the vessel. Doubtless the same is the case in the human body; but when drawn and examined on a slide without reagents, the blood-globules often collect into heaps like rouleaux of coins (fig. 1, c).

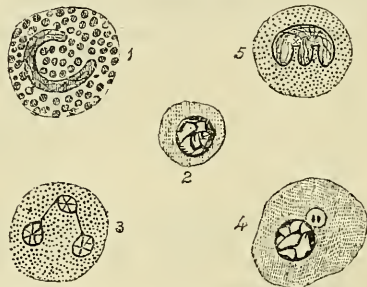
During life the red corpuscles may be seen to change their shape under pressure so as to adapt themselves to some extent to the size of the vessel. They

FIG. 1.—Coloured corpuscles.



a. Seen from the surface. b. Seen in profile. c. United in rouleaux. d. Rendered spherical by water. e. Decolourised by the same. f. Crenate or stellate red corpuscles.

FIG. 2.—Varieties of leucocytes found in human blood.



1. Eosinophilic cell with coarse granules and horse-shoe shaped nucleus. 2. Lymphocyte. 3. Polymuclear or finely granular oxyphilic cell. 4. Hyaline cell, showing nucleus with chromatin threads and two centrosomes in clear protoplasm. 5. Finely granular leucocyte; the nucleus is lobed, the granules stain with basic dyes, such as methylene blue.

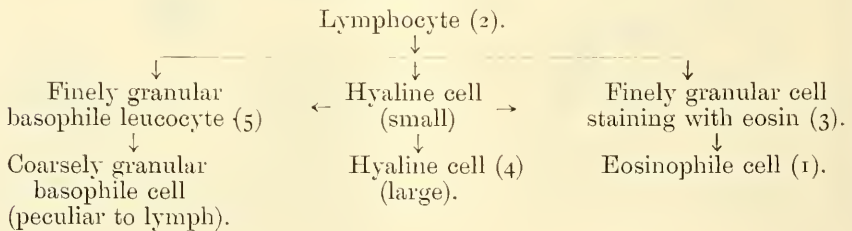
are also highly elastic, for they speedily recover their shape when the pressure is removed. They are soon influenced by the medium in which they are placed, and by the specific gravity of the medium. In water they swell up, lose their shape, and become globular; subsequently the hæmoglobin becomes dissolved out, and the envelope can be barely distinguished as a faint, circular outline. Solutions of salt or sugar, denser than the serum, give them a stellate or crenated appearance (fig. 1, f); and the usual shape may be restored by diluting the solution to the proper point. The same crenated outline may be produced as the first effect of the passage of an electric shock; subsequently, if sufficiently strong, the shock ruptures the envelope. A solution of salt or sugar of the same specific gravity as serum merely separates the blood-globules mechanically without changing their shape.

The **white corpuscles** (*leucocytes*) are of various sizes; some are no larger than the red corpuscles, and some are even smaller, but the majority are rather larger than the coloured ones in human blood, measuring from about  $\frac{1}{2000}$  to  $\frac{1}{2500}$  of an inch in diameter (fig. 2). They consist of a minute mass of nucleated protoplasm, and several varieties are met with in the blood. (1) The most

numerous and important are spherical in shape, and are characterised by a nucleus, which often consists of two or three parts, connected together by fine threads of chromatin. The protoplasm is clear and contains a number of very fine granules, which are only very faintly stained with acid dyes, as eosin (fig. 2, 3). (2) A leucocyte, characterised by the presence of a lobed nucleus and a protoplasm with fine granules which stain with basic dyes, such as methylene blue, is found constantly in the blood. These cells are very few in number (fig. 2, 5). (3) A third variety comprise about 2·4 per cent. of the leucocytes. They are larger than the previous kind, and are made up of a coarsely granular protoplasm, the granules being highly refracting particles, grouped together around a single nucleus. They are deeply stained with eosin, and are therefore often termed *eosinophile* cells. The nucleus is reniform or horse-shoe in shape (fig. 2, 1). (4) The fourth variety is called the *hyaline* cell. They are usually about the same size as the eosinophile cell, and when at rest are spherical in shape and contain a single round or oval nucleus. Their protoplasm is free from granules, but is not quite transparent, having the appearance of ground glass. About 2 per cent. of the leucocytes consist of this variety (fig. 2, 4). (5) The fifth kind of colourless corpuscle is designated the *lymphocyte* (fig. 2, 2), because it is identical with the lymphoid cell, which is derived from the lymphatic glands, the spleen, tonsil, and thymus. It is of small size, and consists chiefly of a spheroidal nucleus, with very little surrounding homogeneous protoplasm. It is regarded as the immature form of all the varieties of corpuscles met with in the blood.

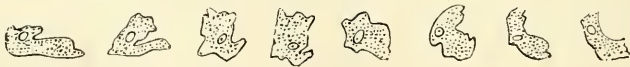The following scheme of Gulland illustrates the relations of the leucocytes to each other. The numbers refer to those of fig. 2.

#### MITOSIS IN LEUCOCYTES



The white corpuscles are very various in shape in living blood, because they have the power of constantly changing it—that is to say, they have the power of sending out finger-shaped or filamentous processes of their own substance, by which they move and take up granules from the surrounding substance. In locomotion the corpuscle pushes out a process of its substance—a *pseudopodium*, as it is called—and then shifts the rest of the body into it (fig. 3). In the same

FIG. 3.—Human colourless blood-corpuscle, showing its successive changes of outline within ten minutes when kept moist on a warm stage. (Schofield.)



way, when any granule or particle comes in its way, it wraps a pseudopodium round it, and then withdrawing it, lodges the particle in its own substance. By means of these amoeboid properties they have the power of wandering or emigrating from the blood-vessels, by penetrating their coats, and thus finding their way into the perivascular spaces.

In addition to these corpuscles, another variety is found in mammalian blood. These, as stated above, are minute chromocytes. They are pale circular or oval

discs, about one-quarter or one-third the size of the red blood-corpuscles, and apparently contain no nucleus. They have been named *blood-platelets* or *blood-plaques*, and are supposed by Bizzozero to originate the fibrin-ferment, and to be especially concerned in the coagulation of the blood.

The white corpuscles originate from lymphoid tissue generally—that is to say, from lymphatic glands, the spleen, and adenoïd tissue—and the view was long maintained that they eventually became developed into red corpuscles; but no observations have ever been made which conclusively prove that this is so, and this theory must be regarded merely as a supposition.

The red corpuscles during embryonic life are developed from mesoblastic cells in the vascular area of the blastoderm. They are at first nucleated and resemble white corpuscles, except in their colour, and, like them, are possessed of amœboid movements. They are succeeded by smaller, non-nucleated corpuscles, having all the characters of adult coloured corpuscles, probably formed by a conversion of the former into the latter. So that at birth the nucleated red corpuscles have disappeared. In after life, an important source of the red corpuscles is the red marrow of bones, in which certain cells found in the marrow are converted into coloured blood-corpuscles by the loss of their nuclei, and by their protoplasm becoming tinged with yellow. A second source of the red corpuscles is believed by Hayem to be the blood-platelets, to which he gives the name of hæmatoblasts. It is probable, also, that the spleen may be a place for the formation of red corpuscles. This theory, which was formerly universally believed, and was then discarded for the hypothesis that the spleen was concerned in the destruction of the red corpuscles, has lately been revived by Bizzozero. The question must still be regarded as *sub judice*. The chief seats of the destruction of the red corpuscles in the adult are believed to be the spleen and the liver. The proportion of white corpuscles appears to vary considerably in different parts of the circulation, being much larger in the blood of the splenic vein and hepatic vein than in other parts of the body, while in the splenic artery they are very scanty.

The **liquor sanguinis** or **plasma** is the fluid part of the blood, and is composed of a permanently fluid portion, the *serum*, and of fibrinogen, which during coagulation becomes converted into or gives rise to fibrin. There is also another proteid in the plasma, and also to a small extent in the colourless corpuscles, named paraglobulin, which, however, is not an essential factor in coagulation. It can be obtained by diluting the liquor sanguinis with ten times its volume of ice-cold water, and then transmitting through it a stream of carbon-dioxide. Fibrinogen may be obtained in the same way as paraglobulin, but the liquor sanguinis must be still further diluted and the current of carbon-dioxide must pass for a much longer time. Fibrin may be obtained by whipping the blood, after it has been withdrawn from the body, with a bundle of twigs, to which the fibrin, as it coagulates, adheres. Fibrin may also be obtained by filtering the freshly drawn blood of an animal whose corpuscles are large, care being taken to retard coagulation as long as possible. Under these circumstances the corpuscles are retained on the filter, and the liquor sanguinis, passing through, coagulates and separates into fibrin, free from corpuscles, and serum.

Fibrin, thus obtained, is a white or buff-coloured substance, presenting a stringy appearance, and under the microscope exhibiting fibrillation. When exposed to the air for some time, it becomes hard, dry, brown, and brittle. It is a proteid compound, insoluble in hot or cold water, alcohol or ether. Under the influence of dilute hydrochloric acid it swells up, but does not dissolve; but when thus swollen it is easily dissolved by a solution of pepsin. If heated for a considerable time in a solution of dilute hydrochloric acid, it gradually dissolves.

**Serum** differs from liquor sanguinis in that it contains no fibrinogen. It is a straw-coloured fluid, having a specific gravity of 1·027, with an alkaline reaction. Upon boiling it becomes solid, on account of the albumen which it contains. It contains also salts, fatty matters, sugar, and gases.



**Gases of the Blood.**—When blood is exposed to the vacuum of an air-pump, about half its volume is given off in the form of gases. These are carbon-dioxide, oxygen, and nitrogen. The relative quantities in 100 volumes of arterial and venous blood, at 0° C. and 1 m. pressure of mercury, are shown in the accompanying table :

	Oxygen	Carbon-dioxide	Nitrogen
Arterial blood . .	16 vols.	30 vols.	1 to 2 vols.
Venous blood . .	6 to 10 vols.	35 vols.	1 to 2 vols.

Roughly stated they are as follows : Carbon-dioxide about two-thirds of the whole quantity of gas, oxygen rather less than one-third, nitrogen below one-tenth (Huxley). The greater quantity of the oxygen is in loose chemical combination with the hæmoglobin of the blood-corpuscles as oxyhæmoglobin, but some part is simply absorbed, just as it would be by water. The carbon-dioxide is in a state of chemical combination with the salts of the serum, especially the sodium, with which it is combined partly as a carbonate and partly as a bicarbonate. The nitrogen is unimportant. It (or at least the greater part of it) is merely absorbed from the atmosphere under the pressure to which the blood is exposed, and can therefore be mechanically removed.

**Blood-crystals.**—Hæmoglobin, as stated above, when separated from the blood-corpuscles, readily undergoes crystallisation. These crystals, named *hæmoglobin crystals*, all belong, with the exception of those obtained from the squirrel, to the rhombic system. In human blood they are elongated prisms (fig. 4, A). In the squirrel they are hexagonal plates. Other crystals may be

FIG. 4.—Blood-crystals.



A. Haemoglobin crystals from human blood. B. Haemin crystals from blood treated with acetic acid. C. Haematoidin crystals from an old apoplectic clot.

obtained by mixing dried blood with an equal quantity of common salt, and boiling it with a few drops of glacial acetic acid. A drop of the mixture placed on the slide will show the crystals on cooling. These are named *haemin* crystals, and consist of small acicular prisms (fig. 4, B). Occasionally in old blood-clots a third form of crystal is found, the *haematoidin* crystal (fig. 4, C).

## LYMPH AND CHYLE

**Lymph** is a transparent, colourless, or slightly yellow fluid, which is conveyed by a system of vessels, named *lymphatics*, into the blood. These vessels take their rise in nearly all parts of the body, and take up from the worn-out tissues that portion which is still available for purposes of nutrition, and return it into the veins close to the heart, there to be mixed with the mass of the blood. The greater number of these lymphatics empty themselves into one main duct, the *thoracic duct*, which passes along the front of the spine, and opens into one of the large veins at the root of the neck. The remainder empty themselves into a smaller duct, which terminates in the corresponding vein on the opposite side of the neck.

**Chyle** is an opaque, milky-white fluid, absorbed by the villi of the small intestines from the food, and carried by a set of vessels similar to the lymphatics, named *lacteals*, to the commencement of the thoracic duct, where it is intermingled with the lymph and poured into the circulation through the same channels. It must be borne in mind that these two sets of vessels, lymphatics and lacteals, though differing in name, are identical in structure, and that the character of the fluid they convey is different only while digestion is going on. At other times the lacteals convey a transparent, nearly colourless fluid not to be distinguished from lymph. Both these sets of vessels, in their passage to the central duct, pass through certain small glandular bodies, termed *lymphatic glands*, where their contents undergo elaboration.

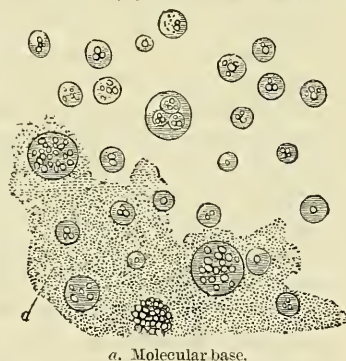**Lymph**, as its name implies, is a watery fluid. It closely resembles the liquor sanguinis, but is more dilute, containing about 5 per cent. of proteids and 1 per cent. of salts. When examined under the microscope it is found to consist of a clear colourless fluid, in which are floating a number of corpuscles, *lymph-corpuscles*. These bodies are identical in structure, and not to be distinguished from the white blood-corpuscles previously described. They vary in number in different parts of the lymphatic vessels, and indeed are said by Kölliker to be absent in the smaller ones. They are always increased in number after the passage of the lymph through a lymphatic gland, and are said to be increased in size as the fluid ascends higher in the course of the circulation. They are constantly furnishing a fresh supply of white corpuscles to the blood.

**Chyle** is a milk-white fluid, which exactly resembles lymph in its physical and chemical properties, except that it has in addition to the other constituents of lymph an enormous amount of fatty granules, 'the molecular base of chyle,' and it is to the presence of these molecules that chyle owes its milky colour. Under the microscope it presents a number of corpuscles, named 'chyle-corpuscles,' which are indistinguishable from lymph-corpuscles or white blood-cells, and the molecular base, consisting principally of fatty granules of extreme minuteness (fig. 5, a), but also of a few small oil-globules. Lymph and chyle after their passage through their respective glands, if withdrawn from the body and allowed to stand, separate more or less completely into a clear liquid, which is identical with the serum of the blood, and a thin jelly-like clot, consisting of a fibrillated matrix in which lymph-corpuscles or chyle-corpuscles and fatty molecules, as the case may be, are entangled.

If the contents of the thoracic duct are examined, especially after a meal, there may be found in it corpuscles with a reddish tinge. These were formerly regarded as *immature* red corpuscles, or lymph and chyle corpuscles in process of transformation into blood-globules.

Mature red corpuscles have also sometimes been found, but these are regarded by most observers as accidental, i.e. introduced into the lymphatics by the rupture of some of the small vessels.

FIG. 5.—Chyle from the lacteals.



a. Molecular base.

## THE ANIMAL CELL

All the tissues and organs of which the body is composed were originally developed from a microscopic body (the *ovum*), consisting of a soft gelatinous granular material enclosed in a membrane, and containing a vesicle, or small spherical body, inside which are one or more solid spots (see fig. 75). This may be regarded as a perfect cell. Moreover, all the solid tissues can be shown to consist largely of similar bodies, differing, it is true, in external form, but essentially similar to an ovum. These are also cells.



In the higher organisms all such cells may be defined as 'nucleated masses of protoplasm of microscopic size.' The two essentials, therefore, of an animal cell in the higher organisms are, the presence of a soft gelatinous granular material, similar to that found in the ovum, and which is usually styled *protoplasm*; and a small spherical body embedded in it, and termed a *nucleus*;\* the remaining constituents of the ovum, viz. its limiting membrane and the solid spot contained in the nucleus, called the *nucleolus*, are not considered essential to the cell, and in fact many cells exist without them.

**Protoplasm** (*sarcodæ, blastema, germinal matter, or bioplasm*) is a proteid compound, consisting largely of muco-globulin. It also contains certain inorganic substances, as phosphorus and calcium, which latter appears to be essential to its life and function. It is of a semi-fluid, viscid consistence, and appears, sometimes, either as a hyaline substance, homogeneous and clear, or as a granular substance, consisting of minute molecules embedded in a transparent matrix. These molecules are regarded as adventitious material taken in from without, and often probably of a fatty nature, since they are soluble in ether. Under a high power of the microscope, in most cells, protoplasm appears to consist of a network or honeycombed reticulum, containing in its meshes a homogeneous substance. The former of these is known as the spongioplasm, the latter as the hyaloplasm. The size and shape of the meshes of the spongioplasm vary in different cells and in different parts of the same cell. In many fixed cells, e.g. epithelial cells, the external layer becomes denser than the rest, and often altered by the deposition in it of some chemical substance, so as to constitute a membrane which encloses the rest of the protoplasm and forms the cell wall. The relative amount of spongioplasm and hyaloplasm to each other varies in different cells; the latter preponderating in the young cell and the former increasing in amount, at the expense of the hyaloplasm, as the cell grows. Protoplasm is insoluble in water, coagulates at 130° Fahr., and has a great affinity for certain staining reagents, as logwood or carmine.

The most striking characteristics of protoplasm are its vital properties of *motion* and *nutrition*. By motion is meant the power which protoplasm has of changing its shape and position by some internal power in itself, which enables it to thrust out from its main body an irregular process, into which the whole of the protoplasmic substance is gradually drawn, so that the mass comes to occupy a new position. This, on account of its resemblance to the movements observed in the *Amœba* or *Proteus* animalcule, has been termed 'amœboid movement.' Ciliary movement, or the vibration of hair-like processes from the surface of any structure, may also be regarded as a variety of the motion with which protoplasm is endowed. Nutrition is the power which protoplasm has of attracting to itself the materials of growth from surrounding matter. When any foreign particle comes in contact with the protoplasmic substance, it becomes incorporated in it, by being enwrapped by one or more processes projected from the parent mass which enclose it. When thus taken up, it may remain in the substance of the protoplasm for some time without change, and finally may be extruded again.

The **Nucleus** is a minute body, embedded in the protoplasm, and usually of a spherical or oval form, its size having little relation to the size of the cell. It is usually surrounded by a well-defined wall, the *nuclear membrane*, which encloses the nuclear contents. This, known as the nuclear substance, is composed of a homogeneous amorphous material and a stroma or network. The former is probably of the same nature as the hyaloplasm of the cell, but the latter, which forms also the wall of the nucleus, differs from the spongioplasm of the cell substance. It is sometimes known as the nucleoplasm, and consists of a network of fibres or filaments arranged in a reticular manner. These filaments stain very readily with certain dyes; they are therefore named *Chromatin*; while the

\* In certain lower forms of life, masses of protoplasm without any nucleus have been described by Huxley and others, as cells.

interstitial substance does not stain readily, and is hence called *Achromatin*. In some resting nuclei the nuclear filaments do not form a network, but present the appearance of a convoluted skein, similar in appearance to what is found in a nucleus about to undergo division, and which will be immediately described.

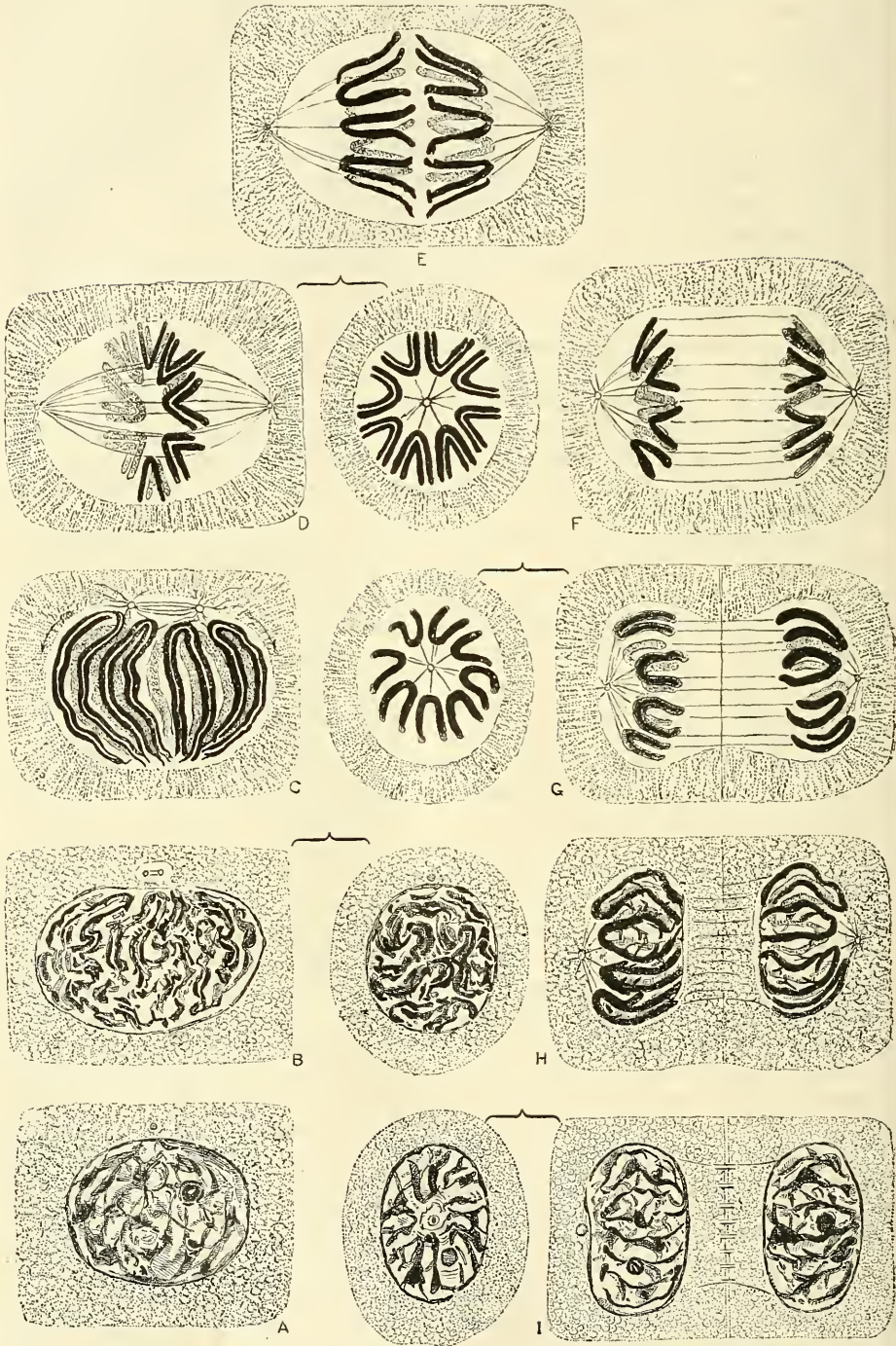
Within the nuclear matrix are one or more highly refracting bodies, termed *Nucleoli*, connected with the nuclear membrane by the nuclear filaments. They are regarded by some as mere local condensations of the nucleoplasm; by others as distinct bodies, differing both in nature and chemical composition. The nuclear substance differs chemically from ordinary protoplasm in containing nuclein, in its power of resisting the action of acids and alkalies, in its imbibing more intensely the stain of carmine, hæmatoxylin, &c., and in its remaining unstained by some reagents which colour ordinary protoplasm—as, for example, nitrate of silver.

The process of reproduction of cells commences in the nucleus, and is usually described as being brought about by *indirect* or by *direct division*. *Indirect division* or *karyokinesis* (*karyomitosis*) has been observed in all the tissues—generative cells, epithelial tissue, connective tissue, muscular tissue, and nerve tissue, and it may be that it will hereafter be shown that the division of cells always takes place in this way, and that the process of reproduction of cells by direct division is, as is believed by some observers, merely a sort of imperfect or abnormal karyokinesis.

The process of reproduction by *indirect* division commences in the nucleus, the stroma of which undergoes complex changes, leading to the division of this body previous to the cleavage of the protoplasm of the cell. The changes consist briefly of the following. At the commencement of the process the nuclear network is well developed, but shows only slight indications of activity. The chromatic fibrils forming the nuclear network, after rearranging themselves, become thicker, and probably combined in one long filament, which forms a loose convolution. This is called the *spirem* or *skein*. At the same time a number of achromatic fibrils, arranged in the form of a spindle, appear at a definite point in the nucleus, towards which the loops of the glomerulus or skein are directed. This point is known as the polar end of the nucleus. From this point the spindle, which is called the *achromatic spindle*, moves gradually towards the centre of the nucleus, where it takes up its position; the two extremities of the spindle, known as the *poles of the spindle*, reach the limit of the nucleus at either side; here they are connected with a central protoplasmic granule, the *polar corpuscle*, and from this the achromatic fibrils of which the spindle is composed radiate outwards into the protoplasm of the cell. The line midway between the poles, and bisecting at right angles a line connecting the two, is called the *equator*. As the achromatic spindle leaves the polar end of the nucleus in order to assume its permanent position it carries with it the loops of the chromatic filaments of the skein, and by the time it has reached the centre of the nucleus these filaments, which have now become V-shaped, assume a stellate arrangement around the equator, and form a festooned ring or star in this situation. This is known as the *mother star* or *monaster*. The chromatic fibrils of which the loops forming the star are composed now undergo a longitudinal cleavage and become divided into two exactly similar, but smaller fibrils. This cleavage or division begins at the apices of the V-shaped loops and gradually extends along the limbs. As soon as this cleavage has taken place, one division of each loop turns to either pole and, passing along the fibrils of the achromatic spindle, by which they appear to be guided, converge to either pole of the spindle. The limbs of the loops remain for some time connected, but afterwards become separated and remain simply attached to each other by a delicate achromatic fibril. When viewed in the axis of the spindle, there appear now to be two stellate arrangements of the looped chromatic filaments, one at either pole. These are known as *dyaster* or *daughter stars*, and have been formed by the longitudinal splitting of the loops



FIG. 6.—Karyokinesis: or indirect cell-division.



SIDE OR EQUATORIAL VIEW.

END OR POLAR VIEW.

SIDE OR EQUATORIAL VIEW.

A. Resting nucleus. B. Skein or spirem, close. C. Skein or spirem, open. D. Mother star, aster, astroid. E. Metakinesis. F. Daughter stars or dyaster. G. Daughter skeins or dispirem, beginning to form. H. Daughter skeins or dispirem, formed. I. Resting daughter nuclei.



which formed the monaster or single star. The chromatic fibrils now begin to lose their regular arrangement in loops, and becoming joined together, present a convoluted appearance at either extremity of the achromatic spindle constituting the daughter skein or dispirem. Cleavage of the protoplasm now commences and continues until it is complete, except where the achromatic threads are found. By further convolution and contraction the loops of the chromatic fibrils become fused together and again form a network. The protoplasm is now again in contact with the nuclear network, which serves to form a wall around the nuclei, and two daughter cells with nuclei are formed. The remains of the achromatic threads bridge across the intercellular substance constituting the prickles of prickle cells.

The diagram on the preceding page, by Professor S. Delépine, is intended to explain the formation of some of the most important chromatic and achromatic figures observed in nuclei of cells during karyokinesis (mitosis); it is based chiefly on the work of Flemming, Strasburger, E. van Beneden, Rabl, O'Hertwig, Henneguy, &c. A. *Resting nucleus*. Nucleolus and nuclear membrane visible. A polar corpuscle (centrosome) is represented diagrammatically at some distance from the nucleus in the protoplasm of the cell, but such a body is usually very difficult to recognise in ordinary cells. B. *Skein or spirem (close)*. Closely packed, much convoluted chromatic filaments. Evidence of longitudinal splitting begins to be distinct in several parts. The polar corpuscle has divided; the nuclear membrane is becoming indistinct. C. *Skein or spirem (open)*. Chromatic filaments thicker, less closely packed; distinctly arranged in loops occupying a definite position in relation to the polar area. The polar corpuscles are widely separated, and the space between them is occupied by the achromatic spindle. (Two arrows indicate the position which the polar corpuscles will ultimately occupy; during their passage to these points the achromatic spindle seems to be within the nucleus.) The nuclear membrane has disappeared. D. *Mother star, aster, astroid*. The nuclear segments (chromosomes) resulting from the breaking-up of the chromatic filament into fragments of nearly equal length have moved towards the equatorial plane of the spindle, where they now form an equatorial plate. These segments are all split longitudinally, and their internal ends are free. The homœotypic form of division is here represented. E. *Metakinesis*. One half of each chromosome moves towards one pole and the other half towards the other pole, being guided and possibly pulled towards the polar corpuscles by contracting achromatic filaments attached to them. F. *Daughter stars or dyaster*. G. *Daughter skeins or dispirem, beginning to form*. Segments in the form of thick loops not closely packed. H. *Daughter skeins or dispirem, formed*. Segments more closely packed and less distinct, owing to the formation of anastomoses. A depression corresponds to the polar area on each side. I. *Resting daughter nuclei*. Cell completely divided, but bridges remain between them in the region previously occupied by the achromatic filaments, these being specially distinct in certain cells (e.g. prickle cells). The nucleus has a distinct nuclear membrane and a nucleolus.

In the reproduction of cells by *direct* division the process is brought about either by segmentation or by gemmation. In reproduction by *segmentation* or *fission*, the nucleus first splits, by becoming constricted in its centre, and thus assuming an hour-glass shape. This leads to a cleavage or division of the whole protoplasmic mass of the cell; and thus we find that two new cells have been formed, consisting of the same substance as the original one, and each containing a nucleus. These daughter cells are of course at first smaller than the original mother cell; but they grow, and the process may be repeated in them, so that multiplication may rapidly take place. In reproduction by *gemmation*, a budding-off or separation of a portion of the nucleus and parent cell takes place, and, becoming separated, forms a new organism.

The **cell-wall**, which is not an essential constituent, and in fact is often absent, is merely the external layer of the protoplasm, firmer than the rest of the cell,

and often thickened by the deposit in it of certain chemical substances. It forms a flexible, transparent, finely striated membrane, sometimes furnished with minute pores, so as to be permeable to fluids.

As far as is known, every animal cell is derived from a pre-existing cell. The death of cells is accomplished either by their mechanical detachment from the surface, preceded possibly by their bursting and discharging their contents, or by various forms of degeneration—fatty, pigmentary, or calcareous.

## EPITHELIUM

All the surfaces of the body—the external surface of the skin, the internal surface of the digestive, respiratory, and genito-urinary tracts, the closed serous cavities, the inner coat of the vessels, and the acini and ducts of all secreting and excreting glands, the ventricles of the brain and the central canal of the spinal cord—are covered by one or more layers of simple cells, called *epithelium* or *epithelial cells*. These cells are also present in the sensory and terminal parts of the organs of special sense, and in some other organs, as the pituitary and thyroid bodies. They serve various purposes, forming in some cases a protective layer, in others acting as an agent in secretion and excretion, and again in others being concerned in the elaboration of the organs of special sense. Thus, in the skin, the main purpose served by the epithelium (here called the *epidermis*) is that of protection. As the surface is worn away by the agency of friction or change of temperature new cells are supplied, and thus the surface of the true skin and the vessels and nerves which it contains, are defended from damage. In the gastro-intestinal mucous membrane and in the glands, the epithelial cells appear to be the principal agents in separating the secretion from the blood or from the alimentary fluids. In other situations (as the nose, fauces, and respiratory passages) the chief office of the epithelial cells appears to be to maintain an equable temperature by the moisture with which they keep the surface always slightly lubricated. In the serous cavities they also keep the opposed layers moist, and thus facilitate their movements on each other. Finally, in all internal parts they ensure a perfectly smooth surface.

Of late years there has been a tendency on the part of many histologists to divide these several epithelial linings into two classes: into (1) *epithelial tissue proper*, consisting of nucleated protoplasmic cells, which form continuous masses on the skin and mucous surfaces and the linings of the ducts and alveoli of secreting and excreting glands; and (2) *endothelium*, which is composed of a single layer of flattened transparent squamous cells, joined edge to edge in such a manner as to form a membrane of cells. This is found on the free surfaces of the serous membranes; as the lining membrane of the heart, blood-vessels, and lymphatics; on the surface of the brain and spinal cord, and in the anterior chamber of the eye.

1. **True epithelial tissue** consists of one or more layers of cells, united together by an interstitial cement-substance, supported on a basement-membrane, and is naturally grouped into two classes according as there is a single layer of cells (*simple epithelium*) or more than one (*stratified epithelium*). The various kinds of epithelium, whether arranged in a single layer or in more than one layer, are usually spoken of as squamous or pavement, columnar, spheroidal or glandular, and ciliated.

The *pavement epithelium* (fig. 7) is composed of flat nucleated scales of various shapes, usually polygonal, and varying in size. These cells fit together by their edges, like the tiles of a mosaic pavement. The nucleus is generally flattened, but may be spheroidal. The flattening depends upon the thinness of the cell. The protoplasm of the cell presents a fine reticulum or honey-combed network, which gives to the cell the appearance of granulation. This



kind of epithelium, forming a single layer (endothelium), is found lining serous membranes, blood-vessels, the anterior chamber of the eye, and in some other situations.

The *columnar* or *cylindrical* epithelium (fig. 8) is formed of cylindrical or rod-shaped cells set together so as to form a complete layer, resembling, when viewed in profile, a palisade. The cells have a prismatic figure, more or less flattened from mutual pressure, and are set upright on the surface on which they are supported. Their protoplasm is always more or less reticulated, which gives them a granular appearance, and they contain a nucleus which is oval in shape and contains an intranuclear network.

This form of epithelium covers the mucous membrane of nearly the whole gastro-intestinal tract and the glands of that part, the greater part of the urethra, the vas deferens, the prostate, Cowper's glands, Bartholini's glands, and a portion of the uterine mucous membrane.

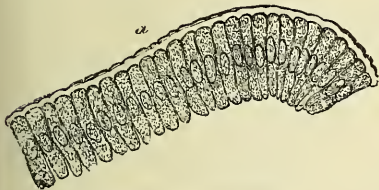
*Goblet* or *chalice* cells are a modification of the columnar cell. They appear to be formed by an alteration in shape of the columnar epithelium (ciliated or otherwise) consequent on the secretion into the interior of the cell of *mucin*, the chief organic constituent of mucus, which distends the upper part of the cell, while the nucleus is pressed down towards its deep part, until the cell bursts and the mucus is discharged on to the surface of the mucous membrane as shown in fig. 9).

The *spheroidal* or *glandular* epithelium (fig. 10) is composed of circular or polyhedral cells. Like other forms of epithelial cells, the protoplasm is a

FIG. 7.—Simple pavement epithelium.

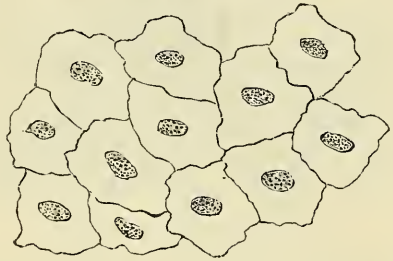

FIG. 8.—Epithelium of the intestinal villi of the rabbit. Magnified 300 times.



a. Basement-membrane.

FIG. 9.—Simple columnar epithelium, from the mucous membrane of the intestine, with goblet-cells pouring out their contents. (Klein and Noble Smith.)



fine reticulum, which gives to the cell the appearance of granulation. They are found in the terminal recesses of secreting glands, and the protoplasm of the cells usually contains the materials which the cells secrete.

*Ciliated* epithelium (fig. 11) may be of any of the preceding forms, but usually inclines to the columnar shape. It is distinguished by the presence of minute processes, which are direct prolongations of the cell-protoplasm, like hairs or eyelashes (*cilia*) standing up from the free surface. If the cells are examined during life or immediately on removal from the living body (for which in the human subject the removal of a nasal polypus offers a convenient opportunity) in a weak solution of salt, the cilia will be seen in lashing motion; and if the cells are separate, they will often be seen to be moved about in the field by this motion.

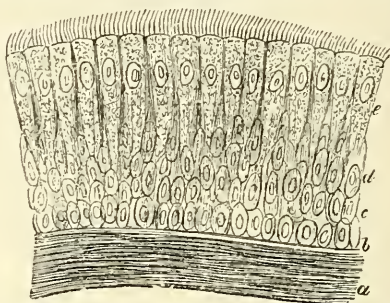
The situations in which ciliated epithelium is found in the human body are :

the respiratory tract from the nose downwards to the smallest ramifications of the bronchial tubes, except a part of the pharynx and the surface of the vocal

FIG. 10.—Spheroidal epithelium.  
Magnified 250 times.

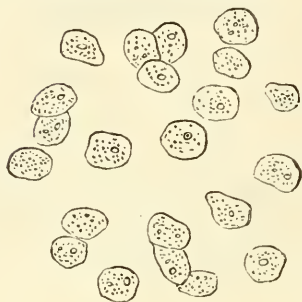

FIG. 11.—Ciliated epithelium from the human trachea. Magnified 350 times.

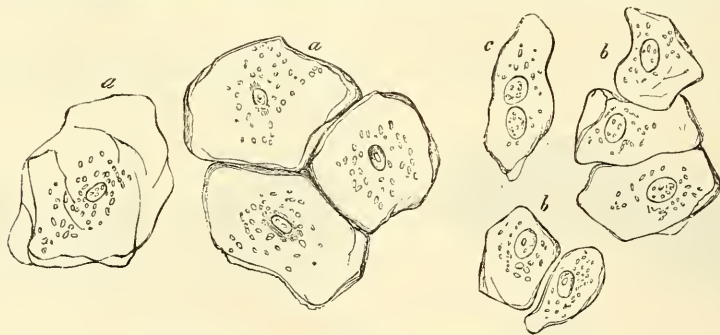


*a.* Innermost layers of the elastic longitudinal fibres.  
*b.* Homogeneous innermost layers of the mucous membrane. *c.* Deepest round cells. *d.* Middle elongated cells. *e.* Superficial cells, bearing cilia.

cords ; the tympanum and Eustachian tube ; the Fallopian tube and upper portion of the uterus ; the vasa efferentia ; conii vasculosi ; the first part of the excretory duct of the testicle ; and the ventricles of the brain and central canal of the spinal cord.

**Stratified epithelium** consists of several layers of cells superimposed one on the top of the other and varying greatly in shape. The cells of the deepest layer are for the most part columnar in form, and as a rule form a single layer, placed vertically on the supporting membrane ; above these are several layers of

FIG. 12.—Epithelial cells from the oral cavity of man. Magnified 350 times.



*a.* Large. *b.* Middle sized. *c.* The same with two nuclei.

spheroidal cells, which as they approach the surface become more and more compressed, until the superficial layers are found to consist of flattened scales (fig. 12), the margins of which overlap one another so as to present an imbricated appearance. They here undergo a chemical change from the conversion of their protoplasm into a horny substance.

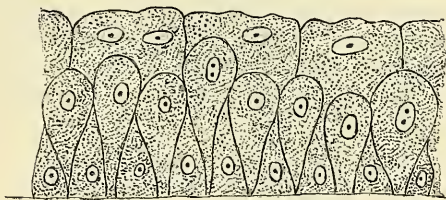
A variety of squamous epithelium which is found in the deeper layers of stratified pavement-epithelium has been termed *prickle cells*. These cells possess short fine fibrils which pass from their margins to those of neighbouring cells, serving to connect them together. Since they are not here closely connected together by cement-substance, but are separated from each other by intercellular channels, across which these fine fibrils may be seen bridging, this gives to the cell, when isolated, the appearance of being covered over with a number of short



spikes, in consequence of the fibrils being broken through. They were first described by Max Schultze and Virchow, and it was believed by them that the cells were dovetailed together. Subsequently this was shown not to be so by Dr. Martyn, who pointed out that the prickles were attached to each other by their apices; and recently Dr. Delépine has stated that he believes the prickles of prickle cells are parts of fibrils forming internuclear bundles between the nuclei of the cells of an epithelium in a state of active growth (see page 11, and fig. 6).

Another form of stratified epithelium is found in what has been termed *transitional* epithelium, such as exists in the ureters and urinary bladder. Here the cells of the most superficial layer are cubical, with depressions on their under surfaces, which fit on to the rounded ends of the cells of the second layer, which are pear-shaped, the apices touching the basement-membrane. Between their tapering points is a third variety of cells, filling in the intervals between them, and of smaller size than those of the other two layers (fig. 13).

FIG. 13.—Transitional epithelium.



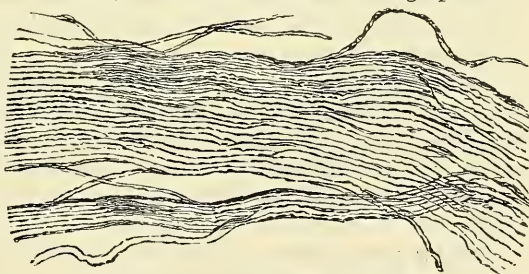
## CONNECTIVE TISSUES

By the term **connective tissue** we mean a number of tissues which possess this feature in common, viz. that they serve the general purpose in the animal economy of supporting and connecting the tissues of the frame. These tissues may differ considerably from each other in external appearance, but they present nevertheless many points of relationship, and are moreover developed from the same embryonal elements. They are divided into three great groups: (1) the fibrous connective tissues, (2) cartilage, and (3) bone.

**The fibrous connective tissues.**—Three principal forms or varieties of fibrous connective tissue are recognised:—(1) White fibrous tissue. (2) Yellow elastic tissue. (3) Areolar tissue. They are all composed of a matrix in which cells are embedded, and between the cells are fibres of two kinds, the white and yellow or elastic. The difference between the three forms of tissue depends on the relative proportion of the two kinds of fibre, in the first variety enumerated the *white* fibre preponderating; in the second variety the *yellow elastic* fibres being greatly in excess of the white; and in the third form, areolar tissue, the two being blended in much more equal proportions.

The **white fibrous tissue** (fig. 14) is a true connecting structure, and serves three purposes in the animal economy. It serves to bind bones together

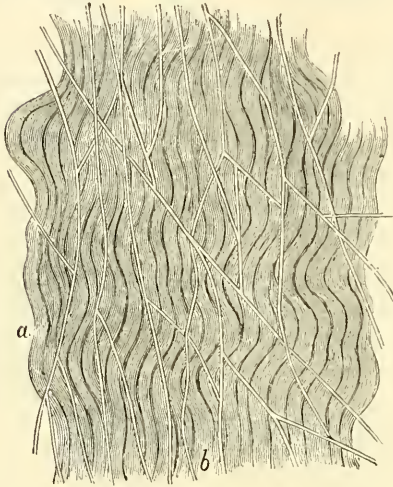
FIG. 14.—White fibrous tissue. High power.



in the form of ligaments, it serves to connect muscles to bones or other structures in the form of tendons, and it forms an investing or protecting structure to various organs in the form of membranes. Examples of where it serves this latter office are to be found in the muscular fasciæ or sheaths, the periosteum, and perichondrium; the investments of the various glands (such as the tunica albuginea testis, the capsule of the kidney, &c.), the investing sheath of the nerves (epineurium), and of various organs, as the penis and the eye (sheath of the corpora cavernosa and corpus spongiosum and of the sclerotic). But in all these

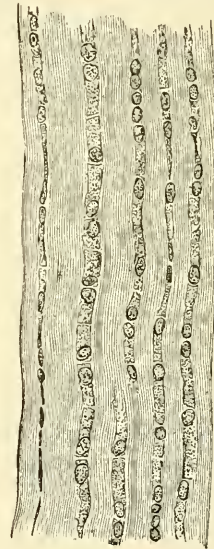
parts the student must bear in mind that the elastic tissue enters in greater or less proportion. It presents to the naked eye the appearance of silvery white glistening fibres, covered over with a quantity of loose, flocculent tissue which binds the fibres together and carries the blood-vessels. It is not possessed of any elasticity, and only the very slightest extensibility; it is exceedingly strong, so that upon the application of any external violence the bone with which it is connected will fracture before the fibrous tissue will give way. When examined under the microscope it is found to consist of wavy bands or bundles of minute, transparent, homogeneous filaments or fibrillæ, held together by an albuminous semi-fluid cement-substance (fig. 15). In ligaments and tendons these bundles run parallel with each other; in membranes they intersect one another in different

FIG. 15.—Connective tissue. (Klein and Noble Smith.)



*a.* The white fibrous element—a layer of more or less sharply outlined, parallel, wavy bundles of connective-tissue fibrils. On the surface of this layer is *b*, a network of fine elastic fibres.

FIG. 16.—Tendon of mouse's tail, stained with logwood, showing chains of cells between the tendon-bundles. (From Quain's 'Anatomy.' E. A. Schäfer.)



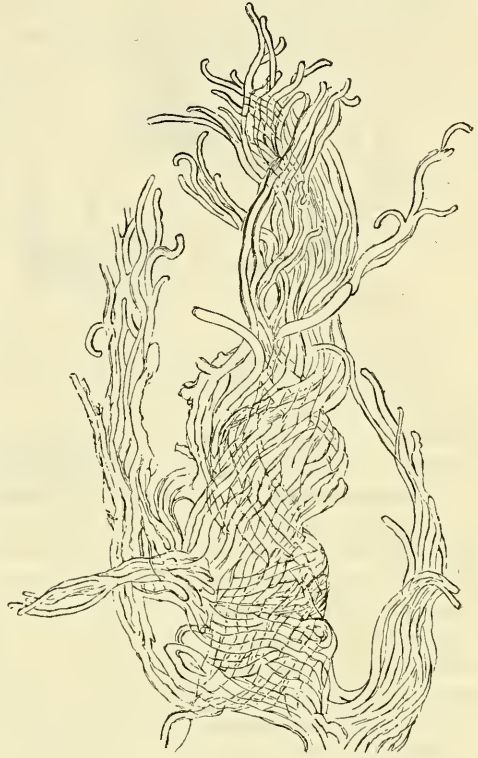places. The bundles have a tendency to split up longitudinally or send off slips to join other bundles and receive others in return. The cells occurring in white fibrous tissue are often called 'tendon cells.' They are situated on the surface of groups of bundles and are quadrangular in shape, arranged in rows in single file, each cell being separated from its neighbours by a narrow line of cement-substance. The nucleus is generally situated at one end of the cell, the nucleus of the adjoining cell being in close proximity to it (fig. 16). Upon the addition of acetic acid to white fibrous tissue it swells up into a glassy-looking indistinguishable mass. When boiled in water it is converted almost completely into gelatin.

**Yellow elastic tissue.**—In certain parts of the body a tissue is found which when viewed in mass is of a yellowish colour, and is possessed of great elasticity; so that it is capable of considerable extension, and when the extending force is withdrawn returns at once to its original condition. This is *yellow elastic tissue*, in which the elastic fibres greatly preponderate, to the almost complete exclusion of the white fibrous element. It is found in this condition in the ligamenta subflava, in the vocal cords, in the longitudinal coat of the trachea and bronchi, in the inner coats of the blood-vessels, especially the larger arteries, and to a very considerable extent in the thyro-hyoid, crico-thyroid, and stylo-hyoid ligaments. It is also found in the ligamentum nuchæ of the lower animals. When viewed



under the microscope (fig. 17) it is seen to consist of an aggregation of curling fibres, with a well-defined outline. They are considerably larger in size than the fibrillæ of the white fibrous element, and vary much, being from the  $\frac{1}{240000}$  to the  $\frac{1}{40000}$  of an inch in diameter. The fibres form bold and wide curves, branch and freely anastomose with each other. They are homogeneous in appearance, and have a tendency to curl up, especially at their broken ends. In some parts where the fibres are broad and large and the network close, the tissue presents the appearance of a membrane, with gaps or perforations corresponding to the intervening space. This is to be found in the inner coat of the arteries, and to it the name of *fenestrated membrane* has been given by Henle. The yellow elastic fibres remain unaltered by acetic acid.

FIG. 17.—Yellow elastic tissue. High power.



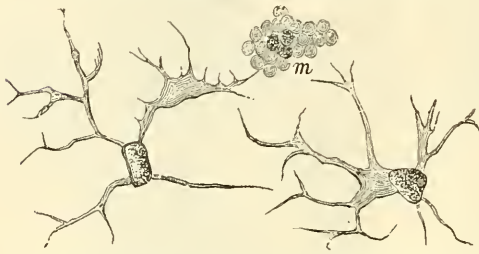
**Areolar tissue** is so called because its meshes are easily distended, and thus separated into areolæ or spaces, which all open freely into each other, and are consequently easily blown up with air, or permeated by fluid, when injected into any part of the tissue. Such spaces, however, do not exist in the natural condition of the body, but the whole tissue forms one unbroken membrane composed of a number of interlacing fibres, variously superimposed. Hence the term 'cellular membrane' is in many parts of the body more appropriate than its more modern equivalent. The chief use of the areolar tissue is to bind parts together; while by the laxity of its fibres, and the permeability of its areolæ, it allows them to move on each other, and affords a ready exit for inflammatory and other effused fluids. It is one of the most extensively distributed of all the tissues in the body. It is found beneath the skin, in a continuous layer all over the body, connecting it to the subjacent parts. In the same way it is situated beneath the mucous and serous membranes. It is also found between muscles, vessels, and nerves, forming investing sheaths for them, and connecting them with surrounding structures. In addition to this, it is found in the interior of organs, binding together the various lobes and lobules of the compound glands, the various coats of the hollow viscera, and the fibres of muscles &c., and thus forms one of the most important connecting media of the various structures or organs of which the body is made up. In many parts the areolæ or interspaces of areolar tissue are occupied by fat-cells, constituting *adipose tissue*, which will presently be described.

Areolar tissue presents to the naked eye a flocculent appearance, somewhat like spun-silk. When stretched out, it is seen to consist of delicate soft elastic threads interlacing with each other in every direction, and forming a network of extreme delicacy. When examined under the microscope it is found to be composed of white fibres and elastic fibres intercrossing in all directions, and united together by a homogeneous cement or ground-substance, and filled by cellular elements, which contain the protoplasm out of which the whole is developed and regenerated.

These cell-spaces may be brought into view by treating the tissue with nitrate of silver, and exposing it to the light. This will colour the fibres and ground-substance, leaving the cell-spaces unstained.

The cells of areolar tissue (fig. 18) are of three kinds: 1, flattened transparent cells, more or less branched, and often united together by thin-branched processes, thus forming a network in the ground-substance.

FIG. 18.—Connective-tissue corpuscles.  
(Klein and Noble Smith.)



m. Granular connective-tissue cell. The other two are the ordinary branched cells, each with an oblong nucleus.

They are composed of clear cell-substance, in which is contained a large oval nucleus; 2, other cells, instead of presenting a clear cell-substance, are distinctly granular, and to these the term *granular cells* is applied. These granules, which are albuminous in character, like one form of leucocyte, stain deeply with eosin; 3, a third class of

cells are distinguished from the other two by containing large vacuoles; these are termed *plasma cells*. The vacuoles are filled with fluid, and the protoplasm between the spaces is clear, with occasionally a few scattered granules.

**Vessels and Nerves of Connective Tissue.**—The *blood-vessels* of connective tissue are very few—that is to say, there are few actually destined for the tissue itself, although many vessels may permeate one of its forms, the areolar tissue, carrying blood to other structures. In white fibrous tissue the blood-vessels usually run parallel to the longitudinal bundles and between them, sending transverse communicating branches across, and in some forms, as in the periosteum and dura mater, being fairly numerous. In yellow elastic tissue, the blood-vessels also run between the fibres, and do not penetrate them. *Lymphatic* vessels are very numerous in most forms of connective tissue, especially in the areolar tissue beneath the skin and the mucous and serous surfaces. They are also found in abundance in the sheaths of tendons, as well as in the tendons themselves. *Nerves* are to be found in the white fibrous tissue, where they terminate in a special manner; but it is doubtful whether any nerves terminate in areolar tissue; at all events, they have not yet been demonstrated, and the tissue is possessed of very little sensibility.

**Development of Connective Tissue.**—Fibrous connective tissue is developed from embryonic connective-tissue cells, derived from the mesoblast. At an early period of development it consists of nucleated cells and a muco-albuminous fluid, which subsequently becomes a pellucid jelly, and forms the ground-substance. In this ground-substance the two varieties of fibres become developed. As to the manner in which they do so there are two theories, some believing that they are developed from the protoplasm of the cells, others that they are formed by a deposit in the ground-substance. In the former case the protoplasm of the cells is converted wholly into elementary fibres, the nucleus disappearing; or else the peripheral part of the protoplasm produces the fibrous tissue, the original cell growing again to its original size, and then throwing off a fresh portion to form a new fibre, and itself persisting in contact with the fibres it has formed as a permanent connective-tissue corpuscle.

Yellow elastic fibres are said by some to be formed by the processes of stellate embryonal cells, which, joining with processes of other cells, form the elastic fibres.

Three special forms of connective tissue must be described: the mucoid, the lymphoid or retiform, and basement-membranes.

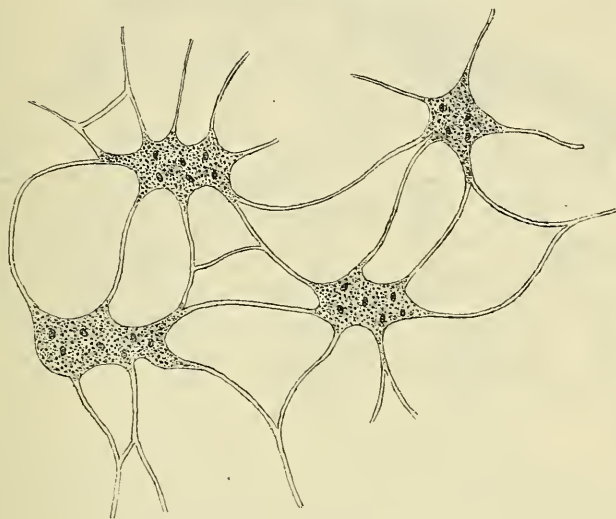
1. The **mucoïd** or **gelatinous** connective tissue exists chiefly in the 'jelly of Wharton,' which forms the bulk of the umbilical cord, but is also found in some other situations in the foetus, as in the pulp of young teeth, and in certain stages of the development of connective tissue in various regions. In the adult, the



vitreous humour of the eye is formed of the same material. This tissue consists of nucleated cells, which branch and become connected so as to form trabeculæ, in which is contained a jelly-like substance, containing the chemical principle of mucus, or *mucin*, and in smaller quantities albumen, but no gelatin (fig. 19). Sometimes, as in the vitreous humour of the eye, the cells disappear, and the jelly only remains.

2. **Retiform** connective tissue is found extensively in many parts of the body, forming the framework of some organs and entering into the construction

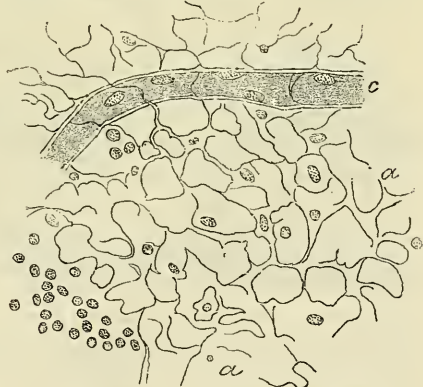FIG. 19.—Mucoïd or gelatinous connective tissue.



of many mucous membranes. It is formed of an interlacement or network of very fine fibres, which closely resemble white fibrous tissue, and in certain situations may be demonstrated to be continuous with it. In many places flattened cells may be seen connected with the fibres and partially concealing them, presenting an appearance as if the tissue were formed of a network of branching and anastomosing cells. This, however, is not so, as the cells can be removed or brushed away, leaving the fibres intact. In many situations the interstices of the fibres are filled with rounded granular corpuscles, and the tissue is then termed **lymphoid** or **adenoid tissue** (fig. 20).

3. **Basement-membranes**, formerly described as homogeneous membranes, are really a form of connective tissue. They constitute the supporting membrane, or *membrana propria*, supporting the epithelium of mucous membranes or secreting glands, and in other situations. By means of staining with nitrate of silver they may be shown to consist of flattened cells in close apposition, and form therefore an example of an epithelioid arrangement of connective-tissue cells. In some situations the cells, instead of adhering by their edges, give off branching processes, which join with similar processes of other cells and so form a network, rather than a continuous membrane.

FIG. 20.—Retiform connective tissue, from a lymphatic gland: most of the lymph-corpuscles are removed. (From Klein's 'Elements of Histology.')

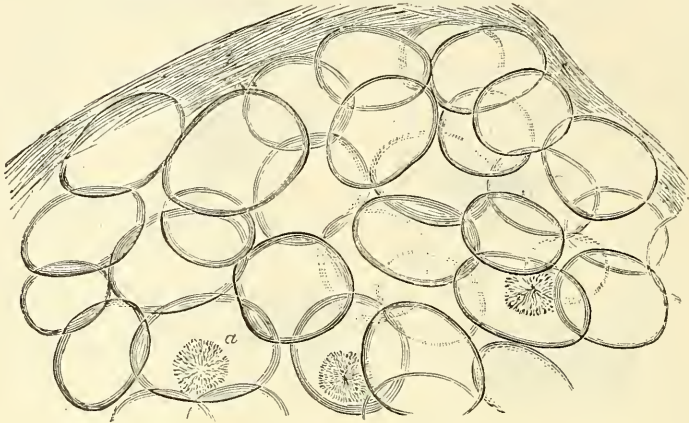


a. The reticulum. c. A capillary blood-vessel.

## ADIPOSE TISSUE

In almost all parts of the body the ordinary areolar tissue contains a variable quantity of fat. The principal situations where it is not found are the subcutaneous tissue of the eyelids, the penis and scrotum, the nymphæ, within the cavity of the cranium, and in the lungs, except near their roots.

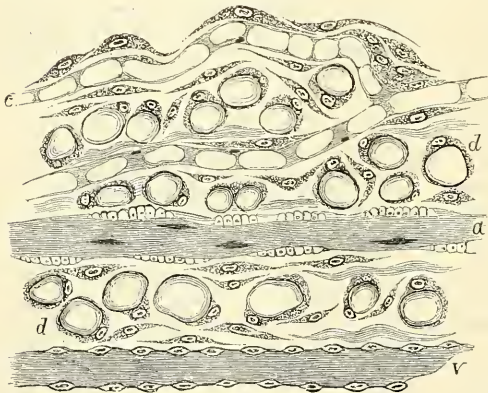
FIG. 21.—Adipose tissue. High power.



a. Starlike appearance, from crystallisation of fatty acids.

Nevertheless its distribution is not uniform; in some parts it is collected in great abundance, as in the subcutaneous tissue, especially of the abdomen; around the kidneys; on the surface of the heart between the furrows, and in some other situations. Lastly, fat enters largely into the formation of the marrow of bones. A distinction must be made between fat and adipose tissue; the latter being a distinct tissue, the former an oily matter, which in addition to forming adipose tissue is also widely present in the body, as in the fat of the brain and liver, and in the blood and chyle, &c.

FIG. 22.—Development of fat. (Klein and Noble Smith.)



a. Minute artery. v. Minute vein. c. Capillary blood-vessels in the course of formation; they are not yet completely hollowed out, there being still left in them protoplasmic septa. d. The ground-substance, containing numerous nucleated cells, some of which are more distinctly branched and flattened than others, and appear therefore more spindle-shaped.

Adipose tissue consists of small vesicles, *fat-cells*, lodged in the meshes of areolar tissue. The fat cells (fig. 21) vary in size, but are of about the average diameter of  $\frac{1}{500}$  of an inch. They are formed of an exceedingly delicate protoplasmic membrane, filled with fatty matter, which is liquid during life, but becomes solidified after death.

They are round or spherical where they have not been subjected to pressure; otherwise they assume a more or less angular outline. A nucleus is always present and can be easily demonstrated by staining with logwood; in the natural condition it is so compressed by the contained oily matter as to be scarcely recognisable. These fat-cells are contained in clusters in the areolæ of fine connective tissue, and are held together mainly by a network of capillary blood-vessels, which are distributed to them.


Fat is an inorganised substance, consisting of a liquid material (glycerine) in combination with certain fatty acids, stearic, palmitic, and oleic. Sometimes the acids separate spontaneously before the fat is examined, and are seen under the microscope in a crystalline form, as in fig. 21, *a*. By boiling the tissue in ether or strong alcohol, the fat may be extracted from the vesicle, which is then seen empty and shrunken.

Fat is said to be first detected in the human embryo about the fourteenth week. According to Klein, the fat-cells are formed by the transformation of the protoplasmic connective-tissue corpuscles, in which small globules of fat are deposited, and increase until they distend the corpuscle into the thin mantle of protoplasm which forms the cell-wall, and in which its nucleus is still to be seen (fig. 22). Others of the connective-tissue corpuscles are transformed into the vessels and the lymphatic tissue which accompanies the vessels.

PIGMENT

In various parts of the body **pigment** is found; most frequently in epithelial cells and in the cells of connective tissue. Pigmented epithelial cells are found forming the external layer of the retina (fig. 23) and on the posterior surface of the iris. Pigment is also found in the epithelial cells of the deeper layers of the cuticle in some parts of the body—such as the areola of the nipple and in coloured patches of skin and especially in the skin of the coloured races, and also in hair. It is also found in the epithelial cells of the olfactory region, and of the membranous labyrinth of the ear.

FIG. 23.—Pigment-cells of retina.



In the connective-tissue cells pigment is frequently met with in the lower vertebrates. In man it is found in the choroid coat of the eye, and in the iris of all but the light blue eyes and the albino. It is also occasionally met with in the cells of retiform tissue and in the pia mater of the upper part of the spinal cord. These cells are characterised by their larger size and branched processes, which, as well as the body of the cells, are filled with granules. The pigment consists of dark brown or black granules of very small size closely packed together within the cells, but not invading the nucleus. Occasionally the pigment is yellow, and when occurring in the cells of the cuticle constitutes 'freckles.'

CARTILAGE

**Cartilage** is a non-vascular structure which is found in various parts of the body—in adult life chiefly in the joints, in the parietes of the thorax, and in various tubes, such as the air-passages, nostrils, and ears, which are to be kept permanently open. In the fœtus at an early period the greater part of the skeleton is cartilaginous. As this cartilage is afterwards replaced by bone, it is called *temporary*, in contra-distinction to that which remains unossified during the whole of life, and which is called *permanent*.

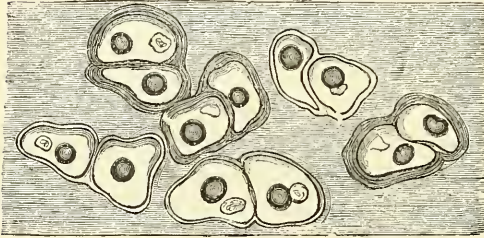
Cartilage is divided, according to its minute structure, into true or hyaline cartilage, fibrous or fibro-cartilage, and yellow or elastic or reticular cartilage. Besides these varieties met with in the adult human subject, there is a variety called *cellular cartilage*, which consists entirely, or almost entirely, of cells, united in some cases by a network of very fine fibres, in other cases apparently destitute of any intercellular substance. This is found in the external ear of rats, mice, and some other animals, and is present in the chorda dorsalis of the human embryo, but is not found in any other human structure. The various cartilages in the body are also classified, according to their function and position, into articular, interarticular, costal, and membraniform.

**Hyaline cartilage**, which may be taken as the type of this tissue, consists of a glistly mass of a firm consistence, but of considerable elasticity and of a pearly-



bluish colour. Except where it coats the articular ends of bones, it is covered externally by a fibrous membrane, the *perichondrium*, from the vessels of which it imbibes its nutritive fluids, being destitute of blood-vessels; nor have any nerves been traced into it. Its intimate structure is very simple. If a thin slice is examined under the microscope, it will be found to consist of cells of a rounded or bluntly angular form, lying in groups of two or more in a granular or almost homogeneous matrix (fig. 24). The cells, when arranged in groups of two or more, have generally a straight outline where they are in contact with each other,

FIG. 24.—Human cartilage-cells, from the ericoid cartilage. Magnified 350 times.



and in the rest of their circumference are rounded. The cell-contents consist of clear translucent protoplasm, containing fine interlacing filaments and minute granules, and embedded in this are one or two round nuclei, having usually a granular appearance, but occasionally being clear and occupied by one or more nucleoli. The cells are embedded in cavities in the matrix, called *cartilage lacunæ*, which are lined by a distinct transparent membrane termed the *capsule*. Each lacuna is generally occupied by a single cell, but during the division of the cells it may contain two, four, or eight cartilage-cells. By boiling the cartilage for some hours and treating it with concentrated mineral acid, the capsule may be freed from the matrix and can then be demonstrated as a distinct vesicle containing the cell or cells. By exposure to the action of an electric shock the cell assumes a jagged outline and shrinks away from the interior of the capsule.

The matrix is transparent and apparently without structure, or else presents a dimly granular appearance, like ground glass. Some observers have shown that the matrix of hyaline cartilage, and especially the articular variety, after prolonged maceration, can be broken up into fine fibrils. These fibrils are probably of the same nature, chemically, as the white fibres of connective tissue. It is believed by some histologists that the matrix is permeated by a number of fine channels, which connect the lacunæ with each other, and that these canals communicate with the lymphatics of the perichondrium, and thus the structure is permeated with a current of nutritious fluid.

Articular cartilage, costal cartilage, and temporary cartilage are all of the hyaline variety. They present minute differences in the size and shape of their cells and in the arrangement of their matrix. In **articular cartilage**, which shows no tendency to ossification, the matrix is finely granular under a high power; the cells and nuclei are small and are disposed parallel to the surface in the superficial part, while nearer to the bone they become vertical. Articular cartilages have a tendency to split in a vertical direction, probably from some peculiarity in the intimate structure or arrangement of the component parts of the matrix. In disease this tendency to a fibrous splitting becomes very manifest. Articular cartilage is not covered by perichondrium, on its free surface, where it is exposed to friction, though a layer of connective tissue can be traced in the adult over a small part of its circumference continuous with that of the synovial membrane, and here the cartilage-cells are more or less branched and pass insensibly into the branched connective-tissue corpuscles of the synovial membrane.

Articular cartilage forms a thin incrustation upon the joint-surfaces of the bones, and its elasticity enables it to break the force of any concussion, whilst its smoothness affords ease and freedom of movement. It varies in thickness according to the shape of the bone on which it lies; where this is convex the cartilage is thickest at the centre, where the greatest pressure is received; and the reverse is the case on the concave surfaces of the bones. Articular cartilage



appears to imbibe its nutriment partly from the vessels of the neighbouring synovial membrane, partly from those of the bone upon which it is implanted. Mr. Toynebee has shown that the minute vessels of the cancellous tissue as they approach the articular lamella dilate and form arches, and then return into the substance of the bone.

In **costal cartilage** the cells and nuclei are large, and the matrix has a tendency to fibrous striation, especially in old age (fig. 25). These cartilages are also very prone to ossify. In the thickest parts of the costal cartilages a few large vascular channels may be detected. This appears at first sight an exception to the statement that cartilage is a non-vascular tissue, but is not so really, for the vessels give no branches to the cartilage-substance itself, and the channels may rather be looked upon as involutions of the perichondrium. The ensiform cartilage may be regarded as one of the costal cartilages, and the cartilages of the nose and of the larynx and trachea resemble them in microscopical characters, except the epiglottis and cornicula laryngis, which are of the reticular variety.

**Temporary cartilage** and the process of its ossification will be described with bone.

The hyaline cartilages, especially in adult and advanced life, are prone to calcify—that is to say, to have their matrix permeated by the salts of lime without any appearance of true bone. The process of calcification occurs also and still more frequently, according to Rollett, in such cartilages as those of the trachea, which are prone afterwards to conversion into true bone.

**White fibro-cartilage** consists of a mixture of white fibrous tissue and cartilaginous tissue in various proportions; it is to the first of these two constituents that its flexibility and toughness are chiefly owing, and to the latter its elasticity. When examined under the microscope it is found to be made up of fibrous connective tissue arranged in bundles, with cartilage-cells between the bundles; these to a certain extent resemble tendon-cells, but may be distinguished from them by being surrounded by an investing capsule and by their being less flattened (fig. 26). The fibro-cartilages admit of arrangement into four groups—interarticular, connecting, circumferential, and stratiform.

1. The **interarticular fibro-cartilages** (*menisci*) are flattened fibro-cartilaginous plates, of a round, oval, triangular, or sickle-like form, interposed between the articular cartilages of certain joints. They are free on both surfaces, thinner

FIG. 25.—Costal cartilage from a man seventy-six years of age, showing the development of fibrous structure in the matrix. In several portions of the specimen two or three generations of cells are seen enclosed in a parent cell-wall. High power.

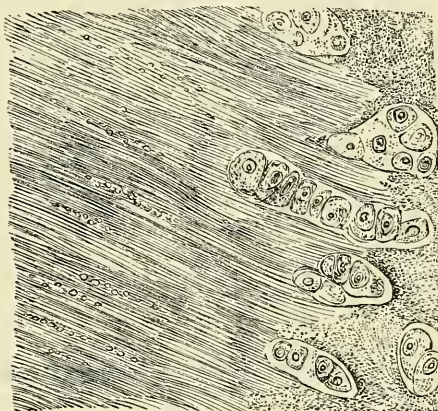
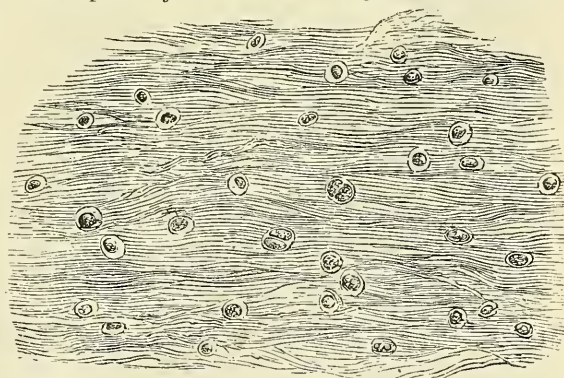


FIG. 26.—White fibro-cartilage from the semilunar disc of the patella joint of an ox. Magnified 100 times.



towards their centre than at their circumference, and held in position by their margins and extremities being connected to the surrounding ligaments. The synovial membrane of the joint is prolonged over them a short distance from their attached margins. They are found in the temporo-maxillary, sternoclavicular, acromio-clavicular, wrist and knee joints. These cartilages are usually found in those joints which are most exposed to violent concussion and subject to frequent movement. Their use is—to maintain the apposition of the opposed surfaces in their various motions; to increase the depth of the articular surfaces and give ease to the gliding movement; to moderate the effects of great pressure and deaden the intensity of the shocks to which the parts may be subjected. Humphry has pointed out that these interarticular fibro-cartilages serve an important purpose in increasing the variety of movements in a joint. Thus, in the knee-joint, there are two kinds of motion, viz. angular movement and rotation, although it is a hinge joint, in which, as a rule, only one variety of motion is permitted; the former movement takes place between the condyles of the femur and the interarticular cartilage, the latter between the cartilage and the head of the tibia. So, also, in the temporo-maxillary joint, the upward and downward movement of opening and shutting the mouth takes place between the cartilage and the jaw-bone, the grinding movement between the glenoid cavity and the cartilage, the latter moving with the jaw-bone.

2. The **connecting fibro-cartilages** are interposed between the bony surfaces of those joints which admit of only slight mobility, as between the bodies of the vertebræ and between the pubic bones. They form discs, which adhere closely to both of the opposed surfaces, and are composed of concentric rings of fibrous tissue, with cartilaginous laminae interposed, the former tissue predominating towards the circumference, the latter towards the centre.

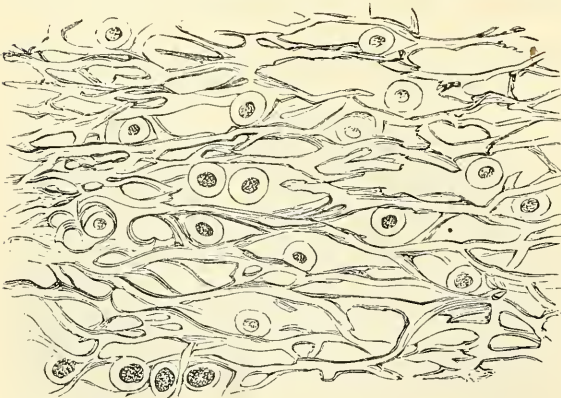
3. The **circumferential fibro-cartilages** consist of a rim of fibro-cartilage, which surrounds the margin of some of the articular cavities, as the cotyloid cavity of the hip, and the glenoid cavity of the shoulder; they serve to deepen the articular surface, and to protect the edges of the bone.

4. The **stratiform fibro-cartilages** are those which form a thin coating to osseous grooves through which the tendons of certain muscles glide. Small masses of fibro-cartilages are also developed in the tendons of some muscles,

where they glide over bones, as in the tendons of the peroneus longus and the tibialis posticus.

**Yellow, or reticular, elastic cartilage** is found in the human body in the auricle of the external ear, the Eustachian tubes, the cornicula laryngis, and the epiglottis. It consists of cartilage-cells and a matrix, the latter being pervaded in every direction, except immediately around each cell, by a network of yellow elastic fibres, branching and anastomosing

FIG. 27.—Yellow cartilage, ear of horse. High power.



in all directions (fig. 27). The fibres resemble those of yellow elastic tissue, both in appearance and in being unaffected by acetic acid; and according to Rollett their continuity with the elastic fibres of the neighbouring tissue admits of being demonstrated.

The distinguishing feature of cartilage as to its chemical composition, is that it yields on boiling a substance called *chondrin*, very similar to gelatin, but differing from it in not being precipitated by tannin. According to Kühne there



is a small amount of gelatin in hyaline cartilage. Virchow believes that the semilunar discs in the knee-joint are wrongly denominated cartilages, since they yield no chondrin on boiling; and he appears to regard them as a modification of a tendinous structure, which, however, agrees with the cartilages in the important particular of being non-vascular.

## BONE

**Structure and Physical Properties of Bone.**—Bone is one of the hardest structures of the animal body; it possesses also a certain degree of toughness and elasticity. Its colour, in a fresh state, is of a pinkish white externally, and deep red within. On examining a section of any bone, it is seen to be composed of two kinds of tissue, one of which is dense in texture, like ivory, and is termed *compact tissue*; the other consists of slender fibres and lamellæ, which join to form a reticular structure; this, from its resemblance to lattice-work, is called *cancellous*. The compact tissue is always placed on the exterior of the bone; the cancellous is always internal. The relative quantity of these two kinds of tissue varies in different bones, and in different parts of the same bone, as strength or lightness is requisite. Close examination of the compact tissue shows it to be extremely porous, so that the difference in structure between it and the cancellous tissue depends merely upon the different amount of solid matter, and the size and number of spaces in each; the cavities being small in the compact tissue and the solid matter between them abundant, whilst in the cancellous tissue the spaces are large and the solid matter in smaller quantity. There is, moreover, no abrupt limit between the two, but the one tissue gradually merges into the other.

Bone during life is permeated by vessels and is enclosed in a fibrous membrane, the *periosteum*, by means of which many of these vessels reach the hard tissue. If the periosteum is stripped from the surface of the living bone small bleeding points are seen, which mark the entrance of the periosteal vessels; and on section during life, every part of the bone will be seen to exude blood from the minute vessels which ramify in it. The interior of the bones of the limbs presents a cylindrical cavity filled with marrow and lined by a highly vascular areolar structure, called the *medullary membrane* or *internal periosteum*, which, however, is rather the areolar envelope of the cells of the marrow, than a definite membrane.

The **periosteum** adheres to the surface of the bones in nearly every part, excepting at their cartilaginous extremities. Where strong tendons or ligaments are attached to the bone, the periosteum is incorporated with them. It consists of two layers closely united together, the outer one formed chiefly of connective tissue, containing occasionally a few fat-cells; the inner one, of elastic fibres of the finer kind, forming dense membranous networks, which can be again separated into several layers. In young bones the periosteum is thick and very vascular, and is intimately connected at either end of the bone with the epiphyseal cartilage, but less closely with the shaft, from which it is separated by a layer of soft blastema, containing a number of granular corpuscles or 'osteoblasts,' in which ossification proceeds on the exterior of the young bone. Later in life the periosteum is thinner, less vascular, and the osteoblasts have become converted into an epithelial layer, which is separated from the rest of the periosteum in many places by cleft-like spaces, which are supposed to serve for the transmission of lymph. The periosteum serves as a nidus for the ramification of the vessels previous to their distribution in the bone; hence the liability of bone to exfoliation or necrosis, when denuded of this membrane by injury or disease. Fine nerves and lymphatics, which generally accompany the arteries, may also be demonstrated in the periosteum.

The **marrow** not only fills up the cylindrical cavity in the shafts of the long bones, but also occupies the spaces of the cancellous tissue and extends into the

larger bony canals (Haversian canals) which contain the blood-vessels. It differs in composition in different bones. In the shafts of adult long bones the marrow is of a *yellow* colour, and contains, in 100 parts, 96 of fat, 1 of areolar tissue and vessels, and 3 of fluid, with extractive matter, and consists of a matrix of retiform connective tissue, supporting numerous blood-vessels and cells, most of which are fat-cells, but some few are 'marrow-cells.' In the flat and short bones, in the articular ends of the long bones, in the bodies of the vertebræ, in the cranial diploë, and in the sternum and ribs, it is of a *red* colour, and contains, in 100 parts, 75 of water and 25 of solid matter, consisting of albumen, fibrin, extractive matter, salts, and a mere trace of fat. The red marrow consists of a small quantity of areolar tissue, blood-vessels, and numerous cells, some few of which are fat-cells, but the great majority roundish nucleated cells, the true 'marrow-cells' of Kölliker. These marrow-cells resemble in appearance the white corpuscles of the blood, though they are larger and have a relatively larger nucleus and a clearer protoplasm, but, like them, possess amœboid movements. Amongst them may be seen smaller cells, which possess a slightly pinkish hue; and it has been stated by Neumann that they are then in a transitional stage between marrow-cells and red blood-corpuscles, and that one of the principal sources of blood-globules is the marrow of the spongy bones.

*Giant-cells* (*myelo-plaques*, *osteoclasts*), large, multi-nucleated, protoplasmic masses, are also to be found in both sorts of adult marrow, but more particularly in red marrow. They were believed by Kölliker to be concerned in the absorption of bone-matrix, and hence the name which he gave to them—*osteoclasts*. They excavate small shallow pits or cavities, which are named *Howship's lacunæ*, in which they are found lying.

**Vessels of Bone.**—The blood-vessels of bone are very numerous. Those of the compact tissue are derived from a close and dense network of vessels ramifying in the periosteum. From this membrane, vessels pass into the minute orifices in the compact tissue, and run through the canals which traverse its substance. The cancellous tissue is supplied in a similar way, but by a less numerous set of larger vessels, which, perforating the outer compact tissue, are distributed to the cavities of the spongy portion of the bone. In the long bones, numerous apertures may be seen at the ends near the articular surfaces, some of which give passage to the arteries of the larger set of vessels referred to; but the most numerous and largest apertures are for the veins of the cancellous tissue, which run separately from the arteries. The medullary canal in the shafts of the long bones is supplied by one large artery (or sometimes more), which enters the bone at the nutrient foramen (situated in most cases near the centre of the shaft), and perforates obliquely the compact structure. The *medullary* or *nutrient* artery, usually accompanied by one or two veins, sends branches upwards and downwards, to supply the medullary membrane, which lines the central cavity and the adjoining canals. The ramifications of this vessel anastomose with the arteries both of the cancellous and compact tissues.\* In most of the flat, and in many of the short spongy bones, one or more large apertures are observed, which transmit, to the central parts of the bone, vessels corresponding to the medullary arteries and veins. The veins emerge from the long bones in three places (Kölliker)—(1) by one or two large veins, which accompany the artery; (2) by numerous large and small veins at the articular extremities; (3) by many small veins which arise in the compact substance. In the flat cranial bones the veins are large, very numerous, and run in tortuous canals in

\* This view is not, however, entertained by all anatomists. Mr. Charles Stewart believes that, in many cases at all events, the vessels of the periosteum supply only the circumferential lamellæ on the surface of the shaft of the bone, which are formed from this membrane, and that the whole of the rest of its structure is supplied by the vessels of the medullary membrane, and that only very exceptionally does any anastomosis take place between the two sets of vessels. Certainly, in one microscopic section which I had an opportunity of examining, through the kindness of Mr. Stewart, this appeared to be the case.



the diploic tissue, the sides of the canals being formed by a thin lamella of bone, perforated here and there for the passage of branches from the adjacent cancelli. The same condition is also found in all cancellous tissue, the veins being enclosed and supported by osseous structure, and having exceedingly thin coats. When the bony structure is divided, the vessels remain patulous, and do not contract in the canals in which they are contained. Hence the occurrence of purulent absorption after amputation, in those cases where the stump becomes inflamed, and the cancellous tissue is infiltrated and bathed in pus.

**Lymphatic vessels**, in addition to those found in the periosteum, have been traced, by Cruikshank, into the substance of bone, and Klein describes them as running in the Haversian canals.

**Nerves** are distributed freely to the periosteum, and accompany the nutrient arteries into the interior of the bone. They are said by Kölliker to be most numerous in the articular extremities of the long bones, in the vertebræ and the larger flat bones.

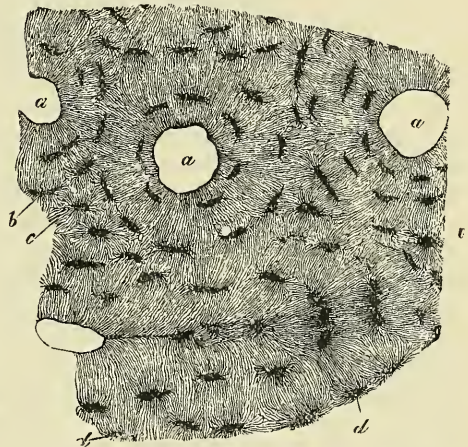
**Minute Anatomy.**—The intimate structure of bone, which in all essential particulars is identical in the compact and cancellous tissue, is most easily studied in a transverse section from the compact wall of one of the long bones after maceration, such as is shown in fig. 28.

If this is examined with a rather low power the bone will be seen to be mapped out into a number of circular districts: each one of which consists of a central hole surrounded by a number of concentric rings. These districts are termed *Haversian systems*; the central hole is an *Haversian canal*, and the rings around are layers of bone-tissue arranged concentrically around the central canal, and termed *lamellæ*. Moreover, on closer examination, it will be found that between these lamellæ, and therefore also arranged concentrically around the central canal, are a number of little dark specks, the *lacunæ*, and that these lacunæ are connected with each other and with the central

Haversian canal by a number of fine dark lines, which radiate like the spokes of a wheel and are called *canaliculi*. All these structures—the concentric lamellæ, the lacunæ, and the canaliculi—may be seen in any single Haversian system, forming a circular district round a central, Haversian, canal. Between these circular systems, filling in the irregular intervals which are left between them, are other lamellæ, with their lacunæ and canaliculi, running in various directions, but more or less curved (fig. 29). These are termed *interstitial lamellæ*. Again, other lamellæ, for the most part found on the surface of the bone, are arranged concentrically to the circumference of bone, constituting, as it were, a single Haversian system of the whole bone, of which the medullary cavity would represent the Haversian canal. These latter lamellæ are termed *circumferential*, or by some authors *primary* or *fundamental lamellæ*, to distinguish them from those laid down around the axis of the Haversian canals, which are then termed *secondary* or *special lamellæ*.

The *Haversian canals*, seen as round holes in a transverse section of bone at or about the centre of each Haversian system, may be demonstrated to be true canals, if a longitudinal section is made, as in fig. 31. It will then be seen that

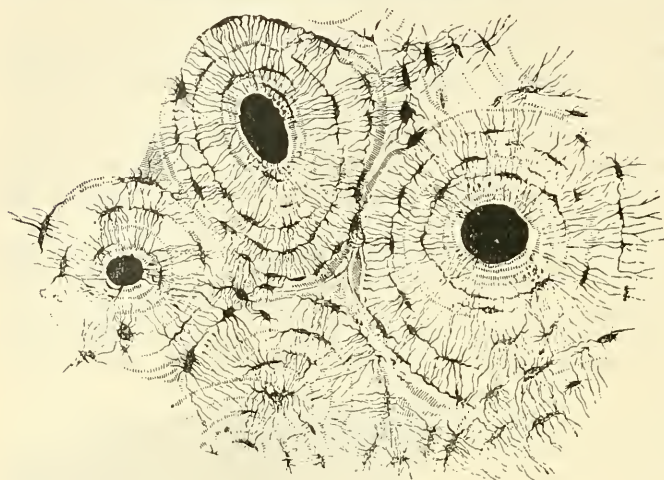FIG. 28.—From a transverse section of the diaphysis of the humerus. Magnified 350 times.



a. Haversian canals. b. Lacunæ, with their canaliculi in the lamellæ of these canals. c. Lacunæ, of the interstitial lamellæ. d. Others at the surface of the Haversian systems, with canaliculi given off from one side.

these round holes are tubes cut across, which run parallel with the longitudinal axis of the bone for a short distance, and then branch and communicate. They vary considerably in size, some being as large as  $\frac{1}{20}$  of an inch in diameter; the average size being, however, about  $\frac{1}{50}$  of an inch. Near the medullary cavity

FIG. 29.—Transverse section of compact tissue of bone. Magnified about 150 diameters. (Sharpey.)

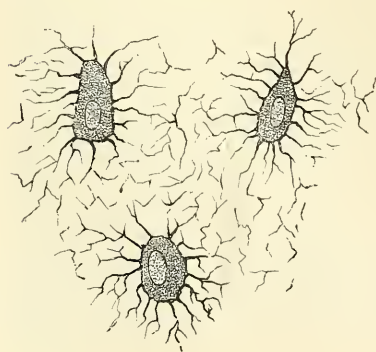


the canals are larger than those near the surface of the bone. Each canal, as a rule, contains two blood-vessels, a small artery and vein; the larger ones also contain a small quantity of delicate connective tissue, with branched cells, the processes of which communicate with the branched processes of certain bone-cells in the substance of the bone. Those canals near the surface of the bone open upon it

by minute orifices, and those near the medullary cavity open in the same way into this space, so that the whole of the bone is permeated by a system of blood-vessels running through the bony canals in the centre of the Haversian systems.

The *lamellæ* are thin plates of bone-tissue encircling the central canal, and might be compared, for the sake of illustration, to a number of sheets of paper pasted one over another around a central hollow cylinder. After macerating a piece of bone in dilute mineral acid, these lamellæ may be stripped off in a longitudinal direction as thin films. If one of these is examined with a high power under the microscope it will be found to be composed of a finely reticular structure, presenting the appearance of lattice-work made up of very slender, trans-

FIG. 30.—Nucleated bone-cells and their processes, contained in the bone-lacunæ and their canaliculi respectively. From a section through the vertebra of an adult mouse. (Klein and Noble Smith.)



parent fibres, decussating obliquely, and coalescing at the points of intersection so as to form an exceedingly delicate network. In many places the various lamellæ may be seen to be held together by tapering fibres, which run obliquely through them, pinning or bolting them together. These fibres were first described by Sharpey, and were named by him *perforating fibres*.

The *lacunæ* are situated between the lamellæ, and consist of a number of oblong spaces. In an ordinary microscopic section, viewed by transmitted light, they appear as dark, oblong, opaque spots, and were formerly believed to be solid cells. Subsequently, when it was seen that the Haversian canals were channels which lodge the vessels of the part, and the canaliculi minute tubes by which the plasma of the blood circulates through the tissue, it was

taught that the lacunæ were hollow spaces filled during life with the same fluid, and only lined (if lined at all) by a delicate membrane. But this view appears



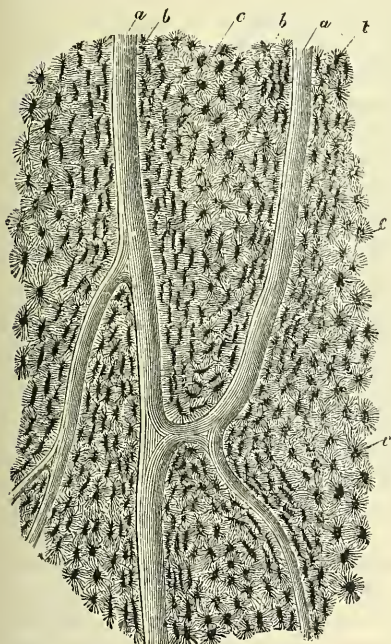
also to be delusive. Examination of the structure of bone, when recent, led Virchow to believe that the lacunæ are occupied during life by a nucleated cell, the processes from which pass down the canaliculi—a view which is now universally received (fig. 30). It is by means of these cells that the fluids necessary for nutrition are brought into contact with the ultimate tissue of bone.

The *canaliculi* are exceedingly minute channels, which pass *across* the lamellæ and connect the lacunæ with neighbouring lacunæ and also with the Haversian canal. From this central canal a number of the canaliculi are given off, which radiate from it, and open into the first set of lacunæ arranged around the Haversian canal, between the first and second lamellæ. From these lacunæ a second set of canaliculi are given off, which pass outwards to the next series of lacunæ, and so on until they reach the periphery of the Haversian system; here the canaliculi given off from the last series of lacunæ do not communicate with the lacunæ of neighbouring Haversian systems, but after passing outwards for a short distance form loops and return to their own lacuna. Thus every part of an Haversian system is supplied with nutrient fluids derived from the vessels in the Haversian canal and traversing the canaliculi and lacunæ.

The *bone-cells* are contained in the lacunæ, which, however, they do not completely fill. They are flattened nucleated cells, which Virchow has shown are homologous with those of connective tissue. The cells are branched, and the branches, especially in young bones, pass into the canaliculi from the lacunæ.

If a longitudinal section is examined, as in fig. 31, the structure is seen to be the same. The appearance of concentric rings is replaced by that of lamellæ or

FIG. 31.—Section parallel to the surface from the shaft of the femur. Magnified 100 times.

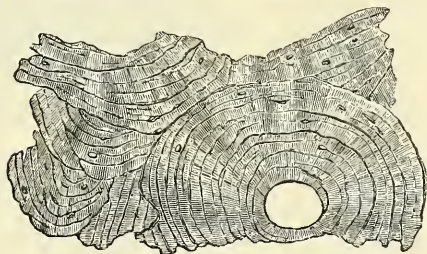


a. Haversian canals. b. Lacunæ seen from the side.  
c. Others seen from the surface in lamellæ which are cut horizontally.

rows of lacunæ, parallel to the course of the Haversian canals, and these canals appear like half-tubes instead of circular spaces. The tubes are seen to branch and communicate, so that each separate Haversian canal runs only a short distance. In other respects the structure has much the same appearance as in transverse sections.

In sections of thin plates of bone (as in the walls of the cells which form the cancellous tissue) the Haversian canals are absent and the canaliculi open into the spaces of the cancellous tissue (medullary

FIG. 32.—Section of bone after the removal of the earthy matter by the action of acids.



spaces), which thus have the same function as the Haversian canals in the more compact bone.

**Chemical Composition.**—Bone consists of an animal and an earthy part intimately combined together.

The animal part may be obtained by immersing the bone for a considerable

time in dilute mineral acid, after which process the bone comes out exactly the same shape as before, but perfectly flexible, so that a long bone (one of the ribs, for example) can easily be tied in a knot. If now a transverse section is made (fig. 32) the same general arrangement of the Haversian canals, lamellæ, lacunæ, and canaliculi is seen, though not so plainly as in the ordinary section.

The earthy part may be obtained separate by calcination, by which the animal matter is completely burnt out. The bone will still retain its original form, but it will be white and brittle, will have lost about one-third of its original weight, and will crumble down with the slightest force. The earthy matter confers on bone its hardness and rigidity, and the animal matter its tenacity.

The animal base is often called cartilage, but differs from it in structure, in the fact that it is softer and more flexible, and that when boiled with a high pressure it is almost entirely resolved into gelatin.

The organic constituent of bone forms about *one-third*, or 33·3 per cent.; the inorganic matter, *two-thirds*, or 66·7 per cent.; as is seen in the subjoined analysis of Berzelius:—

Organic matter . . .	Gelatin and blood-vessels . . .	33·30
	Phosphate of lime . . .	51·04
Inorganic	Carbonate of lime . . .	11·30
or	Fluoride of calcium . . .	2·00
Earthy matter . . .	Phosphate of magnesia . . .	1·16
	Soda and chloride of sodium . . .	1·20
		100·00

Some chemists add to this about 1 per cent. of fat.

Some difference exists in the proportion between the two constituents of bone at different periods of life. In the child the animal matter predominates, whereas in aged people the bones contain a larger proportion of earthy matter, and the animal matter is deficient in quantity and quality. Hence in children it is not uncommon to find, after an injury to the bones, that they become bent or only partially broken, whereas in old people the bones are more brittle and fracture takes place more readily. Some of the diseases, also, to which bones are liable mainly depend on the disproportion between the two constituents of bone. Thus in the disease called rickets, so common in the children of the poor, the bones become bent and curved, either from the superincumbent weight of the body, or under the action of certain muscles. This depends upon some defect of nutrition by which bone becomes deprived of its normal proportion of earthy matter, whilst the animal matter is of unhealthy quality. In the vertebræ of a rickety subject, Dr. Bostock found in 100 parts 79·75 animal and 20·25 earthy matter.

**Development of Bone.**—In the foetal skeleton some bones, such as the long bones of the limbs, are cartilaginous; others, as the cranial bones, are membranous. Hence two kinds of ossification are described: the *intracartilaginous* and the *intramembranous*; and to these a third is sometimes added, the *subperiosteal*; this, however, is the same as the second, only taking place under different circumstances.

**Intracartilaginous Ossification.**—Just before ossification begins the bone is entirely cartilaginous, and in a long bone, which may be taken as an example, the process commences in the centre and proceeds towards the extremities, which for some time remain cartilaginous. Subsequently a similar process commences in one or more places in those extremities and gradually extends through it. The extremity does not, however, become joined to the shaft of the bone until growth has ceased, but remains separated by a layer of cartilaginous tissue termed *epiphysial cartilage*.

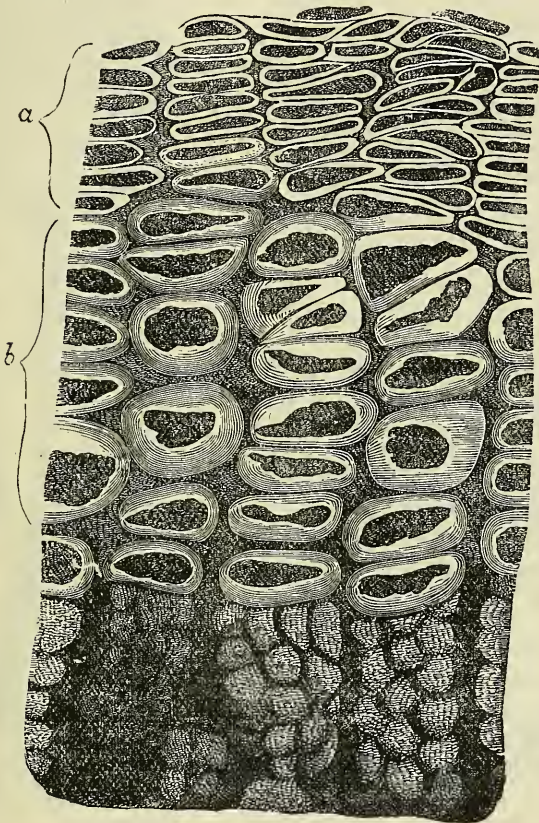
The first step in the ossification of the cartilage is that the cartilage-cells, at the point where ossification is commencing and which is termed a *centre of ossification*, enlarge and arrange themselves in rows (fig. 33). The matrix in which they are embedded increases in quantity, so that the cells become further separated from each other. A deposit of calcareous material now takes place in



this matrix, between the rows of cells, so that they become separated from each other by longitudinal columns of calcified matrix, presenting a granular and opaque appearance. Here and there the matrix between two cells of the same row also becomes calcified, and thus we have transverse bars of calcified substance stretching across from one calcareous column to another. Thus we have longitudinal groups of the cartilage-cells enclosed in oblong cavities, the walls of which are formed of calcified matrix. These cavities are called the *primary areolæ* (Sharpey).

At the same time that this process is going on in the centre of the cartilage of which the foetal bone consists, certain changes are taking place on its surface. This is covered by a very vascular membrane, the *perichondrium*, on the inner surface of which, that is to say, on the surface in contact with the cartilage, are a number of cells called *osteoblasts*. By the agency of these cells a thin layer of bony

FIG. 33.—Longitudinal section through the ossifying portion of a long bone in the human embryo.

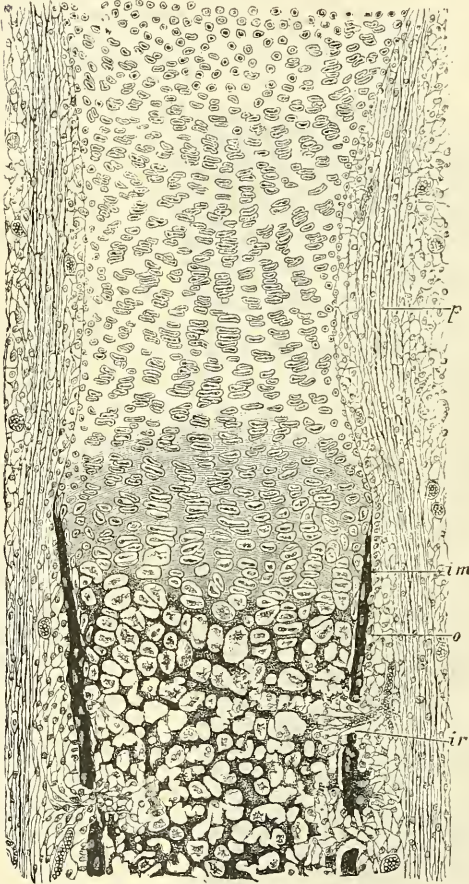


a Cartilaginous region. b. Region of calcified matrix.

tissue is being formed between the perichondrium and the cartilage, by the *intramembranous* mode of ossification presently to be described. We have then, in this first stage of ossification, two processes going on simultaneously: in the centre of the cartilage the formation of a number of oblong spaces, formed of calcified matrix and containing the cartilage-cells enlarged and arranged in groups, and on the surface of the cartilage the formation of a layer of true membrane-bone. The second stage consists in the prolongation into the cartilage of processes of the deeper or osteogenetic layer of the perichondrium, which has now become periosteum (fig. 34, *ir*). The processes consist of blood-vessels and cells (osteoblasts). They excavate passages through the new-formed bony layer by absorption, and pass through it into the calcified matrix (fig. 34). Wherever

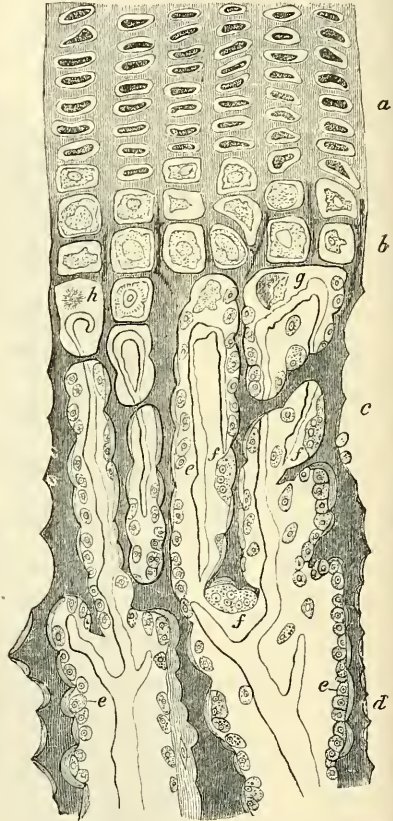
these processes come in contact with the calcified walls of the primary areolæ they absorb it, and thus cause a fusion of the original cavities and the formation of larger spaces, which are termed the *secondary areolæ* (Sharpey) or *medullary spaces* (Müller). In these secondary spaces the original cartilage-cells disappear, and their cavities become filled with embryonic marrow, consisting of osteoblasts and vessels, and derived, at all events in part, in the manner described above, from the osteogenetic layer of the periosteum (fig. 35). What becomes of the cartilage-cells is not finally determined. By most histologists they are believed to be converted, after division, into osteoblasts,

FIG. 34.—Section of foetal bone of cat.



*ir.* Irruption of the subperiosteal tissue. *p.* Fibrous layer of the periosteum. *o.* Layer of osteoblasts. *im.* Subperiosteal bony deposit. (From Quain's 'Anatomy,' E. A. Schäfer.)

FIG. 35.—Part of a longitudinal section of the developing femur of a rabbit.



*a.* Flattened cartilage-cells. *b.* Enlarged cartilage-cells. *c, d.* Newly formed bone. *e.* Osteoblasts. *f.* Giant-cells or osteoclasts. *g, h.* Shrunken cartilage-cells. (From 'Atlas of Histology,' Klein and Noble Smith.)

and so assist in forming the embryonic marrow. Others, on the other hand, believe that they are simply absorbed and take no part in the formation of bone.

Thus far, then, we have got enlarged spaces (secondary areolæ), the walls of which are still formed by calcified cartilage-matrix, containing an embryonic marrow, derived from the processes sent in from the osteogenetic layer of the periosteum, and consisting of blood-vessels and round cells, osteoblasts (fig. 35), some of which probably are derived from the division of the original cartilage-cells, which have disappeared. The walls of these secondary areolæ are at this time of only inconsiderable thickness, but they now become thickened by the deposition of layers of new bone on their interior. This process takes place in the following manner. Some of the osteoblasts of the embryonic marrow, after



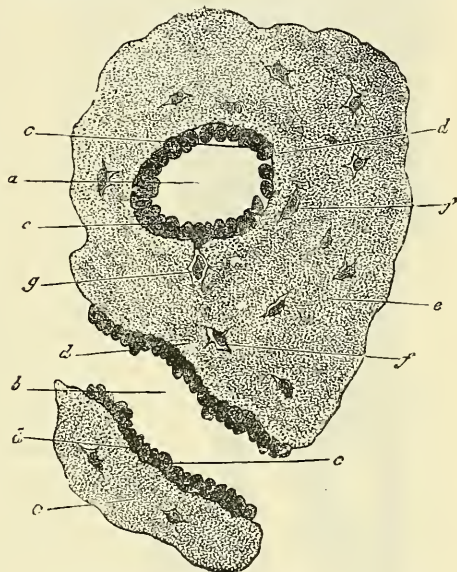
undergoing rapid division, arrange themselves as an epithelioid layer on the surface of the wall of the space (fig. 36). This layer of osteoblasts forms a bony stratum, and thus the wall of the space becomes gradually covered with a layer of true osseous substance. On this a second layer of osteoblasts arrange themselves, and in their turn form an osseous layer. By the repetition of this process the original cavity becomes very much reduced in size, and at last only remains as a small circular hole in the centre, containing the remains of the embryonic marrow—that is, a blood-vessel and a few osteoblasts. This small cavity constitutes the Haversian canal of the perfectly ossified bone. The successive layers of osseous matter which have been laid down and which encircle this central canal, constitute the lamellæ of which, as we have seen, each Haversian system is made up. As the successive layers of osteoblasts form osseous tissue, certain of the osteoblastic cells remain included between the various bony layers. These continue persistent and remain as the corpuscles of the future bone, the spaces enclosing them forming the lacunæ (fig. 36). The mode of the formation of the canaliculi is not known.

Such are the changes which may be observed at one particular point, the centre of ossification. While they have been going on here a similar process has been proceeding in the same manner towards the end of the shaft, so that in the ossifying bone all the changes described above may be seen in different parts, from the true bone in the centre of the shaft to the hyaline cartilage at the extremities. The bone thus formed differs from the bone of the adult in being more spongy and less regularly lamellated.

Thus far, then, we have followed the steps of a process by which a solid bony mass is produced, having vessels running into it from the periosteum, Haversian canals in which those vessels run, medullary spaces filled with fœtal marrow, lacunæ with their contained bone-cells, and canaliculi growing out of these lacunæ.

This process of ossification, however, is not the origin of the whole of the skeleton, for even in those bones in which the ossification proceeds in a great measure from a single centre, situated in the cartilaginous shaft of a long bone, a considerable part of the original bone is formed by intramembranous ossification beneath the perichondrium or periosteum; so that the girth of the bone is increased by bony deposit from the deeper layer of this membrane. The shaft of the bone is at first solid, but a tube is hollowed out in it by absorption around the vessels passing into it, which becomes the medullary canal. This absorption is supposed to be brought about by large 'giant-cells,' which have long been recognised as a constituent of fœtal marrow, and which are believed by Kölliker to have the power of absorbing or dissolving bone, and he has therefore named them 'osteoclasts' (fig. 35, *f*). They vary in shape and size, and are known by containing a large number of clear nuclei, sometimes as many as twenty. The occurrence of similar cells in some tumours of bones has led to such tumours being denominated 'myeloid.'

FIG. 36.—Transverse section from the femur of a human embryo about eleven weeks old.

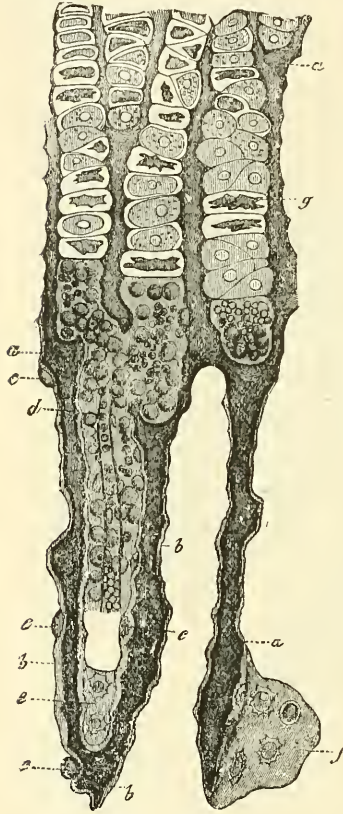


*a.* A medullary sinus cut transversely; and *b.* another longitudinally. *c.* Osteoblasts. *d.* Newly formed osseous substance of a lighter colour. *e.* That of greater age. *f.* Lacunæ with their cells. *g.* A cell still united to an osteoblast.



As more and more bone is removed by this process of absorption from the interior of the bone to form the medullary canal, so more and more bone is deposited on the exterior from the periosteum, until at length it has attained the shape and size which it is destined to retain during adult life.

FIG. 37.—Vertical section from the edge of the ossifying portion of the diaphysis of a metatarsal bone from a foetal calf. (After Müller.)



a. Ground-mass of the cartilage. b. Of the bone. c. Newly formed bone-cells in profile, more or less embedded in intercellular substance. d. Medullary canal in process of formation, with vessels and medullary cells. e, f. Bone-cells on their broad aspect. g. Cartilage-capsules arranged in rows, and partly with shrunken cell-bodies.

As the ossification of the cartilaginous shaft extends towards the articular ends it carries with it, as it were, a layer of cartilage, or the cartilage grows as it ossifies, and thus the bone is increased in length. During this period of growth the articular end, or epiphysis, remains for some time entirely cartilaginous, then a bony centre appears in it, and it commences the same process of intracartilaginous ossification; but this process never extends to any great distance. The epiphyses remain separated from the shaft by a narrow cartilaginous layer for a definite time. This layer ultimately ossifies, the distinction between shaft and epiphysis is obliterated, and the bone assumes its completed form and shape. The same remarks also apply to the processes of bone which are separately ossified, such as the trochanters of the femur. The bones, having been formed, continue to grow until the body has acquired its full stature. They increase in length by ossification continuing to extend in the epiphysial cartilage, which goes on growing in advance of the ossifying process. They increase in circumference by deposition of new bone, from the deeper layer of the periosteum, on their external surface, and at the same time an absorption takes place from within, by which the medullary cavity is increased.

The medullary spaces which characterise the cancellous tissue are produced by the absorption of the original foetal bone in the same way as the original medullary canal is formed. The distinction between the cancellous and compact tissue appears to depend essentially upon the extent to which this process of absorption has been carried; and we may perhaps remind the reader that in morbid states of the bone inflammatory absorption produces exactly the same change, and converts portions of bone, naturally compact, into cancellous tissue.

**Intramembranous Ossification.**—The intramembranous ossification is that by which the bones of the vertex of the skull are entirely formed. In the bones which are so developed, no cartilaginous mould precedes the appearance of the bone-tissue. In the membrane which occupies the place of the future bone, a little network of bony spiculæ is first noticed, radiating from the point of ossification. When these rays of growing bone are examined by the microscope, they are found to consist of a network of fine clear fibres and granular corpuscles, with a ground-substance between. The fibres are termed *osteogenic* fibres, and soon become dark and granular from calcification, and as they calcify they are found to enclose the granular corpuscles or 'osteoblasts' (fig. 38). The calcification not only involves the osteogenic fibres, but also the ground-substance of the tissue in which they are contained. The corpuscles at first lie upon the osteogenic fibres, so that they can be removed

by brushing the specimen with a hair-pencil, in order to render the fibres clear; but they gradually become involved in the ossifying matrix, and form the corpuscles of the future bone, the spaces in which they are enclosed constituting the lacunæ. As the tissue increases in thickness, vessels shoot into it, grooving for themselves spaces or channels, which become the Haversian canals. Thus, the intramembranous and intracartilaginous processes of ossification are similar in their more essential features.

The number of ossific centres is different in different bones. In most of the short bones ossification commences by a single point in the centre, and proceeds towards the circumference. In the long bones there is a central point of ossification for the shaft or diaphysis: and one or more for each extremity, the epiphysis. That for the shaft is the first to appear. The union of the epiphyses with the shaft takes place in the reverse order to that in which their ossi-

fication began, and appears to be regulated by the direction of the nutrient artery of the bone. Thus, the nutrient arteries of the bones of the arm and fore-arm are directed towards the elbow, and the epiphyses of the bones forming this joint become united to the shaft before those at the opposite extremity. In the lower limb, on the other hand, the nutrient arteries pass in a direction from the knee: that is, upwards in the femur, downwards in the tibia and fibula; and in them it is observed that the upper epiphysis of the femur, and the lower epiphysis of the tibia and fibula, become first united to the shaft.

Where there is only one epiphysis, the medullary artery is directed towards that end of the bone where there is no additional centre; as towards the acromial end of the clavicle, towards the distal end of the metacarpal bone of the thumb and great toe, and towards the proximal end of the other metacarpal and metatarsal bones.

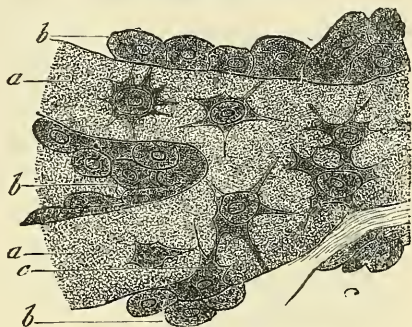
Besides these epiphyses for the articular ends, there are others for projecting parts or processes, which are formed separately from the bulk of the bone. For an account of these, the reader must be referred to the description of the individual bones in the sequel.

A knowledge of the exact periods when the epiphyses become joined to the shaft is often of great importance in medico-legal inquiries. It also aids the surgeon in the diagnosis of many of the injuries to which the joints are liable; for it not infrequently happens that, on the application of severe force to a joint, the epiphysis becomes separated from the shaft, and such injuries may be mistaken for fracture or dislocation.

## MUSCULAR TISSUE

The **muscles** are formed of bundles of reddish fibres, endowed with the property of contractility. Two kinds of muscular tissue are found in the body, viz. that of voluntary or animal life, and that of involuntary or organic life. The former of these, from the characteristic appearances which their fibres exhibit under the microscope, are known as the 'striped' muscles, and from the fact that they are capable of being put into action and controlled by the will, as the 'voluntary' muscles. The fibres of the latter do not present any cross-striped appearance, and for the most part are not under the control of the will; hence they are known as the 'unstriped' or 'involuntary' muscles. The muscular fibres of the heart

FIG. 38.—Osteoblasts from the parietal bone of a human embryo thirteen weeks old. (After Gegenbauer.)



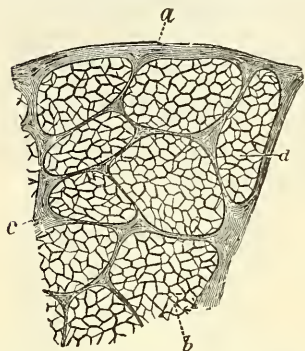
*a.* Bony septa with the cells of the lacunæ. *b.* Layers of osteoblasts. *c.* The latter in transition to bone-corpuscles.



differ in certain particulars from both these groups, and they are therefore separately described as 'cardiac' muscular fibres.

The **striped** or **voluntary muscles** are composed of bundles of fibres enclosed in a delicate web called the 'internal perimysium,' in contradistinction to the sheath of areolar tissue which invests the entire muscle, the 'epimysium' or 'external perimysium.' The bundles are termed 'fasciculi'; they are prismatic in shape, of different sizes in different muscles, and for the most part placed parallel to one another, though they have a tendency to converge towards their

FIG. 39.—Transverse section from the sterno-mastoid in man. Magnified 50 times.



a. External perimysium. b. Fasciculus.  
c. Internal perimysium. d. Fibre.

tendinous attachments. Each fasciculus is made up of a bundle of *fibres*, which also run parallel with each other, and which are separated from one another by a delicate connective tissue derived from the perimysium, and termed *endomysium* (fig. 39). This does not form the sheath of the fibres, but serves to support the blood-vessels and nerves ramifying between them. The fibres are enclosed in a separate and distinct sheath of their own, but it is not areolar tissue and is therefore not derived from the perimysium.

A *muscular fibre* may be said to consist of a soft contractile substance enclosed in a tubular sheath, named by Bowman the *sarcolemma*. The fibres are cylindrical or prismatic in shape, and are of no great length, not exceeding, it is said, an inch and a half. They end either by blending with the tendon or aponeurosis, or else by becoming drawn out into a tapering extremity which is connected to the neighbouring fibre by means of the sarcolemma. Their breadth varies in man from  $\frac{1}{200}$  to  $\frac{1}{600}$  of an inch, the average of the majority being about  $\frac{1}{400}$ . As a rule, the fibres do not divide or anastomose; but occasionally, especially in the tongue and facial muscles, the fibres may be seen to divide into several branches. The precise mode in which the muscular fibre joins the tendon has been variously described by different observers. It may, perhaps, be sufficient to say that the sarcolemma, or membranous investment of the muscular fibre, appears to become blended with a small bundle of fibres, into which the tendon becomes subdivided, while the muscular substance terminates abruptly and can be readily made to retract from the point of junction. The areolar tissue between the fibres appears to be prolonged more or less into the tendon, so as to form a kind of sheath around the tendon bundles for a longer or shorter distance. When muscular fibres are attached to the skin or mucous membranes, their fibres are described by Hyde Salter as becoming continuous with those of the areolar tissue.

The *sarcolemma*, or tubular sheath of the fibre, is a transparent, elastic, and apparently homogeneous membrane of considerable toughness, so that it will sometimes remain entire when the included substance is ruptured (see fig. 40). On the internal surface of the sarcolemma in mammalia, and also in the substance of the fibre in the lower animals, elongated nuclei are seen (fig. 57), and in connection with these a row of granules, apparently fatty, is sometimes observed.

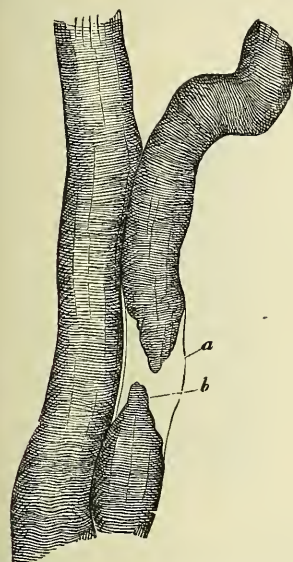
Upon examination of a muscular fibre by transmitted light under a sufficiently high power, it is found to be apparently marked by alternate light and dark bands or striæ, which pass transversely, or somewhat obliquely, round the fibre (fig. 40). The dark and light bands are of nearly equal breadth, and alternate with great regularity. They vary in breadth from about the  $\frac{1}{1200}$  to the  $\frac{1}{1700}$  of an inch. Other striæ pass longitudinally over the fibres, though they are less distinct than the former. This longitudinal striation gives the fibre the appearance of being made up of a bundle of fibrillæ. The muscular fibre can



be broken up either in a longitudinal or transverse direction (fig. 41). If hardened in alcohol, it can be broken up longitudinally, and forms the so-called fibrillæ of which some suppose the fibre to be made up. Each fibril is marked by transverse striæ, and appears to consist of a single row of minute quadrangular particles, named 'sarcous elements' by Bowman. A still further division, however, is capable of being made, and each of these fibrillæ may be divided into minute threads (fig. 42, B, b), consisting of an alternate dark and light spot. After exposure to the action of dilute hydrochloric acid, the muscular fibre can be broken transversely (fig. 41, B). It then forms discs or plates, consisting of the same quadrangular particles, attached by their lateral surfaces.

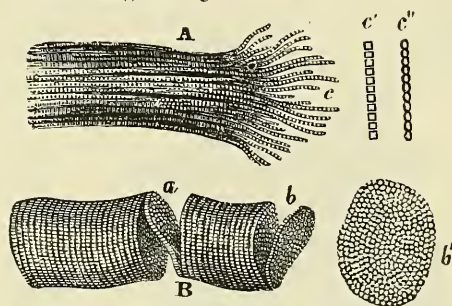
Upon closer examination with a very high power the appearances become more complicated and are susceptible of various interpretations. The transverse striation, which in figs. 40 and 41 appears as a mere alternation of dark and light bands, is resolved into the appearance shown in fig. 42, which shows a series of broad dark bands, separated by a light band, which is itself divided into two by a

FIG. 40.—Two human muscular fibres. Magnified 350 times.



In the one, the bundle of fibrillæ (b) is torn, and the sarcolemma (a) is seen as an empty tube.

FIG. 41.—Fragments of striped elementary fibres, showing a cleavage in opposite directions. Magnified 300 diameters.



A. Longitudinal cleavage. The longitudinal and transverse lines are both seen. Some longitudinal lines are darker and wider than the rest, and are not continuous from end to end. This results from partial separation of the fibrillæ. c. Fibrillæ separated from one another by violence at the broken end of the fibre, and marked by transverse lines equal in width to those on the fibre. c' c'' represent two appearances commonly presented by the separated single fibrillæ (more highly magnified). At c' the borders and transverse lines are all perfectly rectilinear, and the included spaces perfectly rectangular. At c'' the borders are scalloped and the spaces bead-like. When most distinct and definite the fibrilla presents the former of these appearances.

B. Transverse cleavage. The longitudinal lines are scarcely visible. a. Incomplete fracture following the opposite surfaces of a disc, which stretches across the interval, and retains the two fragments in connection. The edge and surfaces of this disc are seen to be minutely granular, the granules corresponding in size to the thickness of the disc, and to the distance between the faint longitudinal lines. b. Another disc nearly detached. b'. Detached disc, more highly magnified, showing the sarcous elements.

dark streak. This streak is termed Krause's membrane; it is continuous at each end with the sarcolemma investing the muscular fibre. Thus it may be said that the fibre is divided into a number of transverse compartments by this membrane, each compartment containing in the centre a dark plate with a bright border above and below; that is to say, between the dark central part and the membrane of Krause. A muscular fibre presents, then, the appearance of the following layers in regular alternation: a dark layer, the *transverse disc*; a bright transparent layer, the *lateral disc*; a dark line, the *intermediate disc* or *membrane of Krause*; then another lateral disc, a transverse disc, and so on (figs. 42 and 43). This appearance, following the observations of Rollett, is due to the mode of formation of a muscular fibre, which is made up of two principal parts: 1, fibrillæ; and 2, a hyaline or faintly granular substance, resembling protoplasm, and called *sarcoplasm*. The fibrillæ are arranged in bundles called *muscular columns* or *sarcostyles*, and these again in larger groups, which, collected together,

form the fibre. The fibrillæ are surrounded by the sarcoplasm, which encloses also the columns and groups of columns, being in these latter situations greater in amount than between the fibrillæ. So that on transverse section a muscular fibre is seen to be divided into a number of areas, called the *areas of Cohnheim*, more or less polyhedral in shape, and consisting of the columns of fibrillæ surrounded by transparent series of sarcoplasm. And these areas are collected into larger or smaller groups, which in the same manner are surrounded by transparent sarcoplasm. Each area of Cohnheim presents a granular appearance due to the cross-section of its constituent fibrillæ, surrounded by a small amount of the hyaline sarcoplasm. The fibrillæ extend throughout the whole length of, and are parallel to, the long axis of the muscular fibre. They present the following appearances in regular alternation: (1) a dim prismatic or rod-shaped element, the *sarcous element of Bowman*; (2) a thin bridge, which joins the sarcous element to (3) a dark granule. Then again another thin bridge joining the same granule to the next sarcous element, and so on (fig. 42, B, *d*). When

FIG. 42.—A. Portion of a medium-sized human muscular fibre. Magnified nearly 800 diameters. B. Separated bundles of fibrils, equally magnified. *a, a*. Larger, and *b, b*, smaller collections. *c*. Still smaller. *d, d*. The smallest which could be detached.

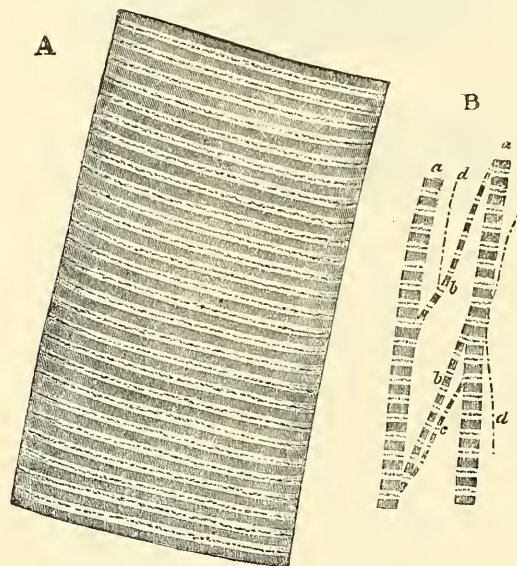
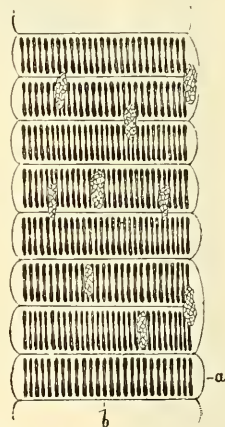


FIG. 43.—Part of a striped muscular fibre of the water-beetle, prepared with absolute alcohol. Magnified 300 diameters. (Klein and Noble Smith.)



*a*. Sarcolemma. *b*. Membrane of Krause; owing to contraction during hardening, the sarcolemma shows regular bulgings. At the side of Krause's membrane is the transparent lateral disc.

Several nuclei of muscle-corpuscles are shown, and in them a minute network.

these fibrillæ are collected together into columns, and the columns into muscular fibres, the appearance mentioned above is produced. The sarcous elements, when arranged side by side and almost touching each other, with very little sarcoplasm between them, represent the transverse disc. The bridges, being much thinner than the sarcous element or the dark granules, have between each other a much larger amount of sarcoplasm, and this gives to this part the transparent appearance of the lateral disc. And, lastly, the granules joined edge to edge in a row present the appearance of a membrane, which represents the intermediate disc.

On the muscular fibre, immediately beneath the sarcolemma, the sarcoplasm becomes here and there collected into small, plate-like masses. They contain oval nuclei, and are termed 'muscle corpuscles.' Finally, in the centre of each sarcous element a transparent lighter band can sometimes be discerned; this is known as the *median disc* of Hensen, and is due to the substance of the sarcous elements being here thinner.

This form of muscular fibre composes the whole of the voluntary muscles,



all the muscles of the ear, those of the larynx, pharynx, tongue, the upper half of the œsophagus, and the walls of the large veins at the point where they open into the heart.

The *capillaries* of striped muscle are very abundant, and form a sort of rectangular network, the branches of which run longitudinally in the endomysium between the muscular fibres, and are joined at short intervals by transverse anastomosing branches. The larger vascular channels, arteries and veins, are found only in the perimysium, between the muscular fasciculi. The smaller vessels present peculiar saccular dilatations, which are supposed to act as receptacles for the blood during the contraction of the muscular fibres, when it is pressed out from some of the capillaries.

*Nerves* are profusely distributed to striped muscle. The mode of their termination will be described on a subsequent page.

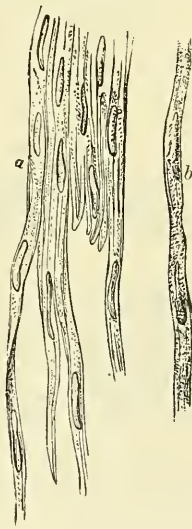The existence of *lymphatic* vessels in striped muscle has not been ascertained, though they have been found in tendons and in the sheath of the muscle.

The **unstriped muscle**, or **muscle of organic life**, is found in the walls of the hollow viscera—viz. the lower half of the œsophagus and the whole of the remainder of the gastro-intestinal tube; in the trachea and bronchi, and the alveoli and infundibula of the lungs; in the gall-bladder and ductus communis choledochus; in the large ducts of the salivary and pancreatic glands; in the pelvis and calices of the kidney, the ureter, bladder and urethra; in the female sexual organs—viz. the ovary, the Fallopian tubes, the uterus (enormously developed in pregnancy), the vagina, the broad ligaments, and the erectile tissue of the clitoris; in the male sexual organs—viz. the dartos of the scrotum, the vas deferens and epididymis, the vesiculæ seminales, the prostate gland, and the corpora cavernosa and corpus spongiosum; in the ducts of certain glands, as in Wharton's duct; in the capsule and trabeculæ of the spleen; in the mucous membranes, forming the muscularis mucosæ; in the skin, forming the arrectores pilorum, and also in the sweat-glands; in the arteries, veins, and lymphatics; in the iris and the ciliary muscle.

Plain or unstriped muscular fibre is made up of spindle-shaped cells, called *contractile fibre-cells*, collected into bundles and held together by a cement-substance in which are contained some connective-tissue corpuscles (fig. 44). These bundles are further aggregated into larger bundles, or flattened bands, and bound together by ordinary connective tissue.

The *contractile fibre-cells* (fig. 45) are elongated, spindle-shaped, nucleated cells of various lengths, averaging from  $\frac{1}{600}$  to  $\frac{1}{300}$  of an inch in length, and  $\frac{1}{4500}$  to  $\frac{1}{3500}$  of an inch in breadth. On transverse section they are more or less polyhedral in shape, from mutual pressure. They present a faintly longitudinal striated appearance, and consist of an elastic cell-wall containing a central bundle of fibrillæ, representing the contractile substance, and an oval or rod-like nucleus, which includes, within a membrane, a fine network communicating at the poles of the nucleus with the contractile fibres (Klein). The adhesive interstitial substance, which connects the fibre-cells together, represents the endomysium, or delicate connective tissue which binds the fibres of striped muscular tissue into fasciculi; while the tissue connecting the individual bundles together represents the perimysium. The unstriped muscle, as a rule, is not under the control of the will, nor is the contraction rapid and involving the whole muscle, as is the case with the muscles of animal life. The membranes

FIG. 44.—Non-striated elementary fibres from the human colon.



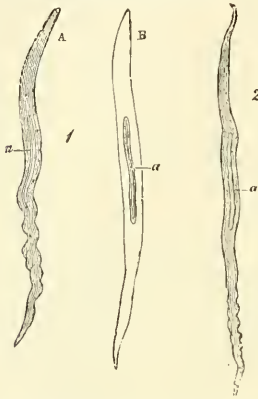
a. Treated with acetic acid, showing the corpuscles. b. Fragment of a detached fibre, not touched with acid.



which are composed of the unstriped muscle slowly contract in a part of their extent, generally under the influence of a mechanical stimulus, as that of distension or of cold; and then the contracted part slowly relaxes while another portion of the membrane takes up the contraction. This peculiarity of action is most strongly marked in the intestines, constituting their *vermicular motion*.

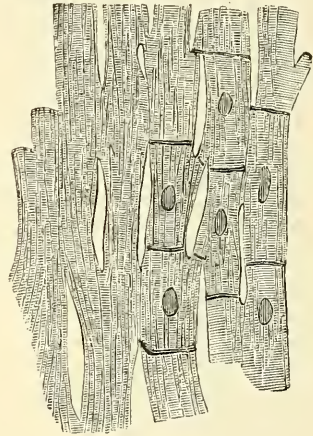
**Cardiac Muscular Tissue.**—The fibres of the heart differ very remarkably from those of other striped muscles. They are smaller by one-third, and their transverse striæ are by no means so distinct. The fibres are made up of distinct quadrangular cells joined end to end (fig. 46). Each cell contains a clear oval nucleus, situated near the centre of the cell. The extremities of the cells have a tendency to branch or divide, the subdivisions uniting with offsets from other

FIG. 45.—Muscular fibre-cells from human arteries.



1. From the popliteal artery. A, without; B, with acetic acid. 2. From a branch of the anterior tibial. a. Nuclei of the fibres. Magnified 350 times.

FIG. 46.—Anastomosing muscular fibres of the heart seen in a longitudinal section. On the right the limits of the separate cells with their nuclei are exhibited somewhat diagrammatically.



cells, and thus producing an anastomosis of the fibres. The connective tissue between the bundles of fibres is much less than in ordinary striped muscle, and no sarcolemma has been proved to exist.

**Chemical Composition of Muscle.**—In chemical composition the muscular fibres of both forms consist mainly of a proteid substance—myosin—which Dr. M. Foster speaks of as intermediate between fibrin and globulin. It is readily converted by the action of dilute acids into syntonin or acid-albumen, and by the action of dilute alkalis into alkali-albumen. Muscle, which is neutral or slightly alkaline in reaction when at rest, is rendered acid by contraction, from the development probably of sarcolactic acid. After death, muscle also exhibits an acid reaction, but this appears to be due to post-mortem change.

## NERVOUS TISSUE

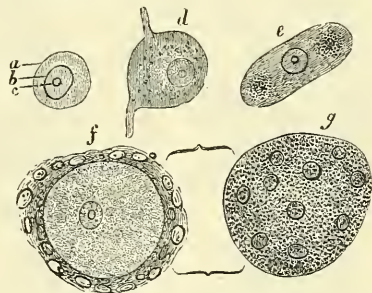
The **nervous tissues** of the body are comprised in two great systems—the *cerebro-spinal* and the *sympathetic*; and each of these systems consists of a *central organ*, or series of central organs, and of *nerves*.

The *cerebro-spinal* system comprises the brain (including the medulla oblongata), the spinal cord, the cranial nerves, the spinal nerves, and the ganglia connected with both these classes of nerves. The *sympathetic* system consists of a double chain of ganglia, with the nerves which go to and come from them. It is not directly connected with the brain or spinal cord, though it is so indirectly by means of its numerous communications with the cranial and spinal nerves.

All these nervous tissues are composed chiefly of two different structures—the *grey* or *vesicular*, and the *white* or *fibrous*. It is in the former, as is generally supposed, that nervous impressions and impulses originate, and by the latter that they are conducted. Hence the grey matter forms the essential constituent of all the ganglionic centres, both those in the isolated ganglia and those aggregated in the cerebro-spinal axis; while the white matter is found in all the commissural portions of the nerve-centres and in all the cerebro-spinal nerves. The nerves of the sympathetic system are chiefly composed of a somewhat different material in structure, which is named *grey* or *gelatinous* nerve-fibre. This form of nerve-fibre is also found in some of the cerebro-spinal nerves.

The **grey or vesicular nervous substance** is distinguished by its dark reddish-grey colour and soft consistence. It is found in the brain, spinal cord, and various ganglia intermingled with the fibrous nervous substance, and also in some of the nerves of special sense, and in gangliform enlargements which are found here and there in the course of certain cerebro-spinal nerves. It is composed, as its name implies, of vesicles, or corpuscles, commonly called *nerve-cells* or *ganglion-corpuscles*, containing nuclei and nucleoli; the vesicles, together with the blood-vessels, in the vesicular nerve-substance, and the nerve-fibres and vessels in the white nerve-substance, are embedded in a peculiar ground-connective tissue. It was named by Kölliker as a modified form of retiform connective tissue. It was named by Virchow *neuroglia*, and consists of large branched cells, the branches passing in every direction amongst the nerve-tissue, thus holding it and binding it together. It is developed from the epiblast, and contains neither the characteristic fibres nor cells of connective tissue, and therefore cannot be regarded as belonging to the true connective tissues. Each nerve-cell consists of a finely granular protoplasmic material, of a reddish or yellowish-brown colour, which occasionally presents patches of a deeper tint, caused by the aggregation of pigment-granules (fig. 47). No distinct limiting membrane or cell-wall has been ascertained to exist. The nucleus is, as a rule, a large, well-defined, round, vesicular body, often presenting an intranuclear network, and containing a nucleolus which is peculiarly clear and brilliant. The nerve-corpuscles vary in shape and size; some are small, spherical or ovoid, with generally an even outline, such as those frequently found in the spinal ganglia; others are more or less angular, as in the ganglia of the sympathetic; others, again, are caudate or stellate in shape, and are characterised by their large size and by their having one or more tail-like processes issuing from them, which occasionally divide and subdivide into numerous branches (fig. 48). These are found in greatest number in the grey matter of the spinal cord. Still others are flask-shaped, as in the cortex of the cerebellum; or conical, as in the cerebral convolutions. For the most part nerve-cells have one or more processes, and they are distinguished, by the number of these processes, as unipolar, bipolar, or multipolar cells. These processes are very delicate, apparently tubular, and contain a granular material similar to that found within the corpuscle. Some of the processes terminate in fine, transparent fibres, which become lost among the other elements of the nervous tissue; others may be traced until, after losing their granular appearance, they become continuous with an ordinary nerve-fibre.

FIG. 47.—Nerve-vesicles from the Gasserian ganglion of the human subject.



a. A globular one with defined border. b. Its nucleus. c. Its nucleolus. d. Caudate vesicle. e. Elongated vesicle with two groups of pigment-particles. f. Vesicle surrounded by its sheath or capsule of nucleated particles. g. The same, the sheath only being in focus. Magnified 300 diameters.

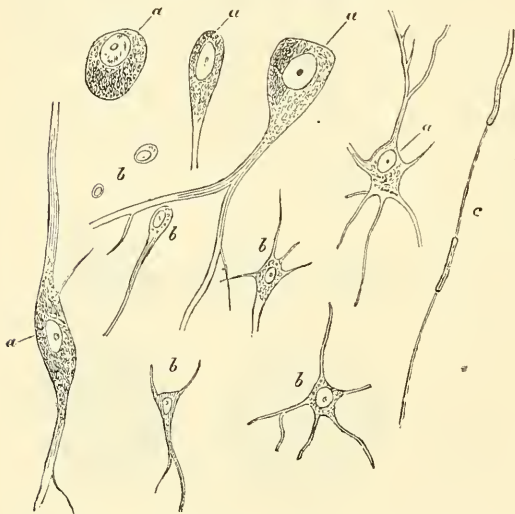
The **white or fibrous** nerve-substance or *nerve-fibre* is found universally in

the nervous cords, and also constitutes a great part of the brain and spinal cord. The fibres of which it consists are of two kinds, the *medullated* or *white* fibres, and the *non-medullated* or *grey* fibres.

The **medullated** fibres form the white part of the brain and spinal cord, and also the greater part of the cerebro-spinal nerves, and give to these structures their opaque, white aspect. When perfectly fresh they appear to be homogeneous; but soon after removal from the body they present, when examined by transmitted light, a double outline or contour, as if consisting of two parts. The central portion is named the *axis-cylinder of Purkinje*; around this is a sort of sheath of fatty material, named the *white substance of Schwann*, which gives to the fibre its double contour, and the whole is enclosed in a delicate membrane, the *neurilemma*,\* *primitive sheath*, or *nucleated sheath of Schwann* (fig. 49).

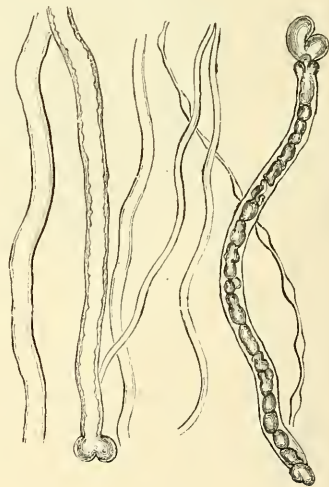
The *axis-cylinder* is the essential part of the nerve-fibre, and is always present: the other parts, the medullary sheath and the neurilemma, being occasionally absent, especially at the origin and termination of the nerve-fibre.

FIG. 48.—Nerve-vesicles from the inner part of the grey matter of the convolutions of the human brain. Magnified 350 times.



Nerve-cells: a. Larger. b. Smaller. c. Nerve-fibre with axis-cylinder.

FIG. 49.—Human nerve-tubes. Magnified 350 times. Three of them are fine, one of which is varicose, one of middling thickness, and with a simple contour; and three thick, two of which are double-contoured, and one with grumous contents.



It undergoes no interruption from its origin in the nerve-centre to its peripheral termination, and must be regarded as a direct prolongation of a nerve-cell. It constitutes about one-half or one-third of the nerve-tube, the white substance being greater in proportion in the nerves than in the central organs. It is perfectly transparent, and is therefore indistinguishable in a perfectly fresh and natural state of the nerve. It is described by Kölliker as being distinguished from the white substance by the fact that, though soft and flexible, it is not fluid and viscid, but firm and elastic, somewhat like coagulated albumen, with which it appears for the most part also to agree in its chemical characters. When examined under a high power it presents the appearance of longitudinal striation, as if composed of very fine, homogeneous fibrillæ, held together in a faintly granular interstitial material. Occasionally at its termination the axis-cylinder of a fibre may be seen to break up into exceedingly fine fibrillæ, confirming the

\* In older histological works the term 'neurilemma' is used to designate the fibrous envelope of the whole nerve, now called 'perineurium.'



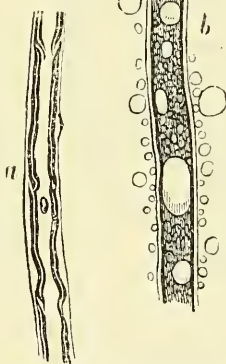
view of its fibrillar structure. These fibrillæ have been termed the *primitive fibrille* of Schultze. The axis-cylinder is said by some to be enveloped in a very delicate, hyaline sheath, which separates it from the white matter of Schwann, but it is doubtful whether this really exists. The *medullary sheath* or *white matter of Schwann* is regarded as being a fatty matter in a fluid state, which insulates and protects the essential part of the nerve—the axis-cylinder. The white matter varies in thickness to a very considerable extent, in some forming a layer of extreme thinness, so as to be scarcely distinguishable, in others forming about one-half the nerve-tube. The size of the nerve-fibres, which varies from  $\frac{1}{12000}$  to  $\frac{1}{20000}$  of an inch, depends mainly upon the amount of the white substance, though the axis-cylinder also varies in size within certain limits. The white matter of Schwann does not always form a continuous sheath to the axis-cylinder, but undergoes interruptions in its continuity at regular intervals, giving to the fibre the appearance of constriction at these points. These were first described by Ranvier, and are known as the *nodes of Ranvier* (fig. 50). The portion of nerve-fibre between two nodes is called an *internodal segment*. The neurilemma or primitive sheath is not interrupted at the nodes, but passes over them as a continuous membrane. Each internodal segment contains an oval nucleus embedded in the medullary sheath. Medullated nerve-fibres, when examined, frequently present a beaded or varicose appearance: this is due to manipulation and pressure causing the oily matter to collect into drops, and in consequence of the extreme delicacy of the primitive sheath, even slight pressure will cause the transudation of the fatty matter, which collects as drops of oil outside the membrane. This is, of course, promoted by the action of ether (fig. 51).

FIG. 50.—A node of Ranvier of a medullated nerve-fibre, viewed from above, magnified about 750 diameters. The medullary sheath is discontinuous at the node, whereas the axis-cylinder passes from one segment into the other. At the node the sheath of Schwann appears thickened. (Klein and Noble Smith.)



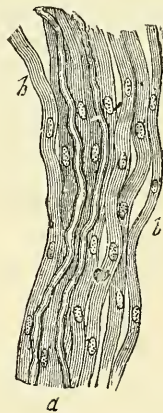Each internodal segment contains an oval nucleus embedded in the medullary sheath. Medullated nerve-fibres, when examined, frequently present a beaded or varicose appearance: this is due to manipulation and pressure causing the oily matter to collect into drops, and in consequence of the extreme delicacy of the primitive sheath, even slight pressure will cause the transudation of the fatty matter, which collects as drops of oil outside the membrane. This is, of course, promoted by the action of ether (fig. 51).

FIG. 51.—Magnified 300 diameters.



a. Nerve-tube of the common eel in water. The delicate line on its exterior indicates the tubular membrane. The dark double-edged inner one is the white matter of Schwann, slightly wrinkled. b. The same in ether. Several oil-globules have coalesced in the interior, and others have accumulated around the exterior of the tube. The white matter has in part disappeared.

FIG. 52.—A small nervous branch from the sympathetic of a mammal.



a. Two dark-bordered nerve-tubes among a number of Remak's fibres, b.

The *neurilemma* or *primitive sheath* (sometimes called the *tubular membrane* or *sheath of Schwann*) presents the appearance of a delicate, structureless membrane. Here and there beneath it, and situated in depressions in the white matter of Schwann, are nuclei surrounded by a small amount of protoplasm. The nuclei are oval and somewhat flattened, and bear a definite relation to the nodes of Ranvier; one nucleus generally lying in the centre of each node.

**Non-medullated Fibres.**—Most of the nerves of the sympathetic system, and some of the cerebro-spinal, consist of another variety of nervous fibres, which are called the *grey* or *gelatinous* nerve-fibres—*fibres of Remak* (fig. 52). These consist of finely striated fibres enclosed in a delicate, homogeneous sheath,

similar to the neurilemma of the medullated nerve-fibres. Nuclei may be detected at intervals in each fibre, situated between the axis-cylinder and the neurilemma. In external appearance the gelatinous nerves are semi-transparent and grey or yellowish-grey. The individual fibres vary in size, generally averaging about half the size of the medullated fibres; they are often branched; the branches uniting with other neighbouring branches, so as to form a network. The olfactory nerve is made up of these gelatinous nerve-fibres, but they are of large size, and possess a distinct nucleated sheath.

**Chemical Composition.**—The different portions of the nervous system are composed of the two above-described kinds of nervous structure, the chemical composition of which is shown by the following analysis, by Lassaigne, which represents the relative proportion of the different constituents composing the grey and white matter of the brain.

	Grey	White
Water . . . . .	85·2	73·0
Albuminous matter . . . . .	7·5	9·9
Colourless fat . . . . .	1·0	13·9
Red fat . . . . .	3·7	0·9
Osmazome and lactates . . . . .	1·4	1·0
Phosphates . . . . .	1·2	1·3

It appears from this analysis that the cerebral substance consists of albumen, dissolved in water, combined with fatty matter and salts. The fatty matters consist of cerebrin, neurin, and lecithin. The two latter were first described by Liebreich as a crystalline phosphuretted fat, which he termed *protagon*. It seems probable, however, that it is simply a mixture of neurin and lecithin. Cholesterine is also described as one of the chemical constituents of the nervous tissues, being found in conjunction with lecithin. The salts are the phosphates of potash, soda, lime, magnesia, and iron, sulphate of potash, and chloride of sodium, with traces of silica. According to Vauquelin, the cord contains a larger proportion of fat than the brain; and according to L'Héritier, the nerves contain more albumen and more soft fat than the brain.

The nervous structures are divided, as before mentioned, into two great systems—viz. the *cerebro-spinal*, comprising the brain and spinal cord, the nerves connected with these structures, and the ganglia situated on them; and the *sympathetic*, consisting of a double chain of ganglia and the nerves connected with them. All these structures require separate consideration; they are composed of the two kinds of nervous tissue above described, intermingled in various proportions and having, in some parts, a very intricate arrangement.

The **brain** or **encephalon** is that part of the cerebro-spinal system which is contained in the cavity of the skull. It is divided into several parts, named the medulla oblongata, pons Varolii, cerebellum, and cerebrum. In these parts the grey or vesicular nervous matter is found partly on the surface of the brain, forming the convolutions of the cerebrum, and partly in the laminae of the cerebellum. Again, grey matter is found in the interior of the brain, collected into large and distinct masses or ganglionic bodies, such as the corpus striatum, optic thalamus, and corpora quadrigemina. Finally, grey matter is found intermingled intimately with the white, but without definite arrangement, as in the corpora dentata of the medulla and cerebellum, or the grey matter in the pons Varolii and the floor of the fourth ventricle.

The white matter of the brain is divisible into three distinct classes of fibres. These are, in the first place, the nerves which arise in the grey matter and pass out through the cranial foramina. Next, the fibres which connect the brain with the spinal cord; that is to say, those which are usually traced upwards from the columns of the spinal cord, through the medulla oblongata into the encephalon, chiefly by means of the anterior pyramids, lateral tract, and restiform bodies, passing through the pons Varolii and crura cerebri to ex-



pand into the corpora striata, optic thalamus, and convolutions (*corona radiata*), and by means of the restiform bodies into the cerebellum. The other class of white fibres in the brain are commissural, some of the commissures serving to connect different parts of the same hemisphere together (as the fornix, *processus e cerebello ad testes*, &c.), or even different parts of the same section, as the arciform fibres of the medulla. Most of these commissures are longitudinal; while others, as the corpus callosum and the transverse fibres of the pons Varolii, are transverse, serving to connect opposite hemispheres, and thus probably securing the single action of a double organ.

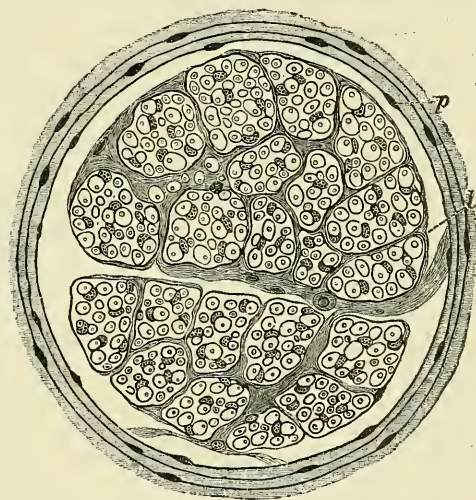
The manner in which the grey and white matter are intermingled in the brain and spinal cord is very intricate, and can only be fully understood by a careful study of the details of its descriptive anatomy in the sequel. The further consideration of this subject will therefore be deferred until after the description of the various divisions of which the cerebro-spinal system is made up.

The **nerves** are round or flattened cords, formed of the nerve-fibres already described. They are connected at one end with the cerebro-spinal centre or with the ganglia, and are distributed at the other end to the various textures of the body; they are subdivided into two great classes—the *cerebro-spinal*, which proceed from the cerebro-spinal axis, and the *sympathetic* or *ganglionic* nerves, which proceed from the ganglia of the sympathetic. The **cerebro-spinal nerves** consist of numerous nerve-fibres collected together and enclosed in a membranous sheath (fig. 53). A small bundle of primitive fibres, enclosed in a tubular sheath, is called a *funiculus*; if the nerve is of small size, it may consist only of a single funiculus; but if large, the funiculi are collected together into larger bundles or fasciculi, which are bound together in a common membranous investment, and constitute the nerve.

In structure, the common membranous investment, or sheath of the whole nerve, which is called the *epineurium*, as well as the septa given off from it, and which separate the fasciculi, consists of connective tissue, composed of white and yellow elastic fibres, the latter existing in great abundance. The tubular sheath of the funiculi, called the *perineurium*, consists of a fine, smooth, transparent membrane, which may be easily separated, in the form of a tube, from the fibres it encloses; in structure it consists of connective tissue, which has a distinctly lamellar arrangement, consisting of several lamellæ, separated from each other by spaces containing lymph. The nerve-fibres are held together and supported within the funiculus by delicate connective tissue, called the *endoneurium*. It is continuous with septa which pass inwards from the innermost layer of the perineurium, and consists of a ground-substance in which are embedded fine bundles of fibrous connective tissue which run for the most part longitudinally.

FIG. 53.—Transverse section through a microscopic nerve, representing a compound nerve-bundle, surrounded by perineurium. Magnified 120 diameters.

The medullated fibres are seen as circles with a central dot, viz. medullary sheath and axis-cylinder, in transverse section. They are embedded in endoneurium, containing numerous nuclei, which belong to the connective-tissue cells of the latter. (Klein and Noble Smith.)



p. Perineurium, consisting of laminae of fibrous connective tissues, alternating with flattened nucleated connective-tissue cells. l. Lymph-space between perineurium and surface of nerve-bundle.



It serves to support the capillary vessels, which are arranged so as to form a network with the elongated meshes. The cerebro-spinal nerves consist almost exclusively of the medullated nerve-fibres, the non-medullated existing in very small proportions.

The blood-vessels supplying a nerve terminate in a minute capillary plexus, the vessels composing which pierce the perineurium and run, for the most part, parallel with the fibres; they are connected together by short, transverse vessels, forming narrow, oblong meshes, similar to the capillary system of muscle. Fine non-medullated nerve-fibres accompany these capillary vessels, *vaso-motor fibres*, and break up into elementary fibrils, which form a network around the vessel. Horsley has also recently demonstrated certain medullated fibres as running in the epineurium and terminating in small spheroidal tactile corpuscles or end-bulbs of Krause. These nerve-fibres, which Professor Marshall believes to be sensory, and which he has termed *nervi nervorum*, are considered by him to have an important bearing upon certain neuralgic pains.

The nerve-fibres, as far as is at present known, do not coalesce, but pursue an uninterrupted course from the centre to the periphery. In separating a nerve, however, into its component funiculi, it may be seen that these do not pursue a perfectly insulated course, but occasionally join at a very acute angle with other funiculi proceeding in the same direction; from this, branches are given off, to join again in like manner with other funiculi. It must be distinctly understood, however, that in these communications the nerve-fibres do not coalesce, but merely pass into the sheath of the adjacent nerve, become intermixed with its nerve-fibres, and again pass on, to become blended with the nerve-fibres in some adjoining funiculus.

Nerves, in their course, subdivide into branches, and these frequently communicate with branches of a neighbouring nerve. The communications which thus take place form what is called a *plexus*. Sometimes a plexus is formed by the primary branches of the trunks of the nerves—as the cervical, brachial, lumbar, and sacral plexuses—and occasionally by the terminal funiculi, as in the plexuses formed at the periphery of the body. In the formation of a plexus, the component nerves divide, then join, and again subdivide in such a complex manner that the individual funiculi become interlaced most intricately; so that each branch leaving a plexus may contain filaments from each of the primary nervous trunks which form it. In the formation also of smaller plexuses at the periphery of the body there is a free interchange of the funiculi and primitive fibres. In each case, however, the individual filaments remain separate and distinct, and do not inosculate with one another.

It is probable that through this interchange of fibres the different branches passing off from a plexus have a more extensive connection with the spinal cord than if they each had proceeded to be distributed without such connection with other nerves. Consequently, the parts supplied by these nerves have more extended relations with the nervous centres; by this means, also, groups of muscles may be associated for combined action.

The **sympathetic** nerves are constructed in the same manner as the cerebro-spinal nerves, but consist mainly of non-medullated fibres, collected into funiculi, and enclosed in a sheath of connective tissue. There is, however, in these nerves, a certain admixture of medullated fibres, and the amount varies in different nerves, and may be known by its colour. Those branches of the sympathetic which present a well-marked grey colour are composed more especially of gelatinous nerve-fibres, intermixed with a few medullated fibres; whilst those of a white colour contain more of the latter fibres, and a few of the former. Occasionally, the grey and white cords run together in a single nerve, without any intermixture, as in the branches of communication between the sympathetic ganglia and the spinal nerves, or in the communicating cords between the ganglia.

The nerve-fibres, both of the cerebro-spinal and sympathetic system, convey

impressions of a twofold kind. The sensory nerves, called also *centripetal* or *afferent* nerves, transmit to the nervous centres impressions made upon the peripheral extremities of the nerves, and in this way the mind, through the medium of the brain, becomes conscious of external objects. The *motor* nerves, called also *centrifugal* or *efferent* nerves, transmit impressions from the nervous centres to the parts to which the nerves are distributed, these impressions either exciting muscular contraction, or influencing the processes of nutrition, growth, and secretion.

**Origin and Termination of Nerves.**—By the expression 'the termination of nerve-fibres' is signified their connections with the nerve-centres, and with the parts they supply. The former are sometimes called their *origin*, or *central* termination; the latter their *peripheral* termination. The origin in some cases is single—that is to say, the whole nerve emerges from the nervous centre by a single root; in other instances the nerve arises by two or more roots, which come off from different parts of the nerve-centre, sometimes widely apart from each other, and it often happens, when a nerve arises in this way by two roots, that the functions of these two roots are different; as, for example, in the spinal nerves, each of which arises by two roots, the anterior of which is motor, and the posterior sensory. The point where the nerve root or roots emerge from the nervous centre is named the *superficial* or *apparent* origin, but the fibres of which the nerve consists can be traced for a certain distance into the nervous centre to some portion of the grey substance, which constitutes the *deep* or *real* origin of the nerve. The exact manner in which these fibres arise at their deep origin is still open to some doubt, but it would appear to be probable that the centrifugal or efferent nerve-fibres are directly continuous with one of the processes of the multipolar nerve-cells, and may therefore be said to be prolongations from the nerve-cells of the grey substance. The centripetal or afferent fibres, on the other hand, do not appear to be continuous with the nerve-cells. If traced from their apparent origin into the nerve-centre, they may be seen to bifurcate, assume a straight course, and send off lateral branches, which become lost in the grey matter.

**Peripheral Terminations of Nerves.**—The manner in which nerve-fibres terminate peripherally are several, and may be conveniently studied in the sensory and motor nerves respectively. **Sensory** nerves would appear to terminate either in *minute primitive fibrillæ* or networks of these; or else in special terminal organs, which have been termed *peripheral end-organs*, and of which there are three principal varieties, viz. the end-bulbs of Krause, the tactile corpuscles of Wagner, and the Pacinian corpuscles.

**Termination in Fibrillæ.**—When a medullated nerve-fibre approaches its termination, the white matter of Schwann suddenly disappears, leaving only the axis-cylinder, surrounded by the neurilemma, and we have now a non-medullated fibre. This, after a time, loses its neurilemma, and consists only of an axis-cylinder, which can be seen, in preparations stained with chloride of gold, to be made up of fine varicose fibrils. Finally, the axis-cylinder breaks up into its constituent primitive nerve-fibrillæ, which anastomose with one another, thus forming a network, and often present regular varicosities. This network passes between the elements of the tissue to which the nerves are distributed, which is always epithelial, the nerve-fibrils lying in the interstitial substance between the epithelial cells, and, as is believed by some, actually terminating *within* the cells, as minute swellings close to the nucleus. In this way nerve-fibres have been found to terminate in the epithelium of the skin and mucous membranes, and in the anterior epithelium of the cornea.

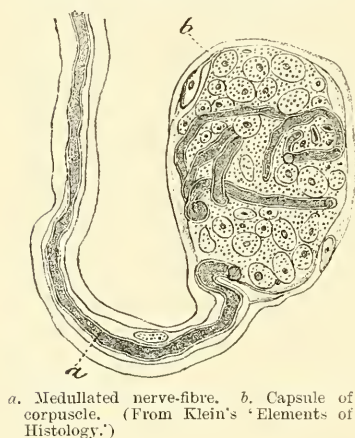
The **end-bulbs of Krause** (fig. 54) are of two kinds: 1. The *cylindrical end-bulbs*, found principally in the lower animals, are oblong or cylindrical corpuscles, into the interior of which the axis-cylinder of the nerve-fibres passes and terminates in a bulbous extremity. The corpuscle consists of a simple nucleated capsule, containing a soft, homogeneous core, in which the termination of the



axis-cylinder is contained. The white matter of Schwann ceases abruptly as the axis-cylinder enters the corpuscle, but the neurilemma is continued inwards with the axis-cylinder, and forms an investment of the core, lining the interior of the capsule. 2. The small *spheroidal end-bulb*, found only in men and monkeys, consists of a capsule of connective tissue, enclosing a number of polygonal cells, amongst which the axis-cylinder terminates. These spheroidal end-bulbs are found in the conjunctiva of man, in the mucous membrane of the mouth, nasal cavities and rectum, and also in the mucous membrane of the glans penis and clitoris. In this latter situation they have a mulberry-like appearance, from being constricted by connective-tissue septa into from two to six knob-like masses, and have received the name of *genital corpuscles*. Very similar corpuscles are found in the epineurium of nerve-trunks (see p. 45). In the synovial membrane of certain joints (e.g. those of the fingers), rounded or oval end-bulbs have been found; these are designated *articular end-bulbs*.

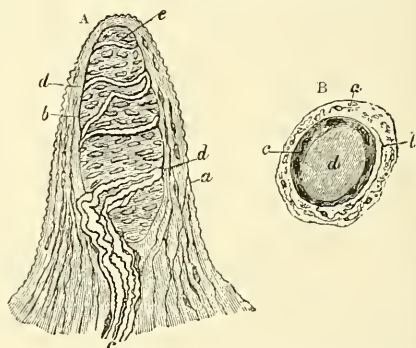
The **tactile corpuscles** (fig. 55), described by Wagner and Meissner, are oval-shaped bodies, made up of connective tissue, and consisting of a capsule, and im-

FIG. 54.—End-bulb of Krause.



a. Medullated nerve-fibre, b. Capsule of corpuscle. (From Klein's 'Elements of Histology'.)

FIG. 55.—Papilla of the hand, treated with acetic acid. Magnified 350 times.



A. Side view of a papilla of the hand. a. Cortical layer. b. Tactile corpuscle, with transverse nuclei. c. Small nerve of the papilla, with neurilemma. d. Its two nervous fibres running with spiral coils around the tactile corpuscle. e. Apparent termination of one of these fibres. B. A tactile papilla seen from above so as to show its transverse section. a. Cortical layer. b. Nerve-fibre. c. Outer layer of the tactile body, with nuclei. d. Clear interior substance.

perfect membranous septa, derived from it, which penetrate its interior. One or more medullated nerve-fibres pass to each corpuscle, and sometimes pass at once into its interior, at other times wind round it two or three times; then lose their medullary sheath, and the axis-cylinders, entering the capsule, pursue a convoluted course, supported by the septa, and terminate in small globular or pyriform enlargements, near the inner surface of the capsule. These tactile corpuscles have been described as occurring in the papillæ of the corium of the hand and foot, the front of the fore-arm, the skin of the lips, and the mucous membrane of the tip of the tongue, the palpebral conjunctiva, and the skin of the nipple. They are not found in all the papillæ; but from their existence in those parts in which the skin is highly sensitive, it is probable that they are specially concerned in the sense of touch, though their absence from the papillæ of other tactile parts shows that they are not essential to this sense.

The **Pacinian corpuscles**\* (fig. 56) are found in the human subject chiefly on the nerves of the palm of the hand and sole of the foot and in the genital organs of both sexes lying in the subcutaneous tissue; but they have also

\* Often called in German anatomical works 'corpuscles of Vater.'



been described as connected with the nerves of the joints, and in some other situations, as the mesentery of the cat and along the tibia of the rabbit. Each of these corpuscles is attached to and encloses the termination of a single nerve-fibre. The corpuscle, which is perfectly visible to the naked eye (and which can be most easily demonstrated in the mesentery of a cat), consists of a number of lamellæ or capsules, arranged more or less concentrically around a central clear space, in which the nerve-fibre is contained. Each lamella is composed of bundles of fine connective-tissue fibres, and is lined on its inner surface by a single layer of nucleated endothelial cells. The central clear space, which is elongated or cylindrical in shape, is filled with a transparent material, in the middle of which is the single medullated fibre, which traverses the space to near its distal extremity. Here it terminates in a rounded knob or end, sometimes bifurcating previously, in which case each branch has a similar arrangement. Todd and Bowman have described minute arteries as entering by the sides of the nerves and forming capillary loops in the intercapsular spaces, and even penetrating into the central space. Other authors describe the artery as entering the corpuscle at the pole opposite to the nerve-fibre.

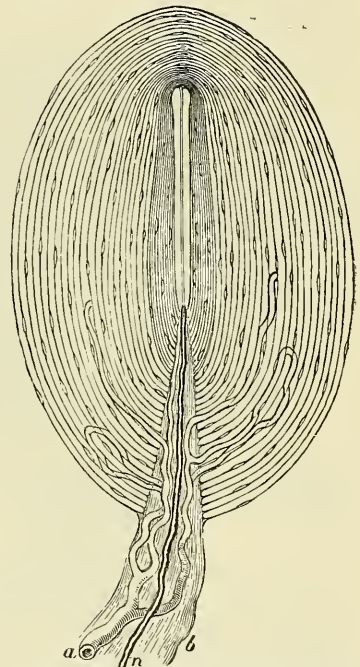
Herbst has described a somewhat similar 'nerve-ending' to the Pacinian corpuscle, as being found in the mucous membrane of the tongue of the duck, and in some other situations. It differs, however, from the Pacinian corpuscles, in being smaller, its capsule thinner and more closely approximated, and especially in the fact that the axis-cylinder in the central clear space is coated with a continuous row of nuclei. These bodies are known as the *corpuscles of Herbst*.

**Tactile corpuscles** have been described by Grandry as occurring in the papillæ of the beak and tongue of birds, and by Merkel as occurring in the papillæ and epithelium of the skin of man and animals, especially in those parts of the skin devoid of hair. They consist of a capsule composed of a very delicate, nucleated membrane, and contain two or more granular, somewhat flattened cells, between which the medullated nerve-fibre, which enters the capsule by piercing its investing membrane, is supposed to terminate.

In the organs of **special sense** the nerves terminate in cells, which belong to the epithelial class, and have received the name of *sensory* or *nerve-epithelium* cells. The axis-cylinders terminate in these epithelial cells, which are variously modified and to the peripheral extremity of which are often connected peculiar styliform processes. These cells will be more particularly described in the sequel, in connection with the description of the organs of special sense.

**Motor nerves** are to be traced either into unstriped or striped muscular fibres. In the **unstriped** or **involuntary** muscles the nerves are derived from the sympathetic, and are composed mainly of the non-medullated fibres. Near their termination they divide into a number of branches, which communicate and form an intimate plexus. At the junction of the branches small triangular nuclear bodies

Fig. 56.—Pacinian corpuscle, with its system of capsules and central cavity.

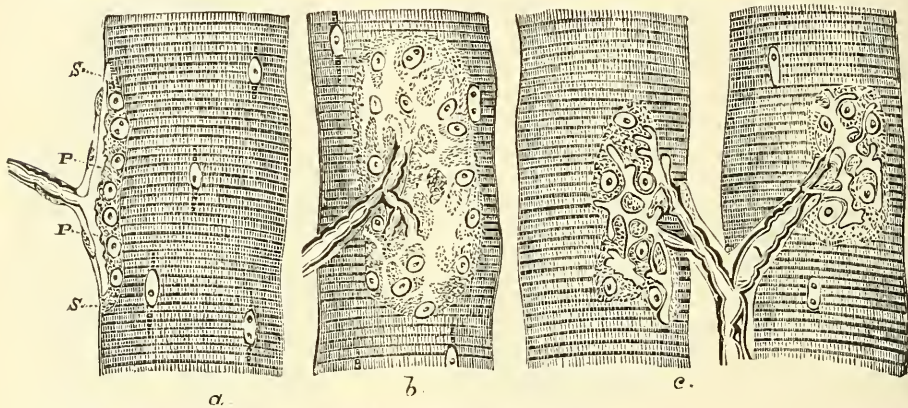


*a.* Arterial twig, ending in capillaries, which form loops in some of the intercapsular spaces, and one penetrates to the central capsule. *b.* The fibrous tissue of the stalk prolonged from the neurilemma. *n.* Nerve-tube advancing to the central capsule, there losing its white matter, and stretching along the axis to the opposite end, where it is fixed by a tubercular enlargement.

(ganglion-cells) are situated. From these plexuses minute branches are given off, which divide and break up into the ultimate fibrillæ of which the nerve is composed. These fibrillæ course between the involuntary muscle-cells, and, according to Elischer, terminate on the surface of the cell, opposite the nucleus, in a minute swelling. Arnold and Frankenhäuser believed that these ultimate fibrillæ penetrated the muscular cell, and ended in the nucleus. More recent observation has, however, tended to disprove this.

In the **striped or voluntary** muscle, the nerves supplying the muscular fibres are derived from the cerebro-spinal nerves, and are composed mainly of medullated fibres. The nerve, after entering the sheath of the muscle, breaks up into fibres, or bundles of fibres, which form plexuses, and gradually divide until, as a rule, a single nerve-fibre enters a single muscular fibre. Sometimes, however, if the muscular fibre is long, more than one nerve-fibre enters it. Within the muscular fibre the nerve terminates in a special expansion, called by Kühne, who first accurately described them, *motorial end-plates* (fig. 57).\* The nerve-

FIG. 57.—Muscular fibres of *Lacerta viridis* with the terminations of nerves.



*a.* Seen in profile. *p p.* The nerve end-plates. *s s.* The base of the plate, consisting of a granular mass with nuclei. *b.* The same as seen in looking at a perfectly fresh fibre, the nervous ends being probably still excitable. (The forms of the variously divided plate can hardly be represented in a woodcut by sufficiently delicate and pale contours to reproduce correctly what is seen in nature.) *c.* The same as seen two hours after death from poisoning by curare.

fibre, on approaching the muscular fibre, suddenly loses its white matter of Schwann, which abruptly terminates; the neurilemma becomes continuous with the sarcolemma of the muscle, and only the axis-cylinder enters the muscular fibre, where it immediately spreads out, ramifying like the roots of a tree, immediately beneath the sarcolemma, and is embedded in a layer of granular matter, containing a number of clear, oblong nuclei, the whole constituting an end-plate from which the contractile wave of the muscular fibre is said to start.

The nerves supplying tendons have peculiar nerve-endings, and are especially numerous near the point where the tendon becomes muscular. In this situation spindle-shaped bodies are found, and are known as the *organs of Golgi*. They are apparently composed of several tendinous bundles, fused into one, into which one or more nerve-fibres pass, and, dividing, spread out between the tendon-bundles and form a branched expansion. Nerve-fibres occasionally terminate in tendons as end-bulbs or as small Pacinian corpuscles.

The **Ganglia** may be regarded as separate and independent nervous centres, of smaller size and less complex structure than the brain, connected with each other, with the cerebro-spinal axis, and with the nerves in various situations. They are found on the posterior root of each of the spinal nerves; on the posterior or sensory root of the fifth cranial nerve; on the facial and auditory nerves;

\* They had, however, previously been noticed, though not accurately described, by Doyère, who named them 'nerve-hillocks.'

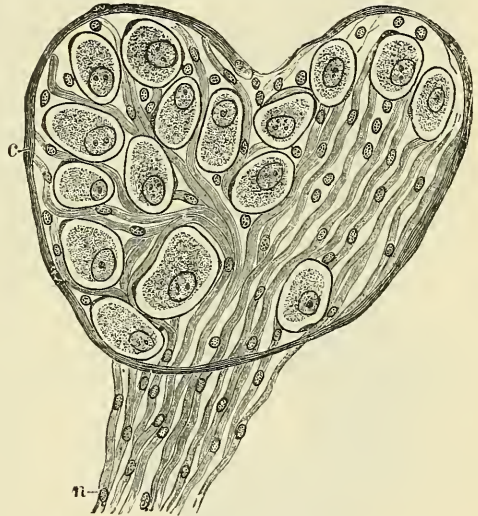


on the glosso-pharyngeal and pneumogastric nerves; and on the branches of certain spinal nerves. They are also found in a connected series along each side of the vertebral column, forming the trunk of the sympathetic; and on the branches of that nerve, generally in the plexuses or at the point of junction of two or more nerves with each other, or with branches of the cerebro-spinal system. On section they are seen to consist of a reddish-grey substance, traversed by numerous white nerve-fibres; they vary considerably in form and size; the largest are found in the cavity of the abdomen; the smallest, not visible to the naked eye, exist in considerable numbers upon the nerves distributed to the different viscera. The ganglia are invested by a smooth and firm, closely adhering, membranous envelope, consisting of dense areolar tissue; this sheath is continuous with the perineurium of the nerves, and sends numerous processes into the interior of the ganglion, which support the blood-vessels supplying its substance.

In structure all ganglia are essentially similar (fig. 58), consisting of the same structural elements as the other nervous centres—viz. a collection of *vesicular nervous matter* traversed by tubular and gelatinous *nerve-fibres*. The vesicular nervous matter consists of nerve or ganglion cells, most of which appear to be free and of a round or oval form; these are more especially seated near the surface of the ganglion; others are unipolar, bipolar, or multipolar, and their caudate processes give origin to nerve-fibres. In the ganglion the nerve-cells are enclosed in a transparent capsule with nuclei on its inner surface. The nerve-fibres on entering the ganglion lay aside their perineurium, which becomes continuous with the capsule. Some of the fibres run through the ganglion without being connected with the cells, others arise from the caudate processes of the cells.

A remarkable modification of the bipolar nerve-cell is found in the sympathetic ganglia, especially in the frog, but also in some few instances in the mammal. The cells are pear-shaped, and from the narrow end two processes arise: one a straight axis-cylinder process, into which the substance of the ganglion is prolonged; the other, a thin fibre, winds spirally round the straight fibre, and then passes away from the cell in the opposite direction and becomes invested with a medullary sheath and neurilemma of its own, and constitutes a medullated fibre, while the straight axis-cylinder process forms a non-medullated fibre.

FIG. 58.—Section through a microscopic ganglion. Magnified 300 diameters. (Klein and Noble Smith.)



c. Capsule of the ganglion. n. Nerve-fibres passing out of the ganglion. The nerve-fibres which entered the ganglion are not represented. The nerve-fibres are ordinary medullated fibres, but the details of their structure are not shown, owing to the low magnifying power. The ganglion-cells are invested by a special capsule, lined by a few nuclei, which are here represented as if contained in the capsule.

## THE VASCULAR SYSTEM

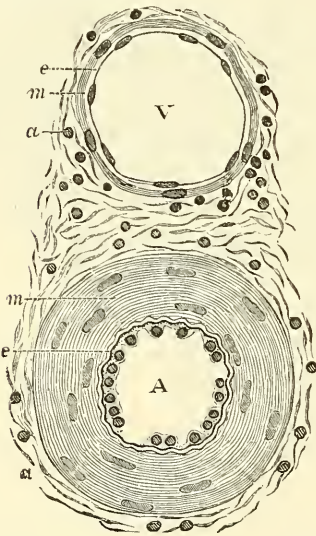
The **Vascular System**, exclusive of its central organ, the heart, is divided into four classes of vessels: the arteries, capillaries, veins, and lymphatics; the minute structure of which we will now proceed briefly to describe, referring the reader to the body of the work for all that is necessary in the details of their ordinary anatomy.



**Structure of Arteries** (fig. 59).—The arteries are composed of three coats: internal or endothelial coat (*tunica intima* of Kölliker); middle muscular coat (*tunica media*); and external cellular coat (*tunica adventitia*).

The two inner coats together are very easily separated from the external, as by the ordinary operation of tying a ligature on an artery. If a fine string be tied forcibly upon an artery and then taken off, the external coat will be found undivided, but the internal coats are divided in the track of the ligature and can easily be further dissected from the outer coat. The *inner coat* can be separated from the middle by a little maceration, or it may be stripped off in small pieces; but, on account of its friability, it cannot be separated as a complete membrane. It is a fine, transparent, colourless structure which is highly elastic, and is commonly corrugated into longitudinal wrinkles. The inner coat consists of

FIG. 59.—Transverse section through a small artery and vein of the mucous membrane of the epiglottis of a child. Magnified about 350 diameters. (Klein and Noble Smith.)



A. Artery, showing the nucleated endothelium, *e*, which lines it: the vessel being contracted, the endothelial cells appear very thick. Underneath the endothelium is the wavy elastic intima. The chief part of the wall of the vessel is occupied by the circular muscle-coat *m*: the staff-shaped nuclei of the muscle-cells are well seen. Outside this is *a*, part of the adventitia. This is composed of bundles of connective-tissue fibres, shown in section, with the nuclei of the connective-tissue corpuscles. The adventitia gradually merges into the surrounding connective tissue. V. Vein showing a thin endothelial membrane, *e*, raised accidentally from the intima, which on account of its delicacy is seen as a mere line on the media *m*. This latter is composed of a few circular unstriped muscle-cells. *a*. The adventitia, similar in structure to that of an artery.

muscular tissue, being made up of muscle-fibre cells in fine bundles, arranged in lamellæ and disposed circularly around the vessel. These lamellæ vary in number according to the size of the vessel; the very small arteries having only a single layer, and those not larger than one-tenth of a line in diameter three or four layers. It is to this coat that the great thickness of the walls of the artery is mainly due (fig. 59 A *m*). In the larger vessels, as the iliac, femoral, and

of silver. 2. A sub-epithelial layer, consisting of delicate connective tissue with branched cells lying in the interspaces of the tissue. 3. An elastic or fenestrated layer, which consists of an elastic membrane containing a network of elastic fibres, having principally a longitudinal direction and in which, under the microscope, small, elongated apertures or perforations may be seen, giving it a fenestrated appearance. It was therefore called by Henle the *fenestrated membrane*. This membrane forms the chief thickness of the inner coat, and can be separated into several layers, some of which present the appearance of a network of longitudinal elastic fibres, and others present a more membranous character, marked by pale lines having a longitudinal direction. In arteries of less than a line in diameter the sub-epithelial layer consists of a single layer of stellate cells, and the connective tissue is only largely developed in the large-sized vessels. The fenestrated membrane in microscopic arteries is a very thin layer, but in the larger arteries, and especially in the aorta, it has a very considerable thickness.

The *middle coat* (*tunica media*) is distinguished from the inner by its colour and by the transverse arrangement of its fibres, in contradistinction to the longitudinal direction of those of the inner coat. It consists principally of

carotid, elastic fibres unite to form lamellæ, which alternate with the layers of muscular fibre and are united by elastic fibres which pass between the muscular bundles. In the largest arteries, as the aorta and innominate, the amount of elastic tissue is very considerable. In these vessels also bundles of white connective tissue have been found in small quantities in the middle coat. The muscle-fibre cells of which the middle coat is made up are about  $\frac{1}{500}$  of an inch in length and contain well-marked, rod-shaped nuclei, which are often slightly curved.

The *external coat (tunica adventitia)* consists mainly of fine and closely felted bundles of white connective tissue, but also contains elastic fibres in all but the smallest arteries. The elastic tissue is much more abundant next the tunica

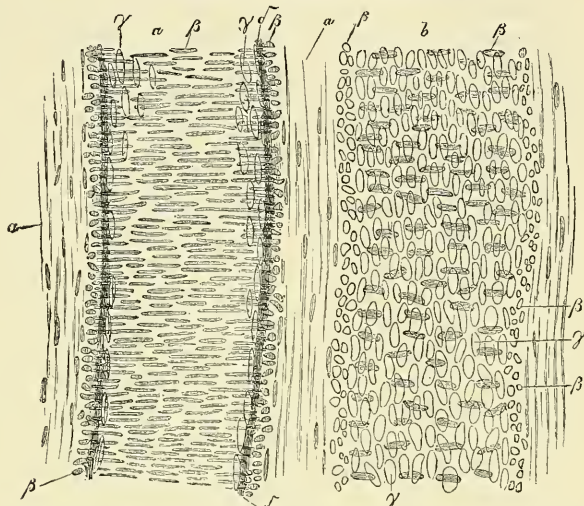
media, and it is sometimes described as forming here, between the adventitia and media, a special layer, the *tunica elastica externa* of Henle. This layer is most marked in arteries of medium size. In the largest vessels the external coat is relatively thin; but in small arteries it is of greater proportionate thickness. In the smaller arteries it consists of a single layer of white connective tissue and elastic fibres; while in the smallest arteries, just above the capillaries, the elastic fibres are wanting, and the connective tissue, of which the coat is composed, becomes more homogeneous the nearer it approaches the capillaries, and is gradually reduced to a thin membranous envelope, which finally disappears.

Some arteries have extremely thin coats in proportion to their size; this is especially the case in those situated in the cavity of the cranium and spinal canal, the difference depending on the greater thinness of the external and middle coats.

The arteries, in their distribution throughout the body, are included in a thin fibro-areolar investment, which forms what is called their *sheath*. In the limbs this is usually formed by a prolongation of the deep fascia; in the upper part of the thigh it consists of a continuation downwards of the transversalis and iliac fasciæ of the abdomen; in the neck, of a prolongation of the deep cervical fascia. The included vessel is loosely connected with its sheath by a delicate areolar tissue; and the sheath usually encloses the accompanying veins, and sometimes a nerve. Some arteries, as those in the cranium, are not included in sheaths.

All the larger arteries are supplied with blood-vessels like the other organs of the body; they are called the *vasa vasorum*. These nutrient vessels arise from a branch of the artery or from a neighbouring vessel, at some considerable distance from the point at which they are distributed; they ramify in the loose areolar tissue connecting the artery with its sheath, and are distributed to the external coat, but do not, in man, penetrate the other coats; though in some of

FIG. 60.—Longitudinal section of artery and vein.



An artery from the mesentery of a child, '062"', and *b*, vein '067"' in diameter, treated with acetic acid and magnified 350 times. *a*. Tunica adventitia, with elongated nuclei. *b*. Nuclei of the contractile fibre cells of the tunica media, seen partly from the surface, partly apparent in transverse section. *gamma*. Nuclei of the endothelial cells. *delta*. Elastic longitudinal fibrous coat.



the larger mammals some few vessels have been traced into the middle coat. Minute veins serve to return the blood from these vessels; they empty themselves into the *venæ comites* in connection with the artery. Lymphatic vessels and lymphatic spaces are also present in the outer coat.

Arteries are also supplied with nerves, which are derived chiefly from the sympathetic, but partly from the cerebro-spinal system. They form intricate plexuses upon the surfaces of the larger trunks, and run along the smaller branches as single filaments or bundles of filaments, which twist around the vessel and unite with each other in a plexiform manner. The branches derived from these plexuses penetrate the external coat and are principally distributed to the muscular tissue of the middle coat, and thus regulate, by causing the contraction and relaxation of this tissue, the amount of blood sent to any part.

**The Capillaries.**—The smaller arterial branches (excepting those of the cavernous structure of the sexual organs, of the spleen, and in the uterine placenta) terminate in a network of vessels which pervade nearly every tissue of the body. These vessels, from their minute size, are termed capillaries (*capillus*, a 'hair'). They are interposed between the smallest branches of the arteries and the commencing veins, constituting a network, the branches of which maintain the same diameter throughout; the meshes of the network being more uniform in shape and size than those formed by the anastomoses of the small arteries and veins.

The *diameter* of the capillaries varies in the different tissues of the body, their usual size being about  $\frac{1}{30000}$  of an inch. The smallest are those of the brain, and the mucous membrane of the intestines; and the largest those of the skin and the marrow of bone, where they are stated to be as large as  $\frac{1}{12000}$  of an inch. The *form* of the capillary net varies in the different tissues, the meshes being generally rounded or elongated. The *rounded form of mesh* is most common, and prevails where there is a dense network, as in the lungs, in most glands and mucous membranes, and in the cutis; here the meshes are more or less angular, sometimes nearly quadrangular, or polygonal; more frequently irregular.

*Elongated meshes* are observed in the bundles of fibres and tubes composing muscles and nerves, the meshes being usually of a parallelogram form, the long axis of the mesh running parallel with the long axis of the nerve and fibre. Sometimes the capillaries have a *looped* arrangement; a single vessel projecting from the common network and returning after forming one or more loops, as in the papillæ of the tongue and skin. The number of the capillaries, and the size of the meshes, determine the degree of vascularity of a part. The closest network and the smallest interspaces are found in the lungs and in the choroid coat of the eye. In these situations the interspaces are smaller than the capillary vessels themselves. In the kidney, in the conjunctiva, and in the cutis the interspaces are from three to four times as large as the capillaries which form them; and in the brain from eight to ten times as large as the capillaries in their long diameter, and from four to six times as large in their transverse diameter. In the adventitia of arteries the width of the meshes is ten times that of the capillary vessels. As a general rule, the more active the function of the organ, the closer is its capillary net and the larger its supply of blood; the meshes of the network being very narrow in all growing parts, in the glands and in the mucous membranes; wider in bones and ligaments, which are comparatively inactive; and nearly altogether absent in tendons, in which very little organic change occurs after their formation.

**Structure.**—The walls of the capillaries consist of a fine, transparent, epithelial layer, composed of cells joined edge to edge by an interstitial cement-substance, and continuous with the endothelial cells which line the arteries and veins. When stained with nitrate of silver the edges which bound the epithelial cells are brought into view (fig. 61). These cells are of large size and of an irregular polygonal or lanceolate shape, each containing an oval nucleus which may be brought into view by carmine or logwood. Between their edges, at various points of their meeting, roundish dark spots are sometimes seen, which have



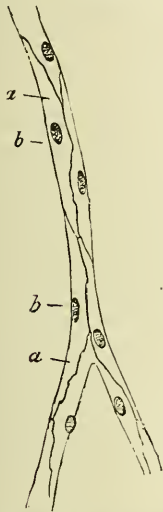
been described as stomata, though they are closed by intercellular substance. They have been believed to be the situation through which the white corpuscles of the blood, when migrating from the blood-vessels, emerge; but this view, though probable, is not universally accepted.

Kolossoff, a Russian observer, describes these cells as having a rather more complex structure. He states that they consist of two parts: of hyaline ground-plates and of a protoplasmic granular part, in which is embedded the nucleus, on the outside of the ground-plates. This hyaline internal coat of the capillaries does not form a complete membrane, but consists of 'plates' which are inelastic, and though in contact with each other, are not continuous; when therefore the capillaries are subjected to intra-vascular pressure, the plates become separated from each other; the protoplasmic portions of the cells, on the other hand, are united together.

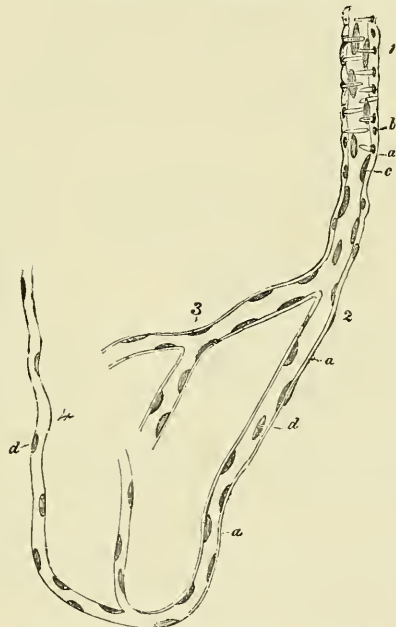
In many situations a delicate sheath or envelope of branched nucleated connective-tissue cells is found around the simple capillary tube, particularly in the

FIG. 62.—Finest vessels on the arterial side. From the human brain. Magnified 300 times.

FIG. 61.—Capillaries from the mesentery of a guinea-pig after treatment with solution of nitrate of silver.



*a.* Cells. *b.* Their nuclei.



1. Smallest artery. 2. Transition vessel. 3. Coarser capillaries. 4. Finer capillaries. *a.* Structureless membrane still with some nuclei, representative of the tunica adventitia. *b.* Nuclei of the muscular fibre-cells. *c.* Nuclei within the small artery, perhaps appertaining to an endothelium. *d.* Nuclei in the transition vessels.

larger ones; and in other places, especially in the glands, the capillaries are invested with retiform lymphatic tissue; and again, in other situations, as the pia mater of the brain and cord, and in the retina, the capillaries are invested with a sheath composed of a delicate epithelial membrane.

In the largest capillaries (which ought, perhaps, to be described rather as the smallest arteries) there is, outside the epithelial layer, a muscular layer, consisting of contractile fibre-cells, arranged transversely, as in the tunica media of the larger arteries (fig. 62).

The **veins**, like the arteries, are composed of three coats—internal, middle, and external; and these coats are, with the necessary modifications, analogous to the coats of the arteries; the internal being the epithelial, the middle the muscular, and the external the connective or areolar. The main difference

between the veins and the arteries is in the comparative weakness of the middle coat of the former, and to this it is due that the veins do not stand open when divided, as the arteries do, and that they are passive rather than active organs of the circulation.

In the veins immediately above the capillaries the three coats are hardly to be distinguished. The epithelium is supported on an outer membrane separable into two layers, the outer of which is the thicker, and consists of a delicate, nucleated membrane (adventitia), while the inner is composed of a network of longitudinal elastic fibres (media). In the veins next above these in size (one-fifth of a line according to Kölliker) a muscular layer and a layer of circular fibres can be traced, forming the middle coat, while the elastic and connective elements of the outer coat become more distinctly perceptible. In the middle-sized veins the typical structure of these vessels becomes clear. The epithelium is of the same character as in the arteries, but its cells are more oval and less fusiform. It is supported by a connective-tissue layer, consisting of a delicate network of branched cells, and external to this is a layer of longitudinal elastic fibres, but seldom any appearance of a fenestrated membrane. This constitutes the *internal* coat. The *middle* coat is composed of a thick layer of connective tissue with elastic fibres, intermixed, in some veins, with a transverse layer of muscular fibres. The white fibrous element is in considerable excess, and the elastic fibres are in much smaller proportion in the veins than in the arteries. The *outer* coat consists of areolar tissue, as in the arteries, with longitudinal elastic fibres. In the largest veins the outer coat is from two to five times thicker than the middle coat, and contains a large number of longitudinal muscular fibres. This is most distinct in the inferior vena cava, especially at the termination of this vein in the heart, in the trunks of the hepatic veins, in all the large trunks of the vena portæ, in the splenic, superior mesenteric, external iliac, renal and azygos veins. In the renal and portal veins it extends through the whole thickness of the outer coat, but in the other veins mentioned a layer of connective and elastic tissue is found external to the muscular fibres. All the large veins which open into the heart are covered for a short distance with a layer of striped muscular tissue continued on to them from the heart. Muscular tissue is wanting—(1) in the veins of the maternal part of the placenta; (2) in the venous sinuses of the dura mater and the veins of the pia mater of the brain and spinal cord; (3) in the veins of the retina; (4) in the veins of the cancellous tissue of bones; (5) in the venous spaces of the corpora cavernosa. The veins of the above-mentioned parts consist of an internal epithelial lining supported on one or more layers of areolar tissue. The internal and external jugular veins and the subclavian vein are said to contain either no muscular fibres at all, or at all events only a slight amount in their middle coat.

Most veins are provided with valves, which serve to prevent the reflux of the blood. They are formed by a reduplication of the inner coat, strengthened by connective tissue and elastic fibres, and are covered on both surfaces with epithelium, the arrangement of which differs on the two surfaces. On the surface of the valve next the wall of the vein, the cells are arranged transversely; whilst on the other surface, over which the current of blood flows, the cells are arranged vertically in the direction of the current. Their form is semilunar. They are attached by their convex edge to the wall of the vein; the concave margin is free, directed in the course of the venous current, and lies in close apposition with the wall of the vein as long as the current of blood takes its natural course; if, however, any regurgitation takes place, the valves become distended, their opposed edges are brought into contact, and the current is interrupted. Most commonly two such valves are found placed opposite one another, more especially in the smaller veins or in the larger trunks at the point where they are joined by smaller branches; occasionally there are three and sometimes only one. The wall of the vein on the cardiac side of the point of attachment of each segment of the valve is expanded into a pouch or sinus, which gives to the vessel, when

injected or distended with blood, a knotted appearance. The valves are very numerous in the veins of the extremities, especially of the lower extremities, these vessels having to conduct the blood against the force of gravity. They are absent in the very small veins, i.e. those less than  $\frac{1}{12}$  of an inch in diameter, also in the venæ cavæ, the hepatic veins, portal vein and its branches, the renal, uterine, and ovarian veins. A few valves are found in the spermatic veins, and one also at their point of junction with the renal vein and inferior vena cava respectively. The cerebral and spinal veins, the veins of the cancellated tissue of bone, the pulmonary veins, and the umbilical vein and its branches, are also destitute of valves. They are occasionally found, few in number, in the venæ azygos and intercostal veins.

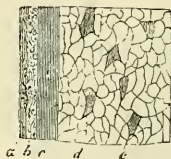The veins are supplied with nutrient vessels, *vasa vasorum*, like the arteries. Nerves also are distributed to them in the same manner as to the arteries, but in much less abundance.

The **lymphatic** vessels, including in this term the lacteal vessels, which are identical in structure with them, are composed of three coats. The *internal* is an epithelial and elastic coat. It is thin, transparent, slightly elastic, and ruptures sooner than the other coats. It is composed of a layer of elongated epithelial cells with serrated margins, by which the adjacent cells are dovetailed into one another. These are supported on a single layer of longitudinal elastic fibres. The *middle* coat is composed of smooth muscular and fine elastic fibres, disposed in a transverse direction. The *external*, or fibro-areolar, coat consists of filaments of connective tissue, intermixed with smooth muscular fibres, longitudinally or obliquely disposed. It forms a protective covering to the other coats, and serves to connect the vessel with the neighbouring structures. The above description applies only to the larger lymphatics; in the smaller vessels there is no muscular or elastic coat, and their structure consists only of a connective-tissue coat, lined by epithelium. The thoracic duct (fig. 63) is a somewhat more complex structure than the other lymphatics; it presents a distinct sub-epithelial layer of branched corpuscles, similar to that found in the arteries, and in the middle coat is a layer of connective tissue with its fibres arranged longitudinally. The lymphatics are supplied by nutrient vessels, which are distributed to their outer and middle coats; but no nerves have at present been traced into them.

The lymphatics are very generally provided with valves, which assist materially in effecting the circulation of the fluid they contain. These valves are formed of a thin layer of fibrous tissue, lined on both surfaces by epithelium, which presents the same arrangement upon the two surfaces as was described in connection with the valves of veins. Their form is semilunar; they are attached by their convex edge to the sides of the vessel, the concave edge being free and directed along the course of the contained current. Usually two such valves, of equal size, are found opposite one another; but occasionally exceptions occur, especially at or near the anastomoses of lymphatic vessels. Thus, one valve may be of very rudimentary size and the other increased in proportion.

The valves in the lymphatic vessels are placed at much shorter intervals than in the veins. They are most numerous near the lymphatic glands, and they are found more frequently in the lymphatics of the neck and upper extremity than in the lower. The wall of the lymphatics immediately above the point of attachment of each segment of a valve is expanded into a pouch or sinus, which gives to these vessels, when distended, the knotted or beaded appearance which they

FIG. 63.—Transverse section through the coats of the thoracic duct of man. Magnified 30 times.



a. Epithelium, striated lamella, and inner elastic coat. b. Longitudinal connective tissue of the middle coat. c. Transverse muscles of the same. d. Tunica adventitia, with e, the longitudinal muscular fibres.



present. Valves are wanting in the vessels composing the plexiform network in which the lymphatics usually originate on the surface of the body.

**Origin of Lymphatics.**—The finest visible lymphatic vessels (lymphatic capillaries) form a plexiform network in the tissues and organs, and they consist of a single layer of epithelial plates, with more or less sinuous margins. These vessels commence in an intercommunicating system of clefts or spaces in the connective tissue of the different organs, which have no complete epithelial lining. They have been named the *rootlets* of the lymphatics, and are identical with the spaces in which the connective-tissue corpuscles are contained. This then is properly regarded as one method of their commencement, where the lymphatic vessels are apparently continuous with spaces in the connective tissue, and Klein has described and figured a direct communication between these spaces and the

lymphatic vessel.\* But the lymphatics have also other modes of origin, for the intestinal lacteals commence by closed extremities, though some observers believe that the closed extremity is continuous with a minute network contained in the substance of the villus, through which the lacteal is connected with the epithelial cells covering it. Again, it seems now to be conclusively proved that the serous membranes present stomata or openings between the epithelial cells (fig. 64), by which there is an open communication with the lymphatic system and through which the lymph is thought to be pumped by the alternate dilatation and contraction of the serous surface, due to the movements of respiration and circulation, so that the serous and synovial sacs may be regarded, in a certain sense, as large lymph cavities or sinuses.† Von Recklinghausen was the first to observe the passage of milk and other coloured fluids through these stomata on the peritoneal surface of the central tendon of the diaphragm. Again, in most glandular structures the lymphatic capillaries have a lacunar origin. Here they begin in irregular clefts or spaces in the tissue of the part; occupying the penetrating connective tissue and surrounding the lacunæ or tubules of the gland, and in many places separating the capillary network from the alveolus or tubule, so that the interchange between the blood

and the secreting cells of the part must be carried

on through this lymph-space or lacuna. Closely allied to this is the mode of origin of lymphatics in perivascular and perineural spaces. Sometimes a minute artery may be seen to be ensheathed for a certain distance by a lymphatic capillary vessel, which is often many times wider than a blood capillary. These are known as perivascular lymphatics.

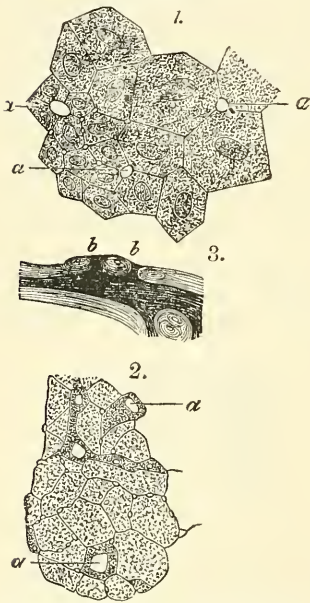
**Terminations of Lymphatics.**—The lymphatics, including the lacteals, discharge their contents into the veins at two points; namely, at the angles of junction of the subclavian and internal jugular veins: on the left side by means of the thoracic duct, and on the right side by the right lymphatic duct. (See description of lymphatics on a subsequent page.)

**Lymphatic glands** (*conglobate glands*) are small oval or bean-shaped bodies,

\* *Atlas of Histology*, pl. viii. fig. xiv.

† The resemblance between lymph and serum led Hewson long ago to regard the serous cavities as sacs into which the lymphatics open. Recent microscopic discoveries confirm this opinion in a very interesting manner.

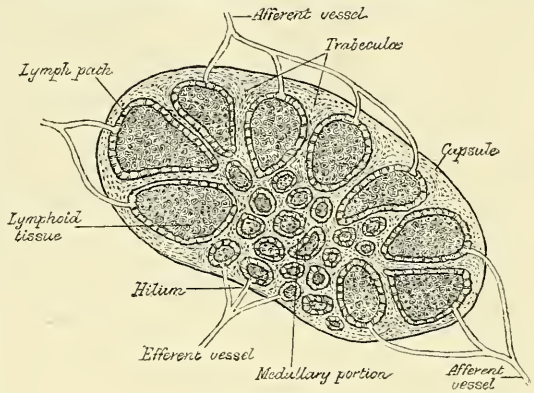
FIG. 64.—Stomata of serous membranes.



1. Epithelium on the under surface of the *centrum tendineum* of the rabbit. *a*. Stomata.
2. Epithelium of the mediastinum of the dog. *a*. Stomata.
3. Section through the pleura of the same animal. *b*. Free orifices of short lateral passages of the lymph-canals. (Copied from Ludwig, Schweigger-Seydell and Dybkowski.)

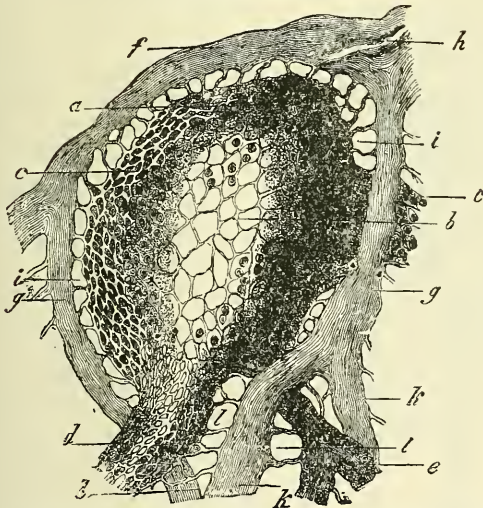
situated in the course of lymphatic and lacteal vessels so that the lymph and chyle pass through them on their way to the blood. They generally present on one side a slight depression—the *hilum*—through which the blood-vessels enter and leave the interior. The efferent lymphatic vessel also emerges from the gland at this spot, while the afferent vessels enter the organ at different parts of the periphery. On section (fig. 65), a lymphatic gland displays two different structures: an external, of lighter colour—the *cortical*; and an internal, darker—the *medullary*. The cortical structure does not form a complete investment, but is deficient at the hilum, where the medullary portion reaches the surface of the gland; so that the efferent vessel is derived directly from the medullary structure, while the afferent vessels empty themselves into the cortical substance.

FIG. 65.—Diagrammatic section of lymphatic gland, showing the course of the lymph.



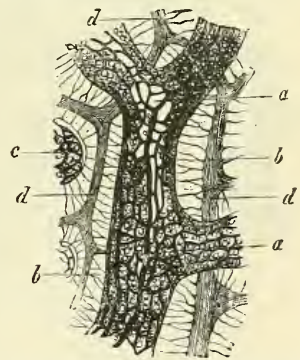
Lymphatic glands consist of (1) a fibrous envelope, or *capsule*, from which a framework of processes (*trabeculae*) proceed inwards, dividing the gland into open

FIG. 66.—Follicle from a lymphatic gland of the dog, in vertical section.



a. Reticular sustentacular substance of the more external portion, b, of the more internal, and c, of the most external and most finely webbed part on the surface of the follicle. d. Origin of a large lymph-tube. e. Of a smaller one. f. Capsule. g. Septa. h. Vas afferens. i. Investing space of the follicle, with its retinacula. k. One of the divisions of the septa. l. Attachment of the lymph-tubes to the septa.

FIG. 67.—From the medullary substance of an inguinal gland of the ox. (After His.)



a. Lymph-tube, with its complicated system of vessels. b. Retinacula stretched between the tube and the septa. c. Portion of another lymph-tube. d. Septa.

spaces (*alveoli*) freely communicating with each other; (2) a quantity of adenoid tissue occupying these spaces without completely filling them; (3) a free supply of blood-vessels, which are supported on the trabeculae; and (4) the *afferent* and *efferent* vessels. Little is known of the nerves, though Kölliker describes some fine nervous filaments passing into the hilum.

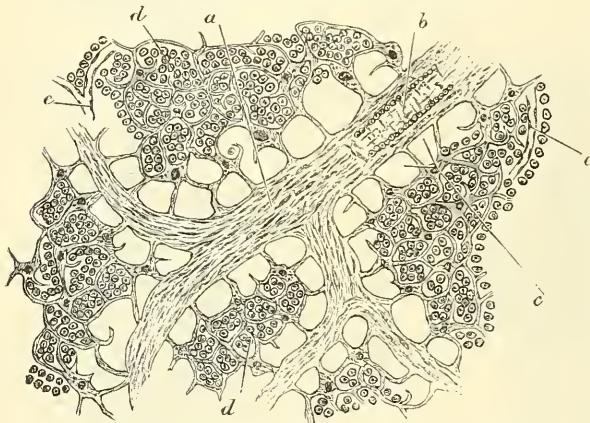
The *capsule* is composed of a layer of connective tissue, and from its internal surface are given off a number of membranous septa or lamellae, consisting, in



man, of connective tissue, with a small admixture of muscular fibre-cells; but in many of the lower animals composed almost entirely of involuntary muscular fibre. They pass inwards, radiating towards the centre of the gland, for a certain distance, that is to say, for about one-third or one-fourth of the space between the circumference and the centre of the gland. They thus divide the outer part of its interior into a number of oval compartments, or *alveoli* (fig. 65). This is the cortical portion of the gland. After having penetrated into the gland for some distance, these septa break up into a number of smaller trabeculae, which form flattened bands or cords, interlacing with each other in all directions, forming in the central part of the organ a number of intercommunicating spaces, also called *alveoli*. This is the medullary portion of the gland, and the spaces or alveoli in it not only freely communicate with each other, but also with the alveoli of the cortical portion. In these alveoli or spaces (fig. 66) is contained the proper gland-substance or lymphoid tissue. The gland-pulp does not, however, completely fill the alveolar spaces, but leaves, between its outer margin and the trabeculae forming the alveoli, a channel or space of uniform width throughout. This is termed the *lymph-path* or *lymph-sinus* (fig. 68). Running across it are a number of trabeculae of retiform connective tissue, the fibres of which are, for the most part, covered by ramified cells. This tissue appears to serve the purpose of maintaining the gland-pulp in the centre of the space in its proper position.

On account of the peculiar arrangement of the framework of the organ, the gland-pulp in the cortical portion is disposed in the form of nodules, and in the

FIG. 68.—Section of lymphatic-gland tissue.



a. Trabeculae. b. Small artery in substance of same. c. Lymph-paths.  
d. Lymph-corpuses. e. Capillary plexus.

medullary part in the form of rounded cords. It consists of ordinary lymphoid tissue, being made up of a delicate reticulum of retiform tissue, which is continuous with that in the lymph-paths, but marked off from it by a closer reticulation; in its meshes are closely packed lymph-corpuses, traversed by a dense plexus of capillary blood-vessels.

The *afferent vessels*, as above stated, enter at all parts of the periphery of the gland, and after branching and forming a dense plexus in the sub-

stance of the capsule open into the lymph-sinuses of the cortical part. In doing this, they lose all their coats except their epithelial lining, which is continuous with a layer of similar cells lining the lymph-paths. In like manner the *efferent vessel* commences from the lymph-sinuses of the medullary portion. The stream of lymph carried to the gland by the afferent vessel thus passes through the plexus in the capsule to the lymph-paths of the cortical portion, where it is exposed to the action of the gland-pulp; flowing through these it enters the paths or sinuses of the medullary portion, and finally emerges from the hilum by means of the efferent vessel. The stream of lymph in its passage through the lymph-sinuses is much retarded by the presence of the reticulum. Hence morphological elements, either normal or morbid, are easily arrested and deposited in the sinuses. This is a matter of considerable importance in connection with the subject of poisoned wounds and the absorption of the poison by the lymphatic system, since by this means septic organisms carried along the lymphatic



vessels may be arrested in the lymph-sinuses of the gland tissue, and thus be prevented from entering the general circulation. The arteries of the gland enter at the hilum and either pass at once to the gland-pulp, to break up into a capillary plexus, or else run along the trabeculae, partly to supply them and partly running across the lymph-paths to assist in forming the capillary plexus of the gland-pulp. This plexus traverses the lymphoid tissue, but does not pass into the lymph-sinuses. From it the veins commence and emerge from the organ at the same place as that at which the artery enters.

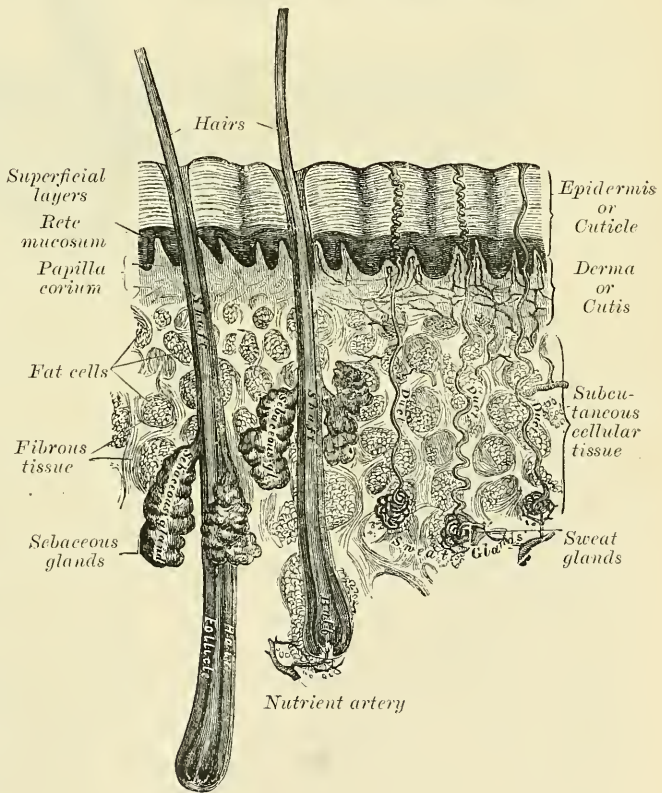
## THE SKIN AND ITS APPENDAGES

The **skin** (fig. 69) is the principal seat of the sense of touch, and may be regarded as a covering for the protection of the deeper tissues; it is also an important excretory and absorbing organ. It consists principally of a layer of vascular tissue, named the *derma*, *corium*, or *cutis vera*, and an external covering of epithelium, termed the *epidermis* or *cuticle*. On the surface of the former layer are the sensitive *papillae*; and within, or embedded beneath it, are certain organs with special functions, namely, the *sweat-glands*, *hair-follicles*, and *sebaceous glands*.

The **epidermis** or **cuticle** (*scarf-skin*) is an epithelial structure belonging to the class of stratified epithelium (fig. 70). It is accurately moulded on the papillary layer of the derma.

It forms a defensive covering to the surface of the true skin, and limits the evaporation of watery vapour from its free surface. It varies in thickness in different parts. In some situations, as in the palms of the hands and soles of the feet, it is thick, hard, and horny in texture. This may be partly due to the fact that these parts are exposed to intermittent pressure, but that this is not the only cause is proved by the fact that the condition exists to a very considerable extent at birth. The more superficial layer of cells, called the *horny layer* (*stratum corneum*) may be separated by maceration from the deeper layers, which are called the *rete mucosum*, and which consist of

FIG. 69.—A sectional view of the skin (magnified).

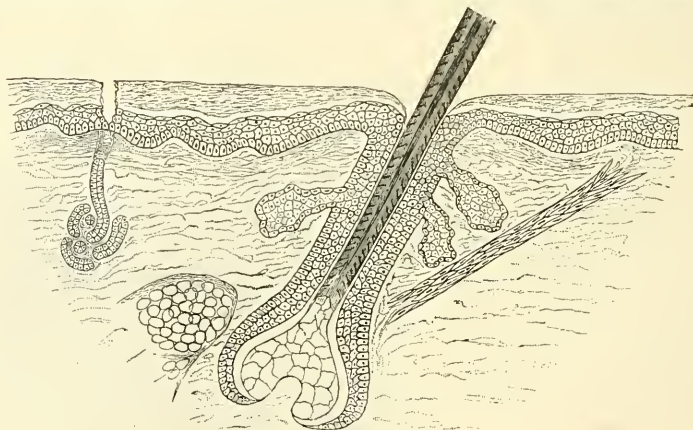


several layers of differently shaped cells. The free surface of the epidermis is marked by a network of linear furrows of variable size, marking out the surface into a number of spaces of polygonal or lozenge-shaped form. Some of these furrows are large, as opposite the flexures of the joints, and correspond to

the folds in the derma produced by their movements. In other situations, as upon the back of the hand, they are exceedingly fine, and intersect one another at various angles; upon the palmar surface of the hand and fingers, and upon the sole of the foot, these lines are very distinct, and are disposed in curves. They depend upon the large size and peculiar arrangement of the papillæ upon which the epidermis is placed. The deep surface of the epidermis is accurately moulded upon the papillary layer of the derma, each papilla being invested by its epidermic sheath; so that when this layer is removed by maceration, it presents on its under surface a number of pits or depressions corresponding to the elevations in the papillæ, as well as the ridges left in the intervals between them. Fine tubular prolongations are continued from this layer into the ducts of the sudoriferous and sebaceous glands.

In structure, the epidermis consists of several layers of epithelial cells, agglutinated together and having a laminated arrangement. These several layers may be described as composed of four different strata from within outwards: (1) the *rete Malpighii*, composed of several layers of epithelial cells, of which the deepest layer is elongated in figure and placed perpendicularly on the surface of the corium, their lower ends being denticulate, to fit into corresponding denticulations of the true skin; while the succeeding laminæ consist of cells of a more rounded or polyhedral form, the contents of which

FIG. 70.—Microscopic section of skin, showing the epidermis and derma: a hair in its follicle: the arrector pili muscle: sebaceous and sudoriferous glands.



are soft, opaque, granular, and soluble in acetic acid. They are often marked on their surfaces with ridges and furrows, and are covered with numerous fibrils, which connect the surfaces of the cells: these are known as *prickle cells* (see page 14). (2) Immediately superficial to these is a single layer of flattened, spindle-shaped cells, the *granular layer*, which contain granules that become deeply stained in hæmatoxylin. They are supposed to be cells in a transitional stage between the protoplasmic cells of the rete Malpighii and the horny cells of the superficial layers. (3) Above this layer, the cells become indistinct, and appear, in sections, to form a homogeneous or dimly striated membrane, composed of closely packed scales, in which traces of a flattened nucleus may be found. It is called the *stratum lucidum*. (4) As these cells successively approach the surface by the development of fresh layers from beneath, they assume a flattened form; from the evaporation of their fluid contents, and consist of many layers of horny epithelial scales in which no nucleus is discernible, forming the *stratum corneum*. These cells apparently become changed in their chemical composition, as they are now unaffected by acetic acid. The deepest layer of the rete Malpighii is separated from the papillæ by an apparently homogeneous basement-membrane, which is most distinctly brought into view in specimens prepared with chloride of gold. This, according to Klein, is merely the deepest portion of the epithelium, and is



'made up of the basis of the individual cells, which have undergone a chemical and morphological alteration.' The black colour of the skin in the negro, and the tawny colour among some of the white races, is due to the presence of pigment in the cells of the cuticle. This pigment is more especially distinct in the cells of the deeper layer, or rete mucosum, and is similar to that found in the cells of the pigmentary layer of the retina. As the cells approach the surface and desiccate, the colour becomes partially lost.

The **derma, corium, or cutis vera**, is tough, flexible, and highly elastic, in order to defend the parts beneath from violence.

It varies in thickness, from a quarter of a line to a line and a half, in different parts of the body. Thus it is very thick in the palms of the hands and soles of the feet; thicker on the posterior aspect of the body than the front, and on the outer than the inner side of the limbs. In the eyelids, scrotum, and penis it is exceedingly thin and delicate. The skin generally is thicker in the male than in the female, and in the adult than in the child.

The corium consists of fibrous connective tissue, with a varying amount of elastic fibres and numerous blood-vessels, lymphatics, and nerves. The fibro-areolar tissue forms the framework of the cutis, and is differently arranged in different parts, so that it is usual to describe it as consisting of two layers: the deeper or *reticular* layer, and the superficial or *papillary* layer. Unstripped muscular fibres are found in the superficial layers of the corium, wherever hairs are found; and in the subcutaneous areolar tissue of the scrotum, penis, labia majora of the female, and the nipples. In the latter situation the fibres are arranged in bands, closely reticulated and disposed in superimposed laminae.

The *reticular* layer consists of strong interlacing fibrous bands, composed chiefly of the white variety of fibrous tissue, but containing, also, some fibres of the yellow elastic tissue, which vary in amount in different parts, and connective-tissue corpuscles, which are often to be found flattened against the white fibrous tissue bundles. Towards the attached surface the fasciculi are large and coarse, and the areolæ which are left by their interlacement are large, and occupied by adipose tissue and sweat-glands. Below this the elements of the skin become gradually blended with the subcutaneous areolar tissue, which, except in a few situations, contains fat. Towards the free surface the fasciculi are much finer, and their mode of interlacing close and intricate.

The *papillary layer* is situated upon the free surface of the *reticular layer*; it consists of numerous small, highly sensitive, and vascular eminences, the *papillæ*, which rise perpendicularly from its surface, and form the essential element of the organ of touch. The papillæ are conical-shaped eminences, having a round or blunted extremity, occasionally divided into two or more parts and connected by a thin base with the free surface of the corium. Their average length is about  $\frac{1}{100}$  of an inch, and they measure at their base  $\frac{1}{50}$  of an inch in diameter. On the general surface of the body, more especially in those parts which are endowed with slight sensibility, they are few in number, short, exceedingly minute, and irregularly scattered over the surface; but in some situations, as upon the palmar surface of the hands and fingers, upon the plantar surface of the feet and toes, and around the nipple, they are long, of large size, closely aggregated together, and arranged in parallel curved lines, forming the elevated ridges seen on the free surface of the epidermis. In these ridges the larger papillæ are arranged in a double row, with smaller papillæ between them; and these rows are subdivided into small square-shaped spaces by short transverse furrows, regularly disposed; in the centre of each of these transverse furrows is the minute orifice of the duct of a sweat-gland. No papillæ exist in the grooves between the ridges. In structure the papillæ consist of very small and closely interlacing bundles of finely fibrillated tissue, with a few elastic fibres.

The *arteries* supplying the skin form a network in the subcutaneous tissue, from which branches are given off to supply the sweat-glands, the hair-follicles, and the fat. Other branches are given off which form a plexus immediately beneath the corium; from this, fine capillary vessels pass into the papillæ,



forming, in the smaller papillæ, a single capillary loop, but in the larger, a more or less convoluted vessel. There are numerous *lymphatics* supplied to the skin, which form two networks, superficial and deep, communicating with each other and with those of the subcutaneous tissue by oblique branches. They originate in the cell-spaces of the tissue.

The *nerves* of the skin terminate partly in the epidermis and partly in the cutis vera. The former form a dense plexus in the superficial layer of the corium, which extends horizontally and gives off numerous fibrils; these are prolonged into the epidermis and terminate between the cells in bulbous extremities; or, according to more recent observations, in the deep epithelial cells themselves. The latter terminate in end-bulbs, touch-corpuscles, or Pacinian bodies, in the manner already described; and, in addition to these, a considerable number of fibrils are distributed to the hair-follicles, which are said to entwine the follicle in a circular manner. Other nerve-fibres are supplied to the plain muscular tissues of the hair-muscles (*arrectores pili*) and to the muscular coat of the blood-vessels. These are probably non-medullated fibres.

The **appendages of the skin** are the nails, the hairs, the sudoriferous and sebaceous glands, and their ducts.

The nails and hairs are peculiar modifications of the epidermis, consisting essentially of the same cellular structure as that tissue.

The **nails** are flattened, elastic structures of a horny texture, placed upon the dorsal surface of the terminal phalanges of the fingers and toes. Each nail is convex on its outer surface, concave within, and is implanted by a portion, called the *root*, into a groove in the skin; the exposed portion is called the *body*, and the anterior extremity the *free edge*. The nail has a very firm adhesion to the cutis, being accurately moulded upon its surface, as the epidermis is in other parts. The part of the cutis beneath the body and root of the nail is called the *matrix*, because it is the part from which the nail is produced. Corresponding to the body of the nail, the matrix is thick, and covered with large, highly vascular papillæ, arranged in longitudinal rows, the colour of which is seen through the transparent tissue. Behind this, near the root of the nail, the papillæ are small, less vascular, and have no regular arrangement, and here the tissue of the nail is somewhat more opaque; hence this portion is of a whiter colour, and is called the *lunula* on account of its shape.

The cuticle, as it passes forwards on the dorsal surface of the finger or toe, is attached to the surface of the nail, a little in advance of its root; at the extremity of the finger it is connected with the under surface of the nail a little behind its free edge. The cuticle and horny substance of the nail (both epidermic structures) are thus directly continuous with each other. The nails, in structure, consist of cells having a laminated arrangement, and these are essentially similar to those composing the epidermis. The deepest layer of cells, which lie in contact with the papillæ of the matrix, are of elongated form, arranged perpendicularly to the surface and provided with nuclei; those which succeed them are of a rounded or polygonal form, the more superficial ones becoming broad, thin, and flattened, and so closely compacted as to make the limits of each cell very indistinct. It is by the successive growth of new cells at the root and under surface of the body of the nail that it advances forwards and maintains a due thickness, whilst, at the same time, the growth of the nail in the proper direction is secured. As these cells in their turn become displaced by the growth of new cells, they assume a flattened form, lose their nuclei, and finally become closely compacted together into a firm, dense, horny texture. In *chemical composition* the nails resemble epidermis. According to Mulder, they contain a somewhat larger proportion of carbon and sulphur.

The **hairs** are peculiar modifications of the epidermis, and consist essentially of the same structure as that membrane. They are found on nearly every part of the surface of the body, excepting the palms of the hands, soles of the feet, and

the penis. They vary much in length, thickness, and colour in different parts of the body and in different races of mankind. In some parts, as in the skin of the eyelids, they are so short as not to project beyond the follicles containing them; in other parts, as upon the scalp, they are of considerable length; again, in other parts, as the eyelashes, the hairs of the pubic region, and the male whiskers and beard, they are remarkable for their thickness. The hairs generally present a cylindrical or more or less flattened form and a reniform outline upon transverse section.

A hair consists of a *root*, the part implanted in the skin; the *shaft* or *stem*, the portion projecting from its surface; and the *point*.

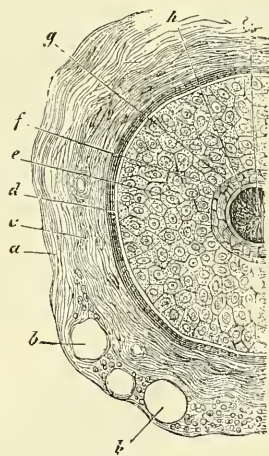
The *root of the hair* presents at its extremity a bulbous enlargement, which is whiter in colour and softer in texture than the shaft, and is lodged in a follicular involution of the epidermis called the *hair-follicle*. When the hair is of considerable length the follicle extends into the subcutaneous cellular tissue. The hair-follicle commences on the surface of the skin with a funnel-shaped opening, and passes inwards in an oblique direction to become dilated at its deep extremity, to correspond with the bulbous condition of the hair which it contains. It has opening into it, near its free extremity, the orifices of the ducts of one or more sebaceous glands (fig. 70). At the bottom of each hair-follicle is a small conical vascular eminence or papilla, similar in every respect to those found upon the surface of the skin; it is continuous with the dermic layer of the follicle, is highly vascular, and probably supplied with nervous fibrils; this is the part through which material is supplied for the production and constant growth of the hair. In structure the hair-follicle consists of two coats—an outer or *dermic*, and an inner or *epidermic*.

The *outer* or *dermic* coat is formed mainly of fibrous tissue; it is continuous with the corium, is highly vascular, and supplied by numerous minute nervous filaments. It consists of three layers (fig. 71). The most internal, next the cuticular lining of the follicle, consists of a hyaline basement-membrane having a glassy, transparent appearance, which is well marked in the larger hair-follicles, but is not very distinct in the follicles of minute hairs. It is continuous with the basement-membrane of the surface of the corium. External to this is a layer of spindle-shaped cells, with oblong nuclei, arranged in a circular manner around the follicle, but reaching only as high as the entrance of the ducts of the sebaceous glands. Externally is a thick layer of connective tissue, arranged in longitudinal bundles, in which are contained the blood-vessels and nerves. This is continuous above with the corium.

The *inner* or *epidermic* layer is closely adherent to the root of the hair, so that when the hair is plucked from its follicle this layer most commonly adheres to it and forms what is called the *root-sheath*. It consists of two strata named respectively the *outer* and *inner root-sheath*; the former of these corresponds with the Malpighian layer of the epidermis, and resembles it in the rounded form and soft character of its cells; at the bottom of the hair-follicle these cells become continuous with those of the root of the hair. The *inner* root-sheath consists of a delicate cuticle next the hair; then of one or two layers of horny, flattened, nucleated cells, known as *Huxley's layer*; and finally of a single layer of non-nucleated, horny, cubical cells, called *Henle's layer*.

The hair-follicle contains the root of the hair, which terminates in a bulbous

FIG. 71.—Transverse section of hair-follicle.



1. Dermic coat of follicle. 2. Epidermic coat or root-sheath. *a*. Outer layer of dermic coat, with blood-vessels. *b, b*. Vessels cut across. *c*. Middle layer. *d*. Inner or hyaline layer. *e*. Outer root-sheath. *f, g*. Inner root-sheath. *h*. Cuticle of root-sheath. *i*. Hair. (From Quain's 'Anatomy,' Biesiadecki.)



extremity, and is excavated so as to exactly fit the papilla from which it grows. The bulb is composed of polyhedral epithelial cells, which as they pass upwards into the root of the hair become elongated and spindle-shaped, except some in the centre which remain polyhedral. Some of these latter cells contain pigment-granules, which give rise to the colour of the hair. It occasionally happens that these pigment-granules completely fill the cells in the centre of the bulb; this gives rise to the dark tract of pigment often found, of greater or less length, in the axis of the hair.

The *shaft of the hair* consists of a central pith or medulla, the fibrous part of the hair, and the cortex externally. The *medulla* occupies the centre of the shaft and ceases towards the point of the hair. It is usually wanting in the fine hairs covering the surface of the body, and commonly in those of the head. It is more opaque and deeper coloured when viewed by transmitted light than the fibrous part; but when viewed by reflected light it is white. It is composed of rows of polyhedral cells, which contain air-bubbles. The *fibrous* portion of the hair constitutes the chief part of the shaft; its cells are elongated and unite to form flattened fusiform fibres. Between the fibres are found minute spaces which contain either pigment-granules in dark hair, or minute air-bubbles in white hair. In addition to this there is also a diffused pigment contained in the fibres. The cells which form the *cortex* of the hair consist of a single layer which surrounds those of the fibrous part; they are converted into thin, flat scales, having an imbricated arrangement.

Connected with the hair-follicles are minute bundles of involuntary muscular fibres, termed the *arrectores pili*. They arise from the superficial layer of the corium, and are inserted into the outer surface of the hair-follicle, below the entrance of the duct of the sebaceous gland. They are placed on the side towards which the hair slopes, and by their action elevate the hair (fig. 70).

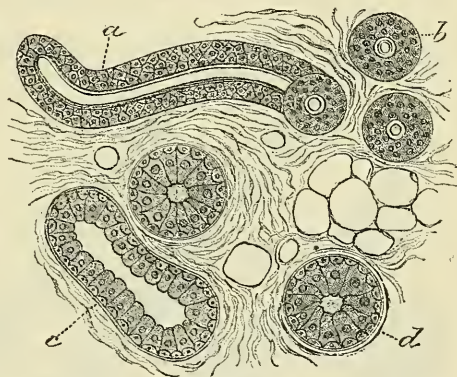
The **sebaceous glands** are small, sacculated, glandular organs, lodged in the substance of the corium. They are found in most parts of the skin, but are most abundant in the scalp and face: they are also very numerous around the apertures of the anus, nose, mouth, and external ear; but are wanting in the palms of the hands and soles of the feet. Each gland consists of a single duct, more or less capacious, which terminates in a cluster of small secreting pouches or saccules. The sacculi connected with each duct vary, as a rule, in number from two to five, but, in some instances, may be as many as twenty. They are composed of a transparent, colourless membrane, enclosing a number of cells. Of these, the outer layer or marginal cells are small, polyhedral, epithelial cells, continuous with the lining cells of the duct. The remainder of the sac is filled with larger cells, containing fat, except in the centre, where the cells have become broken up, leaving a cavity containing their débris and a mass of fatty matter, which constitutes the sebaceous secretion. The orifices of the ducts open most frequently into the hair-follicles, but occasionally upon the general surface, as in the labia minora and the free margin of the lips. On the nose and face the glands are of large size, distinctly lobulated, and often become much enlarged from the accumulation of pent-up secretion. The largest sebaceous glands are those found in the eyelids—the Meibomian glands.

The **sudoriferous** or **sweat glands** are the organs by which a large portion of the aqueous and gaseous materials are excreted by the skin. They are found in almost every part of this structure and are situated in small pits in the deep parts of the corium, or, more frequently, in the subcutaneous areolar tissue, surrounded by a quantity of adipose tissue. They are small, lobular, reddish bodies, consisting of a single convoluted tube, from which the efferent duct proceeds upwards through the corium and cuticle, becomes somewhat dilated at its extremity, and opens on the surface of the cuticle by an oblique valve-like aperture. The efferent duct, as it passes through the epidermis, presents a spiral arrangement, being twisted like a corkscrew, in those parts where the epidermis is thick; where, however, it is thin, the spiral arrangement does not



exist. In the superficial layers of the corium, the duct is straight, but in the deeper layers it is convoluted or even twisted. The spiral course of these ducts is especially distinct in the thick cuticle of the palm of the hand and sole of the foot. The size of the glands varies. They are especially large in those regions where the amount of perspiration is great, as in the axillæ, where they form a thin, mammillated layer of a reddish colour, which corresponds exactly to the situation of the hair in this region; they are large also in the groin. Their number varies. They are most numerous on the palm of the hand, presenting, according to Krause, 2,800 orifices on a square inch of the integument, and are rather less numerous on the sole of the foot. In both of these situations the orifices of the ducts are exceedingly regular, and correspond to the small transverse grooves which intersect the ridges of the papillæ. In other situations they are more irregularly scattered, but in nearly equal numbers, over parts including the same extent of surface. In the neck and back they are least numerous, their number amounting to 417 on the square inch (Krause). Their total number is estimated by the same writer at 2,381,248, and, supposing the aperture of each gland to represent a surface of  $\frac{1}{36}$  of a line in diameter, he calculates that the whole of these glands would present an evaporating surface of about eight square inches. Each gland consists of a single tube intricately convoluted, terminating at one end by a blind extremity, and opening at the other end upon the surface of the skin. In the larger glands this single duct usually divides and subdivides dichotomously; the smaller ducts ultimately terminating in short cæcal pouches, rarely anastomosing. The wall of the duct is thick, the width of the canal rarely exceeding one third of its diameter. The tube, both in the gland and where it forms the excretory duct, consists of two layers—an outer, formed by fine areolar tissue, and an inner layer of epithelium. The external or fibro-cellular coat is thin, continuous with the superficial layer of the corium, and extends only as high as the surface of the true skin. The epithelial lining in the distal part of the coiled tube of the gland proper consists of a single layer of cubical epithelium, supported on a basement-membrane, and beneath it, between the epithelium and the fibro-cellular coat, a layer of plain muscular fibres, arranged longitudinally. In the duct and the proximal part of the coiled

FIG. 72.—Coiled tube of a sweat-gland cut in various directions.



a. Longitudinal section of the proximal part of the coiled tube. b. Transverse section of the same. c. Longitudinal section of the distal part of the coiled tube. d. Transverse section of the same. (From Klein and Noble Smith's 'Atlas of Histology'.)

tube of the gland proper there are two or more layers of polyhedral cells, lined on their internal surface, i.e. next the lumen of the tube, by a delicate membrane or cuticle, and on their outer surface by a limiting membrana propria, but there are no muscular fibres. The epithelium is continuous with the epidermis and with the delicate internal cuticle which is all that is present in the epidermic portion of the tube. When the cuticle is carefully removed from the surface of the cutis, these convoluted tubes of epithelium may be drawn out and form short, thread-like processes on its under surface.

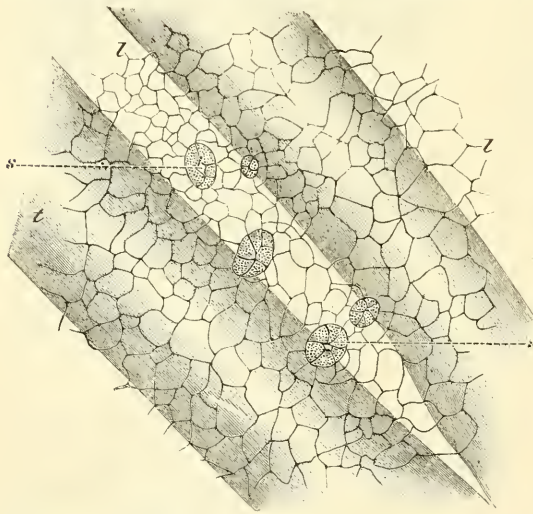
The contents of the smaller sweat-glands are quite fluid; but in the larger glands the contents are semi-fluid and opaque, and contain a number of coloured granules and cells which appear analogous to epithelial cells.

## SEROUS MEMBRANES

The **serous membranes** form shut sacs and may be regarded as lymph-sacs, from which lymphatic vessels arise by stomata or openings between the epithelial cells (see page 58). The sac consists of one portion which is applied to the walls of the cavity which it lines—the *parietal* portion; and another reflected over the surface of the organ or organs contained in the cavity—the *visceral* portion. Sometimes the sac is arranged quite simply, as the tunica vaginalis testis; at others with numerous involutions or recesses, as the peritoneum, in which, nevertheless, the membrane can always be traced continuously around the whole circumference. The sac is completely closed, so that no communication exists between the serous cavity and the parts in its neighbourhood. An apparent exception exists in the peritoneum of the female; for the Fallopian tube opens freely into the peritoneal cavity in the dead subject so that a bristle can be passed from the one into the other. But this communication is closed during life, except at the moment of the passage of the ovum out of the ovary into the tube, as is proved by the fact that no interchange of fluids ever takes place between the two cavities in dropsy of the peritoneum, or in accumulation of fluid in the Fallopian tubes.\* The serous membrane is often supported by a firm, fibrous layer, as is the case with the pericardium, and such membranes are sometimes spoken of as 'fibro-serous.'

The various serous membranes are the peritoneum, lining the cavity of the abdomen; the two pleuræ and the pericardium, lining the lungs and heart respectively; and the tunicae vaginales, surrounding each testicle in the scrotum.† Serous membranes are thin, transparent, glistening structures, lined on their

FIG. 73.—Part of peritoneal surface of the central tendon of diaphragm of rabbit, prepared with nitrate of silver.



s. Stomata. z. Lymph-channels. t. Tendon-bundles. The stomata are surrounded by germinating epithelial cells. (From 'Handbook for the Physiological Laboratory,' Klein.)

inner surface by a single layer of polygonal or pavement epithelial cells, supported on a matrix of fibrous connective tissue, with networks of fine elastic fibres, in which are contained numerous capillaries and lymphatics. On the surface of the epithelium between the cells numerous apertures or interruptions are to be seen. Some of these are stomata, surrounded by a ring of cubical epithelium (see fig. 73), and communicate with a lymphatic capillary; others (*pseudostomata*) are mere interruptions in the epithelial layer, and are occupied by processes of the branched connective-tissue corpuscle of the subjacent tissue or by accumulations of the intercellular cement-substance.

The secretion of these membranes is, in most cases, only sufficient in quantity to moisten the surface, but not to furnish any appreciable quantity of fluid. When a small quantity can

\* The communication between the uterine cavity and the peritoneal sac is not only apparent in the dead subject, but is an anatomical fact, which is established by the continuity of its epithelium with that covering the uterus, Fallopian tubes, and fimbriæ.

† The arachnoid membrane lining the brain and spinal cord was formerly regarded as a serous membrane, but is now no longer classed with them, as it differs from them in structure, and does not form a shut sac as do the other serous membranes.



be collected, it appears to resemble in many respects the lymph, and like that fluid coagulates spontaneously; but when secreted in large quantities, as in dropsy, it is a watery fluid, which gives a precipitate of albumen on boiling.

### SYNOVIAL MEMBRANES

**Synovial membranes**, like serous membranes, are connective-tissue membranes placed between two movable tissues, so as to diminish friction, as between the two articular ends of the bones forming a movable joint; between a tendon and a bone, where the former glides over the latter; and between the skin and various subcutaneous bony prominences.

The synovial membranes are composed essentially of connective tissue, with the cells and fibres of that structure, containing numerous vessels and nerves. It was formerly supposed that these membranes were analogous in structure to the serous membranes, and consisted of a layer of flattened cells on a basement-membrane. No such cells, however, exist, and the only ones found on the surface are irregularly branched connective-tissue corpuscles, similar to those found throughout the tissue. Here and there these cells are collected in patches and present the appearance of epithelium, but do not possess the true characters of an epithelial layer. They are surrounded and held together by an albuminous ground-substance. A further description of the synovial membranes will be found in the descriptive anatomy of the joints.

### MUCOUS MEMBRANE

**Mucous membranes** line all those passages by which the internal parts communicate with the exterior, and are continuous with the skin at the various orifices of the surface of the body. They are soft and velvety, and very vascular, and their surface is coated over by their secretion, *mucus*, which is of a tenacious consistence, and serves to protect them from the foreign substances introduced into the body with which they are brought in contact.

They are described as lining the two tracts—the gastro-pulmonary and the genito-urinary; and all, or almost all, mucous membranes may be classed as belonging to and continuous with the one or the other of these tracts.

The external surfaces of these membranes are attached to the parts which they line by means of connective tissue, which is sometimes very abundant, forming a loose and lax bed, so as to allow considerable movement of the opposed surfaces on each other. It is then termed the *submucous tissue*. At other times it is exceedingly scanty, and the membrane is closely connected to the tissue beneath; sometimes, for example, to muscle, as in the tongue; sometimes to cartilage, as in the larynx; and sometimes to bone, as in the nasal fossæ and sinuses of the skull.

In structure a mucous membrane is composed of *corium* and *epithelium*. The epithelium is of various forms, including the squamous, columnar, and ciliated, and is often arranged in several layers (see fig. 11). This epithelial layer is supported by the corium, which is analogous to the derma of the skin, and consists of connective tissue, either simply areolar, or containing a greater or less quantity of lymphoid tissue. This tissue is usually covered on its external surface by a transparent structureless basement-membrane, and internally merges into the submucous areolar tissue. It is only in some situations that the basement-membrane can be demonstrated. The corium is an exceedingly vascular membrane, containing a dense network of capillaries, which lie immediately beneath the epithelium, and are derived from small arteries in the submucous tissue.

The fibro-vascular layer of the corium contains, besides the areolar tissue and vessels, unstriped muscle-cells, which form in many situations a definite



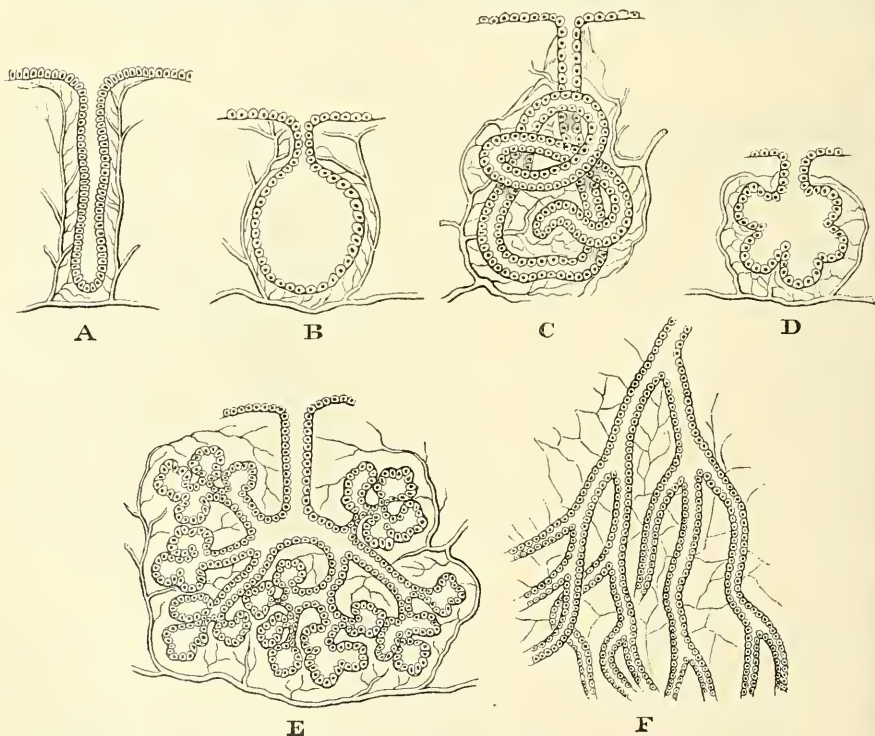
layer, called the *muscularis mucosæ*. These are situated in the deepest part of the membrane, and are plentifully supplied with nerves. Other nerves pass to the epithelium and terminate between the cells. Lymphatic vessels are found in great abundance, commencing either by cæcal extremities or in networks, and communicating with plexuses in the submucous tissue.

Embedded in the mucous membrane are found numerous glands, and projecting from it are processes (villi and papillæ) analogous to the papillæ of the skin. These glands and processes, however, exist only at certain parts, and it will be more convenient to defer their description to the sequel, where the parts are described as they occur.

### SECRETING GLANDS

The **secreting glands** are organs in which the blood, circulating in capillary vessels, is brought into contact with epithelial cells, whereby certain elements are separated ('secreted') out of the blood. The essential parts therefore of a secreting gland are *cells*, which have the power of extracting from the blood certain matters, and in some cases converting them into new chemical compounds; and *blood-vessels*, by which the blood is brought into close relation-

FIG. 74.—Diagrammatic plan of varieties of secreting glands.



A. Simple gland. B. Sacculated simple gland. C. Simple convoluted tubular gland. D, E. Racemose gland. F. Compound tubular gland.

ship with these cells. The general arrangement in all secreting structures—that is to say, not only in secreting glands, but also in secreting membranes—is that the cells are arranged on one surface of an extra-vascular basement-membrane, which supports them, and a minute plexus of capillary vessels ramifies on the other surface of the membrane. The cells then extract from the blood certain constituents which pass through the membrane into the cells, where they are prepared and elaborated. The basement-membrane does not

however, always exist, and any free surface would appear to answer the same purpose in some cases.

By the various modifications of this secreting surface the different glands are formed. This is generally effected by an involution of the membrane in different ways, the object being to increase the extent of secreting surface within a given bulk.

In the simplest form a single involution takes place, constituting a *simple* gland; this may be either in the form of an open tube (fig. 74, A), or the walls of the tube may be dilated so as to form a saccule (fig. 74, B). These are named the *simple tubular* or *saccular* glands. Or, instead of a short tube, the involution may be lengthened to a considerable extent, and then coiled up to occupy less space. This constitutes the *simple convoluted tubular* gland, an example of which may be seen in the sweat-glands of the skin (fig. 74, C).

If, instead of a single involution, secondary involutions take place from the primary one, as in fig. 74, D and E, the gland is then termed a compound one. These secondary involutions may assume either a saccular or tubular form, and so constitute the two subdivisions—the *compound saccular* or *racemose* gland, and the *compound tubular*. The racemose gland in its simplest form consists of a primary involution which forms a sort of duct, upon the extremity of which are found a number of secondary involutions, called saccules or alveoli, as in Brunner's glands (fig. 74, D). But, again, in other instances, the duct, instead of being simple, may divide into branches, and these again into other branches, and so on; each ultimate ramification terminating in a dilated cluster of saccules, and thus we may have the secreting surface almost indefinitely extended, as in the salivary glands (fig. 74, E). In the *compound tubular* glands the division of the primary duct takes place in the same way as in the racemose glands, but the branches retain their tubular form, and do not terminate in saccular recesses, but become greatly lengthened out (fig. 74, F). The best examples of this form of gland are to be found in the kidney and testicle. All these varieties of glands are produced by a more or less complicated involution of a secreting membrane, and they are all identical in structure; that is to say, the saccules or tubes, as the case may be, are lined with cells, generally spheroidal or columnar in figure, and on their outer surface is an intimate plexus of capillary vessels. The secretion, whatever it may be, is eliminated by the cells from the blood, and is poured into the saccule or tube, and so finds its way out through the primary involution on to the free surface of the secreting membrane. In addition, however, to these glands, which are formed by an *involution* of the secreting membrane, there are some few others which are formed by a *protrusion* of the same structure, as in the vascular fringes of synovial membranes. This form of secreting structure is not nearly so frequently met with.

# ORIGIN AND DEVELOPMENT OF THE BODY

## THE OVUM

THE whole body is developed out of the **ovum** (fig. 75) when fertilised by the spermatozoa. The ovum is merely a simple nucleated cell, or collection of protoplasm, and the spermatozoa disappear when they have accomplished their mysterious function. All the complicated changes by which the various intricate organs of the whole body are formed from one simple cell may be reduced to two general processes, viz. the *segmentation* or *cleavage* of cells, and their *differentiation*. The former process consists in the splitting of the nucleus and its investing cell-wall, whereby the original cell is represented by two. The differentiation of cells is a term used to describe that unknown power or tendency impressed on cells which, to all methods of examination now known, seem absolutely identical, whereby they grow into different forms; so that (to take the first instance which occurs in the growth of the embryo) the indifferent cells of the

FIG. 75.—Ovum of the sow.

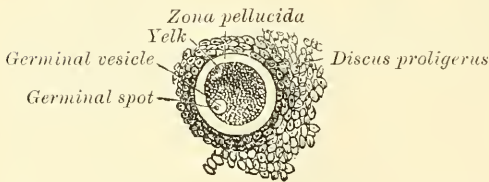
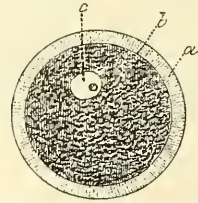


FIG. 76.—Human ovum from a middle-sized follicle. Magnified 350 times.



a. Vitelline membrane or zona pellucida. b. External border of the yolk and internal border of the vitelline membrane. c. Germinal vesicle and germinal spot.

vascular area are differentiated, some of them into blood-globules, others into the solid tissue which forms the blood-vessels. The extreme complexity of the process of development renders it at all times difficult to describe intelligibly, and still more so in a work like this, where adequate space and illustration can hardly be afforded, having respect to the main purpose of the work. I can only hope to render the leading features of the process tolerably plain, and must refer the reader who wishes to follow the various changes more minutely to the special works on the subject, and especially the work of Foster and Balfour. Many of the statements which are accepted in human embryology are made only on the strength of experiments on the lower animals, direct observation on the human subject being impossible.

The **ovum** is a small spheroidal body situated in immature Graafian vesicles near their centre, but in the mature ones in contact with the membrana granulosa,\* at that part of the vesicle which projects from the surface of the ovary. The cells of the membrana granulosa are accumulated round the ovum in greater number

\* See the description of the ovary at a future page.



than at any other part of the vesicle, forming a kind of granular zone, the *discus proligerus*.

The **human ovum** (fig. 76) is extremely minute, measuring from  $\frac{1}{240}$  to  $\frac{1}{120}$  of an inch in diameter. It is a cell consisting externally of a transparent envelope, the *zona pellucida* or *vitelline membrane*. Within this, and in close contact with it, is the *yolk* or *vitellus*; embedded in the substance of the yolk is a small vesicular body, the *germinal vesicle* (*vesicle of Purkinje*), the nucleus of the cell; and this contains as its nucleolus a small spot, the *macula germinativa*, or *germinal spot* of Wagner.

The **zona pellucida**, or **vitelline membrane**, is a thick, colourless, transparent membrane, which appears under the microscope as a radially striated membrane, bounded externally and internally by a dark outline. The striæ are believed to be minute pores, and are regarded as the channels by which nutritive particles are admitted into the interior of the ovum and possibly the way by which the spermatozoa gain access into the interior of the ovum, after the rupture of the Graafian follicle. The presence of these striæ has given to the zona pellucida the name of *zona radiata*, or striated membrane of the ovum. The zona pellucida corresponds to the chorion of the impregnated ovum.

The **yolk** consists of granular protoplasm, i.e. granules or globules of various sizes, embedded in a finely reticulated matrix. The smaller granules resemble pigment; the larger granules, which are in the greatest number at the periphery of the yolk, resemble fat-globules. In the human ovum the number of granules is comparatively small. Before and immediately after fertilisation it shows distinct movements of contraction and expansion.

The **germinal vesicle** consists of a fine, transparent, structureless membrane containing a clear matrix, embedded in which is occasionally found a small amount of nucleoplasm (see p. 8). It is about  $\frac{1}{720}$  of an inch in diameter, and in immature ova lies nearly in the centre of the yolk; but as the ovum becomes developed it approaches the surface, and enlarges much less rapidly than the yolk.

The **germinal spot** occupies that part of the periphery of the germinal vesicle which is nearest to the periphery of the yolk. It is opaque, of a yellow colour, and finely granular in structure, measuring from  $\frac{1}{36000}$  to  $\frac{1}{24000}$  of an inch.

The phenomena attending the discharge of the ova from the Graafian vesicles, since they belong as much or more to the ordinary function of the ovary than to the general subject of the growth of the body, are described with the anatomy of the ovaries on a subsequent page.

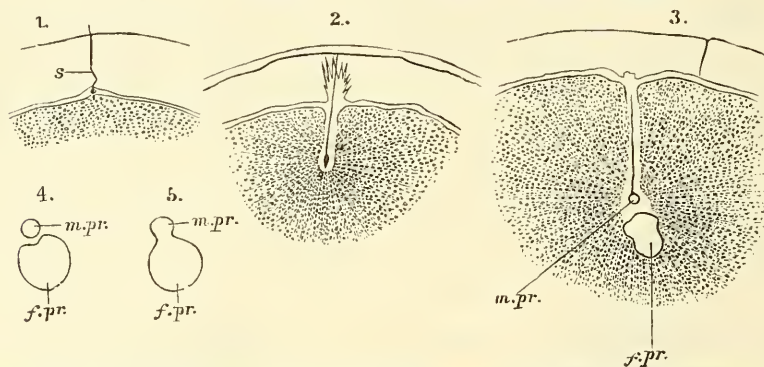
Either before its escape from the Graafian follicle or immediately after, the ovum undergoes a peculiar change, which results in the formation of one or more peculiar bodies, the *polar globules* of Robin, the origin of which has not hitherto been known; and also with the formation of another body, which appears to take a remarkable part in fecundation, and is named the 'female pronucleus.' The manner in which these bodies are developed from the germinal vesicle is briefly as follows: usually before the rupture of the Graafian follicle, but after the ovum has become mature or ripe, a portion of the germinal vesicle is protruded outside the yolk, but still remains within the vitelline membrane; this forms a small globular mass and constitutes the first polar globule. After a time, generally not till the ovum has entered the tube, a second protrusion of a portion of the germinal vesicle takes place, and forms a second polar globule. We have thus about two-thirds of the germinal vesicle extruded from the yolk and about one-third remaining behind, and at the ejection of each of these bodies a visible shrinking of the yolk takes place. The portion of the germinal vesicle which remains behind recedes from the surface towards the centre of the yolk and assumes a spherical form, and is now termed the 'female pronucleus.' All these changes, it must be understood, occur at each expulsion of an ovum, and are quite independent of fecundation.

## FERTILISATION AND EARLY CHANGES IN THE OVUM

The first changes in the ovum which take place at the time of conception appear to be as follows: One or more spermatozoa penetrate the ovum, and come into contact with the yolk, and with the portion of the germinal vesicle remaining in the yolk. It seems as if this normally occurs in the Fallopian tube,\* but it is possible that it sometimes occurs before the ovum has entered the tube; abnormally it may even take place in the peritoneal cavity. One spermatozoon, more advanced than the rest, becomes buried in the yolk, the tail disappears, and the head, a sort of nuclear body, constitutes the 'male pronucleus.' This gradually approaches the female pronucleus, which by this time is situated in the centre of the yolk. As soon as they come into contact they fuse into one, and form together a new nucleus, and thus fecundation is effected (fig. 77).† It is believed by most physiologists that one spermatozoon is sufficient for fecundation.

The first result of the fertilisation of the ovum is a cleavage or multiplication of the yolk, which is first cleft into two masses, the germinal vesicle having pre-

Fig. 77.—Fertilisation of the ovum of an echinoderm.



s. Spermatozoon. m. pr. Male pronucleus. f. pr. Female pronucleus. 1. Accession of a spermatozoon to the periphery of the vitellus. 2. Its penetration. 3. Transformation of the head of the spermatozoon into the male pronucleus. 4, 5. Blending of the male and female pronuclei. (From Quain's 'Anatomy,' Selenka.)

viously split up into two nuclei; so that it now consists of two separate masses of protoplasm, each containing a nucleus, situated within the original vitelline membrane, which takes no part in this process of division. Then, each of these two daughter elements divides in like manner, and thus four nucleated elements are formed, and so on, until at length a mulberry-like agglomeration of nucleated masses of protoplasm results (fig. 78). These masses are sometimes termed *vitelline spheres*.

The manner in which segmentation occurs is somewhat peculiar. The two spheres resulting from the first cleavage are of unequal size. One, which for the sake of distinction we will call the *upper* or epiblastic cell, is larger than the other, the *lower* or hypoblastic cell. And after they have divided three or four times, the rate of cleavage in the spheres derived from the upper or epiblastic segment becomes more rapid than in those derived from the lower or hypo-

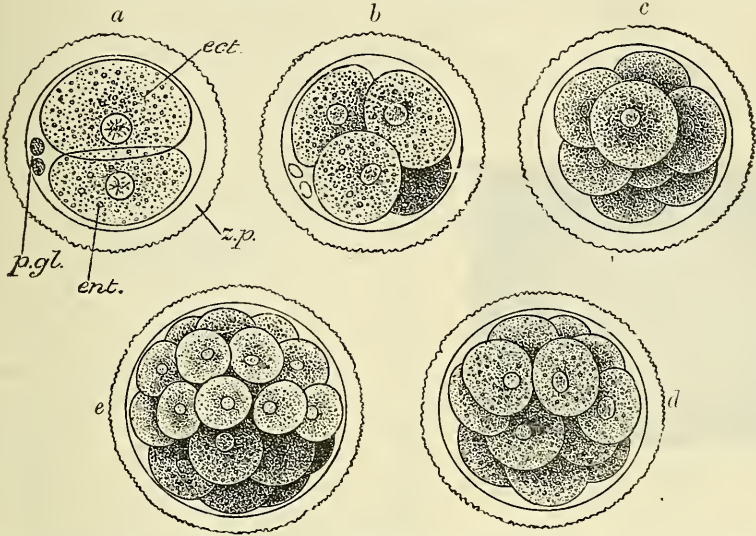
\* Many physiologists, as Bischoff and Dr. M. Barry, taught that the ovum is fecundated in the ovary, but the reasoning of Dr. Allen Thomson appears very cogent in proving that the usual spot at which the spermatozoa meet the ovum is in the tube, down which it slowly travels to the uterus, in its course becoming surrounded by an albuminous envelope derived from the walls of the tube.

† If the student refers to the development of the generative organs, he will find that the ovum of the female and the spermatozoon of the male are derived from fundamentally the same structures, and therefore their fusion is the union of two elements of very similar morphological value.



blastic segment. In addition to this, the spheres derived from the upper segment have a tendency to spread over and enclose those from the lower segment; so that by about the ninth or tenth division there is an external layer of spheres derived from the primary upper or epiblastic segment surrounding and almost enclosing a mass of spheres, which in consequence of their diminished rate of

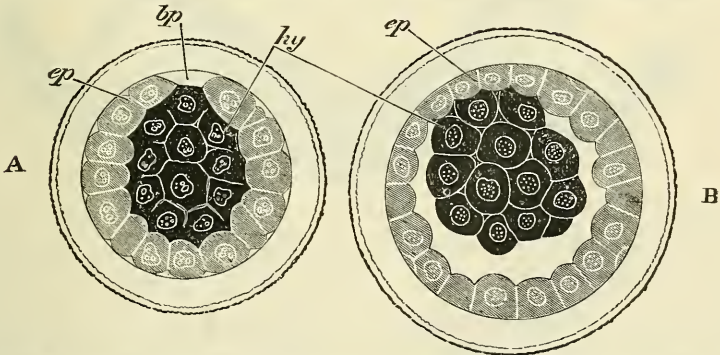
FIG. 78.—First stages of segmentation of a mammalian ovum: semi-diagrammatic. (From a drawing by Allen Thomson.)



*z.p.* Zona pellucida. *p. gl.* Polar globules. *ect.* Epiblastic cell. *ent.* Hypoblastic cell. *a.* Division into two spheres. *b.* Stage of four spheres. *c.* Eight spheres, the epiblastic cells partially enclosing the hypoblastic cells. *d, e.* Succeeding stages of segmentation, showing the more rapid division of the epiblastic cells and the enclosure of the hypoblastic cells by them.

cleavage are fewer in number and larger in size, derived from the primary lower or hypoblastic segment (fig. 79, A). Fluid collects between the two sets of spheres, except at one part, where they remain in contact, and the ovum is converted into a sac, formed by a layer of spheres derived from the upper primary

FIG. 79.—Ovum of the rabbit at the end of the process of segmentation.



*ep.* Epiblast. *hy.* Primitive hypoblast. *bp.* Place where the epiblast has not yet grown over the hypoblast. (From Balfour, after Ed. van Beneden.)

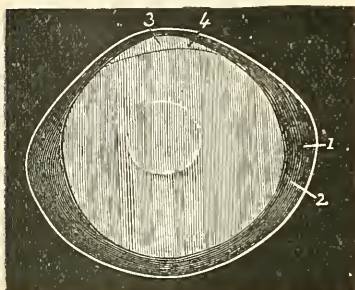
segment and containing at one part another mass of spheres derived from the lower primary segment (fig. 79, B). The inner cells are rather more granular than the outer, beneath which they gradually spread, becoming applied over a part of their inner surface in a single layer; so that the cavity is afterwards enclosed in a double layer of cells. This complete investment does not, however,



take place for some time, being generally not completed until after the mesoblast has begun to form.

The ultimate destination of the outermost complete layer of spheres is, at present, doubtful. By some they are believed to be transitory and to gradually disappear in the course of the formation of the various layers of the blastodermic membrane; by others it is thought that they form the outer layer (epiblast) of this membrane. Adopting the latter and more general view, the ovum would consist of a cavity surrounded by (1) a layer of cells completely lining the interior of the vitelline membrane, and (2) by a second layer internal to these and partially lining the interior of the outer layer, both sets of cells derived from the segmentation of the yolk. The double layer of cells is called the 'blastodermic membrane,' the outer layer being termed the 'epiblast,' and the inner the 'hypoblast.'

FIG. 80.—Ovum with the germinal area, seen in profile to show the division of the blastodermic membrane.

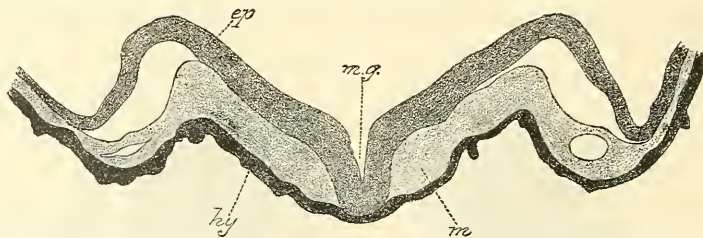


1. Vitelline membrane. 2. Blastoderm. 3. Germinal area. 4. Place where the blastoderm is just divided into its two layers.

**Blastodermic membrane.**—At first the area of the blastodermic membrane, which consists of both the inner and outer layers of cells, is a small disc; that is to say, when the inner or more granular cells have only spread for a short distance over the outer ones. This disc is called the *germinal disc* or *area germinativa*, because in it the first traces of the embryo are seen (fig. 80). The first trace of the embryo appears as a faint streak at the posterior end of the area germinativa, called the *primitive trace*. After the formation of the primitive trace, but previous to the appearance of the next parts of the embryo, presently to be described, viz. the laminae dorsales and the notochord, the blastodermic membrane consists of only two layers, the *epiblast* and *hypoblast*, but after the formation of these structures a third layer makes its appearance. This is the *mesoblast*, and is situated between the other two (fig. 81). As to the precise origin

of this third layer considerable difference of opinion exists. According to some embryologists it is formed entirely by proliferation of cells belonging to the epiblastic layer; according to others it is formed by a splitting of the hypoblast, or, at all events, a differentiation of it into a central layer of mesoblastic cells and a lower layer of hypoblastic cells. Or, what seems most probable, it is derived mainly from the epiblast, the hypoblast taking a smaller and more subordinate share in its formation. But in whichever way this third stratum may be formed, the blastodermic membrane eventually consists of three layers. The external, which used to be called the serous layer, but is now more commonly termed the

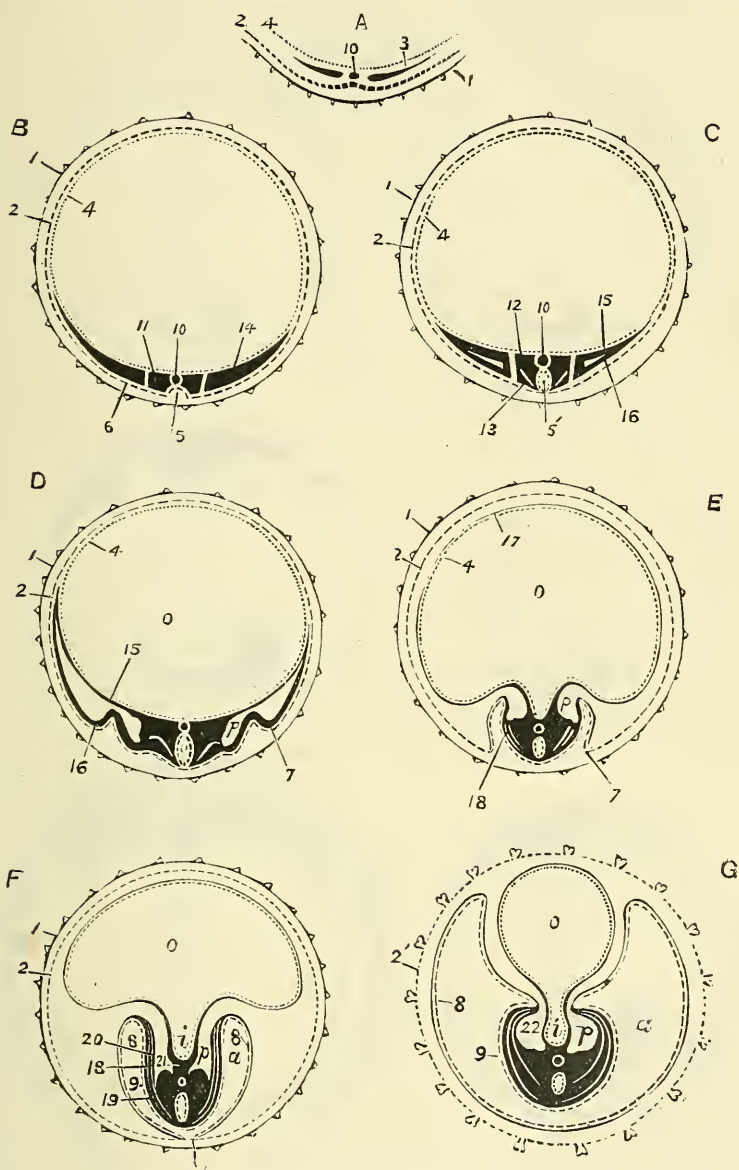
FIG. 81.—Section across the anterior part of the medullary groove of an early embryo of the guinea-pig. (By Schäfer. From Quain's 'Anatomy,' 1890.)



*ep.* Folds of epiblast rising up on either side of the middle line, and thus bounding the medullary groove. *mg.* Middle of medullary groove. *hy.* Hypoblast, which is in contact with the medullary epiblast at the middle of the groove, but is elsewhere separated from it by mesoblast, *m*, which has burrowed forwards between the two primary layers. A cleft is seen in the mesoblast on either side; this is the commencement of the anterior part of the body-cavity.

of this third layer considerable difference of opinion exists. According to some embryologists it is formed entirely by proliferation of cells belonging to the epiblastic layer; according to others it is formed by a splitting of the hypoblast, or, at all events, a differentiation of it into a central layer of mesoblastic cells and a lower layer of hypoblastic cells. Or, what seems most probable, it is derived mainly from the epiblast, the hypoblast taking a smaller and more subordinate share in its formation. But in whichever way this third stratum may be formed, the blastodermic membrane eventually consists of three layers. The external, which used to be called the serous layer, but is now more commonly termed the

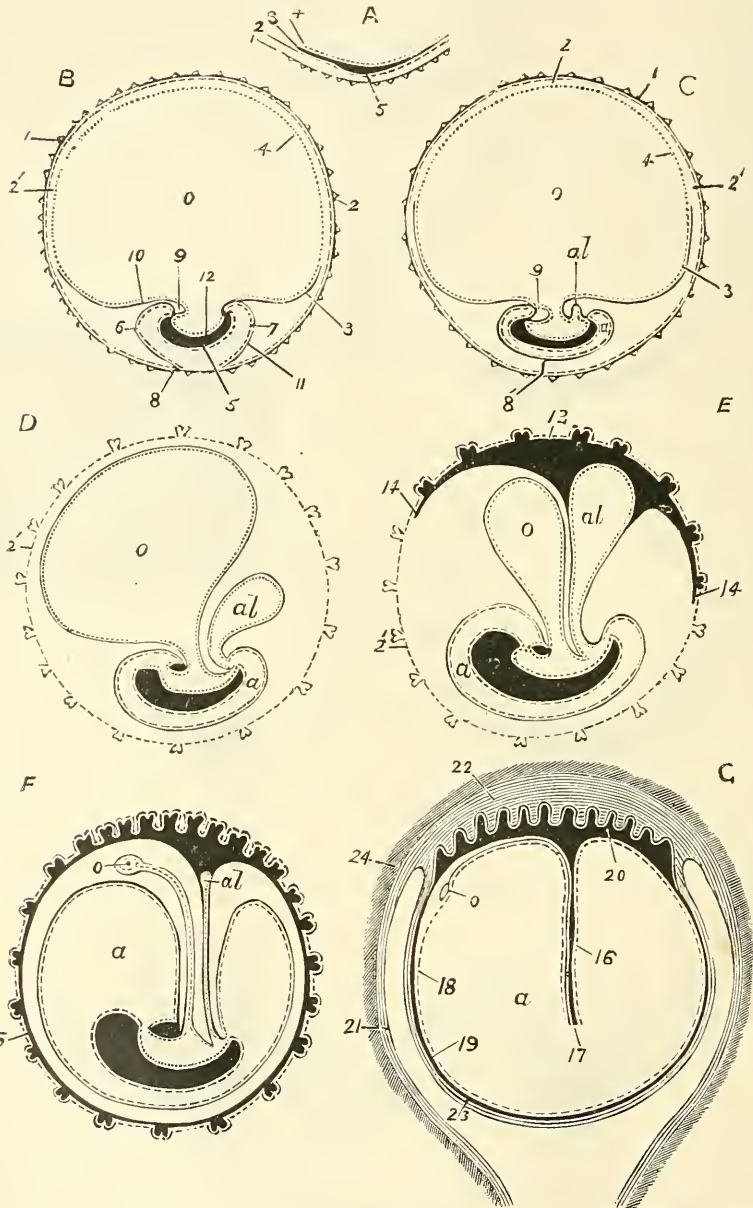
FIG. 82.\*—Diagrams to show the development of the three layers of the blastodermic membrane on transverse section.



A. Portion of the ovum with the zona pellucida and the germinal area. B C D E F G. Different stages of development. *o*, Umbilical vesicle. *a*, Amnion. *i*, Intestine. *p*, Peritoneal cavity, bounded by the splanchno-pleural and somato-pleural layers of mesoblast. 1, Vitelline membrane. 2, External blastodermic layer. 3, Middle layer. 4, Internal layer. 5, Medullary laminae and groove. 5', Medullary canal. 6, Epidermic laminae. 7, Lateral flexures of the amnion. 7', The same almost in contact. 8, Internal epithelial layer of the amnion. 9, Epidermis of the embryo. 10, Chorda dorsalis. 11, Vertebral laminae. 12, Protovertebrae proper. 13, Muscular laminae. 14, Lateral laminae. 15, Fibro-intestinal laminae. 16, Cutaneous laminae. 17, Internal fibrous layer of the umbilical vesicle. 18, Muscular laminae extending to meet the cutaneous. 19, External layer of the cutaneous laminae. 20, Internal layer of the same. 21, Mesentery. 22, Fibrous layer of the intestine.

\* The dotted lines indicate the parts belonging to the internal blastodermic layer; the plain lines those belonging to the middle; the interrupted lines those belonging to the external. The embryo has been represented, in this and the following diagram, lying on its back. The natural position is generally assumed to be the reverse.

FIG. 83.\*—Diagrams to show the development of the three blastodermic layers on antero-posterior section.



A. Portion of ovum with the vitelline membrane and germinal area. B C D E F. Various stages of development. G. Ovum in the uterus and formation of decidua. 1. Vitelline membrane. 2. External blastodermic layer. 2'. Vesicula serosa. 3. Middle blastodermic layer. 4. Internal layer. 5. Vestige of the future embryo. 6. Cephalic flexure of the amnion. 7. Caudal flexure. 8. Spot where the amnion and vesicula serosa are continuous. 8'. Posterior umbilicus. 9. Cardiac cavity. 10. External fibrous layer of the umbilical vesicle. 11. External fibrous layer of the amnion. 12. Internal layer of the blastoderm forming the intestine. 13, 14. External layer of the allantois, extending to the inner surface of the vesicula serosa. 15. The same now completely applied to the inner surface of the vesicula serosa. 16. Umbilical cord. 17. Umbilical vessels. 18. Amnion. 19. Chorion. 20. Foetal placenta. 21. Mucous membrane of uterus. 22. Maternal placenta. 23. Decidua reflexa. 24. Muscular wall of uterus.

\* The same note applies to this as to the preceding diagram.



*epiblast*, or *ectoderm*; the internal, the mucous layer, the *hypoblast*, or *entoderm*; and the middle, which is now usually called the *mesoblast*, or *mesoderm*, but which was formerly named the 'vascular layer.'

The *epiblast* is mainly concerned in the formation of the external cuticle and the whole of the nervous system. It consists of cells of an epithelial character; that is to say, cells of an irregular columnar shape, forming, for the most part, a single stratum, but becoming more numerous and flattened at the germinal disc. The epidermis of the body and all the involutions of the epidermis in the ducts of superficial glands, as the mammæ, as well as the brain, the spinal cord, the nerves, and the portions of the nose, eye, and ear, which are directly formed from the brain, are developed from it. The external layer of the amnion is also formed from the *epiblast*, and probably also a portion of the chorion.

The *hypoblast* is mainly concerned in forming the internal epithelium, viz. that of the whole alimentary passages except the mouth and the anus (which are formed by involutions of the *epiblast*); and the epithelium of all the glandular organs which open into the intestinal tract, the epithelium of the trachea, bronchial tubes and air sacs of the lungs; the epithelium of the urinary organs and of the thyroid and thymus glands. The *hypoblast* forms also the deeper layer of the umbilical vesicle and allantois. Its cells are epithelial and are at first flattened, but subsequently become columnar and larger than those of the *epiblast*.

All the rest of the embryo is formed from the *mesoblast*, viz. all the vascular and locomotive system, the cutis, all the connective tissues, and the genito-urinary organs, with the exception of the epithelium of the bladder and urethra, which is developed from the *hypoblast*. The vascular system of the fœtus extends to the yolk and the maternal parts along the umbilical vesicle and allantois, so that the greater part of these bodies and the outer layer of the amnion are also formed out of the *mesoblast*. The fœtal portion of the placenta, being essentially a vascular structure, is also developed from the *mesoblast*. Its cells are irregular and branched and surrounded by a considerable amount of intercellular fluid. It may therefore be regarded as resembling more closely embryonic connective tissue.

## FIRST RUDIMENTS OF THE EMBRYO

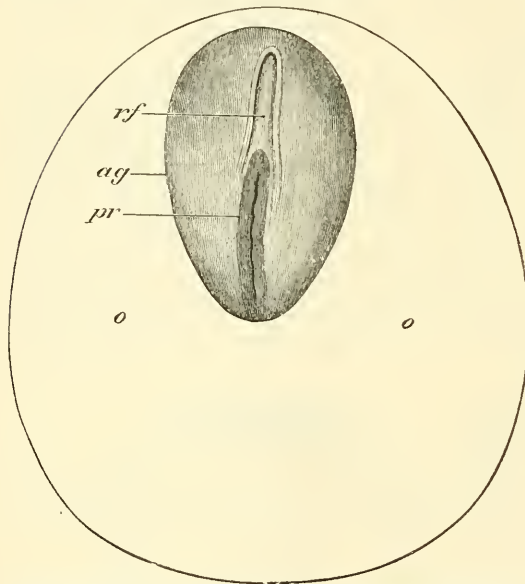
The *primitive trace* alluded to above as appearing in the *area germinativa*, is a very transitory structure, which marks the direction of the embryonic axis, and is gradually lost in consequence of its place becoming occupied by the rudimentary spinal column (figs. 82 and 83).

The first real approach towards a definite form in the embryo is made (1) by the development of the rudimentary spinal column; (2) by the cleavage of the middle layer of the blastodermic membrane from which a part of that column is derived; and (3) by the incurvation of the column at its cephalic end to form the brain and brain-case.

First, a folding up of the cells of the *epiblast* or outer layer takes place. This commences in the anterior part of the *area germinativa* and extends in the same direction as the *primitive trace*, gradually occupying its position until this latter is lost at the caudal extremity of the embryo (fig. 84). This folding up of the *epiblast* gives rise to a longitudinal groove down its centre, in consequence of the manner in which the cells of the *epiblast* are heaped up into two longitudinal ridges, with a furrow between them, so that the sides and base of the groove are formed of *epiblastic* cells (fig. 85, A). The *mesoblast*, lying between the *epiblast* and *hypoblast*, fills up the space thus caused between these two layers, so that the sides of the groove are occupied by a longitudinal thickening of *mesoblast*; the two masses being separated at the bottom of the groove by the junction of the *epiblast* and *hypoblast* at the situation of the *primitive trace*. The groove becomes deeper and deeper in consequence of the further growing up of the cells

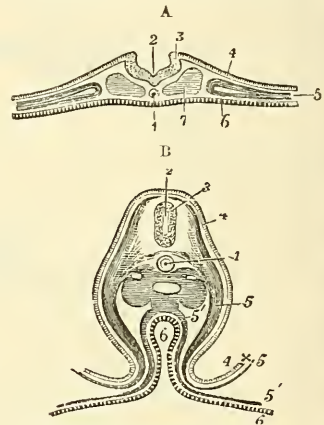
to form the ridge on either side. In this way the ridges eventually become two plates, the *laminae dorsales* or *medullary plates*, which finally, bending over the groove, coalesce and thus form a closed tube, the *neural canal*, lined by epiblast and having a covering of the same membrane (fig. 85). These layers of epiblast are at first in contact with one another, but eventually become separated, mesoblastic structures growing up between them and the line of coalescence becomes obliterated. The coalescence first takes place in the middle of the embryo, then towards the cephalic end, and lastly at the caudal extremity. The lining of this tube is developed into the nervous centres, the covering into the epidermis of the back and head. The cephalic extremity of the neural canal is soon seen to be more dilated than the rest, and to present constrictions dividing it imperfectly

FIG. 84.—Embryonic area of the ovum of a rabbit at the seventh day.



ag. Embryonic area. o, o. Region of the blastodermic vesicle immediately surrounding the embryonic area. pr. Primitive streak. rf. Medullary groove. (From Kölliker.)

FIG. 85.—Transverse sections through the embryo chick before and some time after the closure of the medullary canal, to show the upward and downward inflections of the blastoderm. (After Remak.)



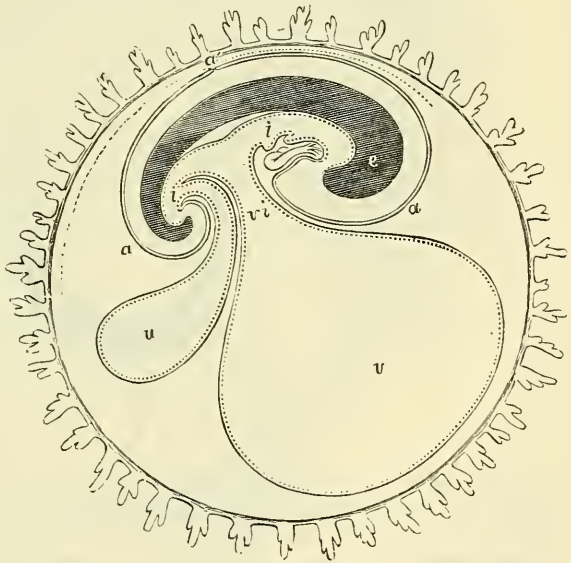
A. At the end of the first day. 1. Notochord. 2. Primitive groove in the medullary canal. 3. Edge of the dorsal lamina. 4. Corneous layer or epiblast. 5. Mesoblast divided in its inner part. 6. Hypoblast or epithelial layer. 7. Section of protovertebral plate. B. On the third day in the lumbar region. 1. Notochord in its sheath. 2. Medullary canal now closed in. 3. Section of the medullary substance of the spinal cord. 4. Corneous layer. 5. Somatopleure of the mesoblast. 5'. Splanchnopleure (one figure is placed in the pleuro-peritoneal cavity). 6. Layers of hypoblast in the intestines spreading also over the yolk. 4x5. Part of the fold of the amnion formed by epiblast and somatopleure.

into three chambers: the brain is developed from this dilated portion; the spinal cord takes its origin from the remainder of the tube. Below the neural canal, the hypoblast and epiblast are in contact, separating the two longitudinal thickenings of mesoblast on either side of the canal. Here a thickening of the hypoblast, commencing from the anterior end of the primitive trace, takes place and gradually separates itself off from the hypoblast, so as to form a rod-like column, lying between the hypoblast and the epiblast, beneath the neural canal. This is known as the *notochord* or *chorda dorsalis*. This, when fully developed, is composed of clear epithelium-like cells enclosed in a sheath of homogeneous substance. It is essentially an embryonic structure, though traces of it remain in the centre of the intervertebral discs throughout life. The collection of mesoblastic cells, which forms a thick longitudinal column on either side

of the neural canal, becomes separated from the rest of the mesoblastic layer. It undergoes a series of transverse segmentations and becomes converted into a row of well-defined, dark, square segments or masses, separated by clear, transverse intervals, called the *protovertebræ* or *mesoblastic somites*. They first make their appearance in the region which afterwards becomes the neck, then further forwards towards the head, and afterwards extend along the body. These bodies, as will be explained hereafter, are not the same as the permanent vertebræ, but they are differentiated, partly into the vertebræ and partly into the muscles and true skin. On either side of the protovertebræ the mesoblast splits into two layers, the upper, or that covered by epiblast, is called *somatopleure*, and the lower, lined by hypoblast, the *splanchnopleure* (fig. 85, B, 5-5'). From the former the skeleton muscles and true skin of the external parts of the body are derived, from the latter the muscular and other mesoblastic portions of the viscera. The space between them is the common pleuro-peritoneal cavity. Whilst the parietes of the body are still unclosed, this common pleuro-peritoneal cavity is continuous with the space between the amnion and chorion, as seen in fig. 82, F. The embryo, which at first seems to be a mere streak, extends longitudinally and laterally. As it

grows forward the cephalic end becomes remarkably curved on itself (cephalic flexure), owing to the growth forwards of the anterior extremity of the embryo over the blastodermic membrane in front of it, thus causing a dipping down of the blastoderm in front of the neural canal. A smaller but similar folding-over takes place at its hinder end (caudal flexure). At the same time the sides of the embryo grow and curve towards each other; so that the embryo is aptly compared to a canoe turned over (fig. 86). In consequence of this incurving of the embryo, both in an antero-posterior and a lateral direction, the original yolk, with the three layers derived from

FIG. 86.—Diagrammatic section through the ovum of a mammal in the long axis of the embryo.



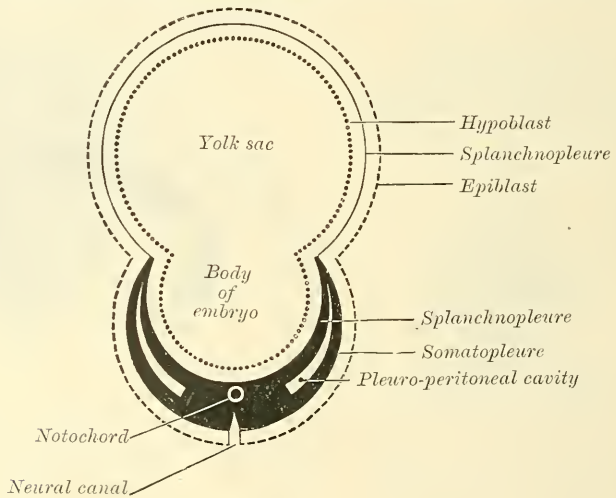
*a.* The cranio-vertebral axis. *i, i.* The cephalic and caudal portions of the primitive alimentary canal. *a.* The amnion. *a'* The point of reflection into the false amnion. *e.* Yolk-sac, communicating with the middle part of the intestine by *v i*, the vitello-intestinal duct. *u.* The allantois. The ovum is surrounded externally by the villous chorion.

the cleavage of the blastodermic membrane which cover it, is converted into a sort of hour-glass shape with two unequal globes. The smaller globe is formed by the part of the blastodermic membrane (area germinativa) which has already undergone certain changes in the formation of the embryo, and constitutes the part which has been compared to a canoe. The larger globe is called the *yolk-sac* or *umbilical vesicle*, and is formed by the rest of the blastodermic membrane, i.e. that part which is not concerned in the formation of the area germinativa. The two freely communicate through the constriction which is the site of the future umbilicus, and through this constriction the internal layer of the blastodermic membrane (the hypoblast) and the innermost of the two layers into which the mesoblast divides, viz. the *splanchnopleure*, and the *somatopleure*, pass out; the incurving having only involved the somatopleural layer of the mesoblast and the epiblast



(fig. 87). The umbilical vesicle is, therefore, at first a mere part of the general cavity of the yolk, partly enclosed by the embryo; but as the latter grows round on all sides towards the umbilical aperture, the yolk becomes distinguished into two portions. One lies inside the embryo and eventually forms a part of the intestinal cavity (out of which also, as will hereafter be seen, the bladder is developed). The other lies external to the embryo and remains therefore for a time a part of what is, in a more restricted sense, the ovum. The two parts are almost separated from each other by the meeting of the abdominal walls of the embryo at the umbilicus, through which they still communicate by a passage, the *omphalo-mesenteric duct*, the destination of which will be pointed out presently. The extra-embryonic portion is of small importance and very temporary duration in the human subject. It is for the purpose of supplying nutrition to the embryo during the very earliest period, before it can obtain it from the uterine sinuses of the mother. In the oviparous animals, however, where no supply of nutrition can be obtained from the mother,

FIG. 87.—Diagrammatic section of embryo, showing the formation of the umbilical vesicle.

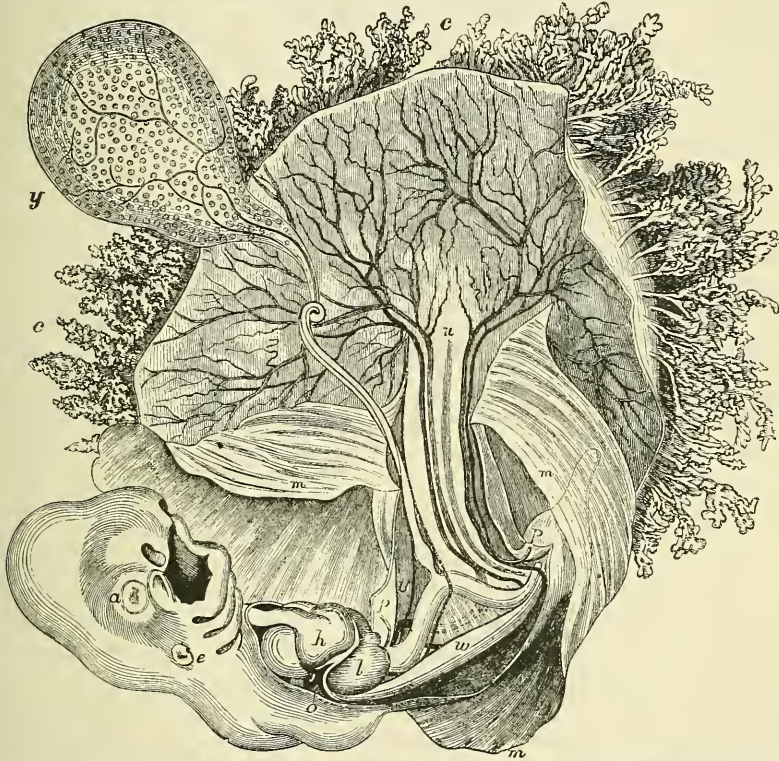


since the egg is entirely separated from her, the yolk-sac is large and of great importance, as it supplies nutrition to the chick during the whole of fetation. Vessels developed in the middle blastodermic layer soon cover the umbilical vesicle, forming the *vascular area*, the chief vessels of which are the *omphalo-mesenteric*, two in number (fig. 88). The vessels of this area appear to absorb the fluid of the umbilical vesicle, which as the fluid is absorbed dries up and has no further function. The activity of the umbilical vesicle ceases about the fifth or sixth week, at the same time that the allantois, which is the great bond of vascular connection between the embryo and the uterine tissues, is formed. In fact, the umbilical vesicle provides for the nutrition of the foetus from the ovum itself, while the allantois is the channel whereby it is nourished from the uterine tissues. The umbilical vesicle, containing fluid, remains visible, however, up to the fourth or fifth month, with its pedicle and the omphalo-mesenteric vessels. The latter vessels become atrophied as the functional activity of the body with which they are connected ceases.

So far we have traced—(1) the segmentation or cleavage of the yolk into a number of nucleated cells—'vitelline spheres.' (2) The accumulation of fluid within the ovum, and the arrangement of the vitelline spheres around the fluid on the internal surface of the vitelline membrane, forming a second membrane, the 'blastodermic membrane.' (3) The separation of the blastodermic membrane

into three layers, named, from within outwards, the 'hypoblast,' the 'mesoblast,' and the 'epiblast.' (4) The formation of an elongated, oval-shaped disc, called the 'area germinativa.' (5) The appearance in the centre of the area germinativa of a delicate line or furrow, running longitudinally, and called the 'primitive trace.' (6) The formation of a distinct groove in the situation of this primitive trace, caused by the growing-up of the cells on either side of it, so as to form two longitudinal ridges, called the 'laminae dorsales.' (7) The increase and incurvation of these laminae dorsales, until they meet behind, enclosing a canal, lined by epiblast. The canal is the neural canal, and from the epiblast which lines it the nervous centres are developed. (8) The formation, in the hypoblast immediately under this canal, of a continuous rod-shaped body, the

FIG. 88.—Magnified view of the human embryo of four weeks, with the membranes opened. (From Leishmann after Coste.)



*y*, The umbilical vesicle with the omphalo-mesenteric vessels, *z*, and its long tubular attachment to the intestine. *c*, The villi of the chorion. *m*, The amnion opened. *u*, Cal-de-sac of the allantois, and on each side of this the umbilical vessels passing out to the chorion. In the embryo: *a*, The eye. *e*, The ear-vesicle. *h*, The heart. *l*, The liver. *o*, The upper; *p*, the lower limb. *w*, Wolffian body, in front of which are the mesentery and fold of intestine. The Wolffian duct and tubes are not represented.

'chorda dorsalis' or 'notochord.' (9) The formation from the mesoblast, on either side of the notochord, of a longitudinal column, divided into a number of square segments, the 'protovertebræ.' (10) The splitting of the mesoblast, external to the protovertebræ, into two layers—the outer, called the 'somatopleure,' lined externally by the epiblast; the inner, called the 'splanchnopleure,' lined internally by the hypoblast, a space being left between the two, which forms the 'pleuro-peritoneal cavity.' (11) The curving of the embryo on itself, both longitudinally and laterally, so as to be comparable to a canoe; the walls being formed of all three layers of the blastodermic membrane and the well of the canoe—that is, the body-cavity of the embryo, opening into the cavity of the yolk-sac. (12) A portion of the yolk-sac lying in the body-cavity of the embryo, and a portion outside it; the two communicating by a duct, the 'omphalo-



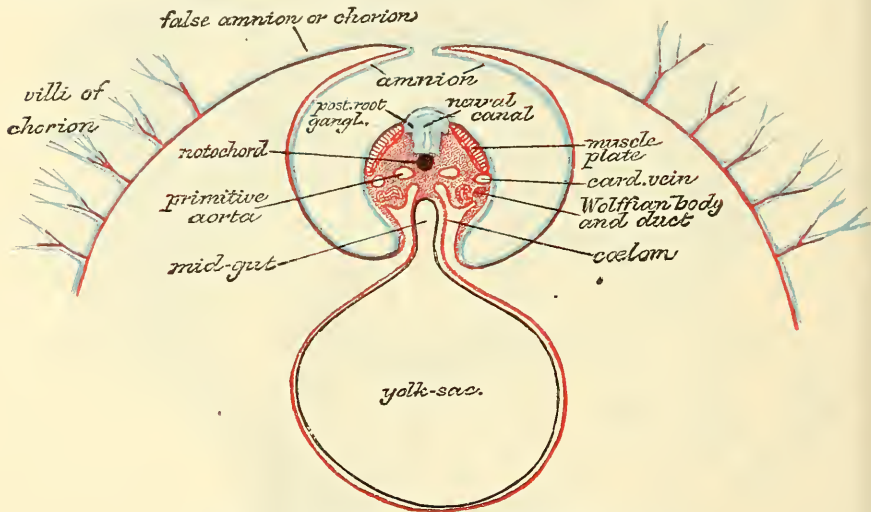
mesenteric' duct. The portion of the yolk-sac external to the body-cavity is termed the umbilical vesicle, and provides nutrition to the embryo until such time as the allantois is formed; vessels, developed from the middle blastodermic layer, ramifying over it, and gradually absorbing its contents.\*

### FORMATION OF MEMBRANES

The **membranes** investing the fœtus are the amnion, the chorion, and the decidua. The two former are developed from fœtal structures, and are proper to the fœtus; the latter is formed in the uterus, and is derived from the maternal structures.

**The Amnion.**—The amnion is the membrane which immediately surrounds the embryo. It is of small size at first, but increases considerably towards the middle of pregnancy, as the fœtus acquires the power of independent movement. It exists only in reptiles, birds, and mammals, which are hence called 'Amniota,' but is absent in amphibia and fishes. It is formed thus. At or near the

FIG. 89.—Diagram of a transverse section of a mammalian embryo, showing the mode of formation of the amnion. The amniotic folds have nearly united in the middle line. (From Quain's 'Anatomy,' vol. i. pt. I. 1890.)



Epiblast, blue; mesoblast, red; hypoblast and notochord, black.

extremities of the incurved fœtus—that is to say, at the point of constriction of the blastodermic membrane, where the portion which has undergone changes to form the body of the embryo joins the part devoted to the formation of the umbilical vesicle—an inflection of the epiblast and outer layer of the mesoblast, which have become separated from the inner layer of the mesoblast and hypoblast by the formation of the pleuro-peritoneal cavity, takes place (fig. 82, D 7). These inflections or backward folds commence first at the cephalic extremity, and subsequently at the caudal end and sides, and deepen more and more, in consequence of the sinking of the embryo into the blastodermic vesicle, until, gradually approaching, they meet one another (fig. 82, E 7, and 89). After they come in contact they fuse together, and the septum between them disappears; so that the inner layer of the cephalic fold becomes continuous with the inner layer of the caudal fold, and the outer with the outer (fig. 82, F 7'). Thus we have two membranes, one formed by the inner layer of the fold—the *true amnion*—which encloses a space over the back of the embryo—the *amniotic cavity*

\* According to Professor John A. Ryder, it is 'very doubtful if any considerable amount of nutriment is supplied to the embryo from the yolk-sac at any time.'



(fig. 82, F and G, a)—containing a clear fluid, the *liquor amnii*.\* The other, the outer layer of the fold—the *false amnion*—lines the internal surface of the original vitelline membrane. Between the two is an interval, which of course communicates with the pleuro-peritoneal cavity. This it continues to do until the body-walls of the embryo have grown up and coalesced at the umbilicus. Then the amniotic fold is carried downwards, and encloses the umbilical cord, by which the fœtus is attached to the placenta. The true amnion—or, as it is usually called, the amnion—is formed of two layers, derived respectively from the epiblast and from the parietal layer of the mesoblast. The one from the epiblast consists of nucleated cells; the other, from the mesoblast, has a fibrous and, according to some embryologists, a muscular structure; at all events, it possesses the power of rhythmic contraction during life. In some animals this layer is vascular.

The amnion is at first in close contact with the surface of the body of the embryo, but about the fourth or fifth week fluid begins to accumulate, and thus separates the two. The quantity steadily increases up to about the sixth month of pregnancy, after which it diminishes somewhat. The use of the liquor amnii is believed to be chiefly to allow of the movements of the fœtus in the later stages of pregnancy, though it no doubt serves other purposes also. It contains about one per cent. of solid matter, chiefly albumen, with traces of urea, the latter probably derived from the urinary secretion of the fœtus.

**The Chorion.**—The chorion is rather a complex membrane made up essentially of two parts:—first, of the membranes of the ovum external to the pleuro-peritoneal cavity—that is to say, of the vitelline membrane and false amnion; and, secondly, of a diverticulum of those layers of the original blastodermic membrane which are internal to the pleuro-peritoneal cavity. This diverticulum is called the *allantois*.

1. *The portion of the chorion which is formed from the membranes of the ovum external to the pleuro-peritoneal cavity.* We have seen that in the formation of the amnion we had two layers formed out of a reduplication of the epiblast and outer layer of the mesoblast: one—the *true amnion*—which surrounds the embryo and encloses a cavity between it and the embryo—the *amniotic cavity*; and secondly, the *false amnion*, which lies in apposition with the internal surface of the vitelline membrane, and forms a complete covering to the ovum and its contents; and that between these two layers there is a space (which must not be confounded with the amniotic cavity) which communicates with the pleuro-peritoneal space, and, according to Dalton, contains a semi-fluid, gelatinous material. At a very early period of gestation cellular processes or fringes grow outwards from the external surface of the false amnion, which have been likened by Dalton to tufts of seaweed. They are at first destitute of vessels, and are of simple cellular structure. These fringes, or villi, as they subsequently become, cover at first the whole surface of the chorion; but as development progresses and the placenta, by which the extent of the attachment of the ovum to the uterine walls is to be limited, is about to be formed, the villi are not further developed over the rest of the chorion, but are confined to that part only which is to form the fœtal portion of the placenta. They may, however, be recognised all over the chorion, as abortive processes, during the whole of fœtal gestation.

2. *The Allantois.*—This structure is derived from the layers of the blastodermic membrane which are internal to the pleuro-peritoneal space, being formed by the projection of a hollow bud of that part of the hypoblast and splanchno-

\* The student should be careful not to confound this cavity with that formed between the true and false amnion, which communicates with the pleuro-peritoneal cavity of the embryo. This latter space ought with more propriety to be called the 'amniotic cavity,' since it is contained between the layers of the amnion; whereas the so-called amniotic cavity is not really between the layers of the amnion at all, but between the inner layer of the amnion and the body of the embryo.

pleure which is contained in the body-cavity of the embryo, and which, as we have before stated, is intended for the formation of the intestinal canal (fig. 86, *u*). It extends into and through the pleuro-peritoneal space, into the cavity between the true and false amnion, until it meets the latter, over the internal surface of which it spreads. In this diverticulum two arteries and two veins, the *allantoic vessels*, are developed. The arteries are in the first instance branches of the two primary divisions of the abdominal aorta, but subsequently, when the two aortas coalesce, they become branches of the hypogastric arteries. The veins join the veins of the yolk-sac, and form the umbilical veins. When the allantois meets the chorion, branches from these allantoic vessels permeate the cellular tufts or fringes which have been described as growing from the outer surface of the false amnion and convert them into villi, and these eventually form the foetal portion of the placenta\* (fig. 88, *c*). The allantois is the chief agent of the early circulation, for it is the duct or tract along which the vessels extend which convey the blood of the embryo to the foetal chorion, where it is exposed to the influence of the maternal blood circulating in the decidua or uterine portion of the placenta, from which it imbibes the materials of nutrition, and to which it gives up effete materials, the removal of which is necessary for its purification. In some animals the allantois is a hollow projection and is usually styled the *allantoic vesicle*; but in most mammals, and especially in man, the external or mesoblastic element undergoes great development, while the internal or hypoblastic element undergoes little increase beyond the body of the embryo, so that it is very doubtful whether any cavity exists in the allantois beyond the limits of the umbilicus, or whether it does not rather consist of a solid mass of material derived from the mesoblastic tissue.† A portion of the allantoic vesicle *within* the body-cavity is eventually destined to form the bladder, while the remainder forms an impervious cord, the *urachus*, stretching from the summit of the bladder to the umbilicus. The part external to the foetus forms the umbilical cord, by which the foetus is connected with the villi of the chorion, and which eventually form the foetal portion of the placenta.

**The Decidua.**—The growth of the chorion and placenta can only be understood by tracing the formation of the decidua.

The decidua (figs. 83 G, 90) is formed from the mucous membrane of the uterus. Even before the arrival of the fecundated ovum in the uterus, the mucous membrane of the latter becomes vascular and tumid, and when the ovum has reached the uterus it becomes embedded in the folds of the mucous membrane, which grow up around it and finally completely encircle it, so as to cover it in entirely and exclude it from the uterine cavity. Thus two portions of the uterine mucous membrane (decidua) are formed, viz. that which coats the muscular wall of the uterus, *decidua vera*, and that which is in contact with the ovum, *decidua reflexa*. The decidua vera at the os internum and at the openings of the Fallopian tubes is continuous with the lining membrane of these canals, the thickening of the original mucous membrane of the uterus which converts it into decidua abruptly ceasing at these points. The neck of the uterus after conception is closed by a plug of mucus. The decidua vera is perforated by the openings formed by the enlarged uterine glands, which become much hypertrophied and developed into tortuous tubes. It contains at a later period numerous arteries and venous channels, continuous with the uterine sinuses, and it is from it that the uterine part of the placenta is developed. The portion of

\* In some animals, some of the vessels of the villi of the chorion are derived from the yolk-sac, that is from the omphalo-mesenteric vessels.

† Indeed, it would appear, from the researches of His, that in the human embryo not only is the allantois formed unusually early, as is admitted by all, but in an altogether exceptional manner, not consisting of an outgrowth from the portion of the splanchnopleure engaged in the formation of the alimentary canal, but being present from the very earliest period as a stalk connecting the posterior extremity of the embryo with the chorion.



the decidua vera which takes part in the formation of the placenta is called the *decidua serotina* (fig. 90, *f*).

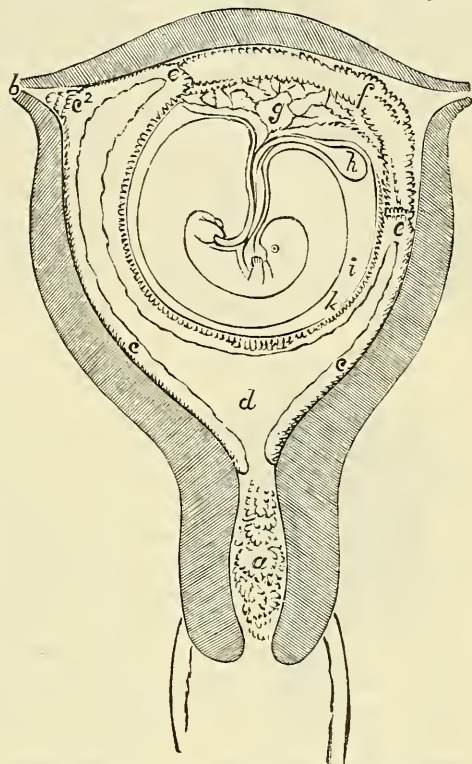
Here the greater part of the glands disappear, only a small portion of the deeper part of the tubes which are imbedded in the uterine muscular coat remaining, and the whole of this portion of the decidua, except a thin layer next the uterine wall, becomes converted into a series of vascular spaces or sinuses, which freely communicate with each other. This constitutes the maternal portion of the placenta.

The decidua reflexa is shaggy on its outer aspect, but smooth within. The vessels, which it contains at first, disappear after about the third month. About the fifth or sixth month the space between the two layers of the decidua disappears, and towards the end of pregnancy the decidua reflexa is transformed into a thin yellowish membrane, which constitutes the external envelope of the ovum.

Much additional interest has been given to the physiology of the decidua by the fact, which seems to be now established by the researches of Sir John Williams, that every discharge of an ovum, whether impregnated or not, is, as a rule, accompanied by the formation of a decidua, and that the essence of menstruation consists in the separation of a decidual layer of the mucous membrane from the uterus; while in the case of pregnancy there is no exfoliation of the membrane, but, on the contrary, it undergoes further development in the manner described above.

The **Placenta** is the organ by which the connection between the fetus and mother is maintained. It subserves the purposes both of circulation and respiration. It is formed of two parts, as already shown—viz. the maternal portion, which is developed out of the decidua vera (serotina), and the foetal portion formed out of the villi of the chorion. Its shape in the human subject is that of a disc, one side of which adheres to the uterine wall, while the other is covered by the amnion. The villi of the chorion gradually enlarge, forming large projections—‘cotyledons’—which each contain the ramifications of vessels communicating with the umbilical (allantoic) arteries and veins of the fetus. These vascular tufts are covered with epithelium, and project into the vascular spaces or sinuses above mentioned, which constitute the maternal portion of the organ. In these sinuses the uterine blood is brought into close proximity with the villi of the foetal placenta, which lie in the sinuses. The interchange of fluids necessary for the growth of the fetus and for the depuration of the blood takes place through the walls of the villi, but there is no direct continuity between the maternal and foetal vessels. The foetal vessels form tufts of

FIG. 90.—Sectional plan of the gravid uterus in the third and fourth month. (From Wagner.)



*a*. Plug of mucus in the neck of the uterus. *b*. Fallopian tube. *c*. The decidua vera. *c*<sup>2</sup>. The decidua vera passing into the right Fallopian tube: the cavity of the uterus is almost completely occupied by the ovum. *e*, *e*. Points of reflection of the decidua reflexa (in nature the united decidua do not stop here, but pass over the whole uterine surface of the placenta). *g*. Supposed allantois. *h*. Umbilical vesicle. *i*. Amnion. *k*. Chorion, covered with the decidua reflexa. *d*. Cavity of the decidua. *f*. Decidua serotina, or placental decidua.



capillaries, the blood from which is returned by small veins, which end in tributaries of the umbilical vein. The maternal arteries open into the sinuses somewhat after the manner of the arteries of erectile tissues. These spaces communicate with a plexus of veins which anastomose freely with one another and give rise, at the edge of the placenta, to a venous channel which runs around its whole circumference—the *placental sinus*.

✓ The **umbilical cord** appears about the end of the fifth week after conception. It consists of the coils of two arteries (*umbilical*, originally *allantoic*) and a single vein, united together by a gelatinous tissue (*jelly of Wharton*). There are originally two umbilical veins, but one of these vessels becomes obliterated, as do also the two omphalo-mesenteric arteries and veins and the duct of the umbilical vesicle, all of which are originally contained in the rudimentary cord. The permanent structures of the cord are, therefore, furnished by the allantois.

In this manner the human embryo eventually becomes surrounded by three membranes: (1) the *amnion*, derived from the outer layer of the mesoblast and the epiblast; (2) the *chorion*, formed most probably by three layers—the allantois (which is derived from the inner layer of the mesoblast and hypoblast), the false amnion, and perhaps the vitelline membrane; and (3) the *decidua*, derived from the mucous membrane of the uterus.

### DEVELOPMENT OF THE EMBRYO

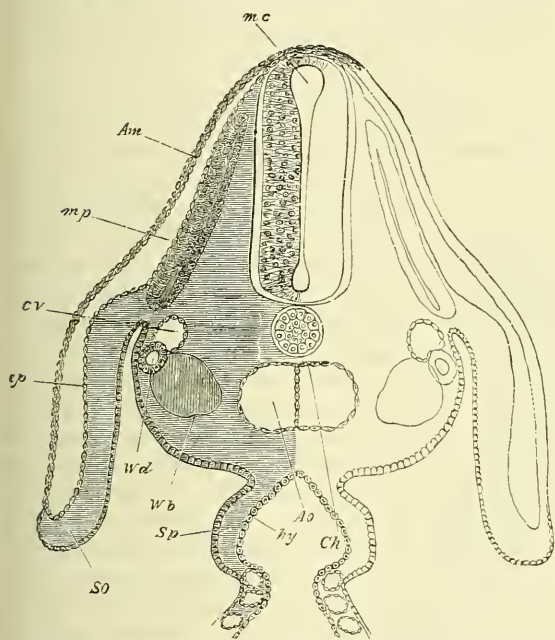
The further development of the embryo will, perhaps, be better understood if we follow as briefly as possible the principal facts relating to the chief parts of which the body consists—viz. the spine, the cranium, the pharyngeal cavity, mouth, &c., the nervous centres, the organs of the senses, the respiratory system, the alimentary canal and its appendages, the organs of respiration, and the genito-urinary organs.\* The reader is also referred to the chronological table of the development of the fœtus at the end of this section.

**Development of the Spine.**—We have already traced the first steps in the formation of the spine.—(1) The looping up of two longitudinal folds from the cells of the epiblast on either side of the primitive streak, so as to form a groove, and the gradual growing together of these ridges (*lamina dorsales*) so as to convert the groove into a canal, which is lined by epiblast, and out of which the spinal cord is developed. (2) The formation in front of this groove of a continuous cellular cord, enclosed in a structureless sheath, the *notochord* or *chorda dorsalis* (fig. 91). The notochord extends from the cephalic to the caudal extremity of the embryo, and lies in the place which is afterwards occupied by the bodies of the vertebræ. (3) On either side of the neural canal, a portion of the mesoblastic layer is divided longitudinally from the rest of the mesoblast, so as to form a thick column, which extends from the cephalic to the caudal extremity of the embryo on either side of the spinal canal and notochord (fig. 85, A 7); this is the *protovertebral column*. From the greater part of it is derived the vertebral column, a small portion at the upper and outer part being differentiated from it and eventually forming the muscles of the back. (4) This column undergoes a process of transverse segmentation and becomes converted into a number of quadrilateral blocks, the *protovertebral somites* (fig. 92). The process of segmentation commences in the cervical region and proceeds successively through the other regions of the spine until a number of segments are formed, which correspond very closely to the number of the permanent vertebræ. (5) These protovertebral somites extend laterally; they grow forwards and inwards until they meet in front of the notochord in the middle line, which they thus enclose; and backwards and inwards, around the spinal canal, which they also enclose.

\* The scope of this work only permits the briefest possible reference to these subjects. Those who wish to study the subject of embryology in more detail are referred to Kölliker's *Entwickelungsgeschichte*; to vol. i. pt. 1, of the tenth edition of Quain's *Anatomy*; or to the works of Professor Dalton and of Foster and Balfour.

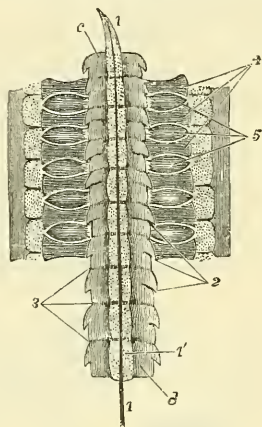
The notochord and the spinal canal are thus surrounded by a cellular mass derived from the mesoblastic layer, which constitutes the *membranous matrix* of the vertebræ. This structure is covered on its internal surface by hypoblast, and on its outer by epiblast, and presents the transverse segmentation already described (page 81). (6) The next step is the conversion of this primitive membranous matrix into cartilage. This takes place probably about the fourth or fifth week in the human embryo (Kölliker). The part of the protovertebral somites which has extended backwards to enclose the spinal foramen, and which eventually forms the arches of the vertebræ, simply undergoes a process of chondrification, so that the permanent arches correspond to the primary segments of the protovertebral somites, spaces being left between them for the spinal nerves and ganglia to grow out from the spinal chord. But a somewhat

FIG. 91.—Transverse section through the dorsal region of an embryo-chick, end of third day. (From Foster and Balfour.)



Am. Amnion. mp. Muscle-plate. cv. Cardinal vein. Ao. Dorsal aorta at the point where its two roots begin to join. Ch. Notochord. Wd. Wolffian duct. Wb. Commencement of formation of Wolfian body. ep. Epiblast. So. Somatopleure. hy. Hypoblast. The section passes through the place where the alimentary canal (hy) communicates with the yolk-sac. Sp. Splanchnopleure.

FIG. 92.—Cervical part of the primitive vertebral column and adjacent parts of an embryo of the sixth day, showing the division of the primitive vertebral segments. (From Kölliker, after Remak.)



1. 1. Chorda dorsalis in its sheath, pointed at its upper end. 2. points by three lines to the original intervals of the primitive vertebrae. 3. in a similar manner, indicates the places of new division into permanent bodies of vertebrae. c indicates the body of the first cervical vertebra; in this and the next the primitive division has disappeared, as also in the two lowest represented, viz. d and the one above; in those intermediate the line of division is shown. 4. points in three places to the vertebral arches; and 5. similarly, to three commencing ganglia of the spinal nerves: the dotted segments outside these parts are the muscular plates.

more complex change goes on in the portion of the protovertebral somites which encloses the notochord and which is destined to form the bodies of the vertebræ. Here each one of the protovertebral segments undergoes a second transverse division through its centre, and in the interval which is left between these secondary segmentations the fibrous structure of the intervertebral discs is formed. The half-segment of the original protovertebral somites on either side of this secondary segmentation joins with the segment above and below, and undergoes chondrification, and thus forms the basis of the body of a future vertebra. Each cartilaginous body of a vertebra is formed therefore out of half an original protovertebral plate joined to the half of another plate above or below it, as the case may be. (7) The notochord contained in the centre of this



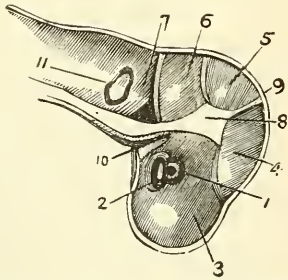
chondrifying mass does not continue to grow, but becomes in the human subject relatively smaller, so as, at last, to form a mere slender thread, except opposite the secondary segmentations; that is to say, corresponding to the intervals between the bodies of the permanent vertebræ. Here it presents thickenings, and forms an irregular network, the remains of which are to be found at all periods of life in the central pulp of the intervertebral discs.

**Development of the Ribs and Sternum.**—The ribs are formed by extensions of the protovertebral mesoblast between the muscle-plates, growing out from the cartilaginous vertebræ. These speedily undergo chondrification, and appear as cartilaginous bars, and become separated from the vertebræ at their posterior extremities. At their anterior ends the costal bars, which are to form the nine upper ribs, turn upwards and fuse together so as to form a cartilaginous strip bounding a central median fissure. The strips on either side then join in the middle line from before backwards, and so give rise to a longitudinal piece of cartilage, which represents the manubrium and gladiolus of the sternum. In the process of development the sternal attachment of the eighth rib disappears, while that of the ninth subdivides, one portion remaining attached to the inferior extremity of the cartilaginous sternum and becoming developed into the ensiform cartilage, the other portion receding from the sternum and becoming attached to the rib above.

The further development of the vertebræ, ribs, and sternum, and the ossification of their cartilaginous structure, are described in the body of the work.

**Development of the Cranium in general and the Face.**—We have seen that the first trace of the embryo consists in the formation of a longitudinal fold of the epiblast on either side of a median groove, and that these folds or ridges grow backwards and meet in the median line, thus forming a canal. This canal, at the cephalic extremity of the embryo, is dilated and forms a bulbous enlargement. The bulbous enlargement soon expands into three vesicular dilatations, which are known as the three *primary cerebral vesicles*, from which all the different parts

FIG. 93.—Longitudinal section of the head of an embryo four weeks old, seen from the inside.



1. Ocular vesicle. 2. Optic nerve flattened out. 3. Fore brain. 4. Intermediary brain. 5. Middle brain. 6. Hinder brain. 7. After brain. 8. Anterior portion of the tentorium cerebelli. 9. Its lateral portion intervening between Nos. 4 and 5. 10. The pharyngeal curve, bent into a *cul-de-sac*. 11. The auditory vesicle.

of the encephalon are presently to be developed. The most anterior of the three forms the optic thalamus, whilst a hollow projection from it forms the corpus striatum and the cerebral hemispheres; the middle one forms the tubercula quadrigemina; the posterior the medulla oblongata. The primary cerebral vesicles are at this time, of course, hollow, and their cavities freely communicate with each other at the points of constriction. As the embryo grows, the cerebral vesicles become twice bent forward on their own axis (figs. 93, 94, A and B). The upper or posterior curvature is called the cerebral; the lower or anterior, the frontal protuberance.

Thus, we have a triple cavity (see fig. 94, A, where the three cavities are marked *c*, *mc*, and *mo*), lined by epiblast and covered by the same structure. Between these two layers of epiblast, a layer of mesoblast, derived from the

protovertebral plates of the trunk, is prolonged and spreads over the whole surface of the cerebral vesicles. From these structures the cranium and its contents are developed. The external layer of the epiblast forms the superficial epithelium of the scalp. The mesoblastic layer forms the true skin, the blood-vessels, muscles, connective tissue, bones of the skull and membranes of the brain. The layer of epiblast lining the cavity forms the nervous substance of the encephalon, while the cavity itself constitutes the ventricles.

The upper end of the notochord terminates at its cephalic end in a pointed



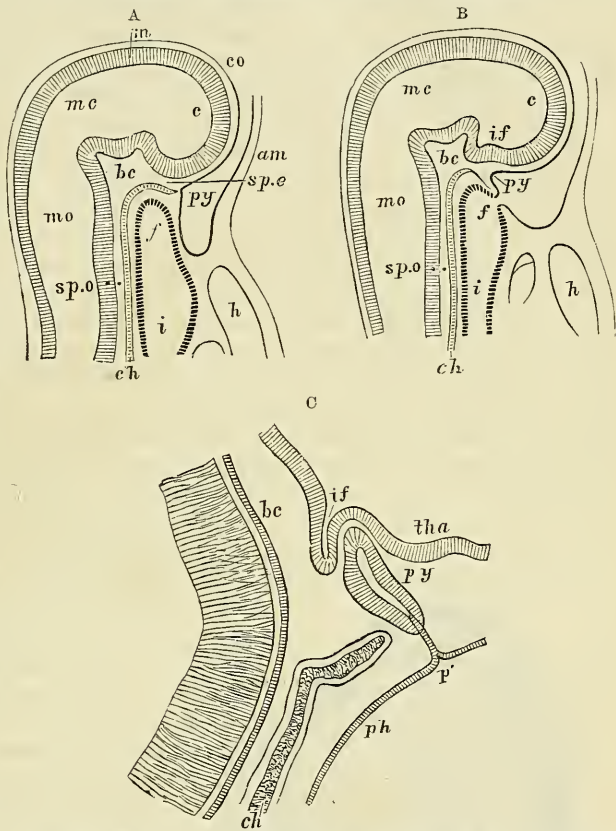
extremity which extends as far forwards as the situation of the body of the future sphenoid bone, and is there embedded in a mass of tissue, the 'investing mass of Rathke.' This mass, derived from mesoblastic tissue, becomes cartilaginous, and from it is developed the basi-occipital and basi-sphenoid bones; and by lateral expansions from it the occipitals, the greater wings of the sphenoid, and the periotic mass of cartilage surrounding the primary auditory vesicles.

From the front of the investing mass of Rathke, which corresponds in position to the future dorsum sellæ, two lateral bars are directed forwards enclosing a space, which forms the pituitary fossa, in which the pituitary body is eventually developed. These bars are named the *trabecula cranii*, and extend as far forwards as the anterior extremity of the head, where they coalesce with each other. From them the pre-sphenoid and lateral masses of the ethmoid are developed; and from their coalescence a process, the *fronto-nasal process*, is prolonged downwards to form a portion of the framework of the face, hereafter to be described. From the pre-sphenoids, which are developed from these trabeculæ, a lateral expansion takes place, which forms the orbito-sphenoid or lesser wings of the sphenoid, enclosing the optic foramen.

The portions of the base of the skull above enumerated are formed from cartilage; the remaining parts, comprising the vault of the skull, are of membranous formation.

The head at first consists simply of a cranial cavity, the face being subsequently developed in the manner now to be described by a series of arches with clefts between them (fig. 95). It is usual in our text-books to describe the arches as a series of processes which jut out and grow downwards, inclining towards each other until they meet in the middle line and thus form a series of inverted arches; whilst the clefts are the spaces left between each pair of processes. This, however, is scarcely the true description, and leads rather to the false impression that the arches are formed by processes budding out from the embryo, much in the same way as the extremities do, and that they are free on every

FIG. 94.—Vertical section of the head in early embryos of the rabbit. Magnified. (From Mihalkovics.)

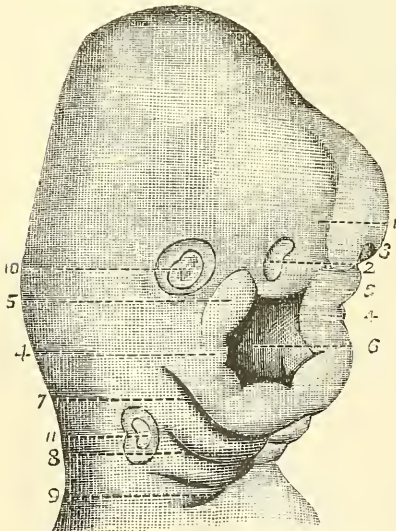


A. From an embryo of five millimètres long. B. From an embryo of six millimètres long. C. Vertical section of the anterior end of the notochord and pituitary body, &c., from an embryo sixteen millimètres long. In A, the faucial opening is still closed. In B, it is formed. c. Anterior cerebral vesicle. mc. Meso-cerebrum. mo. Medulla oblongata. co. Corneous layer. m. Medullary layer. if. Infundibulum. am. Amnion. spe. Spheno-ethmoidal. bc. Central (dorsum sellæ), and spo, spheno-occipital parts of the basis cranii. h. Heart. f. Anterior extremity of primitive alimentary canal and opening (later) of the fauces. i. Cephalic portion of primitive intestine. tha. Thalamus. p'. Closed opening or the involuted part of the pituitary body (py). ch. Notochord. ph. Pharynx.

side. The more correct description is that the clefts are first formed, and that the arches consist of a thickening of the tissue on either side of the cleft. The arches thus formed may be divided into two sets, according as they are placed in front or behind the buccal cavity or mouth, the former being known as the *pre-oral*, and the latter as the *post-oral* or *visceral* arches. Four clefts on each side appear laterally in the undifferentiated somato-splanchno-pleural wall of the fore-gut, and between them thickenings occur which ultimately meet and fuse in the middle line, and above are connected with the investing mass. These are the so-called post-oral visceral arches. Differentiation of tissue occurs from above downwards, and cartilage is formed in them in connection with the investing mass. The first post-oral arch has no cleft in front of it, but forms a rim in front of the fore-gut. The pre-oral arches are formed in much the same way by local thickening, in which differentiation of tissue and formation of cartilage proceeds in a direction forwards and downwards from the investing mass.

The *pre-oral* or *maxillary arch* unites with the *fronto-nasal* process. The latter, which is derived, as stated above, from the coalescence of the trabeculae cranii, consists of three plates, a central single one and two lateral ones. The *central* is called the '*mid-frontal*' process. It is prolonged downwards and forwards from the middle of the base of the skull, from the point of coalescence of the two trabeculae cranii, and from it the septum of the nose is developed. It is free in front and below, but behind it is united with the coalesced portion of the trabeculae, which therefore probably assists in the formation of the septum nasi, and, in addition, of the prominent part of the future nose. The *lateral* plates of the fronto-nasal process are separated from the central one by a depression or furrow on either side; these furrows form the primary nasal pits or fossae. The lateral plates project downwards parallel to the mid-process for a certain distance, and then, curving inwards, unite with it, thus shutting off the nasal fossae from the rest of the face. The lateral masses of the ethmoid and lachrymal bones are developed in the lateral plates, and by their union with the mid-frontal process form the intermaxillary bone and the *lunula*, or central part of the upper lip.

FIG. 95.—Face of an embryo of 25 to 28 days. Magnified 15 times.



1. Frontal prominence.
- 2, 3. Right and left olfactory fossae.
4. Inferior maxillary tubercles, united in the middle line.
5. Superior maxillary tubercles.
6. Mouth or fauces.
7. Second pharyngeal arch.
8. Third.
9. Fourth.
10. Primitive ocular vesicle.
11. Primitive auditory vesicle.

The *maxillary* processes spring from the base of the skull further back than the fronto-nasal process, and at their origin are closely connected with the first post-oral or visceral arch. They descend for a short distance, forming the outer wall of the orbit, in which the malar bone is developed; they then incline inwards, and, meeting the lateral plate of the fronto-nasal process, form the floor of the orbit, and shut it off from the rest of the face; then, continuing their course downwards and inwards, they join the mid-frontal process, and with it complete the alveolar arch and the superior maxillary bone. Finally, palatal processes are formed by an extension of the inner sides of this arch; these coalesce with each other in the median line, thus separating the cavity of the mouth from the nasal fossae, and completing the palate.

In front, however, the palatal processes do not join with the mid-frontal process, but a cleft is left which constitutes the naso-palatine canal.

The *post-oral* arches are five in number in the amniota, and of these the



first only is concerned in the formation of the face proper, for the lower jaw or mandible is in part developed from it, and hence it is called the *mandibular* arch. The second is named the *hyoid* arch: from it are formed the styloid process, the stylo-hyoid ligament, and the lesser cornu of the hyoid bone. The third, or *thyro-hyoid* arch, gives origin to the great cornu of the hyoid bone, while the body of this bone is formed between the second and third arches. This third arch, together with the fourth and fifth, correspond to the arches which, in fishes and amphibia, form the gill-plates, but which, in the anniota, never do so. They are appropriately named *branchial*, a name which was primarily given to the whole series by Rathke, who first described them.

The deeper part of the first or mandibular arch contains a transitory cartilaginous rod, which has long been known as the 'cartilage of Meckel,' the proximal end of which is at first attached to the basis cranii, and afterwards to the periotic capsule. It is, during some part of fœtal life, directly continuous with the malleus, which by some is believed to be developed from it. The median end of the lower jaw-bone is developed from this cartilage; the greater part of the rest of the bone being developed from membrane.

Between the mandibular arch and the pre-oral arch the buccal cavity or mouth is formed; this therefore owes its origin to the formation of the pre-oral and post-oral arches, and consists of mesoblastic tissue lined by epiblast. As has been already stated (page 81) the cephalic end of the embryo becomes remarkably curved on itself, the fore- and mid-brain bending downwards over the anterior portion of the original blastodermic membrane which remains within the body of the embryo and from which the fore-gut is to be developed. This fore-gut terminates as a blind extremity beneath the head (fig. 94, A, f). Another prominence forms on the ventral surface of the fore-gut, which represents the rudimentary heart (fig. 94, A, h). Between these two prominences, caused by the projection of the fore-brain and the heart, an involution of the epiblast takes place, gradually deepening until it comes in contact with the upper part of the alimentary canal. This is the *stomodæum* or *mouth*, which becomes bounded by prominences, constituting the pre-oral and mandibular arches. It is at first quite distinct from the upper part of the alimentary canal, which, as we shall hereafter see, is formed by the inner or splanchno-pleural layer of the mesoblast and the hypoblast, the two cavities being separated by all the layers of the blastodermic membrane. A communication between the two is, however, gradually effected by the absorption of these layers at the anterior extremity of the primitive alimentary cavity and the hinder portion of the epiblastic involution from which the mouth is formed.

Between each of these visceral arches are clefts, four in number, which run through the tissues of the neck to the cavity of the pharynx; the first persists, though only in a portion of its extent, forming the Eustachian tube, the meatus auditorius, and the tympanic cavity. The other fissures are wholly closed by the sixth week.

**Development of the Nervous Centres and the Nerves.**—The medullary groove above described (page 80) presents, about the third week, three dilatations at its upper end, separated from one another by two constrictions, and at its posterior part another dilatation, called the *rhomboidal sinus*. Soon afterwards the groove becomes a closed canal (*medullary canal*) and a soft blastema lines it, exhibiting corresponding dilatations. This is the rudiment of the cerebro-spinal axis. As the embryo grows, its cephalic part becomes more curved, and the three dilatations at the anterior end of the primitive cerebro-spinal axis become vesicles distinctly differentiated from each other (fig. 93). These are the primary cerebral vesicles—anterior, middle, and posterior. Subsequently the anterior and posterior vesicles become subdivided and each forms two vesicles, whilst the middle one remains permanently undivided. It will thus be seen that at the anterior extremity of the medullary groove are five dilatations, separated from each other by constrictions, from which the five fundamental divisions of the



brain are formed. These five permanent rudiments of the brain and medulla have received the names, from before backwards, of prosencephalon, thalamencephalon, mesencephalon, epencephalon, and metencephalon. The first two of these are formed from the anterior primary vesicle, the last two from the posterior primary vesicle, and the mesencephalon from the middle primary vesicle. In addition to this a hollow protrusion takes place from the anterior primary vesicle, which constitutes the rudiment of the optic nerve and retina, as will be explained in the sequel (fig. 96, A). Subsequently another protrusion takes place from the anterior vesicle (prosencephalon), which is at first simple, but soon becomes divided into two parts by an antero-posterior fissure. These expand forwards, backwards, and laterally, and form the cerebral hemispheres (fig. 96 H).

These vesicles do not, however, remain in the same line as the cord, but certain definite flexures take place, which result in an alteration of the position of the vesicles to one another. The first of these flexures takes place opposite the base of the middle vesicle, which becomes sharply bent on itself over the end of the notochord. This has the effect of causing the mid-brain to become the most prominent part of the encephalon on the convexity of the curve (fig. 96, M). A second flexure, with its curve in the opposite direction, takes place in the epencephalon and is very abrupt. A third, but less marked, flexure, takes place in the metencephalon at its junction with the cord and has its concavity forwards, in the same direction as the first curve. The first of these curves or flexures remains permanently, but the second and third almost entirely disappear in the further development of the brain.

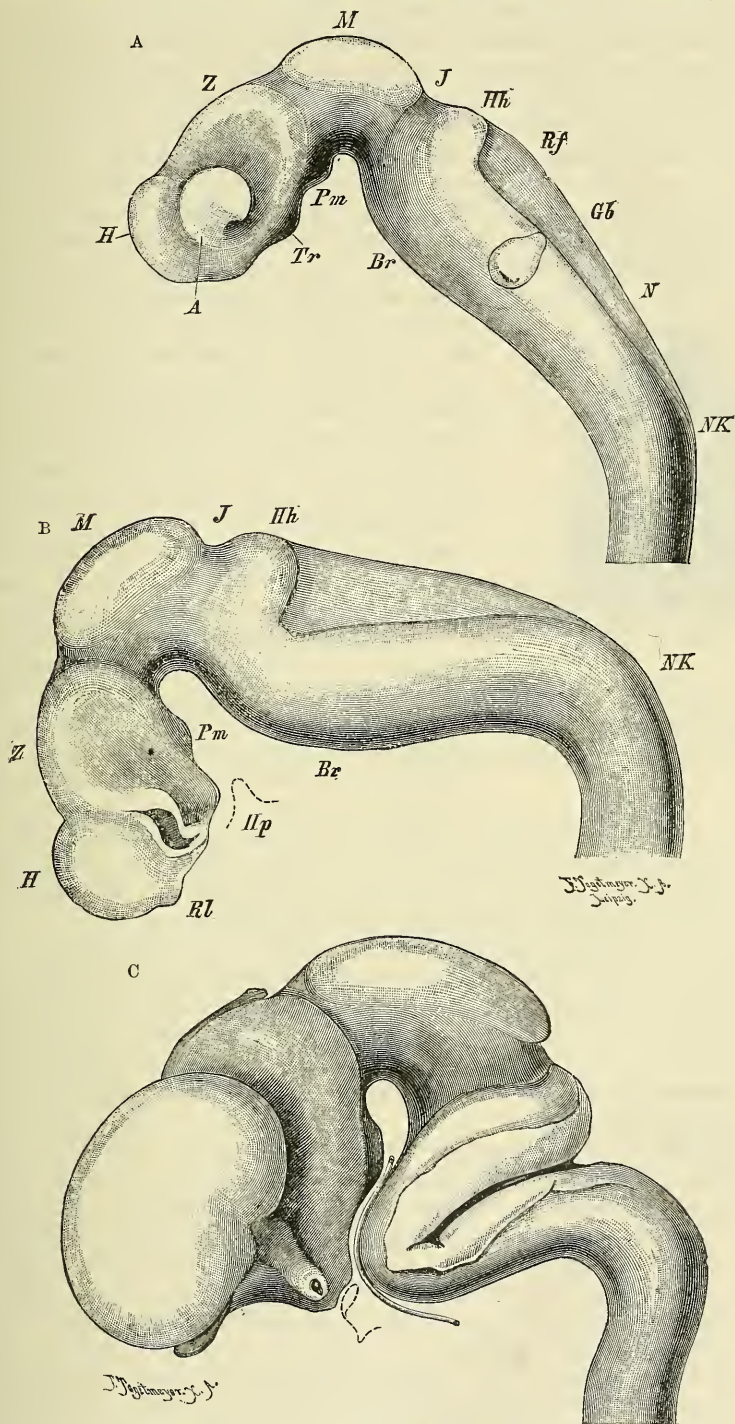
The different parts of the brain are formed on the walls of the vesicles as local thickenings in different positions. These thickenings, as they increase, gradually encroach upon the interior of the vesicles; a permanent cavity, however, remains, which constitutes the cavity of the ventricles.

The parts of the brain formed from the prosencephalon, or first secondary vesicle, are first of all the cerebral hemispheres, which, as has been stated, are formed as hollow outgrowths from this vesicle, on the interior of which thickening takes place. They are at first covered and concealed by the middle primary vesicle, in consequence of the flexure which takes place, but by the third month they have risen above the optic thalami, and by the sixth month above the cerebellum. The other parts formed from the prosencephalon are the corpora striata, the corpus callosum, the fornix, and the olfactory bulbs and tract. The cavity of this vesicle forms the lateral ventricles, the foramen of Monro, and the anterior part of the third ventricle. The portions of the encephalon developed from the thalamencephalon, or second secondary vesicle, are the optic thalami, the pineal gland, a part of the pituitary body, and, by a special prolongation, the optic nerve and retina. The cavity of this vesicle constitutes that part of the third ventricle which is not formed by the first secondary vesicle. The mesencephalon, or third secondary vesicle, corresponding to the middle primary vesicle, is developed into the corpora quadrigemina and the crura cerebri. This vesicle is at first situated at the summit of the angle caused by the first flexure (fig. 96, A). Its smooth surface is soon divided by a median and transverse groove into four tubercles (tubercula quadrigemina), which are gradually covered in by the growth of the cerebral hemispheres. Its cavity diminishes as its walls thicken, and contracts to form the aqueduct of Sylvius.

The epencephalon, or fourth secondary vesicle, is developed into the pons Varolii and the cerebellum, and the metencephalon, or fifth secondary vesicle, forms the medulla. The cavity of these two secondary vesicles, which it will be remembered constituted the third primary vesicle, forms the fourth ventricle.

The development of the pituitary body has of late received much attention. It is mainly formed by a diverticulum from the buccal involution of epiblast. At its upper and front part this involution, from which the mouth or stomodæum is developed, forms a hollow saccular protrusion, which extends into the angle formed by the bend of the mid-brain. Here it comes in contact with a median

FIG. 96.—Profile views of the brain of human embryos at three several stages, reconstructed from sections (His.) Copied from Quain's 'Anatomy.'



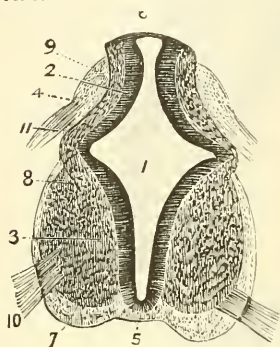
A. Brain of an embryo of about fifteen days, magnified 35 diameters. B. Brain of an embryo about three and a half weeks old. The optic vesicle has been cut away. C. Brain of an embryo about seven and a half weeks old. The optic stalk is cut through. A. Optic vesicle. H. Vesicle of cerebral hemisphere, first secondary vesicle. Z. Thalamencephalon, second secondary vesicle. M. Mid-brain. J. Isthmus between mid- and hind-brain. Hh. Fourth secondary vesicle. N. Fifth secondary vesicle. Gb. Optic vesicle. Rf. Fourth ventricle. NK. Neck curvature. Br. Pons curvature. Pm. Mammillary process. Tr. Infundibulum. Hp. (in B). Outline of hypophysis-fold of buccal epiblast. Rl. Olfactory fold. In C the basilar artery is represented along its whole course.



hollow protrusion, which passes downwards and backwards from the posterior portion of the anterior cerebral vesicle (fig. 94, c, *if*). They become intimately connected, and together form the pituitary body or hypophysis.

When the medullary groove is first closed, the foetal spinal marrow occupies its whole length, and presents a large central canal, which gradually contracts in consequence of the thickening and rapid growth of the epiblast around it. This increase in thickness takes place principally at the sides, so that eventually the central canal acquires on section the appearance of a slit. According to

FIG. 97.—Section of the medulla in the cervical region, at six weeks. Magnified 50 diameters.



1. Central canal. 2. Its epithelium. 3. Anterior grey matter. 4. Posterior grey matter. 5. Anterior commissure. 6. Posterior portion of the canal, closed by the epithelium only. 7. Anterior column. 8. Lateral column. 9. Posterior column. 10. Anterior roots. 11. Posterior roots.

some investigators, the two sides of this slit eventually join in the middle, and the original canal is divided into two: an *anterior*, which becomes the central permanent canal, which in after-life is no longer perceptible to the eye, though it is still visible on microscopic section; and a *posterior*, which becomes filled about the ninth week with a septum of connective tissue from the pia mater, and forms the posterior fissure of the cord. According to other observers, the posterior fissure is formed independently of the central canal, as a cleft formed by the enlarging lateral halves of the cord, into which an ingrowth of connective tissue from the pia mater takes place. The anterior fissure is apparently formed in this latter manner, simply as a cleft left between the lateral halves of the cord.

After the fourth month the spinal column begins to grow in length more rapidly than the medulla spinalis, so that the latter no longer occupies the whole canal. The cord is composed at first entirely of uniform-looking cells, which soon separate into two layers, the inner

of which forms the epithelium of the central canal, while the outer forms the central grey substance of the cord (fig. 97). The white columns are formed later; their rudiments can be detected about the fourth week, and some embryologists believe that they are developed from the mesoblast.

The cerebral and spinal membranes are, according to Kölliker, a production from the protovertebral discs, and are recognisable about the sixth week. As the fissures separating the segments of the cerebro-spinal axis appear, the membranes extend through them, and the pia mater passes into the cerebral ventricles. Bischoff, however, describes the pia mater and arachnoid as developed from the cerebral vesicles, so that they are, according to him, formed in the position which they permanently occupy.

**The Nerves.**—The nerves are developed, like the rest of the nervous system, from epiblast. The spinal nerves are developed as follows:—Close to the point of involution of the epiblast in the median line, that is to say, in the angle of junction of the neural and general epiblast, a cellular swelling constituting the *neural crest* appears and forms a continuous ridge on the dorsal aspect of the neural canal. On this crest enlargements occur, corresponding with the middle of each protovertebral segment. These grow downwards between the neural canal and the mesoblastic tissue forming the protovertebræ, and occupy a position on the lateral wall of the canal. These enlargements are the rudiments of the ganglia of the posterior roots; they are at first attached to the neural crest from which they spring, but subsequently this attachment becomes lost, and they then form isolated masses on either side of the neural canal, which now contains the rudimentary cord. They consist of oval cells, from either end of which a process eventually springs; one, passing centrally, grows into the embryonic cord and constitutes the posterior root of the nerve; the other, growing peripherally, joins the fibres of the anterior root to form the spinal nerve.



The anterior root is, according to the recent researches of His, a direct outgrowth of certain cells which are found in the rudimentary cord and which are named *neuroblasts*. These cells, like those mentioned above, are oval, and have a prolongation directed outwards towards the surface of the cord. These processes pass out of the cord in bundles and penetrate the mesoblast and join with fibres of the posterior root, and from the point of union the nerve grows towards its peripheral termination.

Most of the cranial nerves are developed in the same manner as the posterior roots of the spinal nerves. That is to say, the neural crest, developed from the epiblast, is continued onwards, along the dorsal surface of the cephalic portion of the neural tube, as far as the mid-brain. From this a series of swellings at irregular intervals form the rudimentary ganglia, from the polar cells of which the nerve is formed and its connection with the brain established. This appears to be the case with the third, fifth, the facial, the auditory, the glosso-pharyngeal, and the pneumogastric and probably the fourth. With regard to the mode of origin of the sixth, the spinal accessory and the hypoglossal, our knowledge is not so exact, but they would appear to arise, like the anterior roots of the spinal nerves, from groups of oval cells (*neuroblasts*) in the basal lamina.

The olfactory tract and bulb is a protrusion of the antero-ventral part of each cerebral hemisphere. This protrusion comes in contact with the thickened epiblast of the olfactory area (see page 100), from which neuroblastic cells, which are formed within the area, pass out and form a ganglion between the area and the olfactory bulb. From this ganglion cell-processes grow centripetally to form the nerve-roots, and centrifugally to form the olfactory nerves which ramify on the Schneiderian membrane.

The optic nerve arises in a manner entirely different from any of the other cranial nerves, as a hollow outgrowth of the brain, which subsequently becomes solid. It will be considered in connection with the development of the eye.

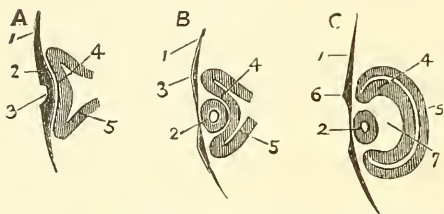
The sympathetic nerves are developed as outgrowths from the gangliated roots of the spinal and cranial nerves.

**Development of the Eye.**—The nervous elements and non-vascular parts of the eye are formed from the epiblast, and the vascular portions from the mesoblast; but the method of development is somewhat complicated. The essential portion of the eye—i.e. the retina and the parts immediately connected with it—is an outgrowth from the rudimentary brain (primitive ocular vesicle), and this outgrowth is met by an ingrowth from the common epidermic or corneous layer of the epiblast, out of which the lens and the conjunctival and corneal epithelium are developed.

The first appearance of the eye consists in the protrusion or evolution from the medullary wall of the thalamencephalon of a vesicle, called the *primitive ocular vesicle*. This is at first an open cavity communicating by a hollow stalk with the general cavity of the cerebral vesicle. As development advances the hollow stalk becomes solid, and thus the optic nerve is formed, receiving, however, in a way presently to be explained, mesoblastic elements for the formation of its central artery and connective tissue. As the primitive ocular vesicle is prolonged forwards, it meets the epidermic layer of the epiblast, which at the point of contact becomes thickened, and then forms a depression which gradually encroaches on the most prominent part of the primitive ocular vesicle, which in its turn appears to recede before it, so as to become at first depressed and then inverted in the manner indicated in fig. 98, so that the cavity is finally almost obliterated by the folding back of its anterior half, and the original sac converted into a cup-shaped cavity, the *ocular cup*, in which the involuted epiblastic layer, the rudiment of the lens, is received (fig. 98, B). This cup-shaped cavity consists therefore of two layers: one, the outer, originally the posterior half of the primitive ocular vesicle, is thin, and eventually forms

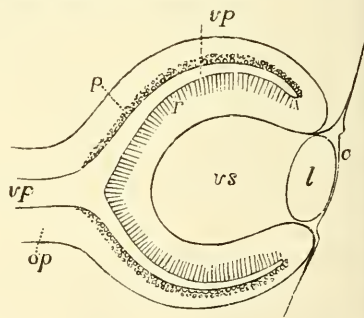
the pigmental layer of the retina;\* the other layer, the inner, originally the anterior or more prominent half, which has become folded back, and is much thicker, is converted into the nervous layers of the retina. Between the two are the remains of the cavity of the original primary vesicle, which finally becomes obliterated by the union of its two layers. As development proceeds the cup-shaped cavity or ocular cup increases in size, and thus a space is formed between it and the rudimentary lens which it contains; this is the *secondary ocular vesicle*, and in it the vitreous humour is developed (fig. 98, c). The folding in of the primary optic vesicle to produce the optic cup not only takes place in front, at its most prominent part, opposite the lens, but also below, where a cleft or fissure is formed, the *choroidal fissure* or *ocular cleft*, through which vascular elements, within the vesicle and derived from the mesoblast, retain their connection with the rest of the mesoblast. This gap or cleft is continued for some distance into the stalk of the optic vesicle and thus allows a process of the mesoblast to extend down the stalk to form the *arteria centralis retinae* and its accompanying vein. After a time the gap or fissure becomes closed, by a coalescence of its margins, but the line of union remains apparent for some considerable period. The lens is at first a thickening of the epiblast, then a depression or involution takes place, thus forming an open follicle, the margins

FIG. 98.—Diagram of development of the lens.



A B C. Different stages of development. 1. Epidermic layer. 2. Thickening of this layer. 3. Crystalline depression. 4. Primitive ocular vesicle, its anterior part pushed back by the crystalline depression. 5. Posterior part of the primitive ocular vesicle, forming the external layer of the secondary ocular vesicle. 6. Point of separation between the lens and the epidermic layer. 7. Cavity of the secondary ocular vesicle, occupied by the vitreous.

FIG. 99.—Diagrammatic sketch of a vertical longitudinal section through the eyeball of a human fetus of four weeks. (After Kölliker.) Magnified 100 diameters. The section is a little to the side, so as to avoid passing through the ocular cleft.



c. The cuticle, where it becomes later the cornea. l. The lens. op. Optic nerve formed by the pedicle of the primary optic vesicle. vp. Primary medullary cavity of the optic vesicle. p. The pigment-layer of the outer wall. r. The inner wall forming the retina. vs. Secondary ocular vesicle containing the rudiment of the vitreous humour.

of which gradually approach each other and coalesce, forming an enclosed cavity of epiblastic cells (fig. 98). At the point of involution the external layer of epiblast separates from the ball of the lens and passes freely over the surface, so that the lens becomes disconnected from the epiblastic layer from which it was developed, and recedes into the ocular cup, while the cuticular layer covering it is developed into the corneal epithelium. The cells forming the posterior or inner wall of the cavity, which is to form the lens, rapidly increase in size, becoming elongated and developed into fibres, and, filling up the cavity, convert it into a solid body. The cells on the anterior wall undergo no change and retain their cellular character. The secondary ocular vesicle, or space between the lens and the hollow of the ocular cup (figs. 98, c, 7, and 99), contains a quantity of mesoblastic tissue continuous through the ocular cleft with the rest of the mesoblast, and into this blood-vessels project themselves through the ocular cleft. The iris and ciliary processes are formed from this vascular tissue, and the choroid is developed in the mesoblast surrounding the ocular vesicle.

\* This layer forms functionally part of the choroid, and was formerly described as belonging to this membrane; it is now described as part of the retina, on account of its method of development.



A portion of this tissue also becomes converted into the vitreous humour, and surrounds the lens with a vascular membrane—the *vascular capsule of the lens*, which is connected with the termination of the temporary artery (hyaloid) that forms the continuation of the central artery of the retina through the vitreous chamber. This vascular capsule of the crystalline lens forms the *membrana pupillaris* (described on a subsequent page), and also attaches the borders of the iris to the capsule of the lens. It disappears about the seventh month.

The eyelids are formed at the end of the third month, as small cutaneous folds, which come together and unite in front of the globe and cornea. This union is broken up and the eyelids separate before the end of foetal life.

The lachrymal canal appears to result from the non-closure of a fissure which exists between the lateral plates of the fronto-nasal and maxillary processes. Born, however, considers that it is formed by a thickening of the deeper layer of the epidermis which sinks into the corium and subsequently becomes hollowed out into a tube.

**Development of the Ear.**—The first rudiment of the ear appears shortly after that of the eye, in the form of a thickening of the epiblast, on the outside of that part of the third primary cerebral vesicle which eventually forms the medulla oblongata, opposite the dorsal end of the first post-oral visceral cleft. The thickening is then followed by an involution of the epiblast, which becomes deeper and deeper, sinking towards the base of the skull, and a flask-shaped cavity is formed; by the narrowing of the external aperture the neck of the flask constitutes the *recessus labyrinthi*. The mouth of the flask then becomes closed, and thus a shut sac is formed, the *primitive auditory* or *otic vesicle*, which by its sinking inwards comes to be placed between the ali-sphenoid and basi-occipital matrices. From it the internal ear is formed. The middle ear and the Eustachian tube are developed from the remains of the first branchial cleft, while the pinna and external meatus are developed from the soft parts overhanging the posterior margin of the same cleft. The primary otic vesicle becomes embedded in a mass of mesoblastic tissue, which rapidly undergoes chondrification and ossification. It, as before stated, is at first flask- or pear-shaped; the neck of the flask, or *recessus labyrinthi*, prolonged backwards, forms the aqueductus vestibuli. From it are given off certain prolongations or diverticula, from which the various parts of the labyrinth are formed. One from the anterior end gradually elongates, and, forming a tube, bends on itself from left to right and becomes the cochlea. Three others, which appear on the surface of the vesicle, form the semicircular canals. Of these, the one which is to constitute the external semicircular canal does not appear at such an early date as the other two. Subsequently, a constriction takes place in the original vesicle, which, gradually increasing, divides it into two, and from these are formed the utricle and saccule. Finally, the auditory nerve, which has been developed from the 'neural crest' in the manner above described (page 97), pierces the auditory capsule in two main divisions—one for the vestibule, the other for the cochlea. The middle ear and Eustachian tube are the remains of the first pharyngeal or branchial cleft (hyo-mandibular), and are, from an early period, closed by the formation of the *membrana tympani*, which consists of a layer of epiblast externally, a layer of hypoblast internally, and between the two of mesoblastic tissue constituting its fibrous and vascular layer. With regard to the exact mode of development of the ossicles of the middle ear there is considerable difference of opinion. By some the *malleus* is believed to be developed from the proximal end of the mandibular (Meckel's) cartilage, and the *incus* from the proximal end of the hyoidean cartilage. Others, again, believe that they are both developed from the mandibular cartilage. A third group of observers believe that they are developed from a hyo-mandibular cartilage, similar to that which in some of the lower animals forms a suspensory apparatus for both mandibular and hyoidean arches. The *stapes* is believed by some to be formed



by a deposit of cartilaginous cells around the fenestra ovalis; by others it is supposed to be developed from the proximal end of the hyoidean arch.

The external auditory meatus is developed, like the pinna, from the soft parts on the posterior margin of the first visceral cleft by an outgrowth of the tissues in this situation.

**Development of the Nose.**—The olfactory fossæ, like the primary auditory vesicles, are formed in the first instance by a thickening and involution of the epiblast, which takes place at a point below and in front of the ocular vesicle (fig. 95, 2, 3). The thickening appears at a very early period, about the fourth week. The borders of the involuted portion very soon become prominent, in consequence of the development of the mid-frontal and lateral naso-frontal plates above spoken of (page 92), which are formed on either side of the rudimentary fossæ. As these processes increase, the fossæ deepen and become converted into a deep channel, which eventually forms the upper part of the nasal fossæ—that is, the two superior meatuses, the part to which the olfactory nerves are distributed. At this time they are continuous with the buccal cavity, a portion of which forms the lower part, or inferior meatus of the nasal fossæ. For as the palatine septum is formed, the buccal cavity is divided into two parts, the upper of which forms the lower part of the nasal fossæ, while the remainder forms the permanent mouth.

The soft parts of the nose are formed from the coverings of the frontal projections and of the olfactory fossæ. The nose is perceptible about the end of the second month. The nostrils are at first closed by epithelium, but this disappears about the fifth month.

The olfactory nerve, as above pointed out, is formed from the anterior cerebral vesicle, as a secondary vesicle on its under surface, and it lies upon the involuted epiblast, which subsequently forms the nasal fossæ.

**Development of the Skin, Glands, and Soft Parts.**—The epidermis is produced from the external, the true skin from the middle, blastodermic layer (fig. 82, 19, 20). About the fifth week the epidermis presents two layers, the deeper one corresponding to the rete mucosum. The subcutaneous fat forms about the fourth month, and the papillæ of the true skin about the sixth. A considerable desquamation of epidermis takes place during foetal life, and this desquamated epidermis, mixed with a sebaceous secretion, constitutes the *vernix caseosa*, with which the skin is smeared during the last three months of foetal life. The nails are formed at the third month, and begin to project from the epidermis about the sixth. The hairs appear between the third and fourth month in the form of depressions of the deeper layer of the epithelium, which then become inverted by a projection from the papillary layer of the skin. The papillæ grow into the interior of the epithelial layer; and finally, about the fifth month, the foetal hairs (*lanugo*) appear first on the head and then on the other parts. These hairs drop off after birth, and give place to the permanent hairs. The cellular structure of the sudoriferous and sebaceous glands is formed from the epithelial layer, while the connective tissue and blood-vessels are derived from the mesoblast about the fifth or sixth month. The mammary gland is also formed: partly from mesoblast—its blood-vessels and connective tissue; and partly from epiblast—its cellular elements. Its first rudiment is seen about the third month, in the form of a small projection inwards of epithelial elements, which invade the mesoblast; from this, similar tracts of cellular elements radiate; these subsequently give rise to the glandular follicles and ducts. The development of the former, however, remains imperfect, except in the adult female, and especially after pregnancy.

**Development of the Limbs.**—The upper and lower limbs begin to project, as buds, from the anterior and posterior part of the embryo about the fourth week. These buds are formed by a projection of the somatopleure (i.e. the outer layer of the mesoblast and the epiblast) from the point where the mesoblast splits into its parietal and visceral layers, just external to the vertebral somites, of which

they may be regarded as lateral extensions. The division of the terminal portion of the bud into fingers and toes is early indicated, and soon a notch or constriction marks the future separation of the hand or foot from the fore-arm or leg. Next, a similar groove appears at the site of the elbow or knee. The indifferent tissue or blastema, of which the whole projection is at first composed, is differentiated into muscle and cartilage, before the appearance of any internal cleft for the joints between the chief bones.

The **muscles** become visible about the seventh or eighth week. The vertebral muscles appear to be developed from the 'muscle-plates' of the protovertebræ. These bodies (page 81, and fig. 82, c, 13) consist of a compact mass of cells for the most part irregularly arranged, but externally—that is to say, next the cutaneous epiblast—they become arranged in the form of a single layer of columnar cells. This is known as the *muscle-plate*. On the inner surface of this a second layer of cells makes its appearance, and these begin to elongate in an antero-posterior direction and become developed into longitudinal groups of muscle-fibres. The muscles of the neck and jaws, as well as those which enclose the cavities of the thorax and abdomen, and probably also those of the limbs, are also formed from the same source. The cutaneous muscles are developed from the cutaneous portion of the middle blastodermic layer.

**Development of the Blood-vascular System.**—There are three distinct stages in the development of the circulatory system before it arrives at its complete or adult condition, in accordance with the manner in which nourishment is provided for at different periods of the existence of the individual. In the first stage there is the *vitelline circulation*, during which nutriment is extracted from the yolk or contents of the vitelline membrane. In the second stage there is the *placental circulation*, which commences after the formation of the placenta, and during which nutrition is obtained by means of this organ from the blood of the mother. In the third stage there is the *complete circulation of the adult*, commencing at birth, and during which nutrition is provided for by the organs of the individual itself.

1. The **vitelline circulation** is carried on partly within the body of the embryo and partly external to it in the vascular area of the yolk. It consists of a median tubular heart, from which two vessels (arteries) project anteriorly. These carry the blood to a plexus of capillaries spread over the area vasculosa, and also, though to a less extent, in the body of the embryo. From this plexus the blood is returned by two vessels (veins) which enter the heart posteriorly, and thus a complete circulation is formed.

In these vessels and the heart a fluid (*blood*) is contained, in which rudimentary corpuscles are found. The mode of formation of these elementary parts will have first to be considered.

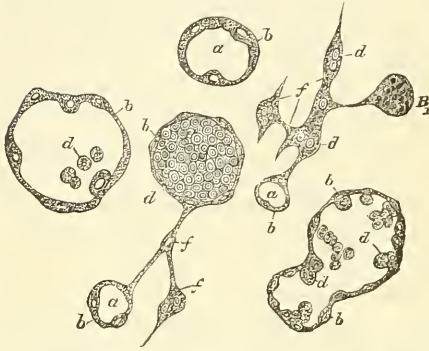
✕ In mammalia the heart is formed by a dilatation of the body cavity on either side of the median line in front of the anterior extremity of the rudimentary pharynx, at about the level of the posterior primary cerebral vesicle. This dilatation is the rudiment of the future pericardium. Into it an invagination of the splanchnopleure takes place on either side of the embryo; this invagination speedily becomes separated from the rest of the splanchnopleure and the aperture of invagination becomes closed. In this manner two closed tubes are formed which present two distinct strata of cells; the inner and thinner layer, derived from the hypoblast, forms the endocardium, the outer and thicker, derived from the visceral mesoblast, forms the muscular wall of the heart. In its very earliest and primitive condition, the heart consists therefore of a pair of tubes, one on either side of the body. These, however, soon coalesce in the median line, and, fusing together, form a single central tube.\* Each of the two primary tubes receives posteriorly a large vessel (a vein), and is prolonged anteriorly into a second vessel (an artery). So that after fusion of the heart-tubes has taken place, there is, in the primitive vitelline

\* In most fishes and in amphibia the heart originates as a single median tube.



circulation, as above mentioned, a single tubular heart, with two arteries proceeding from it and two veins emptying themselves into it. The earliest *vessels* are also formed in the visceral layer of the mesoblast. They are developed from that part of the mesoblast which surrounds the portion of blastoderm which is occupied by

FIG. 100.—Various forms of mother-cells undergoing development into blood-vessels, from the middle layer of the chick's blastoderm. (Klein.)



a. Large mother-cell vacuolated, forming the rudimentary vessel. b. The wall of this cell formed of protoplasm, with nuclei embedded, and in some cases more or less detached and projecting. c. Processes connected with neighbouring cells, formed of the common cellular substance of the germinal area. d. Blood-corpuscles. e. Small mother-cells—vacuolation commencing. f. Mother-cell in which only obscure granular matter is found.

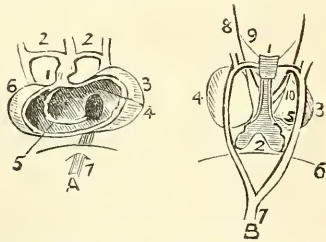
the developing body of the embryo and which is known as the 'vascular area.' So that the first blood-vessels are developed outside the body of the embryo. The indifferent cells of which this layer is composed become enlarged and give off processes, which grow out from the cells in two or more directions. The cells or their processes fuse together, so that an irregular network is formed, consisting of tubes derived from the enlarged cells and their processes (fig. 100). The nuclei of these enlarged cells multiply; some few of the proliferated nuclei remain embedded in the walls of the cell, but the greater number of them are free and are converted into blood-corpuscles. The tubes or primary vessels consist in the first instance of the original protoplasm of the cell, with here and there nuclei, derived from the original divided nucleus embedded in it.

Then differentiation of the protoplasm into flattened cells around these nuclei takes place and constitutes the wall of the capillary or the lining membrane of the larger vessel. In these latter, other cells, derived from the mesoblast, apply themselves externally and form the other coats of the vessel at a later period.

The *blood-discs* are formed from the original divided nucleus of the vacuolated mesoblastic cells. They are free, and accumulate, each one around itself, a small quantity of the protoplasm of the cell, which rapidly acquires a tinge of colour. The earliest blood-corpuscles are therefore at first nucleated, and in this and other respects—

that is, in their possession of amœboid movements and in their capability of undergoing multiplication by division—resemble the white corpuscles. As soon, however, as the liver is formed, true white corpuscles make their appearance, and it seems that the chief source from which they are derived is the embryonic liver, though later on the spleen and lymphatic glands take up this function and continue it after birth. The nucleated condition of the red globules ceases before birth. The vitelline circulation commences about the fifteenth day and lasts till the fifth week. When fully established it is carried on as follows:—Proceeding from the tubular heart are two arteries,

FIG. 101.—Heart at the fifth week.



A. Opened from the abdominal aspect. 1. Arterial sinus. 2. Aortic arches uniting behind to form the descending aorta. 3. Auricle. 4. Auriculo-ventricular orifice. 5. Commencing septum ventriculorum. 6. Ventricle. 7. Inferior vena cava. B. Posterior view of the same. 1. Trachea. 2. Lungs. 3. Ventricles. 4, 5. Auricles. 6. Diaphragm. 7. Descending aorta. 8, 9, 10. Pneumogastric nerves and their branches.

the first aortic arteries (fig. 101), which unite at some distance from the heart into a single artery. This runs down in front of the primitive vertebræ and in the walls of the intestinal cavity, and again divides into two *primitive aortæ* or *vertebral arteries*, and these give off five or six *omphalo-mesenteric* arteries, which ramify



in that part of the blastoderm which surrounds the developing body of the embryo and which is known as the *vascular area*. They terminate peripherally in a circular vessel—the *terminal sinus*. This vessel surrounds the vascular portion of the germinal area, but does not extend up to the anterior end of the embryo. It terminates on either side in a vein called the *omphalo-mesenteric*. The two omphalo-mesenteric veins open into the opposite extremity of the heart to that from which the arteries proceeded.

**2. The Placental Circulation.**—As the umbilical vesicle diminishes, the allantois, which is formed by a protrusion from the lower part of the intestine, enlarges and becomes converted into a vascular chorion, a part of which forms the placenta. When the umbilical vesicle disappears this becomes the only source of nutrition for the embryo. The allantois carries with it two arteries, derived from branches of the primitive aorta, and two veins; these vessels become much enlarged as the placental circulation is established, but subsequently one of the veins disappears, and in the later stages of uterine life the circulation is carried on between the foetus and the placenta by two arteries and one vein (*umbilical*).

During the occurrence of these changes great alterations take place in the primitive heart and blood-vessels, above alluded to, which will now require description.

*Further Development of the Heart.*—The simple median tube, formed by the coalescence of the pair of tubes of which the primitive heart consists, becomes elongated and bent on itself, so as to form an S-shaped tube, the anterior part of the tube bending over to the right, and the posterior to the left. At the same time the middle portion is protruded forwards and arches transversely from right to left, and at the same time becomes twisted on itself so that the extremity from which the arteries are prolonged is situated in front and to the right, and that into which the veins enter is behind and to the left. The bent tube then becomes divided by two transverse constrictions into three parts. One, the posterior, becomes the auricles, the middle one forms the two ventricular cavities, while the anterior forms the aortic bulb, from which the commencement of the aorta and pulmonary artery is developed. A division of each of these cavities now takes place, so as to convert them into right and left ventricle, right and left auricle, and aorta and pulmonary artery respectively. This division first takes place in the middle portion of the tubular heart, the rudimentary ventricular cavities (fig. 101, A, 5). A partition rises up from the lower part of the right wall of this cavity, and gradually grows until it reaches the constrictions which separate it from the other two, and thus the interventricular septum is completed. At the same time a cleft appears on the outside, a little to the right of the most prominent point, which ultimately becomes the apex of the heart. The cleft becomes less marked as development progresses, but remains, to some extent, persistent throughout life, as the interventricular groove.

The first appearance of a division in the posterior or auricular portion of the tubular heart makes its appearance, at a very early period of development, in the shape of two projecting pouches, one on either side; these are the rudiments of the auricular appendages, but the actual division of the cavity by a septum does not occur until some time after the appearance of the ventricular septum. This is formed by the growth of a partition from the anterior wall of the auricular cavity, which grows backwards, and partially separates the cavity into two. The partition, however, is not completed until after birth, a part remaining undeveloped, and thus permitting of a communication (*foramen ovale*) between the two auricles during the whole of foetal life. In a like manner, the aortic bulb is divided into two by the growth of a septum downwards, from the distal end of the bulb, which divides the cavity into the permanent aorta and the pulmonary artery. Very soon a superficial furrow appears on the external surface of this portion of the heart corresponding to the septum internally, and, becoming deeper, the two vessels are gradually separated from each other through the septum, in the immediate neighbourhood of the ventricular portion

of the heart, whilst beyond this they still remain joined together, and give origin to the fourth and fifth aortic arches, presently to be described.

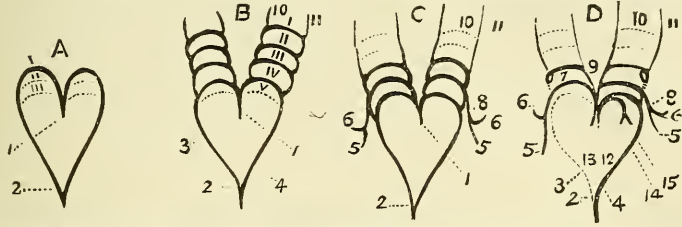
*Further Development of the Arteries.*—In the vitelline circulation, two arteries were described as coming off from the primitive heart, and running down in front of the developing vertebræ. The first change consists in the fusion of these arteries into one at some distance from the heart, thus forming the descending thoracic and abdominal aorta. In consequence of the heart falling backwards to the lower part of the neck and then into the thorax, as the head is developed, the two original arteries, proceeding from the heart to the point of fusion in the common descending aorta, become elongated, and assume an arched form, curving backwards on each side, from the front of the body towards the vertebral column (fig. 102, A). These are the first or primitive aortic arches. As the heart recedes into the thorax, and these arches, which correspond in position to the first pharyngeal or mandibular arch, become elongated, four pairs of arches are formed behind them around the pharynx (fig. 102). The arches, five in number, remain permanent in fishes, giving off from their convex borders the branchial arteries to supply the gills. In many animals the five pairs do not exist together, for the first two have disappeared before the others are formed; but this is not so in man, where all five arches are present and pervious during a certain period of embryonic existence. Only some of the arches in mammalia remain as permanent structures; other arches, or portions of them, become obliterated or disappear. The first two arches entirely disappear. The third remains as a part of the internal carotid artery, the remainder being formed by the upper part of the posterior aortic root, i.e. the descending part of the original vessel which proceeded from the rudimentary tubular heart. The common and external carotid are formed from the anterior aortic root, that is, the ascending portion of the same primitive vessel. The fourth arch on the left side becomes developed into the permanent arch of the aorta in mammals; but in birds it is the fourth arch on the right side which forms the aortic arch; while in reptiles the fourth arch on both sides persists, as there is a permanent double aortic arch. The fourth arch on the right side forms the subclavian artery, and by the junction of its commencement with the anterior aortic root, from which the common carotid is developed, it forms the innominate artery.\* The fifth arch on the left side forms the pulmonary artery and the ductus arteriosus; that on the right side becomes atrophied and disappears. The first part of the fifth left arch remains connected with that part of the bulbous aorta which is separated as the pulmonary stem, and with it forms the common pulmonary artery. From about the middle of this arch two branches are given off, which form the right and left pulmonary arteries respectively, and the remaining portion, i.e. the part beyond the origin of the branches, communicating with the left fourth arch—that is, the descending part of the arch of the aorta—constitutes the ductus arteriosus. This duct remains pervious during the whole of fetal life, and after birth becomes obliterated.

The development of the arteries in the lower part of the body is going on during the same time. We have seen that originally there were two primitive arteries coming off from the primary tubular heart, and that these two vessels, at some distance from the heart, became fused together to form a single median artery, which coursed down in front of the vertebræ to the bottom of the spinal column, forming the permanent descending aorta. From the extremity of this the two vitelline arteries, which were originally parts of the primitive main trunks, passed to the area vasculosa. As the umbilical vesicle dwindles and the allantois grows, two large branches are formed as lateral offshoots of the median aorta. These are the two *umbilical* or *hypogastric* arteries, and are concerned in the

\* This is interesting in connection with the position of the recurrent laryngeal nerve, which is thus seen to hook round the *same* primitive fetal structure, which becomes on the right side the subclavian artery, on the left the arch of the aorta.

placental circulation. The portion of the median aorta beyond this point becomes much diminished in size, and eventually forms the sacra media artery, and thus the two umbilical branches become in appearance bifurcating branches of the

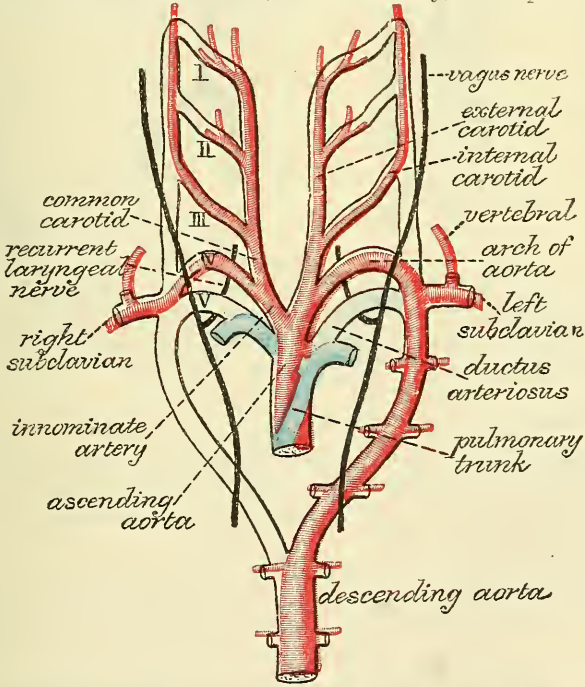
FIG. 102.—Diagram of the formation of the aortic arches and the large arteries.



I, II, III, IV, V. First, second, third, fourth, and fifth aortic arches. A. Common trunk from which the first pair spring; the place where the succeeding pairs are formed is indicated by dotted lines. B. Common trunk, with four arches and a trace of the fifth. C. Common trunk, with the three last pairs, the first two having been obliterated. D. The persistent arteries, those which have disappeared being indicated by dotted lines. 1. Common arterial trunk. 2. Thoracic aorta. 3. Right branch of the common trunk which is only temporary. 4. Left branch, permanent. 5. Axillary artery. 6. Vertebral. 7, 8. Subclavian. 9. Common carotid. 10. External; and 11, Internal carotid. 12. Aorta. 13. Pulmonary artery. 14, 15. Right and left pulmonary arteries.

main aorta. The common and internal iliac arteries are developed from the proximal end of these umbilical arteries; the middle portion of the vessel, after birth, becomes partially atrophied, but in part remains pervious as the superior vesical artery; the distal portion becomes obliterated, constituting part of the superior ligament of the bladder. The external iliac and femoral arteries are

FIG. 103.—Diagram to show the destination of the arterial arches in man and mammals. (Modified from Rathke. From Quain's 'Anatomy,' vol. i. pt. 1. 1890.)



The truncus arteriosus and the five arterial arches springing from it are represented in outline only; the permanent vessels in colours—those belonging to the aortic system red, to the pulmonary system blue.

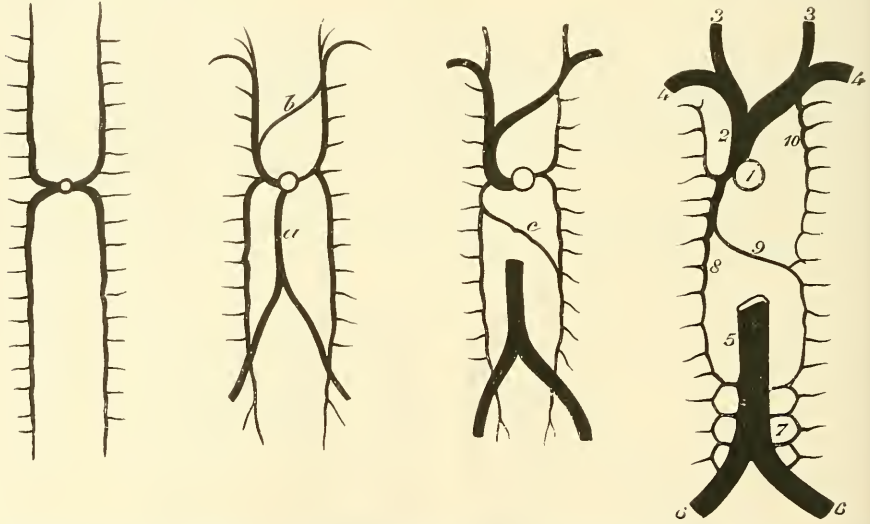
developed from a small branch given off from the umbilical arteries near their origin, and are at first of comparatively small size.

*Development of the Veins.*—The formation of the great veins of the embryo may be best considered under two groups, visceral and parietal.



The visceral are derived from the vitelline and umbilical veins. In the earliest period of the circulation of the embryo, we have seen that there were two veins (vitelline or omphalo-mesenteric) returning the blood from the vitelline membrane. These unite together to form a single channel, the *sinus venosus*, which opens into the auricular extremity of the heart. As soon as the placenta begins to be formed, two umbilical veins appear and open into the sinus venosus, close to the vitelline veins. The two vitelline veins enter the abdomen and run upwards, at first in front of, and subsequently on either side of the intestinal canal; at the upper part of the abdomen, in the site of the future liver, which now begins to form around them, transverse communications are formed, which encircle the duodenum and enclose it in two vascular rings. The portion of veins above these vascular rings loses its connection with the sinus, whilst the portion between them breaks up into a capillary plexus, which ramifies in the now partially developed liver together with capillary vessels from the upper venous ring. Of these latter, some pass towards the heart and join the sinus.

FIG. 104.—Diagrams illustrating the development of the great veins.



The first figure shows the vertebral veins emptying into the heart by two lateral trunks, 'the ducts of Cuvier.' The second figure shows the formation of the iliac and subclavian veins. *a.* Inferior vena cava. *b.* Left innominate vein. The third figure shows the vertebral veins much diminished in size and the duct of Cuvier on the left side, gradually disappearing. *c.* Vena azygos minor. The fourth figure shows the adult condition of the venous system. 1. Right auricle of heart. 2. Vena cava superior. 3. Jugular veins. 4. Subclavian veins. 5. Vena cava inferior. 6. Iliac veins. 7. Lumbar veins. 8. Vena azygos major. 9. Vena azygos minor. 10. Superior intercostal vein. (After Dalton.)

They have received the name of the *venæ hepaticæ revehentes*, and eventually become the hepatic veins; others ramify in the liver, under the name of *venæ hepaticæ advehentes*, and become the branches of the portal vein. The lower vascular ring receives veins from the stomach and intestines, and becomes the commencement of the portal vein.

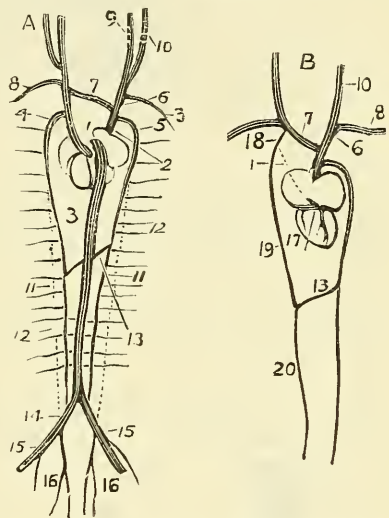
The umbilical veins at first open into the sinus venosus near to the vitelline veins. Subsequently this communication becomes interrupted by the development of a vascular network; the vein on the right side atrophies and disappears, whilst that on the left side greatly enlarges, as the placental circulation becomes established, and communicates with the upper venous circle of the vitelline circulation. Finally a branch is formed between the upper venous circle and the right hepatic veins, which becomes the *ductus venosus*, and by it most of the blood from the umbilical vein is carried direct to the heart.

*The Parietal Veins.*—The first appearance of a parietal system consists in the appearance of two short transverse veins (the *ducts of Cuvier*), which open on either side of the auricular portion of the heart. Each of these ducts is formed

by an ascending and descending vein. The ascending veins return the blood from the parietes of the trunk and the Wolfian bodies, and are called *cardinal* veins. The two descending ones return the blood (fig. 104) from the head, and are called *primitive jugular* veins. As the kidneys are developed, the veins conveying the blood from them unite together to form a single trunk which passes up the abdomen behind the intestines, and, joining the common trunk of the vitelline and umbilical veins above the point of entrance of the *venae revehentes*, constitutes the inferior vena cava. Two small veins receiving branches from the lower extremity unite to form the lower part of the inferior vena cava, below the point of entrance of the veins from the kidneys. These are the primitive iliac veins, and in their course upwards they cross the cardinal veins and communicate with them. The part of the iliac vein between this point of communication and their junction with one another constitutes the common iliac vein; while the distal portion forms the external iliac vein. The internal iliac vein is formed from that part of the cardinal vein which lies below the point of communication. The greater part of the remainder of the cardinal vein—that is to say, of that portion above the iliac veins—becomes obliterated; a small part, however, at the upper extremity remains persistent, and becomes continuous with two new veins, which are formed one on either side of the vertebral column. These veins receive the intercostal and lumbar veins, and eventually form the azygos veins. They become joined by an oblique communicating branch, which crosses the middle line, and constitutes the junction of the vena azygos minor with the vena azygos major. These veins are termed the *posterior vertebral veins* of Rathke. The upper part of the left one, with its continuation, the cardinal vein, forms the superior intercostal of the left side.

The veins first formed in the upper part of the trunk are, as above stated, the *primitive jugular* veins. In the greater part of their extent they become the external jugular vein. Shortly, two small branches may be noticed opening into them near their termination; these form the subclavian and internal jugular veins. From the point of junction of these veins on the left side, a communicating branch makes its appearance, running obliquely across the neck downwards and to the right, to open into the primitive jugular vein of the right side below the point of entrance of the subclavian vein. At the same time, in consequence of the alteration in the position of the heart, and its descent into the thorax, the direction of the ducts of Cuvier becomes altered, and they assume an almost vertical position. From the portion of the primitive jugular veins, above the branch of communication, the internal jugulars are formed, except that part of the right one which lies between the point of entrance of the subclavian of this side, and the termination of the communicating branch, which becomes the right innominate vein. The

FIG. 105.—Diagram of the formation of the main systemic veins.



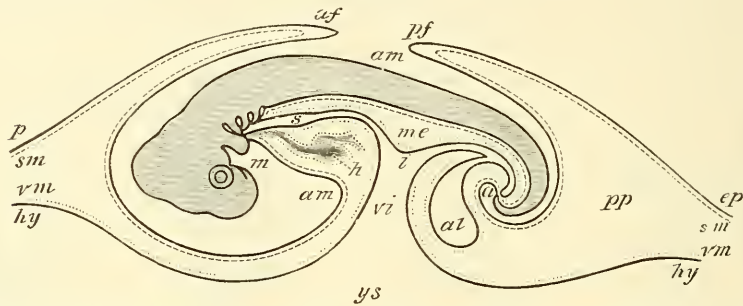
A. Heart and venous system at the period when there are two *venae cavæ superiores*, posterior view. 1. Left superior cava. 2. Right superior cava. 3. Inferior cava. 4. Left inferior cardinal. 5. Right inferior cardinal. 6. Right jugular. 7. Anastomosing branch between the jugulars (left innominate). 8. Subclavian. 9. Internal jugular. 10. External jugular. 11. Middle obliterated portion of the posterior cardinal veins. 12. Newly-formed posterior vertebral veins. 13. Anastomosis between the two vertebrals—trunk of small azygos. 14. Iliac veins, proceeding from anastomosis between the inferior cava and posterior cardinals. 15. Crural. 16. Hypogastric—originally the distal ends of the cardinals. B. Heart and permanent veins, posterior view. 1. Obliterated left superior cava. 6. Right innominate. 7. Left innominate. 8. Subclavian. 10. Jugular. 13. Trunk of the small azygos. 17. Coronary sinus receiving the coronary vein. 18. Superior intercostal. 19. Superior small azygos. 20. Inferior small azygos.

communicating branch becomes the left innominate vein. The primitive jugular of the right side, below the communicating vein and the right duct of Cuvier, becomes the vena cava superior, into which the right cardinal (vena azygos major) enters. The lower part of the left primitive jugular, and the left duct of Cuvier become almost entirely obliterated, except the lower end, which remains as a fibrous band, or sometimes a small vein, and runs obliquely over the posterior surface of the left auricle. The termination of the left duct of Cuvier remains persistent, and forms the coronary sinus (fig. 105).

The foetal circulation is described at a future page.

**Development of the Alimentary Canal.**—The development of the intestinal cavity is, as shown above (page 82), one of the earliest phenomena of embryonic

FIG. 106.—Diagrammatic outline of a longitudinal vertical section of the chick on the fourth day.

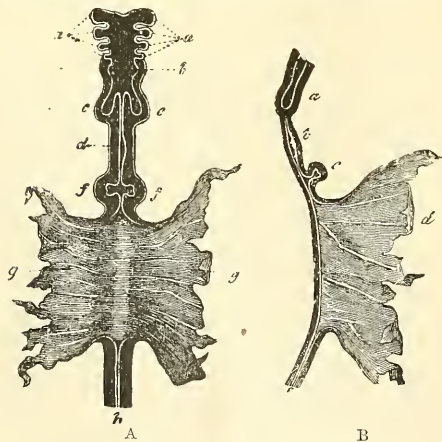


*ep.* Epiblast. *sm.* Somatic mesoblast. *hy.* Hypoblast. *vm.* Visceral mesoblast: *af.* Cephalic fold. *pf.* Caudal fold. *am.* Cavity of true amnion. *ys.* Yolk-sac. *i.* Intestine. *s.* Stomach and pharynx. *a.* Future anus, still closed. *m.* The mouth. *mc.* The mesentery. *al.* The allantoic vesicle. *pp.* Space between inner and outer folds of amnion. (From Quain's 'Anatomy,' Allen Thomson.)

life. The original intestine consists of an inflection of the blastodermic layers extending from one end of the embryo to the other, and is situated just below the primitive vertebral column. At either extremity it forms a closed tube, in

consequence of the cephalic and caudal flexures (page 81), and this manifestly divides it into three parts; a front part, enclosed in the cephalic fold, called the *fore-gut*; a posterior part, enclosed in the caudal fold, the *hind-gut*; and a central part or *mid-gut*, which at this time freely communicates with the umbilical vesicle (fig. 106). The ends of the fore- and hind-gut do not communicate with the surface of the body, the buccal and anal orifices being subsequently formed by involutions of the epiblast, which later on form communications with the gut. From the fore-gut are developed the pharynx, œsophagus, stomach, and duodenum; from the hind-gut a part of the rectum; and from the middle division the rest of the intestinal tube (fig. 107). The changes which take place in the fore-gut are as follow: The middle portion becomes dilated to form the

FIG. 107.—Early form of the alimentary canal. (From Kölliker, after Bischoff.)



In A a front view, and in B an antero-posterior section are represented. *a.* Four pharyngeal or visceral plates. *b.* The pharynx. *c. c.* The commencing lungs. *d.* The stomach. *f. f.* The diverticula connected with the formation of the liver. *g.* The yolk-sac into which the middle intestinal groove opens. *h.* The posterior part of the intestine.

stomach, and undergoes a vertical rotation to the right, so that the posterior border, by which it is attached to the vertebral column by a mesentery, is now



directed to the left, and the anterior border to the right. At this time it is straight, but it soon undergoes a lateral curve or bend to the right at its upper end. It thus assumes an oblique direction, and the left border (originally the posterior or attached border) becomes inferior, and forms the great curvature. The mesentery by which it was attached forms the great omentum. The portion of the fore-gut above this dilatation remains straight, forming the pharynx and œsophagus, and in consequence of the mesoblast being here undivided, there is no serous investment to this part of the tube. Below this, division of the mesoblast has taken place, and the splanchnopleure alone forms the walls of the remainder of the intestinal canal, the space between this layer and the somatopleure constituting the pleuro-peritoneal cavity.

The part of the fore-gut below the dilated stomach forms the duodenum, and in connection with this the liver and pancreas are developed.

The *hind-gut* is also a closed tube, and from it the middle third of the rectum is developed, as well as the allantois (page 85), which will be again referred to in connection with the development of the bladder.

The *mid-gut* is at first an open cavity freely communicating with the umbilical vesicle. As the body-walls grow, this communication contracts very materially, though it still exists to a certain extent, and the open cavity becomes converted into a straight tube, still open where it communicates with the umbilical vesicle. This tube grows rapidly in length, and presents a primitive curve or loop downwards and forwards, and, in consequence of its growth exceeding that of the walls of the body-cavity, a portion of the loop protrudes into the stalk of the umbilical vesicle. At a subsequent period, however, the walls of the abdomen grow more rapidly than the intestine, which again recedes into the body-cavity. At a short distance below the most prominent point of this loop a diverticulum arises, which marks the separation between the large and small intestine. The lower part of this diverticulum forms the vermiform appendix; the proximal part, by its continued growth, constitutes the cæcum. After this the anterior or upper part of the gut, corresponding to the small intestine, rapidly increases in length, and about the eighth week becomes convoluted. The lower or posterior part, corresponding to the large intestine, is at first less in calibre than the upper part, and lies wholly to the left side of the convolutions of the small intestine; but later on the curve of the large intestine begins to form, and the first part (ascending colon) slowly crosses over to the right side, first lying in the middle line, just below the liver. It is not until the sixth month that the cæcum descends into the right iliac fossa, and so drags the ascending colon into its normal position in the right flank.

The peritoneal cavity is the space left between the visceral and parietal layers of the mesoblast, and the serous membrane is developed from these structures. The mesenteries are formed from mesoblastic tissue extending between the notochord and the gut which develops the vascular and connective-tissue elements of these parts.

The *buccal* cavity is formed by an involution of the external layers of the blastodermic membrane, which passes inwards and meets the pharynx, or upper part of the fore-gut. The two cavities are, however, at first completely separated from each other by all the layers of the blastoderm; but at an early period of development a vertical slit appears between them; this gradually widens and becomes the opening by which the common cavity of the nose and mouth communicates with the pharynx. The common cavity is afterwards divided into nose and mouth by the development of the palate, in the manner spoken of above.

The *tongue* appears about the fifth week as a small elevation behind the inferior maxillary arch, to which another projection from the second pharyngeal arch is united. The epithelial layer is furnished by the epiblast. The tonsils appear about the fourth month.

The *anus* is also formed by an inflection of the epiblast, which extends inwards to a slight extent, and approaches the termination of the hind-gut,

and finally communicates with it by a solution of continuity in the septum between the two. The persistence of the foetal septum at either the buccal or anal orifices constitutes a well-known deformity—imperforate oesophagus or imperforate rectum, as the case may be.

The *liver* appears after the Wolffian bodies, about the third week, in the form of a bifid mass of cells, connected with the epithelial and mesoblastic layers of the splanchnopleure. It projects from the intestine at that part which afterwards forms the duodenum. This mass of cells becomes hollowed out into a cavity, lined by hypoblast, the rudiment of the main duct of the liver, the cells on either side being developed into the right and left lobes. These grow very rapidly around the vitelline and, later, the umbilical veins, which break up into a capillary plexus and ramify in its substance. About the third month the liver almost fills the abdominal cavity. From this period the relative development of the liver is less active, more especially that of the left lobe, which now becomes smaller than the right; but the liver remains up to the end of foetal life relatively larger than in the adult.

The *gall-bladder* appears about the second month, as an extension of the cavity from which the main duct of the liver is developed; and bile is detected in the intestines by the third month.

The *pancreas* is also an early formation, being far advanced in the second month. It, as well as the salivary glands, which appear about the same period, originates in a projection from the epithelial layer, which afterwards forms a cavity, and the lobules of the gland are developed from the ramifications of this cavity. It is generally admitted that the epithelial lining of the ducts is furnished by the hypoblast, in the development of both the pancreas and the liver; and that the vessels owe their origin to the mesoblast. But authorities differ as to the mode of formation of the parenchyma, as to whether this is entirely of mesoblastic origin, or whether the hypoblast shares in its development.

The *spleen*, on the other hand, is apparently entirely of mesoblastic origin, for there is never any connection between the intestinal cavity and the substance of this organ. It originates from the mesenteric fold which connects the stomach to the vertebral column (mesogastrium).

**Development of the Respiratory Organs.**—The lungs appear somewhat later than the liver. They are developed from a small median *cul-de-sac* or diverticulum from the upper part of the fore-gut, immediately behind the fourth visceral cleft, as a projection from the epithelial and fibrous laminae of the intestines. During the fourth week a pouch is formed on either side of the central diverticulum, and opens freely through it into the fore-gut (pharynx). From these, other (secondary) pouches are given off, so that by the eighth week the form of the lobes of the lungs may be made out. The two primary pouches have thus a common pedicle of communication with the pharynx. This is developed into the trachea (fig. 101, B), the cartilaginous rings of which are perceptible about the seventh week. The parts which afterwards form the larynx are recognised as early as the sixth week—viz. a projection on either side of the pharyngeal opening, which is the rudiment of the arytenoid cartilage and a transverse elevation from the third pharyngeal arch, which afterwards becomes the epiglottis; the vocal cords and ventricles of the larynx are seen about the fourth month. Traces of the diaphragm appear in the form of a fine membrane, separating the lungs from the Wolffian bodies, the stomach and the liver, whilst the heart is still near the head. As the diaphragm extends forwards from the vertebral column it separates the common pleuro-peritoneal cavity into two parts, a thoracic and abdominal.

**Development of the Urinary Organs.**—The urinary organs appear to be entirely of mesoblastic origin, and are developed from a mass of cells, which makes its appearance below the heart and behind the common pleuro-peritoneal cavity, from the mesoblast at the point of separation of its two layers into somatopleure and splanchnopleure. As this ridge is situated in front of the epiblast

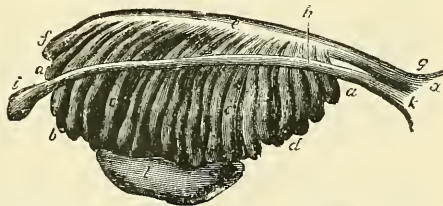


(reflected from the medullary cavity), at the side of the protovertebræ and behind the common pleuro-peritoneal cavity, it has been named the 'intermediate cell-mass.' It is at first solid, and in it is formed a cord-like arrangement of some of the cells, which extends longitudinally from just below the heart to the posterior extremity of the body-cavity. In this cord-like structure a tube is hollowed out; it gradually becomes separated from the rest of the intermediate cell-mass, and is then named the Wolffian duct. Its posterior end becomes connected with and eventually opens into the hind-gut. On either side of its anterior end an invagination of hypoblast takes place, and in the mesoblastic tissue between these invaginations a vascular glomerulus is formed which projects into the peritoneal cavity. It is known as the *head-kidney* or *pronephros* (Lankester), and it is situated in the region of the rudimentary heart. It is a very rudimentary organ and speedily disappears. Behind this body and to the inner side of the Wolffian duct, between it and the body-cavity, a number of tubes are formed, which communicate by one extremity with the Wolffian duct, and, passing transversely towards the body-cavity, terminate in cœcal extremities. These tubes are called segmental tubes, and the whole mass is known as the *mid-kidney*, *Wolffian body*, or *mesonephros* (Lankester). After a time the cœcal extremities become dilated and enclose a tuft or glomerulus of capillary blood-vessels. The Wolffian body is not a permanent organ, at all events as regards its greater part, for as soon as the permanent kidneys are formed, it for the most part disappears. In the male, however, the vasa efferentia and rete testis of the testicle are formed as out-growths from it. In the female traces of it are left as the *parovarium* and *epoophoron*.

Finally, in that portion of the intermediate cell-mass which lies behind the Wolffian body, a differentiation of cells takes place which results in the formation of a number of convoluted tubes; into this a hollow protrusion of the lower end of the Wolffian duct grows up, and thus is formed the *hind-kidney* or *metanephros* (Lankester). This is the rudimentary permanent kidney. The uriniferous convoluted tubes and Malpighian corpuscles are formed from the intermediate cell-mass, and the collecting tubules and ureter from the protrusion from the posterior end of the Wolffian duct.

Shortly after the formation of the Wolffian body, a second duct becomes developed. It arises on the outer side of this body as a slight thickening of the hypoblast. This thickening then becomes invaginated into the mesoblast and extends as a cord along the outer side of the Wolffian body, to the posterior extremity of the embryo. It speedily acquires a lumen, and is then known as the Müllerian duct (fig. 108). In its passage to the posterior extremity of the embryo it comes into close relation with the Wolffian duct, and the two ducts on either side become connected with their fellows on the opposite side by cellular substance into a single mass—the *genital cord*—in which the Wolffian ducts lay side by side in front, and the ducts of Müller behind. These latter tubes in the substance of the genital cord become fused together, and open by a single orifice into the hind-gut (cloaca). At their anterior extremities the ducts of Müller open by a somewhat funnel-shaped orifice into the pleuro-peritoneal cavity. The greater part of the Müllerian duct is in the female developed into the Fallopian tube, but the posterior fused portion of the ducts is converted into the uterus and vagina. In the male the greater part of the ducts disappear; the fused

FIG. 108.—Enlarged view from the front of the left Wolffian body before the establishment of the distinction of sex. (From Farre, after Kobelt.)



*a, a, b, d.* Tubular structure of the Wolffian body. *e.* Wolffian duct. *f.* Its upper extremity. *g.* Its termination in *x*, the urogenital sinus. *h.* The duct of Müller. *i.* Its upper, funnel-shaped extremity. *k.* Its lower end, terminating in the urogenital sinus. *l.* The mass of blastema for the reproductive organ, ovary or testicle.

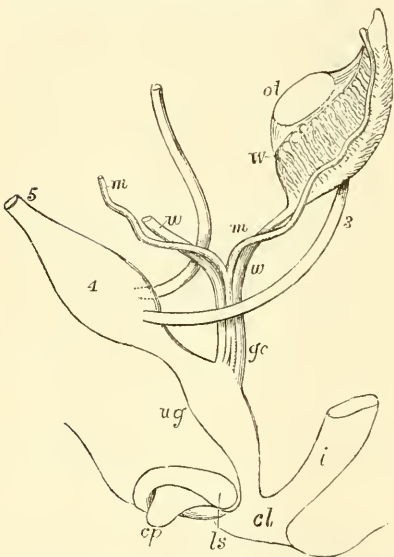


portion is believed to be represented by the *sinus pocularis (uterus masculinus)* of the urethra.

It will be seen, therefore, that the Wolffian ducts, which in the male become the epididymis and vas deferens, and in the female a functionless tube, the duct of Gartner, and the Müllerian ducts, open into the common urogenital sinus or cloaca, which is the termination of the intestinal cavity, into which the allantois also opens in front (fig. 109). As the allantois expands into the urinary bladder this common cavity is divided into two by a septum, to form the bladder in front and the rectum behind.

The *urinary bladder*, as before stated, is formed by a dilatation of a part of the stalk of the allantois. At the end of the second month this forms a spindle-shaped cavity, the bladder. Between

FIG. 109.—Diagram of the primitive urogenital organs in the embryo previous to sexual distinction. The parts are shown chiefly in profile, but the Müllerian and Wolffian ducts are seen from the front.



3. Ureter. 4. Urinary bladder. 5. Urachus. *ot*. The mass of blastema from which ovary or testicle is afterwards formed. *W*. Left Wolffian body. *w, w*. Right and left Wolffian ducts. *m, m*. Right and left Müllerian ducts uniting together and with the Wolffian ducts in *gc*, the genital cord. *ug*. Sinus urogenitalis. *i*. Lower part of the intestine. *cl*. Common opening of the intestine and urogenital sinus. *cp*. Elevation which becomes clitoris or penis. *ls*. Ridge from which the labia majora or scrotum are formed.

the lower extremity of the spindle-shaped dilatation and the primitive intestine is a small tract of undilated allantois, forming a short canal, which at first opens into the urogenital sinus, but subsequently becomes closed by the septum just mentioned. From this short canal is formed the first part of the urethra in the male and the whole of the urethra in the female. The upper part of the stalk of the allantois, which is not dilated, forms the *urachus*; this extends up into the umbilical cord, and at an early period of embryonic existence forms a tube of communication with the allantois. It is obliterated before the termination of foetal life, but the cord formed by its obliteration is perceptible throughout life, passing from the upper part of the bladder to the umbilicus. It occasionally remains patent in the adult, constituting a well-known malformation.

The *suprarenal* bodies are developed from two different sources. The medullary part of the organ is of epiblastic origin, and is derived from the tissues forming the sympathetic ganglia of the abdomen, while the cortical portion is of mesoblastic origin, and originates as an outgrowth from the upper part of the Wolffian body. The two parts are at first quite distinct, but become combined in the process of development. The suprarenal capsules are at first larger than the kidney, but become equal in size

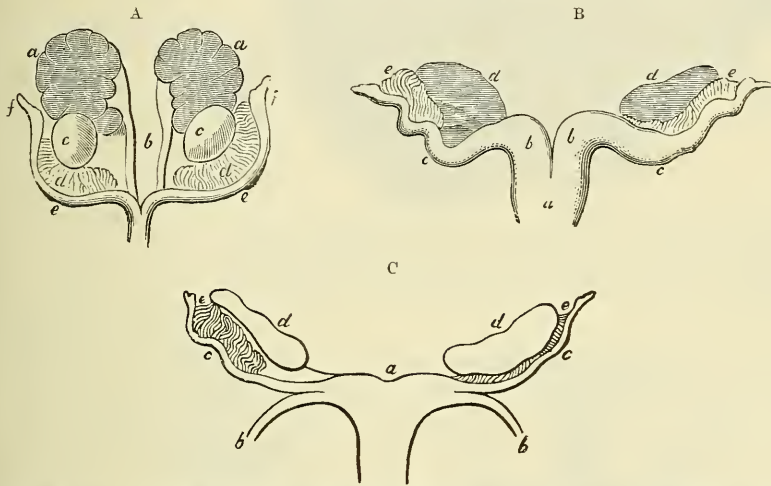
about the tenth week, and from that time decrease relatively to the kidney, though they remain, throughout foetal life, much larger in proportion than in the adult.

**Development of the Generative Organs.**—The first appearance of the reproductive organs is essentially the same in the two sexes, and consists in a thickening at one spot of the epithelial layer which lines the peritoneal or body cavity. This is termed the *germinal epithelium*, and consists of two, three, or more layers of columnar cells. Beneath them an increase in the mesoblast takes place, forming a distinct projection or ridge. This is termed the *genital ridge*, and is situated on the mesial side of each Wolffian body, and from it the testicle in the one sex, and the ovary in the other, are developed. Amongst the cells of the germinal epithelium are to be seen some larger cells; these eventually become the ova or spermatozoa of the completed organ, either ovary or testes, as the

case may be. The genital ridge, as the embryo grows, gradually becomes pinched off from the Wolffian body, with which it is at first continuous, though it still remains connected to the remnant of this body by a fold of peritoneum, the *mesorchium* or *mesovarium*. About the seventh week the distinction of sex begins to be perceptible.

**Development of the Ovary.**—The ovary, thus formed from the genital ridge, has become pinched off from the remains of the Wolffian body, though still attached to it by a mesovarium, before it can be distinguished from the testicle. It now consists of a central part of connective tissue covered by a layer or layers of germ epithelium. A mingling of these two tissues takes place in the following manner. The epithelium undergoes repeated division, so that it rapidly increases in thickness and grows downwards in the form of columns into the central connective tissue, carrying with it some of the larger cells, which, as above stated, are to form the ova. Simultaneously with this an upward growth of the connective tissue takes place between the epithelial cells.

FIG. 110.—Female genital organs of the embryo, with the remains of the Wolffian bodies. (After J. Müller.)



A. From a foetal sheep : *a*. The kidneys. *b*. The ureters. *c*. The ovaries. *d*. Remains of Wolffian bodies. *e*. Fallopian tubes. *f*. Their abdominal openings. B. More advanced, from a foetal deer : *a*. Body of the uterus. *b*. Cornua. *c*. Tubes. *d*. Ovaries. *e*. Remains of Wolffian bodies. C. Still more advanced, from the human foetus of three months : *a*. The body of the uterus. *b*. The round ligament. *c*. The Fallopian tubes. *d*. The ovaries. *e*. Remains of the Wolffian bodies.

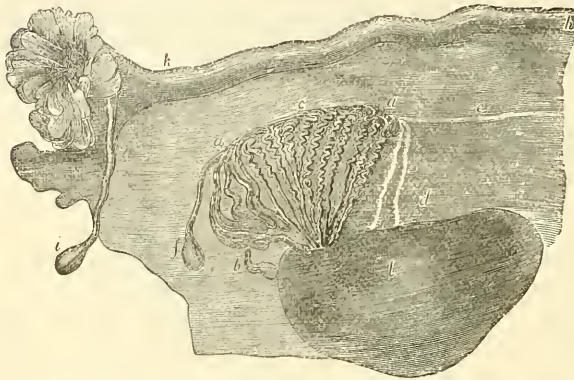
It results from this that the columns of cells, which are sometimes termed *egg-tubes*, become enclosed in meshes of connective tissue. They then become broken up into rounded masses of epithelial cells, enclosing one or more of the larger cells or primordial ova. These rounded masses form the Graafian vesicles. The larger cells form the ova, the other cells form the epithelium of the Graafian follicle, whilst the connective tissue around forms the stroma of the ovary. The remains of the genital epithelium on the surface of the ovary form the permanent epithelium of this organ.

**Development of the Testicle.**—The testicle is developed in a very similar way to the ovary, but the processes are not so well marked. Like the ovary, in its earliest stages it consists of a central mass of connective tissue covered by germ epithelium, amongst which may be seen larger cells, corresponding to the primordial ova of the female. A thickening of this epithelium takes place and a downward growth of columns of epithelium into the central connective tissue. From these the seminiferous tubules are developed and become connected with outgrowths from the Wolffian body, which, as before mentioned, form the rete testis and vasa efferentia.

With regard to the other parts of the internal female organs, the Fallopian

tube, as has already been mentioned, is developed from the upper part of the duct of Müller, while the lower part of the two ducts approach each other, and, lying side by side, finally coalesce to form the cavity of the uterus and vagina. This coalescence commences in the middle of the genital cord, and corresponds to the body of the uterus. The upper parts of the Müllerian ducts in the genital cord constitute the cornua of the uterus, little developed in the human species (fig. 111). With regard to the further changes in the female organs the only remains of the Wolffian body in the complete condition are two rudimentary or vestigial structures, which can be found, on careful search, in the broad

FIG. 111.—Adult ovary, parovarium, and Fallopian tube.  
(From Farre, after Kobelt.)



*a, a.* Epoophoron formed from the upper part of the Wolffian body. *b.* Remains of the uppermost tubes sometimes forming hydatids. *c.* Middle set of tubes. *d.* Some lower atrophied tubes. *e.* Atrophied remains of the Wolffian duct. *f.* The terminal bulb or hydatid. *h.* The Fallopian tube, originally the duct of Müller. *i.* Hydatid attached to the extremity. *z.* The ovary.

an annular constriction marks the position of the neck of the uterus, and after the sixth month the walls of the uterus begin to thicken. The round ligament is derived from a band containing involuntary muscular fibres, which runs downwards from the lower part of the Wolffian body to the groin, and which in the male forms the gubernaculum testis; the peritoneum constitutes the broad ligament; the superior ligament of the Wolffian body, which serves to connect it with the diaphragm, disappears with that structure.

With regard to the other parts of the male organs, the Müllerian ducts disappear, with the exception of their lower ends. These unite in the middle line, and open by a common orifice into the urogenital sinus. This constitutes the *utriculus hominis* or *sinus prostaticus*. Occasionally, however, the upper end of the duct of Müller remains visible in the male, constituting the little pedunculated body, called the hydatid of Morgagni, sometimes found in the neighbourhood of the epididymis,\* between the testes and globus major.

The head of the epididymis, its canal, the vas deferens and ejaculatory duct, are formed from the canals and duct of the Wolffian body. One or more of the tubes of the Wolffian body form the vas aberrans and a structure described by Giralaldès, and called, after him, 'the organ of Giralaldès,' which bears a good deal of resemblance to the organ of Rosenmüller in the other sex. It consists of a number of convoluted tubules, lying in the cellular tissue in front of the cord, and close to the head of the epididymis.

The descent of the testis and the formation of the gubernaculum are described in the body of the work.

\* Mr. Osborn, in the St. Thomas's Hospital Reports, 1875, has written an interesting paper pointing out the probable connection between this fetal structure and one form of hydrocele.

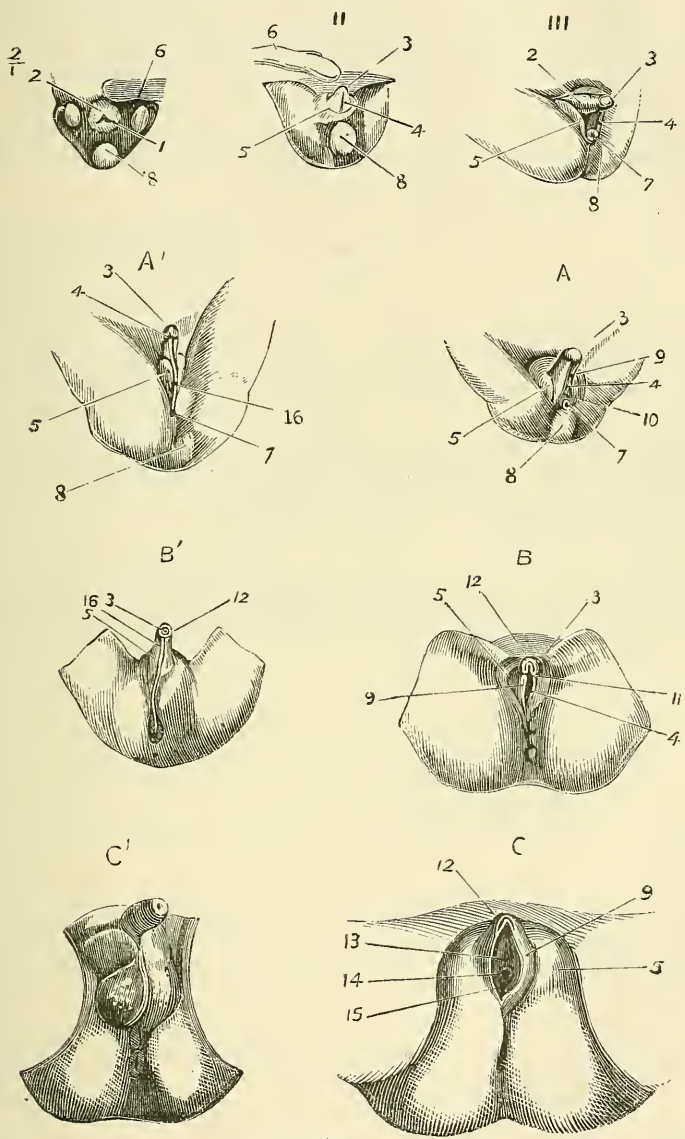
ligament near the ovary; the *parovarium* or *organ of Rosenmüller* and the *epoophoron* (fig. 111). The organ of Rosenmüller consists of a number of tubes which converge to a transverse portion, the *epoophoron*, and this is sometimes prolonged into a distinct duct, running transversely, the *duct of Gartner*, which is much more conspicuous and extends further in some of the lower animals. This is the remains of the Wolffian duct. About the fifth month



The **external organs of generation**, like the internal, pass through a stage in which there is no distinction of sex (fig. 112, I, II, III). We must therefore describe this stage, and then follow the development of the female and male organs respectively.

As stated above, the anal depression at an early period is formed by an involution of the external epithelium, and the intestine is still closed at its lower

FIG. 112.—Development of the external genital organs.



*Indifferent type*, I, II, III. *Female*. A, and B. At the middle of the fifth month. C. At the beginning of the sixth. *Male*. A'. At the beginning of the fourth month. B'. At the middle of the fourth month. C'. At the end of the fourth month. 1. Cloaca. 2. Genital tubercle. 3. Glans penis or clitoridis. 4. Genital furrow. 5. External genital folds (labia majora or serotum). 6. Umbilical cord. 7. Anus. 8. Caudal extremity and coccygeal tubercle. 9. Labia minora. 10. Urogenital sinus. 11. Frænum clitoridis. 12. Preputium penis or clitoridis. 13. Opening of the urethra. 14. Opening of the vagina. 15. Hymen. 16. Scrotal raphe.

end. When the septum between the two opens, which is about the fourth week, the urachus in front and the intestine behind both communicate with the anal depression. This, which is now called the cloaca, is afterwards divided by a transverse septum, the *perineum*, which appears about the second month. Two

tubes are thus formed; the posterior becomes the lower part of the rectum, the anterior is the urogenital sinus. In the sixth week a tubercle, the *genital tubercle*, is formed in front of the cloaca, and this is soon surrounded by two folds of skin, the *genital folds*. Towards the end of the second month the tubercle presents, on its lower aspect, a groove, the *genital furrow*, turned towards the cloaca. All these parts are well developed by the second month, yet no distinction of sex is possible.

*Female Organs* (fig. 112, A, B, C).—The female organs are developed by an easy transition from the above. The urogenital sinus persists as the vestibule of the vagina, and forms a single tube with the upper part of the vagina, which, as we have already seen, is developed from the united Müllerian ducts. The genital tubercle forms the clitoris, the genital folds the labia majora, and the lips of the genital furrow the labia minora, which remain open. An involution of the epithelium takes place on either side close to the root of the genital tubercle, which becomes the glands of Bartholin.

*Male Organs* (fig. 112, A', B', C').—In the male the changes are greater. The genital tubercle is developed into the penis, the glans appearing in the third month, the prepuce and corpora cavernosa in the fourth. The genital furrow closes and thus forms a canal, the spongy portion of the urethra. The urogenital sinus becomes elongated and forms the membranous urethra. The genital folds unite in the middle line to form the scrotum, at about the same time as the genital furrow closes—viz. between the third and fourth month. A similar involution of epithelium to that which in the female forms the glands of Bartholin takes place in the male and becomes the glands of Cowper.

The following table is translated from the work of Beaunis and Bouchard, with some alterations, especially in the earlier weeks. It will serve to present a *résumé* of the above facts in an easily accessible form.\*

\* It will be noticed that the time assigned in this table for the appearance of the first rudiment of some of the bones varies in some cases from that assigned in the description of the various bones in the sequel. This is a point on which anatomists differ, and which probably varies in different cases.

# CHRONOLOGICAL TABLE

OF

## THE DEVELOPMENT OF THE FŒTUS

(FROM BEAUNIS AND BOUCHARD)



- First Week.*—During this period the ovum is in the Fallopian tube. Having been fertilised in the upper part of the tube, it slowly passes down, undergoing segmentation, and reaches the uterus probably about the end of the first week. During this time it does not undergo much increase in size.
- Second Week.*—The ovum rapidly increases in size and becomes embedded in the decidua, so that it is completely enclosed in the decidua reflexa by the end of this period. An ovum believed to be of the thirteenth day after conception is described by Reichert. There was no appearance of any embryonic structure. The equatorial margins of the ovum were beset with villi, but the surface in contact with the uterine wall and the one opposite to it were bare. In another ovum, described by His, believed to be of about the fourteenth day, there was a distinct indication of an embryo. There was a medullary groove bounded by folds. In front of this a slightly prominent ridge, the rudimentary heart. The amnion was formed and the embryo was attached by a stalk, the allantois, to the inner surface of the chorion. It may be said, therefore, that these parts, the amnion and the allantois, and the first rudiments of the embryo, the medullary groove and the heart, are formed at the end of the second week.
- Third Week.*—By the end of the third week the flexures of the embryo have taken place, so that it is strongly curved. The protovertebral discs, which begin to be formed early in the third week, present their full complement. In the nervous system the primary divisions of the brain are visible, and the primitive ocular and auditory vesicles are already formed. The primary circulation is established. The alimentary canal presents a straight tube communicating with the yolk-sac. The pharyngeal arches are formed. The limbs have appeared as short buds. The Wolffian bodies are visible.
- Fourth Week.*—The umbilical vesicle has attained its full development. The caudal extremity projects. The upper and the lower limbs and the cloacal aperture appear. The heart separates into a right and left heart. The special ganglia and anterior roots of the spinal nerves, the olfactory fossæ, the lungs and the pancreas can be made out.
- Fifth Week.*—The allantois is vascular in its whole extent. The first traces of the hands and feet can be seen. The primitive aorta divides into aorta and pulmonary artery. The duct of Müller and genital gland are visible. The ossification of the clavicle and the lower jaw commences. The cartilage of Meckel occupies the first post-oral arch.
- Sixth Week.*—The activity of the umbilical vesicle ceases. The pharyngeal clefts disappear. The vertebral column, primitive cranium, and ribs assume the cartilaginous condition. The posterior roots of the nerves, the membranes of the nervous centres, the bladder, kidney, tongue, larynx, thyroid body, the germs of teeth, and the genital tubercle and folds are apparent.
- Seventh Week.*—The muscles begin to be perceptible. The points of ossification of the ribs, scapula, shaft of humerus, femur, tibia, palate, and upper jaw appear.
- Eighth Week.*—The distinction of arm and forearm, and of thigh and leg, is apparent, as well as the interdigital clefts. The capsule of the lens and pupillary membrane, the interventricular and commencement of the interauricular septum, the salivary glands, the spleen and suprarenal capsules are distinguishable. The larynx begins to become cartilaginous. All the vertebral bodies are cartilaginous. The points of ossification



for the ulna, radius, fibula, and ilium make their appearance. The two halves of the hard palate unite. The sympathetic nerves are now for the first time to be discerned.

*Ninth Week.*—The corpus striatum and the pericardium are first apparent. The ovary and testicle can be distinguished from each other. The genital furrow appears. The osseous nuclei of the bodies and arches of the vertebræ, of the frontal, vomer, and malar bones, of the shafts of the metacarpal and metatarsal bones, and of the phalanges appear. The union of the hard palate is completed. The gall-bladder is seen.

*Third Month.*—The formation of the fetal placenta advances rapidly. The projection of the caudal extremity disappears. It is possible to distinguish the male and female organs from each other. The cloacal aperture is divided into two parts. The cartilaginous arches on the dorsal region of the spine close. The points of ossification for the occipital, sphenoid, lachrymal, nasal, squamous portion of temporal and ischium appear, as well as the orbital centre of the superior maxillary. The pons Varolii and fissure of Sylvius can be made out. The eyelids, the hair, and the nails begin to form. The mammary gland, the epiglottis, and prostate are beginning to develop. The union of the testicle with the canals of the Wolffian body takes place.

*Fourth Month.*—The closure of the cartilaginous arches of the spine is complete. Osseous points for the first sacral vertebra and os pubis appear. The ossification of the malleus and incus takes place. The corpus callosum, the membrana lamina spiralis, the cartilage of the Eustachian tube, and the tympanic ring are seen. Fat is first developed in the subcutaneous cellular tissue. The tonsils are seen, and the closure of the genital furrow and the formation of the serotum and prepuce take place.

*Fifth Month.*—The two layers of the decidua begin to coalesce. Osseous nuclei of the axis and odontoid process, of the lateral points of the first sacral vertebra, of the median points of the second, and of the lateral masses of the ethmoid make their appearance. Ossification of the stapes and the petrous bone, and ossification of the germs of the teeth take place. The germs of the permanent teeth and the organ of Corti appear. The eruption of hair on the head commences. The sudoriferous glands, Brunner's glands, the follicles of the tonsil and base of the tongue, and the lymphatic glands appear at this period. The differentiation between the uterus and vagina becomes apparent.

*Sixth Month.*—The points of ossification for the anterior root of the transverse process of the seventh cervical vertebra, the lateral points of the second sacral vertebra, the median points of the third, the manubrium sterni and the os calcis appear. The sacro-vertebral angle forms. The cerebral hemispheres cover the cerebellum. The papillæ of the skin, the sebaceous glands, and Peyer's patches make their appearance. The free border of the nail projects from the corium of the dermis. The walls of the uterus thicken.

*Seventh Month.*—The additional points of the first sacral vertebra, the lateral points of the third, the median point of the fourth, the first osseous point of the body of the sternum, and the osseous point for the astragalus appear. Meckel's cartilage disappears. The cerebral convolutions, the island of Reil, and the tubercula quadrigemina are apparent. The pupillary membrane atrophies. The testicle passes into the vaginal process of the peritoneum.

*Eighth Month.*—Additional points for the second sacral vertebra, lateral points for the fourth and median points for the fifth sacral vertebra, can be seen.

*Ninth Month.*—Additional points for the third sacral vertebra, lateral points for the fifth, osseous points for the middle turbinated bone, for the body and great cornu of the hyoid, for the second and third pieces of the body of the sternum, and for the lower end of the femur appear. Ossification of the bony lamina spiralis and axis of the cochlea takes place. The eyelids open, and the testicles are in the scrotum.

# DESCRIPTIVE AND SURGICAL ANATOMY

## THE SKELETON

**T**HE entire skeleton in the adult consists of 200 distinct bones. These are—

The Spine or vertebral column (sacrum and coccyx included) . . . . .	26
Cranium . . . . .	8
Face . . . . .	14
Hyoid bone, sternum, and ribs . . . . .	26
Upper extremities . . . . .	64
Lower extremities . . . . .	62
	200

In this enumeration the patellæ are included as separate bones, but the smaller sesamoid bones, and the ossicula auditûs, are not reckoned. The teeth belong to the tegumentary system.

These bones are divisible into four classes: *Long*, *Short*, *Flat*, and *Irregular*.

The **Long Bones** are found in the limbs, where they form a system of levers, which have to sustain the weight of the trunk, and to confer the power of locomotion. A long bone consists of a shaft and two extremities. The *shaft* is a hollow cylinder, contracted and narrowed to afford greater space for the bellies of the muscles; the walls consist of dense, compact tissue of great thickness in the middle, but becoming thinner towards the extremities; the spongy tissue is scanty, and the bone is hollowed out in its interior to form the *medullary canal*. The *extremities* are generally somewhat expanded, for greater convenience of mutual connection, for the purposes of articulation, and to afford a broad surface for muscular attachment. Here the bone is made up of spongy tissue with only a thin coating of compact substance. The long bones are not straight, but curved; the curve generally taking place in two directions, thus affording greater strength to the bone. The bones belonging to this class are: the *clavicle*, *humerus*, *radius*, *ulna*, *femur*, *tibia*, *fibula*, *metacarpal* and *metatarsal* bones, and the *phalanges*.

**Short Bones.**—Where a part of the skeleton is intended for strength and compactness, and its motion is at the same time slight and limited, it is divided into a number of small pieces united together by ligaments, and the separate bones are short and compressed, such as the bones of the *carpus* and *tarsus*. These bones, in their structure, are spongy throughout, excepting at their surface, where there is a thin crust of compact substance. The *patellæ* also, together with the other sesamoid bones, are by some regarded as short bones.

**Flat Bones.**—Where the principal requirement is either extensive protection or the provision of broad surfaces for muscular attachment, we find the osseous structure expanded into broad, flat plates, as is seen in the bones of the skull and the shoulder-blade. These bones are composed of two thin layers of compact tissue enclosing between them a variable quantity of cancellous tissue. In the

cranial bones, these layers of compact tissue are familiarly known as the *tables* of the skull; the outer one is thick and tough; the inner one thinner, denser, and more brittle, and hence termed the *vitreous table*. The intervening cancellous tissue is called the *diploë*. The flat bones are: the *occipital*, *parietal*, *frontal*, *nasal*, *lachrymal*, *vomer*, *scapula*, *os innominatum*, *sternum*, *ribs*, and *patella*.

The **Irregular** or **Mixed Bones** are such as, from their peculiar form, cannot be grouped under either of the preceding heads. Their structure is similar to that of other bones, consisting of a layer of compact tissue externally, and of spongy cancellous tissue within. The irregular bones are: the *vertebræ*, *sacrum*, *coccyx*, *temporal*, *sphenoid*, *ethmoid*, *malar*, *superior maxillary*, *inferior maxillary*, *palate*, *inferior turbinated*, and *hyoid*.

**Surfaces of Bones.**—If the surface of any bone is examined, certain eminences and depressions are seen, to which descriptive anatomists have given the following names.

These eminences and depressions are of two kinds: *articular* and *non-articular*. Well-marked examples of articular eminences are found in the heads of the humerus and femur; and of articular depressions, in the glenoid cavity of the scapula, and the acetabulum. Non-articular eminences are designated according to their form. Thus, a broad, rough, uneven elevation is called a *tuberosity*; a small, rough prominence, a *tubercle*; a sharp, slender, pointed eminence, a *spine*; a narrow, rough elevation, running some way along the surface, a *ridge* or *line*.

The non-articular depressions are also of very variable form, and are described as *fossæ*, *grooves*, *furrows*, *fissures*, *notches*, etc. These non-articular eminences and depressions serve to increase the extent of surface for the attachment of ligaments and muscles, and are usually well-marked in proportion to the muscularity of the subject.

A prominent process projecting from the surface of a bone, which it has never been separate from or movable upon, is termed an *apophysis* (from ἀπόφυσις, an *excrescence*); but if such process is developed as a separate piece from the rest of the bone, to which it is afterwards joined, it is termed an *epiphysis* (from ἐπίφυσις, an *accretion*).

## THE SPINE

The **Spine** is a flexuous and flexible column, formed of a series of bones called *vertebræ* (from *vertere*, to turn).

The **Vertebræ** are thirty-three in number, exclusive of those which form the skull, and have received the names *cervical*, *dorsal*, *lumbar*, *sacral*, and *coccygeal*, according to the position which they occupy; seven being found in the cervical region, twelve in the dorsal, five in the lumbar, five in the sacral, and four in the coccygeal.

This number is sometimes increased by an additional vertebra in one region, or the number may be diminished in another region, the deficiency being supplied by an additional vertebra in another. These observations do not apply to the cervical portion of the spine, the number of bones forming which is seldom increased or diminished.

The **Vertebræ** in the upper three regions of the spine are separate throughout the whole of life; but those found in the sacral and coccygeal regions are in the adult firmly united, so as to form two bones—five entering into the formation of the upper bone or *sacrum*, and four into the terminal bone of the spine or *coccyx*.

### GENERAL CHARACTERS OF A VERTEBRA

Each **vertebra** consists of two essential parts—an anterior solid segment or *body*, and a posterior segment or *arch*. The arch (neural) is formed of two



*pedicles*, and two *laminae*, supporting seven *processes*—viz. four *articular*, two *transverse*, and one *spinous*.

The bodies of the vertebræ are piled one upon the other, forming a strong pillar, for the support of the cranium and trunk; the arches forming a hollow cylinder behind the bodies for the protection of the spinal cord. The different vertebræ are connected together by means of the articular processes and the intervertebral cartilages; while the transverse and spinous processes serve as levers for the attachment of muscles which move the different parts of the spine. Lastly, between each pair of vertebræ apertures exist through which the spinal nerves pass from the cord. Each of these constituent parts must now be separately examined.

The **Body** or **centrum** is the largest and most solid part of a vertebra. Above and below, it is flattened; its upper and lower surfaces are rough, for the attachment of the intervertebral fibro-cartilages, and present a rim around their circumference. In front, it is convex from side to side, concave from above downwards. Behind, it is flat from above downwards and slightly concave from side to side. Its anterior surface is perforated by a few small apertures, for the passage of nutrient vessels; whilst on the posterior surface is a single large, irregular aperture, or occasionally more than one, for the exit of veins from the body of the vertebra—the *vena basis vertebrae*.

The **Pedicles** are two short, constricted columns of bone, which project backwards, one on each side, from the upper part of the body of the vertebra, at the line of junction of its posterior and lateral surfaces. The concavities above and below the pedicles are the *intervertebral notches*; they are four in number, two on each side, the inferior ones being generally the deeper. When the vertebræ are articulated, the notches of each contiguous pair of bones form the intervertebral foramina, which communicate with the spinal canal and transmit the spinal nerves and blood-vessels.

The **Laminae** are two broad plates of bone which complete the neural arch behind, enclosing a foramen, the *spinal foramen*, which serves for the protection of the spinal cord; they are connected to the body by means of the pedicles.

The **Spinous Process** projects backwards from the junction of the two laminae, and serves for the attachment of muscles.

The **Articular Processes**, four in number, two on each side, spring from the junction of the pedicles with the laminae. The two superior project upwards, their articular surfaces being directed more or less backwards; the two inferior project downwards, their articular surfaces looking more or less forwards.\*

The **Transverse Processes**, two in number, project one at each side from the point where the lamina joins the pedicle, between the superior and inferior articular processes. They also serve for the attachment of muscles.

#### CHARACTER OF THE CERVICAL VERTEBRÆ (fig. 113)

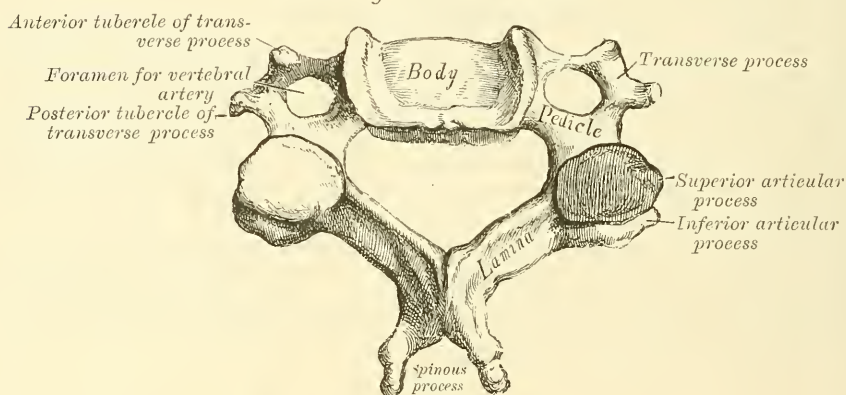
The **Cervical Vertebræ** are smaller than those in any other region of the spine, and may readily be distinguished by the foramen in the transverse process, which does not exist in the transverse process of either the dorsal or lumbar vertebræ.

The **Body** is small, comparatively dense, and broader from side to side than from before backwards. The anterior and posterior surfaces are flattened and of equal depth; the former is placed on a lower level than the latter, and its inferior border is prolonged downwards, so as to overlap the upper and fore part of the vertebra below. Its upper surface is concave transversely, and presents a projecting lip on each side; its lower surface is convex from side to side, concave from before backwards, and presents laterally a shallow concavity, which receives the corresponding projecting lip of the adjacent vertebra. The

\* It may, perhaps, be as well to remind the reader that the direction of a surface is determined by that of a line drawn at right angles to it.

*pedicles* are directed outwards and backwards, and are attached to the body midway between the upper and lower borders, so that the superior intervertebral notch is as deep as the inferior, but it is, at the same time, narrower. The *laminae* are narrow, long, thinner above than below, and overlap each other, enclosing the spinal foramen, which is very large, and of a triangular form. The *spinous processes* are short, and bifid at the extremity to afford greater extent of surface for the attachment of muscles, the two divisions being often of unequal size. They increase in length from the fourth to the seventh. The *articular processes* are oblique: the superior are of an oval form, flattened, and directed backwards and upwards; the inferior forwards and downwards. The *transverse processes* are short, directed downwards, outwards, and forwards, bifid at their extremity, and marked by a groove along their upper surface, which runs downwards and outwards from the superior intervertebral notch, and serves for the transmission of one of the cervical nerves. They are situated in front of the articular processes and on the outer side of the pedicles. The transverse processes are pierced at their base by a foramen, for the transmission of the vertebral artery, vein, and plexus of nerves. Each process is formed by two roots: the anterior root, sometimes called the *costal process*, arises from the side of the

FIG. 113.—Cervical vertebra.



body, and is the homologue of the rib in the dorsal region of the spine; the posterior root springs from the junction of the pedicle with the lamina, and corresponds with the transverse process in the dorsal region. It is by the junction of the two that the foramen for the vertebral vessels is formed. The extremity of each of these roots forms the *anterior* and *posterior tubercles* of the transverse processes.\*

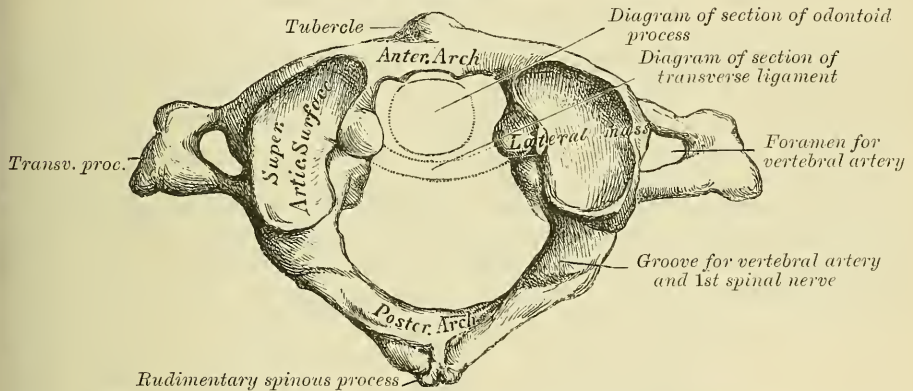
The peculiar vertebræ in the cervical region are the first, or *Atlas*; the second, or *Axis*; and the seventh, or *Vertebra prominens*. The great modifications in the form of the atlas and axis are designed to admit of the nodding and rotatory movements of the head.

The **Atlas** (fig. 114) is so named from supporting the globe of the head. The chief peculiarities of this bone are that it has neither body nor spinous process. The body is detached from the rest of the bone, and forms the odontoid process of the second vertebra; while the parts corresponding to the pedicles join in front to form the anterior arch. The atlas consists of an anterior arch, a posterior arch, and two lateral masses. The *anterior* arch forms about one-fifth of the bone: its anterior surface is convex, and presents about its centre a

\* The anterior tubercle of the transverse process of the sixth cervical vertebra is of large size, and is sometimes known as 'Chassaignac's' or the 'carotid tubercle.' It is in close relation with the carotid artery, which lies in front and a little external to it; so that, as was first pointed out by Chassaignac, the vessel can with ease be compressed against it.

*tubercle*, for the attachment of the Longus colli muscle; posteriorly it is concave, and marked by a smooth, oval or circular facet, for articulation with the odontoid process of the axis. The upper and lower borders give attachment to the anterior occipito-atlantal and the anterior atlanto-axial ligaments which connect it with the occipital bone above and the axis below. The *posterior* arch forms about two-fifths of the circumference of the bone; it terminates behind in a *tubercle*, which is the rudiment of a spinous process, and gives origin to the Rectus capitis posticus minor. The diminutive size of this process prevents any interference in the movements between it and the cranium. The posterior part of the arch presents above and behind a rounded edge for the attachment of the posterior occipito-atlantal ligament, whilst in front, immediately behind each superior articular process, is a groove, sometimes converted into a foramen by a delicate bony spiculum which arches backwards from the posterior extremity of the superior articular process. These grooves represent the superior intervertebral notches, and are peculiar from being situated behind the articular processes, instead of in front of them, as in the other vertebræ. They serve for the transmission of the vertebral artery, which, ascending through the foramen in the transverse process, winds round the lateral mass in a direction backwards and inwards. They also transmit the suboccipital (first spinal) nerve. On the under surface of the posterior arch, in the same situation, are two other grooves, placed

FIG. 114.—First cervical vertebra, or Atlas.



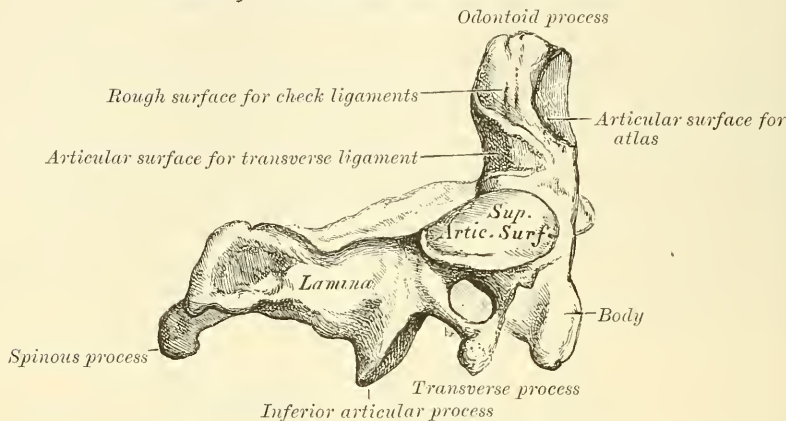
behind the lateral masses, and representing the inferior intervertebral notches of other vertebræ. They are much less marked than the superior. The lower border also gives attachment to the posterior atlanto-axial ligament, which connects it with the axis. The *lateral masses* are the most bulky and solid parts of the atlas, in order to support the weight of the head: they present two articulating processes above, and two below. The two superior are of large size, oval, concave, and approach each other in front, but diverge behind: they are directed upwards, inwards, and a little backwards, forming a kind of cup for the condyles of the occipital bone, and are admirably adapted to the nodding movements of the head. Not unfrequently they are partially subdivided by a more or less deep indentation which encroaches upon each lateral margin. The inferior articular processes are circular in form, flattened or slightly concave and directed downwards and inwards, articulating with the axis, and permitting the rotatory movements. Just below the inner margin of each superior articular surface is a small tubercle, for the attachment of the transverse ligament which, stretching across the ring of the atlas, divides it into two unequal parts—the anterior or smaller segment receiving the odontoid process of the axis, the posterior allowing the transmission of the spinal cord and its membranes. This part of the spinal canal is of considerable size, to afford space for the spinal cord; and hence lateral displacement of the atlas may



occur without compression of this structure. The *transverse processes* are of large size, project directly outwards from the lateral masses, and serve for the attachment of special muscles which assist in rotating the head. They are long, not bifid, and perforated at their base by a canal for the vertebral artery, which is directed from below, upwards and backwards.

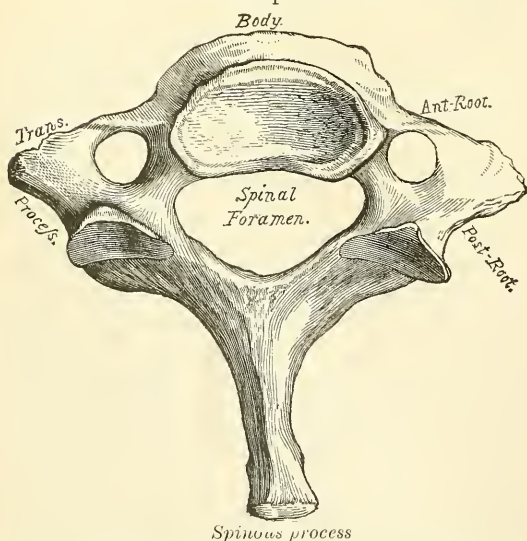
The *Axis* (fig. 115) is so named from forming the pivot upon which the first vertebra, carrying the head, rotates. The most distinctive character of this

FIG. 115.—Second cervical vertebra, or Axis.



bone is the strong, prominent process, tooth-like in form (hence the name *odontoid*), which rises perpendicularly from the upper surface of the body. The *body* is of a triangular form, deeper in front than behind, and prolonged downwards anteriorly so as to overlap the upper and fore part of the adjacent vertebra. It presents in front a median longitudinal ridge, separating two lateral depressions for the attachment of the *Longus colli* muscle of either side. The *odontoid process* presents two articulating surfaces: one in front, of an oval form, for articulation with the atlas; another behind for the transverse ligament—the latter frequently encroaching on the sides of the process.

FIG. 116.—Seventh cervical vertebra, or vertebra prominens.



The apex is pointed, and gives attachment to one fasciculus of the odontoid ligament (*ligamentum suspensorium*). Below the apex the process is somewhat enlarged, and presents on either side a rough impression for the attachment of the lateral fasciculi of the odontoid or check ligaments, which connect it to the occipital bone; the base of the process, where it is attached to the body, is constricted, so as to prevent displacement from the transverse ligament, which binds it in this situation to the anterior arch of the atlas. Sometimes, however, this process does become displaced, especially in children, in whom the ligaments are more relaxed:

instant death is the result of this accident. The *pedicles* are broad and strong, especially their anterior extremities, which coalesce with the sides of the body

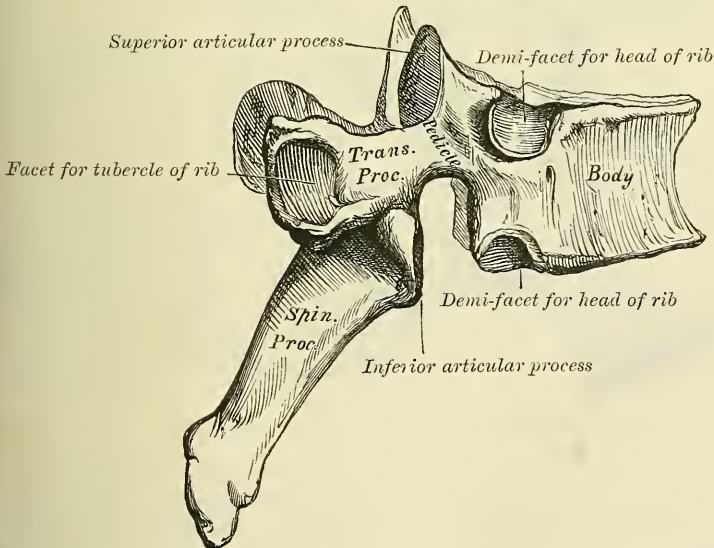
and the root of the odontoid process. The *laminae* are thick and strong, and the spinal foramen large, but smaller than that of the atlas. The *transverse processes* are very small, not bifid, and perforated by the vertebral foramen, or foramen for the vertebral artery, which is directed obliquely upwards and outwards. The *superior articular surfaces* are round, slightly convex, directed upwards and outwards, and are peculiar in being supported on the body, pedicles, and transverse processes. The *inferior articular surfaces* have the same direction as those of the other cervical vertebræ. The *superior intervertebral notches* are very shallow, and lie behind the articular processes; the *inferior* in front of them, as in the other cervical vertebræ. The *spinous process* is of large size, very strong, deeply channelled on its under surface, and presents a bifid, tubercular extremity for the attachment of muscles which serve to rotate the head upon the spine.

**Seventh Cervical** (fig. 116).—The most distinctive character of this vertebra is the existence of a very long and prominent spinous process; hence the name 'vertebra prominens.' This process is thick, nearly horizontal in direction, not bifurcated, and has attached to it the ligamentum nuchæ. The *transverse process* is usually of large size, and its posterior tubercles large and prominent; its upper surface has usually a shallow groove, and it seldom presents more than a trace of bifurcation at its extremity. The vertebral foramen is sometimes as large as in the other cervical vertebræ, but is usually smaller on one or both sides, and sometimes wanting. On the left side it occasionally gives passage to the vertebral artery; more frequently the vertebral vein traverses it on both sides; but the usual arrangement is for both artery and vein to pass in front of the transverse process, and not through the foramen. Occasionally the anterior root of the transverse process exists as a separate bone, and attains a large size. It is then known as a 'cervical rib.'

#### CHARACTERS OF THE DORSAL VERTEBRÆ

The **Dorsal Vertebræ** are intermediate in size between those in the cervical and those in the lumbar region, and increase in size from above downwards, the upper vertebræ in this segment of the spine being much smaller than those in the

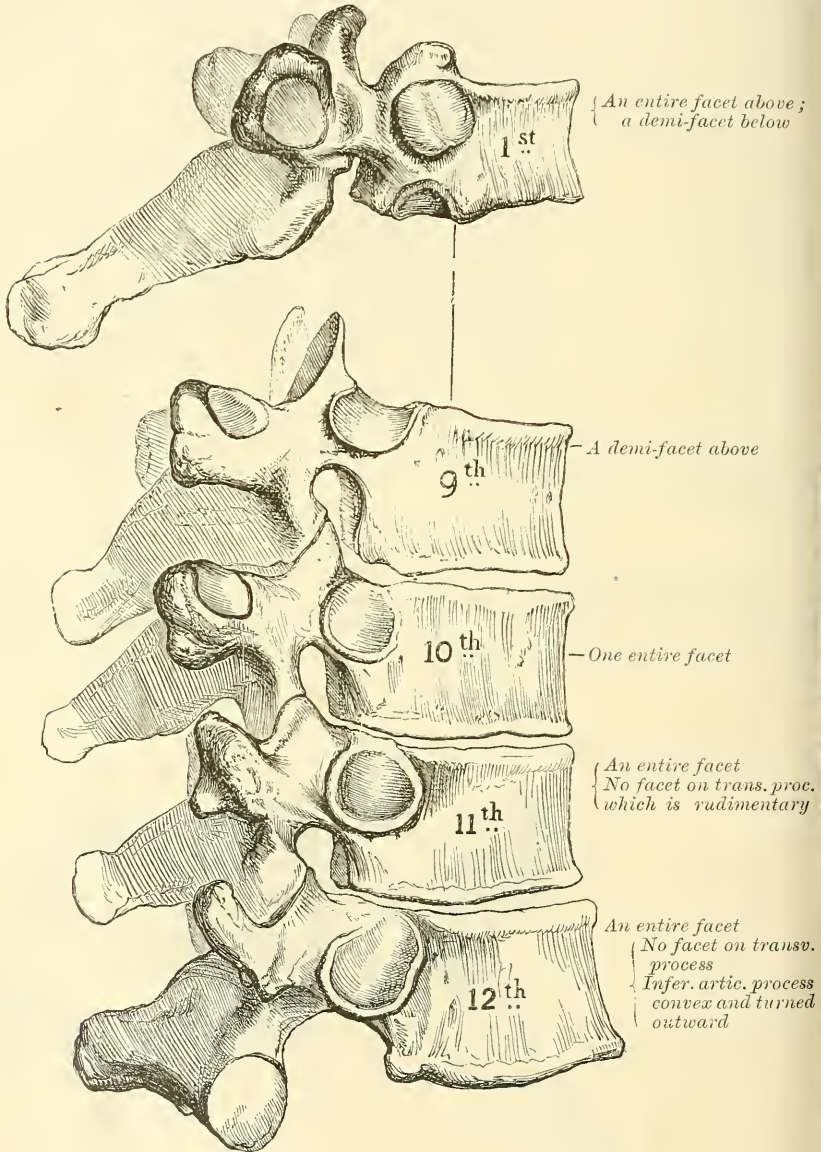
FIG. 117.—A dorsal vertebra.



lower part of the region. The dorsal vertebræ may be at once recognised by the presence on the sides of the body of one or more facets or half-facets for the heads of the ribs.

The **bodies** of the dorsal vertebræ resemble those in the cervical and lumbar regions at the respective ends of this portion of the spine; but in the middle of the dorsal region their form is very characteristic, being heart-shaped, and as broad in the antero-posterior as in the lateral direction. They are thicker behind than in front, flat above and below, convex and prominent in front, deeply concave behind, slightly constricted in front and at the sides, and marked on each side, near the root of the pedicle, by two demi-facets, one above, the other below.

FIG. 118.—Peculiar dorsal vertebræ.



These are covered with cartilage in the recent state, and, when articulated with the adjoining vertebræ, form, with the intervening fibro-cartilage, oval surfaces for the reception of the heads of the corresponding ribs. The *pedicles* are directed backwards, and the inferior intervertebral notches are of large size, and deeper than in any other region of the spine. The *laminae* are broad, thick, and imbricated—that is to say, overlapping one another like tiles on a roof. The



spinal foramen is small, and of a circular form. The *spinous processes* are long, triangular on transverse section, directed obliquely downwards, and terminate in a tubercular extremity. They overlap one another from the fifth to the eighth, but are less oblique in direction above and below. The *articular processes* are flat, nearly vertical in direction, and project from the upper and lower parts of the pedicles; the superior being directed backwards and a little outwards and upwards, the inferior forwards and a little inwards and downwards. The *transverse processes* arise from the same parts of the arch as the posterior roots of the transverse processes in the neck, and are situated behind the articular processes and pedicles; they are thick, strong, and of great length, directed obliquely backwards and outwards, presenting a clubbed extremity, which is tipped on its anterior part by a small, concave surface, for articulation with the tubercle of a rib. Besides the articular facet for the rib, three indistinct tubercles may be seen rising from the transverse processes, one at the upper border, one at the lower border, and one externally. In man, they are comparatively of small size, and serve only for the attachment of muscles. But in some animals they attain considerable magnitude, either for the purpose of more closely connecting the segments of this portion of the spine, or for muscular and ligamentous attachment.

The peculiar dorsal vertebræ are the *first, ninth, tenth, eleventh, and twelfth* (fig. 118).

The **First Dorsal Vertebra** presents, on each side of the *body*, a single entire articular facet for the head of the first rib, and a half-facet for the upper half of the second. The body is like that of a cervical vertebra, being broad transversely; its upper surface is concave, and lipped on each side. The *articular surfaces* are oblique and the *spinous process* thick, long, and almost horizontal.

The **Ninth Dorsal** has no demi-facet below. In some subjects, however, the ninth has two demi-facets on each side, then the tenth has a demi-facet at the upper part; none below.

The **Tenth Dorsal** has (except in the cases just mentioned) an entire articular facet on each side above, which is partly placed on the outer surface of the pedicle. It has no demi-facet below.

In the **Eleventh Dorsal**, the body approaches in its form and size to the lumbar. The articular facets for the heads of the ribs, one on each side, are of large size, and placed chiefly on the pedicles, which are thicker and stronger in this and the next vertebra than in any other part of the dorsal region. The *spinous process* is short, and nearly horizontal in direction. The *transverse processes* are very short, tubercular at their extremities, and have no articular facets for the tubercles of the ribs.

The **Twelfth Dorsal** has the same general characters as the eleventh; but may be distinguished from it by the inferior articular processes being convex and turned outwards, like those of the lumbar vertebræ; by the general form of the body, laminae, and spinous process, approaching to that of the lumbar vertebræ; and by the transverse processes being shorter, and marked by three elevations, the superior, inferior, and external tubercles, which correspond to the mammillary, accessory, and transverse processes of the lumbar vertebræ. Traces of similar elevations are usually to be found upon the other dorsal vertebræ (*vide ut supra*).

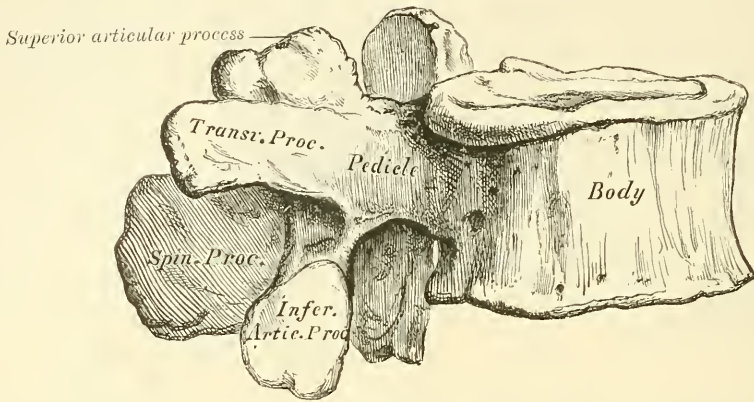
#### CHARACTERS OF THE LUMBAR VERTEBRÆ

The **Lumbar Vertebræ** (fig. 119) are the largest segments of the vertebral column, and can at once be distinguished by the absence of the foramen in the transverse process, the characteristic point of the cervical vertebræ, and by the absence of any articulating facet on the side of the body, the distinguishing mark of the dorsal vertebræ.

The **body** is large, and has a greater diameter from side to side than from before backwards, slightly thicker in front than behind, flattened or slightly

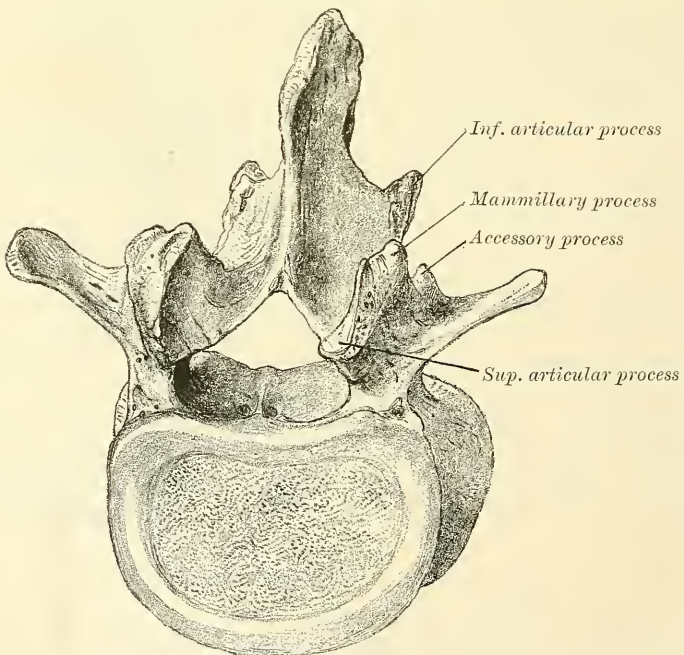
concave above and below, concave behind, and deeply constricted in front and at the sides, presenting prominent margins, which afford a broad basis for the support of the superincumbent weight. The *pedicles* are very strong, directed backwards from the upper part of the bodies; consequently, the inferior intervertebral notches are of considerable depth. The *laminae* are broad, short, and

FIG. 119.—Lumbar vertebra.



strong; and the spinal foramen triangular, larger than in the dorsal, smaller than in the cervical, region. The *spinous processes* are thick and broad, somewhat quadrilateral, horizontal in direction, thicker below than above, and terminating by a rough, uneven border. The *superior articular processes* are concave, and look backwards and inwards; the *inferior*, convex, look forwards

FIG. 120.—Lumbar vertebra.



and outwards; the former are separated by a much wider interval than the latter, embracing the lower articulating processes of the vertebra above. The *transverse processes* are long, slender, directed transversely outwards in the upper three lumbar vertebrae, slanting a little upwards in the lower two. They are



situated in front of the articular processes instead of behind them as in the dorsal vertebræ, and are homologous with the ribs. Of the three tubercles noticed in connection with the transverse processes of the twelfth dorsal vertebra, the *superior* ones become connected in this region with the back part of the superior articular processes, and have received the name of *mammillary* processes; the *inferior* are represented by a small process pointing downwards, situated at the back part of the base of the transverse process, and called the *accessory* processes—these are the true transverse processes, which are rudimental in this region of the spine; the *external* ones are the so-called transverse processes, the homologue of the rib, and hence sometimes called *costal* processes (fig. 120). Although in man these are comparatively small, in some animals they attain considerable size, and serve to lock the vertebræ more closely together.

The **Fifth Lumbar** vertebra is characterised by having the body much thicker in front than behind, which accords with the prominence of the sacro-vertebral articulation; by the smaller size of its spinous process; by the wide interval between the inferior articulating processes; and by the greater size and thickness of its transverse processes.

**Structure of the Vertebræ.**—The structure of a vertebra differs in different parts. The body is composed of light, spongy, cancellous tissue, having a thin coating of compact tissue on its external surface perforated by numerous orifices, some of large size, for the passage of vessels; its interior is traversed by one or two large canals, for the reception of veins, which converge towards a single large, irregular aperture, or several small apertures, at the posterior part of the body of each bone. The arch and processes projecting from it have, on the contrary, an exceedingly thick covering of compact tissue.

**Development.**—Each vertebra is formed of four primary centres of ossification (fig. 121), one for each lamina and its processes, and two for the body.\* Ossification commences in the laminae about the sixth week of fœtal life, in the situation where the transverse processes afterwards project, the ossific granules shooting backwards to the spine, forwards into the pedicles, and outwards into the transverse and articular processes. Ossification in the body commences in the middle of the cartilage about the eighth week by two closely approximated centres, which speedily coalesce to form one central ossific point. According to some authors, ossification commences in the laminae, only in the upper vertebræ—i.e. in the cervical and upper dorsal; the first ossific points in the lower vertebræ being those which are to form the body, the osseous centres for the laminae appearing at a subsequent period. At birth these three pieces are perfectly separate. During the first year the laminae become united behind by a portion of cartilage in which the spinous process is ultimately formed, and thus the arch is completed. About the third year the body is joined to the arch on each side, in such a manner that the body is formed from the three original centres of ossification, the amount contributed by the pedicles increasing in extent from below upwards. Thus the bodies of the sacral vertebræ are formed almost entirely from the central nuclei; the bodies of the lumbar are formed laterally and behind by the pedicles; in the dorsal region, the pedicles advance as far forward as the articular depressions for the head of the ribs, forming these cavities of reception; and in the neck the lateral portions of the bodies are formed entirely by the advance of the pedicles. Before puberty, no other changes occur, excepting a gradual increase in the growth of these primary centres; the upper and under surfaces of the bodies, and the ends of the transverse and

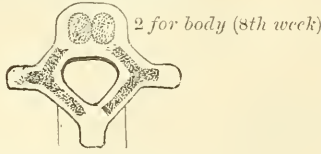
\* By many observers it is asserted that the bodies of the vertebræ are developed from a single centre which speedily becomes bilobed, so as to give the appearance of two nuclei, but that there are two centres, at all events sometimes, is evidenced by the fact that the two halves of the body of the vertebra may remain distinct throughout life, and be separated by a fissure through which a protrusion of the spinal membranes may take place, constituting an anterior spina bifida.



spinous processes, being tipped with cartilage, in which ossific granules are not as yet deposited. At sixteen years (fig. 122), four secondary centres appear, one

FIG. 121.—Development of a vertebra.

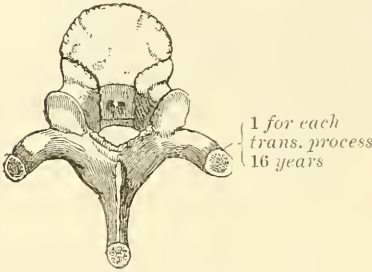
By 4 primary centres



1 for each lamina (6th week)

FIG. 122.

By 4 secondary centres



2 (sometimes 1) for spinous process (16 years)

FIG. 123.

By 2 additional plates

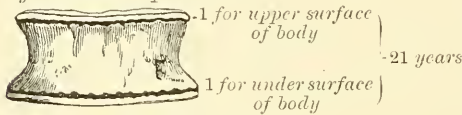


FIG. 124.—Atlas.

By 3 centres

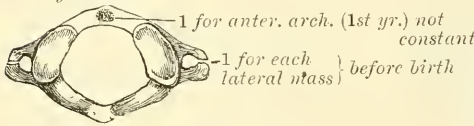


FIG. 125.—Axis.

By 6 centres

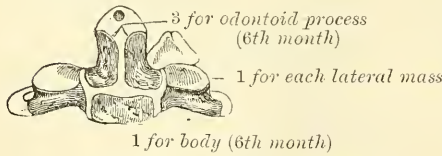
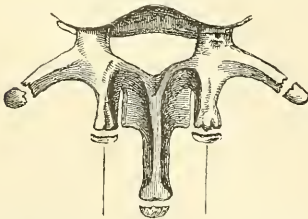


FIG. 126.—Lumbar vertebra.

2 additional centres



for tubercles on superior articular process

for the tip of each transverse process, and two (sometimes united into one) for the end of the spinous process. At twenty-one years (fig. 123), a thin circular epiphysial plate of bone is formed in the layer of cartilage situated on the upper and under surfaces of the body, the former being the thicker of the two. All these become joined, and the bone is completely formed between the twenty-fifth and thirtieth year of life.

Exceptions to this mode of development occur in the first, second, and seventh cervical, and in the vertebrae of the lumbar region.

**The Atlas** (fig. 124).—The number of centres of ossification of the atlas is very variable. It may be developed from two, three, four, or five centres. The most frequent arrangement is by three centres. Two of these are destined for the two lateral or neural masses, the ossification of which commences about the seventh week near the articular processes, and extends backwards; these portions of bone are separated from one another behind, at birth, by a narrow interval filled in with cartilage. Between the second and third years they unite either directly or through the medium of a separate centre, developed in the cartilage in the middle line. The anterior arch, at birth, is altogether cartilaginous, and in this a separate nucleus appears about the end of the first year after birth, and extending laterally joins the neural processes in front of the pedicles. Sometimes there are two nuclei developed in the cartilage, one on either side of the median line, which join to form a single mass. And occasionally there is no separate centre, but the anterior arch is formed by the gradual extension forwards and ultimate junction of the two neural processes.

Exceptional cases

The **Axis** (fig. 125) is developed by *six* centres. The body and arch of this bone are formed in the same manner as the corresponding parts in the other

vertebræ: one centre (or two, which speedily coalesce) for the lower part of the body, and one for each lamina. The odontoid process consists originally of an extension upwards of the cartilaginous mass, in which the lower part of the body is formed. At about the sixth month of foetal life, two osseous nuclei make their appearance in the base of this process: they are placed laterally, and join before birth to form a conical bilobed mass deeply cleft above; the interval between the cleft and the summit of the process is formed by a wedge-shaped piece of cartilage, the base of the process being separated from the body by a cartilaginous interval, which gradually becomes ossified at its circumference, but remains cartilaginous in its centre until advanced age.\* Finally, as Humphry has demonstrated, the apex of the odontoid process has a separate nucleus, which appears in the second year and joins about the twelfth year. In addition to these there is a secondary centre for a thin epiphysial plate on the under surface of the body of the bone.

**The Seventh Cervical.**—The anterior or costal part of the transverse process of the seventh cervical is developed from a separate osseous centre at about the sixth month of foetal life, and joins the body and posterior division of the transverse process between the fifth and sixth years. Sometimes this process continues as a separate piece, and, becoming lengthened outwards, constitutes what is known as a cervical rib.

The **Lumbar Vertebrae** (fig. 126) have *two additional centres* (besides those common to the vertebrae generally) for the mammillary tubercles, which project from the back part of the superior articular processes. The transverse process of the first lumbar is sometimes developed as a separate piece, which may remain permanently unconnected with the remaining portion of the bone, thus forming a lumbar rib—a peculiarity which is rarely met with.

**Progress of Ossification in the Spine generally.**—Ossification of the laminæ of the vertebrae commences at the upper part of the spine, and proceeds gradually downwards. Ossification of the bodies, on the other hand, commences a little below the centre of the spinal column (about the ninth or tenth dorsal vertebra), and extends both upwards and downwards. Although, however, the ossific nuclei make their first appearance in the lower dorsal vertebrae, the lumbar and first sacral are those in which these nuclei are largest at birth.

**Attachment of Muscles.**—To the *Atlas* are attached nine pairs: the Longus colli, Rectus capitis anticus minor, Rectus lateralis, Obliquus capitis superior and inferior, Splenius colli, Levator anguli scapulæ, First Intertransverse, and Rectus capitis posticus minor.

To the *Axis* are attached eleven pairs: the Longus colli, Levator anguli scapulæ, Splenius colli, Scalenus medius, Transversalis colli, Intertransversales, Obliquus capitis inferior, Rectus capitis posticus major, Semi-spinalis colli, Multifidus spinæ, Interspinales.

To the remaining vertebrae, generally, are attached thirty-five pairs and a single muscle: *anteriorly*, the Rectus capitis anticus major, Longus colli, Scalenus anticus, medius, and posticus, Psoas magnus and parvus, Quadratus lumborum, Diaphragm, Obliquus abdominis internus, and Transversalis abdominis,—*posteriorly*, the Trapezius, Latissimus dorsi, Levator anguli scapulæ, Rhomboideus major and minor, Serratus posticus superior and inferior, Splenius, Erector spinæ, Ilio-costalis, Longissimus dorsi, Spinalis dorsi, Cervicalis ascendens, Transversalis colli, Trachelo-mastoid, Complexus, Biventer cervicis, Semi-spinalis dorsi et colli, Multifidus spinæ, Rotatores spinæ, Interspinales, Supraspinales, Intertransversales, Levatores costarum.

#### SACRAL AND COCCYGEAL VERTEBRÆ

The **Sacral and Coccygeal Vertebrae** consist at an early period of life of nine separate pieces which are united in the adult, so as to form two bones, five

\* See Cunningham, *Journ. Anat.* vol. xx. p. 238.

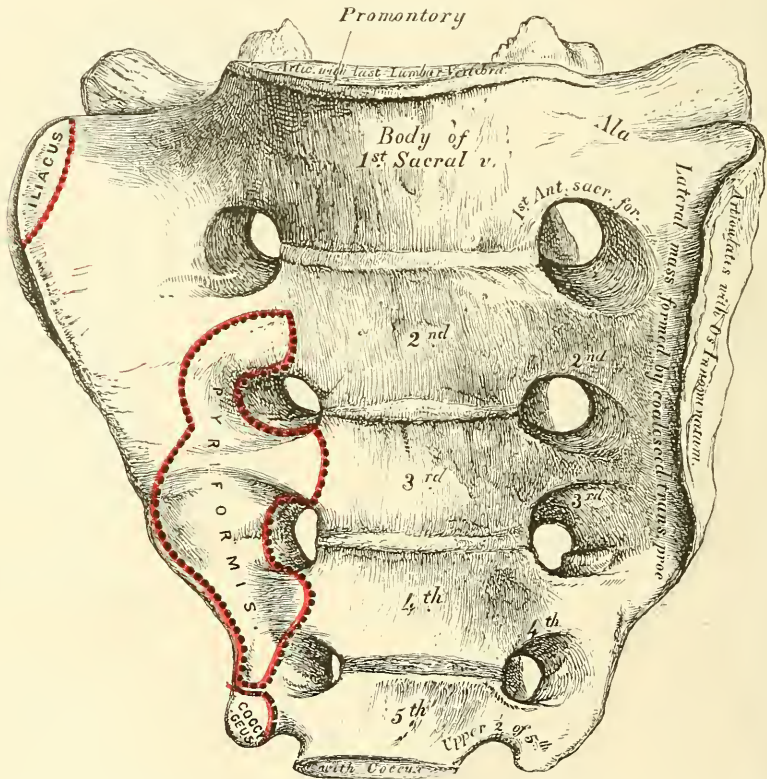


entering into the formation of the sacrum, four into that of the coccyx. Occasionally, the coccyx consists of five bones.\*

### THE SACRUM

The **Sacrum** (*sacer, sacred*) is a large, triangular bone (fig. 127), situated at the lower part of the vertebral column, and at the upper and back part of the pelvic cavity, where it is inserted like a wedge between the two innominate bones; its upper part or base, articulating with the last lumbar vertebra, its apex with the coccyx. The sacrum is curved upon itself, and placed very obliquely, its upper extremity projecting forwards, and forming, with the last lumbar vertebra, a very prominent angle, called the *promontory* or *sacro-vertebral angle*; whilst its central part is directed backwards, so as to give increased

FIG. 127.—Sacrum, anterior surface.



capacity to the pelvic cavity. It presents for examination an anterior and posterior surface, two lateral surfaces, a base, an apex and a central canal.

The **Anterior Surface** is concave from above downwards, and slightly so from side to side. In the middle are seen four transverse ridges, indicating the original division of the bone into five separate pieces. The portions of bone intervening between the ridges correspond to the bodies of the vertebrae. The body of the first segment is of large size, and in form resembles that of a lumbar vertebra; the succeeding ones diminish in size from above downwards, are flattened from before backwards, and curved so as to accommodate themselves to the form of the sacrum, being concave in front, convex behind. At each end of the ridges above mentioned are seen the *anterior sacral foramina*, analogous to the intervertebral foramina, four in number on each side, somewhat rounded in

\* The late Sir George Humphry described this as the usual composition of the coccyx.—*On the Skeleton*, p. 456.



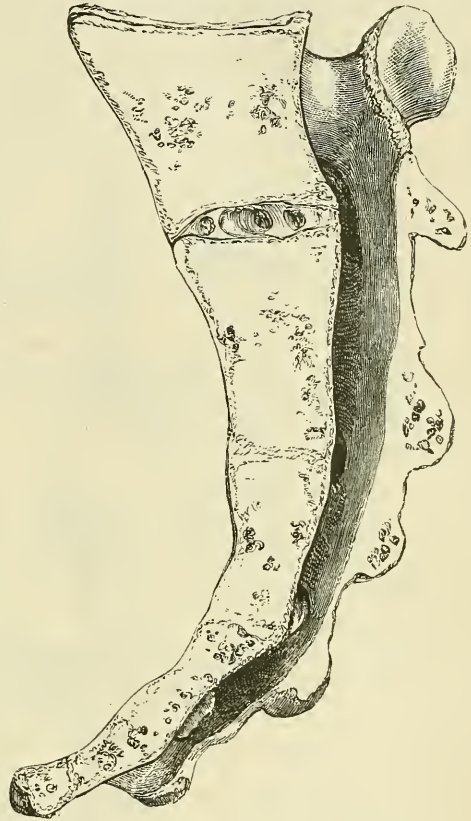form, diminishing in size from above downwards, and directed outwards and forwards: they transmit the anterior branches of the sacral nerves and the lateral sacral arteries. External to these foramina is the *lateral mass*, consisting, at an early period of life, of separate segments; these become blended, in the adult, with the bodies, with each other, and with the posterior transverse processes. Each lateral mass is traversed by four broad, shallow grooves, which lodge the anterior sacral nerves as they pass outwards, the grooves being separated by prominent ridges of bone which give attachment to the slips of the *Pyriformis* muscle.

If a vertical section is made through the centre of the bone (fig. 128), the bodies are seen to be united at their circumference by bone, a wide interval being left centrally, which, in the recent state, is filled by intervertebral substance. In some bones, this union is more complete between the lower segments than between the upper ones.

The **Posterior Surface** (fig. 129) is convex and much narrower than the anterior. In the middle line are three or four tubercles, which represent the rudimentary spinous processes of the sacral vertebræ. Of these tubercles, the first is usually prominent, and perfectly distinct from the rest; the second and third are either separate or united into a tubercular ridge, which diminishes in size from above downwards; the fourth usually, and the fifth always remaining undeveloped.

External to the spinous processes on each side are the *laminae*, broad and well marked in the first three pieces; sometimes the fourth, and generally the fifth, are only partially developed and fail to meet in the middle line. These partially-developed laminae are prolonged downwards, as rounded processes, the *sacral cornua*, and are connected to the cornua of the coccyx. Between them the bony wall of the lower end of the sacral canal is imperfect, and is liable to be opened in the sloughing of bed-sores. External to the laminae is a linear series of indistinct tubercles representing the *articular processes*; the upper pair are large, well developed, and correspond in shape and direction to the superior articulating processes of a lumbar vertebra; the second and third are small; the fourth and fifth (usually blended together) are situated on each side of the sacral canal and assist in forming the sacral cornua. External to the articular processes are the four *posterior sacral foramina*; they are smaller in size and less regular in form than the anterior, and transmit the posterior branches of the sacral nerves. On the outer side of the posterior sacral foramina is a series of tubercles, the rudimentary *transverse processes* of the sacral vertebræ. The first pair of transverse tubercles are of large size, very distinct, and correspond with each superior angle of the bone; the second, small in size, enter into the formation of the sacro-iliac articulation; the third give attachment to the oblique fasciculi of the posterior sacro-iliac ligaments; and the fourth and fifth to the great sacro-sciatic ligaments. The interspace between the spinous and trans-

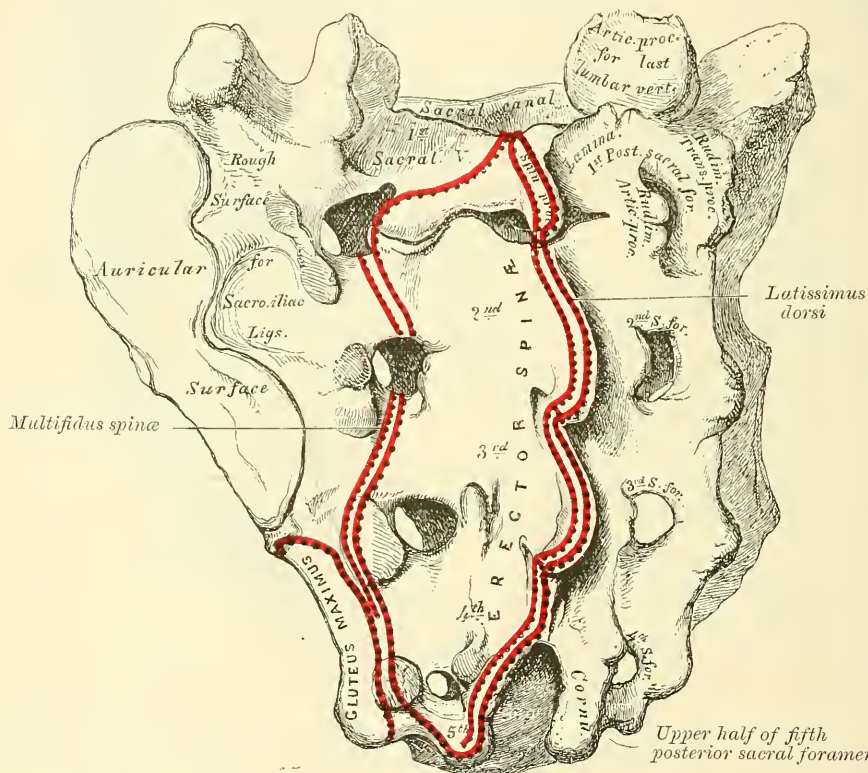
FIG. 128.—Vertical section of the sacrum.



verse processes on the back of the sacrum presents a wide, shallow concavity, called the *sacral groove*; it is continuous above with the vertebral groove, and lodges the origin of the Erector spinæ.

The **Lateral Surface**, broad above, becomes narrowed into a thin edge below. Its upper half presents in front a broad, ear-shaped surface for articulation with the ilium. This is called the *auricular surface*, and in the fresh state is coated with fibro-cartilage. It is bounded posteriorly by deep and uneven impressions, for the attachment of the posterior sacro-iliac ligaments. The lower half is thin and sharp, and gives attachment to the greater and lesser sacro-sciatic ligaments, and to some fibres of the Gluteus maximus; below, it presents a deep notch,

FIG. 129.—Sacrum, posterior surface.



which is converted into a foramen by articulation with the transverse process of the upper piece of the coccyx, and transmits the anterior division of the fifth sacral nerve.

The **Base** of the sacrum, which is broad and expanded, is directed upwards and forwards. In the middle is seen a large oval articular surface, which is connected with the under surface of the body of the last lumbar vertebra by a fibro-cartilaginous disc. It is bounded behind by the large, triangular orifice of the sacral canal. The orifice is formed behind by the laminæ and spinous process of the first sacral vertebra: the superior articular processes project from it on each side; they are oval, concave, directed backwards and inwards, like the superior articular processes of a lumbar vertebra; and in front of each articular process is an intervertebral notch, which forms the lower half of the last intervertebral foramen. Lastly, on each side of the large oval articular surface is a broad and flat triangular surface of bone, which extends outwards, supports the Psoas magnus muscle and lumbo-sacral cord, and is continuous on each side with the iliac fossa. This is called the *ala* of the sacrum, and gives attachment to a few of the fibres of the Iliacus muscle.



The **Apex**, directed downwards and forwards, presents a small, oval, concave surface for articulation with the coccyx.

The **Spinal Canal** runs throughout the greater part of the bone; it is large and triangular in form above; small and flattened, from before backwards, below. In this situation its posterior wall is incomplete, from the non-development of the laminae and spinous processes. It lodges the sacral nerves, and is perforated by the anterior and posterior sacral foramina, through which these pass out.

**Structure.**—It consists of much loose, spongy tissue within, invested externally by a thin layer of compact tissue.

**Differences in the Sacrum of the Male and Female.**—The sacrum in the female is usually wider than in the male; the lower half forms a greater angle with the upper; the upper half of the bone being nearly straight, the lower half presenting the greatest amount of curvature. The bone is also directed more obliquely backwards, which increases the size of the pelvic cavity; but the sacro-vertebral angle projects less. In the male the curvature is more evenly distributed over the whole length of the bone, and is altogether greater than in the female.

**Peculiarities of the Sacrum.**—This bone, in some cases, consists of six pieces; occasionally, the number is reduced to four. Sometimes the bodies of the first and second segments are not joined, or the laminae and spinous processes have not coalesced. Occasionally, the upper pair of transverse tubercles are not joined to the rest of the bone on one or both sides; and, lastly, the sacral canal may be open for nearly the lower half of the bone, in consequence of the imperfect development of the laminae and spinous processes. The sacrum, also, varies considerably with respect to its degree of curvature. From the examination of a large number of skeletons, it would appear that, in one set of cases, the anterior surface of this bone was nearly straight, the curvature, which was very slight, affecting only its lower end. In another set of cases, the bone was curved throughout its whole length, but especially towards its middle. In a third set, the degree of curvature was less marked, and affected especially the lower third of the bone.

**Development** (fig. 130).—The sacrum, formed by the union of five vertebrae, has *thirty-five* centres of ossification.

The *bodies* of the sacral vertebrae have each three ossific centres: one for the central part, and one for the epiphysial plates on its upper and under surface. Occasionally the primary centres for the bodies of the first and second piece of the sacrum are double.

The arch of each sacral vertebra is developed by two centres, one for each lamina. These unite with each other behind, and subsequently join the body.

The *lateral masses* have six additional centres, two for each of the first three vertebrae. These centres make their appearance above and to the outer side of the anterior sacral foramina (fig. 130), and are developed into separate segments (fig. 131); they are subsequently blended with each other, and with the bodies and transverse processes, to form the lateral mass.

Lastly, each *lateral surface* of the sacrum is developed by two epiphysial plates (fig. 132): one for the auricular surface, and one for the remaining part of the thin lateral edge of the bone.

**Period of Development.**—At about the eighth or ninth week of foetal life, ossification of the central part of the bodies of the first three vertebrae commences; and, at a somewhat later period, that of the last two. Between the sixth and eighth month ossification of the laminae takes place; and at about the same period, the characteristic osseous tubercles for the first three sacral vertebrae make their appearance. The period at which the arch becomes completed by the junction of the laminae with the bodies in front, and with each other behind, varies in different segments. The junction between the laminae and the bodies takes place first in the lower vertebrae as early as the second year, but is not



effected in the uppermost until the fifth or sixth year. About the sixteenth year the epiphyses for the upper and under surfaces of the bodies are formed; and between the eighteenth and twentieth years, those for each lateral surface of the sacrum make their appearance. The bodies of the sacral vertebræ are, during early life, separated from each other by intervertebral discs. But about the eighteenth year the two lowest segments become joined together by ossification extending through the disc. This process gradually extends upwards until all the segments become united; and the bone is completely formed from the twenty-fifth to the thirtieth year of life.

FIG. 130.—Development of the sacrum.

*Additional centres  
for the first three pieces \**

*At birth*

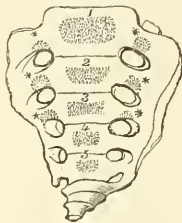


FIG. 131.

*At 4½ yrs.*

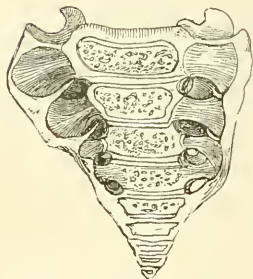
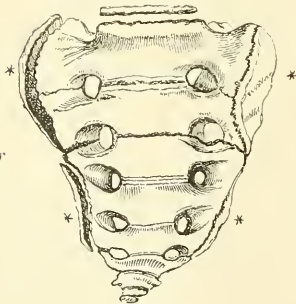


FIG. 132.

*Two epiphysial laminae  
for each lateral surface \**

*At  
25th year*



so as to form a single bone. The gradual diminution in the size of the pieces gives this bone a triangular form, the base of the triangle joining the end of the sacrum. It presents for examination an anterior and posterior surface, two borders, a base, and an apex. The *anterior surface* is slightly concave, and marked with three transverse grooves, indicating the points of junction of the different pieces. It has attached to it the anterior sacro-coccygeal ligament and Levator ani muscle, and supports the lower end of the rectum. The *posterior surface* is convex, marked by transverse grooves similar to those on the anterior surface; and presents on each side a lineal row of tubercles, the rudimentary articular processes of the coccygeal vertebræ. Of these, the superior pair are large, and are called the *cornua of the coccyx*: they project upwards, and articulate with the cornua of the sacrum, the junction between these two bones com-

**Articulations.**—With four bones: the last lumbar vertebra, coccyx, and the two innominate bones.

**Attachment of Muscles.**—To eight pairs: in front, the Piriformis and Coccygeus, and a portion of the Iliacus to the base of the bone; behind, the Gluteus maximus, Latissimus dorsi, Multifidus spinæ, and Erector spinæ, and sometimes the Extensor coccygis.

#### THE COCCYX

The **Coccyx** (κόκκυξ, *cuckoo*), so called from having been compared to a cuckoo's beak (fig. 133), is usually formed of four small segments of bone, and is the most rudimentary part of the vertebral column. In each of the first three segments may be traced a rudimentary body, articular and transverse processes; the last piece (sometimes the third) is a mere nodule of bone, without distinct processes. All the segments are destitute of pedicles, laminae, and spinous processes; and, consequently, of intervertebral foramina and spinal canal. The first segment is the largest; it resembles the lowermost sacral vertebra, and often exists as a separate piece; the last three, diminishing in size from above downwards, are usually blended together

pleting the fifth posterior sacral foramen for the transmission of the posterior division of the fifth sacral nerve. The *lateral borders* are thin, and present a series of small eminences, which represent the transverse processes of the coccygeal vertebræ. Of these, the first on each side is the largest, flattened from before backwards, and often ascends to join the lower part of the thin lateral edge of the sacrum, thus completing the fifth anterior sacral foramen for the transmission of the anterior division of the fifth sacral nerve; the others diminish in size from above downwards, and are often wanting. The *borders* of the coccyx are narrow, and give attachment on each side to the sacro-sciatic ligaments, to the Coccygeus muscle in front of the ligaments, and to the Gluteus maximus behind them. The *base* presents an oval surface for articulation with the sacrum. The *apex* is rounded, and has attached to it the tendon of the external Sphincter muscle. It is occasionally bifid, and sometimes deflected to one or other side.

**Development.**—The coccyx is developed by *four* centres, one for each piece. Occasionally one of the first three pieces of this bone is developed by two centres, placed side by side. The ossific nuclei make their appearance in the following order: in the first segment at birth; in the second piece, at from five to ten years; in the third, from ten to fifteen years; in the fourth from fifteen to twenty years. As age advances, these various segments become united in the following order: the first two pieces join; then the third and fourth; and, lastly, the bone is completed by the union of the second and third. At a late period of life, especially in females, the coccyx often becomes joined to the end of the sacrum.

**Articulation.**—With the sacrum.

**Attachment of Muscles.**—To four pairs and one single muscle: on either side, the Coccygeus; behind, the Gluteus maximus and Extensor coccygis, when present; at the apex, the Sphincter ani; and in front/ the Levator ani.

#### OF THE SPINE IN GENERAL

The **Spinal Column**, formed by the junction of the vertebræ, is situated in the median line, at the posterior part of the trunk; its average length is about two feet two or three inches, measuring along the curved anterior surface of the column. Of this length the cervical part measures about five, the dorsal about eleven, the lumbar about seven inches, and the sacrum and coccyx the remainder. The female spine is about one inch less than the male.

Viewed in front, it presents two pyramids joined together at their bases, the upper one being formed by all the vertebræ from the second cervical to the last lumbar, the lower one by the sacrum and coccyx. When examined more closely, the upper pyramid is seen to be formed of three smaller pyramids. The uppermost of these consists of the six lower cervical vertebræ; its apex being formed by the axis or second cervical, its base by the first dorsal. The second pyramid, which is inverted, is formed by the four upper dorsal vertebræ, the base being at the first dorsal, the smaller end at the fourth. The third pyramid commences at the fourth dorsal, and gradually increases in size to the fifth lumbar.

FIG. 133.—Coccyx.

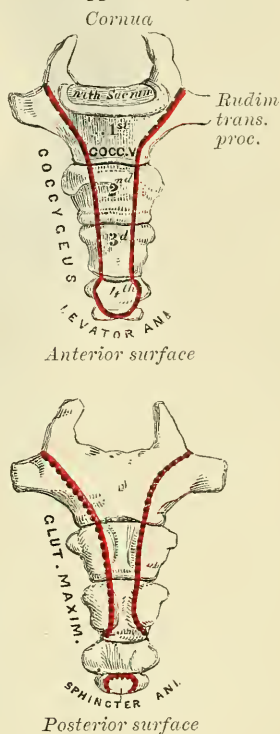
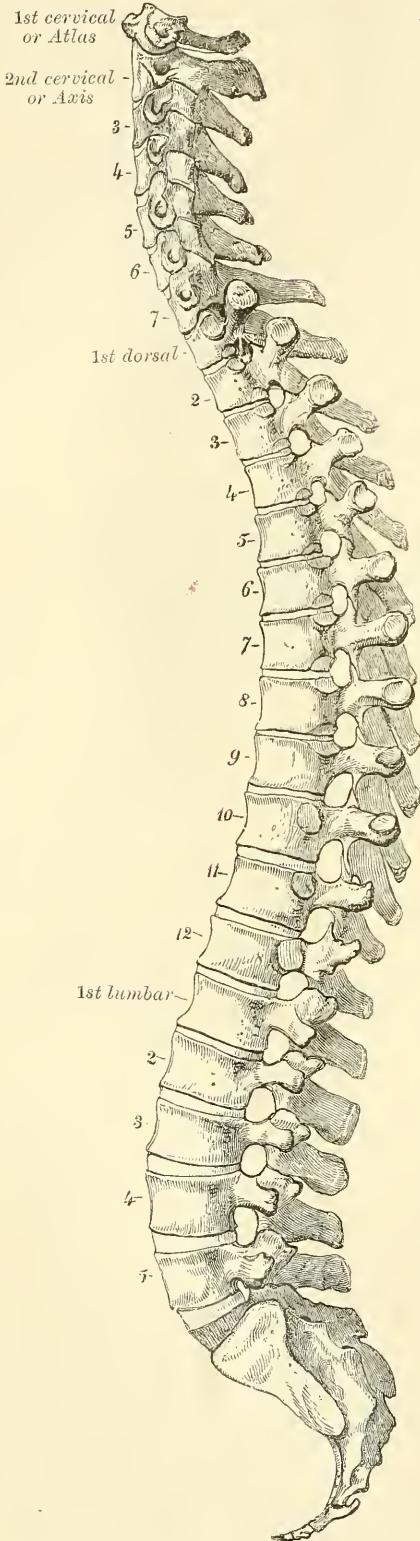


FIG. 134.—Lateral view of the spine.



Viewed laterally (fig. 134), the spinal column presents several curves, which correspond to the different regions of the column, and are called *cervical*, *dorsal*, *lumbar*, and *pelvic*. The *cervical* curve commences at the apex of the odontoid process, and terminates at the middle of the second dorsal vertebra; it is convex in front, and is the least marked of all the curves. The *dorsal* curve, which is concave forwards, commences at the middle of the second and terminates at the middle of the twelfth dorsal vertebra. Its most prominent point behind corresponds to the spine of the seventh dorsal. The *lumbar* curve commences at the middle of the last dorsal vertebra, and terminates at the sacro-vertebral angle. It is convex anteriorly; the convexity of the lower three vertebræ being much greater than that of the upper ones. The *pelvic* curve commences at the sacro-vertebral articulation, and terminates at the point of the coccyx. It is concave anteriorly. The dorsal and pelvic curves are the primary curves, and begin to be formed at an early period of foetal life, and are due to the shape of the bodies of the vertebræ. The cervical and lumbar curves are compensatory or secondary, and are developed after birth in order to maintain the erect position. They are due mainly to the shape of the intervertebral discs.

The spine has also a slight lateral curvature, the convexity of which is directed towards the right side. This is most probably produced, as Bichat first explained, \*chiefly by muscular action; most persons using the right arm in preference to the left, especially in making long-continued efforts, when the body is curved to the right side. In support of this explanation, it has been found, by Béclard, that in one or two individuals who were left-handed, the lateral curvature was directed to the left side.

The spinal column presents for examination an anterior, a posterior, and two lateral surfaces: a base, summit, and spinal canal.

The **anterior surface** presents the bodies of the vertebræ separated in the recent state by the intervertebral discs. The bodies are broad in the cervical



region, narrow in the upper part of the dorsal, and broadest in the lumbar region. The whole of this surface is convex transversely, concave from above downwards in the dorsal region, and convex in the same direction in the cervical and lumbar regions.

The **posterior surface** presents in the median line the spinous processes. These are short, horizontal, with bifid extremities, in the cervical region. In the dorsal region, they are directed obliquely above, assume almost a vertical direction in the middle, and are horizontal below, as are also the spines of the lumbar vertebræ. They are separated by considerable intervals in the loins, by narrower intervals in the neck, and are closely approximated in the middle of the dorsal region. Occasionally one of these processes deviates a little from the median line—a fact to be remembered in practice, as irregularities of this sort are attendant also on fractures or displacements of the spine. On either side of the spinous processes, extending the whole length of the column, is the vertebral groove formed by the laminæ in the cervical and lumbar regions, where it is shallow, and by the laminæ and transverse processes in the dorsal region, where it is deep and broad. In the recent state, these grooves lodge the deep muscles of the back. External to the vertebral grooves are the articular processes, and still more externally the transverse process. In the dorsal region, the latter processes stand backwards, on a plane considerably posterior to the same processes in the cervical and lumbar regions. In the cervical region, the transverse processes are placed in front of the articular processes, and on the outer side of the pedicles, between the intervertebral foramina. In the dorsal region they are posterior to the pedicles, intervertebral foramina, and articular processes. In the lumbar, they are placed also in front of the articular processes, but behind the intervertebral foramina.

The **lateral surfaces** are separated from the posterior by the articular processes in the cervical and lumbar regions, and by the transverse processes in the dorsal. These surfaces present in front the sides of the bodies of the vertebræ, marked in the dorsal region by the facets for articulation with the heads of the ribs. More posteriorly are the intervertebral foramina, formed by the juxtaposition of the intervertebral notches, oval in shape, smallest in the cervical and upper part of the dorsal regions, and gradually increasing in size to the last lumbar. They are situated between the transverse processes in the neck, and in front of them in the back and loins, and transmit the spinal nerves.

The **base** of that portion of the vertebral column formed by the twenty-four movable vertebræ is formed by the under surface of the body of the fifth lumbar vertebra; and the **summit** by the upper surface of the atlas.

The **vertebral or spinal canal** follows the different curves of the spine; it is largest in those regions in which the spine enjoys the greatest freedom of movement, as in the neck and loins, where it is wide and triangular; and narrow and rounded in the back, where motion is more limited.

*Surface Form.*—The only part of the vertebral column which lies closely under the skin, and so directly influences surface form, is the apices of the spinous processes. These are always distinguishable at the bottom of a median furrow, which, more or less evident, runs down the mesial line of the back from the external occipital protuberance above to the middle of the sacrum below. In the neck the furrow is broad, and terminates in a conspicuous projection, which is caused by the spinous process of the seventh cervical vertebra (*vertebra prominens*). Above this the spinous process of the sixth cervical vertebra may sometimes be seen; the other cervical spines are sunken, and are not visible, though the spine of the axis can be felt, and generally also the spines of the third, fourth, and fifth cervical vertebræ. In the dorsal region, the furrow is shallow, and during stooping disappears, and then the spinous processes become more or less visible. The markings produced by these spines are small and close together. In the lumbar region the furrow is deep, and the situation of the lumbar spines is frequently indicated by little pits or depressions, especially if the muscles in the loins are well developed and the spine incurved. They are much larger and farther apart than in the dorsal region. In the sacral region the furrow is shallower, presenting a flattened area which terminates below at the most prominent part of the posterior surface of the sacrum, formed by the spinous

process of the third sacral vertebra. At the bottom of the furrow may be felt the irregular posterior surface of the bone. Below this, in the deep groove leading to the anus, the coccyx may be felt. The only other portions of the vertebral column which can be felt from the surface are the transverse processes of three of the cervical vertebrae—viz. the first, the sixth, and the seventh. The transverse process of the atlas can be felt as a rounded nodule of bone just below and in front of the apex of the mastoid process, along the anterior border of the sterno-mastoid. The transverse process of the sixth cervical vertebra is of surgical importance. If deep pressure be made in the neck, in the course of the carotid artery, opposite the cricoid cartilage, the prominent anterior tubercle of the transverse process of the sixth cervical vertebra can be felt. This has been named *Chassaignac's tubercle*, and against it the carotid artery may be most conveniently compressed by the finger. The transverse process of the seventh cervical vertebra can also often be felt. Occasionally the anterior root, or costal process, is large and segmented off, forming a cervical rib.

*Surgical Anatomy.*—Occasionally the coalescence of the laminae is not completed, and consequently a cleft is left in the arches of the vertebrae, through which a protrusion of the spinal membranes (dura mater and arachnoid), and sometimes of the spinal cord itself, takes place, constituting the disease known as *spina bifida*. This disease is most common in the lumbo-sacral region, on account of the fact, previously stated, that the closure of the arches takes place gradually from above downwards; but it may occur in the dorsal or cervical region, or the arches throughout the whole length of the canal may remain unapproximated. In some rare cases, in consequence of the non-coalescence of the two primary centres from which the body is formed, a similar condition may occur in front of the canal, the bodies of the vertebrae being found cleft and the tumour projecting into the thorax, abdomen, or pelvis, between the lateral halves of the bodies affected.

The construction of the spinal column of a number of pieces, securely connected together and enjoying only a slight degree of movement between any two individual pieces, though permitting of a very considerable range of movement as a whole, allows a sufficient degree of mobility without any material diminution of strength. The many joints of which the spine is composed, together with the very varied movements to which it is subjected, render it liable to sprains; but so closely are the individual vertebrae articulated that these sprains are rarely or ever severe, and any amount of violence sufficiently great to produce tearing of the ligaments would tend rather to cause a dislocation or fracture. The further safety of the column and its less liability to injury is provided for by its disposition in curves, instead of in one straight line. For it is an elastic column, and must first bend before it breaks; under these circumstances, being made up of three curves, it represents three columns, and greater force is required to produce bending of a short column, than of a longer one that is equal to it in breadth and material. Again, the safety of the column is provided for by the interposition of the intervertebral disc between the bodies of the vertebrae, which act as admirable buffers in counteracting the effects of violent jars or shocks. Fracture-dislocation of the spine may be caused by direct or indirect violence or by a combination of the two, as when a person, falling from a height, strikes against some prominence and is doubled over it. The fractures from indirect violence are the more common, and here the bodies of the vertebrae are compressed, whilst the arches are torn asunder; in fractures from direct violence, on the other hand, the arches are compressed and the bodies of the vertebrae separated from each other. It will therefore be seen that in both classes of injury the spinal marrow is the part least likely to be injured, and may escape damage even where there has been considerable lesion of the bony framework. For, as Mr. Jacobson states, 'being lodged in the centre of the column, it occupies neutral ground in respect to forces which might cause fracture. For it is a law in mechanics that when a beam, as of timber, is exposed to breakage and the force does not exceed the limits of the strength of the material, one division resists compression, another laceration of the particles, while the third, between the two, is in a negative condition.'\* Applying this principle to the spine, it will be seen that, whether the fracture-dislocation be produced by direct violence or indirect, one segment, either the anterior or posterior, will be exposed to compression, the other to laceration, and the intermediate part, where the cord is situated, will be in a neutral state. When a fracture-dislocation is produced by indirect violence, the displacement is almost always the same; the upper segment being driven forwards on the lower, so that the cord is compressed between the body of the vertebra below and the arch of the vertebra above.

The parts of the spine most liable to be injured are (1) the dorsi-lumbar region, for this part is near the middle of the column and there is therefore a greater amount of leverage, and moreover the portion above is comparatively fixed, and the vertebrae which form it, though much smaller, have nevertheless to bear almost as great a weight as those below; (2) the cervico-dorsal region, because here the flexible cervical portion of the spine joins the more fixed dorsal region; and (3) the alto-axoid region, because it enjoys an extensive range of movement, and, being near the skull, is influenced by violence applied to the head. In fracture-dislocation it has been proposed to trephine the spine and remove portions of the laminae and spinous processes. The operation can only be of use when

\* Holmes's *System of Surgery*, vol. i. p. 529. 1883.



the paralysis is due to the pressure of bone or the effusion of blood, and not to cases, which are by far the most common, where the cord is crushed to a pulp. And even in those cases where the cord is compressed by bone, the portion of displaced bone which presses on the cord is generally the body of the vertebra below, and is therefore inaccessible to operation. The operative proceeding is one of great severity, involving an extensive and deep wound and great risk of septic meningitis, and as the advantages to be derived from it are exceedingly problematical and confined to a very few cases, it is not often resorted to. Trephining has also been employed in some cases of paraplegia, due to Potts's disease of the spine. Here the paralysis is due to the pressure of inflammatory products, and where this is new scar-tissue, formed by the organisation of granulation tissue, its removal has been attended with a very considerable amount of success.

## THE SKULL

The **Skull**, or superior expansion of the vertebral column, has been described as if composed of four vertebræ, the elementary parts of which are specially modified in form and size, and almost immovably connected, for the reception of the brain and special organs of the senses. These vertebræ are the occipital, parietal, frontal, and nasal. Descriptive anatomists, however, divide the skull into two parts, the Cranium and the Face. The Cranium (*κράνος*, a *helmet*) is composed of *eight* bones—viz. the *occipital*, two *parietal*, *frontal*, two *temporal*, *sphenoid*, and *ethmoid*. The face is composed of *fourteen* bones—viz. the two *nasal*, two *superior maxillary*, two *lachrymal*, two *malar*, two *palate*, two *inferior turbinated*, *vomer*, and *inferior maxillary*. The *ossicula auditûs*, the *teeth*, and *Wormian bones* are not included in this enumeration.

Skull, 22 bones	}	Cranium, 8 bones	Occipital.
			Two parietal.
Frontal.			
Two Temporal.			
Sphenoid.			
Ethmoid.			
Face, 14 bones			Two Nasal.
			Two Superior Maxillary.
	Two Lachrymal.		
	Two Malar.		
	Two Palate.		
	Two Inferior Turbinated.		
	Vomer.		
Inferior Maxillary.			

## THE OCCIPITAL BONE

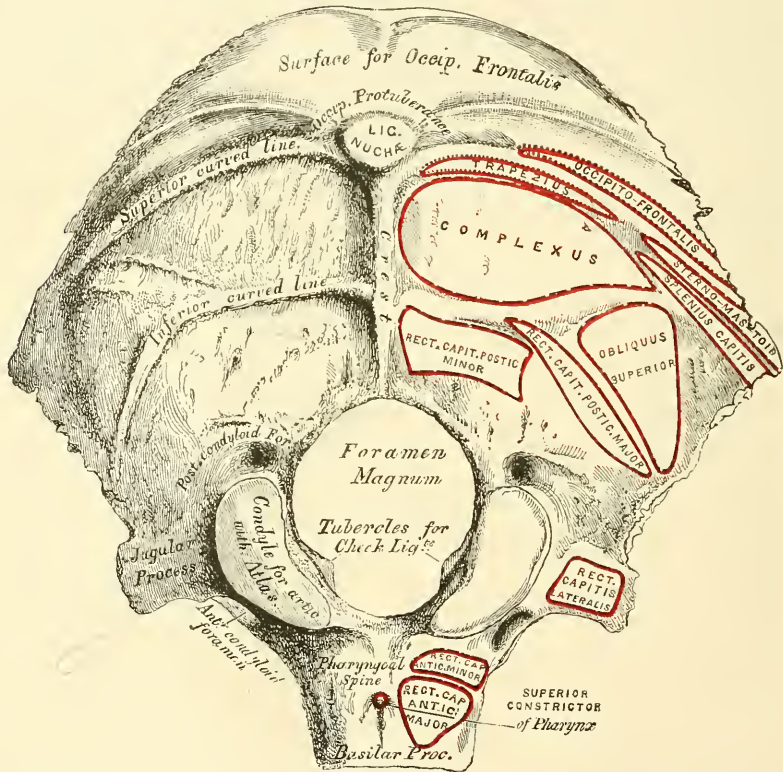
The **Occipital Bone** (*ob, caput, against the head*) is situated at the back part and base of the cranium. It is trapezoid in shape and is much curved on itself (fig. 135). It presents at its front and lower part a large oval aperture, the *foramen magnum*, by which the cranial cavity communicates with the spinal canal. The portion of bone behind this opening is flat and expanded and forms the *tabula*; the portion in front is a thick, elongated mass of bone, the *basilar process*; whilst on either side of the foramen are situated processes bearing the condyles, by which the bone articulates with the atlas. These processes are known as the *condylar portions*. It presents for examination two surfaces, four borders, and four angles.

The **external surface** is convex. Midway between the summit of the bone and the posterior margin of the foramen magnum is a prominent tubercle, the *external occipital protuberance*, for the attachment of the Ligamentum nuchæ; and descending from it as far as the foramen, a vertical ridge, the *external occipital crest*. This tubercle and crest vary in prominence in different skulls. Passing outwards from the occipital protuberance is a semicircular ridge on each side,



the *superior curved line*. Above this line there is often a second less distinctly marked ridge, called the *highest curved line (linea suprema)*, to which the epicranial aponeurosis is attached. The bone between these two lines is smoother and denser than the rest of the surface. Running parallel with these from the middle of the crest is another semicircular ridge on each side, the *inferior curved line*. The surface of the bone above the *linea suprema* is rough and porous, and, in the recent state, is covered by the Occipito-frontalis muscle, whilst the ridges, as well as the surface of the bone between them, serve for the attachment of numerous muscles. The superior curved line gives attachment internally to the Trapezius, externally to the muscular origin of the Occipito-frontalis, and to the Sterno-cleido-mastoid, to the extent shown in fig. 135; the depressions between the curved lines to the Complexus internally, the Splenius capitis and Obliquus

FIG. 135.—Occipital bone. Outer surface.



capitis superior externally. The inferior curved line, and the depressions below it, afford insertion to the Rectus capitis posticus, major and minor.

The **foramen magnum** is a large, oval aperture, its long diameter extending from before backwards. It transmits the medulla oblongata and its membranes, the spinal accessory nerves, the vertebral arteries, the anterior and posterior spinal arteries, and the occipito-axial ligaments. Its back part is wide for the transmission of the medulla, and the corresponding margin rough for the attachment of the dura mater enclosing it; the fore part is narrower, being encroached upon by the condyles; it has projecting towards it, from below, the odontoid process, and its margins are smooth and bevelled internally to support the medulla oblongata. On each side of the foramen magnum are the *condyles*, for articulation with the atlas; they are convex, oblong or reniform in shape, and directed downwards and outwards; they converge in front, and encroach slightly upon the anterior segment of the foramen. On the inner border of each

condyle is a rough tubercle for the attachment of the ligaments (*check*) which connect this bone with the odontoid process of the axis; whilst external to them is a rough tubercular prominence, the *transverse* or *jugular process* (the representative of the transverse process of a vertebra), channelled in front by a deep notch, which forms part of the jugular foramen, or foramen lacerum posterius. The under surface of this process presents an eminence, which represents the *paramastoid process* of some mammals. The eminence is occasionally large, and extends as low as the transverse process of the atlas. This surface affords attachment to the Rectus capitis lateralis muscle and to the lateral occipito-atlantal ligament; its upper or cerebral surface presents a deep groove which lodges part of the lateral sinus, whilst its external surface is marked by a quadrilateral rough facet, covered with cartilage in the fresh state, and articulating with a similar surface on the petrous portion of the temporal bone. On the outer side of each condyle, near its fore part, is a foramen, the *anterior condyloid*; it is directed downwards, outwards, and forwards, and transmits the hypoglossal nerve, and occasionally a meningeal branch of the ascending pharyngeal artery. This foramen is sometimes double. Behind each condyle is a fossa,\* sometimes perforated at the bottom by a foramen, the *posterior condyloid*, for the transmission of a vein to the lateral sinus. In front of the foramen magnum is a strong quadrilateral plate of bone, the *basilar process*, wider behind than in front; its under surface, which is rough, presenting in the median line a tubercular ridge, the *pharyngeal spine*, for the attachment of the tendinous raphé and Superior constrictor of the pharynx; and on each side of it, rough depressions for the attachment of the Rectus capitis anticus, major and minor.

The **Internal or Cerebral Surface** (fig. 136) is deeply concave. The posterior part or tabula is divided by a crucial ridge into four fossæ. The two superior fossæ receive the occipital lobes of the cerebrum, and present slight eminences and depressions corresponding to their convolutions. The two inferior, which receive the hemispheres of the cerebellum, are larger than the former, and comparatively smooth; both are marked by slight grooves for the lodgment of arteries. At the point of meeting of the four divisions of the crucial ridge is an eminence, the *internal occipital protuberance*. It nearly corresponds to that on the outer surface, and is perforated by one or more large vascular foramina. From this eminence, the superior division of the crucial ridge runs upwards to the superior angle of the bone; it presents a deep groove for the superior longitudinal sinus, the margins of which give attachment to the falx cerebri. The inferior division, the *internal occipital crest*, runs to the posterior margin of the foramen magnum, on the edge of which it becomes gradually lost; this ridge, which is bifurcated below, serves for the attachment of the falx cerebelli. It is usually marked by a single groove, which commences at the back part of the foramen magnum and lodges the occipital sinus. Occasionally the groove is double where two sinuses exist. The transverse grooves pass outwards to the lateral angles; they are deeply channelled, for the lodgment of the lateral sinuses, their prominent margins affording attachment to the tentorium cerebelli.† At the point of meeting of these grooves is a depression, the *torcular Herophili*,‡ placed a little to one or the other side of the internal occipital protuberance. More anteriorly is the foramen magnum, and on each side of it, but nearer its anterior than its posterior part, the internal openings of the anterior condyloid foramina; the internal

\* This fossa presents many variations in size. It is usually shallow, and the foramen small; occasionally wanting on one or both sides. Sometimes both fossa and foramen are large, but confined to one side only; more rarely, the fossa and foramen are very large on both sides.

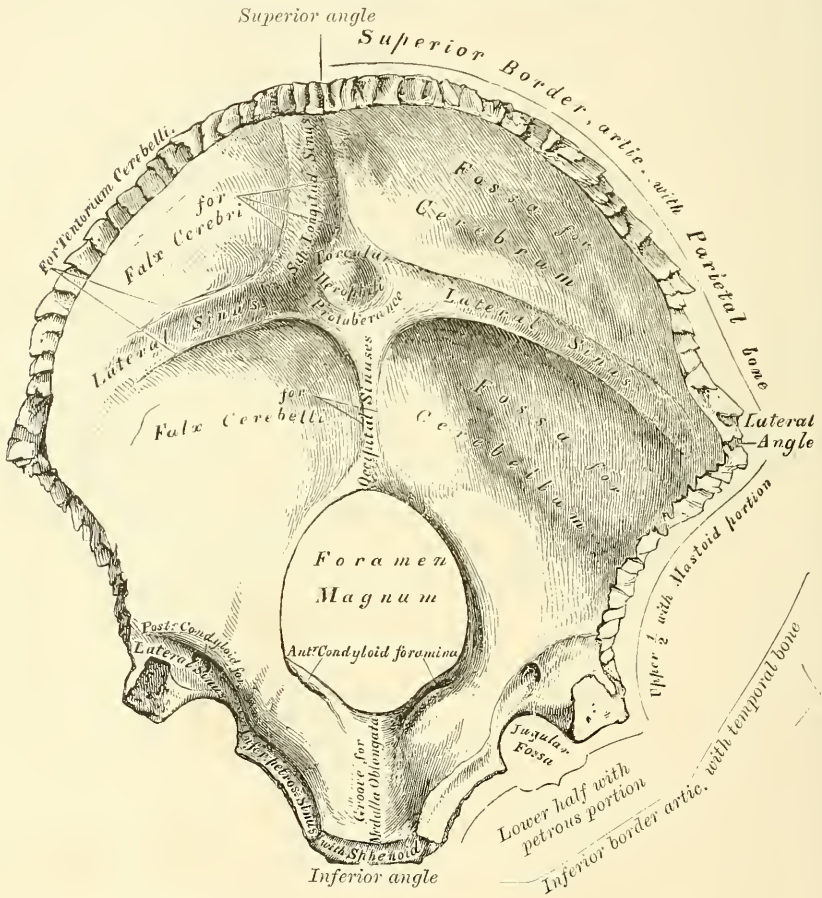
† Usually one of the transverse grooves is deeper and broader than the other; occasionally, both grooves are of equal depth and breadth, or both equally indistinct. The broader of the two transverse grooves is nearly always continuous with the vertical groove for the superior longitudinal sinus.

‡ The columns of blood coming in different directions were supposed to be *pressed* together at this point (*torcular*, a wine-press).



openings of the posterior condyloid foramina are a little external and posterior to them, protected by a small arch of bone. At this part of the internal surface there is a very deep groove, in which the posterior condyloid foramen, when it exists, has its termination. This groove is continuous, in the complete skull, with the transverse groove on the posterior part of the bone, and lodges the end of the same sinus, the lateral. In front of the foramen magnum is the basilar process, presenting a shallow depression, the *basilar groove*, which slopes from behind, upwards and forwards, and supports the medulla oblongata and part of the pons Varolii, and on each side of the basilar process is a narrow channel,

FIG. 136.—Occipital bone. Inner surface.



which, when united with a similar channel on the petrous portion of the temporal bone, forms a groove, which lodges the inferior petrosal sinus.

**Angles.**—The *superior angle* is received into the interval between the posterior superior angles of the two parietal bones: it corresponds with that part of the skull in the fœtus which is called the *posterior fontanelle*. The *inferior angle* is represented by the square-shaped surface of the basilar process. At an early period of life, a layer of cartilage separates this part of the bone from the sphenoid; but in the adult, the union between them is osseous. The *lateral angles* correspond to the outer ends of the transverse grooves, and are received into the interval between the posterior inferior angles of the parietal and the mastoid portion of the temporal.

**Borders.**—The *superior border* extends on each side from the superior to the lateral angle, is deeply serrated for articulation with the parietal bone, and forms,

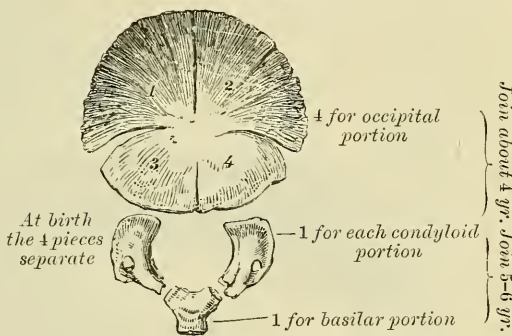


by this union, the lambdoid suture; the *inferior* border extends from the lateral to the inferior angle; its upper half is rough, and articulates with the mastoid portion of the temporal, forming the masto-occipital suture; the inferior half articulates with the petrous portion of the temporal, forming the petro-occipital suture; these two portions are separated from one another by the jugular process. In front of this process is a deep notch, which, with a similar one on the petrous portion of the temporal, forms the *foramen lacerum posterius* or *jugular foramen*. This notch is occasionally subdivided into two parts by a small process of bone, and it generally presents an aperture at its upper part, the internal opening of the posterior condyloid foramen.

**Structure.**—The occipital bone consists of two compact laminae, called the *outer* and *inner tables*, having between them the diploic tissue; this bone is especially thick at the ridges, protuberances, condyles, and anterior part of the basilar process; whilst at the bottom of the fossae, especially the inferior, it is thin, semi-transparent, and destitute of diploë.

**Development** (fig. 137).—At birth the bone consists of four distinct parts: a *tabular* or expanded portion, which lies behind the foramen magnum; two *condylar* parts which form the sides of the foramen; and a *basilar* part which lies in front of the foramen. The number of nuclei for the tabular part vary. As a rule there are four, but there may be only one (Blandin), or as many as eight (Meckel). They appear about the eighth week of foetal life, and soon unite to form a single piece; which is, however, fissured in the direction indicated in the plate. The basilar and two condyloid portions are each developed from a single nucleus, which appears a little later. The upper portion of the tabular surface, that is to say, the portion above the transverse fissures, is developed from membrane; the rest of the bone is developed from cartilage. At about the fourth year, the tabular and the two condyloid pieces join; and about the sixth year, the bone consists of a single piece. At a later period, between the eighteenth and twenty-fifth years, the occipital and sphenoid become united, forming a single bone.

FIG. 137.—Development of occipital bone.  
By seven centres.



**Articulations.**—With six bones: two parietal, two temporal, sphenoid, and atlas.

**Attachment of Muscles.**—To twelve pairs; to the superior curved line are attached the Occipito-frontalis, Trapezius, and Sterno-cleido-mastoid. To the space between the curved lines, the Complexus,\* Splenius capitis, and Obliquus capitis superior; to the inferior curved line, and the space between it and the foramen magnum, the Rectus capitis posticus, major and minor; to the transverse process, the Rectus capitis lateralis; and to the basilar process, the Rectus capitis anticus, major and minor, and Superior constrictor of the pharynx.

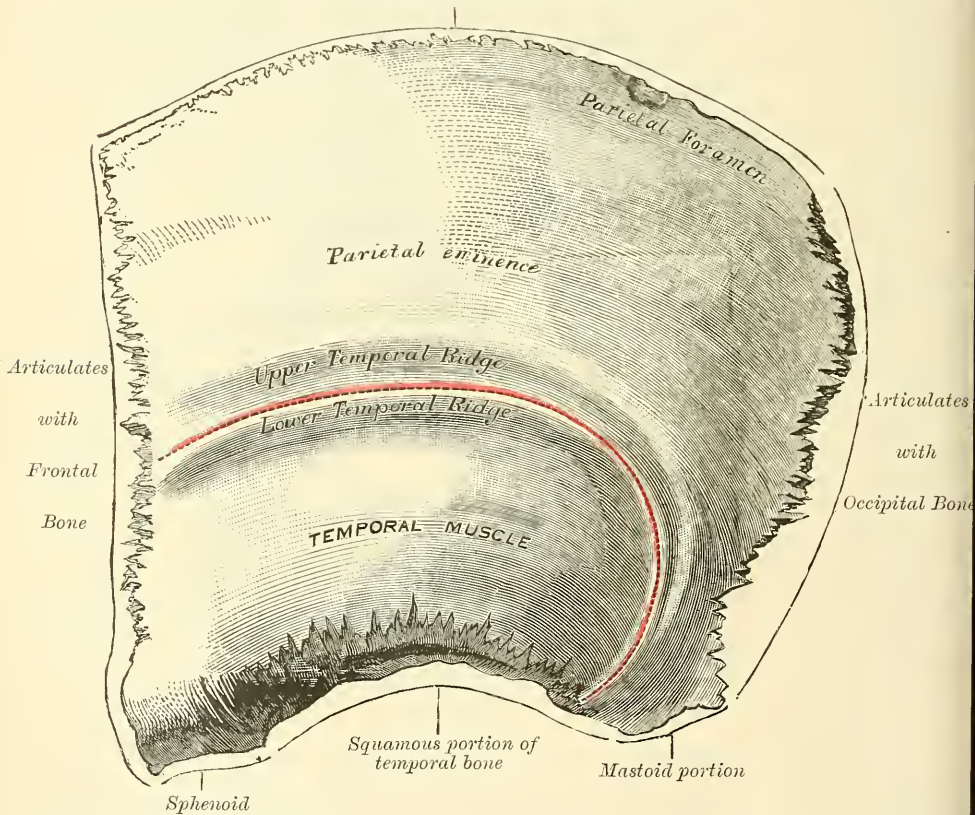
THE PARIETAL BONES

The **Parietal Bones** (*paries, a wall*) form, by their union, the sides and roof of the skull. Each bone is of an irregular quadrilateral form, and presents for examination two surfaces, four borders, and four angles.

\* To these the Biventer cervicis should be added, if it is regarded as a separate muscle.

**Surfaces.**—The *external surface* (fig. 138) is convex, smooth, and marked about its centre by an eminence, called the *parietal eminence*, which indicates the point where ossification commenced. Crossing the middle of the bone in an arched direction are two well-marked curved lines or ridges, of which the lower is the more distinct and is termed the *temporal ridge*; it marks the upper attachment of the temporal muscle, and follows a semicircular course across the bone. The upper ridge is less marked, and pursues a similar course across the bone, but about two-fifths of an inch above the temporal ridge; it marks the attachment of the temporal fascia. Above these ridges, the surface of the bone is rough and porous, and covered by the aponeurosis of the Occipito-frontalis; between them the bone is smoother and more polished than the rest; below them the bone forms part of the temporal fossa, and affords attachment to the Temporal muscle. At the back part of the superior border, close to the sagittal suture, is a small

FIG. 138.—Left parietal bone. External surface.  
*Articulates with opposite parietal bone*



foramen, the *parietal foramen*, which transmits a vein to the superior longitudinal sinus, and sometimes a small branch of the occipital artery. Its existence is not constant, and its size varies considerably.

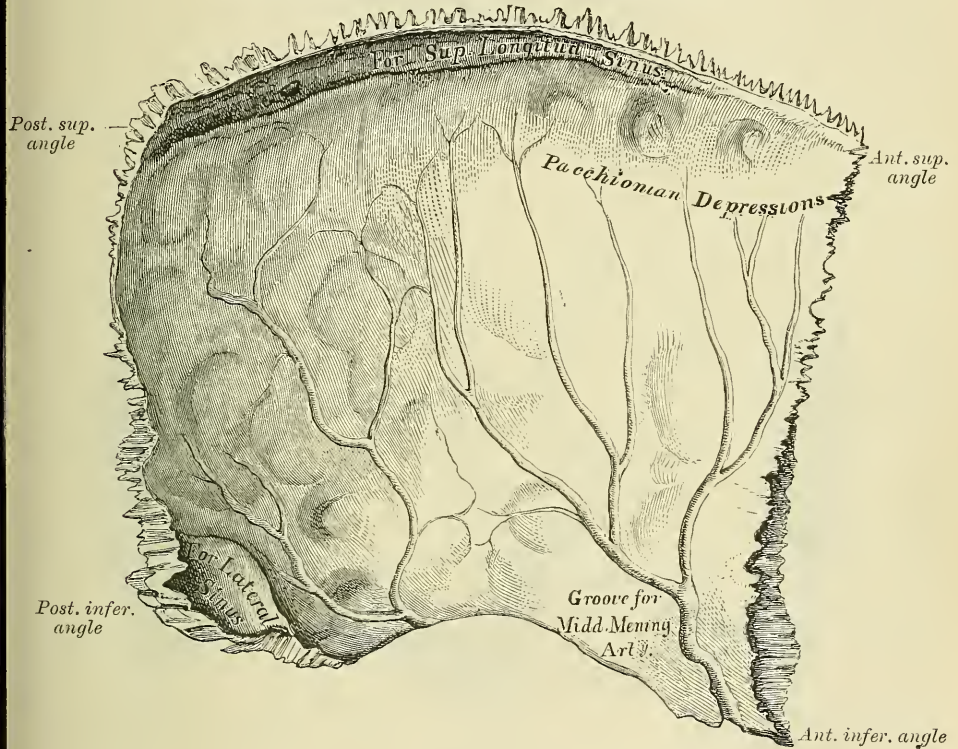
The **internal surface** (fig. 139), concave, presents eminences and depressions for lodging the convolutions of the cerebrum, and numerous furrows for the ramifications of the meningeal arteries; the latter run upwards and backwards from the anterior inferior angle, and from the central and posterior part of the lower border of the bone. Along the upper margin is part of a shallow groove, which, when joined to the opposite parietal, forms a channel for the superior longitudinal sinus, the elevated edges of which afford attachment to the falx cerebri. Near the groove are seen several depressions, especially in the skulls



of old persons ; they lodge the Pacchionian bodies. The internal opening of the parietal foramen is also seen when that aperture exists.

**Borders.**—The *superior*, the longest and thickest, is dented to articulate with its fellow of the opposite side, forming the sagittal suture. The *inferior* is divided into three parts : of these, the anterior is thin and pointed, bevelled at the expense of the outer surface, and overlapped by the tip of the great wing of the sphenoid ; the middle portion is arched, bevelled at the expense of the outer surface, and overlapped by the squamous portion of the temporal ; the posterior portion is thick and serrated for articulation with the mastoid portion of the temporal. The *anterior border*, deeply serrated, is bevelled at the expense of the outer surface above and of the inner below ; it articulates with the frontal bone, forming the *coronal suture*. The *posterior border*, deeply denticulated, articulates with the occipital, forming the *lambdoid suture*.

FIG. 139.—Left parietal bone. Internal surface.



**Angles.**—The *anterior superior angle*, thin and pointed, corresponds with that portion of the skull which in the fœtus is membranous, and is called the *anterior fontanelle*. The *anterior inferior angle* is thin and lengthened, being received in the interval between the great wing of the sphenoid and the frontal. Its inner surface is marked by a deep groove, sometimes a canal, for the anterior branch of the middle meningeal artery. The *posterior superior angle* corresponds with the junction of the sagittal and lambdoid sutures. In the fœtus this part of the skull is membranous, and is called the *posterior fontanelle*. The *posterior inferior angle* articulates with the mastoid portion of the temporal bone, and generally presents on its inner surface a broad, shallow groove for lodging part of the lateral sinus.

**Development.**—The parietal bone is formed in membrane, being developed by one centre, which corresponds with the parietal eminence, and makes its first appearance about the seventh or eighth week of fetal life. Ossification gradually



extends from the centre to the circumference of the bone: the angles are consequently the parts last formed, and it is in their situation that the fontanelles exist previous to the completion of the growth of the bone.

**Articulations.**—With five bones: the opposite parietal, the occipital, frontal, temporal, and sphenoid.

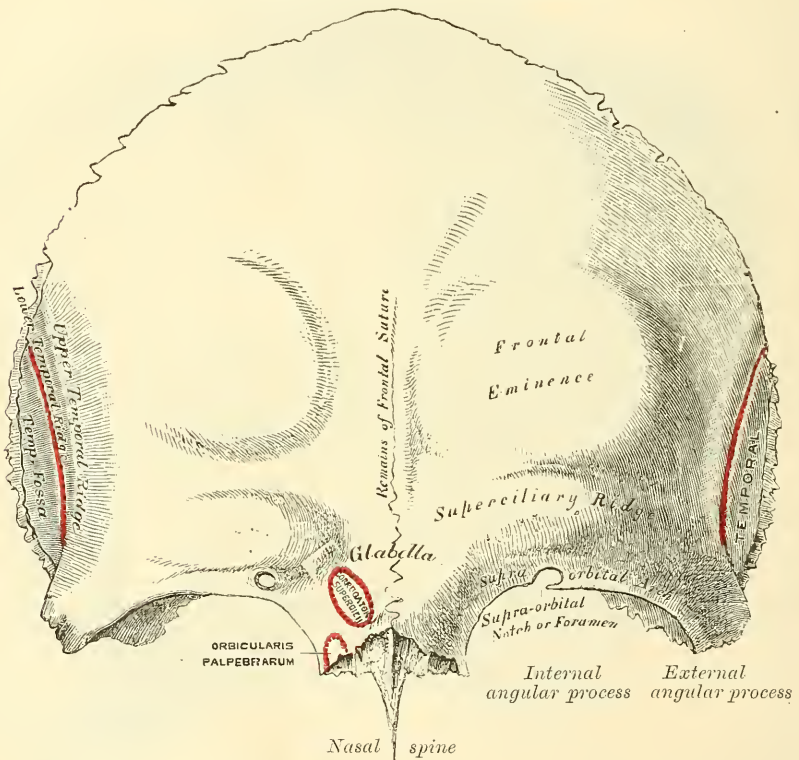
**Attachment of Muscles.**—One only, the Temporal.

### THE FRONTAL BONE

The **Frontal Bone** (frons, *the forehead*) resembles a cockle-shell in form, and consists of two portions—a *vertical* or *frontal* portion situated at the anterior part of the cranium, forming the forehead; and a *horizontal* or *orbito-nasal* portion which enters into the formation of the roof of the orbits and nasal fossæ.

**Vertical Portion.**—*External Surface* (fig. 140).—In the median line, traversing

FIG. 140.—Frontal bone. Outer surface.



the bone from the upper to the lower part, is occasionally seen a slightly elevated ridge, and in young subjects a suture, which represents the line of union of the two lateral halves of which the bone consists at an early period of life: in the adult this suture is usually obliterated, and the bone forms one piece; traces of the obliterated suture are, however, generally perceptible at the lower part. On either side of this ridge, a little below the centre of the bone, is a rounded eminence, the *frontal eminence*. These eminences vary in size in different individuals, and are occasionally unsymmetrical in the same subject. They are especially prominent in cases of well-marked cerebral development. The whole surface of the bone above this part is smooth, and covered by the aponeurosis of the Occipito-frontalis muscle. Below the frontal eminence, and separated from it by a slight groove, is the *superciliary ridge*, broad internally, where it is continuous with the nasal eminence, but less distinct as it arches outwards. These

ridges are caused by the projection outwards of the frontal sinuses,\* and give attachment to the *Orbicularis palpebrarum* and *Corrugator supercilii*. Between the two superciliary ridges is a smooth surface, the *glabella* or *nasal eminence*. Beneath the superciliary ridge is the *supra-orbital arch*, a curved and prominent margin, which forms the upper boundary of the orbit, and separates the vertical from the horizontal portion of the bone. The outer part of the arch is sharp and prominent, affording to the eye, in that situation, considerable protection from injury; the inner part is less prominent. At the junction of the internal and middle third of this arch is a notch, sometimes converted into a foramen by a bony process, and called the *supra-orbital notch* or *foramen*. It transmits the supra-orbital artery, vein, and nerve. A small aperture is seen in the upper part of the notch, which transmits a vein from the diploë to join the supra-orbital vein. The supra-orbital arch terminates externally in the *external angular process*, and internally in the *internal angular process*. The external angular process is strong, prominent, and articulates with the malar bone; running upwards and backwards from it are two well-marked lines, which, commencing together from the external angular process, soon diverge from each other and run in a curved direction across the bone. The lower one, the *temporal ridge*, gives attachment to the Temporal muscle, the upper one to the temporal fascia. Beneath them is a slight concavity, that forms the anterior part of the temporal fossa, and gives origin to the Temporal muscle. The internal angular processes are less marked than the external, and articulate with the lachrymal bones. Between the internal angular processes is a rough, uneven interval, the *nasal notch*, which articulates in the middle line with the nasal bone, and on either side with the nasal process of the superior maxillary bone. From the concavity of this notch projects a process, the *nasal process*, which extends beneath the nasal bones and nasal processes of the superior maxillary bones, and supports the bridge of the nose. On the under surface of this is a long pointed process, the *nasal spine*, and on either side a small grooved surface enters into the formation of the roof of the nasal fossa. The nasal spine forms part of the septum of the nose, articulating in front with the nasal bones and behind with the perpendicular plate of the ethmoid.

**Internal Surface** (fig. 141).—Along the middle line is a vertical groove, the edges of which unite below to form a ridge, the *frontal crest*; the groove lodges the superior longitudinal sinus, whilst its margins afford attachment to the *falx cerebri*. The crest terminates below at a small notch which is converted into a foramen by articulation with the ethmoid. It is called the *foramen cæcum*, and varies in size in different subjects; it is sometimes partially or completely impervious, lodges a process of the *falx cerebri*, and, when open, transmits a vein from the lining membrane of the nose to the superior longitudinal sinus. On either side of the groove the bone is deeply concave, presenting eminences and depressions for the convolutions of the brain, and numerous small furrows for lodging the ramifications of the anterior meningeal arteries. Several small, irregular fossæ are also seen on either side of the groove, for the reception of the Pacchionian bodies.

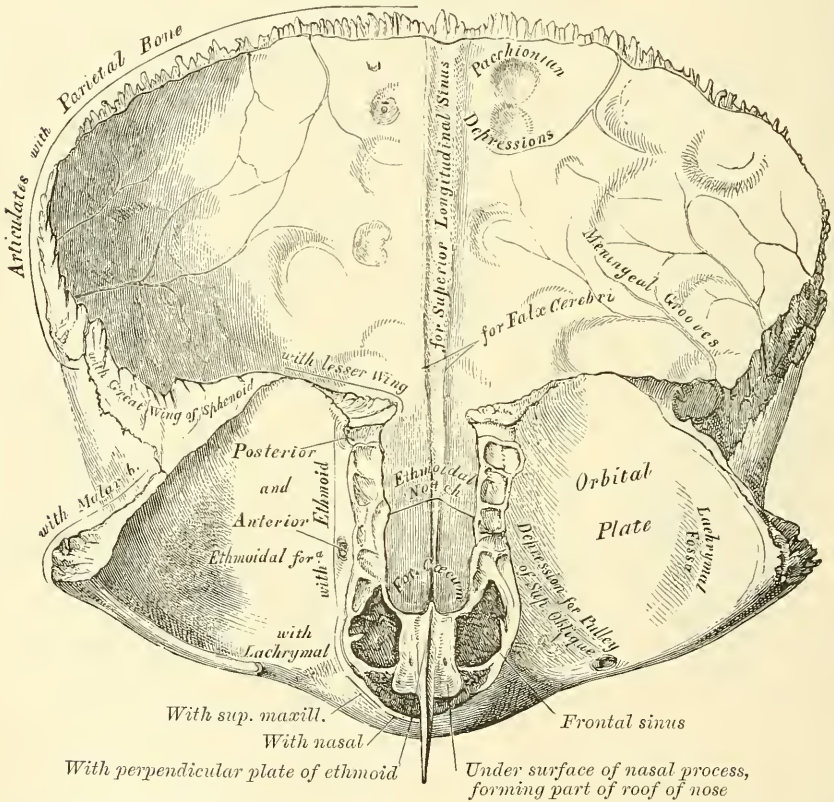
**Horizontal Portion.**—*External Surface.*—This portion of the bone consists of two thin plates, the *orbital plates*, which form the vault of the orbit, separated from one another by a median gap, the *ethmoidal notch*. Each orbital plate consists of a smooth, concave, triangular lamina of bone, marked at its anterior and

\* Some confusion is occasioned to students commencing the study of anatomy by the name 'sinuses' having been given to two perfectly different kinds of spaces connected with the skull. It may be as well, therefore, to state here, at the outset, that the 'sinuses' in the interior of the cranium which produce the grooves on the inner surface of the bones are venous channels along which the blood runs in its passage back from the brain, while the 'sinuses' external to the cranial cavity (the frontal, sphenoidal, ethmoidal, and maxillary) are hollow spaces in the bones themselves which communicate with the nostrils, and contain air.



external part (immediately beneath the external angular process) by a shallow depression, the *lachrymal fossa*, for lodging the lachrymal gland; and at its anterior and internal part, by a depression (sometimes a small tubercle), the *trochlear fossa*, for the attachment of the cartilaginous pulley of the Superior oblique muscle of the eye. The ethmoidal notch separates the two orbital plates; it is quadrilateral, and filled up, when the bones are united, by the cribriform plate of the ethmoid. The margins of this notch present several half-cells, which, when united with corresponding half-cells on the upper surface of the ethmoid, complete the ethmoidal cells; two grooves are also seen crossing these edges transversely; they are converted into canals by articulation with the ethmoid, and are called the *anterior* and *posterior ethmoidal* canals: they open on the inner wall of the orbit. The anterior one transmits the nasal nerve and anterior ethmoidal vessels, the posterior one the posterior ethmoidal vessels. In

FIG. 141.—Frontal bone. Inner surface.



front of the ethmoidal notch, on either side of the nasal spine, are the openings of the frontal sinuses. These are two irregular cavities, which extend upwards and outwards, a variable distance, between the two tables of the skull, and are separated from one another by a thin, bony septum. They give rise to the prominences above the supra-orbital arches called the *superciliary ridges*. In the child they are generally absent, and they become gradually developed as age advances. These cavities vary in size in different persons, are larger in men than in women, and are frequently of unequal size on the two sides, the right being commonly the larger. They are subdivided by a bony lamina, which is often displaced to one side. They are lined by mucous membrane, and communicate with the nose by the infundibulum, and occasionally with each other by apertures in their septum.

The **internal surface of the horizontal portion** presents the convex upper



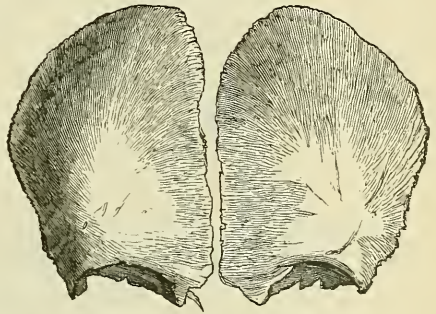
surfaces of the orbital plates, separated from each other in the middle line by the ethmoidal notch, and marked by eminences and depressions for the convolutions of the frontal lobes of the brain.

**Borders.**—The border of the vertical portion is thick, strongly serrated, bevelled at the expense of the internal table above, where it rests upon the parietal bones, and at the expense of the external table at each side, where it receives the lateral pressure of those bones; this border is continued below into a triangular, rough surface, which articulates with the great wing of the sphenoid. The border of the horizontal portion is thin, serrated, and articulates with the lesser wing of the sphenoid.

**Structure.**—The vertical portion and external angular processes are very thick, consisting of diploic tissue contained between two compact laminae. The horizontal portion is thin, translucent, and composed entirely of compact tissue; hence the facility with which instruments can penetrate the cranium through this part of the orbit.

**Development** (fig. 142).—The frontal bone is formed in membrane, being developed by *two* centres, one for each lateral half, which make their appearance about the seventh or eighth week, above the orbital arches. From this point ossification extends, in a radiating manner, upwards into the forehead, and backwards over the orbit. At birth the bone consists of two pieces, which afterwards become united, along the middle line, by a suture which runs from the vertex to the root of the nose. This suture usually becomes obliterated within a few years after birth; but it occasionally remains throughout life. Occasionally secondary centres of ossification appear for the nasal spine; one on either side at the internal angular process where it articulates with the lachrymal bone; and sometimes there is one on either side at the lower end of the coronal suture. This latter centre sometimes remains ununited, and is known as the pterion ossicle; or it may join with the parietal, sphenoid, or temporal bone.

FIG. 142.—Frontal bone at birth.  
Developed by two lateral halves.



**Articulations.**—With twelve bones: two parietal, the sphenoid, the ethmoid, two nasal, two superior maxillary, two lachrymal, and two malar.

**Attachment of Muscles.**—To three pairs: the *Corrugator supercilii*, *Orbicularis palpebrarum*, and *Temporal* on each side.

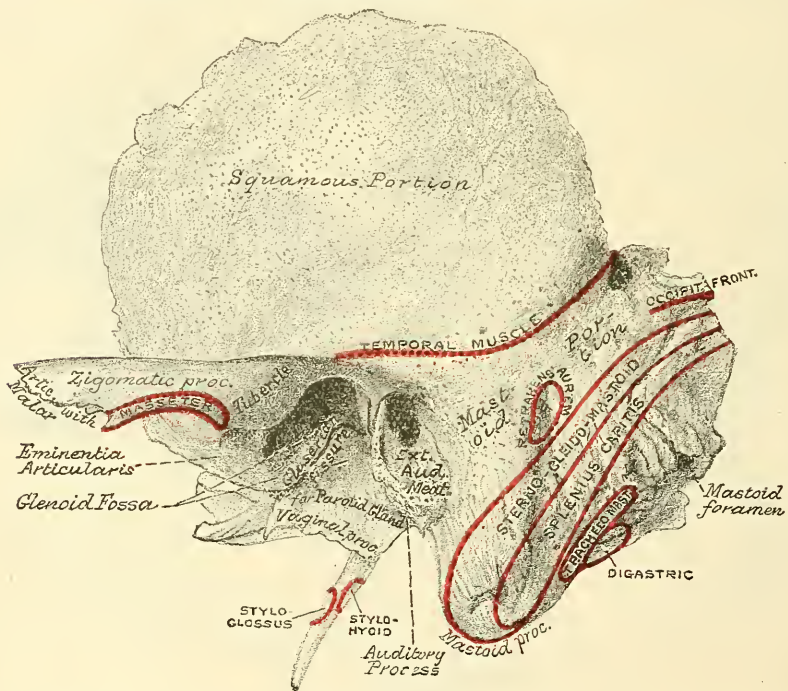
### THE TEMPORAL BONES

The **Temporal Bones** (*tempus, time*) are situated at the sides and base of the skull, and present for examination a *squamous*, *mastoid*, and *petrous* portion.

The **squamous portion** (*squama, a scale*), the anterior and upper part of the bone, is scale-like in form, and thin and translucent in texture (fig. 143). Its *outer surface* is smooth, convex, and grooved at its back part for the deep temporal arteries; it affords attachment to the Temporal muscle, and forms part of the temporal fossa. At its back part may be seen a curved ridge—part of the *temporal ridge*; it serves for the attachment of the temporal fascia, limits the origin of the Temporal muscle, and marks the boundary between the squamous and mastoid portions of the bone. Projecting from the lower part of the squamous portion is a long, arched process of bone, the *zygoma* or zygomatic process. This process is at first directed outwards, its two surfaces looking upwards and downwards; it then appears as if twisted upon itself, and runs forwards, its surfaces now looking inwards and outwards. The superior border

of the process is long, thin, and sharp, and serves for the attachment of the temporal fascia. The inferior, short, thick, and arched, has attached to it some fibres of the Masseter muscle. Its outer surface is convex and subcutaneous; its inner is concave, and also affords attachment to the Masseter. The extremity, broad and deeply serrated, articulates with the malar bone. The zygomatic process is connected to the temporal bone by three divisions, called its *roots*—an anterior, middle, and posterior. The anterior, which is short, but broad and strong, is directed inwards, to terminate in a rounded eminence, the *eminentia articularis*. This eminence forms the front boundary of the glenoid fossa, and in the recent state is covered with cartilage. The middle root forms the outer margin of the glenoid fossa; running obliquely inwards, it terminates at the commencement of a well-marked fissure, the *Glaserian fissure*; whilst the posterior root, which is strongly marked, runs from the upper border of the zygoma, backwards over the external auditory meatus. It is termed the *supra-*

FIG. 143.—Left temporal bone. Outer surface.



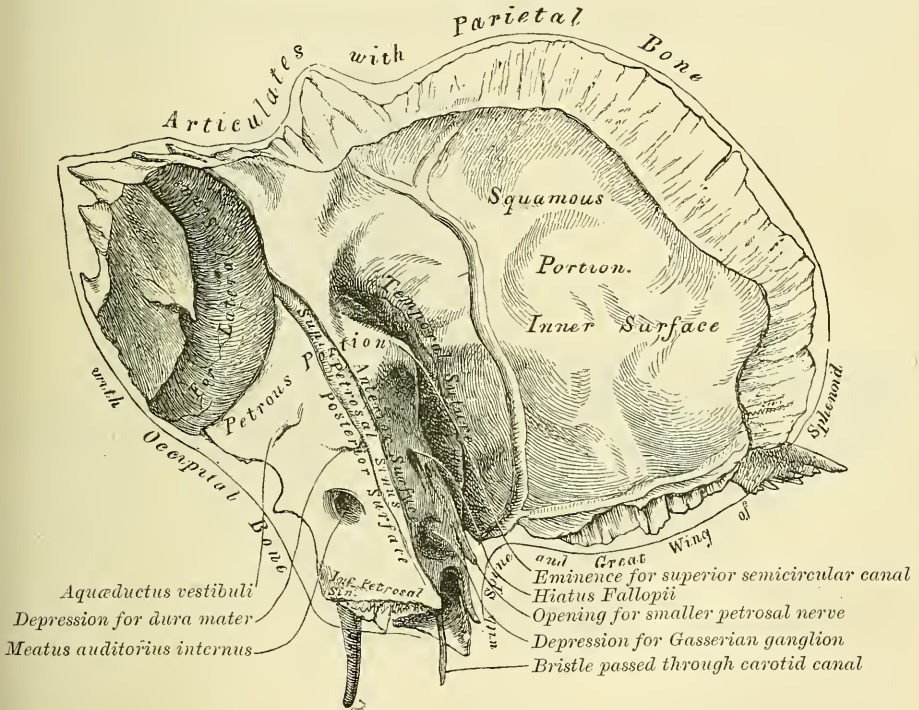
*mastoid crest*, and separates the squamous from the mastoid portion of the bone. At its posterior extremity it becomes continuous with the temporal ridge. At the junction of the anterior root with the zygoma is a projection, called the *tubercle*, for the attachment of the external lateral ligament of the lower jaw; and between the anterior and middle roots is an oval depression, forming part of the glenoid fossa (*γλήνη*, a *socket*), for the reception of the condyle of the lower jaw. This fossa is bounded, in front, by the eminentia articularis; behind, by the tympanic plate; and, externally, by the middle root of the zygoma; and is divided into two parts by a narrow slit, the *Glaserian fissure*. The anterior part, formed by the squamous portion of the bone, is smooth, covered in the recent state with cartilage, and articulates with the condyle of the lower jaw. This part of the glenoid fossa presents posteriorly a small conical eminence, situated at the extremity of the middle root and in front of the external auditory meatus; it is known as the *post-glenoid process*, and is the representative of a prominent tubercle which, in some of the mammalia, descends behind the condyle of the jaw, and prevents it being displaced backwards during mastication



(Humphry). The posterior part of the glenoid fossa, which lodges a portion of the parotid gland, is formed chiefly by a lamina of bone, the *tympanic plate*, which forms the anterior wall of the tympanum and external auditory meatus. This plate of bone terminates above in the Glaserian fissure, and below forms a sharp edge, the *vaginal process*, which gives origin to some of the fibres of the Tensor palati muscle. The Glaserian fissure, which leads into the tympanum, lodges the processus gracilis of the malleus, and transmits the tympanic branch of the internal maxillary artery. The chorda tympani nerve passes through a separate canal, parallel to the Glaserian fissure (*canal of Huguier*), on the outer side of the Eustachian tube, in the retiring angle between the squamous and petrous portions of the temporal bone.\*

The **internal surface** of the squamous portion (fig. 144) is concave, presents numerous eminences and depressions for the convolutions of the cerebrum, and two well-marked grooves for the branches of the middle meningeal artery.

FIG. 144.—Left temporal bone. Inner surface.



**Borders.**—The superior border is thin, bevelled at the expense of the internal surface, so as to overlap the lower border of the parietal bone, forming the squamous suture. The anterior inferior border is thick, serrated, and bevelled, alternately at the expense of the inner and outer surfaces, for articulation with the great wing of the sphenoid.

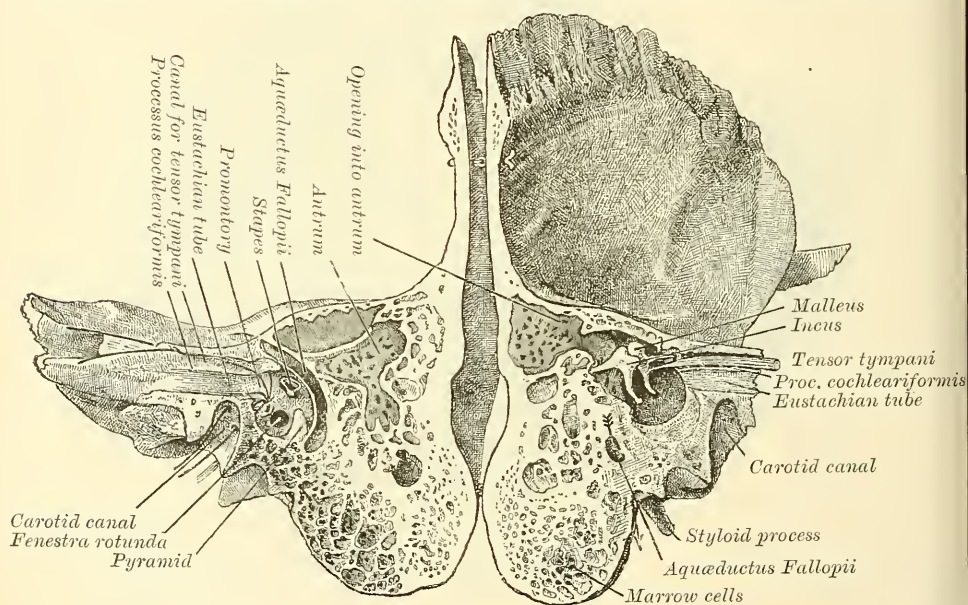
The **Mastoid Portion** (*μαστός*, a nipple or teat) is situated at the posterior part of the bone; its outer surface is rough, and gives attachment to the Occipito-frontalis and Retrahens aurem muscles. It is perforated by numerous foramina; one of these, of large size, situated at the posterior border of the bone, is termed the *mastoid foramen*; it transmits a vein to the lateral sinus and a small artery from the occipital, to supply the dura mater. The position and size of this foramen are very variable. It is not always present; sometimes it is situated in

\* This small fissure must not be confounded with the large canal which lies above the Eustachian tube and transmits the Tensor tympani muscle.



the occipital bone, or in the suture between the temporal and the occipital. The mastoid portion is continued below into a conical projection, the *mastoid process*, the size and form of which vary somewhat. This process serves for the attachment of the Sterno-mastoid, Splenius capitis, and Trachelo-mastoid muscles. On the inner side of the mastoid process is a deep groove, the *digastric fossa*, for the attachment of the Digastric muscle; and, running parallel with it, but more internal, the *occipital groove*, which lodges the occipital artery. The internal surface of the mastoid portion presents a deep, curved groove, the *fossa sigmoidea*, which lodges part of the lateral sinus; and into it may be seen opening the mastoid foramen. A section of the mastoid process shows it to be hollowed out into a number of cellular spaces, communicating with each other, called the *mastoid cells*. These cells, at the upper and front part of the bone, are large and irregular and contain air, but towards the lower part of the bone they diminish in size, whilst those at the apex of the mastoid process are quite small and usually contain marrow. In addition to these may be seen a large

FIG. 145.—Section through the petrous and mastoid portions of the temporal bone, showing the communication of the cavity of the tympanum with the mastoid antrum.



irregular cavity (fig. 145) situated at the upper and front part of the section. It is called the *mastoid antrum* and must be distinguished from the mastoid cells, though it communicates with them. It is filled with air and is lined by a prolongation of the mucous membrane of the tympanum, which extends into it through an opening, by which it communicates with the cavity of the tympanum. The mastoid antrum is bounded above by a thin plate of bone, which separates it from the middle fossa of the base of the skull on the anterior surface of the petrous portion of the temporal bone; below by the mastoid process; externally by the squamous portion of the bone just below the supra-mastoid crest, and internally by the external semicircular canal of the internal ear which projects into its cavity. The opening by which it communicates with the tympanum is situated at the superior internal angle of the posterior wall of that cavity, and opens into that portion of the tympanic cavity which is known as the *attic*, that is to say, that portion of the tympanum which is above the level of the superior margin of the external auditory meatus.

The mastoid cells, like the other sinuses of the cranium, are not developed

until after puberty; hence the prominence of this process in the adult. But the mastoid antrum is of large size at birth; as however the bone increases in thickness the cavity becomes relatively smaller.

In consequence of the communication which exists between the tympanum and mastoid antrum, inflammation of the lining membrane of the former cavity may easily travel backwards to that of the antrum, leading to caries and necrosis of its walls and the risk of transference of the inflammation to the lateral sinus or encephalon.

**Borders.**—The superior border of the mastoid portion is broad and rough, its serrated edge sloping outwards, for articulation with the posterior inferior angle of the parietal bone. The posterior border, also uneven and serrated, articulates with the inferior border of the occipital bone between its lateral angle and jugular process.

The **Petrous Portion** (*πέτρος, a stone*), so named from its extreme density and hardness, is a pyramidal process of bone, wedged in at the base of the skull between the sphenoid and occipital bones. Its direction from without is inwards, forwards, and a little downwards. It presents for examination a base, an apex, three surfaces, and three borders; and contains, in its interior, the essential parts of the organ of hearing. The *base* is applied against the internal surface of the squamous and mastoid portions, its upper half being concealed; but its lower half is exposed by the divergence of these two portions of the bone, which brings into view the oval expanded orifice of a canal leading into the tympanum, the *meatus auditorius externus*. This canal is situated in front of the mastoid process, and between the posterior and middle roots of the zygoma; its upper margin is smooth and rounded, but the greater part of its circumference is surrounded by a curved plate of bone, the *tympanic plate*, the free margin of which is thick and rough, for the attachment of the cartilage of the external ear.

The **apex** of the petrous portion, rough and uneven, is received into the angular interval between the posterior border of the greater wing of the sphenoid and the basilar process of the occipital; it presents the anterior or internal orifice of the carotid canal, and forms the posterior and external boundary of the foramen lacerum medium.

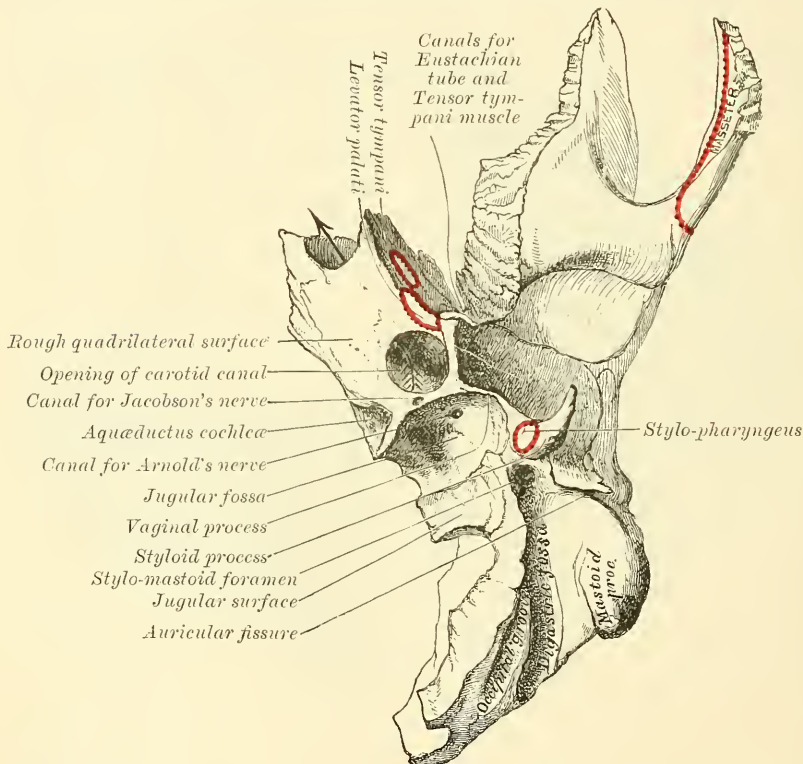
The **anterior surface** of the petrous portion (fig. 144) forms the posterior part of the middle fossa of the skull. This surface is continuous with the squamous portion, to which it is united by a suture, the *temporal or petro-squamous suture*, the remains of which are distinct even at a late period of life; it presents six points for examination: 1. an eminence near the centre, which indicates the situation of the superior semicircular canal: 2. in front and a little to the outer side of this eminence a depression, indicating the position of the tympanum; here the layer of bone which separates the tympanum from the cranial cavity is extremely thin, and is known as the *tegmen tympani*: 3. a shallow groove, sometimes double, leading outwards and backwards to an oblique opening, the *hiatus Fallopii*, for the passage of the petrosal branch of the Vidian nerve and the petrosal branch of the middle meningeal artery: 4. a smaller opening, occasionally seen external to the latter, for the passage of the smaller petrosal nerve: 5. near the apex of the bone, the termination of the carotid canal, the wall of which in this situation is deficient in front: 6. above this canal a shallow depression for the reception of the Gasserian ganglion.

The **posterior surface** forms the front part of the posterior fossa of the skull, and is continuous with the inner surface of the mastoid portion of the bone. It presents three points for examination: 1. about its centre, a large orifice, the *meatus auditorius internus*, the size of which varies considerably; its margins are smooth and rounded; and it leads into a short canal, about four lines in length, which runs directly outwards, and is closed by a vertical plate, the *lamina cribrosa*, which is divided by a horizontal crest, the *crista falciformis*, into two unequal portions; the *lower* presenting three foramina, or sets of foramina; one, just below the posterior part of the crest, consisting of a number of small openings



for the nerves to the sacculæ; a second, below and posterior to this, for the nerve to the posterior semicircular canal; and a third, in front and below the first, consisting of a number of small openings which terminate in the *canalis centralis cochleæ* and transmit the nerve to the cochlea; the *upper* portion, that above the *crista*, presents behind a series of small openings for the passage of filaments to the vestibule and superior and external semicircular canals, and, in front, one large opening, the commencement of the *aquæductus Fallopii*, for the passage of the facial nerve: 2. behind the *meatus auditorius*, a small slit almost hidden by a thin plate of bone, leading to a canal, the *aquæductus vestibuli*, which transmits a small artery and vein, and lodges a process of the *dura mater*: 3. in the interval between these two openings, but above them, an angular depression which lodges a process of the *dura mater*, and transmits a small vein into the cancellous tissue of the bone.

FIG. 146.—Petrous portion. Inferior surface.



The *inferior* or *basilar* surface (fig. 146) is rough and irregular, and forms part of the base of the skull. Passing from the apex to the base, this surface presents eleven points for examination: 1. a rough surface, quadrilateral in form, which serves partly for the attachment of the *Levator palati* and *Tensor tympani* muscles: 2. the large, circular aperture of the *carotid canal*, which ascends at first vertically, and then, making a bend, runs horizontally forwards and inwards; it transmits the *internal carotid artery*, and the *carotid plexus*: 3. the *aquæductus cochleæ*, a small, triangular opening, lying on the inner side of the latter, close to the posterior border of the petrous portion; it transmits a vein from the cochlea, which joins the *internal jugular*: 4. behind these openings a deep depression, the *jugular fossa*, which varies in depth and size in different skulls; it lodges the *lateral sinus*, and, with a similar depression on the margin of the *jugular process* of the *occipital bone*, forms the *foramen lacerum posterius*, or *jugular foramen*: 5. a small foramen for the passage of *Jacobson's nerve* (the *tympanic branch* of



the glosso-pharyngeal); this foramen is seen in the bony ridge dividing the carotid canal from the jugular fossa: 6. a small foramen on the wall of the jugular fossa, for the entrance of the auricular branch of the pneumogastric (Arnold's nerve): 7. behind the jugular fossa, a smooth, square-shaped facet, the *jugular surface*; it is covered with cartilage in the recent state, and articulates with the jugular process of the occipital bone: 8. the *vaginal process*, a very broad, sheath-like plate of bone, which extends backwards from the carotid canal and gives attachment to part of the Tensor palati muscle; this plate divides behind into two laminae, the outer of which is continuous with the auditory process, the inner with the jugular process: between these laminae is the 9th point for examination, the *styloid process*; a long, sharp spine, about an inch in length; it is directed downwards, forwards, and inwards, varies in size and shape, and sometimes consists of several pieces united by cartilage; it affords attachment to three muscles, the Stylo-pharyngeus, Stylo-hyoideus, and Stylo-glossus; and two ligaments, the stylo-hyoid and stylo-maxillary: 10. the *stylo-mastoid foramen*, a rather large orifice, placed between the styloid and mastoid processes; it is the termination of the aquæductus Fallopii, and transmits the facial nerve and stylo-mastoid artery: 11. the *auricular fissure*, situated between the tympanic plate and mastoid processes, for the exit of the auricular branch of the pneumogastric nerve.

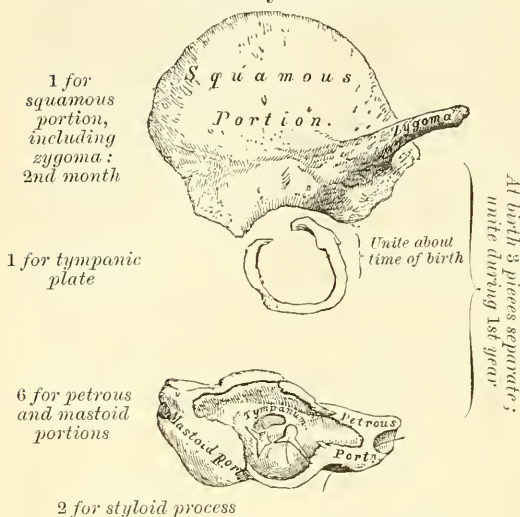
**Borders.**—The *superior*, the longest, is grooved for the superior petrosal sinus, and has attached to it the tentorium cerebelli; at its inner extremity is a semilunar notch, upon which the fifth nerve lies. The *posterior* border is intermediate in length between the superior and the anterior. Its inner half is marked by a groove, which, when completed by its articulation with the occipital, forms the channel for the inferior petrosal sinus. Its outer half presents a deep excavation—the *jugular fossa*—which, with a similar notch on the occipital, forms the foramen lacerum posterius. A projecting eminence of bone occasionally stands out from the centre of the notch, and divides the foramen into two parts. The *anterior* border is divided into two parts—an outer joined to the squamous portion by a suture, the remains of which are distinct; an inner, free, articulating with the spinous process of the sphenoid. At the angle of junction of the petrous and squamous portions are seen two canals, separated from one another by a thin plate of bone, the *processus cochleariformis*; they both lead into the tympanum, the upper one transmitting the Tensor tympani muscle, the lower one the Eustachian tube.

**Structure.**—The squamous portion is like that of the other cranial bones: the mastoid portion cellular, and the petrous portion dense and hard.

**Development** (fig. 147).—The temporal bone is developed by *ten* centres, exclusive of those for the internal ear and the ossicula—viz. one for the squamous portion including the zygoma, one for the tympanic plate, six for the petrous and mastoid parts, and two for the styloid process. Just before the close of fœtal life the temporal bone consists of four parts: 1. The *squamo-zygomatic*, which is ossified in membrane from a single nucleus, which appears at its lower part about the second month. 2. The *tympanic plate*, an imperfect ring, which encloses the tympanic membrane. This is also ossified from a single centre which appears rather later than that for the squamous portion. 3. The *petro-mastoid*, which is developed from six centres, which appear about the fifth or sixth month. Four of these are for the petrous portion, and are placed around the labyrinth, and two for the mastoid (Vrolik). According to Huxley, the centres are more numerous, and are disposed so as to form three portions: (1) including most of the labyrinth with a part of the petrous and mastoid, he has named *prootic*; (2) the rest of the petrous, the *opisthotic*; and (3) the remainder of the mastoid, the *epiotic*. The petro-mastoid is ossified in cartilage. 4. The *styloid process* is also ossified in cartilage from two centres: one for the base, which appears before birth, and is termed the *tympano-hyal*; the other, comprising the rest of the process, is named the *stylo-hyal*, and does not appear until after birth. Shortly before birth the

tympenic plate joins with the squamous. The petrous and mastoid join with the squamous during the first year, and the tympano-hyal portion of the styloid process about the same time. The stylo-hyal does not join the rest of the bone until after puberty, and in some skulls never becomes united. The subsequent changes in this bone are, that the tympanic plate extends outwards, so as to form the meatus auditorius; the glenoid fossa becomes deeper; and the mastoid part, which at an early period of life is quite flat, enlarges from the development of the cellular cavities in its interior.

FIG. 147.—Development of the temporal bone. By ten centres.



mastoid, Splenius capitis, Trachelo-mastoid, Digastricus, and Retrahens aurem; to the styloid process, the Stylo-pharyngeus, Stylo-hyoideus, and Stylo-glossus; and to the petrous portion, the Levator palati, Tensor tympani, Tensor palati, and Stapedius.

#### THE SPHENOID BONE

The **Sphenoid Bone** (*σφήν*, a wedge) is situated at the anterior part of the base of the skull, articulating with all the other cranial bones, which it binds firmly and solidly together. In its form it somewhat resembles a bat with its wings extended; and is divided into a central portion or body, two greater and two lesser wings extending outwards on each side of the body, and two processes—the pterygoid processes—which project from it below.

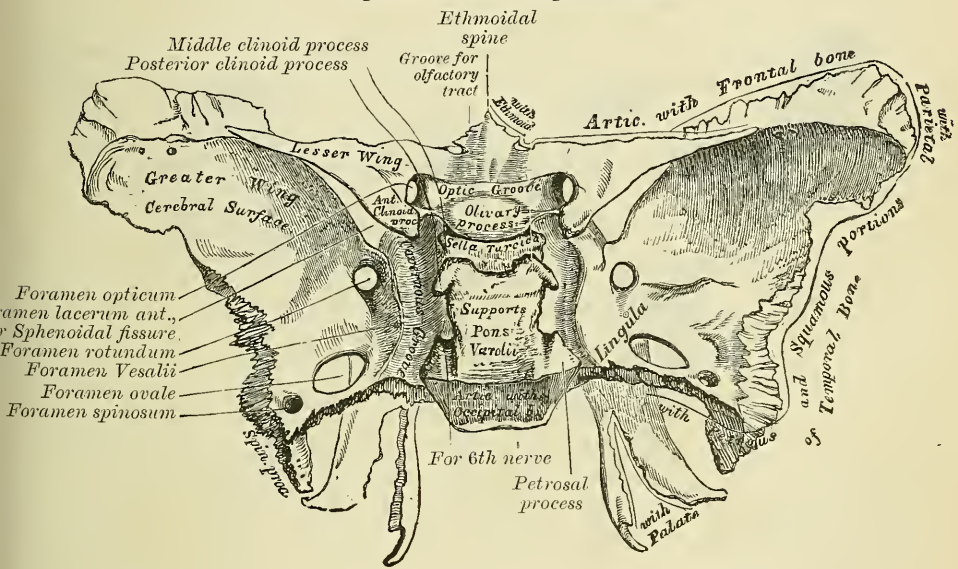
The **body** is of large size, cuboid in form, and hollowed out in its interior so as to form a mere shell of bone. It presents for examination *four* surfaces—a superior, an inferior, an anterior, and a posterior.

**The Superior Surface** (fig. 148).—In front is seen a prominent spine, the *ethmoidal spine*, for articulation with the cribriform plate of the ethmoid; behind this a smooth surface presenting, in the median line, a slight longitudinal eminence, with a depression on each side, for lodging the olfactory tracts. This surface is bounded behind by a ridge, which forms the anterior border of a narrow, transverse groove, the *optic groove*; it lodges the optic commissure, and terminates on either side in the *optic foramen*, for the passage of the optic nerve and ophthalmic artery. Behind the optic groove is a small eminence, olive-like in shape, the *olivary process*; and still more posteriorly, a deep depression, the *pituitary fossa*, or *sella turcica*, which lodges the pituitary body. This fossa is perforated by numerous foramina, for the transmission of nutrient vessels into the substance of the bone. It is bounded in front by two small eminences, one on either side, called the *middle clinoid processes* (*κλίνη*, a bed), which are sometimes connected by a spiculum of bone to the anterior clinoid processes, and behind by a square-shaped plate of bone, the *dorsum ephippii* or *dorsum selle*, terminating at each superior angle in a tubercle, the *posterior clinoid processes*, the size and form of which vary considerably in different individuals. These processes deepen the pituitary fossa, and serve for the attachment of prolonga-



tions from the tentorium cerebelli. The sides of the dorsum ephippii are notched for the passage of the sixth pair of nerves, and below present a sharp process, the *petrosal process*, which is joined to the apex of the petrous portion of the temporal bone, forming the inner boundary of the middle lacerated foramen. Behind this plate, the bone presents a shallow depression, which slopes obliquely backwards, and is continuous with the basilar groove of the occipital bone; it is called the *clivus*, and supports the upper part of the pons Varolii. On either side of the body is a broad groove, curved something like the italic letter *f*; it lodges the internal carotid artery and the cavernous sinus, and is called the *carotid* or *cavernous groove*. Along the outer margin of this groove, at its posterior part, is a ridge of bone, in the angle between the body and greater wing, called the *lingula*. The **posterior surface**, quadrilateral in form, is joined to the basilar process of the occipital bone. During childhood these bones are separated by a layer of cartilage; but in after-life (between the eighteenth and twenty-fifth years) this becomes ossified, ossification commencing above and extending downwards; and the two bones then form one piece. The **anterior surface** (fig. 149)

FIG. 148.—Sphenoid bone. Superior surface.



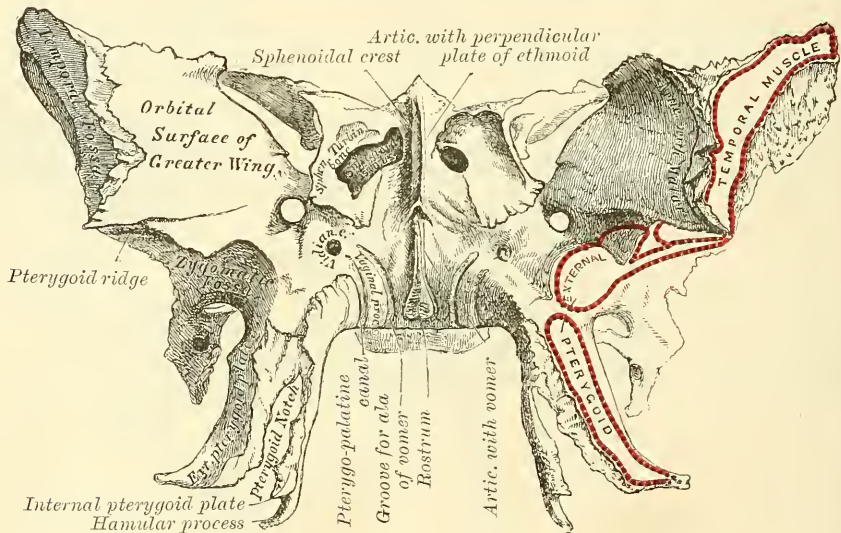
presents, in the middle line, a vertical ridge of bone, the *sphenoidal crest*, which articulates in front with the perpendicular plate of the ethmoid, forming part of the septum of the nose. On either side of it are irregular openings leading into the *sphenoidal cells* or *sinuses*. These are two large, irregular cavities hollowed out of the interior of the body of the sphenoid bone, and separated from one another by a more or less complete perpendicular bony septum. Their form and size vary considerably; they are seldom symmetrical, and are often partially subdivided by irregular osseous laminae. Occasionally, they extend into the basilar process of the occipital nearly as far as the foramen magnum. The septum is seldom quite vertical, being commonly bent to one or the other side. These sinuses do not exist in children, but they increase in size as age advances. They are partially closed, in front and below, by two thin, curved plates of bone, the *sphenoidal turbinated bones*, leaving a round opening at their upper parts, by which they communicate with the upper and back part of the nose and occasionally with the posterior ethmoidal cells or sinuses. The lateral margins of this surface present a serrated edge, which articulates with the os planum of the ethmoid, completing the posterior ethmoidal cells; the lower margin, also rough and serrated, articulates with the orbital process of the palate bone;



and the upper margin with the orbital plate of the frontal bone. The **inferior surface** presents, in the middle line, a triangular spine, the *rostrum*, which is continuous with the ethmoidal crest on the anterior surface, and is received into a deep fissure between the alæ of the vomer. On each side may be seen a projecting lamina of bone, which runs horizontally inwards from near the base of the pterygoid process: these plates, termed the *vaginal processes*, articulate with the edges of the vomer. Close to the root of the pterygoid process is a groove, formed into a complete canal when articulated with the sphenoidal process of the palate bone; it is called the *pterygo-palatine canal*, and transmits the pterygo-palatine vessels and pharyngeal nerve.

The **Greater Wings** are two strong processes of bone, which arise from the sides of the body, and are curved in a direction upwards, outwards and backwards; being prolonged behind into a sharp-pointed extremity, the *spinous process* of the sphenoid. Each wing presents three surfaces and a circumference. The *superior* or *cerebral surface* (fig. 148) forms part of the middle fossa of the skull; it is deeply concave, and presents eminences and depres-

FIG. 149.—Sphenoid bone. Anterior surface.\*



sions for the convolutions of the brain. At its anterior and internal part is seen a circular aperture, the *foramen rotundum*, for the transmission of the second division of the fifth nerve. Behind and external to this is a large, oval foramen, the *foramen ovale*, for the transmission of the third division of the fifth nerve, the small meningeal artery, and sometimes the small petrosal nerve.† At the inner side of the foramen ovale, a small aperture may occasionally be seen opposite the root of the pterygoid process; it is the *foramen Vesalii*, transmitting a small vein. Lastly, in the posterior angle, near to the spine of the sphenoid, is a short canal, sometimes double, the *foramen spinosum*; it transmits the middle meningeal artery. The *external surface* (fig. 149) is convex, and divided by a transverse ridge, the *pterygoid ridge*,‡ into two portions. The superior or larger, convex from above downwards, concave from before backwards, enters into the formation of the temporal fossa, and gives attachment to part of the Temporal muscle. The inferior portion, smaller in size and con-

\* In this figure, both the anterior and inferior surfaces of the body of the sphenoid bone are shown, the bone being held with the pterygoid processes almost horizontal.

† The small petrosal nerve sometimes passes through a special foramen between the foramen ovale and foramen spinosum.

‡ Sometimes called *infra-temporal crest*.

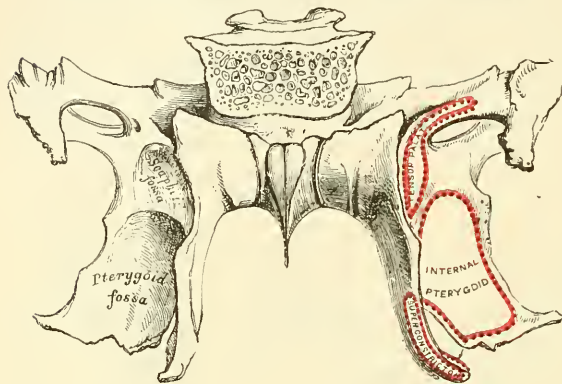
cave, enters into the formation of the zygomatic fossa, and affords attachment to the External pterygoid muscle. It presents, at its posterior part, a sharp-pointed eminence of bone, the *spinous process*, to which are connected the internal lateral ligament of the lower jaw and the Tensor palati muscle. The pterygoid ridge, dividing the temporal and zygomatic portions, gives attachment to part of the External pterygoid muscle. At its inner and anterior extremity is a triangular spine of bone, which serves to increase the extent of origin of this muscle. The *anterior* or *orbital* surface, smooth, and quadrilateral in form, assists in forming the outer wall of the orbit. It is bounded above by a serrated edge, for articulation with the frontal bone; below, by a rounded border, which enters into the formation of the spheno-maxillary fissure. Internally, it presents a sharp border, which forms the lower boundary of the sphenoidal fissure, and has projecting from about its centre a little tubercle of bone, which gives origin to one head of the External rectus muscle of the eye; and at its upper part is a notch for the transmission of a branch of the lachrymal artery: externally, it presents a serrated margin for articulation with the malar bone. One or two small foramina may occasionally be seen for the passage of branches of the deep temporal arteries: they are called the *external orbital foramina*. *Circumference of the great wing* (fig. 148): commencing from behind; that portion of the circumference which extends from the body of the sphenoid to the spine is serrated and articulates by its outer half with the petrous portion of the temporal bone; whilst the inner half forms the anterior boundary of the foramen lacerum medium, and presents the posterior aperture of the Vidian canal for the passage of the Vidian nerve and artery. In front of the spine the circumference of the great wing presents a serrated edge, bevelled at the expense of the inner table below, and of the external above, which articulates with the squamous portion of the temporal bone. At the tip of the great wing a triangular portion is seen bevelled at the expense of the internal surface, for articulation with the anterior inferior angle of the parietal bone. Internal to this is a broad, serrated surface, for articulation with the frontal bone: this surface is continuous internally with the sharp inner edge of the orbital plate, which assists in the formation of the sphenoidal fissure, and externally with the serrated margin for articulation with the malar bone.

The **Lesser Wings** (*processes of Ingrassias*) are two thin, triangular plates of bone, which arise from the upper and lateral parts of the body of the sphenoid, and, projecting transversely outwards, terminate in a sharp point (fig. 148). The superior surface of each is smooth, flat, broader internally than externally, and supports part of the frontal lobe of the brain. The inferior surface forms the back part of the roof of the orbit, and the upper boundary of the sphenoidal fissure or foramen lacerum anterius. This fissure is of a triangular form, and leads from the cavity of the cranium into the orbit; it is bounded internally by the body of the sphenoid; above, by the lesser wing; below, by the internal margin of the orbital surface of the great wing; and is converted into a foramen by the articulation of this bone with the frontal. It transmits the third, the fourth, the three branches of the ophthalmic division of the fifth, the sixth nerve, some filaments from the cavernous plexus of the sympathetic, the orbital branch of the middle meningeal artery, a recurrent branch from the lachrymal artery to the dura mater, and the ophthalmic vein. The anterior border of the lesser wing is serrated for articulation with the frontal bone; the posterior, smooth and rounded, is received into the fissure of Sylvius of the brain. The inner extremity of this border forms the *anterior clinoid process*. The lesser wing is connected to the side of the body by two roots, the upper thin and flat, the lower thicker, obliquely directed, and presenting on its outer side, near its junction with the body, a small tubercle, for the attachment of the common tendon of origin of three of the muscles of the eye. Between the two roots is the *optic foramen*, for the transmission of the optic nerve and ophthalmic artery.



The **Pterygoid Processes** (*πτέρυξ*, a wing; *εἶδος*, likeness), one on each side, descend perpendicularly from the point where the body and greater wing unite (fig. 150). Each process consists of an external and an internal plate, which are joined together by their anterior borders above, but are separated below, leaving an angular cleft, the *pterygoid notch*, in which the pterygoid process or tuberosity of the palate bone is received. The two plates diverge from each other from their line of connection in front, so as to form a V-shaped fossa, the *pterygoid fossa*. The *external pterygoid plate* is broad and thin, turned a little outwards,

FIG. 150.—Sphenoid bone. Posterior surface.



and, by its outer surface, forms part of the inner wall of the zygomatic fossa, giving attachment to the External pterygoid; its inner surface forms part of the pterygoid fossa, and gives attachment to the Internal pterygoid. The *internal pterygoid plate* is much narrower and longer, curving outwards, at its extremity, into a hook-like process of bone, the *hamular process*, around which turns the tendon of the Tensor palati muscle. The outer surface of this plate forms part of the pterygoid fossa,

the inner surface forming the outer boundary of the posterior aperture of the nares. On the posterior surface of the base of the process, above the pterygoid fossa, is a small, oval, shallow depression, the *scaphoid fossa*, from which arises the Tensor palati, and above which is seen the posterior orifice of the Vidian canal. Below and to the inner side of the Vidian canal, on the posterior surface of the base of the internal plate, is a little prominence, which is known by the name of the *pterygoid tubercle*. The Superior constrictor of the pharynx is attached to the posterior edge of the internal plate. The anterior surface of the pterygoid process is very broad at its base, and forms the posterior wall of the sphenomaxillary fossa. It supports Meckel's ganglion. It presents, above, the anterior orifice of the Vidian canal; and below, a rough margin, which articulates with the perpendicular plate of the palate bone.

The **Sphenoidal Spongy Bones** are two thin, curved plates of bones, which exist as separate pieces until puberty, and occasionally are not joined to the sphenoid in the adult. They are situated at the anterior and inferior part of the body of the sphenoid, an aperture of variable size being left in their anterior wall, through which the sphenoidal sinuses open into the nasal fossæ. They are irregular in form, and taper to a point behind, being broader and thinner in front. Their upper surface, which looks towards the cavity of the sinus, is concave; their under surface convex. Each bone articulates in front with the ethmoid, externally with the palate; its pointed posterior extremity is placed above the vomer, and is received between the root of the pterygoid process on the outer side, and the rostrum of the sphenoid on the inner.\*

**Development.**—Up to about the eighth month of foetal life the sphenoid bone consists of two distinct parts: a posterior or *post-sphenoid* part, which comprises the pituitary fossa, the greater wings, and the pterygoid processes; and an anterior or *pre-sphenoid* part, to which the anterior part of the body and lesser

\* A small portion of the sphenoidal turbinated bone sometimes enters into the formation of the inner wall of the orbit, between the os planum of the ethmoid in front, the orbital plate of the palate below, and the frontal above. Cleland. *Roy. Soc. Trans.* 1862.



wings belong. It is developed by fourteen centres: eight for the posterior sphenoid division, and six for the anterior sphenoid. The eight centres for the posterior sphenoid are—one for each greater wing and external pterygoid plate, one for each internal pterygoid plate, two for the posterior part of the body, and one on each side for the lingula. The six for the anterior sphenoid are one for each lesser wing, two for the anterior part of the body, and one for each sphenoidal turbinated bone.

*Post-sphenoid Division.*—The first nuclei to appear are those for the greater wings. They make their appearance between the foramen rotundum and foramen ovale

about the eighth week, and from them the external pterygoid plates are also formed. Soon after, the nuclei for the posterior part of the body appear, one on either side of the sella turcica, and become blended together about the middle of foetal life. About the fourth month the remaining four centres appear, those for the internal pterygoid-plates being ossified in membrane and becoming joined to the external pterygoid plate about the sixth month. The centres for the lingulae speedily become joined to the rest of the bone.

*Pre-sphenoid Division.*—The first nuclei to appear are those for the lesser wings. They make their appearance about the ninth week, at the outer borders of the optic foramina. A second pair of nuclei appear on the inner side of the foramina shortly after, and becoming united, form the front part of the body of the bone. The remaining two centres for the sphenoidal turbinated bones make their appearance about the fifth month. At birth they consist of small triangular laminae, and it is not till the third year that they become hollowed out and cone shaped.

The pre-sphenoid is united to the body of the post-sphenoid about the eighth month, so that at birth the bone consists of three pieces—viz. the body in the centre, and on each side the great wings with the pterygoid processes. The lesser wings become joined to the body at about the time of birth. At the first year after birth the greater wings and body are united. From the tenth to the twelfth year the spongy bones are partially united to the sphenoid, their junction being complete by the twentieth year. Lastly, the sphenoid joins the occipital from the eighteenth to the twenty-fifth year.

*Articulations.*—The sphenoid articulates with *all* the bones of the cranium, and five of the face—the two malar, two palate, and vomer: the exact extent of articulation with each bone is shown in the accompanying figures.\*

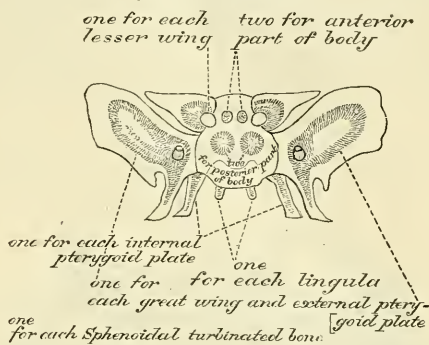
*Attachment of Muscles.*—To eleven pairs: the Temporal, External pterygoid, Internal pterygoid, Superior constrictor, Tensor palati, Levator palpebrae, Obliquus oculi superior, Superior rectus, Internal rectus, Inferior rectus, External rectus.

### THE ETHMOID BONE

The **Ethmoid** (*ἔθμός*, a sieve) is an exceedingly light, spongy bone, of a cubical form, situated at the anterior part of the base of the cranium, between the two orbits, at the root of the nose, and contributing to form each of these cavities. It consists of three parts: a horizontal plate, which forms part of the base of the cranium; a perpendicular plate, which forms part of the septum nasi; and two lateral masses of cells.

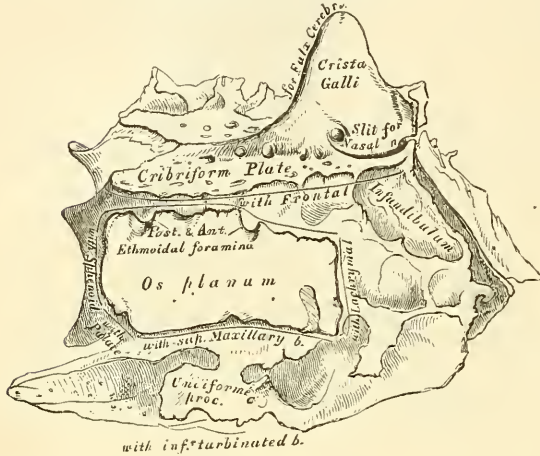
\* It also sometimes articulates with the tuberosity of the superior maxilla (see p. 170).

FIG. 151.—Plan of the development of sphenoid. By fourteen centres.



The **Horizontal or Cribriform Plate** (fig. 152) forms part of the anterior fossa of the base of the skull, and is received into the ethmoid notch of the frontal bone between the two orbital plates. Projecting upwards from the middle line of this plate is a thick, smooth, triangular process of bone, the *crista galli*, so called from its resemblance to a cock's comb. Its base joins the cribriform plate. Its posterior border, long, thin, and slightly curved, serves for the attachment of the falx cerebri. Its anterior border, short and thick, articulates with the frontal bone, and presents two small projecting alæ, which are received into corresponding depressions in the frontal, completing the foramen cæcum behind. Its sides are smooth and sometimes bulging; in which case it is found to enclose a small sinus.\* On each side of the crista galli, the cribriform plate is narrow, and deeply grooved, to support the bulb of the olfactory tract, and perforated by foramina for the passage of the olfactory nerves. These foramina are arranged in three rows: the

FIG. 152.—Ethmoid bone. Outer surface of right lateral mass (enlarged).



innermost, which are the largest and least numerous, are lost in grooves on the upper part of the septum; the foramina of the outer row are continued on to the surface of the upper spongy bone. The foramina of the middle row are the smallest; they perforate the bone, and transmit nerves to the roof of the nose. At the front part of the cribriform plate, on each side of the crista galli, is a small fissure, which transmits the nasal branch of the ophthalmic nerve; and at its posterior part a triangular notch, which receives the ethmoidal spine of the sphenoid.

The **Perpendicular Plate** (fig. 153) is a thin, flattened lamella of bone, which descends from the under surface of the cribriform plate, and assists in forming the septum of the nose. It is much thinner in the middle than at the circumference, and is generally deflected a little to one side. Its anterior border articulates with the nasal spine of the frontal bone and crest of the nasal bones. Its posterior, divided into two parts, articulates by its upper half with the sphenoidal crest of the sphenoid, by its lower half with the vomer. The inferior border serves for the attachment of the triangular cartilage of the nose. On each side of the perpendicular plate numerous grooves and canals are seen, leading from foramina on the cribriform plate; they lodge filaments of the olfactory nerves.

The **Lateral Masses** of the ethmoid consist of a number of thin-walled cellular cavities, the *ethmoidal cells*, interposed between two vertical plates of bone, the outer one of which forms part of the orbit, and the inner one part of the nasal fossa of the corresponding side. In the disarticulated bone many of these cells appear to be broken; but when the bones are articulated, they are closed in at every part. The upper surface of each lateral mass presents a number of apparently half-broken cellular spaces; these are closed in when articulated by the edges of the ethmoidal notch of the frontal bone. Crossing this surface are two

\* Sir George Humphry states that the crista galli is commonly inclined to one side, usually the opposite to that towards which the lower part of the perpendicular plate is bent.—*The Human Skeleton*, 1858, p. 277.

\* Sir George Humphry states that the crista galli is commonly inclined to one side, usually the opposite to that towards which the lower part of the perpendicular plate is bent.—*The Human Skeleton*, 1858, p. 277.



grooves on each side, converted into canals by articulation with the frontal; they are the *anterior* and *posterior ethmoidal* canals, and open on the inner wall of the orbit. The posterior surface also presents large, irregular cellular cavities, which are closed in by articulation with the sphenoidal turbinated bones and orbital process of the palate. The cells at the anterior surface are completed by the lachrymal bone and nasal process of the superior maxillary, and those below by the superior maxillary. The outer surface of each lateral mass is formed of a thin, smooth, square plate of bone, called the *os planum*; it forms part of the inner wall of the orbit, and articulates, above, with the orbital plate of the frontal; below, with the superior maxillary; in front, with the lachrymal; and behind, with the sphenoid and orbital process of the palate.

From the inferior part of each lateral mass, immediately beneath the *os planum*, there projects downwards and backwards an irregular lamina of bone, called the *unciform process*, from its

hook-like form; it serves to close in the upper part of the orifice of the antrum, and articulates with the ethmoidal process of the inferior turbinated bone. It is often broken in disarticulating the bones.

The inner surface of each lateral mass forms part of the outer wall of the nasal fossa of the corresponding side. It is formed of a thin lamella of bone, which descends from the under surface of the cribriform plate, and terminates below in a free, convoluted margin, the *middle turbinated* bone. The whole of this surface is rough, and marked above by numerous grooves, which run nearly vertically downwards from the cribriform plate; they lodge branches of the olfactory nerve, which are distributed on the mucous membrane covering the bone. The back part of this surface is subdivided by a narrow oblique fissure, the *superior meatus* of the nose, bounded above by a thin, curved plate of bone, the *superior turbinated* bone. By means of an orifice at the upper part of this fissure, the posterior ethmoidal cells open into the nose. Below, and in front of the superior meatus, is seen the convex surface of the middle turbinated bone. It extends along the whole length of the inner surface of each lateral mass; its lower margin is free and thick, and its concavity, directed outwards, assists in forming the middle meatus.

It is by a large orifice at the upper and front part of the middle meatus that the anterior ethmoidal cells, and through them the frontal sinuses, communicate with the nose, by means of a funnel-

FIG. 153.—Perpendicular plate of ethmoid (enlarged).  
Shown by removing the right lateral mass.

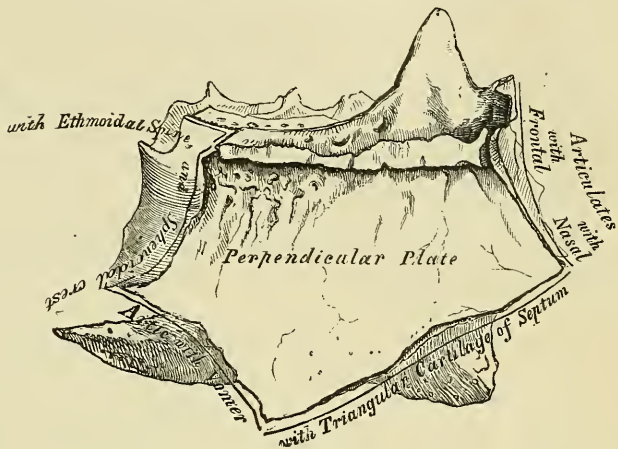
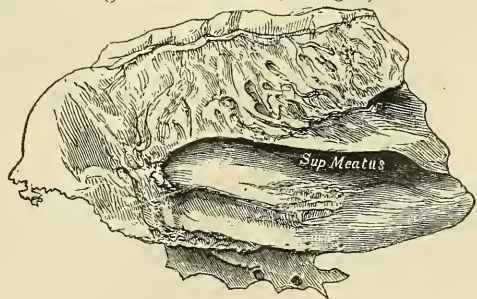


FIG. 154.—Ethmoid bone. Inner surface of right lateral mass (enlarged).





shaped canal, the *infundibulum*. The cellular cavities of each lateral mass, thus walled in by the os planum on the outer side, and by the other bones already mentioned, are divided by a thin transverse bony partition into two sets, which do not communicate with each other; they are termed the *anterior* and *posterior ethmoidal cells*, or *sinuses*. The former, more numerous, communicate with the frontal sinuses above, and the middle meatus below, by means of a long, flexuous canal, the *infundibulum*; the posterior, less numerous, open into the superior meatus, and communicate (occasionally) with the sphenoidal sinuses.

**Development.**—By *three* centres: one for the perpendicular lamella, and one for each lateral mass.

The lateral masses are first developed, ossific granules making their appearance in the os planum between the fourth and fifth months of foetal life, and extending into the spongy bones. At birth, the bone consists of the two lateral masses, which are small and ill-developed. During the first year after birth, the perpendicular and horizontal plates begin to ossify, from a single nucleus, and become joined to the lateral masses about the beginning of the second year. The formation of the ethmoidal cells, which completes the bone, does not commence until about the fourth or fifth year.

**Articulations.**—With fifteen bones: the sphenoid, two sphenoidal turbinated, the frontal, and eleven of the face—the two nasal, two superior maxillary, two lachrymal, two palate, two inferior turbinated, and the vomer. No muscles are attached to this bone.

#### DEVELOPMENT OF THE CRANIUM

The early stages of the development of the cranium have already been described (see page 90). We have seen that it is formed from a layer of mesoblast, derived from the protovertebral plates of the trunk, which is spread over the whole surface of the rudimentary brain. That portion of this layer from which the bones of the skull are to be developed consists of a thin, membranous capsule.

Ossification commences in the roof, and is preceded by the deposition of a membranous blastema upon the surface of the cerebral capsule, in which the ossifying process extends; the primitive membranous capsule becoming the internal periosteum, and

FIG. 155.—Skull at birth, showing the anterior and posterior fontanelles.

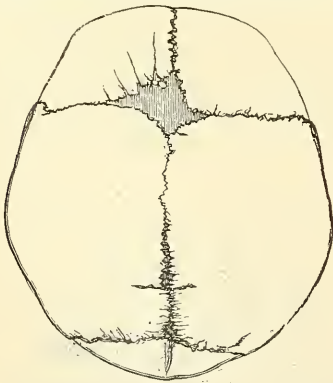
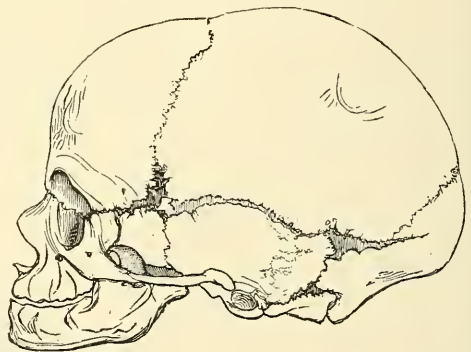


FIG. 156.—The lateral fontanelles.



being ultimately blended with the dura mater. The ossification of the bones of the base takes place for the most part in cartilage, and although the bones of the vertex of the skull appear before those at the base, and make considerable progress in their growth, at birth ossification is more advanced in the base, this portion of the skull forming a solid, immovable groundwork.

#### THE FONTANELLES

Before birth, the bones at the vertex and side of the skull are separated from each other by membranous intervals, in which bone is deficient. These intervals are principally found at the four angles of the parietal bones. Hence there are six of these intervals.

Their formation is due to the wave of ossification being circular and the bones quadrilateral; the ossific matter first meets at the margins of the bones, at the points nearest to their centres of ossification, and vacuities or spaces are left at the angles, which are called *fontanelles*, so named from the pulsations of the brain; which are perceptible at the anterior fontanelle, and were likened to the rising of water in a fountain. The anterior fontanelle is the largest, and corresponds to the junction of the sagittal and coronal sutures; the posterior fontanelle, of smaller size, is situated at the junction of the sagittal and lambdoid sutures; the remaining ones are situated at the inferior angles of each parietal bone. The latter are closed soon after birth; the two at the two superior angles remain open longer; the posterior being closed in a few months after birth; the anterior remaining open until the first or second year. These spaces are gradually filled in by an extension of the ossifying process, or by the development of a Wormian bone. Sometimes the anterior fontanelle remains open beyond two years, and is occasionally persistent throughout life.

#### SUPERNUMERARY OR WORMIAN\* BONES

In addition to the constant centres of ossification of the skull, additional ones are occasionally found in the course of the sutures. These form irregular, isolated bones, interposed between the cranial bones, and have been termed *Wormian bones* or *ossa triquetra*. They are most frequently found in the course of the lambdoid suture, but occasionally also occupy the situation of the fontanelles, especially the posterior and, more rarely, the anterior. Frequently one is found between the anterior inferior angle of the parietal bone and the greater wing of the sphenoid, the *pterion ossicle* (fig. 156). They have a great tendency to be symmetrical on the two sides of the skull, and they vary much in size, being in some cases not larger than a pin's head, and confined to the outer table; in other cases so large that one pair of these bones may form the whole of the occipital bone above the superior curved lines, as described by Bécларd and Ward. Their number is generally limited to two or three; but more than a hundred have been found in the skull of an adult hydrocephalic skeleton. In their development, structure, and mode of articulation, they resemble the other cranial bones.

#### CONGENITAL FISSURES AND GAPS

An arrest in the ossifying process may give rise to deficiencies, or gaps; or to fissures which are of importance in a medico-legal point of view, as they are liable to be mistaken for fractures. The fissures generally extend from the margins towards the centre of the bone, but the gaps may be found in the middle as well as at the edges. In course of time they may become covered with a thin lamina of bone.

#### BONES OF THE FACE

The Facial Bones are fourteen in number—viz. the

Two Nasal.	Two Palate.
Two Superior Maxillary.	Two Inferior Turbinated.
Two Lachrymal.	Vomer.
Two Malar.	Inferior Maxillary.

‘Of these, the upper and lower jaws are the fundamental bones for mastication, and the others are accessories; for the chief function of the facial bones is to provide an apparatus for mastication, while subsidiary functions are to provide for the sense-organs (eye, nose, tongue) and a vestibule to the respiratory and vocal organs. Hence the variations in the shape of the face in man and the lower animals depend chiefly on the question of the character of their food and their mode of obtaining it.’†

#### NASAL BONES

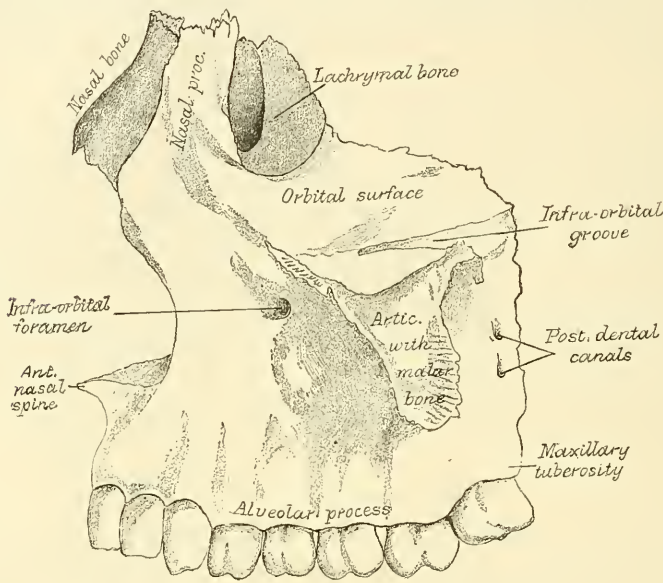
The **Nasal** (*nasus*, *the nose*) are two small oblong bones, varying in size and form in different individuals; they are placed side by side at the middle and upper part of the face, forming, by their junction, ‘the bridge’ of the nose (fig. 157). Each bone presents for examination two surfaces and four borders. The *outer* surface is concave from above downwards, convex from side to side;

\* Wormius, a physician in Copenhagen, is said to have given the first detailed description of these bones.

† W. W. Keen. American edition, p. 185.

it is covered by the *Pyramidalis* and *Compressor nasi* muscles, and gives attachment at its upper part to a few fibres of the *Occipito-frontalis* muscle (Theile). It is marked by numerous small arterial furrows, and perforated about its centre by a foramen, sometimes double, for the transmission of a small vein. Sometimes this foramen is absent on one or both sides, and occasionally the foramen *æcæum* opens on this surface. The *inner* surface is concave from side to side, convex from above downwards; in which direction it is traversed by a longitu-

FIG. 157.—Nasal bone and Lachrymal bone *in situ*.



dinal groove (sometimes a canal), for the passage of a branch of the nasal nerve. The *superior* border is narrow, thick, and serrated for articulation with the nasal notch of the frontal bone. The *inferior* border is broad, thin, sharp, inclined obliquely downwards, outwards, and backwards, and serves for the attachment of the lateral cartilage of the nose. This border presents, about its middle, a notch, through which passes the branch of the nasal nerve above re-

FIG. 158.—Right nasal bone.

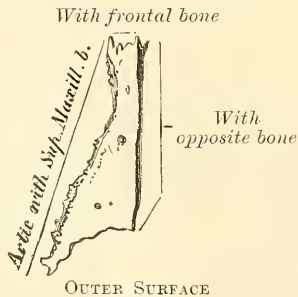
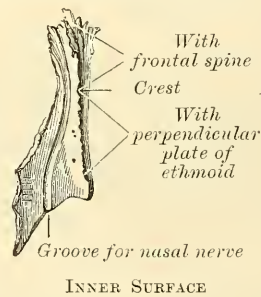


FIG. 159.—Left nasal bone.



ferred to; and is prolonged at its inner extremity into a sharp spine, which, when articulated with the opposite bone, forms the *nasal angle*. The *external* border is serrated, bevelled at the expense of the internal surface above, and of the external below, to articulate with the nasal process of the superior maxillary. The *internal* border, thicker above than below, articulates with its fellow of the opposite side, and is prolonged behind into a vertical crest, which forms part of the septum of the nose: this crest articulates, from above downwards, with the



nasal spine of the frontal, the perpendicular plate of the ethmoid, and the triangular septal cartilage of the nose.

**Development.**—By *one* centre for each bone, which appears about the same period as in the vertebræ.

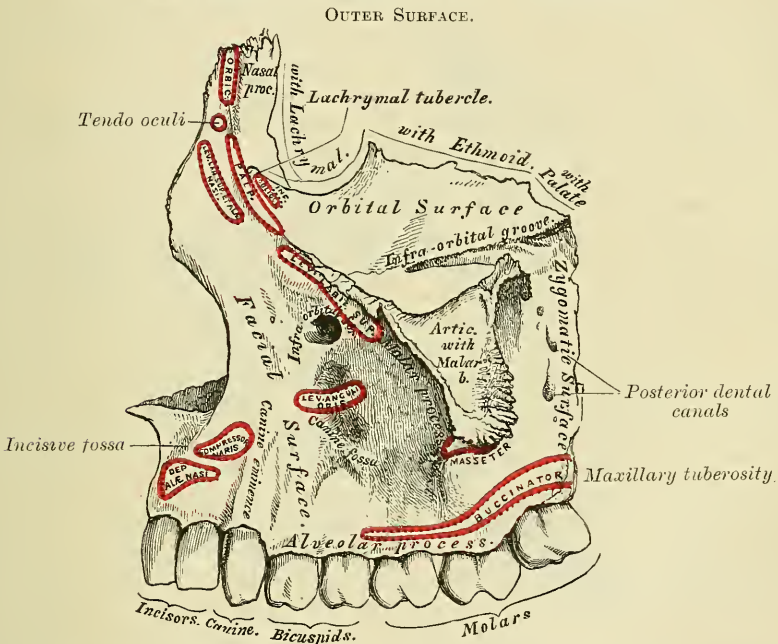
**Articulations.**—With four bones : two of the cranium, the frontal and ethmoid, and two of the face, the opposite nasal and the superior maxillary.

**Attachment of Muscles.**—A few fibres of the Occipito-frontalis muscle.

### SUPERIOR MAXILLARY BONES

The **Superior Maxillary Bones** (*maxilla, the jaw-bone*) are the most important bones of the face from a surgical point of view, on account of the number of diseases to which some of their parts are liable. Their careful examination becomes, therefore, a matter of considerable interest. They are the largest bones of the face, excepting the lower jaw, and form, by their union, the whole of the upper jaw. Each bone assists in the formation of three cavities,

FIG. 160.—Left superior maxillary bone. Outer surface.



the roof of the mouth, the floor and outer wall of the nasal fossæ, and the floor of the orbit; and also enters into the formation of two fossæ, the zygomatic and spheno-maxillary, and two fissures, the spheno-maxillary and pterygo-maxillary.

The bone presents for examination a body and four processes—malar, nasal, alveolar, and palatæ.

The **body** is somewhat cuboid, and is hollowed out in its interior to form a large cavity, the *antrum of Highmore*. Its surfaces are four—an external or facial, a posterior or zygomatic, a superior or orbital, and an internal.

The **external or facial surface** (fig. 160) is directed forwards and outwards. It presents at its lower part a series of eminences corresponding to the position of the teeth. Just above those for the incisor teeth is a depression, the *incisive* or *myrtiform fossa*, which gives origin to the *Depressor alæ nasi*; and, below it, to the alveolar border is attached a slip of the *Orbicularis oris*. Above and a little external to it, the *Compressor nasi* arises. More external is another depression, the *canine fossa*, larger and deeper than the incisive fossa, from which it is separated by a vertical ridge, the *canine eminence*, corresponding to the socket of

the canine tooth. The canine fossa gives origin to the Levator anguli oris. Above the canine fossa is the *infra-orbital foramen*, the termination of the infra-orbital canal; it transmits the infra-orbital vessels and nerve. Above the infra-orbital foramen is the margin of the orbit, which affords partial attachment to the Levator labii superioris proprius. To the sharp margin of bone which bounds this surface in front and separates it from the internal surface is attached the Dilator naris posterior.

The **posterior** or **zygomatic surface** is convex, directed backwards and outwards, and forms part of the zygomatic fossa. It is separated from the facial surface by a strong ridge of bone, which extends upwards from the socket of the second molar tooth. It presents about its centre several apertures leading to canals in the substance of the bone; they are termed the *posterior dental canals*, and transmit the posterior dental vessels and nerves. At the lower part of this surface is a rounded eminence, the *maxillary tuberosity*, especially prominent after the growth of the wisdom-tooth, rough on its inner side for articulation with the tuberosity of the palate-bone and sometimes with the external pterygoid plate. It gives attachment to a few fibres of origin of the Internal pterygoid muscle. Immediately above this is a smooth surface, which forms the anterior boundary of the spheno-maxillary fossa; it presents a groove, which, running obliquely downwards, is converted into a canal by articulation with the palate-bone, forming the *posterior palatine canal*.

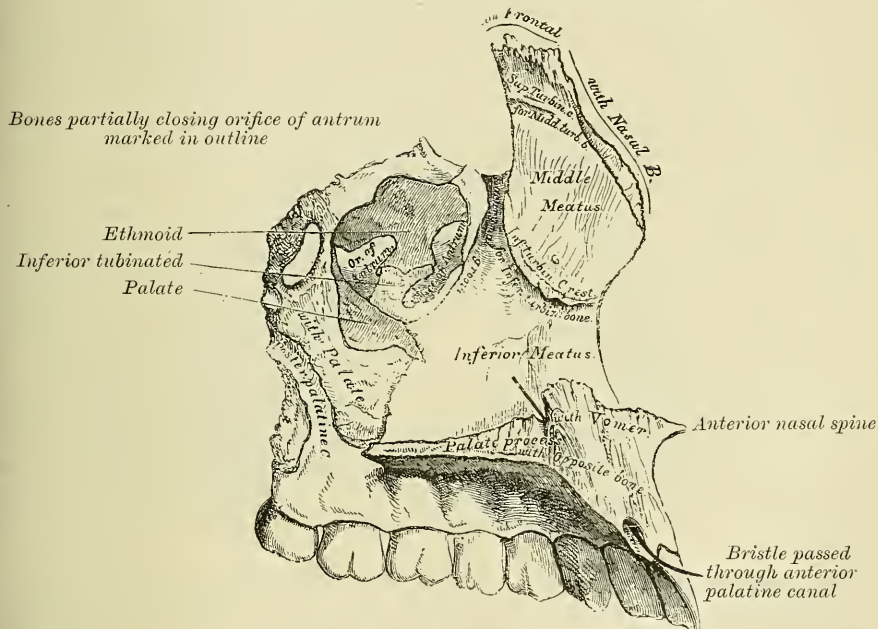
The **superior** or **orbital surface** is thin, smooth, triangular, and forms part of the floor of the orbit. It is bounded internally by an irregular margin which in front presents a notch, the *lachrymal notch*, which receives the lachrymal bone; in the middle articulates with the os planum of the ethmoid, and behind with the orbital process of the palate-bone; it is bounded externally by a smooth, rounded edge which enters into the formation of the spheno-maxillary fissure, and which sometimes articulates at its anterior extremity with the orbital plate of the sphenoid; and it is bounded in front by part of the circumference of the orbit, which is continuous, on the inner side with the nasal, on the outer side with the malar process. Along the middle line of the orbital surface is a deep groove, the *infra-orbital*, for the passage of the infra-orbital vessels and nerve. The groove commences at the middle of the outer border of this surface, and, passing forwards, terminates in a canal, which subdivides into two branches. One of the canals, the *infra-orbital*, opens just below the margin of the orbit; the other, which is smaller, runs in the substance of the anterior wall of the antrum; it is called the *anterior dental canal*, and transmits the anterior dental vessels and nerve to the front teeth of the upper jaw. From the back part of the infra-orbital canal, a second small canal is sometimes given off, which runs in the substance of the bone, and conveys the middle dental nerve to the bicuspid teeth. Occasionally, this canal is derived from the anterior dental. At the inner and fore part of the orbital surface, just external to the lachrymal groove for the nasal duct, is a depression, which gives origin to the Inferior oblique muscle of the eye.

The **internal surface** (fig. 161) is unequally divided into two parts by a horizontal projection of bone, the *palate process*: the portion above the palate process forms part of the outer wall of the nasal fossæ; that below it forms part of the cavity of the mouth. The superior division of this surface presents a large, irregular opening leading into the *antrum of Highmore*. At the upper border of this aperture are numerous broken cellular cavities, which, in the articulated skull, are closed in by the ethmoid and lachrymal bones. Below the aperture is a smooth concavity which forms part of the inferior meatus of the nasal fossæ, and behind it is a rough surface which articulates with the perpendicular plate of the palate-bone, traversed by a groove which, commencing near the middle of the posterior border, runs obliquely downwards and forwards, and forms, when completed by its articulation with the palate-bone, the *posterior palatine canal*. In front of the opening of the antrum is a deep groove, converted into a canal by the lachrymal and inferior turbinated bones. It is called the *lachrymal groove*, and lodges the

nasal duct. More anteriorly is a well-marked rough ridge, the *inferior turbinated crest*, for articulation with the inferior turbinated bone. The concavity above this ridge forms part of the middle meatus of the nose; whilst that below it forms part of the inferior meatus. The portion of this surface below the palate process is concave, rough and uneven, and perforated by numerous small foramina for the passage of nutrient vessels. It enters into the formation of the roof of the mouth.

The **Antrum of Highmore**, or **Maxillary Sinus**, is a large pyramidal cavity, hollowed out of the body of the maxillary bone: its apex, directed outwards, is formed by the malar process; its base, by the outer wall of the nose. Its walls are everywhere exceedingly thin, and correspond to the orbital, facial, and zygomatic surfaces of the body of the bone. Its inner wall, or base, presents, in the disarticulated bone, a large, irregular aperture, which communicates with the nasal fossa. The margins of this aperture are thin and ragged, and the aperture itself is much contracted by its articulation with the ethmoid above, the

FIG. 161.—Left superior maxillary bone. Inner surface.



inferior turbinated below, and the palate-bone behind.\* In the articulated skull, this cavity communicates with the middle meatus of the nasal fossæ, generally by two small apertures left between the above-mentioned bones. In the recent state, usually only one small opening exists, near the upper part of the cavity sufficiently large to admit the end of a probe, the other being closed by the lining membrane of the sinus.

Crossing the cavity of the antrum are often seen several projecting laminae of bone, similar to those seen in the sinuses of the cranium; and on its posterior wall are the *posterior dental canals*, transmitting the posterior dental vessels and nerves to the teeth. Projecting into the floor are several conical processes, corresponding to the roots of the first and second molar teeth; † in some cases the floor is perforated by the teeth in this situation.

\* In some cases, at any rate, the lachrymal bone also encroaches slightly on the anterior superior portion of the opening, and assists in forming the inner wall of the antrum.

† The number of teeth whose fangs are in relation with the floor of the antrum is variable. The antrum 'may extend so as to be in relation to all the teeth of the true maxilla, from the canine to the *dens sapientiae*.'—See Mr. Salter on Abscess of the Antrum, in a *System of Surgery*, edited by T. Holmes, 2nd edit. vol. iv. p. 356.



It is from the extreme thinness of the walls of this cavity that we are enabled to explain how a tumour growing from the antrum encroaches upon the adjacent parts, pushing up the floor of the orbit, and displacing the eyeball, projecting inwards into the nose, protruding forwards on to the cheek, and making its way backwards into the zygomatic fossa, and downwards into the mouth.

The **Malar Process** is a rough triangular eminence, situated at the angle of separation of the facial from the zygomatic surface. In front it is concave, forming part of the facial surface; behind, it is also concave, and forms part of the zygomatic fossa; above, it is rough and serrated for articulation with the malar bone; whilst below, a prominent ridge marks the division between the facial and zygomatic surfaces. A small part of the Masseter muscle arises from this process.

The **Nasal Process** is a thick, triangular plate of bone, which projects upwards, inwards, and backwards, by the side of the nose, forming part of its lateral boundary. Its *external* surface is concave, smooth, perforated by numerous foramina, and gives attachment to the Levator labii superioris alæque nasi, the Orbicularis palpebrarum, and Tendo oculi. Its *internal* surface forms part of the outer wall of the nasal fossæ: at its upper part it presents a rough, uneven surface, which articulates with the ethmoid bone, closing in the anterior ethmoidal cells; below this is a transverse ridge, the *superior turbinated crest*, for articulation with the middle turbinated bone of the ethmoid, bounded below by a smooth concavity which forms part of the middle meatus; below this again is the inferior turbinated crest (already described), where the process joins the body of the bone. Its upper border articulates with the frontal bone. The *anterior* border of the nasal process is thin, directed obliquely downwards and forwards, and presents a serrated edge for articulation with the nasal bone; its *posterior* border is thick, and hollowed into a groove, the *lachrymal groove*, for the nasal duct: of the two margins of this groove, the inner one articulates with the lachrymal bone, the outer one forms part of the circumference of the orbit. Just where the latter joins the orbital surface is a small tubercle, the *lachrymal tubercle*; this serves as a guide to the position of the lachrymal sac in the operation for fistula lachrymalis. The lachrymal groove in the articulated skull is converted into a canal by the lachrymal bone and lachrymal process of the inferior turbinated; it is directed downwards, and a little backwards and outwards, is about the diameter of a goose-quill, slightly narrower in the middle than at either extremity, and terminates below in the inferior meatus. It lodges the nasal duct.

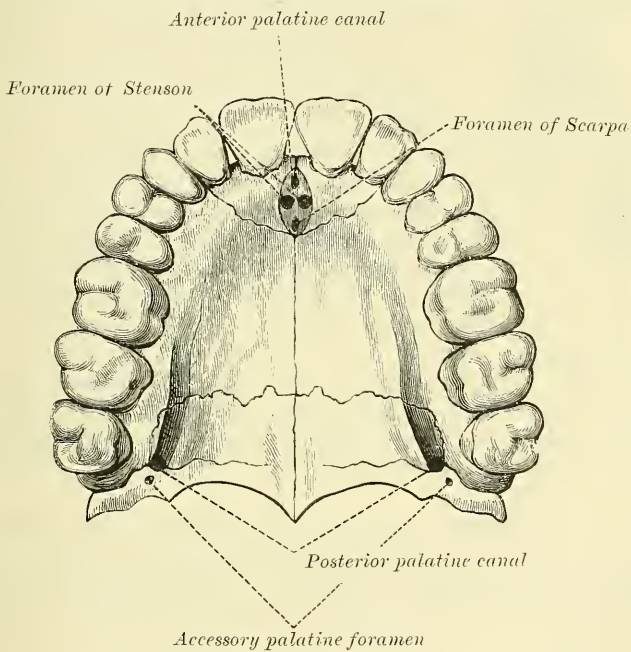
The **Alveolar Process** is the thickest and most spongy part of the bone, broader behind than in front, and excavated into deep cavities for the reception of the teeth. These cavities are eight in number, and vary in size and depth according to the teeth they contain. That for the canine tooth is the deepest; those for the molars are the widest, and subdivided into minor cavities; those for the incisors are single, but deep and narrow. The Buccinator muscle arises from the outer surface of this process, as far forward as the first molar tooth.

The **Palate Process**, thick and strong, projects horizontally inwards from the inner surface of the bone. It is much thicker in front than behind, and forms a considerable part of the floor of the nostril and the roof of the mouth.

Its *inferior* surface (fig. 162) is concave, rough and uneven, and forms part of the roof of the mouth. This surface is perforated by numerous foramina for the passage of the nutrient vessels; channelled at the back part of its alveolar border by a longitudinal groove, sometimes a canal, for the transmission of the posterior palatine vessels, and the anterior and external palatine nerves from Meckel's ganglion; and presents little depressions for the lodgment of the palatine glands. When the two superior maxillary bones are articulated together, a large orifice may be seen in the middle line, immediately behind the incisor teeth. This is the *anterior palatine canal* or *fossa*. This canal, as it passes through the thickness of the palate process, is divided into four compartments; that is to say, two

canals branch off laterally to the right and left nasal fossæ, and two canals, one in front and one behind, lie in the middle line. The former pair of these canals is named the *foramina of Stenson*, and through them passes the anterior or terminal branch of the descending or posterior palatine arteries, which ascends from the mouth to the nasal fossæ. The remaining pair of canals is termed the *foramina of Scarpa*, and transmit the naso-palatine nerves, the left passing through the anterior, and the right through the posterior canal. On the palatal surface of the process, a delicate linear suture may sometimes be seen extending from the anterior palatine fossa to the interval between the lateral incisor and the canine tooth. This marks out the intermaxillary, or incisive bone, which in some animals exists permanently as a separate piece. It includes the whole thickness of the alveolus, the corresponding part of the floor of the nose and the anterior nasal spine, and contains the sockets of the incisor teeth. One or two small foramina in the alveolar margin behind the incisor teeth are occasionally seen in the adult, almost constantly in the young subject. They are called the

FIG. 162.—The palate and alveolar arch.

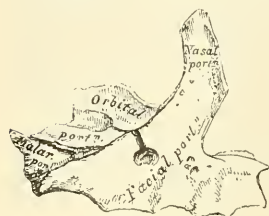

incisive foramina, and transmit vessels and nerves to the incisor teeth. The *upper* surface is concave from side to side, smooth, and forms part of the floor of the nose. It presents the upper orifices of the foramina of Stenson and Scarpa, the former being on each side of the middle line, the latter being situated in the intermaxillary suture, and therefore not visible unless the two bones are placed in apposition. The *outer* border of the palate process is incorporated with the rest of the bone. The *inner* border is thicker in front than behind, and is raised above into a ridge, the *nasal crest*, which, with the corresponding ridge in the opposite bone, forms a groove for the reception of the vomer. In front, this crest rises to a considerable height, and this portion is named the *incisor crest*. The *anterior* margin is bounded by the thin, concave border of the opening of the nose prolonged forwards internally into a sharp process, forming, with a similar process of the opposite bone, the *anterior nasal spine*. The *posterior* border is serrated for articulation with the horizontal plate of the palate-bone.

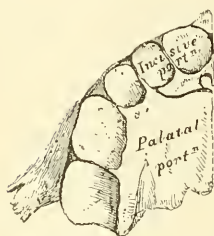
**Development.**—This bone commences to ossify at a very early period, and ossification proceeds in it with great rapidity, so that it is difficult to ascertain

with certainty its precise number of centres. It appears, however, probable that it is ossified from four centres, which are deposited in membrane. 1. One which forms that portion of the body of the bone which lies internal to the infra-orbital canal, including the floor of the orbit, the outer wall of the nasal fossa and the nasal process; 2. a second which gives origin

FIG. 163.—Development of superior maxillary bone. At birth.



ANTERIOR SURFACE.



INFERIOR SURFACE.

to that portion of the bone which lies external to the infra-orbital canal and the malar process; 3. a third from which is developed the palatine process posterior to Stenson's canal and the adjoining part of the nasal wall; 4. and a fourth for the front part of the alveolus which carries the incisor teeth and corresponds to the pre-maxillary bone of the lower animals. These centres appear about the eighth week, and by the tenth week the three first named centres have become fused together and the bone consists of two portions, one the greater part of the bone, and the other the pre-maxillary portion. The suture between these two portions on the palate persists till middle life, but is not to be seen on the facial surface. This is believed by Callender to be due to the fact that the front wall of the sockets of the incisive teeth is not formed by the pre-maxillary bone, but by an outgrowth from the facial part of the superior maxilla. The antrum appears as a shallow groove on the inner surface of the bone at an earlier period than any of the other nasal sinuses, its development commencing about the fourth month of fetal life. The sockets for the teeth are formed by the growing downwards of two plates from the dental

groove, which subsequently becomes divided by partitions jutting across from the one to the other.

**Articulations.**—With *nine* bones: two of the cranium, the frontal and ethmoid, and seven of the face—viz. the nasal, malar, lachrymal, inferior turbinated, palate, vomer, and its fellow of the opposite side. Sometimes it articulates with the orbital plate of the sphenoid, and sometimes with its external pterygoid plate.

**Attachment of Muscles.**—To twelve: the Orbicularis palpebrarum, Obliquus oculi inferior, Levator labii superioris alaeque nasi, Levator labii superioris proprius, Levator anguli oris, Compressor nasi, Depressor alae nasi, Dilator naris posterior, Masseter, Buccinator, Internal pterygoid, and Orbicularis oris.

#### CHANGES PRODUCED IN THE UPPER JAW BY AGE

At birth and during infancy the diameter of the bone is greater in an antero-posterior than in a vertical direction. Its nasal process is long, its orbital surface large, and its tuberosity well marked. In the adult the vertical diameter is the greater, owing to the development of the alveolar process and the increase in size of the antrum. In old age the bone approaches again in character to the infantile condition: its height is diminished, and after the loss of the teeth the alveolar process is absorbed, and the lower part of the bone contracted and diminished in thickness.

#### THE LACHRYMAL BONE

The **Lachrymal** (*lachryma, a tear*) are the smallest and most fragile bones of the face. They are situated at the front part of the inner wall of the orbit (fig. 157), and resemble somewhat in form, thinness, and size, a finger-nail; hence they are termed the *ossa unguis*. Each bone presents for examination two surfaces and four borders. The *external* or *orbital* surface (fig. 164) is divided by a vertical ridge, the *lachrymal crest*, into two parts. The portion of bone in



front of this ridge presents a smooth, concave, longitudinal groove, the free margin of which unites with the nasal process of the superior maxillary bone, completing the lachrymal groove. The upper part of this groove lodges the lachrymal sac; the lower part lodges the nasal duct. The portion of bone behind the ridge is smooth, slightly concave, and forms part of the inner wall of the orbit. The ridge, with a part of the orbital surface immediately behind it, affords attachment to the Tensor tarsi: the ridge terminates below in a small, hook-like projection, the *hamular process*, which articulates with the lachrymal tubercle of the superior maxillary bone, and completes the upper orifice of the lachrymal groove. It sometimes exists as a separate piece, which is then called the *lesser lachrymal bone*. The *internal or nasal surface* presents a depressed furrow, corresponding to the ridge on its outer surface. The surface of bone in front of this forms part of the middle meatus; and that behind it articulates with the ethmoid bone, filling in the anterior ethmoidal cells. Of the *four borders* the *anterior* is the longest, and articulates with the nasal process of the superior maxillary bone. The *posterior*, thin and uneven, articulates with the os planum of the ethmoid. The *superior*, the shortest and thickest, articulates with the internal angular process of the frontal bone. The *inferior* is divided by the lower edge of the vertical crest into two parts: the posterior part articulates with the orbital plate of the superior maxillary bone; the anterior portion is prolonged downwards into a pointed process, which articulates with the lachrymal process of the inferior turbinated bone, and assists in the formation of the lachrymal groove.

**Development.**—By a single centre, which makes its appearance soon after ossification of the vertebræ has commenced.

**Articulations.**—With four bones: two of the cranium, the frontal and ethmoid, and two of the face, the superior maxillary and the inferior turbinated.

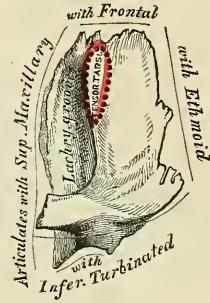
**Attachment of Muscles.**—To one muscle, the Tensor tarsi.

#### THE MALAR BONES

The **Malar** (*mala*, *the cheek*) are two small, quadrangular bones, situated at the upper and outer part of the face: they form the prominence of the cheek, part of the outer wall and floor of the orbit, and part of the temporal and zygomatic fossæ (fig. 165). Each bone presents for examination an external and an internal surface; four processes, the frontal, orbital, maxillary, and zygomatic; and four borders. The **external surface** (fig. 166) is smooth, convex, perforated near its centre by one or two small apertures, the *malar foramina*, for the passage of nerves and vessels, covered by the Orbicularis palpebrarum muscle, and affords attachment to the Zygomaticus major and minor muscles.

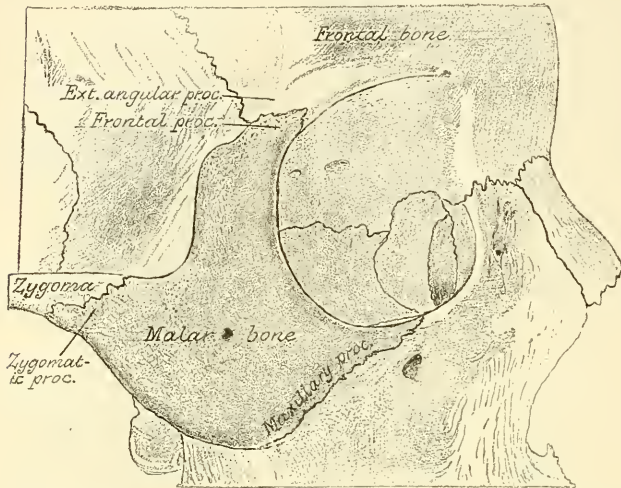
The **internal surface** (fig. 167), directed backwards and inwards, is concave, presenting internally a rough, triangular surface, for articulation with the superior maxillary bone; and externally, a smooth, concave surface, which above forms the anterior boundary of the temporal fossa, and below, where it is wider, forms part of the zygomatic fossa. This surface presents, a little above its centre, the aperture of one or two malar canals, and affords attachment to a portion of the Masseter muscle at its lower part. Of the four processes, the **frontal** is thick and serrated, and articulates with the external angular process of the frontal bone. To its orbital margin is attached the external tarsal ligament. The **orbital** process is a thick and strong plate, which projects backwards from the orbital margin of the bone. Its *supero-internal surface*

FIG. 164.—Left lachrymal bone. External surface. (Slightly enlarged.)



smooth and concave, forms, by its junction with the orbital surface of the superior maxillary bone and with the great wing of the sphenoid, part of the floor and outer wall of the orbit. Its *infero-external* surface, smooth and convex, forms part of the zygomatic and temporal fossae. Its *anterior* margin is smooth and rounded, forming part of the circumference of the orbit. Its *superior* margin, rough, and directed horizontally, articulates with the frontal bone behind the

FIG. 165.—Malar bone *in situ*.

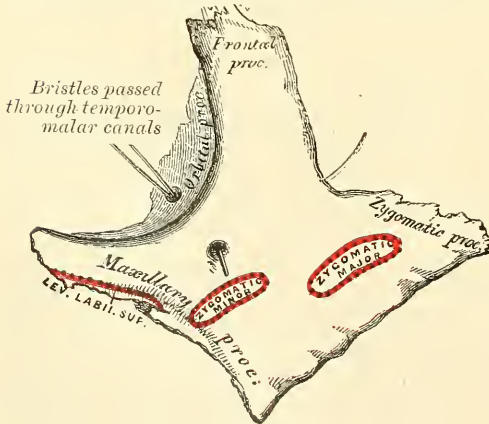


external angular process. Its *posterior* margin is rough, and serrated for articulation with the sphenoid; *internally* it is also serrated for articulation with the orbital surface of the superior maxillary. At the angle of junction of the sphenoidal and maxillary portions, a short, rounded, non-articular margin is generally seen; this forms the anterior boundary of the sphenomaxillary fissure: occasionally, no such non-articular margin exists,

the fissure being completed by the direct junction of the maxillary and sphenoid bones, or by the interposition of a small Wormian bone in the angular interval between them. On the *upper* surface of the orbital process are seen the orifices of one or two temporo-malar canals; one of these usually opens on the posterior surface, the other (occasionally two) on the facial surface: they transmit filaments

(temporo-malar) of the orbital branch of the superior maxillary nerve. The **maxillary** process is a rough, triangular surface which articulates with the superior maxillary bone. The **zygomatic** process, long, narrow, and serrated, articulates with the zygomatic process of the temporal bone. Of the **four borders**, the *antero-superior* or *orbital* is smooth, arched, and forms a considerable part of the circumference of the orbit. The *antero-inferior* or *maxillary* border is rough, and bevelled at the expense of its inner table, to articulate with the superior maxillary bone; affording attachment by its margin

FIG. 166.—Left malar bone. Outer surface.



to the Levator labii superioris proprius, just at its point of junction with the superior maxillary. The *postero-superior* or *temporal* border, curved like an italic letter *f*, is continuous above with the commencement of the temporal ridge; below, with the upper border of the zygomatic arch: it affords attachment to the temporal fascia. The *postero-inferior* or *zygomatic* border is continuous with the lower border of the zygomatic arch, affording attachment by its rough edge to the Masseter muscle.

**Development.**—The malar bone ossifies generally from two, but occasionally

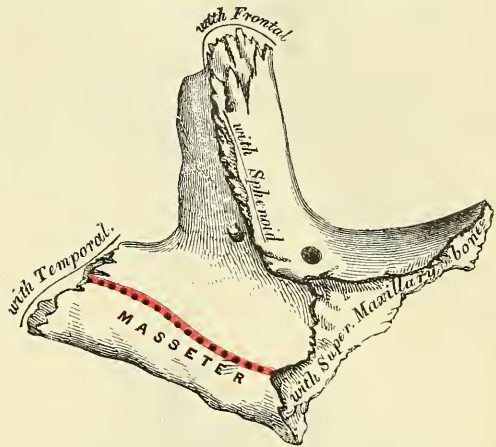


from three, centres. One, which forms the chief part of the bone, appears about the seventh week, near the orbital margin. The second appears somewhat later, along the lower margin. The third, when it exists, is found in the hinder border. The bone is sometimes, after birth, seen to be divided, by a horizontal suture, into an upper and larger division, and a lower and smaller. This divided condition is probably due to the persistent separation of the two centres of ossification. In some quadrumana the malar bone consists of two parts, an orbital and a malar, which are ossified by separate centres.

**Articulations.**—With four bones: three of the cranium, frontal, sphenoid, and temporal; and one of the face, the superior maxillary.

**Attachment of Muscles.**—To four: the Levator labii superioris proprius, Zygomaticus major and minor, and Masseter.

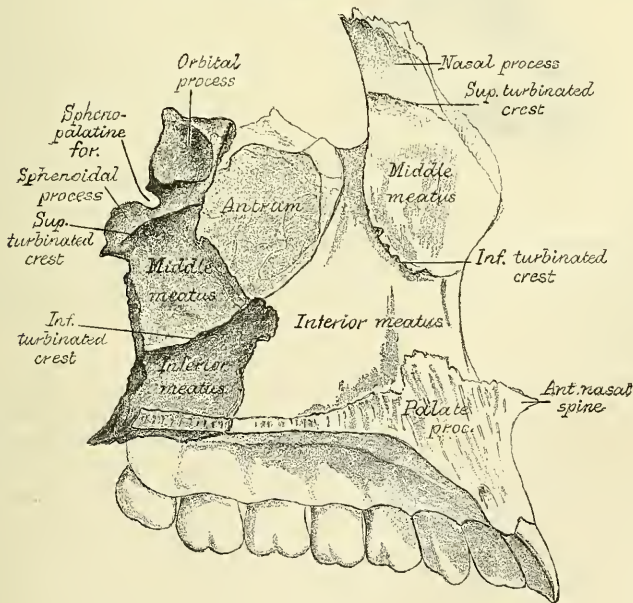
FIG. 167.—Left malar bone. Inner surface.



THE PALATE BONES

The **Palate Bones** (*palatum, the palate*) are situated at the back part of the nasal fossæ: they are wedged in between the superior maxillary bones and the pterygoid processes of the sphenoid (fig. 168). Each bone assists in the formation of three cavities: the floor and outer wall of the nose, the roof of the mouth, and the floor of the orbit; and enters into the formation of two fossæ: the

FIG. 168.—Palate bone *in situ*.



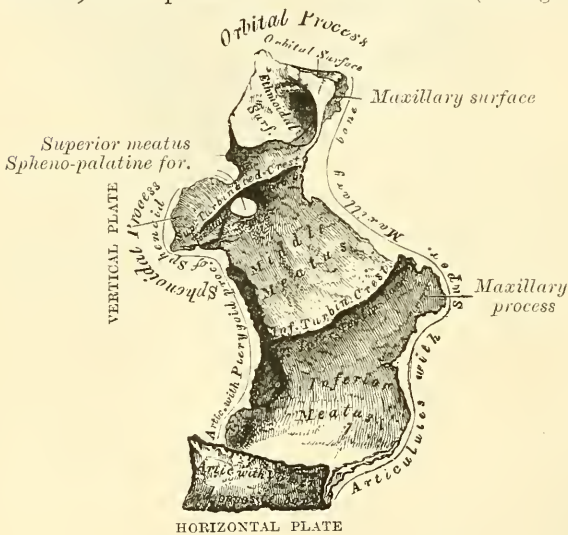
spheno-maxillary and pterygoid; and one fissure, the spheno-maxillary. In form the palate-bone somewhat resembles the letter L, and may be divided into an inferior or horizontal plate and a superior or vertical plate.

The **Horizontal Plate** is thick, of a quadrilateral form, and presents two



surfaces and four borders. The *superior* surface, concave from side to side, forms the back part of the floor of the nostril. The *inferior* surface, slightly concave and rough, forms the back part of the hard palate. At its posterior part may be seen a transverse ridge, more or less marked, for the attachment of part of the aponeurosis of the Tensor palati muscle. At the outer extremity of this ridge is a deep groove converted into a canal by its articulation with the tuberosity of the superior maxillary bone, and forming the *posterior palatine canal*. Near this groove, the orifices of one or two small canals, *accessory posterior palatine*, may be seen. The *anterior* border is serrated, bevelled at the expense of its inferior surface, and articulates with the palate process of the superior maxillary bone. The *posterior* border is concave, free, and serves for the attachment of the soft palate. Its inner extremity is sharp and pointed, and, when united with the opposite bone, forms a projecting process, the *posterior nasal spine*, for the attachment of the Azygos uvulæ. The *external* border is united with the lower part of the perpendicular plate almost at right angles. The *internal* border, the thickest, is serrated for articulation with its fellow of the opposite side; its superior edge is raised into a ridge, which, united with the opposite bone, forms a crest in which the vomer is received.

FIG. 169.—Left palate bone. Internal view. (Enlarged.)



for articulation with its fellow of the opposite side; its superior edge is raised into a ridge, which, united with the opposite bone, forms a crest in which the vomer is received.

The **Vertical Plate** (fig. 169) is thin, of an oblong form, and directed upwards and a little inwards. It presents two surfaces, an external and an internal, and four borders.

The **internal surface** presents at its lower part a broad, shallow depression, which forms part of the inferior meatus of the nose. Immediately above this is a well-marked, horizontal

ridge, the *inferior turbinate crest*, for articulation with the inferior turbinate bone; above this, a second broad, shallow depression, which forms part of the middle meatus, surmounted above by a horizontal ridge less prominent than the inferior, the *superior turbinate crest*, for articulation with the middle turbinate bone. Above the superior turbinate crest is a narrow, horizontal groove, which forms part of the superior meatus.

The **external surface** is rough and irregular throughout the greater part of its extent, for articulation with the inner surface of the superior maxillary bone, its upper and back part being smooth where it enters into the formation of the spheno-maxillary fossa; it is also smooth in front, where it covers the orifice of the antrum. Towards the back part of this surface is a deep groove, converted into a canal, the *posterior palatine*, by its articulation with the superior maxillary bone. It transmits the posterior or descending palatine vessels, and one of the descending palatine branches from Meckel's ganglion.

The *anterior* border is thin, irregular, and presents, opposite the inferior turbinate crest, a pointed, projecting lamina, the *maxillary process*, which is directed forwards, and closes in the lower and back part of the opening of the antrum. The *posterior* border (fig. 170) presents a deep groove, the edges of which are serrated for articulation with the pterygoid process of the sphenoid. At the lower part of this border is seen a pyramidal process of bone, the *pterygoid*

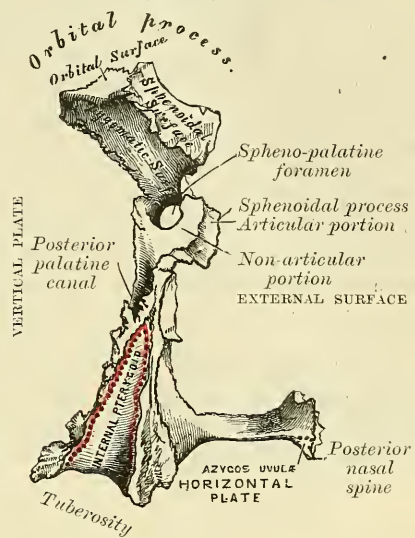
process or tuberosity of the palate, which is received into the angular interval between the two pterygoid plates of the sphenoid at their inferior extremity. This process presents at its back part a median groove and two lateral surfaces. The groove is smooth, and forms part of the pterygoid fossa affording attachment to the Internal pterygoid muscle; whilst the lateral surfaces are rough and uneven, for articulation with the anterior border of each pterygoid plate. A few fibres of the Superior constrictor arise from the tuberosity of the palate-bone. The base of this process, continuous with the horizontal portion of the bone, presents the apertures of the *accessory descending palatine canals*, through which pass the two smaller descending branches of Meckel's ganglion; whilst its outer surface is rough for articulation with the inner surface of the body of the superior maxillary bone.

The *superior* border of the vertical plate presents two well-marked processes separated by an intervening notch or foramen. The anterior, or larger, is called the *orbital process*; the posterior, the *sphenoidal*.

The **Orbital Process**, directed upwards and outwards, is placed on a higher level than the sphenoidal. It presents five surfaces, which enclose a hollow cellular cavity, and is connected to the perpendicular plate by a narrow, constricted neck. Of these five surfaces, three are articular, two non-articular or free surfaces. The three articular are the *anterior* or *maxillary* surface, which is directed forwards, outwards, and downwards, is of an oblong form, and rough for articulation with the superior maxillary bone. The *posterior* or *sphenoidal* surface is directed backwards, upwards, and inwards. It ordinarily presents a small, open cell, which communicates with the sphenoidal cells, and the margins of which are serrated for articulation with the vertical part of the sphenoidal turbinated bone. The *internal* or *ethmoidal* surface is directed inwards, upwards, and forwards, and articulates with the lateral mass of the ethmoid bone. In some cases, the cellular cavity above mentioned opens on this surface of the bone; it then communicates with the posterior ethmoidal cells. More rarely it opens on both surfaces, and then communicates both with the posterior ethmoidal and the sphenoidal cells. The non-articular or free surfaces are the *superior* or *orbital*, directed upwards and outwards, of triangular form, concave, smooth, and forming the back part of the floor of the orbit; and the *external* or *zygomatic* surface, directed outwards, backwards, and downwards, of an oblong form, smooth, lying in the speno-maxillary fossa, and looking into the zygomatic fossa. The latter surface is separated from the orbital by a smooth, rounded border, which enters into the formation of the speno-maxillary fissure.

The **Sphenoidal Process** of the palate-bone is a thin, compressed plate, much smaller than the orbital, and directed upwards and inwards. It presents three surfaces and two borders. The *superior* surface, the smallest of the three, articulates with the under surface of the sphenoidal turbinated bone; it presents a groove, which contributes to the formation of the pterygo-palatine canal. The *internal* surface is concave, and forms part of the outer wall of the nasal fossa. The *external* surface is divided into an articular and non-articular portion: the

FIG. 170.—Left palate bone. Posterior view. (Enlarged.)





former is rough, for articulation with the inner surface of the internal pterygoid plate of the sphenoid; the latter is smooth, and forms part of the sphenomaxillary fossa. The *anterior* border forms the posterior boundary of the sphenopalatine foramen. The *posterior* border, serrated at the expense of the outer table, articulates with the inner surface of the internal pterygoid plate.

The orbital and sphenoidal processes are separated from one another by a deep notch, which is converted into a foramen, the *spheno-palatine*, by articulation with the sphenoidal turbinated bone. Sometimes the two processes are united above, and form between them a complete foramen, or the notch is crossed by one or more spiculæ of bone, so as to form two or more foramina. In the articulated skull, this foramen opens into the back part of the outer wall of the superior meatus, and transmits the spheno-palatine vessels and the superior nasal and naso-palatine nerves.

**Development.**—From a single centre, which makes its appearance about the second month at the angle of junction of the two plates of the bone. From this point ossification spreads inwards to the horizontal plate, downwards into the tuberosity, and upwards into the vertical plate. In the fœtus, the horizontal plate is much longer than the vertical; and even after it is fully ossified, the whole bone is at first remarkable for its shortness.

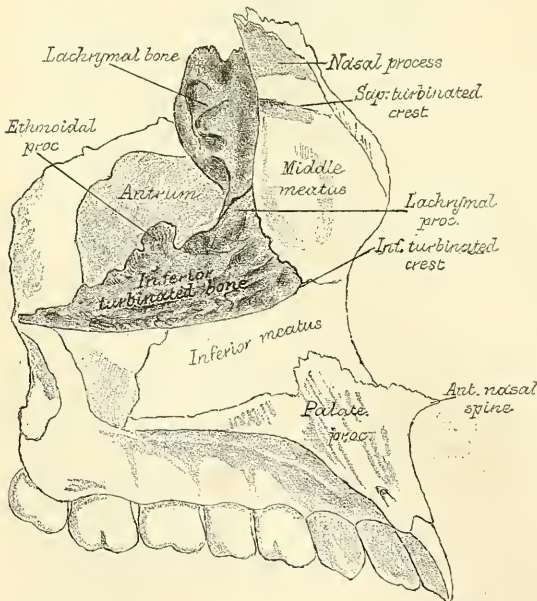
**Articulations.**—With six bones: the sphenoid, ethmoid, superior maxillary, inferior turbinated, vomer, and opposite palate.

**Attachment of Muscles.**—To four: the Tensor palati, Azygos uvulæ, Internal pterygoid, and Superior constrictor of the pharynx.

#### THE INFERIOR TURBINATED BONES

The **Inferior Turbinated Bones** (*turbo, a whirl*) are situated one on each side of the outer wall of the nasal fossæ. Each consists of a layer of thin, spongy

FIG. 171.—Inferior turbinated bone and Lachrymal bone *in situ*.



bone, curled upon itself like a scroll—hence its name ‘turbinated’—and extends horizontally along the outer wall of the nasal fossa, immediately below the orifice of the antrum (fig. 171). Each bone presents two surfaces, two borders, and two extremities.

The **internal surface** (fig. 172) is convex, perforated by numerous apertures, and traversed by longitudinal grooves and canals for the lodgment of arteries and veins. In the recent state it is covered by the lining membrane of the nose. The **external surface** is concave (fig. 173), and forms part of the inferior meatus. Its *upper border* is thin, irregular, and connected to various bones along the outer wall of the nose. It may be divided into three portions; of these, the anterior

articulates with the inferior turbinated crest of the superior maxillary bone; the posterior with the inferior turbinated crest of the palate-bone; the middle portion of the superior border presents three well-marked processes, which vary much in their size and form. Of these, the anterior and smallest is situated at the



junction of the anterior fourth with the posterior three-fourths of the bone: it is small and pointed, and is called the *lachrymal process*; it articulates, by its apex, with the anterior inferior angle of the lachrymal bone, and, by its margins, with the groove on the back of the nasal process of the superior maxillary, and thus assists in forming the canal for the nasal duct. At the junction of the two middle fourths of the bone, but encroaching on its posterior fourth, a broad, thin plate, the *ethmoidal process*, ascends to join the unciform process of the ethmoid; from the lower border of this process a thin lamina of bone curves downwards and outwards, hooking over the lower edge of the orifice of the antrum, which it narrows below: it is called the *maxillary process*, and fixes the bone firmly on to the outer wall of the nasal fossa. The *inferior border* is free, thick, and cellular in structure, more especially in the middle of the bone. Both *extremities* are more or less narrow and pointed, the posterior being the more tapering. If the bone is held so that its outer concave surface is directed backwards (i.e. towards the holder), and its superior border, from which the

FIG. 172.—Right inferior turbinate bone.  
Internal surface.

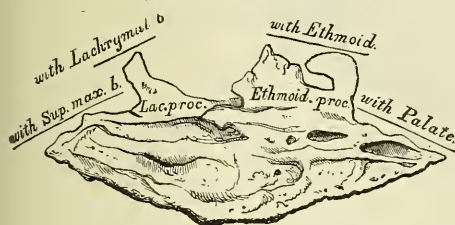
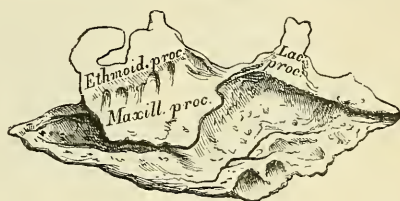


FIG. 173.—Right inferior turbinate bone.  
External surface.



lachrymal and ethmoidal processes project, upwards, the lachrymal process will be directed to the side to which the bone belongs.\*

**Development.**—By a single centre, which makes its appearance about the middle of foetal life.

**Articulations.**—With four bones: one of the cranium, the ethmoid, and three of the face, the superior maxillary, lachrymal, and palate.

No muscles are attached to this bone.

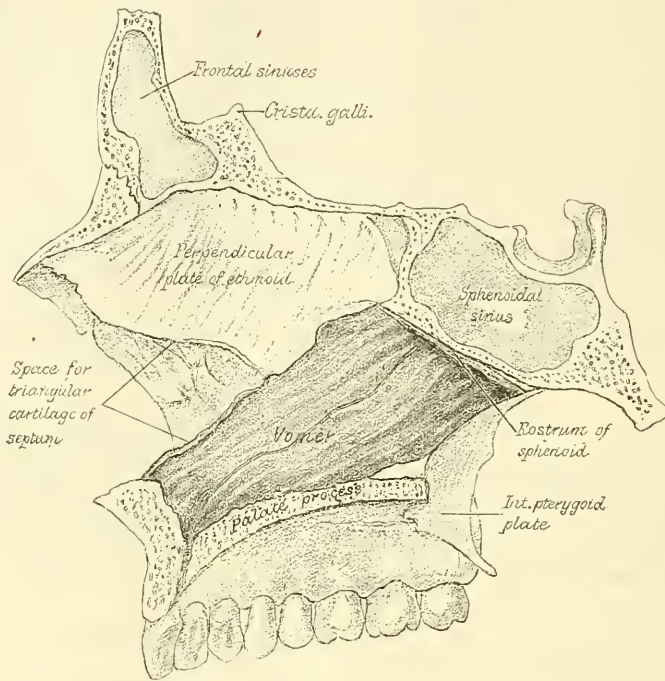
### THE VOMER

The **Vomer** (vomer, a *ploughshare*) is a single bone, situated vertically at the back part of the nasal fossæ, forming part of the septum of the nose (fig. 174). It is thin, somewhat like a ploughshare in form; but it varies in different individuals, being frequently bent to one or the other side; it presents for examination two surfaces and four borders. The *lateral surfaces* are smooth, marked by small furrows for the lodgment of blood-vessels, and by a groove on each side, sometimes a canal, the *naso-palatine*, which runs obliquely downwards and forwards to the intermaxillary suture; it transmits the naso-palatine nerve. The *superior border*, the thickest, presents a deep groove, bounded on each side by a horizontal projecting ala of bone; the groove receives the rostrum of the sphenoid, whilst the alæ are overlapped and retained by laminae (the *vaginal processes*) which project from the under surface of the body of the sphenoid at the base of the pterygoid processes. At the front of the groove a fissure is left for the transmission of blood-vessels to the substance of the bone. The *inferior border*, the longest, is broad and uneven in front, where it articulates with the two superior maxillary bones; thin and sharp behind, where it joins with the palate-bones. The upper half of the *anterior border* usually consists of two

\* If the lachrymal process is broken off, as is often the case, the side to which the bone belongs may be known by recollecting that the maxillary process is nearer the back than the front of the bone.

laminae of bone, between which is received the perpendicular plate of the ethmoid; the lower half, also separated into two lamellae, receives between them the lower margin of the triangular cartilage of the nose. The *posterior border* is

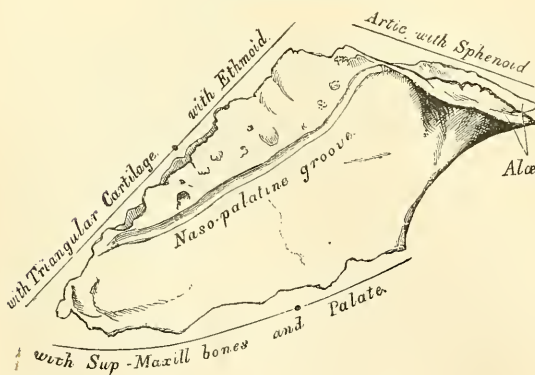
FIG. 174.—Vomer *in situ*.



free, concave, and separates the nasal fossae behind. It is thick and bifid above, thin below.

The surfaces of the vomer are covered by mucous membrane, which is intimately connected with the periosteum, with the intervention of very little, if any, submucous connective tissue.

FIG. 175.—The vomer.



Hence polypi are rarely found growing from this surface, though they frequently grow from the outer wall of the nasal fossae, where the submucous tissue is abundant.

**Development.**—The vomer at an early period consists of two laminae, separated by a very considerable interval, and enclosing between them a plate of cartilage, which is prolonged forwards to form the remainder of the septum. Ossification commences in it

by a single centre about the eighth week. From this nucleus the two laminae are formed. They begin to coalesce at the lower part, but their union is not complete until after puberty.

**Articulations.**—With six bones: two of the cranium, the sphenoid and ethmoid; and four of the face, the two superior maxillary and the two palate-bones; and with the cartilage of the septum.

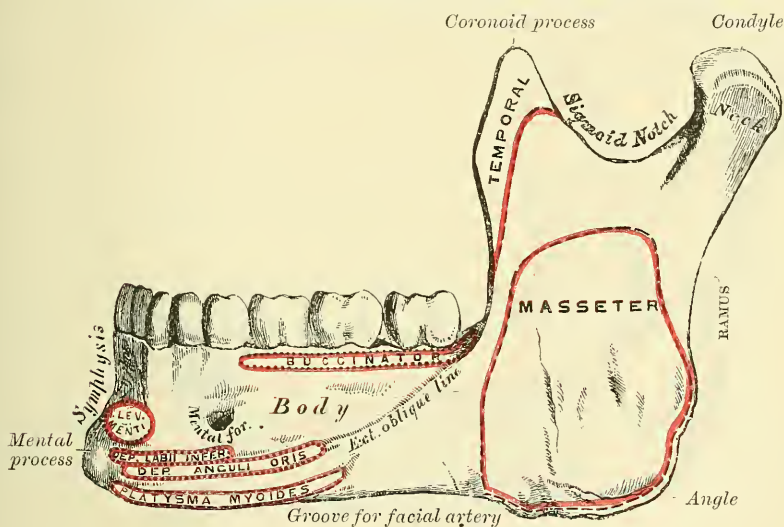
The vomer has no muscles attached to it.

THE INFERIOR MAXILLARY BONE

The **Inferior Maxillary Bone** (the *Mandible*), the largest and strongest bone of the face, serves for the reception of the lower teeth. It consists of a curved, horizontal portion, the *body*, and two perpendicular portions, the *rami*, which join the back part of the body nearly at right angles.

The **Horizontal Portion**, or **Body** (fig. 176), is convex in its general outline, and curved somewhat like a horse-shoe. It presents for examination two surfaces and two borders. The **external surface** is convex from side to side, concave from above downwards. In the median line is a vertical ridge, the *symphysis*, which extends from the upper to the lower border of the bone, and indicates the point of junction of the two pieces of which the bone is composed at an early period of life. The lower part of the ridge terminates in a prominent triangular eminence, the *mental process*. This eminence is rounded below, and often presents a median depression separating two processes, the *mental tubercles*. It forms the chin, a feature peculiar to the human skull. On either side of the symphysis,

FIG. 176.—Inferior maxillary bone. Outer surface. Side view.



just below the cavities for the incisor teeth, is a depression, the *incisive fossa*, for the attachment of the Levator menti (or Levator labii inferioris); more externally is attached a portion of the Orbicularis oris (*Accessorii Orbicularis inferioris*), and, still more externally, a foramen, the *mental foramen*, for the passage of the mental vessels and nerve. This foramen is placed just below the interval between the two bicuspid teeth. Running outwards from the base of the mental process on each side is a ridge, the *external oblique line*. The ridge is at first nearly horizontal, but afterwards inclines upwards and backwards, and is continuous with the anterior border of the ramus: it affords attachment to the Depressor labii inferioris and Depressor anguli oris; below it the Platysma myoides is attached.

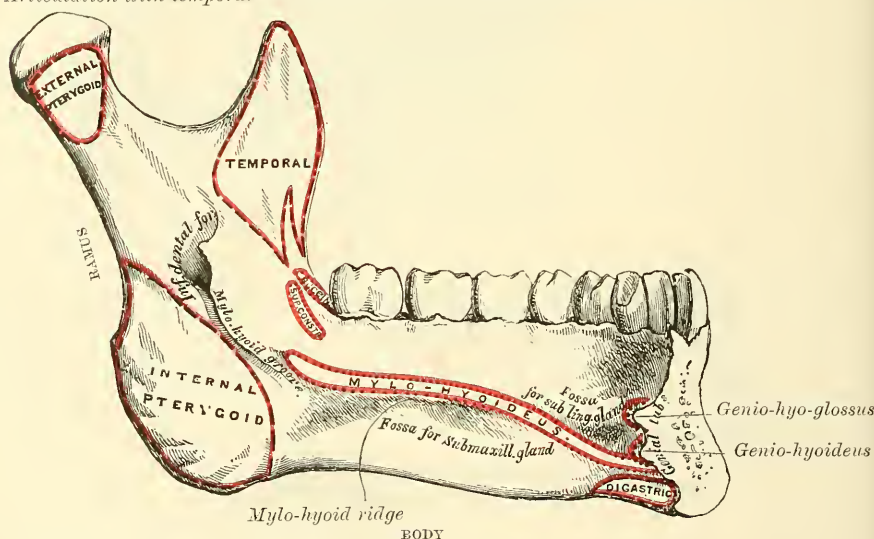
The **internal surface** (fig. 177) is concave from side to side, convex from above downwards. In the middle line is an indistinct linear depression, corresponding to the symphysis externally; on either side of this depression, just below its centre, are four prominent tubercles, placed in pairs, two above and two below; they are called the *genial tubercles*, and afford attachment, the upper pair to the Genio-hyo-glossi muscles, the lower pair to the Genio-hyoidei muscles. Sometimes the tubercles on each side are blended into one, at others they all unite into



an irregular eminence, or again, nothing but an irregularity may be seen on the surface of the bone at this part. On either side of the genial tubercles is an oval depression, the *sublingual fossa*, for lodging the sublingual gland; and beneath the fossa, a rough depression on each side, which gives attachment to the anterior belly of the Digastric muscle. At the back part of the sublingual fossa, the *internal oblique line (mylo-hyoidean)* commences; it is at first faintly marked, but becomes more distinct as it passes upwards and outwards, and is especially prominent opposite the last two molar teeth; it affords attachment throughout its whole extent to the Mylo-hyoid muscle: the Superior constrictor of the pharynx with the pterygo-maxillary ligament, being attached above its posterior extremity, near the alveolar margin. The portion of bone above this ridge is smooth, and covered by the mucous membrane of the mouth; the portion below presents an oblong depression, the *submaxillary fossa*, wider behind than in front, for the lodgment of the submaxillary gland. The external oblique line and the internal or mylo-hyoidean line divide the body of the bone into a superior or alveolar and an inferior or basilar portion.

FIG. 177.—Inferior maxillary bone. Inner surface. Side view.

Articulation with temporal



The **superior** or **alveolar** border is wider, and its margins thicker, behind than in front. It is hollowed into numerous cavities, for the reception of the teeth; these cavities are sixteen in number, and vary in depth and size according to the teeth which they contain. To its outer side, the Buccinator muscle is attached as far forward as the first molar tooth. The **inferior** border is rounded, longer than the superior and thicker in front than behind; it presents a shallow groove, just where the body joins the ramus, over which the facial artery turns.

The **Perpendicular Portions**, or **Rami**, are of a quadrilateral form. Each presents for examination two surfaces, four borders, and two processes. The *external surface* is flat, marked with ridges, and gives attachment throughout nearly the whole of its extent to the Masseter muscle. The *internal surface* presents about its centre the oblique aperture of the inferior dental canal, for the passage of the inferior dental vessels and nerve. The margin of this opening is irregular; it presents in front a prominent ridge, surmounted by a sharp spine, the *lingula*, which gives attachment to the internal lateral ligament of the lower jaw, and at its lower and back part a notch leading to a groove, the *mylo-hyoidean*, which runs obliquely downwards to the back part of the submaxillary fossa,

and lodges the mylo-hyoid vessels and nerve. Behind the groove is a rough surface, for the insertion of the Internal pterygoid muscle. The inferior dental canal runs obliquely downwards and forwards in the substance of the ramus, and then horizontally forwards in the body; it is here placed under the alveoli, with which it communicates by small openings. On arriving at the incisor teeth, it turns back to communicate with the mental foramen, giving off two small canals, which run forward, to be lost in the cancellous tissue of the bone beneath the incisor teeth. This canal, in the posterior two-thirds of the bone, is situated nearer the internal surface of the jaw; and in the anterior third, nearer its external surface. Its walls are composed of compact tissue at either extremity, and of cancellous in the centre. It contains the inferior dental vessels and nerve, from which branches are distributed to the teeth through small apertures at the bases of the alveoli. The *lower border* of the ramus is thick, straight, and continuous with the body of the bone. At its junction with the posterior border is the *angle of the jaw*, which is either inverted or everted, and marked by rough, oblique ridges on each side, for the attachment of the Masseter externally, and the Internal pterygoid internally; the stylo-maxillary ligament is attached to the bone between these muscles. The *anterior border* is thin above, thicker below, and continuous with the external oblique line. The *posterior border* is thick, smooth, rounded, and covered by the parotid gland. The *upper border* of the ramus is thin, and presents two processes, separated by a deep concavity, the *sigmoid notch*. Of these processes, the anterior is the *coronoid*, the posterior the *condyloid*.

The **Coronoid Process** is a thin, flattened triangular eminence of bone, which varies in shape and size in different subjects, and serves chiefly for the attachment of the Temporal muscle. Its *external surface* is smooth, and affords attachment to the Temporal muscle. Its *internal surface* gives attachment to the Temporal muscle, and presents the commencement of a longitudinal ridge, which is continued to the posterior part of the alveolar process. On the outer side of this ridge is a deep groove, continued below on the outer side of the alveolar process; this ridge and part of the groove afford attachment, above, to the Temporal; below, to the Buccinator muscle.

The **Condyloid Process**, shorter but thicker than the coronoid, consists of two portions: the *condyle*, and the constricted portion which supports the condyle, the *neck*. The *condyle* is of an oblong form, its long axis being transverse, and set obliquely on the neck in such a manner that its outer end is a little more forward and a little higher than its inner. It is convex from before backwards, and from side to side, the articular surface extending further on the posterior than on the anterior aspect. At its outer extremity is a small tubercle for the attachment of the external lateral ligament of the temporo-maxillary joint. The *neck* of the condyle is flattened from before backwards, and strengthened by ridges which descend from the fore part and sides of the condyle. Its lateral margins are narrow, and present externally a tubercle for the external lateral ligament. Its posterior surface is convex; its anterior is hollowed out on its inner side by a depression (the *pterygoid fossa*) for the attachment of the External pterygoid.

The **Sigmoid Notch**, separating the two processes, is a deep semilunar depression, crossed by the masseteric vessels and nerve.

**Development.**—The lower jaw is developed principally from membrane, but partly from cartilage. The process of ossification commences early—earlier than any other bone except the clavicle. Between the fifth and sixth week a centre of ossification appears in the membrane on the outer surface of Meckel's cartilage (see page 93), from which the greater part of the bone is formed. A second centre appears in the membrane on the inner surface of the tooth sockets, from which the inner wall of the sockets of the teeth is formed; this terminates above in the lingula. The anterior extremity of Meckel's cartilage becomes ossified, forming the body of the bone on each side of the symphysis. And, finally, two

## SIDE VIEW OF THE LOWER JAW AT DIFFERENT PERIODS OF LIFE

FIG. 178.—At birth.

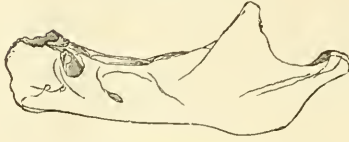

FIG. 179.—At puberty.

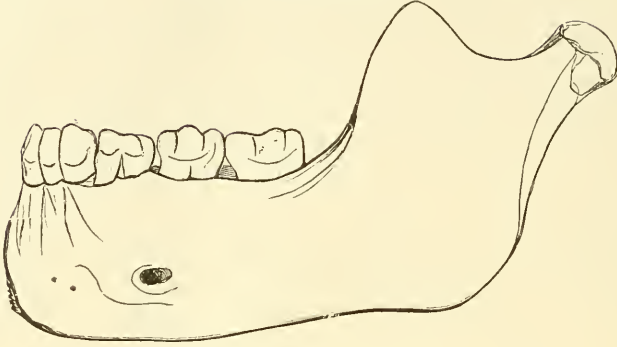


FIG. 180.—In the adult.

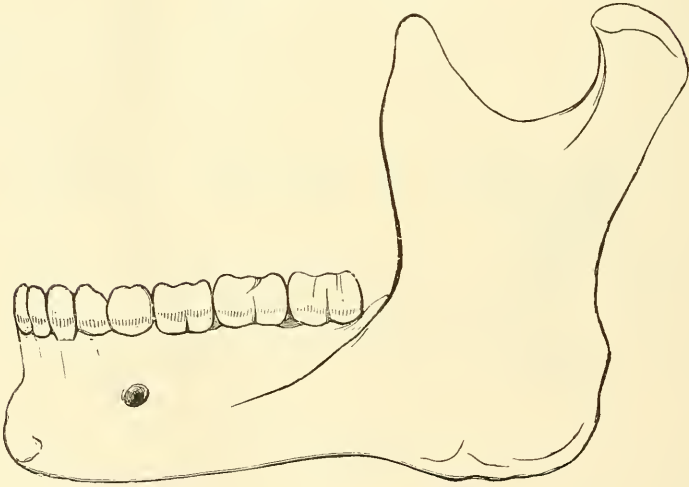
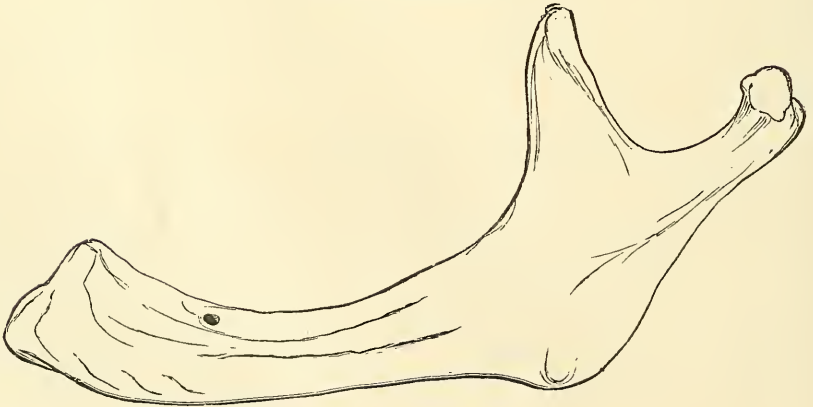


FIG. 181.—In old age.





supplemental patches of cartilage appear at the condyle and at the angle, in which centres of ossification for these parts appear. At birth the bone consists of two halves, united by a fibrous symphysis, in which ossification takes place during the first year.

**Articulation.**—With the glenoid fossæ of the two temporal bones.

**Attachment of Muscles.**—To fifteen pairs; to its external surface, commencing at the symphysis, and proceeding backwards: Levator menti, Depressor labii inferioris, Depressor anguli oris, Platysma myoides, Buccinator, Masseter; a portion of the Orbicularis oris (Accessorii Orbicularis inferioris) is also attached to this surface. To its internal surface, commencing at the same point: Genio-hyo-glossus, Genio-hyoideus, Mylo-hyoideus, Digastric, Superior constrictor, Temporal, Internal pterygoid, External pterygoid.

#### CHANGES PRODUCED IN THE LOWER JAW BY AGE

The changes which the Lower Jaw undergoes after birth, relate (1) to the alterations effected in the body of the bone by the first and second dentitions, the loss of the teeth in the aged, and the subsequent absorption of the alveoli; (2) to the size and situation of the dental canal; and (3) to the angle at which the ramus joins with the body.

*At birth* (fig. 178), the bone consists of lateral halves, united by fibrous tissue. The body is a mere shell of bone, containing the sockets of the two incisor, the canine, and the two temporary molar teeth, imperfectly partitioned from one another. The dental canal is of large size, and runs near the lower border of the bone, the mental foramen opening beneath the socket of the first molar. The angle is obtuse ( $175^\circ$ ), and the condyloid portion nearly in the same horizontal line with the body; the neck of the condyle is short, and bent backwards. The coronoid process is of comparatively large size, and situated at right angles with the rest of the bone.

*After birth* (fig. 179), the two segments of the bone become joined at the symphysis, from below upwards, in the first year; but a trace of separation may be visible in the beginning of the second year, near the alveolar margin. The body becomes elongated in its whole length, but more especially behind the mental foramen, to provide space for the three additional teeth developed in this part. The depth of the body becomes greater, owing to increased growth of the alveolar part, to afford room for the fangs of the teeth, and by thickening of the subdental portion which enables the jaw to withstand the powerful action of the masticatory muscles; but the alveolar portion is the deeper of the two and, consequently, the chief part of the body lies above the oblique line. The dental canal, after the second dentition, is situated just above the level of the mylo-hyoid ridge; and the mental foramen occupies the position usual to it in the adult. The angle becomes less obtuse, owing to the separation of the jaws by the teeth. (About the fourth year it is  $140^\circ$ .)

*In the adult* (fig. 180), the alveolar and basilar portions of the body are usually of equal depth. The mental foramen opens midway between the upper and lower border of the bone, and the dental canal runs nearly parallel with the mylo-hyoid line. The ramus is almost vertical in direction, and joins the body nearly at right angles.

*In old age* (fig. 181), the bone becomes greatly reduced in size: for with the loss of the teeth the alveolar process is absorbed, and the basilar part of the bone alone remains; consequently, the chief part of the bone is *below* the oblique line. The dental canal, with the mental foramen opening from it, is close to the alveolar border. The rami are oblique in direction, the angle obtuse, and the neck of the condyle more or less bent backwards.

#### THE SUTURES

The bones of the cranium and face are connected to each other by means of *Sutures*. That is, the articulating surfaces or edges of the bones are more or less roughened or uneven, and are closely adapted to each other, a small amount of intervening fibrous tissue fastening them together. The *Cranial Sutures* may be divided into three sets: 1. Those at the vertex of the skull. 2. Those at the side of the skull. 3. Those at the base.

The sutures at the vertex of the skull are three: the *sagittal*, *coronal*, and *lambdoid*.

The **Sagittal Suture** (*interparietal*) is formed by the junction of the two parietal bones, and extends from the middle of the frontal bone, backwards to the superior angle of the occipital. In childhood, and occasionally in the adult, when the two halves of the frontal bone are not united, it is continued forwards

to the root of the nose. This suture is sometimes perforated, near its posterior extremity, by the parietal foramen; and in front, where it joins the coronal suture, a space is occasionally left, which encloses a large Wormian bone.

The **Coronal Suture** (*fronto-parietal*) extends transversely across the vertex of the skull, and connects the frontal with the parietal bones. It commences at the extremity of the greater wing of the sphenoid on one side, and terminates at the same point on the opposite side. The dentations of the suture are more marked at the sides than at the summit, and are so constructed that the frontal rests on the parietal above, whilst laterally the frontal supports the parietal.

The **Lambdoid Suture** (*occipito-parietal*), so called from its resemblance to the Greek letter  $\Lambda$ , connects the occipital with the parietal bones. It commences on each side at the mastoid portion of the temporal bone, and inclines upwards to the end of the sagittal suture. The dentations of this suture are very deep and distinct, and are often interrupted by several small Wormian bones.

The sutures at the side of the skull extend from the external angular process of the frontal bone to the lower end of the lambdoid suture behind. The anterior portion is formed between the lateral part of the frontal bone above and the malar and great wing of the sphenoid below, forming the *fronto-malar* and *fronto-sphenoidal* sutures. These sutures can also be seen in the orbit, and form part of the so-called *transverse facial* suture. The posterior portion is formed between the parietal bone above and the great wing of the sphenoid, the squamous and mastoid portions of the temporal bone, forming the *spheno-parietal*, *squamo-parietal*, and *masto-parietal* sutures.

The **Spheno-parietal** is very short; it is formed by the tip of the great wing of the sphenoid, which overlaps the anterior inferior angle of the parietal bone.

The **Squamo-parietal**, or **Squamous Suture**, is arched. It is formed by the squamous portion of the temporal bone overlapping the middle division of the lower border of the parietal.

The **Masto-parietal** is a short suture, deeply dentated, formed by the posterior inferior angle of the parietal, and the superior border of the mastoid portion of the temporal.

The sutures at the base of the skull are, the *basilar* in the centre, and on each side, the *petro-occipital*, the *masto-occipital*, the *petro-sphenoidal*, and the *squamo-sphenoidal*.

The **Basilar Suture** is formed by the junction of the basilar surface of the occipital bone with the posterior surface of the body of the sphenoid. At an early period of life a thin plate of cartilage exists between these bones; but in the adult they become fused into one. Between the outer extremity of the basilar suture and the termination of the lambdoid, an irregular suture exists, which is subdivided into two portions. The inner portion, formed by the union of the petrous part of the temporal with the occipital bone, is termed the **petro-occipital**. The outer portion, formed by the junction of the mastoid part of the temporal with the occipital, is called the **masto-occipital**. Between the bones forming the petro-occipital suture, a thin plate of cartilage exists; in the masto-occipital is occasionally found the opening of the mastoid foramen. Between the outer extremity of the basilar suture and the spheno-parietal, an irregular suture may be seen, formed by the union of the sphenoid with the temporal bone. The inner and smaller portion of this suture is termed the **petro-sphenoidal**; it is formed between the petrous portion of the temporal and the great wing of the sphenoid: the outer portion, of greater length, and arched, is formed between the squamous portion of the temporal and the great wing of the sphenoid; it is called the **squamo-sphenoidal**.

The cranial bones are connected with those of the face, and the facial bones with each other, by numerous sutures, which, though distinctly marked, have received no special names. The only remaining suture deserving especial consideration is the **transverse**. This extends across the upper part of the face, and is formed by the junction of the frontal with the facial bones; it extends from the



external angular process of one side to the same point on the opposite side, and connects the frontal with the malar, the sphenoid, the ethmoid, the lachrymal, the superior maxillary, and the nasal bones on each side.

The sutures remain separate for a considerable period after the complete formation of the skull. It is probable that they serve the purpose of permitting the growth of the bones at their margins; while their peculiar formation, together with the interposition of the sutural ligament between the bones forming them, prevents the dispersion of blows or jars received upon the skull. Humphry remarks 'that, as a general rule, the sutures are first obliterated at the parts in which the ossification of the skull was last completed—viz. in the neighbourhood of the fontanelles; and the cranial bones seem in this respect to observe a similar law to that which regulates the union of the epiphyses to the shafts of the long bones.' The same author remarks that the time of their disappearance is extremely variable: they are sometimes found well marked in skulls edentulous with age, while in others which have only just reached maturity they can hardly be traced.

### THE SKULL AS A WHOLE

The Skull, formed by the union of the several cranial and facial bones already described, when considered as a whole, is divisible into five regions: a superior region or vertex, an inferior region or base, two lateral regions, and an anterior region, the face.

#### VERTEX OF THE SKULL

The **Superior Region, or Vertex**, presents two surfaces, an external and an internal.

The **external surface** is bounded, in front, by the glabella and supra-orbital ridges; behind, by the occipital protuberance and superior curved lines of the occipital bone; laterally, by an imaginary line extending from the outer end of the superior curved line, along the temporal ridge, to the external angular process of the frontal. This surface includes the vertical portion of the frontal, the greater part of the parietal, and the superior third of the occipital bone; it is smooth, convex, of an elongated oval form, crossed transversely by the coronal suture, and from before backwards by the sagittal, which terminates behind in the lambdoid. The point of junction of the coronal and sagittal sutures is named the *bregma*, and is represented by a line drawn vertically upwards from the external auditory meatus, the head being in its normal position. The point of junction of the sagittal and lambdoid sutures is called the *lambda*, and is about  $2\frac{3}{4}$  inches above the external occipital protuberance. From before backwards may be seen the frontal eminences and remains of the suture connecting the two lateral halves of the frontal bone; on each side of the sagittal suture are the parietal foramen and parietal eminence, and still more posteriorly the convex surface of the occipital bone. In the neighbourhood of the parietal foramen the skull is often flattened, and to this region the name of *obelion* is sometimes given.

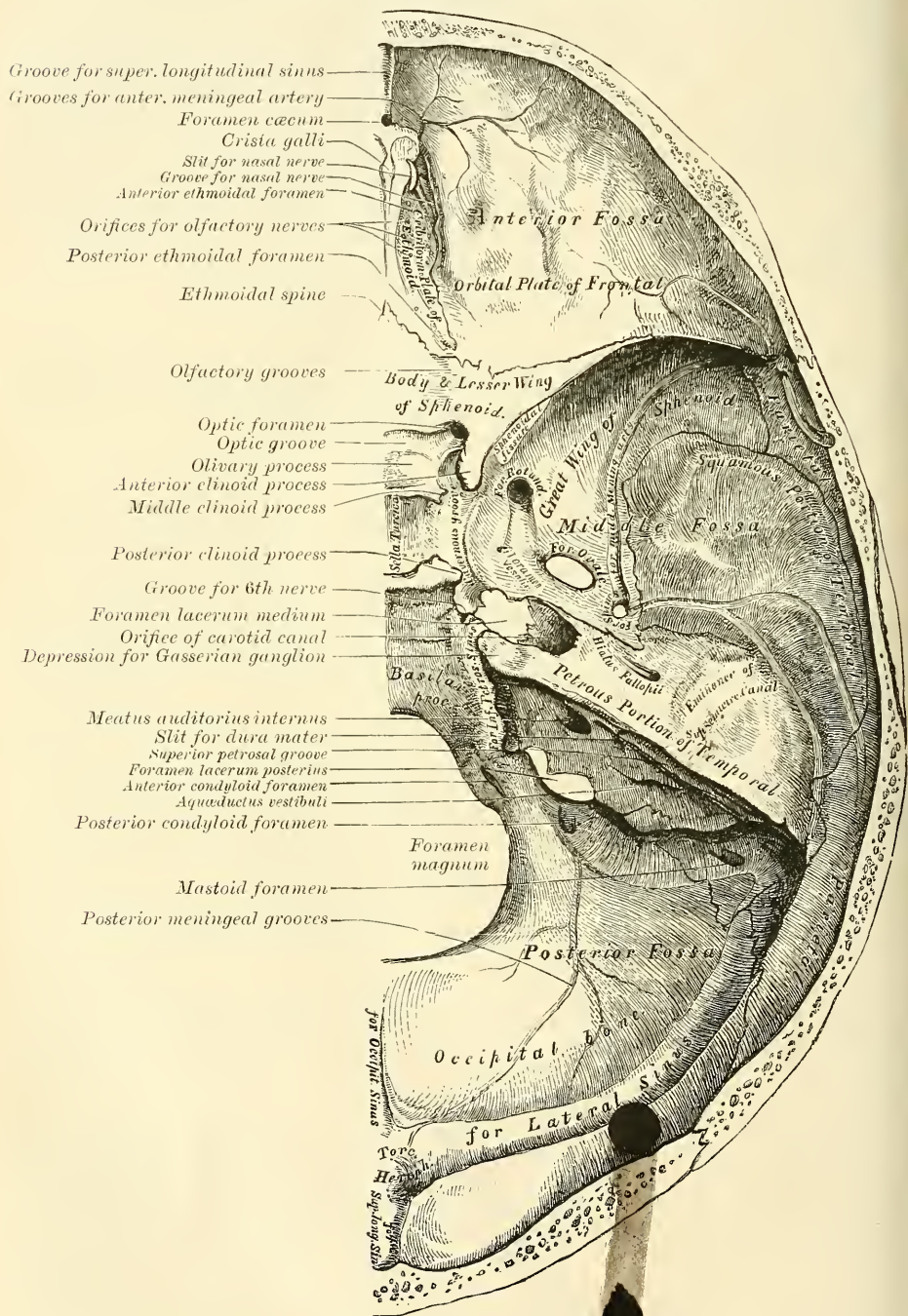
The **internal surface** is concave, presents eminences and depressions for the convolutions of the cerebrum, and numerous furrows for the lodgment of branches of the meningeal arteries. Along the middle line of this surface is a longitudinal groove, narrow in front, where it commences at the frontal crest; but broader behind, where it lodges the superior longitudinal sinus, and by its margin affords attachment to the falx cerebri. On either side of it are several depressions for the Pacchionian bodies, and at its back part, the internal openings of the parietal foramina. This surface is crossed, in front, by the coronal suture; from before backwards, by the sagittal; behind by the lambdoid.



## BASE OF THE SKULL

The **Inferior Region**, or **Base of the Skull**, presents two surfaces—an internal or cerebral, and an external or basilar.

FIG. 182.—Base of the skull. Inner or cerebral surface.



The **internal** or **cerebral surface** (fig. 182) presents three fossæ, called the *anterior*, *middle*, and *posterior* fossæ of the cranium.

The **Anterior Fossa** is formed by the orbital plates of the frontal, the cribriform

plate of the ethmoid, the anterior third of the superior surface of the body, and the upper surface of the lesser wings of the sphenoid. It is the most elevated of the three fossæ, convex externally where it corresponds to the roof of the orbit, concave in the median line in the situation of the cribriform plate of the ethmoid. It is traversed by three sutures, the *ethmo-frontal*, *ethmo-sphenoidal*, and *fronto-sphenoidal*; and lodges the frontal lobes of the cerebrum. It presents, in the median line, from before backwards, the commencement of the *groove* for the superior longitudinal sinus, and the *frontal crest* for the attachment of the falx cerebri; the *foramen cæcum*, an aperture formed between the frontal bone and the crista galli of the ethmoid, which, if pervious, transmits a small vein from the nose to the superior longitudinal sinus; behind the foramen cæcum, the *crista galli*, the posterior margin of which affords attachment to the falx cerebri; on either side of the crista galli, the *olfactory groove*, which supports the bulb of the olfactory tract, and presents three rows of foramina for its filaments, and in front a slit-like opening for the nasal branch of the ophthalmic division of the fifth nerve. On the outer side of each olfactory groove are the internal openings of the *anterior* and *posterior ethmoidal foramina*; the former, situated about the middle of the outer margin of the olfactory groove, transmits the anterior ethmoidal vessels and the nasal nerve, which latter runs in a depression along the surface of the ethmoid, to the slit-like opening above mentioned; whilst the posterior ethmoidal foramen opens at the back part of this margin under cover of the projecting lamina of the sphenoid, and transmits the posterior ethmoidal vessels. Further back in the middle line is the *ethmoidal spine*, bounded behind by an elevated ridge, separating two longitudinal grooves which support the olfactory tracts. Behind this is a transverse sharp ridge, running outwards on either side to the anterior margin of the optic foramen, and separating the anterior from the middle fossa of the base of the skull. The anterior fossa presents, laterally, eminences and depressions for the convolutions of the brain, and grooves for the lodgment of the anterior meningeal arteries.

The **Middle Fossa**, deeper than the preceding, is narrow in the middle line, but becomes wider at the side of the skull. It is bounded in front by the posterior margin of the lesser wing of the sphenoid, the anterior clinoid process, and the ridge forming the anterior margin of the optic groove; behind, by the superior border of the petrous portion of the temporal, and the dorsum ephippii; externally by the squamous portion of the temporal, anterior inferior angle of the parietal bone, and greater wing of the sphenoid. It is traversed by four sutures, the squamo-parietal, spheno-parietal, squamo-sphenoidal, and petro-sphenoidal.

In the middle line, from before backwards, is the *optic groove*, which supports the optic commissure, and terminates on each side in the optic foramen, for the passage of the optic nerve and ophthalmic artery; behind the optic groove is the *olivary process*, and laterally the *anterior clinoid processes*, to which are attached processes of the tentorium cerebelli. Further back is the *sella turcica*, a deep depression, which lodges the pituitary gland, bounded in front by a small eminence on either side, the *middle clinoid process*, and behind by a broad square plate of bone, the *dorsum ephippii*, surmounted at each superior angle by a tubercle, the *posterior clinoid process*; beneath the latter process is a notch, for the sixth nerve. On each side of the sella turcica is the *cavernous groove*: it is broad, shallow, and curved somewhat like the italic letter *f*; it commences behind at the foramen lacerum medium, and terminates on the inner side of the anterior clinoid process, and presents along its outer margin a ridge of bone. This groove lodges the cavernous sinus, the internal carotid artery, and the nerves of the orbit. The sides of the middle fossa are of considerable depth: they present eminences and depressions for the convolutions of the brain, and grooves for the branches of the middle meningeal artery; the latter commence on the outer side of the foramen spinosum, and consist of two large branches,



an anterior and a posterior; the former passing upwards and forwards to the anterior inferior angle of the parietal bone, the latter passing upwards and backwards. The following foramina may also be seen from before backwards. Most anteriorly is the *foramen lacerum anterius*, or *sphenoidal fissure*, formed above by the lesser wing of the sphenoid; below, by the greater wing; internally, by the body of the sphenoid; and sometimes completed externally by the orbital plate of the frontal bone. It transmits the third, the fourth, the three branches of the ophthalmic division of the fifth, the sixth nerve, some filaments from the cavernous plexus of the sympathetic, the orbital branch of the middle meningeal artery, a recurrent branch from the lachrymal artery to the dura mater, and the ophthalmic vein. Behind the inner extremity of the sphenoidal fissure is the *foramen rotundum*, for the passage of the second division of the fifth or superior maxillary nerve; still more posteriorly is seen a small orifice, the *foramen Vesalii*, an opening situated between the foramen rotundum and ovale, a little internal to both: it varies in size in different individuals, and is often absent; when present, it transmits a small vein. It opens below into the pterygoid fossa, just at the outer side of the scaphoid depression. Behind and external to the latter opening is the *foramen ovale*, which transmits the third division of the fifth or inferior maxillary nerve, the small meningeal artery, and the small petrosal nerve.\* On the outer side of the foramen ovale is the *foramen spinosum*, for the passage of the middle meningeal artery; and on the inner side of the foramen ovale, the *foramen lacerum medium*. The lower part of this aperture is filled up with cartilage in the recent state. The Vidian nerve and a meningeal branch from the ascending pharyngeal artery pierce this cartilage. On the anterior surface of the petrous portion of the temporal bone is seen, from without inwards, the eminence caused by the projection of the superior semicircular canal; in front of and a little outside this a depression corresponding to the roof of the tympanum; the groove leading to the hiatus Fallopii, for the transmission of the petrosal branch of the Vidian nerve and the petrosal branch of the middle meningeal artery; beneath it, the smaller groove, for the passage of the lesser petrosal nerve, and, near the apex of the bone, the depression for the Gasserian ganglion; and the orifice of the carotid canal, for the passage of the internal carotid artery and carotid plexus of nerves.

The **Posterior Fossa**, deeply concave, is the largest of the three, and situated on a lower level than either of the preceding. It is formed by the posterior third of the superior surface of the body of the sphenoid, by the occipital, the petrous and mastoid portions of the temporal, and the posterior inferior angle of the parietal bone; it is crossed by four sutures, the petro-occipital, the masto-occipital, the masto-parietal, and the basilar; and lodges the cerebellum, pons Varolii, and medulla oblongata. It is separated from the middle fossa in the median line by the dorsum ephippii, and on each side by the superior border of the petrous portion of the temporal bone. This border serves for the attachment of the tentorium cerebelli, is grooved for the superior petrosal sinus, and at its inner extremity presents a notch, upon which rests the fifth nerve. The circumference of the fossa is bounded posteriorly by the grooves for the lateral sinuses. In the centre of this fossa is the *foramen magnum*, bounded on either side by a rough tubercle, which gives attachment to the odontoid or check ligaments; and a little above these are seen the internal openings of the *anterior condyloid foramina*, through which pass the hypoglossal nerve and a meningeal branch from the ascending pharyngeal artery. In front of the foramen magnum is a grooved surface, formed by the basilar process of the occipital bone and by the posterior third of the superior surface of the body of the sphenoid, which supports the medulla oblongata and pons Varolii, and articulates on each side with the petrous portion of the temporal bone, forming the petro-occipital suture, the anterior half of which is grooved for the inferior petrosal sinus, the posterior half being encroached

\* See footnote, p. 16c.

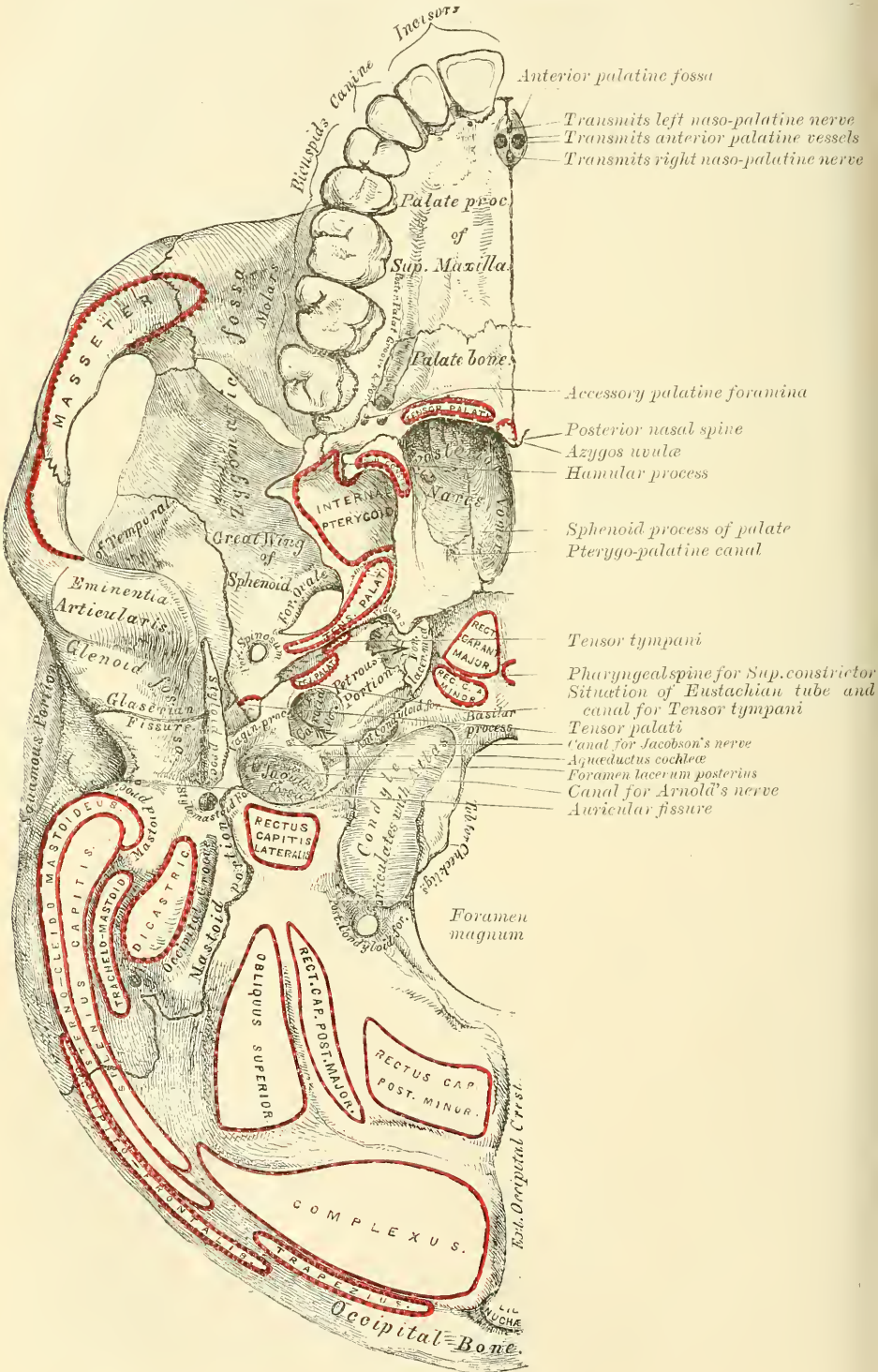


upon by the *foramen lacerum posterius*, or *jugular foramen*. This foramen presents three compartments: through the anterior, passes the inferior petrosal sinus; through the posterior, the lateral sinus and some meningeal branches from the occipital and ascending pharyngeal arteries; and through the middle, the glosso-pharyngeal, pneumo-gastric and spinal accessory nerves. Above the jugular foramen is the *internal auditory meatus*, for the facial and auditory nerves and auditory artery; behind and external to this is the slit-like opening leading into the aquæductus vestibuli; whilst between the two latter, and near the superior border of the petrous portion, is a small, triangular depression which lodges a process of the dura mater and occasionally transmits a small vein into the substance of the bone. Behind the foramen magnum are the *inferior occipital fossæ*, which lodge the hemispheres of the cerebellum, separated from one another by the *internal occipital crest*, which serves for the attachment of the falx cerebelli, and lodges the occipital sinus. The posterior fossæ are surmounted, above, by the deep transverse grooves for the lodgment of the *lateral sinuses*. These channels, in their passage outwards, groove the occipital bone, the posterior inferior angle of the parietal, the mastoid portion of the temporal, and the jugular process of the occipital, and terminate at the back part of the jugular foramen. Where this sinus grooves the mastoid portion of the temporal bone, the orifice of the *mastoid foramen* may be seen; and, just previous to its termination, it has opening into it the *posterior condyloid foramen*. Neither foramen is constant.

The **External Surface** of the Base of the Skull (fig. 183) is extremely irregular. It is bounded in front by the incisor teeth in the upper jaw; behind, by the superior curved lines of the occipital bone; and laterally by the alveolar arch, the lower border of the malar bone, the zygoma, and an imaginary line, extending from the zygoma to the mastoid process and extremity of the superior curved line of the occiput. It is formed by the palate processes of the superior maxillary and palate bones, the vomer, the pterygoid processes, under surface of the great wing, spinous processes and part of the body of the sphenoid, the under surface of the squamous, mastoid, and petrous portions of the temporal, and the under surface of the occipital bone. The anterior part of the base of the skull is raised above the level of the rest of this surface (when the skull is turned over for the purpose of examination), surrounded by the alveolar process, which is thicker behind than in front, and excavated by sixteen depressions for lodging the teeth of the upper jaw, the cavities varying in depth and size according to the teeth they contain. Immediately behind the incisor teeth is the *anterior palatine fossa*. At the bottom of this fossa may usually be seen four apertures: two placed laterally, the *foramina of Stenson*, which open above, one in the floor of each nostril, and transmit the anterior branch of the posterior palatine vessels, and two in the median line in the intermaxillary suture, the *foramina of Scarpa*, one in front of the other, the anterior transmitting the left, and the posterior (the larger) the right, naso-palatine nerve. These two latter canals are sometimes wanting, or they may join to form a single one, or one of them may open into one of the lateral canals above referred to. The palatine vault is concave, uneven, perforated by numerous foramina, marked by depressions for the palatine glands, and crossed by a crucial suture, formed by the junction of the four bones of which it is composed. At the front part of this surface, a delicate linear suture may frequently be seen, marking off the pre-maxillary portion of the bone. One or two small foramina in the alveolar margin behind the incisor teeth, occasionally seen in the adult, almost constantly in young subjects, are called the *incisive foramina*; they transmit nerves and vessels to the incisor teeth. At each posterior angle of the hard palate is the *posterior palatine foramen*, for the transmission of the posterior palatine vessels and large descending palatine nerve; and running forwards and inwards from it a groove, for the same vessels and nerve. Behind the posterior palatine foramen is the *tuberosity of the palate-bone*, perforated by one or more accessory posterior palatine canals, and marked by the commencement of a ridge, which runs transversely inwards, and

serves for the attachment of the tendinous expansion of the Tensor palati muscle. Projecting backwards from the centre of the posterior border of the hard palate is the posterior nasal spine, for the attachment of the Azygos uvulae. Behind and

FIG. 183.—Base of the skull. External surface.





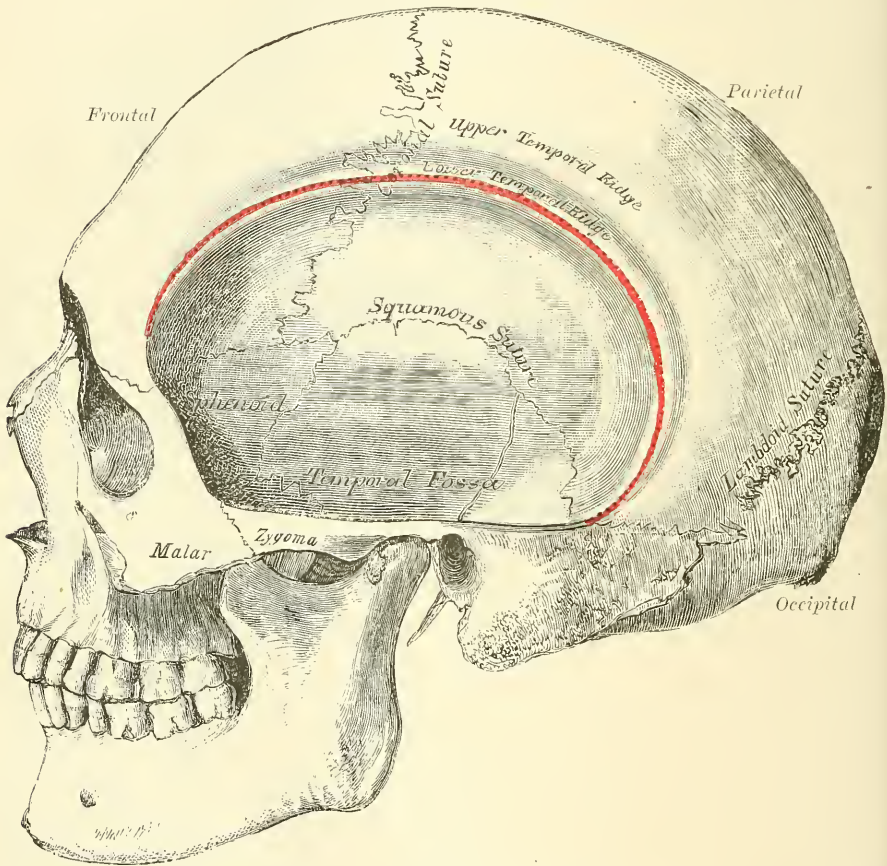
above the hard palate is the posterior aperture of the nares, divided into two parts by the vomer, bounded above by the body of the sphenoid, below by the horizontal plate of the palate-bone, and laterally by the pterygoid processes of the sphenoid. Each aperture measures about an inch and a quarter in the vertical, and about half an inch in the transverse direction. At the base of the vomer may be seen the expanded *alæ* of this bone, receiving between them the rostrum of the sphenoid. Near the lateral margins of the vomer, at the root of the pterygoid processes, are the *pterygo-palatine canals*. The pterygoid process, which bounds the posterior nares on each side, presents near its base the *pterygoid* or *Vidian canal*, for the Vidian nerve and artery. Each process consists of two plates, which bifurcate at the extremity to receive the tuberosity of the palate-bone, and are separated behind by the pterygoid fossa, which lodges the Internal pterygoid muscle. The internal plate is long and narrow, presenting on the outer side of its base the *scaphoid fossa*, for the origin of the Tensor palati muscle, and at its extremity the *hamular process*, around which the tendon of this muscle turns. The external pterygoid plate is broad, forms the inner boundary of the zygomatic fossa, and affords attachment, by its outer surface, to the External pterygoid muscle.

Behind the nasal fossæ in the middle line is the basilar surface of the occipital bone, presenting in its centre the *pharyngeal spine* for the attachment of the Superior constrictor muscle of the pharynx, with depressions on each side for the insertion of the Rectus capitis anticus major and minor. At the base of the external pterygoid plate is the *foramen ovale*; behind this, the *foramen spinosum*, and the prominent spinous process of the sphenoid, which gives attachment to the internal lateral ligament of the lower jaw and the Tensor palati muscle. External to the spinous process is the *glenoid fossa*, divided into two parts by the Glaserian fissure (page 152), the anterior portion concave, smooth, bounded in front by the eminentia articularis, and serving for the articulation of the condyle of the lower jaw; the posterior portion rough, bounded behind by the tympanic plate, and serving for the reception of part of the parotid gland. Emerging from between the laminae of the vaginal process of the tympanic plate is the *styloid process*; and at the base of this process is the *stylo-mastoid foramen*, for the exit of the facial nerve, and entrance of the stylo-mastoid artery. External to the stylo-mastoid foramen is the *auricular fissure* for the auricular branch of the pneumogastric, bounded behind by the mastoid process. Upon the inner side of the mastoid process is a deep groove, the *digastric fossa*; and a little more internally, the *occipital groove*, for the occipital artery. At the base of the internal pterygoid plate is a large and somewhat triangular aperture, the *foramen lacerum medium*, bounded in front by the great wing of the sphenoid, behind by the apex of the petrous portion of the temporal bone, and internally by the body of the sphenoid and basilar process of the occipital bone: it presents in front the posterior orifice of the Vidian canal; behind, the aperture of the carotid canal. The basilar surface of this opening is filled up in the recent state by a fibro-cartilaginous substance; across its upper or cerebral aspect pass the internal carotid artery and Vidian nerve. External to this aperture, the *petro-sphenoidal suture* is observed, at the outer termination of which is seen the orifice of the canal for the Eustachian tube, and that for the Tensor tympani muscle. Behind this suture is seen the under surface of the petrous portion of the temporal bone, presenting, from within outwards, the quadrilateral, rough surface, part of which affords attachment to the Levator palati and Tensor tympani muscles; external to this surface the orifices of the carotid canal and the aquæductus cochleæ, the former transmitting the internal carotid artery and the ascending branches of the superior cervical ganglion of the sympathetic, the latter serving for the passage of a small artery and vein to the cochlea. Behind the carotid canal is a large aperture, the *jugular fossa*, formed in front by the petrous portion of the temporal, and behind by the occipital; it is generally larger on the right than on the left side, and is divided into three compartments by processes of dura mater. The anterior is for the passage of the inferior petrosal sinus; the posterior for



the lateral sinus and some meningeal branches from the occipital and ascending pharyngeal arteries; the central one for the glosso-pharyngeal, pneumogastric, and spinal accessory nerves. On the ridge of bone dividing the carotid canal from the jugular fossa is the small foramen for the transmission of Jacobson's nerve; and on the wall of the jugular foramen, near the root of the styloid process, is the small aperture for the transmission of Arnold's nerve. Behind the basilar surface of the occipital bone is the *foramen magnum*, bounded on each side by the condyles, rough internally for the attachment of the check or odontoid ligaments, and presenting externally a rough surface, the *jugular process*, which serves for the attachment of the Rectus capitis lateralis muscle and the lateral occipito-atlantal ligament. On either side of each condyle anteriorly is the *anterior*

FIG. 184.—Side view of the skull.



*condyloid fossa*, perforated by the anterior condyloid foramen, for the passage of the hypoglossal nerve and a meningeal artery. Behind each condyle is the *posterior condyloid fossa*, perforated on one or both sides by the posterior condyloid foramen, for the transmission of a vein to the lateral sinus. Behind the foramen magnum is the *external occipital crest*, terminating above at the *external occipital protuberance*, whilst on each side are seen the *superior* and *inferior curved lines*; these, as well as the surfaces of bone between them, are rough for the attachment of the muscles, which are enumerated on page 142.

#### LATERAL REGION OF THE SKULL

The **Lateral Region** of the Skull is of a somewhat triangular form, the base of the triangle being formed by a line extending from the external angular process

of the frontal bone along the temporal ridge backwards to the outer extremity of the superior curved line of the occiput: and the sides by two lines, the one drawn downwards and backwards from the external angular process of the frontal bone to the angle of the lower jaw, the other from the angle of the jaw upwards and backwards to the outer extremity of the superior curved line. This region is divisible into three portions—temporal fossa, mastoid portion, and zygomatic fossa.

#### THE TEMPORAL FOSSA

The **Temporal Fossa** is bounded above and behind by the temporal ridge, which extends from the external angular process of the frontal upwards and backwards across the frontal and parietal bones, curving downwards behind to terminate in the posterior root of the zygomatic process (*supra mastoid crest*). This ridge is generally double, at all events in front, where it is most marked. In front, it is bounded by the frontal, malar, and great wing of the sphenoid; externally, by the zygomatic arch, formed conjointly by the malar and temporal bones; below, it is separated from the zygomatic fossa by the pterygoid ridge, seen on the outer surface of the great wing of the sphenoid. This fossa is formed by five bones, part of the frontal, great wing of the sphenoid, parietal, squamous portion of the temporal, and malar bones, and is traversed by six sutures, part of the transverse facial, spheeno-malar, coronal, spheeno-parietal, squamo-parietal, and squamo-sphenoidal. The point where the coronal suture crosses the superior temporal ridge is sometimes named the *stephanion*; and the region where the four bones, the parietal, the frontal, the squamous, and the greater wing of the sphenoid, meet at the anterior inferior angle of the parietal bone, is named the *pterion*. This point is about on a level with the external angular process of the frontal bone and about one and a half inch behind it. This fossa is deeply concave in front, convex behind, traversed by grooves which lodge branches of the deep temporal arteries, and filled by the Temporal muscles.

#### THE MASTOID PORTION

The **Mastoid Portion** of the side of the skull is bounded in front by the tubercle of the zygoma; above, by a line which runs from the posterior root of the zygoma to the end of the masto-parietal suture; behind and below by the masto-occipital suture. It is formed by the mastoid and part of the squamous and petrous portions of the temporal bone; its surface is convex and rough for the attachment of muscles, and presents, from behind forwards, the mastoid foramen, the mastoid process, the external auditory meatus, surrounded by the tympanic plate, and, most anteriorly, the temporo-maxillary articulation.

#### THE ZYGOMATIC FOSSA

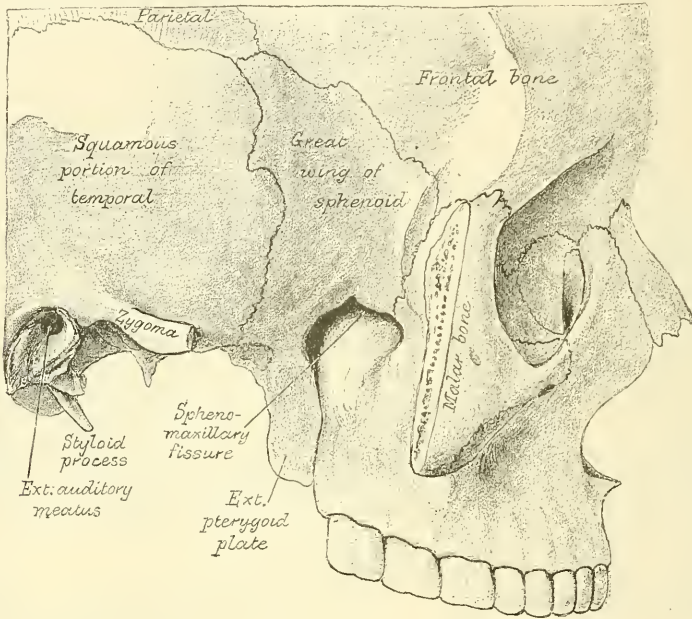
The **Zygomatic Fossa** is an irregularly shaped cavity, situated below and on the inner side of the zygoma; bounded, in front, by the zygomatic surface of the superior maxillary bone and the ridge which descends from its malar process; behind, by the posterior border of the pterygoid process and the eminentia articularis; above, by the pterygoid ridge on the outer surface of the great wing of the sphenoid, and the under part of the squamous portion of the temporal; below, by the alveolar border of the superior maxilla; internally, by the external pterygoid plate; and externally, by the zygomatic arch and ramus of the lower jaw (fig. 185). It contains the lower part of the Temporal, the External and Internal pterygoid muscles, the internal maxillary artery and vein, and inferior maxillary nerve and their branches. At its upper and inner part may be observed two fissures, the spheeno-maxillary and pterygo-maxillary.

The **Spheno-maxillary Fissure**, horizontal in direction, opens into the outer and back part of the orbit. It is formed above by the lower border of the orbital

surface of the great wing of the sphenoid; below, by the external border of the orbital surface of the superior maxilla and a small part of the palate-bone; externally, by a small part of the malar bone:\* internally, it joins at right angles with the pterygo-maxillary fissure. This fissure opens a communication from the orbit into three fossæ—the temporal, zygomatic, and speno-maxillary; it transmits the superior maxillary nerve and its orbital branch, the infra-orbital vessels, and ascending branches from the speno-palatine or Meckel's ganglion.

The **Pterygo-maxillary Fissure** is vertical, and descends at right angles from the inner extremity of the preceding; it is a V-shaped interval, formed by the

FIG. 185.—Zygomatic fossa.



divergence of the superior maxillary bone from the pterygoid process of the sphenoid. It serves to connect the spheno-maxillary fossa with the zygomatic fossa, and transmits branches of the internal maxillary artery.

#### THE SPHENO-MAXILLARY FOSSA

The **Spheno-maxillary Fossa** is a small, triangular space situated at the angle of junction of the spheno-maxillary and pterygo-maxillary fissures, and placed beneath the apex of the orbit. It is formed above by the under surface of the body of the sphenoid and by the orbital process of the palate-bone; in front, by the superior maxillary bone; behind, by the anterior surface of the base of the pterygoid process and lower part of the anterior surface of the great wing of the sphenoid; internally by the vertical plate of the palate. This fossa has three fissures terminating in it, the *sphenoidal*, *spheno-maxillary*, and *pterygo-maxillary*; it communicates with the orbit by the spheno-maxillary fissure; with the nasal fossæ by the spheno-palatine foramen, and with the zygomatic fossa by the pterygo-maxillary fissure. It also communicates with the cavity of the cranium, and has opening into it five foramina. Of these there are three on the posterior wall: the *foramen rotundum* above; below, and internal to this, the *Vidian*; and still

\* Occasionally the superior maxillary bone and the sphenoid articulate with each other at the anterior extremity of this fissure; the malar is then excluded from entering into its formation.



more inferiorly and internally, the *pterygo-palatine*. On the inner wall is the *spheno-palatine foramen* by which the spheno-maxillary communicates with the nasal fossa; and below is the superior orifice of the *posterior palatine canal*, besides occasionally the orifices of the *accessory posterior palatine canals*. The fossa contains the superior maxillary nerve and Meckel's ganglion, and the termination of the internal maxillary artery.

#### ANTERIOR REGION OF THE SKULL

The **Anterior Region** of the Skull, which forms the face, is of an oval form, presents an irregular surface, and is excavated for the reception of two of the organs of sense, the eye and the nose. It is bounded above by the glabella and margins of the orbit; below, by the prominence of the chin; on each side, by the malar bone, and anterior margin of the ramus of the jaw. In the median line are seen from above downwards the glabella, and diverging from it are the *superciliary ridges*, which indicate the situation of the frontal sinuses and support the eyebrows. Beneath the glabella is the fronto-nasal suture, the mid-point of which is termed the *nasion*, and below this is the arch of the nose, formed by the nasal bones, and the nasal processes of the superior maxillary. The nasal arch is convex from side to side, concave from above downwards, presenting in the median line the inter-nasal suture formed between the nasal bones, laterally the naso-maxillary suture formed between the nasal bone and the nasal process of the superior maxillary bone. Below the nose is seen the opening of the anterior nares, which is heart-shaped, with the narrow end upwards, and presents laterally the thin, sharp margins serving for the attachment of the lateral cartilages of the nose, and in the middle line below, a prominent process, the *anterior nasal spine*, bounded by two deep notches. Below this is the *intermaxillary suture*, and on each side of it the *incisive fossa*. Beneath this fossa are the alveolar processes of the upper and lower jaws, containing the incisor teeth, and at the lower part of the median line, the *symphysis of the chin*, the *mental process*, with its two *mental tubercles*, separated by a median groove, and the *incisive fossa* of the lower jaw.

On each side, proceeding from above downwards, is the *supra-orbital ridge*, terminating externally in the external angular process at its junction with the malar, and internally in the internal angular process; towards the inner third of this ridge is the *supra-orbital notch or foramen*, for the passage of the supra-orbital vessels and nerve. Beneath the supra-orbital ridge is the opening of the orbit, bounded externally by the orbital ridge of the malar bone; below, by the orbital ridge formed by the malar, superior maxillary, and lachrymal bones; internally, by the nasal process of the superior maxillary, and the internal angular process of the frontal bone. On the outer side of the orbit is the quadrilateral anterior surface of the malar bone perforated by one or two small malar foramina. Below the inferior margin of the orbit is the *infra-orbital foramen*, the termination of the infra-orbital canal, and beneath this the *canine fossa*, which gives attachment to the Levator anguli oris; bounded below by the alveolar processes, containing the teeth of the upper and lower jaws. Beneath the alveolar arch of the lower jaw is the *mental foramen* for the passage of the mental vessels and nerve, the *external oblique line*, and at the lower border of the bone, at the point of junction of the body with the ramus, a shallow groove for the passage of the facial artery.

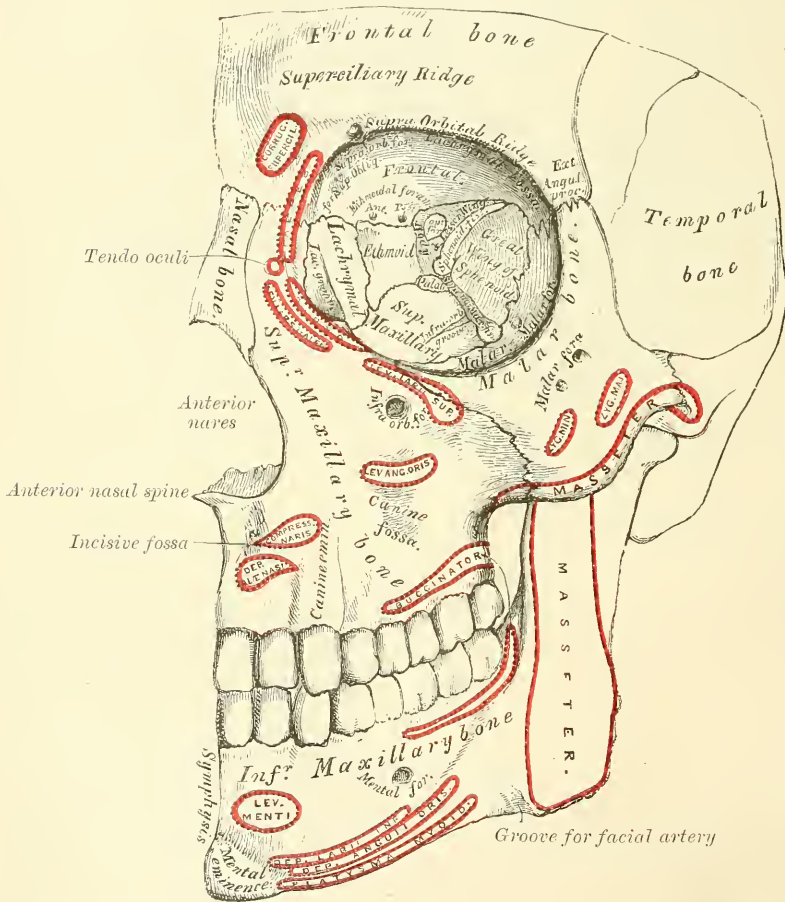
#### THE ORBITS

The **Orbits** (fig. 186) are two quadrilateral pyramidal cavities, situated at the upper and anterior part of the face, their bases being directed forwards and outwards, and their apices backwards and inwards, so that the axes of the two, if continued backwards, would meet over the body of the sphenoid bone. Each orbit is formed of *seven* bones, the frontal, sphenoid, ethmoid, superior maxillary,

malar, lachrymal, and palate; but three of these, the frontal, ethmoid, and sphenoid, enter into the formation of *both* orbits, so that the two cavities are formed of *eleven* bones only. Each cavity presents for examination a roof, a floor, an inner and an outer wall, four angles, a circumference or base, and an apex. The **roof** is concave, directed downwards and forwards, and formed in front by the orbital plate of the frontal; behind by the lesser wing of the sphenoid. This surface presents internally the depression for the cartilaginous pulley of the Superior oblique muscle; externally, the depression for the lachrymal gland; and posteriorly, the suture connecting the frontal and lesser wing of the sphenoid.

The **floor** is nearly flat, and of less extent than the roof; it is formed chiefly by the orbital process of the superior maxillary; in front, to a small extent, by

FIG. 186.—Anterior region of the skull.



the orbital process of the malar, and behind, by the superior surface of the orbital process of the palate. This surface presents at its anterior and internal part, just external to the lachrymal groove, a depression for the attachment of the Inferior oblique muscle; externally, the suture between the malar and superior maxillary bones; near its middle, the infra-orbital groove; and posteriorly, the suture between the maxillary and palate bones.

The **inner wall** is flattened, and formed from before backwards by the nasal process of the superior maxilla, the lachrymal, or planum of the ethmoid, and a small part of the body of the sphenoid. This surface presents the lachrymal groove, and crest of the lachrymal bone, and the sutures connecting the lachrymal

with the superior maxillary, the ethmoid with the lachrymal in front, and the ethmoid with the sphenoid behind.

The **outer wall** is formed in front by the orbital process of the malar bone; behind, by the orbital surface of the sphenoid. On it are seen the orifices of one or two malar canals, and the suture connecting the sphenoid and malar bones.

**Angles.**—The *superior external angle* is formed by the junction of the upper and outer walls; it presents, from before backwards, the suture connecting the frontal with the malar in front, and with the great wing of the sphenoid behind; quite posteriorly is the foramen lacerum anterius, or sphenoidal fissure, which transmits the third, the fourth, the three branches of the ophthalmic division of the fifth, the sixth nerve, some filaments from the cavernous plexus of the sympathetic, the orbital branch of the middle meningeal artery, a recurrent branch from the lachrymal artery to the dura mater, and the ophthalmic vein. The *superior internal angle* is formed by the junction of the upper and inner wall, and presents the suture connecting the frontal bone with the lachrymal in front, and with the ethmoid behind. The point of junction of these three sutures has been named the *dacryon*. This angle presents two foramina, the anterior and posterior ethmoidal, the former transmitting the anterior ethmoidal vessels and nasal nerve, the latter the posterior ethmoidal vessels. The *inferior external angle*, formed by the junction of the outer wall and floor, presents the speno-maxillary fissure, which transmits the superior maxillary nerve and its orbital branches, the infra-orbital vessels, and the ascending branches from the speno-palatine or Meckel's ganglion. The *inferior internal angle* is formed by the union of the lachrymal and os planum of the ethmoid, with the superior maxillary and palate bones. The *circumference*, or base, of the orbit, quadrilateral in form, is bounded above by the supra-orbital ridge; below, by the anterior border of the orbital plate of the malar, superior maxillary, and lachrymal bones; externally, by the external angular process of the frontal and the malar bones; internally, by the internal angular process of the frontal, and the nasal process of the superior maxillary. The circumference is marked by three sutures, the fronto-maxillary internally, the fronto-malar externally, and the malo-maxillary below; it contributes to the formation of the lachrymal groove, and presents, above, the supra-orbital notch (or foramen), for the passage of the supra-orbital vessels and nerve. The *apex*, situated at the back of the orbit, corresponds to the optic foramen, a short, circular canal, which transmits the optic nerve and ophthalmic artery. It will thus be seen that there are *nine* openings communicating with each orbit—viz. the optic foramen, sphenoidal fissure, speno-maxillary fissure, supra-orbital foramen, infra-orbital canal, anterior and posterior ethmoidal foramina, malar foramina, and canal for the nasal duct.

#### THE NASAL FOSSÆ

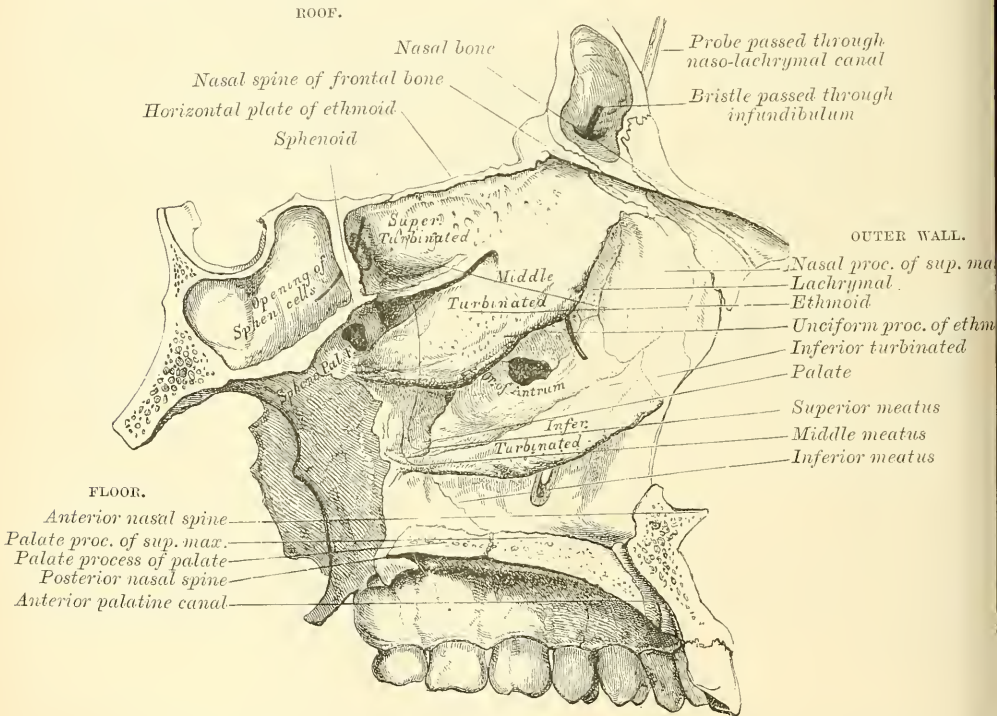
The **Nasal Fossæ** are two large, irregular cavities, situated on either side of the middle line of the face, extending from the base of the cranium to the roof of the mouth, and separated from each other by a thin vertical septum. They communicate by two large apertures, the anterior nares, with the front of the face; and by the two posterior nares with the pharynx behind. These fossæ are much narrower above than below, and in the middle than at the anterior or posterior openings: their depth, which is considerable, is much greater in the middle than at either extremity. Each nasal fossa communicates with four sinuses, the frontal above, the sphenoidal behind, and the maxillary and ethmoidal on the outer wall. Each fossa also communicates with four cavities: with the orbit by the lachrymal groove, with the mouth by the anterior palatine canal, with the cranium by the olfactory foramina, and with the speno-maxillary fossa by the speno-palatine foramen; and they occasionally communicate with each other by an aperture in the septum. The bones entering into their formation are fourteen in number: three of the cranium, the frontal, sphenoid, and ethmoid, and all



the bones of the face, excepting the malar and lower jaw. Each cavity is bounded by a roof, a floor, an inner and an outer wall.

The **upper wall**, or **roof** (fig. 187) is long, narrow, and horizontal in its centre, but sloped downwards at its anterior and posterior extremities; it is formed in front by the nasal bones and nasal spine of the frontal, which are directed downwards and forwards; in the middle, by the cribriform plate of the ethmoid, which is horizontal; and behind, by the under surface of the body of the sphenoid, and sphenoidal turbinated bones, the ala of the vomer and the sphenoidal process of the palate bone, which are directed downwards and backwards. This surface presents, from before backwards, the internal aspect of the nasal bones; on their outer side, the suture formed between the nasal bone and the nasal process of the superior maxillary; on their inner side, the elevated crest which receives the nasal spine of the frontal and the perpendicular plate of the ethmoid, and articulates with its fellow of the opposite side; whilst the surface of the bones is

FIG. 187.—Roof, floor, and outer wall of left nasal fossa.



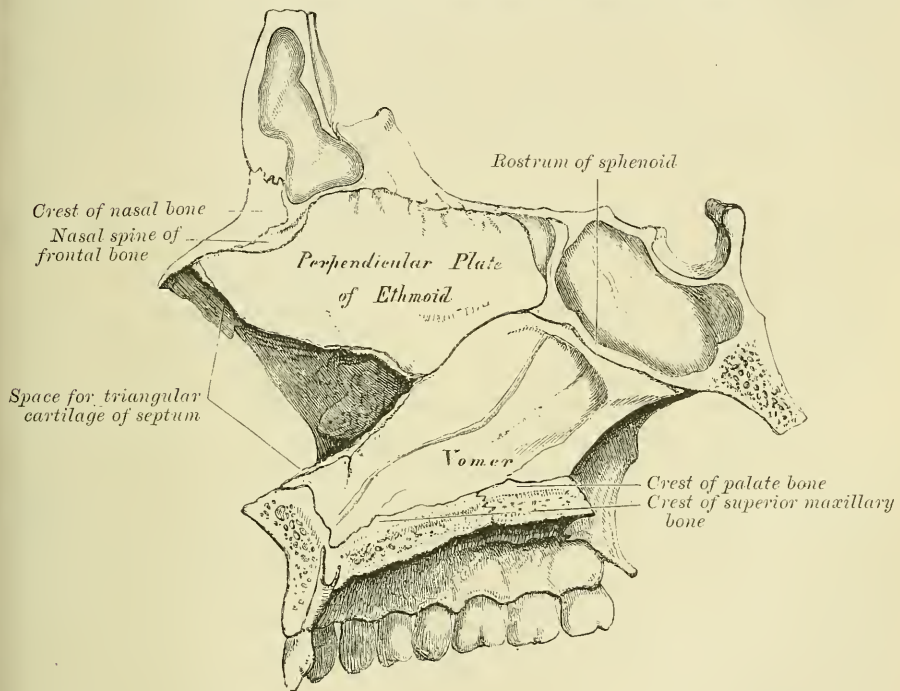
perforated by a few small vascular apertures, and presents the longitudinal groove for the nasal nerve: further back is the transverse suture, connecting the frontal with the nasal in front, and the ethmoid behind, the olfactory foramina and nasal slit on the under surface of the cribriform plate, and the suture between it and the sphenoid behind: quite posteriorly are seen the sphenoidal turbinated bones, the orifices of the sphenoidal sinuses, and the articulation of the alæ of the vomer with the under surface of the body of the sphenoid.

The **floor** is flattened from before backwards, concave from side to side, and wider in the middle than at either extremity. It is formed in front by the palate process of the superior maxillary; behind, by the palate process of the palate-bone. This surface presents, from before backwards, the anterior nasal spine; behind this, the upper orifices of the anterior palatine canal; internally, the elevated crest which articulates with the vomer; and behind, the suture between the palate and superior maxillary bones, and the posterior nasal spine.

The **inner wall**, or septum (fig. 188), is a thin vertical partition, which separates the nasal fossæ from one another; it is occasionally perforated, so that the fossæ communicate, and it is frequently deflected considerably to one side.\* It is formed, in front, by the crest of the nasal bones and nasal spine of the frontal; in the middle, by the perpendicular plate of the ethmoid; behind, by the vomer and rostrum of the sphenoid; below, by the crest of the superior maxillary and palate bones. It presents, in front, a large, triangular notch, which receives the triangular cartilage of the nose; and behind, the guttural edge of the vomer. Its surface is marked by numerous vascular and nervous canals and the groove for the naso-palatine nerve, and is traversed by sutures connecting the bones of which it is formed.

The **outer wall** (fig. 187) is formed, in front, by the nasal process of the superior maxillary and lachrymal bones; in the middle, by the ethmoid and

FIG. 188.—Inner wall of nasal fossæ, or septum of nose.



inner surface of the superior maxillary and inferior turbinated bones; behind, by the vertical plate of the palate-bone, and the internal pterygoid plate of the sphenoid. This surface presents three irregular longitudinal passages, or *meatuses*, formed between three horizontal plates of bone that spring from it; they are termed the superior, middle, and inferior meatuses of the nose. The *superior meatus*, the smallest of the three, is situated at the upper and back part of each nasal fossa, occupying the posterior third of the outer wall. It is situated between the superior and middle turbinated bones, and has opening into it two foramina, the *spheno-palatine* at the back of its outer wall, and the *posterior ethmoidal cells* at the front part of the outer wall. The opening of the sphenoidal sinuses is usually at the upper and back part of the nasal fossæ immediately behind the superior turbinated bone. The *middle meatus* is situated between the middle and inferior turbinated bones, and occupies the posterior two-thirds of the outer wall of the nasal fossa. It presents two apertures. In front is the orifice of the *infundibulum*, by which the middle meatus communicates with the

\* See footnote, p. 164.

anterior ethmoidal cells, and through these with the frontal sinuses. At the centre of the outer wall is the *orifice of the antrum*, which varies somewhat as to its exact position in different skulls. The *inferior meatus*, the largest of the three, is the space between the inferior turbinated bone and the floor of the nasal fossa. It extends along the entire length of the outer wall of the nose, is broader in front than behind, and presents anteriorly the lower *orifice of the canal for the nasal duct*.

The **anterior nares** present a heart-shaped or pyriform opening, whose long axis is vertical, and narrow extremity upwards. This opening in the recent state is much contracted by the cartilages of the nose. It is bounded above by the inferior border of the nasal bone; laterally by the thin, sharp margin which separates the facial from the nasal surface of the superior maxillary bone; and below by the same border, where it slopes inwards to join its fellow of the opposite side at the anterior nasal spine.

The **posterior nares** are the two posterior oval openings of the nasal fossæ, by which they communicate with the upper part of the pharynx. They are situated immediately in front of the basilar process, and are bounded above by the under surface of the body of the sphenoid; below, by the posterior border of the horizontal plate of the palate-bone; externally, by the internal surface of the internal pterygoid plate; and internally, in the middle line, they are separated from each other by the guttural border of the Vomer.

*Surface Form.*—The various bony prominences or landmarks which are to be easily felt and recognised in the head and face, and which afford the means of mapping out the important structures comprised in this region, are as follow:—

- |  |                            |
|--|----------------------------|
| 1. Supra-orbital arch.                     | 8. Parietal eminence.      |
| 2. Internal angular process.               | 9. Temporal ridge.         |
| 3. External angular process.               | 10. Frontal eminence.      |
| 4. Zygomatic arch.                         | 11. Superciliary ridge.    |
| 5. Mastoid process.                        | 12. Nasal bone.            |
| 6. External occipital protuberance.        | 13. Lower margin of orbit. |
| 7. Superior curved line of occipital bone. | 14. Lower jaw.             |

1. The *supra-orbital arch* is to be felt throughout its entire extent, covered by the eyebrow. It forms the upper boundary of the circumference or base of the orbit and separates the face from the forehead. It is strong and arched, and terminates internally at the root of the nose, in the *internal angular process*, which articulates with the lachrymal bone. Externally it terminates in the *external angular process* which articulates with the malar bone. This arched ridge is sharper and more defined in its outer than in its inner half, and forms an overhanging process which protects and shields the lachrymal gland. It thus protects the eye in its most exposed situation and in the direction from which blows are more likely to descend. The supra-orbital arch varies in prominence in different individuals. It is more marked in the male than in the female, and in some races of mankind than others. In the less civilised races, as the forehead recedes backwards, the supra-orbital arch becomes more prominent and approaches more to the characters of the monkey tribe, in which the supra-orbital arches are very largely developed and acquire additional prominence from the oblique direction of the frontal bone.

2. The *internal angular process* is scarcely to be felt. Its position is indicated by the angle formed by the supra-orbital arch with the nasal process of the superior maxillary bone and the lachrymal bone at the inner side of the orbit. Between the internal angular processes of the two sides is a broad surface which assists in forming the root of the nose, and immediately above this a broad, smooth, somewhat triangular surface, the *glabella*, situated between the superciliary ridges.

3. The *external angular process* is much more strongly marked than the internal, and is plainly to be felt. It is formed by the junction or confluence of the supra-orbital and temporal ridges, and, articulating with the malar bone, it serves to a very considerable extent to support the bones of the face. In carnivorous animals the external angular process does not articulate with the malar, and therefore this lateral support to the bones of the face is not present.

4. The *zygomatic arch* is plainly to be felt throughout its entire length, being situated almost immediately under the skin. It is formed by the malar bone and the zygomatic process of the temporal bone. At its anterior extremity, where it is formed by the malar bone, it is broad and forms the prominence of the cheek; the posterior part is narrower, and terminates just in front and a little above the tragus of the external ear. The lower border is more plainly to be felt than the upper, in consequence of the dense temporal fascia being attached to the upper border, which somewhat obscures its outline. Its shape differs very much in individuals and in different races of mankind. In the most degraded type of skull—as, for instance, in the skull of the



negro of the Guinea Coast—the malar bones project forwards and not outwards, and the zygoma at its posterior extremity extends further outwards before it is twisted on itself to be prolonged forwards. This makes the zygomatic arch stand out in bold relief, and affords greater space for the Temporal muscle. In skulls which have a more pyramidal shape, as in the Esquimaux or Greenlander, the malar bones do not project forwards and downwards under the eyes, as in the preceding form, but take a direction outwards, forming with the zygoma a large, rounded sweep or segment of a circle. Thus it happens that if two lines are drawn from the zygomatic arches, touching the temporal ridges, they meet over the top of the head, instead of being parallel, or nearly so, as in the European skull, in which the zygomatic arches are not nearly so prominent. This gives to the face a more or less oval type. 5. Behind the ear is the *mastoid portion of the temporal bone*, plainly to be felt, and terminating below in a nipple-shaped process. Its anterior border can be traced immediately behind the concha, and its apex is on about a level with the lobule of the ear. It is rudimentary in infancy, but gradually develops in childhood, and is more marked in the negro than in the European. 6. The *external occipital protuberance* is always plainly to be felt just at the level where the skin of the neck joins that of the head. At this point the skull is thick for the purposes of safety, while radiating from it are numerous curved arches or buttresses of bone which give to this portion of the skull further security. 7. Running outwards on either side from the external occipital protuberance is an arched ridge of bone, which can be more or less plainly perceived. This is the *superior curved line* of the occipital bone, and gives attachment to some of the muscles which keep the head erect on the spine; accordingly, we find it more developed in the negro tribes, in whom the jaws are much more massive, and therefore require stronger muscles to prevent their extra weight carrying the head forwards. Below this line the surface of bone at the back of the head is obscured by the overlying muscles. Above it, the vault of the cranium is thinly covered with soft structures, so that the form of this part of the head is almost exactly that of the upper portion of the occipital, the parietal, and the frontal bones themselves; and, in bald persons, even the lines of junction of the bones, especially the junction of the occipital and parietal at the lambdoid suture, may be defined as a slight depression, caused by the thickening of the borders of the bones in this situation. 8. In the line of the greatest transverse diameter of the head, on each side of the middle line, are generally to be found the *parietal eminences*; though sometimes these eminences are not situated at the point of the greatest transverse diameter, which is at some other prominent part of the parietal region. They denote the point where ossification of the bone began. They are much more prominent and well-marked in early life, in consequence of the sharper curve of the bone at this period, so that it describes the segment of a smaller circle. Later in life, as the bone grows, the curve spreads out and forms the segment of a larger circle, so that the eminence becomes less distinguishable. In consequence of this sharp curve of the bone in early life, the whole of the vault of the skull has a squarer shape than it has in later life, and this appearance may persist in some rickety skulls. The eminence is more apparent in the negro's skull than in that of the European. This is due to greater flattening of the temporal fossa in the former skull to accommodate the larger Temporal muscle which exists in these races. The parietal eminence is particularly exposed to injury from blows or falls on the head, but fracture is to a certain extent prevented by the shape of the bone, which forms an arch, so that the force of the blow is diffused over the bone in every direction. 9. At the side of the head may be felt the *temporal ridge*. Commencing at the external angular process, it may be felt as a curved ridge, passing upwards and then curving backwards, on the frontal bone, separating the forehead from the temporal fossa. It may then be traced, passing backwards in a curved direction, over the parietal bone, and, though less marked, still generally to be recognised. Finally, the ridge curves downwards, and terminates in the posterior root of the zygoma, which separates the squamous from the subcutaneous mastoid portion of the temporal bone. Mr. Victor Horsley has recently shown, in an article on the 'Topography of the Cerebral Cortex,' that the second temporal ridge (see page 146) can be made out on the living body. 10. The *frontal eminences* vary a good deal in different individuals, being considerably more prominent in some than in others, and they are often not symmetrical on the two sides of the body, the one being much more pronounced than the other. This is often especially noticeable in the skull of the young child or infant, and becomes less marked as age advances. The prominence of the frontal eminences depends more upon the general shape of the whole bone than upon the size of the protuberances themselves. As the skull is more highly developed in consequence of increased intellectual capacity, so the frontal bone becomes more upright, and the frontal eminences stand out in bolder relief. Thus they may be considered as affording, to a certain extent, an indication of the development of the hemispheres of the brain beneath, and of the mental powers of the individual. They are not so much exposed to injury as the parietal eminences. In falls forward the upper extremities are involuntarily thrown out, and break the force of the fall, and thus shield the frontal bone from injury. 11. Below the frontal eminences on the forehead are the *superciliary ridges*, which denote the position of the frontal sinuses, and vary according to the size of the sinuses in different individuals, being, as a rule, small in the female, absent in children, and sometimes unusually prominent in the male, when the frontal sinuses are largely developed. They commence on either side

of the glabella, and at first present a rounded form, which gradually fades away at their outer ends. 12. The *nasal bones* form the prominence of the nose. They vary much in size and shape, and to them is due the varieties in the contour of this organ and much of the character of the face. Thus, in the Mongolian or Ethiopian they are flat, broad, and thick at their base, giving to these tribes the flattened nose by which they are characterised, and differing very decidedly from the Caucasian, in whom the nose, owing to the shape of the nasal bones, is narrow, elevated at the bridge, and elongated downwards. Below, the nasal bones are thin and connected with the cartilages of the nose, and the angle or arch formed by their union serves to throw out the bridge of the nose, and is much more marked in some individuals than others. 13. The *lower margin of the orbit*, formed by the superior maxillary bone and the malar bone, is plainly to be felt throughout its entire length. It is continuous internally with the nasal process of the superior maxillary bone, which forms the inner boundary of the orbit. At the point of junction of the lower margin of the orbit with the nasal process is to be felt a little tubercle of bone, which can be plainly perceived by running the finger along the bone in this situation. This tubercle serves as a guide to the position of the lachrymal sac, which is situated above and behind it. 14. The outline of the *lower jaw* is to be felt throughout its entire length. Just in front of the tragus of the external ear, and below the zygomatic arch, the condyle can be made out. When the mouth is opened, this prominence of bone can be perceived advancing out of the glenoid fossa on to the eminentia articularis, and receding again when the mouth is closed. From the condyle the posterior border of the ramus can be felt extending down to the angle. A line drawn from the condyle to the angle would indicate the exact position of this border. From the angle to the symphysis of the chin, the lower, rounded border of the body of the bone is plainly to be felt. At the point of junction of the two halves of the bone is a well-marked, triangular eminence, the *mental process*, which forms the prominence of the chin.

*Surgical Anatomy.*—An arrest in the ossifying process may give rise to deficiencies or gaps; or to fissures, which are of importance in a medico-legal point of view, as they are liable to be mistaken for fractures. The fissures generally extend from the margin towards the centre of the bone, but gaps may be found in the middle, as well as at the edges. In course of time they may become covered with a thin lamina of bone.

Occasionally a protrusion of the brain or its membranes may take place through one of these gaps in an imperfectly developed skull. When the protrusion consists of membranes only, and is filled with cerebro-spinal fluid, it is called a *meningocele*; when the protrusion consists of brain as well as membranes, it is termed an *encephalocele*; and when the protruded brain is a prolongation from one of the ventricles, and is distended by a collection of fluid from an accumulation in the ventricle, it is termed an *hydroencephalocele*. This latter condition is frequently found at the root of the nose, where a protrusion of the anterior horn of the lateral ventricle takes place through a deficiency of the fronto-nasal suture. These malformations are usually found in the middle line, and most frequently at the back of the head, the protrusion taking place through the fissures which separate the four centres of ossification from which the tabular portion of the occipital bone is originally developed (see page 145). They most frequently occur through the upper part of the vertical fissure, which is the last to ossify, but not uncommonly through the lower part, when the foramen magnum may be incomplete. More rarely these protrusions have been met with in other situations than those two above mentioned, both through normal fissures, as the sagittal, lambdoid, and other sutures, and also through abnormal gaps and deficiencies at the sides, and even at the base of the skull.

Fractures of the skull may be divided into those of the vault and those of the base. Fractures of the vault are usually produced by direct violence. This portion of the skull varies in thickness and strength in different individuals, but, as a rule, is sufficiently strong to resist a very considerable amount of violence without being fractured. This is due to several causes:—the rounded shape of the head and its construction of a number of secondary elastic arches, each made up of a single bone; the fact that it consists of a number of bones, united, at all events in early life, by a sutural ligament, which acts as a sort of buffer and interrupts the continuity of any violence applied to the skull; the presence of arches or ridges, both on the inside and outside of the skull, which materially strengthen it; and the mobility of the head upon the spine which further enables it to withstand violence. The elasticity of the bones of the head is especially marked in the skull of the child, and this fact, together with the wide separation of the individual bones from each other, and the interposition between them of other softer structures, renders fracture of the bones of the head a very uncommon event in infants and quite young children; as age advances, and the bones become joined, fracture is more common, though still less liable to occur than in the adult. Fractures of the vault may, and generally do, involve the whole thickness of the bone; but sometimes one table may be fractured without any corresponding injury to the other. Thus, the outer table of the skull may be splintered and driven into the diploë, or in the frontal or mastoid regions into the frontal or mastoid cells, without any injury to the internal table. And, on the other hand, the internal table has been fractured, and portions of it depressed and driven inwards, without any fracture of the outer table. As a rule, in fractures of the skull, the inner table is more splintered and comminuted than the outer, and this is due to



several causes. It is thinner and more brittle; the force of the violence as it passes inwards becomes broken up, and is more diffused by the time it reaches the inner table; the bone being in the form of an arch bends as a whole and spreads out, and thus presses the particles together on the convex surface of the arch, i.e. the outer table, and forces them asunder on the concave surface or inner table; and, lastly, there is nothing firm under the inner table to support it and oppose the force. Fractures of the vault may be simple fissures, or starred and comminuted fractures, and these may be depressed or elevated. These latter cases of fracture with elevation of the fractured portion are uncommon, and can only be produced by direct wound. In comminuted fracture, a portion of the skull is broken into several pieces, the lines of fracture radiating from a centre where the chief impact of the blow was felt; if depressed, a fissure circumscribes the radiating lines, enclosing a portion of skull. If this area is circular it is termed a 'pond' fracture, and would in all probability have been caused by a round instrument, as a life preserver or hammer; if elliptical in shape it is termed a 'gutter fracture,' and would owe its shape to the instrument which had produced it, as a poker.

Fractures of the base are most frequently produced by the extension of a fissure from the vault, as in falls on the head, where the fissure starts from the part of the vault which first struck the ground. Sometimes, however, they are caused by direct violence, when foreign bodies have been forced through the thin roof of the orbit, through the cribriform plate of the ethmoid from being thrust up the nose, or through the roof of the pharynx. Other cases of fracture of the base occur from indirect violence, as in fracture of the occipital bone from impaction of the spinal column against its condyles in falls on the buttocks, knees, or feet, or in cases where the glenoid cavity has been fractured by the violent impact of the condyle of the lower jaw against it from blows on the chin.

The most common place for fracture of the base to occur is through the middle fossa, and here the fissure usually takes a fairly definite course. Starting from the point struck, which is generally somewhere in the neighbourhood of the parietal eminence, it runs downwards through the parietal and squamous portion of the temporal bone and across the petrous portion of this bone, frequently traversing and implicating the internal auditory meatus, to the middle lacerated foramen. From this it may pass across the body of the sphenoid, through the pituitary fossa to the middle lacerated foramen of the other side, and may indeed travel round the whole cranium, so as to completely separate the anterior from the posterior part. The course of the fracture should be borne in mind, as it explains the symptoms to which fracture in this region may give rise: thus, if the fissure pass across the internal auditory meatus, injury to the facial and auditory nerves may result, with consequent facial paralysis and deafness; or the tubular prolongation of the arachnoid around these nerves in the meatus may be torn and thus permit of the escape of the cerebro-spinal fluid should there be a communication between the internal ear and the tympanum and the membrana tympani be ruptured, as is frequently the case: again, if the fissure passes across the pituitary fossa and the mucoperiosteum covering the under surface of the body of the sphenoid is torn, blood will find its way into the pharynx and be swallowed, and after a time vomiting of blood will result. Fractures of the anterior fossa, involving the bones forming the roof of the orbit and nasal fossa, are generally the results of blows on the forehead; but fracture of the cribriform plate of the ethmoid may be a complication of fracture of the nasal bone. When the fracture implicates the roof of the orbit, the blood finds its way into this cavity and, travelling forwards, appears as a subconjunctival ecchymosis. If the roof of the nasal fossa be fractured, the blood escapes from the nose. In rare cases there may be also escape of cerebro-spinal fluid from the nose, where the dura mater and arachnoid have been torn. In fractures of the posterior fossa, extravasation of blood may appear at the nape of the neck.

The bones of the skull being subcutaneous are frequently the seat of nodes, and not uncommonly necrosis results from this cause, as well as from injury. Necrosis may involve the entire thickness of the skull, but is usually confined to the external table. Necrosis of the internal table alone is rarely met with. The bones of the skull are also frequently the seat of sarcomatous tumour.

The skull in rickets is peculiar: the forehead is high, square, and projecting; and the antero-posterior diameter of the skull is long, in relation to the transverse diameter. The bones of the face are small and ill-developed, and this gives the appearance of a larger head than actually exists. The bones of the head are often thick, especially in the neighbourhood of the sutures, and the anterior fontanelle is late in closing, sometimes remaining unclosed till the fourth year. The condition of *cranio-tabes* has by some been also believed to be the result of rickets; by others is believed to be due to inherited syphilis. In these cases the bone undergoes atrophic changes in patches, so that it becomes greatly thinned in places, generally where there is pressure, as from the pillow or nurse's arm. It is, therefore, usually met with in the parietal bone and vertical plate of the occipital bone.

In congenital syphilis deposits of porous bone are often found at the angles of the parietal bones, and two halves of the frontal bone which bound the anterior fontanelle. These deposits are separated by the coronal and sagittal sutures, and give to the skull an appearance like a 'hot cross bun.' They are known as Parrot's nodes, and such a skull has received the name of *natiform*, from its fancied resemblance to the buttocks.



In connection with the bones of the face a common malformation is *cleft palate*, owing to the non-union of the palatal processes of the maxillary or pre-oral arch (see page 92). This cleft may involve the whole or only a portion of the hard palate, and usually involves the soft palate also. The cleft is in the middle line, except it involves the alveolus in front, when it follows the suture between the main portion of the bone and the pre-maxillary bone. Sometimes the cleft runs on either side of the pre-maxillary bone, so that this bone is quite isolated from the maxillary bones and hangs from the end of the vomer. The malformation is usually associated with hare-lip, which, when single, is almost always on one side, corresponding to the position of the suture between the lateral incisor and canine tooth. Some few cases of median hare-lip have been described. In double hare-lip there is a cleft on each side of the middle line.

The bones of the face are sometimes fractured as the result of direct violence. The two most commonly broken are the nasal bone and the inferior maxilla, and of these, the latter is by far the most frequently fractured of all the bones of the face. Fracture of the *nasal* bone is for the most part transverse, and takes place about half an inch from the free margin. The broken portion may be displaced backwards or more generally to one side by the force which produced the lesion, as there are no muscles here which can cause displacement. The *malar* bone is probably never broken alone, that is to say, unconnected with a fracture of the other bones of the face. The *zygomatic arch* is occasionally fractured, and when this occurs from direct violence, as is usually the case, the fragments may be displaced inwards. This lesion is often attended with great difficulty or even inability to open and shut the mouth, and this has been stated to be due to the depressed fragments perforating the temporal muscle, but would appear rather to be caused by the injury done to the bony origin of the masseter muscle. Fractures of the *superior maxilla* may vary much in degree, from the chipping off of a portion of the alveolar arch, a frequent accident when the old 'key' instrument was used for the extraction of teeth, to an extensive comminution of the whole bone from severe violence, as the kick of a horse. The most common situation for a fracture of the *inferior maxillary bone* is in the neighbourhood of the canine tooth, as at this spot the jaw is weakened by the deep socket for the fang of this tooth; it is next most frequently fractured at the angle; then at the symphysis, and finally the neck of the condyle or the coronoid process may be broken. Occasionally a double fracture may occur, one in either half of the bone. The fractures are usually compound, from laceration of the mucous membrane covering the gums. The displacement is mainly the result of the same violence as produced the injury, but may be further increased by the action of the muscles passing from the neighbourhood of the symphysis to the hyoid bone.

The superior and inferior maxillary bones are both of them frequently the seat of necrosis: though the disease affects the lower much more frequently than the upper jaw, probably on account of the greater supply of blood to the latter. It may be the result of periostitis, from tooth irritation, injury, or the action of some specific poison, as syphilis, or from salivation by mercury; it not unfrequently occurs in children after attacks of the exanthematous fevers, and a special form occurs from the action of the fumes of phosphorus in persons engaged in match-making.

Tumours attack the jaw-bones not unfrequently, and these may be either innocent or malignant: in the upper jaw cysts may occur in the antrum, constituting the so-called dropsy of the antrum; or, again, cysts may form in either jaw in connection with the teeth: either cysts connected with the roots of fully developed teeth, the 'dental cyst'; or cysts connected with imperfectly developed teeth, the 'dentigerous cyst.' Solid innocent tumours include the fibroma, the chondroma, and the osteoma. Of malignant tumours there are two classes, the sarcomata and the epithelioma. The sarcoma are of various kinds, the spindle-celled and round-celled of a very malignant character, and the myeloid sarcoma principally affecting the alveolar margin of the bone. Of the epitheliomata we find the squamous variety spreading to the bone from the palate or gum, and the cylindrical epithelioma originating in the antrum or nasal fosse.

Both superior and inferior maxillary bones occasionally require removal for tumours and in some other conditions. The upper jaw is removed by an incision from the inner canthus of the eye, along the side of the nose, round the ala, and down the middle line of the upper lip. A second incision is carried outwards from the inner canthus of the eye along the lower margin of the orbit as far as the prominence of the malar bone. The flap thus formed is reflected outwards and the surface of the bone exposed. The connections of the bone to the other bones of the face are then divided with a narrow saw. They are (1) the junction with the malar bone, passing into the sphenomaxillary fissure: (2) the nasal process; a small portion of its upper extremity, connected with the nasal bone in front, the lachrymal bone behind, and the frontal bone above, being left: (3) the connection with the bone on the opposite side and the palate in the roof of the mouth. The bone is now firmly grasped with lion-forceps, and by means of a rocking movement upwards and downwards the remaining attachments of the orbital plate with the ethmoid, and of the back of the bone with the palate, broken through. The soft palate is first separated from the hard with a scalpel and is not removed. Occasionally in removing the upper jaw, it will be found that the orbital plate can be spared, and this should always be done if possible. A horizontal saw-cut is to be made just below the infra-orbital foramen, and the bone cut through with a chisel and mallet.

Removal of one half of the lower jaw is sometimes required. If possible, the section of the bone should be made to one side of the symphysis so as to save the genial tubercles and the origin of the Genio-hyo-glossus muscle, as otherwise the tongue tends to fall backwards and may produce suffocation. Having extracted the central or preferably the lateral incisor tooth, a vertical incision is made down to the bone, commencing at the free margin of the lip, and carried to the lower border of the bone; it is then carried along its lower border to the angle and up the posterior margin of the ramus to a level with the lobule of the ear. The flap thus formed is raised by separating all the structures attached to the outer surface of the bone. The jaw is now sawn through at the point where the tooth has been extracted, and the knife passed along the inner side of the jaw, separating the structures attached to this surface. The jaw is then grasped by the surgeon and strongly depressed, so as to bring down the coronoid process and enable the operator to sever the tendon of the Temporal muscle. The jaw can be now further depressed, care being taken not to evert it or rotate it outwards, which would endanger the internal maxillary artery, and the External pterygoid torn through or divided. The capsular ligament is now opened in front and the lateral ligaments divided, and the jaw removed with a few final touches of the knife.

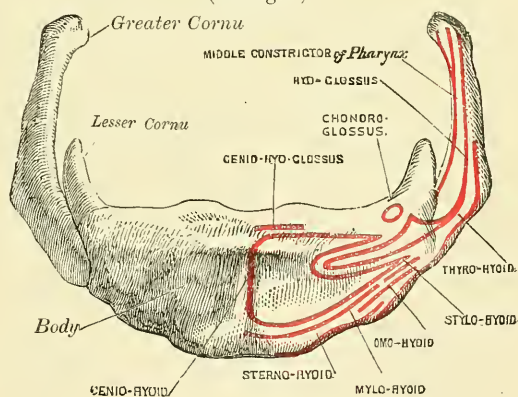
The antrum occasionally requires tapping for suppuration. This may be done through the socket of a tooth, preferably the first molar, the fangs of which are most intimately connected with the antrum, or through the facial aspect of the bone above the alveolar process. This latter method does not perhaps afford such efficient drainage, but there is less chance of food finding its way into the cavity. The operation may be performed by incising the mucous membrane above the second molar tooth, and driving a trocar or any sharp pointed instrument into the cavity.

## HYOID BONE

The **Hyoid bone** is named from its resemblance to the Greek upsilon; it is also called the *lingual bone*, because it supports the tongue, and gives attachment to its numerous muscles. It is a bony arch, shaped like a horse-shoe, and consisting of five segments, a body, two greater cornua, and two lesser cornua. It is suspended from the tip of the styloid processes of the temporal bones by ligamentous bands, the *stylo-hyoid* ligaments.

The **Body** (*basi-hyal*) forms the central part of the bone, and is of a quadrilateral form; its *anterior surface* (fig. 189), convex, directed forwards and upwards, is divided into two parts by a vertical ridge which descends along the median line, and is crossed at right angles by a horizontal ridge, so that this surface is divided into four spaces or depressions. At the point of meeting of these two lines is a prominent elevation, the *tubercle*. The portion above the horizontal ridge is directed upwards, and is sometimes described as the superior border. The anterior surface gives attachment to the Genio-hyoid in the greater part of its extent; above, to the Genio-hyo-glossus; below, to the Mylo-hyoid, Stylo-hyoid, and aponeurosis of the Digastric (suprahyoid aponeurosis); and between these to part of the Hyo-glossus. The *posterior surface* is smooth, concave, directed backwards and downwards, and separated from the epiglottis by the thyro-hyoid membrane, and by a quantity of loose areolar tissue. The *superior border* is rounded, and gives attachment to the thyro-hyoid membrane, part of the Genio-hyo-glossi, and Chondro-glossi muscles. The *inferior border* gives attachment, in front, to the Sterno-hyoid; behind, to the Omo-hyoid and to part of the Thyro-hyoid, at its junction with the great cornu. It also gives attachment to the Levator glandulæ thyroideæ, when this muscle is present. The *lateral surfaces*

FIG. 189.—Hyoid bone. Anterior surface (enlarged).





are small, oval, convex facets, covered with cartilage for articulation with the greater cornua.

The **Greater Cornua** (*thyro-hyal*) project backwards from the lateral surfaces of the body; they are flattened from above downwards, diminish in size from before backwards, and terminate posteriorly in a tubercle for the attachment of the lateral thyro-hyoid ligament. The outer surface gives attachment to the Hyo-glossus, their upper border to the Middle constrictor of the pharynx, their lower border to part of the Thyro-hyoid muscle. In youth, the great cornua are connected to the body by cartilaginous surfaces, and held together by ligaments; in middle life they usually become joined.

The **Lesser Cornua** (*cerato-hyals*) are two small, conical-shaped eminences, attached by their bases to the angles of junction between the body and greater cornua, and giving attachment by their apices to the stylo-hyoid ligaments.\* The smaller cornua are connected to the body of the bone by a distinct diarthrodial joint, which usually persists throughout life, but occasionally becomes ankylosed.

**Development.**—By *five* centres: one for the body, and one for each cornu. Ossification commences in the body about the eighth month, and in the greater cornua towards the end of foetal life. Ossification of the lesser cornua commences some months after birth.

**Attachment of Muscles.**—Sterno-hyoid, Thyro-hyoid, Omo-hyoid, aponeurosis of the Digastric, Stylo-hyoid, Mylo-hyoid, Genio-hyoid, Genio-hyo-glossus; Chondro-glossus, Hyo-glossus, Middle constrictor of the pharynx, and occasionally a few fibres of the Inferior lingualis. It also gives attachment to the thyro-hyoidean membrane, and the stylo-hyoid, thyro-hyoid, and hyo-epiglottic ligaments.

**Surface Form.**—The hyoid bone can be felt in the receding angle below the chin, and the finger can be carried along the whole length of the bone to the greater cornu, which is situated just below the angle of the jaw. This process of bone is best perceived by making pressure on one cornu and so pushing the bone over to the opposite side, when the cornu of this side will be distinctly felt immediately beneath the skin. This process of bone is an important landmark in ligature of the lingual artery.

**Surgical Anatomy.**—The hyoid bone is occasionally fractured, generally from direct violence, as in the act of garotting or throttling. The great cornu is the part of the bone most frequently broken, but sometimes the fracture takes place through the body of the bone. In consequence of the muscles of the tongue having important connections with this bone, there is great pain upon any attempt being made to move the tongue, as in speaking or swallowing.

## THE THORAX

The **Thorax**, or **Chest**, is an osseo-cartilaginous cage, containing and protecting the principal organs of respiration and circulation. It is conical in shape, being narrow above and broad below, flattened from before backwards, and longer behind than in front. It is somewhat cordiform on transverse section.

**Boundaries.**—The *posterior* surface is formed by the twelve dorsal vertebræ and the posterior part of the ribs. It is convex from above downwards, and presents on each side of the middle line a deep groove, in consequence of the direction backwards and outwards which the ribs take from their vertebral extremities to their angles. The *anterior* surface is flattened or slightly convex, and inclined forwards from above downwards. It is formed by the sternum and costal cartilages. The *lateral* surfaces are convex; they are formed by the ribs, separated from each other by spaces, the *intercostal spaces*. These spaces are eleven in number, and are occupied by the intercostal muscles.

The *upper opening* of the thorax is reniform in shape, being broader from side to side than from before backwards. It is formed by the first dorsal vertebra behind, the upper margin of the sternum in front, and the first rib on each side. It slopes downwards and forwards, so that the anterior part of the

\* These ligaments in many animals are distinct bones, and in man are occasionally ossified to a certain extent.



ring is on a lower level than the posterior. The antero-posterior diameter is about two inches. The *lower* opening is formed by the twelfth dorsal vertebra behind, by the twelfth rib at the sides, and in front by the cartilages of the eleventh, tenth, ninth, eighth, and seventh ribs, which ascend on either side and form an angle, the *subcostal angle*, from the centre of which the ensiform cartilage projects. It is wider transversely than from before backwards. It slopes obliquely downwards and backwards; so that the cavity of the thorax is much deeper behind than in front. The Diaphragm closes in the opening forming the floor of the thorax.

In the female, the thorax differs as follows from the male:—1. Its general capacity is less. 2. The sternum is shorter. 3. The upper margin of the sternum is on a level with the lower part of the body of the third dorsal vertebra, whereas in the male it is on a level with the lower part of the body of the second dorsal vertebra. 4. The upper ribs are more movable, and so allow a greater enlargement of the upper part of the thorax than in the male.

### THE STERNUM

The **Sternum** (*στέρνον*, the chest) (figs. 190, 191) is a flat, narrow bone, situated in the median line of the front of the chest, and consisting, in the adult, of three portions. It has been likened to an ancient sword: the upper piece, representing the handle, is termed the *manubrium*; the middle and largest piece, which represents the chief part of the blade, is termed the *gladiolus*; and the inferior piece, which is likened to the point of the sword, is termed the *ensiform* or *xiphoid appendix*. In its natural position its inclination is oblique from above, downwards and forwards. It is flattened in front, concave behind, broad above, becoming narrowed at the point where the first and second pieces are connected; after which it again widens a little, and is pointed at its extremity. Its average length in the adult is six inches, being rather longer in the male than in the female.

The **First Piece** of the sternum, or **Manubrium** (*pre-sternum*), is of a somewhat triangular form, broad and thick above, narrow below at its junction with the middle piece. Its *anterior surface*, convex from side to side, concave from above downwards, is smooth, and affords attachment on each side to the Pectoralis major and sternal origin of the Sterno-cleido-mastoid muscles. In well-marked bones the ridges limiting the attachment of these muscles are very distinct. Its *posterior surface*, concave and smooth, affords attachment on each side to the Sterno-hyoid and Sterno-thyroid muscles. The *superior border*, the thickest, presents at its centre the *pre-sternal notch*; and on each side an oval articular surface, directed upwards, backwards, and outwards, for articulation with the sternal end of the clavicle. The *inferior border* presents an oval, rough surface, covered in the recent state with a thin layer of cartilage, for articulation with the second portion of the bone. The *lateral borders* are marked above by a depression for the first costal cartilage, and below by a small facet, which, with a similar facet on the upper angle of the middle portion of the bone, forms a notch for the reception of the costal cartilage of the second rib. These articular surfaces are separated by a narrow, curved edge, which slopes from above downwards and inwards.

The **Second Piece** of the sternum, or **Gladiolus** (*meso-sternum*), considerably longer, narrower, and thinner than the first piece, is broader below than above. Its *anterior surface* is nearly flat, directed upwards and forwards, and marked by three transverse lines which cross the bone opposite the third, fourth, and fifth articular depressions. These lines are produced by the union of the four separate pieces of which this part of the bone consists at an early period of life. At the junction of the third and fourth pieces is occasionally seen an orifice, the *sternal foramen*; it varies in size and form in different individuals, and pierces the bone from before backwards. This surface affords attachment on each side to the

FIG. 190.—Sternum and costal cartilages.

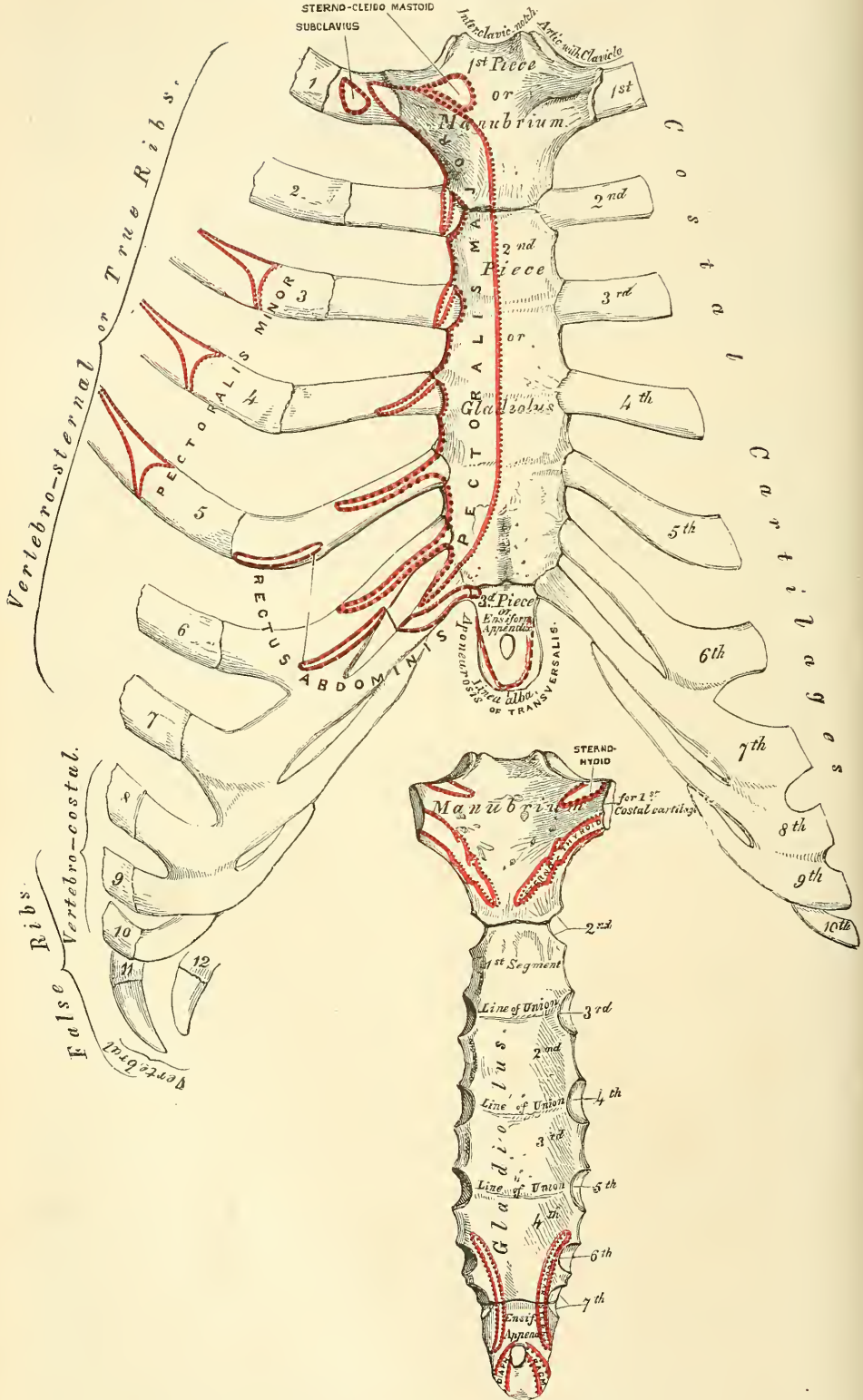


FIG. 191.—Posterior surface of sternum.

sternal origin of the Pectoralis major. The *posterior surface*, slightly concave, is also marked by three transverse lines; but they are less distinct than those in front: this surface affords attachment below, on each side, to the Triangularis sterni muscle, and occasionally presents the posterior opening of the sternal foramen. The *superior border* presents an oval surface for articulation with the manubrium. The *inferior border* is narrow, and articulates with the ensiform appendix. Each *lateral border* presents, at each superior angle, a small facet, which, with a similar facet on the manubrium, forms a cavity for the cartilage of the second rib; the four succeeding angular depressions receive the cartilages of the third, fourth, fifth, and sixth ribs, whilst each inferior angle presents a small facet, which, with a corresponding one on the ensiform appendix, forms a notch for the cartilage of the seventh rib. These articular depressions are separated by a series of curved interarticular intervals, which diminish in length from above downwards, and correspond to the intercostal spaces. Most of the cartilages belonging to the true ribs, as will be seen from the foregoing description, articulate with the sternum at the line of junction of two of its primitive component segments. This is well seen in many of the lower animals, where the separate parts of the bone remain ununited longer than in man. In this respect a striking analogy exists between the mode of connection of the ribs with the vertebral column, and the connection of the costal cartilages with the sternum.

The **Third Piece** of the sternum, the **Ensiform** or **Xiphoid Appendix** (*meta-sternum*), is the smallest of the three; it is thin and elongated in form, cartilaginous in structure in youth, but more or less ossified at its upper part in the adult. Its *anterior surface* affords attachment to the chondro-xiphoid ligament; its *posterior surface*, to some of the fibres of the Diaphragm and Triangularis sterni muscles; its *lateral borders*, to the aponeurosis of the abdominal muscles. Above, it articulates with the lower end of the gladiolus, and at each superior angle presents a facet for the lower half of the cartilage of the seventh rib; below, by its pointed extremity, it gives attachment to the linea alba. This portion of the sternum is very various in appearance, being sometimes pointed, broad and thin, sometimes bifid, or perforated by a round hole, occasionally curved, or deflected considerably to one or the other side.

**Structure.**—The bone is composed of delicate cancellous structure, covered by a thin layer of compact tissue, which is thickest in the manubrium, between the articular facets for the clavicles.

**Development.**—The sternum, including the ensiform appendix, is developed by six centres: one for the first piece or manubrium, four for the second piece or gladiolus, and one for the ensiform appendix. Up to the middle of foetal life the sternum is entirely cartilaginous, and when ossification takes place the ossific granules are deposited in the middle of the intervals between the articular depressions for the costal cartilages, in the following order: in the first piece, between the fifth and sixth months; in the second and third, between the sixth and seventh months; in the fourth piece, at the ninth month; in the fifth, within the first year, or between the first and second years after birth; and in the ensiform appendix, between the second and the seventeenth or eighteenth years by a single centre which makes its appearance at the upper part, and proceeds gradually downwards (fig. 192). To these may be added the occasional existence, as described by Breschet, of two small episternal centres, which make their appearance one on each side of the pre-sternal notch. They are probably vestiges of the episternal bone of the monotremata and lizards. It occasionally happens that some of the segments are formed from more than one centre, the number and position of which vary (fig. 194). Thus, the first piece may have two, three, or even six centres. When two are present, they are generally situated one above the other, the upper one being the larger;\* the second piece has seldom more than one; the third, fourth, and fifth pieces are often

\* Sir George Humphry states that this is 'probably the more complete condition.'



Fig. 192.—Development of the sternum, by six centres.

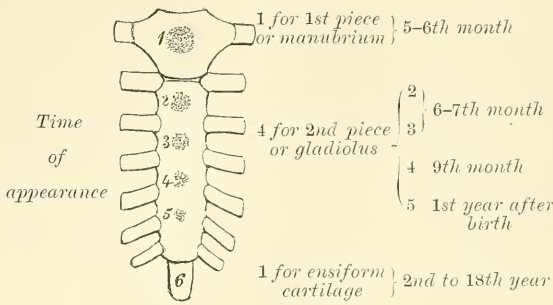


FIG. 193.

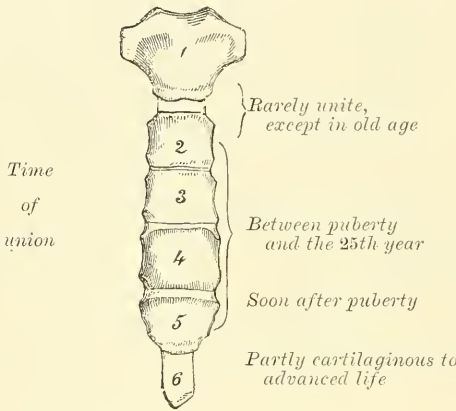


FIG. 194.—Peculiarities.

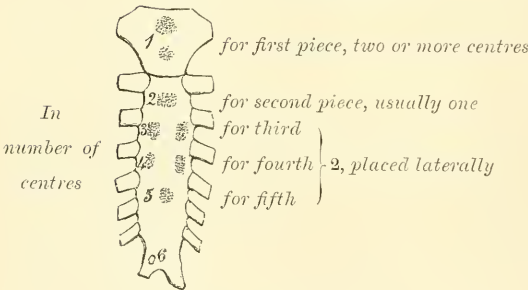
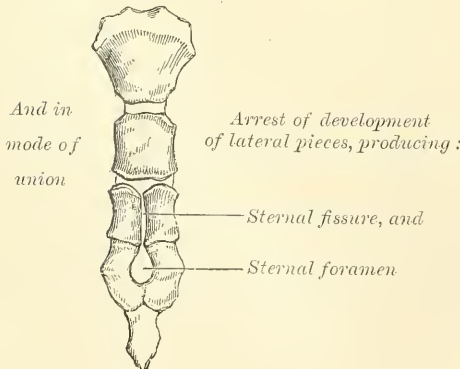


FIG. 195.



formed from two centres placed laterally, the irregular union of which will serve to explain the occasional occurrence of the sternal foramen (fig. 195), or of the vertical fissure which occasionally intersects this part of the bone, and which is further explained by the manner in which the cartilaginous matrix, in which ossification takes place, is formed (see page 90). Union of the various centres of the gladiolus commences about puberty, from below, and proceeds upwards, so that by the age of twenty-five they are all united, and this portion of bone consists of one piece (fig. 193). The ensiform cartilage becomes joined to the gladiolus about forty. The manubrium is occasionally, but not invariably, joined to the gladiolus in advanced life by bone. When this union takes place, however, it is generally only superficial, a portion of the centre of the sutural cartilage remaining unossified.

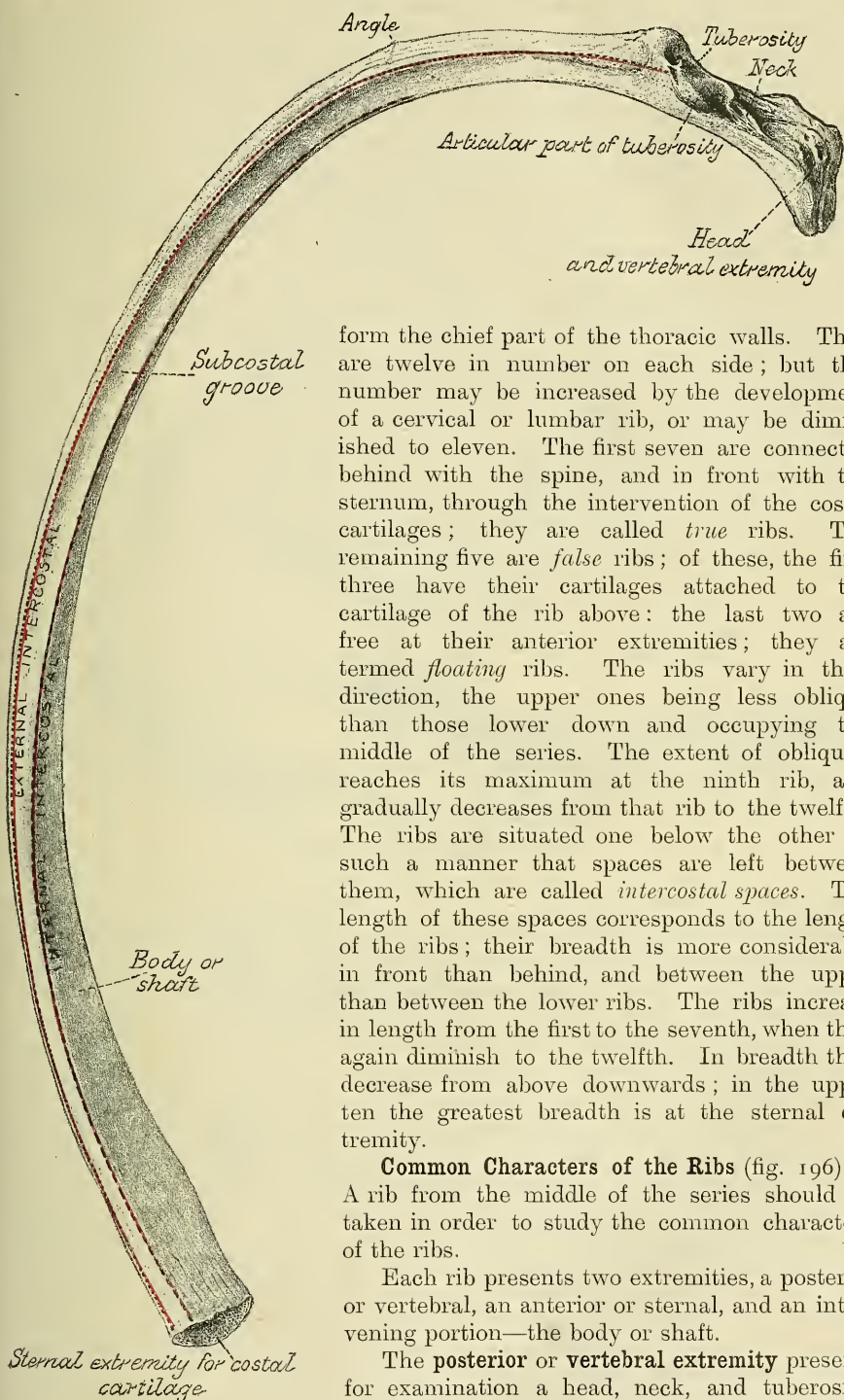
**Articulations.** — With the clavicles and seven costal cartilages on each side.

**Attachment of Muscles.** — To nine pairs and one single muscle: the Pectoralis major, Sterno-cleido-mastoid, Sterno-hyoid, Sterno-thyroid, Triangularis sterni, the aponeuroses of the Obliquus externus, Obliquus internus, Transversalis, and Rectus muscles, and Diaphragm.

THE RIBS

The **Ribs** are elastic arches of bone, which

FIG. 196.—A central rib of left side.



form the chief part of the thoracic walls. They are twelve in number on each side; but this number may be increased by the development of a cervical or lumbar rib, or may be diminished to eleven. The first seven are connected behind with the spine, and in front with the sternum, through the intervention of the costal cartilages; they are called *true ribs*. The remaining five are *false ribs*; of these, the first three have their cartilages attached to the cartilage of the rib above: the last two are free at their anterior extremities; they are termed *floating ribs*. The ribs vary in their direction, the upper ones being less oblique than those lower down and occupying the middle of the series. The extent of obliquity reaches its maximum at the ninth rib, and gradually decreases from that rib to the twelfth. The ribs are situated one below the other in such a manner that spaces are left between them, which are called *intercostal spaces*. The length of these spaces corresponds to the length of the ribs; their breadth is more considerable in front than behind, and between the upper than between the lower ribs. The ribs increase in length from the first to the seventh, when they again diminish to the twelfth. In breadth they decrease from above downwards; in the upper ten the greatest breadth is at the sternal extremity.

#### Common Characters of the Ribs (fig. 196).—

A rib from the middle of the series should be taken in order to study the common characters of the ribs.

Each rib presents two extremities, a posterior or vertebral, an anterior or sternal, and an intervening portion—the body or shaft.

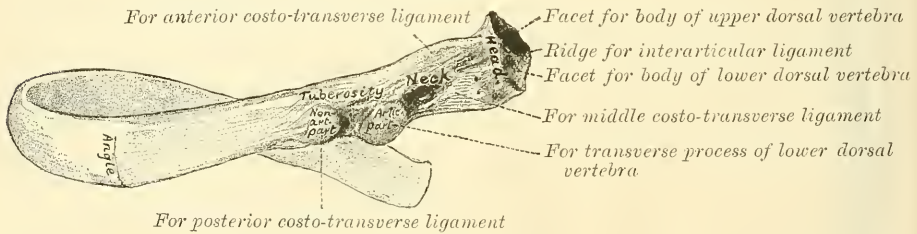
The **posterior or vertebral extremity** presents for examination a head, neck, and tuberosity.

The **head** (fig. 197) is marked by a kidney-shaped articular surface, divided by a horizontal ridge into two facets for articulation with the costal cavity formed by the junction of the bodies of two contiguous dorsal vertebræ; the upper facet is small, the inferior one of larger size; the ridge separating them serves for the attachment of the interarticular ligament.

The **neck** is that flattened portion of the rib which extends outwards from the head; it is about an inch long, and is placed in front of the transverse process of the lower of the two vertebræ with which the head articulates. Its *anterior surface* is flat and smooth, its *posterior* rough, for the attachment of the middle costo-transverse ligament, and perforated by numerous foramina, the direction of which is less constant than those found on the inner surface of the shaft. Of its two borders the *superior* presents a rough crest for the attachment of the anterior costo-transverse ligament; its *inferior border* is rounded. On the posterior surface of the neck, just where it joins the shaft, and nearer the lower than the upper border, is an eminence—the **tuberosity**, or **tubercle**; it consists of an articular and a non-articular portion. The *articular portion*, the more internal and inferior of the two, presents a small, oval surface for articulation with the extremity of the transverse process of the lower of the two vertebræ to which the head is connected. The *non-articular portion* is a rough elevation, which affords attachment to the posterior costo-transverse ligament. The tubercle is much more prominent in the upper than in the lower ribs.

The **shaft** is thin and flat, so as to present two surfaces, an external and an internal; and two borders, a superior and an inferior. The *external surface* is convex, smooth, and marked, at its back part, a little in front of the tuberosity, by a prominent line, directed obliquely from above downwards and outwards; this gives attachment to a tendon of the Ilio-costalis muscle, or of one of its accessory portions, and is called the **angle**. At this point the rib is bent in two

FIG. 197.—Vertebral extremity of a rib. External surface.



directions. If the rib is laid upon its lower border, it will be seen that the portion of the shaft in front of the angle rests upon this border, while the portion of the shaft behind the angle is bent inwards and at the same time tilted upwards. The interval between the angle and the tuberosity increases gradually from the second to the tenth rib. The portion of bone between these two parts is rounded, rough, and irregular, and serves for the attachment of the Longissimus dorsi muscle. The portion of bone between the tubercle and sternal extremity is also slightly twisted upon its own axis, the external surface looking downwards behind the angle, a little upwards in front of it. This surface presents, towards its sternal extremity, an oblique line, the *anterior angle*. The *internal surface* is concave, smooth, directed a little upwards behind the angle, a little downwards in front of it. This surface is marked by a ridge which commences at the lower extremity of the head; it is strongly marked as far as the inner side of the angle, and gradually becomes lost at the junction of the anterior with the middle third of the bone. The interval between it and the inferior border presents a groove, *subcostal*, for the intercostal vessels and nerve. At the back part of the bone, this groove belongs to the inferior border, but just in front of the angle, where it is deepest and broadest, it corresponds to the internal surface. The superior edge of the groove is rounded; it serves for the attachment of the Internal intercostal muscle. The inferior edge corresponds to the lower margin of the rib, and gives attachment to the External intercostal. Within the groove are seen the orifices of numerous small foramina, which traverse the wall of the shaft obliquely from before backwards. The *superior border*, thick and rounded, is marked by



an external and an internal lip, more distinct behind than in front; they serve for the attachment of the External and Internal intercostal muscles. The inferior border, thin and sharp, has attached to it the External intercostal muscle. The anterior or sternal extremity is flattened, and presents a porous, oval, concave depression, into which the costal cartilage is received.

PECULIAR RIBS

The ribs which require especial consideration are five in number—viz. the first, second, tenth, eleventh, and twelfth.

Peculiar ribs.

FIG. 198.

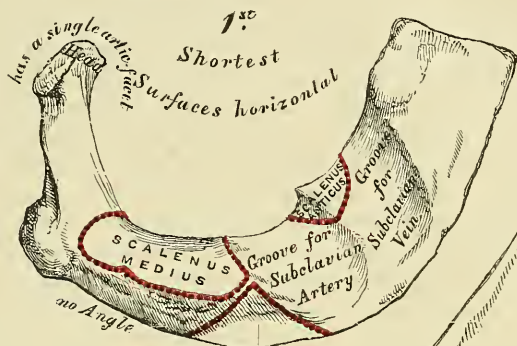


FIG. 199.

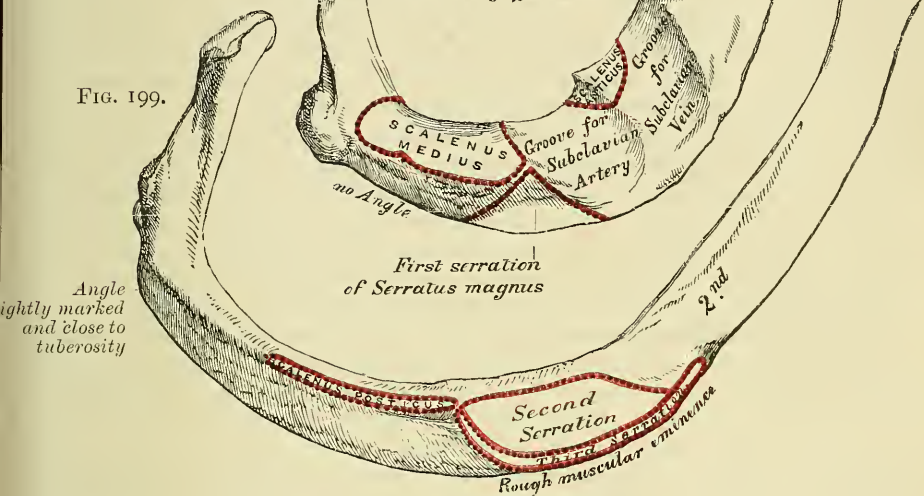


FIG. 200.

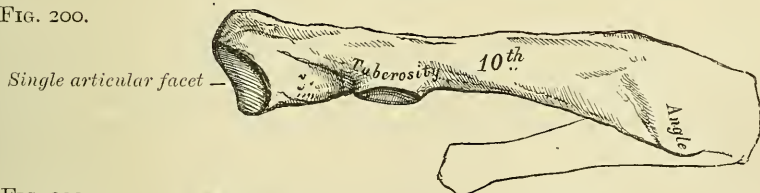


FIG. 201.





FIG. 202.



The first rib (fig. 198) is one of the shortest and the most curved of all the ribs; it is broad and flat, its surfaces looking upwards and downwards, and its borders inwards and outwards. The head is of small size, rounded, and presents only a single articular facet for articulation with the body of the first dorsal

vertebra. The *neck* is narrow and rounded. The *tuberosity*, thick and prominent, rests on the outer border. There is no angle, but in this situation the rib is slightly bent, with the convexity of the bend upwards, so that the head of the bone is directed downwards. The *upper surface* of the shaft is marked by two shallow depressions, separated by a small rough surface for the attachment of the Scalenus anticus muscle—the groove in front of it transmitting the subclavian vein, that behind it the subclavian artery. Between the groove for the subclavian artery and the tuberosity is a rough surface for the attachment of the Scalenus medius muscle. The *under surface* is smooth, and destitute of the groove observed on the other ribs. The *outer border* is convex, thick, and rounded, and at its posterior part gives attachment to the first serration of the Serratus magnus; the *inner* is concave, thin, and sharp, and marked about its centre by the commencement of the rough surface for the Scalenus anticus. The *anterior extremity* is larger and thicker than any of the other ribs.

The **second rib** (fig. 199) is much longer than the first, but bears a very considerable resemblance to it in the direction of its curvature. The non-articular portion of the tuberosity is occasionally only slightly marked. The *angle* is slight, and situated close to the tuberosity, and the shaft is not twisted, so that both ends touch any plane surface upon which it may be laid; but there is a similar though slighter bend, with its convexity upwards, to that found in the first rib. The shaft is not horizontal, like that of the first rib; its *outer surface*, which is convex, looking upwards and a little outwards. It presents, near the middle, a rough eminence for the attachment of the second and third digitations of the Serratus magnus; behind and above which is attached the Scalenus posticus. The *inner surface*, smooth and concave, is directed downwards and a little inwards: it presents a short groove towards its posterior part.

The **tenth rib** (fig. 200) has only a single articular facet on its head.

The **eleventh and twelfth ribs** (figs. 201 and 202) have each a single articular facet on the head, which is of rather large size; they have no neck or tuberosity, and are pointed at the extremity. The eleventh has a slight angle and a shallow groove on the lower border. The twelfth has neither, and is much shorter than the eleventh, and the head has a slight inclination downwards.

**Structure.**—The ribs consist of cancellous tissue, enclosed in a thin, compact layer.

**Development.**—Each rib, with the exception of the last two, is developed by *three* centres: one for the shaft, one for the head, and one for the tubercle. The last two have only *two* centres, that for the tubercle being wanting. Ossification commences in the shaft of the ribs at a very early period, before its appearance in the vertebræ. The epiphysis of the head, which is of a slightly angular shape, and that for the tubercle, of a lenticular form, make their appearance between the sixteenth and twentieth years, and are not united to the rest of the bone until about the twenty-fifth year.

**Attachment of Muscles.**—To nineteen: the Internal and External intercostals, Scalenus anticus, Scalenus medius, Scalenus posticus, Pectoralis minor, Serratus magnus, Obliquus externus, Quadratus lumborum, Diaphragm, Latissimus dorsi, Serratus posticus superior, Serratus posticus inferior, Ilio-costalis, Musculus accessorius ad ilio-costalem, Longissimus dorsi, Cervicalis ascendens, Levatores costarum, and Infra-costales.

#### THE COSTAL CARTILAGES

The **Costal Cartilages** (fig. 190, p. 212) are bars of white, elastic hyaline cartilage, which serve to prolong the ribs forward to the front of the chest, and contribute very materially to the elasticity of its walls. The first seven are connected with the sternum, the next three with the lower border of the cartilage of the preceding rib. The cartilages of the last two ribs, which have pointed extremities, float freely in the walls of the abdomen. Like the ribs, the costal

cartilages vary in their length, breadth, and direction. They increase in length from the first to the seventh, then gradually diminish to the last. They diminish in breadth, as well as the intervals between them, from the first to the last. They are broad at their attachment to the ribs, and taper towards their sternal extremities, excepting the first two, which are of the same breadth throughout, and the sixth, seventh, and eighth, which are enlarged where their margins are in contact. In direction they also vary: the first descends a little, the second is horizontal, the third ascends slightly, whilst all the rest follow the course of the ribs for a short extent, and then ascend to the sternum or preceding cartilage. Each costal cartilage presents two surfaces, two borders, and two extremities. The *anterior surface* is convex, and looks forwards and upwards: that of the first gives attachment to the costo-clavicular ligament and the Subclavius muscle; that of the second, third, fourth, fifth, and sixth, at their sternal ends, to the Pectoralis major.\* The others are covered by, and give partial attachment to, some of the great flat muscles of the abdomen. The *posterior surface* is concave, and directed backwards and downwards, the first giving attachment to the Sterno-thyroid, and the six or seven inferior ones affording attachment to the Transversalis muscle and the Diaphragm. Of the two borders, the *superior* is concave, the *inferior* convex: they afford attachment to the Intercostal muscles, the upper border of the sixth giving attachment to the Pectoralis major muscle. The contiguous borders of the sixth, seventh, and eighth, and sometimes the ninth and tenth, costal cartilages present small, smooth, oblong-shaped facets at the points where they articulate. Of the two extremities, the *outer* one is continuous with the osseous tissue of the rib to which it belongs. The *inner* extremity of the first is continuous with the sternum; the six succeeding ones have rounded extremities, which are received into shallow concavities on the lateral margins of the sternum. The inner extremities of the eighth, ninth, and tenth costal cartilages are pointed, and are connected with the cartilage above. Those of the eleventh and twelfth are free and pointed.

The costal cartilages are most elastic in youth, those of the false ribs being more so than the true. In old age they become of a deep yellow colour, and are prone to calcify.

**Attachment of Muscles.**—To nine: the Subclavius, Sterno-thyroid, Pectoralis major, Internal oblique, Transversalis, Rectus, Diaphragm, Triangularis sterni, and Internal intercostals.

*Surface Form.*—The bones of the chest are to a very considerable extent covered by muscles, so that in the strongly-developed muscular subject they are for the most part concealed. In the emaciated subject, on the other hand, the ribs, especially in the lower and lateral region, stand out as prominent ridges with the sunken, intercostal spaces between them.

In the middle line, in front, the superficial surface of the sternum is to be felt throughout its entire length, at the bottom of a deep median furrow situated between the two great pectoral muscles and called the *sternal furrow*. These muscles overlap the anterior surface somewhat, so that the whole of the sternum in its entire width is not subcutaneous, and this overlapping is greater opposite the centre of the bone than above and below, so that the furrow is wide at its upper and lower part, but narrower in the middle. The centre of the upper border of the sternum is visible, constituting the presternal notch, but the lateral parts of this border are obscured by the tendinous origins of the Sterno-mastoid muscles, which present themselves as oblique tendinous cords, which narrow and deepen the notch. Lower down on the subcutaneous surface a well-defined transverse ridge is always to be felt. This denotes the line of junction of the manubrium and body of the bone and is a useful guide to the second costal cartilage, and thus to the identity of any given rib. The second rib being found, through its costal cartilage, it is easy to count downwards and find any other. From the middle of the bone the furrow spreads out, and, exposing more of the surface of the body of the sternum, terminates below in a sudden depression, the *infra-sternal depression* or *pit of the stomach* (*scrobiculus cordis*), which corresponds to the ensiform cartilage. This depression lies between the cartilages of the seventh rib, and in it the ensiform cartilage may be felt. The sternum in its vertical diameter presents a general convexity forwards, the most prominent point of which is at the joint between the manubrium and gladiolus.

\* The first and seventh also, occasionally, give origin to the same muscle.



On each side of the sternum the costal cartilages and ribs on the front of the chest are partially obscured by the great pectoral muscle; through which, however, they are to be felt as ridges, with depressed intervals between them, corresponding to the intercostal spaces. Of these spaces, the one between the second and third ribs is the widest, the next two somewhat narrower, and the remainder, with the exception of the last two, comparatively narrow.

The lower border of the Pectoralis major muscle corresponds to the fifth rib, and below this, on the front of the chest, the broad, flat outline of the ribs, as they begin to ascend, and the more rounded outline of the costal cartilages, are often visible. The lower boundary of the front of the thorax, the *abdomino-thoracic arch*, which is most plainly seen by arching the body backwards, is formed by the ensiform cartilage and the cartilages of the seventh, eighth, ninth, and tenth ribs, and the extremities of the eleventh and twelfth ribs or their cartilages.

On each side of the chest, from the axilla downwards, the flattened external surfaces of the ribs may be defined in the form of oblique ridges, separated by depressions corresponding to the intercostal spaces. They are, however, covered by muscles, which obscure their outline to a certain extent in the strongly developed. Nevertheless, the ribs, with the exception of the first, can generally be followed over the front and sides of the chest without difficulty. The first rib, being almost completely covered by the clavicle and scapula, can only be distinguished in a small portion of its extent. At the back, the angles of the ribs form a slightly-marked oblique line, on each side of and some distance from the vertebral spines. This line diverges somewhat as it descends, and external to it is a broad, convex surface, caused by the projection of the ribs beyond their angles. Over this surface, except where covered by the scapula, the individual ribs can be distinguished.

*Surgical Anatomy.*—Malformations of the sternum present nothing of surgical importance beyond the fact that abscesses of the mediastinum may sometimes escape through the sternal foramen. Fracture of the sternum is by no means common, owing, no doubt, to the elasticity of the ribs and their cartilages which support it like so many springs. When broken, it is frequently associated with fracture of the spine, and may be caused by forcibly bending the body either backwards; or forwards until the chin becomes impacted against the top of the sternum. It may also be fractured by direct violence or by muscular action. The fracture usually occurs in the upper half of the body of the bone. Dislocation of the gladiolus from the manubrium also takes place, and is sometimes described as a fracture.

The bone being subcutaneous is frequently the seat of gummatous tumours and not uncommonly is affected with caries. Occasionally the bone, and especially its ensiform appendix, becomes altered in shape and driven inwards by the pressure, in workmen, of tools against their chest.

The ribs are frequently broken, though from their connections and shape they are able to withstand great force, yielding under the injury and recovering themselves like a spring. The middle of the series are the ones most liable to fracture. The first and to a less extent the second, being protected by the clavicle, are rarely fractured; and the eleventh and twelfth on account of their loose and floating condition enjoy a like immunity. The fracture generally occurs from indirect violence, from forcible compression of the chest wall, and the bone then gives way at its weakest part, i.e. just in front of the angle. But the ribs may also be broken by direct violence, when the bone gives way and is driven inwards at the point struck, or by muscular action. It seems probable, however, that in these latter cases the bone has undergone some atrophic changes. Fracture of the ribs is frequently complicated with some injury to the viscera contained within the thorax or upper part of the abdominal cavity, and this is most likely to occur in fractures from direct violence.

Fracture of the costal cartilages may also take place, though it is a comparatively rare injury.

The thorax is frequently found to be altered in shape in certain diseases.

The *rickety* thorax is caused chiefly by atmospheric pressure. The balance between the air on the inside of the chest and the outside during some stage of respiration is not equal, the preponderance being in favour of the air outside, and this, acting on the softened ribs, causes them to be forced in at the junction of the cartilages with the bones, which is the weakest part. In consequence of this the sternum projects forwards, with a deep depression on either side caused by the sinking in of the softened ribs. The depression is less on the left side, on account of the ribs being supported by the heart. The condition is known as 'pigeon-breast.' The lower ribs, however, are not involved in this deformity, as they are prevented from falling in by the presence of the stomach, liver, and spleen. And when the liver and spleen are enlarged, as they sometimes are in rickets, the lower ribs may be pushed outwards: this causes a transverse constriction just above the costal arch. The anterior extremities of the ribs are usually enlarged in rickets, giving rise to what has been termed the 'rickety rosary.' The *phthisical chest* is often long and narrow, flattened from before backwards, and with great obliquity of the ribs and projection of the scapulae. In *pulmonary emphysema* the chest is enlarged in all its diameters, and presents on section an almost circular outline. It has received the name of the 'barrel-shaped chest.' In severe cases of *lateral curvature of the spine*, the thorax

becomes much distorted. In consequence of the rotation of the bodies of the vertebræ, which takes place in this disease, the ribs opposite the convexity of the dorsal curve become extremely convex behind, being thrown out and bulging, and at the same time flattened in front, so that the two ends of the same rib are almost parallel. Coincident with this the ribs on the opposite side, on the concavity of the curve, are sunk and depressed behind, and bulging and convex in front. In addition to this the ribs become occasionally welded together by bony material.

The ribs are frequently the seat of necrosis leading to abscesses and sinuses, which may burrow to a considerable extent over the wall of the chest. The only special anatomical point in connection with these is that care must be taken in dealing with them, that the intercostal space is not punctured and the pleural cavity opened or the intercostal vessels wounded.

In cases of empyema the chest requires opening to evacuate the pus. There is considerable difference of opinion as to the best position to do this. Probably the best place in most cases will be found to be between the fifth and sixth ribs, in or a little in front of the mid-axillary line. This is the last part of the cavity to be closed by the expansion of the lung; it is not thickly covered by soft parts; the space between the two ribs is sufficiently great to allow of the introduction of a fair-sized drainage tube, and the opening is in a dependent position, when the patient is confined to bed, as he usually inclines towards the affected side, so as to allow the sound lung the freest possible play, and so permits of efficient drainage.

## OF THE EXTREMITIES

The extremities, or limbs, are those long, jointed appendages of the body which are connected to the trunk by one end, and free in the rest of their extent. They are *four* in number: an *upper* or *thoracic pair*, connected with the thorax through the intervention of the shoulder, and subservient mainly to prehension; and a *lower pair*, connected with the pelvis, intended for support and locomotion. Both pairs of limbs are constructed after one common type, so that they present numerous analogies; while, at the same time, certain differences are observed in each, dependent on the peculiar offices they have to perform.

The bones by which the upper and lower limbs are attached to the trunk are named respectively the *shoulder* and *pelvic girdles*, and they are constructed on the same general type, though presenting certain modifications relating to the different uses to which the upper and lower limbs are respectively applied. The *shoulder girdle* is formed by the scapula and clavicle, and is imperfect in front and behind. In front, however, the girdle is completed by the upper end of the sternum, with which the inner extremities of the clavicle articulate. Behind, the girdle is widely imperfect, and the scapula is connected to the trunk by muscles only. The *pelvic girdle* is formed by the innominate bones, and is completed in front, through the symphysis pubis, at which the two innominate bones articulate with each other. It is imperfect behind, but the intervening gap is filled in by the upper part of the sacrum. The pelvic girdle therefore presents, with the sacrum, a complete ring, comparatively fixed, and presenting an arched form which confers upon it a solidity manifestly intended for the support of the trunk, and in marked contrast to the lightness and mobility of the shoulder girdle.

With regard to the morphology of these girdles, the blade of the scapula is generally believed to correspond to the ilium: but with regard to the clavicles there is some difference of opinion; formerly it was believed that they corresponded to the ossa pubis meeting at the symphysis, but it is now generally taught that the clavicle has no homologue in the pelvic girdle, and that the os pubis and ischium are represented by the small coracoid process in man and most mammals.

## OF THE UPPER EXTREMITY

The bones of the upper extremity consist of those of the shoulder girdle, of the arm, the forearm, and the hand. The shoulder girdle consists of two bones, the clavicle and the scapula.



## THE CLAVICLE

The **Clavicle** (*clavis, a key*), or collar-bone, forms the anterior portion of the shoulder girdle. It is a long bone, curved somewhat like the italic letter *f*, and placed nearly horizontally at the upper and anterior part of the thorax, immediately above the first rib. It articulates by its inner extremity with the upper border of the sternum, and by its outer extremity with the acromion process of the scapula; serving to sustain the upper extremity in the various positions which it assumes, whilst, at the same time, it allows of great latitude of motion in the arm.\* It presents a double curvature, when looked at in front; the convexity being forwards at the sternal end, and the concavity at the scapular end. Its outer third is flattened from above downwards, and extends, in the natural position of the bone, from a point opposite the coracoid process to the acromion. Its inner two-thirds are of a cylindrical form, and extend from the sternum to a point opposite the coracoid process of the scapula.

**External or Flattened Portion.**—The *outer third* is flattened from above downwards, so as to present two surfaces, an upper and a lower; and two borders, an anterior and a posterior. The *upper surface* is flattened, rough, marked by impressions for the attachment of the Deltoid in front, and the Trapezius behind; between these two impressions, externally, a small portion of the bone is subcutaneous. The *under surface* is flattened. At its posterior border, a little external to the point where the prismatic joins with the flattened portion, is a rough eminence, the *conoid tubercle*; this, in the natural position of the bone, surmounts the coracoid process of the scapula, and gives attachment to the conoid ligament. From this tubercle, an oblique line, occasionally a depression, passes forwards and outwards to near the outer end of the anterior border; it is called the *oblique line*, and affords attachment to the trapezoid ligament. The *anterior border* is concave, thin, and rough; and gives attachment to the Deltoid; it occasionally presents, at its inner end, at the commencement of the deltoid impression, a tubercle, the *deltoid tubercle*, which is sometimes to be felt in the living subject. The *posterior border* is convex, rough, broader than the anterior, and gives attachment to the Trapezius.

**Internal or Cylindrical Portion.**—The cylindrical portion forms the *inner two-thirds* of the bone. It is curved so as to be convex in front, concave behind, and is marked by three borders, separating three surfaces. The *anterior border* is continuous with the anterior margin of the flat portion. At its commencement it is smooth, and corresponds to the interval between the attachment of the Pectoralis major and Deltoid muscles; at the inner half of the clavicle it forms the lower boundary of an elliptical space for the attachment of the clavicular portion of the Pectoralis major, and approaches the posterior border of the bone. The *superior border* is continuous with the posterior margin of the flat portion, and separates the anterior from the posterior surface. At its commencement it is smooth and rounded, becomes rough towards the inner third for the attachment of the Sterno-mastoid muscle, and terminates at the upper angle of the sternal extremity. The *posterior or subclavian border* separates the posterior from the inferior surface, and extends from the conoid tubercle to the rhomboid impression. It forms the posterior boundary of the groove for the Subclavius muscle, and gives attachment to a layer of cervical fascia, covering the Omohyoid muscle. The *anterior surface* is included between the superior and anterior borders. It is directed forwards and a little upwards at the sternal end, outwards and still more upwards at the acromial extremity, where it becomes

\* The clavicle acts especially as a fulcrum to enable the muscles to give lateral motion to the arm. It is accordingly absent in those animals whose fore limbs are used only for progression, but is present for the most part in those animals whose anterior extremities are clawed and used for prehension, though in some of them—as, for instance, in a large number of the carnivora—it is merely a rudimentary bone suspended among the muscles, and not articulating either with the scapula or sternum.



continuous with the upper surface of the flat portion. Externally, it is smooth, convex, nearly subcutaneous, being covered only by the *Platysma*; but, corresponding to the inner half of the bone, it is divided by a more or less prominent line into two parts: a lower portion, elliptical in form, rough, and slightly convex, for the attachment of the *Pectoralis major*; and an upper part, which is rough, for the attachment of the *Sterno-cleido-mastoid*. Between the two muscular impressions is a small, subcutaneous interval. The *posterior* or *cervical surface* is smooth, flat, and looks backwards towards the root of the neck. It is limited, above, by the superior border; below, by the subclavian border; internally, by the margin of the sternal extremity; externally, it is continuous with the posterior border of the flat portion. It is concave from within outwards, and is in relation, by its lower part, with the suprascapular vessels. This surface, at about the junction of the inner and outer curves, is also in close relation with the brachial plexus and subclavian vessels. It gives attachment, near the sternal extremity, to part of the *Sterno-hyoid* muscle; and presents, at or near the middle, a

FIG. 203.—Left clavicle. Superior surface.

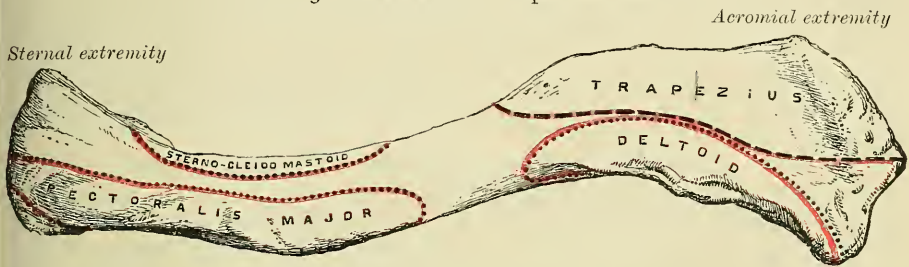
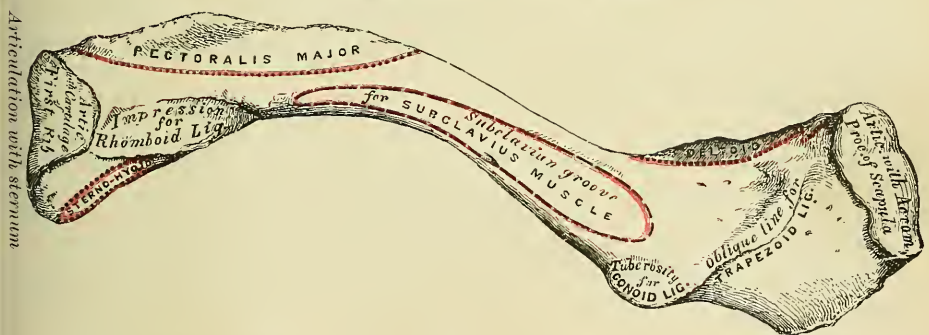


FIG. 204.—Left clavicle. Inferior surface.



foramen, directed obliquely outwards, which transmits the chief nutrient artery of the bone. Sometimes there are two foramina on the posterior surface, or one on the posterior, the other on the inferior surface. The *inferior* or *subclavian surface* is bounded, in front, by the anterior border; behind, by the subclavian border. It is narrow internally, but gradually increases in width externally, and is continuous with the under surface of the flat portion. Commencing at the sternal extremity may be seen a small facet for articulation with the cartilage of the first rib. This is continuous with the articular surface at the sternal end of the bone. External to this is a broad, rough impression, the *rhomboid*, rather more than an inch in length, for the attachment of the costo-clavicular (rhomboid) ligament. The remaining part of this surface is occupied by a longitudinal groove, the *subclavian groove*, broad and smooth externally, narrow and more uneven internally; it gives attachment to the *Subclavius* muscle, and, by its anterior margin, to the costo-coracoid membrane. Not unfrequently this groove is subdivided into two parts by a longitudinal line, which gives attachment to the intermuscular septum of the *Subclavius* muscle.

The **internal** or **sternal extremity** of the clavicle is triangular in form, directed inwards, and a little downwards and forwards; and presents an articular facet, concave from before backwards, convex from above downwards, which articulates with the sternum through the intervention of an interarticular fibro-cartilage; the circumference of the articular surface is rough, for the attachment of numerous ligaments. The posterior border of this surface is prolonged backwards so as to increase the size of the articular facet; the upper border gives attachment to the interarticular fibro-cartilage, and the lower border is continuous with the costal facet on the inner end of the inferior or subclavian surface, which articulates with the cartilage of the first rib.

The **outer** or **acromial extremity**, directed outwards and forwards, presents a small, flattened, oval facet, which looks obliquely downwards, for articulation with the acromion process of the scapula. The circumference of the articular facet is rough, especially above, for the attachment of the acromio-clavicular ligaments.

*Peculiarities of the Bone in the Sexes and in Individuals.*—In the female, the clavicle is generally shorter, thinner, less curved, and smoother than in the male. In those persons who perform considerable manual labour, which brings into constant action the muscles connected with this bone, it becomes thicker and more curved, its ridges for muscular attachment become prominently marked, and its sternal end of a prismatic form. The right clavicle is generally longer, thicker, and rougher than the left.

**Structure.**—The shaft, as well as the extremities, consists of cancellous tissue, invested in a compact layer much thicker in the middle than at either end. The clavicle is highly elastic, by reason of its curves. From the experiments of Mr. Ward, it has been shown that it possesses sufficient longitudinal elastic force to project its own weight nearly two feet on a level surface, when a smart blow is struck on it; and sufficient transverse elastic force, opposite the centre of its anterior convexity, to throw its own weight about a foot. This extent of elastic power must serve to moderate very considerably the effect of concussions received upon the point of the shoulder.

**Development.**—By *two* centres: one for the shaft, and one for the sternal extremity. The centre for the shaft appears very early, before any other bone; according to Bécлар, as early as the thirtieth day. The centre for the sternal end makes its appearance about the eighteenth or twentieth year, and unites with the rest of the bone about the twenty-fifth year.

**Articulations.**—With the sternum, scapula, and cartilage of the first rib.

**Attachment of Muscles.**—To six: the Sterno-cleido-mastoid, Trapezius, Pectoralis major, Deltoid, Subclavius, and Sterno-hyoid.

*Surface Form.*—The clavicle can be felt throughout its entire length, even in persons who are very fat. Commencing at the inner end, the enlarged sternal extremity, where the bone projects above the upper margin of the sternum, can be felt, forming with the sternum and the rounded tendon of the Sterno-mastoid a V-shaped notch, the *presternal notch*. Passing outwards, the shaft of the bone can be felt immediately under the skin, with its convexity forwards in the inner two-thirds, the surface partially obscured above and below by the attachments of the Sterno-mastoid and Pectoralis major muscles. In the outer third it forms a gentle curve backwards, and terminates at the outer end in a somewhat enlarged extremity which articulates with the acromion process of the scapula. The direction of the clavicle is almost, if not quite, horizontal when the arm is lying quietly by the side, though in well-developed subjects it may incline a little upwards at its outer end. Its direction is, however, very changeable with the varying movements of the shoulder-joint.

*Surgical Anatomy.*—The clavicle is the most frequently broken of any single bone in the body. This is due to the fact that it is much exposed to violence, and is the only bony connection between the upper limb and the trunk. The bone, moreover, is slender, and is very superficial. The bone may be broken by direct or indirect violence, or by muscular action. The most common cause is, however, from indirect violence, and the bone then gives way at the junction of the outer with the inner two-thirds of the bone; that is to say, at the junction of the two curves, for this is the weakest part of the bone. The fracture is generally oblique, and the displacement of the fragments is inwards, away



from the surface of the body, hence compound fracture of the clavicle is of rare occurrence. Beneath the bone the main vessels of the upper limb and the great nerve-cords of the brachial plexus lie on the first rib and are liable to be wounded in fracture; especially in fracture from direct violence, when the force of the blow drives the broken ends inwards. Fortunately the subclavius muscle is interposed between these structures and the clavicle, and this often protects them from injury.

The clavicle is not uncommonly the seat of sarcomatous tumours, rendering the operation of excision of the entire bone necessary. This is an operation of considerable difficulty and danger. It is best performed by exposing the bone freely, disarticulating at the acromial end, and turning it inwards. The removal of the outer part is comparatively easy, but resection of the inner part is fraught with difficulty, the main danger being the risk of wounding the great veins which are in relation with its under surface.

### THE SCAPULA

The **Scapula** (*σκαπάνη*, a *spade*) forms the back part of the shoulder girdle. It is a large, flat bone, triangular in shape, situated at the posterior aspect and side of the thorax, between the second and seventh or sometimes the eighth ribs, its posterior border or base being about an inch from, and nearly, but not quite parallel with, the spinous processes of the vertebræ, so that it is rather closer to them above than below. It presents for examination two surfaces, three borders, and three angles.

The **anterior surface**, or **venter** (fig. 205), presents a broad concavity, the *subscapular fossa*. It is marked, in the posterior two-thirds, by several oblique ridges, which pass from behind obliquely outwards and upwards; the anterior third is smooth. The oblique ridges give attachment to the tendinous intersections, and the surfaces between them to the fleshy fibres, of the Subscapularis muscle. The anterior third of the fossa, which is smooth, is covered by, but does not afford attachment to, the fibres of this muscle. The venter is separated from the posterior border by a smooth, triangular margin at the superior and inferior angles, and in the interval between these by a narrow edge which is often deficient. This marginal surface affords attachment throughout its entire extent to the Serratus magnus muscle. The subscapular fossa presents a transverse depression at its upper part, where the bone appears to be bent on itself, forming a considerable angle, called the *subscapular angle*, thus giving greater strength to the body of the bone from its arched form; while the summit of the arch serves to support the spine and acromion process. It is in this situation that the fossa is deepest; so that the thickest part of the Subscapularis muscle lies in a line perpendicular to the plane of the glenoid cavity, and must consequently operate most effectively on the head of the humerus, which is contained in that cavity.

The **posterior surface**, or **dorsum** (fig. 206), is arched from above downwards, alternately concave and convex from side to side. It is subdivided unequally into two parts by the *spine*; the portion above the spine is called the *supraspinous fossa*, and that below it the *infraspinous fossa*.

The *supraspinous fossa*, the smaller of the two, is concave, smooth, and broader at the vertebral than at the humeral extremity. It affords attachment by its inner two-thirds to the Supraspinatus muscle.

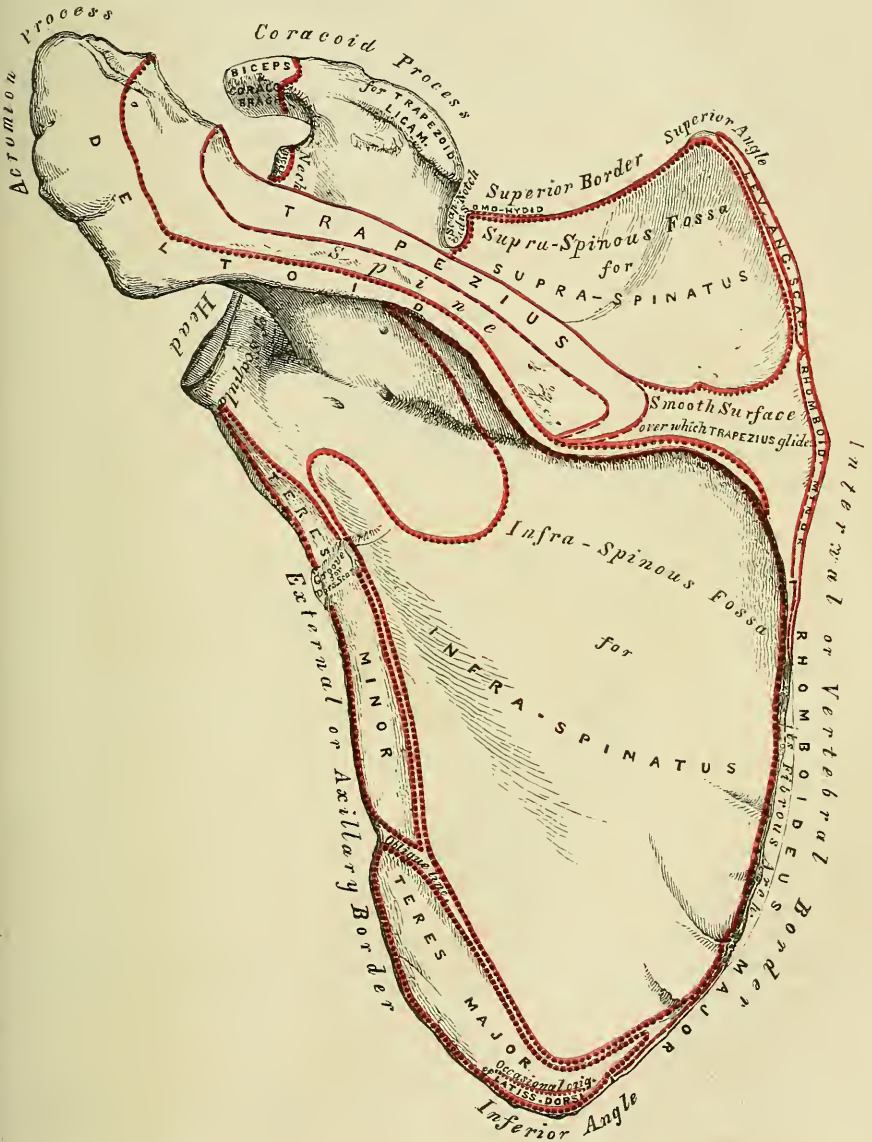
The *infraspinous fossa* is much larger than the preceding; towards its vertebral margin a shallow concavity is seen at its upper part; its centre presents a prominent convexity, whilst towards the axillary border is a deep groove which runs from the upper towards the lower part. The inner two-thirds of this surface affords attachment to the Infraspinatus muscle; the outer third is only covered by it, without giving origin to its fibres. This surface is separated from the axillary border by an elevated ridge, which runs from the lower part of the glenoid cavity, downwards and backwards to the posterior border, about an inch above the inferior angle. The ridge serves for the attachment of a strong aponeurosis, which separates the Infraspinatus from the two Teres muscles. The surface of bone between this line and the axillary border is narrow in the





to the posterior border, its base (which is directed outwards) to the neck of the scapula. It presents two surfaces and three borders. Its *superior surface* is concave, assists in forming the supraspinous fossa, and affords attachment to part of the Supraspinatus muscle. Its *inferior surface* forms part of the infraspinous fossa, gives origin to part of the Infraspinatus muscle, and presents near its centre the orifice of a nutrient canal. Of the three borders, the *anterior* is

FIG. 206.—Left scapula. Posterior surface, or dorsum.



attached to the dorsum of the bone; the *posterior*, or *crest of the spine*, is broad, and presents two lips and an intervening rough interval. To the superior lip is attached the Trapezius, to the extent shown in the figure. A rough tubercle is generally seen occupying that portion of the spine which receives the insertion of the middle and inferior fibres of this muscle. To the inferior lip, throughout its whole length, is attached the Deltoid. The interval between the lips is also partly covered by the fibres of these muscles. The *external border*, or *base*, the

shortest of the three, is slightly concave, its edge thick and round, continuous above with the under surface of the acromion process, below with the neck of the scapula. The narrow portion of bone external to this border, and separating it from the glenoid cavity, is called the *great scapular notch*, and serves to connect the supra- and infra-spinous fossæ.

The **Acromion Process**, so called from forming the summit of the shoulder (*ἄκρον*, a *summit*; *ᾠμος*, the *shoulder*), is a large and somewhat triangular process, flattened from behind forwards, directed at first a little outwards, and then curving forwards and upwards, so as to overhang the glenoid cavity. Its *upper surface*, directed upwards, backwards, and outwards, is convex, rough, and gives attachment to some fibres of the Deltoid, and in the rest of its extent it is subcutaneous. Its *under surface* is smooth and concave. Its *outer border* is thick and irregular, and presents three or four tubercles for the tendinous origins of the Deltoid muscle. Its *inner margin*, shorter than the outer, is concave, gives attachment to a portion of the Trapezius muscle, and presents about its centre a small, oval surface for articulation with the acromial end of the clavicle. Its *apex*, which corresponds to the point of meeting of these two borders in front, is thin, and has attached to it the coraco-acromial ligament.

Of the three borders or costæ of the scapula, the *superior* is the shortest and thinnest; it is concave, terminating at its inner extremity at the superior angle, at its outer extremity at the coracoid process. At its outer part is a deep, semicircular notch, the *suprascapular*, formed partly by the base of the coracoid process. This notch is converted into a foramen by the transverse ligament, and serves for the passage of the suprascapular nerve. The adjacent margin of the superior border affords attachment to the Omo-hyoid muscle. The *external*, or *axillary*, border is the thickest of the three. It commences above at the lower margin of the glenoid cavity, and inclines obliquely downwards and backwards to the inferior angle. Immediately below the glenoid cavity is a rough impression (the *infra-glenoid tubercle*), about an inch in length, which affords attachment to the long head of the Triceps muscle; to this succeeds a longitudinal groove, which extends as far as its lower third, and affords origin to part of the Subscapularis muscle. The inferior third of this border, which is thin and sharp, serves for the attachment of a few fibres of the Teres major behind and of the Subscapularis in front. The *internal*, or *vertebral*, border, also named the *base*, is the longest of the three, and extends from the superior to the inferior angle of the bone. It is arched, intermediate in thickness between the superior and the external borders, and the portion of it above the spine is bent considerably outwards, so as to form an obtuse angle with the lower part. The vertebral border presents an anterior lip, a posterior lip, and an intermediate space. The *anterior lip* affords attachment to the Serratus magnus; the *posterior lip*, to the Supraspinatus above the spine, the Infraspinatus below; the interval between the two lips, to the Levator anguli scapulæ above the triangular surface at the commencement of the spine, the Rhomboideus minor to the edge of that surface; the Rhomboideus major being attached by means of a fibrous arch, connected above to the lower part of the triangular surface at the base of the spine, and below to the lower part of the posterior border.

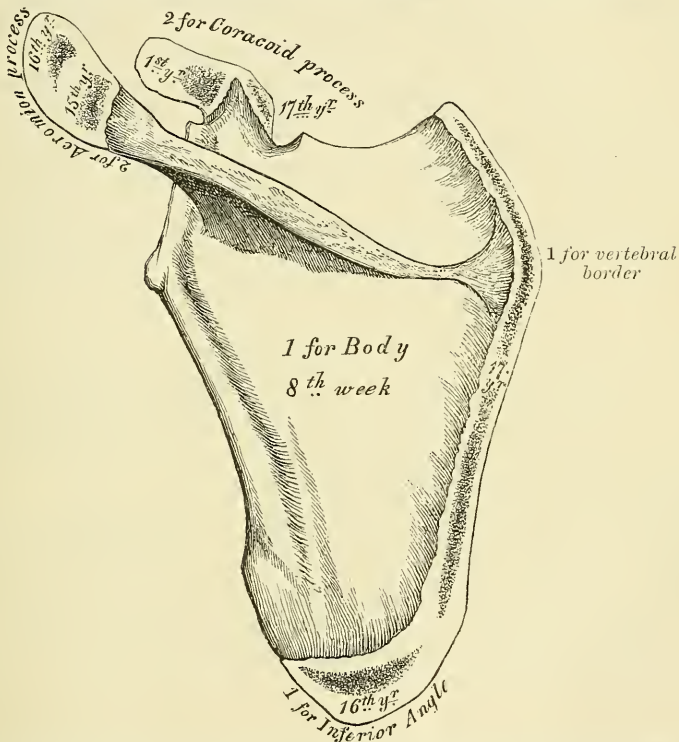
Of the three angles, the *superior*, formed by the junction of the superior and internal borders, is thin, smooth, rounded, somewhat inclined outwards, and gives attachment to a few fibres of the Levator anguli scapulæ muscle. The *inferior* angle, thick and rough, is formed by the union of the vertebral and axillary borders, its outer surface affording attachment to the Teres major and occasionally a few fibres of the Latissimus dorsi. The *anterior* angle is the thickest part of the bone, and forms what is called the *head* of the scapula. The head presents a shallow, pyriform, articular surface, the *glenoid cavity* (*γλήνη*, a *socket*), whose longest diameter is from above downwards, and its direction outwards and forwards. It is broader below than above; at its apex is a slight impression (the *supra-glenoid tubercle*), to which is attached the long tendon of



the Biceps muscle. It is covered with cartilage in the recent state; and its margins, slightly raised, give attachment to a fibro-cartilaginous structure, the *glenoid ligament*, by which its cavity is deepened. The *neck* of the scapula is the slightly depressed surface which surrounds the head; it is more distinct on the posterior than on the anterior surface, and below than above. In the latter situation it has, arising from it, a thick prominence, the coracoid process.

The **Coracoid Process**, so called from its fancied resemblance to a crow's beak (*κόραξ, a crow*), is a thick, curved process of bone, which arises by a broad base from the upper part of the neck of the scapula; it is directed at first upwards and inwards; then, becoming smaller, it changes its direction, and passes forwards and outwards. The ascending portion, flattened from before backwards, presents in front a smooth, concave surface, over which passes the Subscapularis muscle. The horizontal portion is flattened from above downwards; its upper

FIG. 207.—Plan of the development of the scapula. By seven centres.



The epiphyses (except one for the coracoid process) appear from fifteen to seventeen years, and unite between twenty-two and twenty-five years of age.

surface is convex and irregular, and gives attachment to the Pectoralis minor; its under surface is smooth; its inner border is rough, and gives attachment to the Pectoralis minor; its outer border is also rough for the coraco-acromial ligament, while the apex is embraced by the conjoined tendon of origin of the short head of the Biceps and of the Coraco-brachialis and gives attachment to the costo-coracoid ligament. At the inner side of the root of the coracoid process is a rough impression for the attachment of the conoid ligament; and running from it obliquely forwards and outwards, on the upper surface of the horizontal portion, an elevated ridge for the attachment of the trapezoid ligament.

**Structure.**—In the head, processes, and all the thickened parts of the bone, the scapula is composed of cancellous tissue, while in the rest of its extent it is

composed of a thin layer of dense, compact tissue. The centre and upper part of the dorsum, but especially the former, are usually so thin as to be semi-transparent; occasionally the bone is found wanting in this situation, and the adjacent muscles come into contact.

**Development** (fig. 207).—By *seven* centres; one for the body, two for the coracoid process, two for the acromion, one for the vertebral border, and one for the inferior angle.

Ossification of the body of the scapula commences about the second month of foetal life, by the formation of an irregular quadrilateral plate of bone, immediately behind the glenoid cavity. This plate extends itself so as to form the chief part of the bone, the spine growing up from its posterior surface about the third month. At birth, the chief part of the scapula is osseous, only the coracoid and acromion processes, the posterior border, and inferior angle being cartilaginous. About the first year after birth, ossification takes place in the middle of the coracoid process, which usually becomes joined with the rest of the bone at the time when the other centres make their appearance. Between the fifteenth and seventeenth years, ossification of the remaining centres takes place in quick succession, and in the following order: first, near the base of the acromion and in the root of the coracoid process, the latter appearing in the form of a broad scale; secondly, in the inferior angle and contiguous part of the posterior border; thirdly, near the extremity of the acromion; fourthly, in the posterior border. The acromion process, besides being formed of two separate nuclei, has its base formed by an extension into it of the centre of ossification which belongs to the spine, the extent of which varies in different cases. The two separate nuclei unite, and then join with the extension carried in from the spine. These various epiphyses become joined to the bone between the ages of twenty-two and twenty-five years. Sometimes failure of union between the acromion process and spine occurs, the junction being effected by fibrous tissue, or by an imperfect articulation; in some cases of supposed fracture of the acromion with ligamentous union, it is probable that the detached segment was never united to the rest of the bone. Very often, in addition to these, a minute epiphysis appears at the margin of the glenoid cavity.

**Articulations.**—With the humerus and clavicle.

**Attachment of Muscles.**—To seventeen: to the anterior surface, the Subscapularis; posterior surface, Supraspinatus, Infraspinatus; spine, Trapezius, Deltoid; superior border, Omo-hyoid; vertebral border, Serratus magnus, Levator anguli scapulae, Rhomboideus minor and major; axillary border, Triceps, Teres minor, Teres major; glenoid cavity, long head of the Biceps; coracoid process, short head of the Biceps, Coraco-brachialis, Pectoralis minor; and to the inferior angle occasionally a few fibres of the Latissimus dorsi.

**Surface Form.**—The only parts of the scapula which are truly subcutaneous are the spine and acromion process, but, in addition to these, the coracoid process, the internal or vertebral border and inferior angle, and, to a less extent, the axillary border, may be defined. The acromion process and spine of the scapula are easily felt throughout their entire length, forming, with the clavicle, the arch of the shoulder. The acromion can be ascertained to be connected to the clavicle at the acromio-clavicular joint by running the finger along it, its position being often indicated by an irregularity or bony outgrowth from the clavicle close to the joint. The acromion can be felt forming the point of the shoulder, and from this can be traced backwards to join the spine of the scapula. The place of junction is usually denoted by a prominence, which is sometimes called the angle. From here the spine can be felt as a prominent ridge of bone, marked on the surface as an oblique depression, which becomes less and less distinct and terminates a little external to the spinous processes of the vertebrae. Its termination is usually indicated by a slight dimple in the skin, on a level with the interval between the third and fourth dorsal spines. Below this point the vertebral border of the scapula may be traced, running downwards and outwards, and thus diverging from the vertebral spines, to the inferior angle of the bone, which can be recognised, although covered by the Latissimus dorsi muscle. From this angle the axillary border can usually be traced through its thick muscular covering, forming, with the muscles, the posterior fold of the axilla. The coracoid process may be felt about an inch below the junction of the middle and outer third of the clavicle. Its

position is indicated on the surface of the body by a slight depression, which corresponds to the interval between the Pectoralis major and Deltoid muscles. When the arms are hanging by the side, the upper angle of the scapula corresponds to the upper border of the second rib or the interval between the first and second dorsal spines, the inferior angle to the upper border of the eighth rib or the interval between the seventh and eighth dorsal spines.

*Surgical Anatomy.*—Fractures of the body of the scapula are rare, owing to the mobility of the bone, the thick layer of muscles by which it is encased on both surfaces, and the elasticity of the ribs on which it rests. Fracture of the neck of the bone is also uncommon. The most frequent course of the fracture is from the suprascapular notch to the infraglenoid tubercle, and it derives its principal interest from its simulation to a subglenoid dislocation of the humerus. The diagnosis can be made by noting the alteration in the position of the coracoid process. A fracture of the neck external to and not including the coracoid process is said to occur, but it is exceedingly doubtful whether such an accident ever takes place. The acromion process is more frequently broken than any other part of the bone, and there is sometimes, in young subjects, a separation of the epiphysis. It is believed that many of the cases of supposed fracture of the acromion, with fibrous union, which have been found on post-mortem examination are really cases of imperfectly united epiphysis. Sir Astley Cooper believed that most fractures of this bone united by fibrous tissue, and the cause of this mode of union was the difficulty there was in keeping the fractured ends in constant apposition. The coracoid process is occasionally broken off, either from direct violence or, perhaps rarely, from muscular action.

Tumours of various kinds grow from the scapula. Of the innocent form of tumours probably the osteomata are the most common. When this grows from the venter of the scapula, as it sometimes does, it is of the compact variety, such as usually grows from membrane-formed bones, as the bones of the skull. This would appear to afford evidence that this portion of the bone is formed from membrane, and not like the rest of the bone from cartilage. Sarcomatous tumours sometimes grow from the scapula and may necessitate removal of the bone, with or without amputation of the upper limb. The bone may be excised by a T incision, and the flaps being reflected, the removal is commenced from the posterior or vertebral border, so that the subscapular vessels which lie along the axillary border are among the last structures divided, and can be at once secured.

## THE HUMERUS

The **Humerus** is the longest and largest bone of the upper extremity; it presents for examination a shaft and two extremities.

The **Upper Extremity** is the largest part of the bone; it presents a rounded *head*, joined to the shaft by a constricted portion, called the *neck*, and two other eminences, the *greater* and *lesser tuberosities* (fig. 208).

The **head**, nearly hemispherical in form,\* is directed upwards, inwards, and a little backwards, and articulates with the glenoid cavity of the scapula; its surface is smooth, and coated with cartilage in the recent state. The circumference of its articular surface is slightly constricted, and is termed the *anatomical neck*, in contradistinction to the constriction which exists below the tuberosities. The latter is called the *surgical neck*, from its being most frequently the seat of fracture. It should be remembered, however, that fracture of the *anatomical neck* does sometimes, though rarely, occur.

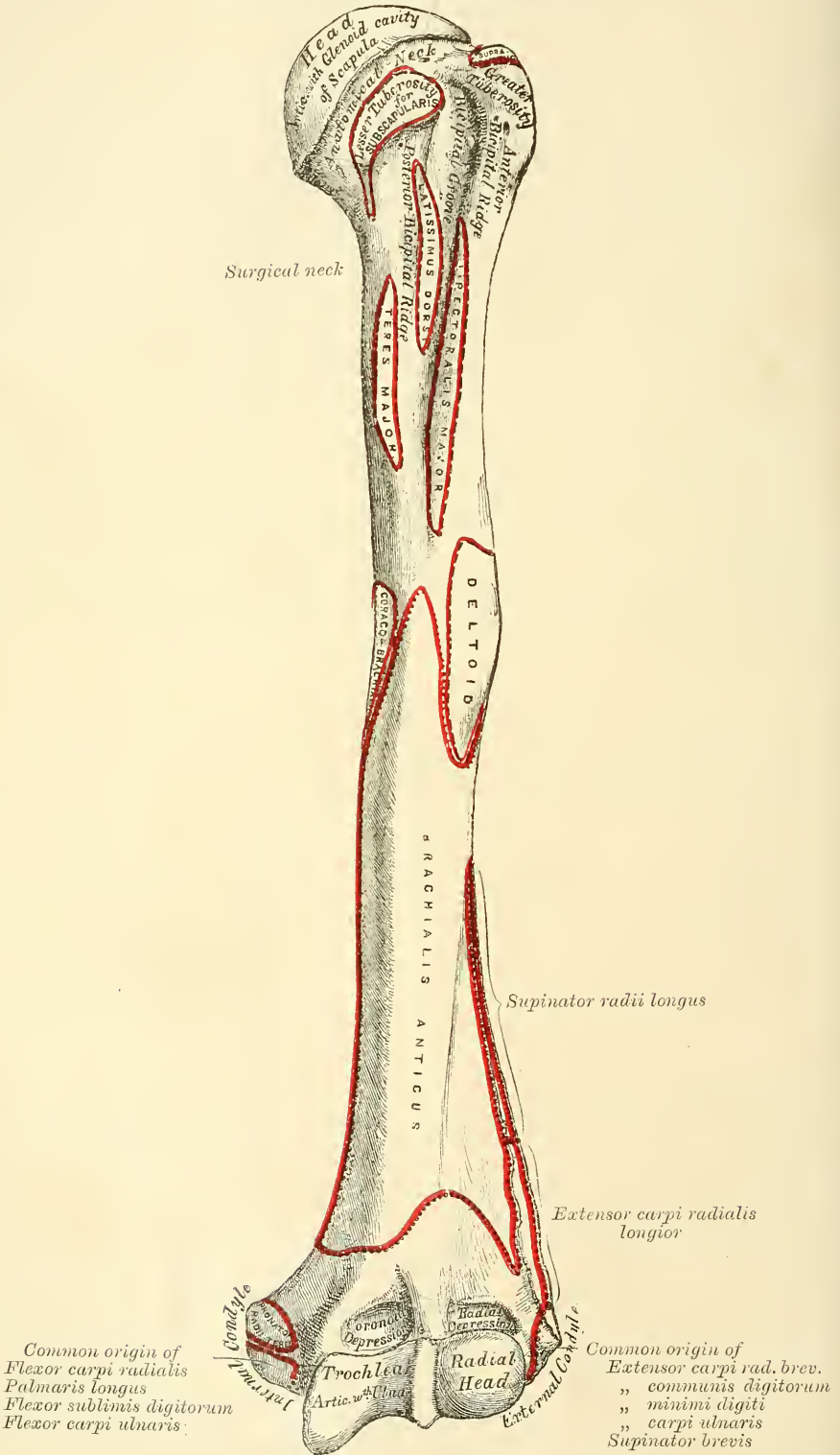
The **anatomical neck** is obliquely directed, forming an obtuse angle with the shaft. It is more distinctly marked in the lower half of its circumference than in the upper half, where it presents a narrow groove, separating the head from the tuberosities. Its circumference affords attachment to the capsular ligament, and is perforated by numerous vascular foramina.

The **greater tuberosity** is situated on the outer side of the head and lesser tuberosity. Its upper surface is rounded and marked by three flat facets, separated by two slight ridges: the superior facet gives attachment to the tendon of the Supraspinatus; the middle one to the Infraspinatus; the inferior facet, and the shaft of the bone below it, to the Teres minor. The outer surface of

\* Though the head is nearly hemispherical in form, its margin, as Sir G. Humphry has shown, is by no means a true circle. Its greatest measurement is, from the top of the bicapital groove in a direction downwards, inwards, and backwards. Hence it follows that the greatest elevation of the arm can be obtained by rolling the articular surface in this direction—that is to say, obliquely upwards, outwards, and forwards.



FIG. 208.—Left humerus. Anterior view.



Common origin of  
Flexor carpi radialis  
Palmaris longus  
Flexor sublimis digitorum  
Flexor carpi ulnaris:

Common origin of  
Extensor carpi rad. brev.  
" commonis digitorum  
" minimi digiti  
" carpi ulnaris  
Supinator brevis

the great tuberosity is convex, rough, and continuous with the outer side of the shaft.

The **lesser tuberosity** is more prominent, although smaller, than the greater : it is situated in front of the head, and is directed inwards and forwards. Its summit presents a prominent facet for the insertion of the tendon of the Subscapularis muscle. The tuberosities are separated from one another by a deep groove, the *bicipital groove*, so called from its lodging the long tendon of the Biceps muscle, with which runs a branch of the anterior circumflex artery. It commences above between the two tuberosities, passes obliquely downwards and a little inwards, and terminates at the junction of the upper with the middle third of the bone. It is deep and narrow at the commencement, and becomes shallow and a little broader as it descends. Its borders are called, respectively, the anterior and posterior *bicipital ridges*, and form the upper part of the anterior and internal borders of the shaft of the bone. In the recent state it is covered with a thin layer of cartilage, lined by a prolongation of the synovial membrane of the shoulder-joint, and receives the tendon of insertion of the Latissimus dorsi muscle.

The **Shaft** of the humerus is almost cylindrical in the upper half of its extent, prismatic and flattened below, and presents three borders and three surfaces for examination.

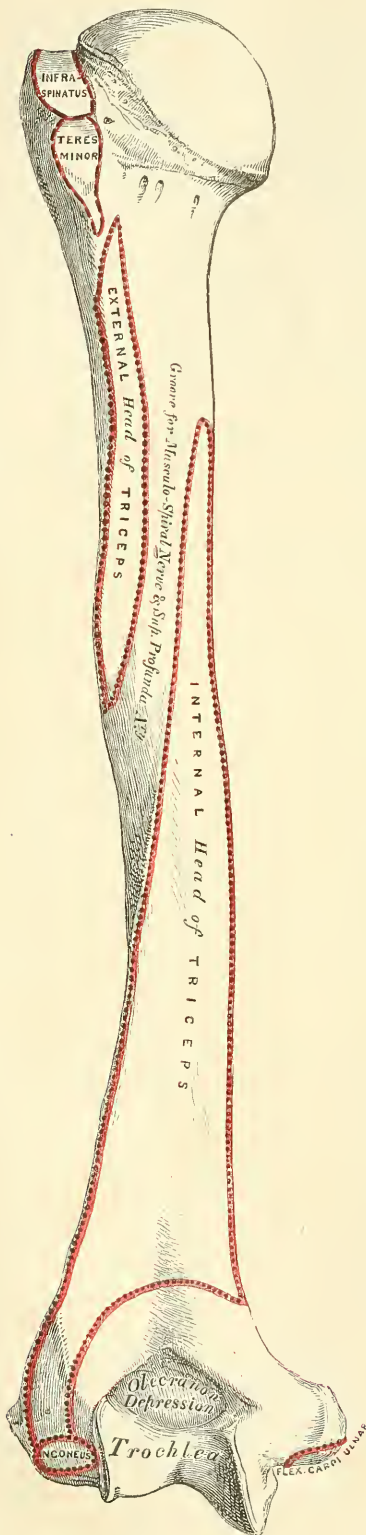The **anterior border** runs from the front of the great tuberosity above to the coronoid depression below, separating the internal from the external surface. Its upper part is very prominent and rough, and forms the outer lip of the bicipital groove. It is sometimes called the *anterior bicipital ridge*, and serves for the attachment of the tendon of the Pectoralis major. About its centre it forms the anterior boundary of the rough deltoid impression; below, it is smooth and rounded, affording attachment to the Brachialis anticus.

The **external border** runs from the back part of the greater tuberosity to the external condyle, and separates the external from the posterior surface. It is rounded and indistinctly marked in its upper half, serving for the attachment of the lower part of the insertion of the Teres minor, and below this of the external head of the Triceps muscle; its centre is traversed by a broad but shallow, oblique depression, the *musculo-spiral groove*; its lower part is marked by a prominent, rough margin, a little curved from behind forwards, the *external condyloid ridge*, which presents an anterior lip for the attachment of the Supinator longus above, and Extensor carpi radialis longior below, a posterior lip for the Triceps, and an interstice for the attachment of the external intermuscular septum.

The **internal border** extends from the lesser tuberosity to the internal condyle. Its upper third is marked by a prominent ridge, forming the posterior lip of the bicipital groove, and gives attachment to the tendon of the Teres major. About its centre is a rough ridge for the attachment of the Coraco-brachialis, and just below this is seen the entrance of the nutrient canal, directed downwards. Sometimes there is a second canal situated at the commencement of the musculo-spiral groove for a nutrient artery derived from the superior profunda branch of the brachial artery. The inferior third of this border is raised into a slight ridge, the *internal condyloid ridge*, which becomes very prominent below; it presents an anterior lip for the attachment of the Brachialis anticus, a posterior lip for the internal head of the Triceps, and an intermediate space for the internal intermuscular septum.

The **external surface** is directed outwards above, where it is smooth, rounded, and covered by the Deltoid muscle; forwards and outwards below, where it is slightly concave from above downwards, and gives origin to part of the Brachialis anticus muscle. About the middle of this surface is seen a rough, triangular impression for the insertion of the Deltoid muscle; and below it the musculo-spiral groove, directed obliquely from behind, forwards, and downwards, and transmitting the musculo-spiral nerve and superior profunda artery.

FIG. 209.—Left humerus. Posterior surface.



The **internal surface**, less extensive than the external, is directed inwards above, forwards and inwards below; at its upper part it is narrow, and forms the floor of the bicipital groove: to it is attached the *Latissimus dorsi*. The middle part of this surface is slightly rough for the attachment of some of the fibres of the tendon of insertion of the *Coraco-brachialis*; its lower part is smooth, concave, and gives attachment to the *Brachialis anticus* muscle.\*

The **posterior surface** (fig. 209) appears somewhat twisted, so that its upper part is directed a little inwards, its lower part backwards and a little outwards. Nearly the whole of this surface is covered by the external and internal heads of the *Triceps*, the former of which is attached to its upper and outer part, the latter to its inner and back part, the two being separated by the musculo-spiral groove.

The **Lower Extremity** is flattened from before backwards, and curved slightly forwards; it terminates below in a broad, articular surface, which is divided into two parts by a slight ridge. Projecting on either side are the external and internal condyles (*epicondyles*). The articular surface extends a little lower than the condyles, and is curved slightly forwards, so as to occupy the more ante-

\* A small, hook-shaped process of bone, varying from  $\frac{1}{10}$  to  $\frac{3}{8}$  of an inch in length, is not unfrequently found projecting from the inner surface of the shaft of the humerus two inches above the internal condyle. It is curved downwards, forwards, and inwards, and its pointed extremity is connected to the internal border, just above the inner condyle, by a ligament or fibrous band, completing an arch, through which the median nerve and brachial artery pass, when these structures deviate from their usual course. Sometimes the nerve alone is transmitted through it, or the nerve may be accompanied by the ulnar artery, in cases of high division of the brachial. A well-marked groove is usually found behind the process, in which the nerve and artery are lodged. This space is analogous to the supra condyloid foramen in many animals, and probably serves in them to protect the nerve and artery from compression during the contraction of the muscles in this region. A detailed account of this process is given by Dr. Struthers, in his *Anatomical and Physiological Observations*, p. 202. An accessory portion of the *Coraco-brachialis* muscle is frequently connected with this process, according to Mr. J. Wood, *Journal of Anat. and Phys.* No. 1, Nov. 1866, p. 47.



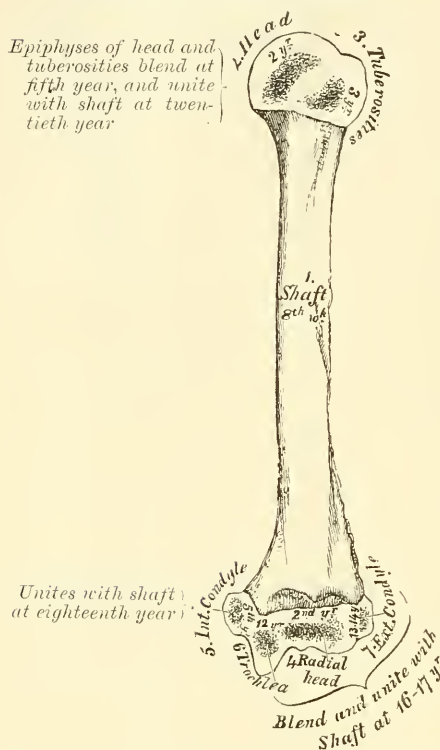
rior part of the bone; its greatest breadth is in the transverse diameter, and it is obliquely directed, so that its inner extremity occupies a lower level than the outer. The outer portion of the articular surface presents a smooth, rounded eminence, which has received the name of the *capitellum*, or *radial head* of the humerus; it articulates with the cup-shaped depression on the head of the radius, and is limited to the front and lower part of the bone, not extending as far back as the other portion of the articular surface. On the inner side of this eminence is a shallow groove, in which is received the inner margin of the head of the radius. Above the front part of the capitellum is seen a slight depression, which receives the anterior border of the head of the radius, when the fore-arm is flexed. The inner portion of the articular surface, the *trochlear*, presents a deep depression between two well-marked borders. This surface is convex from before backwards, concave from side to side, and occupies the anterior, lower, and posterior parts of the bone. The external border, less prominent than the internal, corresponds to the interval between the radius and the ulna. The internal border is thicker, more prominent, and consequently of greater length, than the external. The grooved portion of the articular surface fits accurately within the greater sigmoid cavity of the ulna; it is broader and deeper on the posterior than on the anterior aspect of the bone, and is inclined obliquely from behind forwards, and from without inwards. Above the front part of the trochlear surface is seen a smaller depression, the *coronoid fossa*, which receives the coronoid process of the ulna during flexion of the fore-arm. Above the back part of the trochlear surface is a deep, triangular depression, the *olecranon fossa*, in which is received the summit of the olecranon process in extension of the forearm. These fossæ are separated from one another by a thin, transparent lamina of bone, which is sometimes perforated, forming the *supratrochlear foramen*; their upper margins afford attachment to the anterior and posterior ligaments of the elbow-joint, and they are lined, in the recent state, by the synovial membrane of this articulation. The articular surfaces, in the recent state, are covered with a thin layer of cartilage. The external condyle (*radial epicondyle*) is a small, tubercular eminence, less prominent than the internal, curved a little forwards, and giving attachment to the external lateral ligament of the elbow-joint, and to a tendon common to the origin of some of the extensor and supinator muscles. The internal condyle (*ulnar epicondyle*), larger and more prominent than the external, is directed a little backwards: it gives attachment to the internal lateral ligament, to the Pronator radii teres, and to a tendon common to the origin of some of the flexor muscles of the forearm. The ulnar nerve runs in a groove at the back of the internal condyle, or between it and the olecranon process. These eminences are directly continuous above with the external and internal borders—i.e. the external and internal condyloid ridges. The great prominence of the inner one renders it more liable to fracture.

**Structure.**—The extremities consist of cancellous tissue, covered with a thin, compact layer; the shaft is composed of a cylinder of compact tissue, thicker at the centre than at the extremities, and hollowed out by a large medullary canal, which extends along its whole length.

**Development.**—By *seven*, or occasionally *eight* centres (fig. 210): one for the shaft, one for the head, one for the tuberosities, one for the radial head, one for the trochlear portion of the articular surface, and one for each condyle. The nucleus for the shaft appears near the centre of the bone in the eighth week, and soon extends towards the extremities. At birth the humerus is ossified nearly in its whole length, the extremities remaining cartilaginous. During the first year, sometimes earlier, ossification commences in the head of the bone, and during the third year the centre for the tuberosities makes its appearance, usually by a single ossific point, but sometimes, according to Bécлар, by one for each tuberosity, that for the lesser being small, and not appearing until the fifth year. By the sixth year the centres for the head and tuberosities have enlarged and become joined, so as to form a single large epiphysis.

The lower end of the humerus is developed in the following manner:—At the end of the second year ossification commences in the radial portion of the articular surface, and from this point extends inwards, so as to form the chief part of the articular end of the bone, the centre for the inner part of the articular

FIG. 210.—Plan of the development of the humerus. By seven centres.



surface not appearing until about the age of twelve. Ossification commences in the internal condyle about the fifth year, and in the external one not until about the thirteenth or fourteenth year. About sixteen or seventeen years, the outer condyle and both portions of the articulating surface (having already joined) unite with the shaft; at eighteen years the inner condyle becomes joined, whilst the upper epiphysis, although the first formed, is not united until about the twentieth year.

**Articulations.**—With the glenoid cavity of the scapula, and with the ulna and radius.

**Attachment of Muscles.**—To twenty-four: to the greater tuberosity, the Supraspinatus, Infraspinatus, and Teres minor; to the lesser tuberosity, the Subscapularis; to the anterior bicipital ridge, the Pectoralis major; to the posterior bicipital ridge, the Teres major; to the bicipital groove, the Latissimus dorsi; to the shaft, the Deltoid, Coraco-brachialis, Brachialis anticus, external and internal heads of the Triceps; to the internal condyle, the Pronator radii teres, and common

tendon of the Flexor carpi radialis, Palmaris longus, Flexor sublimis digitorum, and Flexor carpi ulnaris; to the external condyloid ridge, the Supinator longus, and Extensor carpi radialis longior; to the external condyle, the common tendon of the Extensor carpi radialis breviar, Extensor communis digitorum, Extensor minimi digiti, Extensor carpi ulnaris, and Supinator brevis; to the back of the external condyle, the Anconeus.

**Surface Form.**—The humerus is almost entirely clothed by the muscles which surround it, and the only parts of this bone which are strictly subcutaneous are small portions of the internal and external condyles. In addition to these, the tuberosities and a part of the head of the bone can be felt under the skin and muscles by which they are covered. Of these the greater tuberosity forms the most prominent bony point of the shoulder, extending beyond the acromion process and covered by the Deltoid muscle. It influences materially the surface form of the shoulder. It is best felt while the arm is lying loosely by the side; if the arm be raised, it recedes from under the finger. The lesser tuberosity, directed forwards and inwards, is to be felt to the inner side of the greater tuberosity, just below the acromio-clavicular joint. Between the two tuberosities lies the bicipital groove. This can be defined by placing the finger, and making firm pressure, just internal to the greater tuberosity; then, by rotating the humerus, the groove will be felt to pass under the finger as the bone is rotated. With the arm abducted from the side, by pressing deeply in the axilla, the lower part of the head of the bone is to be felt. On each side of the elbow-joint, and just above it, the internal and external condyles of the bone are to be felt. Of these the internal is the more prominent, but the ridge passing upwards from it, the internal condyloid ridge, is much less marked than the external, and, as a rule, is not to be felt. Occasionally, however, we find along this border the hook-shaped process mentioned above. The external condyle is most plainly to be seen during semiflexion of the forearm, and its position is indicated by a depression between the attachment of



the adjacent muscles. From it is to be felt a strong bony ridge running up the outer border of the shaft of the bone. This is the external condyloid ridge; it is concave forwards, and corresponds with the curved direction of the lower extremity of the humerus.

*Surgical Anatomy.*—There are several points of surgical interest connected with the humerus. First, as regards its development. The upper end, though the first to ossify, is the last to join the shaft, and the length of the bone is mainly due to growth from this upper epiphysis. Hence, in cases of amputation of the arm in young subjects, the humerus continues to grow considerably, and the end of the bone which immediately after the operation was covered with a thick cushion of soft tissue begins to project, thinning the soft parts and rendering the stump conical. This may necessitate the removal of a couple of inches or so of the bone, and even after this operation a recurrence of the conical stump may take place.

There are several points of surgical interest in connection with fractures. First, as regards their causation; the bone may be broken by direct or indirect violence like the other long bones, but, in addition to this, it is probably more frequently fractured by muscular action than any other of this class of bone in the body. It is usually the shaft, just below the insertion of the deltoid, which is thus broken. I have seen the accident happen from throwing a stone, and in an apparently healthy adult from cutting a piece of hard 'cake tobacco' on a table. In this latter case there was no disease of the bone that could be discovered. Fractures of the upper end may take place through the anatomical neck, through the surgical neck, or separation of the greater tuberosity may occur. Fracture of the anatomical neck is a very rare accident; in fact, it is doubted by some whether it ever occurs. These fractures are usually considered to be intracapsular, but they are probably partly within and partly without the capsule, as the lower part of the capsule is inserted some little distance below the anatomical neck, while the upper part is attached to it. They may be impacted or non-impacted. In most cases there is little or no displacement on account of the capsule, in whole or in part, remaining attached to the lower fragment. But occasionally a very remarkable alteration in position takes place; the upper fragment turns on its own axis, so that the cartilaginous surface of the head rests against the upper end of the lower fragment. When the fractured end is entirely separated from all its surroundings, its vascular supply must be entirely cut off, and one would expect it, theoretically, to necrose. But this must be exceedingly rare, for Gurlt was unable to find a single authenticated case recorded. Separation of the upper epiphysis of the humerus sometimes occurs in the young subject, and is marked by a characteristic deformity, by which the lesion may be at once recognised. This consists in the presence of an abrupt projection at the front of the joint some short distance below the coracoid process, caused by the upper end of the lower fragment. In fractures of the shaft of the humerus the lesion may take place at any point, but appears to be more common in the lower than the upper part of the bone. The points of interest in connection with these fractures are (1) that the musculo-spiral nerve may be injured as it lies in the groove on the bone, or may become involved in the callus which is subsequently thrown out; and (2) the frequency of non-union. This is believed to be more common in the humerus than in any other bone, and various causes have been assigned for it. It would seem most probably to be due to the difficulty that there is in fixing the shoulder-joint and the upper fragment, and possibly the elbow-joint and lower fragment also. Other causes which have been assigned for the non-union are: (1) that in attempting passive motion of the elbow-joint to overcome any rigidity which may exist, the movement does not take place at the articulation but at the seat of fracture; or that the patient, in consequence of the rigidity of the elbow, in attempting to flex or extend the forearm, moves the fragment and not the joint. (2) The presence of small portions of muscular tissue between the broken ends. (3) Want of support to the elbow, so that the weight of the arm tends to drag the lower fragment away from the upper. An important distinction to make in fractures of the lower end of the humerus, is between those that involve the joint and those which do not; the former are always serious, as they may lead to impairment of the utility of the limb. They include the T-shaped fracture and oblique fractures which involve the articular surface. The fractures which do not involve the joint are the transverse above the condyles, and detachment of one or other condyle.

Under the head of separation of the epiphysis two separate injuries have been described. One where the whole of the four ossific centres which form the lower extremity of the bone are separated from the shaft; and secondly, where the articular portion is alone separated, the two condyles remaining attached to the shaft of the bone. The epiphysial line between the shaft and lower end runs across the bone just above the tips of the condyles, a point to be borne in mind in performing the operation of excision.

Tumours originating from the humerus are of frequent occurrence. A not uncommon place for a chondroma to grow from is the shaft of the bone somewhere in the neighbourhood of the insertion of the deltoid. Sarcomata frequently grow from this bone.

The **Forearm** is that portion of the upper extremity which is situated between the elbow and wrist. It is composed of two bones, the ulna and the radius.



## THE ULNA

The **Ulna** (figs. 211, 212), so called from its forming the elbow (*ὀλένη*), is a long bone, prismatic in form, placed at the inner side of the forearm, parallel with the radius. It is the larger and longer of the two bones. Its upper extremity, of great thickness and strength, forms a large part of the articulation of the elbow-joint; it diminishes in size from above downwards, its lower extremity being very small, and excluded from the wrist-joint by the interposition of an interarticular fibro-cartilage. It is divisible into a shaft and two extremities.

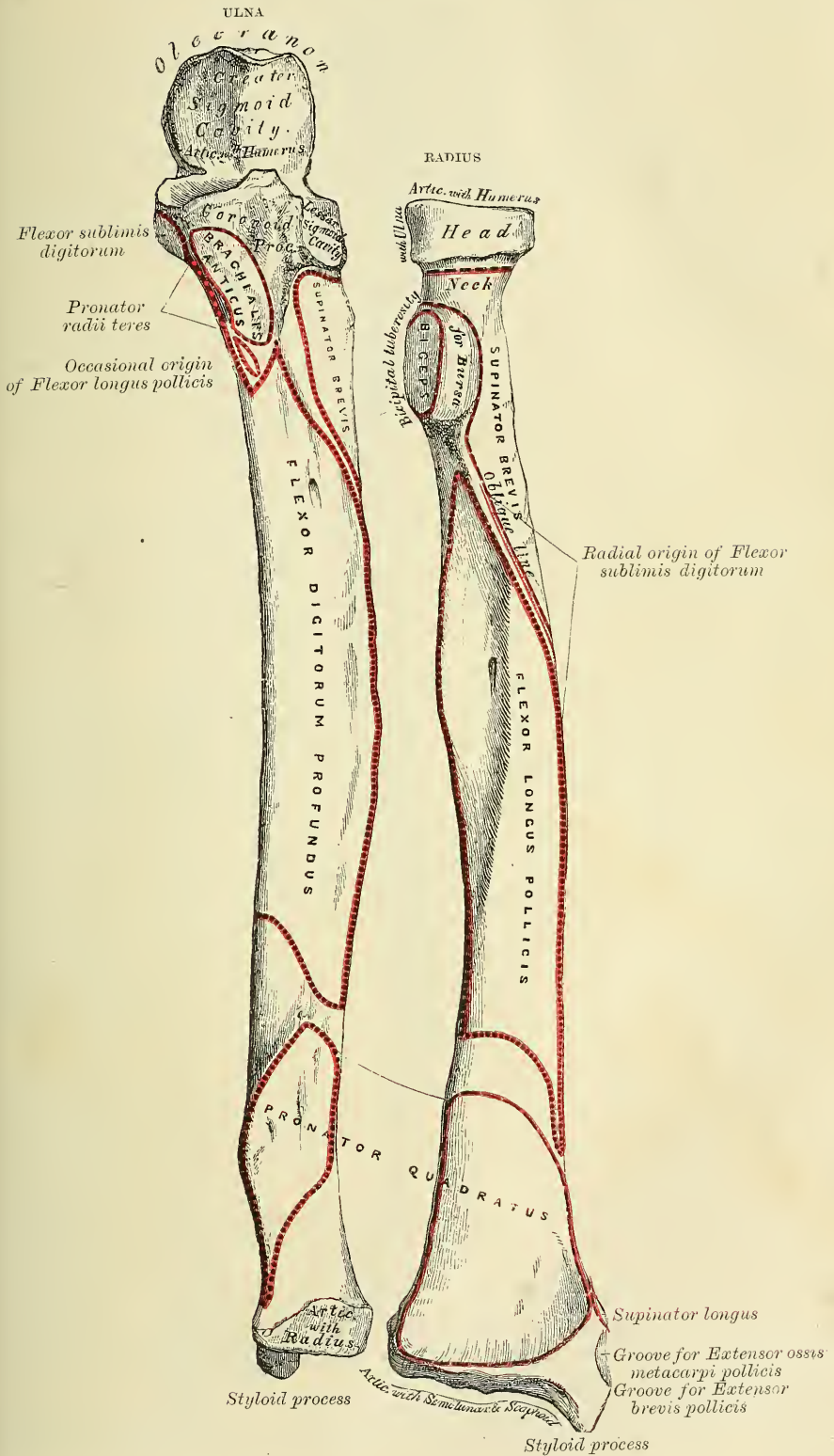
The **Upper Extremity**, the strongest part of the bone, presents for examination two large, curved processes, the Olecranon process and the Coronoid process; and two concave, articular cavities, the greater and lesser sigmoid cavities.

The **Olecranon Process** (*ὀλένη*, elbow; *κρανίον*, head) is a large, thick, curved eminence, situated at the upper and back part of the ulna. It is curved forwards at the summit so as to present a prominent tip, its base being contracted where it joins the shaft. This is the narrowest part of the upper end of the ulna, and, consequently, the most usual seat of fracture. The posterior surface of the olecranon, directed backwards, is triangular, smooth, subcutaneous, and covered by a bursa. Its upper surface is of quadrilateral form, marked behind by a rough impression for the attachment of the Triceps muscle; and in front, near the margin, by a slight transverse groove for the attachment of part of the posterior ligament of the elbow-joint. Its anterior surface is smooth, concave, covered with cartilage in the recent state, and forms the upper and back part of the great sigmoid cavity. The lateral borders present a continuation of the same groove that was seen on the margin of the superior surface; they serve for the attachment of ligaments—viz. the back part of the internal lateral ligament internally, the posterior ligament externally. To the inner border is also attached a part of the Flexor carpi ulnaris; while to the outer border is attached the Anconeus.

The **Coronoid Process** (*κορόνη*, anything hooked like a crow's beak) is a triangular eminence of bone which projects horizontally forwards from the upper and front part of the ulna, forming the lower part of the great sigmoid cavity. Its base is continuous with the shaft, and of considerable strength; so much so that fracture of it is an accident of rare occurrence. Its apex is pointed, slightly curved upwards, and received into the coronoid depression of the humerus in flexion of the forearm. Its upper surface is smooth, concave, and forms the lower part of the greater sigmoid cavity. The under surface is concave, and marked internally by a rough impression for the insertion of the Brachialis anticus. At the junction of this surface with the shaft is a rough eminence, the *tubercle of the ulna*, for the attachment of the oblique ligament. Its outer surface presents a narrow, oblong, articular depression, the *lesser sigmoid cavity*. The inner surface, by its prominent, free margin, serves for the attachment of part of the internal lateral ligament. At the front part of this surface is a small, rounded eminence for the attachment of one head of the Flexor sublimis digitorum; behind the eminence, a depression for part of the origin of the Flexor profundus digitorum; and, descending from the eminence, a ridge, which gives attachment to one end of the Pronator radii teres. Generally, the Flexor longus pollicis arises from the lower part of the coronoid process by a rounded bundle of muscular fibres.

The **Greater Sigmoid Cavity**, so called from its resemblance to the old shape of the Greek letter Σ, is a semilunar depression of large size, formed by the olecranon and coronoid processes, and serving for articulation with the trochlear surface of the humerus. About the middle of either lateral border of this cavity is a notch, which contracts it somewhat, and serves to indicate the junction of the two processes of which it is formed. The cavity is concave from above downwards, and divided into two lateral parts by a smooth, elevated ridge which runs from the summit of the olecranon to the tip of the coronoid process. Of these

FIG. 211.—Bones of the left forearm. Anterior surface.



two portions, the internal is the larger, and is slightly concave transversely; the external portion is convex above, slightly concave below. The articular surface, in the recent state, is covered with a thin layer of cartilage.

The **Lesser Sigmoid Cavity** is a narrow, oblong, articular depression, placed on the outer side of the coronoid process, and receives the lateral articular surface of the head of the radius. It is concave from before backwards; and its extremities, which are prominent, serve for the attachment of the orbicular ligament. In the recent state, it is covered with a thin layer of cartilage.

The **Shaft**, at its upper part, is prismatic in form, and curved from behind forwards, and from without inwards, so as to be convex behind and externally; its central part is quite straight; its lower part rounded, smooth, and bent a little outwards; it tapers gradually from above downwards, and presents for examination three borders, and three surfaces.

The **anterior border** commences above at the prominent inner angle of the coronoid process, and terminates below in front of the styloid process. It is well marked above, smooth and rounded in the middle of its extent, and affords attachment to the Flexor profundus digitorum: its lower fourth, marked off from the rest of the border by the commencement of an oblique ridge on the anterior surface, serves for the attachment of the Pronator quadratus. It separates the anterior from the internal surface.

The **posterior border** commences above at the apex of the triangular subcutaneous surface at the back part of the olecranon, and terminates below at the back part of the styloid process; it is well marked in the upper three-fourths, and gives attachment to an aponeurosis common to the Flexor carpi ulnaris, the Extensor carpi ulnaris, and the Flexor profundus digitorum muscles; its lower fourth is smooth and rounded. This border separates the internal from the posterior surface.

The **external or interosseous border** commences above by two lines, which converge one from each extremity of the lesser sigmoid cavity, enclosing between them a triangular space for the attachment of part of the Supinator brevis, and terminates below at the middle of the head of the ulna. Its two middle fourths are very prominent, its lower fourth is smooth and rounded. This border gives attachment to the interosseous membrane, except along its upper fourth, and separates the anterior from the posterior surface.

The **anterior surface**, much broader above than below, is concave in the upper three-fourths of its extent, and affords attachment to the Flexor profundus digitorum; its lower fourth, also concave, to the Pronator quadratus. The lower fourth is separated from the remaining portion of the bone by a prominent ridge, directed obliquely from above downwards and inwards; this ridge (the *oblique* or *Pronator ridge*) marks the extent of attachment of the Pronator quadratus above. At the junction of the upper with the middle third of the bone is the nutrient canal, directed obliquely upwards and inwards.

The **posterior surface**, directed backwards and outwards, is broad and concave above, somewhat narrower and convex in the middle of its course, narrow, smooth, and rounded below. It presents, above, an oblique ridge, which runs from the posterior extremity of the lesser sigmoid cavity, downwards to the posterior border; the triangular surface above this ridge receives the insertion of the Anconeus muscle, whilst the ridge itself affords attachment to the Supinator brevis. The surface of bone below this is subdivided by a longitudinal ridge, sometimes called the *perpendicular line*, into two parts: the internal part is smooth, concave, and is covered by the Extensor carpi ulnaris; the external portion, wider and rougher, gives attachment from above downwards to part of the Supinator brevis, the Extensor ossis metacarpi pollicis, the Extensor longus pollicis, and the Extensor indicis muscles.

The **internal surface** is broad and concave above, narrow and convex below. It gives attachment by its upper three-fourths to the Flexor profundus digitorum muscle: its lower fourth is subcutaneous.



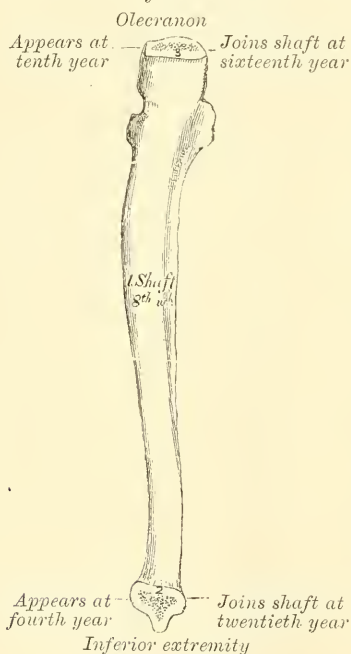


The **Lower Extremity** of the ulna is of small size, and excluded from the articulation of the wrist-joint. It presents for examination two eminences, the outer and larger of which is a rounded, articular eminence, termed the *head* of the ulna; the inner, narrower and more projecting, is a non-articular eminence, the *styloid process*. The *head* presents an articular facet, part of which, of an oval form, is directed downwards, and articulates with the upper surface of the interarticular fibro-cartilage which separates it from the wrist-joint; the remaining portion, directed outwards, is narrow, convex, and received into the sigmoid cavity of the radius. The *styloid process* projects from the inner and back part of the bone, and descends a little lower than the head, terminating in a rounded summit, which affords attachment to the internal lateral ligament of the wrist. The head is separated from the styloid process by a depression for the attachment of the triangular interarticular fibro-cartilage; and behind, by a shallow groove for the passage of the tendon of the Extensor carpi ulnaris.

**Structure.**—Similar to that of the other long bones.

**Development.**—By three centres: one for the shaft, one for the inferior extremity, and one for the olecranon (fig. 213). Ossification commences near the

FIG. 213.—Plan of the development of the ulna. By three centres.



middle of the shaft about the eighth week, and soon extends through the greater part of the bone. At birth the ends are cartilaginous. About the fourth year, a separate osseous nucleus appears in the middle of the head, which soon extends into the styloid process. About the tenth year, ossific matter appears in the olecranon near its extremity, the chief part of this process being formed from an extension of the shaft of the bone into it. At about the sixteenth year, the upper epiphysis becomes joined, and at about the twentieth year the lower one.

**Articulations.**—With the humerus and radius.

**Attachment of Muscles.**—To fourteen: to the olecranon, the Triceps, Anconeus, and one head of the Flexor carpi ulnaris. To the coronoid process, the Brachialis anticus, Pronator radii teres, Flexor sublimis digitorum, and Flexor profundus digitorum; generally also the Flexor longus pollicis. To the shaft, the Flexor profundus digitorum, Pronator quadratus, Flexor carpi ulnaris, Extensor

carpi ulnaris, Anconeus, Supinator brevis, Extensor ossis metacarpi pollicis, Extensor longus pollicis, and Extensor indicis.

**Surface Form.**—The most prominent part of the ulna on the surface of the body is the olecranon process, which can always be felt at the back of the elbow-joint. When the forearm is flexed, the upper triangular surface can be felt, directed backwards; during extension it recedes into the olecranon fossa, and the contracting fibres of the Triceps prevent its being perceived. At the back of the olecranon is the smooth, triangular, subcutaneous surface, which below is continuous with the posterior border of the shaft of the bone; this is to be felt in every position of the joint. During extension, the upper border of the olecranon is slightly above the level of the internal condyle, and the process itself is nearer to this condyle than the outer one. Running down the back of the forearm, from the apex of the triangular surface which forms the posterior surface of the olecranon, is a prominent ridge of bone, the posterior border of the ulna. This is to be felt throughout the entire length of the shaft of the bone, from the olecranon above to the styloid process below. As it passes down the forearm it pursues a sinuous course and inclines to the

inner side, so that, though it is situated in the middle of the back of the limb above, it is on the inner side of the wrist at its termination. It becomes rounded off in its lower third, and may be traced below to the small, subcutaneous surface of the styloid process. Internal to this border the lower fourth of the internal surface is to be felt. The styloid process is to be felt as a prominent tubercle of bone, continuous above with the posterior subcutaneous border of the ulna, and terminating below in a blunt apex, which lies a little internal, and behind, but on a level with, the wrist-joint. The styloid process is best felt when the hand is in the same line as the bones of the forearm, and in a position midway between supination and pronation. If the forearm is pronated while the finger is placed on the process, it will be felt to recede, and another prominence of bone will appear just external and above it. This is the head of the ulna, which articulates with the lower end of the radius and the triangular interarticular fibro-cartilage, and now projects between the tendons of the Extensor carpi ulnaris and the Extensor minimi digiti muscles.

### THE RADIUS

The **Radius** (*radius, a ray, or spoke of a wheel*) is situated on the outer side of the forearm, lying side by side with the ulna, which exceeds it in length and size (figs. 211, 212). Its upper end is small, and forms only a small part of the elbow-joint; but its lower end is large, and forms the chief part of the wrist. It is one of the long bones, prismatic in form, slightly curved longitudinally, and, like other long bones, has a shaft and two extremities.

The **Upper Extremity** presents a head, neck, and tuberosity. The *head* is of a cylindrical form, depressed on its upper surface into a shallow cup which articulates with the capitellum or radial head of the humerus. In the recent state it is covered with a layer of cartilage, which is thinnest at its centre. Around the circumference of the head is a smooth, articular surface, broad internally where it articulates with the lesser sigmoid cavity of the ulna; narrow in the rest of its circumference, where it rotates within the orbicular ligament. It is coated with cartilage in the recent state. The head is supported on a round, smooth, and constricted portion of bone, called the *neck*, which presents, behind, a slight ridge, for the attachment of part of the Supinator brevis. Beneath the neck, at the inner and front aspect of the bone, is a rough eminence, the *bicipital tuberosity*. Its surface is divided into two parts by a vertical line—a posterior, rough portion, for the insertion of the tendon of the Biceps muscle; and an anterior, smooth portion, on which a bursa is interposed between the tendon and the bone.

The **Shaft** of the bone is prismoid in form, narrower above than below, and slightly curved, so as to be convex outwards. It presents three surfaces, separated by three borders.

The **anterior border** extends from the lower part of the tuberosity above, to the anterior part of the base of the styloid process below. It separates the anterior from the external surface. Its upper third is very prominent; and from its oblique direction, downwards and outwards, has received the name of the *oblique line of the radius*. It gives attachment, externally, to the Supinator brevis; internally, to the Flexor longus pollicis, and between these to the Flexor sublimis digitorum. The middle third of the anterior border is indistinct and rounded. Its lower fourth is sharp, prominent, affords attachment to the Pronator quadratus, and terminates in a small tubercle, into which is inserted the tendon of the Supinator longus.

The **posterior border** commences above, at the back part of the neck of the radius, and terminates below, at the posterior part of the base of the styloid process; it separates the posterior from the external surface. It is indistinct above and below, but well marked in the middle third of the bone.

The **internal or interosseous border** commences above, at the back part of the tuberosity, where it is rounded and indistinct, becomes sharp and prominent as it descends, and at its lower part divides into two ridges, which descend to the anterior and posterior margins of the sigmoid cavity. This border separates the



anterior from the posterior surface, and has the interosseous membrane attached to it throughout the greater part of its extent.

The **anterior surface** is narrow and concave for its upper three-fourths, and gives attachment to the Flexor longus pollicis muscle; it is broad and flat for its lower fourth, and gives attachment to the Pronator quadratus. A prominent ridge limits the attachment of the Pronator quadratus below, and between this and the inferior border is a triangular rough surface for the attachment of the anterior ligament of the wrist-joint. At the junction of the upper and middle third of this surface is the nutrient foramen, which is directed obliquely upwards.

The **posterior surface** is rounded, convex, and smooth in the upper third of its extent, and covered by the Supinator brevis muscle. Its middle third is broad, slightly concave, and gives attachment to the Extensor ossis metacarpi pollicis above, the Extensor brevis pollicis below. Its lower third is broad, convex, and covered by the tendons of the muscles, which subsequently run in the grooves on the lower end of the bone.

The **external surface** is rounded and convex throughout its entire extent. Its upper third gives attachment to the Supinator brevis muscle. About its centre is seen a rough ridge, for the insertion of the Pronator radii teres muscle. Its lower part is narrow, and covered by the tendons of the Extensor ossis metacarpi pollicis and Extensor brevis pollicis muscles.

The **Lower Extremity** of the radius is large, of quadrilateral form, and provided with two articular surfaces—one at the extremity, for articulation with the carpus, and one at the inner side of the bone, for articulation with the ulna. The carpal articular surface is of triangular form, concave, smooth, and divided by a slight antero-posterior ridge into two parts. Of these, the external is large, of a triangular form, and articulates with the scaphoid bone; the inner, smaller and quadrilateral, articulates with the semilunar. The articular surface for the ulna is called the *sigmoid cavity* of the radius; it is narrow, concave, smooth, and articulates with the head of the ulna. The circumference of this end of the bone presents three surfaces—an anterior, external, and posterior. The *anterior surface*, rough and irregular, affords attachment to the anterior ligament of the wrist-joint. The *external surface* is prolonged obliquely downwards into a strong, conical projection, the *styloid process*, which gives attachment by its base to the tendon of the Supinator longus, and by its apex to the external lateral ligament of the wrist-joint. The outer surface of this process is marked by a flat groove, which runs obliquely downwards and forwards, and gives passage to the tendons of the Extensor ossis metacarpi pollicis, and the Extensor brevis pollicis. The *posterior surface* is convex, affords attachment to the posterior ligament of the wrist, and is marked by three grooves. Proceeding from without inwards, the first groove is broad, but shallow, and subdivided into two by a slightly elevated ridge: the outer of these two transmits the tendon of the Extensor carpi radialis longior, the inner the tendon of the Extensor carpi radialis brevior. The second, which is near the centre of the bone, is a deep but narrow groove, bounded on its outer side by a sharply defined ridge; it is directed obliquely from above, downwards and outwards, and transmits the tendon of the Extensor longus pollicis. The third, lying most internally, is a broad groove, for the passage of the tendons of the Extensor indicis and Extensor communis digitorum.

**Structure.**—Similar to that of the other long bones.

**Development** (fig. 214).—By *three* centres: one for the shaft, and one for each extremity. That for the shaft makes its appearance near the centre of the bone, soon after the development of the humerus commences. At birth the shaft is ossified, but the ends of the bone are cartilaginous. About the end of the second year, ossification commences in the lower epiphysis; and about the fifth year, in the upper one. At the age of seventeen or eighteen the upper epiphysis becomes joined to the shaft; the lower epiphysis becoming united about the twentieth year.

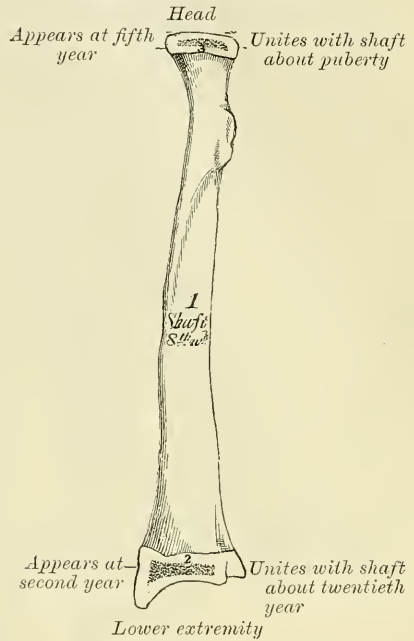
**Articulations.**—With four bones: the humerus, ulna, scaphoid, and semilunar.

**Attachment of Muscles.**—To nine; to the tuberosity, the Biceps; to the oblique ridge, the Supinator brevis, Flexor sublimis digitorum, and Flexor longus pollicis; to the shaft (its anterior surface), the Flexor longus pollicis and Pronator quadratus; (its posterior surface), the Extensor ossis metacarpi pollicis and Extensor brevis pollicis; (its outer surface), the Pronator radii teres; and to the styloid process, the Supinator longus.

**Surface Form.**—Just below, and a little in front of, the posterior surface of the external condyle a part of the head of the radius may be felt, covered by the orbicular and external lateral ligaments. There is in this situation a little dimple in the skin, which is most visible when the arm is extended, and which marks the position of the head of the bone. If the finger is placed on this dimple, and the forearm pronated and supinated, the head of the bone will be distinctly perceived rotating in the lesser sigmoid cavity. The upper half of the shaft of the radius cannot be felt, as it is surrounded by the fleshy bellies of the muscles arising from the external condyle. The lower half of the shaft can be readily examined, though covered by tendons and muscles and not strictly subcutaneous. If traced downwards, the shaft will be felt to terminate in a lozenge-shaped, convex surface on the outer side of the base of the styloid process. This is the only subcutaneous part of the bone, and from its lower extremity the apex of the styloid process will be felt bending inwards towards the wrist. About the middle of the posterior aspect of the lower extremity of the bone is a well-marked ridge, best perceived when the hand is slightly flexed on the wrist. It bounds the oblique groove on the posterior surface of the bone, through which the tendon of the Extensor longus pollicis runs, and serves to keep that tendon in its place.

**Surgical Anatomy.**—The two bones of the forearm are more often broken together, than is either the radius or ulna separately. It is therefore convenient to consider the fractures of these two bones together in the first instance and subsequently to mention the principal fractures which take place in each bone individually. These fractures may be produced by either direct or indirect violence, though more commonly by direct violence. When indirect force is applied to the forearm the radius generally alone gives way, though both bones may suffer. The fracture from indirect force generally takes place somewhere about the middle of the bones, fracture from direct violence may occur at any part, more often, however, in the lower half of the bone. The fracture is usually transverse, but may be more or less oblique. A point of interest in connection with these fractures is the tendency that there is for the two bones to unite across the interosseous membrane; the limb should therefore be put up in a position midway between supination and pronation, which is not only the most comfortable position, but also separates the bones most widely from each other and therefore diminishes the risk of the bones becoming united across the interosseous membrane. The splints, anterior and posterior, which are applied in these cases should be rather wider than the limb, so as to prevent any lateral pressure on the bones. For in these cases there is a greater liability to gangrene from the pressure of the splints than in other parts of the body. This is no doubt due principally to two causes: (1) the flexion of the forearm compressing to a certain extent the brachial artery and retarding the flow of blood to the limb; and (2) the superficial position of the two main arteries of the forearm in a part of their course, and their liability to be compressed by the splints. The special fractures of the ulna are:—(1) fracture of the olecranon. This may be caused by direct violence, falls on the elbow with the forearm flexed, or by muscular action by the sudden contraction of the Triceps. The most common place for the fracture to occur is at the constricted portion where the olecranon joins the shaft of the bone, and the fracture may be either transverse or oblique; but any part may be broken, even a thin shell may

FIG. 214.—Plan of the development of the radius. By three centres.



be torn off. Fractures from direct violence are occasionally comminuted. The displacement is sometimes very slight, owing to the fibrous structures around the process not being torn. (2) Fracture of the coronoid process sometimes occurs as a complication of dislocation backwards of the bones of the forearm, but it is doubtful if it ever occurs as an uncomplicated injury. (3) Fractures of the shaft of the ulna may occur at any part, but usually take place at the middle of the bone or a little below it. They are almost always the result of direct violence. (4) The styloid process may be knocked off by direct violence. Fractures of the radius consist of (1) fracture of the head of the bone; this generally occurs in conjunction with some other lesion, but may occur as an uncomplicated injury. (2) Fracture of the neck may also take place, but is generally complicated with other injury. (3) Fractures of the shaft of the radius are very common, and may take place at any part of the bone. They may take place from either direct or indirect violence. In fractures of the upper third of the shaft of the bone, that is to say, above the insertion of the *Pronator radii teres*, the displacement is very great. The upper fragment is strongly supinated by the *Biceps* and *Supinator brevis*, and flexed by the *Biceps*; whilst the lower fragment is pronated and drawn towards the ulna by the two pronators. If such a fracture is put up in the ordinary position, midway between supination and pronation, the fracture will unite with the upper fragment in a position of supination, and the lower one in the mid position, and thus considerable impairment of the movements of the hand result. The limb should be put up with the forearm supinated. (4) The most important fracture of the radius is that of the lower end (*Colles's fracture*). The fracture is transverse, and generally takes place about an inch from the lower extremity. It is caused by falls on the palm of the hand, and is an injury of advanced life, occurring more frequently in the female than the male. In consequence of the manner in which the fracture is caused, the upper fragment becomes driven into the lower, and impaction is the result; or else the lower fragment becomes split up into two or more pieces, so that no fixation occurs. Separation of the lower epiphysis of the radius may take place in the young. This injury and *Colles's fracture* may be distinguished from other injuries in this neighbourhood—especially dislocation, with which it is liable to be confounded—by observing the relative positions of the styloid processes of the ulna and radius. In the natural condition of parts, with the arm hanging by the side, the styloid process of the radius is on a lower level than that of the ulna, that is to say, nearer the ground. After fracture or separation of the epiphysis this process is on the same or higher level than that of the ulna, whereas it would be unaltered in position in dislocation.

## THE HAND

The skeleton of the Hand is subdivided into three segments—the *Carpus* or wrist bones; the *Metacarpus* or bones of the palm; and the *Phalanges* or bones of the fingers.

## THE CARPUS

The bones of the *Carpus* (*καρπός*, *the wrist*), eight in number, are arranged in two rows. Those of the upper row, enumerated from the radial to the ulnar side, are the scaphoid, semilunar, cuneiform, and pisiform; those of the lower row, enumerated in the same order, are the trapezium, trapezoid, os magnum, and unciform.

### COMMON CHARACTERS OF THE CARPAL BONES

Each bone (excepting the pisiform) presents six surfaces. Of these the *anterior* or *palmar* and the *posterior* or *dorsal* are rough, for ligamentous attachment; the dorsal surface being the broader, except in the scaphoid and semilunar. The *superior* or *proximal* and *inferior* or *distal* are articular, the superior generally convex, the inferior concave; and the *internal* and *external* are also articular when in contact with contiguous bones, otherwise rough and tubercular. The structure in all is similar, consisting of cancellous tissue enclosed in a layer of compact bone. Each bone is also developed from a single centre of ossification.

### BONES OF THE UPPER ROW

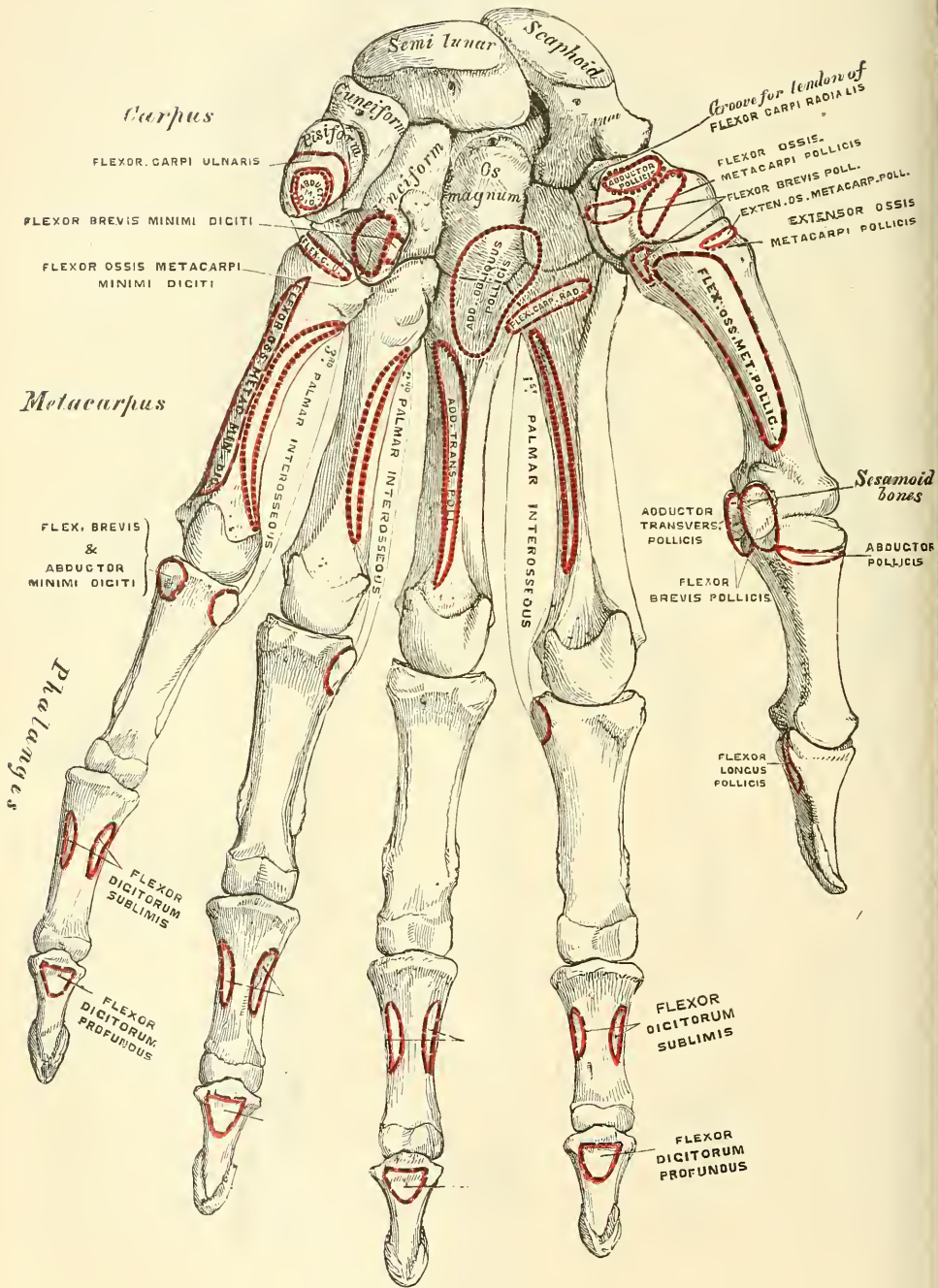
#### SCAPHOID (fig. 217)

The **Scaphoid** is the largest bone of the first row. It has received its name from its fancied resemblance to a boat, being broad at one end, and



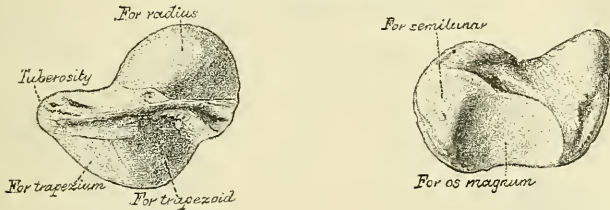


FIG. 216.—Bones of the left hand. Palmar surface.



narrowed, like a prow, at the opposite (*σκάφη, a boat; εἶδος, like*). It is situated at the upper and outer part of the carpus, its long axis being from above downwards, outwards, and forwards. The *superior surface* is convex, smooth, of triangular shape, and articulates with the lower end of the radius. The *inferior surface*, directed downwards, outwards, and backwards, is smooth, convex, also triangular, and divided by a slight ridge into two parts, the external of which articulates with the trapezium, the inner with the trapezoid. The *posterior or dorsal surface* presents a narrow, rough groove, which runs the entire breadth of

FIG. 217.—The left scaphoid.



the bone, and serves for the attachment of ligaments. The *anterior or palmar surface* is concave above, and elevated at its lower and outer part into a prominent, rounded tubercle, which projects forwards from the front of the carpus and gives attachment to the anterior annular ligament of the wrist and sometimes a few fibres of the *Abductor pollicis*. The *external surface* is rough and narrow, and gives attachment to the external lateral ligament of the wrist. The *internal surface* presents two articular facets; of these, the superior or smaller one is flattened, of semilunar form, and articulates with the semilunar; the inferior or larger is concave, forming, with the semilunar bone, a concavity for the head of the *os magnum*.

To ascertain to which side the bone belongs, hold it with the superior or radial, convex, articular surface upwards, and the posterior surface—i.e. the narrow, non-articular, grooved surface—towards you. The tubercle on the outer surface points to the side to which the bone belongs.\*

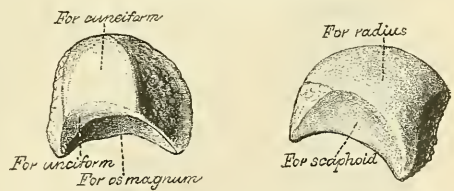
**Articulations.**—With five bones: the radius above, trapezium and trapezoid below, *os magnum* and semilunar internally.

**Attachment of Muscles.**—Occasionally a few fibres of the *Abductor pollicis*.

SEMI LUNAR (fig. 218)

The **Semilunar** bone may be distinguished by its deep concavity and crescentic outline (*semi, half; luna, moon*). It is situated in the centre of the upper row of the carpus, between the scaphoid and cuneiform. The *superior surface*, convex, smooth, and bounded by four edges, articulates with the radius. The *inferior surface* is deeply concave, and of greater extent from before backwards than transversely: it articulates with the head of the *os magnum*, and, by a long, narrow facet (separated by a ridge from the general surface), with the unciform bone. The *anterior or palmar* and *posterior or dorsal surfaces* are rough, for the attachment of ligaments, the former being the broader, and of somewhat rounded form. The *external surface* presents a narrow, flattened,

FIG. 218.—The left semilunar.



\* In these directions each bone is supposed to be placed in its natural position—that is, such a position as it would occupy when the arm is hanging by the side, the forearm in a position of supination, the thumb being directed outwards and the palm of the hand looking forwards.



semilunar facet for articulation with the scaphoid. The *internal surface* is marked by a smooth, quadrilateral facet, for articulation with the cuneiform.

Hold it with the convex articular surface for the radius upwards, and the narrowest non-articular surface towards you. The semilunar facet for the scaphoid will be on the side to which the bone belongs.

**Articulations.**—With five bones: the radius above, os magnum and unciform below, scaphoid and cuneiform on either side.

#### CUNEIFORM (fig. 219)

The **Cuneiform** (*cuneus, a wedge; forma, likeness*) may be distinguished by its pyramidal shape (*os pyramidal*), and by its having an oval, isolated facet for articulation with the pisiform bone. It is situated at the upper and inner side of the carpus. The *superior surface* presents an internal, rough, non-articular portion, and an external or articular portion, which is convex, smooth, and articulates with the triangular interarticular fibro-cartilage of the wrist. The *inferior surface*, directed outwards, is concave, sinuously curved, and smooth for articulation with the unciform. The *posterior or dorsal surface* is rough, for the attachment of ligaments. The *anterior or palmar surface* presents, at its inner side, an oval facet, for articulation with the pisiform; and is rough externally, for ligamentous attachment. The *external surface*, the base of the pyramid, is marked by a flat, quadrilateral, smooth facet, for articulation with the semilunar. The *internal surface*, the summit of the pyramid, is pointed and roughened, for the attachment of the internal lateral ligament of the wrist.

Hold the bone with the surface supporting the pisiform facet away from you, and the concavo-convex surface for the unciform downwards. The base of the wedge (i.e. the broad end of the bone) will be on the side to which it belongs.

**Articulations.**—With three bones: the semilunar externally, the pisiform in front, the unciform below; and with the triangular, interarticular fibro-cartilage which separates it from the lower end of the ulna.

#### PISIFORM (fig. 220)

The **Pisiform** (*pisum, a pea; forma, likeness*) may be known by its small size, and by its presenting a single articular facet. It is situated on a plane anterior to the other bones of the carpus; it is spheroidal in form, with its long diameter directed vertically. Its *posterior surface* presents a smooth, oval facet, for articulation with the cuneiform: this facet approaches the superior, but not the inferior, border of the bone. The *anterior or palmar surface* is rounded and rough, and gives attachment to the anterior annular ligament and to the Flexor carpi ulnaris and Abductor minimi digiti muscles. The *outer and inner surfaces* are also rough, the former being concave, the latter usually convex.

Hold the bone with the posterior surface—that which presents the articular facet—towards you, in such a manner that the faceted portion of the surface is uppermost. The outer, concave surface will point to the side to which it belongs.

**Articulations.**—With one bone, the cuneiform.

**Attachment of Muscles.**—To two: the Flexor carpi ulnaris and Abductor minimi digiti; and to the anterior annular ligament.

FIG. 219.—The left cuneiform.

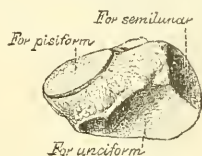
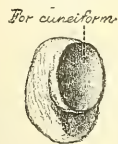

FIG. 220.—The left pisiform.

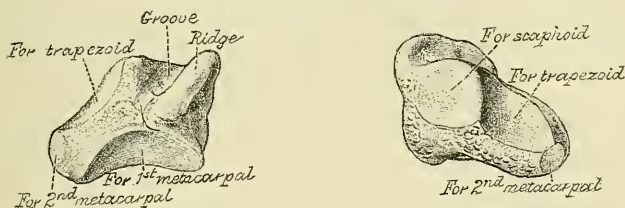


BONES OF THE LOWER ROW

TRAPEZIUM (fig. 221)

The **Trapezium** (τράπεζα, a table) is of very irregular form. It may be distinguished by a deep groove, for the tendon of the Flexor carpi radialis muscle. It is situated at the external and inferior part of the carpus, between the scaphoid and first metacarpal bone. The *superior surface*, concave and smooth, is directed upwards and inwards, and articulates with the scaphoid. The *inferior surface*, directed downwards and inwards, is oval, concave from side to side, convex from before backwards, so as to form a saddle-shaped surface, for articulation with

FIG. 221.—The left trapezium.



the base of the first metacarpal bone. The *anterior or palmar surface* is narrow and rough. At its upper part is a deep groove, running from above obliquely downwards and inwards: it transmits the tendon of the Flexor carpi radialis, and is bounded externally by a prominent ridge, the oblique ridge of the trapezium. This surface gives attachment to the Abductor pollicis, Flexor ossis metacarpi pollicis, and Flexor brevis pollicis muscles, and the anterior annular ligament. The *posterior or dorsal surface* is rough. The *external surface* is also broad and rough, for the attachment of ligaments. The *internal surface* presents two articular facets: the upper one, large and concave, articulates with the trapezoid; the lower one, narrow and flattened, with the base of the second metacarpal bone.

Hold the bone with the saddle-shaped surface downwards and the grooved surface away from you. The prominent, rough, non-articular surface points to the side to which the bone belongs.

**Articulations.**—With four bones: the scaphoid above, the trapezoid and second metacarpal bones internally, the first metacarpal below.

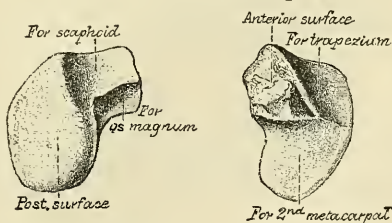
**Attachment of Muscles.**—Abductor pollicis, Flexor ossis metacarpi pollicis, and part of the Flexor brevis pollicis.

TRAPEZOID (fig. 222)

The **Trapezoid** is the smallest bone in the second row. It may be known by its wedge-shaped form, the broad end of the wedge forming the dorsal, the narrow end the palmar, surface; and by its having four articular surfaces touching each other, and separated by sharp edges. The *superior surface*, quadrilateral in form, smooth, and slightly concave, articulates with the scaphoid. The *inferior surface* articulates with the upper end of the second metacarpal bone; it is convex from side to side, concave from before backwards, and subdivided, by an elevated ridge, into two unequal lateral facets.

The *posterior or dorsal* and *anterior or palmar surfaces* are rough, for the attachment of ligaments, the former being the larger of the two. The *external*

FIG. 222.—The left trapezoid.



surface, convex and smooth, articulates with the trapezium. The *internal surface* is concave and smooth in front, for articulation with the os magnum; rough behind, for the attachment of an interosseous ligament.

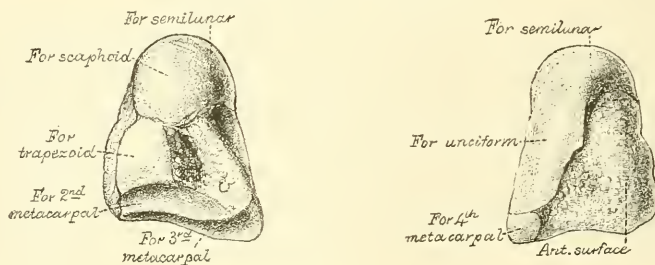
Hold the bone with the larger, non-articular surface towards you, and the smooth, quadrilateral articular surface upwards. The convex, articular surface will point to the side to which the bone belongs.\*

**Articulations.**—With four bones: the scaphoid above, second metacarpal bone below, trapezium externally, os magnum internally.

#### OS MAGNUM (fig. 223)

The **Os Magnum** is the largest bone of the carpus, and occupies the centre of the wrist. It presents, above, a rounded portion or head, which is received into the concavity formed by the scaphoid and semilunar bones; a constricted portion or neck; and, below this, the body. The *superior surface* is rounded, smooth, and articulates with the semilunar. The *inferior surface* is divided by two ridges into three facets, for articulation with the second, third, and fourth metacarpal bones, that for the third (the middle facet) being the largest of the three. The *posterior or dorsal surface* is broad and rough; the *anterior or palmar, narrow,*

FIG. 223.—The left os magnum.



rounded, and also rough, for the attachment of ligaments and a part of the Adductor obliquus pollicis. The *external surface* articulates with the trapezoid by a small facet at its anterior inferior angle, behind which is a rough depression for the attachment of an interosseous ligament. Above this is a deep and rough groove, which forms part of the neck, and serves for the attachment of ligaments, bounded superiorly by a smooth, convex surface, for articulation with the scaphoid. The *internal surface* articulates with the unciform by a smooth, concave, oblong facet, which occupies its posterior and superior parts; and is rough in front, for the attachment of an interosseous ligament.

Hold the bone with the broader, non-articular surface towards you, and the head upwards. The small, articular facet at the anterior inferior angle of the external surface will point to the side to which the bone belongs.

**Articulations.**—With seven bones: the scaphoid and semilunar above; the second, third, and fourth metacarpal below; the trapezoid on the radial side; and the unciform on the ulnar side.

**Attachment of Muscles.**—Part of the Adductor obliquus pollicis.

#### UNCIFORM (fig. 224)


The **Unciform** (*uncus, a hook; forma, likeness*) may be readily distinguished by its wedge-shaped form, and the hook-like process that projects from its palmar surface. It is situated at the inner and lower angle of the carpus, with its base

\* Occasionally in a badly marked bone there is some difficulty in ascertaining to which side the bone belongs; the following method will sometimes be found useful. Hold the bone with its broader, non-articular surface upwards, so that its sloping border is directed towards you. The border will slope to the side to which the bone belongs.



downwards, resting on the two inner metacarpal bones, and its apex directed upwards and outwards. The *superior surface*, the apex of the wedge, is narrow, convex, smooth, and articulates with the semilunar. The *inferior surface* articulates with the fourth and fifth metacarpal bones, the concave surface for each being separated by a ridge, which runs from before backwards. The *posterior* or *dorsal surface* is triangular and rough, for ligamentous attachment. The *anterior* or *palmar surface* presents, at its lower and inner side, a curved, hook-like process of bone, the *unciform process*, directed from the palmar surface forwards and outwards. It gives attachment, by its apex, to the annular ligament and the Flexor carpi ulnaris; by its inner surface to the Flexor brevis minimi digiti and the Flexor ossis metacarpi minimi digiti; and is grooved on its outer side, for the passage of the Flexor tendons into the palm of the hand. This is one of the four eminences on the front of the carpus to which the anterior annular ligament is attached; the others being the pisiform internally, the oblique ridge of the trapezium and the tuberosity of the scaphoid externally. The *internal surface* articulates with the cuneiform by an oblong facet, cut obliquely from above, down-

FIG. 224.—The left unciform.



wards and inwards. The *external surface* articulates with the os magnum by its upper and posterior part, the remaining portion being rough, for the attachment of ligaments.

Hold the bone with the hooked process away from you, and the articular surface, divided into two parts for the metacarpal bones, downwards. The concavity of the process will be on the side to which the bone belongs.

**Articulations.**—With five bones: the semilunar above, the fourth and fifth metacarpal below, the cuneiform internally, the os magnum externally.

**Attachment of Muscles.**—To three: the Flexor brevis minimi digiti, the Flexor ossis metacarpi minimi digiti, the Flexor carpi ulnaris.

## THE METACARPUS

The **Metacarpal Bones** are five in number: they are long cylindrical bones, presenting for examination a shaft and two extremities.

### COMMON CHARACTERS OF THE METACARPAL BONES

The **shaft** is prismoid in form, and curved longitudinally, so as to be convex in the longitudinal direction behind, concave in front. It presents three surfaces: two lateral and one posterior. The *lateral surfaces* are concave, for the attachment of the Interossei muscles, and separated from one another by a prominent ridge. The *posterior* or *dorsal surface* presents in its distal half a smooth, triangular, flattened area which is covered, in the recent state, by the tendons of the Extensor muscles. This triangular surface is bounded by two lines, which commence in small tubercles situated on the dorsal aspect of either side of the digital extremity, and, running backwards, converge to meet together a little behind the centre of the bone and form a ridge which runs along the rest of the dorsal surface to the carpal extremity. This ridge separates two lateral, sloping surfaces for the attachment of the Dorsal interossei muscles.\* To the tubercles

\* By these sloping surfaces the metacarpal bones of the hand may be at once differentiated from the metatarsal bones of the foot.

on the digital extremities are attached the lateral ligaments of the metacarpophalangeal joints.

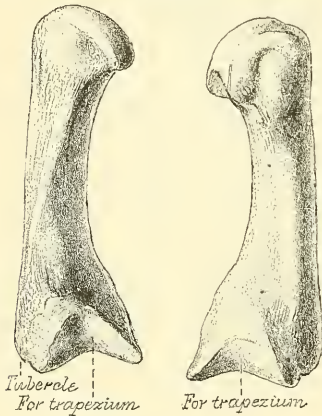
The **carpal extremity**, or **base**, is of a cuboidal form, and broader behind than in front : it articulates above with the carpus, and on each side with the adjoining metacarpal bones ; its *dorsal* and *palmar surfaces* are rough, for the attachment of tendons and ligaments.

The **digital extremity**, or **head**, presents an oblong surface, flattened at each side ; it articulates with the proximal phalanx ; it is broader, and extends farther forwards, on the palmar than on the dorsal aspect. It is longer in the antero-posterior than in the transverse diameter. On either side of the head is a tubercle for the attachment of the lateral ligament of the metacarpophalangeal joint. The *posterior surface*, broad and flat, supports the Extensor tendons ; the *anterior surface* is grooved in the middle line for the passage of the Flexor tendons and marked on each side by an articular eminence continuous with the terminal articular surface.

#### PECULIAR CHARACTERS OF THE METACARPAL BONES

The **metacarpal bone of the thumb** (fig. 225) is shorter and wider than the rest, diverges to a greater degree from the carpus, and its *palmar surface* is directed inwards towards the palm. The *shaft* is flattened and broad on its dorsal aspect, and does not present the ridge which is found on the other metacarpal bones ; it is concave from before backwards, on its palmar surface. The *carpal extremity*, or *base*, presents a concavo-convex surface, for articulation with the trapezium ; it has no lateral facets, but presents externally a tubercle for the insertion of the Extensor ossis metacarpi pollicis. The *digital extremity* is less convex than that of the other metacarpal bones, broader from side to side than from before backwards. It presents on its palmar aspect two distinct articular eminences for the two sesamoid bones in the tendons of the Flexor brevis pollicis ; the outer one being the larger of the two.

FIG. 225.—The first metacarpal.  
(Left.)



The *carpal extremity*, or *base*, presents a concavo-convex surface, for articulation with the trapezium ; it has no lateral facets, but presents externally a tubercle for the insertion of the Extensor ossis metacarpi pollicis. The *digital extremity* is less convex than that of the other metacarpal bones, broader from side to side than from before backwards. It presents on its palmar aspect two distinct articular eminences for the two sesamoid bones in the tendons of the Flexor brevis pollicis ; the outer one being the larger of the two.

The side to which this bone belongs may be known by holding it in the position it occupies in the hand, with the carpal extremity upwards and the dorsal surface backwards ; the tubercle for the Extensor ossis metacarpi pollicis will point to the side to which it belongs.

**Attachment of Muscles.**—To four : the Flexor ossis metacarpi pollicis, the Extensor ossis metacarpi pollicis, the Flexor brevis pollicis, and the First dorsal interosseous.

The **metacarpal bone of the index finger** (fig. 226) is the longest, and its base the largest, of the other four. Its *carpal extremity* is prolonged upwards and inwards, forming a prominent ridge. The dorsal and palmar surfaces of this extremity are rough, for the attachment of tendons and ligaments. It presents four articular facets : three on the upper aspect of the base ; the middle one of the three is the largest, concave from side to side, convex from before backwards, for articulation with the trapezoid ; the external one is a small, flat, quadrilateral facet, for articulation with the trapezium ; the internal one on the summit of the ridge is long and narrow, for articulation with the os magnum. The fourth facet is on the inner or ulnar side of the extremity of the bone, and is for articulation with the third metacarpal bone.

The side to which this bone belongs is indicated by the absence of the lateral

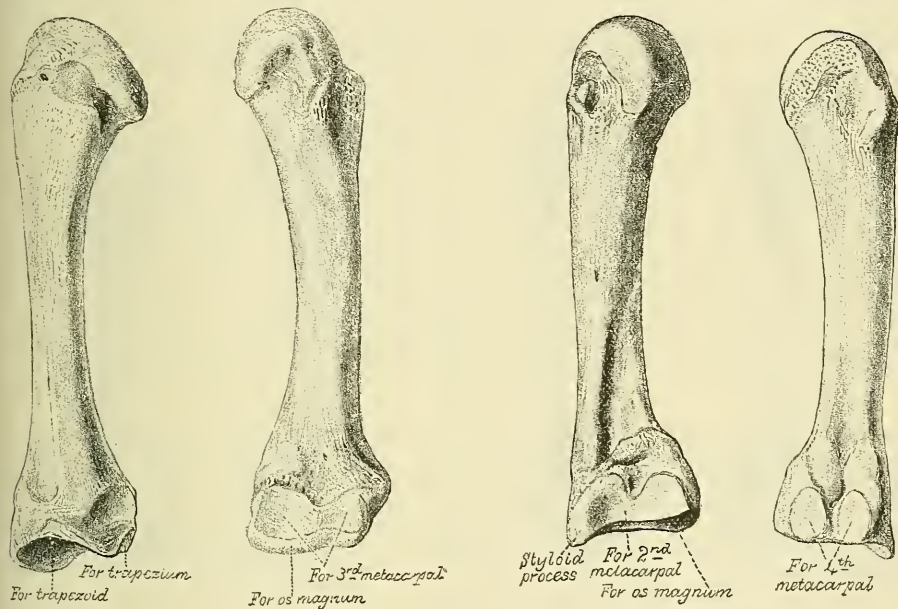
facet on the outer (radial) side of its base, so that if the bone is placed with its base towards the student, and the palmar surface upwards, the side on which there is no lateral facet will be that to which it belongs.

**Attachment of Muscles.**—To six : Flexor carpi radialis, Extensor carpi radialis longior, Adductor obliquus pollicis, First and Second dorsal interosseous, and First palmar interosseous.

The **metacarpal bone of the middle finger** (fig. 227) is a little smaller than the preceding ; it presents a pyramidal eminence (the styloid process) on the radial side of its base (dorsal aspect), which extends upwards behind the os magnum ; immediately below this, on the dorsal aspect, is a rough surface for the attachment of the Extensor carpi radialis brevior. The carpal, articular facet is concave behind, flat in front, and articulates with the os magnum. On the radial side is a smooth, concave facet for articulation with the second metacarpal bone, and on the ulnar side two small, oval facets, for articulation with the fourth metacarpal.

FIG. 226.—The second metacarpal. (Left.)

FIG. 227.—The third metacarpal. (Left.)



The side to which this bone belongs is easily recognised by the styloid process on the radial side of its base. With the palmar surface uppermost, and the base towards the student, this process points towards the side to which the bone belongs.

**Attachment of Muscles.**—To six : Extensor carpi radialis brevior, Flexor carpi radialis, Adductor transversus pollicis, Adductor obliquus pollicis, and Second and Third dorsal interosseous.

The **metacarpal bone of the ring-finger** (fig. 228) is shorter and smaller than the preceding, and its base small and quadrilateral ; the carpal surface of the base presenting two facets, for articulation with the unciform and os magnum. On the radial side are two oval facets, for articulation with the third metacarpal bone ; and on the ulnar side, a single concave facet, for the fifth metacarpal.

If this bone is placed with the base towards the student, and the palmar surface upwards, the radial side of the base, which has two facets for articulation with the third metacarpal bone, will be on the side to which it belongs. If, as sometimes happens in badly marked bones, one of these facets is indistinguishable, the side may be known by selecting the surface on which the larger



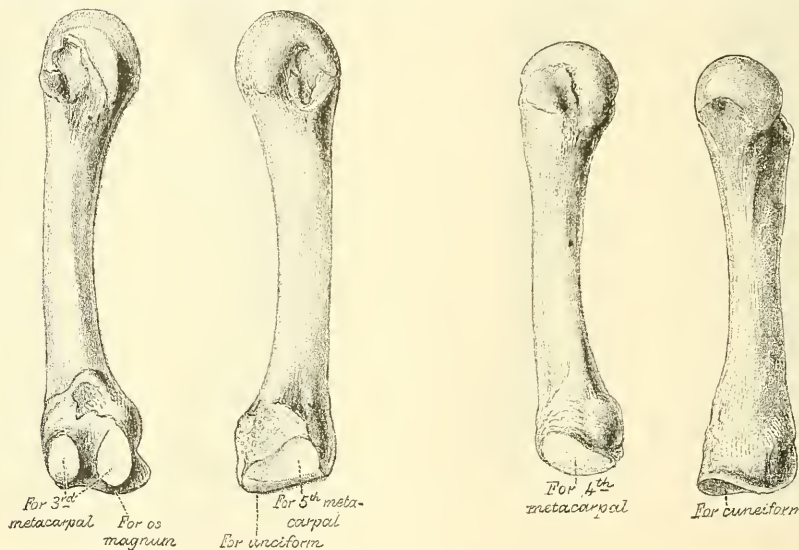
articular facet is present. This facet is for the fifth metacarpal bone, and would therefore be situated on the ulnar side—that is, the one to which the bone does *not* belong.

**Attachment of Muscles.**—To three: the Third and Fourth dorsal and Second palmar interosseous.

The **metacarpal bone of the little finger** (fig. 229) presents on its base one facet, which is concavo-convex, and which articulates with the unciform bone, and one lateral, articular facet, which articulates with the fourth metacarpal bone. On its ulnar side is a prominent tubercle, for the insertion of the tendon of the Extensor carpi ulnaris. The dorsal surface of the shaft is marked by an oblique ridge, which extends from near the ulnar side of the upper extremity to the radial side of the lower. The outer division of this surface serves for the attachment of the Fourth dorsal interosseous muscle; the inner division is smooth, and covered by the Extensor tendons of the little finger.

If this bone is placed with its base towards the student, and its palmar surface upwards, the side of the head which has a lateral facet will be that to which the bone belongs.

FIG. 228.—The fourth metacarpal. (Left.) FIG. 229.—The fifth metacarpal. (Left.)



**Attachment of Muscles.**—To five: the Extensor carpi ulnaris, Flexor carpi ulnaris, Flexor ossis metacarpi minimi digiti, Fourth dorsal, and Third palmar interosseous.

**Articulations.**—Besides the phalangeal articulations, the first metacarpal bone articulates with the trapezium; the second with the trapezium, trapezoid, os magnum, and third metacarpal bones; the third with the os magnum, and second and fourth metacarpal bones; the fourth with the os magnum, unciform, and third and fifth metacarpal bones; and the fifth with the unciform and fourth metacarpal.

The *first* has no lateral facets on its carpal extremity; the *second* has no lateral facet on its radial side, but one on its ulnar side; the *third* has one on its radial and two on its ulnar side; the *fourth* has two on its radial and one on its ulnar side; and the *fifth* has only one on its radial side.

## PHALANGES

The **Phalanges** (*internodia*) are the bones of the fingers; they are fourteen in number, three for each finger, and two for the thumb. They are long bones,

and present for examination a shaft and two extremities. The *shaft* tapers from above downwards, is convex posteriorly, concave in front from above downwards, flat from side to side, and marked laterally by rough ridges, which give attachment to the fibrous sheaths of the Flexor tendons. The *metacarpal extremity* or *base*, in the first row presents an oval, concave, articular surface, broader from side to side than from before backwards; and the same extremity in the other two rows, a double concavity, separated by a longitudinal median ridge, extending from before backwards. The *digital extremities* are smaller than the others, and terminate, in the first and second rows, in two small, lateral condyles, separated by a slight groove; the articular surface being prolonged farther forwards on the palmar than on the dorsal surface, especially in the first row.

The **Ungual Phalanges** are convex on their dorsal, flat on their palmar surfaces; they are recognised by their small size, and by a roughened, elevated surface of a horseshoe form on the palmar aspect of their unguis extremity, which serves to support the sensitive pulp of the finger.

**Articulations.**—The first row with the metacarpal bones and the second row of phalanges; the second row with the first and third; the third with the second row.

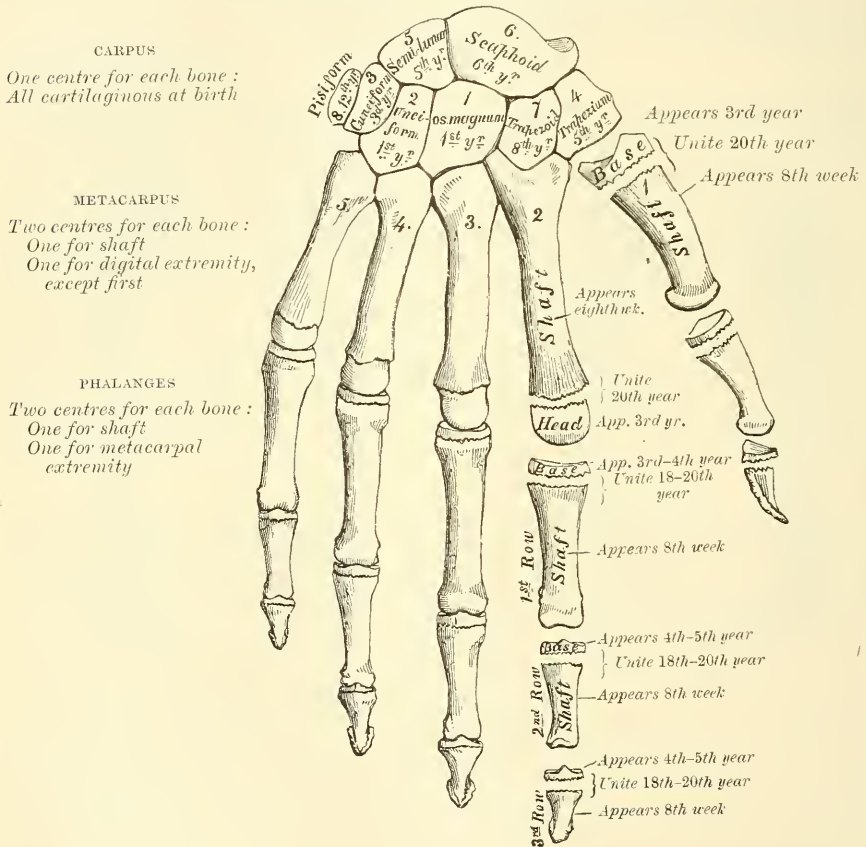
**Attachment of Muscles.**—To the base of the first phalanx of the thumb, five muscles: the Extensor brevis pollicis, Flexor brevis pollicis, Abductor pollicis, Adductor transversus and obliquus pollicis. To the second phalanx, two: the Flexor longus pollicis and the Extensor longus pollicis. To the base of the first phalanx of the index finger, the First dorsal and the First palmar interosseous; to that of the middle finger, the Second and Third dorsal interosseous; to that of the ring-finger, the Fourth dorsal and the Second palmar interosseous; and to that of the little finger, the Third palmar interosseous, the Flexor brevis minimi digiti, and Abductor minimi digiti. To the second phalanges, the Flexor sublimis digitorum, Extensor communis digitorum, and, in addition, the Extensor indicis to the index finger, the Extensor minimi digiti to the little finger. To the third phalanges, the Flexor profundus digitorum and Extensor communis digitorum.

**Surface Form.**—On the front of the wrist are two subcutaneous eminences, one on the radial side, the larger and flatter, due to the tuberosity of the scaphoid and the ridge on the trapezium; the other, on the ulnar side, caused by the pisiform bone. The tubercle of the scaphoid is to be felt just below and in front of the apex of the styloid process of the radius. It is best perceived by extending the hand on the forearm. Immediately below is to be felt another prominence, better marked than the tubercle; this is the ridge on the trapezium, which gives attachment to some of the short muscles of the thumb. On the inner side of the front of the wrist the pisiform bone is to be felt, forming a small but prominent projection in this situation. It is some distance below the styloid process of the ulna, and may be said to be just below the level of the styloid process of the radius. The rest of the front of the carpus is covered by tendons and the annular ligament, and entirely concealed, with the exception of the hooked process of the unciform, which can only be made out with difficulty. The back of the carpus is convex and covered by the Extensor tendons, so that none of the posterior surfaces of the bones are to be felt, with the exception of the cuneiform on the inner side. Below the carpus the dorsal surface of the metacarpal bones except the fifth are covered by tendons, and are scarcely visible except in very thin hands. The dorsal surface of the fifth is, however, subcutaneous throughout almost its whole length, and is plainly to be perceived and felt. In addition to this, slightly external to the middle line of the hand, is a prominence, frequently well marked, but occasionally indistinct, formed by the base of the metacarpal of the middle finger. The heads of the metacarpal bones are plainly to be felt and seen, rounded in contour and standing out in bold relief under the skin, when the fist is clenched. It should be borne in mind that when the fingers are flexed on the hand, the articular surfaces of the first phalanges glide off the heads of the metacarpal bones on to their anterior surfaces; so that the heads of these bones form the prominence of the knuckles and receive the force of any blow which may be given. The head of the third metacarpal bone is the most prominent, and receives the greater part of the shock of the blow. This bone articulates with the os magnum, so that the concussion is carried through this bone to the scaphoid and semilunar, with which the head of the os magnum articulates, and by these bones is transferred to the radius, along which it may be carried to the capitellum of the humerus. The enlarged extremities of the phalanges are to be plainly felt: they form

the joints of the fingers. When the digits are bent, the proximal phalanges of the joints form prominences, which in the joint between the first and second phalanges is slightly hollowed, in accordance with the grooved shape of their articular surfaces, whilst in the last row the prominence is flattened and square-shaped. In the palm of the hand the four inner metacarpal bones are covered by muscles, tendons, and the palmar fascia, and no part of them but their heads is to be distinguished. With regard to the thumb, on the dorsal aspect, the base of the metacarpal bone forms a prominence, below the styloid process of the radius; the shaft is to be felt, covered by tendons, terminating at its head in a flattened prominence, in front of which can be felt the sesamoid bones.

*Surgical Anatomy.*—The carpal bones are little liable to fracture, except from extreme violence, when the parts are so comminuted as to necessitate amputation. Occasionally they are the seat of tuberculous disease. The metacarpal bones and the phalanges are not unfrequently broken from direct violence. The first metacarpal bone is the one most commonly fractured, then the second, the fourth and the fifth, the third being the one least frequently broken. There are two diseases of the metacarpal bones and phalanges which

FIG. 230.—Plan of the development of the hand.



require special mention on account of the frequency of their occurrence. One is tuberculous dactylitis, consisting in a deposit of tuberculous material in the medullary canal, expansion of the bone, with subsequent caseation and resulting necrosis. The other is chondroma, which is perhaps more frequently found in connection with the metacarpal bones and phalanges than with any other bones. The tumours are commonly multiple, and may spring either from the medullary canal, or from the periosteum.

#### DEVELOPMENT OF THE BONES OF THE HAND

The **Carpal Bones** are each developed by a *single* centre. At birth, they are all cartilaginous. Ossification proceeds in the following order (fig. 230) : In the os magnum and unciform an ossific point appears during the first year, the former preceding the latter ; in the cuneiform, at the third year ; in the trapezium



and semilunar, at the fifth year, the former preceding the latter ; in the scaphoid, at the sixth year ; in the trapezoid, during the eighth year ; and in the pisiform, about the twelfth year.

The **Metacarpal Bones** are each developed by *two* centres : one for the shaft, and one for the digital extremity, for the four inner metacarpal bones ; one for the shaft, and one for the base, for the metacarpal bone of the thumb, which in this respect resembles the phalanges.\* Ossification commences in the centre of the shaft about the eighth or ninth week, and gradually proceeds to either end of the bone ; about the third year the digital extremities of the four inner metacarpal bones, and the base of the first metacarpal, begin to ossify, and they unite about the twentieth year.

The **Phalanges** are each developed by *two* centres : one for the shaft, and one for the base. Ossification commences in the shaft, in all three rows, at about the eighth week, and gradually involves the whole of the bone excepting the upper extremity. Ossification of the base commences in the first row between the third and fourth years, and a year later in those of the second and third rows. The two centres become united, in each row, between the eighteenth and twentieth years.

In the ungual phalanges the centre for the shaft appears at the distal extremity of the phalanx, instead of at the middle of the shaft as is the case with the other phalanges.

#### OF THE LOWER EXTREMITY

The **Lower Extremity** consists of three segments, the *thigh*, *leg*, and *foot*, which correspond to the *arm*, *forearm*, and *hand* in the upper extremity. It is connected to the trunk through the os innominatum, or hip-bone, which forms the pelvic girdle.

#### THE OS INNOMINATUM

The **Os Innominatum** (in, *not* ; *nomino*, *I name*), or *nameless bone*, so called from bearing no resemblance to any known object, is a large, irregularly shaped, flat bone, constricted in the centre and expanded above and below. With its fellow of the opposite side, it forms the sides and anterior wall of the pelvic cavity. In young subjects it consists of three separate parts, which meet and form the large, cup-like cavity situated near the middle of the outer surface of the bone : and, although in the adult these have become united, it is usual to describe the bone as divisible into three portions—the ilium, the ischium, and the os pubis.

The **ilium**, so called from its supporting the flank (*ilia*), is the superior, broad and expanded portion which runs upwards from the upper and back part of the acetabulum, and forms the prominence of the hip.

The **ischium** (*ισχίον*, *the hip*) is the inferior and strongest portion of the bone ; it proceeds downwards from the acetabulum, expands into a large tuberosity, and then, curving upwards, forms, with the descending ramus of the os pubis, a large aperture, the obturator foramen.

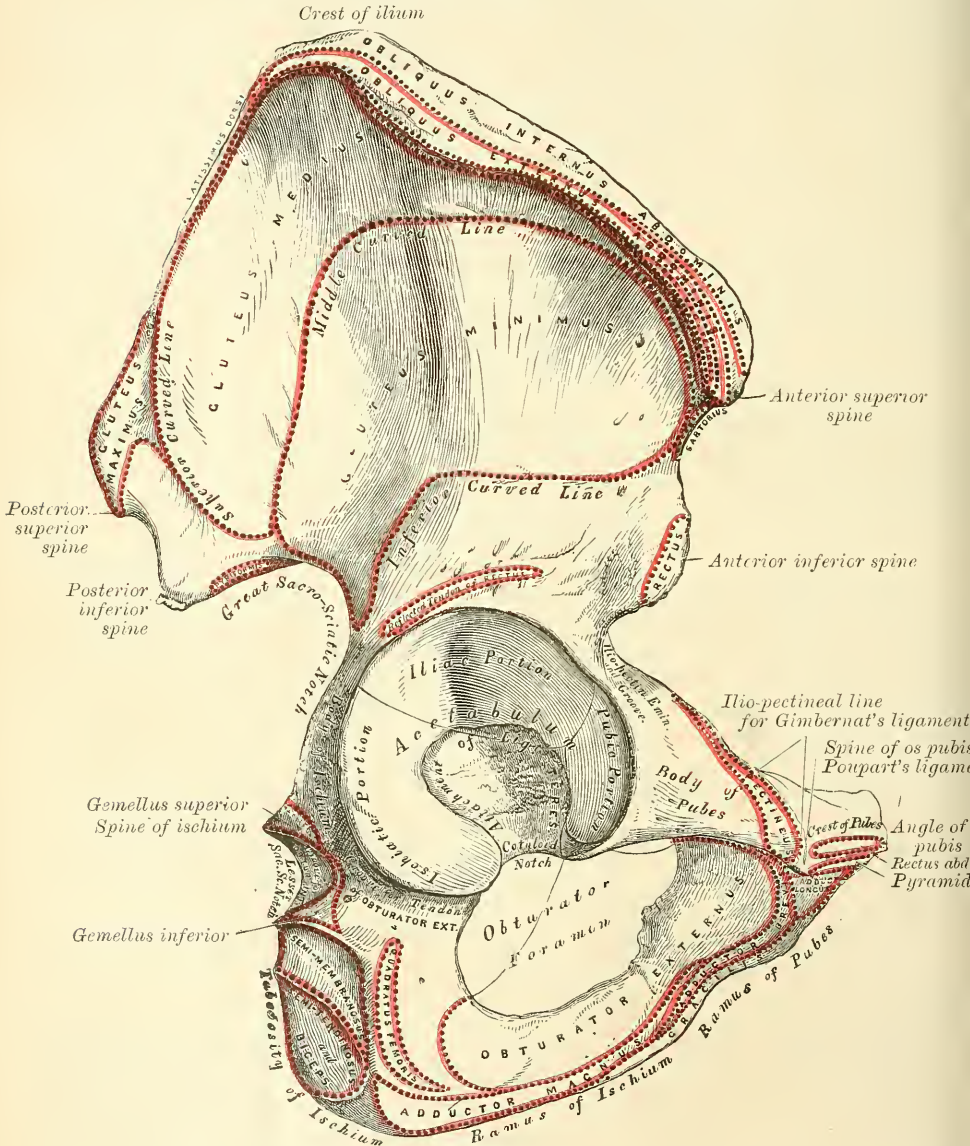
The **os pubis** is that portion which extends inwards from the inner side of the acetabulum for about two inches, then makes a sudden bend, and descends for about one inch : it forms the front of the pelvis, supports the external organs of generation, and has received its name from the skin over it being covered with hair.

The **Ilium** presents for examination two surfaces—an external and an internal—a crest, and two borders—an anterior and a posterior.

\* Allen Thomson has demonstrated the fact that the first metacarpal bone is often developed from three centres ; that is to say, there is a separate nucleus for the distal end, forming a distinct epiphysis visible at the age of seven or eight years. He also states that there are traces of a proximal epiphysis in the second metacarpal bone. *Journal of Anatomy*, 1869.

**External Surface or Dorsum of the Ilium** (fig. 231).—The back part of this surface is directed backwards, downwards, and outwards; its front part forwards, downwards, and outwards. It is smooth, convex in front, deeply concave behind; bounded above by the crest, below by the upper border of the acetabulum; in front and behind, by the anterior and posterior borders. This surface is crossed in an arched direction by three semicircular lines—the superior, middle, and inferior curved lines. The superior curved line, the shortest

FIG. 231.—Right os innominatum. External surface.

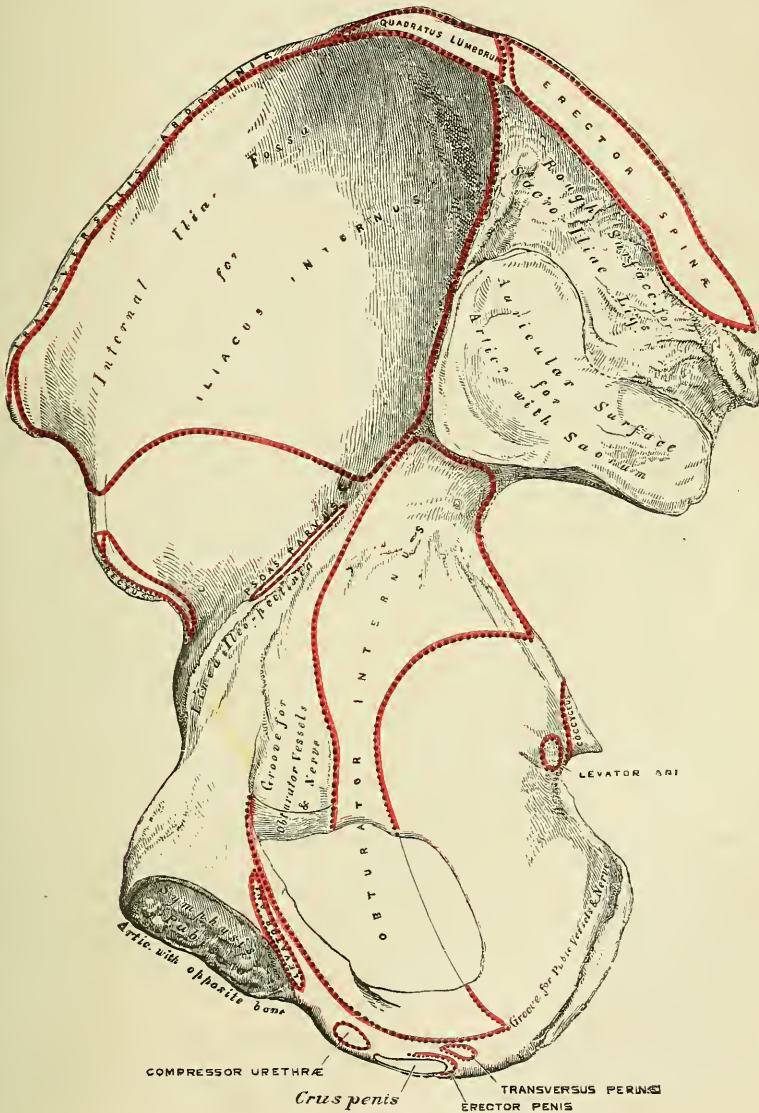


of the three, commences at the crest, about two inches in front of its posterior extremity; it is at first distinctly marked, but as it passes downwards and outwards to the upper part of the great sacro-sciatic notch, where it terminates, it becomes less marked, and is often altogether lost. Behind this line is a narrow semilunar surface, the upper part of which is rough and affords attachment to part of the Gluteus maximus; the lower part is smooth and has no muscular fibres attached to it. The middle curved line, the longest of the three, com-



mences at the crest, about an inch behind its anterior extremity, and, taking a curved direction downwards and backwards, terminates at the upper part of the great sacro-sciatic notch. The space between the superior and middle curved lines and the crest is concave, and affords attachment to the *Gluteus medius* muscle. Near the central part of this line may often be observed the orifice of a nutrient foramen. The inferior curved line, the least distinct of the three, commences in front at the notch on the anterior border, and, taking a

FIG. 232.—Right os innominatum. Internal surface.



curved direction backwards and downwards, terminates at the middle of the great sacro-sciatic notch. The surface of bone included between the middle and inferior curved lines is concave from above downwards, convex from before backwards, and affords attachment to the *Gluteus minimus* muscle. Beneath the inferior curved line, and corresponding to the upper part of the acetabulum, is a roughened surface (sometimes a depression), to which is attached the reflected tendon of the *Rectus femoris* muscle.

The **Internal Surface** (fig. 232) of the ilium is bounded above by the crest;



below it is continuous with the pelvic surfaces of the os pubis and ischium, a faint line only indicating the place of union; and before and behind it is bounded by the anterior and posterior borders. It presents anteriorly a large, smooth, concave surface, called the *internal iliac fossa*, or *venter of the ilium*, which lodges the Iliacus muscle, and presents at its lower part the orifice of a nutrient canal; and below this a smooth, rounded border, the *linea ilio-pectinea*, which separates the iliac fossa from that portion of the internal surface which enters into the formation of the true pelvis, and which gives attachment to part of the Obturator internus muscle. Behind the iliac fossa is a rough surface, divided into two portions, an anterior and a posterior. The anterior or auricular portion, so called from its resemblance in shape to the ear, is coated with cartilage in the recent state, and articulates with a surface of similar shape on the side of the sacrum. The posterior portion is rough, for the attachment of the posterior sacro-iliac ligaments and for a part of the origin of the Erector spinæ.

The **crest** of the ilium is convex in its general outline and sinuously curved, being concave inwards in front, concave outwards behind. It is longer in the female than in the male, very thick behind, and thinner at the centre than at the extremities. It terminates at either end in a prominent eminence, the *anterior superior* and *posterior superior spinous process*. The surface of the crest is broad, and divided into an external lip, an internal lip, and an intermediate space. To the external lip is attached the Tensor vaginæ femoris, Obliquus externus abdominis, and Latissimus dorsi, and by its whole length the fascia lata; to the space between the lips, the Internal oblique; to the internal lip, the Transversalis, Quadratus lumborum, and Erector spinæ, the Iliacus, and the fascia iliaca.

The **anterior border** of the ilium is concave. It presents two projections, separated by a notch. Of these, the uppermost, situated at the junction of the crest and anterior border, is called the *anterior superior spinous process* of the ilium, the outer border of which gives attachment to the fascia lata, and the origin of the Tensor vaginæ femoris; its inner border, to the Iliacus; whilst its extremity affords attachment to Poupart's ligament and the origin of the Sartorius. Beneath this eminence is a notch which gives attachment to the Sartorius muscle, and across which passes the external cutaneous nerve. Below the notch is the *anterior inferior spinous process*, which terminates in the upper lip of the acetabulum; it gives attachment to the straight tendon of the Rectus femoris muscle and the ilio-femoral ligament. On the inner side of the anterior inferior spinous process is a broad, shallow groove, over which passes the Iliacus muscle. This groove is bounded internally by an eminence, the *ilio-pectineal*, which marks the point of union of the ilium and os pubis.

The **posterior border** of the ilium, shorter than the anterior, also presents two projections separated by a notch, the *posterior superior* and the *posterior inferior spinous processes*. The former corresponds with that portion of the posterior surface of the ilium which serves for the attachment of the oblique portion of the sacro-iliac ligaments and the Multifidus spinæ; the latter to the auricular portion which articulates with the sacrum. Below the posterior inferior spinous process is a deep notch, the *great sacro-sciatic*.

The **Ischium** forms the lower and back part of the os innominatum. It is divisible into a thick and solid portion, the *body*; a large, rough eminence, on which the body rests in sitting, the *tuberosity*; and a thin, ascending part, the *ramus*.

The **body**, somewhat triangular in form, presents three surfaces, external, internal, and posterior; and three borders, external, internal, and posterior. The *external surface* corresponds to that portion of the acetabulum formed by the ischium; it is smooth and concave, and forms a little more than two-fifths of the acetabular cavity; its outer margin is bounded by a prominent rim or lip, the external border, to which the cotyloid fibro-cartilage is attached. Below the acetabulum, between it and the tuberosity, is a deep groove, along which the tendon of the Obturator externus muscle runs, as it passes outwards to be inserted

into the digital fossa of the femur. The *internal surface* is smooth, concave, and enters into the formation of the lateral boundary of the true pelvic cavity. This surface is perforated by two or three large, vascular foramina, and affords attachment to part of the Obturator internus muscle. The *posterior surface* is quadrilateral in form, broad and smooth. Below, where it joins the tuberosity, it presents a groove continuous with that on the external surface, for the tendon of the Obturator externus muscle. The lower edge of this groove is formed by the tuberosity of the ischium, and affords attachment to the Gemellus inferior muscle. This surface is limited, in front, by the margin of the acetabulum; behind, by the posterior border; it supports the Pyliformis, the two Gemelli, and the Obturator internus muscles, in their passage outwards to the great trochanter. The *external border* forms the prominent rim of the acetabulum, and separates the posterior from the external surface. To it is attached the cotyloid fibro-cartilage. The *internal border* is thin, and forms the outer circumference of the obturator foramen. The *posterior border* of the body of the ischium presents, a little below the centre, a thin and pointed triangular eminence, the *spine of the ischium*, more or less elongated in different subjects; its external surface gives attachment to the Gemellus superior, its internal surface to the Coccygeus and Levator ani; whilst to the pointed extremity is connected the lesser sacro-sciatic ligament. Above the spine is a notch of large size, the *great sacro-sciatic*, converted into a foramen by the lesser sacro-sciatic ligament; it transmits the Pyliformis muscle, the gluteal vessels and superior gluteal nerve, the sciatic vessels, the greater and lesser sciatic nerves, the internal pudic vessels and nerve, and muscular branches from the sacral plexus. Of these, the gluteal vessels and superior gluteal nerve pass out above the Pyliformis muscle, the other structures below it. Below the spine is a smaller notch, the *lesser sacro-sciatic*; it is smooth, coated in the recent state with cartilage, the surface of which presents numerous markings corresponding to the subdivisions of the tendon of the Obturator internus, which winds over it. It is converted into a foramen by the sacro-sciatic ligaments, and transmits the tendon of the Obturator internus, the nerve which supplies that muscle, and the internal pudic vessels and nerve.

The **tuberosity** presents for examination three surfaces: external, internal, and inferior. The *external surface* is quadrilateral in shape and rough for the attachment of muscles. It is bounded above by the groove for the tendon of the Obturator externus; in front it is limited by the posterior margin of the obturator foramen, and below it is continuous with the ramus of the bone; behind, it is bounded by a prominent margin which separates it from the inferior surface. In front of this margin the surface gives attachment to the Quadratus femoris, and anterior to this to some of the fibres of origin of the Obturator externus. The lower part of the surface gives origin to part of the Adductor magnus. The *internal surface* forms part of the bony wall of the true pelvis. In front, it is limited by the posterior margin of the obturator foramen. Behind, it is bounded by a sharp ridge, for the attachment of a falciform prolongation of the great sacro-sciatic ligament; it presents a groove on the inner side of this for the lodgment of the internal pudic vessels and nerve; and, more anteriorly, has attached the Transversus perinæi and Erector penis muscles. The *inferior surface* is divided into two portions: an anterior, rough, somewhat triangular part, and a posterior, smooth, quadrilateral portion. The anterior surface is subdivided by a prominent vertical ridge, passing from base to apex, into two parts; the outer one gives attachment to the Adductor magnus, the inner to the great sacro-sciatic ligament. The posterior portion is subdivided into two facets by an oblique ridge, which runs forwards and outwards; from the upper and outer facet arises the Semi-membranosus; from the lower and inner, the Biceps and Semi-tendinosus.

The **ramus**, or **ascending ramus**, is the thin, flattened part of the ischium, which ascends from the tuberosity upwards and inwards, and joins the ramus of the os

pubis—their point of junction being indicated in the adult by a rough line. The outer surface of the ramus is rough, for the attachment of the Obturator externus muscle, and also some fibres of the Adductor magnus; its inner surface forms part of the anterior wall of the pelvis. Its inner border is thick, rough, slightly everted, forms part of the outlet of the pelvis, and presents two ridges and an intervening space. The ridges are continuous with similar ones on the descending ramus of the os pubis: to the outer one is attached the deep layer of the superficial perineal fascia, and to the inner the anterior layer of the triangular ligament of the perinæum. If these two ridges are traced downwards, they will be found to join with each other just behind the point of origin of the Transversus perinæi muscle; here the two layers of fascia are continuous behind the posterior border of the muscle. To the intervening space, just in front of the point of junction of the ridges, is attached the Transversus perinæi muscle, and in front of this a portion of the crus penis vel clitoridis and the Erector penis vel clitoridis muscle. Its outer border is thin and sharp, and forms part of the inner margin of the obturator foramen.

The **Os Pubis** forms the anterior part of the os innominatum, and, with the bone of the opposite side, forms the front boundary of the true pelvic cavity. It is divisible into a body, an ascending and a descending ramus.

The **body** is somewhat quadrilateral in shape, and presents for examination two surfaces and three borders. The *anterior surface* is rough, directed forwards and outwards, and serves for the attachment of various muscles. To the upper and inner angle, immediately below the crest, is attached the Adductor longus; lower down, from without inwards, are attached the Obturator externus, the Adductor brevis, and the upper part of the Gracilis. The *posterior surface*, convex from above downwards, concave from side to side, is smooth, and forms part of the anterior wall of the pelvis. It gives attachment to the Levator ani, Obturator internus, a few muscular fibres prolonged from the bladder, and the pubo-prostatic ligaments. The *upper border* presents for examination a prominent tubercle, which projects forwards and is called the *spine*; to it is attached the outer pillar of the external abdominal ring and Poupart's ligament. Passing outwards from this is a prominent ridge, forming part of the *ilio-pectineal line* which, running outwards, marks the brim of the true pelvis: to it is attached a portion of the conjoined tendon of the Internal oblique and Transversalis muscles, Gimbernat's ligament and the triangular ligament of the abdomen. Internal to the spine of the os pubis is the *crest*, which extends from this process to the inner extremity of the bone. It affords attachment, anteriorly, to the conjoined tendon of the Internal oblique and Transversalis; and posteriorly, to the Rectus and Pyramidalis muscles. The point of junction of the crest with the inner border of the bone is called the *angle*; to it, as well as to the symphysis, is attached the internal pillar of the external abdominal ring. The *internal border* is the symphysis; it is oval, covered by eight or nine transverse ridges, or a series of nipple-like processes arranged in rows, separated by grooves; they serve for the attachment of a thin layer of cartilage, placed between it and the central fibro-cartilage. The *outer border* presents a sharp margin, which forms part of the circumference of the obturator foramen and affords attachment to the obturator membrane.

The **ascending** or **superior ramus** extends from the body to the point of junction of the os pubis with the ilium, and forms the upper part of the circumference of the obturator foramen. It presents for examination a superior, inferior, and posterior surface, and an outer extremity. The *superior surface* presents a continuation of the ilio-pectineal line, already mentioned as commencing on the body of the bone. In front of this ridge, the surface of bone is triangular in form, wider externally than internally, smooth, and affords attachment to the Pectineus muscle. The surface is bounded externally by a rough eminence, the *ilio-pectineal*, which serves to indicate the point of junction of the ilium and os pubis, and gives attachment to the Psoas parvus, when this muscle is present. The



triangular surface for the Pectineus muscle is bounded below by a prominent ridge, the *obturator crest*, which extends from the margin of the acetabulum, at the anterior extremity of the cotyloid notch, to the spine of the os pubis. The *inferior surface* forms the upper boundary of the obturator foramen, and presents, externally, a broad and deep, oblique groove, for the passage of the obturator vessels and nerve; and internally, a sharp margin which forms part of the circumference of the obturator foramen, and to which the obturator membrane is attached. The *posterior surface* forms part of the anterior boundary of the true pelvis. It is smooth, convex from above downwards, and affords attachment to the upper fibres of the Obturator internus. The *outer extremity*, the thickest part of the ramus, forms one-fifth of the cavity of the acetabulum.

The **descending** or **inferior ramus** of the os pubis is thin and flattened. It passes outwards and downwards, becoming narrower as it descends and joins with the ramus of the ischium. Its *anterior surface* is rough, for the attachment of muscles—the Gracilis along its inner border; a portion of the Obturator externus where it enters into the formation of the foramen of that name; and between these two muscles, the Adductores brevis and magnus from within outwards. The *posterior surface* is smooth, and gives attachment to the Obturator internus, and, close to the inner margin, to the Compressor urethræ. The *inner border* is thick, rough, and everted, especially in females. It presents two ridges, separated by an intervening space. The ridges extend downwards, and are continuous with similar ridges on the ascending ramus of the ischium; to the external one is attached the deep layer of the superficial perineal fascia, and to the internal one the anterior layer of the triangular ligament of the perinæum. The *outer border* is thin and sharp, forms part of the circumference of the obturator foramen, and gives attachment to the obturator membrane.

The **cotyloid cavity**, or **acetabulum**, is a deep, cup-shaped, hemispherical depression, directed downwards, outwards, and forwards; formed internally by the os pubis, above by the ilium, behind and below by the ischium; a little less than two-fifths being formed by the ilium, a little more than two-fifths by the ischium, and the remaining fifth by the pubic bone. It is bounded by a prominent, uneven rim, which is thick and strong above, and serves for the attachment of a fibro-cartilaginous structure which contracts its orifice, and deepens the surface for articulation. It presents, on its inner side, a deep notch, the *cotyloid notch*, which is continuous with a circular depression, the *fossa acetabuli*, at the bottom of the cavity: this depression is perforated by numerous apertures, lodges a mass of fat, and its margins, as well as those of the notch, serve for the attachment of the ligamentum teres. The notch is converted, in the natural state, into a foramen by a dense ligamentous band which passes across it. Through this foramen the nutrient vessels and nerves enter the joint.

The **obturator** or **thyroid foramen** is a large aperture, situated between the ischium and os pubis. In the male it is large, of an oval form, its longest diameter being obliquely from above downwards; in the female it is smaller, and more triangular. It is bounded by a thin, uneven margin, to which a strong membrane is attached; and presents, at its upper and outer part, a deep groove, which runs from the pelvis obliquely forwards, inwards, and downwards. This groove is converted into a foramen by the obturator membrane, and transmits the obturator vessels and nerve.

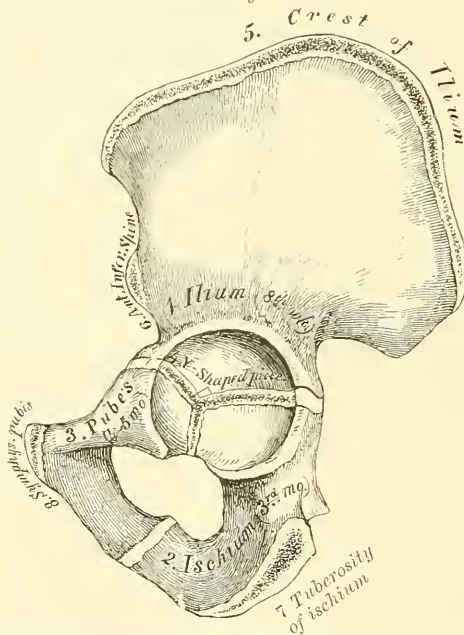
**Structure.**—This bone consists of much cancellous tissue, especially where it is thick, enclosed between two layers of dense, compact tissue. In the thinner parts of the bone, as at the bottom of the acetabulum and centre of the iliac fossa, it is usually semi-transparent, and composed entirely of compact tissue.

**Development** (fig. 233).—By *eight* centres: three primary—one for the ilium, one for the ischium, and one for the os pubis; and *five* secondary—one for the crest of the ilium, one for the anterior inferior spinous process (said to occur more frequently in the male than the female), one for the tuberosity of the ischium, one for the symphysis pubis (more frequent in the female than the

male), and one for the Y-shaped piece at the bottom of the acetabulum. These various centres appear in the following order: First, in the ilium, at the lower part of the bone, immediately above the sciatic notch, at about the eighth or ninth week; secondly, in the body of the ischium, at about the third month of fetal life; thirdly, in the body of the os pubis, between the fourth and fifth months. At birth, the three primary centres are quite separate, the crest, the bottom of the acetabulum, and the rami of the ischium and pubes being still cartilaginous. At about the seventh or eighth year, the rami of the os pubis and ischium are almost completely ossified. About the thirteenth or fourteenth year, the three divisions of the bone have extended their growth into the bottom of the acetabulum, being separated from each other by a Y-shaped portion of cartilage, which now presents traces of ossification, often by two or more centres. The ilium and ischium then become joined, and lastly the os pubis, through the intervention of this Y-shaped portion. At about the age of puberty, ossification

FIG. 233.—Plan of the development of the os innominatum.

By eight centres { Three primary (Ilium, Ischium, and Os Pubis)  
Five secondary



The three primary centres unite through Y-shaped piece about puberty.  
Epiphyses appear about puberty, and unite about 25th year

takes place in each of the remaining portions, and they become joined to the rest of the bone about the twenty-fifth year.

**Articulations.**—With its fellow of the opposite side, the sacrum and femur.

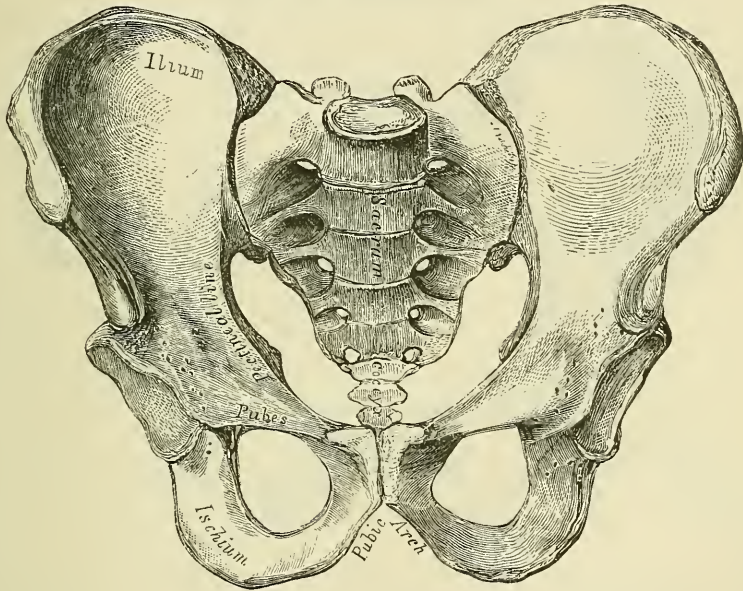
**Attachment of Muscles.**—To the *ilium*, sixteen. To the outer lip of the crest, the Tensor vaginae femoris, Obliquus externus abdominis, and Latissimus dorsi; to the internal lip, the Iliacus, Transversalis, Quadratus lumborum, and Erector spinae; to the interspace between the lips, the Obliquus internus. To the outer surface of the ilium, the Gluteus maximus, Gluteus medius, Gluteus minimus, reflected tendon of the Rectus; to the upper part of the great sacro-sciatic notch a portion of the Piriformis; to the internal surface, the Iliacus; to that portion of the internal surface below the linea ilio-pectinea, the Obturator internus; and the Multifidus spinae to the internal surface of the posterior superior spine; to the anterior border, the Sartorius and straight tendon of the Rectus. To the *ischium*, thirteen. To the outer surface of the ramus, the Obturator externus and Adductor magnus; to the internal surface, the Obturator internus and

Erector penis. To the spine, the Gemellus superior, Levator ani, and Coccygeus. To the tuberosity, the Biceps, Semi-tendinosus, Semi-membranosus, Quadratus femoris, Adductor magnus, Gemellus inferior, Transversus perinæi, Erector penis. To the *os pubis*, sixteen: Obliquus externus, Obliquus internus, Transversalis, Rectus, Pyramidalis, Psoas parvus, Pectineus, Adductor magnus, Adductor longus, Adductor brevis, Gracilis, Obturator externus and internus, Levator ani, Compressor urethræ, and occasionally a few fibres of the Accelerator urinæ.

THE PELVIS (figs. 234, 235)

The **Pelvis**, so called from its resemblance to a basin (*L. pelvis*), is stronger and more massively constructed than either the cranial or thoracic cavity; it is a bony ring, interposed between the lower end of the spine, which it supports, and the lower extremities, upon which it rests. It is composed of four bones: the two ossa innominata, which bound it on either side and in front; and the sacrum and coceyx, which complete it behind.

FIG. 234.—Male pelvis (adult).



The pelvis is divided by a plane passing through the prominence of the sacrum, the linea ilio-pectinea, and the upper margin of the symphysis pubis, into the false and true pelvis.

The **false pelvis** is all that expanded portion of the pelvic cavity which is situated above this plane. It is bounded on each side by the ossa ili; in front it is incomplete, presenting a wide interval between the spinous processes of the ilia on either side, which is filled up in the recent state by the parietes of the abdomen; behind, in the middle line, is a deep notch. This broad, shallow cavity is fitted to support the intestines, and to transmit part of their weight to the anterior wall of the abdomen, and is, in fact, really a portion of the abdominal cavity. The term false pelvis is incorrect, and this space ought more properly to be regarded as part of the hypogastric region of the abdomen.

The **true pelvis** is all that part of the pelvic cavity which is situated beneath the plane. It is smaller than the false pelvis, but its walls are more perfect. For convenience of description, it is divided into a superior circumference or inlet, an inferior circumference or outlet, and a cavity.

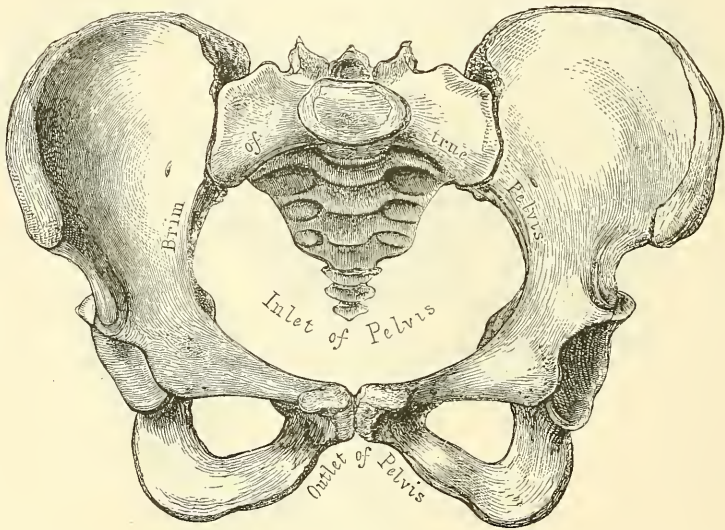
The **superior circumference** forms the margin or brim of the pelvis, the



included space being called the *inlet*. It is formed by the linea ilio-pectinea, completed in front by the crests of the pubic bones, and behind by the anterior margin of the base of the sacrum and sacro-vertebral angle. The *inlet* of the pelvis is somewhat heart-shaped, obtusely pointed in front, diverging on either side, and encroached upon behind by the projection forwards of the promontory of the sacrum. It has three principal diameters: antero-posterior (sacro-pubic), transverse, and oblique. The antero-posterior extends from the sacro-vertebral angle to the symphysis pubis; its average measurement is four inches in the male, four and three-quarters in the female. The transverse extends across the greatest width of the inlet, from the middle of the brim on one side to the same point on the opposite; its average measurement is four and a half in the male, five and a quarter in the female. The oblique extends from the margin of the pelvis, corresponding to the ilio-pectineal eminence on one side, to the sacro-iliac symphysis on the opposite side; its average measurement is four and a quarter in the male, and five in the female.

The *cavity* of the true pelvis is bounded in front by the symphysis pubis; behind, by the concavity of the sacrum and coccyx, which, curving forwards

FIG. 235.—Female pelvis (adult).



above and below, contracts the inlet and outlet of the canal; and laterally it is bounded by a broad, smooth, quadrangular surface of bone, corresponding to the inner surface of the body of the ischium and that part of the ilium which is below the ilio-pectineal line. The cavity is shallow in front, measuring at the symphysis an inch and a half in depth, three inches and a half in the middle, and four inches and a half posteriorly. From this description, it will be seen that the cavity of the pelvis is a short, curved canal, considerably deeper on its posterior than on its anterior wall, and broader in the middle than at either extremity, from the projection forwards of the sacro-coccygeal column above and below. This cavity contains, in the recent subject, the rectum, bladder, and part of the organs of generation. The rectum is placed at the back of the pelvis, and corresponds to the curve of the sacro-coccygeal column; the bladder in front, behind the symphysis pubis. In the female, the uterus and vagina occupy the interval between these parts.

The *lower circumference* of the pelvis is very irregular, and forms what is called the *outlet*. It is bounded by three prominent eminences: one posterior, formed by the point of the coccyx; and one on each side, the tuberosities of the ischia. These eminences are separated by three notches: one in front, the *pubic arch*, formed by the convergence of the rami of the ischia and pubic bones on

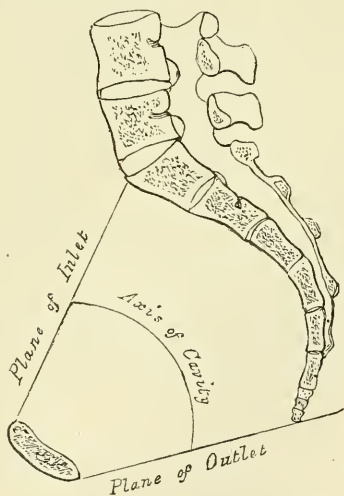
each side. The other notches, one on each side, are formed by the sacrum and coccyx behind, the ischium in front, and the ilium above: they are called the *sacro-sciatic notches*; in the natural state they are converted into foramina by the lesser and greater sacro-sciatic ligaments. In the recent state, when the ligaments are *in situ*, the outlet of the pelvis is lozenge-shaped, bounded, in front, by the subpubic ligament and the rami of the ossa pubes and ischia; on each side, by the tuberosities of the ischia; and behind, by the great sacro-sciatic ligaments and the tip of the coccyx.

The diameters of the outlet of the pelvis are two, antero-posterior and transverse. The *antero-posterior* extends from the tip of the coccyx to the lower part of the symphysis pubis; its average measurement is three and a quarter inches in the male and five in the female. The antero-posterior diameter varies with the length of the coccyx, and is capable of increase or diminution, on account of the mobility of that bone. The *transverse* extends from the posterior part of one ischiatic tuberosity to the same point on the opposite side; the average measurement is three and a half inches in the male and four and three-quarters in the female.\*

**Position of the Pelvis.**—In the erect posture, the pelvis is placed obliquely with regard to the trunk of the body: the bony ring, which separates the true from the false pelvis, and which forms the essential part of the pelvis, is placed so as to form an angle of about 60° to 65° with the ground on which we stand. The pelvic surface of the symphysis pubis looks upwards and backwards, the concavity of the sacrum and coccyx downwards and forwards; the base of the sacrum in well-formed female bodies being nearly four inches above the upper border of the symphysis pubis, and the apex of the coccyx a little more than half an inch above its lower border. The obliquity is much greater in the fetus, and at an early period of life, than in the adult. In consequence of this obliquity of the pelvis, the line of gravity of the head, which passes through the middle of the odontoid process of the axis and through the points of junction of the curves of the vertebral column to the sacro-vertebral angle, descends towards the front of the cavity, so that it bisects a line drawn transversely through the middle of the heads of the thigh-bones. And thus the centre of gravity of the head is placed immediately over the heads of the thigh-bones on which the trunk is supported.

**Axes of the Pelvis** (fig. 236).—The plane of the inlet of the true pelvis will be represented by a line drawn from the base of the sacrum to the upper margin of the symphysis pubis. A line carried at right angles with this at its middle, would correspond at one extremity with the umbilicus, and at the other with the middle of the coccyx: the axis of the inlet is therefore directed downwards and

FIG. 236.—Vertical section of the pelvis, with lines indicating the axes of the pelvis.



\* The measurements of the pelvis given above are, I believe, fairly accurate, but different measurements are given by various authors, no doubt due in a great measure to differences in the physique and stature of the population from whom the measurements have been taken. The accompanying chart has been formulated to show the measurements of the pelvis, which are adopted by many obstetricians.—ED.

	A.P.	Ob.	Tr.
Inlet . . . . .	4	4½	5
Cavity . . . . .	4½	4½	4½
Outlet . . . . .	5	4½	4

backwards. The axis of the outlet, produced upwards, would touch the base of the sacrum, and is therefore directed downwards and forwards. The axis of the cavity is curved like the cavity itself: this curve corresponds to the concavity of the sacrum and coccyx, the extremities being indicated by the central points of the inlet and outlet. A knowledge of the direction of these axes serves to explain the course of the foetus in its passage through the pelvis during parturition. It is also important to the surgeon, as indicating the direction of the force required in the removal of calculi from the bladder, and as determining the direction in which instruments should be used in operations upon the pelvic viscera.

**Differences between the Male and Female Pelvis.**—The *female* pelvis, looked at as a whole, is distinguished from the *male* by the bones being more delicate, by its width being greater and its depth smaller. The whole pelvis is less massive, and its bones are lighter and more slender, and its muscular impressions are slightly marked. The iliac fossæ are broad and expanded, and the anterior iliac spines widely separated; hence the greater prominence of the hips. The *inlet* in the female is larger than in the male; it is more nearly circular, and the sacro-vertebral angle projects less forwards. The *cavity* is shallower and wider; the sacrum is shorter and wider, and its lower half forms a greater angle with its upper; the obturator foramina are triangular and smaller in size than in the male. The *outlet* is larger and the coccyx more movable. The spines of the ischia project less inwards. The tuberosities of the ischia and the acetabula are wider apart. The *pubic arch* is wider and more rounded than in the male, where it is an angle rather than an arch; its pillars are somewhat excavated, and sloped from within outwards, so that their inner surfaces look forwards. In consequence of this the width of the fore part of the pelvic outlet is much increased and the passage of the foetal head facilitated.

The size of the pelvis varies, not only in the two sexes, but also in different members of the same sex. This does not appear to be influenced in any way by the height of the individual. Women of short stature, as a rule, have broad pelves. Occasionally the pelvis is equally contracted in all its dimensions, so much so that all its diameters measure an inch less than the average, and this even in women of average height and otherwise well formed. The principal divergences, however, are found at the inlet, and affect the relation of the antero-posterior to the transverse diameter. Thus we may have a pelvis the inlet of which is elliptical either in a transverse or antero-posterior direction; the transverse diameter in the former, and the antero-posterior in the latter, greatly exceeding the other diameters. Again, the inlet of the pelvis in some instances is seen to be almost circular.

The same differences are found in various races. European women are said to have the most roomy pelves. That of the negress is smaller, circular in shape, and with a narrow pubic arch. The Hottentots and Bushwomen possess the smallest pelves.

In the *foetus*, and for several years after birth, the pelvis is small in proportion to that of the adult. The cavity is deep, and the projection of the sacro-vertebral angle less marked. The antero-posterior and transverse diameters are nearly equal. *About puberty*, the pelvis in both sexes presents the general characters of the adult male pelvis; but *after puberty* it acquires its proper sexual characters.

**Surface Form.**—The pelvic bones are so thickly covered with muscles that it is only at certain points that they approach the surface and can be felt through the skin. In front, the anterior superior spinous process is easily to be recognised; a portion of it is subcutaneous, and in thin subjects may be seen to stand out as a prominence at the outer extremity of the fold of the groin. In fat subjects its position is marked by an oblique depression amongst the surrounding fat, at the bottom of which the bony process may be felt. Proceeding upwards and outwards from this process, the crest of the ilium may be traced throughout its whole length, sinuously curved. It is represented, in muscular subjects, on the surface, by a groove or furrow, the *iliac furrow*, caused by the projection of fleshy fibres of the External oblique muscle of the abdomen. It terminates behind in



the posterior superior spinous process, the position of which is indicated by a slight depression on a level with and on each side of the spinous process of the second sacral vertebra. Between the two posterior superior spinous processes, but at a lower level, is to be felt the spinous process of the third sacral vertebra (see page 140). Another part of the bony pelvis which is easily accessible to the touch is the tuberosity of the ischium, situated beneath the gluteal fold, and, when the hip is flexed, easily to be felt, as it is then to a great extent uncovered by muscle. Finally, the spine of the os pubis can always be readily felt, and constitutes an important surgical guide, especially in connection with the subject of hernia. It is nearly in the same horizontal line with the upper edge of the great trochanter. In thin subjects it is very apparent, but in the obese it is obscured by the pubic fat. It can, however, be detected by following up the tendon of origin of the Adductor longus muscle.

*Surgical Anatomy.*—There is arrest of development in the bones of the pelvis in cases of extroversion of the bladder; the anterior part of the pelvic girdle being deficient, the bodies of the pubic bones imperfectly developed, and the symphysis absent. ‘The pubic bones are separated to the extent of from two to four inches, the superior rami shortened and directed forwards, and the obturator foramen diminished in size, narrowed, and turned outwards. The iliac bones are straightened out more than normal. The sacrum is very peculiar. The lateral curve, instead of being concave, is flattened out or even convex, with the ilio-sacral facets turned more outward than normal, while the vertical curve is straightened.’\*

Fractures of the pelvis are divided into fractures of the false pelvis and of the true pelvis. Fractures of the false pelvis vary in extent; a small portion of the crest may be broken, or one of the spinous processes may be torn off, and this may be the result of muscular action; or the bone may be extensively comminuted. This latter accident is the result of some crushing violence, and may be complicated with fracture of the true pelvis. These cases may be accompanied by injury to the intestine as it lies in the hollow of the bone, or to the iliac vessels as they course along the margin of the true pelvis. Fractures of the true pelvis generally occur through the ascending ramus of the os pubis and the ascending ramus of the ischium, as this is the weakest part of the bony ring, and may be caused either by crushing violence applied in an antero-posterior direction, when the fracture occurs from direct force, or by compression laterally, when the acetabula are pressed together and the bone gives way in the same place from indirect violence. Occasionally the fracture may be double, occurring on both sides of the body. It is in these cases that injury to the contained viscera is liable to take place, the urethra, the bladder, the rectum, the vagina in the female, the small intestines, and even the uterus, have all been lacerated by a displaced fragment. Fractures of the acetabulum are occasionally met with: either a portion of the rim may be broken off, or a fracture may take place through the bottom of the cavity and the head of the femur driven inwards and project into the pelvic cavity. Separation of the Y-shaped cartilage at the bottom of the acetabulum may also occur in the young subject, separating the bone into its three anatomical portions.

The sacrum is occasionally, but rarely, broken by direct violence—i.e. blows, kicks, or falls on the part. The lesion may be complicated with injury to the nerves of the sacral plexus, leading to paralysis and loss of sensation in the lower extremity, or to incontinence of feces from paralysis of the sphincter ani.

The pelvic bones often undergo important deformity in rickets, the effect of which in the adult woman may interfere seriously with child-bearing. In consequence of the yielding nature of the bones, the acetabula become approximated, the symphysis is pushed forward, and the antero-posterior diameter lessened. In osteo-malacia also great deformity may occur, the pelvis becoming beak-shaped. The promontory of the sacrum is pushed forward by the weight of the body, and the sides of the pelvis are approximated by the pressure of the two thigh-bones: this gives to the pelvis the peculiar deformity which is characteristic of this disease.

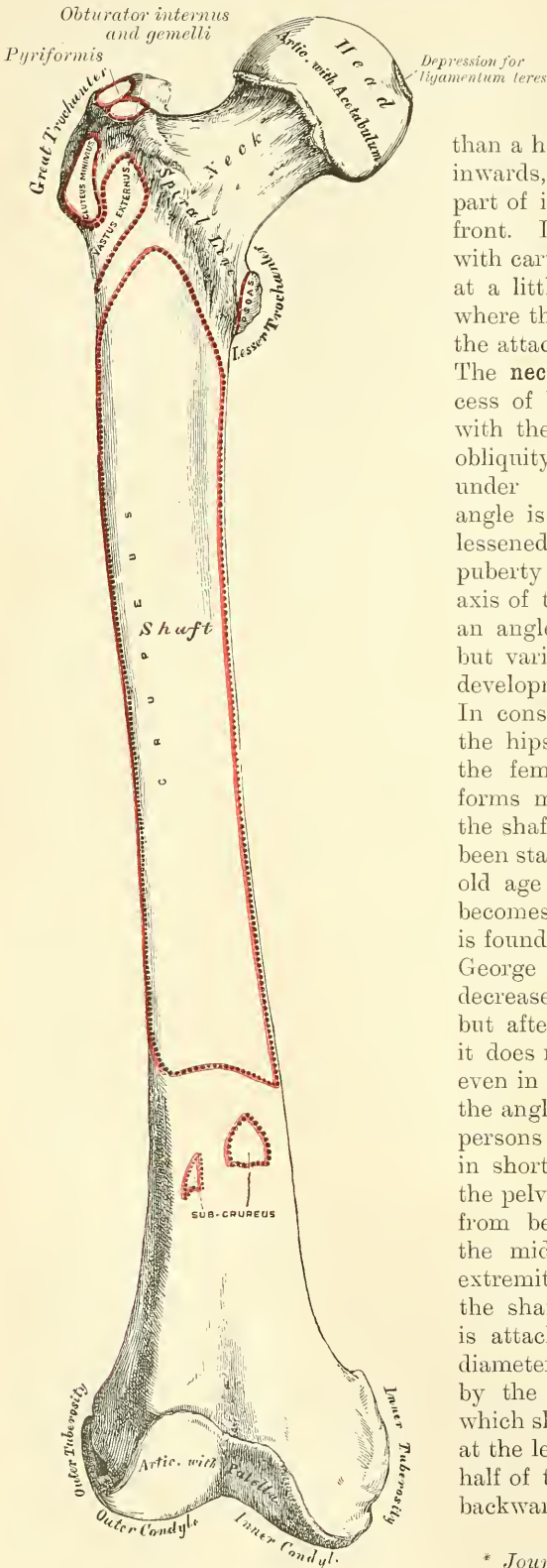
#### THE FEMUR OR THIGH-BONE

The **Femur** (femur, *the thigh*) is the longest,† largest, and strongest bone in the skeleton, and almost perfectly cylindrical in the greater part of its extent. In the erect posture it is not vertical, being separated from its fellow above by a considerable interval, which corresponds to the entire breadth of the pelvis, but inclining gradually downwards and inwards, so as to approach its fellow towards its lower part, for the purpose of bringing the knee-joint near the line of gravity of the body. The degree of this inclination varies in different persons, and is greater in the female than the male, on account of the greater breadth of the pelvis. The femur, like other long bones, is divisible into a shaft and two extremities.

\* Wood. *Heath's Dictionary of Practical Surgery*, i. 426.

† In a man six feet high, it measures eighteen inches—one-fourth of the whole body.

FIG. 237.—Right femur. Anterior surface.



The **Upper Extremity** presents for examination a head, a neck, and the great and lesser trochanters.

The **head**, which is globular, and forms rather more than a hemisphere, is directed upwards, inwards, and a little forwards, the greater part of its convexity being above and in front. Its surface is smooth, coated with cartilage in the recent state, except at a little behind and below its centre, where there is an ovoid depression, for the attachment of the ligamentum teres. The **neck** is a flattened pyramidal process of bone, which connects the head with the shaft. It varies in length and obliquity at various periods of life, and under different circumstances. The angle is widest in infancy, and becomes lessened during growth, so that at puberty it forms a gentle curve from the axis of the shaft. In the adult it forms an angle of about  $130^\circ$  with the shaft, but varies in inverse proportion to the development of the pelvis and the stature. In consequence of the prominence of the hips and widening of the pelvis in the female, the neck of the thigh-bone forms more nearly a right angle with the shaft than it does in man. It has been stated that the angle diminishes in old age and the direction of the neck becomes horizontal, but this statement is founded on insufficient evidence! Sir George Humphry states that the angle decreases during the period of growth, but after full growth has been attained it does not usually undergo any change, even in old age. He further states that the angle varies considerably in different persons of the same age. It is smaller in short than in long bones, and when the pelvis is wide.\* The neck is flattened from before backwards, contracted in the middle, and broader at its outer extremity, where it is connected with the shaft, than at its summit, where it is attached to the head. The vertical diameter of the outer half is increased by the thickening of the lower edge, which slopes downwards to join the shaft at the lesser trochanter, so that the outer half of the neck is flattened from before backwards, and its vertical diameter

\* *Journal of Anatomy and Physiology.*



measures one third more than the antero-posterior. The inner half is smaller, and of a more circular shape. The *anterior surface* of the neck is perforated by numerous vascular foramina. The *posterior surface* is smooth, and is broader and more concave than the anterior; it gives attachment to the posterior part of the capsular ligament of the hip-joint, about half an inch above the posterior intertrochanteric line. The *superior border* is short and thick, and terminates externally at the great trochanter; its surface is perforated by large foramina. The *inferior border*, long and narrow, curves a little backwards, to terminate at the lesser trochanter.

The **Trochanters** (*τροχάω*, to run or roll) are prominent processes of bone which afford leverage to the muscles which rotate the thigh on its axis. They are two in number, the great and the lesser.

The **Great Trochanter** is a large, irregular, quadrilateral eminence, situated at the outer side of the neck, at its junction with the upper part of the shaft. It is directed a little outwards and backwards, and, in the adult, is about three-quarters of an inch lower than the head. It presents for examination two surfaces and four borders. The *external surface*, quadrilateral in form, is broad, rough, convex, and marked by a prominent diagonal line, which extends from the posterior superior to the anterior inferior angle; this line serves for the attachment of the tendon of the Gluteus medius. Above the line is a triangular surface, sometimes rough for part of the tendon of the same muscle, sometimes smooth for the interposition of a bursa between that tendon and the bone. Below and behind the diagonal line is a smooth, triangular surface, over which the tendon of the Gluteus maximus muscle plays, a bursa being interposed. The *internal surface* is of much less extent than the external, and presents at its base a deep depression, the *digital or trochanteric fossa*, for the attachment of the tendon of the Obturator externus muscle, and in front of this an impression for the attachment of the Obturator internus and Gemelli. The *superior border* is free; it is thick and irregular, and marked near the centre by an impression for the attachment of the Pyliformis. The *inferior border* corresponds to the point of junction of the base of the trochanter with the outer surface of the shaft; it is marked by a rough, prominent, slightly curved ridge, which gives attachment to the upper part of the Vastus externus muscle. The *anterior border* is prominent, somewhat irregular, as well as the surface of bone immediately below it; it affords attachment at its outer part to the Gluteus minimus. The *posterior border* is very prominent, and appears as a free, rounded edge, which forms the back part of the digital fossa.

The **Lesser Trochanter** is a conical eminence, which varies in size in different subjects; it projects from the lower and back part of the base of the neck. Its base is triangular, and connected with the adjacent parts of the bone by three well-marked borders: two of these are above—the *internal* continuous with the lower border of the neck, the *external* with the posterior intertrochanteric line—while the *inferior border* is continuous with the middle division of the *linea aspera*. Its summit, which is directed inwards and backwards, is rough, and gives insertion to the tendon of the Psoas magnus. The Iliacus is inserted into the shaft below the lesser trochanter, between the Vastus internus in front and the Pectineus behind.

A well-marked prominence, of variable size, which projects from the upper and front part of the neck, at its junction with the great trochanter, is called the *tubercle of the femur*; it is the point of meeting of five muscles: the Gluteus minimus externally, the Vastus externus below, and the tendon of the Obturator internus and Gemelli above. Running obliquely downwards and inwards from the tubercle is the *spiral line* of the femur, or *anterior intertrochanteric line*; it winds round the inner side of the shaft, below the lesser trochanter, and terminates in the *linea aspera*, about two inches below this eminence. Its upper half is rough, and affords attachment to the capsular ligament of the hip-joint; its lower half is less prominent, and gives attachment to the upper part of the Vastus internus. Running obliquely downwards and inwards from the summit





space, the *popliteal surface*, upon which rests the popliteal artery. Of these two ridges, the outer one is the more prominent, and descends to the summit of the outer condyle. The inner one is less marked, especially at its upper part, where it is crossed by the femoral artery. It terminates, below, at the summit of the internal condyle, in a small tubercle, the *Adductor tubercle*, which affords attachment to the tendon of the Adductor magnus.

To the inner lip of the *linea aspera* and its inner prolongation above and below is attached the Vastus internus; and to the outer lip and its outer prolongation above is attached the Vastus externus. The Adductor magnus is attached to the *linea aspera*, to its outer prolongation above, and its inner prolongation below. Between the Vastus externus and the Adductor magnus are attached two muscles—viz. the Gluteus maximus above and the short head of the Biceps below. Between the Adductor magnus and the Vastus internus four muscles are attached: the Iliacus and Pectineus above (the latter to the middle of the upper divisions); below these, the Adductor brevis and Adductor longus. The *linea aspera* is perforated a little below its centre by the nutrient canal, which is directed obliquely upwards.

The two *lateral borders* of the femur are only slightly marked, the outer one extending from the anterior inferior angle of the great trochanter to the anterior extremity of the external condyle; the inner one from the spiral line, at a point opposite the trochanter minor, to the anterior extremity of the internal condyle. The internal border marks the limit of attachment of the Crureus muscle internally.

The **anterior surface** includes that portion of the shaft which is situated between the two lateral borders. It is smooth, convex, broader above and below than in the centre, slightly twisted, so that its upper part is directed forwards and a little outwards, its lower part forwards and a little inwards. To the upper three-fourths of this surface the Crureus is attached; the lower fourth is separated from the muscle by the intervention of the synovial membrane of the knee-joint and a bursa, and affords attachment to the Subcrureus to a small extent. The *external surface* includes the portion of bone between the external border and the outer lip of the *linea aspera*; it is continuous above with the outer surface of the great trochanter, below with the outer surface of the external condyle: to its upper three-fourths is attached the outer portion of the Crureus muscle. The *internal surface* includes the portion of bone between the internal border and the inner lip of the *linea aspera*; it is continuous above with the lower border of the neck, below with the inner side of the internal condyle: it is covered by the Vastus internus muscle.

The **Lower Extremity**, larger than the upper, is of a cuboid form, flattened from before backwards, and divided into two large eminences, the *condyles* (*κόνδυλος*, a *knuckle*), by an interval which presents a smooth depression in front called the *trochlea*, and a notch of considerable size behind—the *intercondyloid notch*. The *external condyle* is the more prominent anteriorly, and is the broader both in the antero-posterior and transverse diameters. The *internal condyle* is the narrower, longer, and more prominent inferiorly. This difference in the length of the two condyles is only observed when the bone is perpendicular, and depends upon the obliquity of the thigh-bones, in consequence of their separation above at the articulation with the pelvis. If the femur is held obliquely, the surfaces of the two condyles will be seen to be nearly horizontal. The two condyles are directly continuous in front, and form a smooth trochlear surface, which articulates with the patella. This surface presents a median groove, which extends downwards and backwards to the intercondyloid notch; and two lateral convexities, of which the external is the broader, more prominent, and prolonged farther upwards upon the front of the outer condyle. The external border of this articular surface is also more prominent, and ascends higher than the internal one. The intercondyloid notch lodges the crucial ligaments; it is bounded laterally by the opposed surfaces of the two condyles, and in front by the lower end of the shaft.



**Outer Condyle.**—The *outer surface* of the external condyle presents, a little behind its centre, an eminence, the *outer tuberosity*; it is less prominent than the inner tuberosity, and gives attachment to the external lateral ligaments of the knee. Immediately beneath it is a groove which commences at a depression a little behind the centre of the lower border of this surface: the front part of this depression gives origin to the Popliteus muscle, the tendon of which is lodged in the groove during flexion of the knee. The groove is smooth, covered with cartilage in the recent state, and runs upwards and backwards to the posterior extremity of the condyle. The *inner surface* of the outer condyle forms one of the lateral boundaries of the intercondyloid notch, and gives attachment, by its posterior part, to the anterior crucial ligament. The *inferior surface* is convex, smooth, and broader than that of the internal condyle. The posterior extremity is convex and smooth: just above the articular surface is a depression for the tendon of the outer head of the Gastrocnemius, above which is the origin of the Plantaris.

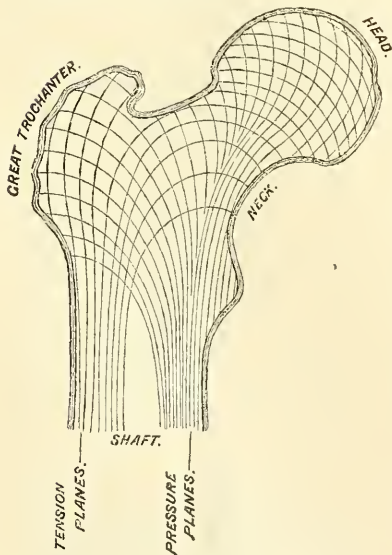
**Inner Condyle.**—The *inner surface* of the inner condyle presents a convex eminence, the *inner tuberosity*, rough, for the attachment of the internal lateral ligament. The *outer side* of the inner condyle forms one of the lateral boundaries of the intercondyloid notch, and gives attachment, by its anterior part, to the posterior crucial ligament. Its *inferior* or *articular surface* is convex, and presents a less extensive surface than the external condyle. Just above the articular surface of the condyle, behind, is a depression for the tendon of origin of the inner head of the Gastrocnemius.

**Structure.**—The shaft of the femur is a cylinder of compact tissue, hollowed by a large medullary canal. The cylinder is of great thickness and density in the middle third of the shaft, where the bone is narrowest and the medullary canal well formed; but above and below this the cylinder gradually becomes thinner, owing to a separation of the layers of the bone into cancelli, which project into the medullary canal and finally obliterate it, so that the upper and lower ends of the shaft, and the articular extremities more especially, consist of cancellated tissue, invested by a thin compact layer.

The arrangement of the cancelli in the ends of the femur is remarkable. In the upper end they are arranged in two sets. One, starting from the top of the head, the upper surface of the neck, and the great trochanter, converge to the inner circumference of the shaft (fig. 239); these are placed in the direction of greatest pressure, and serve to support the vertical weight of the body. The second set are planes of lamellæ intersecting the former nearly at right angles, and are situated in the line of the greatest tension—that is to say, along the lines in which the muscles and ligaments exert their traction. In the head of the bone these planes are arranged in a curved form, in order to strengthen the bone when exposed to pressure in all directions. In the midst of the cancellous tissue of the

neck is a vertical plane of compact bone, the *femoral spur* (*calcar femorale*) which commences at the point where the neck joins the shaft midway between the lesser trochanter and the internal border of the shaft of the bone, and extends in the direction of the digital fossa (fig. 240). This materially strengthens this portion of the bone. Another point in connection with the structure of the neck

FIG. 239.—Diagram showing the arrangement of the cancelli of the neck of the femur.





of the femur requires mention, especially on account of its influence on the production of fracture in this situation. It will be noticed that a considerable portion of the great trochanter lies behind the level of the posterior surface of the neck; and if a section be made through the trochanter at this level, it will be seen that the posterior wall of the neck is prolonged into the trochanter. This prolongation is termed by Bigelow the 'true neck,'\* and forms a thin, dense plate of bone, which passes beneath the posterior intertrochanteric ridge towards the outer surface of the bone.

In the lower end, the cancelli spring on all sides from the inner surface of the cylinder, and descend in a perpendicular direction to the articular surface, the cancelli being strongest and having a more accurately perpendicular course above the condyles. In addition to this, however, horizontal planes of cancellous tissue are to be seen, so that the spongy tissue in this situation presents an appearance of being mapped out into a series of rectangular areas.

FIG. 240.—Calcar femorale.

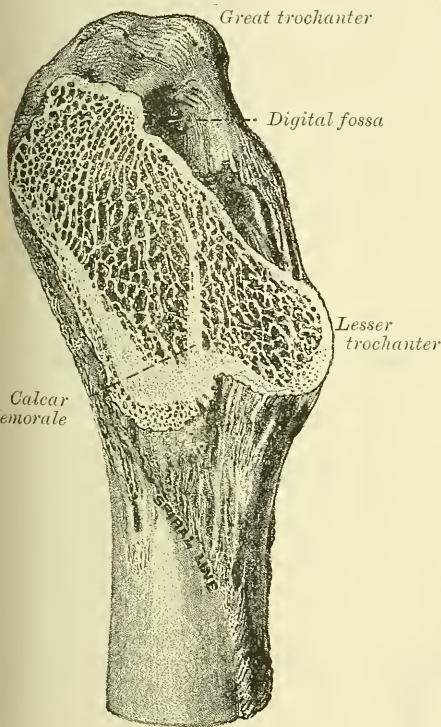
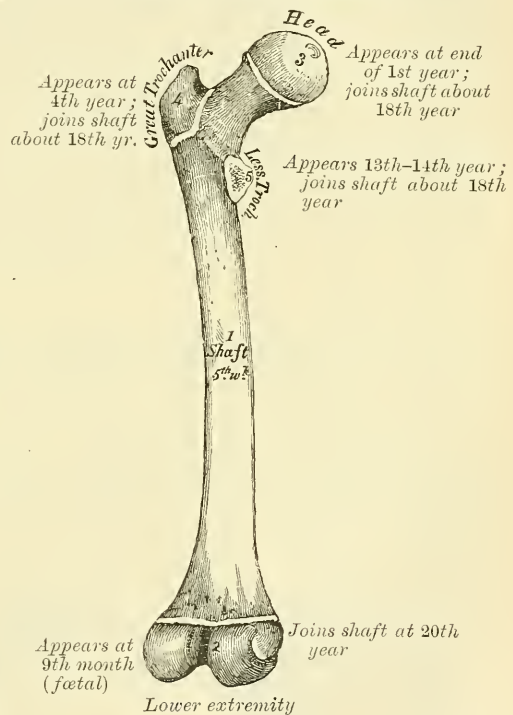


FIG. 241.—Plan of the development of the femur. By five centres.



**Articulations.**—With three bones: the os innominatum, tibia, and patella.

**Development** (fig. 241).—The femur is developed by *five* centres: one for the shaft, one for each extremity, and one for each trochanter. Of all the long bones, except the clavicle, it is the first to show traces of ossification; this commences in the shaft, at about the fifth week of fœtal life, the centres of ossification in the epiphyses appearing in the following order: First, in the lower end of the bone, at the ninth month of fœtal life † (from this the condyles and tuberosities are formed); in the head at the end of the first year after birth; in the great trochanter, during the fourth year; and in the lesser trochanter, between the thirteenth and fourteenth. The order in which the epiphyses are joined to the shaft is the reverse of that of their appearance: their junction does not commence

\* Bigelow on the Hip, p. 121.

† This is the only epiphysis in which ossification begins before birth.

until after puberty, the lesser trochanter being first joined, then the great, then the head, and, lastly, the inferior extremity (the first in which ossification commenced), which is not united until the twentieth year.

**Attachment of Muscles.**—To twenty-three. To the great trochanter: the Gluteus medius, Gluteus minimus, Pyliformis, Obturator internus, Obturator externus, Gemellus superior, Gemellus inferior, and Quadratus femoris. To the lesser trochanter: the Psoas magnus and the Iliacus below it. To the shaft: the Vastus externus, Gluteus maximus, short head of the Biceps, Vastus internus, Adductor magnus, Pectineus, Adductor brevis, Adductor longus, Crureus, and Subcrureus. To the condyles: the Gastrocnemius, Plantaris, and Popliteus.

*Surface Form.*—The femur is covered with muscles, so that in fairly muscular subjects the shaft is not to be detected through its fleshy covering, and the only parts accessible to the touch are the outer surface of the great trochanter and the lower expanded end of the bone. The external surface of the great trochanter is to be felt, especially in certain positions of the limb. Its position is generally indicated by a depression, owing to the thickness of the Gluteus medius and minimus, which project above it. When, however, the thigh is flexed, and especially if crossed over the opposite one, the trochanter produces a blunt eminence on the surface. The upper border is about on a line with the spine of the os pubis, and its exact level is indicated by a line drawn from the anterior superior spinous process of the ilium, over the outer side of the hip, to the most prominent point of the tuberosity of the ischium. This is known as Nélaton's line. The outer and inner condyles of the lower extremity are easily to be felt. The outer one is more subcutaneous than the inner one, and readily felt. The tuberosity on it is comparatively little developed, but can be more or less easily recognised. The inner condyle is more thickly covered, and this gives a general convex outline to this part, especially when the knee is flexed. The tuberosity on it is easily felt, and at the upper part of the condyle the sharp tubercle for the insertion of the tendon of the Adductor magnus can be recognised without difficulty. When the knee is flexed, and the patella situated in the interval between the condyles and the upper end of the tibia, a part of the trochlear surface of the femur can be made out above the patella.

*Surgical Anatomy.*—There are one or two points about the ossification of the femur bearing on practice to which allusion must be made. It has been stated above that the lower end of the femur is the only epiphysis in which ossification has commenced at the time of birth.\* The presence of this ossific centre is, therefore, a proof, in newly-born children found dead, that the child has arrived at the full period of utero-gestation, and is always relied upon in medico-legal investigations. The position of the epiphysial line should be carefully noted. It is on a level with the adductor tubercle, and the epiphysis does not, therefore, form the whole of the cartilage-clad portion of the lower end of the bone. It is essential to bear this point in mind in performing excision of the knee, since growth in length of the femur takes place chiefly from the lower epiphysis, and any interference with the epiphysial cartilage in a young child would involve such ultimate shortening of the limb, from want of growth, as to render it almost useless. Separation of the lower epiphysis may take place up to the age of twenty, at which time it becomes completely joined to the shaft of the bone; but, as a matter of fact, few cases occur after the age of sixteen or seventeen. The upper epiphysis of the femur is of interest principally on account of its being the seat of origin of a large number of cases of tuberculous disease of the hip-joint. The disease commences in the majority of cases in the highly vascular and growing tissue in the neighbourhood of the epiphysis, and from here extends into the joint.

Fractures of the femur are divided, like those of the other long bones, into fractures of the upper end; of the shaft; and of the lower end. The fractures of the upper end may be classified into (1) fracture of the neck; (2) fracture at the junction of the neck with the great trochanter; (3) fracture of the great trochanter; and (4) separation of the epiphysis, either of the head or of the great trochanter. The first of these, fracture of the neck, is usually termed intracapsular fracture, but this is scarcely a correct designation, as, owing to the attachment of the capsular ligament, the fracture may be partly within and partly without the capsule when the fracture occurs at the lower part of the neck. It generally occurs in old people, principally women, and usually from a very slight degree of indirect violence. Probably the main cause of the fracture taking place in old people is in consequence of the degenerative changes which the bone has undergone. Merkel believes that it is mainly due to the absorption of the calcar femorale. These fractures are occasionally impacted. As a rule they unite by fibrous tissue, and frequently no union takes place, and the surfaces of the fracture become smooth and eburnated.

Fractures at the junction of the neck with the great trochanter are usually termed

\* According to some observers the centre for the upper epiphysis of the tibia also appears before birth.



extra-capsular, but this designation is also incorrect, as the fracture is partly within the capsule, owing to its attachment in front to the anterior intertrochanteric line, which is situated below the line of fracture. These fractures are produced by direct violence to the great trochanter, as from a blow or fall laterally on the hip. From the manner in which the accident is caused, the neck of the bone is driven into the trochanter, where it may remain impacted, or the trochanter may be split up into two or more fragments, and thus no fixation takes place.

Fractures of the great trochanter may be either 'oblique fracture through the trochanter major, without implicating the neck of the bone' (Astley Cooper), or separation of the great trochanter. Most of the recorded cases of this latter injury occurred in young persons, and were probably cases of separation of the epiphysis of the great trochanter. Separation of the epiphysis of the head of the femur has been said to occur, but, as far as I know, has never been verified by post-mortem examination.

Fractures of the shaft may occur at any part, but the most usual situation is at or near the centre of the bone. They may be caused by direct or indirect violence or by muscular action. Fractures of the upper third of the shaft are almost always the result of indirect violence, whilst those of the lower third are the result, for the most part, of direct violence. In the middle third fractures occur from both forms of injury in about equal proportions. Fractures of the shaft are generally oblique, but they may be transverse, longitudinal, or spiral. The transverse fracture occurs most frequently in children. The fractures of the lower end of the femur include transverse fracture above the condyles, the most common; and this may be complicated by a vertical fracture between the condyles, constituting the T-shaped fracture. In these cases the popliteal artery is in danger of being wounded. Oblique fracture separating either the internal or external condyle, and a longitudinal incomplete fracture between the condyles, may also take place.

The femur as well as the other bones of the leg are frequently the seat of acute necrosis in young children. This is no doubt due to their greater exposure to injury, which is often the exciting cause of this disease. Tumours not unfrequently are found growing from the femur: the most common forms being sarcoma, which may grow either from the periosteum or from the medullary tissue within the interior of the bone; and exostosis, which is commonly found originating in the neighbourhood of the epiphysial cartilage of the lower end.

THE LEG

The skeleton of the Leg consists of three bones: the Patella, a large, sesamoid bone, placed in front of the knee; the Tibia; and the Fibula.

THE PATELLA (figs. 242, 243)

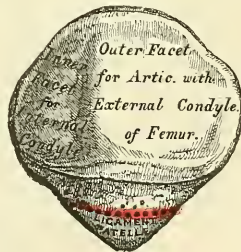The **Patella** (*patella, a small pan*) is a flat, triangular bone, situated at the anterior part of the knee-joint. It is usually regarded as a sesamoid bone, developed in the tendon of the Quadriceps extensor. It resembles these bones (1) in its being developed in a tendon; (2) in its centre of ossification presenting a knotty or tuberculated outline similar to other sesamoid bones; (3) in its structure being composed mainly of dense cancellous tissue, as in the other sesamoid bones. It serves to protect the front of the joint, and increases the leverage of the Quadriceps extensor by making it act at a greater angle. It presents an anterior and posterior surface, three borders, and an apex.

The **anterior surface** is convex, perforated by small apertures, for the passage of nutrient vessels, and marked by numerous rough, longitudinal striæ. This surface is covered, in the recent state, by an expansion from the tendon of the Quadriceps extensor, which is continuous below with the superficial fibres of the ligamentum patella. It is separated from the integument by a bursa. The **posterior surface** presents a smooth, oval-shaped, articular surface, covered with

FIG. 242.—Right patella. Anterior surface.



FIG. 243.—Posterior surface.





cartilage in the recent state, and divided into two facets by a vertical ridge, which descends from the superior border towards the inferior angle of the bone. The ridge corresponds to the groove on the trochlear surface of the femur, and the two facets to the articular surfaces of the two condyles; the outer facet, for articulation with the outer condyle, being the broader and deeper. This character serves to indicate the side to which the bone belongs. Below the articular surface is a rough, convex, non-articular depression, the lower half of which gives attachment to the ligamentum patellæ; the upper half being separated from the head of the tibia by adipose tissue.

The **superior border** is thick, and sloped from behind, downwards and forwards: it gives attachment to that portion of the Quadriceps extensor which is derived from the Rectus and Crureus muscles. The **lateral borders** are thinner, converging below. They give attachment to that portion of the Quadriceps extensor derived from the external and internal Vasti muscles.

The **apex** is pointed, and gives attachment to the ligamentum patellæ.

**Structure.**—It consists of a nearly uniform dense cancellous tissue, covered by a thin compact lamina. The cancelli immediately beneath the anterior surface are arranged parallel with it. In the rest of the bone they radiate from the posterior articular surface towards the other parts of the bone.

**Development.**—By a single centre, which makes its appearance, according to Béclard, about the third year. In two instances, I have seen this bone cartilaginous throughout, at a much later period (six years). More rarely, the bone is developed by two centres, placed side by side. Ossification is completed about the age of puberty.

**Articulations.**—With the two condyles of the femur.

**Attachment of Muscles.**—To four: the Rectus, Crureus, Vastus internus, and Vastus externus. These muscles, joined at their insertion, constitute the Quadriceps extensor cruris.

**Surface Form.**—The external surface of the patella can be seen and felt in front of the knee. In the extended position of the limb the internal border is a little more prominent than the outer, and if the Quadriceps extensor is relaxed, the bone can be moved from side to side and appears to be loosely fixed. If the joint is flexed, the patella recedes into the hollow between the condyles of the femur and the upper end of the tibia, and becomes firmly fixed against the femur.

**Surgical Anatomy.**—The main surgical interest about the patella is in connection with fractures, which are of common occurrence. They may be produced by muscular action, that is to say, by violent contraction of the Quadriceps extensor, while the limb is in a position of semi-flexion, so that the bone is snapped across the condyles; or by direct violence, such as falls on the knee. In the former class of cases the fracture is transverse; in the latter it may be oblique, longitudinal, stellate, or the bone variously comminuted. The principal interest in these cases attaches to their treatment. Owing to the wide separation of the fragments, and the difficulty there is in maintaining them in apposition, union takes place by fibrous tissue, and this may subsequently stretch, producing wide separation of the fragments and permanent lameness. Various plans, including opening the joint and suturing the fragments, have been advocated for overcoming this difficulty.

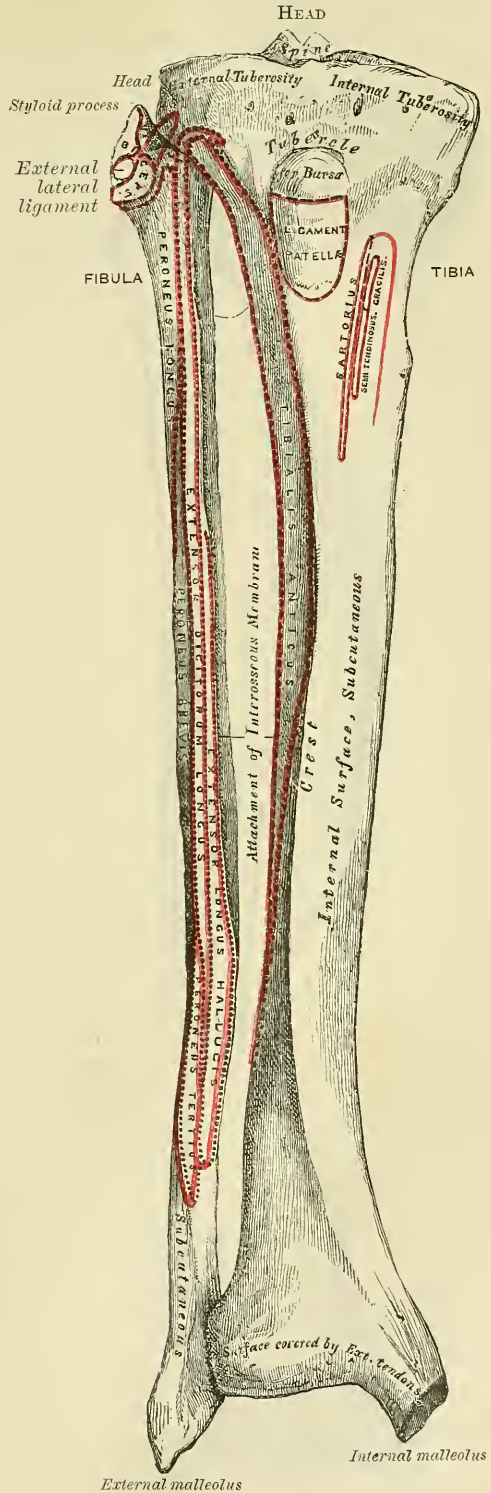
In the larger number of cases of fracture of the patella, the knee-joint is involved, the cartilage which covers its posterior surface being also torn. In some cases of fracture from direct violence, however, this need not necessarily happen, the lesion involving only the superficial part of the bone; and, as Morris has pointed out, it is an anatomical possibility, in complete fracture, if the lesion involve only the lower and non-articular part of the bone, for it to take place without injury to the synovial membrane.

#### THE TIBIA (figs. 244, 245)

The **Tibia** (tibia, *a flute or pipe*) is situated at the front and inner side of the leg, and, excepting the femur, is the longest and largest bone in the skeleton. It is prismoid in form, expanded above, where it enters into the knee-joint, more slightly enlarged below. In the male, its direction is vertical, and parallel with the bone of the opposite side; but in the female it has a slightly oblique direction downwards and outwards, to compensate for the oblique direction of the femur inwards. It presents for examination a shaft and two extremities.

The **Upper Extremity**, or **Head**, is large, and expanded on each side into two lateral eminences, the *tuberosities*. Superiorly, the tuberosities present two smooth, concave surfaces, which articulate with the condyles of the femur; the internal articular surface is longer, deeper, and narrower than the external, oval from before backwards, to articulate with the internal condyle; the external one is broader, concave from side to side, but slightly convex from before backwards, and more circular, to articulate with the external condyle. Between the two articular surfaces, and nearer the posterior than the anterior aspect of the bone, is an eminence, the *spinous process* of the tibia, surmounted by a prominent tubercle on each side, which gives attachment to the extremities of the semilunar fibro-cartilages; in front and behind the spinous process is a rough depression for the attachment of the anterior and posterior crucial ligaments and the semilunar fibro-cartilages. The *anterior surfaces* of the tuberosities are continuous with one another, forming a single large surface, which is somewhat flattened: it is triangular, broad above, and perforated by large vascular foramina: narrow below where it terminates in a prominent oblong elevation of large size, the *tubercle* of the tibia; the lower half of this tubercle is rough, for the attachment of the ligamentum patellæ; the upper half presents a smooth facet supporting, in the recent state, a bursa which separates the ligament from the bone. Posteriorly the tuberosities are separated from each other by a shallow depression, the *popliteal notch*, which gives attachment to part of the posterior crucial ligament, and part of the posterior ligament of the knee-joint.

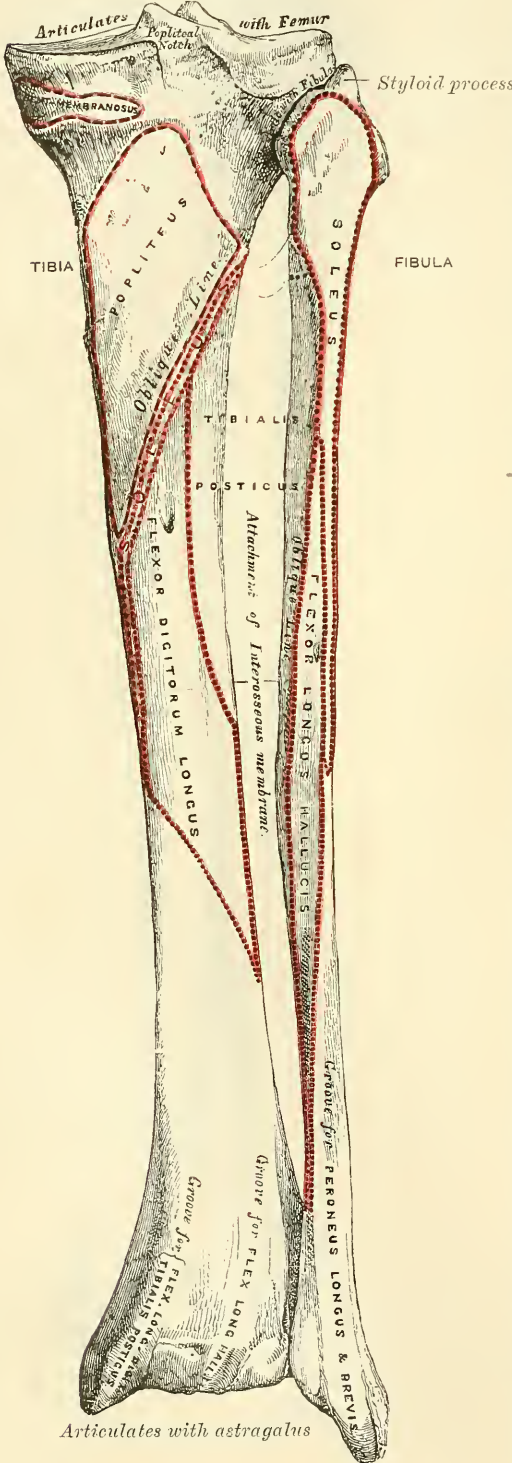
FIG. 244.—Bones of the right leg. Anterior surface.





The *inner tuberosity* presents posteriorly a deep transverse groove, for the insertion of one of the fasciculi of the tendon of the Semi-membranosus. Its *lateral surface* is convex, rough and prominent: it gives attachment to the internal lateral ligament. The *outer tuberosity* presents posteriorly a flat articular facet, nearly circular in form, directed downwards, backwards, and outwards, for articulation with the fibula. Its lateral surface is convex and rough, more prominent in front than the internal: it presents a prominent rough eminence, situated on a level with the upper border of the tubercle of the tibia at the junction of its anterior and outer surfaces, for the attachment of the ilio-fibial band. Just below this the Extensor longus digitorum and a slip from the Biceps are attached.

FIG. 245.—Bones of the right leg. Posterior surface.



The *inner tuberosity* presents posteriorly a deep transverse groove, for the insertion of one of the fasciculi of the tendon of the Semi-membranosus. Its *lateral surface* is convex, rough and prominent: it gives attachment to the internal lateral ligament. The *outer tuberosity* presents posteriorly a flat articular facet, nearly circular in form, directed downwards, backwards, and outwards, for articulation with the fibula. Its lateral surface is convex and rough, more prominent in front than the internal: it presents a prominent rough eminence, situated on a level with the upper border of the tubercle of the tibia at the junction of its anterior and outer surfaces, for the attachment of the ilio-fibial band. Just below this the Extensor longus digitorum and a slip from the Biceps are attached.

The **Shaft** of the tibia is of a triangular prismoid form, broad above, gradually decreasing in size to its most slender part, at the commencement of its lower fourth, where fracture most frequently occurs. It then enlarges again towards its lower extremity. It presents for examination three borders and three surfaces.

The **anterior border**, the most prominent of the three, is called the *crest of the tibia*, or, in popular language, the *shin*; it commences above at the tubercle, and terminates below at the anterior margin of the inner malleolus. This border is very prominent in the upper two-thirds of its extent, smooth and rounded below. It presents a very flexuous course, being usually curved outwards above, and inwards below; it gives attachment to the deep fascia of the leg.

The **internal border** is smooth and rounded above and below, but more prominent in the centre; it commences at the back part of the inner



tuberosity, and terminates at the posterior border of the internal malleolus; its upper part gives attachment to the internal lateral ligament of the knee to the extent of about two inches, and to some fibres of the Popliteus muscle; its middle third, to some fibres of the Soleus and Flexor longus digitorum muscles.

The **external border**, or **interosseous ridge**, is thin and prominent, especially its central part, and gives attachment to the interosseous membrane; it commences above in front of the fibular articular facet, and bifurcates below, to form the boundaries of a triangular rough surface, for the attachment of the interosseous ligament connecting the tibia and fibula.

The **internal surface** is smooth, convex, and broader above than below; its upper third, directed forwards and inwards, is covered by the aponeurosis derived from the tendon of the Sartorius, and by the tendons of the Gracilis and Semitendinosus, all of which are inserted nearly as far forwards as the anterior border; in the rest of its extent it is subcutaneous.

The **external surface** is narrower than the internal; its upper two-thirds presents a shallow groove for the attachment of the Tibialis anticus muscle; its lower third is smooth, convex, curves gradually forwards to the anterior aspect of the bone, and is covered from within outwards by the tendons of the following muscles: Tibialis anticus, Extensor proprius hallucis, Extensor longus digitorum.

The **posterior surface** (fig. 245) presents, at its upper part, a prominent ridge, the *oblique line* of the tibia, which extends from the back part of the articular facet for the fibula obliquely downwards, to the internal border, at the junction of its upper and middle thirds. It marks the limit for the insertion of the Popliteus muscle, and serves for the attachment of the popliteal fascia and part of the Soleus, Flexor longus digitorum, and Tibialis posticus muscles; the triangular concave surface, above and to the inner side of this line, gives attachment to the Popliteus muscle. The middle third of the posterior surface is divided by a vertical ridge into two lateral halves: the ridge is well marked at its commencement at the oblique line, but becomes gradually indistinct below; the inner and broader half gives attachment to the Flexor longus digitorum, the outer and narrower to part of the Tibialis posticus. The remaining part of the bone presents a smooth surface covered by the Tibialis posticus, Flexor longus digitorum, and Flexor longus hallucis muscles. Immediately below the oblique line is the medullary foramen, which is directed obliquely downwards.

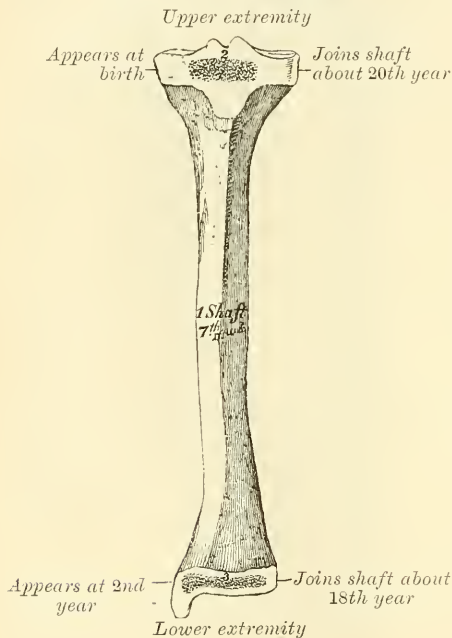
The **Lower Extremity**, much smaller than the upper, presents five surfaces; it is prolonged downwards, on its inner side into a strong process, the *internal malleolus*. The *inferior surface* of the bone is quadrilateral, and smooth for articulation with the astragalus. This surface is concave from before backwards, and broader in front than behind. It is traversed from before backwards by a slight elevation, separating two lateral depressions. It is narrow internally, where the articular surface becomes continuous with that on the inner malleolus. The *anterior surface* of the lower extremity is smooth and rounded above, and covered by the tendons of the Extensor muscles of the toes; its lower margin presents a rough transverse depression, for the attachment of the anterior ligament of the ankle-joint; the *posterior surface* presents a superficial groove directed obliquely downwards and inwards, continuous with a similar groove on the posterior extremity of the astragalus, and serving for the passage of the tendon of the Flexor longus hallucis; the *external surface* presents a triangular rough depression for the attachment of the inferior interosseous ligament connecting it with the fibula; the lower part of this depression is smooth, covered with cartilage in the recent state, and articulates with the fibula. The surface is bounded by two prominent ridges, continuous above with the interosseous ridge; they afford attachment to the anterior and posterior inferior tibio-fibular ligaments. The *internal surface* of the lower extremity is prolonged downwards to form a strong pyramidal process, flattened from without inwards—the *inner malleolus*. The *inner surface* of this process is convex and subcutaneous; its *outer surface* is smooth and slightly concave, and articulates with the astragalus; its *anterior*

*border* is rough, for the attachment of the anterior fibres of the Deltoid ligament ; its *posterior border* presents a broad and deep groove, directed obliquely downwards and inwards, which is occasionally double ; this groove transmits the tendons of the Tibialis posticus and Flexor longus digitorum muscles. The *summit* of the internal malleolus is marked by a rough depression behind, for the attachment of the internal lateral ligament of the ankle-joint.

**Structure.**—Like that of the other long bones. At the junction of the middle and lower third, where the bone is smallest, the wall of the shaft is thicker than in other parts, in order to compensate for the smallness of the calibre of the bone.

**Development.**—By *three centres* (fig. 246) : one for the shaft, and one for each extremity. Ossification commences in the centre of the shaft about the seventh

FIG. 246.—Plan of the development of the tibia. By three centres.



week, and gradually extends towards either extremity. The centre for the upper epiphysis appears during the first year ; it is flattened in form, and has a thin tongue-shaped process in front, which forms the tubercle. That for the lower epiphysis appears in the second year. The lower epiphysis joins the shaft at about the eighteenth, and the upper one about the twentieth year. Two additional centres occasionally exist, one for the tongue-shaped process of the upper epiphysis, which forms the tubercle, and one for the inner malleolus.

**Articulations.**—With three bones : the femur, fibula, and astragalus.

**Attachment of Muscles.**—To twelve : to the inner tuberosity, the Semi-membranosus ; to the outer tuberosity, the Tibialis anticus and Extensor longus digitorum and Biceps ; to the shaft, its internal surface, the Sartorius, Gracilis, and Semi-tendinosus ; to its external surface, the Tibialis anticus ; to its posterior surface, the Popliteus, Soleus, Flexor longus digitorum, and Tibialis posticus ; to the tubercle, the ligamentum patellæ, by which the Quadriceps extensor muscle is inserted into the tibia. In addition to these muscles, the Tensor vaginæ femoris is inserted indirectly into the tibia, through the ilio-tibial band, and the Peroneus longus occasionally derives a few fibres of origin from the outer tuberosity.

**Surface Form.**—A considerable portion of the tibia is subcutaneous and easily to be felt. At the upper extremity the tuberosities are to be recognised just below the knee. The internal one is broad and smooth, and merges into the subcutaneous surface of the shaft below. The external one is narrower and more prominent, and on it, about midway between the apex of the patella and the head of the fibula, may be felt a prominent tubercle for the insertion of the ilio-tibial band. In front of the upper end of the bone, between the tuberosities, is the tubercle of the tibia, forming an oval eminence, which is continuous below with the anterior border or crest of the bone. This border can be felt, forming the prominence of the shin, in the upper two-thirds of its extent as a sharp and flexuous ridge, curved outwards above and inwards below. In the lower third of the leg the border disappears and the bone is concealed by the tendons of the muscles on the front of the leg. Internal to the anterior border is to be felt the broad internal surface of the tibia, slightly encroached upon by the muscles in front and behind. It commences above at the wide expanded inner tuberosity and terminates below at the internal malleolus. The internal malleolus is a broad prominence situated on a higher level and somewhat further forwards than the external malleolus. It overhangs the inner border of



the arch of the foot. Its anterior border is nearly straight, its posterior border presents a sharp edge, which forms the inner margin of the groove for the tendon of the Tibialis posticus muscle.

#### THE FIBULA (figs. 244, 245)

The **Fibula** (*fibula, a clasp*) is situated at the outer side of the leg. It is the smaller of the two bones, and, in proportion to its length, the most slender of all the long bones; it is placed on the outer side of the tibia, with which it is connected above and below. Its upper extremity is small, placed towards the back of the head of the tibia, below the level of the knee-joint, and excluded from its formation; the lower extremity inclines a little forwards, so as to be on a plane anterior to that of the upper end, projects below the tibia, and forms the outer ankle. It presents for examination a shaft and two extremities.

The **Upper Extremity**, or **Head**, is of an irregular quadrate form, presenting above a flattened articular facet, directed upwards, forwards and inwards, for articulation with a corresponding facet on the external tuberosity of the tibia. On the outer side is a thick and rough prominence, continued behind into a pointed eminence, the *styloid process*, which projects upwards from the posterior part of the head. The prominence gives attachment to the tendon of the Biceps muscle, and to the long external lateral ligament of the knee, the ligament dividing the tendon into two parts. The summit of the styloid process gives attachment to the short external lateral ligament. The remaining part of the circumference of the head is rough, for the attachment of muscles and ligaments. It presents in front a tubercle for the origin of the upper and anterior part of the Peroneus longus, and the adjacent surface gives attachment to the anterior superior tibio-fibular ligament; and behind, another tubercle for the attachment of the posterior superior tibio-fibular ligament, and the upper fibres of the Soleus muscle.

The **shaft** presents four borders—the antero-external, the antero-internal, the postero-external, and the postero-internal; and four surfaces—anterior, posterior, internal, and external.

The **antero-external border** commences above in front of the head, runs vertically downwards to a little below the middle of the bone, and then curving somewhat outwards, bifurcates so as to embrace the triangular subcutaneous surface immediately above the outer surface of the external malleolus. This border gives attachment to an intermuscular septum, which separates the extensor muscles on the anterior surface of the leg from the Peroneus longus and brevis muscles.

The **antero-internal border**, or **interosseous ridge**, is situated close to the inner side of the preceding, and runs nearly parallel with it in the upper third of its extent, but diverges from it so as to include a broader space in the lower two-thirds. It commences above just beneath the head of the bone (sometimes it is quite indistinct for about an inch below the head), and terminates below at the apex of a rough triangular surface immediately above the articular facet of the external malleolus. It serves for the attachment of the interosseous membrane, which separates the extensor muscles in front from the flexor muscles behind.

The **postero-external border** is prominent; it commences above at the base of the styloid process, and terminates below in the posterior border of the outer malleolus. It is directed outwards above, backwards in the middle of its course, backwards and a little inwards below, and gives attachment to an aponeurosis which separates the Peronei muscles on the outer surface of the shaft from the flexor muscles on its posterior surface.

The **postero-internal border**, sometimes called the *oblique line*, commences above at the inner side of the head, and terminates by becoming continuous with the antero-internal border or interosseous ridge at the lower fourth of the bone. It is well marked and prominent at the upper and middle parts of the bone. It



gives attachment to an aponeurosis which separates the Tibialis posticus from the Soleus above and the Flexor longus hallucis below.

The **anterior surface** is the interval between the antero-external and antero-internal borders. It is extremely narrow and flat in the upper third of its extent; broader and grooved longitudinally in its lower third; it serves for the attachment of three muscles, the Extensor longus digitorum, Peroneus tertius, and Extensor proprius hallucis.

The **external surface** is the space between the antero-external and postero-external borders. It is much broader than the preceding, and often deeply grooved, is directed outwards in the upper two-thirds of its course, backwards in the lower third, where it is continuous with the posterior border of the external malleolus. This surface is completely occupied by the Peroneus longus and brevis muscles.

The **internal surface** is the interval included between the antero-internal and the postero-internal borders. It is directed inwards, and is grooved for the attachment of the Tibialis posticus muscle.

The **posterior surface** is the space included between the postero-external and the postero-internal borders; it is continuous below with the rough triangular surface above the articular facet of the outer malleolus; it is directed backwards above, backwards and inwards at its middle, directly inwards below. Its upper third is rough, for the attachment of the Soleus muscle; its lower part presents a triangular rough surface, connected to the tibia by a strong interosseous ligament, and between these two points the entire surface is covered by the fibres of origin of the Flexor longus hallucis muscle. At about the middle of this surface is the nutrient foramen, which is directed downwards.

The **Lower Extremity**, or **external malleolus**, is of a pyramidal form, somewhat flattened from without inwards, and is longer, and descends lower, than the internal malleolus. Its *external surface* is convex, subcutaneous, and continuous with the triangular (also subcutaneous) surface on the outer side of the

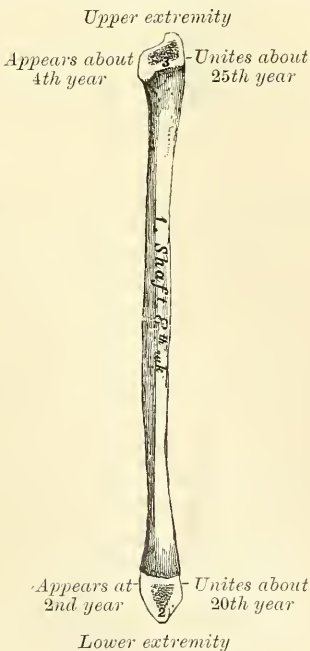shaft. The *internal surface* presents in front a smooth triangular facet, broader above than below, and convex from above downwards, which articulates with a corresponding surface on the outer side of the astragalus. Behind and beneath the articular surface is a rough depression, which gives attachment to the posterior fasciculus of the external lateral ligament of the ankle. The *anterior border* is thick and rough, and marked below by a depression for the attachment of the anterior fasciculus of the external lateral ligament. The *posterior border* is broad and marked by a shallow groove, for the passage of the tendons of the Peroneus longus and brevis muscles. The *summit* is rounded, and gives attachment to the middle fasciculus of the external lateral ligament.

In order to distinguish the side to which the bone belongs, hold it with the lower extremity downwards, and the broad groove for the Peronei tendons backwards, i.e. towards the holder: the triangular subcutaneous surface will then be directed to the side to which the bone belongs.

**Articulations.**—With two bones: the tibia and astragalus.

**Development.**—By three centres (fig. 247): one for the shaft, and one for

FIG. 247.—Plan of the development of the fibula. By three centres.



each extremity. Ossification commences in the shaft about the eighth week of foetal life, a little later than in the tibia, and extends gradually towards the extremities. At birth both ends are cartilaginous. Ossification commences in the lower end in the second year, and in the upper one about the fourth year. The lower epiphysis, the first in which ossification commences, becomes united to the shaft about the twentieth year; the upper epiphysis joins about the twenty-fifth year. Ossification appearing first in the lower epiphysis is contrary to the rule which prevails with regard to the commencement of ossification in epiphyses, viz. that that epiphysis towards which the nutrient artery is directed commences to ossify last; but it follows the rule which prevails with regard to the union of epiphyses, by uniting first.

**Attachment of Muscles.**—To nine: to the head, the Biceps, Soleus, and Peroneus longus; to the shaft, its anterior surface, the Extensor longus digitorum, Peroneus tertius, and Extensor proprius hallucis; to the internal surface, the Tibialis posticus; to the posterior surface, the Soleus and Flexor longus hallucis; to the external surface, the Peroneus longus and brevis.

**Surface Form.**—The only parts of the fibula which are to be felt are the head, the lower part of the external surface of the shaft and the external malleolus. The head is to be seen and felt behind and to the outer side of the outer tuberosity of the tibia. It presents a small, prominent, triangular eminence slightly above the level of the tubercle of the tibia. The external malleolus presents a narrow elongated prominence, situated on a plane posterior to the internal malleolus and reaching to a lower level. From it may be traced the lower third or half of the external surface of the shaft of the bone in the interval between the Peroneus tertius in front and the other two Peronei tendons behind.

**Surgical Anatomy.**—In fractures of the bones of the leg, both bones are usually fractured, but each bone may be broken separately, the fibula more frequently than the tibia. Fracture of both bones may be caused either by direct or indirect violence. When it occurs from indirect force, the fracture in the tibia is at the junction of the middle and lower third of the bone. Many causes conduce to render this the weakest part of the bone. The fracture of the fibula is usually at rather a higher level. These fractures present great variety, both as regards their direction and condition. They may be oblique, transverse, longitudinal, or spiral. When oblique, they are usually the result of indirect violence, and the direction of the fracture is from behind, downwards, forwards, and inwards in many cases, but may be downwards and outwards, or downwards and backwards. When transverse, the fracture is often at the upper part of the bone, and is the result of direct violence. The spiral fracture usually commences as a vertical fissure, involving the ankle-joint, and is associated with fracture of the fibula higher up. It is the result of torsion, from twisting of the body whilst the foot is fixed.

Fractures of the tibia alone are almost always the result of direct violence, except where the malleolus is broken off by twists of the foot. Fractures of the fibula alone may arise from indirect or direct force, those of the lower end being usually the result of the former, and those higher up being caused by a direct blow on the part.

The tibia and fibula, like the femur, are frequently the seat of acute necrosis. Chronic abscess is more frequently met with in the cancellous tissue of the head and lower end of the tibia than in any other bone of the body. The abscess is of small size, very chronic, and probably the result of tuberculous osteitis in the highly vascular growing tissue at the end of the shaft near the epiphysal cartilage in the young subject.

The tibia is the bone which is most frequently and most extensively distorted in rickets. It gives way at the junction of the middle and lower third, its weakest part, and presents a curve forwards and outwards.

## THE FOOT (figs. 248, 249)

The skeleton of the foot consists of three divisions: the Tarsus, Metatarsus, and Phalanges.

### THE TARSUS

The bones of the **Tarsus** are seven in number: viz. the calcaneum or os calcis, astragalus, cuboid, navicular, internal, middle, and external cuneiform bones.

#### THE CALCANEUM (fig. 250)

The **Calcaneum**, or **Os Calcis** (calx, *the heel*), is the largest and strongest of the tarsal bones. It is irregularly cuboidal in form, having its long axis directed



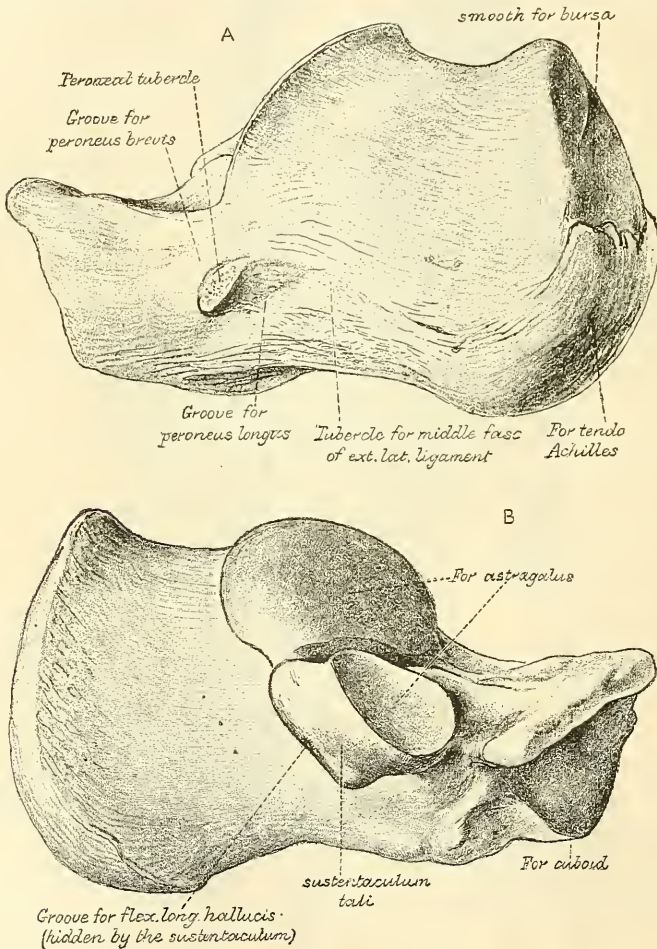




forwards and outwards. It is situated at the lower and back part of the foot, serving to transmit the weight of the body to the ground, and forming a strong lever for the muscles of the calf. It presents for examination six surfaces: superior, inferior, external, internal, anterior, and posterior.

The *superior surface* is formed behind by the upper aspect of that part of the os calcis which projects backwards to form the heel. It varies in length in different individuals; is convex from side to side, concave from before backwards, and upon it rests a mass of adipose substance placed in front of the tendo Achillis. In the middle of the superior surface are two (sometimes three) articular facets, separated by a broad shallow groove, which is directed obliquely forwards

FIG. 250.—The left os calcis. A. Postero-external view. B. Antero-internal view.



and outwards, and is rough for the attachment of the interosseous ligament connecting the astragalus and os calcis. Of the two articular surfaces, the *external* is the larger, and situated on the body of the bone: it is of an oblong form, wider behind than in front and convex from before backwards. The *internal articular surface* is supported on a projecting process of bone, called the *lesser process* of the calcaneum (*sustentaculum tali*); it is also oblong, concave longitudinally, and sometimes subdivided into two parts, which differ in size and shape. More anteriorly is seen the upper surface of the *greater process*, marked by a rough depression for the attachment of numerous ligaments, and a tubercle for the origin of the Extensor brevis digitorum muscle.

The *inferior surface* is narrow, rough, uneven, wider behind than in front,

and convex from side to side ; it is bounded posteriorly by two tubercles, separated by a rough depression ; the *external*, small, prominent, and rounded, gives attachment to part of the Abductor minimi digiti ; the *internal*, broader and larger, for the support of the heel, gives attachment, by its prominent inner margin, to the Abductor hallucis, and in front to the Flexor brevis digitorum muscles ; the depression between the tubercles gives attachment to the Abductor minimi digiti and plantar fascia. The rough surface in front of the tubercles gives attachment to the long plantar ligament, and to the outer head of the Flexor accessorius muscle ; and to a prominent tubercle nearer the anterior part of this surface, as well as to a transverse groove in front of it, is attached the short plantar ligament.

The *external surface* is broad, flat, and almost subcutaneous ; it presents near its centre a tubercle, for the attachment of the middle fasciculus of the external lateral ligament. At its upper and anterior part, this surface gives attachment to the external calcaneo-astragaloid ligament ; and in front of the tubercle it presents a narrow surface marked by two oblique grooves, separated by an elevated ridge which varies much in size in different bones ; it is named the *peroneal tubercle*, and gives attachment to a fibrous process from the external annular ligament. The *superior groove* transmits the tendon of the Peroneus brevis ; the *inferior*, the tendon of the Peroneus longus.

The *internal surface* is deeply concave ; it is directed obliquely downwards and forwards, and serves for the transmission of the plantar vessels and nerves into the sole of the foot ; it affords attachment to part of the Flexor accessorius muscle. At its upper and fore part it presents an eminence of bone, the *lesser process* or *sustentaculum tali*, which projects horizontally inwards, and to it a slip of the tendon of the Tibialis posticus is attached. This process is concave above, and supports the anterior articular surface of the astragalus ; below, it is grooved for the tendon of the Flexor longus hallucis. Its free margin is rough for the attachment of part of the internal lateral ligament of the ankle-joint.

The *anterior surface*, of a somewhat triangular form, articulates with the cuboid. It is concave from above, downwards and outwards, and convex in the opposite direction. Its inner border gives attachment to the inferior calcaneo-navicular ligament.

The *posterior surface* is rough, prominent, convex, and wider below than above. Its lower part is rough, for the attachment of the tendo Achillis and the tendon of the Plantaris muscle ; its upper part is smooth, and is covered by a bursa which separates the tendons from the bone.

**Articulations.**—With two bones : the astragalus and cuboid.

**Attachment of Muscles.**—To eight : part of the Tibialis posticus, the tendo Achillis, Plantaris, Abductor hallucis, Abductor minimi digiti, Flexor brevis digitorum, Flexor accessorius, and Extensor brevis digitorum.

#### THE ASTRAGALUS (fig. 251)

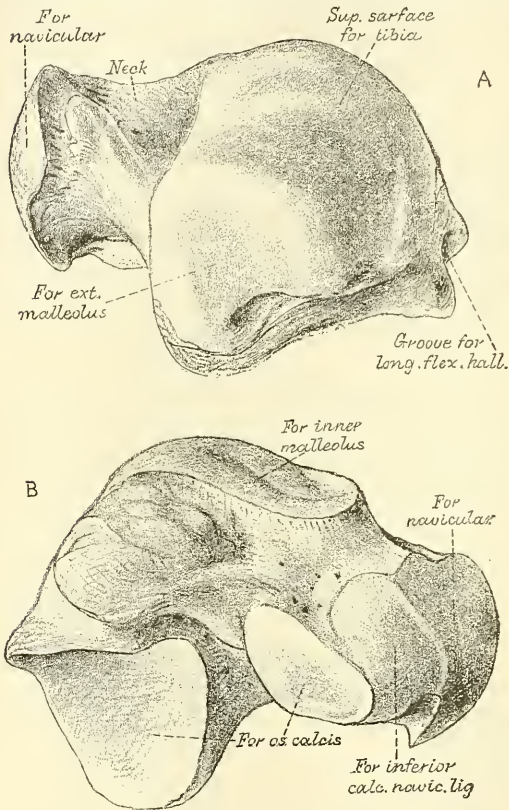
The **Astragalus** (*ἀσπράγαλος, a die*) is the largest of the tarsal bones, next to the os calcis. It occupies the middle and upper part of the tarsus, supporting the tibia above, articulating with the malleoli on either side, resting below upon the os calcis, and joined in front to the navicular. This bone may easily be recognised by its large rounded head, by the broad articular facet on its upper convex surface, or by the two articular facets separated by a deep groove on its under concave surface. It presents six surfaces for examination.

The *superior surface* presents, behind, a broad smooth trochlear surface, for articulation with the tibia. The trochlea is broader in front than behind, convex from before backwards, slightly concave from side to side : in front of it is the upper surface of the neck of the astragalus ; rough for the attachment of ligaments. The *inferior surface* presents two articular facets separated by a deep groove.



The groove runs obliquely forwards and outwards, becoming gradually broader and deeper in front: it corresponds with a similar groove upon the upper surface of the os calcis, and forms, when articulated with that bone, a canal, filled up in the recent state by the interosseous calcaneo-astragaloid ligament. Of the two

FIG. 251.—The left astragalus. A. Superior and external view. B. Inferior and internal view.



articular facets, the posterior is the larger, of an oblong form, and deeply concave from side to side; the anterior is shorter and narrower, of an elongated oval form, convex longitudinally, and often subdivided into two by an elevated ridge; of these the posterior articulates with the lesser process of the os calcis; the anterior, with the upper surface of the inferior calcaneo-navicular ligament. The *internal surface* presents at its upper part a pear-shaped articular facet for the inner malleolus, continuous above with the trochlear surface; below the articular surface is a rough depression, for the attachment of the deep portion of the internal lateral ligament. The *external surface* presents a large triangular facet, concave from above downwards, for articulation with the external malleolus; it is continuous above with the trochlear surface; and in front of it is a rough depression for the attachment of the anterior fasciculus of the external lateral ligament of the ankle-joint. The *anterior surface*, convex and rounded, forms

the *head* of the astragalus; it is smooth, of an oval form, and directed obliquely inwards and downwards; it articulates with the navicular. On its under and inner surface is a small facet, continuous in front with the articular surface of the head, and behind with the smaller facet for the os calcis. This rests on the inferior calcaneo-navicular ligament, being separated from it by the synovial membrane, which is prolonged from the anterior calcaneo-astragaloid joint to the astragalo-navicular joint. The head is surrounded by a constricted portion, the *neck* of the astragalus. The *posterior surface* is narrow, and traversed by a groove, which runs obliquely downwards and inwards, and transmits the tendon of the Flexor longus hallucis, external to which is a prominent tubercle, to which the posterior fasciculus of the external lateral ligament is attached. To the inner side of the groove is a second, but less marked tubercle.

To ascertain to which foot the bone belongs, hold it with the broad articular surface upwards, and the rounded head forwards; the lateral triangular articular surface for the external malleolus will then point to the side to which the bone belongs.

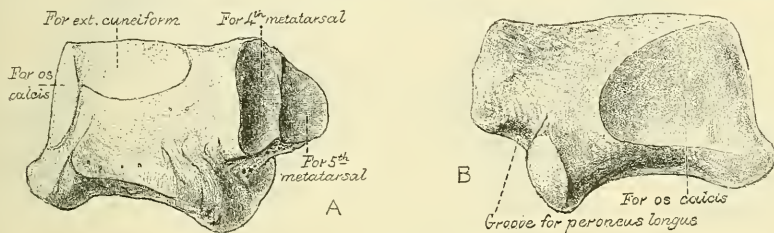
**Articulations.**—With four bones: tibia, fibula, os calcis, and navicular.

## THE CUBOID (fig. 252)

The **Cuboid** (*κύβος, a cube; εἶδος, like*) bone is placed on the outer side of the foot, in front of the os calcis, and behind the fourth and fifth metatarsal bones. It is of a pyramidal shape, its base being directed inwards, its apex outwards. It may be distinguished from the other tarsal bones by the existence of a deep groove on its under surface, for the tendon of the Peroneus longus muscle. It presents for examination six surfaces: three articular, and three non-articular.

The **non-articular surfaces** are the superior, inferior, and external. The *superior* or *dorsal surface*, directed upwards and outwards, is rough, for the attachment of numerous ligaments. The *inferior* or *plantar surface* presents in front a deep groove, which runs obliquely from without, forwards and inwards; it lodges the tendon of the Peroneus longus, and is bounded behind by a prominent ridge, to which is attached the long calcaneo-cuboid ligament. The ridge terminates externally in an eminence, the *tuberosity of the cuboid*, the surface of which presents a convex facet, for articulation with the sesamoid bone of the tendon contained in the groove. The surface of bone behind the groove is rough, for the attachment of the short plantar ligament, a few fibres of the

FIG. 252.—The left cuboid. A. Antero-internal view. B. Postero-external view.



Flexor brevis hallucis and a fasciculus from the tendon of the Tibialis posticus. The *external surface*, the smallest and narrowest of the three, presents a deep notch formed by the commencement of the peroneal groove.

The **articular surfaces** are the posterior, anterior, and internal. The *posterior surface* is smooth, triangular, and concavo-convex, for articulation with the anterior surface of the os calcis. The *anterior*, of smaller size, but also irregularly triangular, is divided by a vertical ridge into two facets: the inner one, quadrilateral in form, articulates with the fourth metatarsal bone; the outer one, larger and more triangular, articulates with the fifth metatarsal. The *internal surface* is broad, rough, irregularly quadrilateral, presenting at its middle and upper part a smooth oval facet, for articulation with the external cuneiform bone; and behind this (occasionally) a smaller facet, for articulation with the navicular; it is rough in the rest of its extent, for the attachment of strong interosseous ligaments.

To ascertain to which foot the bone belongs, hold it so that its under surface, marked by the peroneal groove, looks downwards, and the large concavo-convex articular surface backwards, towards the holder: the narrow non-articular surface, marked by the commencement of the peroneal groove, will point to the side to which the bone belongs.

**Articulations.**—With four bones: the os calcis, external cuneiform, and the fourth and fifth metatarsal bones; occasionally with the navicular.

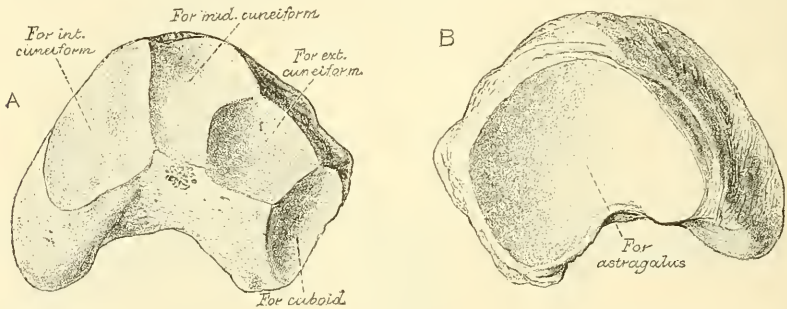
**Attachment of Muscles.**—Part of the Flexor brevis hallucis and a slip from the tendon of the Tibialis posticus.

## THE NAVICULAR (fig. 253)

The **Navicular** or **Scaphoid bone** is situated at the inner side of the tarsus, between the astragalus behind and the three cuneiform bones in front. It may be distinguished by its form, being concave behind, convex and subdivided into three facets in front.

The *anterior surface*, of an oblong form, is convex from side to side, and subdivided by two ridges into three facets, for articulation with the three cuneiform bones. The *posterior surface* is oval, concave, broader externally than internally, and articulates with the rounded head of the astragalus. The *superior surface* is convex from side to side, and rough for the attachment of ligaments. The *inferior* is irregular, and also rough for the attachment of ligaments. The *internal surface* presents a rounded tubercular eminence, the *tuberosity* of the navicular, the lower part of which projects, and gives attachment to part of the tendon of the Tibialis posticus. The *external surface* is rough, and irregular, for the attachment of ligamentous fibres, and occasionally presents a small facet for articulation with the cuboid bone.

FIG. 253.—The left navicular. A. Antero-external view. B. Postero-internal view.



To ascertain to which foot the bone belongs, hold it with the concave articular surface backwards, and the convex dorsal surface upwards; the external surface, i.e. the surface opposite the tubercle, will point to the side to which the bone belongs.

**Articulations.**—With four bones: astragalus and three cuneiform; occasionally also with the cuboid.

**Attachment of Muscles.**—Part of the Tibialis posticus.

## THE CUNEIFORM BONES

The **Cuneiform Bones** have received their name from their wedge-like shape (*cuneus, a wedge; forma, likeness*). They form, with the cuboid, the anterior row of the tarsus, being placed between the navicular behind, the three innermost metatarsal bones in front, and the cuboid externally. They are called the *first, second, and third*, counting from the inner to the outer side of the foot, and, from their position, *internal, middle, and external*.

## THE INTERNAL CUNEIFORM (fig. 254)

The **Internal Cuneiform** is the largest of the three. It is situated at the inner side of the foot, between the navicular behind and the base of the first metatarsal in front. It may be distinguished from the other two by its large size, and by its not presenting such a distinct wedge-like form. Without the others, it may be known by the large kidney-shaped anterior articulating surface, and by the prominence on the inferior or plantar surface for the attachment of the Tibialis posticus. It presents for examination six surfaces.



The *internal surface* is subcutaneous, and forms part of the inner border of the foot; it is broad, quadrilateral, and presents at its anterior inferior angle a smooth oval facet, into which the tendon of the Tibialis anticus is partially inserted; in the rest of its extent it is rough, for the attachment of ligaments. The *external surface* is concave,

presenting, along its superior and posterior borders, a narrow reversed L-shaped surface for articulation with the middle cuneiform behind, and second metatarsal bone in front: in the rest of its extent it is rough for the attachment of ligaments and part of the tendon of the Peroneus longus. The *anterior surface*, kidney-shaped, much larger than the posterior, articulates with the metatarsal bone of the great toe. The *posterior surface* is triangular, concave, and articulates with the innermost and largest of the three facets on the anterior surface of the navicular. The *inferior or plantar surface* is rough, and presents a prominent tuberosity at its back part for the attachment of part of the tendon of the Tibialis posticus. It also gives attachment in front to part of the tendon of the Tibialis anticus. The *superior surface* is the narrow pointed end of the wedge, which is directed upwards and outwards; it is rough for the attachment of ligaments.

To ascertain to which side the bone belongs, hold it so that its superior narrow edge looks upwards, and the long, kidney-shaped, articular surface forwards; the external surface, marked by its vertical and horizontal articular facets, will point to the side to which it belongs.

**Articulations.**—With four bones: navicular, middle cuneiform, first and second metatarsal bones.

**Attachment of Muscles.**—To three: the Tibialis anticus and posticus, and Peroneus longus.

#### THE MIDDLE CUNEIFORM (fig. 255)

The **Middle Cuneiform**, the smallest of the three, is of very regular wedge-like form, the broad extremity being placed upwards, the narrow end downwards. It is situated between the other two bones of the same name, and articulates with the navicular behind, and the second metatarsal in front. It may be distinguished from the external cuneiform bone, which it much resembles in general appearance, by the articular facet, of angular form, which runs round the upper and back part of its inner surface; and if the two bones from the same foot are together, the middle cuneiform is much the smaller.

The *anterior surface*, triangular in form, and narrower than the posterior, articulates with the base of the second metatarsal bone. The *posterior surface*, also triangular, articulates with the navicular. The *internal surface* presents a reversed L-shaped articular facet,

FIG. 254.—The left internal cuneiform. A. Antero-internal view. B. Postero-external view.

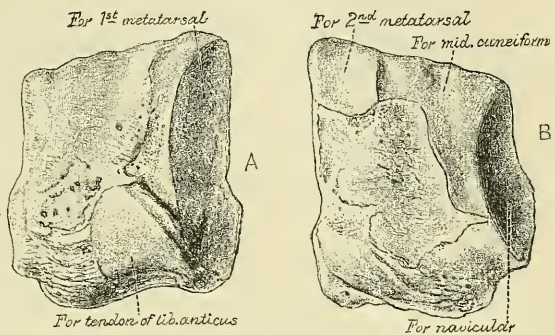
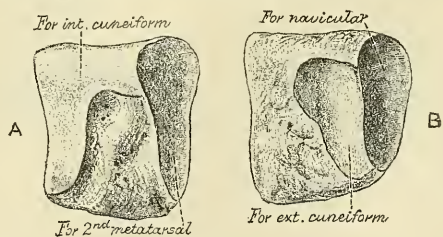


FIG. 255.—The left middle cuneiform. A. Antero-internal view. B. Postero-external view.



running along the superior and posterior borders, for articulation with the internal cuneiform, and is rough in the rest of its extent for the attachment of ligaments. The *external surface* presents posteriorly a smooth facet for articulation with the external cuneiform bone. The *superior surface* forms the base of the wedge; it is quadrilateral, broader behind than in front, and rough for the attachment of ligaments. The *inferior surface*, pointed and tubercular, is also rough for ligamentous attachment, and for the insertion of a slip from the tendon of the Tibialis posticus.

To ascertain to which foot the bone belongs, hold its superior or dorsal surface upwards, the broadest edge being towards the holder: the smooth facet (limited to the posterior border) will then point to the side to which it belongs.

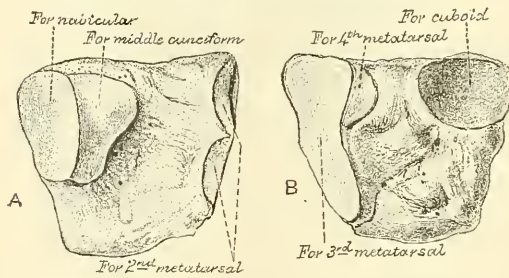
**Articulations.**—With four bones: navicular, internal and external cuneiform, and second metatarsal bone.

**Attachment of Muscle.**—A slip from the tendon of the Tibialis posticus is attached to this bone.

#### THE EXTERNAL CUNEIFORM (fig. 256)

The **External Cuneiform**, intermediate in size between the two preceding, is of a very regular wedge-like form, the broad extremity being placed upwards, the narrow end downwards. It occupies the centre of the front

FIG. 256.—The left external cuneiform. A. Postero-internal view. B. Antero-external view.



row of the tarsus between the middle cuneiform internally, the cuboid externally, the navicular behind, and the third metatarsal in front. It is distinguished from the internal cuneiform bone by its more regular wedge-like shape, and by the absence of the kidney-shaped articular surface: from the middle cuneiform, by the absence of the reversed L-shaped facet, and by

the two articular facets which are present on both its inner and outer surfaces. It has six surfaces for examination.

The *anterior surface*, triangular in form, articulates with the third metatarsal bone. The *posterior surface* articulates with the most external facet of the navicular, and is rough below for the attachment of ligamentous fibres. The *internal surface* presents two articular facets, separated by a rough depression, the anterior one, sometimes divided into two, articulates with the outer side of the base of the second metatarsal bone; the posterior one skirts the posterior border, and articulates with the middle cuneiform; the rough depression between the two gives attachment to an interosseous ligament. The *external surface* also presents two articular facets, separated by a rough non-articular surface; the anterior facet, situated at the superior angle of the bone, is small, and articulates with the inner side of the base of the fourth metatarsal; the posterior and larger one articulates with the cuboid; the rough, non-articular surface serves for the attachment of an interosseous ligament. The three facets for articulation with the three metatarsal bones are continuous with one another, and covered by a prolongation of the same cartilage; the facets for articulation with the middle cuneiform and navicular are also continuous, but that for articulation with the cuboid is usually separate. The *superior or dorsal surface* is of an oblong square form; its posterior external angle being prolonged backwards. The *inferior or plantar surface* is an obtuse rounded margin, and serves for the attachment of part of the tendon of the Tibialis posticus, part of the Flexor brevis hallucis, and ligaments.

To ascertain to which side the bone belongs, hold it with the broad dorsal



surface upwards, the prolonged edge backwards; the separate articular facet for the cuboid will point to the proper side.

**Articulations.**—With six bones: the navicular, middle cuneiform, cuboid, and second, third, and fourth metatarsal bones.

**Attachment of Muscles.**—To two: part of the Tibialis posticus, and Flexor brevis hallucis.

#### THE METATARSAL BONES

The **Metatarsal Bones** are five in number, and are numbered one to five, in accordance with their position from within outwards; they are long bones, and present for examination a shaft and two extremities.

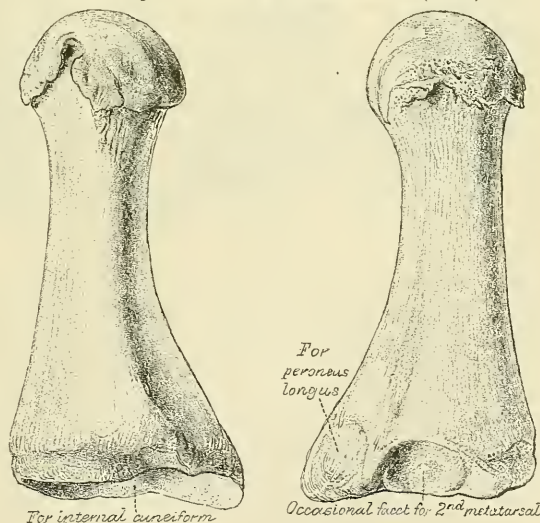
#### COMMON CHARACTERS OF THE METATARSAL BONES

The **Shaft** is prismoid in form, tapers gradually from the tarsal to the phalangeal extremity, and is slightly curved longitudinally, so as to be concave below, slightly convex above. The *posterior extremity*, or *base*, is wedge-shaped, articulating by its terminal surface with the tarsal bones, and by its lateral surfaces with the contiguous metatarsal bones: its dorsal and plantar surfaces being rough for the attachment of ligaments. The *anterior extremity*, or *head*, presents a terminal rounded articular surface, oblong from above downwards, and extending further backwards below than above. Its sides are flattened, and present a depression, surmounted by a tubercle, for ligamentous attachment. Its under surface is grooved in the middle line for the passage of the Flexor tendon, and marked on each side by an articular eminence continuous with the terminal articular surface.

#### PECULIAR CHARACTERS OF THE METATARSAL BONES

The **First** (fig. 257) is remarkable for its great thickness, but is the shortest of all the metatarsal bones. The *shaft* is strong, and of well-marked prismoid form. The *posterior extremity* presents, as a rule, no lateral articular facets, but occasionally on the outer side there is an oval facet, by which it articulates with the second metatarsal bones. Its terminal articular surface is of large size, kidney-shaped; its circumference is grooved, for the tarso-metatarsal ligaments, and internally gives attachment to part of the tendon of the Tibialis anticus; its inferior angle presents a rough oval prominence for the insertion of the tendon of the Peroneus longus. The *head* is of large size; on its plantar surface are two grooved facets, over which glide sesamoid bones; the facets are separated by a smooth elevated ridge.

FIG. 257.—The first metatarsal. (Left.)



This bone is known by the single kidney-shaped articular surface on its base; the deeply grooved appearance of the plantar surface of its head; and its great thickness, relatively to its length. When it is placed in its natural position, the concave border of the kidney-shaped articular surface on its base points to the side to which the bone belongs.

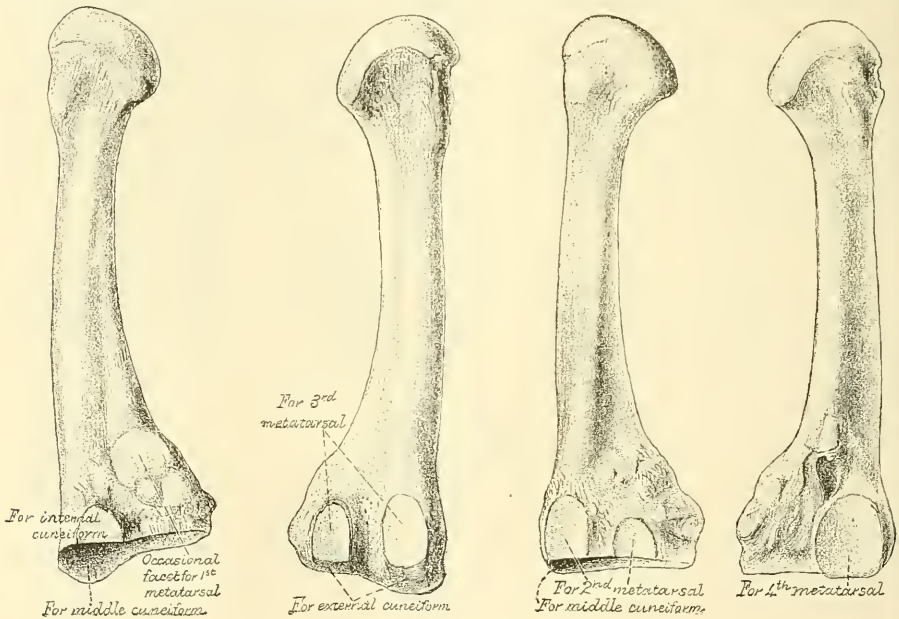


**Attachment of Muscles.**—To three: part of the *Tibialis anticus*, the *Peroneus longus*, and the *First dorsal interosseus*.

The **Second** (fig. 258) is the longest and largest of the remaining metatarsal bones, being prolonged backwards into the recess formed between the three cuneiform bones. Its *tarsal extremity* is broad above, narrow and rough below. It presents four articular surfaces: one behind, of a triangular form, for articulation with the middle cuneiform; one at the upper part of its internal lateral surface, for articulation with the internal cuneiform; and two on its external lateral surface, an upper and lower, separated by a rough non-articular interval. Each of these articular surfaces is divided by a vertical ridge into two facets, thus making four facets; the two anterior of these articulate with the third metatarsal; the two posterior (sometimes continuous) with the external cuneiform. In addition to these articular surfaces, there is occasionally a fifth when this bone articulates with the first metatarsal bone. It is oval in shape, and is situated on the inner side of the shaft near the base.

FIG. 258.—The second metatarsal. (Left)

FIG. 259.—The third metatarsal. (Left.)



The facets on the tarsal extremity of the second metatarsal bone serve at once to distinguish it from the rest, and to indicate the foot to which it belongs; there being one facet at the upper angle of the internal surface, and two facets, each subdivided into two parts, on the external surface, pointing to the side to which the bone belongs. The fact that the two posterior subdivisions of these external facets sometimes run into one should not be forgotten.

**Attachment of Muscles.**—To four: the *Adductor obliquus hallucis*, *First and Second dorsal interosseous*, and a slip from the tendon of the *Tibialis posticus*, occasionally also a slip from the *Peroneus longus*.

The **Third** (fig. 259) articulates behind, by means of a triangular smooth surface, with the external cuneiform; on its inner side, by two facets, with the second metatarsal; and on its outer side, by a single facet, with the fourth metatarsal. The latter facet is of circular form, and situated at the upper angle of the base.

The third metatarsal is known by its having at its tarsal end two undivided facets on the inner side, and a single facet on the outer. This distinguishes it from the second metatarsal, in which the two facets, found on one side of its

tarsal end, are each subdivided into two. The single facet (when the bone is put in its natural position) is on the side to which the bone belongs.

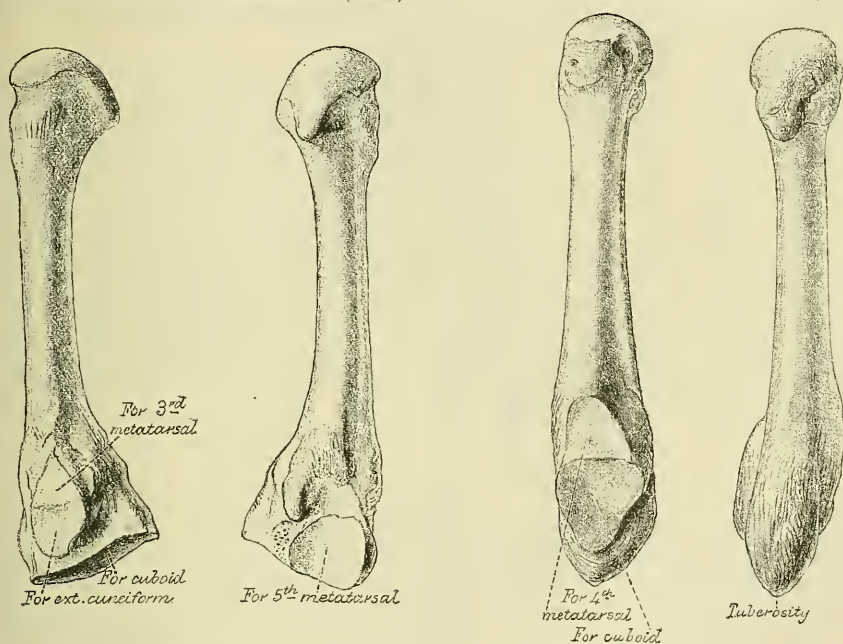
**Attachment of Muscles.**—To five: Adductor obliquus hallucis, Second and Third dorsal, and First plantar interosseous, and a slip from the tendon of the Tibialis posticus.

The **Fourth** (fig. 260) is smaller in size than the preceding; its *tarsal extremity* presents a terminal quadrilateral surface for articulation with the cuboid; a smooth facet on the inner side, divided by a ridge into an anterior portion for articulation with the third metatarsal, and a posterior portion for articulation with the external cuneiform; on the outer side a single facet, for articulation with the fifth metatarsal.

The fourth metatarsal is known by its having a single facet on either side of the tarsal extremity, that on the inner side being divided into two parts. If this subdivision be not recognisable, the fact that its tarsal end is bent somewhat outwards will indicate the side to which it belongs.

FIG. 260.—The fourth metatarsal. (Left.)

FIG. 261.—The fifth metatarsal. (Left.)



**Attachment of Muscles.**—To five: Adductor obliquus hallucis, Third and Fourth dorsal, and Second plantar interosseous, and a slip from the tendon of the Tibialis posticus.

The **Fifth** (fig. 261) is recognised by the tubercular eminence on the outer side of its base. It articulates behind, by a triangular surface cut obliquely from without inwards, with the cuboid; and internally, with the fourth metatarsal.

The projection on the outer side of this bone at its tarsal end at once distinguishes it from the others, and points to the side to which it belongs.

**Attachment of Muscles.**—To six: the Peroneus brevis, Peroneus tertius, Flexor brevis minimi digiti, Adductor transversus hallucis, Fourth dorsal, and Third plantar.

**Articulations.**—Each bone articulates with the tarsal bones by one extremity, and by the other with the first row of phalanges. The number of tarsal bones with which each metatarsal articulates is one for the first, three for the second, one for the third, two for the fourth, and one for the fifth.

## PHALANGES

The **Phalanges** of the foot, both in number and general arrangement, resemble those in the hand; there being two in the great toe, and three in each of the other toes.

The phalanges of the *first row* closely resemble those of the hand. The *shaft* is compressed from side to side, convex above, concave below. The *posterior extremity* is concave; and the *anterior extremity* presents a trochlear surface, for articulation with the second phalanges.

The phalanges of the *second row* are remarkably small and short, but rather broader than those of the first row.

The *ungual* phalanges, in form, resemble those of the fingers; but they are smaller, flattened from above downwards, presenting a broad base for articulation with the second row, and an expanded extremity for the support of the nail and end of the toe.

**Articulations.**—The first row, with the metatarsal bones behind and second phalanges in front; the second row, of the four outer toes, with the first and third phalanges; of the great toe, with the first phalanx; the third row, of the four outer toes, with the second phalanges.

**Attachment of Muscles.**—To the first phalanges. Great toe five muscles: innermost tendon of Extensor brevis digitorum, Abductor hallucis, Adductor obliquus hallucis, Flexor brevis hallucis, Adductor transversus hallucis. Second toe, three muscles: First and Second dorsal interosseous, and First lumbrical. Third toe, three muscles: Third dorsal and First plantar interosseous, and Second lumbrical. Fourth toe, three muscles: Fourth dorsal and Second plantar interosseous, and Third lumbrical. Fifth toe, four muscles: Flexor brevis minimi digiti, Abductor minimi digiti, and Third plantar interosseous, and Fourth lumbrical.—Second phalanges. Great toe: Extensor longus hallucis, Flexor longus hallucis. Other toes: Flexor brevis digitorum, one slip of the common tendon of the Extensor longus and brevis digitorum.\*—Third phalanges: two slips from the common tendon of the Extensor longus and Extensor brevis digitorum, and the Flexor longus digitorum.

## DEVELOPMENT OF THE FOOT (fig. 262)

The **Tarsal bones** are each developed by a single centre, excepting the os calcis, which has an epiphysis for its posterior extremity. The centres make their appearance in the following order: os calcis, at the sixth month of foetal life; astragalus, about the seventh month; cuboid, at the ninth month; external cuneiform, during the first year; internal cuneiform, in the third year; middle cuneiform and navicular in the fourth year. The epiphysis for the posterior tuberosity of the os calcis appears at the tenth year, and unites with the rest of the bone soon after puberty.

The **Metatarsal bones** are each developed by *two* centres: one for the shaft, and one for the digital extremity, in the four outer metatarsal; one for the shaft, and one for the base, in the metatarsal bone of the great toe.† Ossification commences in the centre of the shaft about the ninth week, and extends towards either extremity. The centre in the proximal end of the first metatarsal bone appears about the third year; the centre in the distal end of the other bones between the fifth and eighth year; they become joined between the eighteenth and twentieth years.

The **Phalanges** are developed by *two* centres for each bone; one for the shaft,

\* Except the second phalanx of the fifth toe, which receives no slip from the Extensor brevis digitorum.

† As was noted in the first metacarpal bone, so in the first metatarsal, there is often to be observed a tendency to the formation of a second epiphysis in the distal extremity (see footnote, p. 259).

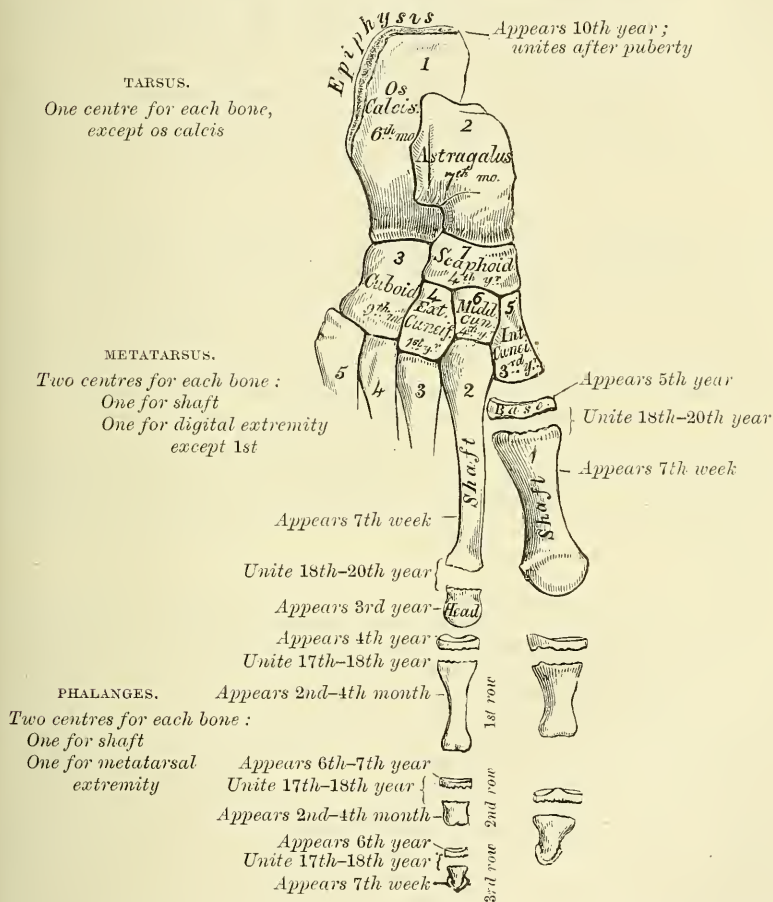


and one for the metatarsal extremity. The centre for the shaft appears about the tenth week ; that for the epiphysis between the fourth and tenth year, they join the shaft about the eighteenth year.

CONSTRUCTION OF THE FOOT AS A WHOLE

The foot is constructed on the same principles as the hand, but modified to form a firm basis of support for the rest of the body when in the erect position. It is more solidly constructed, and its component parts are less movable on each other than in the hand. This is especially the case with the great toe, which has to assist in supporting the body, and is therefore constructed with greater solidity ;

FIG. 262.—Plan of the development of the foot.



it lies parallel with the other toes, and has a very limited degree of mobility, whereas the thumb, which is occupied in numerous and varied movements, is constructed in such a manner as to permit of great mobility ; its metacarpal bone is directed away from the others, so as to form an acute angle with the second, and it enjoys a considerable range of motion at its articulation with the carpus. The foot is placed at right angles to the leg—a position which is almost peculiar to man, and has relation to the erect position which he maintains. In order to allow of its supporting the weight of the whole body in this position, with the least expenditure of material, it is constructed in the form of an arch. This arch is not, however, made up of two equal limbs. The hinder one, which is made up of the os calcis and the posterior part of the astragalus, is about half

the length of the anterior limb, and measures about three inches. The anterior limb consists of the rest of the tarsal and the metatarsal bones, and measures about six inches. It may be said to consist of two parts, an inner segment made up of the head of the astragalus, the navicular, the three cuneiform, and the three inner metatarsal bones; and an outer segment composed of the cuboid and the two outer metatarsal bones. The summit of the arch is at the superior articular surface of the astragalus; and its two extremities, that is to say the two points on which the arch rests in standing, are the tubercles on the under surface of the os calcis posteriorly, and the heads of the metatarsal bones anteriorly. The weakest part of the arch is the joint between the astragalus and scaphoid, and here it is more liable to yield in those who are overweighted, and in those in whom the ligaments which complete and preserve the arch are relaxed. This weak point in the arch is braced on its concave surface by the inferior calcaneo-navicular ligament, which is more elastic than most other ligaments, and thus allows the arch to yield from jars or shocks applied to the anterior portion of the foot, and quickly restores it to its pristine condition. This ligament is supported on its under surface by the tendon of the Tibialis posticus muscle, which is spread out into a fan-shaped insertion, and prevents undue tension of the ligament or such an amount of stretching as would permanently elongate it.

In addition to this longitudinal arch the foot presents a transverse arch, at the anterior part of the tarsus and hinder part of the metatarsus. This, however, can scarcely be described as a true arch, but presents more the character of a half-dome. The inner border of the central portion of the longitudinal arch is elevated from the ground, and from this point the bones arch over to the outer border, which is in contact with the ground, and, assisted by the longitudinal arch, produce a sort of rounded niche on the inner side of the foot, which gives the appearance of a transverse as well as a longitudinal arch.

The line of the foot, from the point of the heel to the toes, is not quite straight, but is directed a little outwards, so that the inner border is a little convex and the outer border concave. This disposition of the bones becomes more marked when the longitudinal arch of the foot is lost, as in the disease known under the name of 'flat-foot.'

*Surface Form.*—On the dorsum of the foot the individual bones are not to be distinguished, with the exception of the head of the astragalus, which forms a rounded projection in front of the ankle-joint when the foot is forcibly extended. The whole surface forms a smooth convex outline, the summit of which is the ridge formed by the head of the astragalus, the navicular, the middle cuneiform, and the second metatarsal bones; from this it gradually inclines outwards and more rapidly inwards. On the inner side of the foot, the internal tuberosity of the os calcis and the ridge separating the inner from the posterior surface of the bone may be felt most posteriorly. In front of this, and below the internal malleolus, may be felt the projection of the sustentaculum tali. Passing forwards is the well-marked tuberosity of the navicular bone, situated about an inch or an inch and a quarter in front of the internal malleolus. Further towards the front, the ridge formed by the base of the first metatarsal bone can be obscurely felt, and from this the shaft of the bone can be traced to the expanded head articulating with the base of the first phalanx of the great toe. Immediately beneath the base of this phalanx, the internal sesamoid bone is to be felt. Lastly, the expanded ends of the bones forming the last joint of the great toe are to be felt. On the outer side of the foot the most posterior bony point is the outer tuberosity of the os calcis, with the ridge separating the posterior from the outer surface of the bone. In front of this the greater part of the external surface of the os calcis is subcutaneous; on it, below and in front of the external malleolus, may be felt the peroneal ridge, when this process is present. Further forwards, the base of the fifth metatarsal bone forms a prominent and well-defined landmark, and in front of this the shaft of the bone, with its expanded head, and the base of the first phalanx, may be defined. The sole of the foot is almost entirely covered by soft parts, so that but few bony parts are to be made out, and these somewhat obscurely. The hinder part of the under surface of the os calcis and the heads of the metatarsal bones, with the exception of the first, which is concealed by the sesamoid bones, may be recognised.

*Surgical Anatomy.*—Considering the injuries to which the foot is subjected, it is surprising how seldom the tarsal bones are fractured. This is no doubt due to the fact that the tarsus is composed of a number of bones, articulated by a considerable extent of



surface and joined together by very strong ligaments, which serve to break the force of violence applied to this part of the body. When fracture does occur, these bones being composed for the most part of a soft cancellous structure, covered only by a thin shell of compact tissue, are often extensively comminuted, especially as most of the fractures are produced by direct violence. And having only a very scanty amount of soft parts over them, the fractures are very often compound, and amputation is frequently necessary.

When fracture occurs in the anterior group of tarsal bones, it is almost invariably the result of direct violence; but fractures of the posterior group, that is, of the calcaneum and astragalus, are most frequently produced by falls from a height on to the feet; though fracture of the os calcis may be caused by direct violence or by muscular action. The posterior part of the bone, that is, the part behind the articular surfaces, is the most frequent seat of the fracture, though some few cases of fracture of the sustentaculum tali and of vertical fracture between the two articulating facets have been recorded. The neck of the astragalus, being the weakest part of the bone, is most frequently fractured, though fractures may occur in any part and almost in any direction, either associated or not with fracture of other bones.

In cases of club foot, especially in congenital cases, the bones of the tarsus become altered in shape and size, and displaced from their proper positions. This is especially the case in congenital equino-varus, in which the astragalus, particularly about the head, becomes twisted and atrophied, and a similar condition may be present in the other bones, more especially the navicular. The tarsal bones are peculiarly liable to become the seat of tuberculous caries from comparatively trivial injuries. There are several reasons to account for this. They are composed of a delicate cancellated structure, surrounded by intricate synovial membranes. They are situated at the furthest point from the central organ of the circulation and exposed to vicissitudes of temperature; and, moreover, on their dorsal surface are thinly clad with soft parts which have but a scanty blood-supply. And finally, after slight injuries, they are not maintained in a condition of rest to the same extent as similar injuries in some other parts of the body. Caries of the calcaneum and astragalus may remain limited to the one bone for a long period, but when one of the other bones is affected, the remainder frequently become involved, in consequence of the disease spreading through the large and complicated synovial membrane which is more or less common to these bones.

Amputation of the whole or a part of the foot is frequently required either for injury or disease. The principal amputations are as follow: (1) Syme's: amputations at the ankle-joint by a heel-flap, with removal of the malleoli and sometimes a thin slice from the lower end of the tibia. (2) Roux's: amputation at the ankle-joint by a large internal flap. (3) Pirogoff's amputation: removal of the whole of the tarsal bones, except the posterior part of the os calcis, and a thin slice from the tibia and fibula including the two malleoli. The sawn surface of the os calcis is then turned up and united to the similar surface of the tibia. (4) Subastragaloid amputation: removal of the foot below the astragalus through the joint between it and the os calcis. This operation has been modified by Hancock, who leaves the posterior third of the os calcis and turns it up against the denuded surface of the astragalus. This latter operation is of doubtful utility, and is rarely performed. (5) Chopart's or medio-tarsal: removal of the anterior part of the foot with all the tarsal bones except the os calcis and astragalus; disarticulation being effected through the joints between the scaphoid and cuboid in front, and the astragalus and os calcis behind. (6) Lisfranc's: amputation of the anterior part of the foot through the tarso-metatarsal joints. This has been modified by Hey, who disarticulated through the joints of the four outer metatarsal bones with the tarsus, and sawed off the projecting internal cuneiform; and by Skey, who sawed off the base of the second metatarsal bone and disarticulated the others.

The bones of the tarsus occasionally require removal individually. This is especially the case with the astragalus and os calcis for disease limited to the one bone, or again the astragalus may require excision in cases of subastragaloid dislocation, or, as recommended by Mr. Lund, in cases of inveterate talipes. The cuboid has been removed for the same reason by Mr. Solly. But both these two latter operations have fallen very much into disuse, and have been superseded by resection of a wedge-shaped piece of bone from the outer side of the tarsus. Finally, Mickulicz and Watson have devised operations for the removal of more extensive portions of the tarsus. Mickulicz's operation consists in the removal of the os calcis and astragalus, along with the articular surfaces of the tibia and fibula, and also of the scaphoid and cuboid. The remaining portion of the tarsus is then brought into contact with the sawn surfaces of the tibia and fibula, and fixed there. The result is a position of the shortened foot resembling talipes equinus. Watson's operation is adapted to those cases where the disease is confined to the anterior tarsal bones. By two lateral incisions he saws through the bases of the metatarsal bones in front and opens up the joints between the scaphoid and astragalus, and the cuboid and os calcis, and removes the intervening bones.

The metatarsal bones and phalanges are nearly always broken by direct violence, and in the majority of cases the injury is the result of severe crushing accidents, necessitating amputation. The metatarsal bones, and especially the one of the great toe, are frequently diseased, either in tuberculous subjects or in perforating ulcer of the foot.



## SESAMOID BONES

These are small rounded masses, cartilaginous in early life, osseous in the adult, which are developed in those tendons which exert a great amount of pressure upon the parts over which they glide. It is said that they are more commonly found in the male than in the female, and in persons of an active muscular habit than in those who are weak and debilitated. They are invested throughout their whole surface by the fibrous tissue of the tendon in which they are found, excepting upon that side which lies in contact with the part over which they play, where they present a free articular facet. They may be divided into two kinds : those which glide over the articular surfaces of joints, and those which play over the cartilaginous facets found on the surfaces of certain bones.

The sesamoid bones of the joints in the upper extremity are two on the palmar surface of the metacarpo-phalangeal joint in the thumb, developed in the tendons of the *Flexor brevis pollicis* ; occasionally one or two opposite the metacarpo-phalangeal articulations of the fore and little fingers ; and, still more rarely, one opposite the same joints of the third and fourth fingers. In the lower extremity, the patella, which is developed in the tendon of the *Quadriceps extensor* ; two small sesamoid bones, found in the tendons of the *Flexor brevis hallucis*, opposite the metatarso-phalangeal joint of the great toe ; and occasionally one in the metatarso-phalangeal joint of the second toe, the little toe, and, still more rarely, the third and fourth toes.

Those found in the tendons which glide over certain bones occupy the following situations : one sometimes found in the tendon of the *Biceps cubiti*, opposite the tuberosity of the radius ; one in the tendon of the *Peroneus longus*, where it glides through the groove in the cuboid bone ; one appears late in life in the tendon of the *Tibialis anticus*, opposite the smooth facet of the internal cuneiform bone ; one is found in the tendon of the *Tibialis posticus*, opposite the inner side of the head of the astragalus ; one in the outer head of the *Gastrocnemius*, behind the outer condyle of the femur ; and one in the conjoined tendon of the *Psoas* and *Iliacus*, where it glides over the os pubis. Sesamoid bones are found occasionally in the tendon of the *Gluteus maximus*, as it passes over the great trochanter ; and in the tendons which wind round the inner and outer malleoli.

# THE ARTICULATIONS

**T**HE various bones of which the Skeleton consists are connected together at different parts of their surfaces, and such a connection is designated by the name of *Joint* or *Articulation*. If the joint is *immovable*, as between the cranial and most of the facial bones, the adjacent margins of the bones are applied in almost close contact, a thin layer of fibrous membrane, the *sutural ligament*, and, at the base of the skull, in certain situations, a thin layer of cartilage being interposed. Where slight movement is required, combined with great strength, the osseous surfaces are united by tough and elastic fibro-cartilages, as in the joints of the spine, the sacro-iliac and interpubic articulations; but in the *movable* joints, the bones forming the articulation are generally expanded for greater convenience of mutual connection, covered by *cartilage*, held together by strong bands or capsules of fibrous tissue, called *ligaments*, and partially lined by a membrane, the *synovial membrane*, which secretes a fluid to lubricate the various parts of which the joint is formed: so that the structures which enter into the formation of a joint are bone, cartilage, fibro-cartilage, ligament, and synovial membrane.

**Bone** constitutes the fundamental element of all the joints. In the long bones, the extremities are the parts which form the articulations; they are generally somewhat enlarged, consisting of spongy cancellous tissue with a thin coating of compact substance. In the flat bones, the articulations usually take place at the edges; and in the short bones at various parts of their surface. The layer of compact bone which forms the articular surface, and to which the cartilage is attached, is called the *articular lamella*. It is of white colour, extremely dense, and varies in thickness. Its structure differs from ordinary bone-tissue in this respect, that it contains no Haversian canals, and its lacunæ are much larger than in ordinary bone, and have no canaliculi. The vessels of the cancellous tissue, as they approach the articular lamella, turn back in loops, and do not perforate it; this layer is consequently more dense and firmer than ordinary bone, and is evidently designed to form a firm and unyielding support for the articular cartilage.

The **cartilage** which covers the articular surfaces of bone, and is called *articular*, will be found described, with the other varieties of cartilage, in the section on General Anatomy (page 21).

**Ligaments** consist of bands of various forms, serving to connect together the articular extremities of bones, and composed mainly of bundles of *white fibrous tissue* placed parallel with, or closely interlaced with one another, and presenting a white, shining silvery aspect. A ligament is pliant and flexible, so as to allow of the most perfect freedom of movement, but strong, tough, and inextensible, so as not readily to yield under the most severely applied force; it is consequently well adapted to serve as the connecting medium between the bones. Some ligaments consist entirely of *yellow elastic tissue*, as the ligamenta subflava, which connect together the adjacent arches of the vertebræ, and the ligamentum nuchæ in the lower animals. In these cases it will be observed that the elasticity of the ligament is intended to act as a substitute for muscular power.

**Synovial membrane** is a thin, delicate membrane of connective tissue, with branched connective-tissue corpuscles. Its secretion is thick, viscid, and glairy, like the white of an egg; and is hence termed *synovia*. The synovial membranes found in the body admit of subdivision into three kinds—articular, bursal, and vaginal.

The *articular synovial membranes* are found in all the freely movable joints. In the fœtus this membrane is said, by Toynebee, to be continued over the surface of the cartilages; but in the adult it is wanting, excepting at their circumference, upon which it encroaches for a short distance and to which it is firmly attached: it then invests the inner surface of the capsular or other ligaments enclosing the

joint, and is reflected over the surface of any tendons passing through its cavity, as the tendon of the Popliteus in the knee, and the tendon of the Biceps in the shoulder. Hence the articular synovial membrane may be regarded as a short wide tube, attached by its open ends to the margins of the articular cartilages and covering the inner surface of the various ligaments which connect the articular surfaces, so that along with the cartilages it completely encloses the joint cavity. In some of the joints the synovial membrane is thrown into folds, which pass across the cavity. They are called *synovial ligaments*, and are especially distinct in the knee. In other joints there are flattened folds, subdivided at their margins into fringe-like processes, the vessels of which have a convoluted arrangement. These latter generally project from the synovial membrane near the margin of the cartilage, and lie flat upon its surface. They consist of connective tissue, covered with endothelium, and contain fat-cells in variable quantities, and, more rarely, isolated cartilage-cells. The larger folds often contain considerable quantities of fat. They were described, by Clopton Havers, as *mucilaginous glands*, and as the source of the synovial secretion. Under certain diseased conditions, similar processes are found covering the entire surface of the synovial membrane, forming a mass of pedunculated fibro-fatty growths, which projects into the joint. Similar structures are also found in some of the bursal and vaginal synovial membranes.

The *bursal synovial membranes* are found interposed between surfaces which move upon each other, producing friction, as in the gliding of a tendon, or of the integument over projecting bony surfaces. They admit of subdivision into two kinds, the *bursæ mucosæ* and the *bursæ synoviæ*. The *bursæ mucosæ* are large, simple, or irregular cavities in the subcutaneous areolar tissue, enclosing a clear viscid fluid. They are found in various situations, as between the integument and the front of the patella, over the olecranon, the malleoli, and other prominent parts. The *bursæ synoviæ* are found interposed between muscles or tendons as they play over projecting bony surfaces, as between the Glutei muscles and the surface of the great trochanter. They consist of a thin wall of connective tissue, partially covered by patches of cells, and contain a viscid fluid. Where one of these exists in the neighbourhood of a joint, it usually communicates with its cavity, as is generally the case with the bursa between the tendon of the Psoas and Iliacus and the capsular ligament of the hip, or the one interposed between the under surface of the Subscapularis and the neck of the scapula.

The *vaginal synovial membranes (synovial sheaths)* serve to facilitate the gliding of tendons in the osseo-fibrous canals through which they pass. The membrane is here arranged in the form of a sheath, one layer of which adheres to the wall of the canal, and the other is reflected upon the surface of the contained tendon; the space between the two free surfaces of the membrane being partially filled with the synovia. These sheaths are chiefly found surrounding the tendons of the flexor and extensor muscles of the fingers and toes, as they pass through the osseo-fibrous canals in the hand or foot.

**Synovia** is a transparent, yellowish-white, or slightly reddish fluid, viscid like the white of egg, having an alkaline reaction and slightly saline taste. It consists, according to Frerichs, in the ox, of 94·85 water, 0·56 mucus and epithelium, 0·07 fat, 3·51 albumen and extractive matter, and 0·99 salts.

The articulations are divided into three classes: *synarthrosis*, or immovable; *amphiarthrosis*, or mixed; and *diarthrosis*, or movable joints.

#### I. SYNARTHROSIS: IMMOVABLE ARTICULATIONS

**Synarthrosis** includes all those articulations in which the surfaces of the bones are in almost direct contact, fastened together by an intervening mass of connective tissue, and in which there is no appreciable motion, as the joints between the bones of the cranium and face, excepting those of the lower jaw. The varieties of synarthrosis are four in number: Sutura, Schindylesis, Gomphosis, and Synchondrosis.



**Sutura** (*a seam*) is that form of articulation where the contiguous margins of flat bones are united by a thin layer of fibrous tissue. It is met with only in the skull. When the articulating surfaces are connected by a series of processes and indentations interlocked together, it is termed *sutura vera*; of which there are three varieties: *sutura dentata*, *serrata*, and *limbosa*. The surfaces of the bones are not in direct contact, being separated by a layer of membrane, continuous externally with the pericranium, internally with the dura mater. The *sutura dentata* (*dens, a tooth*) is so called from the tooth-like form of the projecting articular processes, as in the suture between the parietal bones. In the *sutura serrata* (*serra, a saw*) the edges of the two bones forming the articulation are serrated like the teeth of a fine saw, as between the two portions of the frontal bone. In the *sutura limbosa* (*limbus, a selvage*), besides the dentated processes, there is a certain degree of bevelling of the articular surfaces, so that the bones overlap one another, as in the suture between the parietal and frontal bones. When the articulation is formed by roughened surfaces placed in apposition with one another, it is termed the *false suture* (*sutura notha*), of which there are two kinds, the *sutura squamosa* (*squama, a scale*), formed by the overlapping of two contiguous bones by broad bevelled margins, as in the squamo-parietal (squamous) suture; and the *sutura harmonia* (*ἄρμονία, a joining together*), where there is simple apposition of two contiguous rough bony surfaces, as in the articulation between the two superior maxillary bones, or of the horizontal plates of the palate bones.

**Schindylesis** (*σχινδύλησις, a fissure*) is that form of articulation in which a thin plate of bone is received into a cleft or fissure formed by the separation of two laminae in another bone, as in the articulation of the rostrum of the sphenoid and perpendicular plate of the ethmoid with the vomer, or in the reception of the latter in the fissure between the superior maxillary and palate bones.

**Gomphosis** (*γόμφος, a nail*) is an articulation formed by the insertion of a conical process into a socket, as a nail is driven into a board; this is not illustrated by any articulation between bones, properly so called, but is seen in the articulation of the teeth with the alveoli of the maxillary bones.

**Synchondrosis**.—Where the connecting medium is cartilage the joint is termed a synchondrosis. This is a temporary form of joint, for the cartilage becomes converted into bone before adult life. Such a joint is found between the epiphyses and shafts of long bones.

## 2. AMPHIARTHROSIS. MIXED ARTICULATIONS

In this form of articulation, the contiguous osseous surfaces are either connected together by broad flattened discs of fibro-cartilage, of a more or less complex structure, which adhere to the end of each bone, as in the articulation between the bodies of the vertebræ, and the sacro-iliac and pubic symphyses. This is termed **Symphysis**. Or, secondly, the bony surfaces are united by an interosseous ligament, as in the inferior tibio-fibular articulation. To this the term **Syndesmosis** is applied.

## 3. DIARTHROSIS. MOVABLE ARTICULATIONS

This form of articulation includes the greater number of the joints in the body, mobility being their distinguishing character. They are formed by the approximation of two contiguous bony surfaces, covered with cartilage, connected by ligaments, and lined by synovial membrane. The varieties of joints in this class have been determined by the kind of motion permitted in each. There are two varieties in which the movement is uniaxial, that is to say, all movements take place around one axis. In one form, the Ginglymus, this axis is practically speaking transverse; in the other, the trochoid or pivot-joint, it is longitudinal. There are two varieties where the movement is biaxial, or around two horizontal axes at right angles to each other, or at any intervening axis between the two. These are the condyloid and saddle-joint. There is one form of joint where the

movement is polyaxial, the enarthrosis or ball-and-socket joint. And finally there are the Arthrodia or Gliding joints.

**Ginglymus or Hinge-joint** (*γίγγλυμος, a hinge*).—In this form of joint the articular surfaces are moulded to each other in such a manner as to permit motion only in one plane, forwards and backwards; the extent of motion at the same time being considerable. The direction which the distal bone takes in this motion is never in the same plane as that of the axis of the proximal bone, but there is always a certain amount of alteration from the straight line during flexion. The articular surfaces are connected together by strong lateral ligaments, which form their chief bond of union. The most perfect forms of ginglymus are the interphalangeal joints and the joint between the humerus and ulna; the knee and ankle are less perfect, as they allow a slight degree of rotation or lateral movement in certain positions of the limb.

**Trochoides** (*pivot-joint*).—Where the movement is limited to rotation, the joint is formed by a pivot-like process turning within a ring, or the ring on the pivot, the ring being formed partly of bone, partly of ligament. In the superior radio-ulnar articulation, the ring is formed partly by the lesser sigmoid cavity of the ulna; in the rest of its extent, by the orbicular ligament; here, the head of the radius rotates within the ring. In the articulation of the odontoid process of the axis with the atlas, the ring is formed in front by the anterior arch of the atlas; behind, by the transverse ligament; here the ring rotates round the odontoid process.

**Condyloid Articulations**.—In this form of joint, an ovoid articular head, or condyle, is received into an elliptical cavity in such a manner as to permit of flexion and extension, adduction and abduction and circumduction, but no axial rotation. The articular surfaces are connected together by anterior, posterior, and lateral ligaments. An example of this form of joint is found in the wrist.

**Articulations by Reciprocal Reception** (*saddle-joint*).—In this variety the articular surfaces are concavo-convex; that is to say, they are inversely convex in one direction and concave in the other. The movements are the same as in the preceding form; that is to say, there is flexion, extension, adduction, abduction, and circumduction, but no axial rotation. The articular surfaces are connected by a capsular ligament. The best example of this form of joint is the carpo-metacarpal joint of the thumb.

**Enarthrosis** is that form of joint in which the distal bone is capable of motion around an indefinite number of axes, which have one common centre. It is formed by the reception of a globular head into a deep cup-like cavity (hence the name 'ball-and-socket'), the parts being kept in apposition by a capsular ligament strengthened by accessory ligamentous bands. Examples of this form of articulation are found in the hip and shoulder.

**Arthrodia** is that form of joint which admits of a gliding movement; it is formed by the approximation of plane surfaces, or one slightly concave, the other slightly convex; the amount of motion between them being limited by the ligaments, or osseous processes, surrounding the articulation; as in the articular processes of the vertebræ, the carpal joints, except that of the os magnum with the scaphoid and semilunar bones, and the tarsal joints with the exception of the joint between the astragalus and the navicular.

On the next page, in a tabular form, are the names, distinctive characters, and examples of the different kinds of articulations.

#### THE KINDS OF MOVEMENT ADMITTED IN JOINTS

The movements admissible in joints may be divided into four kinds: gliding, angular movement, circumduction, and rotation. These movements are often, however, more or less combined in the various joints, so as to produce an infinite variety, and it is seldom that we find only one kind of motion in any particular joint.

*Synarthrosis*,  
or Immovable  
Joint. Surfaces  
separated by fibrous membrane, without any intervening synovial cavity, and immovably connected with each other.

As in joints of cranium and face (except lower jaw).

*Amphiarthrosis*,  
Mixed Articulation.

*Diarthrosis*,  
Movable Joint.

*Sutura*. Articulation by processes and indentations interlocked together.

*Sutura vera*  
(true) articulate  
by indented borders.

*Sutura notha*  
(false) articulate  
by rough surfaces.

*Dentata*, having tooth-like processes.

As in interparietal suture.

*Serrata*, having serrated edges like the teeth of a saw.

As in interfrontal suture.

*Limboza*, having bevelled margins, and dentated processes.

As in fronto-parietal suture.

*Squamosa*, formed by thin bevelled margins, overlapping each other.

As in squamo-parietal suture.

*Harmonia*, formed by the apposition of contiguous rough surfaces.

As in intermaxillary suture.

*Schindylesis*.—Articulation formed by the reception of a thin plate of one bone into a fissure of another.

As in articulation of rostrum of sphenoid with vomer.

*Gomphosis*.—Articulation formed by the insertion of a conical process into a socket.

The teeth.

*Symphysis*.—Surfaces connected by fibro-cartilage, not separated by synovial membrane, and having limited motion.

As in joints between bodies of vertebræ.

*Syndesmosis*.—Surfaces united by an interosseous ligament. As in the inferior tibio-fibular articulation.

*Ginglymus*.—Hinge-joint; motion limited to two directions, forwards and backwards. Articular surfaces fitted together so as to permit of movement in one plane. As in the inter-phalangeal joints and the joint between the humerus and the ulna.

*Trochoides or Pivot-joint*.—Articulation by a pivot process turning within a ring, or ring around a pivot. As in superior radio-ulnar articulation, and atlanto-axial joint.

*Condylloid*.—Ovoid head received into elliptical cavity. Movements in every direction except axial rotation. As the wrist-joint.

*Reciprocal Reception (Saddle-joint)*.—Articular surfaces inversely convex in one direction and concave in the other. Movement in every direction except axial rotation. As in the carpo-metacarpal joint of the thumb.

*Enarthrosis*.—Ball-and-socket joint; capable of motion in all directions. Articulations by a globular head received into a cup-like cavity. As in hip- and shoulder-joints.

*Arthrodia*.—Gliding-joint; articulations by plane surfaces, which glide upon each other. As in carpal and tarsal articulations.



*Gliding movement* is the most simple kind of motion that can take place in a joint, one surface gliding or moving over another without any angular or rotatory movement. It is common to all movable joints; but in some, as in most of the articulations of the carpus and tarsus, it is the only motion permitted. This movement is not confined to plane surfaces, but may exist between any two contiguous surfaces, of whatever form, limited by the ligaments which enclose the articulation.

*Angular movement* occurs only between the long bones, and by it the angle between the two bones is increased or diminished. It may take place in four directions: forwards and backwards, constituting flexion and extension, or inwards and outwards, from the mesial line of the body (or in the fingers and toes from the middle line of the hand or foot), constituting adduction and abduction. The strictly ginglymoid or hinge-joints admit of flexion and extension only. Abduction and adduction, combined with flexion and extension, are met with in the more movable joints; as in the hip, shoulder, and metacarpal joint of the thumb, and partially in the wrist.

*Circumduction* is that limited degree of motion which takes place between the head of a bone and its articular cavity, whilst the extremity and sides of the limb are made to circumscribe a conical space, the base of which corresponds with the inferior extremity of the limb, the apex with the articular cavity; this kind of motion is best seen in the shoulder- and hip-joints.

*Rotation* is the movement of a bone upon an axis, which is the axis of the pivot on which the bone turns, as in the articulation between the atlas and axis, where the odontoid process serves as a pivot around which the atlas turns; or else is the axis of a pivot-like process which turns within a ring, as in the rotation of the radius upon the humerus.

*Ligamentous Action of Muscles.*—The movements of the different joints of a limb are combined by means of the long muscles which pass over more than one joint, and which, when relaxed and stretched to their greatest extent, act to a certain extent as elastic ligaments in restraining certain movements of one joint, except when combined with corresponding movements of the other—these latter movements being usually in the opposite direction. Thus the shortness of the hamstring muscles prevents complete flexion of the hip, unless the knee-joint is also flexed, so as to bring their attachments nearer together. The uses of this arrangement are threefold. 1. It co-ordinates the kinds of movement which are the most habitual and necessary, and enables them to be performed with the least expenditure of power. ‘Thus in the usual gesture of the arms, whether in grasping or rejecting, the shoulder and the elbow are flexed simultaneously, and simultaneously extended, in consequence of the passage of the Biceps and Triceps cubiti over both joints.’ 2. It enables the short muscles which pass over only one joint to act upon more than one. ‘Thus, if the Rectus femoris remain tonically of such length that, when stretched over the extended hip, it compels extension of the knee, then the Gluteus maximus becomes, not only an extensor of the hip, but an extensor of the knee as well.’ 3. It provides the joints with ligaments which, while they are of very great power in resisting movements to an extent incompatible with the mechanism of the joint, at the same time spontaneously yield when necessary. ‘Taxed beyond its strength a ligament will be ruptured, whereas a contracted muscle is easily relaxed; also, if neighbouring joints be united by ligaments, the amount of flexion or extension of each must remain in constant proportion to that of the other; while, if the union be by muscles, the separation of the points of attachment of those muscles may vary considerably in different varieties of movement, the muscles adapting themselves tonically to the length required.’ The quotations are from a very interesting paper by Dr. Cleland in the ‘Journal of Anatomy and Physiology,’ No. 1, 1866, p. 85; by whom I believe this important fact in the mechanism of joints was first clearly pointed out, though it has been independently observed afterwards by other anatomists. Dr. W. W. Keen points out how important it is ‘that the

surgeon should remember this ligamentous action of muscles in making passive motion—for instance, at the wrist after Colles' fracture. If the fingers be extended, the wrist can be flexed to a right angle. If, however, they be first flexed as in "making a fist," flexion at the wrist is quickly limited to from forty to fifty degrees in different persons, and is very painful beyond that point. Hence passive motion here should be made with the fingers extended. In the leg, when flexing the hip, the knee should be flexed.' Dr. Keen further points out that 'a beautiful illustration of this is seen in the perching of birds, whose toes are forced to clasp the perch by just such a passive ligamentous action so soon as they stoop. Hence they can go to sleep and not fall off the perch.'

The articulations may be arranged into those of the trunk, those of the upper extremity, and those of the lower extremity.

## ARTICULATIONS OF THE TRUNK

These may be divided into the following groups, viz. :—

- |  |   |
|--|---|
| I. Of the vertebral column.                | VII. Of the cartilages of the ribs with the sternum, and with each other. |
| II. Of the atlas with the axis.            | VIII. Of the sternum.   |
| III. Of the atlas with the occipital bone. | IX. Of the vertebral column with the pelvis.                              |
| IV. Of the axis with the occipital bone.   | X. Of the pelvis.   |
| V. Of the lower jaw.                       |   |
| VI. Of the ribs with the vertebræ.         |   |

### I. ARTICULATIONS OF THE VERTEBRAL COLUMN

The different segments of the spine are connected together by ligaments, which admit of the same arrangement as the vertebræ. They may be divided into five sets. 1. Those connecting the *bodies* of the vertebræ. 2. Those connecting the *laminae*. 3. Those connecting the *articular processes*. 4. Those connecting the *spinous processes*. 5. Those connecting the *transverse processes*.

The articulations of the *bodies* of the vertebræ with each other form a series of amphiarthrodial joints; those between the *articular processes* form a series of arthrodial joints.

#### 1. THE LIGAMENTS OF THE BODIES

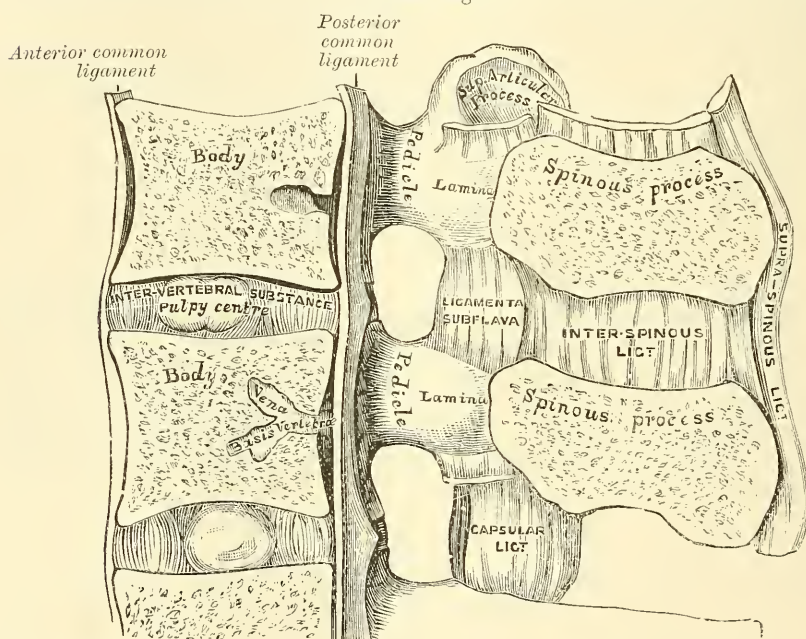
Anterior Common Ligament.	Posterior Common Ligament.
Intervertebral Substance.	

The **Anterior Common Ligament** (figs. 263, 264, 271, 275) is a broad and strong band of ligamentous fibres, which extends along the front surface of the bodies of the vertebræ, from the axis to the sacrum. It is broader below than above, thicker in the dorsal than in the cervical or lumbar regions, and somewhat thicker opposite the front of the body of each vertebra than opposite the intervertebral substance. It is attached, above, to the body of the axis by a pointed process, where it is continuous with the anterior atlanto-axial ligament, and is connected with the tendon of insertion of the Longus colli muscle, and extends down as far as the upper bone of the sacrum. It consists of dense longitudinal fibres, which are intimately adherent to the intervertebral substance, and the prominent margins of the vertebræ; but less closely to the middle of the bodies. In the latter situation the fibres are exceedingly thick, and serve to fill up the concavities on their front surface, and to make the anterior surface of the spine more even. This ligament is composed of several layers of fibres, which vary in length, but are closely interlaced with each other. The most superficial or longest fibres extend between four or five vertebræ. A second subjacent set extend between two or three vertebræ; whilst a third set, the

shortest and deepest, extend from one vertebra to the next. At the sides of the bodies the ligament consists of a few short fibres, which pass from one vertebra to the next, separated from the median portion by large oval apertures, for the passage of vessels.

The **Posterior Common Ligament** (figs. 263, 267) is situated within the spinal canal, and extends along the posterior surface of the bodies of the vertebræ, from the body of the axis above, where it is continuous with the occipito-axial ligament, to the sacrum below. It is broader above than below, and thicker in the dorsal than in the cervical or lumbar regions. In the situation of the intervertebral substance and contiguous margins of the vertebræ, where the ligament is more intimately adherent, it is broad, and presents a series of dentations with intervening concave margins; but it is narrow and thick over the centre of the bodies, from which it is separated by the *vena basis vertebræ*. This ligament is composed of smooth, shining, longitudinal fibres, denser and more compact than those of the anterior ligament, and composed of a superficial layer occupying

FIG. 263.—Vertical section of two vertebræ and their ligaments, from the lumbar region.



the interval between three or four vertebræ, and of a deeper layer which extends between one vertebra and the next adjacent to it. It is separated from the dura mater of the spinal cord by some loose connective tissue which is very liable to serous infiltration.

The **Intervertebral Substance** (figs. 263, 272) is a lenticular disc of composite structure interposed between the adjacent surfaces of the bodies of the vertebræ, from the axis to the sacrum, and forming the chief bond of connection between these bones. The discs vary in shape, size, and thickness, in different parts of the spine. In *shape* they accurately correspond with the surfaces of the bodies between which they are placed, being oval in the cervical and lumbar regions, and circular in the dorsal. Their *size* is greatest in the lumbar region. In *thickness* they vary not only in the different regions of the spine, but in different parts of the same disc: thus, they are much thicker in front than behind in the cervical and lumbar regions, while they are uniformly thick in the dorsal region. The intervertebral discs form about one-fourth of the spinal column, exclusive of the first two vertebræ; they are not equally distributed, however, between



the various bones; the dorsal portion of the spine having, in proportion to its length, a much smaller quantity than the cervical and lumbar regions, which necessarily gives to the latter parts greater pliancy and freedom of movement. The intervertebral discs are adherent, by their surfaces, to a thin layer of hyaline cartilage which covers the upper and under surfaces of the bodies of the vertebræ, and in which in early life the epiphysial plate develops; and by their circumference are closely connected in front to the anterior, and behind to the posterior common ligament; whilst in the dorsal region they are connected laterally, by means of the interarticular ligament, to the heads of those ribs which articulate with two vertebræ: they, consequently, form part of the articular cavities in which the heads of these bones are received.

**Structure of the Intervertebral Substance.**—The intervertebral substance is composed, at its circumference, of laminae of fibrous tissue and fibro-cartilage; and, at its centre, of a soft, pulpy, highly elastic substance, of a yellowish colour, which rises up considerably above the surrounding level when the disc is divided horizontally. This pulpy substance, which is especially well developed in the lumbar region, is the remains of the chorda dorsalis, and, according to Luschka, contains a small synovial cavity in its centre. The laminae are arranged concentrically one within the other, the outermost consisting of ordinary fibrous tissue, but the others and more numerous consisting of white fibro-cartilage. These plates are not quite vertical in their direction, those near the circumference being curved outwards and closely approximated; whilst those nearest the centre curve in the opposite direction, and are somewhat more widely separated. The fibres of which each plate is composed are directed, for the most part, obliquely from above downwards; the fibres of adjacent plates passing in opposite directions and varying in every layer: so that the fibres of one layer are directed across those of another, like the limbs of the letter X. This laminar arrangement belongs to about the outer half of each disc. The pulpy substance presents no concentric arrangement, and consists of a fine fibrous matrix, containing angular cells, united to form a reticular structure.

## 2. LIGAMENTS CONNECTING THE LAMINÆ

### Ligamenta Subflava.

The **Ligamenta Subflava** (fig. 263) are interposed between the laminae of the vertebræ, from the axis to the sacrum. They are most distinct when seen from the interior of the spinal canal: when viewed from the outer surface they appear short, being overlapped by the laminae. Each ligament consists of two lateral portions, which commence on each side at the root of either articular process, and pass backwards to the point where the laminae converge to form the spinous process, where their margins are in contact and to a certain extent united; slight intervals being left for the passage of small vessels. These ligaments consist of yellow elastic tissue, the fibres of which, almost perpendicular in direction, are attached to the anterior surface of the lamina above, some distance from its inferior margin, and to the posterior surface, as well as to the margin of the lamina below. In the cervical region they are thin in texture, but very broad and long; they become thicker in the dorsal region; and in the lumbar acquire very considerable thickness. Their highly elastic property serves to preserve the upright posture, and to assist the spine in resuming it, after it has been flexed. These ligaments do not exist between the occiput and atlas, or between the atlas and axis.

## 3. LIGAMENTS CONNECTING THE ARTICULAR PROCESSES

### Capsular.

The **Capsular Ligaments** (fig. 265) are thin and loose ligamentous sacs, attached to the contiguous margins of the articulating processes of each vertebra, through

the greater part of their circumference, and completed internally by the ligamenta subflava. They are longer and looser in the cervical than in the dorsal or lumbar regions. The capsular ligaments are lined on their inner surface by synovial membrane.

#### 4. LIGAMENTS CONNECTING THE SPINOUS PROCESSES

Supraspinous.

Interspinous.

The **Supraspinous Ligament** (fig. 263) is a strong fibrous cord, which connects together the apices of the spinous processes from the seventh cervical to the spinous processes of the sacrum. It is thicker and broader in the lumbar than in the dorsal region, and intimately blended, in both situations, with the neighbouring aponeurosis. The most superficial fibres of this ligament connect three or four vertebræ; those deeper-seated pass between two or three vertebræ; whilst the deepest connect the contiguous extremities of neighbouring vertebræ. It is continued upwards to the external occipital protuberance, as the ligamentum nuchæ, which, in the human subject, is thin, and forms merely an intermuscular septum.

The **Interspinous Ligaments** (fig. 263), thin and membranous, are interposed between the spinous processes. These ligaments extend from the root to the summit of each spinous process, and are connected with the ligamenta subflava in front and the supraspinous ligament behind. They are narrow and elongated in the dorsal region; broader, quadrilateral in form, and thicker in the lumbar region; and only slightly developed in the neck.

#### 5. LIGAMENTS CONNECTING THE TRANSVERSE PROCESSES

Intertransverse.

The **Intertransverse Ligaments** consist of bundles of fibres, interposed between the transverse processes. In the cervical region they consist of a few irregular, scattered fibres; in the dorsal, they are rounded cords intimately connected with the deep muscles of the back; in the lumbar region they are thin and membranous.

**Actions.**—The movements permitted in the spinal column are, Flexion, Extension, Lateral Movement, Circumduction, and Rotation.

In *Flexion*, or movement of the spine forwards, the anterior common ligament is relaxed, and the intervertebral substances are compressed in front; while the posterior common ligament, the ligamenta subflava, and the inter- and supraspinous ligaments are stretched, as well as the posterior fibres of the intervertebral discs. The interspaces between the laminae are widened, and the inferior articular processes of the vertebræ above glide upwards, upon the articular processes of the vertebræ below. Flexion is the most extensive of all the movements of the spine.

In *Extension*, or movement of the spine backwards, an exactly opposite disposition of the parts takes place. This movement is not extensive, being limited by the anterior common ligament, and by the approximation of the spinous processes.

Flexion and extension are most free in the lower part of the lumbar region between the third and fourth and fourth and fifth lumbar vertebræ; above the third they are much diminished, and reach their minimum in the middle and upper part of the back. They increase again in the neck, the capability of motion backwards from the upright position being in this region greater than that of the motion forwards, whereas in the lumbar region the reverse is the case.

In *Lateral Movement*, the sides of the intervertebral discs are compressed, the extent of motion being limited by the resistance offered by the surrounding ligaments, and by the approximation of the transverse processes. This movement may take place in any part of the spine, but is most free in the neck and loins.

*Circumduction* is very limited, and is produced merely by a succession of the preceding movements.

*Rotation* is produced by the twisting of the intervertebral substances; this, although only slight between any two vertebrae, produces a great extent of movement, when it takes place in the whole length of the spine, the front of the upper part of the column being turned to one or the other side. This movement takes place only to a slight extent in the neck, but is freer in the upper part of the dorsal region, and is altogether absent in the lumbar region.

It is thus seen that the *cervical region* enjoys the greatest extent of each variety of movement, flexion and extension especially being very free. In the *dorsal region*, the three movements of flexion, extension, and circumduction are only permitted to a slight extent; while rotation is very free in the upper part and ceases below. In the lumbar region there is free flexion, extension, and lateral movement, but no rotation.

As Sir George Humphry has pointed out, the movements permitted are mainly due to the shape and position of the articulating processes. In the loins the inferior articulating processes are turned outwards and embraced by the superior; this renders rotation in this region of the spine impossible, while there is nothing to prevent a sliding upwards and downwards of the surfaces on each other so as to allow of flexion and extension. In the dorsal region, on the other hand, the articulating processes, by their direction and mutual adaptation, especially at the upper part of the series, permit of rotation, but prevent extension and flexion; while in the cervical region the greater obliquity and lateral slant of the articular processes allow not only flexion and extension, but also rotation.

The principal muscles which produce *flexion* are the Sterno-mastoid, Rectus capitus anticus major, and Longus colli; the Scaleri; the abdominal muscles and the Psoas magnus. *Extension* is produced by the fourth layer of the muscles of the back, assisted in the neck by the Splenius, Semispinalis dorsi et colli, and the Multifidus spinæ. *Lateral* motion is produced by the fourth layer of the muscles of the back, by the Splenius and the Scaleri, the muscles of one side only acting; and *rotation* by the action of the following muscles of one side only, viz. the Sterno-mastoid, the Rectus capitus anticus major, the Scaleri, the Multifidus spinæ, the Complexus, and the abdominal muscles.

## II. ARTICULATION OF THE ATLAS WITH THE AXIS

The articulation of the Atlas with the Axis is of a complicated nature, comprising no fewer than four distinct joints. There is a pivot articulation between the odontoid process of the axis and the ring formed between the anterior arch of the atlas and the transverse ligament (see fig. 266). Here there are two joints: one in front between the posterior surface of the anterior arch of the atlas and the front of the odontoid process (the *atlo-odontoid joint of Cruveilhier*); the other between the anterior surface of the transverse ligament and the back of the process (the *syndesmo-odontoid joint*). Between the articulating processes of the two bones there is a double arthrodia or gliding joint. The ligaments which connect these bones are the

Two Anterior Atlanto-axial.

Posterior Atlanto-axial.

Transverse.

Two Capsular.

Of the **Two Anterior Atlanto-axial Ligaments** (fig. 264), the more superficial is a rounded cord, situated in the middle line; it is attached, above, to the tubercle on the anterior arch of the atlas; below, to the base of the odontoid process and to the front of the body of the axis. The deeper ligament is a membranous layer, attached, above, to the lower border of the anterior arch of the atlas; below, to the base of the odontoid process, and front of the

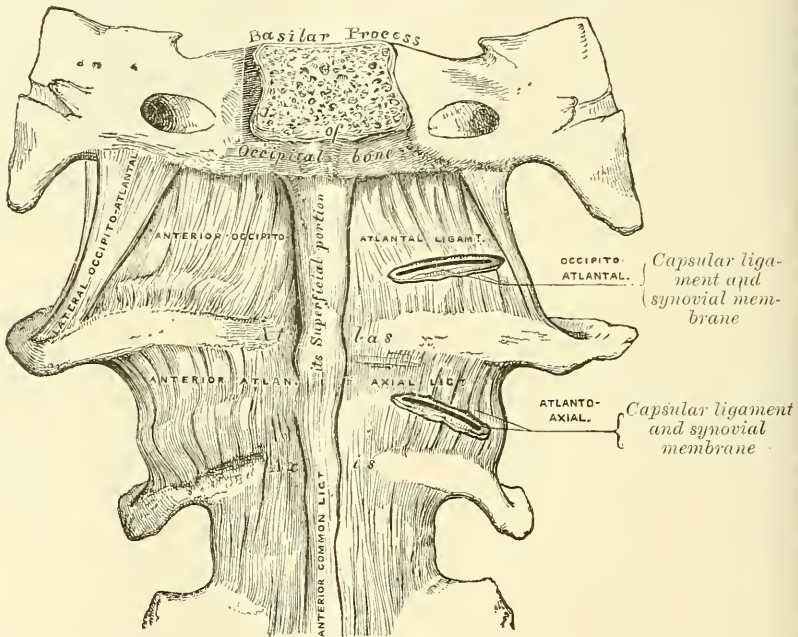


body of the axis. These ligaments are in relation, in front, with the *Recti antici majores*.

The **Posterior Atlanto-axial Ligament** (fig. 265) is a broad and thin membranous layer, attached, above, to the lower border of the posterior arch of the atlas; below, to the upper edge of the laminae of the axis. This ligament supplies the place of the *ligamenta subflava*, and is in relation, behind, with the *Inferior oblique* muscles.

The **Transverse Ligament** \* (figs. 266, 267) is a thick and strong ligamentous band, which arches across the ring of the atlas, and serves to retain the odontoid process in firm connection with its anterior arch. This ligament is flattened from before backwards, broader and thicker in the middle than at either extremity, and firmly attached on each side to a small tubercle on the inner surface of the lateral mass of the atlas. As it crosses the odontoid process, a small fasciculus is derived from its upper and lower borders; the former passing upwards, to be

FIG. 264.—Occipito-atloid and atlo-axoid ligaments. Front view.



inserted into the basilar process of the occipital bone; the latter, downwards, to be attached to the posterior surface of the body of the axis; hence, the whole ligament has received the name of *cruciform*. The transverse ligament divides the ring of the atlas into two unequal parts: of these, the posterior and larger serves for the transmission of the cord and its membranes and the spinal accessory nerves; the anterior and smaller contains the odontoid process. Since the space between the anterior arch of the atlas and the transverse ligament is smaller at the lower part than the upper (because the transverse ligament embraces firmly the narrow neck of the odontoid process), this process is retained in firm connection with the atlas after all the other ligaments have been divided.

The **Capsular Ligaments** are two thin and loose capsules, connecting the articular processes of the atlas and axis, the fibres being strongest on the posterior and inner part of the articulation.

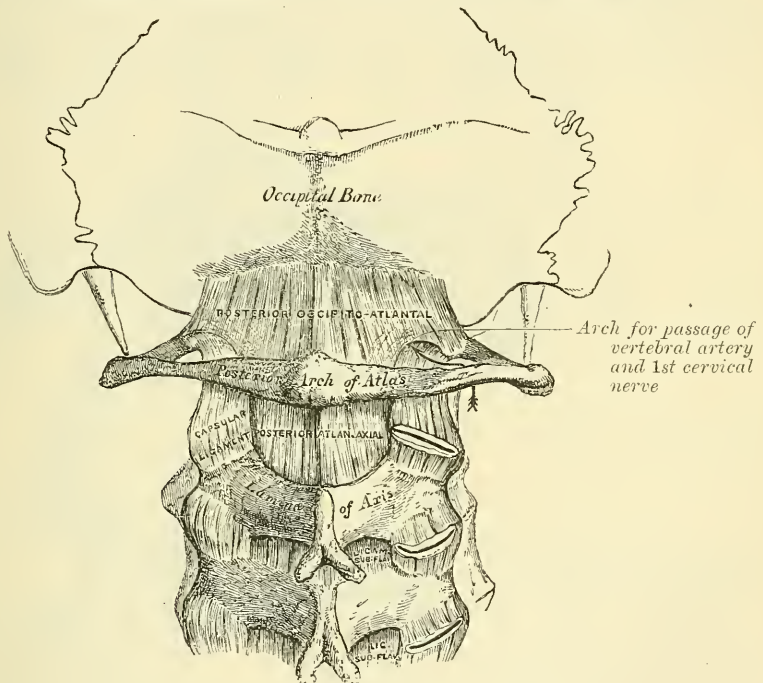
\* It has been found necessary to describe the transverse ligament with those of the atlas and axis; but the student must remember that it is really a portion of the mechanism by which the movements of the head on the spine are regulated; so that the connections between the atlas and axis ought always to be studied together with those between the latter bones and the skull.

There are *four Synovial Membranes* in this articulation: one lining the inner surface of each of the capsular ligaments; one between the anterior surface of the odontoid process and the anterior arch of the atlas, the *atlo-odontoid joint*; and one between the posterior surface of the odontoid process and the transverse ligament, the *syndesmo-odontoid joint*. The latter often communicates with those between the condyles of the occipital bone and the articular surfaces of the atlas.

**Actions.**—This joint allows the rotation of the atlas (and, with it, of the cranium) upon the axis, the extent of rotation being limited by the odontoid ligaments.

The principal muscles by which this action is produced are the Sternomastoid and Complexus of one side, acting with the Rectus capitis anticus major, Splenius, Trachelo-mastoid, Rectus capitis posticus major, and Inferior oblique of the other side.

FIG. 265.—Occipito-atloid and atlo-axoid ligaments. Posterior view.



### ARTICULATIONS OF THE SPINE WITH THE CRANIUM

The ligaments connecting the spine with the cranium may be divided into two sets, those connecting the occipital bone with the atlas, and those connecting the occipital bone with the axis.

#### III. ARTICULATION OF THE ATLAS WITH THE OCCIPITAL BONE

This articulation is a double condyloid joint. Its ligaments are, the

Two Anterior Occipito-atlantal.

Two Lateral Occipito-atlantal.

Posterior Occipito-atlantal.

Two Capsular.

Of the **Two Anterior Occipito-atlantal Ligaments** (fig. 264) the superficial is a strong, narrow, rounded cord, attached, above, to the basilar process of the occiput; below, to the tubercle on the anterior arch of the atlas: the deeper ligament is a broad and thin membranous layer which passes between the anterior margin of the foramen magnum above, and the whole length of

the upper border of the anterior arch of the atlas below. This ligament is in relation, in front, with the *Recti antici minores*; behind, with the odontoid ligaments.

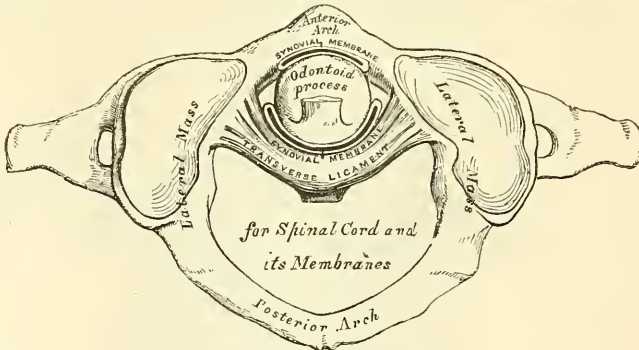
The **Posterior Occipito-atlantal Ligament** (fig. 265) is a very broad but thin membranous lamina, intimately blended with the dura mater. It is connected, above, to the posterior margin of the foramen magnum; below, to the upper border of the posterior arch of the atlas. This ligament is incomplete at each side, and forms, with the superior intervertebral notch, an opening for the passage of the vertebral artery and suboccipital nerve. It is in relation, behind, with the *Recti postici minores* and *Obliqui superiores*; in front, with the dura mater of the spinal canal, to which it is intimately adherent.

The **Lateral Ligaments** are strong fibrous bands, directed obliquely upwards and inwards, attached above to the jugular process of the occipital bone; below, to the base of the transverse process of the atlas.

The **Capsular Ligaments** surround the condyles of the occipital bone, and connect them with the articular processes of the atlas; they consist of thin and loose capsules, which enclose the synovial membrane of the articulation.

**Synovial Membranes.**—There are two synovial membranes in this articulation: one lining the inner surface of each of the capsular ligaments. These

FIG. 266.—Articulation between odontoid process and atlas.



occasionally communicate with that between the posterior surface of the odontoid process and the transverse ligament.

**Actions.**—The movements permitted in this joint are flexion and extension, which give rise to the ordinary forward and backward nodding of the head, besides slight lateral motion to one or the other side. When either of these actions is carried beyond a slight extent, the whole of the cervical portion of the spine assists in its production. Flexion is mainly produced by the action of the *Rectus capitis anticus major et minor* and the *Sterno-mastoid* muscles; extension by the *Rectus capitis posticus major et minor*, the *Superior oblique*, the *Complexus*, *Splenius*, and upper fibres of the *Trapezius*. The *Recti laterales* are concerned in the lateral movement, assisted by the *Trapezius*, *Splenius*, *Complexus*, *Sterno-mastoid* and the *Recti laterales* of the same side, all acting together. According to Cruveilhier, there is a slight motion of rotation in this joint.

#### IV. ARTICULATION OF THE AXIS WITH THE OCCIPITAL BONE

##### Occipito-axial.

##### Three Odontoid

To expose these ligaments, the spinal canal should be laid open by removing the posterior arch of the atlas, the laminae and spinous process of the axis, and the portion of the occipital bone behind the foramen magnum, as seen in fig. 267.

The **Occipito-axial Ligament** (*apparatus ligamentosus colli*) is situated within the spinal canal. It is a broad and strong ligamentous band which covers the

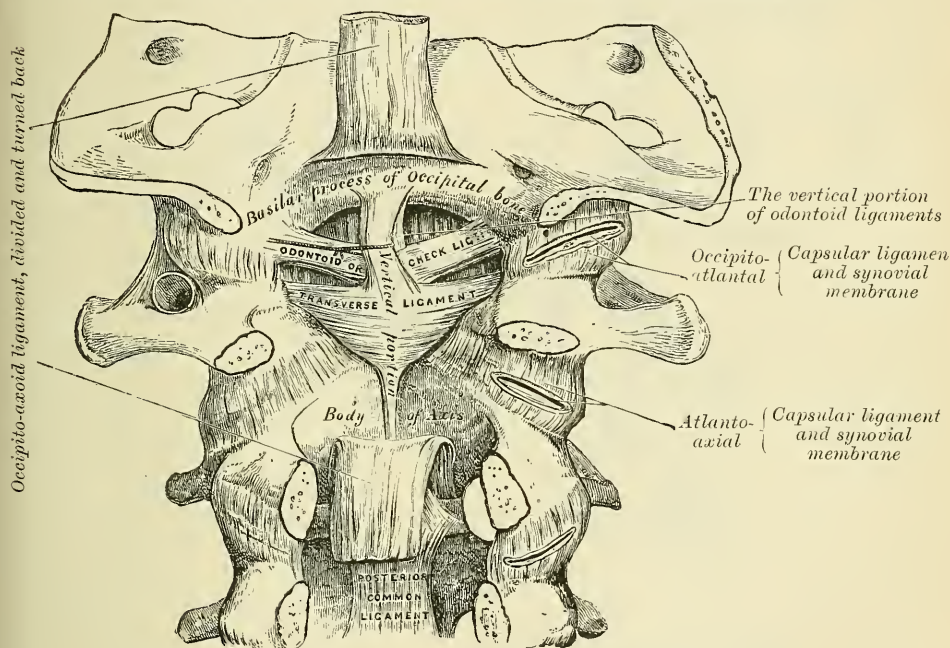


odontoid process and its ligaments, and appears to be a prolongation upwards of the posterior common ligament of the spine. It is attached, below, to the posterior surface of the body of the axis, and, becoming expanded as it ascends, is inserted into the basilar groove of the occipital bone, in front of the foramen magnum, where it becomes blended with the dura mater of the skull.

**Relations.**—By its anterior surface with the transverse ligament, by its posterior surface with the dura mater.

The **Odontoid or Check Ligaments** (*alar ligaments*) are strong, rounded, fibrous cords, which arise one on either side of the upper part of the odontoid process, and, passing obliquely upwards and outwards, are inserted into the rough depressions on the inner side of the condyles of the occipital bone. In the triangular interval left between these ligaments another strong fibrous cord (*ligamentum suspensorium* or *middle odontoid ligament*) may be seen, which

FIG. 267.—Occipito-axoid and atlo-axoid ligaments. Posterior view, obtained by removing the arches of the vertebrae and the posterior part of the skull.



passes almost perpendicularly from the apex of the odontoid process to the anterior margin of the foramen magnum, being intimately blended with the deep portion of the anterior occipito-atloid ligament, and upper fasciculus of the transverse ligament of the atlas.

**Actions.**—The odontoid ligaments serve to limit the extent to which rotation of the cranium may be carried; hence they have received the name of *check ligaments*.

In addition to these ligaments which connect the atlas and axis to the skull, the ligamentum nuchæ must be regarded as one of the ligaments by which the spine is connected with the cranium. It is described on a subsequent page.

**Surgical Anatomy.**—The ligaments which unite the component parts of the vertebrae together are so strong, and these bones are so interlocked by the arrangement of their articulating processes, that dislocation is very uncommon, and, indeed, unless accompanied by fracture, rarely occurs, except in the upper part of the neck. Dislocation of the occiput from the atlas has only been recorded in one or two cases; but dislocation of the atlas from the axis, with rupture of the transverse ligament, is much more common: it is the

mode in which death is produced in many cases of execution by hanging. In the lower part of the neck—that is, below the third cervical vertebra—dislocation unattended by fracture occasionally takes place.

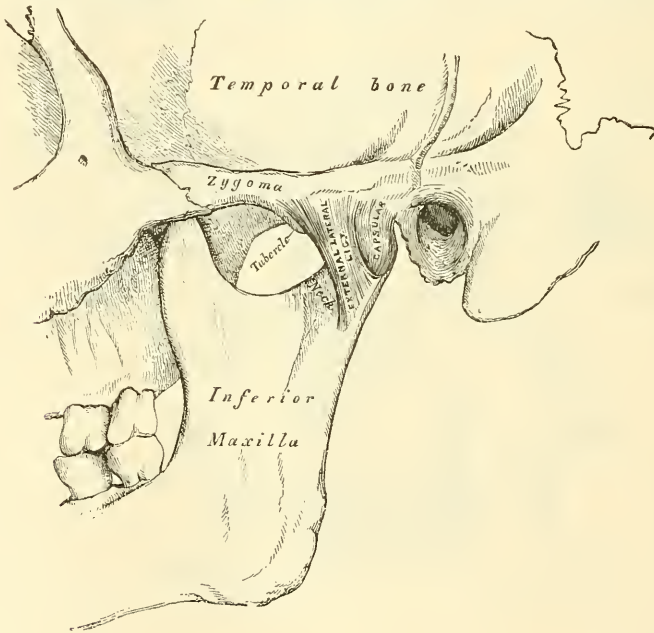
#### V. ARTICULATION OF THE LOWER JAW (TEMPORO-MAXILLARY)

This is a ginglymo-arthrodial joint; the parts entering into its formation on each side are, above, the anterior part of the glenoid cavity of the temporal bone and the eminentia articularis; and, below, the condyle of the lower jaw. The ligaments are the following:—

External Lateral.	Stylo-maxillary.
Internal Lateral.	Capsular.
Interarticular Fibro-cartilage.	

The **External Lateral Ligament** (fig. 268) is a short, thin, and narrow fasciculus attached, above, to the outer surface of the zygoma and to the tubercle on

FIG. 268.—Temporo-maxillary articulation. External view.



its lower border; below, to the outer surface and posterior border of the neck of the lower jaw. It is broader above than below; its fibres are placed parallel with one another, and directed obliquely downwards and backwards. Externally, it is covered by the parotid gland, and by the integument. Internally, it is in relation with the capsular ligament of which it is an accessory band, and not separable from it.

The **Internal Lateral Ligament** (fig. 269) is a flat thin band which is attached above to the spinous process of the sphenoid bone, and, becoming broader as it descends, is inserted into the lingula and margin of the dental foramen. Its outer surface is in relation, above, with the External pterygoid muscle; lower down, it is separated from the neck of the condyle by the internal maxillary artery; and still more inferiorly, the inferior dental vessels and nerve separate it from the ramus of the jaw. The inner surface is in relation with the Internal pterygoid. It is really the fibrous covering of a part of Meckel's cartilage. (see p. 93).

The **Stylo-maxillary Ligament** is a specialised band of the cervical fascia, which extends from near the apex of the styloid process of the temporal bone to the angle and posterior border of the ramus of the lower jaw, between the Masseter and Internal pterygoid muscles. This ligament separates the parotid from the submaxillary gland, and has attached to its inner side part of the fibres of origin of the Stylo-glossus muscle. Although usually classed among the ligaments of the jaw, it can only be considered as an accessory to the articulation.

The **Capsular Ligament** forms a thin and loose ligamentous capsule, attached above to the circumference of the glenoid cavity and the articular surface immediately in front; below, to the neck of the condyle of the lower jaw. It consists of a few thin scattered fibres, and can hardly be considered as a distinct ligament; it is thickest at the back part of the articulation.\*

The **Interarticular Fibro-cartilage** (fig. 270) is a thin plate of an oval form, placed horizontally between the condyle of the jaw and the glenoid cavity. Its upper surface is concavo-convex from before backwards, and a little convex transversely, to accommodate itself to the form of the glenoid cavity. Its under surface, where it is in contact with the condyle, is concave. Its circumference is connected to the capsular ligament; and in front to the tendon of the External pterygoid muscle. It is thicker at its circumference, especially behind, than at its centre. The fibres of which it is composed have a concentric arrangement, more apparent at the circumference than at the centre. Its surfaces are smooth. It divides the joint into two cavities, each of which is furnished with a separate synovial membrane.

The **Synovial Membranes**, two in number, are placed one above, and the other below, the fibro-cartilage. The upper one, the larger and looser of the two, is continued from the margin of the cartilage covering the glenoid cavity and eminentia articularis on to the upper surface of the fibro-cartilage. The lower one passes from the under surface of the fibro-cartilage to the neck of the condyle of the jaw, being prolonged downwards a little further behind than in front.

\* Sir G. Humphry describes the internal portion of the capsular ligament separately, as the short internal lateral ligament; and it certainly seems as deserving of a separate description as the external lateral ligament is.

FIG. 269.—Temporo-maxillary articulation. Internal view.

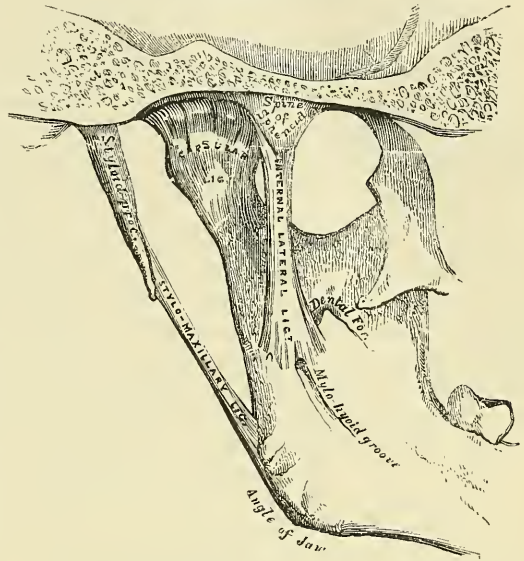
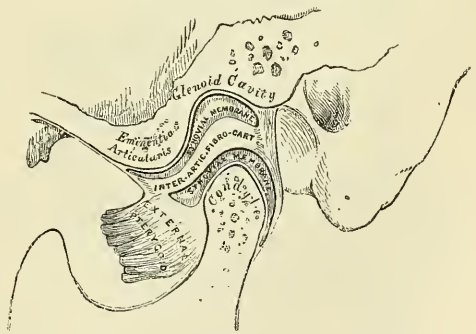


FIG. 270.—Vertical section of temporo-maxillary articulation.





The interarticular cartilage is sometimes perforated in its centre, the two synovial sacs then communicate with each other.

The *nerves* of this joint are derived from the auriculo-temporal and masseteric branches of the inferior maxillary. The *arteries* are derived from the temporal branch of the external carotid.

**Actions.**—The movements permitted in this articulation are very extensive. Thus, the jaw may be depressed or elevated, or it may be carried forwards or backwards. It must be borne in mind that there are two distinct joints in this articulation—that is to say, one between the condyle of the jaw and the interarticular fibro-cartilage, and another between the fibro-cartilage and the glenoid fossa; when the jaw is depressed, as in opening the mouth, the movements which take place in these two joints are not the same. In the lower compartment, that between the condyle and the fibro-cartilage, the movement is of a ginglymoid or hinge-like character, the condyle rotating on a transverse axis on the fibro-cartilage; whilst in the upper compartment the movement is of a gliding character, the fibro-cartilage, together with the condyle, gliding forwards on to the eminentia articularis. These two movements take place simultaneously, the condyle and fibro-cartilage move forwards on the eminence, and at the same time the condyle revolves on the fibro-cartilage. In the opposite movement of shutting the mouth the reverse action takes place; the fibro-cartilage glides back, carrying the condyle with it, and this at the same time revolves back to its former position. When the jaw is carried horizontally forwards, as in protruding the lower incisors in front of the upper, the movement takes place principally in the upper compartment of the joint, the fibro-cartilage, carrying with it the condyle, glides forwards on the glenoid fossa. This is because this movement is mainly effected by the External pterygoid muscles, which are inserted into both condyle and interarticular fibro-cartilage. The grinding or chewing movement is produced by the alternate movement of one condyle, with its fibro-cartilage, forwards and backwards, while the other condyle moves simultaneously in the opposite direction; at the same time the condyle undergoes a vertical rotation on its own axis on the fibro-cartilage in the lower compartment. One condyle advances and rotates, the other condyle recedes and rotates, in alternate succession.

The lower jaw is *depressed* by its own weight, assisted by the Platysma, the Digastric, the Mylo-hyoid, and the Genio-hyoid. It is *elevated* by the anterior part of the Temporal, Masseter, and Internal pterygoid. It is drawn *forwards* by the simultaneous action of the External pterygoid, and the superficial fibres of the Masseter; and it is drawn *backwards* by the deep fibres of the Masseter and the posterior fibres of the Temporal muscle. The grinding movement is caused by the alternate action of the two External pterygoids.

*Surface Form.*—The temporo-maxillary articulation is quite superficial, situated below the base of the zygoma, in front of the tragus and external auditory meatus, and behind the posterior border of the upper part of the Masseter muscle. Its exact position can be at once ascertained by feeling for the condyle of the jaw, the working of which can be distinctly felt in the movements of the lower jaw in opening and shutting the mouth. When the mouth is opened wide, the condyle advances out of the glenoid fossa on to the eminentia articularis and a depression is felt in the situation of the joint.

*Surgical Anatomy.*—The lower jaw is dislocated only in one direction—viz. forwards. The accident is caused by violence or muscular action. When the mouth is open, the condyle is situated on the eminentia articularis, and any sudden violence, or even a sudden muscular spasm as during a convulsive yawn, may displace the condyle forwards into the zygomatic fossa. The displacement may be unilateral or bilateral, according as one or both of the condyles are displaced. The latter of the two is the more common.

Sir Astley Cooper described a condition which he termed 'subluxation.' It occurs principally in delicate women, and is believed by some to be due to relaxation of the ligaments, permitting too free movement of the bone, and possibly some displacement of the fibro-cartilage. Others have believed that it is due to gouty or rheumatic changes in the joint. In close relation to the condyle of the jaw is the external auditory meatus and the tympanum; any force, therefore, applied to the bone is liable to be attended with damage to these parts, or inflammation in the joint may extend to the ear, or on the other hand

inflammation of the middle ear may involve the articulation and cause its destruction, thus leading to ankylosis of the joint. In children, arthritis of this joint may also follow the exanthemata, and in adults occurs as the result of some constitutional conditions, as rheumatism or gout. The temporo-maxillary joint is also frequently the seat of osteo-arthritis, leading to great suffering during efforts of mastication. A peculiar affection sometimes attacks the neck and condyle of the lower jaw, consisting in hypertrophy and elongation of these parts and consequent protrusion of the chin to the opposite side.

VI. ARTICULATIONS OF THE RIBS WITH THE VERTEBRÆ

The articulations of the ribs with the vertebral column may be divided into two sets: 1. Those which connect the heads of the ribs with the bodies of the vertebræ (*costo-central*). 2. Those which connect the necks and tubercles of the ribs with the transverse processes (*costo-transverse*).

1. ARTICULATIONS BETWEEN THE HEADS OF THE RIBS AND THE BODIES OF THE VERTEBRÆ (fig. 271)

These constitute a series of arthrodial joints, formed by the articulation of the heads of the ribs with the cavities on the contiguous margins of the bodies of the dorsal vertebræ and the intervertebral substance between them, except in the case of the first, tenth, eleventh, and twelfth ribs, where the cavity is formed by a single vertebra. The bones are connected by the following ligaments:—

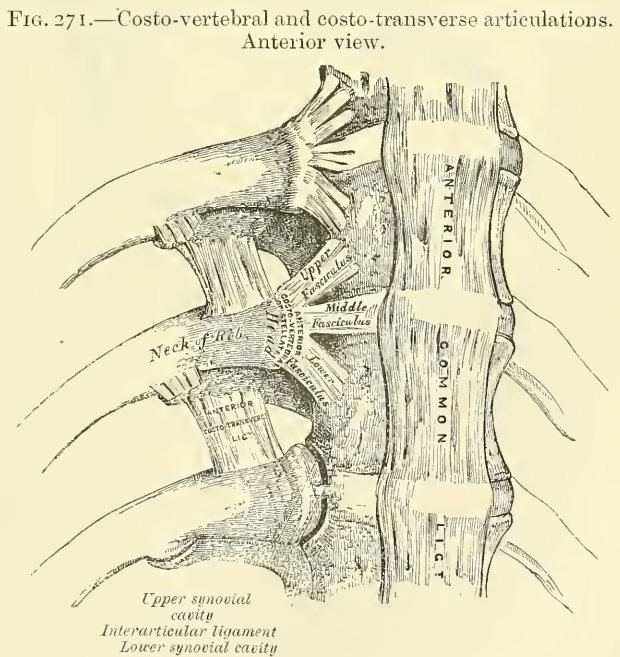
- Anterior Costo-vertebral or Stellate.
- Capsular.
Interarticular.

The **Anterior Costo-vertebral or Stellate Ligament** connects the anterior part of the head of each rib with the sides of the bodies of two vertebræ, and the intervertebral disc between them. It consists of flat bundles of ligamentous fibres, which are

attached to the anterior part of the head of the rib, just beyond the articular surface. The superior fibres pass upwards to be connected with the body of the vertebra above; the inferior ones descend to the body of the vertebra below; and the middle ones, the smallest and least distinct, pass horizontally inwards, to be attached to the intervertebral substance.

*Relations.*—In front, with the thoracic ganglia of the sympathetic, the pleura, and, on the right side, with the vena azygos major; behind, with the interarticular ligament and synovial membranes.

In the first rib, which articulates with a single vertebra, this ligament does not present a distinct division into three fasciculi; its fibres, however, radiate, and are attached to the body of the last cervical vertebra, as well as to the body

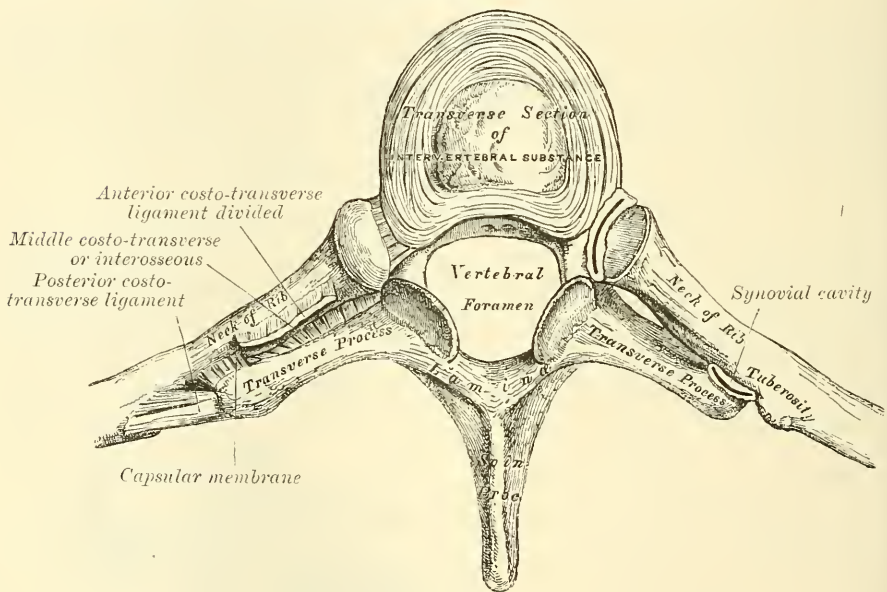


of the vertebra with which the rib articulates. In the tenth, eleventh, and twelfth ribs, which also articulate with a single vertebra, the division does not exist; but the fibres of the ligament in each case radiate and are connected with the vertebra above, as well as that with which the ribs articulate.

The **Capsular Ligament** is a thin and loose ligamentous bag, which surrounds the joint between the head of the rib and the articular cavity formed by the intervertebral disc and the adjacent vertebræ. It is very thin, firmly connected with the anterior ligament, and most distinct at the upper and lower parts of the articulation. Behind, some of its fibres pass through the intervertebral foramen to the back of the intervertebral disc. This is the analogue of the ligamentum conjugale of some mammals, which unites the heads of opposite ribs across the back of the intervertebral disc.

The **Interarticular Ligament** is situated in the interior of the joint. It consists of a short band of fibres, flattened from above downwards, attached by one extremity to the sharp crest which separates the two articular facets on the head

FIG. 272.—Costo-transverse articulation. Seen from above.



of the rib, and by the other to the intervertebral disc. It divides the joint into two cavities, which have no communication with each other. In the first, tenth, eleventh, and twelfth ribs, the interarticular ligament does not exist; consequently, there is but one synovial membrane.

**The Synovial Membrane.**—There are two synovial membranes in each of the articulations in which there is an interarticular ligament, one on each side of this structure.

## 2. ARTICULATIONS OF THE NECKS AND TUBERCLES OF THE RIBS WITH THE TRANSVERSE PROCESSES (fig. 272)

The articular portion of the tubercle of the rib and adjacent transverse process form an arthrodial joint.

In the *eleventh* and *twelfth ribs* this articulation is wanting.

The ligaments connecting these parts are the—

- Anterior Costo-transverse.
- Middle Costo-transverse (Interosseous).
- Posterior Costo-transverse.
- Capsular.



The **Anterior Costo-transverse Ligament** (*superior* or *long*) consists of two sets of fibres: the one (anterior) is attached below to the sharp crest on the upper border of the neck of each rib, and passes obliquely upwards and outwards, to the lower border of the transverse process immediately above; the other (posterior) is attached below to the neck of the rib, and passes upwards and inwards to the base of the transverse process and outer border of the lower articular process of the vertebra above. This ligament is in relation, in front, with the intercostal vessels and nerves; behind, with the Longissimus dorsi. Its *internal border* is thickened and free, and bounds an aperture through which pass the posterior branches of the intercostal vessels and nerves. Its *external border* is continuous with a thin aponeurosis, which covers the External intercostal muscle.

The *first rib* has no anterior costo-transverse ligament.

The **Middle Costo-transverse** or **Interosseous Ligament** consists of short but strong fibres, which pass between the rough surface on the posterior part of the neck of each rib and the anterior surface of the adjacent transverse process. In order fully to expose this ligament a horizontal section should be made across the transverse process and corresponding part of the rib; or the rib may be forcibly separated from the transverse process, and its fibres put on the stretch.

In the *eleventh* and *twelfth ribs* this ligament is quite rudimentary or wanting.

The **Posterior Costo-transverse Ligament** is a short but thick and strong fasciculus, which passes obliquely from the summit of the transverse process to the rough non-articular portion of the tubercle of the rib. This ligament is shorter and more oblique in the upper than in the lower ribs. Those corresponding to the superior ribs ascend, while those of the inferior ribs descend slightly.

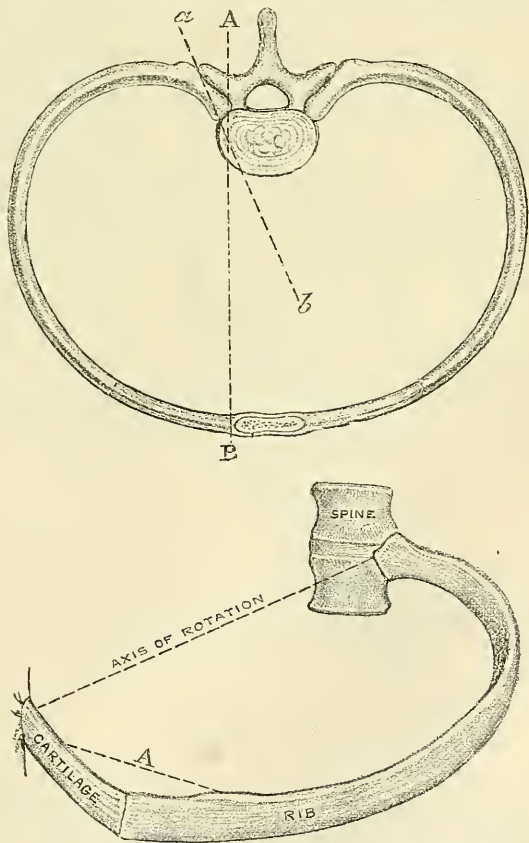
In the *eleventh* and *twelfth ribs* this ligament is wanting.

The **Capsular Ligament** is a thin, membranous sac attached to the circumference of the articular surfaces, and enclosing a small synovial membrane.

In the *eleventh* and *twelfth ribs* this ligament is absent.

**Actions.**—The heads of the ribs are so closely connected to the bodies of the vertebræ by the stellate and interarticular ligaments, and the necks and tubercles of the ribs to the transverse processes, that only a slight gliding movement of

FIG. 273.—Diagrams showing the axis of rotation of the ribs in the movements of respiration. The one axis of rotation corresponds with a line drawn through the two articulations which the rib forms with the spine (*a, b*), and the other with a line drawn from the head of the rib to the sternum (*A, B*). (From Kirke's 'Handbook of Physiology.')



the articular surfaces on each other can take place in these articulations. The result of this gliding movement is an elevation of the front and middle portion of the rib, the hinder part being prevented from performing any upward movement by its close connection with the spine. In this gliding movement there are two axes of rotation—that is to say, the rib rotates on an axis corresponding with a line drawn through the two articulations, Costo-central and Costo-transverse, which the rib forms with the spine; and secondly, it rotates on an axis corresponding with a line drawn from the head of the rib to the sternum. By the first movement—that of rotation of the rib on an axis corresponding with a line drawn through the two articulations which this bone forms with the spine—an elevation of the anterior part of the rib takes place, and a consequent enlargement of the antero-posterior diameter of the chest. None of the ribs lie in a truly horizontal plane: they are all directed more or less obliquely, so that their anterior extremities lie on a lower level than their posterior, and this obliquity increases from the first to the seventh, and then again decreases. If we examine any one rib—say, that in which there is the greatest obliquity—we shall see that it is obvious that as its sternal extremity is carried upwards, it must also be thrown forwards; so that the rib may be regarded as a radius, moving on the vertebral joint as a centre, and causing the sternal attachment to describe an arc of a circle in the vertical plane of the body. Since all the ribs are oblique and connected in front to the sternum by the elastic costal cartilages, they must have a tendency to thrust the sternum forwards, and so increase the antero-posterior diameter of the chest. By the second movement—that of the rotation of the rib on an axis corresponding with a line drawn from the head of the rib to the sternum—an elevation of the middle portion of the rib takes place, and consequently an increase in the transverse diameter of the chest. For the ribs not only slant downwards and forwards from their vertebral attachment, but they are also oblique in relation to their transverse plane—that is to say, their middle is on a lower level than either their vertebral or sternal extremities. It results from this that when the ribs are raised, the centre portion is thrust outwards, somewhat after the fashion in which the handle of a bucket is thrust away from the side when raised to a horizontal position, and the lateral diameter of the chest is increased (see fig. 273). The mobility of the different ribs varies very much. The first rib is more fixed than the others, on account of the weight of the upper extremity and the strain of the ribs beneath; but on the freshly dissected thorax it moves as freely as the others. From the same causes the movement of the second rib is also not very extensive. In the other ribs, this mobility increases successively down to the last two, which are very movable. The ribs are generally more movable in the female than in the male.

#### VII. ARTICULATION OF THE CARTILAGES OF THE RIBS WITH THE STERNUM, ETC. (fig. 274)

The articulations of the cartilages of the true ribs with the sternum are arthrodial joints, with the exception of the first, in which the cartilage is almost always directly united with the sternum, and which must, therefore, be regarded as a synarthrodial articulation. The ligaments connecting them are—

Anterior Chondro-sternal.	Interarticular Chondro-sternal.
Posterior Chondro-sternal.	Anterior Chondro-xiphoid.
Capsular.	Posterior Chondro-xiphoid.

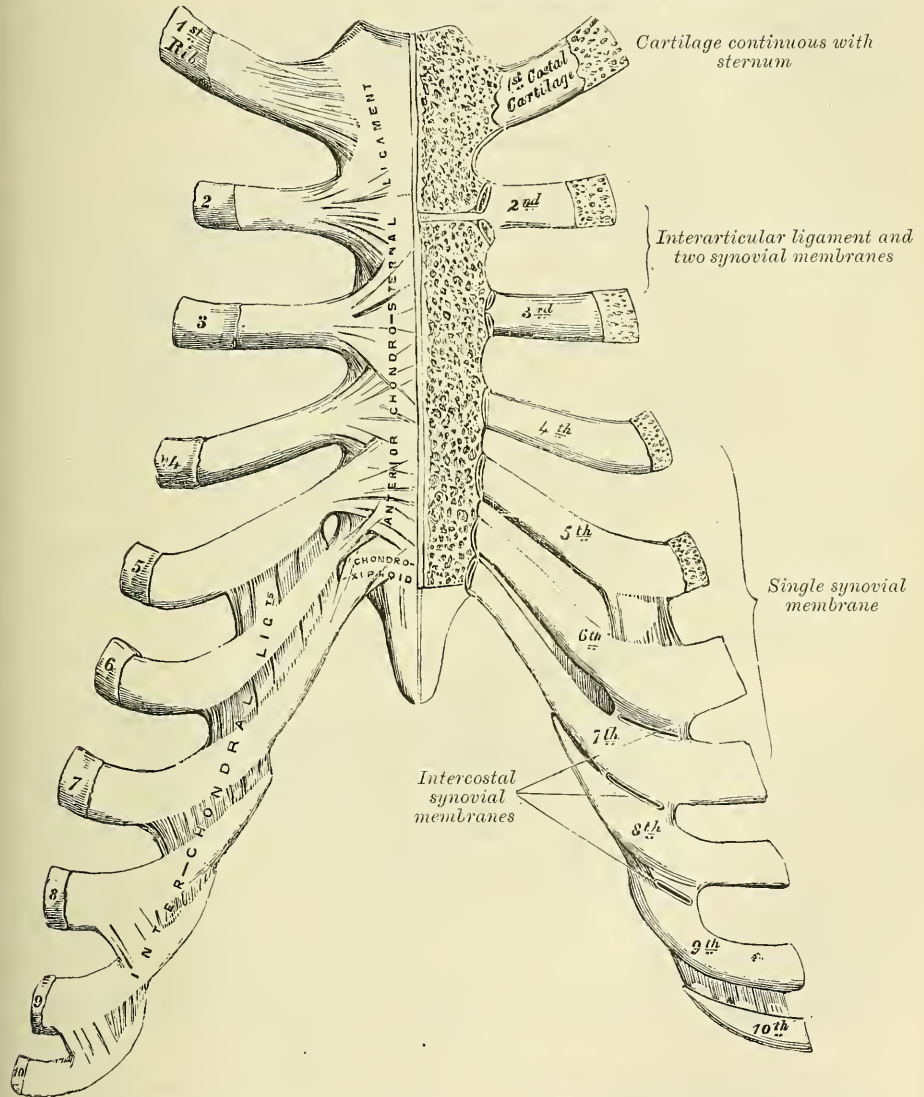
The **Anterior Chondro-sternal Ligament** is a broad and thin membranous band that radiates from the front of the inner extremity of the cartilages of the true ribs to the anterior surface of the sternum. It is composed of fasciculi which pass in different directions. The *superior fasciculi* ascend obliquely, the *inferior* pass obliquely downwards, and the *middle fasciculi* horizontally. The superficial fibres of this ligament are the longest; they intermingle with the fibres of the

ligaments above and below them, with those of the opposite side, and with the tendinous fibres of origin of the Pectoralis major, forming a thick fibrous membrane, which covers the surface of the sternum. This is more distinct at the lower than at the upper part.

The **Posterior Chondro-sternal Ligament**, less thick and distinct than the anterior, is composed of fibres which radiate from the posterior surface of the

FIG. 274.—Chondro-sternal, chondro-xiphoid, and interchondral articulations. Anterior view.

*The synovial cavities exposed by a vertical section of the sternum and cartilage*



sternal end of the cartilages of the true ribs to the posterior surface of the sternum, becoming blended with the periosteum.

The **Capsular Ligament** surrounds the joints formed between the cartilages of the true ribs and the sternum. It is very thin, intimately blended with the anterior and posterior ligaments, and strengthened at the upper and lower part of the articulation by a few fibres, which pass from the cartilage to the side of the sternum. These ligaments protect the synovial membranes.



**The Interarticular Chondro-sternal Ligaments.**—These are only found between the second and third costal cartilages and the sternum. The cartilage of the *second rib* is connected with the sternum by means of an interarticular ligament, attached by one extremity to the cartilage of the second rib, and by the other extremity to the cartilage which unites the first and second pieces of the sternum. This articulation is provided with two synovial membranes. The cartilage of the *third rib* is connected with the sternum by means of an interarticular ligament which is attached by one extremity to the cartilage of the third rib, and by the other extremity to the point of junction of the second and third pieces of the sternum. This articulation is provided with two synovial membranes.

**The Anterior Chondro-xiphoid.**—This is a band of ligamentous fibres, which connects the anterior surface of the seventh costal cartilage, and occasionally also that of the sixth, to the anterior surface of the ensiform appendix. It varies in length and breadth in different subjects.

The **Posterior Chondro-xiphoid** is a similar band of fibres on the internal or posterior surface, though less thick and distinct.

**Synovial Membranes.**—There is no synovial membrane between the first costal cartilage and the sternum, as this cartilage is directly continuous with the sternum. There are two synovial membranes both in the articulation of the second and third costal cartilages to the sternum. There is generally one synovial membrane in each of the joints between the fourth, fifth, sixth, and seventh costal cartilages to the sternum; but it is sometimes absent in the sixth and seventh chondro-sternal joints. Thus there are *eight* synovial cavities on each side in the articulations between the costal cartilages of the true ribs and the sternum. After middle life the articular surfaces lose their polish, become roughened, and the synovial membranes appear to be wanting. In old age, the articulations do not exist, the cartilages of most of the ribs becoming continuous with the sternum.

**Actions.**—The movements which are permitted in the chondro-sternal articulations are limited to elevation and depression, and these only to a slight extent.

#### ARTICULATIONS OF THE CARTILAGES OF THE RIBS WITH EACH OTHER (INTERCHONDRAL) (fig. 274)

The contiguous borders of the sixth, seventh, and eighth, and sometimes the ninth and tenth, costal cartilages articulate with each other by small, smooth, oblong-shaped facets. Each articulation is enclosed in a thin *capsular ligament* lined by *synovial membrane*, and strengthened externally and internally by ligamentous fibres (interchondral ligaments), which pass from one cartilage to the other. Sometimes the fifth costal cartilage, more rarely that of the ninth, articulates, by its lower border, with the adjoining cartilage by a small oval facet; more frequently they are connected together by a few ligamentous fibres. Occasionally, the articular surfaces above mentioned are wanting.

#### ARTICULATIONS OF THE RIBS WITH THEIR CARTILAGES (COSTO-CHONDRAL) (fig. 274)

The outer extremity of each costal cartilage is received into a depression in the sternal end of the ribs, and the two are held together by the periosteum.

### VIII. ARTICULATIONS OF THE STERNUM

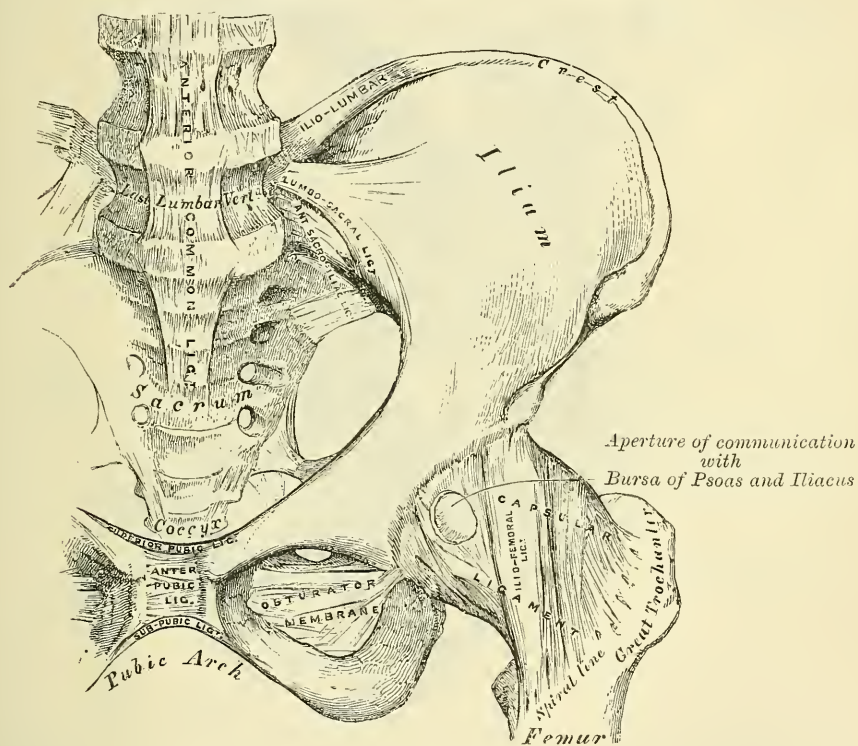
The first piece of the sternum is united to the second either by an amphiarthrodial joint—a single piece of true fibro-cartilage uniting the segments—or by a diarthrodial joint, in which each bone is clothed with a distinct lamina of cartilage, adherent on one side, free and lined with synovial membrane on the

other. In the latter case, the cartilage covering the gladiolus is continued without interruption on to the cartilages of the second ribs. Mr. Rivington has found the diarthrodial form of joint in about one-third of the specimens examined by him, Mr. Maisonneuve more frequently. It appears to be rare in childhood, and is formed, in Mr. Rivington's opinion, from the amphiarthrodial form, by absorption. The diarthrodial joint seems to have no tendency to ossify at any age, while the amphiarthrodial is more liable to do so, and has been found ossified as early as thirty-four years of age. The two segments are further connected by an

Anterior Intersternal Ligament. .  
Posterior Intersternal Ligament.

The **Anterior Intersternal Ligament** consists of a layer of fibres, having a longitudinal direction; it blends with the fibres of the anterior chondro-sternal

FIG. 275.—Articulations of pelvis and hip. Anterior view.



ligaments on both sides, and with the tendinous fibres of origin of the Pectoralis major. This ligament is rough, irregular, and much thicker below than above.

The **Posterior Intersternal Ligament** is disposed in a somewhat similar manner on the posterior surface of the articulation.

#### IX. ARTICULATION OF THE VERTEBRAL COLUMN WITH THE PELVIS

The ligaments connecting the last lumbar vertebra with the sacrum are similar to those which connect the segments of the spine with each other—viz. :  
1. The continuation downwards of the anterior and posterior common ligaments.  
2. The intervertebral substance connecting the flattened oval surfaces of the two bones and forming an amphiarthrodial joint. 3. Ligamenta subflava, connecting the arch of the last lumbar vertebra with the posterior border of the



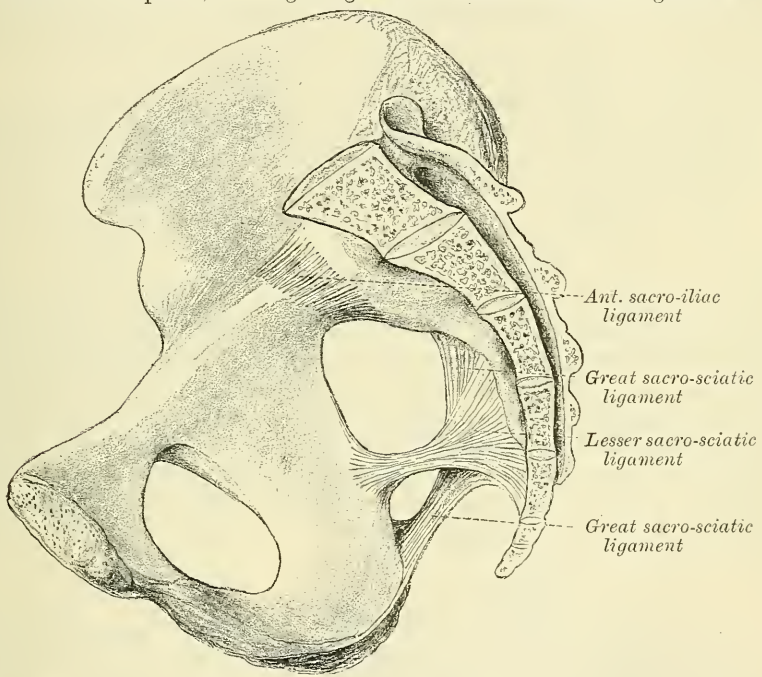


each articular surface is covered with a thin plate of cartilage, thicker on the sacrum than on the ilium. These are usually connected together by fine transverse fibres, so as to convert the whole into one mass; but occasionally the surfaces of the cartilages are rough and irregular, and separated from one another by a soft, yellow, pulpy substance. The ligaments connecting these surfaces are the anterior and posterior sacro-iliac.

The **Anterior Sacro-iliac Ligament** (fig. 277) consists of numerous thin ligamentous bands, which connect the anterior surfaces of the sacrum and ilium.

The **Posterior Sacro-iliac** (fig. 276) is a strong interosseous ligament, situated in a deep depression between the sacrum and ilium behind, and forming the chief bond of connection between those bones. It consists of numerous strong fasciculi, which pass between the bones in various directions. Three of these are of large size; the *two superior*, nearly horizontal in direction, arise from the first and second transverse tubercles on the posterior surface of the sacrum, and are inserted into the rough, uneven surface at the posterior part of the inner

FIG. 277.—Side view of pelvis, showing the great and lesser sacro-sciatic ligaments.



surface of the ilium. The third fasciculus, oblique in direction, is attached by one extremity to the third transverse tubercle on the posterior surface of the sacrum, and by the other to the posterior superior spine of the ilium; it is sometimes called the *oblique sacro-iliac ligament*.

The position of the sacro-iliac joint is indicated by the posterior superior spine of the ilium. This process is immediately behind the centre of the articulation.

## 2. LIGAMENTS PASSING BETWEEN THE SACRUM AND ISCHIUM (fig. 277)

The Great Sacro-sciatic (Posterior).

The Lesser Sacro-sciatic (Anterior).

The **Great or Posterior Sacro-sciatic Ligament** is situated at the lower and back part of the pelvis. It is thin, flat, and triangular in form; narrower in the middle than at the extremities; attached by its broad base to the posterior inferior spine of the ilium, to the fourth and fifth transverse tubercles of the sacrum, and

to the lower part of the lateral margin of that bone and the coccyx. Passing obliquely downwards, outwards, and forwards, it becomes narrow and thick; and at its insertion into the inner margin of the tuberosity of the ischium, it increases in breadth, and is prolonged forwards along the inner margin of the ramus, forming what is known as the *falciform ligament*. The free concave edge of this prolongation has attached to it the obturator fascia, with which it forms a kind of groove, protecting the internal pudic vessels and nerve. One of its surfaces is turned towards the perinæum, the other towards the Obturator internus muscle.

The *posterior surface* of this ligament gives origin, by its whole extent, to fibres of the Gluteus maximus. Its *anterior surface* is united to the lesser sacro-sciatic ligament. Its *external border* forms, above, the posterior boundary of the great sacro-sciatic foramen, and, below, the lower boundary of the lesser sacro-sciatic foramen. Its *lower border* forms part of the boundary of the perinæum. It is pierced by the coccygeal branch of the sciatic artery and coccygeal nerve.

The **Lesser or Anterior Sacro-sciatic Ligament**, much shorter and smaller than the preceding, is thin, triangular in form, attached by its apex to the spine of the ischium, and internally, by its broad base, to the lateral margin of the sacrum and coccyx, anterior to the attachment of the great sacro-sciatic ligament with which its fibres are intermingled.

It is in relation, *anteriorly*, with the Coccygeus muscle; *posteriorly*, it is covered by the great sacro-sciatic ligament, and crossed by the internal pudic vessels and nerve. Its *superior border* forms the lower boundary of the great sacro-sciatic foramen; its *inferior border*, part of the lesser sacro-sciatic foramen.

These two ligaments convert the sacro-sciatic notches into foramina. The *superior or great sacro-sciatic foramen* is bounded, in front and above, by the posterior border of the os innominatum; behind, by the great sacro-sciatic ligament; and below, by the lesser sacro-sciatic ligament. It is partially filled up, in the recent state, by the Pyriformis muscle which passes through it. Above this muscle, the gluteal vessels and superior gluteal nerve emerge from the pelvis; and below it, the sciatic vessels and nerves, the internal pudic vessels and nerve, and muscular branches from the sacral plexus. The *inferior or lesser sacro-sciatic foramen* is bounded, in front, by the tuber ischii; above, by the spine and lesser sacro-sciatic ligament; behind, by the greater sacro-sciatic ligament. It transmits the tendon of the Obturator internus muscle, its nerve, and the internal pudic vessels and nerve.

### 3. ARTICULATION OF THE SACRUM AND COCCYX

This articulation is an amphiarthrodial joint, formed between the oval surface at the apex of the sacrum, and the base of the coccyx. It is analogous to the joints between the bodies of the vertebræ, and is connected by similar ligaments. They are the

Anterior Sacro-coccygeal.  
Posterior Sacro-coccygeal.

Lateral Sacro-coccygeal.  
Interposed Fibro-cartilage.

The **Anterior Sacro-coccygeal Ligament** consists of a few irregular fibres, which descend from the anterior surface of the sacrum to the front of the coccyx, becoming blended with the periosteum.

The **Posterior Sacro-coccygeal Ligament** is a flat band of ligamentous fibres, of a pearly tint, which arises from the margin of the lower orifice of the sacral canal, and descends to be inserted into the posterior surface of the coccyx. This ligament completes the lower and back part of the sacral canal. Its superficial fibres are much longer than the more deeply seated. This ligament is in relation, behind, with the Gluteus maximus.

The **Lateral Sacro-coccygeal Ligaments** are ligamentous bands which pass

from the cornua of the last sacral vertebra to the cornua of the first piece of the coccyx.

A **Fibro-cartilage** is interposed between the contiguous surfaces of the sacrum and coccyx; it differs from that interposed between the bodies of the vertebræ in being thinner, and its central part firmer in texture. It is somewhat thicker in front and behind than at the sides. Occasionally, a synovial membrane is found when the coccyx is freely movable, which is more especially the case during pregnancy.

The different segments of the coccyx are connected together by an extension downwards of the anterior and posterior sacro-coccygeal ligaments, a thin annular disc of fibro-cartilage being interposed between each of the bones. In the adult male, all the pieces become ossified; but in the female, this does not commonly occur until a later period of life. The separate segments of the coccyx are first united, and at a more advanced age the joint between the sacrum and coccyx is obliterated.

**Actions.**—The movements which take place between the sacrum and coccyx, and between the different pieces of the latter bone, are slightly forwards and backwards; they are very limited. Their extent increases during pregnancy.

#### 4. ARTICULATION OF THE OSSA PUBIS (fig. 278)

The articulation between the pubic bones is an amphiarthrodial joint, formed by the junction of the two oval articular surfaces of the ossa pubis. The articular surface has been described on a former page under the name of *symphysis*, and the same name is given to the joint. The ligaments of this articulation are the

Anterior Pubic.	Posterior Pubic.
Superior Pubic.	Subpubic.
Intertubercular Disc.	

The **Anterior Pubic Ligament** consists of several superimposed layers, which pass across the front of the articulation. The superficial fibres pass obliquely from one bone to the other, decussating and forming an interlacement with the fibres of the aponeurosis of the External oblique and the tendon of the Rectus muscles. The deep fibres pass transversely across the symphysis, and are blended with the fibro-cartilage.

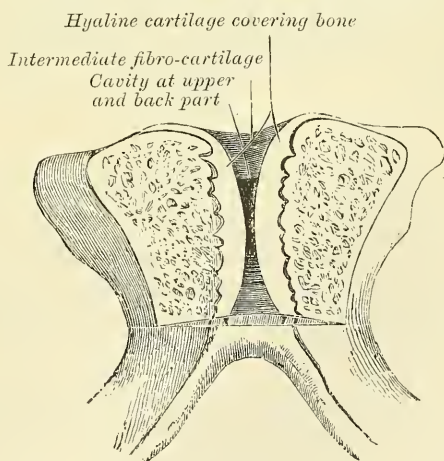
The **Posterior Pubic Ligament** consists of a few thin, scattered fibres, which unite the two pubic bones posteriorly.

The **Superior Pubic Ligament** is a band of fibres, which connects together the two pubic bones superiorly.

The **Subpubic Ligament** is a thick, triangular arch of ligamentous fibres, connecting together the two pubic bones below, and forming the upper boundary of the pubic arch. Above, it is blended with the interarticular fibro-cartilage; laterally, it is united with the descending rami of the ossa pubis. Its fibres are closely connected, and have an arched direction.

The **Intertubercular Disc** consists of a disc of cartilage and fibro-cartilage connecting the surfaces of the pubic bones in front. Each pubic symphysis is

FIG. 278.—Vertical section of the symphysis pubis. Made near its posterior surface.





covered by a thin layer of hyaline cartilage, which is firmly connected to the bone by a series of nipple-like processes which accurately fit within corresponding depressions on the osseous surfaces. These opposed cartilaginous surfaces are connected together by an intermediate stratum of fibrous tissue and fibro-cartilage which varies in thickness in different subjects. It often contains a cavity in its centre, probably formed by the softening and absorption of the fibro-cartilage, since it rarely appears before the tenth year of life, and is not lined by synovial membrane. It is larger in the female than in the male, but it is very questionable whether it enlarges, as was formerly supposed, during pregnancy. It is most frequently limited to the upper and back part of the joint; but it occasionally reaches to the front, and may extend the entire length of the cartilage. This cavity may be easily demonstrated by making a vertical section of the symphysis pubis near its posterior surface.

The **Obturator Ligament** is more properly regarded as analogous to the muscular fasciæ, with which it will be described.

## ARTICULATIONS OF THE UPPER EXTREMITY

The articulations of the Upper Extremity may be arranged in the following groups:—I. Sterno-clavicular articulation. II. Acromio-clavicular articulation. III. Ligaments of the Scapula. IV. Shoulder-joint. V. Elbow-joint. VI. Radio-ulnar articulations. VII. Wrist-joint. VIII. Articulations of the Carpal Bones. IX. Carpo-metacarpal articulations. X. Metacarpo-phalangeal articulations. XI. Articulations of the Phalanges.

### I. STERNO-CLAVICULAR ARTICULATION (fig. 279)

The **Sterno-clavicular** is regarded by most anatomists as an arthrodial joint; but Cruveilhier considers it to be an articulation by reciprocal reception. Probably the former opinion is the correct one; the varied movements, which the joint enjoys, being due to the interposition of an interarticular fibro-cartilage between the joint surfaces. The parts entering into its formation are the sternal end of the clavicle, the upper and lateral part of the first piece of the sternum, and the cartilage of the first rib. The articular surface of the clavicle is much larger than that of the sternum, and invested with a layer of cartilage,\* which is considerably thicker than that on the latter bone. The ligaments of this joint are the

Capsular.

Anterior Sterno-clavicular.

Posterior Sterno-clavicular.

Interclavicular.

Costo-clavicular (rhomboid).

Interarticular Fibro-cartilage.

The **Capsular Ligament** completely surrounds the articulation, consisting of fibres of varying degrees of thickness and strength. Those in front and behind are of considerable thickness, and form the anterior and posterior sterno-clavicular ligaments, but those above and below, especially in the latter situation, are thin and scanty, and partake more of the character of connective tissue than true fibrous tissue.

The **Anterior Sterno-clavicular Ligament**, the anterior part of the capsular ligament, is a broad band of fibres, which covers the anterior surface of the articulation, being attached, above, to the upper and front part of the inner extremity of the clavicle; and, passing obliquely downwards and inwards, is attached, below, to the upper and front part of the first piece of the sternum. This ligament is covered, in front, by the sternal portion of the Sterno-cleido-mastoid and the integument; behind, it is in relation with the interarticular fibro-cartilage and the two synovial membranes.

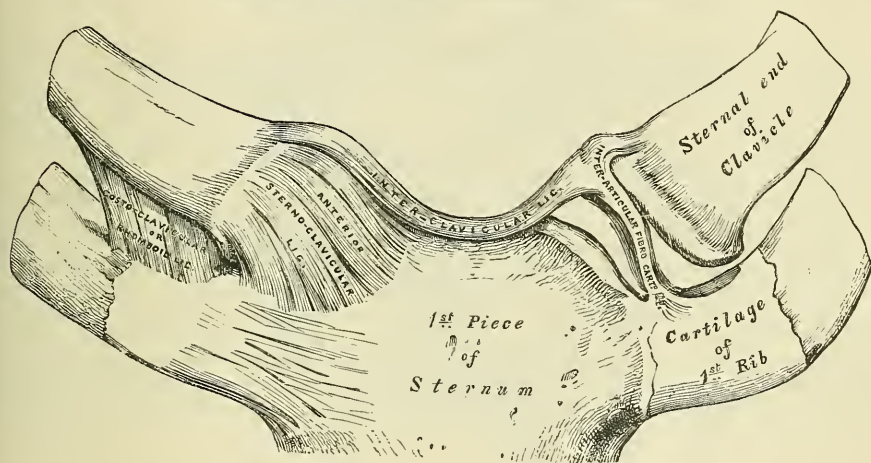
\* According to Bruch, the sternal end of the clavicle is covered by a tissue, which is rather fibrous than cartilaginous in structure.

The **Posterior Sterno-clavicular Ligament**, the posterior part of the capsular ligament, is a similar band of fibres, which covers the posterior surface of the articulation, being attached, above, to the upper and back part of the inner extremity of the clavicle; and, passing obliquely downwards and inwards, is attached, below, to the upper and back part of the first piece of the sternum. It is in relation, in front, with the interarticular fibro-cartilage and synovial membranes; behind, with the Sterno-hyoid and Sterno-thyroid muscles.

The **Interclavicular Ligament** is a flattened band, which varies considerably in form and size in different individuals; it passes in a curved direction from the upper part of the inner extremity of one clavicle to the other, and is closely attached to the upper margin of the sternum. It is in relation, in front, with the integument; behind, with the Sterno-thyroid muscles.

The **Costo-clavicular Ligament (rhomboid)** is short, flat, and strong: it is of a rhomboid form, attached, below, to the upper and inner part of the cartilage of the first rib, it ascends obliquely backwards and outwards, and is attached, above, to the rhomboid depression on the under surface of the clavicle. It is in relation, in front, with the tendon of origin of the Subclavius; behind, with the subclavian vein.

FIG. 279.—Sterno-clavicular articulation. Anterior view.



The **Interarticular Fibro-cartilage** is a flat and nearly circular disc, interposed between the articulating surfaces of the sternum and clavicle. It is attached, above, to the upper and posterior border of the articular surface of the clavicle; below, to the cartilage of the first rib, at its junction with the sternum; and by its circumference to the anterior and posterior sterno-clavicular and interclavicular ligaments. It is thicker at the circumference, especially its upper and back part, than at its centre, or below. It divides the joint into two cavities, each of which is furnished with a separate synovial membrane.

Of the two **Synovial Membranes** found in this articulation, one is reflected from the sternal end of the clavicle, over the adjacent surface of the fibro-cartilage, and cartilage of the first rib; the other is placed between the articular surface of the sternum and adjacent surface of the fibro-cartilage; the latter is the larger of the two.

**Actions.**—This articulation is the centre of the movements of the shoulder, and admits of a limited amount of motion in nearly every direction—upwards, downwards, backwards, forwards, as well as circumduction. When these movements take place in the joint, the clavicle in its motion carries the scapula with it, this bone gliding on the outer surface of the chest. This joint therefore forms

the centre from which all movements of the supporting arch of the shoulder originate, and is the only point of articulation of this part of the skeleton with the trunk. 'The movements attendant on elevation and depression of the shoulder take place between the clavicle and the interarticular fibro-cartilage, the bone rotating upon the ligament on an axis drawn from before backwards through its own articular facet. When the shoulder is moved forwards and backwards, the clavicle, with the interarticular fibro-cartilage, rolls to and fro on the articular surface of the sternum, revolving, with a sliding movement, round an axis drawn nearly vertically through the sternum. In the circumduction of the shoulder, which is compounded of these two movements, the clavicle revolves upon the interarticular fibro-cartilage, and the latter, with the clavicle, rolls upon the sternum.'\* Elevation of the clavicle is principally limited by the costo-clavicular ligament; depression, by the interclavicular. The muscles which raise the clavicle, as in shrugging the shoulders, are the upper fibres of the Trapezius, the Levator anguli scapulæ, the clavicular head of the Sternomastoid, assisted to a certain extent by the two Rhomboids, which pull the inferior angle of the Scapula backwards and upwards and so raise the clavicle. The depression of the clavicle is principally effected by gravity, assisted by the Subclavius, Pectoralis minor, and lower fibres of the Trapezius. It is drawn backwards by the Rhomboids and the middle and lower fibres of the Trapezius, and forwards by the Serratus magnus and Pectoralis minor.

*Surface Form.*—The position of the sterno-clavicular joint may be easily ascertained by feeling the enlarged sternal end of the collar-bone just external to the long, cord-like, sternal origin of the Sternomastoid muscle. If this muscle is relaxed by bending the head forwards, a depression just internal to the end of the clavicle, and between it and the sternum, can be felt, indicating the exact position of the joint, which is subcutaneous. When the arm hangs by the side, the cavity of the joint is V-shaped. If the arm is raised, the bones become more closely approximated, and the cavity becomes a mere slit.

*Surgical Anatomy.*—The strength of this joint mainly depends upon its ligaments, and it is owing to this, and to the fact that the force of the blow is generally transmitted along the long axis of the clavicle, that dislocation rarely occurs, and that the bone is generally broken rather than displaced. When dislocation does occur, the course which the displaced bone takes depends more upon the direction in which the violence is applied than upon the anatomical construction of the joint; it may be either forwards, backwards, or upwards. The chief point worthy of note, as regards the construction of the joint, in regard to dislocations, is the fact that, owing to the shape of the articular surfaces being so little adapted to each other, and that the strength of the joint mainly depends upon the ligaments, the displacement when reduced is very liable to recur, and hence it is extremely difficult to keep the end of the bone in its proper place.

## II. ACROMIO-CLAVICULAR ARTICULATION (fig. 280)

The **Acromio-clavicular** is an arthrodial joint, formed between the outer extremity of the clavicle and the inner margin of the acromion process of the scapula. Its ligaments are the

Superior Acromio-clavicular.	Coraco-clavicular	} Trapezoid and Conoid.
Inferior Acromio-clavicular.		
Interarticular Fibro-cartilage.		

The **Superior Acromio-clavicular Ligament** is a broad band, of a quadrilateral form, which covers the superior part of the articulation, extending between the upper part of the outer end of the clavicle and the adjoining part of the upper surface of the acromion. It is composed of parallel fibres, which interlace with the aponeurosis of the Trapezius and Deltoid muscles; below, it is in contact with the interarticular fibro-cartilage (when it exists) and the synovial membranes.

The **Inferior Acromio-clavicular Ligament**, somewhat thinner than the preceding, covers the under part of the articulation, and is attached to the adjoining

\* Humphry. *On the Human Skeleton*, p. 402.



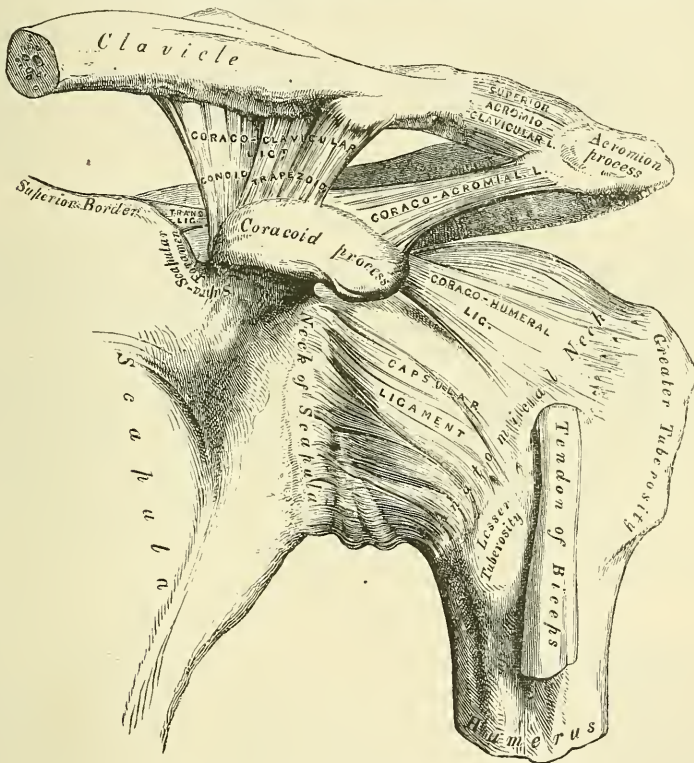
surfaces of the two bones. It is in relation, above, with the synovial membranes, and in rare cases with the interarticular fibro-cartilage; below, with the tendon of the Supraspinatus. These two ligaments are continuous with each other in front and behind, and form a complete capsule round the joint.

The **Interarticular Fibro-cartilage** is frequently absent in this articulation. When it exists, it generally only partially separates the articular surfaces, and occupies the upper part of the articulation. More rarely, it completely separates the joint into two cavities.

**The Synovial Membrane.**—There is usually only one synovial membrane in this articulation, but when a complete interarticular fibro-cartilage exists, there are two synovial membranes.

The **Coraco-clavicular Ligament** serves to connect the clavicle with the coracoid process of the scapula. It does not properly belong to this articulation,

FIG. 280.—The left shoulder-joint, scapulo-clavicular articulation, and proper ligaments of scapula.



but as it forms a most efficient means in retaining the clavicle in contact with the acromial process, it is usually described with it. It consists of two fasciculi, called the *trapezoid* and *conoid ligaments*.

The *Trapezoid Ligament*, the anterior and external fasciculus, is broad, thin, and quadrilateral: it is placed obliquely between the coracoid process and the clavicle. It is attached, below, to the upper surface of the coracoid process; above, to the oblique line on the under surface of the clavicle. Its anterior border is free; its posterior border is joined with the conoid ligament: the two forming, by their junction, a projecting angle.

The *Conoid Ligament*, the posterior and internal fasciculus, is a dense band of fibres, conical in form, the base being turned upwards, the summit downwards. It is attached by its apex to a rough impression at the base of the coracoid process, internal to the preceding; above, by its expanded base, to the conoid tubercle on

the under surface of the clavicle, and to a line proceeding internally from it for half an inch. These ligaments are in relation, in front, with the Subclavius and Deltoid; behind, with the Trapezius. They serve to limit rotation of the scapula; the Trapezoid limiting rotation forwards, and the Conoid backwards.

**Actions.**—The movements of this articulation are of two kinds. 1. A gliding motion of the articular end of the clavicle on the acromion. 2. Rotation of the scapula forwards and backwards upon the clavicle, the extent of this rotation being limited by the two portions of the coraco-clavicular ligament.

The acromio-clavicular joint has important functions in the movements of the upper extremity. It has been well pointed out by Sir George Humphry, that if there had been no joint between the clavicle and scapula, the circular movement of the scapula on the ribs (as in throwing the shoulders backwards or forwards) would have been attended with a greater alteration in the direction of the shoulder than is consistent with the free use of the arm in such positions, and it would have been impossible to give a blow straight forwards with the full force of the arm, that is to say, with the combined force of the scapula, arm, and fore arm. 'This joint,' as he happily says, 'is so adjusted as to enable either bone to turn in a hinge-like manner upon a vertical axis drawn through the other, and it permits the surfaces of the scapula, like the baskets in a roundabout swing, to look the same way in every position, or nearly so.' Again, when the whole arch formed by the clavicle and scapula rises and falls (in elevation or depression of the shoulders), the joint between these two bones enables the scapula still to maintain its lower part in contact with the ribs.

*Surface Form.*—The position of the acromio-clavicular joint can generally be ascertained by the slightly enlarged extremity of the outer end of the clavicle, which causes it to project above the level of the acromion process of the scapula. Sometimes this enlargement is so considerable as to form a rounded eminence, which is easily to be felt. The joint lies in the plane of a vertical line passing up the middle of the front of the arm.

*Surgical Anatomy.*—Owing to the slanting shape of the articular surfaces of this joint, dislocation generally occurs downwards, that is to say, the acromion process of the scapula is dislocated under the outer end of the clavicle; but dislocation in the opposite direction has been described. The displacement is often incomplete, on account of the strong coraco-clavicular ligaments, which remain untornd. The same difficulty exists, as in the sterno-clavicular dislocation, in maintaining the ends of the bone in position after reduction.

### III. PROPER LIGAMENTS OF THE SCAPULA (fig. 280)

The proper ligaments of the scapula are, the

Coraco-acromial.

Transverse.

The **Coraco-acromial Ligament** is a broad, thin, flat band, of a triangular shape, extended transversely above the upper part of the shoulder-joint, between the coracoid and acromion processes. It is attached, by its apex, to the summit of the acromion just in front of the articular surface for the clavicle; and by its broad base to the whole length of the outer border of the coracoid process. Its posterior fibres are directed obliquely backwards and inwards, its anterior fibres transversely inwards. This ligament completes the vault formed by the coracoid and acromion processes for the protection of the head of the humerus. It is in relation, above, with the clavicle and under surface of the Deltoid; below, with the tendon of the Supraspinatus muscle, a bursa being interposed. Its anterior border is continuous with a dense cellular lamina that passes beneath the Deltoid upon the tendons of the Supra- and Infraspinatus muscles. This ligament is sometimes described as consisting of two marginal bands and a thinner intervening portion, the two bands being attached respectively to the apex and base of the coracoid process, and joining together at their attachment into the acromion process. When the Pectoralis minor is inserted, as sometimes is the case, into the capsule of the shoulder-joint instead of into the coracoid process, it passes between these two bands, and the intervening portion is then deficient.

The **Transverse or Coracoid** (*suprascapular*) **Ligament** converts the suprascapular notch into a foramen. It is a thin and flat fasciculus, narrower at the middle than at the extremities, attached by one end to the base of the coracoid process, and by the other to the inner extremity of the scapular notch. The suprascapular nerve passes through the foramen; the suprascapular vessels pass over the ligament.

**Movements of Scapula.**—The scapula is capable of being moved upwards and downwards, forwards and backwards, or, by a combination of these movements, circumducted on the wall of the chest. The muscles which *raise* the scapula are the upper fibres of the Trapezius, the Levator anguli scapulæ, and the two Rhomboids; those which *depress* it are the lower fibres of the Trapezius, the Pectoralis minor and, through the clavicle, the Subclavius. The scapula is drawn *backwards* by the Rhomboids and the middle and lower fibres of the Trapezius, and *forwards* by the Serratus magnus and Pectoralis minor, assisted, when the arm is fixed, by the Pectoralis major. The mobility of the scapula is very considerable, and greatly assists the movements of the arm at the shoulder-joint. Thus, in raising the arm from the side, the Deltoid and Suprascapularis can only lift it to a right angle with the trunk, the further elevation of the limb being effected by the Trapezius moving the scapula on the wall of the chest. This mobility is of special importance in ankylosis of the shoulder-joint, the movements of this bone compensating to a very great extent for the immobility of the joint.

#### IV. SHOULDER-JOINT (fig. 280)

The **Shoulder** is an enarthrodial or ball-and-socket joint. The bones entering into its formation are the large globular head of the humerus, which is received into the shallow glenoid cavity of the scapula, an arrangement which permits of very considerable movement, whilst the joint itself is protected against displacement by the tendons which surround it and by atmospheric pressure. The ligaments do not maintain the joint surfaces in apposition, because when they alone remain the humerus can be separated to a considerable extent from the glenoid cavity; their use therefore is to limit the amount of movement. Above, the joint is protected by an arched vault, formed by the under surface of the coracoid and acromion processes, and the coraco-acromial ligament. The articular surfaces are covered by a layer of cartilage: that on the head of the humerus is thicker at the centre than at the circumference, the reverse being the case in the glenoid cavity. The ligaments of the shoulder are, the

Capsular.

Coraco-humeral.

Glenoid.\*

Transverse-humeral.

The **Capsular Ligament** completely encircles the articulation, being attached, above, to the circumference of the glenoid cavity beyond the glenoid ligament; below, to the anatomical neck of the humerus, approaching nearer to the articular cartilage above than in the rest of its extent. It is thicker above and below than elsewhere, and is remarkably loose and lax, and much larger and longer than is necessary to keep the bones in contact, allowing them to be separated from each other more than an inch, an evident provision for that extreme freedom of movement which is peculiar to this articulation. Its external surface is strengthened, above, by the Suprascapularis; below, by the long head of the Triceps; externally, by the tendons of the Infraspinatus and Teres minor; and internally, by the tendon of the Subscapularis. The capsular ligament usually presents three openings: one anteriorly, below the coracoid process, establishes a communication between the synovial membrane of the joint and a bursa

\* The long tendon of origin of the Biceps muscle also acts as one of the ligaments of this joint. See the observations on p. 310, on the function of the muscles passing over more than one joint.

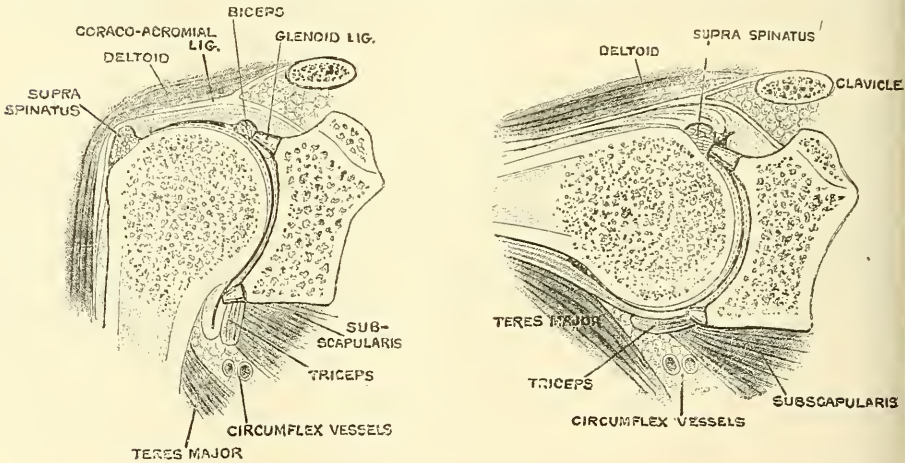


beneath the tendon of that muscle. The second, which is not constant, is at the outer part, where a communication sometimes exists between the joint and a bursal sac belonging to the Infraspinatus muscle. The third is seen in the lower border of the ligament, between the two tuberosities, for the passage of the long tendon of the Biceps muscle.

The **Coraco-humeral** or **Accessory Ligament** is a broad band which strengthens the upper part of the capsular ligament. It arises from the outer border of the coracoid process, and passes obliquely downwards and outwards to the front of the great tuberosity of the humerus, being blended with the tendon of the Supraspinatus muscle. This ligament is intimately united to the capsular in the greater part of its extent.

The **Transverse Humeral Ligament**.—This is a broad band of fibrous tissue passing from the lesser to the greater tuberosity of the humerus, and always limited to that portion of the bone which lies above the epiphysial line. It converts the bicipital groove into an osseo-aponeurotic canal, and is the analogue of the strong process of bone which connects the summits of the two tuberosities in the musk ox.

FIG. 281.—Vertical sections through the shoulder-joint, the arm being vertical and horizontal. (After Henle.)



**Supplemental Bands of the Capsular Ligament.**—In addition to the coraco-humeral or accessory ligament, the capsular ligament is strengthened by supplemental bands in the interior of the joint. One of these bands is situated on the inner side of the joint, and passes from the inner edge of the glenoid cavity to the lower part of the lesser tuberosity of the humerus. This is sometimes known as *Flood's ligament*, and is supposed to correspond with the ligamentum teres of the hip-joint. A second of these bands is situated at the lower part of the joint, and passes from the under edge of the glenoid cavity to the under part of the neck of the humerus, and is known as *Schlemm's ligament*. A third, called the *gleno-humeral ligament*, is situated at the upper part of the joint, and projects into its interior, so that it can only be seen when the capsule is opened. It is attached above to the apex of the glenoid cavity close to the root of the zygoma, and passing downwards along the inner edge of the tendon of the Biceps is attached below to the lesser tuberosity of the humerus, where it forms the inner boundary of the upper part of the bicipital groove. It is a thin, ribbon-like band, occasionally quite free from the capsule.

The **Glenoid Ligament** is a fibro-cartilaginous rim attached round the margin of the glenoid cavity. It is triangular on section, the thickest portion being fixed to the circumference of the cavity, the free edge being thin and sharp. It is

continuous above with the long tendon of the Biceps muscle, which bifurcates at the upper part of the cavity into two fasciculi, and becomes continuous with the fibrous tissue of the glenoid ligament. This ligament deepens the cavity for articulation, and protects the edges of the bone. It is lined by the synovial membrane.

The **Synovial Membrane** is reflected from the margin of the glenoid cavity over the fibro-cartilaginous rim surrounding it; it is then reflected over the internal surface of the capsular ligament, covers the lower part and sides of the neck of the humerus, and is continued a short distance over the cartilage covering the head of the bone. The long tendon of the Biceps muscle which passes through the capsular ligament is enclosed in a tubular sheath of synovial membrane, which is reflected upon it at the point where it perforates the capsule, and is continued around it as far as the summit of the glenoid cavity. The tendon of the Biceps is thus enabled to traverse the articulation, but it is not contained in the interior of the synovial cavity. The synovial membrane communicates with a large bursal sac beneath the tendon of the Subscapularis, by an opening at the inner side of the capsular ligament; it also occasionally communicates with another bursal sac, beneath the tendon of the Infraspinatus, through an orifice at its outer part. A third bursal sac, which does not communicate with the joint, is placed between the under surface of the Deltoid and the outer surface of the capsule.

The *Muscles* in relation with the joint are, above, the Supraspinatus; below, the long head of the Triceps; internally, the Subscapularis; externally, the Infraspinatus and Teres minor; within, the long tendon of the Biceps. The Deltoid is placed most externally, and covers the articulation on its outer side, as well as in front and behind.

The *Arteries* supplying the joint are articular branches of the anterior and posterior circumflex, and suprascapular.

The *Nerves* are derived from the circumflex and suprascapular.

**Actions.**—The shoulder-joint is capable of movement in every direction, forwards, backwards, abduction, adduction, circumduction, and rotation. The humerus is drawn *forwards* by the Pectoralis major, anterior fibres of the Deltoid, Coraco-brachialis, and by the Biceps, when the forearm is flexed; *backwards* by the Latissimus dorsi, Teres major, posterior fibres of the Deltoid, and by the Triceps when the forearm is extended; it is *abducted* (elevated) by the Deltoid and Supraspinatus; it is *adducted* (depressed) by the Subscapularis, Pectoralis major, Latissimus dorsi, and Teres major; it is *rotated outwards* by the Infraspinatus and Teres minor; and it is *rotated inwards* by the Subscapularis, Latissimus dorsi, Teres major, and Pectoralis major.

The most striking peculiarities in this joint are: 1. The large size of the head of the humerus in comparison with the depth of the glenoid cavity, even when supplemented by the glenoid ligament. 2. The looseness of the capsule of the joint. 3. The intimate connection of the capsule with the muscles attached to the head of the humerus. 4. The peculiar relation of the Biceps tendon to the joint.

It is in consequence of the relative size of the two articular surfaces that the joint enjoys such free movement in every possible direction. When these movements of the arm are arrested in the shoulder-joint by the contact of the bony surfaces, and by the tension of the corresponding fibres of the capsule, together with that of the muscles acting as accessory ligaments, they can be carried considerably further by the movements of the scapula, involving, of course, motion at the acromio- and sterno-clavicular joints. These joints are therefore to be regarded as accessory structures to the shoulder-joint.\* The extent of these movements of the scapula is very considerable, especially in extreme elevation of the arm, which movement is best accomplished when the arm is thrown

\* See p. 338.

somewhat forwards, since the articular surface of the humerus is broader in the middle than at either end, especially the lower, so that the range of elevation directly forwards is less, and that directly backwards still more restricted. The great width of the central portion of the humeral head also allows of very free horizontal movement when the arm is raised to a right angle, in which movement the arch formed by the acromion, the coracoid process, and the coraco-acromial ligament, constitutes a sort of supplemental articular cavity for the head of the bone.

The looseness of the capsule is so great that the arm will fall about an inch from the scapula when the muscles are dissected from the capsular ligament, and an opening made in it to remove the atmospheric pressure. The movements of the joint, therefore, are not regulated by the capsule so much as by the surrounding muscles and by the pressure of the atmosphere, an arrangement which 'renders the movements of the joint much more easy than they would otherwise have been, and permits a swinging, pendulum-like vibration of the limb when the muscles are at rest' (Humphry). The fact, also, that in all ordinary positions of the joint the capsule is not put on the stretch, enables the arm to move freely in all directions. Extreme movements are checked by the tension of appropriate portions of the capsule, as well as by the interlocking of the bones. Thus it is said that 'abduction is checked by the contact of the great tuberosity with the upper edge of the glenoid cavity, adduction by the tension of the coraco-humeral ligament' (Beaunis et Bouchard).

The intimate union of the tendons of the four short muscles with the capsule converts these muscles into elastic and spontaneously acting ligaments of the joint, and it is regarded as being also intended to prevent the folds into which all portions of the capsule would alternately fall in the varying positions of the joint from being driven between the bones by the pressure of the atmosphere.

The peculiar relations of the Biceps tendon to the shoulder-joint appear to subservise various purposes. In the first place, by its connection with both the shoulder and elbow the muscle harmonises the action of the two joints, and acts as an elastic ligament in all positions, in the manner previously adverted to.\* Next, it strengthens the upper part of the articular cavity, and prevents the head of the humerus from being pressed up against the acromion process, when the Deltoid contracts, instead of forming the centre of motion in the glenoid cavity. By its passage along the bicipital groove it assists in rendering the head of the humerus steady in the various movements of the arm. When the arm is raised from the side it assists the Supra- and Infraspinatus in rotating the head of the humerus in the glenoid cavity. It also holds the head of the bone firmly in contact with the glenoid cavity, and prevents its slipping over its lower edge, or being displaced by the action of the Latissimus dorsi and Pectoralis major, as in climbing and many other movements.

*Surface Form.*—The direction and position of the shoulder-joint may be indicated by a line drawn from the middle of the coraco-acromial ligament, in a curved direction, with its convexity inwards, to the innermost part of that portion of the head of the humerus which can be felt in the axilla when the arm is forcibly abducted from the side. When the arm hangs by the side, not more than one-third of the head of the bone is in contact with the glenoid cavity, and three-quarters of its circumference is in front of a vertical line drawn from the anterior border of the acromion process.

*Surgical Anatomy.*—Owing to the construction of the shoulder-joint and the freedom of movement which it enjoys, as well as in consequence of its exposed situation, it is more frequently dislocated than any other joint in the body. Dislocation occurs when the arm is abducted, and when, therefore, the head of the humerus presses against the lower and front part of the capsule, which is the thinnest and least supported part of the ligament. The rent in the capsule almost invariably takes place in this situation, and through it the head of the bone escapes, so that the dislocation in most instances is primarily subglenoid. The head of the bone does not usually remain in this situation, but generally assumes some other position, which varies according to the direction and amount of force producing the dislocation and the relative strength of the muscles in front and behind the joint.

\* See p. 310.



In consequence of the muscles at the back being stronger than those in front, and especially on account of the long head of the Triceps preventing the bone passing backwards, dislocation forwards is much more common than backwards. The most frequent position which the head of the humerus ultimately assumes is on the front of the neck of the scapula, beneath the coracoid process, and hence named subcoracoid. Occasionally, in consequence probably of a greater amount of force being brought to bear on the limb, the head is driven farther inwards, and rests on the upper part of the front of the chest, beneath the clavicle (subclavicular). Sometimes it remains in the position in which it was primarily displaced, resting on the axillary border of the scapula (subglenoid), and rarely it passes backwards and remains in the infraspinatus fossa, beneath the spine (subspinous).

The shoulder-joint is sometimes the seat of all those inflammatory affections, both acute and chronic, which attack joints, though perhaps less frequently than some other joints of equal size and importance. Acute synovitis may result from injury, rheumatism, or pyæmia, or may follow secondarily on the so-called acute epiphysitis of infants. It is attended with effusion into the joint, and when this occurs the capsule is evenly distended, and the contour of the joint rounded. Special projections may occur at the site of the openings in the capsular ligament. Thus a swelling may appear just in front of the joint, internal to the lesser tuberosity, from effusion into the bursa beneath the Subscapularis muscle; or, again, a swelling which is sometimes bilobed may be seen in the interval between the Deltoid and Pectoralis major muscles, from effusion into the diverticulum, which runs down the bicipital groove with the tendon of the Biceps. The effusion into the synovial membrane can be best ascertained by examination from the axilla, where a soft, elastic, fluctuating swelling can usually be felt.

Tuberculous arthritis not unfrequently attacks the shoulder-joint, and may lead to total destruction of the articulation, when ankylosis may result, or long protracted suppuration may necessitate excision. This joint is also one of those which is most liable to be the seat of osteo-arthritis, and may also be affected in gout and rheumatism; or in locomotor ataxy, when it becomes the seat of Charcot's disease.

Excision of the shoulder-joint may be required in cases of arthritis (especially the tuberculous form) which have gone on to destruction of the articulation; in compound dislocations and fractures, particularly those arising from gunshot injuries, in which there has been extensive injury to the head of the bone; in some cases of old unreduced dislocation, where there is much pain; and possibly in some few cases of growth connected with the upper end of the bone. The operation is best performed by making an incision from the middle of the coraco-acromial ligament down the arm for about three inches: this will expose the bicipital groove and the tendon of the biceps, which may be either divided or hooked out of the way, according as to whether it is implicated in the disease or not. The capsule is then freely opened, and the muscles attached to the greater and lesser tuberosities of the humerus divided. The head of the bone can then be thrust out of the wound and sawn off; or divided with a narrow saw *in situ* and subsequently removed. The section should be made, if possible, just below the articular surface, so as to leave the bone as long as possible. The glenoid cavity must then be examined, and gouged if carious.

## V. ELBOW-JOINT

The **Elbow** is a *ginglymus* or hinge-joint. The bones entering into its formation are the trochlear surface of the humerus, which is received into the greater sigmoid cavity of the ulna, and admits of the movements peculiar to this joint, viz. flexion and extension; whilst the lesser, or radial, head of the humerus articulates with the cup-shaped depression on the head of the radius; the circumference of the head of the radius articulates with the lesser sigmoid cavity of the ulna, allowing of the movement of rotation of the radius on the ulna, the chief action of the superior radio-ulnar articulation. The articular surfaces are covered with a thin layer of cartilage, and connected together by a capsular ligament of unequal thickness, being especially thickened on its two sides and, to a less extent, in front and behind. These thickened portions are usually described as distinct ligaments under the following names:—

Anterior.	Internal Lateral.
Posterior.	External Lateral.

The orbicular ligament of the upper radio-ulnar articulation must also be reckoned among the ligaments of the elbow.

The **Anterior Ligament** (fig. 282) is a broad and thin fibrous layer, which covers the anterior surface of the joint. It is attached to the front of the internal

condyle and to the front of the humerus immediately above the coronoid fossa ; below, to the anterior surface of the coronoid process of the ulna and orbicular ligament, being continuous on each side with the lateral ligaments. Its superficial fibres pass obliquely from the inner condyle of the humerus outwards to the orbicular ligament. The middle fibres, vertical in direction, pass from the upper part of the coronoid depression and become partly blended with the preceding, but mainly inserted into the anterior surface of the coronoid process. The deep or transverse set intersects these at right angles. This ligament is in relation, in front, with the *Brachialis anticus*, except at its outermost part ; behind, with the synovial membrane.

The **Posterior Ligament** (fig. 283) is a thin and loose membranous fold, attached, above, to the lower end of the humerus, on a level with the upper part

FIG. 282.—Left elbow-joint, showing anterior and internal ligaments.

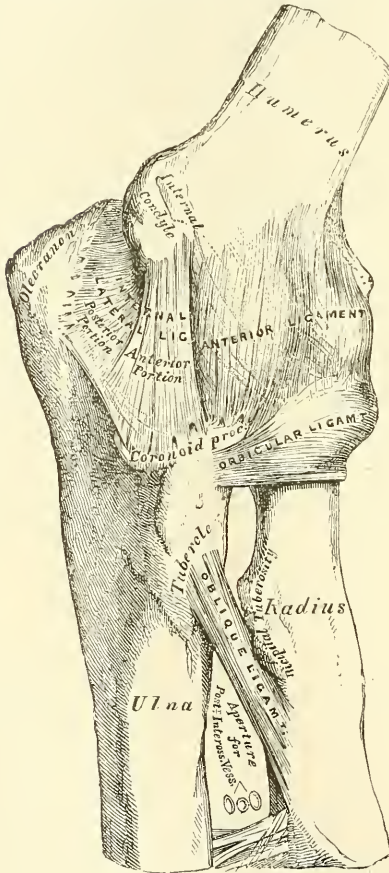
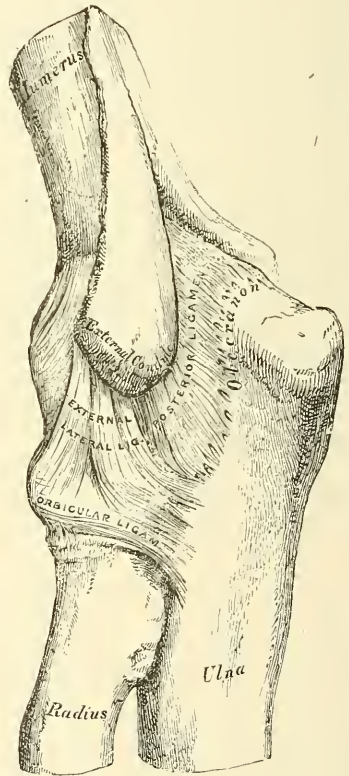


FIG. 283.—Left elbow-joint, showing posterior and external ligaments.



of the olecranon fossa ; below, to the groove on the upper and outer surfaces of the olecranon. The superficial or transverse fibres pass between the adjacent margins of the olecranon fossa. The deeper portion consists of vertical fibres, some of which, thin and weak, pass from the upper part of the olecranon fossa to the margin of the olecranon ; others, thicker and stronger, pass from the back of the capitellum of the humerus to the posterior border of the lesser sigmoid cavity of the ulna. This ligament is in relation, behind, with the tendon of the *Triceps* and the *Anconeus* ; in front, with the synovial membrane.

The **Internal Lateral Ligament** (fig. 282) is a thick triangular band consisting of two portions, an anterior and posterior, united by a thinner intermediate portion. The *anterior portion*, directed obliquely forwards, is attached, above,



by its apex, to the lowest front part of the internal condyle of the humerus; and, below, by its broad base, to the inner margin of the coronoid process. The *posterior portion*, also of triangular form, is attached, above, by its apex, to the lower and back part of the internal condyle; below, to the inner margin of the olecranon. Between these two bands a few intermediate fibres descend from the internal condyle to blend with a transverse band of ligamentous tissue which bridges across the notch between the olecranon and coronoid processes. This ligament is in relation, internally, with the Triceps and Flexor carpi ulnaris muscles, and the ulnar nerve, and gives origin to part of the Flexor sublimis digitorum.

The **External Lateral Ligament** (fig. 283) is a short and narrow fibrous band, less distinct than the internal, attached, above, to a depression below the external condyle of the humerus; below, to the orbicular ligament, some of its most posterior fibres passing over that ligament, to be inserted into the outer margin of the ulna. This ligament is intimately blended with the tendon of origin of the Supinator brevis muscle.

The **Synovial Membrane** is very extensive. It covers the margin of the articular surface of the humerus, and lines the coronoid and olecranon fossæ on that bone: from these points, it is reflected over the anterior, posterior, and lateral ligaments; and forms a pouch between the lesser sigmoid cavity, the internal surface of the orbicular ligament, and the circumference of the head of the radius. Projecting into the cavity is a crescentic fold of synovial membrane, between the radius and ulna, suggesting the division of the joint into two; one the humero-radial, the other the humero-ulnar.

Between the capsular ligament and the synovial membrane are three masses of fat: one, the largest, above the olecranon fossa, which is pressed into the fossa by the Triceps during flexion; a second, over the coronoid fossa; and a third over the radial fossa. These are pressed into their respective fossæ during extension.

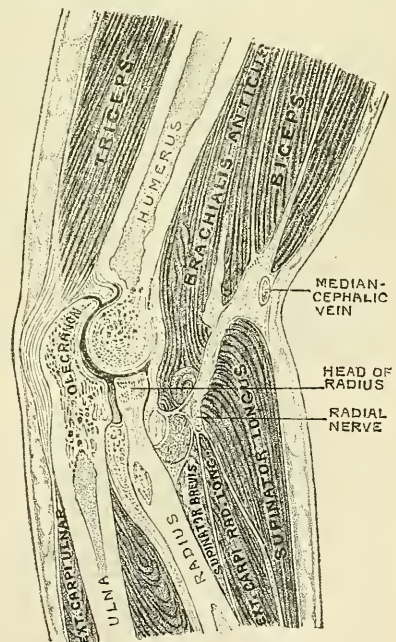
The *Muscles* in relation with the joint are, in front, the Brachialis anticus; behind, the Triceps and Anconeus; externally, the Supinator brevis, and the common tendon of origin of the Extensor muscles; internally, the common tendon of origin of the Flexor muscles, and the Flexor carpi ulnaris, with the ulnar nerve (fig. 284).

The *Arteries* supplying the joint are derived from the communicating branches between the superior profunda, inferior profunda, and anastomotica magna arteries, branches of the brachial, with the anterior, posterior, and interosseous recurrent branches of the ulna, and the recurrent branch of the radial. These vessels form a complete chain of inosculation around the joint.

The *Nerves* are derived from the ulnar, as it passes between the internal condyle and the olecranon; a filament from the musculo-cutaneous (Rüdinger), and two from the median (Macalister).

**Actions.**—The elbow-joint comprises three different portions: viz. the joint between the ulna and humerus, that between the head of the radius and the humerus, and the superior radio-ulnar articulation, described below. All these articular surfaces are invested by a

FIG. 284.—Sagittal section of the right elbow-joint, taken somewhat obliquely and seen from the radial aspect. (After Braune.)





common synovial membrane, and the movements of the whole joint should be studied together. The combination of the movements of flexion and extension of the forearm with those of pronation and supination of the hand, which is ensured by the two being performed at the same joint, is essential to the accuracy of the various minute movements of the hand.

The portion of the joint between the ulna and humerus is a simple hinge-joint, and allows of movements of flexion and extension only. Owing to the obliquity of the trochlear surface of the humerus, this movement does not take place in a straight line; so that when the forearm is extended and supinated, the axis of the arm and forearm is not in the same line, but the one portion of the limb forms an angle with the other, and the hand, with the forearm, is directed outwards. During flexion, on the other hand, the forearm and the hand tend to approach the middle line of the body, and thus enable the hand to be easily carried to the face. The shape of the articular surface of the humerus, with its prominences and depressions accurately adapted to the opposing surfaces of the olecranon, prevents any lateral movement. *Flexion* is produced by the action of the Biceps and Brachialis anticus, assisted by the muscles arising from the internal condyle of the humerus and the Supinator longus; *extension*, by the Triceps and Anconeus, assisted by the extensors of the wrist and by the Extensor communis digitorum and Extensor minimi digiti.

The joint between the head of the radius and the capitellum or radial head of the humerus is an arthrodial joint. The bony surfaces would of themselves constitute an enarthrosis and allow of movement in all directions, were it not for the orbicular ligament by which the head of the radius is bound down firmly to the sigmoid cavity of the ulna, and which prevents any separation of the two bones laterally. It is to the same ligament that the head of the radius owes its security from dislocation, which would otherwise constantly occur, as a consequence of the shallowness of the cup-like surface on the head of the radius. In fact, but for this ligament, the tendon of the Biceps would be liable to pull the head of the radius out of the joint.\* In complete extension, the head of the radius glides so far back on the outer condyle that its edge is plainly felt at the back of the articulation. Flexion and extension of the elbow-joint are limited by the tension of the structures on the front and back of the joint; the limitation of flexion being also aided by the soft structures of the arm and forearm coming in contact.

In combination with any position of flexion or extension, the head of the radius can be rotated in the upper radio-ulnar joint, carrying the hand with it. The hand is articulated to the lower surface of the radius only, and the concave or sigmoid surface on the lower end of the radius travels round the lower end of the ulna. The latter bone is excluded from the wrist-joint (as will be seen in the sequel) by the interarticular fibro-cartilage. Thus, rotation of the head of the radius round an axis which passes through the centre of the radial head of the humerus imparts circular movement to the hand through a very considerable arc.

*Surface Form.*—If the forearm be slightly flexed on the arm, a curved crease or fold with its convexity downwards may be seen running across the front of the elbow, extending from one condyle to the other. The centre of this fold is some slight distance above the line of the joint. The position of the radio-humeral portion of the joint can be at once ascertained by feeling for a slight groove or depression between the head of the radius and the capitellum of the humerus at the back of the articulation.

*Surgical Anatomy.*—From the great breadth of the joint, and the manner in which the articular surfaces are interlocked, and also on account of the strong lateral ligaments and the support which the joint derives from the mass of muscles attached to each condyle of the humerus, lateral displacement of the bones is very uncommon. Whereas antero-posterior dislocation, on account of the shortness of the antero-posterior diameter, the weakness of the anterior and posterior ligaments, and the want of support of muscles, much more frequently takes place. Dislocation backwards takes place when the forearm

\* Humphry, *op. cit.* p. 419.

is in a position of extension, and forwards when in a position of flexion. For, in the former position, that of extension, the coronoid process is not interlocked into the coronoid fossa, and loses its grip to a certain extent, whereas the olecranon process is in the olecranon fossa, and entirely prevents displacement forwards. On the other hand, during flexion, the coronoid process is in the coronoid fossa, and prevents dislocation backwards, while the olecranon loses its grip and is not so efficient, as during extension, in preventing a forward displacement. When lateral dislocation does take place it is generally incomplete.

Dislocation of the elbow-joint is of common occurrence in children, far more common than dislocation of any other articulation, for, as a rule, fracture of a bone more frequently takes place, under the application of any severe violence, in young persons than dislocation. In lesions of this joint there is often very great difficulty in ascertaining the exact nature of the injury.

The elbow-joint is occasionally the seat of acute synovitis. The synovial membrane then becomes distended with fluid, the bulging showing itself principally around the olecranon process, that is to say, on its inner and outer sides and above, in consequence of the laxness of the posterior ligament. Occasionally a well-marked triangular projection may be seen on the outer side of the olecranon, from bulging of the synovial membrane beneath the Anconeus muscle. Again, there is often some swelling just above the head of the radius, in the line of the radio-humeral joint. There is generally not much swelling at the front of the joint, though sometimes deep-seated fulness beneath the Brachialis anticus may be noted. When suppuration occurs the abscess usually points at one or other border of the Triceps muscle; occasionally the pus discharges itself in front, near the insertion of the Brachialis anticus muscle. Chronic synovitis, usually of tuberculous origin, is of common occurrence in the elbow-joint: under these circumstances the forearm tends to assume the position of semi-flexion, which is that of greatest ease and relaxation of ligaments. It should be borne in mind, that should ankylosis occur in this or the extended position, the limb will not be nearly so useful as if ankylosed in a position of rather less than a right angle. Loose cartilages are sometimes met with in the elbow-joint, not so commonly, however, as in the knee; nor do they, as a rule, give rise to such urgent symptoms as in this articulation, and rarely require operative interference. The elbow-joint is also sometimes affected with osteo-arthritis, but this affection is less common in this articulation than in some other of the larger joints.

Excision of the elbow is principally required for three conditions—viz. tuberculous arthritis, injury and its results, and faulty ankylosis—but may be necessary for some other rarer conditions, such as disorganising arthritis after pyæmia, unreduced dislocations, and osteo-arthritis. The results of the operation are, as a rule, more favourable than those of excision of any other joint, and it is one, therefore, that the surgeon should never hesitate to perform, especially in the first three of the conditions mentioned above. The operation is best performed by a single vertical incision down the back of the joint, a transverse incision, over the outer condyle, being added if the parts are much thickened and fixed. A straight incision is made about four inches long, the mid-point of which is on a level with and a little to the inner side of the tip of the olecranon. This incision is made down to the bone, through the substance of the Triceps muscle. The operator with the point of his knife, and guarding the soft parts with his thumb-nail, separates them from the bone. In doing this there are two structures which he should carefully avoid: the ulnar nerve, which lies parallel to his incision, but a little internal, as it courses down between the internal condyle and the olecranon process, and the prolongation of the Triceps into the deep fascia of the forearm over the Anconeus muscle. Having cleared the bones and divided the lateral and posterior ligaments, the forearm is strongly flexed and the ends of the bone turned out and sawn off. The section of the humerus should be through the base of the condyles, that of the ulna and radius should be just below the level of the lesser sigmoid cavity of the ulna and the neck of the radius. In this operation the object is to obtain such union as shall allow free motion of the bones of the forearm; and, therefore, passive motion must be commenced early—that is to say, about the tenth day.

## VI. RADIO-ULNAR ARTICULATIONS

The articulation of the radius with the ulna is effected by ligaments, which connect together both extremities as well as the shafts of these bones. They may, consequently, be subdivided into three sets:—1. The superior radio-ulnar, which is a portion of the elbow-joint; 2. the middle radio-ulnar; and, 3. the inferior radio-ulnar articulations.

### I. SUPERIOR RADIO-ULNAR ARTICULATION

This articulation is a trochoid or pivot-joint. The bones entering into its formation are the inner side of the circumference of the head of the radius

rotating within the lesser sigmoid cavity of the ulna. Its only ligament is the *annular* or *orbicular*.

The **Orbicular Ligament** (fig. 283) is a strong, flat band of ligamentous fibres, which surrounds the head of the radius, and retains it in firm connection with the lesser sigmoid cavity of the ulna. It forms about four-fifths of an osseo-fibrous ring, attached by each end to the extremities of the lesser sigmoid cavity, and is smaller at the lower part of its circumference than above, by which means the head of the radius is more securely held in its position. Its *outer surface* is strengthened by the external lateral ligament of the elbow, and affords origin to part of the Supinator brevis muscle. Its *inner surface* is smooth, and lined by synovial membrane. The synovial membrane is continuous with that which lines the elbow-joint.

**Actions.**—The movement which takes place in this articulation is limited to rotation of the head of the radius within the orbicular ligament, and upon the lesser sigmoid cavity of the ulna; rotation forwards being called *pronation*; rotation backwards, *supination*. Supination is performed by the Biceps and Supinator brevis, assisted to a slight extent by the Extensor muscles of the thumb and, in certain positions, by the Supinator longus. Pronation is performed by the Pronator radii teres and the Pronator quadratus, assisted, in some positions, by the Supinator longus.

**Surface Form.**—The position of the superior radio-ulnar joint is marked on the surface of the body by the little dimple on the back of the forearm which indicates the position of the head of the radius.

**Surgical Anatomy.**—Dislocation of the head of the radius alone is not an uncommon accident, and occurs most frequently in young persons from falls on the hand when the forearm is extended and supinated, the head of the bone being displaced forward. It is attended by rupture of the orbicular ligament.

## 2. MIDDLE RADIO-ULNAR ARTICULATION

The interval between the shafts of the radius and ulna is occupied by two ligaments.

Oblique.

Interosseous.

The **Oblique** or **Round Ligament** (fig. 282) is a small, flattened fibrous band, which extends obliquely downwards and outwards, from the tubercle of the ulna at the base of the coronoid process to the radius a little below the bicipital tuberosity. Its fibres run in the opposite direction to those of the interosseous ligament; and it appears to be placed as a substitute for it in the upper part of the interosseous interval. This ligament is sometimes wanting.

The **Interosseous Membrane** is a broad and thin plane of fibrous tissue descending obliquely downwards and inwards, from the interosseous ridge on the radius to that on the ulna. It is deficient above, commencing about an inch beneath the tubercle of the radius; is broader in the middle than at either extremity; and presents an oval aperture just above its lower margin for the passage of the anterior interosseous vessels to the back of the forearm. This ligament serves to connect the bones, and to increase the extent of surface for the attachment of the deep muscles. Between its upper border and the oblique ligament an interval exists, through which the posterior interosseous vessels pass. Two or three fibrous bands are occasionally found on the posterior surface of this membrane, which descend obliquely from the ulna towards the radius, and which have consequently a direction contrary to that of the other fibres. It is in relation, *in front*, by its upper three-fourths, with the Flexor longus pollicis on the outer side, and with the Flexor profundus digitorum on the inner, lying upon the interval between which are the anterior interosseous vessels and nerve; by its lower fourth with the Pronator quadratus; *behind*, with the Supinator brevis, Extensor ossis metacarpi pollicis, Extensor brevis pollicis,



Extensor longus pollicis, Extensor indicis; and, near the wrist, with the anterior interosseous artery and posterior interosseous nerve.

### 3. INFERIOR RADIO-ULNAR ARTICULATION

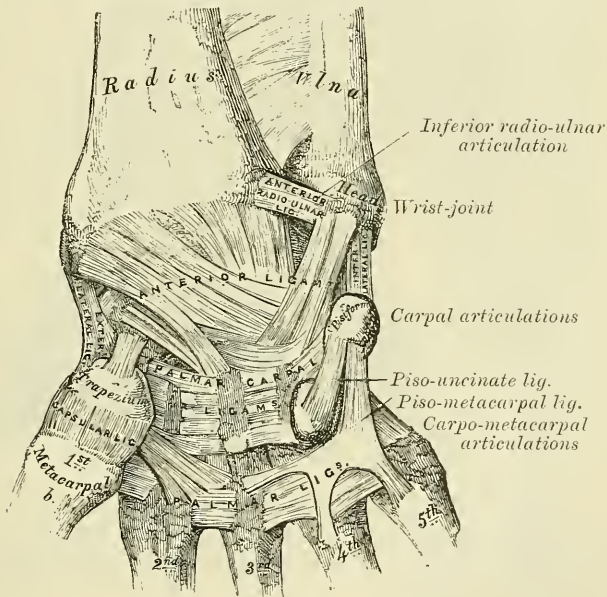
This is a pivot-joint, formed by the head of the ulna received into the sigmoid cavity at the inner side of the lower end of the radius. The articular surfaces are covered by a thin layer of cartilage, and connected together by the following ligaments:—

Anterior Radio-ulnar.                      Posterior Radio-ulnar.  
Interarticular Fibro-cartilage.

The **Anterior Radio-ulnar Ligament** (fig. 285) is a narrow band of fibres extending from the anterior margin of the sigmoid cavity of the radius to the anterior surface of the head of the ulna.

The **Posterior Radio-ulnar Ligament** (fig. 286) extends between similar points on the posterior surface of the articulation.

FIG. 285.—Ligaments of wrist and hand. Anterior view.



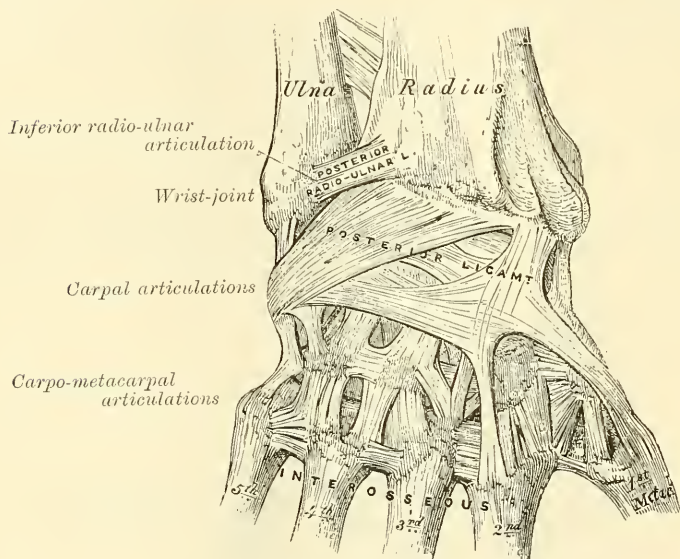
The **Interarticular Fibro-cartilage** (fig. 288) is triangular in shape, and is placed transversely beneath the head of the ulna, binding the lower end of this bone and the radius firmly together. Its circumference is thicker than its centre, which is thin and occasionally perforated. It is attached by its apex to a depression which separates the styloid process of the ulna from the head of that bone; and by its base, which is thin, to the prominent edge of the radius, which separates the sigmoid cavity from the carpal articulating surface. Its margins are united to the ligaments of the wrist-joint. Its *upper surface*, smooth and concave, articulates with the head of the ulna, forming an arthrodial joint; its *under surface*, also concave and smooth, forms part of the wrist-joint and articulates with the cuneiform bone. Both surfaces are lined by a synovial membrane: the upper surface, by one peculiar to the radio-ulnar articulation; the under surface, by the synovial membrane of the wrist.

The **Synovial Membrane** (fig. 288) of this articulation has been called, from its extreme looseness, the *membrana sacciformis*; it extends horizontally inwards

between the head of the ulna and the interarticular fibro-cartilage, and upwards between the radius and the ulna, forming here a very loose *cul-de-sac*. The quantity of synovia which it contains is usually considerable.

**Actions.**—The movement in the inferior radio-ulnar articulation is just the reverse of that between the two bones above. It consists of a movement of rotation of the lower end of the radius round an axis which corresponds to the centre of the head of the ulna. When the radius rotates forwards, *pronation* of the forearm and hand is the result; and when backwards, *supination*. It will thus be seen that in pronation and supination of the forearm and hand the radius describes a segment of a cone, the axis of which extends from the centre of the head of the radius to the middle of the head of the ulna. In this movement, however, the ulna is not quite stationary, but rotates a little in the opposite direction. So that it also describes the segment of a cone, though of smaller size than that described by the radius. The movement which causes this altera-

FIG. 286.—Ligaments of wrist and hand. Posterior view.



tion in the position of the head of the ulna takes place principally at the shoulder-joint by a rotation of the humerus, but possibly also to a slight extent at the elbow-joint.\*

**Surface Form.**—The position of the inferior radio-ulnar joint may be ascertained by feeling for a slight groove at the back of the wrist, between the prominent head of the ulna and the lower end of the radius, when the forearm is in a state of almost complete pronation.

## VII. RADIO-CARPAL OR WRIST-JOINT

The **Wrist** is a condyloid articulation. The parts entering into its formation are the lower end of the radius and under surface of the interarticular fibro-cartilage, which form together the receiving cavity; and the scaphoid, semilunar, and cuneiform bones, which form the condyle. The articular surface of the radius and the under surface of the interarticular fibro-cartilage, the receiving cavity, form together a transversely elliptical concave surface. The articular surfaces of the scaphoid, semilunar, and cuneiform bones form together a smooth, convex surface, the *condyle*, which is received into the concavity above mentioned. All the bony surfaces of the articulation are covered with cartilage,

\* See *Journ. of Anat. and Phys.*, vol. xix. parts ii., iii., and iv.

and connected together by a capsule, which is divided into the following ligaments:—

External Lateral.  
Internal Lateral.

Anterior.  
Posterior.

The **External Lateral Ligament** (*radio-carpal*) (fig. 285) extends from the summit of the styloid process of the radius to the outer side of the scaphoid, some of its fibres being prolonged to the trapezium and annular ligament.

The **Internal Lateral Ligament** (*ulno-carpal*) is a rounded cord, attached, above, to the extremity of the styloid process of the ulna; and dividing below into two fasciculi, which are attached, one to the inner side of the cuneiform bone, the other to the pisiform bone and annular ligament.

The **Anterior Ligament** is a broad membranous band, attached, above, to the anterior margin of the lower end of the radius, its styloid process and the ulna; its fibres pass downwards and inwards to be inserted into the palmar surface of the scaphoid, semilunar, and cuneiform bones, some of the fibres being continued to the os magnum. In addition to this broad membrane, there is a distinct rounded fasciculus, superficial to the rest, which passes from the base of the styloid process of the ulna to the semilunar and cuneiform bones. This ligament is perforated by numerous apertures for the passage of vessels, and is in relation, in front, with the tendons of the Flexor profundus digitorum and Flexor longus pollicis; behind, with the synovial membrane of the wrist-joint.

The **Posterior Ligament** (fig. 286), less thick and strong than the anterior, is attached, above, to the posterior border of the lower end of the radius; its fibres pass obliquely downwards and inwards, to be attached to the dorsal surface of the scaphoid, semilunar, and cuneiform bones, being continuous with those of the dorsal carpal ligaments. This ligament is in relation, behind, with the extensor tendons of the fingers; in front, with the synovial membrane of the wrist.

The **Synovial Membrane** (fig. 288) lines the inner surface of the ligaments above described, extending from the lower end of the radius and interarticular fibro-cartilage above to the articular surfaces of the carpa' bones below. It is loose and lax, and presents numerous folds, especially behind.

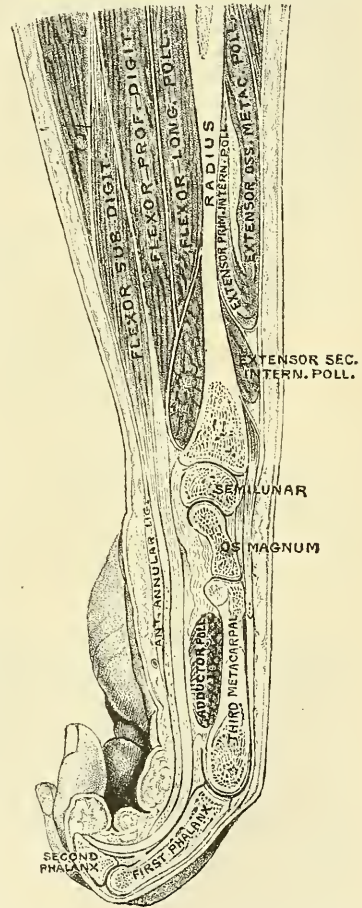
**Relations.**—The wrist-joint is covered in front by the flexor, and behind by the extensor tendons; it is also in relation with the radial and ulnar arteries.

The **Arteries** supplying the joint are the anterior and posterior carpal branches of the radial and ulnar, the anterior and posterior interosseous, and some ascending branches from the deep palmar arch.

The **Nerves** are derived from the ulnar and posterior interosseous.

**Actions.**—The movements permitted in this joint are flexion, extension,

FIG. 287.—Longitudinal section of the right forearm, hand, and third finger, viewed from the ulnar aspect. (After Braune.)





abduction, adduction, and circumduction. Its actions will be further studied with those of the carpus, with which they are combined.

*Surface Form.*—The line of the radio-carpal joint is on a level with the apex of the styloid process of the ulna.

*Surgical Anatomy.*—The wrist-joint is rarely dislocated, its strength depending mainly upon the numerous strong tendons which surround the articulation. Its security is further provided for by the number of small bones of which the carpus is made up, and which are united by very strong ligaments. The slight movement which takes place between the several bones serves to break the jars that result from falls or blows on the hand. Dislocation backwards, which is the more common, simulates to a considerable extent Colles' fracture of the radius, and is liable to be mistaken for it. The diagnosis can be easily made out by observing the relative position of the styloid processes of the radius and the ulna. In the natural condition the styloid process of the radius is on a lower level, i.e. nearer the ground, when the arm hangs by the side, than that of the ulna, and the same would be the case in dislocation. In Colles' fracture, on the other hand, the styloid process of the radius is on the same, or even a higher level than that of the ulna.

The wrist-joint is occasionally the seat of acute synovitis, the result of traumatism, or arising in the rheumatic or pyæmic state. When the synovial sac is distended with fluid, the swelling is greatest on the dorsal aspect of the wrist, showing a general fulness, with some bulging between the tendons. The inflammation is prone to extend to the inter-carpal joints and to attack also the sheaths of the tendons in the neighbourhood. Chronic inflammation of the wrist is generally tuberculous, and often leads to similar disease in the synovial sheaths of adjacent tendons and of the intercarpal joints. The disease, therefore, when progressive, often leads to necrosis of the carpal bones, and the result is often unsatisfactory.

### VIII. ARTICULATIONS OF THE CARPUS

These articulations may be subdivided into three sets—

1. The Articulations of the First Row of Carpal Bones.
2. The Articulations of the Second Row of Carpal Bones.
3. The Articulations of the Two Rows with each other.

#### I. ARTICULATIONS OF THE FIRST ROW OF CARPAL BONES

These are arthrodial joints. The ligaments connecting the scaphoid, semilunar, and cuneiform bones are—

Dorsal.	Palmar.
Two Interosseous.	

The **Dorsal Ligaments** are placed transversely behind the bones of the first row; they connect the scaphoid and semilunar, and the semilunar and cuneiform.

The **Palmar Ligaments** connect the scaphoid and semilunar, and the semilunar and cuneiform bones; they are less strong than the dorsal, and placed very deeply under the anterior ligament of the wrist.

The **Interosseous Ligaments** (fig. 288) are two narrow bundles of fibrous tissue, connecting the semilunar bone, on one side with the scaphoid, and on the other with the cuneiform. They are on a level with the superior surfaces of these bones, and close the upper part of the spaces between them. Their upper surfaces are smooth, and form with the bones the convex articular surfaces of the wrist-joint.

The ligaments connecting the pisiform bone are—

Capsular.	Two palmar ligaments.
-----------	-----------------------

The **Capsular Ligament** is a thin membrane which connects the pisiform bone to the cuneiform. It is lined with a separate synovial membrane.

The **two Palmar Ligaments** are two strong fibrous bands which connect the pisiform to the unciform, the *pisio-uncinate*, and to the base of the fifth carpal bone, the *pisio-metacarpal ligament* (fig. 285).

## 2. ARTICULATIONS OF THE SECOND ROW OF CARPAL BONES

These are also arthrodial joints. The articular surfaces are covered with cartilage, and connected by the following ligaments :—

Dorsal.	Palmar.
Three Interosseous.	

The **Dorsal Ligaments** extend transversely from one bone to another on the dorsal surface, connecting the trapezium with the trapezoid, the trapezoid with the os magnum, and the os magnum with the unciform.

The **Palmar Ligaments** have a similar arrangement on the palmar surface.

The **three Interosseous Ligaments**, much thicker than those of the first row, are placed one between the os magnum and the unciform, a second between the os magnum and the trapezoid, and a third between the trapezium and trapezoid. The first of these is much the strongest, and the third is sometimes wanting. Sometimes a slender interosseous band connects the os magnum and the scaphoid.

## 3. ARTICULATIONS OF THE TWO ROWS OF CARPAL BONES WITH EACH OTHER

The joint between the scaphoid, semilunar, and cuneiform, and the second row of the carpus, or the *mid-carpal joint*, is made up of three distinct portions ; in the centre the head of the os magnum and the superior surface of the unciform articulate with the deep cup-shaped cavity formed by the scaphoid and semilunar bones, and constitute a sort of ball-and-socket joint. On the outer side the trapezium and trapezoid articulate with the scaphoid, and on the inner side the unciform articulates with the cuneiform, forming gliding joints.

The ligaments are :—

Anterior or Palmar.	External Lateral.
Posterior or Dorsal.	Internal Lateral.

The **Anterior or Palmar Ligament** consists of short fibres, which pass, for the most part, from the palmar surface of the bones of the first row to the front of the os magnum.

The **Posterior or Dorsal Ligament** consists of short, irregular bundles of fibres passing between the bones of the first and second row on the dorsal surface of the carpus.

The **Lateral Ligaments** are very short : they are placed, one on the radial, the other on the ulnar side of the carpus ; the former, the stronger and more distinct, connecting the scaphoid and trapezium bones, the latter the cuneiform and unciform ; they are continuous with the lateral ligaments of the wrist-joint.

The **Synovial Membrane of the Carpus** is very extensive ; it passes from the under surface of the scaphoid, semilunar, and cuneiform bones to the upper surface of the bones of the second row, sending upwards two prolongations—between the scaphoid and semilunar, and the semilunar and cuneiform—sending downwards three prolongations between the four bones of the second row, which are further continued onwards into the carpo-metacarpal joints of the four inner metacarpal bones, and also for a short distance between the metacarpal bones. There is a separate synovial membrane between the pisiform and cuneiform bones.

**Actions.**—The articulation of the hand and wrist, considered as a whole, is divided into three parts : (1) the radius and the interarticular fibro-cartilage ; (2) the meniscus, formed by the scaphoid, semilunar, and cuneiform—the pisiform bone having no essential part in the movement of the hand ; (3) the hand proper, the metacarpal bones with the four carpal bones on which they are supported, viz. the trapezium, trapezoid, os magnum, and unciform. These three elements form two joints : (1) the superior (wrist-joint proper), between the

meniscus and bones of the forearm; (2) the inferior, between the hand and meniscus (transverse or mid-carpal joint).

(1) The articulation between the forearm and carpus is a true condyloid articulation, and therefore all movements but rotation are permitted. Flexion and extension are the most free, and of these a greater amount of extension than flexion is permitted on account of the articulating surfaces extending further on the dorsal than on the palmar aspect of the carpal bones. In this movement the carpal bones rotate on a transverse axis drawn between the tips of the styloid processes of the radius and ulna. A certain amount of adduction (or ulnar flexion) and abduction (or radial flexion) is also permitted. Of these the former is considerably greater in extent than the latter. In this movement the carpus revolves upon an antero-posterior axis drawn through the centre of the wrist. Finally, circumduction is permitted by the consecutive movements of adduction, extension, abduction, and flexion, with intermediate movements between them. There is no rotation, but this is provided for by the supination and pronation of the radius on the ulna. The movement of *flexion* is performed by the Flexor carpi radialis, the Flexor carpi ulnaris, and the Palmaris longus; *extension* by the Extensor carpi radialis longior et brevior and the Extensor carpi ulnaris; *adduction* (ulnar flexion) by the Flexor carpi ulnaris and the Extensor carpi ulnaris; and *abduction* (radial flexion) by the Extensors of the thumb, and the Extensor carpi radialis longior et brevior and the Flexor carpi radialis.

(2) The chief movements permitted in the transverse or mid-carpal joint are flexion and extension and a slight amount of rotation. In flexion and extension, which is the movement most freely enjoyed, the trapezium and trapezoid on the radial side and the unciform on the ulnar side glide forwards and backwards on the scaphoid and cuneiform respectively, while the head of the os magnum and the superior surface of the unciform rotate in the cup-shaped cavity of the scaphoid and semilunar. Flexion at this joint is freer than extension. A very trifling amount of rotation is also permitted, the head of the os magnum rotating round a vertical axis drawn through its own centre, while at the same time a slight gliding movement takes place in the lateral portions of the joint.

## IX. CARPO-METACARPAL ARTICULATIONS

### I. ARTICULATION OF THE METACARPAL BONE OF THE THUMB WITH THE TRAPEZIUM

This is a joint of reciprocal reception, and enjoys a great freedom of movement, on account of the configuration of its articular surfaces, which are saddle-shaped, so that, on section, each bone appears to be received into a cavity in the other, according to the direction in which they are cut. Its ligaments are a capsular ligament and a synovial membrane.

The **Capsular Ligament** is a thick but loose capsule, which passes from the circumference of the upper extremity of the metacarpal bone to the rough edge bounding the articular surface of the trapezium; it is thickest externally and behind, and lined by a separate *synovial membrane*.

**Movements.**—In the articulation of the metacarpal bone of the thumb with the trapezium, the movements permitted are flexion, extension, adduction, abduction, and circumduction. When the joint is flexed, the metacarpal bone is brought in front of the palm, and the thumb is gradually turned to the fingers. It is by this peculiar movement that the tip of the thumb is opposed to the other digits; for, by slightly flexing the fingers, the palmar surface of the thumb can be brought in contact with their palmar surfaces one after another.



## 2. ARTICULATIONS OF THE METACARPAL BONES OF THE FOUR INNER FINGERS WITH THE CARPUS

The joints formed between the carpus and four inner metacarpal bones are arthrodial joints. The ligaments are

Dorsal.                      Palmar.  
Interosseous.

The **Dorsal Ligaments**, the strongest and most distinct, connect the carpal and metacarpal bones on their dorsal surface. The second metacarpal bone receives two fasciculi, one from the trapezium, the other from the trapezoid; the third metacarpal receives two, one from the trapezoid, and one from the os magnum; the fourth two, one from the os magnum, and one from the unciform; the fifth receives a single fasciculus from the unciform bone, which is continuous with a similar ligament on the palmar surface, forming an incomplete capsule.

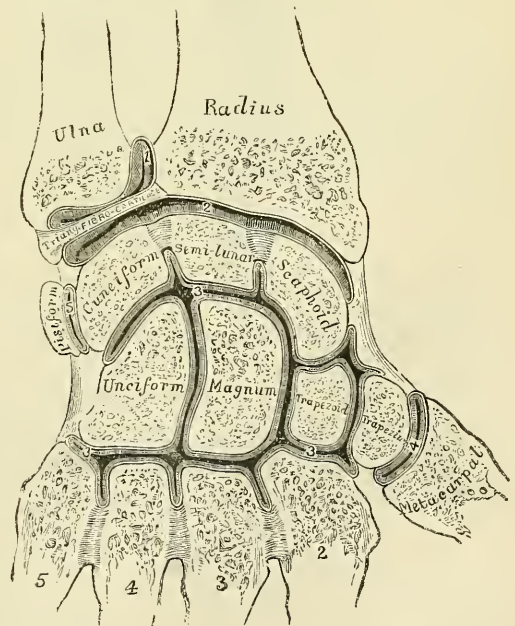
The **Palmar Ligaments** have a somewhat similar arrangement on the palmar surface, with the exception of the third metacarpal, which has three ligaments, an external one from the trapezium, situated above the sheath of the tendon of the Flexor carpi radialis; a middle one from the os magnum; and an internal one from the unciform.

The **Interosseous Ligaments** consist of short, thick fibres, which are limited to one part of the carpo-metacarpal articulation; they connect the contiguous inferior angles of the os magnum and unciform with the adjacent surfaces of the third and fourth metacarpal bones.

The **Synovial Membrane** is a continuation of that between the two rows of carpal bones. Occasionally, the articulation of the unciform with the fourth and fifth metacarpal bones has a separate synovial membrane.

The synovial membranes of the wrist and carpus (fig. 288) are thus seen to be five in number. The *first*, the *membrana sacciformis*, passes from the lower end of the ulna to the sigmoid cavity of the radius, and lines the upper surface of the interarticular fibro-cartilage. The *second* passes from the lower end of the radius and interarticular fibro-cartilage above, to the bones of the first row below. The *third*, the most extensive, passes between the contiguous margins of the two rows of carpal bones and between the bones of the second row to the carpal extremities of the four inner metacarpal bones. The *fourth*, from the margin of the trapezium to the metacarpal bone of the thumb. The *fifth*, between the adjacent margins of the cuneiform and pisiform bones.

FIG. 288.—Vertical section through the articulations at the wrist, showing the five synovial membranes.



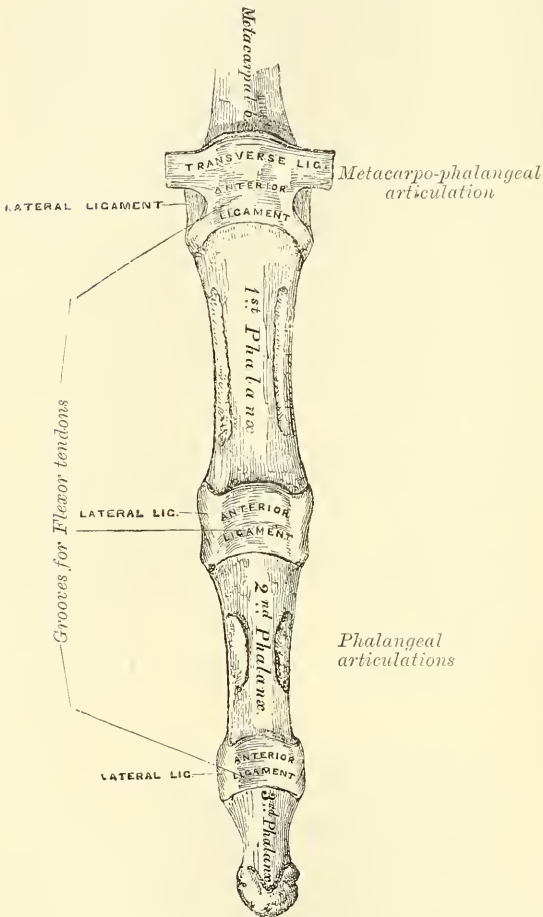
**Actions.**—The movement permitted in the carpo-metacarpal articulations of the four inner fingers is limited to a slight gliding of the articular surfaces upon each other, the extent of which varies in the different joints. Thus the articulation

of the metacarpal bone of the little finger is most movable, then that of the ring-finger. The metacarpal bones of the index and middle fingers are almost immovable.

### 3. ARTICULATIONS OF THE METACARPAL BONES WITH EACH OTHER

The carpal extremities of the four inner metacarpal bones articulate with

FIG. 289.—Articulations of the phalanges.



one another at each side by small surfaces covered with cartilage, and connected together by dorsal, palmar, and interosseous ligaments.

The **Dorsal** and **Palmar Ligaments** pass transversely from one bone to another on the dorsal and palmar surfaces. The *Interosseous Ligaments* pass between their contiguous surfaces, just beneath their lateral articular facets.

The **Synovial Membrane** between the lateral facets is a reflection from that between the two rows of carpal bones.

The **Transverse Metacarpal Ligament** (fig. 289) is a narrow fibrous band, which passes transversely across the anterior surfaces of the digital extremities of the four inner metacarpal bones, connecting them together. It is blended anteriorly with the anterior (glenoid) ligament of the metacarpo-phalangeal articulations. To its posterior border is connected the fascia which covers the *Interossei* muscles. Its superficial surface is concave where the flexor tendons pass over

it. Beneath it the tendons of the *Interossei* muscles pass to their insertion.

### X. METACARPO-PHALANGEAL ARTICULATIONS (fig. 289)

These articulations are of the condyloid kind, formed by the reception of the rounded head of the metacarpal bone into a superficial cavity in the extremity of the first phalanx. The ligaments are :

Anterior. Two lateral.

The **Anterior Ligaments** (*Glenoid Ligaments* of Cruveilhier) are thick, dense, fibrous structures, placed on the palmar surface of the joints in the intervals between the lateral ligaments, to which they are connected; they are loosely united to the metacarpal bone, but very firmly to the base of the first phalanges. Their palmar surface is intimately blended with the transverse metacarpal ligament, and presents a groove for the passage of the flexor tendons, the sheath surrounding which is connected to each side of the groove. By their deep

surface, they form part of the articular surface for the head of the metacarpal bone, and are lined by a synovial membrane.

The **Lateral Ligaments** are strong, rounded cords, placed one on each side of the joint, each being attached by one extremity to the posterior tubercle on the side of the head of the metacarpal bone, and by the other to the contiguous extremity of the phalanx.

**Actions.**—The movements which occur in these joints are flexion, extension, adduction, abduction, and circumduction; the lateral movements are very limited.

*Surface Form.*—The prominences of the knuckles do not correspond to the position of the joints either of the metacarpo-phalangeal or interphalangeal articulations. These prominences are invariably formed by the distal ends of the proximal bone of each joint, and the line indicating the position of the joint must be sought considerably in front of the middle of the knuckle. The usual rule for finding these joints is to flex the distal phalanx on the proximal one to a right angle; the position of the joint is then indicated by an imaginary line drawn along the middle of the lateral aspect of the proximal phalanx.

#### XI. ARTICULATIONS OF THE PHALANGES

These are ginglymus joints. The ligaments are :—

Anterior.

Two Lateral.

The arrangement of these ligaments is similar to those in the metacarpo-phalangeal articulations; the extensor tendon supplies the place of a posterior ligament.

**Actions.**—The only movements permitted in the phalangeal joints are flexion and extension; these movements are more extensive between the first and second phalanges than between the second and third. The movement of flexion is very considerable, but extension is limited by the anterior and lateral ligaments.

#### ARTICULATIONS OF THE LOWER EXTREMITY

The articulations of the Lower Extremity comprise the following groups:—

I. The hip-joint. II. The knee-joint. III. The articulations between the tibia and fibula. IV. The ankle-joint. V. The articulations of the tarsus. VI. The tarso-metatarsal articulations. VII. Articulations of the metatarsal bones with each other. VIII. The metatarso-phalangeal articulations. IX. The articulations of the phalanges.

##### I. HIP-JOINT (fig. 290)

This articulation is an enarthrodial, or ball-and-socket joint, formed by the reception of the head of the femur into the cup-shaped cavity of the acetabulum. The articulating surfaces are covered with cartilage, that on the head of the femur being thicker at the centre than at the circumference, and covering the entire surface with the exception of a depression just below its centre for the ligamentum teres; that covering the acetabulum is much thinner at the centre than at the circumference. It forms an incomplete cartilaginous ring, of a horseshoe shape, deficient below and in front, and having in its centre a circular depression, which is occupied in the recent state by a mass of fat, covered by synovial membrane. The ligaments of the joint are the

Capsular.

Teres.

Ilio-femoral.

Cotyloid.

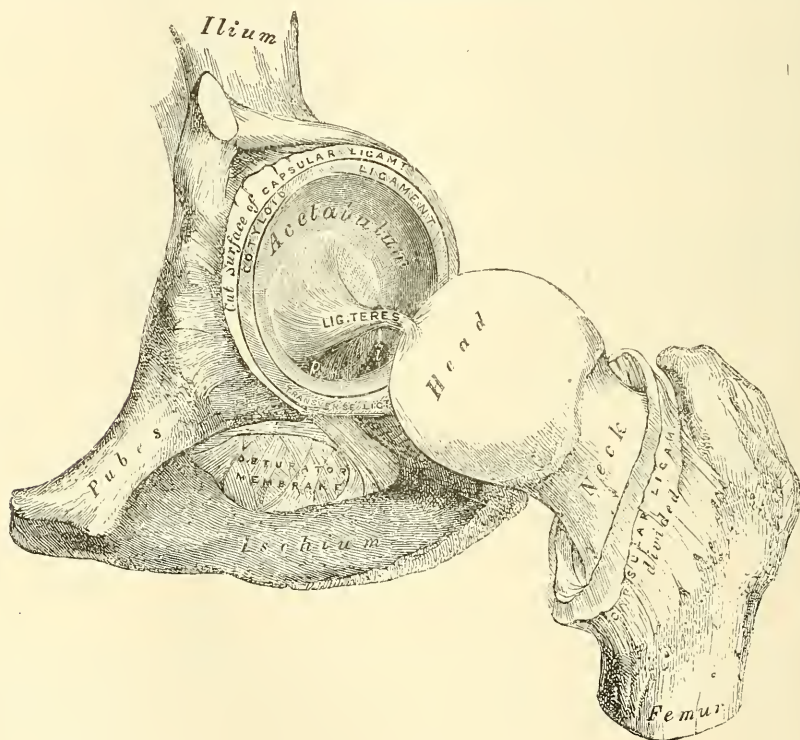
Transverse.

The **Capsular Ligament** is a strong, dense, ligamentous capsule, embracing the margin of the acetabulum above, and surrounding the neck of the femur below. Its *upper circumference* is attached to the acetabulum, two or three lines external to the cotyloid ligament, above and behind; but in front, it is attached



to the outer margin of the ligament, and opposite to the notch where the margin of the cavity is deficient, it is connected to the transverse ligament, and by a few fibres to the edge of the obturator foramen. Its *lower circumference* surrounds the neck of the femur, being attached, in front, to the spiral or anterior intertrochanteric line; above, to the base of the neck; behind, to the neck of the bone, about half an inch above the posterior intertrochanteric line. From this insertion the fibres are reflected upwards over the neck of the femur, forming a sort of tubular sheath (the *cervical reflection*), which blends with the periosteum, and can be traced as far as the articular cartilage. On the surface of the neck of the femur some of these reflected fibres are raised into longitudinal folds, termed *retinacula*. It is much thicker at the upper and fore part of the joint, where the greatest amount of resistance is required, than below and internally, where it is thin, loose, and longer than in any other part. It consists of two sets of fibres, circular and longitudinal. The circular fibres are most abundant

FIG. 290.—Left hip-joint laid open.



at the lower and back part of the capsule, while the longitudinal fibres are greatest in amount at the upper and front part of the capsule, where they form distinct bands, or accessory ligaments, of which the most important is the *ilio-femoral*. The other accessory bands are known as the *pubo-femoral*, passing from the ilio-pectineal eminence to the front of the capsule; *ilio-trochanteric*, from the anterior inferior spine of the ilium to the front of the great trochanter; and *ischio-capsular*, passing from the ischium, just below the acetabulum, to blend with the circular fibres at the lower part of the joint. The external surface (fig. 275, page 329) is rough, covered by numerous muscles, and separated in front from the Psoas and Iliacus by a synovial bursa, which not unfrequently communicates, by a circular aperture, with the cavity of the joint. It differs from the capsular ligament of the shoulder in being much less loose and lax, and in not being perforated for the passage of a tendon.

The **Ilio-femoral Ligament** (figs. 275 and 291) is an accessory band of fibres

extending obliquely across the front of the joint; it is intimately connected with the capsular ligament, and serves to strengthen it in this situation. It is attached, above, to the lower part of the anterior inferior spine of the ilium; and, diverging below, forms two bands, of which one passes downwards to be inserted into the lower part of the anterior intertrochanteric line; the other passes downwards and outwards to be inserted into the upper part of the same line and adjacent part of the neck of the femur. Between the two bands is a thinner part of the capsule. Sometimes there is no division, but the ligament spreads out into a flat triangular band, which is attached below into the whole length of the anterior intertrochanteric line. This ligament is frequently called the Y-shaped ligament of Bigelow.

The **Ligamentum Teres** is a triangular band implanted by its apex into the depression a little behind and below the centre of the head of the femur, and by

FIG. 291.—Hip-joint, showing the ilio-femoral ligament. (After Bigelow.)

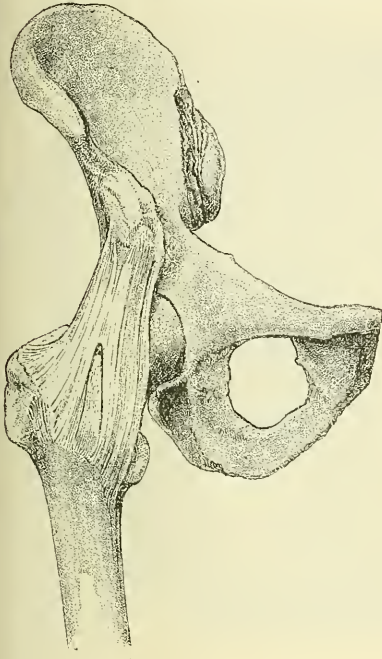
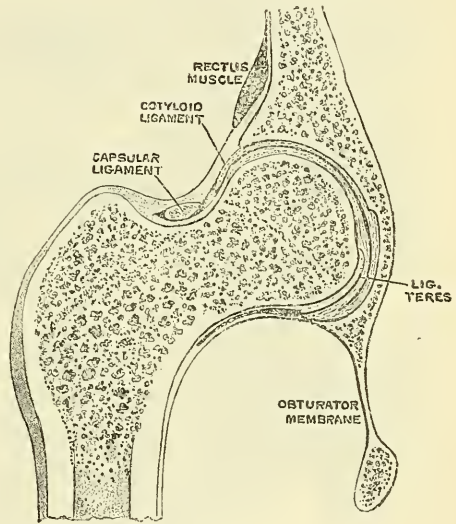


FIG. 292.—Vertical section through hip-joint. (Henle.)



its broad base into the margins of the cotyloid notch, becoming blended with the transverse ligament. It is formed of connective tissue, surrounded by a tubular sheath of synovial membrane. Sometimes only the synovial fold exists, or the ligament may be altogether absent. The ligament is made tense when the hip is semiflexed, and the limb then adducted and rotated outwards; it is, on the other hand, relaxed when the limb is abducted. It has, however, but little influence as a ligament, though it may to a certain extent limit movement, and would appear to be merely a modification of the folds which in other joints fringe the margins of reflection of synovial membranes (see page 306).

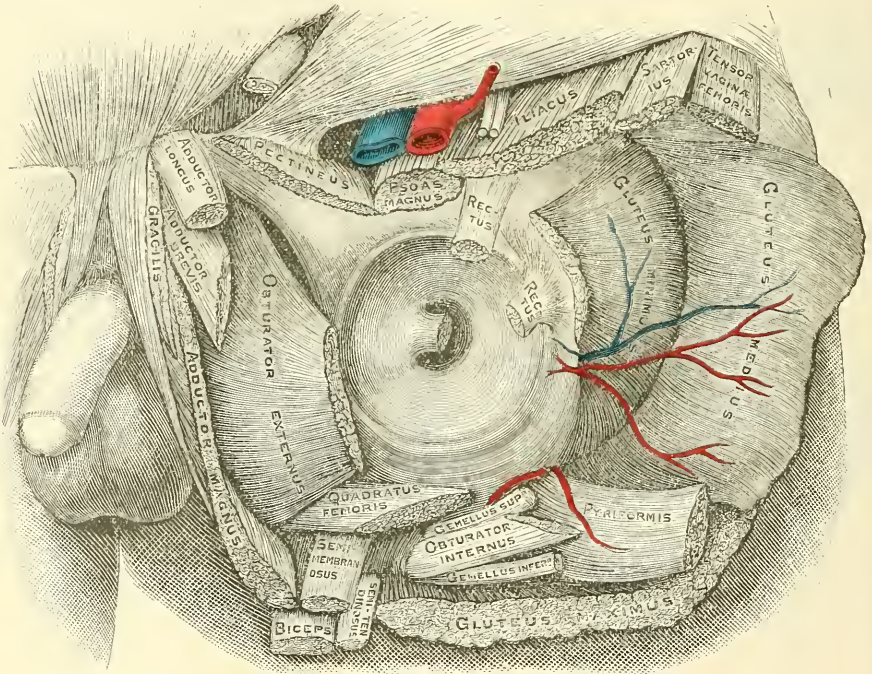
The **Cotyloid Ligament** is a fibro-cartilaginous rim attached to the margin of the acetabulum, the cavity of which it deepens; at the same time it protects the edges of the bone, and fills up the inequalities on its surface. It bridges over the notch as the *transverse ligament*, and thus forms a complete circle, which closely surrounds the head of the femur, and assists in holding it in its place, acting as a sort of valve. It is prismoid in form, its base being attached to the margin of the acetabulum, and its opposite edge being free and sharp; whilst its two



surfaces are invested by synovial membrane, the external one being in contact with the capsular ligament, the internal one being inclined inwards so as to narrow the acetabulum, and embrace the cartilaginous surface of the head of the femur. It is much thicker above and behind than below and in front, and consists of close compact fibres, which arise from different points of the circumference of the acetabulum, and interlace with each other at very acute angles.

The **Transverse Ligament** is in reality a portion of the cotyloid ligament, though differing from it in having no nests of cartilage cells amongst its fibres. It consists of strong, flattened fibres, which cross the notch at the lower part of the acetabulum, and convert it into a foramen. Thus an interval is left beneath the ligament for the passage of nutrient vessels to the joint.

FIG. 293.—Relation of muscles to the capsule of the hip-joint. From a drawing by Mr. F. A. Barton.



The **Synovial Membrane** is very extensive. Commencing at the margin of the cartilaginous surface of the head of the femur, it covers all that portion of the neck which is contained within the joint; from the neck it is reflected on the internal surface of the capsular ligament, covers both surfaces of the cotyloid ligament and the mass of fat contained in the depression at the bottom of the acetabulum, and is prolonged in the form of a tubular sheath around the ligamentum teres, as far as the head of the femur. It sometimes communicates by a hole in the capsular ligament between the two limbs of the Y-shaped ligament with a bursa situated on the under surface of the Ilio-psoas muscle.

The muscles in relation with the joint are, in front, the Psoas and Iliacus, separated from the capsular ligament by a synovial bursa; above, the reflected head of the Rectus and Gluteus minimus, the latter being closely adherent to the capsule; internally the Obturator externus and Pectineus; behind, the Piriformis, Gemellus superior, Obturator internus, Gemellus inferior, Obturator externus, and Quadratus femoris (fig. 293).

The arteries supplying the joint are derived from the obturator, sciatic, internal circumflex, and gluteal.



The nerves are articular branches from the sacral plexus, great sciatic, obturator, accessory obturator, and a filament from the branch of the anterior crural supplying the Rectus.

**Actions.**—The movements of the hip, like those of all enarthrodial joints, are very extensive; they are, flexion, extension, adduction, abduction, circumduction, and rotation.

The hip-joint presents a very striking contrast to the other great enarthrodial joint—the shoulder—in the much more complete mechanical arrangements for its security and for the limitation of its movements. In the shoulder, as we have seen, the head of the humerus is not adapted at all in shape to the glenoid cavity, and is hardly restrained in any of its ordinary movements by the capsular ligament. In the hip-joint, on the contrary, the head of the femur is closely fitted to the acetabulum for a distance extending over nearly half a sphere, and at the margin of the bony cup it is still more closely embraced by the ligamentous ring of the cotyloid ligament, so that the head of the femur is held in its place by that ligament even when the fibres of the capsule have been quite divided (Humphry). The anterior portion of the capsule, described as the ilio-femoral or accessory ligament, is the strongest of all the ligaments in the body, and is put on the stretch by any attempt to extend the femur beyond a straight line with the trunk. That is to say, this ligament is the chief agent in maintaining the erect position without muscular fatigue; for a vertical line passing through the centre of gravity of the trunk falls behind the centres of rotation in the hip-joints, and therefore the pelvis tends to fall backwards, but is prevented by the tension of the ilio-femoral and capsular ligaments. The security of the joint may be also provided for by the two bones being directly united through the ligamentum teres; but it is doubtful whether this so-called ligament can have much influence upon the mechanism of the joint. Flexion of the hip-joint is arrested by the soft parts of the thigh and abdomen being brought into contact when the leg is flexed on the thigh; but, when the leg is extended, by the action of the hamstring muscles; \* extension by the tension of the ilio-femoral ligament and front of the capsule; adduction by the thighs coming into contact; adduction with flexion by the outer band of the ilio-femoral ligament, the ilio-trochanteric ligament, the outer part of the capsular ligament; abduction by the inner band of the ilio-femoral ligament and the pubo-femoral band; rotation outwards by the outer band of the ilio-femoral ligament; and rotation inwards by the ischio-capsular ligament and the hinder part of the capsule. The muscles which *flex* the femur on the pelvis are, the Psoas, Iliacus, Rectus, Sartorius, Pectineus, Adductor longus and brevis, and the anterior fibres of the Gluteus medius and minimus. *Extension* is mainly performed by the Gluteus maximus, assisted by the hamstring muscles. The thigh is *adducted* by the Adductor magnus, longus and brevis, the Pectineus, and Gracilis, and *abducted* by the Gluteus maximus, medius, and minimus. The muscles which *rotate* the thigh *inwards* are the anterior fibres of the Gluteus medius, the Gluteus minimus, and the Tensor vaginæ femoris; while those which rotate it *outwards* are the posterior fibres of the Gluteus medius, the Piriformis, Obturator externus and internus, Gemellus superior and inferior, Quadratus femoris, Psoas, Iliacus, Gluteus maximus, the three Adductors, the Pectineus, and the Sartorius.

**Surface Form.**—A line drawn from the anterior superior spinous process of the ilium to the most prominent part of the tuberosity of the ischium (Nélaton's line) runs through the centre of the acetabulum, and would, therefore, indicate the level of the hip-joint; or, in other words, the upper border of the great trochanter, which lies on Nélaton's line, is on a level with the centre of the hip-joint.

**Surgical Anatomy.**—In dislocation of the hip, 'the head of the thigh-bone may rest at any point around its socket' (Bryant); but whatever position the head ultimately assumes,

\* The hip-joint cannot be completely flexed, in most persons, without at the same time flexing the knee, on account of the shortness of the hamstring muscles.—Cleland, *Journ. of Anat. and Phys.* No. I. Old Series, p. 87.

the primary displacement is generally downwards and inwards, the capsule giving way at its weakest—that is, its lower and inner—part. The situation that the head of the bone subsequently assumes is determined by the degree of flexion or extension, and of outward or inward rotation of the thigh at the moment of luxation, influenced, no doubt, by the ilio-femoral ligament, which is not easily ruptured. When, for instance, the head is forced backwards, this ligament forms a fixed axis, round which the head of the bone rotates, and is thus driven on to the dorsum of the ilium. The ilio-femoral ligament also influences the position of the thigh in the various dislocations: in the dislocations backwards it is tense, and produces inversion of the limb; in the dislocation on to the pubes, it is relaxed, and therefore allows the external rotators to evert the thigh; while in the thyroid dislocation it is tense, and produces flexion. The muscles inserted into the upper part of the femur, with the exception of the Obturator internus, have very little direct influence in determining the position of the bone. But Bigelow has endeavoured to show that the Obturator internus is the principal agent in determining whether, in the backward dislocations, the head of the bone shall be ultimately lodged on the dorsum of the ilium, or in or near the sciatic notch. In both dislocations the head passes, in the first instance, in the same direction; but, as Bigelow asserts, in the displacement on to the dorsum, the head of the bone travels up behind the acetabulum, between the muscle and the pelvis; while in the dislocation into the sciatic notch the head passes behind the muscle, and is therefore prevented from reaching the dorsum, in consequence of the tendon of the muscle arching over the neck of the bone, and so remains in the neighbourhood of the sciatic notch. Bigelow, therefore, distinguishes these two forms of dislocation by describing them as dislocations backwards. ‘above and below,’ the Obturator internus.

The ilio-femoral ligament is rarely torn in dislocations of the hip, and this fact is taken advantage of by the surgeon in reducing these dislocations by manipulation. It is made to act as a fulcrum to a lever, of which the long arm is the shaft of the femur, and the short arm the neck of the bone.

The hip-joint is rarely the seat of acute synovitis from injury, on account of its deep position and its thick covering of soft parts. Acute inflammation may, and does, frequently occur as the result of constitutional conditions, as rheumatism, pyæmia, &c. When, in these cases, effusion takes place, and the joint becomes distended with fluid, the swelling is not very easy to detect on account of the thickness of the capsule and the depth of the articulation. It is principally to be found on the front of the joint, just internal to the ilio-femoral ligament; or behind, at the lower and back part. In these two places the capsule is thinner than elsewhere. Disease of the hip-joint is much more frequently of a chronic character, and is usually of a tuberculous origin. It begins either in the bones or in the synovial membrane. More frequently in the former, and probably, in most cases, at the growing, highly vascular tissue in the neighbourhood of the epiphysal cartilage. In this respect it differs very materially from tuberculous arthritis of the knee, where the disease usually commences in the synovial membrane. The reasons for this are two-fold: first, this part being the centre of rapid growth, its nutrition is unstable and apt to pass into inflammatory action; and, secondly, great strain is thrown upon it, from the frequency of falls and blows upon the hip, which causes crushing of the epiphysal cartilage or the cancellous tissue in its neighbourhood, with the results likely to follow such an injury. In addition to these, the depth of the joint protects it from the causes of synovitis.

In chronic hip-disease the affected limb assumes an altered position, the cause of which it is important to understand. In the early stage of a typical case, the limb is flexed, abducted, and rotated outwards. In this position all the ligaments of the joint are relaxed: the front of the capsule by flexion; the outer band of the ilio-femoral ligament by abduction; and the inner band of this ligament and the back of the capsule by rotation outwards. It is, therefore, the position of greatest ease. The condition is not quite obvious at first, upon examining a patient. If the patient is laid in the supine position, the affected limb will be found to be extended and parallel with the other. But it will be found that the pelvis is tilted downwards on the diseased side and the limb apparently longer than its fellow, and that the lumbar spine is arched forwards (lordosis). If now the thigh is abducted and flexed, the tilting downwards and the arching forwards of the pelvis disappear. The condition is thus explained. A limb which is flexed and abducted is obviously useless for progression, and, in order to overcome the difficulty, the patient depresses the affected side of his pelvis in order to produce parallelism of his limbs, and at the same time rotates his pelvis on its transverse horizontal axis, so as to direct the limb downwards, instead of forwards. In the later stages of the disease the limb becomes flexed and adducted and inverted. This position probably depends upon muscular action, at all events as regards the adduction. The Adductor muscles are supplied by the obturator nerve, which also largely supplies the joint. These muscles are therefore thrown into reflex action by the irritation of the peripheral terminations of this nerve in the inflamed articulation.

Osteo-arthritis is not uncommon in the hip-joint, and is said to be more common in the male than in the female, in whom the knee-joint is more frequently affected. It is a disease of middle age or more advanced period of life.

Congenital dislocation is more commonly met with in the hip-joint than in any other articulation. The displacement usually takes place on to the dorsum ili. It gives rise to extreme lordosis, and a waddling gait is noticed as soon as the child commences to walk.



Excision of the hip may be required for disease or for injury, especially gunshot. It may be performed either by an anterior incision or a posterior one. The former entails less interference with important structures, especially muscles, than the posterior one, but permits of less efficient drainage. In these days, however, when the surgeon aims at securing healing of his wound without suppuration, this second desideratum is not of so much importance. In the operation in front, the surgeon makes an incision three to four inches in length, starting immediately below and external to the anterior superior spinous process of the ilium, downwards and inwards between the Sartorius and Tensor vaginae femoris, to the neck of the bone, dividing the capsule at its upper part. A narrow bladed saw now divides the neck of the femur, and the head of the bone is extracted with sequestrum forceps. All diseased tissue is carefully removed with a sharp spoon or scissors, and the cavity thoroughly flushed out with a hot antiseptic fluid.

The posterior method consists in making an incision three or four inches long, commencing midway between the top of the great trochanter and the anterior superior spine, and ending over the shaft, just below the trochanter. The muscles are detached from the great trochanter, and the capsule opened freely. The head and neck are freed from the soft parts and the bone sawn through just below the top of the trochanter with a narrow saw. The head of the bone is then levered out of the acetabulum. In both operations, if the acetabulum is eroded, it must be freely gouged.

## II. KNEE-JOINT

The knee-joint was formerly described as a ginglymus or hinge-joint, but is really of a much more complicated character. It must be regarded as consisting of three articulations in one: one between each condyle of the femur and the corresponding tuberosity of the tibia, which are condyloid joints, and one between the patella and the femur, which is partly arthrodial, but not completely so, since the articular surfaces are not mutually adapted to each other, so that the movement is not a simple gliding one. This view of the construction of the knee-joint receives confirmation from the study of the articulation in some of the lower mammals, where three synovial membranes are sometimes found, corresponding to these three subdivisions, either entirely distinct or only connected together by small communications. This view is further rendered probable by the existence of the two crucial ligaments within the joint, which must be regarded as the external and internal lateral ligaments of the inner and outer joints respectively. The existence of the ligamentum mucosum would further indicate a tendency to separation of the synovial cavity into two minor sacs, one corresponding to each joint.

The bones entering into the formation of the knee-joint are the condyles of the femur above, the head of the tibia below, and the patella in front. The bones are connected together by ligaments, some of which are placed on the exterior of the joint, while others occupy its interior.

### *External Ligaments*

Anterior, or Ligamentum Patellæ.  
 Posterior, or Ligamentum Posticum Winslowii.  
 Internal Lateral.  
 Two External Lateral.  
 Capsular.

### *Interior Ligaments*

Anterior, or External Crucial.  
 Posterior, or Internal Crucial.  
 Two Semilunar Fibro-Cartilages.  
 Transverse.  
 Coronary.  
 Ligamentum mucosum.  
 Ligamenta alaria.

The **Anterior Ligament** or **Ligamentum Patellæ** (fig. 294) is the central portion of the common tendon of the Extensor muscles of the thigh which is continued from the patella to the tubercle of the tibia, supplying the place of an anterior ligament. It is a strong, flat, ligamentous band, about three inches in length, attached, above, to the apex of the patella and the rough depression on its posterior surface; below, to the lower part of the tubercle of the tibia; its superficial fibres being continuous over the front of the patella with those of the tendon of the Quadriceps extensor. The lateral portions of the tendon of the Extensor muscles pass down on either side of the patella, attached to the borders



of this bone and its ligament, to be inserted into the upper extremity of the tibia on each side of the tubercle; externally, these portions merge into the capsular ligament. They are termed *lateral patellar ligaments*. The posterior surface of the ligamentum patellæ can usually be easily separated from the front of the capsular ligament.

The **Posterior Ligament (Ligamentum Posticum Winslowii)** (fig. 295) is a broad, flat, fibrous band, formed of fasciculi separated from one another by apertures for the passage of vessels and nerves. It is attached above to the upper margin of the intercondyloid notch of the femur, and below to the posterior margin of the head of the tibia. Superficial to the main part of the ligament is a strong fasciculus derived from the tendon of the Semi-membranosus, and passing from the back part of the inner tuberosity of the tibia obliquely upwards and

FIG. 294.—Right knee-joint. Anterior view.

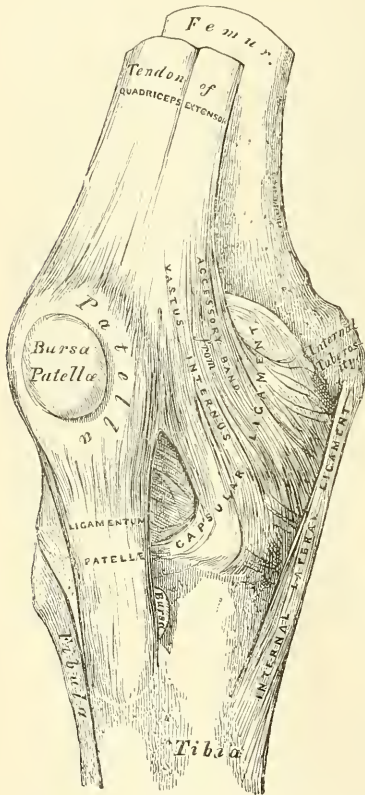
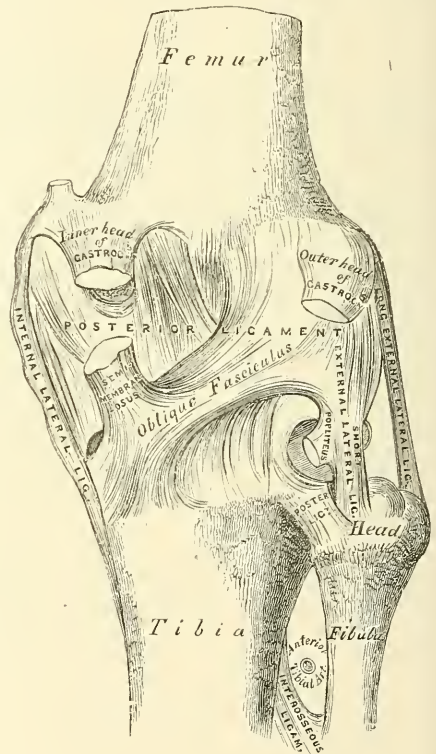


FIG. 295.—Right knee-joint. Posterior view.



outwards to the back part of the outer condyle of the femur. The posterior ligament forms part of the floor of the popliteal space, and the popliteal artery rests upon it.

The **Internal Lateral Ligament** is a broad, flat, membranous band, thicker behind than in front, and situated nearer to the back than the front of the joint. It is attached, above, to the inner tuberosity of the femur; below, to the inner tuberosity and inner surface of the shaft of the tibia, to the extent of about two inches. It is crossed, at its lower part, by the tendons of the Sartorius, Gracilis, and Semi-tendinosus muscles, a synovial bursa being interposed. Its *deep surface* covers the anterior portion of the tendon of the Semi-membranosus, with which it is connected by a few fibres, the synovial membrane of the joint, and the inferior internal articular vessels and nerve; it is intimately adherent to the internal semilunar fibro-cartilage.

The **Long External Lateral Ligament** is a strong, rounded, fibrous cord, situated nearer to the back than the front of the joint. It is attached, above, to the back part of the outer tuberosity of the femur; below, to the outer part of the head of the fibula. Its *outer surface* is covered by the tendon of the Biceps, which divides at its insertion into two parts, separated by the ligament. The ligament has passing beneath it the tendon of the Popliteus muscle, and the inferior external articular vessels and nerve.

The **Short External Lateral Ligament** is an accessory bundle of fibres placed behind and parallel with the preceding, attached, above, to the lower and back part of the outer tuberosity of the femur; below, to the summit of the styloid process of the fibula. This ligament is intimately connected with the capsular ligament, and has, passing beneath it, the tendon of the Popliteus muscle, and the inferior external articular vessels and nerve.

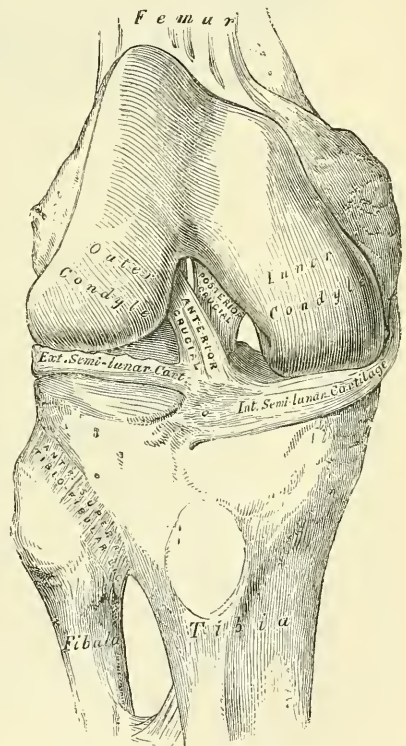
The **Capsular Ligament** consists of an exceedingly thin, but strong, fibrous membrane, which fills in the intervals left between the stronger bands above described, and is inseparably connected with them. In front it blends with and forms part of the lateral patellar ligaments, and fills in the interval between the anterior and lateral ligaments of the joint, with which latter structures it is closely connected. Behind, it is strong, and formed chiefly of vertical fibres, which arise above from the condyles and intercondyloid notch of the femur, and is connected below with the back part of the head of the tibia, being closely united with the origins of the Gastrocnemius, Plantaris, and Popliteus muscles. It passes in front of, but is inseparably connected with, the posterior ligament.

The **Crucial** are two interosseous ligaments of considerable strength, situated in the interior of the joint, nearer its posterior than its anterior part. They are called *crucial* because they cross each other somewhat like the lines of the letter X; and have received the names *anterior* and *posterior*, from the position of their attachment to the tibia.

The **Anterior** or **External Crucial Ligament** (fig. 296) is attached to the depression in front of the spine of the tibia, being blended with the anterior extremity of the external semilunar fibro-cartilage, and passing obliquely upwards, backwards, and outwards, is inserted into the inner and back part of the outer condyle of the femur. Its direction is upwards, backwards, and outwards.

The **Posterior**, or **Internal Crucial Ligament**, is stronger, but shorter and less oblique in its direction, than the anterior. It is attached to the back part of the depression behind the spine of the tibia, to the popliteal notch, and to the posterior extremity of the external semilunar fibro-cartilage; and passes upwards, forwards, and inwards, to be inserted into the outer and fore part of the inner condyle of the femur. As it crosses the anterior crucial ligament, a fasciculus is given off from it, which blends with the posterior part of that ligament. It is in relation, in front, with the anterior crucial ligament; behind, with the capsular ligament.

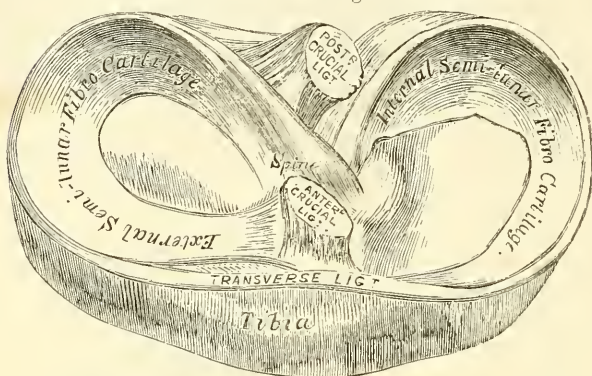
FIG. 296.—Right knee-joint. Showing internal ligaments.





The **Semilunar Fibro-cartilages** (fig. 297) are two crescentic lamellæ, which serve to deepen the surface of the head of the tibia, for articulation with the condyles of the femur. The circumference of each cartilage is thick, convex, and attached to the inside of the capsule of the knee; the inner border is thin, concave, and free. Their upper surfaces are concave, and in relation with the condyles of the femur; their lower surfaces are flat, and rest upon the head of

FIG. 297.—Head of tibia, with semilunar cartilages, etc.  
Seen from above. Right side.



the tibia. Each cartilage covers nearly the outer two-thirds of the corresponding articular surface of the tibia, leaving the inner third uncovered; both surfaces are smooth, and invested by synovial membrane.

The **Internal Semilunar Fibro-cartilage** is nearly semicircular in form, a little elongated from before backwards, and broader behind than in front; its anterior

extremity, thin and pointed, is attached to a depression on the anterior margin of the head of the tibia, in front of the anterior crucial ligament; its posterior extremity is attached to the depression behind the spine, between the attachments of the external semilunar fibro-cartilage and the posterior crucial ligaments.

The **External Semilunar Fibro-cartilage** forms nearly an entire circle, covering a larger portion of the articular surface than the internal one. It is grooved on its outer side for the tendon of the Popliteus muscle. Its extremities, at their insertion, are interposed between the two extremities of the internal semilunar fibro-cartilage; the anterior extremity being attached in front of the spine of the tibia to the outer side of, and behind, the anterior crucial ligament, with which it blends; the posterior extremity being attached behind the spine of the tibia, in front of the posterior extremity of the internal semilunar fibro-cartilage. Just before its insertion posteriorly it gives off a strong fasciculus, which passes obliquely upwards and outwards, to be inserted into the inner condyle of the femur, close to the attachment of the posterior crucial ligament. Occasionally a small fasciculus is given off, which passes forwards to be inserted into the back part of the anterior crucial ligament. The external semilunar fibro-cartilage gives off from its anterior convex margin a fasciculus, which forms the transverse ligament.

The **Transverse Ligament** is a band of fibres which passes transversely from the anterior convex margin of the external semilunar fibro-cartilage to the anterior convex margin of the internal semilunar fibro-cartilage; its thickness varies considerably in different subjects, and it is sometimes absent altogether.

The **Coronary Ligaments** are merely portions of the capsular ligament, which connect the circumference of each of the semilunar fibro-cartilages with the margin of the head of the tibia.

The **Synovial Membrane** of the knee-joint is the largest and most extensive in the body. Commencing at the upper border of the patella, it forms a short *cul-de-sac* beneath the Quadriceps extensor tendon of the thigh, on the lower part of the front of the shaft of the femur: this communicates with a synovial bursa interposed between the tendon and the front of the femur, by an orifice of variable size. On each side of the patella, the synovial membrane extends beneath the





the Biceps; (3) one beneath the external lateral ligament between it and the tendon of the Popliteus (this is sometimes only an expansion from the next bursa); (4) one beneath the tendon of the Popliteus between it and the condyle of the femur, which is almost always an extension from the synovial membrane. On the inner side there are five bursæ: (1) one beneath the inner head of the Gastrocnemius, which sends a prolongation between the tendons of the Gastrocnemius and Semi-membranosus. This bursa often communicates with the joint; (2) one above the internal lateral ligament between it and the tendons of the Sartorius, Gracilis, and Semi-tendinosus; (3) one beneath the internal lateral ligament between it and the tendon of the Semi-membranosus (this is sometimes only an expansion from the next bursa); (4) one beneath the tendon of the Semi-membranosus, between it and the head of the tibia; (5) sometimes there is a bursa between the tendons of the Semi-membranosus and of the Semi-tendinosus.

**Structures around the Joint.**—In front and at the sides, the Quadriceps extensor; on the outer side, the tendons of the Biceps and the Popliteus and the external popliteal nerve; on the inner side, the Sartorius, Gracilis, Semi-tendinosus and Semi-membranosus; behind, an expansion from the tendon of the Semi-membranosus, the popliteal vessels, and the internal popliteal nerve, Popliteus, Plantaris, and inner and outer heads of the Gastrocnemius, some lymphatic glands, and fat.

The *Arteries* supplying the joint are derived from the anastomotica magna branch of the femoral, articular branches of the popliteal, anterior and posterior recurrent branches of the anterior tibial, and descending branch from the external circumflex of the Profunda.

The *Nerves* are derived from the obturator, anterior crural, and external and internal popliteal.

**Actions.**—The knee-joint permits of movements of flexion and extension, and, in certain positions, of slight rotation inwards and outwards. The movement of flexion and extension does not, however, take place in a simple hinge-like manner, as in other joints, but is a complicated movement, consisting of a certain amount of gliding and rotation; so that the same part of one articular surface is not always applied to the same part of the other articular surface, and the axis of motion is not a fixed one. If the joint is examined while in a condition of extreme flexion, the posterior part of the articular surfaces of the tibia will be found to be in contact with the posterior rounded extremities of the condyles of the femur; and if a simple hinge-like movement were to take place, the axis, round which the revolving movement of the tibia occurs, would be in the back part of the condyle. If the leg is now brought forwards into a position of semi-flexion, the upper surface of the tibia will be seen to glide over the condyles of the femur, so that the middle part of the articular facets are in contact, and the axis of rotation must therefore have shifted forwards to nearer the centre of the condyles. If the leg is now brought into the extended position, a still further gliding takes place, and a further shifting forwards of the axis of rotation. This is not, however, a simple movement, but is accompanied by a certain amount of rotation outwards round a vertical axis drawn through the centre of the head of the tibia. This rotation is due to the greater length of the internal condyle and to the fact that the anterior portion of its articular surface is inclined obliquely outwards. In consequence of this, it will be seen that towards the close of the movement of extension, that is to say, just before complete extension is effected, the tibia glides obliquely upwards and outwards over this oblique surface on the inner condyle, and the leg is therefore necessarily rotated outwards. In flexion of the joint the converse of these movements takes place: the tibia glides backwards round the end of the femur, and at the commencement of the movement the tibia is directed downwards and inwards along the oblique curve of the inner condyle, thus causing an inward rotation to the leg.

During flexion and extension, the patella moves on the lower end of the

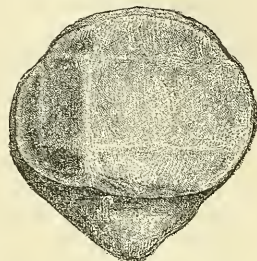


femur, but this movement is not a simple gliding one; for if the articular surface of this bone is examined, it will be found to present on each side of the central vertical ridge two less marked transverse ridges, which divide the surface, except a small portion along the inner border, which is cut off by a slight vertical ridge, into six facets (see fig. 299), and therefore does not present a uniform curved surface, as would be the case if a simple gliding movement took place. These six facets—three on each side of the median vertical ridge—correspond to and denote the parts of the bone respectively in contact with the condyles of the femur during flexion, semi-flexion, and extension. In flexion, only the upper facets on the patella are in contact with the condyles of the femur; the lower two-thirds of the bone rests upon the mass of fat which occupies the space between the femur and tibia. In the semi-flexed position of the joint, the middle facets on the patella rest upon the most prominent portion of the condyles, and thus afford greater leverage to the Quadriceps by increasing its distance from the centre of motion. In complete extension the patella is drawn up so that only the lower facets are in contact with the articular surfaces of the condyles. The narrow strip along the inner border is an exception to this, and would appear to be in contact with the internal condyle throughout its whole extent, in every position of the joint. As in the elbow, so it is in the knee—the axis of rotation in flexion and extension is not precisely at right angles to the axis of the bone, but during flexion there is a certain amount of alteration of plane; so that, whereas in flexion the femur and tibia are in the same plane, in extension the one bone forms an angle of about ten degrees with the other. There is, however, this difference between the two extremities—that in the upper, during extension, the humeri are parallel, and the bones of the forearm diverge; in the lower, the femora converge below, and the tibiae are parallel.

In addition to the slight rotation during flexion and extension, the tibia enjoys an independent rotation on the condyles of the femur, in certain positions of the joint. This movement takes place between the interarticular fibro-cartilages and the tibia, whereas the movement of flexion and extension takes place between the interarticular fibro-cartilages and the femur. So that the knee may be said to consist of two joints, separated by the fibro-cartilages: an upper (menisco-femoral), in which flexion and extension take place; and a lower (menisco-tibial), allowing of a certain amount of rotation. This latter movement can only take place in the semiflexed position of the limb, when all the ligaments are relaxed.

During *flexion* the ligamentum patellæ is put upon the stretch, as is also the posterior crucial ligament in extreme flexion. The other ligaments are all relaxed by flexion of the joint, though the relaxation of the anterior crucial ligament is very trifling. Flexion is only checked during life by the contact of the leg with the thigh. In *extension* the ligamentum patellæ becomes relaxed, and, in extreme extension, completely so, so as to allow free lateral movement to the patella, which then rests on the front of the lower end of the femur. The other ligaments, with the exception of the posterior crucial, which is partly relaxed, are all on the stretch. When the limb has been brought into a straight line, extension is checked mainly by the tension of all the ligaments except the posterior crucial and ligamentum patellæ. The movements of *rotation*, of which the knee is capable, are permitted in the semi-flexed condition by the partial relaxation of both crucial ligaments, as well as the lateral ligaments. Rotation inwards appears to be limited by the tension of the anterior crucial ligament, and by the interlocking of the two ligaments; but rotation outwards does not appear to be checked by either crucial ligament, since they uncross during the

FIG. 299.—View of the posterior surface of the patella. Showing diagrammatically the areas of contact with the femur in different positions of the knee.





execution of this movement, but by the lateral ligaments, especially the internal. The main function of the crucial ligaments is to act as a direct bond of union between the tibia and femur, preventing the former bone from being carried too far backwards or forwards. Thus the anterior crucial ligament prevents the tibia being carried too far forwards by the extensor tendons, and the posterior crucial checks too great movement backwards by the flexors. They also assist the lateral ligaments in resisting any lateral bending of the joint. The interarticular cartilages are intended, as it seems, to adapt the surface of the tibia to the shape of the femur to a certain extent, so as to fill up the intervals which would otherwise be left in the varying positions of the joint, and to interrupt the jars which would be so frequently transmitted up the limb in jumping or falls on the feet; also to permit of the two varieties of motion, flexion and extension, and rotation, as explained above. The patella is a great defence to the knee-joint from any injury inflicted in front, and it distributes upon a large and tolerably even surface, during kneeling, the pressure which would otherwise fall upon the prominent ridges of the condyles; it also affords leverage to the Quadriceps extensor muscle to act upon the tibia, and Mr. Ward has pointed out\* how this leverage varies in the various positions of the joint, so that the action of the muscle produces velocity at the expense of force in the commencement of extension, and, on the contrary, at the close of extension tends to diminish velocity, and therefore the shock to the ligaments at the moment tension of these structures takes place.

*Extension* of the leg on the thigh is performed by the Quadriceps extensor. *Flexion* by the hamstring muscles, assisted by the Gracilis and Sartorius, and, indirectly, by the Gastrocnemius, Popliteus, and Plantaris. *Rotation outwards* by the Biceps, and *rotation inwards* by the Popliteus, Semitendinosus, and, to a slight extent, the Semimembranosus, the Sartorius, and the Gracilis.

*Surface Form.*—The interval between the two bones entering into the formation of the knee-joint can always easily be felt. If the limb is extended, it is situated on a slightly higher level than the apex of the patella; but if the limb is slightly flexed, a knife carried horizontally backwards immediately below the apex of the patella would pass directly into the joint. When the knee-joint is distended with fluid, the outline of the synovial membrane at the front of the knee may be fairly well mapped out.

*Surgical Anatomy.*—From a consideration of the construction of the knee-joint, it would at first sight appear to be one of the least secure of any of the joints in the body. It is formed between the two longest bones, and therefore the amount of leverage which can be brought to bear upon it is very considerable; the articular surfaces are but ill-adapted to each other, and the range and variety of motion which it enjoys is great. All these circumstances tend to render the articulation very insecure; but, nevertheless, on account of the very powerful ligaments which bind the bones together, the joint is one of the strongest in the body, and dislocation from traumatism is of very rare occurrence. When, on the other hand, the ligaments have been softened or destroyed by disease, partial displacement is very liable to occur, and is frequently brought about by the mere action of the muscles displacing the articular surfaces from each other. The tibia may be dislocated in any direction from the femur—forwards, backwards, inwards, or outwards; or a combination of two of these dislocations may occur—that is, the tibia may be dislocated forwards and laterally, or backwards and laterally; and any of these dislocations may be complete or incomplete. As a rule, however, the antero-posterior dislocations are complete, the lateral ones incomplete.

One or other of the semilunar cartilages may become displaced and nipped between the femur and tibia. The accident is produced by a twist of the leg when the knee is flexed, and is accompanied by a sudden pain and fixation of the knee in a flexed position. The cartilage may be displaced either inwards or outwards: that is to say, either inwards towards the tibial spine, so that the cartilage becomes lodged in the intercondyloid notch; or outwards, so that the cartilage projects beyond the margin of the two articulating bones. Acute synovitis, the result of traumatism or exposure to cold, is very common in the knee, on account of its superficial position. When distended with fluid, the swelling shows itself above and at the sides of the patella, reaching about an inch or more above the trochlear surface of the femur, and extending a little higher under the Vastus internus than the Vastus externus. Occasionally the swelling may extend two inches or more. At the sides of the patella the swelling extends lower at the inner side than it does on the outer side. The lower level of the synovial membrane is just above the level of the upper part of the

\* *Human Osteology*, p. 405.

head of the fibula. In the middle line it covers the upper third of the ligamentum patellæ, being separated from it, however, by the capsule and a little fat. Chronic synovitis principally shows itself in the form of pulpy degeneration of the synovial membrane, leading to tuberculous arthritis. The reasons why tuberculous disease of the knee usually commences in the synovial membrane appear to be the complex and extensive nature of this sac; the extensive vascular supply to it; and the fact that injuries are generally diffused and applied to the front of the joint rather than to the ends of the bones. Syphilitic disease not unfrequently attacks the knee-joint. In the hereditary form of the disease it is usually symmetrical, attacking both joints, which become filled with synovial effusion, and is very intractable and difficult of cure. In the tertiary form of the disease, gummatous infiltration of the synovial membrane may take place. The knee is one of the joints most commonly affected with osteo-arthritis, and is said to be more frequently the seat of this disease in women than in men. The occurrence of the so-called loose cartilage is almost confined to the knee, though they are occasionally met with in the elbow, and, rarely, in some other joints. Many of them occur in cases of osteo-arthritis, in which calcareous or cartilaginous material is formed in one of the synovial fringes and constitutes the foreign body, and may or may not become detached, in the former case only meriting the usual term, 'loose' cartilage. In other cases they have their origin in the exudation of inflammatory lymph, and possibly, in some rare instances, a portion of the articular cartilage or one of the semilunar cartilages becomes detached and constitutes the foreign body.

Genu valgum, or knock knee, is a common deformity of childhood, in which, owing to changes in and about the joint, the angle between the outer border of the tibia and femur is diminished, so that as the patient stands the two internal condyles of the femora are in contact, but the two internal malleoli of the tibiæ are more or less widely separated from each other. When, however, the knees are flexed to a right angle, the two legs are practically parallel with each other. At the commencement of the disease there is a yielding of the internal lateral ligament and other fibrous structures on the inner side of the joint; as a result of this there is a constant undue pressure of the outer tuberosity of the tibia against the outer condyle of the femur. This extra pressure causes arrest of growth and, possibly, wasting of the outer condyle, and a consequent tendency for the tibia to become separated from the internal condyle. To prevent this the internal condyle becomes depressed; probably, as was first pointed out by Mikulicz, by an increased growth of the lower end of the diaphysis on its inner side, so that the line of the epiphysis becomes oblique instead of transverse to the axis of the bone, with a direction downwards and inwards.

Excision of the knee-joint is most frequently required for tuberculous disease of this articulation, but is also practised in cases of disorganisation of the knee after rheumatic fever, pyæmia, &c., in osteo-arthritis, and in ankylosis. It is also occasionally called for in cases of injury, gunshot or otherwise. The operation is best performed either by a horseshoe incision, starting from one condyle, descending as low as the tubercle of the tibia, where it crosses the leg, and is then carried upward to the other condyle; or by a transverse incision across the patella. In this latter incision the patella is either removed or sawn across, and the halves subsequently sutured together. The bones having been cleared, and in those cases where the operation is performed for tuberculous disease, all pulpy tissue having been carefully removed, the section of the femur is first made. This should never include, in children, more than, at the most, two-thirds of the articular surface, otherwise the epiphysial cartilage will be included, with disastrous results as regards the growth of the limb. Afterwards a thin slice should be removed from the upper end of the tibia, not more than half an inch. If any diseased tissue still appears to be left in the bones, it should be removed with the gouge, rather than that a further section of the bones should be made.

### III. ARTICULATIONS BETWEEN THE TIBIA AND FIBULA

The articulations between the tibia and fibula are effected by ligaments which connect both extremities, as well as the shafts of the bones. They may, consequently, be subdivided into three sets:—1. The Superior Tibio-fibular articulation. 2. The Middle Tibio-fibular ligament or interosseous membrane. 3. The Inferior Tibio-fibular articulation.

#### 1. SUPERIOR TIBIO-FIBULAR ARTICULATION

This articulation is an arthrodial joint. The contiguous surfaces of the bones present two flat, oval facets covered with cartilage, and connected together by the following ligaments:—

Capsular.

Anterior Superior Tibio-fibular.

Posterior Superior Tibio-fibular.



The **Capsular Ligament** consists of a membranous bag, which surrounds the articulation, being attached round the margins of the articular facets on the tibia and fibula, and is much thicker in front than behind.

The **Anterior Superior Ligament** (fig. 296) consists of two or three broad and flat bands, which pass obliquely upwards and inwards from the front of the head of the fibula to the front of the outer tuberosity of the tibia.

The **Posterior Superior Ligament** (fig. 295) is a single thick and broad band, which passes upwards and inwards from the back part of the head of the fibula to the back part of the outer tuberosity of the tibia. It is covered by the tendon of the Popliteus muscle.

A **Synovial Membrane** lines this articulation, which at its upper and back part is occasionally continuous with that of the knee-joint.

## 2. MIDDLE TIBIO-FIBULAR LIGAMENT OR INTEROSSEOUS MEMBRANE

An interosseous membrane extends between the contiguous margins of the tibia and fibula, and separates the muscles on the front from those on the back of the leg. It consists of a thin, aponeurotic lamina composed of oblique fibres, which for the most part pass downwards and outwards between the interosseous ridges on the two bones; some few fibres, however, pass in the opposite direction, downwards and inwards. It is broader above than below. Its upper margin does not quite reach the superior tibio-fibular joint, but presents a free concave border, above which is a large, oval aperture for the passage of the anterior tibial vessels forwards to the anterior aspect of the leg. At its lower part is an opening for the passage of the anterior peroneal vessels. It is continuous below with the inferior interosseous ligament; and is perforated in numerous parts for the passage of small vessels. It is in relation, in front, with the *Tibialis anticus*, *Extensor longus digitorum*, *Extensor proprius hallucis*, *Peroneus tertius*, and the anterior tibial vessels and nerve; behind, with the *Tibialis posticus* and *Flexor longus hallucis*.

## 3. INFERIOR TIBIO-FIBULAR ARTICULATION

This articulation is formed by the rough, convex surface of the inner side of the lower end of the fibula, connected with a concave rough surface on the outer side of the tibia. Below, to the extent of about two lines, these surfaces are smooth, and covered with cartilage, which is continuous with that of the ankle-joint. The ligaments of this joint are:—

Anterior Inferior Tibio-fibular.	Transverse.
Posterior Inferior Tibio-fibular.	Inferior Interosseous.

The **Anterior Inferior Ligament** (fig. 301) is a flat, triangular band of fibres, broader below than above, which extends obliquely downwards and outwards between the adjacent margins of the tibia and fibula, on the front aspect of the articulation. It is in relation, in front, with the *Peroneus tertius*, the aponeurosis of the leg, and the integument; behind, with the inferior interosseous ligament; and lies in contact with the cartilage covering the astragalus.

The **Posterior Inferior Ligament**, smaller than the preceding, is disposed in a similar manner on the posterior surface of the articulation.

The **Transverse Ligament** is a long, narrow band, continuous with the preceding, passing transversely across the back of the joint, from the external malleolus to the posterior border of the articular surface of the tibia, almost as far as its malleolar process. This ligament projects below the margin of the bones, and forms part of the articulating surface for the astragalus.

The **Inferior Interosseous Ligament** consists of numerous short, strong, fibrous bands, which pass between the contiguous rough surfaces of the tibia and fibula, and constitute the chief bond of union between the bones. This ligament is continuous, above, with the interosseous membrane.



The **Synovial Membrane** lining the articular surface is derived from that of the ankle-joint.

**Actions.**—The movement permitted in these articulations is limited to a very slight gliding of the articular surfaces one upon another.

#### IV. ANKLE-JOINT

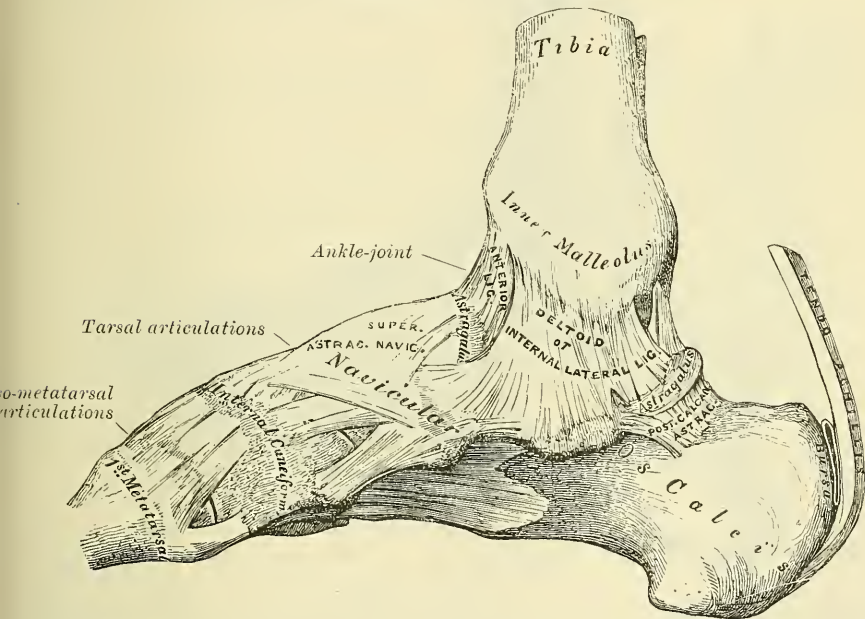
The **Ankle** is a ginglymus, or hinge-joint. The bones entering into its formation are the lower extremity of the tibia and its malleolus, and the external malleolus of the fibula, which form a mortise to receive the upper convex surface of the astragalus and its two lateral facets. The bony surfaces are covered with cartilage, and connected by a capsule, which in places forms thickened bands constituting the following ligaments:—

Anterior.  
Posterior.

Internal Lateral.  
External Lateral.

The **Anterior Tibio-tarsal Ligament** (fig. 300) is a broad, thin, membranous layer, attached, above, to the margin of the articular surface of the tibia; below,

FIG. 300.—Ankle-joint: tarsal and tarso-metatarsal articulations.  
Internal view. Right side.



to the margin of the astragalus, in front of its articular surface. It is in relation, in front, with the Extensor tendons of the toes, with the tendons of the Tibialis anticus and Peroneus tertius, and the anterior tibial vessels and nerve; behind, it lies in contact with the synovial membrane.

The **Posterior Tibio-tarsal Ligament** is very thin, and consists principally of transverse fibres. It is attached, above, to the margin of the articular surface of the tibia, blending with the transverse tibio-fibular ligament; below, to the astragalus, behind its superior articular facet. Externally, where a somewhat thickened band of transverse fibres is attached to the hollow on the inner surface of the external malleolus, it is thicker than internally.

The **Internal Lateral** or **Deltoid Ligament** is a strong, flat, triangular band, attached, above, to the apex and anterior and posterior borders of the inner malleolus. The most anterior fibres pass forwards to be inserted into the navicular bone and the inferior calcaneo-navicular ligament; the middle descend almost

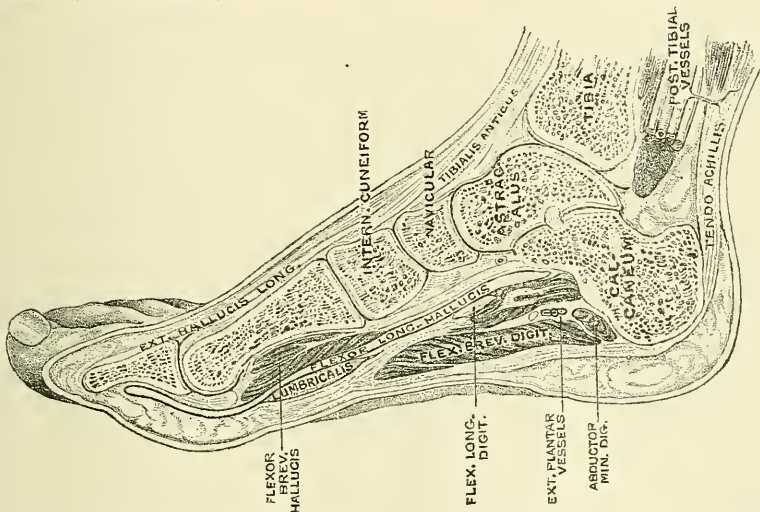


The *Arteries* supplying the joint are derived from the malleolar branches of the anterior tibial and the peroneal.

The *Nerves* are derived from the anterior and posterior tibial.

**Actions.**—The movements of the joint are those of flexion and extension. The malleoli tightly embrace the astragalus in all positions of the joint, so that any slight degree of lateral movement which may exist is simply due to stretching of the inferior tibio-fibular ligaments, and slight bending of the shaft of the fibula. Of the ligaments, the internal, or deltoid, is of very great power—so much so, that it usually resists a force which fractures the process of bone to which it is attached. Its middle portion, together with the middle fasciculus of the external lateral ligament, binds the bones of the leg firmly to the foot, and resists displacement in every direction. Its anterior and posterior fibres limit extension and flexion of the foot respectively, and the anterior fibres also limit abduction. The posterior portion of the external lateral ligament assists the middle portion in resisting the displacement of the foot backwards, and deepens the cavity for the reception of the astragalus. The anterior fasciculus is a security against the displacement of the foot forwards, and limits extension of the

FIG. 302.—Section of the right foot near its inner border, dividing the tibia, astragalus navicular, internal cuneiform, and first metatarsal bone, and the first phalanx of the great toe. (After Braune.)



joint. The movements of abduction and adduction of the foot, together with the minute changes in form by which it is applied to the ground or takes hold of an object in climbing, &c., are mainly effected in the tarsal joints; the one which enjoys the greatest amount of motion being that between the astragalus and os calcis behind, and the navicular and cuboid in front. This is often called the *transverse* or *medio-tarsal joint*, and it can, with the subordinate joints of the tarsus, replace the ankle-joint in a great measure when the latter has become ankylosed.

*Extension* of the tarsal bones upon the tibia and fibula is produced by the Gastrocnemius, Soleus, Plantaris, Tibialis posticus, Peroneus longus and brevis, Flexor longus digitorum, and Flexor longus hallucis. *Flexion*, by the Tibialis anticus, Peroneus tertius, Extensor longus digitorum, and Extensor proprius hallucis.\* *Adduction*, in the extended position, is produced by the Tibialis anticus and posticus; and *abduction* by the Peronei.

\* The student must bear in mind that the Extensor longus digitorum and Extensor proprius hallucis are *extensors* of the toes, but *flexors* of the ankle: and that the Flexor longus digitorum and Flexor longus hallucis are *flexors* of the toes, but *extensors* of the ankle.



*Surface Form.*—The line of the ankle-joint may be indicated by a transverse line drawn across the front of the lower part of the leg, about half an inch above the level of the tip of the internal malleolus.

*Surgical Anatomy.*—Displacement of the trochlear surface of the astragalus from the tibio-fibular mortise is not of common occurrence, as the ankle-joint is a very strong and powerful articulation, and great force is required to produce it. Nevertheless, dislocation does occasionally occur, both in an antero-posterior and a lateral direction. In the latter, which is the most common, fracture is a necessary accompaniment of the injury. The dislocation in these cases is somewhat peculiar, and is not a displacement in a horizontally lateral direction, such as usually occurs in lateral dislocations of ginglymoid joints, but the astragalus undergoes a partial rotation round an antero-posterior axis drawn through its own centre, so that the superior surface, instead of being directed upwards, is inclined more or less inwards or outwards according to the variety of the displacement.

The ankle-joint is more frequently sprained than any joint in the body, and this may lead to acute synovitis. In these cases, when the synovial sac is distended with fluid, the bulging appears principally in the front of the joint, beneath the anterior tendons, and on either side, between the *Tibialis anticus* and the internal lateral ligament on the inner side, and between the *Peroneus tertius* and the external lateral ligament on the outer side. In addition to this, bulging frequently occurs posteriorly, and a fluctuating swelling may be detected on either side of the *tendo Achillis*.

Chronic synovitis may result from frequent sprains, and when once this joint has been sprained it is more liable to a recurrence of the injury than it was before; or it may be tuberculous in its origin, the disease usually commencing in the astragalus and extending to the joint, though it may commence as a tuberculous synovitis the result probably of some slight strain in a tuberculous subject.

Excision of the ankle-joint is not often performed, for two reasons. In the first place, disease of the articulation for which this operation is indicated is frequently associated with disease of the tarsal bones, which prevents its performance; and, secondly, the foot after excision is frequently of very little use; far less, in fact, than after a Symes's amputation, which is often, therefore, a preferable operation in these cases. Excision may, however, be attempted in cases of tuberculous arthritis, in a young and otherwise healthy subject, where the disease is limited to the bones forming the joint. It may also be required after injury, where the vessels and nerves have not been damaged and the patient is young and free from visceral disease. The excision is best performed by two lateral incisions. One commencing two and a half inches above the external malleolus, carried down the posterior border of the fibula, round the end of the bone, and then forwards and downwards as far as the calcaneo-cuboid joint, midway between the tip of the external malleolus and the tuberosity on the fifth metatarsal bone. Through this incision the fibula is cleared, the external lateral ligament is divided, and the bone sawn through at the upper end of the incision and removed. A similar curved incision is now made on the inner side of the foot, commencing two and a half inches above the lower end of the tibia, carried down the posterior border of the bone, round the internal malleolus and forwards and downwards to the tuberosity of the navicular bone. Through this incision the tibia is cleared in front and behind, the internal lateral, the anterior and posterior ligaments divided, and the end of the tibia protruded through the wound by displacing the foot outwards, and sawn off sufficiently high to secure a healthy section of bone. The articular surface of the astragalus is now to be sawn off or the whole bone removed. In cases where the operation is performed for tuberculous arthritis, the latter course is probably preferable, as the injury done by the saw is frequently the starting point of fresh caries; and after removal of the whole bone the shortening is not appreciably increased, and the result as regards union appears to be as good as when two sawn surfaces of bone are brought into apposition.

## V. ARTICULATIONS OF THE TARSUS

### I. ARTICULATIONS OF THE OS CALCIS AND ASTRAGALUS

The articulations between the os calcis and astragalus are two in number— anterior and posterior. They are arthrodial joints. The bones are connected together by four ligaments:—

External Calcaneo-astragaloid.

Posterior Calcaneo-astragaloid.

Internal Calcaneo-astragaloid.

Interosseous.

The **External Calcaneo-astragaloid Ligament** (fig. 301) is a short, strong fasciculus, passing from the outer surface of the astragalus, immediately beneath its external malleolar facet, to the outer surface of the os calcis. It is placed in front of the middle fasciculus of the external lateral ligament of the ankle-joint, with the fibres of which it is parallel.

The **Internal Calcaneo-astragaloid Ligament** is a band of fibres connecting the

internal tubercle of the back of the astragalus with the back of the sustentaculum tali. Its fibres blend with those of the inferior calcaneo-navicular ligament.

The **Posterior Calcaneo-astragaloid Ligament** (fig. 300) connects the posterior external tubercle of the astragalus with the upper and inner part of the os calcis; it is a short, narrow band, the fibres of which radiate from their narrow attachment to the astragalus.

The **Interosseous Ligament** forms the chief bond of union between the bones. It consists of numerous vertical and oblique fibres, attached by one extremity to the groove between the articulating facets on the under surface of the astragalus; by the other, to a corresponding depression on the upper surface of the os calcis. It is very thick and strong, being at least an inch in breadth from side to side, and serves to unite the os calcis and astragalus solidly together.

The **Synovial Membranes** (fig. 304) are two in number; one for the posterior calcaneo-astragaloid articulation; a second for the anterior calcaneo-astragaloid joint. The latter synovial membrane is continued forwards between the contiguous surfaces of the astragalus and navicular bones.

**Actions.**—The movements permitted between the astragalus and os calcis are limited to a gliding of the one bone on the other in a direction from before backwards, and from side to side.

## 2. ARTICULATIONS OF THE OS CALCIS WITH THE CUBOID

The ligaments connecting the os calcis with the cuboid are four in number:—

Dorsal.	{ Superior Calcaneo-cuboid.
	{ Internal Calcaneo-cuboid (Interosseous).
Plantar.	{ Long Calcaneo-cuboid.
	{ Short Calcaneo-cuboid.

The **Superior Calcaneo-cuboid Ligament** (fig. 301) is a thin and narrow fasciculus, which passes between the contiguous surfaces of the os calcis and cuboid, on the dorsal surface of the joint.

The **Internal Calcaneo-cuboid (Interosseous) Ligament** (fig. 301) is a short, but thick and strong, band of fibres, arising from the os calcis, in the deep hollow which intervenes between it and the astragalus, and closely blended, at its origin, with the superior calcaneo-navicular ligament. It is inserted into the inner side of the cuboid bone. This ligament forms one of the chief bonds of union between the first and second rows of the tarsus.

The **Long Calcaneo-cuboid (Long Plantar) Ligament** (fig. 303), the more superficial of the two plantar ligaments, is the longest of all the ligaments of the tarsus: it is attached to the under surface of the os calcis, from near the tuberosities, as far forwards as the anterior tubercle; its fibres pass forwards to be attached to the ridge on the under surface of the cuboid bone, the more superficial fibres being continued onwards to the bases of the second, third, and fourth metatarsal bones. This ligament crosses the groove on the under surface of the cuboid bone, converting it into a canal for the passage of the tendon of the Peroneus longus.

The **Short Calcaneo-cuboid (Short Plantar) Ligament** lies nearer to the bones than the preceding, from which it is separated by a little areolar tissue. It is exceedingly broad, about an inch in length, and extends from the tubercle, and the depression in front of it, on the fore part of the under surface of the os calcis, to the inferior surface of the cuboid bone behind the peroneal groove.

**Synovial Membrane.**—The synovial membrane in this joint is distinct. It lines the inner surface of the ligaments.

**Actions.**—The movements permitted between the os calcis and cuboid are limited to a slight gliding upon each other.



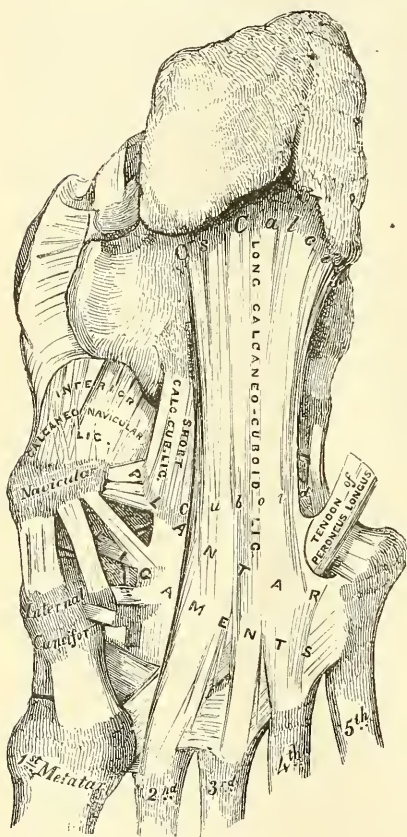
## 3. THE LIGAMENTS CONNECTING THE OS CALCIS AND NAVICULAR

Though these two bones do not directly articulate, they are connected by two ligaments:—

- Superior or External Calcaneo-navicular.
- Inferior or Internal Calcaneo-navicular.

The **Superior or External Calcaneo-navicular** (fig. 301) arises, as already mentioned, with the internal calcaneo-cuboid in the deep hollow between the astragalus and os calcis; it passes forwards from the inner side of the anterior extremity of the os calcis to the outer side of the navicular bone. These two ligaments resemble the letter Y, being blended together behind, but separated in front.

FIG. 303.—Ligaments of plantar surface of the foot.



The **Inferior or Internal Calcaneo-navicular** (fig. 303) is by far the larger and stronger of the two ligaments between these bones; it is a broad and thick band of fibres, which passes forwards and inwards from the anterior margin of the sustentaculum tali of the os calcis to the under surface of the navicular bone. This ligament not only serves to connect the os calcis and navicular, but supports the head of the astragalus, forming part of the articular cavity in which it is received. The *upper surface* presents a fibro-cartilaginous facet, lined by the synovial membrane continued from the anterior calcaneo-astragaloid articulation, upon which the head of the astragalus rests. Its *under surface* is in contact with the tendon of the Tibialis posticus muscle;\* its inner border is blended with the fore part of the Deltoid ligament, thus completing the socket for the head of the astragalus.

*Surgical Anatomy.*—The inferior calcaneo-navicular ligament, by supporting the head of the astragalus, is principally concerned in maintaining the arch of the foot, and, when it yields, the head of the astragalus is pressed downwards, inwards, and forwards by the weight of the body,

and the foot becomes flattened, expanded, and turned outwards, constituting the disease known as *flat-foot*. This ligament contains a considerable amount of elastic fibre, so as to give elasticity to the arch and spring to the foot; hence it is sometimes called the 'spring' ligament. It is supported, on its under surface, by the tendon of the Tibialis posticus, which spreads out at its insertion into a number of fasciculi, which are attached to most of the tarsal and metatarsal bones; this prevents undue stretching of the ligament, and is a protection against the occurrence of flat-foot.

## 4. ARTICULATION OF THE ASTRAGALUS WITH THE NAVICULAR BONE

The articulation between the astragalus and navicular is an arthrodial joint: the rounded head of the astragalus being received into the concavity formed by the posterior surface of the navicular, the anterior articulating surface of the

\* Mr. Hancock describes an extension of this ligament upwards on the inner side of the foot, which completes the socket of the joint in that direction. *Lancet*, 1866, vol. i. p. 618.



calcaneum, and the upper surface of the inferior calcaneo-navicular ligament, which fills up the triangular interval between those bones. The only ligament of this joint is the **superior astragalo-navicular**. It is a broad band, which passes obliquely forwards from the neck of the astragalus to the superior surface of the navicular bone. It is thin, and weak in texture, and covered by the Extensor tendons. The inferior calcaneo-navicular supplies the place of an inferior ligament.

The **Synovial Membrane** which lines the joint is continued forwards from the anterior calcaneo-astragaloid articulation.

**Actions.**—This articulation permits of considerable mobility; but its feebleness is such as to allow occasionally of dislocation of the other bones of the tarsus from the astragalus.

The *transverse tarsal* or *medio-tarsal joint* is formed by the articulation of the os calcis with the cuboid, and by the articulation of the astragalus with the navicular. The movement which takes place in this joint is more extensive than that in the other tarsal joints, and consists of a sort of rotation by means of which the sole of the foot may be slightly flexed and extended or carried inwards and outwards.

#### 5. THE ARTICULATION OF THE NAVICULAR WITH THE CUNEIFORM BONES

The navicular is connected to the three cuneiform bones by  
Dorsal and Plantar ligaments.

The **Dorsal Ligaments** are small, longitudinal bands of fibrous tissue, arranged as three bundles, one to each of the cuneiform bones. That bundle of fibres which connects the navicular with the internal cuneiform is continued round the inner side of the articulation to be continuous with the plantar ligament which connects these two bones.

The **Plantar Ligaments** have a similar arrangement to those on the dorsum. They are strengthened by processes given off from the tendon of the Tibialis posticus.

**Actions.**—The movements permitted between the navicular and cuneiform bones are limited to a slight gliding upon each other.

The **Synovial Membrane** of these joints is part of the great tarsal synovial membrane.

#### 6. THE ARTICULATION OF THE NAVICULAR WITH THE CUBOID

The navicular bone is connected with the cuboid by  
Dorsal, Plantar, and Interosseous ligaments.

The **Dorsal Ligament** consists of a band of fibrous tissue which passes obliquely forwards and outwards from the navicular to the cuboid bone.

The **Plantar Ligament** consists of a band of fibrous tissue which passes nearly transversely between these two bones.

The **Interosseous Ligament** consists of strong transverse fibres which pass between the rough non-articular portions of the lateral surfaces of these two bones.

**Actions.**—The movements permitted between the navicular and cuboid bones are limited to a slight gliding upon each other.

The **Synovial Membrane** of this joint is part of the great tarsal synovial membrane.

#### 7. THE ARTICULATION OF THE CUNEIFORM BONES WITH EACH OTHER

These bones are connected together by  
Dorsal, Plantar, and Interosseous ligaments.

The **Dorsal Ligaments** consist of two bands of fibrous tissue which pass trans-

versely: one connecting the internal with the middle cuneiform, and the other connecting the middle with the external cuneiform.

The **Plantar Ligaments** have a similar arrangement to those on the dorsum. They are strengthened by the processes given off from the tendon of the *Tibialis posticus*.

The **Interosseous Ligaments** consist of strong transverse fibres which pass between the rough non-articular portions of the lateral surfaces of the adjacent cuneiform bones.

The **Synovial Membrane** of these joints is part of the great tarsal synovial membrane.

**Actions.**—The movements permitted between the cuneiform bones are limited to a slight gliding upon each other.

#### 8. THE ARTICULATION OF THE EXTERNAL CUNEIFORM BONE WITH THE CUBOID

These bones are connected together by

Dorsal, Plantar, and Interosseous ligaments.

The **Dorsal Ligament** consists of a band of fibrous tissue which passes transversely between these two bones.

The **Plantar Ligament** has a similar arrangement. It is strengthened by a process given off from the tendon of the *Tibialis posticus*.

The **Interosseous Ligament** consists of strong transverse fibres which pass between the rough non-articular portions of the lateral surfaces of the adjacent sides of these two bones.

The **Synovial Membrane** of this joint is part of the great tarsal synovial membrane.

**Actions.**—The movements permitted between the external cuneiform and cuboid are limited to a slight gliding upon each other.

**Nerve-supply.**—All the joints of the tarsus are supplied by the anterior tibial nerve.

*Surgical Anatomy.*—In spite of the great strength of the ligaments which connect the tarsal bones together, dislocation at some of the tarsal joints does occasionally occur; though, on account of the spongy character of the bones, they are more frequently broken than dislocated, as the result of violence. When dislocation does occur, it is most commonly in connection with the astragalus; for not only may this bone be dislocated from the tibia and fibula at the ankle-joint, but the other bones may be dislocated from it, the trochlear surface of the bone remaining *in situ* in the tibio-fibular mortise. This constitutes what is known as the *sub-astragaloid* dislocation. Or, again, the astragalus may be dislocated from all its connections—from the tibia and fibula above, the os calcis below, and the navicular in front—and may even undergo a rotation, either on a vertical or horizontal axis. In the former case the long axis of the bone becoming directed across the joint, so that the head faces the articular surface on one or other malleolus; or, in the latter, the lateral surfaces becoming directed upwards and downwards, so that the trochlear surface faces to one or the other side. Finally, dislocation may occur at the medio-tarsal joint, the anterior tarsal bones being luxated from the astragalus and calcaneum. The other tarsal bones are also, occasionally, though rarely, dislocated from their connections.

#### VI. TARSO-METATARSAL ARTICULATIONS

These are arthrodial joints. The bones entering into their formation are four tarsal bones, viz. the internal, middle and external cuneiform, and the cuboid, which articulate with the metatarsal bones of the five toes. The metatarsal bone of the great toe articulates with the internal cuneiform; that of the second is deeply wedged in between the internal and external cuneiform, resting against the middle cuneiform, and being the most strongly articulated of all the metatarsal bones; the third metatarsal articulates with the extremity of the external cuneiform; the fourth, with the cuboid and external cuneiform; and the fifth, with the cuboid. The articular surfaces are covered with cartilage, lined by synovial membrane, and connected together by the following ligaments:—

Dorsal.

Plantar.

Interosseous.

The **Dorsal Ligaments** consist of strong, flat, fibrous bands, which connect the tarsal with the metatarsal bones. The first metatarsal is connected to the internal cuneiform by a single broad, thin, fibrous band; the second has three dorsal ligaments, one from each cuneiform bone; the third has one from the external cuneiform; the fourth has two, one from the external cuneiform and one from the cuboid; and the fifth, one from the cuboid.

The **Plantar Ligaments** consist of longitudinal and oblique fibrous bands connecting the tarsal and metatarsal bones, but disposed with less regularity than on the dorsal surface. Those for the first and second metatarsal are the most strongly marked; the second and third metatarsal receive strong fibrous bands, which pass obliquely across from the internal cuneiform; the plantar ligaments of the fourth and fifth metatarsal consist of a few scanty fibres derived from the cuboid.

The **Interosseous Ligaments** are three in number: internal, middle, and external. The *internal* one passes from the outer extremity of the internal cuneiform to the adjacent angle of the second metatarsal. The *middle* one, less strong than the preceding, connects the external cuneiform with the adjacent angle of the second metatarsal. The *external* interosseous ligament connects the outer angle of the external cuneiform with the adjacent side of the third metatarsal.

The **Synovial Membrane** between the internal cuneiform bone and the first metatarsal bone is a distinct sac. The synovial membrane between the middle and external cuneiform behind, and the second and third metatarsal bones in front, is part of the great tarsal synovial membrane. Two prolongations are sent forwards from it, one between the adjacent sides of the second and third metatarsal bones, and one between the third and fourth metatarsal bones. The synovial membrane between the cuboid and the fourth and fifth metatarsal bones is a distinct sac. From it a prolongation is sent forwards between the fourth and fifth metatarsal bones.

**Actions.**—The movements permitted between the tarsal and metatarsal bones are limited to a slight gliding upon each other.

## VII. ARTICULATIONS OF THE METATARSAL BONES WITH EACH OTHER

The base of the first metatarsal bone is not connected with the second metatarsal bone by any ligaments; in this respect it resembles the thumb.

The bases of the four outer metatarsal bones are connected by dorsal, plantar, and interosseous ligaments.

The **Dorsal Ligaments** consist of bands of fibrous tissue which pass transversely between the adjacent metatarsal bones.

The **Plantar Ligaments** have a similar arrangement to those on the dorsum.

The **Interosseous Ligaments** consist of strong transverse fibres which pass between the rough non-articular portions of the lateral surfaces.

The **Synovial Membrane** between the second and third, and the third and fourth metatarsal bones is part of the great tarsal synovial membrane.

The synovial membrane between the fourth and fifth metatarsal bones is a prolongation of the synovial membrane of the cubo-metatarsal joint.

**Actions.**—The movement permitted in the tarsal ends of the metatarsal bones is limited to a slight gliding of the articular surfaces upon one another.

## THE SYNOVIAL MEMBRANES IN THE TARSAL AND METATARSAL JOINTS

The **Synovial Membranes** (fig. 304) found in the articulations of the tarsus and metatarsus are six in number: one for the posterior calcaneo-astragaloid articulation; a second for the anterior calcaneo-astragaloid and astragalo-navicular articulations; a third for the calcaneo-cuboid articulation; and a fourth for the articulations of the navicular with the three cuneiform, the three cuneiform with each other, the external cuneiform with the cuboid, and the middle and external



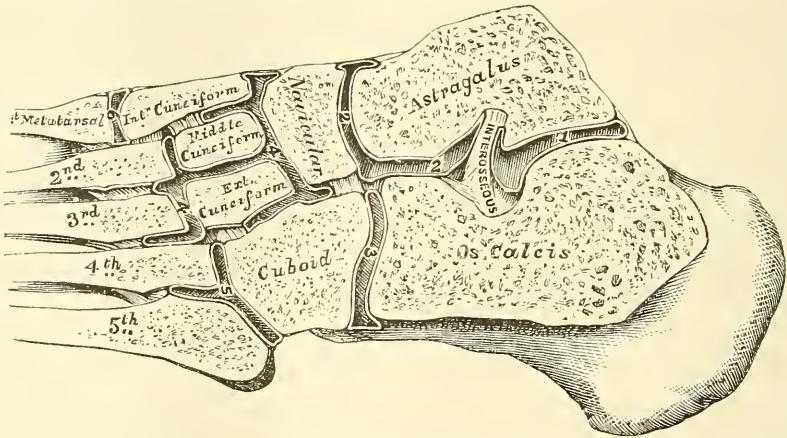
cuneiform with the bases of the second and third metatarsal bones, and the lateral surfaces of the second, third, and fourth metatarsal bones with each other; a fifth for the internal cuneiform with the metatarsal bone of the great toe; and a sixth for the articulation of the cuboid with the fourth and fifth metatarsal bones. A small synovial membrane is sometimes found between the contiguous surfaces of the navicular and cuboid bones.

**Nerve-supply.**—The nerves supplying the tarso-metatarsal joints are derived from the anterior tibial.

The *digital extremities* of all the metatarsal bones are connected together by the *transverse metatarsal ligament*.

The **Transverse Metatarsal Ligament** is a narrow fibrous band which passes transversely across the anterior extremities of all the metatarsal bones, connecting them together. It is blended anteriorly with the plantar (glenoid) ligament of the metatarso-phalangeal articulations. To its posterior border is connected the fascia covering the Interossei muscles. Its superficial surface is concave where the flexor tendons pass over it. Beneath it the tendons of the Interossei

FIG. 304.—Oblique section of the articulations of the tarsus and metatarsus. Showing the six synovial membranes.



muscles pass to their insertion. It differs from the transverse metacarpal ligament in that it connects the metatarsal bone of the great toe with the rest of the metatarsal bones.

#### VIII. METATARSO-PHALANGEAL ARTICULATIONS

The metatarso-phalangeal articulations are of the condyloid kind, formed by the reception of the rounded head of the metatarsal bone into a superficial cavity in the extremity of the first phalanx.

The ligaments are

Plantar.

Two Lateral.

The **Plantar Ligaments** (Glenoid ligaments of Cruveilhier) are thick, dense, fibrous structures. Each is placed on the plantar surface of the joint in the interval between the lateral ligaments, to which they are connected; they are loosely united to the metatarsal bone, but very firmly to the base of the first phalanges. Their plantar surface is intimately blended with the transverse metatarsal ligament, and presents a groove for the passage of the flexor tendons, the sheath surrounding which is connected to each side of the groove. By their deep surface, they form part of the articular surface for the head of the metatarsal bone, and are lined by a synovial membrane.

The **Lateral Ligaments** are strong, rounded cords, placed one on each side of

the joint, each being attached, by one extremity, to the posterior tubercle on the side of the head of the metatarsal bone; and, by the other, to the contiguous extremity of the phalanx.

The **Posterior Ligament** is supplied by the extensor tendon placed over the back of the joint.

**Actions.**—The movements permitted in the metatarso-phalangeal articulations are flexion, extension, abduction, and adduction.

#### IX. ARTICULATIONS OF THE PHALANGES

The articulations of the phalanges are ginglymus joints.

The ligaments are :—

Plantar.

Two lateral.

The arrangement of these ligaments is similar to those in the metatarso-phalangeal articulations; the extensor tendon supplies the place of a posterior ligament.

**Actions.**—The only movements permitted in the phalangeal joints are flexion and extension; these movements are more extensive between the first and second phalanges than between the second and third. The movement of flexion is very considerable, but extension is limited by the anterior and lateral ligaments.

*Surface Form.*—The principal joints which it is necessary to distinguish, with regard to the surgery of the foot, are the medio-tarsal and the tarso-metatarsal joints. The joint between the astragalus and the navicular is best found by means of the tubercle of the navicular bone, for the line of the joint is immediately behind this process. If the foot is grasped and forcibly extended, a rounded prominence, the head of the astragalus, will appear on the inner side of the dorsum in front of the ankle-joint, and if a knife is carried downwards, just in front of this prominence and behind the line of the navicular tubercle, it will enter the astragalo-navicular joint. The calcaneo-cuboid joint is situated midway between the external malleolus and the prominent end of the fifth metatarsal bone. The plane of the joint is in the same line as that of the astragalo-navicular. The position of the joint between the fifth metatarsal bone and the cuboid is easily found by the projection of the fifth metatarsal bone, which is the guide to it. The direction of the line of the joint is very oblique, so that, if continued onwards, it would pass through the head of the first metatarsal bone. The joint between the fourth metatarsal bone and the cuboid and external cuneiform is the direct continuation inwards of the previous joint, but its plane is less oblique; it would be represented by a line drawn from the outer side of the articulation to the middle of the first metatarsal bone. The plane of the joint between the third metatarsal bone and the external cuneiform is almost transverse. It would be represented by a line drawn from the outer side of the joint to the base of the first metatarsal bone. The tarso-metatarsal articulation of the great toe corresponds to a groove which can be felt by making firm pressure on the inner side of the foot one inch in front of the tubercle on the navicular bone; and the joint between the second metatarsal bone and the middle cuneiform is to be found on the dorsum of the foot, half an inch behind the level of the tarso-metatarsal joint of the great toe. The line of the joints between the metatarsal bones and the first phalanges is about an inch behind the webs of the corresponding toes.

## THE MUSCLES AND FASCIÆ\*

THE Muscles are connected with the bones, cartilages, ligaments, and skin, either directly or through the intervention of fibrous structures, called tendons or aponeuroses. Where a muscle is attached to bone or cartilage, the fibres terminate in blunt extremities upon the periosteum or perichondrium, and do not come into direct relation with the osseous or cartilaginous tissue. Where muscles are connected with the skin, they either lie as a flattened layer beneath it, or are connected with its areolar tissue by larger or smaller bundles of fibres, as in the muscles of the face.

The muscles vary extremely in their form. In the limbs, they are of considerable length, especially the more superficial ones, the deep ones being generally broad; they surround the bones, and form an important protection to the various joints. In the trunk, they are broad, flattened, and expanded, forming the parietes of the cavities which they enclose; hence the reason of the terms, *long, broad, short*, etc., used in the description of a muscle.

There is a considerable variation in the arrangement of the fibres of certain muscles with reference to the tendons to which they are attached. In some, the fibres are parallel and run directly from their origin to their insertion; these are quadrilateral muscles, such as the Thyro-hyoid. A modification of these is found in the fusiform muscles, in which the fibres are not quite parallel, but slightly curved, so that the muscle tapers at each end; in their action, however, they resemble the quadrilateral muscles. Secondly, in other muscles the fibres are convergent; arising by a broad origin, they converge to a narrow or pointed insertion. This arrangement of fibres is found in the triangular muscles—e.g. the Temporal. In some muscles, which otherwise would belong to the quadrilateral or triangular type, the origin and insertion are not in the same plane, but the plane of the line of origin intersects that of their insertion: such is the case in the Pectineus muscle. Thirdly, in some muscles the fibres are oblique and converge, like the plumes of a pen, to one side of a tendon, which runs the entire length of the muscle. Such a muscle is rhomboidal or penniform, as the Peronei. A modification of these rhomboidal muscles is found in those cases where oblique fibres converge to both sides of a central tendon which runs down the middle of the muscle; these are called bipenniform, and an example is afforded in the Rectus femoris. Finally, we have muscles in which the fibres are arranged in curved bundles in one or more planes, as in the Sphincter muscles. The arrangement of the muscular fibres is of considerable importance in respect to their relative strength and range of movement. Those muscles where the fibres are long and few in number have great range, but diminished strength; where, on

\* The Muscles and Fasciæ are described conjointly, in order that the student may consider the arrangement of the latter in his dissection of the former. It is rare for the student of anatomy in this country to have the opportunity of dissecting the fasciæ separately; and it is for this reason, as well as from the close connection that exists between the muscles and their investing sheaths, that they are considered together. Some general observations are first made on the anatomy of the muscles and fasciæ, the special description being given in connection with the different regions.



the other hand, the fibres are short and more numerous, there is great power, but lessened range.

Muscles differ much in size: the Gastrocnemius forms the chief bulk of the back of the leg, and the fibres of the Sartorius are nearly two feet in length, whilst the Stapedius, a small muscle of the internal ear, weighs about a grain, and its fibres are not more than two lines in length.

The names applied to the various muscles have been derived: 1, from their situation, as the Tibialis, Radialis, Ulnaris, Peroneus; 2, from their direction, as the Rectus abdominis, Obliqui capitis, Transversalis; 3, from their uses, as Flexors, Extensors, Abductors, etc.; 4, from their shape, as the Deltoid, Trapezius, Rhomboideus; 5, from the number of their divisions, as the Biceps, the Triceps; 6, from their points of attachment, as the Sterno-cleido-mastoid, Sterno-hyoid, Sterno-thyroid.

In the description of a muscle, the term *origin* is meant to imply its more fixed or central attachment; and the term *insertion* the movable point to which the force of the muscle is directed; but the origin is absolutely fixed in only a very small number of muscles, such as those of the face, which are attached by one extremity to the bone, and by the other to the movable integument; in the greater number, the muscle can be made to act from either extremity.

In the dissection of the muscles, the student should pay especial attention to the exact *origin*, *insertion*, and *actions* of each, and its more important *relations* with surrounding parts. An accurate knowledge of the points of attachment of the muscles is of great importance in the determination of their action. By a knowledge of the action of the muscles, the surgeon is able to explain the causes of displacement in various forms of fracture, and the causes which produce distortion in various deformities, and, consequently, to adopt appropriate treatment in each case. The relations, also, of some of the muscles, especially those in immediate apposition with the larger blood-vessels, and the surface-markings they produce, should be especially remembered, as they form useful guides in the application of a ligature to those vessels.

*Tendons* are white, glistening, fibrous cords, varying in length and thickness, sometimes round, sometimes flattened, of considerable strength, and devoid of elasticity. They consist almost entirely of white fibrous tissue, the fibrils of which have an undulating course parallel with each other, and are firmly united together. They are very sparingly supplied with blood-vessels, the smaller tendons presenting in their interior not a trace of them. Nerves also are absent in the smaller tendons; but the larger ones, as the tendo Achillis, receive nerves which accompany the nutrient vessels. The tendons consist principally of a substance which yields gelatin.

*Aponeuroses* are flattened or ribbon-shaped tendons, of a pearly-white colour, iridescent, glistening, and similar in structure to the tendons. They are destitute of nerves, and the thicker ones only sparingly supplied with blood-vessels.

The tendons and aponeuroses are connected, on the one hand, with the muscles; and, on the other hand, with the movable structures, as the bones, cartilages, ligaments, and fibrous membranes (for instance, the sclerotic). Where the muscular fibres are in a direct line with those of the tendon or aponeurosis, the two are directly continuous, the muscular fibre being distinguishable from that of the tendon only by its striation. But where the muscular fibre joins the tendon or aponeurosis at an oblique angle, the former terminates, according to Kölliker, in rounded extremities, which are received into corresponding depressions on the surface of the latter, the connective tissue between the fibres being continuous with that of the tendon. The latter mode of attachment occurs in all the penniform and bipenniform muscles, and in those muscles the tendons of which commence in a membranous form, as the Gastrocnemius and Soleus.

The fasciæ (fascia, *a bandage*) are fibro-areolar or aponeurotic laminae, of variable thickness and strength, found in all regions of the body, investing the

softer and more delicate organs. The fasciæ have been subdivided, from the situation in which they are found, into two groups, superficial and deep.

The *superficial fascia* is found immediately beneath the integument over almost the entire surface of the body. It connects the skin with the deep or aponeurotic fascia, and consists of fibro-areolar tissue, containing in its meshes pellicles of fat in varying quantity. In the eyelids and scrotum, where adipose tissue is rarely deposited, this tissue is very liable to serous infiltration. The superficial fascia varies in thickness in different parts of the body: in the groin it is so thick as to be capable of being subdivided in several laminae. Beneath the fatty layer of the superficial fascia, which is immediately subcutaneous, there is generally another layer of the same structure, comparatively devoid of adipose tissue, in which the trunks of the subcutaneous vessels and nerves are found, as the superficial epigastric vessels in the abdominal region, the radial and ulnar veins in the forearm, the saphenous veins in the leg and thigh, and the superficial lymphatic glands; certain cutaneous muscles also are situated in the superficial fascia, as the *Platysma myoides* in the neck, and the *Orbicularis palpebrarum* around the eyelids. This fascia is most distinct at the lower part of the abdomen, the scrotum, perinaeum, and extremities; is very thin in those regions where muscular fibres are inserted into the integument, as on the side of the neck, the face, and around the margin of the anus. It is very dense in the scalp, in the palms of the hands, and soles of the feet, forming a fibro-fatty layer, which binds the integument firmly to the subjacent structure.

The superficial fascia connects the skin to the subjacent parts, facilitates the movement of the skin, serves as a soft nidus for the passage of vessels and nerves to the integument, and retains the warmth of the body, since the fat contained in its areolæ is a bad conductor of heat.

The *deep fascia* is a dense inelastic unyielding fibrous membrane, forming sheaths for the muscles, and affording them broad surfaces for attachment. It consists of shining tendinous fibres, placed parallel with one another, and connected together by other fibres disposed in a rectilinear manner. It is usually exposed on the removal of the superficial fascia, forming a strong investment, which not only binds down collectively the muscles in each region, but gives a separate sheath to each, as well as to the vessels and nerves. The fasciæ are thick in unprotected situations, as on the outer side of a limb, and thinner on the inner side. The deep fasciæ assist the muscles in their action, by the degree of tension and pressure they make upon their surface: and, in certain situations, this is increased and regulated by muscular action, as, for instance, by the *Tensor vaginæ femoris* and *Gluteus maximus* in the thigh, by the *Biceps* in the upper and lower extremities, and *Palmaris longus* in the hand. In the limbs, the fasciæ not only invest the entire limb, but give off septa which separate the various muscles, and are attached beneath to the periosteum: these prolongations of fasciæ are usually spoken of as intermuscular septa.

The Muscles and Fasciæ may be arranged, according to the general division of the body, into those of the cranium, face, and neck; those of the trunk; those of the upper extremity; and those of the lower extremity.

## MUSCLES AND FASCIÆ OF THE CRANIUM AND FACE

The muscles of the Cranium and Face consist of ten groups, arranged according to the region in which they are situated.

- |                        |                                 |
|------------------------|---------------------------------|
| I. Cranial Region.     | VI. Superior Maxillary Region.  |
| II. Auricular Region.  | VII. Inferior Maxillary Region. |
| III. Palpebral Region. | VIII. Intermaxillary Region.    |
| IV. Orbital Region.    | IX. Temporo-maxillary Region.   |
| V. Nasal Region.       | X. Pterygo-maxillary Region.    |

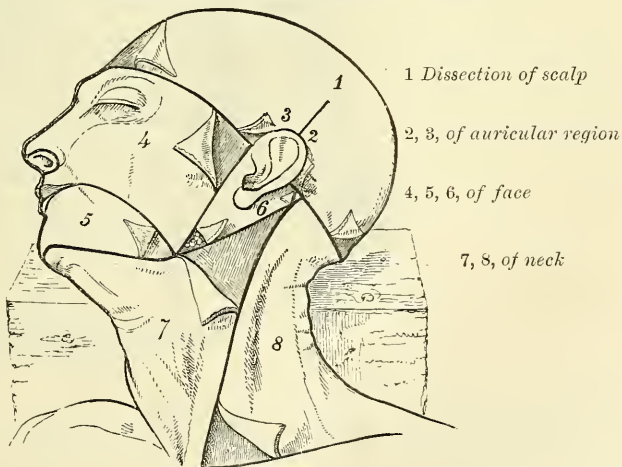
The muscles contained in each of these groups are the following :—

- |                                       |  |
|---------------------------------------|--|
| <i>I. Cranial Region</i>              | Compressor nasi.                       |
| Occipito-frontalis.                   | Compressor narium minor.               |
|                                       | Depressor alæ nasi.                    |
| <i>II. Auricular Region.</i>          | <i>VI. Superior Maxillary Region.</i>  |
| Attollens aurem.                      | Levator labii superioris.              |
| Attrahens aurem.                      | Levator anguli oris.                   |
| Retrahens aurem.                      | Zygomaticus major.                     |
|                                       | Zygomaticus minor.                     |
| <i>III. Palpebral Region.</i>         | <i>VII. Inferior Maxillary Region.</i> |
| Orbicularis palpebrarum.              | Levator labii inferioris.              |
| Corrugator supercillii.               | Depressor labii inferioris.            |
| Tensor tarsi.                         | Depressor anguli oris.                 |
| <i>IV. Orbital Region.</i>            | <i>VIII. Intermaxillary Region.</i>    |
| Levator palpebræ.                     | Buccinator.                            |
| Rectus superior.                      | Risorius.                              |
| Rectus inferior.                      | Orbicularis oris.                      |
| Rectus internus.                      | <i>IX. Temporo-maxillary Region.</i>   |
| Rectus externus.                      | Masseter.                              |
| Obliquus superior.                    | Temporal.                              |
| Obliquus inferior.                    | <i>X. Pterygo-maxillary Region.</i>    |
| <i>V. Nasal Region.</i>               | Pterygoideus externus.                 |
| Pyramidalis nasi.                     | Pterygoideus internus.                 |
| Levator labii superioris alæque nasi. |  |
| Dilatator naris posterior.            |  |
| Dilatator naris anterior.             |  |

#### I. CRANIAL REGION—OCCIPITO-FRONTALIS

*Dissection* (fig. 305).—The head being shaved, and a block placed beneath the back of the neck, make a vertical incision through the skin from before backwards, commencing at the root of the nose in front, and terminating behind at the occipital protuberance ;

FIG. 305.—Dissection of the head, face, and neck.



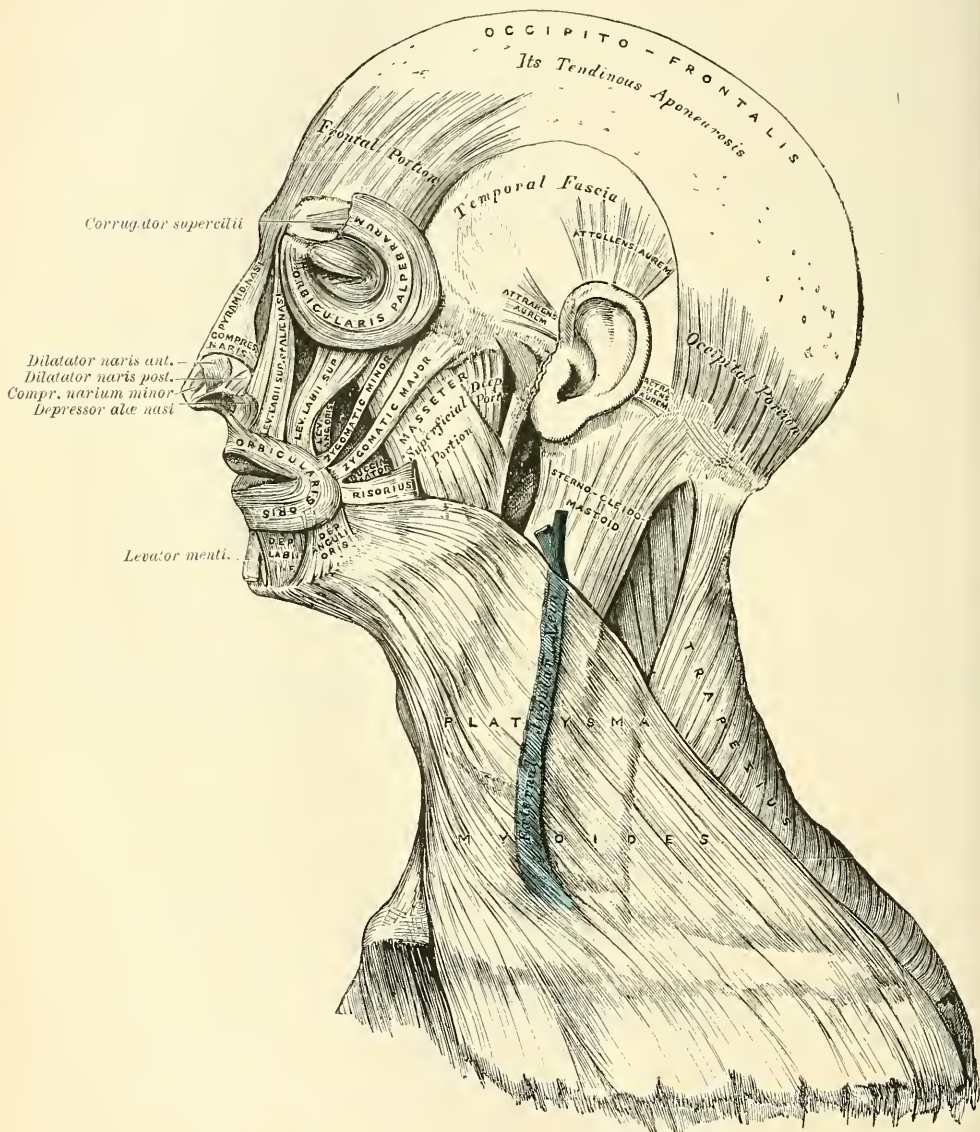
make a second incision in a horizontal direction along the forehead and round the side of the head, from the anterior to the posterior extremity of the preceding. Raise the skin in front, from the subjacent muscle, from below upwards; this must be done with great care, in order to avoid cutting through the vessels and nerves which lie immediately beneath the skin.



**The Skin of the Scalp.**—This is thicker than in any other part of the body. It is intimately adherent to the superficial fascia. The hair-follicles are very closely set together, and extend throughout the whole thickness of the skin. It also contains a number of sebaceous glands.

The **superficial fascia** in the cranial region is a firm, dense, fibro-fatty layer, intimately adherent to the integument, and to the Occipito-frontalis and its

FIG. 306.—Muscles of the head, face, and neck.



tendinous aponeurosis; it is continuous, behind, with the superficial fascia at the back part of the neck; and, laterally, is continued over the temporal fascia. It contains between its layers the superficial vessels and nerves and much granular fat.

The **Occipito-frontalis** (fig. 306) is a broad musculo-fibrous layer, which covers the whole of one side of the vertex of the skull, from the occiput to the eyebrow. It consists of two muscular slips, separated by an intervening tendinous

aponeurosis. The *occipital portion* (sometimes called the *occipitalis* muscle) is thin, quadrilateral in form, and about an inch and a half in length; it arises from the outer two-thirds of the superior curved line of the occipital bone, and from the mastoid portion of the temporal. Its fibres of origin are tendinous, but they soon become muscular, and ascend in a parallel direction to terminate in the tendinous aponeurosis. The *frontal portion* (sometimes called the *frontalis* muscle) is thin, of a quadrilateral form, and intimately adherent to the superficial fascia. It is broader, its fibres are longer, and their structure paler than the occipital portion. Its internal fibres are continuous with those of the *Pyramidalis nasi*. Its middle fibres become blended with the *Corrugator supercilii* and *Orbicularis palpebrarum*; and the outer fibres are also blended with the latter muscle over the external angular process. According to Theile the innermost fibres are attached to the nasal bones, the outer to the external angular process of the frontal bone. From these attachments, the fibres are directed upwards and join the aponeurosis below the coronal suture. The inner margins of the frontal portions of the two muscles are joined together for some distance above the root of the nose; but between the occipital portions there is a considerable, though variable, interval, which is occupied by the aponeurosis.

The **aponeurosis** covers the upper part of the vertex of the skull, being continuous across the middle line with the aponeurosis of the opposite muscle. Behind, it is attached, in the interval between the occipital origins, to the occipital protuberance and superior curved lines above the attachment of the *Trapezius*; in front, it forms a short and narrow prolongation between the frontal portions; and on each side it has connected with it the *Attollens* and *Attrahens aurem* muscles; in this situation it loses its aponeurotic character, and is continued over the temporal fascia to the zygoma as a layer of laminated areolar tissue. This aponeurosis is closely connected to the integument by the firm, dense, fibrofatty layer, which forms the superficial fascia: it is connected with the pericranium by loose cellular tissue, which allows of a considerable degree of movement of the integument.

**Nerves.**—The frontal portion of the *Occipito-frontalis* is supplied by the facial nerve; its occipital portion by the posterior auricular branch of the facial, and sometimes by the *occipitalis minor*.

**Actions.**—The frontal portion of the muscle raises the eyebrows and the skin over the root of the nose, and at the same time draws the scalp forwards, throwing the integument of the forehead into transverse wrinkles. The posterior portion draws the scalp backwards. By bringing alternately into action the frontal and occipital portions the entire scalp may be moved forwards and backwards. In the ordinary action of the muscles, the eyebrows are elevated, and at the same time the aponeurosis is fixed by the posterior portion, thus giving to the face the expression of surprise: if the action is more exaggerated, the eyebrows are still further raised, and the skin of the forehead thrown into transverse wrinkles, as in the expression of fright or horror.

## II. AURICULAR REGION (fig. 306)

*Attrahens aurem.*

*Attollens aurem.*

*Retrahens aurem.*

These three small muscles are placed immediately beneath the skin around the external ear. In man, in whom the external ear is almost immovable, they are rudimentary. They are the analogues of large and important muscles in some of the mammalia.

**Dissection.**—This requires considerable care, and should be performed in the following manner:—To expose the *Attollens aurem*, draw the pinna or broad part of the ear downwards, when a tense band will be felt beneath the skin, passing from the side of the head to the upper part of the concha; by dividing the skin over this band, in a direction from below upwards, and then reflecting it on each side, the muscle is exposed. To bring into



view the *Attrahens aurem*, draw the helix backwards by means of a hook, when the muscle will be made tense, and may be exposed in a similar manner to the preceding. To expose the *Retrahens aurem*, draw the pinna forwards, when the muscle, being made tense, may be felt beneath the skin, at its insertion into the back part of the concha, and may be exposed in the same manner as the other muscles.

The **Attrahens aurem** (*Auricularis anterior*), the smallest of the three, is thin, fan-shaped, and its fibres pale and indistinct; they arise from the lateral edge of the aponeurosis of the Occipito-frontalis, and converge to be inserted into a projection on the front of the helix.

**Relations.**—*Superficially*, with the skin; *deeply*, with the areolar tissue derived from the aponeurosis of the Occipito-frontalis, beneath which are the temporal artery and vein and the temporal fascia.

The **Attollens aurem** (*Auricularis superior*), the largest of the three, is thin and fan-shaped: its fibres arise from the aponeurosis of the Occipito-frontalis, and converge to be inserted by a thin, flattened tendon into the upper part of the cranial surface of the pinna.

**Relations.**—*Superficially*, with the integument; *deeply*, with the areolar tissue derived from the aponeurosis of the Occipito-frontalis, beneath which is the temporal fascia.

The **Retrahens aurem** (*Auricularis posterior*) consists of two or three fleshy fasciculi, which arise from the mastoid portion of the temporal bone by short aponeurotic fibres. They are inserted into the lower part of the cranial surface of the concha.

**Relations.**—*Superficially*, with the integument; *deeply*, with the mastoid portion of the temporal bone.

**Nerves.**—The *Attrahens aurem* and *Attollens aurem* are supplied by the temporal branch of the facial; the *Retrahens aurem* is supplied by the posterior auricular branch of the same nerve.

**Actions.**—In man, these muscles possess very little action: the *Attrahens aurem* draws the ear forwards and upwards; the *Attollens aurem* slightly raises it; and the *Retrahens aurem* draws it backwards.

### III. PALPEBRAL REGION (fig. 306)

Orbicularis palpebrarum.

Levator palpebræ.

Corrugator supercillii.

Tensor tarsi.

**Dissection** (fig. 305).—In order to expose the muscles of the face, continue the longitudinal incision, made in the dissection of the Occipito-frontalis, down the median line of the face to the tip of the nose, and from this point onwards to the upper lip; and carry another incision along the margin of the lip to the angle of the mouth, and transversely across the face to the angle of the jaw. Then make an incision in front of the external ear, from the angle of the jaw upwards, to join the transverse incision made in exposing the Occipito-frontalis. These incisions include a square-shaped flap, which should be removed in the direction marked in the figure, with care, as the muscles at some points are intimately adherent to the integument.

The **Orbicularis palpebrarum** is a sphincter muscle, which surrounds the circumference of the orbit and eyelids. It arises from the internal angular process of the frontal bone, from the nasal process of the superior maxillary in front of the lachrymal groove for the nasal duct, and from the anterior surface and borders of a short tendon, the *tendo oculi*, or *internal tarsal ligament*, placed at the inner angle of the orbit. From this origin, the fibres are directed outwards, forming a broad, thin, and flat layer, which covers the eyelids, surrounds the circumference of the orbit, and spreads out over the temple, and downwards on the cheek. The palpebral portion (ciliaris) of the *Orbicularis* is thin and pale; it arises from the bifurcation of the *tendo palpebrarum*, and forms a series of concentric curves, which are inserted on the outer side of the eyelids into the external tarsal ligament. The orbital portion (*orbicularis latus*) is thicker and



of a reddish colour: its fibres are well developed, and form complete ellipses. The upper fibres of this portion blend with the Occipito-frontalis and Corrugator supercilii.

**Relations.**—By its *superficial surface*, with the integument. By its *deep surface*, above, with the Occipito-frontalis and Corrugator supercilii, with which it is intimately blended, and with the supra-orbital vessels and nerve; below, it covers the lachrymal sac, and the origin of the Levator labii superioris alæque nasi, the Levator labii superioris, and the Zygomaticus minor muscles. *Internally*, it is occasionally blended with the Pyramidalis nasi. *Externally*, it lies on the temporal fascia. On the eyelids, it is separated from the conjunctiva by the Levator palpebræ, the tarsal ligaments, the tarsal plates, and the Meibomian glands.

The *tendo oculi* (internal tarsal ligament) is a short tendon, about two lines in length and one in breadth, attached to the nasal process of the superior maxillary bone in front of the lachrymal groove for the nasal duct. Crossing the lachrymal sac, it divides into two parts, each division being attached to the inner extremity of the corresponding tarsal plate. As the tendon crosses the lachrymal sac, a strong aponeurotic lamina is given off from the posterior surface, which expands over the sac, and is attached to the ridge on the lachrymal bone. This is the reflected aponeurosis of the *tendo oculi*.

The *external tarsal ligament* is a much weaker structure than the *tendo oculi*, and does not divide. It is attached to the margin of the frontal process of the malar bone, and passes inwards to the outer commissure of the eyelids; it connects together the outer extremities of the two tarsal cartilages.

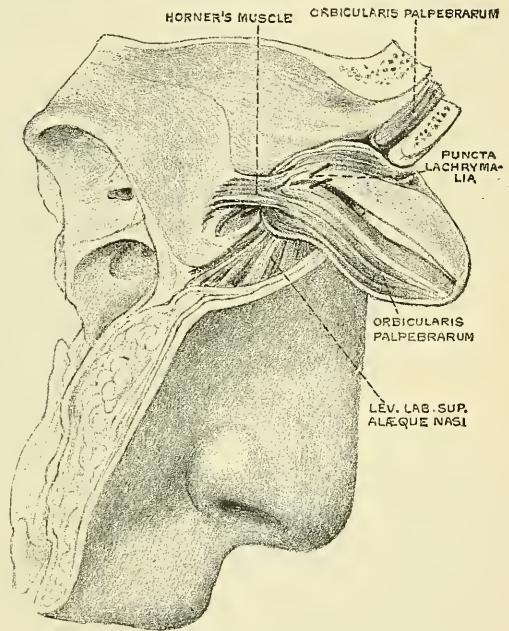
**Use of Tendo oculi.**—Besides giving attachment to part of the Orbicularis palpebrarum, and to the tarsal plates, it serves to suck the tears into the lachrymal sac, by its attachment to the sac. Thus, each time the eyelids are closed, the *tendo oculi* becomes tightened, through the action of the Orbicularis, and draws the wall of the lachrymal sac outwards and forwards, so that a vacuum is made in the sac, and the tears are sucked along the lachrymal canals into it.

The **Corrugator supercilii** is a small, narrow, pyramidal muscle, placed at the inner extremity of the eyebrow, beneath the Occipito-frontalis and Orbicularis palpebrarum muscles. It arises from the inner extremity of the superciliary ridge; whence its fibres pass upwards and outwards, and, passing between the palpebral and orbital portions of the Orbicularis palpebrarum, are inserted into the deep surface of the skin, opposite the middle of the orbital arch.

**Relations.**—By its *anterior surface*, with the Occipito-frontalis and Orbicularis palpebrarum muscles. By its *posterior surface*, with the frontal bone and supra-trochlear nerve.

The **Levator palpebræ** will be described with the muscles of the orbital region.

FIG. 307.—Horner's muscle. (From a preparation in the Museum of the Royal College of Surgeons of England.)



The **Tensor tarsi** (Horner's muscle) (fig. 307) is a small thin muscle, about three lines in breadth and six in length, situated at the inner side of the orbit, behind the *tendo oculi*. It arises from the crest and adjacent part of the orbital surface of the lachrymal bone, and, passing across the lachrymal sac, divides into two slips, which cover the lachrymal canals, and are inserted into the tarsal plates internal to the *puncta lachrymalia*. Its fibres appear to be continuous with those of the palpebral portion of the *Orbicularis palpebrarum*; it is occasionally very indistinct.

**Nerves.**—The *Orbicularis palpebrarum*, *Corrugator supercillii*, and *Tensor tarsi* are supplied by the facial nerve.

**Actions.**—The *Orbicularis palpebrarum* is the sphincter muscle of the eyelids. The palpebral portion acts involuntarily, closing the lids gently, as in sleep or in blinking; the orbicular portion is subject to the will. When the entire muscle is brought into action, the skin of the forehead, temple, and cheek is drawn inwards towards the inner angle of the orbit, and the eyelids are firmly closed as in photophobia. When the skin of the forehead, temple, and cheek is thus drawn inwards by the action of the muscle it is thrown into folds, especially radiating from the outer angle of the eyelids, which give rise in old age to the so-called 'crow's feet.' The *Levator palpebræ* is the direct antagonist of this muscle; it raises the upper eyelid and exposes the globe. The *Corrugator supercillii* draws the eyebrow downwards and inwards, producing the vertical wrinkles of the forehead. It is the 'frowning' muscle, and may be regarded as the principal agent in the expression of suffering. The *Tensor tarsi* draws the eyelids and the extremities of the lachrymal canals inwards and compresses them against the surface of the globe of the eye; thus placing them in the most favourable situation for receiving the tears. It serves, also, to compress the lachrymal sac.

#### IV. ORBITAL REGION (fig. 308)

<i>Levator palpebræ superioris.</i>	<i>Rectus internus.</i>
<i>Rectus superior.</i>	<i>Rectus externus.</i>
<i>Rectus inferior.</i>	<i>Obliquus oculi superior.</i>
<i>Obliquus oculi inferior.</i>	

**Dissection.**—To open the cavity of the orbit, remove the skull-cap and brain; then saw through the frontal bone at the inner extremity of the supra-orbital ridge, and externally at its junction with the malar. Break in pieces the thin roof of the orbit by a few slight blows of the hammer, and take it away; drive forward the superciliary portion of the frontal bone by a smart stroke, but do not remove it, as that would destroy the pulley of the *Obliquus superior*. When the fragments are cleared away, the periosteum of the orbit will be exposed; this being removed, together with the fat which fills the cavity of the orbit, the several muscles of this region can be examined. The dissection will be facilitated by distending the globe of the eye. In order to effect this, puncture the optic nerve near the eyeball with a curved needle, and push the needle onwards into the globe; insert the point of a blow pipe through this aperture, and force a little air into the cavity of the eyeball; then apply a ligature round the nerve so as to prevent the air escaping. The globe being now drawn forwards, the muscles will be put upon the stretch.

The ***Levator palpebræ superioris*** is thin, flat, and triangular in shape. It arises from the under surface of the lesser wing of the sphenoid, above and in front of the optic foramen, from which it is separated by the origin of the *Superior rectus*. At its origin, it is narrow and tendinous, but soon becomes broad and fleshy, and finally terminates in a broad aponeurosis, which is inserted into the upper margin of the superior tarsal plate. From this aponeurosis a thin expansion is continued onwards, passing between the fibres of the *Orbicularis* to be inserted into the skin of the lid, and some deeper fibres blend with an expansion from the sheath of the *Superior rectus* muscle, and are with it prolonged into the conjunctiva.

**Relations.**—By its *upper surface*, with the frontal nerve, the supra-orbital artery, and the periosteum of the orbit; and, in the lid, with the inner surface



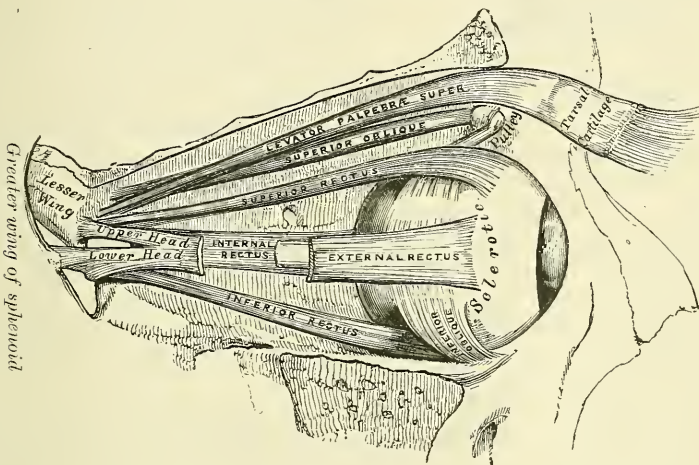
of the tarsal ligament. By its *under surface*, with the Superior rectus; and, in the lid, with the conjunctiva. A small branch of the third nerve enters its under surface.

The **Superior rectus**, the thinnest and narrowest of the four Recti, arises from the upper margin of the optic foramen beneath the Levator palpebræ, and from the fibrous sheath of the optic nerve; and is inserted, by a tendinous expansion, into the sclerotic coat, about three or four lines from the margin of the cornea.

**Relations.**—By its *upper surface*, with the Levator palpebræ. By its *under surface*, with the optic nerve, the ophthalmic artery, the nasal nerve, and the branch of the third nerve which supplies it; and, in front, with the tendon of the Superior oblique, and the globe of the eye.

The **Inferior** and **Internal Recti** arise by a common tendon (the *ligament of Zinn*)\* which is attached round the circumference of the optic foramen, except at its upper and outer part. The **External rectus** has two heads: the upper one arises from the outer margin of the optic foramen immediately beneath the Superior rectus; the lower head, partly from the ligament of Zinn, and partly from a small pointed process of bone on the lower margin of the sphenoidal

FIG. 308.—Muscles of the right orbit.



fissure. Each muscle passes forward in the position implied by its name, to be inserted by a tendinous expansion (the *tunica albuginea*) into the sclerotic coat, about three or four lines from the margin of the cornea. Between the two heads of the External rectus is a narrow interval, through which passes the third, the nasal branch of the ophthalmic division of the fifth and the sixth nerves, and the ophthalmic vein. Although nearly all of these muscles present a common origin and are inserted in a similar manner into the sclerotic coat, there are certain differences to be observed in them, as regards their length and breadth. The Internal rectus is the broadest; the External is the longest; and the Superior is the thinnest and narrowest.

The **Superior oblique** is a fusiform muscle, placed at the upper and inner side of the orbit, internal to the Levator palpebræ. It arises about a line above the inner margin of the optic foramen, and, passing forwards to the inner angle of the orbit, terminates in a rounded tendon, which plays in a ring or pulley,

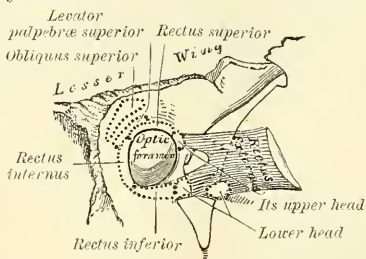
\* The ligament of Zinn ought, perhaps more appropriately, to be termed the *aponeurosis* or *tendon of Zinn*. Mr. C. B. Lockwood has described a somewhat similar structure on the under surface of the Superior rectus muscle, which is attached to the lesser wing of the sphenoid forming the upper and outer margin of the optic foramen. This *superior tendon* gives origin to the Superior rectus, the superior head of the External rectus, and the upper part of the Internal rectus.—*Journal of Anatomy and Physiology*, vol. xx. part i. p. 1.



formed by cartilaginous tissue attached to a depression beneath the internal angular process of the frontal bone, the contiguous surfaces of the tendon and ring being lined by a delicate synovial membrane, and enclosed in a thin fibrous investment. The tendon is reflected backwards, outwards, and downwards beneath the Superior rectus to the outer part of the globe of the eye, and is inserted into the sclerotic coat, midway between the cornea and entrance of the optic nerve, the insertion of the muscle lying between the Superior and External recti.

**Relations.**—By its *upper surface*, with the periosteum covering the roof of the orbit, and the fourth nerve. The tendon, where it lies on the globe of the eye, is covered by the Superior rectus. By its *under surface*, with the nasal nerve, and the upper border of the Internal rectus.

FIG. 309.—The relative position and attachment of the muscles of the left eyeball.



The **Inferior oblique** is a thin, narrow muscle, placed near the anterior margin of the orbit. It arises from a depression on the orbital plate of the superior maxillary bone, external to the lachrymal groove for the nasal duct. Passing outwards, backwards, and upwards beneath the Inferior rectus, and then between the eyeball and the External rectus, it is inserted into the outer part of the

sclerotic coat between the Superior and External recti, near to, but somewhat behind, the tendon of insertion of the Superior oblique.

**Relations.**—By its *ocular surface*, with the globe of the eye, and with the Inferior rectus. By its *orbital surface*, with the periosteum covering the floor of the orbit, and with the External rectus. Its borders look forwards and backwards; and the posterior one receives a branch of the third nerve.

**Nerves.**—The Levator palpebræ, Inferior oblique, and all the Recti excepting the External, are supplied by the third nerve; the Superior oblique, by the fourth; the External rectus, by the sixth.

**Actions.**—The Levator palpebræ raises the upper eyelid, and is the direct antagonist of the Orbicularis palpebrarum. The four Recti muscles are attached in such a manner to the globe of the eye that, acting singly, they will turn it either upwards, downwards, inwards, or outwards, as expressed by their names. The movement produced by the Superior or Inferior rectus is not quite a simple one, for inasmuch as they pass obliquely outwards and forwards to the eyeball, the elevation or depression of the cornea must be accompanied by a certain deviation inwards, with a slight amount of rotation, which, however, is corrected by the Oblique muscles; the Inferior oblique correcting the deviation inwards of the Superior rectus, and the Superior oblique that of the Inferior rectus. The contraction of the External and Internal recti, on the other hand, produces a purely horizontal movement. If any two contiguous recti of one eye act together they carry the globe of the eye in the diagonal of these directions, viz. upwards and inwards, upwards and outwards, downwards and inwards, or downwards and outwards. The movement of circumduction, as in looking round a room, is performed by the alternate action of the four Recti. The oblique muscles rotate the eyeball on its *antero-posterior axis*, this kind of movement being required for the correct viewing of an object when the head is moved laterally, as from shoulder to shoulder, in order that the picture may fall in all respects on the same part of the retina of each eye.\*

\* 'On the Oblique Muscles of the Eye in Man and Vertebrate Animals,' by John Struthers, M.D., in *Anatomical and Physiological Observations*. For a fuller account of the various co-ordinated actions of the muscles of a single eye and of both eyes than our space allows, the reader may be referred to Dr. M. Foster's *Text-book of Physiology*.

**Fasciæ of the Orbit.**—The connective tissue of the orbit is in various places condensed into thin membranous layers, which may be conveniently described as (1) those lining the cavity; (2) those ensheathing the muscles; and (3) that covering the eyeball.

(1) The *orbital fascia*. This forms the periosteum of the orbit. It is loosely connected to the bones, from which it can be readily separated. Behind, it is connected with the dura mater by processes which pass through the optic foramen and sphenoidal fissure, and with the sheath of the optic nerve. In front, it is connected with the periosteum at the margin of the orbit, and sends off a process which assists in forming the palpebral fascia. From the internal surface of this fascia numerous processes are sent off, which enclose the fat lobules: two of these require special mention—one assisting in enclosing the lachrymal gland, the other being connected with the pulley of the Superior oblique muscle, and holding it in position.

(2) The *muscular fascia* connects together the muscles of the orbit, and splitting at their borders forms a sheath to them. Posteriorly, it is thin, and is connected to the orbital fascia. Anteriorly, it is thicker, and divides into two layers: of these one becomes attached to the orbital margin; the other is reflected backwards, and covers the hinder part of the globe of the eye. From the former of these two layers expansions are given off; from the part of the fascia covering the Superior rectus this expansion blends with some deep fibres from the tendon of the Levator palpebræ; while from the part of the fascia covering the Inferior rectus the expansion is carried forwards into the inferior tarsal plate, and is sometimes described as the suspensory ligament of the eye.

(3) The fascia covering the eyeball—Tenon's capsule—will be described in the sequel.

*Surgical Anatomy.*—The position and exact point of insertion of the tendons of the Internal and External recti muscles into the globe should be carefully examined from the front of the eyeball, as the surgeon is often required to divide the one or the other muscle for the cure of strabismus. In convergent strabismus, which is the more common form of the disease, the eye is turned inwards, requiring the division of the Internal rectus. In the divergent form, which is more rare, the eye is turned outwards, the External rectus being especially implicated. The deformity produced in either case is to be remedied by division of one or the other muscle. The operation is thus performed: the lids are to be well separated; the eyeball being rotated outwards or inwards, the conjunctiva should be raised by a pair of forceps, and incised immediately beneath the lower border of the tendon of the muscle to be divided, a little behind its insertion into the sclerotic; the submucous areolar tissue is then divided, and into the small aperture thus made, a blunt hook is passed upwards between the muscle and the globe, and the tendon of the muscle and conjunctiva covering it, divided by a pair of blunt-pointed scissors. Or the tendon may be divided by a subconjunctival incision, one blade of the scissors being passed upwards between the tendon and the conjunctiva, and the other between the tendon and the sclerotic. The student, when dissecting these muscles, should remove on one side of the subject the conjunctiva from the front of the eye, in order to see more accurately the position of the tendons, while on the opposite side the operation may be performed.

#### V. NASAL REGION (fig. 306)

Pyramidalis nasi.	Dilatator naris anterior.
Levator labii superioris alæque nasi.	Compressor nasi.
Dilatator naris posterior.	Compressor narium minor.
Depressor alæ nasi.	

The **Pyramidalis nasi** is a small pyramidal slip placed over the nasal bone. Its origin is by tendinous fibres from the fascia covering the lower part of the nasal bone and upper part of the cartilage, where it blends with the Compressor nasi, and it is inserted into the skin over the lower part of the forehead between the two eyebrows, its fibres decussating with those of the Occipito-frontalis.

**Relations.**—By its *upper surface*, with the skin. By its *under surface*, with the frontal and nasal bones.

The **Levator labii superioris alæque nasi** is a thin triangular muscle, placed by the side of the nose, and extending between the inner margin of the orbit and upper lip. It arises by a pointed extremity from the upper part of the nasal process of the superior maxillary bone, and, passing obliquely downwards and outwards, divides into two slips, one of which is inserted into the cartilage of the ala of the nose; the other is prolonged into the upper lip, becoming blended with the Orbicularis oris and Levator labii superioris proprius.

**Relations.**—In front, with the integument; and with a small part of the Orbicularis palpebrarum above.

The **Dilatator naris posterior** is a small muscle, which is placed partly beneath the elevator of the nose and lip. It arises from the margin of the nasal notch of the superior maxilla, and from the sesamoid cartilages, and is inserted into the skin near the margin of the nostril.

The **Dilatator naris anterior** is a thin delicate fasciculus, passing from the cartilage of the ala of the nose to the integument near its margin. This muscle is situated in front of the preceding.

The **Compressor naris** is a small, thin, triangular muscle, arising by its apex from the superior maxillary bone, above and a little external to the incisive fossa; its fibres proceed upwards and inwards, expanding into a thin aponeurosis which is attached to the fibro-cartilage of the nose, and is continuous on the bridge of the nose with that of the muscle of the opposite side, and with the aponeurosis of the Pyramidalis nasi.

The **Compressor narium minor** is a small muscle, attached by one end to the alar cartilage, and by the other to the integument at the end of the nose.

The **Depressor alæ nasi** is a short, radiated muscle, arising from the incisive fossa of the superior maxilla; its fibres ascend to be inserted into the septum, and back part of the ala of the nose. This muscle lies between the mucous membrane and muscular structure of the lip.

**Nerves.**—All the muscles of this group are supplied by the facial nerve.

**Actions.**—The Pyramidalis nasi draws down the inner angle of the eyebrows and produces transverse wrinkles over the bridge of the nose. The Levator labii superioris alæque nasi draws upwards the upper lip and ala of the nose; its most important action is upon the nose, which it dilates to a considerable extent. The action of this muscle produces a marked influence over the countenance, and it is the principal agent in the expression of contempt and disdain. The two Dilatores nasi enlarge the aperture of the nose. Their action in ordinary breathing is to resist the tendency of the nostrils to close from atmospheric pressure, but in difficult breathing they may be noticed to be in violent action, as well as in some emotions, as anger. The Depressor alæ nasi is a direct antagonist of the other muscles of the nose, drawing the ala of the nose downwards, and thereby constricting the aperture of the nares. The Compressor nasi depresses the cartilaginous part of the nose and draws the alæ together.

## VI. SUPERIOR MAXILLARY REGION (fig. 306)

Levator labii superioris.

Zygomaticus major.

Levator anguli oris.

Zygomaticus minor.

The **Levator labii superioris (proprius)** is a thin muscle of a quadrilateral form. It arises from the lower margin of the orbit immediately above the infra-orbital foramen, some of its fibres being attached to the superior maxilla, others to the malar bone; its fibres converge to be inserted into the muscular substance of the upper lip.

**Relations.**—By its *superficial surface* above, with the lower segment of the Orbicularis palpebrarum; below, it is subcutaneous. By its *deep surface*, it conceals the origin of the Compressor nasi and Levator anguli oris muscles,



and the infra-orbital vessels and nerve, as they escape from the infra-orbital foramen.

The **Levator anguli oris** arises from the canine fossa, immediately below the infra-orbital foramen; its fibres incline downwards and a little outwards, to be inserted into the angle of the mouth, intermingling with those of the Zygomaticus major, the Depressor anguli oris, and the Orbicularis.

**Relations.**—By its *superficial surface*, with the Levator labii superioris and the infra-orbital vessels and nerves. By its *deep surface*, with the superior maxilla, the Buccinator, and the mucous membrane.

The **Zygomaticus major** is a slender fasciculus, which arises from the malar bone, in front of the zygomatic suture, and descending obliquely downwards and inwards, is inserted into the angle of the mouth, where it blends with the fibres of the Levator anguli oris, the Orbicularis oris, and the Depressor anguli oris.

**Relations.**—By its *superficial surface*, with the subcutaneous adipose tissue. By its *deep surface*, with the Masseter and Buccinator muscles and the facial artery and vein.

The **Zygomaticus minor** arises from the malar bone, immediately behind the maxillary suture, and passing downwards and inwards, is continuous with the Orbicularis oris at the outer margin of the Levator labii superioris. It lies in front of the preceding.

**Relations.**—By its *superficial surface*, with the integument and the Orbicularis palpebrarum above. By its *deep surface*, with the Masseter, Buccinator, and Levator anguli oris, and the facial artery and vein.

**Nerves.**—This group of muscles is supplied by the facial nerve.

**Actions.**—The Levator labii superioris is the proper elevator of the upper lip, carrying it at the same time a little forwards. It assists in forming the naso-labial ridge, which passes from the side of the nose to the upper lip and gives to the face an expression of sadness. The Levator anguli oris raises the angle of the mouth and assists the Levator labii superioris in producing the naso-labial ridge. The Zygomaticus major draws the angle of the mouth backwards and upwards, as in laughing; whilst the Zygomaticus minor, being inserted into the outer part of the upper lip and not into the angle of the mouth, draws it backwards, upwards, and outwards, and thus gives to the face an expression of sadness.

## VII. INFERIOR MAXILLARY REGION (fig. 306)

Levator labii inferioris (Levator menti).

Depressor labii inferioris (Quadratus menti).

Depressor anguli oris (Triangularis menti).

**Dissection.**—The Muscles in this region may be dissected by making a vertical incision through the integument from the margin of the lower lip to the chin: a second incision should then be carried along the margin of the lower jaw as far as the angle, and the integument carefully removed in the direction shown in fig. 305.

The **Levator labii inferioris (Levator menti)** is to be dissected by everting the lower lip and raising the mucous membrane. It is a small conical fasciculus, placed on the side of the frænum of the lower lip. It arises from the incisive fossa, external to the symphysis of the lower jaw: its fibres descend to be inserted into the integument of the chin.

**Relations.**—On its *inner surface*, with the mucous membrane; in the *median line*, it is blended with the muscle of the opposite side; and on its *outer side*, with the Depressor labii inferioris.

The **Depressor labii inferioris (Quadratus menti)** is a small quadrilateral muscle. It arises from the external oblique line of the lower jaw, between the symphysis and mental foramen, and passes obliquely upwards and inwards, to be inserted into the integument of the lower lip, its fibres blending with the Orbicularis oris, and with those of its fellow of the opposite side. It is continuous

with the fibres of the Platysma at its origin. This muscle contains much yellow fat intermingled with its fibres.

**Relations.**—By its *superficial surface*, with part of the Depressor anguli oris, and with the integument, to which it is closely connected. By its *deep surface*, with the mental vessels and nerves, the mucous membrane of the lower lip, the labial glands, and the Levator menti, with which it is intimately united.

The **Depressor anguli oris (Triangularis menti)** is triangular in shape, arising, by its broad base, from the external oblique line of the lower jaw, whence its fibres pass upwards, to be inserted, by a narrow fasciculus, into the angle of the mouth. It is continuous with the Platysma at its origin, and with the Orbicularis oris and Risorius at its insertion, and some of its fibres are directly continuous with those of the Levator anguli oris.

**Relations.**—By its *superficial surface*, with the integument. By its *deep surface*, with the Depressor labii inferioris and Buccinator.

**Nerves.**—This group of muscles is supplied by the facial nerve.

**Actions.**—The Levator labii inferioris raises the lower lip, and protrudes it forwards, and at the same time wrinkles the integument of the chin, expressing doubt or disdain. The Depressor labii inferioris draws the lower lip directly downwards and a little outwards, as in the expression of irony. The Depressor anguli oris depresses the angle of the mouth, being the antagonist to the Levator anguli oris and Zygomaticus major; acting with these muscles, it will draw the angle of the mouth directly backwards.

#### VIII. INTERMAXILLARY REGION

Orbicularis oris.

Buccinator.

Risorius.

*Dissection.*—The dissection of these muscles may be considerably facilitated by filling the cavity of the mouth with tow, so as to distend the cheeks and lips; the mouth should then be closed by a few stitches, and the integument carefully removed from the surface.

The **Orbicularis oris** (fig. 306) is not a sphincter muscle like the Orbicularis palpebrarum, but consists of numerous strata of muscular fibres, having different directions, which surround the orifice of the mouth. These fibres are partially derived from the other facial muscles which are inserted into the lips, and are partly fibres proper to the lips themselves. Of the former, a considerable number are derived from the Buccinator and form the deeper stratum of the Orbicularis. Some of them, namely, those near the middle of the muscle, decussate at the angle of the mouth, those arising from the upper jaw passing to the lower lip, and those from the lower jaw to the upper lip. Other fibres of the muscle, situated at its upper and lower part, pass across the lips from side to side without interruption. Superficial to this stratum is a second, formed by the Levator and Depressor anguli oris, which cross each other at the angle of the mouth; those from the Depressor passing to the upper lip, and those from the Levator to the lower lip, along which they run to be inserted into the skin near the median line. In addition to these there are fibres from the other muscles inserted into the lips, the Levator labii superioris, the Levator labii superioris alæque nasi, the Zygomatici, and the Depressor labii inferioris; these intermingle with the transverse fibres above described, and have principally an oblique direction. The proper fibres of the lips are oblique, and pass from the under surface of the skin to the mucous membrane, through the thickness of the lip. And in addition to these are fibres by which the muscle is connected directly with the maxillary bones and the septum of the nose. These consist, in the upper lip, of four bands, two of which (*Musculus incisivus superior*) arise from the alveolar border of the superior maxilla, opposite the lateral incisor tooth, and arching outwards on each side are continuous at the angles of the mouth with the other muscles inserted into this part. The two remaining muscular slips, called the *Naso-labialis*, connect the upper lip to the back of the septum of the nose: as they descend

from the septum, an interval is left between them. It is this interval which forms the depression seen on the surface of the skin beneath the septum of the nose. The additional fibres for the lower segment (*Musculus incisivus inferior*) arise from the inferior maxilla, externally to the Levator labii inferioris, and arch outwards to the angles of the mouth, to join the Buccinator and the other muscles attached to this part.

**Relations.**—By its *superficial surface*, with the integument, to which it is closely connected. By its *deep surface*, with the buccal mucous membrane, the labial glands, and coronary vessels. By its *outer circumference*, it is blended with the numerous muscles which converge to the mouth from various parts of the face. Its *inner circumference* is free, and covered by the mucous membrane.

The **Buccinator** (fig. 319) is a broad, thin muscle, quadrilateral in form, which occupies the interval between the jaws at the side of the face. It arises from the outer surface of the alveolar processes of the upper and lower jaws, corresponding to the three molar teeth; and behind, from the anterior border of the pterygo-maxillary ligament. The fibres converge towards the angle of the mouth, where the central fibres intersect each other, those from below being continuous with the upper segment of the Orbicularis oris; and those from above with the inferior segment; the highest and lowest fibres continue forward uninterruptedly into the corresponding segment of the lip without decussation.

**Relations.**—By its *superficial surface*, behind, with a large mass of fat, which separates it from the ramus of the lower jaw, the Masseter, and a small portion of the Temporal muscle; anteriorly, with the Zygomatici, Risorius, Levator anguli oris, Depressor anguli oris, and Stenson's duct, which pierces it opposite the second molar tooth of the upper jaw; the facial artery and vein cross it from below upwards; it is also crossed by the branches of the facial and buccal nerves. By its *internal surface*, with the buccal glands and mucous membrane of the mouth.

The *pterygo-maxillary ligament* separates the Buccinator muscle from the Superior constrictor of the pharynx. It is a tendinous band, attached by one extremity to the apex of the internal pterygoid plate, and by the other to the posterior extremity of the internal oblique line of the lower jaw. Its *inner surface* corresponds to the cavity of the mouth, and is lined by mucous membrane. Its *outer surface* is separated from the ramus of the jaw by a quantity of adipose tissue. Its *posterior border* gives attachment to the Superior constrictor of the pharynx; its *anterior border*, to the fibres of the Buccinator (see fig. 319).

The **Risorius (Santorini)** (fig. 306) consists of a narrow bundle of fibres, which arises in the fascia over the Masseter muscle and, passing horizontally forwards, is inserted into the skin at the angle of the mouth. It is placed superficial to the Platysma, and is broadest at its outer extremity. This muscle varies much in its size and form.

**Nerves.**—The muscles in this group are all supplied by the facial nerve. The buccal branch of the inferior maxillary nerve pierces the Buccinator muscle, and by some anatomists is regarded as partly supplying this muscle. Probably it merely pierces it on its way to the mucous membrane of the cheek.

**Actions.**—The Orbicularis oris in its ordinary action produces the direct closure of the lips; by its deep fibres, assisted by the oblique ones, it closely applies the lips to the alveolar arch. The superficial part, consisting principally of the decussating fibres, brings the lips together and also protrudes them forwards. The Buccinators contract and compress the cheeks, so that, during the process of mastication, the food is kept under the immediate pressure of the teeth. When the cheeks have been previously distended with air, the Buccinator muscles expel it from between the lips, as in blowing a trumpet. Hence the name (*buccina*, a trumpet). The Risorius retracts the angles of the mouth, and produces the unpleasant expression which is sometimes seen in tetanus, and is known as 'risus sardonius.'



## IX. TEMPORO-MAXILLARY REGION

Masseter.

Temporal.

*Masseteric Fascia.*—Covering the Masseter muscle, and firmly connected with it, is a strong layer of fascia, derived from the deep cervical fascia. Above, this fascia is attached to the lower border of the zygoma, and behind it covers the parotid gland, constituting the *parotid fascia*.

The **Masseter** is exposed by the removal of this fascia (fig. 306); it is a short, thick muscle, somewhat quadrilateral in form, consisting of two portions, superficial and deep. The *superficial portion*, the larger, arises by a thick, tendinous aponeurosis from the malar process of the superior maxilla, and from the anterior two-thirds of the lower border of the zygomatic arch: its fibres pass downwards and backwards, to be inserted into the angle and lower half of the outer surface of the ramus of the jaw. The *deep portion* is much smaller, and more muscular in texture; it arises from the posterior third of the lower border and the whole of the inner surface of the zygomatic arch; its fibres pass downwards and forwards, to be inserted into the upper half of the ramus and outer surface of the coronoid process of the jaw. The deep portion of the muscle is partly concealed, in front, by the superficial portion; behind, it is covered by the parotid gland. The fibres of the two portions are united at their insertion.

**Relations.**—By its *superficial surface*, with the Zygomatici, the Socia parotidis, and Stenson's duct; the branches of the facial nerve and the transverse facial vessels, which cross it; the masseteric fascia; the Risorius Santorini, Platysma myoides, and the integument. By its *deep surface*, with the Temporal muscle at its insertion, the ramus of the jaw, and the Buccinator, from which it is separated by a mass of fat. The masseteric nerve and artery enter it on its under surface. Its *posterior margin* is overlapped by the parotid gland. Its *anterior margin* projects over the Buccinator muscle; and the facial vein lies on it below.

The *temporal fascia* is seen, at this stage of the dissection, covering in the Temporal muscle. It is a strong, fibrous investment, covered, on its outer surface, by the Attrahens and Attollens aurem muscles, the aponeurosis of the Occipito-frontalis, and by part of the Orbicularis palpebrarum. The temporal vessels and the auriculo-temporal nerve cross it from below upwards. Above, it is a single layer, attached to the entire extent of the upper temporal ridge; but below, where it is attached to the zygoma, it consists of two layers, one of which is inserted into the outer, and the other into the inner border of the zygomatic arch. A small quantity of fat, the orbital branch of the temporal artery, and a filament from the orbital, or temporo-malar, branch of the superior maxillary nerve, are contained between these two layers. It affords attachment by its inner surface to the superficial fibres of the Temporal muscle.

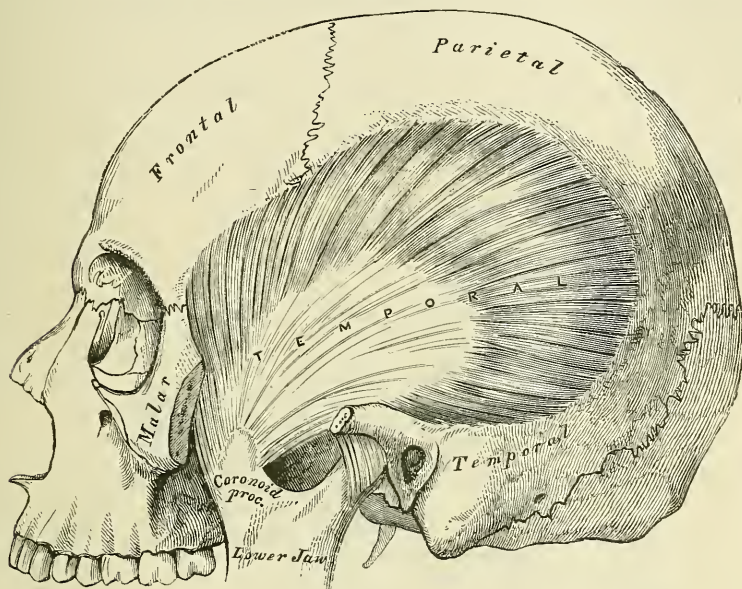
**Dissection.**—In order to expose the Temporal muscle, remove the temporal fascia, which may be effected by separating it at its attachment along the upper border of the zygoma, and dissecting it upwards from the surface of the muscle. The zygomatic arch should then be divided, in front, at its junction with the malar bone; and, behind, near the external auditory meatus, and drawn downwards with the Masseter, which should be detached from its insertion into the ramus and angle of the jaw. The whole extent of the Temporal muscle is then exposed.

The **Temporal** (fig. 310) is a broad, radiating muscle, situated at the side of the head, and occupying the entire extent of the temporal fossa. It arises from the whole of the temporal fossa except that portion of it that is formed by the malar bone. Its attachment extends from the external angular process of the frontal in front, to the mastoid portion of the temporal behind; and from the curved line on the frontal and parietal bones above, to the pterygoid ridge on the great wing of the sphenoid below. It is also attached to the inner surface of the temporal fascia. Its fibres converge as they descend, and terminate in an aponeurosis, the fibres of which, radiated at its commencement, converge into a

thick and flat tendon, which is inserted into the inner surface, apex, and anterior border of the coronoid process of the jaw, nearly as far forwards as the last molar tooth.

**Relations.**—By its *superficial surface*, with the integument, the Attrahens and Attollens aurem muscles, the temporal vessels and nerves, the aponeurosis of the Occipito-frontalis, the temporal fascia, the zygoma, and Masseter. By its *deep surface*, with the temporal fossa, the External pterygoid and part of the Buccinator muscles, the internal maxillary artery, its deep temporal branches, and the deep temporal nerves. Behind the tendon are the masseteric vessels and nerve, and

FIG. 310.—The Temporal muscle, the zygoma and Masseter having been removed.



in front of it the buccal vessels and nerve. Its anterior border is separated from the malar bone by a mass of fat.

**Nerves.**—Both muscles are supplied by the inferior maxillary nerve.

## X. PTERYGO-MAXILLARY REGION (fig. 311)

### External Pterygoid.

### Internal Pterygoid.

**Dissection.**—The Temporal muscle having been examined, saw through the base of the coronoid process, and draw it upwards, together with the Temporal muscle, which should be detached from the surface of the temporal fossa. Divide the ramus of the jaw just below the condyle, and also, by a transverse incision extending across the middle, just above the dental foramen; remove the fragment of bone, and the Pterygoid muscles will be exposed.

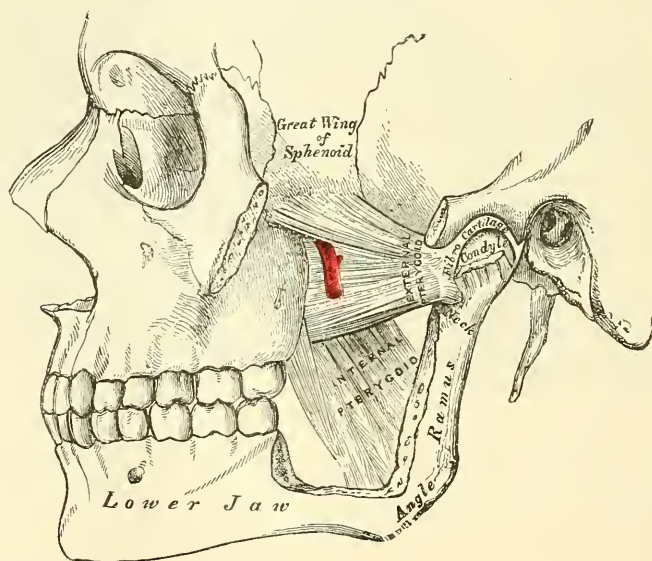
The **External pterygoid** is a short, thick muscle, somewhat conical in form, which extends almost horizontally between the zygomatic fossa and the condyle of the jaw. It arises by two heads, separated by a slight interval: the *upper* arises from the external surface of the greater wing of the sphenoid and from the pterygoid ridge, which separates the zygomatic from the temporal fossa; the *lower* from the outer surface of the external pterygoid plate. Its fibres pass horizontally backwards and outwards, to be inserted into a depression in front of the neck of the condyle of the lower jaw, and into the corresponding part of the interarticular fibro-cartilage.

**Relations.**—By its *external surface*, with the ramus of the lower jaw, the

internal maxillary artery, which crosses it,\* the tendon of the Temporal muscle and the Masseter. By its *internal surface*, it rests against the upper part of the Internal pterygoid, the internal lateral ligament, the middle meningeal artery, and inferior maxillary nerve; by its *upper border* it is in relation with the temporal and masseteric branches of the inferior maxillary nerve; by its lower border it is in relation with the inferior dental and gustatory nerves, and it is pierced by the buccal nerve. In the interval between the two portions of the muscle the internal maxillary artery passes, when this vessel lies on the muscle (see fig. 311).

The **Internal pterygoid** is a thick, quadrilateral muscle, and resembles the Masseter in form. It arises from the pterygoid fossa, being attached to the inner surface of the external pterygoid plate, and to the grooved surface of the tuberosity of the palate bone, and by a second slip from the outer surface of the tuberosities of the palate and superior maxillary bones; its fibres pass downwards, outwards, and backwards, to be inserted, by a strong tendinous lamina into

FIG. 311.—The Pterygoid muscles; the zygomatic arch and a portion of the ramus of the jaw having been removed.



the lower and back part of the inner side of the ramus and angle of the lower jaw, as high as the dental foramen.

**Relations.**—By its *external surface*, with the ramus of the lower jaw, from which it is separated, at its upper part, by the External pterygoid, the internal lateral ligament, the internal maxillary artery, the dental vessels and nerves, and the lingual nerve. By its *internal surface*, with the Tensor palati, being separated from the Superior constrictor of the pharynx by a cellular interval.

**Nerves.**—These muscles are supplied by the inferior maxillary nerve.

**Actions.**—The Temporal, Masseter and Internal pterygoid raise the lower jaw against the upper with great force. The superficial portion of the Masseter assists the External pterygoid in drawing the lower jaw forwards upon the upper; the jaw being drawn back again by the deep fibres of the Masseter, and posterior fibres of the Temporal. The External pterygoid muscles are the direct agents in the trituration of the food, drawing the lower jaw directly forwards, so as to make the lower teeth project beyond the upper. If the muscle of one side acts, the corresponding side of the jaw is drawn forwards, and the other condyle remain-

\* This is the usual relation, but in many cases the artery will be found below the muscle.



ing fixed, the symphysis deviates to the opposite side. The alternation of these movements on the two sides produces trituration.

*Surface Form.*—The outline of the muscles of the head and face cannot be traced on the surface of the body, except in the case of two of the masticatory muscles. Those of the head are thin, so that the outline of the bone is perceptible beneath them. Those in the face are small, covered by soft skin, and often by a considerable layer of fat, so that their outline is concealed; but they serve to round off and smooth prominent borders, and to fill up what would be otherwise unsightly angular depressions. Thus, the *Orbicularis palpebrarum* rounds off the prominent margin of the orbit, and the *Pyramidalis nasi* fills in the sharp depression beneath the glabella, and thus softens and tones down the abrupt depression which is seen on the unclothed bone. In like manner, the labial muscles, converging to the lips, and assisted by the superimposed fat, fill in the sunken hollow of the lower part of the face. Although the muscles of the face are usually described as arising from the bones, and inserted into the nose, lips, and corners of the mouth, they have fibres inserted into the skin of the face along their whole extent, so that almost every point of the skin of the face has its muscular fibre to move it; hence it is that when in action the facial muscles produce alterations in the skin-surface, giving rise to the formation of various folds or wrinkles, or otherwise altering the relative position of parts, so as to produce the varied expressions with which the face is endowed; hence these muscles are termed the ‘Muscles of expression.’ The only two muscles in this region which greatly influence surface-form are the *Masseter* and the *Temporal*. The *Masseter* is a quadrilateral muscle, which imparts fulness to the hinder part of the cheek. When the muscle is firmly contracted, as when the teeth are clenched, its outline is plainly visible; the anterior border forms a prominent vertical ridge, behind which is a considerable fulness, especially marked at the lower part of the muscle; this fulness is entirely lost when the mouth is opened, and the muscle no longer in a state of contraction. The *Temporal* muscle is fan-shaped, and fills the *Temporal fossa*, substituting for it a somewhat convex form, the anterior part of which, on account of the absence of hair over the temple, is more marked than the posterior, and stands out in strong relief when the muscle is in a state of contraction.

## MUSCLES AND FASCIÆ OF THE NECK

The muscles of the Neck may be arranged into groups, corresponding with the region in which they are situated.

These groups are nine in number :—

- |  |  |
|--|--|
| I. Superficial Region.                       | V. Muscles of the Pharynx.                     |
| II. Depressors of the Os Hyoides and Larynx. | VI. Muscles of the Soft Palate.                |
| III. Elevators of the Os Hyoides and Larynx. | VII. Muscles of the Anterior Vertebral Region. |
| IV. Muscles of the Tongue.                   | VIII. Muscles of the Lateral Vertebral Region. |
|  | IX. Muscles of the Larynx.                     |

The muscles contained in each of these groups are the following :—

### I. Superficial Region.

Platysma myoides.  
Sterno-cleido-mastoid.

### Infra-hyoid Region.

### II. Depressors of the Os hyoides and Larynx

Sterno-hyoid.  
Sterno-thyroid.  
Thyro-hyoid.  
Omo-hyoid.

### Supra-hyoid Region.

### III. Elevators of the Os hyoides and Larynx.

Digastric.  
Stylo-hyoid.

Mylo-hyoid.  
Genio-hyoid.

### Lingual Region.

### IV. Muscles of the Tongue.

Genio-hyo-glossus.  
Hyo-glossus.  
Lingualis.  
Stylo-glossus.  
Palato-glossus.

### V. Muscles of the Pharynx.

Constrictor inferior.  
Constrictor medius.  
Constrictor superior.  
Stylo-pharyngeus.  
Palato-pharyngeus.

VI. *Muscles of the Soft Palate.*

Levator palati.  
Tensor palati.  
Azygos uvulæ.  
Palato-glossus.  
Palato-pharyngeus.

Rectus lateralis.  
Longus colli.

VIII. *Muscles of the Lateral Vertebral Region.*

Scalenus anticus.  
Scalenus medius.  
Scalenus posticus.

VII. *Muscles of the Anterior Vertebral Region.*

Rectus capitis anticus major.  
Rectus capitis anticus minor.

IX. *Muscles of the Larynx.*

Included in the description of the Larynx.

## I. SUPERFICIAL CERVICAL REGION

Platysma myoides.

Sterno-cleido-mastoid.

*Dissection.*—A block having been placed at the back of the neck, and the face turned to the side opposite that to be dissected, so as to place the parts upon the stretch, make two transverse incisions: one from the chin, along the margin of the lower jaw, to the mastoid process; and the other along the upper border of the clavicle. Connect these by an oblique incision made in the course of the Sterno-mastoid muscle, from the mastoid process to the sternum; the two flaps of integument having been removed in the direction shown in fig. 305, the superficial fascia will be exposed.

The **Superficial cervical fascia** is a thin, aponeurotic lamina, which is hardly demonstrable as a separate membrane. Beneath it is found the *Platysma myoides* muscle.

The **Platysma myoides** (fig. 306) is a broad, thin plane of muscular fibres, placed immediately beneath the superficial fascia on each side of the neck. It arises by thin, fibrous bands from the fascia covering the upper part of the Pectoral and Deltoid muscles; its fibres proceed obliquely upwards and inwards along the side of the neck. The anterior fibres interlace, in front of the jaw, with the fibres of the muscle of the opposite side; the posterior fibres pass over the lower jaw, some of them being attached to the bone below the external oblique line, others passing on to be inserted into the skin and subcutaneous tissue of the lower part of the face, many of these fibres blending with the muscles about the angle and lower part of the mouth. Sometimes fibres can be traced to the Zygomatic muscles, or to the margin of the Orbicularis palpebrarum. Beneath the *Platysma*, the external jugular vein may be seen descending from the angle of the jaw to the clavicle.

*Surgical Anatomy.*—It is essential to remember the direction of the fibres of the *Platysma*, in connection with the operation of bleeding from the external jugular vein; for if the point of the lancet is introduced in the direction of the muscular fibres, the orifice made will be filled up by the contraction of the muscle, and blood will not flow; but if the incision is made across the course of the fibres, they will retract, and expose the orifice in the vein, and so allow the flow of blood.

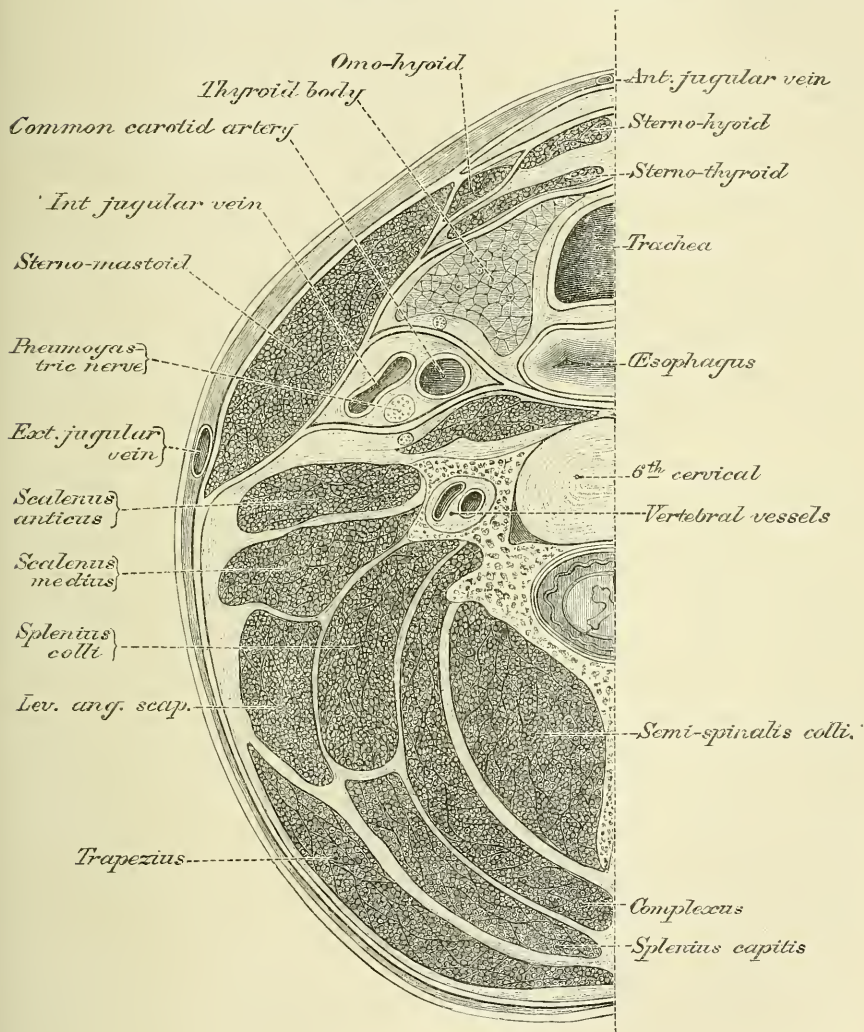
**Relations.**—By its *external surface*, with the integument, to which it is united more closely below than above. By its *internal surface*, with the Pectoralis major, Deltoid, and Trapezius, and with the clavicle. In the *neck*, with the external and anterior jugular veins, the deep cervical fascia, the superficial branches of the cervical plexus, the Sterno-mastoid, Sterno-hyoid, Omo-hyoid, and Digastric muscles. Behind the Sterno-mastoid muscle, it covers the Scaleni muscles and the nerves of the brachial plexus. On the *face*, it is in relation with the parotid gland, the facial artery and vein, and the Masseter and Buccinator muscles.

**Action.**—The *Platysma myoides* produces a slight wrinkling of the surface of the skin of the neck, in an oblique direction, when the entire muscle is brought

into action. Its anterior portion, the thickest part of the muscle, depresses the lower jaw; it also serves to draw down the lower lip and angle of the mouth on each side, being one of the chief agents in the expression of melancholy.

The **Deep cervical fascia** (fig. 312) is a strong, fibrous layer, which invests the muscles of the neck, and encloses the vessels and nerves. It commences, as an extremely thin layer, at the back part of the neck, where it is attached to the ligamentum nuchæ and to the spinous process of the seventh cervical vertebræ, and, passing forwards, invests the Trapezius muscle; from the anterior border

FIG. 312.—Section of the neck at about the level of the sixth cervical vertebra. Showing the arrangement of the deep cervical fascia.



of this muscle it forms a layer, which covers in the posterior triangle of the neck; and, passing forwards to the posterior border of the Sterno-mastoid muscle, divides into two layers, one of which passes in front, and the other behind, that muscle. The layer which passes in front of the muscle is continued forwards to the front of the neck, and blends with the fascia of the opposite side, covering the anterior triangle. It is joined on its under surface, except for about an inch below, by a lamella derived from the layer covering the posterior surface of the



Sterno-mastoid muscle. Where these two layers do not meet, a little space is left between them, as they both pass inwards to the middle line of the neck. This is *Burns's space*, and contains a little areolar tissue and fat, and occasionally a small lymphatic gland. If traced upwards the anterior layer of the cervical fascia is found to pass over the parotid gland and Masseter muscle, forming the *parotid* and *masseteric fascia*, and is attached to the lower border of the zygoma, and, more anteriorly, to the lower border of the body of the jaw; if traced downwards, it is seen to pass to the upper border of the clavicle and sternum, being pierced just above the former bone by the external jugular vein. In the middle line of the neck, the fascia is connected to the symphysis of the inferior maxilla, and, lower down, to the hyoid bone, between which points it is thin; below the hyoid bone it becomes thicker, and is attached below to the anterior margin of the upper border of the sternum. The layer of the deep cervical fascia which passes behind the Sterno-mastoid covers the anterior surface of the Scalenus anticus muscle. At the outer side of the carotid vessels it divides into two, one layer passing in front of the vessels, the other behind them. The layer which passes in front of the vessels again divides into three lamellæ. Of these, the anterior lamella, except for an inch below where it forms the posterior boundary of Burns's space, joins the layer of cervical fascia passing in front of the Sterno-mastoid, and with it passes to the middle line covering the anterior surface of the Depressor muscles of the hyoid bone. The portion of this lamella which invests the Omohyoid is continued downwards as a distinct process, which descends to be inserted into the sternum and cartilage of the first rib, and becomes connected with the Costo-coracoid membrane. The middle lamella passes behind the depressors of the hyoid bone and in front of the thyroid body to meet its fellow of the opposite side, in front of the trachea. At the root of the neck this middle lamella can be traced downwards into the thorax to become continuous with the fibrous layer of the pericardium. The posterior lamella passes on the inner side of the carotid vessels, and speedily joins the layer passing behind them, thus enclosing them in a sheath. The layer of cervical fascia which passes behind the carotid vessels, having been joined by the posterior of the three lamellæ from the layer of fascia passing in front of the vessels, is prolonged inwards, behind the pharynx and œsophagus, forming a sheath for the Prevertebral muscles, the *prevertebral fascia*. To the inner side of the carotid vessels, a special layer of fascia, derived from the prevertebral fascia, is continued inwards towards the middle line, closely covering the constrictor muscles: this is called the *pharyngeal fascia*, and between it and the prevertebral fascia is a space, the *retro-pharyngeal space*, filled in by a quantity of loose connective tissue. This space is continued downwards behind the œsophagus into the thorax, where it becomes continuous with the posterior mediastinum. Above, the pharyngeal fascia is prolonged forwards over the Superior constrictor of the pharynx to the pterygo-maxillary ligament (p. 399), where it becomes continuous with the fascia covering the Buccinator muscle. Finally, from the layer of the deep cervical fascia, which passes behind the Sterno-mastoid, is given off another lamella, which may be regarded as a prolongation of the prevertebral fascia; this passes downwards and outwards over the brachial plexus and subclavian vessels, to assist in forming the axillary sheath. The two layers of the deep cervical fascia, where they unite opposite the angle of the lower jaw, bind the Sterno-mastoid muscle to this part of the bone. From that portion of the cervical fascia which is attached to the angle of the jaw, a process of extreme density is found passing backwards to the inner side of the parotid gland, to be attached to the apex of the styloid process of the temporal bone; this is termed the *Stylo-maxillary ligament*.

*Surgical Anatomy.*—The cervical fascia is of considerable importance from a surgical point of view. As will be seen from the foregoing description, it may be divided into three layers: (1) A superficial layer; (2) a layer passing in front of the trachea, and

forming with the superficial layer a sheath for the depressors of the hyoid bone; (3) a prevertebral layer passing in front of the bodies of the cervical vertebræ, and forming with the second layer a space in which is contained the trachea, œsophagus, &c. The superficial layer forms a complete investment for the neck. It is attached behind to the ligamentum nuchæ and the spine of the seventh cervical vertebra; above it is attached to the external occipital protuberance, to the superior curved line of the occiput, to the mastoid process, to the zygoma and the lower jaw; below it is attached to the manubrium sterni, the clavicle, the acromion process, and the spine of the scapula; in front it blends with the fascia of the opposite side. This layer would oppose the extension of abscesses or new growths towards the surface, and pus forming beneath it would have a tendency to extend laterally. If it is in the posterior triangle, it might extend backwards under the Trapezius, forwards under the Sterno-mastoid, or downwards under the clavicle for some distance, until stopped by the junction of the cervical fascia to the Costo-coracoid membrane. If the pus is contained in the anterior triangle, it might find its way into the anterior mediastinum, being situated in front of the layer of fascia which passes down into the thorax to become continuous with the pericardium; but owing to the less density and thickness of the fascia in this situation it more frequently finds its way through it and points above the sternum. The second layer of fascia is connected above with the hyoid bone. It passes down beneath the depressors and in front of the thyroid body and trachea to become continuous with the fibrous layer of the pericardium. Laterally it invests the great vessels of the neck and is connected with the superficial layer beneath the sterno-mastoid. Pus forming beneath this layer would in all probability find its way into the posterior mediastinum. The third layer (the prevertebral fascia) is connected above to the base of the skull. Pus forming beneath this layer, in cases, for instance, of caries of the bodies of the cervical vertebræ, might extend towards the posterior and lateral part of the neck and point in this situation, or might perforate this layer of fascia and the pharyngeal fascia and point into the pharynx (post-pharyngeal abscess).

In cases of cut throat the cervical fascia is of considerable importance. In cases where the wound involves only the superficial layer the injury is usually trivial, the only special danger being injury to the external jugular vein, and the only special complication being diffuse cellulitis. But where the second of the two layers has been opened up, important structures may have been injured, which may lead to serious results.

It may be worth while mentioning that in Burns's space is contained the sternal head of origin of the Sterno-mastoid muscle, so that this space is opened in division of this tendon. The anterior jugular vein is also contained in the same space.

The **Sterno-mastoid** or **Sterno-cleido-mastoid** (fig. 313) is a large, thick muscle, which passes obliquely across the side of the neck, being enclosed between the two layers of the deep cervical fascia. It is thick and narrow at its central part, but is broader and thinner at each extremity. It arises, by two heads, from the sternum and clavicle. The *sternal portion* is a rounded fasciculus, tendinous in front, fleshy behind, which arises from the upper and anterior part of the first piece of the sternum, and is directed upwards, outwards, and backwards. The *clavicular portion* arises from the inner third of the superior border of the clavicle, being composed of fleshy and aponeurotic fibres; it is directed almost vertically upwards. These two portions are separated from one another, at their origin, by a triangular cellular interval; but become gradually blended, below the middle of the neck, into a thick, rounded muscle, which is inserted, by a strong tendon, into the outer surface of the mastoid process, from its apex to its superior border, and by a thin aponeurosis into the outer half of the superior curved line of the occipital bone. The Sterno-mastoid varies much in its extent of attachment to the clavicle: in one case the clavicular may be as narrow as the sternal portion; in another, as much as three inches in breadth. When the clavicular origin is broad, it is occasionally subdivided into numerous slips, separated by narrow intervals. More rarely, the corresponding margins of the Sterno-mastoid and Trapezius have been found in contact. In the application of a ligature to the third part of the subclavian artery, it will be necessary, where the muscles come close together, to divide a portion of one or of both.

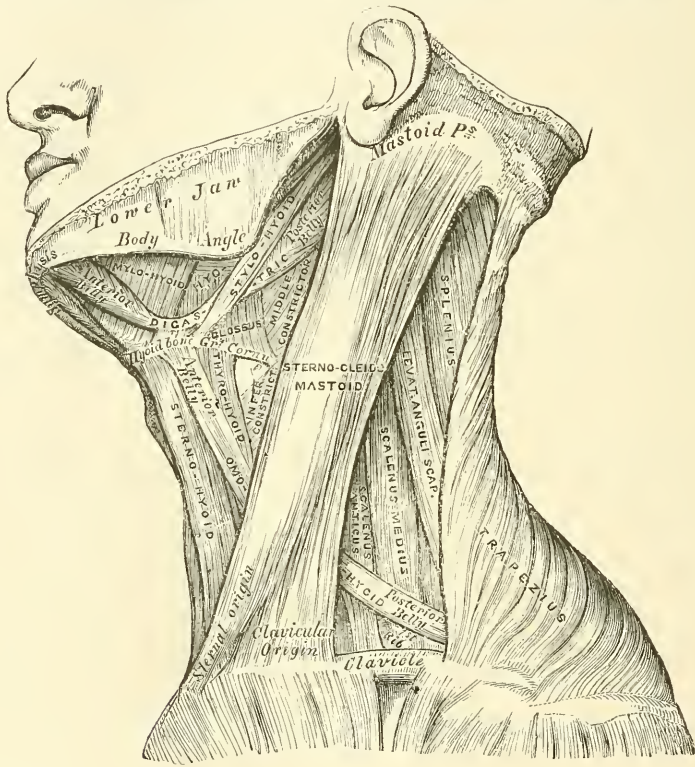
This muscle divides the quadrilateral space at the side of the neck into two triangles, an anterior and a posterior. The boundaries of the *anterior triangle* are, in front, the median line of the neck; above, the lower border of the body of the jaw, and an imaginary line drawn from the angle of the jaw to the mastoid process; behind, the anterior border of the Sterno-mastoid muscle. The boundaries of the *posterior triangle* are, in front, the posterior border of the



Sterno-mastoid; below, the upper border of the clavicle; behind, the anterior margin of the Trapezius.\*

**Relations.**—By its *superficial surface*, with the integument and Platysma, from which it is separated by the external jugular vein, the superficial branches of the cervical plexus, and the anterior layer of the deep cervical fascia. By its *deep surface*, it is in relation with the Sterno-clavicular articulation; a process of the deep cervical fascia; the Sterno-hyoid, Sterno-thyroid, Omo-hyoid, posterior belly of the Digastric, Levator anguli scapulae, Splenius and Scaleni muscles; common carotid artery, internal jugular vein, commencement of the internal and external carotid arteries, the occipital, subclavian, transversalis colli and supra-scapular arteries and veins; the pneumogastric, hypoglossal, descendens and communicans hypoglossi nerves and the spinal accessory nerve, which pierces

FIG. 313.—Muscles of the neck, and boundaries of the triangles.



its upper third; the cervical plexus, part of the parotid gland and deep lymphatic glands.

**Nerves.**—The Platysma myoides is supplied by the facial and superficial branches of the cervical plexus; the Sterno-cleido-mastoid by the spinal accessory and deep branches of the cervical plexus.

**Actions.**—When only one Sterno-mastoid muscle acts, it flexes the head and draws it towards the shoulder of the same side, assisted by the Splenius and the Obliquus capitis inferior of the opposite side. At the same time it rotates the head so as to carry the face towards the opposite side. When both muscles are brought into action, they serve to depress the head upon the neck, and the neck upon the chest. If the head is fixed, they assist in elevating the thorax in forced inspiration.

\* The anatomy of these triangles will be more exactly described with that of the vessels of the neck.



*Surface Form.*—The anterior edge of the muscle forms a very prominent ridge beneath the skin, which it is important to notice, as it forms a guide to the surgeon in making the necessary incisions for ligature of the common carotid artery, and for œsophagotomy.

*Surgical Anatomy.*—The relations of the sternal and clavicular parts of the Sternomastoid should be carefully examined, as the surgeon is sometimes required to divide one or both portions of the muscle in *wry-neck*. One variety of this distortion is produced by spasmodic contraction or rigidity of the Sternomastoid; the head being carried down towards the shoulder of the same side, and the face turned to the opposite side, and fixed in that position. When there is permanent shortening, subcutaneous division of the muscle is resorted to. This is performed by introducing a tenotomy knife beneath it, close to its origin, and dividing it from behind forwards whilst the muscle is put well upon the stretch. There is seldom any difficulty in dividing the sternal portion, by making a puncture on the inner side of the tendon, and then pushing a blunt tenotome behind it, and cutting forwards. In dividing the clavicular portion care must be taken to avoid wounding the external jugular vein, which runs parallel with the posterior border of the muscle in this situation, or the anterior jugular vein, which crosses beneath it. If the external jugular vein lies near the muscle, it is safer to make the first puncture at the outer side of the tendon, and introduce a blunt tenotome from without inwards. Many surgeons prefer dividing the muscle by the open method. An incision is made over either origin of the muscle, the tendon is exposed and a director is passed underneath it, and it is then divided. With care and attention to asepsis this plan of treatment is devoid of risk, and in this way the accidental division of the vessels can be avoided. Some of the fibres of the Sternomastoid muscle are occasionally torn during birth, especially in breech presentations; this is accompanied by hæmorrhage and formation of a swelling within the substance of the muscle. This by some is believed to be one of the causes of wry-neck.

## II. INFRA-HYOID REGION (figs. 313, 314)

### DEPRESSORS OF THE OS HYOIDES AND LARYNX

Sterno-hyoid.	Thyro-hyoid.
Sterno-thyroid.	Omo-hyoid.

*Dissection.*—The muscles in this region may be exposed by removing the deep fascia from the front of the neck. In order to see the entire extent of the Omo-hyoid, it is necessary to divide the Sternomastoid at its centre, and turn its ends aside, and to detach the Trapezius from the clavicle and scapula. This, however, should not be done until the Trapezius has been dissected.

The **Sterno-hyoid** is a thin, narrow, riband-like muscle, which arises from the inner extremity of the clavicle, the posterior sterno-clavicular ligament, and the upper and posterior part of the first piece of the sternum; passing upwards and inwards, it is inserted, by short, tendinous fibres, into the lower border of the body of the os hyoides. This muscle is separated, below, from its fellow by a considerable interval; but they approach one another in the middle of their course, and again diverge as they ascend. It sometimes presents, immediately above its origin, a transverse tendinous intersection, like those in the Rectus abdominis.

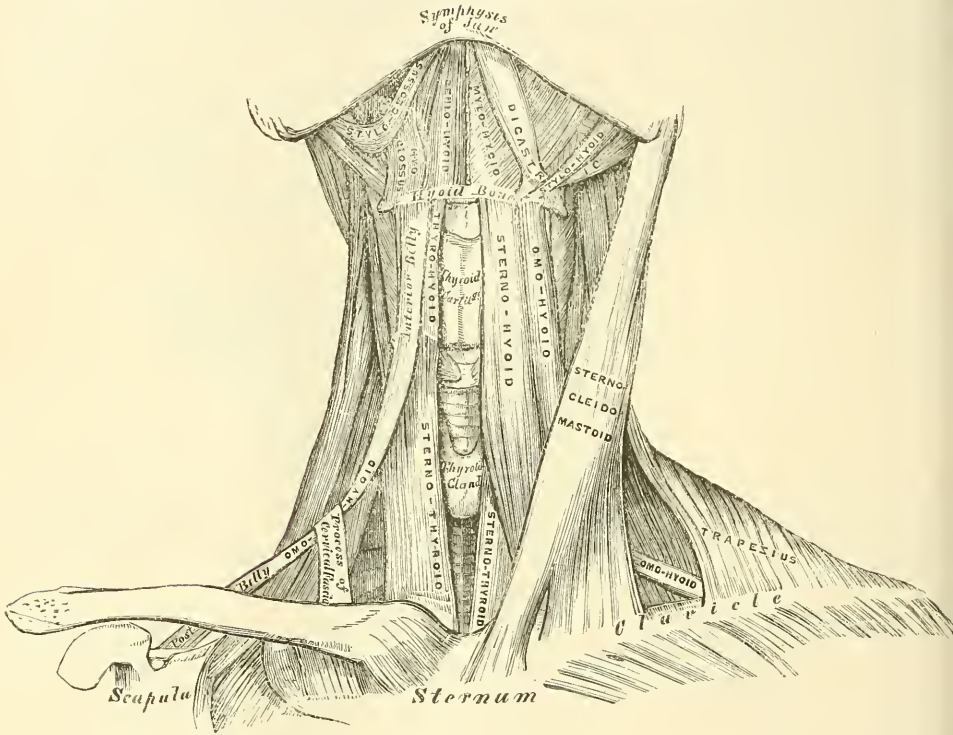
**Relations.**—By its *superficial surface*, below, with the sternum, the sternal end of the clavicle, and the Sternomastoid; and above, with the Platysma and deep cervical fascia. By its *deep surface*, with the Sterno-thyroid, Crico-thyroid, and Thyro-hyoid muscles, the thyroid gland, the superior thyroid vessels, the thyroid cartilage, the crico-thyroid and thyro-hyoid membranes.

The **Sterno-thyroid** is shorter and wider than the preceding muscle, beneath which it is situated. It arises from the posterior surface of the first bone of the sternum, below the origin of the Sternomastoid, and from the edge of the cartilage of the first rib, and occasionally of the second rib also; and is inserted into the oblique line on the side of the ala of the thyroid cartilage. This muscle is in close contact with its fellow at the lower part of the neck; and is occasionally traversed by a transverse or oblique tendinous intersection like those in the Rectus abdominis.

**Relations.**—By its *anterior surface*, with the Sterno-hyoid, Omo-hyoid, and Sterno-mastoid. By its *posterior surface*, from below upwards, with the trachea, vena innominata, common carotid (and on the right side the arteria innominata), the thyroid gland and its vessels, and the lower part of the larynx. The middle thyroid vein lies along its inner border, a relation which it is important to remember in the operation of tracheotomy.

The **Thyro-hyoid** is a small, quadrilateral muscle appearing like a continuation of the Sterno-thyroid. It arises from the oblique line on the side of the thyroid cartilage, and passes vertically upwards to be inserted into the lower border of the body and greater cornu of the hyoid bone.

FIG. 314.—Muscles of the neck. Anterior view.



**Relations.**—By its *external surface*, with the Sterno-hyoid and Omo-hyoid muscles. By its *internal surface*, with the thyro-hyoid membrane, and the superior laryngeal vessels and nerve.

The **Omo-hyoid** passes across the side of the neck, from the scapula to the hyoid bone. It consists of two fleshy bellies, united by a central tendon. It arises from the upper border of the scapula, and occasionally from the transverse ligament which crosses the suprascapular notch; its extent of attachment to the scapula varying from a few lines to an inch. From this origin, the posterior belly forms a flat, narrow fasciculus, which inclines forwards and slightly upwards across the lower part of the neck, behind the Sterno-mastoid muscle, where it becomes tendinous; it then changes its direction, forming an obtuse angle, and terminates in the anterior belly, which passes almost vertically upwards, close to the outer border of the Sterno-hyoid, to be inserted into the lower border of the body of the os hyoides, just external to the insertion of the Sterno-hyoid. The central tendon of this muscle, which varies much in length and form, is held in position by a process of the deep cervical fascia, which includes it in a sheath. This process is prolonged down, to be attached to the cartilage of the first rib.

and the sternum. It is by this means that the angular form of the muscle is maintained.

This muscle subdivides each of the two large triangles at the side of the neck into two smaller triangles; the two posterior ones being the *posterior superior* or *occipital*, and the *posterior inferior* or *subclavian*; the two anterior, the *anterior superior* or *superior carotid*, and the *anterior inferior* or *inferior carotid triangle*.

**Relations.**—By its *superficial surface*, with the Trapezius, the Sternomastoid, deep cervical fascia, Platysma, and integument. By its *deep surface*, with the Scaleni muscles, phrenic nerve, lower cervical nerves, which go to form the brachial plexus, the suprascapular vessels and nerve, sheath of the common carotid artery and internal jugular vein, the Sterno-thyroid and Thyro-hyoid muscles.

**Nerves.**—The Thyro-hyoid is supplied by the hypoglossal; the other muscles of this group by branches from the loop of communication between the descendens and communicans hypoglossi.

**Actions.**—These muscles depress the larynx and hyoid bone, after they have been drawn up with the pharynx in the act of deglutition. The Omo-hyoid muscles not only depress the hyoid bone, but carry it backwards, and to one or the other side. It is concerned especially in prolonged inspiratory efforts; for by tensing the lower part of the cervical fascia it lessens the inward suction of the soft parts, which would otherwise compress the great vessels and the apices of the lungs. The Thyro-hyoid may act as an elevator of the thyroid cartilage, when the hyoid bone ascends, drawing upwards the thyroid cartilage, behind the os hyoides.\* The Sterno-thyroid acts as a depressor of the thyroid cartilage.

### III. SUPRA-HYOID REGION (figs. 313, 314)

#### ELEVATORS OF THE OS HYOIDES—DEPRESSORS OF THE LOWER JAW

Digastric.  
Stylo-hyoid.

Mylo-hyoid.  
Genio-hyoid.

*Dissection.*—To dissect these muscles, a block should be placed beneath the back of the neck, and the head drawn backwards, and retained in that position. On the removal of the deep fascia, the muscles are at once exposed.

The **Digastric** consists of two fleshy bellies united by an intermediate, rounded tendon. It is a small muscle, situated below the side of the body of the lower jaw, and extending, in a curved form, from the side of the head to the symphysis of the jaw. The *posterior belly*, longer than the anterior, arises from the digastric groove on the inner side of the mastoid process of the temporal bone, and passes downwards, forwards, and inwards. The *anterior belly* arises from a depression on the inner side of the lower border of the jaw, close to the symphysis, and passes downwards and backwards. The two bellies terminate in the central tendon which perforates the Stylo-hyoid, and is held in connection with the side of the body and the greater cornu of the hyoid bone by a fibrous loop, lined by a synovial membrane. A broad aponeurotic layer is given off from the tendon of the Digastric on each side, which is attached to the body and great cornu of the hyoid bone; this is termed the *supra-hyoid aponeurosis*. It forms a strong layer of fascia between the anterior portion of the two muscles, and a firm investment for the other muscles of the supra-hyoid region which lie deeper.

The Digastric muscle divides the anterior superior triangle of the neck into two smaller triangles; the upper, or *submaxillary*, being bounded, above, by the

\* It is this action of the Thyro-hyoid muscle which, as Dr. Buchanan has pointed out, 'causes or permits the folding back of the epiglottis over the upper orifice of the larynx.' *Journ. of Anat. and Phys.* 2nd series. No. III. p. 255.



lower border of the body of the jaw, and a line drawn from its angle to the mastoid process; below, by the posterior belly of the Digastric and the Stylo-hyoid muscles; in front, by the middle line of the neck, and anterior belly of the Digastric: the lower or *superior carotid triangle* being bounded above by the posterior belly of the Digastric, behind by the Sterno-mastoid, below by the Omo-hyoid.

**Relations.**—By its *superficial surface*, with the Platysma, Sterno-mastoid, part of the Splenius, Trachelo-mastoid, and Stylo-hyoid muscles, and the parotid gland. By its *deep surface*, the anterior belly lies on the Mylo-hyoid; the posterior belly on the Stylo-glossus, Stylo-pharyngeus, and Hyo-glossus muscles, the external carotid artery and its lingual and facial branches, the internal carotid artery, internal jugular vein, and hypoglossal nerve.

The **Stylo-hyoid** is a small, slender muscle, lying in front of, and above, the posterior belly of the Digastric. It arises from the back and outer surface of the styloid process, near the base; and, passing downwards and forwards, is inserted into the body of the hyoid bone, just at its junction with the greater cornu, and immediately above the Omo-hyoid. This muscle is perforated, near its insertion, by the tendon of the Digastric.

**Relations.**—By its *superficial surface*, above with the parotid gland and deep cervical fascia; below it is superficial, being situated immediately beneath the deep cervical fascia. By its *deep surface*, with the posterior belly of the Digastric, the external carotid artery, with its lingual and facial branches and the Hyo-glossus muscle.

**The Stylo-hyoid ligament.**—In connection with the Stylo-hyoid muscle may be described a ligamentous band, the *Stylo-hyoid ligament*. It is a fibrous cord, often containing a little cartilage in its centre, which continues the styloid process down to the hyoid bone, being attached to the tip of the former and the small cornu of the latter. It is often more or less ossified, and in many animals forms a distinct bone, the *epihyal*.

The Digastric and Stylo-hyoid should be removed, in order to expose the next muscle.

The **Mylo-hyoid** is a flat, triangular muscle, situated immediately beneath the anterior belly of the Digastric, and forming, with its fellow of the opposite side, a muscular floor for the cavity of the mouth. It arises from the whole length of the mylo-hyoid ridge, extending from the symphysis in front to the last molar tooth behind. The posterior fibres pass inwards and slightly downwards, to be inserted into the body of the os hyoides. The middle and anterior fibres are inserted into a median fibrous raphé, extending from the symphysis of the lower jaw to the hyoid bone, where they join at an angle with the fibres of the opposite muscle. This median raphé is sometimes wanting; the muscular fibres of the two sides are then directly continuous with one another.

**Relations.**—By its *cutaneous or under surface*, with the Platysma, the anterior belly of the Digastric, the supra-hyoid aponeurosis, the submaxillary gland, submental vessels, and mylo-hyoid vessels and nerve. By its *deep or superior surface*, with the Genio-hyoid, part of the Hyo-glossus, and Stylo-glossus muscles, the hypo-glossal and lingual nerves, the submaxillary ganglion, the sublingual gland, the deep portion of the submaxillary gland and Wharton's duct; the sublingual and ranine vessels, and the buccal mucous membrane.

**Dissection.**—The Mylo-hyoid should now be removed, in order to expose the muscles which lie beneath; this is effected by detaching it from its attachments to the hyoid bone and jaw, and separating it by a vertical incision from its fellow of the opposite side.

The **Genio-hyoid** is a narrow, slender muscle, situated immediately beneath\* the inner border of the preceding. It arises from the inferior genial tubercle on the inner side of the symphysis of the jaw, and passes downwards and backwards,

\* This refers to the depth of the muscles from the skin in the order of dissection. In the erect position of the body each of these muscles lies above the preceding.

to be inserted into the anterior surface of the body of the os hyoides. This muscle lies in close contact with its fellow of the opposite side, and increases slightly in breadth as it descends.

**Relations.**—It is covered by the Mylo-hyoid, and lies on the Genio-hyo-glossus.

**Nerves.**—The Digastric is supplied: its anterior belly, by the mylo-hyoid branch of the inferior dental; its posterior belly, by the facial; the Stylo-hyoid, by the facial; the Mylo-hyoid, by the mylo-hyoid branch of the inferior dental; the Genio-hyoid, by the hypoglossal.

**Actions.**—This group of muscles performs two very important actions. They raise the hyoid bone, and with it the base of the tongue, during the act of deglutition; or, when the hyoid bone is fixed by its depressors and those of the larynx, they depress the lower jaw. During the first act of deglutition, when the mass is being driven from the mouth into the pharynx, the hyoid bone, and with it the tongue, is carried upwards and forwards by the anterior belly of the Digastric, the Mylo-hyoid, and Genio-hyoid muscles. In the second act, when the mass is passing through the pharynx, the direct elevation of the hyoid bone takes place by the combined action of all the muscles; and after the food has passed, the hyoid bone is carried upwards and backwards by the posterior belly of the Digastric and Stylo-hyoid muscles, which assist in preventing the return of the morsel into the mouth.

#### IV. LINGUAL REGION

Genio-hyo-glossus.

Stylo-glossus.

Hyo-glossus.

Palato-glossus.

Chondro-glossus.

**Dissection.**—After completing the dissection of the preceding muscles, saw through the lower jaw just external to the symphysis. Then draw the tongue forwards, and attach it, by a stitch, to the nose; when its muscles, which are thus put on the stretch, may be examined.

The **Genio-hyo-glossus** has received its name from its triple attachment to the jaw, hyoid bone, and tongue, but it would be better named the *Genio-glossus*, since its attachment to the hyoid bone is very slight or altogether absent. It is a flat, triangular muscle, placed vertically on either side of the middle line, its apex corresponding with its point of attachment to the lower jaw, its base with its insertion into the tongue and hyoid bone. It arises by a short tendon from the superior genial tubercle on the inner side of the symphysis of the jaw, immediately above the Genio-hyoid; from this point the muscle spreads out in a fan-like form, a few of the inferior fibres passing downwards, to be attached by a thin aponeurosis into the upper part of the body of the hyoid bone, a few fibres passing between the Hyo-glossus and Chondro-glossus to blend with the constrictor muscles of the pharynx; the middle fibres passing backwards, and the superior ones upwards and forwards, to enter the whole length of the under surface of the tongue, from the base to the apex. The two muscles lie on either side of the median plane; behind, they are quite distinct from each other, and are separated at their insertion into the under surface of the tongue by a tendinous raphé, which extends through the middle of the organ; in front, the two muscles are more or less blended: distinct fasciculi are to be seen passing off from one muscle, crossing the middle line, and intersecting with bundles of fibres derived from the muscle on the other side (fig. 316).

**Relations.**—By its *internal surface* it is in contact with its fellow of the opposite side. By its *external surface*, with the Inferior lingualis, the Hyo-glossus, the lingual artery and hypoglossal nerve, the lingual nerve, and sublingual gland. By its *upper border*, with the mucous membrane of the floor of the mouth (frænum linguæ). By its *lower border*, with the Genio-hyoid.

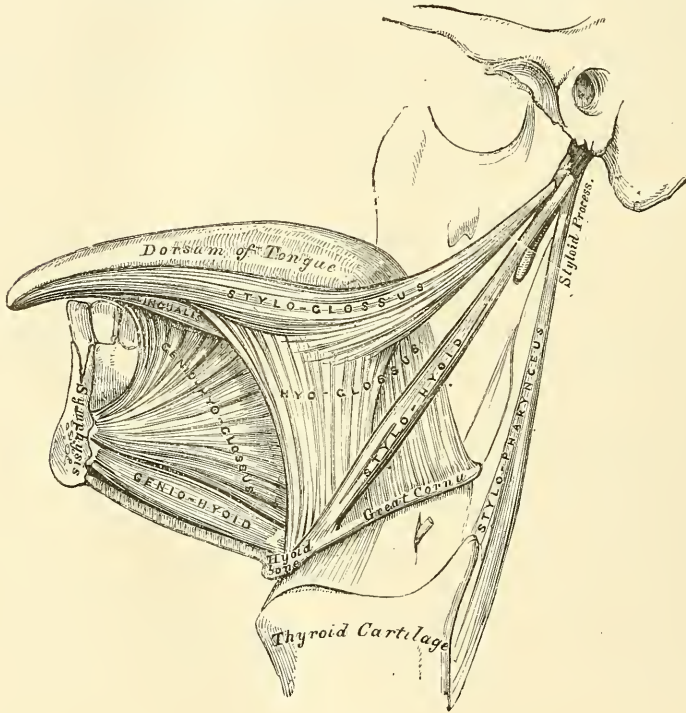
The **Hyo-glossus** is a thin, flat, quadrilateral muscle, which arises from the

side of the body, and whole length of the greater cornu of the hyoid bone, and passes almost vertically upwards to enter the side of the tongue, between the Stylo-glossus and Lingualis. Those fibres of this muscle which arise from the body are directed upwards and backwards, overlapping those arising from the greater cornu, which are directed upwards and forwards.

**Relations.**—By its *external surface*, with the Digastric, the Stylo-hyoid, Stylo-glossus, and Mylo-hyoid muscles, the submaxillary ganglion, the lingual and hypoglossal nerves, Wharton's duct, and the deep portion of the submaxillary gland. By its *deep surface*, with the Stylo-hyoid ligament, the Genio-hyo-glossus, Lingualis, and Middle constrictor, the lingual vessels, and the glosso-pharyngeal nerve.

The **Chondro-glossus** is a distinct muscular slip, though it is sometimes described as a part of the Hyo-glossus, from which, however, it is separated by

FIG. 315.—Muscles of the tongue. Left side.



the fibres of the Genio-hyo-glossus, which pass to the side of the pharynx. It is about three-quarters to an inch in length, and arises from the inner side and base of the lesser cornu and contiguous portion of the body of the hyoid bone, and passes directly upwards to blend with the intrinsic muscular fibres of the tongue, between the Hyo-glossus and Genio-hyo-glossus. A small slip of muscular fibre is occasionally found, arising from the cartilago triticea in the thyro-hyoid ligament, and passing upwards and forwards to enter the tongue with the hindermost fibres of the Hyo-glossus.

The **Stylo-glossus**, the shortest and smallest of the three styloid muscles, arises from the anterior and outer side of the styloid process, near its apex, and from the stylo-maxillary ligament, to which its fibres, in most cases, are attached by a thin aponeurosis. Passing downwards and forwards between the internal and external carotid arteries, and becoming nearly horizontal in its direction, it divides upon the side of the tongue into two portions: one longitudinal, which enters the side of the tongue near its dorsal surface, blending with the fibres of the Lingualis in



front of the Hyo-glossus; the other oblique which overlaps the Hyo-glossus muscle and decussates with its fibres.

**Relations.**—By its *external surface*, from above downwards, with the parotid gland, the Internal pterygoid muscle, the lingual nerve, and the mucous membrane of the mouth. By its *internal surface*, with the tonsil, the Superior constrictor, and the Hyo-glossus muscle.

The **Palato-glossus**, or **Constrictor isthmi faucium**, although it is one of the muscles of the tongue, serving to draw its base upwards during the act of deglutition, is more nearly associated with the soft palate, both in its situation and function; it will, consequently, be described with that group of muscles.

**Nerves.**—The Palato-glossus is probably innervated by the spinal accessory nerve, through the pharyngeal plexus; the remaining muscles of this group by the hypoglossal.

**Muscular substance of tongue.**—The muscular fibres of the tongue run in various directions. These fibres are divided into two sets—Extrinsic and

FIG. 316.—Muscles of the tongue from below.  
From a preparation in the Museum of the  
Royal College of Surgeons of England.

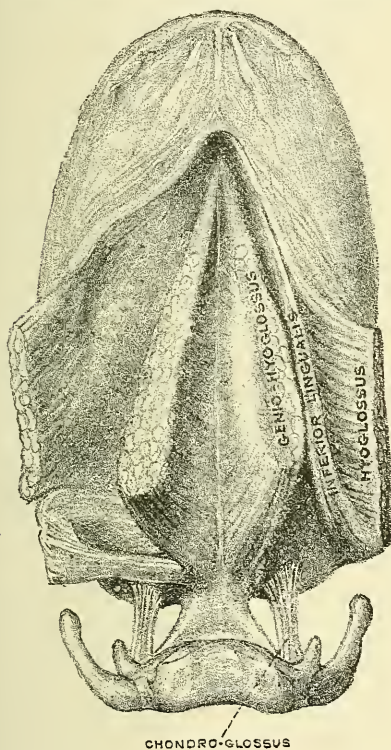
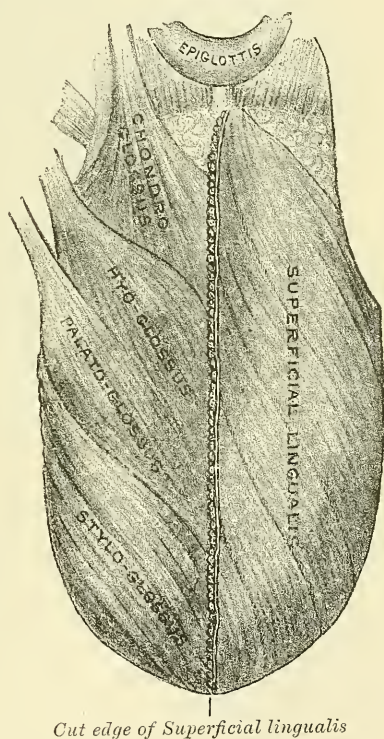


FIG. 317.—Muscles on the dorsum  
of the tongue.



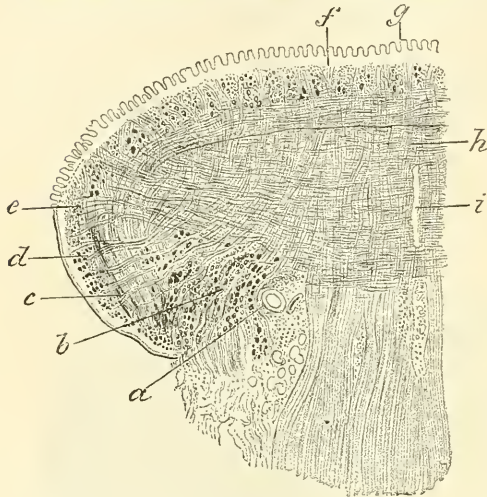
Intrinsic. The extrinsic muscles of the tongue are those which have their origin external and only their terminal fibres contained in the substance of the organ. They are: the Stylo-glossus, the Hyo-glossus, the Palato-glossus, the Genio-hyo-glossus, and part of the Superior constrictor of the pharynx (Pharyngeo-glossus). The intrinsic are those which are contained entirely within the tongue, and form the greater part of its muscular structure.

The tongue consists of symmetrical halves separated from each other in the middle line by a fibrous septum. Each half is composed of muscular fibres arranged in various directions, containing much interposed fat, and supplied by vessels and nerves.

To demonstrate the various fibres of the tongue, the organ should be subjected

to prolonged boiling, in order to soften the connective tissue; the dissection may then be commenced from the dorsum (fig. 317). Immediately beneath the mucous membrane is a submucous, fibrous layer, into which the muscular fibres which terminate on the surface of the tongue are inserted. Upon removing this, with the mucous membrane, the first stratum of muscular fibres is exposed. This belongs to the group of intrinsic muscles, and has been named the *Superior lingualis*. It consists of a thin layer of oblique and longitudinal fibres, which arise from the submucous fibrous layer, close to the Epiglottis, and from the fibrous septum, and pass forwards and outwards to the edges of the tongue. Between its fibres pass some vertical fibres derived from the Genio-hyo-glossus and from the vertical intrinsic muscle, which will be described later on. Beneath

FIG. 318.—Coronal section of tongue. Showing intrinsic muscles. (Altered from Krause.)



a, lingual artery; b, inferior lingualis, cut through; c, fibres of Hyo-glossus; d, oblique fibres of Stylo-glossus; e, insertion of Transverse lingualis; f, Superior lingualis; g, papille of tongue; h, vertical fibres of Genio-hyo-glossus intersecting Transverse lingualis; i, septum.

this layer is the second stratum of muscular fibres, derived principally from the extrinsic muscles. In front, it is formed by the fibres derived from the Stylo-glossus, running along the side of the tongue, and sending one set of fibres over the dorsum which runs obliquely forwards and inwards to the middle line, and another set of fibres, seen at a later period of the dissection, on to the under surface of the sides of the anterior part of the tongue, which runs forwards and inwards, between the fibres of the Hyo-glossus, to the middle line. Behind this layer of fibres, derived from the Stylo-glossus, are fibres derived from the Hyo-glossus, assisted by some few fibres of the Palato-glossus. The Hyo-glossus, entering the side of the under surface of the tongue, between the Stylo-glossus and Inferior lingualis, passes round its margin and spreads out into a layer on the dorsum, which occupies the middle third of the organ, and runs almost transversely inwards to the septum. It is reinforced by some fibres from the Palato-glossus; other fibres of this muscle pass more deeply and intermingle with the next layer. The posterior part of the second layer of the muscular fibres of the tongue is derived from those fibres of the Hyo-glossus which arise from the lesser cornu of the hyoid bone, and are here described as a separate muscle—the Chondro-glossus. The fibres of this muscle are arranged in a fan-shaped manner, and spread out over the posterior third of the tongue. Beneath this layer is the great mass of the intrinsic muscles of the tongue, intersected at right angles by the terminal fibres of one of the extrinsic muscles—the Genio-hyo-glossus. This portion of the tongue is paler in colour and softer in texture than that already described, and is sometimes designated the medullary portion in contradistinction to the firmer superficial part, which is termed the cortical portion. It consists largely of transverse fibres, the *Transverse lingualis*, and of vertical fibres, the *Vertical lingualis*. The Transverse lingualis forms the largest portion of the third layer of muscular fibres of the tongue. The fibres arise from the median septum, and pass outwards to be inserted into the submucous fibrous layer at the sides of the tongue. Intermingled with these transverse intrinsic fibres are transverse extrinsic fibres derived from the Palato-glossus and the Superior constrictor of the pharynx. These transverse extrinsic fibres, however, run in the opposite direction, passing inwards towards



the septum. Intersecting the transverse fibres are a large number of vertical fibres derived partly from the Genio-hyo-glossus and partly from intrinsic fibres, the *Vertical lingualis*. The fibres derived from the Genio-hyo-glossus enter the under surface of the tongue on each side of the median septum from base to apex. They ascend in a radiating manner to the dorsum, being inserted into the sub-mucous fibrous layer covering the tongue on each side of the middle line. The *Vertical lingualis* is found only at the borders of the fore part of the tongue, external to the fibres of the Genio-hyo-glossus. Its fibres extend from the upper to the under surface of the organ, decussating with the fibres of the other muscles, and especially with the *Transverse lingualis*. The fourth layer of muscular fibres of the tongue consists partly of extrinsic fibres derived from the Stylo-glossus, and partly of intrinsic fibres, the *Inferior lingualis*. At the sides of the under surface of the organ are some fibres derived from the Stylo-glossus, which, as it runs forwards at the side of the tongue, gives off fibres which, passing forwards and inwards between the fibres of the Hyo-glossus, form an inferior oblique stratum which joins in front with the anterior fibres of the *Inferior lingualis*. The *Inferior lingualis* is a longitudinal band, situated on the under surface of the tongue, and extending from the base to the apex of the organ. Behind, some of its fibres are connected with the body of the hyoid bone. It lies between the Hyo-glossus and the Genio-hyo-glossus, and in front of the Hyo-glossus it gets into relation with the Stylo-glossus, with the fibres of which it blends. It is in relation by its under surface with the ranine artery.

*Surgical Anatomy.*—The fibrous septum which exists between the two halves of the tongue is very complete, so that the anastomosis between the two lingual arteries is not very free, a fact often illustrated by injecting one-half of the tongue with coloured size, while the other half is left uninjected, or is injected with size of a different colour.

This is a point of considerable importance in connection with removal of one-half of the tongue for cancer, an operation which is now frequently resorted to when the disease is strictly confined to one side of the tongue. If the mucous membrane is divided longitudinally exactly in the middle line, the tongue can be split into halves along the median raphé, without any appreciable hæmorrhage, and the diseased half can then be removed.

**Actions.**—The movements of the tongue, although numerous and complicated, may be understood by carefully considering the direction of the fibres of its muscles. The *Genio-hyo-glossi* muscles, by means of their posterior fibres, draw the base of the tongue forwards, so as to protrude the apex from the mouth. The anterior fibres draw the tongue back into the mouth. The whole length of these two muscles acting along the middle line of the tongue draw it downwards, so as to make it concave from side to side, forming a channel along which fluids may pass towards the pharynx, as in sucking. The *Hyo-glossi* muscles depress the tongue, and draw down its sides, so as to render it convex from side to side. The *Stylo-glossi* muscles draw the tongue upwards and backwards. The *Palato-glossi* muscles draw the base of the tongue upwards. With regard to the intrinsic muscles, both the Superior and Inferior linguales tend to shorten the tongue, but the former, in addition, turn the tip and sides upwards so as to render the dorsum concave, while the latter pull the tip downwards and cause the dorsum to become convex. The *Transverse lingualis* narrows and elongates the tongue, and the *Vertical lingualis* flattens and broadens it. The complex arrangement of the muscular fibres of the tongue, and the various directions in which they run, give to this organ the power of assuming the various forms necessary for the enunciation of the different consonantal sounds; and Dr. Macalister states ‘there is reason to believe that the musculature of the tongue varies in different races owing to the hereditary practice and habitual use of certain motions required for enunciating the several vernacular languages.’



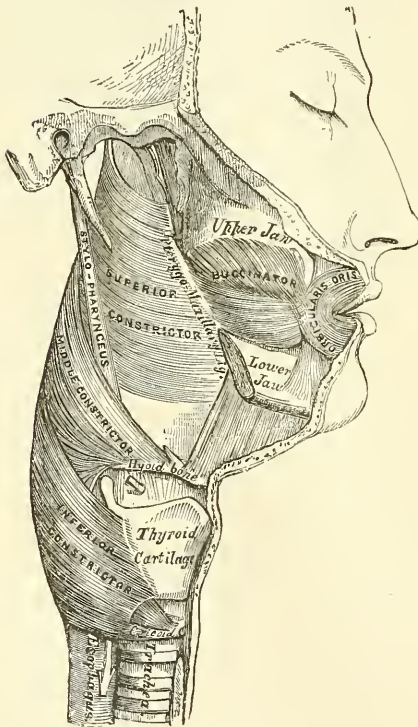
## V. PHARYNGEAL REGION

Inferior constrictor.	Superior constrictor.
Middle constrictor.	Stylo-pharyngeus.
Palato-pharyngeus.	} (See next section.)
Salpingo-pharyngeus.	

*Dissection* (fig. 319).—In order to examine the muscles of the pharynx, cut through the trachea and œsophagus just above the sternum, and draw them upwards by dividing the loose areolar tissue connecting the pharynx with the front of the vertebral column. The parts being drawn well forwards, apply the edge of the saw immediately behind the styloid processes, and saw the base of the skull through from below upwards. The pharynx and mouth should then be stuffed with tow, in order to distend its cavity and render the muscles tense and easier of dissection.

The **Inferior constrictor**, the most superficial and thickest of the three constrictors, arises from the sides of the cricoid and thyroid cartilages. To the cricoid cartilage it is attached in the interval between the Crico-thyroid muscle in

FIG. 319.—Muscles of the pharynx.  
External view.



front, and the articular facet for the thyroid cartilage behind. To the thyroid cartilage it is attached to the oblique line on the side of the great ala, to the cartilaginous surface behind it, nearly as far as its posterior border, and to the inferior cornu. From these attachments the fibres spread backwards and inwards, to be inserted into the fibrous raphé in the posterior median line of the pharynx. The inferior fibres are horizontal, and continuous with the fibres of the œsophagus; the rest ascend, increasing in obliquity, and overlap the Middle constrictor.

**Relations.**—It is covered by a dense cellular membrane which surrounds the entire pharynx (pharyngeal fascia). *Behind*, it is in relation with the vertebral column and the prevertebral muscles; *laterally*, with the thyroid gland, the common carotid artery, and the Sterno-thyroid muscle; by its *internal surface*, with the Middle constrictor, the Stylo-pharyngeus, Palato-pharyngeus, the fibrous coat and mucous membrane of the pharynx. The

superior laryngeal nerve and artery pass near the upper border, and the inferior, or recurrent laryngeal, beneath the lower border of this muscle, previous to their entering the larynx.

The **Middle constrictor** is a flattened, fan-shaped muscle, smaller than the preceding. It arises from the whole length of the upper border of the greater cornu of the hyoid bone, from the lesser cornu, and from the stylo-hyoid ligament. The fibres diverge from their origin: the lower ones descending beneath the Inferior constrictor, the middle fibres passing transversely, and the upper fibres ascending and overlapping the Superior constrictor. The muscle is inserted into

the posterior median fibrous raphé, blending in the middle line with the one of the opposite side.

**Relations.**—This muscle is separated from the Superior constrictor by the glosso-pharyngeal nerve and the Stylo-pharyngeus muscle; and from the Inferior constrictor by the superior laryngeal nerve. *Behind*, it lies on the vertebral column, the Longus colli, and the Rectus capitis anticus major. *On each side* it is in relation with the carotid vessels, the pharyngeal plexus, and some lymphatic glands. Near its origin it is covered by the Hyo-glossus, from which it is separated by the lingual vessels. It lies upon the Superior constrictor, the Stylo-pharyngeus, the Palato-pharyngeus, the fibrous coat, and the mucous membrane of the pharynx.

The **Superior constrictor** is a quadrilateral muscle, thinner and paler than the other constrictors, and situated at the upper part of the pharynx. It arises from the lower third of the posterior margin of the internal pterygoid plate and its hamular process, from the contiguous portion of the palate bone and the reflected tendon of the Tensor palati muscle, from the pterygo-maxillary ligament, from the alveolar process above the posterior extremity of the mylo-hyoid ridge, and by a few fibres from the side of the tongue. From these points the fibres curve backwards, to be inserted into the median raphé, being also prolonged by means of a fibrous aponeurosis to the pharyngeal spine on the basilar process of the occipital bone. The superior fibres arch beneath the Levator palati and the Eustachian tube, the interval between the upper border of the muscle and the basilar process being deficient in muscular fibres, and closed by fibrous membrane. This interval is known as the *sinus of Morgagni*.

**Relations.**—By its *outer surface*, with the vertebral column, the internal carotid artery, the internal jugular vein, the glosso-pharyngeal, pneumogastric, spinal accessory, hypoglossal, and sympathetic nerves, the Middle constrictor which overlaps it, and the Stylo-pharyngeus. By its *internal surface*, with the Palato-pharyngeus, the tonsil, the fibrous coat and mucous membrane of the pharynx.

The **Stylo-pharyngeus** is a long, slender muscle, round above, broad and thin below. It arises from the inner side of the base of the styloid process, passes downwards along the side of the pharynx between the Superior and Middle constrictors, and spreads out beneath the mucous membrane, where some of its fibres are lost in the Constrictor muscles; and others, joining with the Palato-pharyngeus, are inserted into the posterior border of the thyroid cartilage. The glosso-pharyngeal nerve runs on the outer side of this muscle, and crosses over it in passing forward to the tongue.

**Relations.**—*Externally*, with the Stylo-glossus muscle, the parotid gland, the external carotid artery, and the Middle constrictor. *Internally*, with the internal carotid, the internal jugular vein, the Superior constrictor, Palato-pharyngeus and mucous membrane.

**Nerves.**—The Constrictors are supplied by branches from the pharyngeal plexus, the Stylo-pharyngeus by the glosso-pharyngeal nerve, and the Inferior constrictor by additional branches from the external and recurrent laryngeal nerves.

**Actions.**—When deglutition is about to be performed, the pharynx is drawn upwards and dilated in different directions, to receive the morsel propelled into it from the mouth. The Stylo-pharyngei, which are much farther removed from one another at their origin than at their insertion, draw the sides of the pharynx upwards and outwards, and so increase its transverse diameter; its breadth in the antero-posterior direction being increased by the larynx and tongue being carried forwards in their ascent. As soon as the morsel is received in the pharynx, the Elevator muscles relax, the bag descends, and the Constrictors contract upon the morsel, and convey it gradually downwards into the œsophagus. Besides its action in deglutition, the pharynx also exerts an important influence in the modulation of the voice, especially in the production of the higher tones.



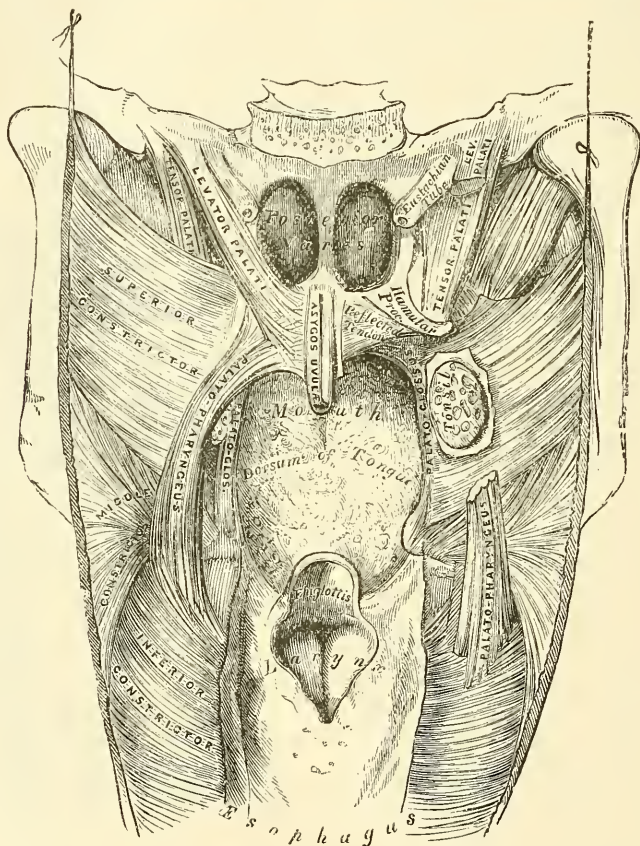
## VI. PALATAL REGION

Levator palati.	Palato-glossus.
Tensor palati.	Palato-pharyngeus.
Azygos uvulæ.	Salpingo-pharyngeus.

*Dissection* (fig. 320).—Lay open the pharynx from behind, by a vertical incision extending from its upper to its lower part, and partially divide the occipital attachment by a transverse incision on each side of the vertical one: the posterior surface of the soft palate is then exposed. Having fixed the uvula so as to make it tense, the mucous membrane and glands should be carefully removed from the posterior surface of the soft palate and the muscles of this part are at once exposed.

The **Levator palati** is a long, thick, rounded muscle, placed on the outer side of the posterior nares. It arises from the under surface of the apex of the petrous

FIG. 320.—Muscles of the soft palate. The pharynx being laid open from behind.



portion of the temporal bone, and from the adjoining cartilaginous portion of the Eustachian tube; after passing into the pharynx, above the upper concave margin of the Superior constrictor, it passes obliquely downwards and inwards, its fibres spreading out in the soft palate as far as the middle line, where they blend with those of the opposite side.

**Relations.**—*Externally*, with the Tensor palati and Superior constrictor. *Internally*, with the mucous membrane of the pharynx. *Posteriorly*, with the posterior fasciculus of the Palato-pharyngeus, the Azygos uvulæ, and the mucous lining of the soft palate.



The **Circumflexus** or **Tensor palati** is a broad, thin, riband-like muscle, placed on the outer side of the Levator palati, and consisting of a vertical and a horizontal portion. The vertical portion arises by a broad, thin, and flat lamella from the scaphoid fossa at the base of the internal pterygoid plate; from the spine of the sphenoid: the vaginal process of the temporal bone and the outer side of the cartilaginous portion of the Eustachian tube: descending vertically between the internal pterygoid plate and the inner surface of the Internal pterygoid muscle, it terminates in a tendon, which winds round the hamular process, being retained in this situation by some of the fibres of origin of the Internal pterygoid muscle. Between the hamular process and the tendon is a small bursa. The tendon or horizontal portion then passes horizontally inwards, and is inserted into a broad aponeurosis, the *palatine aponeurosis*, and into the transverse ridge on the horizontal portion of the palate bone.

**Relations.**—*Externally*, with the Internal pterygoid. *Internally*, with the Levator palati, from which it is separated by the Superior constrictor, and with the internal pterygoid plate. In the soft palate, its tendon and the palatine aponeurosis is anterior to that of the Levator palati, being covered by the Palato-glossus and the mucous membrane.

**Palatine Aponeurosis.**—Attached to the posterior border of the hard palate is a thin, firm, fibrous lamella which supports the muscles and gives strength to the soft palate. It is thicker above than below, where it becomes very thin and difficult to define. Laterally, it is continuous with the pharyngeal aponeurosis.

The **Azygos uvulæ** is not a single muscle, as would be inferred from its name, but a pair of narrow cylindrical fleshy fasciculi, placed on either side of the median line of the soft palate. Each muscle arises from the posterior nasal spine of the palate bone, and from the contiguous tendinous aponeurosis of the soft palate, and descends to be inserted into the uvula.

**Relations.**—*Anteriorly*, with the tendinous expansion of the Levatores palati; *behind*, with the posterior fasciculus of the Palato-pharyngeus and the mucous membrane.

The two next muscles are exposed by removing the mucous membrane from the pillars of the soft palate throughout nearly their whole extent.

The **Palato-glossus (Constrictor isthmi faucium)** is a small fleshy fasciculus, narrower in the middle than at either extremity, forming, with the mucous membrane covering its surface, the anterior pillar of the soft palate. It arises from the anterior surface of the soft palate on each side of the uvula, and, passing downwards, forwards, and outwards in front of the tonsil, is inserted into the side of the tongue, some of its fibres spreading over the dorsum, and others passing deeply into the substance of the organ to intermingle with the Transversus linguae. In the soft palate, the fibres of this muscle are continuous with those of the muscle of the opposite side.

The **Palato-pharyngeus** is a long, fleshy fasciculus, narrower in the middle than at either extremity, forming, with the mucous membrane covering its surface, the posterior pillar of the soft palate. It is separated from the Palato-glossus by an angular interval, in which the tonsil is lodged. It arises from the soft palate by an expanded fasciculus, which is divided into two parts by the Levator palati and Azygos uvulæ. The *posterior fasciculus* lies in contact with the mucous membrane, and joins with the corresponding muscle in the middle line; the *anterior fasciculus*, the thicker, lies in the soft palate between the Levator and Tensor, and joins in the middle line the corresponding part of the opposite muscle. Passing outwards and downwards behind the tonsil, the Palato-pharyngeus joins the Stylo-pharyngeus, and is inserted with that muscle into the posterior border of the thyroid cartilage, some of its fibres being lost on the side of the pharynx, and others passing across the middle line posteriorly, to decussate with the muscle of the opposite side.

**Relations.**—In the soft palate, its *posterior surface* is covered by mucous

membrane, from which it is separated by a layer of palatine glands. By its *anterior surface* it is in relation with the Tensor palati. Where it forms the posterior pillars of the fauces, it is covered by mucous membrane, excepting on its outer surface. In the *pharynx* it lies between the mucous membrane and the Constrictor muscles.

**The Salpingo-pharyngeus.**—This muscle arises from the inferior part of the Eustachian tube near its orifice; it passes downwards and blends with the posterior fasciculus of the Palato-pharyngeus.

In a dissection of the soft palate from its posterior or nasal surface to its anterior or oral surface, the muscles would be exposed in the following order: viz. the posterior fasciculus of the Palato-pharyngeus, covered over by the mucous membrane reflected from the floor of the nasal fossæ; the Azygos uvulæ; the Levator palati; the anterior fasciculus of the Palato-pharyngeus; the aponeurosis of the Tensor palati, and the Palato-glossus covered over by a reflection from the oral mucous membrane.

**Nerves.**—The Tensor palati is supplied by a branch from the otic ganglion; the remaining muscles of this group are in all probability supplied by the internal branch of the spinal accessory, whose fibres are distributed along with certain branches of the pneumogastric through the pharyngeal plexus.\*

**Actions.**—During the *first stage* of deglutition, the morsel of food is driven back into the fauces by the pressure of the tongue against the hard palate: the base of the tongue being, at the same time, retracted, and the larynx raised with the pharynx, and carried forwards under it. During the *second stage*, the epiglottis is pressed over the superior aperture of the larynx, and the morsel glides past it; then the Palato-glossi muscles, the constrictors of the fauces, contract behind the food; the soft palate is slightly raised by the Levator palati, and made tense by the Tensor palati; and the Palato-pharyngei, by their contraction, pull the pharynx upwards over the morsel of food, and at the same time come nearly together, the uvula filling up the slight interval between them. By these means the food is prevented passing into the upper part of the pharynx or the posterior nares; at the same time, the latter muscles form an inclined plane, directed obliquely downwards and backwards, along the under surface of which the morsel descends into the lower part of the pharynx. The Salpingo-pharyngeus raises the upper and lateral part of the pharynx; i.e. that part which is above the point where the Stylo-pharyngeus is attached to the pharynx.

*Surgical Anatomy.*—The muscles of the soft palate should be carefully dissected, the relations they bear to the surrounding parts especially examined, and their action attentively studied upon the dead subject, as the surgeon is required to divide one or more of these muscles in the operation of staphyloraphy. Sir W. Ferguson was the first to show that in the congenital deficiency called *cleft palate*, the edges of the fissure are forcibly separated by the action of the Levatores palati and Palato-pharyngei muscles, producing very considerable impediment to the healing process after the performance of the operation for uniting their margins by adhesion; he, consequently, recommended the division of these muscles as one of the most important steps in the operation. This he effected by an incision made with a curved knife introduced behind the soft palate. The incision is to be half-way between the hamular process and Eustachian tube, and perpendicular to a line drawn between them. This incision perfectly accomplishes the division of the Levator palati. The Palato-pharyngeus may be divided by cutting across the posterior pillar of the soft palate, just below the tonsil, with a pair of blunt-pointed curved scissors; and the anterior pillar may be divided also. To divide the Levator palati, the plan recommended by Mr. Pollock is to be greatly preferred. The soft palate being put upon the stretch, a double-edged knife is passed through it just on the inner side of the hamular process, and above the line of the Levator palati. The handle being now alternately raised and depressed, a sweeping cut is made along the posterior surface of the soft palate, and the knife withdrawn, leaving only a small opening in the mucous membrane on the anterior surface. If this operation is performed on the dead body, and the parts afterwards dissected, the Levator palati will be found completely divided. In the present day, however, this division of the muscles, as part of the operation of staphyloraphy, is not so much insisted upon. All tension is prevented by making longitudinal incisions, on either side,

\* *Journal of Anatomy and Physiology*, vol. xxiii. p. 523.

parallel to the left and just internal to the hamular process, in such a position as to avoid the posterior palatine artery.

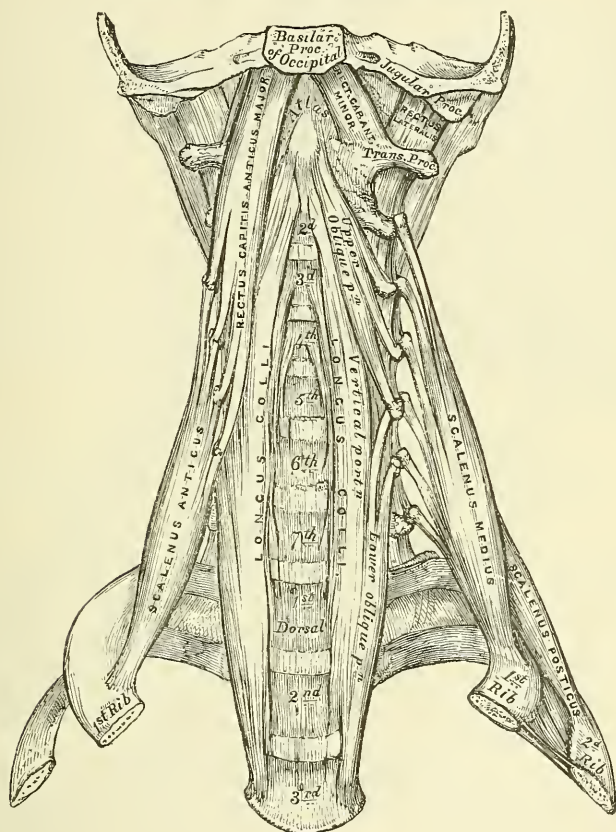
VII. ANTERIOR VERTEBRAL REGION

Rectus capitis anticus major.  
Rectus capitis anticus minor.

Rectus capitis lateralis.  
Longus colli.

The **Rectus capitis anticus major** (fig. 321), broad and thick above, narrow below, appears like a continuation upwards of the Scalenus anticus. It arises by four tendinous slips from the anterior tubercles of the transverse processes of

FIG. 321.—The prevertebral muscles.



the third, fourth, fifth, and sixth cervical vertebræ, and ascends, converging towards its fellow of the opposite side, to be inserted into the basilar process of the occipital bone.

**Relations.**—By its *anterior surface*, with the pharynx, the sympathetic nerve, and the sheath enclosing the internal and common carotid artery, internal jugular vein, and pneumogastric nerve. By its *posterior surface*, with the Longus colli, the Rectus capitis anticus minor, and the upper cervical vertebræ.

The **Rectus capitis anticus minor** is a short, flat muscle, situated immediately behind the upper part of the preceding. It arises from the anterior surface of the lateral mass of the atlas, and from the root of its transverse process, and passing obliquely upwards and inwards, is inserted into the basilar process immediately behind the preceding muscle.

**Relations.**—By its *anterior surface*, with the Rectus capitis anticus major. By its *posterior surface*, with the front of the occipito-atlantal articulation.



The **Rectus capitis lateralis** is a short, flat muscle, which arises from the upper surface of the transverse process of the atlas, and is inserted into the under surface of the jugular process of the occipital bone.

**Relations.**—By its *anterior surface*, with the internal jugular vein. By its *posterior surface*, with the vertebral artery. On its *outer side* lies the occipital artery; on its *inner side* the suboccipital nerve.

The **Longus colli** is a long, flat muscle, situated on the anterior surface of the spine, between the atlas and the third dorsal vertebra. It is broad in the middle, narrow and pointed at each extremity, and consists of three portions: a superior oblique, an inferior oblique, and a vertical portion. The *superior oblique portion* arises from the anterior tubercles of the transverse processes of the third, fourth, and fifth cervical vertebræ; and, ascending obliquely inwards, is inserted by a narrow tendon into the tubercle on the anterior arch of the atlas. The *inferior oblique portion*, the smallest part of the muscle, arises from the front of the bodies of the first two or three dorsal vertebræ; and ascending obliquely outwards, is inserted into the anterior tubercles of the transverse processes of the fifth and sixth cervical vertebræ. The *vertical portion* lies directly on the front of the spine; it arises, below, from the front of the bodies of the upper three dorsal and lower three cervical vertebræ, and is inserted above into the front of the bodies of the second, third, and fourth cervical vertebræ above.

**Relations.**—By its *anterior surface*, with the pharynx, the œsophagus, sympathetic nerve, the sheath of the great vessels of the neck, the inferior thyroid artery, and recurrent laryngeal nerve. By its *posterior surface*, with the cervical and dorsal portions of the spine. Its *inner border* is separated from the opposite muscle by a considerable interval below; but they approach each other above.

#### VIII. LATERAL VERTEBRAL REGION

Scalenus anticus.

Scalenus medius.

Scalenus posticus.

The **Scalenus anticus** is a conical-shaped muscle, situated deeply at the side of the neck, behind the Sterno-mastoid. It arises from the anterior tubercles of the transverse processes of the third, fourth, fifth, and sixth cervical vertebræ, and descending, almost vertically, is inserted by a narrow, flat tendon into the impression on the inner border and upper surface of the first rib. The lower part of this muscle separates the subclavian artery and vein: the latter being in front, and the former, with the brachial plexus, behind.

**Relations.**—*In front*, with the clavicle, the Subclavius, Sterno-mastoid, and Omo-hyoid muscles, the transversalis colli, the suprascapular and ascending cervical arteries, the subclavian vein, and the phrenic nerve. By its *posterior surface*, with the scalenus medius, pleura, the subclavian artery, and brachial plexus of nerves. It is separated from the Longus colli, on the inner side, by the vertebral artery. On the anterior tubercles of the transverse processes of the cervical vertebræ, between the attachments of the Scalenus anticus and Longus colli, lies the ascending cervical branch of the inferior thyroid artery.

The **Scalenus medius**, the largest and longest of the three Scaleni, arises from the posterior tubercles of the transverse processes of the lower six cervical vertebræ, and descending along the side of the vertebral column is inserted by a broad attachment into the upper surface of the first rib, behind the groove for the subclavian artery, as far back as the tubercle. It is separated from the Scalenus anticus by the subclavian artery below and the cervical nerves above. The posterior thoracic, or nerve of Bell, is formed in the substance of the Scalenus medius and emerges from it.

**Relations.**—By its *anterior surface*, with the Sterno-mastoid; it is crossed by the clavicle, the Omo-hyoid muscle, subclavian artery, and the cervical nerves.





position after it has been drawn backwards. These muscles also serve to flex the head, and from their obliquity, rotate it, so as to turn the face to one or the other side. The Longus colli flexes and slightly rotates the cervical portion of the spine. The Scaleni muscles, when they take their fixed point from above, elevate the first and second ribs, and are, therefore, inspiratory muscles. When they take their fixed point from below, they bend the spinal column to one or the other side. If the muscles of both sides act, lateral movement is prevented, but the spine is slightly flexed. The Rectus lateralis, acting on one side, bends the head laterally.

*Surface Form.*—The muscles in the neck, with the exception of the Platysma myoides, are invested by the deep cervical fascia, which softens down their form, and is of considerable importance in connection with deep cervical abscesses and tumours, modifying the direction of their growth and causing them to extend laterally instead of towards the surface. The *Platysma myoides* does not influence surface form except it is in action, when it produces wrinkling of the skin of the neck, which is thrown into oblique ridges parallel with the fasciculi of the muscle. Sometimes this contraction takes place suddenly and repeatedly, as a sort of spasmodic twitching, the result of a nervous habit. The *Sterno-cleido-mastoid* is the most important muscle of the neck as regards its surface form. If the muscle is put into action by drawing the chin downwards and to the opposite shoulder, its surface form will be plainly outlined. The sternal origin will stand out as a sharply defined ridge, while the clavicular origin will present a flatter and not so prominent an outline. The fleshy middle portion will appear as an oblique roll or elevation, with a thick rounded anterior border gradually becoming less marked above. On the opposite side, i.e. on the side to which the head is turned, the outline is lost, its place being occupied by an oblique groove in the integument. When the muscle is at rest its anterior border is still visible, forming an oblique rounded ridge, terminating below in the sharp outline of the sternal head. The posterior border of the muscle does not show above the clavicular head. The anterior border is defined by drawing a line from the tip of the mastoid process to the sterno-clavicular joint. It is an important surface-marking in the operation of ligature of the common carotid artery and some other operations. Between the sternal and clavicular heads is a slight depression, most marked when the muscle is in action. This is bounded below by the prominent sternal extremity of the clavicle. Between the sternal origins of the two muscles is a V-shaped space, the *suprasternal notch*, more pronounced below, and becoming toned down above, where the Sterno-hyoid and Sterno-thyroid muscles, lying upon the trachea, become more prominent. Above the hyoid bone, in the middle line, the anterior belly of the *Digastric* to a certain extent influences surface form. It corresponds to a line drawn from the symphysis of the lower jaw to the side of the body of the hyoid bone, and renders this part of the hyo-mental region convex. In the posterior triangle of the neck, the posterior belly of the *Omo-hyoid*, when in action, forms a conspicuous object, especially in thin necks, presenting a cord-like form running across this region, almost parallel with, and a little above, the clavicle.

## MUSCLES AND FASCLE OF THE TRUNK

The muscles of the Trunk may be arranged in four groups, corresponding with the region in which they are situated.

- |                |                  |
|----------------|------------------|
| I. The Back    | III. The Abdomen |
| II. The Thorax | IV. The Perinæum |

### I. MUSCLES OF THE BACK

The muscles of the back are very numerous, and may be subdivided into five layers.

FIRST LAYER	Rhomboides major.
Trapezius.	
Latissimus dorsi	THIRD LAYER
SECOND LAYER	Serratus posticus superior.
Levator anguli scapulæ.	Serratus posticus inferior.
Rhomboides minor.	Splenius capitis.
	Splenius colli.



## FOURTH LAYER

*Sacral and Lumbar Regions*

Erector spinæ.

*Dorsal Region*

Ilio-costalis.

Musculus accessorius ad ilio-costalem.

Longissimus dorsi.

Spinalis dorsi.

*Cervical Region*

Cervicalis ascendens.

Transversalis colli.

Trachelo-mastoid.

Complexus.

Biventer cervicis.

Spinalis colli.

## FIFTH LAYER

Semispinalis dorsi.

Semispinalis colli.

Multifidus spinæ.

Rotatores spinæ.

Supraspinales.

Interspinales.

Extensor coccygis.

Intertransversales.

Rectus capitis posticus major.

Rectus capitis posticus minor.

Obliquus capitis superior.

Obliquus capitis inferior.

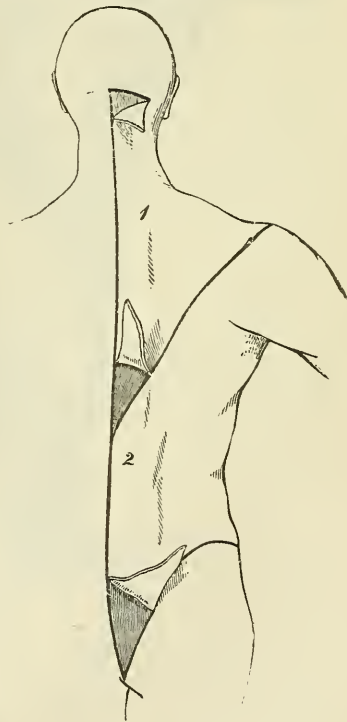
## FIRST LAYER

Trapezius.

Latissimus dorsi.

*Dissection* (fig. 323).—Place the body in the prone position, with the arms extended over the sides of the table, and the chest and abdomen supported by several blocks, so as to render the muscles tense. Then make an incision along the middle line of the back from the occipital protuberance to the coccyx. Make a transverse incision from the upper end of this to the mastoid process; and a third incision from its lower end, along the crest of the ilium to about its middle. This large intervening space should, for convenience of dissection, be subdivided by a fourth incision, extending obliquely from the spinous process of the last dorsal vertebra, upwards and outwards, to the acromion process. This incision corresponds with the lower border of the Trapezius muscle. The flaps of integument are then to be removed in the direction shown in the figure.

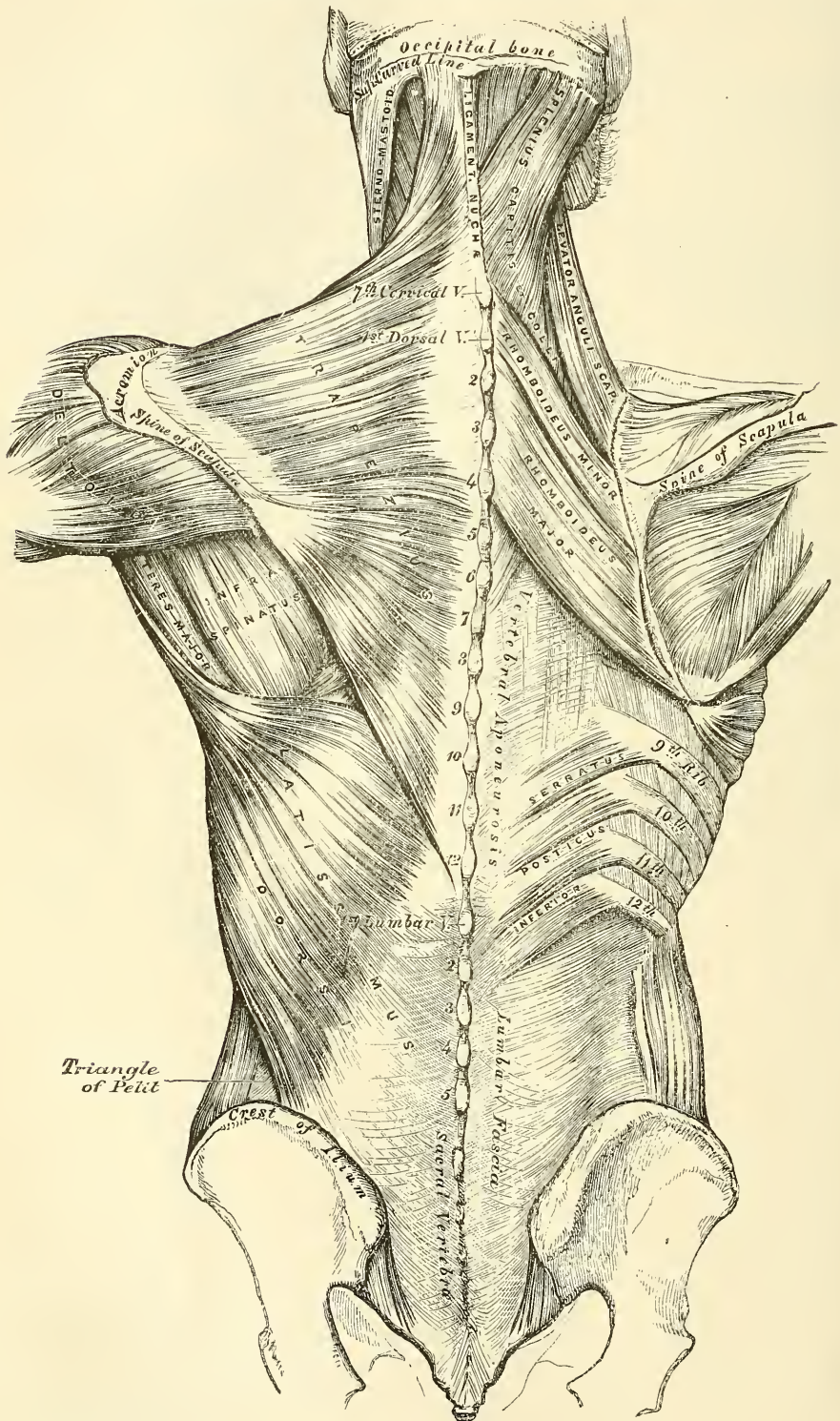
FIG. 323.—Dissection of the muscles of the back.



The **superficial fascia** is exposed upon removing the skin from the back. It forms a layer of considerable thickness and strength, in which a quantity of granular pinkish fat is contained. It is continuous with the superficial fascia in other parts of the body. The **deep fascia** is a dense fibrous layer, attached to the occipital bone, the spines of the vertebræ, the crest of the ilium, and the spine of the scapula. It covers over the superficial muscles, forming sheaths for them, and in the neck forms the posterior part of the deep cervical fascia; in the thorax it is continuous with the deep fascia of the axilla and chest, and in the abdomen with that covering the abdominal muscles.

The **Trapezius** (fig. 324) is a broad, flat, triangular muscle, placed immediately beneath the skin and fascia, and covering the upper and back part of the neck and shoulders. It arises from the external occipital protuberance and the inner third of the superior curved line of the occipital bone; from the ligamentum nuchæ, the spinous process of the seventh cervical, and those of all the dorsal vertebræ; and from the corresponding portion of the supraspinous ligament.

Fig. 324.—Muscles of the back. On the left side is exposed the first layer; on the right side, the second layer and part of the third.





From this origin, the superior fibres proceed downwards and outwards, the inferior ones upwards and outwards; and the middle fibres, horizontally; and are inserted, the superior ones into the outer third of the posterior border of the clavicle; the middle fibres into the inner margin of the acromion process, and into the superior lip of the posterior border or crest of the spine of the scapula; the inferior fibres converge near the scapula, and terminate in a triangular aponeurosis, which glides over a smooth surface at the inner extremity of the spine, to be inserted into a tubercle at the outer part of this smooth surface. The Trapezius is fleshy in the greater part of its extent, but tendinous at its origin and insertion. At its occipital origin, it is connected to the bone by a thin fibrous lamina, firmly adherent to the skin, and wanting the lustrous, shining appearance of aponeuroses. At its origin from the spines of the vertebræ, it is connected to the bones by means of a broad semi-elliptical aponeurosis, which occupies the space between the sixth cervical and the third dorsal vertebræ, and forms, with the aponeurosis of the opposite muscle, a tendinous ellipse. The rest of the muscle arises by numerous short tendinous fibres. If the Trapezius is dissected on both sides, the two muscles resemble a trapezium, or diamond-shaped quadrangle: two angles corresponding to the shoulders; a third to the occipital protuberance; and the fourth to the spinous process of the last dorsal vertebra.

The clavicular insertion of this muscle varies as to the extent of its attachment: it sometimes advances as far as the middle of the clavicle, and may even become blended with the posterior edge of the Sterno-mastoid, or overlap it. This should be borne in mind in the operation for tying the third part of the subclavian artery.

**Relations.**—By its *superficial surface*, with the integument. By its *deep surface*, in the neck, with the Complexus, Splenius, Levator anguli scapulæ, and Rhomboideus minor; in the back, with the Rhomboideus major, Supraspinatus, Infraspinatus, the Vertebral aponeurosis (which separates it from the prolongations of the Erector spinæ), and the Latissimus dorsi. The spinal accessory nerve and the superficial cervical artery pass beneath the anterior border of this muscle, near the clavicle. The anterior margin of its cervical portion forms the posterior boundary of the posterior triangle of the neck, the other boundaries being the Sterno-mastoid in front, and the clavicle below.

The **Ligamentum nuchæ** (fig. 324) is a thin band of condensed cellulo-fibrous membrane, placed in the line of union between the two Trapezii in the neck. It extends from the external occipital protuberance to the spinous process of the seventh cervical vertebra, where it is continuous with the supraspinous ligament. From its anterior surface a fibrous lamina is given off, which is attached to the spinous process of each of the cervical vertebræ, excepting the atlas, so as to form a septum between the muscles on each side of the neck. In man it is merely the rudiment of an important elastic ligament, which, in some of the lower animals, serves to sustain the weight of the head.

The **Latissimus dorsi** is a broad flat muscle, which covers the lumbar and the lower half of the dorsal regions, and is gradually contracted into a narrow fasciculus at its insertion into the humerus. It arises by tendinous fibres from the spinous processes of the six inferior dorsal and from the posterior layer of the lumbar fascia (see page 432), by which it is attached to the spines of the lumbar and sacral vertebræ, and to the supraspinous ligament. It also arises from the external lip of the crest of the ilium, behind the origin of the External oblique, and by fleshy digitations from the three or four lower ribs, which are interposed between similar processes of the External oblique muscle (fig. 329, page 448). From this extensive origin the fibres pass in different directions, the upper ones horizontally, the middle obliquely upwards, and the lower vertically upwards, so as to converge and form a thick fasciculus, which crosses the inferior angle of the scapula, and occasionally receives a few fibres from it. The muscle then curves around the lower border of the Teres major, and is twisted upon



itself, so that the superior fibres become at first posterior and then inferior, and the vertical fibres at first anterior and then superior. It then terminates in a short quadrilateral tendon, about three inches in length, which, passing in front of the tendon of the *Teres major*, is inserted into the bottom of the bicipital groove of the humerus; its insertion extending higher on the humerus than that of the tendon of the *Pectoralis major*. The lower border of the tendon of this muscle is united with that of the *Teres major*, the surfaces of the two being separated by a bursa; another bursa is sometimes interposed between the muscle and the inferior angle of the scapula. This muscle at its insertion gives off an expansion to the deep fascia of the arm.

A muscular slip, varying from 3 to 4 inches in length, and from  $\frac{1}{4}$  to  $\frac{3}{4}$  of an inch in breadth, occasionally arises from the upper edge of the *Latissimus dorsi* about the middle of the posterior fold of the axilla, and crosses the axilla in front of the axillary vessels and nerves, to join the under surface of the tendon of the *Pectoralis major*, the *Coraco-brachialis*, or the fascia over the *Biceps*. The position of this abnormal slip is a point of interest in its relation to the axillary artery, as it crosses the vessel just above the spot usually selected for the application of a ligature, and may mislead the surgeon during the operation. It may be easily recognised by the transverse direction of its fibres. Dr. Struther found it, in 8 out of 105 subjects, occurring seven times on both sides.

**Relations.**—Its *superficial surface* is subcutaneous, excepting at its upper part, where it is covered by the *Trapezius*, and at its insertion, where its tendon is crossed by the axillary vessels and the brachial plexus of nerves. By its *deep surface*, it is in relation with the Lumbar fascia, the *Serratus posticus inferior*, the lower external intercostal muscles and ribs, inferior angle of the scapula, *Rhomboideus major*, *Infraspinatus*, and *Teres major*. Its outer margin is separated below from the *External oblique* by a small triangular interval; and another triangular interval exists between its upper border and the margin of the *Trapezius*, in which the *Rhomboideus major* muscle is exposed.

**Nerves.**—The *Trapezius* is supplied by the spinal accessory, and by branches from the anterior divisions of the third and fourth cervical nerves; the *Latissimus dorsi* by the middle or long subscapular nerve.

## SECOND LAYER

*Levator anguli scapulæ.*

*Rhomboideus minor.*

*Rhomboideus major.*

**Dissection.**—The *Trapezius* must be removed, in order to expose the next layer; to effect this, detach the muscle from its attachment to the clavicle and spine of the scapula, and turn it back towards the spine.

The ***Levator anguli scapulæ*** is situated at the back part and side of the neck. It arises by tendinous slips from the posterior tubercles of the transverse processes of the four upper cervical vertebræ; these, becoming fleshy, are united so as to form a flat muscle, which, passing downwards and backwards, is inserted into the posterior border of the scapula, between the superior angle and the triangular smooth surface at the root of the spine.

**Relations.**—By its *superficial surface*, with the integument, *Trapezius*, and *Sterno-mastoid*. By its *deep surface*, with the *Splenius colli*, *Transversalis colli*, *Cervicalis ascendens*, and *Serratus posticus superior* muscles, and with the *transversalis colli* and posterior scapular arteries.

The ***Rhomboideus minor*** arises from the ligamentum nuchæ and spinous processes of the seventh cervical and first dorsal vertebræ. Passing downwards and outwards, it is inserted into the margin of the triangular smooth surface at the root of the spine of the scapula. This small muscle is usually separated from the *Rhomboideus major* by a slight cellular interval.

**Relations.**—By its *superficial (posterior) surface*, with the *Trapezius*. By its *deep surface*, with the same structures as the *Rhomboideus major*.

The **Rhomboideus major** is situated immediately below the preceding, the adjacent margins of the two being occasionally united. It arises by tendinous fibres from the spinous processes of the four or five upper dorsal vertebræ and the supraspinous ligament, and is inserted into a narrow tendinous arch, attached above to the lower part of the triangular surface at the root of the spine; below, to the inferior angle, the arch being connected to the border of the scapula by a thin membrane. When the arch extends, as it occasionally does, but a short distance, the muscular fibres are inserted into the scapula itself.

**Relations.**—By its *superficial (posterior) surface*, with the *Latissimus dorsi*. By its *deep (anterior) surface*, with the *Serratus posticus superior*, posterior scapular artery, the vertebral aponeurosis which separates it from the prolongations from the *Erector spinæ*, the *Intercostal muscles*, and ribs.

**Nerves.**—The *Rhomboid muscles* are supplied by branches from the anterior division of the fifth cervical nerve; the *Levator anguli scapulæ* by the anterior division of the third and fourth cervical nerves.

**Actions.**—The movements effected by the preceding muscles are numerous, as may be conceived from their extensive attachment. The whole of the *Trapezius* when in action retracts the scapula and rotates it on a sagittal axis; if the head is fixed, the upper part of the *Trapezius* will elevate the point of the shoulder, as in supporting weights; when the lower fibres are brought into action they assist in depressing the bone. If the scapula is prevented from gliding on the chest, the middle and lower fibres of the muscle cause it to rotate, so that the acromion is raised. If the shoulders are fixed, both *Trapezii*, acting together, will draw the head directly backwards; or if only one acts, the head is drawn to the corresponding side.

The *Latissimus dorsi*, when it acts upon the humerus, draws it backwards, adducts, and at the same time rotates it inwards. It is the muscle which is principally employed in giving a downward blow, as in felling a tree or in sabre practice. If the arm is fixed, the muscle may act in various ways upon the trunk: thus, it may raise the lower ribs and assist in forcible inspiration; or, if both arms are fixed, the two muscles may assist the *Abdominal* and great *Pectoral* muscles in suspending and drawing the whole trunk forwards, as in climbing or walking on crutches.

The *Levator anguli scapulæ* raises the superior angle of the scapula, assisting the *Trapezius* in bearing weights or in shrugging the shoulders. If the shoulder be fixed, the *Levator anguli scapulæ* inclines the neck to the corresponding side and rotates it in the same direction. The *Rhomboid muscles* carry the inferior angle backwards and upwards, thus producing a slight rotation of the scapula upon the side of the chest, the *Rhomboideus major* acting especially on the lower angle of the scapula, through the tendinous arch by which it is inserted. The *Rhomboid muscles* acting together with the middle and inferior fibres of the *Trapezius* will draw the scapula directly backwards towards the spine.

### THIRD LAYER

*Serratus posticus superior.*

*Serratus posticus inferior.*

*Splenius* { *Splenius capitis.*  
          { *Splenius colli.*

**Dissection.**—To bring into view the third layer of muscles, remove the whole of the second, together with the *Latissimus dorsi*; by cutting through the *Levator anguli scapulæ* and *Rhomboid muscles* near their insertion, and reflecting them upwards, and by dividing the *Latissimus dorsi* in the middle by a vertical incision carried from its upper to its lower part, and reflecting the two halves of the muscle.

The ***Serratus posticus superior*** is a thin, flat, quadrilateral muscle, situated at the upper and back part of the thorax. It arises by a thin and broad aponeurosis from the *ligamentum nuchæ*, and from the spinous processes of the last cervical and two or three upper dorsal vertebræ and from the supraspinous ligament.

Inclining downwards and outwards, it becomes muscular, and is inserted, by four fleshy digitations, into the upper borders of the second, third, fourth, and fifth ribs, a little beyond their angles.

**Relations.**—By its *superficial surface*, with the Trapezius, Rhomboidei, and Levator anguli scapulæ. By its *deep surface*, with the Splenius, and the vertebral aponeurosis, which separates it from the prolongations of the Erector spinæ, and with the Intercostal muscles and ribs.

The **Serratus posticus inferior** is situated at the junction of the dorsal and lumbar regions: it is of an irregularly quadrilateral form, broader than the preceding, and separated from it by a considerable interval. It arises by a thin aponeurosis from the spinous processes of the last two dorsal and two or three upper lumbar vertebræ, and from the supraspinous ligaments. Passing obliquely upwards and outwards, it becomes fleshy, and divides into four flat digitations, which are inserted into the lower borders of the four lower ribs, a little beyond their angles. The thin aponeurosis of origin is intimately blended with the lumbar fascia.

**Relations.**—By its *superficial surface*, with the Latissimus dorsi. By its *deep surface*, with the Erector spinæ, ribs, and Intercostal muscles. Its upper margin is continuous with the vertebral aponeurosis.

The *Vertebral aponeurosis* is a thin, fibrous lamina, extending along the whole length of the back part of the thoracic region, serving to bind down the long extensor muscles of the back which support the spine and head, and separate them from those muscles which connect the spine to the upper extremity. It consists of longitudinal and transverse fibres blended together, forming a thin lamella, which is attached in the median line to the spinous processes of the dorsal vertebræ; externally, to the angles of the ribs; and below, to the upper border of the Serratus posticus inferior and portion of the lumbar fascia, which gives origin to the Latissimus dorsi; above, it passes beneath the Serratus posticus superior and the Splenius, and blends with the deep fascia of the neck.

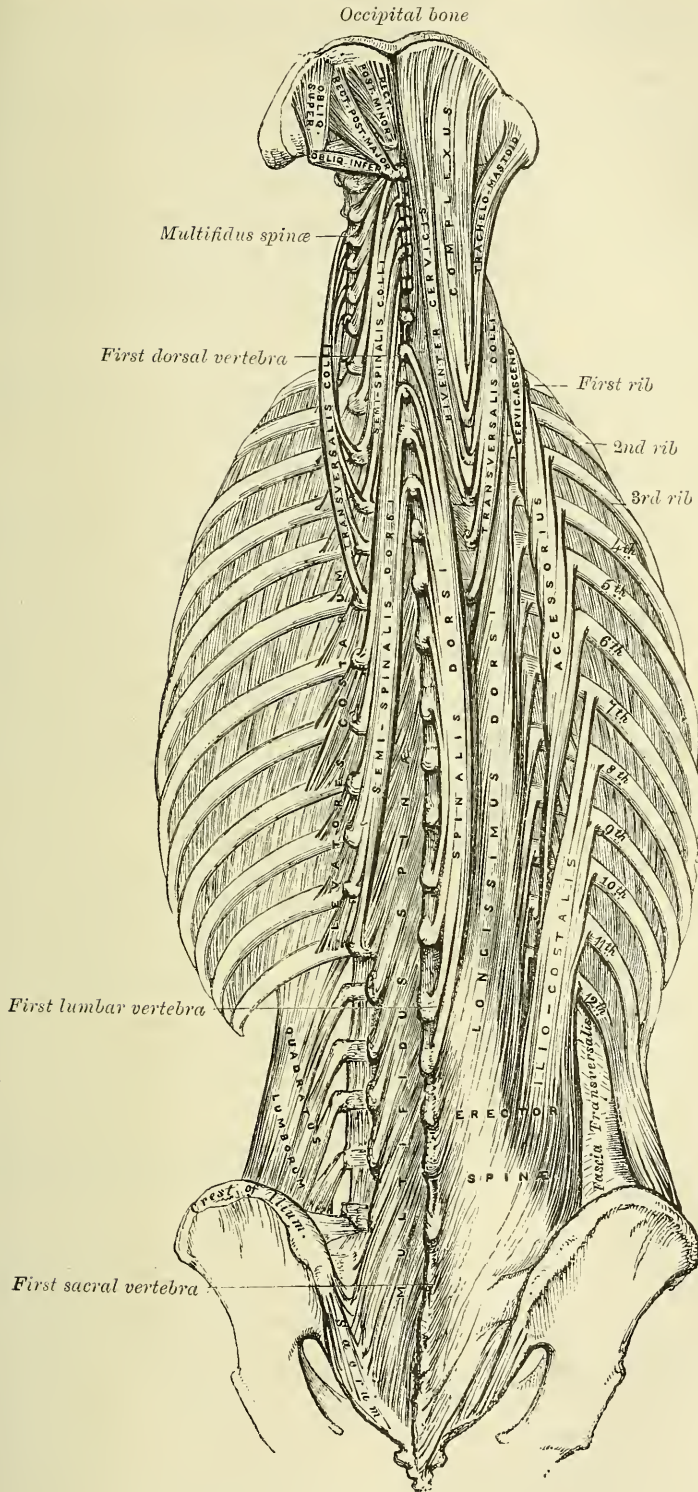
The *Lumbar fascia* (fig. 324) is a thick and strong lamella occupying the interval between the last rib and the crest of the ilium. It is attached internally to the spinous processes of the lumbar and sacral vertebræ; above, to the last rib, and to the cartilage of the eleventh rib; below, to the posterior third of the crest of the ilium. Externally, it blends with the Transversalis abdominis muscle. The posterior or superficial surface of this fascia gives attachment to part of the origin of the Latissimus dorsi, to the Serratus posticus inferior, and to the Internal oblique muscle of the abdomen. The anterior or deep surface gives off two layers: one lies between the Erector spinæ and Quadratus lumborum, and is attached to the tips of the transverse processes of the lumbar vertebræ; the other lies on the anterior or internal surface of the Quadratus lumborum, and is attached to the front part of the same transverse processes. The upper portion of this layer, which extends from the transverse process of the first lumbar vertebra to the apex and lower border of the last rib, constitutes the ligamentum arcuatum externum. Therefore these three layers of the lumbar fascia form two spaces: between the posterior and middle layer is situated the Erector spinæ and the Multifidus spinæ; between the middle and anterior layers is situated the Quadratus lumborum.

Now detach the Serratus posticus superior from its origin, and turn it outwards, when the Splenius muscle will be brought into view.

The **Splenius** is situated at the back of the neck and upper part of the dorsal region. At its origin, it is a single muscle, narrow, and pointed in form; but it soon becomes broader, and divides into two portions, which have separate insertions. It arises, by tendinous fibres, from the lower half of the ligamentum nuchæ, from the spinous processes of the last cervical and of the six upper dorsal vertebræ, and from the supraspinous ligament. From this origin, the fleshy fibres proceed obliquely upwards and outwards forming a broad flat muscle,



FIG. 325.—Muscles of the back. Deep layers



which divides as it ascends into two portions, the *Splenius capitis* and *Splenius colli*.

The *Splenius capitis* is inserted into the mastoid process of the temporal bone, and into the rough surface on the occipital bone just beneath the superior curved line.

The *Splenius colli* is inserted, by tendinous fasciculi, into the posterior tubercles of the transverse processes of the two or three upper cervical vertebræ.

The *Splenius* is separated from its fellow of the opposite side by a triangular interval, in which is seen the *Complexus*.

**Relations.**—By its *superficial surface*, with the *Trapezius*, from which it is separated below by the *Rhomboidei* and the *Serratus posticus superior*. It is covered at its insertion by the *Sterno-mastoid*, and at the lower and back part of the neck by the *Levator anguli scapulæ*. By its *deep surface*, with the *Spinalis dorsi*, *Longissimus dorsi*, *Semispinalis colli*, *Complexus*, *Trachelo-mastoid*, and *Transversalis colli*.

**Nerves.**—The *Splenius* is supplied from the external branches of the posterior divisions of the cervical nerves; the *Serratus posticus superior* is supplied by the external branches of the posterior divisions of the upper dorsal nerves; the *Serratus posticus inferior* by the external branches of the posterior divisions of the lower dorsal nerves.

**Actions.**—The *Serrati* are respiratory muscles. The *Serratus posticus superior* elevates the ribs; it is therefore an inspiratory muscle; while the *Serratus inferior* draws the lower ribs downwards and backwards, and thus elongates the thorax. It also fixes the lower ribs, thus aiding the downward action of the diaphragm and resisting the tendency which it has to draw the lower ribs upwards and forwards. It must therefore be regarded as a muscle of inspiration. This muscle is also probably a tensor of the vertebral aponeurosis. The *Splenii* muscles of the two sides, acting together, draw the head directly backwards, assisting the *Trapezius* and *Complexus*; acting separately, they draw the head to one or the other side, and slightly rotate it, turning the face to the same side. They also assist in supporting the head in the erect position.

#### FOURTH LAYER

<i>Sacral and Lumbar Regions</i>	<i>Cervical Region</i>
Erector spinæ.	<i>Cervicalis ascendens</i> .
<i>Dorsal Region</i>	<i>Transversalis colli</i> .
<i>Ilio-costalis</i> .	<i>Trachelo-mastoid</i> .
<i>Musculus accessorius ad ilio-costalem</i> .	<i>Complexus</i> .
<i>Longissimus dorsi</i> .	<i>Biventer cervicis</i> .
<i>Spinalis dorsi</i> .	<i>Spinalis colli</i> .

**Dissection.**—To expose the muscles of the fourth layer, remove entirely the *Serrati* and the vertebral and lumbar fasciæ. Then detach the *Splenius* by separating its attachment to the spinous processes and reflecting it outwards.

The **Erector spinæ** (fig. 325), and its prolongations in the dorsal and cervical regions, fill up the vertebral groove on each side of the spine. It is covered in the lumbar region by the lumbar fascia; in the dorsal region by the *Serrati* muscles and the vertebral aponeurosis; and in the cervical region by a layer of cervical fascia continued beneath the *Trapezius* and the *Splenius*. This large muscular and tendinous mass varies in size and structure at different parts of the spine. In the sacral region, the *Erector spinæ* is narrow and pointed, and its origin chiefly tendinous in structure. In the lumbar region, the muscle becomes enlarged, and forms a large fleshy mass. In the dorsal region, it subdivides into two parts, which gradually diminish in size as they ascend to be inserted into the vertebræ and ribs. In the cervical region, it divides into a number

of small muscles which are continued upwards to the head and support it upon the spine.

The *Erector spinæ* arises from the sacro-iliac groove, and from the anterior surface of a very broad and thick tendon, which is attached, internally, to the spines of the sacrum, to the spinous processes of the lumbar and the eleventh and twelfth dorsal vertebræ, and the supraspinous ligament; externally, to the back part of the inner lip of the crest of the ilium, and to the series of eminences on the posterior part of the sacrum, which represent the transverse processes, where it blends with the great sacro-sciatic and posterior sacro-iliac ligaments. Some of its fibres are continuous with the fibres of origin of the *Gluteus maximus*. The muscular fibres form a single large fleshy mass, bounded in front by the transverse processes of the lumbar vertebræ, and by the middle lamella of the lumbar fascia. Opposite the last rib it divides into two parts, the *Ilio-costalis* and the *Longissimus dorsi*.

The *Ilio-costalis* (*Sacro-lumbalis*), the external and smaller portion of the *Erector spinæ*, is inserted, generally, by six or seven flattened tendons, into the angles of the six or seven lower ribs. The number of the tendons of this muscle is, however, very variable, and therefore the number of ribs into which it is inserted. Frequently it is found to possess nine or ten tendons, and sometimes as many tendons as there are ribs, and is then inserted into the angles of all the ribs. If this muscle is reflected outwards, it will be seen to be reinforced by a series of muscular slips, which arise from the angles of the ribs; by means of these the *Ilio-costalis* is continued upwards to the upper ribs, and the cervical portion of the spine. The accessory portions form two additional muscles, the *Musculus accessorius* and the *Cervicalis ascendens*.

The *Musculus accessorius ad ilio-costalem* arises, by separate flattened tendons, from the angles of the six lower ribs: these become muscular, and are finally inserted, by separate tendons, into the angles of the six upper ribs and into the back of the transverse process of the seventh cervical vertebra.

The *Cervicalis ascendens*\* is the continuation of the *Accessorius* upwards into the neck; it is situated on the inner side of the tendons of the *Accessorius*, arising from the angles of the four or five upper ribs, and is inserted by a series of slender tendons into the posterior tubercles of the transverse processes of the fourth, fifth, and sixth cervical vertebræ.

The *Longissimus dorsi* is the inner and larger portion of the *Erector spinæ*. In the lumbar region, where it is as yet blended with the *Ilio-costalis*, some of the fibres are attached to the whole length of the posterior surface of the transverse processes and the accessory processes of the lumbar vertebræ, and to the middle layer of the lumbar fascia. In the dorsal region, the *Longissimus dorsi* is inserted, by long thin tendons, into the tips of the transverse processes of all the dorsal vertebræ, and into from seven to eleven of the lower ribs between their tubercles and angles. This muscle is continued upwards, to the cranium and cervical portion of the spine, by means of two additional muscles, the *Transversalis colli* and *Trachelo-mastoid*.

The *Transversalis colli* (or *cervicis*), placed on the inner side of the *Longissimus dorsi*, arises by long thin tendons from the summits of the transverse processes of the six upper dorsal vertebræ, and is inserted by similar tendons into the posterior tubercles of the transverse processes of the cervical vertebræ from the second to the sixth inclusive.

The *Trachelo-mastoid* lies on the inner side of the preceding, between it and the *Complexus* muscle. It arises, by four tendons, from the transverse processes of the five or six upper dorsal vertebræ, and by additional separate tendons from the articular processes of the three or four lower cervical. The fibres form a small muscle, which ascends to be inserted into the posterior margin of the

\* This muscle is sometimes called '*Cervicalis descendens*.' The student should remember that these long muscles take their fixed point from above or from below, according to circumstances.



mastoid process, beneath the Splenius and Sterno-mastoid muscles. This small muscle is almost always crossed by a tendinous intersection near its insertion into the mastoid process.\*

**Relations.**—The Erector spinæ and its prolongations are bound down to the vertebræ and ribs in the lumbar and dorsal regions by the lumbar fascia and the vertebral aponeurosis. The inner part of these muscles covers the muscles of the fifth layer. In the neck, they are in relation, by their *superficial surface*, with the Trapezius and Splenius; by their *deep surface*, with the Semispinalis dorsi et colli, and the Recti and Obliqui.

The **Spinalis dorsi** connects the spinous processes of the upper lumbar and the dorsal vertebræ together by a series of muscular and tendinous slips, which are intimately blended with the Longissimus dorsi. It is situated at the inner side of the Longissimus dorsi, arising, by three or four tendons, from the spinous processes of the first two lumbar and the last two dorsal vertebræ: these, uniting, form a small muscle, which is inserted, by separate tendons, into the spinous processes of the dorsal vertebræ, the number varying from four to eight. It is intimately united with the Semispinalis dorsi, which lies beneath it.

The **Spinalis colli** is a small muscle, connecting together the spinous processes of the cervical vertebræ, and analogous to the Spinalis dorsi in the dorsal region. It varies considerably in its size, and in its extent of attachment to the vertebræ, not only in different bodies, but on the two sides of the same body. It usually arises by fleshy or tendinous slips, varying from two to four in number, from the spinous processes of the fifth, sixth, and seventh cervical vertebræ, and occasionally from the first and second dorsal, and is inserted into the spinous process of the axis, and occasionally into the spinous processes of the two vertebræ below it. This muscle was found absent in five cases out of twenty-four.

The **Complexus** is a broad thick muscle, situated at the upper and back part of the neck, beneath the Splenius, and internal to the Transversalis colli and Trachelo-mastoid. It arises, by a series of tendons, about seven in number, from the tips of the transverse processes of the upper three dorsal and seventh cervical vertebræ, and from the articular processes of the three cervical above this. The tendons, uniting, form a broad muscle, which passes obliquely upwards and inwards, and is inserted into the innermost depression between the two curved lines of the occipital bone. This muscle, about its middle, is traversed by a transverse tendinous intersection.

The **Biventer cervicis** is a small fasciculus, situated on the inner side of the preceding, and in the majority of cases blended with it; it has received its name from having a tendon intervening between two fleshy bellies. It is sometimes described as a part of the Complexus. It arises by from two to four tendinous slips, from the transverse processes of as many of the upper dorsal vertebræ, and is inserted, on the inner side of the Complexus, into the superior curved line of the occipital bone.

**Relations.**—The Complexus is covered by the Splenius and the Trapezius. It lies on the Rectus capitis posticus major and minor, the Obliquus capitis superior and inferior, and on the Semispinalis colli, from which it is separated by the profunda cervicis artery, the princeps cervicis artery, and branches of the posterior cervical plexus of nerves. The Biventer cervicis is separated from its fellow of the opposite side by the ligamentum nuchæ.

**Nerves.**—The Erector spinæ and its subdivisions in the dorsal region are supplied by the external branches of the posterior divisions of the lumbar and dorsal nerves; while its subdivisions in the cervical region, the Transversalis colli and Trachelo-mastoid, are supplied by the external branches of the posterior divisions of the cervical nerves; the Complexus, by the internal branches of the

\* These two muscles (Transversalis colli and Trachelo-mastoid) are sometimes described as one, having a common origin, but dividing above at their insertion. The Trachelo-mastoid is then termed the *Transversalis capitis*.

posterior divisions of the cervical nerves, the suboccipital and great occipital. The *Spinalis colli* is supplied by the internal branches of the posterior divisions of the cervical nerves; and the *Spinalis dorsi* by the internal branches of the posterior divisions of the dorsal nerves.

## FIFTH LAYER

<i>Semispinalis dorsi.</i>	<i>Extensor coccygis.</i>
<i>Semispinalis colli.</i>	<i>Intertransversales.</i>
<i>Multifidus spinæ.</i>	<i>Rectus capitis posticus major.</i>
<i>Rotatores spinæ.</i>	<i>Rectus capitis posticus minor.</i>
<i>Supraspinales.</i>	<i>Obliquus capitis superior.</i>
<i>Interspinales.</i>	<i>Obliquus capitis inferior.</i>

*Dissection.*—Remove the muscles of the preceding layer by dividing and turning aside the *Complexus*; then detach the *Spinalis* and *Longissimus dorsi* from their attachments, divide the *Erector spinæ* at its connection below to the sacral and lumbar spines, and turn it outwards. The muscles filling up the interval between the spinous and transverse processes are then exposed.

The ***Semispinalis dorsi*** (fig. 325) consists of thin, narrow, fleshy fasciculi, interposed between tendons of considerable length. It arises by a series of small tendons from the transverse processes of the lower dorsal vertebræ, from the tenth or eleventh to the fifth or sixth; and is inserted, by five or six tendons, into the spinous processes of the upper four dorsal and lower two cervical vertebræ.

The ***Semispinalis colli***, thicker than the preceding, arises by a series of tendinous and fleshy fibres from the transverse processes of the upper four dorsal vertebræ and from the articular processes of the lower four cervical vertebræ; and is inserted into the spinous processes of four cervical vertebræ, from the axis to the fifth cervical. The fasciculus connected with the axis is the largest, and chiefly muscular in structure.

***Relations.***—By their *superficial surface*, from below upwards, with the *Spinalis dorsi*, *Longissimus dorsi*, *Splenius*, *Complexus*, the *profunda cervicis* artery, the *princeps cervicis* artery, and the internal branches of the posterior divisions of the first, second, and third cervical nerves. By their *deep surface*, with the *Multifidus spinæ*.

The ***Multifidus spinæ*** consists of a number of fleshy and tendinous fasciculi, which fill up the groove on either side of the spinous processes of the vertebræ, from the sacrum to the axis. In the sacral region, these fasciculi arise from the back of the sacrum, as low as the fourth sacral foramen, and from the aponeurosis of origin of the *Erector spinæ*; in the iliac region, from the inner surface of the posterior superior spine of the ilium, and posterior sacro-iliac ligaments; in the lumbar regions, from the articular processes; in the dorsal region, from the transverse processes; and in the cervical region, from the articular processes. Each fasciculus, passing obliquely upwards and inwards, is inserted into the amina and whole length of the spinous process of one of the vertebræ above. These fasciculi vary in length: the most superficial, the longest, pass from one vertebra to the third or fourth above; those next in order pass from one vertebra to the second or third above; whilst the deepest connect two contiguous vertebræ.

***Relations.***—By its *superficial surface*, with the *Longissimus dorsi*, *Spinalis dorsi*, *Semispinalis dorsi*, and *Semispinalis colli*. By its *deep surface*, with the *laminæ* and spinous processes of the vertebræ, and with the *Rotatores spinæ* in the dorsal region.

The ***Rotatores spinæ*** are found only in the dorsal region of the spine, beneath the *Multifidus spinæ*; they are eleven in number on each side. Each muscle is small and somewhat quadrilateral in form; it arises from the upper and back part of the transverse process, and is inserted into the lower border and outer

surface of the lamina of the vertebra above, the fibres extending as far inwards as the root of the spinous process. The first is found between the first and second dorsal; the last, between the eleventh and twelfth. Sometimes the number of these muscles is diminished by the absence of one or more from the upper or lower end.

The **Supraspinales** consist of a series of fleshy bands which lie on the spinous processes in the cervical region of the spine.

The **Interspinales** are short muscular fasciculi, placed in pairs between the spinous processes of the contiguous vertebrae, one on each side of the interspinous ligament. In the *cervical region*, they are most distinct, and consist of six pairs, the first being situated between the axis and third vertebra, and the last between the last cervical and the first dorsal. They are small narrow bundles, attached, above and below, to the apices of the spinous processes. In the *dorsal region*, they are found between the first and second vertebrae, and occasionally between the second and third; and below, between the eleventh and twelfth. In the *lumbar region*, there are four pairs of these muscles in the intervals between the five lumbar vertebrae. There is also occasionally one in the interspinous space, between the last dorsal and first lumbar, and between the fifth lumbar and the sacrum.

The **Extensor coccygis** is a slender muscular fasciculus, occasionally present, which extends over the lower part of the posterior surface of the sacrum and coccyx. It arises by tendinous fibres from the last bone of the sacrum, or first piece of the coccyx, and passes downwards to be inserted into the lower part of the coccyx. It is a rudiment of the Extensor muscle of the caudal vertebrae of the lower animals.

The **Intertransversales** are small muscles placed between the transverse processes of the vertebrae. In the *cervical region* they are most developed, consisting of rounded muscular and tendinous fasciculi, which are placed in pairs, passing between the two anterior and the two posterior tubercles of the transverse processes of two contiguous vertebrae, separated from one another by the anterior division of the cervical nerve, which lies in the groove between them. In this region there are seven pairs of these muscles, the first pair being between the atlas and axis, and the last pair between the seventh cervical and first dorsal vertebrae. In the *dorsal region* they are least developed, consisting chiefly of rounded tendinous cords in the intertransverse spaces of the upper dorsal vertebrae; but between the transverse processes of the lower three dorsal vertebrae, and between the transverse processes of the last dorsal and the first lumbar, they are muscular in structure. In the *lumbar region* they are arranged in pairs, on either side of the spine; one set occupying the entire interspace between the transverse processes of the lumbar vertebrae, the *intertransversales laterales*; the other set, *intertransversales mediales*, passing from the accessory process of one vertebra to the mammillary process of the next.

The **Rectus capitis posticus major** arises by a pointed tendinous origin from the spinous process of the axis, and, becoming broader as it ascends, is inserted into the inferior curved line of the occipital bone and the surface of bone immediately below it. As the muscles of the two sides pass upwards and outwards, they leave between them a triangular space, in which are seen the *Recti capitis postici minores* muscles.

**Relations.**—By its *superficial surface*, with the Complexus; and, at its insertion, with the Superior oblique. By its *deep surface*, with part of the Rectus capitis posticus minor, the posterior arch of the atlas, the posterior occipito-atlantal ligament, and part of the occipital bone.

The **Rectus capitis posticus minor**, the smallest of the four muscles in this region, is of a triangular shape; it arises by a narrow pointed tendon from the tubercle on the posterior arch of the atlas, and, becoming broader as it ascends, is inserted into the rough surface beneath the inferior curved line, nearly as far as the foramen magnum, nearer to the middle line than the preceding.



**Relations.**—By its *superficial surface*, with the Complexus and the Rectus capitis posticus major. By its *deep surface*, with the posterior occipito-atlantal ligament.

The **Obliquus capitis inferior**, the larger of the two Oblique muscles, arises from the apex of the spinous process of the axis, and passes almost horizontally outwards, to be inserted into the lower and back part of the transverse process of the atlas.

**Relations.**—By its *superficial surface*, with the Complexus and with the posterior division of the second cervical nerve which crosses it. By its *deep surface*, with the vertebral artery, and posterior atlanto-axial ligament.

The **Obliquus capitis superior**, narrow below, wide and expanded above, arises by tendinous fibres from the upper surface of the transverse process of the atlas, joining with the insertion of the preceding, and, passing obliquely upwards and inwards, is inserted into the occipital bone, between the two curved lines, external to the Complexus.

**Relations.**—By its *superficial surface*, with the Complexus and Trachelo-mastoid. By its *deep surface*, with the posterior occipito-atlantal ligament.

The **Suboccipital triangle**.—Between the two oblique muscles and the Rectus capitis posticus major a triangular interval exists, the *suboccipital triangle*. This triangle is bounded, above and internally, by the Rectus capitis posticus major; above and externally, by the Obliquus capitis superior; below and externally, by the Obliquus capitis inferior. It is covered in by a layer of dense fibro-fatty tissue, situated beneath the Complexus muscle. The floor is formed by the posterior occipito-atlantal ligament, the posterior arch of the atlas, and the posterior atlanto-axial ligament. It contains the vertebral artery, as it runs in a deep groove on the upper surface of the posterior arch of the atlas; and the posterior division of the suboccipital nerve.

**Nerves.**—The Semispinalis dorsi and Rotatores spinæ are supplied by the internal branches of the posterior divisions of the dorsal nerves; the Semispinalis colli, by the internal branches of the posterior divisions of the cervical nerves; the Supraspinales and Interspinales are supplied by the internal branches of the posterior divisions of the cervical, dorsal, and lumbar nerves in the respective regions; the Intertransversales, by the internal branches of the posterior divisions of the cervical, dorsal, and lumbar nerves; the Multifidus spinæ, by the same, with the addition of the internal branches of the posterior divisions of the sacral nerves. The Recti and Obliqui muscles are all supplied by the suboccipital nerve; the Inferior oblique is also supplied by the great occipital nerve.

**Actions.**—When both the Spinales dorsi contract, they extend the dorsal region of the spine; when only one muscle contracts, it helps to bend the dorsal portion of the spine to one side. The Erector spinæ, comprising the Ilio-costalis and the Longissimus dorsi with their accessory muscles, serves, as its name implies, to maintain the spine in the erect posture; it also serves to bend the trunk backwards when it is required to counterbalance the influence of any weight at the front of the body—as, for instance, when a heavy weight is suspended from the neck, or when there is any great abdominal distension, as in pregnancy or dropsy; the peculiar gait under such circumstances depends upon the spine being drawn backwards, by the counterbalancing action of the Erector spinæ muscles. The muscles which form the continuation of the Erector spinæ upwards steady the head and neck, and fix them in the upright position. If the Ilio-costalis and Longissimus dorsi of one side act, they serve to draw down the chest and spine to the corresponding side. The Cervicales ascendens, taking their fixed points from the cervical vertebræ, elevate those ribs to which they are attached; taking their fixed points from the ribs, both muscles help to extend the neck; while one muscle bends the neck to its own side. The Transversalis colli, when both muscles act, taking their fixed point from below, bend the neck backwards. The Trachelo-mastoid, when both muscles act, taking their fixed point

from below, bend the head backwards; while, if only one muscle acts, the face is turned to the side on which the muscle is acting, and then the head is bent to the shoulder. The two Recti muscles draw the head backwards. The Rectus capitis posticus major, owing to its obliquity, rotates the cranium, with the atlas, round the odontoid process, turning the face to the same side. The Multifidus spinæ acts successively upon the different parts of the spine; thus, the sacrum furnishes a fixed point from which the fasciculi of this muscle act upon the lumbar region; these then become the fixed points for the fasciculi moving the dorsal region, and so on throughout the entire length of the spine; it is by the successive contraction and relaxation of the separate fasciculi of this and other muscles that the spine preserves the erect posture without the fatigue that would necessarily have been produced had this position been maintained by the action of a single muscle. The Multifidus spinæ, besides preserving the erect position of the spine, serves to rotate it, so that the front of the trunk is turned to the side opposite to that from which the muscle acts, this muscle being assisted in its action by the Obliquus externus abdominis. The Complexi draw the head directly backward; if one muscle acts, it draws the head to one side, and rotates it so that the face is turned to the opposite side. The Superior oblique draws the head backwards; and, from the obliquity in the direction of its fibres, will slightly rotate the cranium, turning the face to the opposite side. The Obliquus capitis inferior rotates the atlas, and with it the cranium, round the odontoid process, turning the face to the same side. The Semispinales, when the muscles of the two sides act together, help to extend the spine; when the muscles of one side only act, they rotate the dorsal and cervical parts of the spine, turning the body to the opposite side. The Supraspinales and Interspinales by approximating the spinous process help to extend the spine. The Intertransversales approximate the transverse processes, and help to bend the spine to one side. The Rotatores spinæ assist the Multifidus spinæ to rotate the spine, so that the front of the trunk is turned to the side opposite to that from which the muscle acts.

*Surface Form.*—The surface forms produced by the muscles of the back are numerous and difficult to analyse unless they are considered in systematic order. The most superficial layer, consisting of large strata of muscular substance, influences to a certain extent the surface form, and at the same time reveals the forms of the layers beneath. The *Trapezius* at the upper part of the back, and in the neck, covers over and softens down the outline of the underlying muscles. Its anterior border forms the posterior boundary of the posterior triangle of the neck. It forms a slight undulating ridge which passes downwards and forwards from the occiput to the junction of the middle and outer third of the clavicle. The tendinous ellipse formed by a part of the origin of the two muscles at the back of the neck is always to be seen as an oval depression, more marked when the muscle is in action. A slight dimple on the skin opposite the interval between the spinous processes of the third and fourth dorsal vertebræ marks the triangular aponeurosis by which the inferior fibres are inserted into the root of the spine of the scapula. From this point the inferior border of the muscle may be traced as an undulating ridge to the spinous process of the twelfth dorsal vertebra. In like manner, the *Latissimus dorsi* softens down and modulates the underlying structures at the lower part of the back and lower part of the side of the chest. In this way it modulates the outline of the Erector spinæ; of the *Serratus posticus inferior*, which is sometimes to be discerned through it, and is sometimes entirely obscured by it; of part of the *Serratus magnus* and *Superior oblique*, which it covers, and of the convex oblique ridges formed by the ribs with the intervening intercostal spaces. The anterior border of the muscle is the only part which gives a distinct surface form. This border may be traced, when the muscle is in action, as a rounded edge, starting from the crest of the ilium, and passing obliquely forwards and upwards to the posterior border of the axilla, where it combines with the *Teres major* in forming a thick rounded fold, the posterior boundary of the axillary space. The muscles in the second layer influence to a very considerable extent the surface form of the back of the neck and upper part of the trunk. The *Levator anguli scapulæ* reveals itself as a prominent divergent line, running downwards and outwards, from the transverse processes of the upper cervical vertebræ to the angle of the scapula, covered over and toned down by the overlying *Trapezius*. The *Rhomboidei* produce, when in action, a vertical eminence between the internal border of the scapula and the spinal furrow, varying in intensity according to the condition of contraction or relaxation of the *Trapezius* muscle, by which they are for the most part covered. The lowermost part of the *Rhomboideus major* is



uncovered by the Trapezius and forms on the surface an oblique ridge running upwards and inwards from the inferior angle of the scapula. Of the muscles of the third layer of the back, the *Serratus posticus superior* does not in any way influence surface form. The *Serratus posticus inferior*, when in strong action, may occasionally be revealed as an elevation beneath the *Latissimus dorsi*. The *Splenii* by their divergence serve to broaden out the upper part of the back of the neck and produce a local fulness in this situation, but do not otherwise influence surface form. Beneath all these muscles those of the fourth layer—the *Erector spinæ* and its continuations—influence the surface form in a decided manner. In the loins, the *Erector spinæ*, bound down by the lumbar fascia, forms a rounded vertical eminence, which determines the depth of the spinal furrow, and which below tapers to a point on the posterior surface of the sacrum and becomes lost there. In the back it forms a flattened plane which gradually becomes lost. In the neck the only part of this group of muscles which influences surface form is the *Trachelomastoid*, which produces a short convergent line across the upper part of the posterior triangle of the neck, appearing from under cover of the posterior border of the *Sternomastoid* and being lost below beneath the *Trapezius*.

## II. MUSCLES AND FASCLE OF THE THORAX

The Muscles belonging exclusively to this region are few in number. They are the

Intercostales externi.	Triangularis sterni.
Intercostales interni.	Levatores costarum.
Infracostales.	Diaphragm.

**Intercostal fasciæ.**—A thin but firm layer of fascia covers the outer surface of the External intercostal and the inner surface of the Internal intercostal muscles; and a third layer, the middle intercostal fascia, more delicate, is interposed between the two planes of muscular fibres. These are the intercostal fasciæ: they are best marked in those situations where the muscular fibres are deficient, as between the External intercostal muscles and sternum, in front; and between the Internal intercostals and spine, behind.

The **Intercostal muscles** (fig. 341) are two thin planes of muscular and tendinous fibres, placed one over the other, filling up the intercostal spaces, and being directed obliquely between the margins of the adjacent ribs. They have received the name 'external' and 'internal,' from the position they bear to one another. The tendinous fibres are longer and more numerous than the muscular: hence the walls of the intercostal spaces possess very considerable strength, to which the crossing of the muscular fibres materially contributes.

The **External intercostals** are eleven in number on each side. They extend from the tubercles of the ribs, behind, to the commencement of the cartilages of the ribs, in front, where they terminate in a thin membranous aponeurosis, which is continued forwards to the sternum. They arise from the lower border of each rib, and are inserted into the upper border of the rib below. In the two lowest spaces they extend to the end of the cartilages, and in the upper two or three spaces they do not quite extend to the ends of the ribs. Their fibres are directed obliquely downwards and forwards, in a similar direction with those of the External oblique muscle of the abdomen. They are thicker than the internal intercostals.

**Relations.**—By their *outer surface*, with the muscles which immediately invest the chest, viz. the *Pectoralis major* and *minor*, *Serratus magnus*, and *Rhomboideus major*, *Serratus posticus superior* and *inferior*, *Scalenus posticus*, *Ilio-costalis*, *Longissimus dorsi*, *Cervicalis ascendens*, *Transversalis colli*, *Levatores costarum*, and the *Obliquus externus abdominis*. By their *internal surface*, with the middle intercostal fascia, which separates them from the intercostal vessels and nerve, and the Internal intercostal muscles, and, behind, from the pleura.

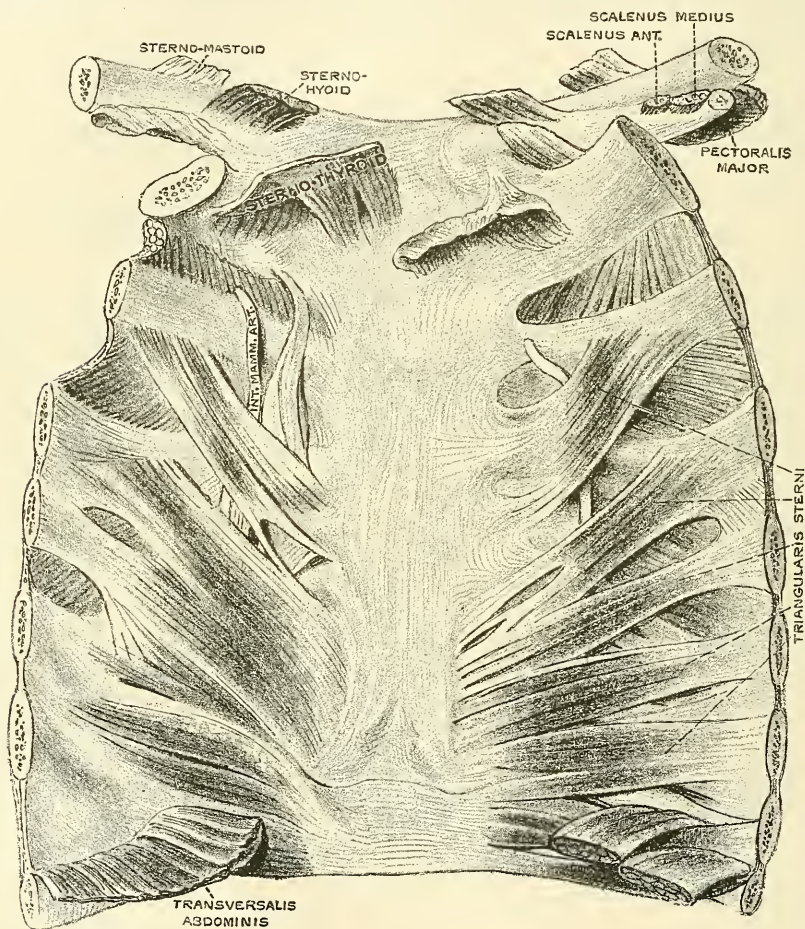
The **Internal intercostals** are also eleven in number on each side. They commence anteriorly at the sternum, in the interspaces between the cartilages of the true ribs, and from the anterior extremities of the cartilages of the false ribs,



and extend backwards as far as the angles of the ribs; whence they are continued to the vertebral column by a thin aponeurosis. They arise from the ridge on the inner surface of each rib, as well as from the corresponding costal cartilage, and are inserted into the upper border of the rib below. Their fibres are directed obliquely downwards and backwards, passing in the opposite direction to the fibres of the External intercostal muscles.

**Relations.**—By their *external surface*, with the intercostal vessels and nerves, and the middle intercostal fascia, which separates them from the External inter-

FIG. 326.—Posterior surface of sternum and costal cartilages, showing Triangularis sterni muscle. (From a preparation in the Museum of the Royal College of Surgeons of England.)



costal muscles. By their *internal surface*, with the internal intercostal fascia, which separates them from the pleura costalis, Triangularis sterni, and Diaphragm.

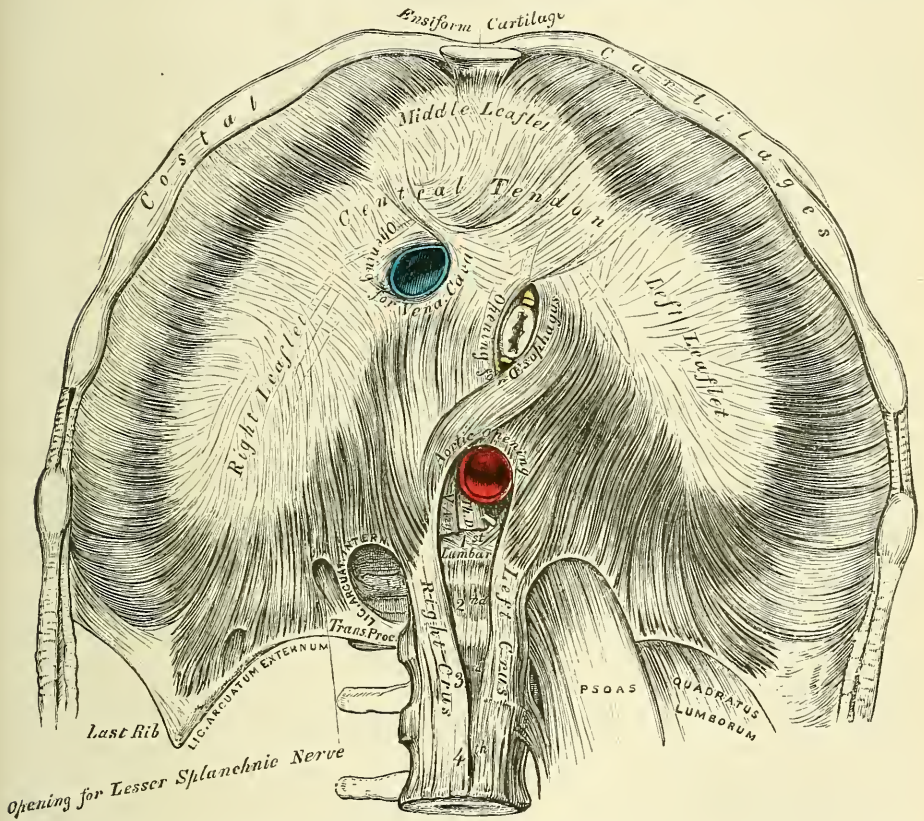
The **Infracostales (subcostales)** consist of muscular and aponeurotic fasciculi, which vary in number and length: they are placed on the inner surface of the ribs, where the Internal intercostal muscles cease; they arise from the inner surface of one rib, and are inserted into the inner surface of the first, second, or third rib below. Their direction is most usually oblique, like the Internal intercostals. They are most frequent between the lower ribs.

The **Triangularis sterni** (fig. 326) is a thin plane of muscular and tendinous fibres, situated upon the inner wall of the front of the chest. It arises from the

lower third of the posterior surface of the sternum, from the posterior surface of the ensiform cartilage, and from the sternal ends of the costal cartilages of the three or four lower true ribs. Its fibres diverge upwards and outwards, to be inserted by fleshy digitations into the lower border and inner surfaces of the costal cartilages of the second, third, fourth, fifth, and sixth ribs. The lowest fibres of this muscle are horizontal in their direction, and are continuous with those of the *Transversalis*: those which succeed are oblique, whilst the superior fibres are almost vertical. This muscle varies much in its attachment, not only in different bodies, but on opposite sides of the same body.

**Relations.**—*In front*, with the sternum, ensiform cartilage, costal cartilages, Internal intercostal muscles, and internal mammary vessels. *Behind*, with the pleura, pericardium, and anterior mediastinum.

FIG. 327.—The Diaphragm. Under surface.



The *Levatores costarum* (fig. 325), twelve in number on each side, are small tendinous and fleshy bundles, which arise from the extremities of the transverse processes of the seventh cervical and eleven upper dorsal vertebræ, and, passing obliquely downwards and outwards, are inserted into the upper border of the rib below them, between the tubercle and the angle. The inferior levatores divide into two fasciculi, one of which is inserted as above described; the other fasciculus passes down to the second rib below its origin; thus, each of the lower ribs receives fibres from the transverse processes of two vertebræ.

**Nerves.**—The muscles of this group are supplied by the intercostal nerves.

The *Diaphragm* (*διάφραγμα*, a partition wall) (fig. 327) is a thin musculo-fibrous septum, consisting of muscular fibres externally, which arise from the circumference of the thoracic cavity and pass upwards and inwards to converge to a central tendon. It is placed obliquely at the junction of the upper with the



middle third of the trunk, and separates the thorax from the abdomen, forming the floor of the former cavity and the roof of the latter. It is elliptical, its longest diameter being from side to side, and somewhat fan-shaped; the broad elliptical portion being horizontal, the narrow part, the *crura*, which represents the handle of the fan, vertical, and joined at right angles to the former. It is from this circumstance that some anatomists describe it as consisting of two portions, the upper or great muscle of the Diaphragm, and the lower or lesser muscle. It arises from the whole of the internal circumference of the thorax: being attached, in front, by fleshy fibres to the ensiform cartilage; on either side, to the inner surface of the cartilages and bony portions of the six or seven inferior ribs, interdigitating with the *Transversalis*; and behind, to two aponeurotic arches, named the *ligamentum arcuatum externum et internum*; and by the *crura*, to the lumbar vertebræ. The fibres from these sources vary in length; those arising from the ensiform appendix are very short and occasionally aponeurotic; those from the *ligamenta arcuata*, and more especially those from the cartilages of the ribs at the side of the chest, are longer, describe well-marked curves as they ascend, and finally converge to be inserted into the circumference of the central tendon. Between the sides of the muscular slip from the ensiform appendix and the cartilages of the adjoining ribs, the fibres of the Diaphragm are deficient, the interval being filled by areolar tissue, covered on the thoracic side by the pleuræ; on the abdominal, by the peritoneum. This is, consequently, a weak point, and a portion of the contents of the abdomen may protrude into the chest, forming phrenic or diaphragmatic hernia, or a collection of pus in the mediastinum may descend through it, so as to point at the epigastrium.

The *ligamentum arcuatum internum* is a tendinous arch, thrown across the upper part of the *Psoas magnus* muscle, on each side of the spine. It is connected, by one end, to the outer side of the body of the first lumbar vertebra, being continuous with the outer side of the tendon of the corresponding crus; and, by the other end, to the front of the transverse process of the first and sometimes also to that of the second, lumbar vertebra.

The *ligamentum arcuatum externum* is the thickened upper margin of the anterior lamella of the lumbar fascia; it arches across the upper part of the *Quadratus lumborum*, being attached, by one extremity, to the front of the transverse process of the first lumbar vertebra; and, by the other, to the apex and lower margin of the last rib.

*The Crura.*—The Diaphragm is connected to the spine by two *crura* or *pillars*, which are situated on the bodies of the lumbar vertebræ, on each side of the aorta. The *crura*, at their origin, are tendinous in structure: the right crus, larger and longer than the left, arising from the anterior surface of the bodies and intervertebral substances of the three or four upper lumbar vertebræ; the left, from the two upper; both blending with the anterior common ligament of the spine. These tendinous portions of the *crura* pass forwards and inwards and gradually converge to meet in the middle line, forming an arch, beneath which passes the aorta, vena *azygos major*, and thoracic duct. From this tendinous arch muscular fibres arise, which diverge, the outermost portion being directed upwards and outwards to the central tendon; the innermost decussating in front of the aorta, and then diverging, so as to surround the œsophagus before ending in the central tendon. The fibres derived from the right crus are the most numerous, and pass in front of those derived from the left.

The *Central* or *Cordiform Tendon* of the Diaphragm is a thin but strong tendinous aponeurosis, situated at the centre of the vault formed by the muscle, immediately below the pericardium, with which its circumference is blended. It is shaped somewhat like a trefoil leaf, consisting of three divisions, or leaflets, separated from one another by slight indentations. The right leaflet is the largest; the middle one, directed towards the ensiform cartilage, the next in size; and the left, the smallest. In structure, the tendon is composed of several planes of fibres, which intersect one another at various angles, and unite



into straight or curved bundles—an arrangement which affords it additional strength.

The *Openings* connected with the Diaphragm are three large and several smaller apertures. The former are the aortic, the œsophageal, and the opening for the vena cava.

The *aortic opening* is the lowest and the most posterior of the three large apertures connected with this muscle, being at the level of the first lumbar vertebra. It is situated in the middle line, immediately in front of the bodies of the vertebræ; and is, therefore, *behind* the Diaphragm, not in it. It is an osseo-aponeurotic aperture, formed by a tendinous arch thrown across the front of the bodies of the vertebræ, from the *crus* on one side to that on the other, and transmits the aorta, vena azygos major, thoracic duct, and sometimes the left cord of the sympathetic. Occasionally some tendinous fibres are prolonged across the bodies of the vertebræ from the inner part of the lower end of the *crura*, passing behind the aorta, and thus converting the opening into a fibrous ring.

The *œsophageal opening* is situated at the level of the tenth dorsal vertebra; it is elliptical in form, muscular in structure, and, formed by the two *crura*, is placed above, and, at the same time, anterior, and a little to the left of the preceding. It transmits the œsophagus and pneumogastric nerves and some small œsophageal arteries. The anterior margin of this aperture is occasionally tendinous, being formed by the margin of the central tendon.

The *opening for the vena cava* (*foramen quadratum*) is the highest, about on the level of the disc between the eighth and ninth dorsal vertebræ; it is quadrilateral in form, tendinous in structure, and placed at the junction of the right and middle leaflets of the central tendon, its margins being bounded by four bundles of tendinous fibres, which meet at right angles.

The *right crus* transmits the sympathetic and the greater and lesser splanchnic nerves of the right side; the *left crus* transmits the sympathetic, when it does not pass through the aortic opening, the greater and lesser splanchnic nerves of the left side, and the vena azygos minor.

The *Serous Membranes* in relation with the Diaphragm are four in number: three lining its upper or thoracic surface; one, its abdominal. The three serous membranes on its upper surface are the pleura on either side, and the serous layer of the pericardium, which covers the middle portion of the tendinous centre. The serous membrane covering its under surface is a portion of the general peritoneal membrane of the abdominal cavity.

The Diaphragm is arched, being convex towards the chest, and concave to the abdomen. The *right portion* forms a complete arch from before backwards, being accurately moulded over the convex surface of the liver, and having resting upon it the concave base of the right lung. The *left portion* is arched from before backwards in a similar manner; but the arch is narrower in front, being encroached upon by the pericardium, and lower than the right, at its summit, by about three-quarters of an inch. It supports the base of the left lung, and covers the great end of the stomach, the spleen, and left kidney. At its circumference the Diaphragm is higher in the mesial line of the body than at either side; but in the middle of the thorax, the central portion, which supports the heart, is on a lower level than the two lateral portions.

**Nerves.**—The Diaphragm is supplied by the phrenic nerves and phrenic plexus of the sympathetic.

**Actions.**—The Intercostals are the chief agents in the movement of the ribs in ordinary respiration. When the first rib is elevated and fixed by the Scaleni, the External intercostals raise the other ribs, especially their fore part, and so increase the capacity of the chest from before backwards; at the same time they evert their lower borders, and so enlarge the thoracic cavity transversely. The Internal intercostals, at the side of the thorax, depress the ribs, and invert their lower borders, and so diminish the thoracic cavity; but at the fore part of

the chest these muscles assist the External intercostals in raising the cartilages.\* The Levatores costarum assist the External intercostals in raising the ribs. The Triangularis sterni draws down the costal cartilages; it is therefore an expiratory muscle.

The Diaphragm is the principal muscle of inspiration. When in a condition of rest the muscle presents a domed surface, concave towards the abdomen; and consists of a circumferential muscular and a central tendinous part. When the muscular fibres contract, they become less arched, or nearly straight, and thus cause the central tendon to descend, and in consequence the level of the chest wall is lowered, the vertical diameter of the chest being proportionately increased. In this descent the different parts of the tendon move unequally. The left leaflet descends to the greatest extent; the right to a less extent, on account of the liver; and the central leaflet the least, because of its connection to the pericardium. In descending the Diaphragm presses on the abdominal viscera, and so to a certain extent causes a projection of the abdominal wall; but in consequence of these viscera not yielding completely, the central tendon becomes a fixed point, and enables the circumferential muscular fibres to act *from* it, and so elevate the lower ribs and expand the lower part of the thoracic cavity; and Duchenne has shown that the Diaphragm has the power of elevating the ribs, to which it is attached, by its contraction, if the abdominal viscera are *in situ*, but that if these organs are removed, this power is lost. When at the end of inspiration, the Diaphragm relaxes, the thoracic walls return to their natural position in consequence of their elastic reaction and of the elasticity and weight of the displaced viscera.†

In all expulsive acts the Diaphragm is called into action, to give additional power to each expulsive effort. Thus, before sneezing, coughing, laughing, and crying; before vomiting; previous to the expulsion of the urine and fæces, or of the foetus from the womb, a deep inspiration takes place.

The height of the Diaphragm is constantly varying during respiration, the muscle being carried upwards or downwards from the average level; its height also varies according to the degree of distension of the stomach and intestines, and the size of the liver. After a forced expiration, the right arch is on a level, in front with the fourth costal cartilage; at the side, with the fifth, sixth, and seventh ribs; and behind with the eighth rib; the left arch being usually from one to two ribs' breadth below the level of the right one. In a forced inspiration, it descends from one to two inches; its slope would then be represented by a line drawn from the ensiform cartilage towards the tenth rib.

*Muscles of Inspiration and Expiration.*—The muscles which assist the action of the Diaphragm in ordinary tranquil inspiration are the Intercostals and the Levatores costarum, as above stated, and the Scaleni. When the need for more forcible action exists, the shoulders and the base of the scapula are fixed, and

\* The view of the action of the Intercostal muscles given in the text is that which is taught by Hutchinson (*Cycl. of Anat. and Phys.* art. 'Thorax'), and is usually adopted in our schools. It is, however, much disputed. Hamberger believed that the External intercostals act as elevators of the ribs, or muscles of inspiration, while the Internal act in expiration. Haller taught that both sets of muscles act in common—viz. as muscles of inspiration—and this view is adopted by many of the best anatomists of the Continent, and appears supported by many observations made on the human subject under various conditions of disease, and on living animals after the muscles have been exposed under chloroform. The reader may consult an interesting paper by Dr. Cleland in the *Journal of Anat. and Phys.* No. II., May 1867, p. 209, 'On the Hutchinsonian Theory of the Action of the Intercostal Muscles.' He refers to Henle, Luschka, Budge, and Bäumlér, *Observations on the Action of the Intercostal Muscles*. Erlangen, 1860. (In *New Syd. Soc.'s Year-Book for 1861*, p. 69.) Dr. W. W. Keen has come to the conclusion, from experiments made upon a criminal executed by hanging, that the External intercostals are muscles of expiration, as they pulled the ribs down, while the Internal intercostals pulled the ribs up, and are muscles of inspiration. (*Trans. Coll. Phys. Philadelphia*, Third Series, vol. i., 1875, p. 97.)

† For a detailed description of the general relations of the Diaphragm, and its action, refer to Dr. Sibson's *Medical Anatomy*.

then the powerful muscles of forced inspiration come into play; the chief of these are the Trapezius, the Pectoralis minor, the Serratus posticus superior and inferior, and the Rhomboidei. The lower fibres of the Serratus magnus may possibly assist slightly in dilating the chest by raising and everting the ribs. The Sterno-mastoid also, when the head is fixed, assists in forced inspiration, by drawing up the sternum, and by fixing the clavicle, and thus affording a fixed point for the action of the muscles of the chest. The Ilio-costalis and Quadratus lumborum assist in forced inspiration by fixing the last rib (see page 458).

The ordinary action of expiration is hardly effected by muscular force, but results from a return of the walls of the thorax to a condition of rest, owing to their own elasticity and to that of the lungs. Forced expiratory actions are performed mainly by the flat muscles (Obliqui and Transversalis) of the abdomen, assisted also by the Rectus. Other muscles of forced expiration are the Internal intercostals and Triangularis sterni (as above mentioned), the Quadratus lumborum, and the Ilio-costalis.

### III. MUSCLES OF THE ABDOMEN

The muscles of the abdomen may be divided into two groups:—1. The superficial muscles of the abdomen; and 2. The deep muscles of the abdomen.

#### 1. SUPERFICIAL MUSCLES

The Muscles in this region are, the

Obliquus Externus.

Obliquus Internus.

Pyramidalis.

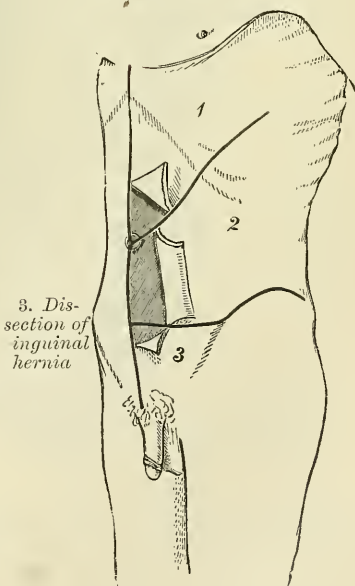
Transversalis.

Rectus.

*Dissection* (fig. 328).—To dissect the abdominal muscles, make a vertical incision from the ensiform cartilage to the symphysis pubis; a second incision from the umbilicus obliquely upwards and outwards to the outer surface of the chest, as high as the lower border of the fifth or sixth rib; and a third, commencing midway between the umbilicus and pubes, transversely outwards to the anterior superior iliac spine, and along the crest of the ilium as far as its posterior third. Then reflect the three flaps included between these incisions from within outwards, in the lines of direction of the muscular fibres. If necessary, the abdominal muscles may be made tense by inflating the peritoneal cavity through the umbilicus.

The **Superficial fascia** of the abdomen consists over the greater part of the abdominal wall of a single layer of fascia, which contains a variable amount of fat; but as this layer approaches the groin it is easily divisible into two layers, between which are found the superficial vessels and nerves and the superficial inguinal lymphatic glands. The superficial layer is thick, areolar in texture, containing adipose tissue in its meshes, the quantity of which varies in different subjects. Below it passes over Poupart's ligament, and is continuous with the outer layer of the superficial fascia of the thigh. In the male this fascia is continued over the penis and outer surface of

FIG. 328.—Dissection of abdomen.

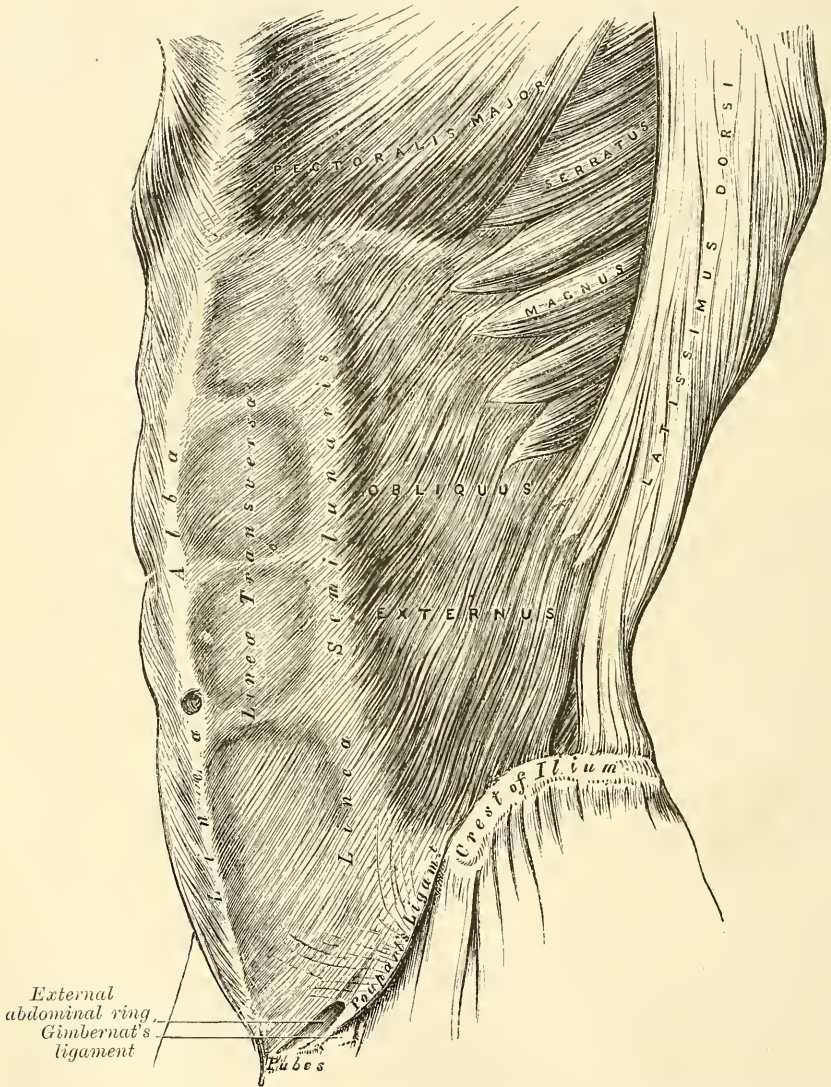


of the cord to the scrotum, where it helps to form the dartos. As it passes to the scrotum it changes its character, becoming thin, destitute of adipose tissue and of a pale reddish colour, and in the scrotum it acquires some involuntary muscular fibres. From the scrotum it may



be traced backwards to be continuous with the superficial fascia of the perinæum. In the female, this fascia is continued into the labia majora. The deeper layer (*fascia of Scarpa*) is thinner and more membranous in character than the superficial layer. In the middle line, it is intimately adherent to the linea alba and to the symphysis pubis, and is prolonged on to the dorsum of the penis, forming the suspensory ligament; above, it is continuous with the superficial fascia over the rest of the trunk; below, it blends with the fascia lata of the thigh a little below Poupart's ligament; and below and internally, it is continued over the penis and

FIG. 329.—The External oblique muscle.



spermatic cord to the scrotum, where it helps to form the dartos. From the scrotum it may be traced backwards to be continuous with the deep layer of the superficial fascia of the perinæum. In the female, it is continued into the labia majora.

The **External** or **Descending oblique muscle** (fig. 329) is situated on the side and fore part of the abdomen; being the largest and the most superficial of the three flat muscles in this region. It is broad, thin, and irregularly quadrilateral, its muscular portion occupying the side, its aponeurosis the anterior wall of the

abdomen. It arises, by eight fleshy digitations, from the external surface and lower borders of the eight inferior ribs; these digitations are arranged in an oblique line running downwards and backwards; the upper ones being attached close to the cartilages of the corresponding ribs; the lowest to the apex of the cartilage of the last rib; the intermediate ones, to the ribs at some distance from their cartilages. The five superior serrations increase in size from above downwards, and are received between corresponding processes of the *Serratus magnus*; the three lower ones diminish in size from above downwards, receiving between them corresponding processes from the *Latissimus dorsi*. From these attachments the fleshy fibres proceed in various directions. Those from the lowest ribs pass nearly vertically downwards, to be inserted into the anterior half of the outer lip of the crest of the ilium; the middle and upper fibres, directed downwards and forwards, terminate in an aponeurosis, opposite a line drawn from the prominence of the ninth costal cartilage to the anterior superior spinous process of the ilium.

The **Aponeurosis of the External oblique** is a thin but strong membranous aponeurosis, the fibres of which are directed obliquely downwards and inwards. It is joined with that of the opposite muscle along the median line, covers the whole of the front of the abdomen; above, it is connected with the lower border of the *Pectoralis major*; below, its fibres are closely aggregated together, and extend obliquely across from the anterior superior spine of the ilium to the spine of the os pubis and the *linea ilio-pectinea*. In the median line, it interlaces with the aponeurosis of the opposite muscle, forming the *linea alba*, which extends from the ensiform cartilage to the symphysis pubis.

That portion of the aponeurosis which extends between the anterior superior spine of the ilium and the spine of the os pubis is a broad band, folded inwards, and continuous below with the *fascia lata*; it is called *Poupart's ligament*. The portion which is reflected from *Poupart's ligament* at the spine of the os pubis along the pectineal line is called *Gimbernat's ligament*. From the point of attachment of the latter to the pectineal line, a few fibres pass upwards and inwards, behind the inner pillar of the ring, to the *linea alba*. They diverge as they ascend, and form a thin triangular fibrous layer, which is called the *triangular fascia of the abdomen*.

In the aponeurosis of the External oblique, immediately above the crest of the os pubis, is a triangular opening, the *external abdominal ring*, formed by a separation of the fibres of the aponeurosis in this situation.

**Relations.**—By its *external surface*, with the superficial fascia, superficial epigastric and circumflex iliac vessels, and some cutaneous nerves. By its *internal surface*, with the Internal oblique, the lower part of the eight inferior ribs, and Intercostal muscles, the Cremaster, the spermatic cord in the male, and round ligament in the female. Its *posterior border*, extending from the last rib to the crest of the ilium, is fleshy throughout and free; it is occasionally overlapped by the *Latissimus dorsi*, though generally a triangular interval exists between the two muscles near the crest of the ilium in which is seen a portion of the Internal oblique. This triangle, *Petit's triangle*, is therefore bounded in front by the External oblique, behind by the *Latissimus dorsi*, below by the crest of the ilium, while its floor is formed by the Internal oblique (fig. 324).

The following parts of the aponeurosis of the External oblique muscle require to be further described, viz. the external abdominal ring, the intercolumnar fibres and fascia, *Poupart's ligament*, *Gimbernat's ligament*, and the triangular ligament of the abdomen.

The **External abdominal ring**.—Just above, and to the outer side of the crest of the os pubis, an interval is seen in the aponeurosis of the External oblique, called the *External abdominal ring*. The aperture is oblique in direction, somewhat triangular in form, and corresponds with the course of the fibres of the aponeurosis. It usually measures from base to apex about an inch, and transversely about half an inch. It is bounded below by the crest of the os pubis;



above, by a series of curved fibres, the *intercolumnar*, which pass across the upper angle of the ring, so as to increase its strength; and on each side, by the margins of the opening in the aponeurosis, which are called the columns or pillars of the ring.

The external pillar, which is at the same time inferior from the obliquity of its direction, is the stronger; it is formed by that portion of Poupart's ligament which is inserted into the spine of the os pubis; it is curved so as to form a kind of groove, upon which the spermatic cord rests. The internal or superior pillar is a broad, thin, flat band which is attached to the front of the symphysis pubis, interlacing with its fellow of the opposite side, that of the right side being superficial.

The external abdominal ring gives passage to the spermatic cord in the male, and round ligament in the female: it is much larger in men than in women, on account of the large size of the spermatic cord, and hence the greater frequency of inguinal hernia in men.

The **intercolumnar fibres** are a series of curved tendinous fibres, which arch across the lower part of the aponeurosis of the External oblique. They have received their name from stretching across between the two pillars of the external ring, describing a curve with the convexity downwards. They are much thicker and stronger at the outer margin of the external ring, where they are connected to the outer third of Poupart's ligament, than internally, where they are inserted into the linea alba. They are more strongly developed in the male than in the female. The intercolumnar fibres increase the strength of the lower part of the aponeurosis, and prevent the divergence of the pillars from one another.

These intercolumnar fibres, as they pass across the external abdominal ring, are themselves connected together by delicate fibrous tissue, thus forming a fascia which, as it is attached to the pillars of the ring, covers it in, and is called the *intercolumnar fascia*. This **intercolumnar fascia** is continued down as a tubular prolongation around the outer surface of the cord and testis, and encloses them in a distinct sheath, hence it is also called the external spermatic fascia.

The sac of an inguinal hernia, in passing through the external abdominal ring, receives an investment from the intercolumnar fascia.

If the finger is introduced a short distance into the external abdominal ring and the limb is then extended and rotated outwards, the aponeurosis of the External oblique, together with the iliac portion of the fascia lata, will be felt to become tense, and the external ring much contracted; if the limb is on the contrary flexed upon the pelvis and rotated inwards, this aponeurosis will become lax and the external abdominal ring sufficiently enlarged to admit the finger with comparative ease; hence the patient should always be put in the latter position when the taxis is applied for the reduction of an inguinal hernia, in order that the abdominal walls may be relaxed as much as possible.

**Poupart's ligament**, or the **crural arch**, is the lower border of the aponeurosis of the External oblique muscle, which extends from the anterior superior spine of the ilium to the spine of the os pubis. From this latter point it is reflected outwards to be attached to the pectineal line for about half an inch, forming Gimbernat's ligament. Its general direction is curved downwards towards the thigh, where it is continuous with the fascia lata. Its outer half is rounded and oblique in direction. Its inner half gradually widens at its attachment to the os pubis, is more horizontal in direction, and lies beneath the spermatic cord.

Nearly the whole of the space included between the crural arch and the innominate bone is filled in by the parts which descend from the abdomen into the thigh. These will be referred to again on a subsequent page.

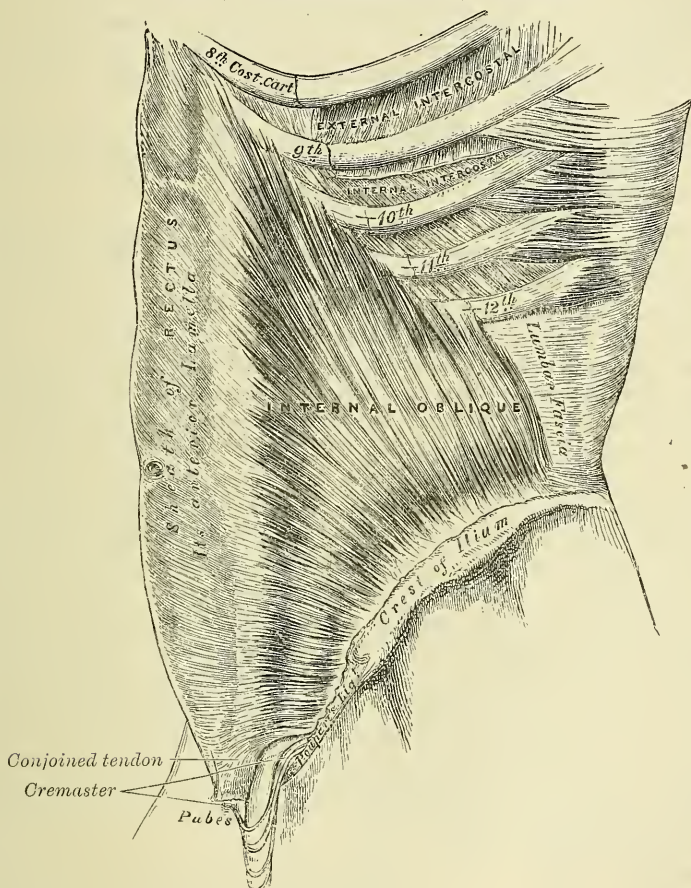
**Gimbernat's ligament** is that part of the aponeurosis of the External oblique muscle which is reflected downwards and outwards from the spine of the os pubis to be inserted into the pectineal line. It is about half an inch in length, larger in the male than in the female, almost horizontal in direction in the erect posture,



and of a triangular form with the base directed outwards. Its base, or outer margin, is concave, thin, and sharp, and lies in contact with the crural sheath; forming the inner boundary of the femoral ring. Its apex corresponds to the spine of the os pubis. Its posterior margin is attached to the pectineal line, and is continuous with the pubic portion of the fascia lata. Its anterior margin is continuous with Poupart's ligament.

The **triangular fascia** of the abdomen is a layer of tendinous fibres of a triangular shape, which is attached by its apex to the pectineal line, where it is continuous with Gimbernat's ligament. It passes inwards beneath the spermatic cord, and expands into a somewhat fan-shaped fascia, lying behind the inner

FIG. 330.—The Internal oblique muscle.



pillar of the external abdominal ring, and in front of the conjoined tendon, and interlaces with the ligament of the other side at the linea alba.

*Dissection.*—Detach the External oblique by dividing it across, just in front of its attachment to the ribs, as far as its posterior border, and separate it below from the crest of the ilium as far as the anterior superior spine; then separate the muscle carefully from the Internal oblique, which lies beneath, and turn it towards the opposite side.

The **Internal** or **Ascending oblique muscle** (fig. 330), thinner and smaller than the preceding, beneath which it lies, is of an irregularly quadrilateral form, and situated at the side and fore part of the abdomen. It arises, by fleshy fibres, from the outer half of Poupart's ligament, being attached to the groove on its upper surface; from the anterior two-thirds of the middle lip of the crest of the ilium, and from the posterior lamella of the lumbar fascia. From this origin the fibres diverge: those from Poupart's ligament, few in number, and paler in colour

than the rest, arch downwards and inwards across the spermatic cord in the male and the round ligament in the female, and, becoming tendinous, are inserted, conjointly with those of the Transversalis, into the crest of the os pubis and pectineal line, to the extent of half an inch, forming what is known as the conjoined tendon of the Internal oblique and Transversalis; those from the anterior third of the iliac origin are horizontal in their direction, and, becoming tendinous along the lower fourth of the linea semilunaris, pass in front of the Rectus muscle to be inserted into the linea alba; those which arise from the middle third of the origin from the crest of the ilium pass obliquely upwards and inwards, and terminate in an aponeurosis, which divides at the outer border of the Rectus muscle into two lamellæ, which are continued forwards, in front and behind this muscle to the linea alba: the posterior lamella being also connected to the cartilages of the seventh, eighth, and ninth ribs; the most posterior fibres pass almost vertically upwards, to be inserted into the lower borders of the cartilages of the three lower ribs, being continuous with the Internal intercostal muscles.

The conjoined tendon of the Internal oblique and Transversalis is inserted into the crest of the os pubis and pectineal line, immediately behind the external abdominal ring, serving to protect what would otherwise be a weak point in the abdominal wall. Sometimes this tendon is insufficient to resist the pressure from within, and is carried forward in front of the protrusion through the external ring, forming one of the coverings of direct inguinal hernia; or the hernia forces its way through the fibres of the conjoined tendon.

The aponeurosis of the Internal oblique is continued forward to the middle line of the abdomen, where it joins with the aponeurosis of the opposite muscle at the linea alba, and extends from the margin of the thorax to the os pubis. At the outer margin of the Rectus muscle, this aponeurosis, for the upper three-fourths of its extent, divides into two lamellæ, which pass, one in front and the other behind the muscle, enclosing it in a kind of sheath, and reuniting on its inner border at the linea alba; the anterior layer is blended with the aponeurosis of the External oblique muscle; the posterior layer with that of the Transversalis. Along the lower fourth, the aponeurosis passes altogether in front of the Rectus without any separation. Where the aponeurosis ceases to split, and passes altogether in front of the Rectus muscle, a deficiency is left in the sheath of the muscle behind; this is marked above by a sharp lunated margin, having its concavity downwards. This is known as the *semilunar fold of Douglas*.

**Relations.**—By its *external surface*, with the External oblique, Latissimus dorsi, spermatic cord, and external ring. By its *internal surface*, with the Transversalis muscle, the lower intercostal vessels and nerves, the ilio-hypogastric and the ilio-inguinal nerves. Near Poupart's ligament, it lies on the fascia transversalis, internal ring, and spermatic cord. Its lower border forms the upper boundary of the spermatic canal.

The **Cremaster muscle** is a thin muscular layer, composed of a number of fasciculi which arise from the inner part of Poupart's ligament where its fibres are continuous with those of the Internal oblique and also occasionally with the Transversalis. It passes along the outer side of the spermatic cord, descends with it through the external abdominal ring upon the front and sides of the cord, and forms a series of loops which differ in thickness and length in different subjects. Those at the upper part of the cord are exceedingly short, but they become in succession longer and longer, the longest reaching down as low as the testicle, where a few are inserted into the tunica vaginalis. These loops are united together by areolar tissue, and form a thin covering over the cord and testis, the *fascia cremasterica*. The fibres ascend along the inner side of the cord, and are inserted by a small pointed tendon into the crest of the os pubis and front of the sheath of the Rectus muscle.

It will be observed that the origin and insertion of the Cremaster is precisely similar to that of the lower fibres of the Internal oblique. This fact affords an



easy explanation of the manner in which the testicle and cord are invested by this muscle. At an early period of foetal life the testis is placed at the lower and back part of the abdominal cavity, but during its descent towards the scrotum, which takes place before birth, it passes beneath the arched fibres of the Internal oblique. In its passage beneath this muscle some fibres are derived from its lower part which accompany the testicle and cord into the scrotum. It occasionally happens that the loops of the Cremaster surround the cord, some lying behind as well as in front. It is probable that under these circumstances the testis, in its descent, passed through instead of beneath the fibres of the Internal oblique.

In the descent of an oblique inguinal hernia, which takes the same course as the spermatic cord, the Cremaster muscle forms one of its coverings. This muscle becomes largely developed in cases of hydrocele and large, old scrotal hernia. The Cremaster muscle is only found in the male, but almost constantly in the female a few muscular fibres may be found on the surface of the round ligament, which correspond to this muscle, and in cases of oblique inguinal hernia in the female a considerable amount of muscular fibre may be found covering the sac.

*Dissection.*—Detach the Internal oblique in order to expose the Transversalis beneath. This may be effected by dividing the muscle above, at its attachment to the ribs; below, at its connection with Poupart's ligament and the crest of the ilium; and behind, by a vertical incision extending from the last rib to the crest of the ilium. The muscle should previously be made tense by drawing upon it with the fingers of the left hand, and if its division is carefully effected, the cellular interval between it and the Transversalis, as well as the direction of the fibres of the latter muscle, will afford a clear guide to their separation; along the crest of the ilium the circumflex iliac vessels are interposed between them, and form an important guide in separating them. The muscle should then be thrown inwards towards the linea alba.

The **Transversalis muscle** (fig. 331), so called from the direction of its fibres, is the most internal flat muscle of the abdomen, being placed immediately beneath the Internal oblique. It arises by fleshy fibres from the outer third of Poupart's ligament; from the inner lip of the crest of the ilium, for its anterior three-fourths; from the inner surface of the cartilages of the six lower ribs, interdigitating with the Diaphragm; and by the lumbar fascia from the spinous and transverse processes of the lumbar vertebræ. The muscle terminates in front in a broad aponeurosis, the lower fibres of which curve downwards and inwards, and are inserted, together with those of the Internal oblique, into the lower part of the linea alba, the crest of the os pubis and pectineal line, forming what is known as the conjoined tendon of the Internal oblique and Transversalis. Throughout the rest of its extent the aponeurosis passes horizontally inwards, and is inserted into the linea alba; its upper three-fourths passing behind the Rectus muscle, blending with the posterior lamella of the Internal oblique; its lower fourth passing in front of the Rectus.

*Relations.*—By its *external surface*, with the Internal oblique, and the inner surface of the cartilages of the lower ribs. By its *internal surface*, with the fascia transversalis, which separates it from the peritoneum. Its lower border forms the upper boundary of the spermatic canal.

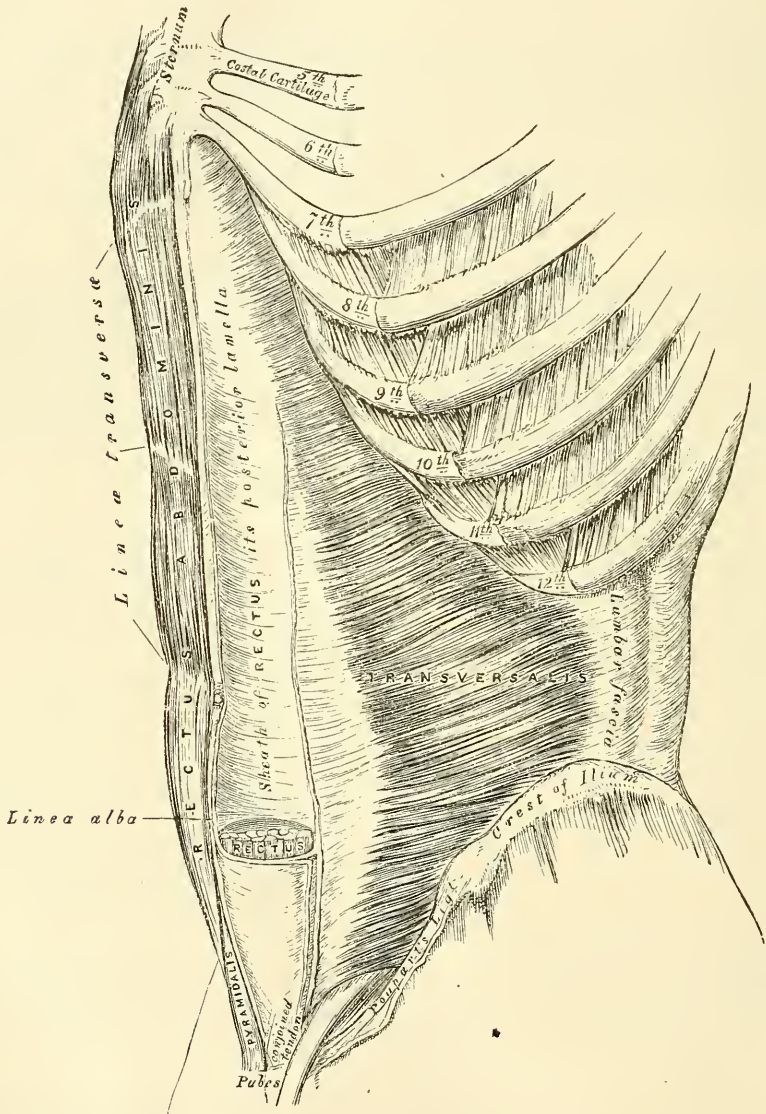
*Dissection.*—To expose the Rectus muscle, open its sheath by a vertical incision extending from the margin of the thorax to the os pubis, and then reflect the two portions from the surface of the muscle, which is easily done, excepting at the lineæ transversæ, where so close an adhesion exists that the greatest care is requisite in separating them. Now raise the outer edge of the muscle, in order to examine the posterior layer of the sheath. By dividing the muscle in the centre, and turning its lower part downwards, the point where the posterior wall of the sheath terminates in a thin curved margin will be seen.

The **Rectus abdominis** is a long flat muscle, which extends along the whole length of the front of the abdomen, being separated from its fellow of the



opposite side by the *linea alba*. It is much broader, but thinner, above than below, and arises by two tendons, the external or larger being attached to the crest of the os pubis; the internal, smaller portion, interlacing with its fellow of the opposite side, and being connected with the ligaments covering the front of the symphysis pubis. The fibres ascend, and the muscle is inserted by three portions of unequal size into the cartilages of the fifth, sixth, and seventh ribs. The upper portion, attached principally to the cartilage of the fifth rib, also

FIG. 331.—The Transversalis, Rectus, and Pyramidalis muscles.



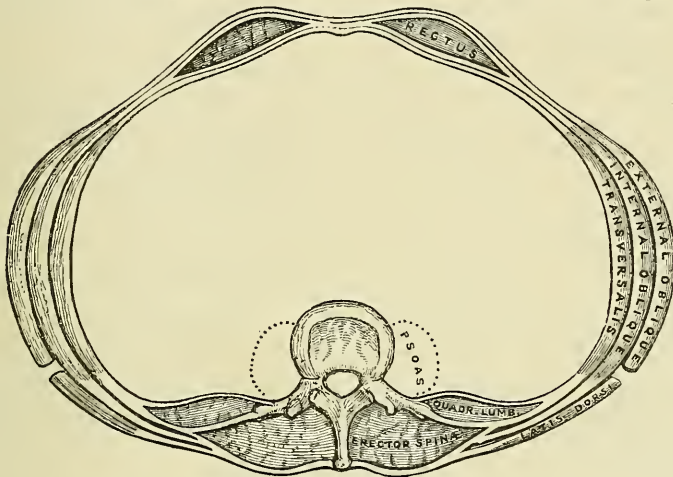
usually has some fibres of insertion into the anterior extremity of the rib itself. Some fibres are occasionally connected with the costo-xiphoid ligaments, and side of the ensiform cartilage.

The Rectus muscle is traversed by tendinous intersections, three in number, which have received the name of *linea transversæ*. One of these is usually situated opposite the umbilicus, and two above that point; of the latter, one corresponds to the extremity of the ensiform cartilage, and the other is about

midway between the ensiform cartilage and the umbilicus. These intersections pass transversely or obliquely across the muscle in a zigzag course; they rarely extend completely through its substance, sometimes pass only half-way across it, and are intimately adherent in front to the sheath in which the muscle is enclosed. Sometimes one or two additional lines may be seen, one usually below the umbilicus; the position of the other, where it exists, is variable. These additional lines are for the most part incomplete.

The Rectus is enclosed in a sheath (fig. 332) formed by the aponeuroses of the Oblique and Transversalis muscles, which are arranged in the following manner. When the aponeurosis of the Internal oblique arrives at the outer margin of the Rectus, it divides into two lamellæ, one of which passes in front of the Rectus, blending with the aponeurosis of the External oblique; the other, behind it, blending with the aponeurosis of the Transversalis; and these, joining again at its inner border, are inserted into the linea alba. This arrangement of the aponeurosis exists along the upper three-fourths of the muscle: at the commencement of the lower fourth, the posterior wall of the sheath terminates in a thin curved margin, the *semilunar fold of Douglas*, the concavity of which looks downwards towards the pubes: the aponeuroses of all three muscles passing in

FIG. 332.—A transverse section of the abdomen in the lumbar region.



front of the Rectus without any separation. The extremities of the fold of Douglas descend as pillows to the os pubis. The inner pillar is attached to the symphysis pubis; the outer pillar, which is named by Braune the ligament of Hesselbach, divides below to enclose the internal abdominal ring; the internal fibres are attached to the ascending ramus of the os pubis and the pectineal fascia; the external ones pass to the Psoas fascia and to the Transversalis where it arises from Poupart's ligament on the outer side of the ring. The Rectus muscle, in the situation where its sheath is deficient, is separated from the peritoneum by the transversalis fascia.

The **Pyramidalis** is a small muscle, triangular in shape, placed at the lower part of the abdomen, in front of the Rectus, and contained in the same sheath with that muscle. It arises by tendinous fibres from the front of the os pubis and the anterior pubic ligament; the fleshy portion of the muscle passes upwards, diminishing in size as it ascends, and terminates by a pointed extremity, which is inserted into the linea alba, midway between the umbilicus and the os pubis. This muscle is sometimes found wanting on one or both sides; the lower end of the Rectus then becomes proportionately increased in size. Occasionally it has been found double on one side, or the muscles of the two sides are of unequal size. Sometimes its length exceeds what is stated above.

**Nerves.**—The abdominal muscles are supplied by the lower intercostal nerves. The Internal oblique also receives a filament from the ilio-inguinal nerve. The Cremaster is supplied by the genital branch of the Genito-crural.

In the description of the abdominal muscles, mention has frequently been made of the *linea alba*, *lineæ semilunares*, and *lineæ transversæ*; when the dissection of the muscles is completed, these structures should be examined.

The **linea alba** is a tendinous raphé seen along the middle line of the abdomen, extending from the ensiform cartilage to the symphysis pubis, to which it is attached. It is placed between the inner borders of the Recti muscles, and is formed by the blending of the aponeuroses of the Obliqui and Transversales muscles. It is narrow below, corresponding to the narrow interval existing between the Recti; but broader above, as these muscles diverge from one another in their ascent, becoming of considerable breadth after great distension of the abdomen from pregnancy or ascites. It presents numerous apertures for the passage of vessels and nerves; the largest of these is the umbilicus, which in the fœtus transmits the umbilical vessels, but in the adult is obliterated, the cicatrix being stronger than the neighbouring parts; hence umbilical hernia occurs in the adult *near* the umbilicus, whilst in the fœtus it occurs *at* the umbilicus. The *linea alba* is in relation, in front, with the integument, to which it is adherent, especially at the umbilicus; behind, it is separated from the peritoneum by the transversalis fascia; and below, by the urachus, and the bladder when that organ is distended.

The **lineæ semilunares** are two curved tendinous lines placed one on each side of the *linea alba*. Each corresponds with the outer border of the Rectus muscle, extends from the cartilage of the ninth rib to the pubic spine, and is formed by the aponeurosis of the Internal oblique at its point of division to enclose the Rectus, where it is reinforced in front by the External oblique, and behind by the Transversalis.

The **lineæ transversæ** are narrow transverse lines which intersect the Recti muscles, as already mentioned; they connect the *lineæ semilunares* with the *linea alba*.

**Actions.**—The abdominal muscles perform a threefold action.

When the pelvis and thorax are fixed, they compress the abdominal viscera, by constricting the cavity of the abdomen, in which action they are materially assisted by the descent of the diaphragm. By these means assistance is given in expelling the fœtus from the uterus, the fæces from the rectum, the urine from the bladder, and the contents of the stomach in vomiting.

If the pelvis and spine are fixed, these muscles compress the lower part of the thorax, materially assisting expiration. If the pelvis alone is fixed, the thorax is bent directly forward, when the muscles of both sides act, or to either side when those of the two sides act alternately, rotation of the trunk at the same time taking place to the opposite side.

If the thorax is fixed, these muscles, acting together, draw the pelvis upwards, as in climbing; or, acting singly, they draw the pelvis upwards, and bend the vertebral column to one side or the other. The Recti muscles, acting from below, depress the thorax, and consequently flex the vertebral column; when acting from above, they flex the pelvis upon the vertebral column. The Pyramidales are tensors of the *linea alba*.

The **fascia transversalis** is a thin aponeurotic membrane which lies between the inner surface of the Transversalis muscle and the peritoneum. It forms part of the general layer of fascia which lines the interior of the abdominal and pelvic cavities, and is directly continuous with the iliac and pelvic fasciæ. In the inguinal region, the transversalis fascia is thick and dense in structure and joined by fibres from the aponeurosis of the Transversalis muscle, but it becomes thin and cellular as it ascends to the Diaphragm, and blends with the fascia covering this muscle. In front, it unites across the middle line with the fascia on the opposite side of the body, and behind it becomes lost in the fat which



covers the posterior surfaces of the kidneys. Below, it has the following attachments: posteriorly, it is connected to the whole length of the crest of the ilium, between the attachments of the Transversalis and Iliacus muscles; between the anterior superior spine of the ilium and the femoral vessels it is connected to the posterior margin of Poupart's ligament, and is there continuous with the iliac fascia. Internal to the femoral vessels it is thin and attached to the os pubis and pectineal line, behind the conjoined tendon, with which it is united; and, corresponding to the point where the femoral vessels pass into the thigh, this fascia descends in front of them, forming the anterior wall of the crural sheath. Beneath Poupart's ligament it is strengthened by a dense band of fibrous tissue, which is only loosely connected to Poupart's ligament, and is specialised as the *deep crural arch*. The spermatic cord in the male and the round ligament in the female pass through this fascia; the point where they pass through is called the *internal abdominal ring*. This opening is not visible externally owing to a prolongation of the transversalis fascia on these structures, forming the infundibuliform process.

The **Internal or deep abdominal ring** is situated in the transversalis fascia, midway between the anterior superior spine of the ilium and the symphysis pubis, and about half an inch above Poupart's ligament. It is of an oval form, the extremities of the oval directed upwards and downwards, varies in size in different subjects, and is much larger in the male than in the female. It is bounded, above and externally, by the arched fibres of the Transversalis; below and internally, by the deep epigastric vessels. It transmits the spermatic cord in the male and the round ligament in the female. From its circumference a thin funnel-shaped membrane, the *infundibuliform fascia*, is continued round the cord and testis, enclosing them in a distinct pouch.

When the sac of an oblique inguinal hernia passes through the internal or deep abdominal ring, the infundibuliform process of the transversalis fascia forms one of its coverings.

The **inguinal or spermatic canal** contains the spermatic cord in the male and the round ligament in the female. It is an oblique canal about an inch and a half in length, directed downwards and inwards, and placed parallel to and a little above Poupart's ligament. It commences above at the internal or deep abdominal ring, which is the point where the cord enters the spermatic canal, and terminates below at the external ring. It is bounded in front by the integument and superficial fascia, by the aponeurosis of the External oblique throughout its whole length, and by the Internal oblique for its outer third; behind, by the triangular fascia, the conjoined tendon of the Internal oblique and Transversalis, transversalis fascia, and the subperitoneal fat and peritoneum; above, by the arched fibres of the Internal oblique and Transversalis; below, by the union of the fascia transversalis with Poupart's ligament.

That form of protrusion in which the intestine follows the course of the spermatic cord along the spermatic canal is called oblique inguinal hernia.

The **deep crural arch**.—Curving over the vessels, just at the point where they become femoral, on the abdominal side of Poupart's ligament and loosely connected with it, is a thickened band of fibres called the deep crural arch. It is apparently a thickening of the fascia transversalis, joining externally to the centre of Poupart's ligament, and arching across the front of the crural sheath to be inserted by a broad attachment into the spine of the os pubis and ilio-pectineal line, behind the conjoined tendons. In some subjects this structure is not very prominently marked, and not unfrequently it is altogether wanting.

*Surface Form*.—The only two muscles of this group which have any considerable influence on surface form are the External oblique and Rectus muscles of the abdomen. With regard to the External oblique, the upper digitations of its origin from the ribs are well marked, intermingled with the serrations of the Serratus magnus; the lower digitations are not visible, being covered by the thick border of the Latissimus dorsi. Its attachment to the

crest of the ilium, in conjunction with the Internal oblique, forms a thick oblique roll, which determines the iliac furrow. Sometimes on the front of the lateral region of the abdomen an undulating outline marks the spot where the muscular fibres terminate and the aponeurosis commences. The outer border of the Rectus is defined by the *linea semi-lunaris*, which may be exactly defined by putting the muscle into action. It corresponds with a curved line, with its convexity outwards, drawn from the end of the cartilage of the ninth rib to the spine of the os pubis, so that the centre of the line, at or near the umbilicus, is three inches from the median line. The inner border of the Rectus corresponds to the *linea alba*, marked on the surface of the body by a groove, the *abdominal furrow*, which extends from the infrasternal fossa to, or to a little below, the umbilicus, where it gradually becomes lost. The surface of the Rectus presents three transverse furrows, the *lineæ transversæ*. The upper two of these, one opposite or a little below the tip of the ensiform cartilage, and another, midway between this point and the umbilicus, are usually well marked; the third, opposite the umbilicus, is not so distinct. The umbilicus, situated in the *linea alba*, varies very much in position as regards its height. It is always situated above a zone drawn round the body opposite the highest point of the crest of the ilium, generally being about three-quarters of an inch to an inch above this line. It generally corresponds, therefore, to the fibro-cartilage between the third and fourth lumbar vertebræ.

## 2. DEEP MUSCLES OF THE ABDOMEN

Psoas parvus.

Iliacus.

Psoas magnus.

Quadratus lumborum.

The Psoas magnus, the Psoas parvus, and the Iliacus muscles, with the fascia covering them, will be described with the Muscles of the Lower Extremity (see page 507).

**The fascia covering the Quadratus lumborum.**—This is the most internal of the two layers of fascia which are given off from the anterior or deep surface of the lumbar fascia. It is a thin layer of fascia which, passing over the anterior surface of the Quadratus lumborum, is attached, internally, to the anterior surface of the transverse processes of the lumbar vertebræ; below, to the ilio-lumbar ligament; and above, to the apex and lower border of the last rib.

The portion of this fascia which extends from the transverse process of the first lumbar vertebra to the apex and lower border of the last rib, constitutes the *ligamentum arcuatum externum*.

The **Quadratus lumborum** (fig. 325, page 433) is situated in the lumbar region. It is irregularly quadrilateral in shape, and broader below than above. It arises by aponeurotic fibres from the ilio-lumbar ligament and the adjacent portion of the crest of the ilium for about two inches, and is inserted into the lower border of the last rib for about half its length and, by four small tendons, into the apices of the transverse processes of the four upper lumbar vertebræ. Occasionally a second portion of this muscle is found situated in front of the preceding. It arises from the upper borders of the transverse processes of three or four of the lower lumbar vertebræ, and is inserted into the lower margin of the last rib. The Quadratus lumborum is contained in a sheath formed by the anterior and middle lamellæ of the lumbar fasciæ.

**Relations.**—Its *anterior surface* (or rather the fascia which covers its anterior surface) is in relation with the colon, the kidney, the Psoas muscle, and the Diaphragm. Its *posterior surface* is in relation with the middle lamella of the lumbar fascia, which separates it from the Erector spinæ. The Quadratus lumborum extends, however, beyond the outer border of the Erector spinæ.

**Nerve-supply.**—The anterior branches of the last dorsal and first lumbar nerves.

**Actions.**—The Quadratus lumborum draws down the last rib, and acts as a muscle of forced expiration; but, at the same time, by fixing the last rib it opposes the tendency of the Diaphragm to draw it upwards, and thus it becomes an assistant to inspiration. If the thorax and spine are fixed, it may act upon the pelvis, raising it towards its own side when only one muscle is put in action; and when both muscles act together, either from below or above, they flex the trunk.

## IV. MUSCLES OF THE PELVIC OUTLET

The muscles of this region are situated at the pelvic outlet in the ischio-rectal region and the perinæum. They include the following :

I. Muscles of the ischio-rectal region.

II. Muscles of the perinæum: A. In the Male; B. In the Female.

## I. MUSCLES OF THE ISCHIO-RECTAL REGION

Corrugator cutis ani.

Internal sphincter ani.

External sphincter ani.

Levator ani.

Coccygeus.

**The Corrugator cutis ani.**—Around the anus is a thin stratum of involuntary muscular fibre, which surrounds it in a radiating manner. Internally, the fibres fade off into the submucous tissue, whilst externally they blend with the true skin. By its contraction it raises the skin into ridges radiating from the margin of the anus.

The **External sphincter ani** is a thin, flat plane of muscular fibres, elliptical in shape and intimately adherent to the integument surrounding the margin of the anus. It measures about three or four inches in length, from its anterior to its posterior extremity, being about an inch in breadth, opposite the anus. It arises from the tip of the coccyx, by a narrow tendinous band, and from the superficial fascia in front of that bone; and is inserted into the central tendinous point of the perinæum, joining with the *Transversus perinæi*, the *Levator ani*, and the *Accelerator urinæ*. Like other sphincter muscles, it consists of two planes of muscular fibre, which surround the margin of the anus, and join in a commissure in front and behind, some fibres crossing from side to side in front and behind the anus.

**Nerve-supply.**—A branch from the anterior division of the fourth sacral and the inferior hæmorrhoidal branch of the internal pudic.

**Actions.**—The action of this muscle is peculiar: 1. It is, like other muscles, always in a state of tonic contraction, and having no antagonistic muscle it keeps the anal orifice closed. 2. It can be put into a condition of greater contraction under the influence of the will, so as to more firmly occlude the anal aperture in other expiratory efforts, unconnected with defæcation. 3. Taking its fixed point at the coccyx, it helps to fix the central point of the perinæum, so that the *Accelerator* may act from this fixed point.

The **Internal sphincter** is a muscular ring which surrounds the lower extremity of the rectum for about an inch; its inferior border being contiguous to, but quite separate from, the *External sphincter*. This muscle is about two lines in thickness, and is formed by an aggregation of the involuntary circular fibres of the intestine. It is paler in colour and less coarse in texture than the *External sphincter*.

**Actions.**—Its action is entirely involuntary. It helps the *External sphincter* to occlude the anal aperture.

The **Levator ani** (fig. 333) is a broad, thin muscle, situated on each side of the pelvis. It is attached to the inner surface of the sides of the true pelvis, and descending unites with its fellow of the opposite side to form the floor of the pelvic cavity. It supports the viscera in this cavity and surrounds the various structures which pass through it. It arises, in front, from the posterior surface of the body of the os pubis on the outer side of the symphysis; posteriorly, from the inner surface of the spine of the ischium; and between these two points, from the angle of division between the obturator and recto-vesical layers of the pelvic fascia at their under part. The fibres pass downwards to the middle line of the floor of the pelvis, and are inserted, the most posterior into the sides of the apex of the coccyx; those placed more anteriorly unite with the muscle of





spine of the ischium and lesser sacro-sciatic ligament, and inserted, by its base, into the margin of the coccyx and into the side of the lower piece of the sacrum. It assists the Levator ani and Pyriformis in closing in the back part of the outlet of the pelvis.

**Relations.**—By its *inner* or *pelvic surface*, with the rectum. By its *external surface*, with the lesser sacro-sciatic ligament. The *lower border* is in relation with the posterior border of the Levator ani, but separated from it by a cellular interval: its *upper border* is in relation with the lower border of the Pyriformis, but separated from it by the sciatic and internal pudic vessels and nerve.

**Nerve-supply.**—A branch from the fourth and fifth sacral nerves.

**Action.**—The Coccygei muscles raise and support the coccyx, after it has been pressed backwards during defæcation or parturition.

## II. A. MUSCLES AND FASCIÆ OF THE PERINÆUM IN THE MALE

Transversus perinæi.

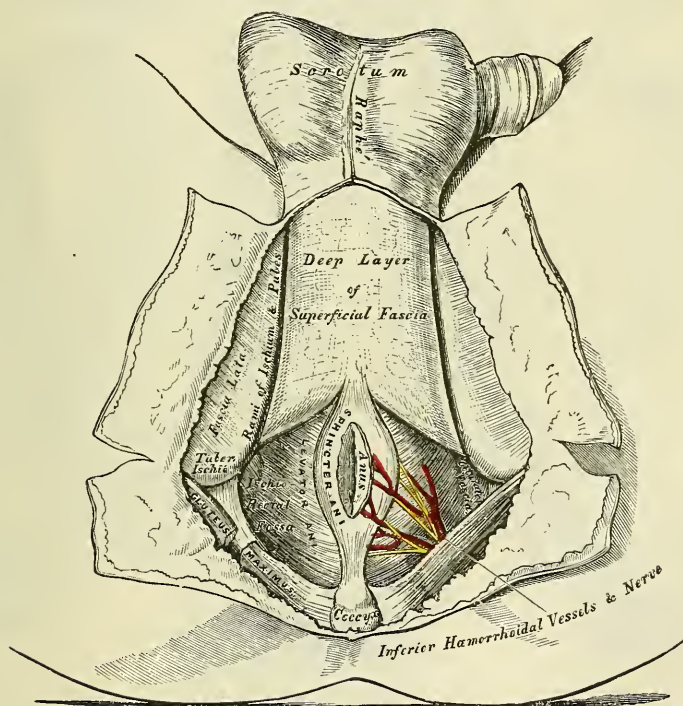
Erector penis.

Accelerator urinæ.

Compressor urethræ.

**Superficial fascia.**—The superficial fascia of the perinæum consists of two layers, superficial and deep, as in other regions of the body.

FIG. 334.—The perinæum. The integument and superficial layer of superficial fascia reflected.



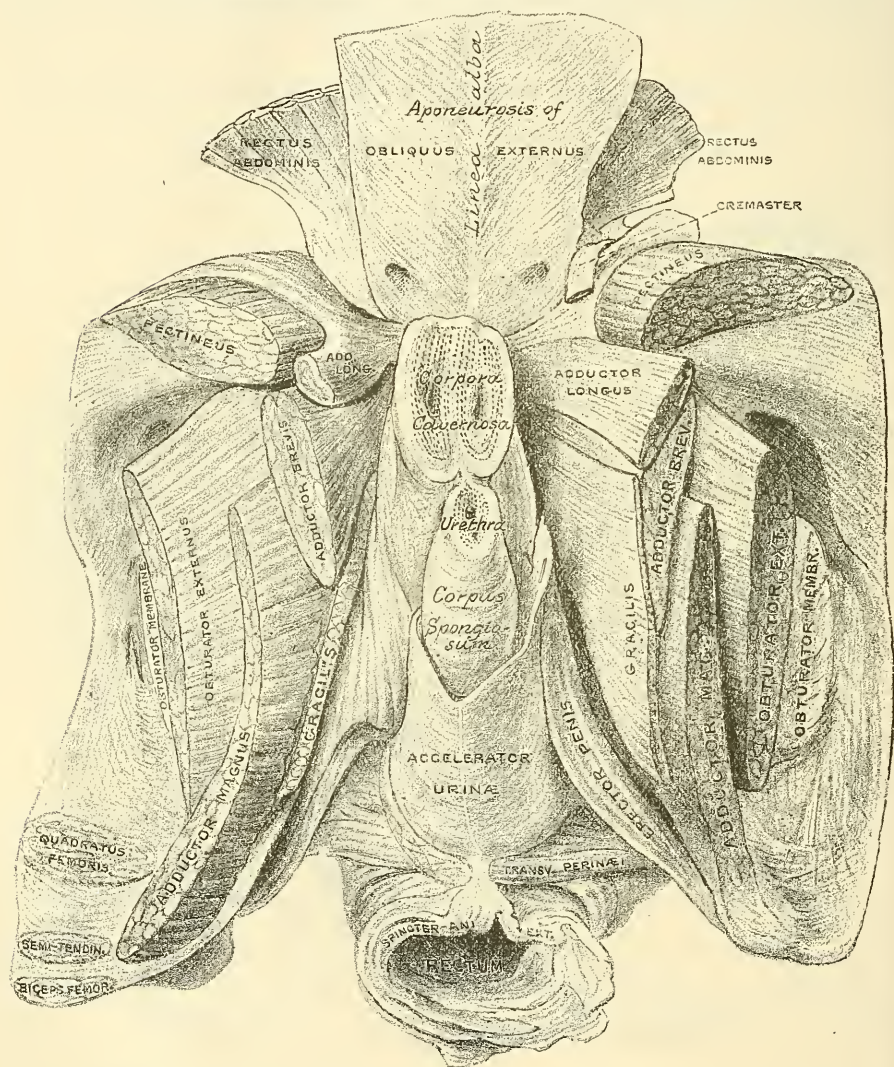
The *superficial layer* is thick, loose, areolar in texture, and contains much adipose tissue in its meshes, the amount of which varies in different subjects. In front, it is continuous with the dartos of the scrotum; behind, it is continuous with the subcutaneous areolar tissue surrounding the anus; and, on either side, with the same fascia on the inner side of the thighs. This layer should be carefully removed after it has been examined, when the deep layer will be exposed.

The *deep layer of superficial fascia* (Fascia of Colles) is thin, aponeurotic in structure, and of considerable strength, serving to bind down the muscles of



the root of the penis. It is continuous, in front, with the dartos of the scrotum ; on either side it is firmly attached to the margins of the rami of the os pubis and ischium, external to the crus penis, and as far back as the tuberosity of the ischium ; posteriorly, it curves down behind the *Transversus perinæi* muscle to join the lower margin of the deep perineal fascia. This fascia not only covers the muscles in this region, but sends down a vertical septum from its under surface, which separates the back part of the subjacent space into two, being incomplete in front.

FIG. 335.—The muscles attached to the front of the pelvis. (From a preparation in the Museum of the Royal College of Surgeons of England.)



**The central tendinous point of the Perinæum.**—This is a fibrous point in the middle line of the perinæum, between the urethra and the rectum, being about half an inch in front of the anus. At this point four muscles converge and are attached: viz. the External sphincter ani, the Accelerator urinæ, and the two *Transversus perinæi*; so that by the contraction of these muscles, which extend in opposite directions, it serves as a fixed point of support.

The ***Transversus perinæi*** is a narrow muscular slip, which passes more or less transversely across the back part of the perineal space. It arises by a small



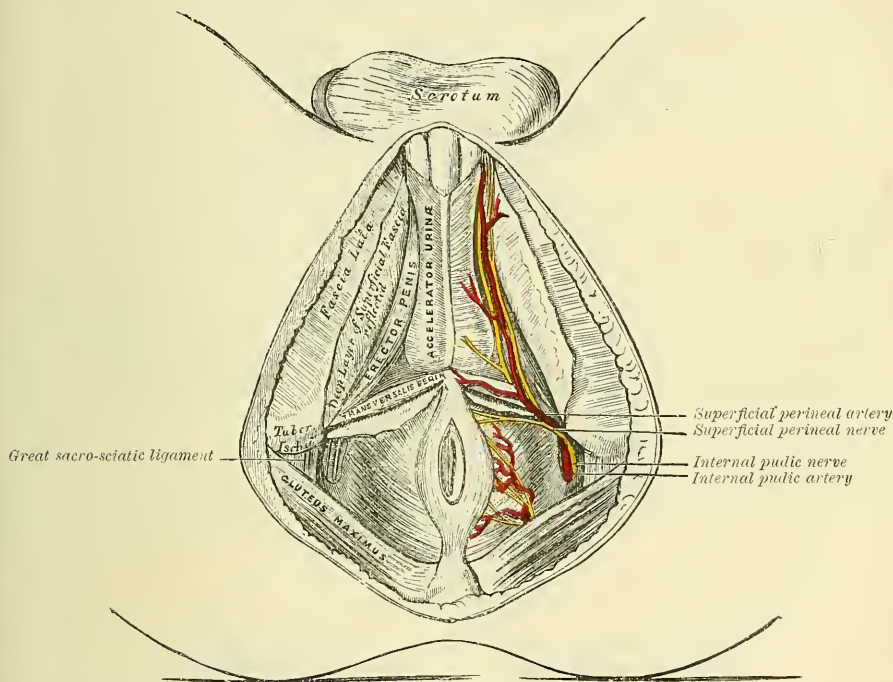
tendon from the inner and fore part of the tuberosity of the ischium, and, passing inwards, is inserted into the central tendinous point of the perinæum, joining in this situation with the muscle of the opposite side, the External sphincter ani behind, and the Accelerator urinæ in front.

**Nerve-supply.**—The perineal branch of the internal pudic.

**Actions.**—By their contraction they serve to fix the central tendinous point of the perinæum.

The **Accelerator urinæ** (*Ejaculator seminis*, or *Bulbo-cavernosus*) is placed in the middle line of the perinæum, immediately in front of the anus. It consists of two symmetrical halves, united along the median line by a tendinous raphé. It arises from the central tendon of the perinæum, and from the median raphé in front. From this point its fibres diverge like the plumes of a pen; the most posterior form a thin layer, which are lost on the anterior surface of the triangular ligament; the middle fibres encircle the bulb and adjacent parts of the corpus

FIG. 336.—The superficial muscles and vessels of the perinæum.



spongiosum, and join with the fibres of the opposite side, on the upper part of the corpus spongiosum, in a strong aponeurosis; the anterior fibres, the longest and most distinct, spread out over the sides of the corpus cavernosum, to be inserted partly into that body, anterior to the Erector penis, occasionally extending to the os pubis; partly terminating in a tendinous expansion, which covers the dorsal vessels of the penis. The latter fibres are best seen by dividing the muscle longitudinally, and dissecting it outwards from the surface of the urethra.

**Action.**—This muscle serves to empty the canal of the urethra, after the bladder has expelled its contents; during the greater part of the act of micturition its fibres are relaxed, and it only comes into action at the end of the process. The middle fibres are supposed, by Krause, to assist in the erection of the corpus spongiosum, by compressing the erectile tissue of the bulb. The anterior fibres, according to Tyrrel, also contribute to the erection of the penis, as they are inserted into, and continuous with, the fascia of the penis, compressing the dorsal vein during the contraction of the muscle.

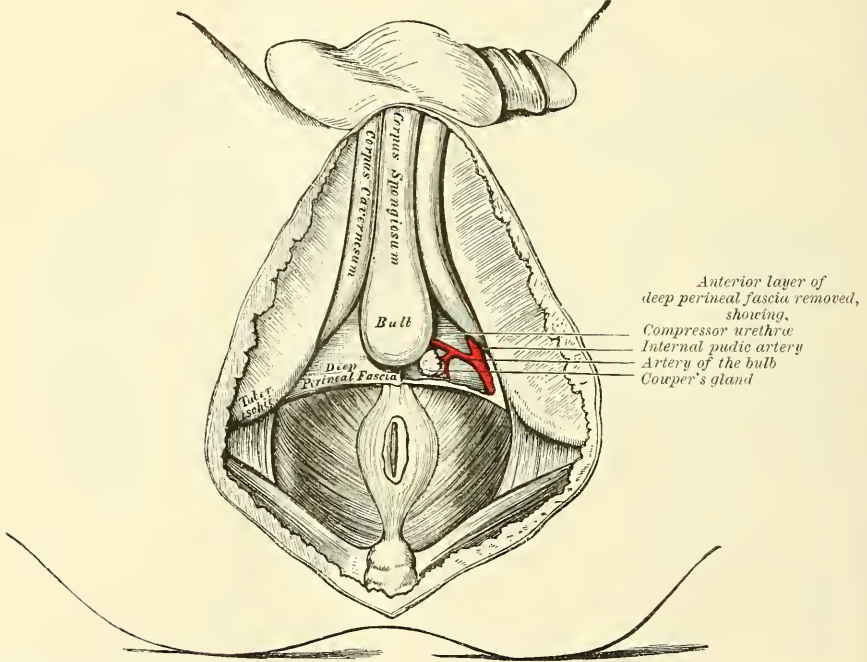
The **Erector penis** (*ischio-cavernosus*) covers part of the crus penis. It is an elongated muscle, broader in the middle than at either extremity, and situated on either side of the lateral boundary of the perinæum. It arises by tendinous and fleshy fibres from the inner surface of the tuberosity of the ischium, behind the crus penis; from the surface of the crus; and from the adjacent portion of the ramus of the ischium. From these points fleshy fibres succeed, which end in an aponeurosis which is inserted into the sides and under surface of the crus penis.

**Nerve-supply.**—The perineal branch of the internal pudic.

**Actions.**—It compresses the crus penis, and retards the return of the blood through the veins, and thus serves to maintain the organ erect.

Between the muscles just examined a triangular space exists, bounded internally by the Accelerator urinæ, externally by the Erector penis, and behind by the Transversus perinæi. The floor of this space is formed by the triangular ligament of the urethra (deep perineal fascia), and running from behind forwards

FIG. 337.—Triangular ligament or deep perineal fascia. On the left side the superficial layer has been removed.



in it are the superficial perineal vessels and nerve, and the transverse perineal artery coursing along the posterior boundary of the space on the Transversus perinæi muscle.

The **triangular ligament** (*Deep perineal fascia*) is stretched across the pubic arch, so as to close in the front part of the outlet of the pelvis. It consists of two dense membranous laminae, which are united along their posterior borders, but are separated in front by intervening structures. The superficial of these two layers, the *inferior layer of the triangular ligament*, is triangular in shape, about an inch and a half in depth, attached above, by its apex, to the under surface of the symphysis pubis and subpubic ligament; and on each side to the rami of the ischium and os pubis, beneath the crura penis. Its inferior margin, or base, is directed towards the rectum, and connected to the central tendinous point of the perinæum. It is continuous with the deep layer of the superficial fascia behind the Transversus perinæi muscle, and with a thin fascia which covers the cutaneous surface of the Levator ani muscle (*anal or ischio-rectal fascia*).

This layer of the triangular ligament is perforated by the urethra, about an inch below the symphysis pubis. The aperture is circular in form, and about three or four lines in diameter. Above this is the aperture for the dorsal vein of the penis; and, outside the latter, branches of the pudic nerve and artery pierce it.

If this superficial or inferior layer of the triangular ligament is detached on either side, the following structures will be seen between it and the deep layer: the subpubic ligament above, close to the pubes; the dorsal vein of the penis; the membranous portion of the urethra, and the Compressor urethræ muscle; Cowper's glands and their ducts; the pudic vessels and nerve; the artery and nerve of the bulb, and a plexus of veins.

The deep layer of the ligament (*superior layer of the triangular ligament*) is derived from the obturator fascia and stretches across the pubic arch. If the obturator fascia is traced inwards after covering the Obturator internus muscle, it will be found to be attached by some of its deeper or anterior fibres to the inner margin of the ischio-pubic ramus, while its superficial or posterior fibres pass over this attachment to become the superior layer of the triangular ligament. Behind, this layer of the fascia is continuous with the inferior layer and with the fascia of Colles, and in front it is separated from the apex of the prostate gland through the intervention of a prolongation of the recto-vesical fascia. It is pierced by the urethra, or rather consists of two halves which are separated in the middle line by the urethra passing between them.

The **Compressor urethræ** (*Constrictor urethræ*) surrounds the whole length of the membranous portion of the urethra, and is contained between the two layers of the triangular ligament. It arises, by aponeurotic fibres, from the upper part of the descending ramus of the os pubis on each side, to the extent of half or three-quarters of an inch: each segment of the muscle passes inwards, and divides into two fasciculi, which surround the urethra from the prostate gland behind, to the bulbous portion of the urethra in front; and unite, at the upper and lower surfaces of this tube, with the muscle of the opposite side, by means of a tendinous raphé.

**Actions.**—The muscles of both sides act together as a sphincter, compressing the membranous portion of the urethra. During the transmission of fluids they, like the Acceleratores urinæ, are relaxed, and only come into action at the end of the process to eject the last of the fluid.

## II. B. MUSCLES OF THE PERINÆUM IN THE FEMALE (fig. 338)

Transversus perinæi.  
Sphincter vaginæ.

Erector clitoridis.  
Compressor urethræ.

The **Transversus perinæi** in the female is a narrow muscular slip, which passes more or less transversely across the back part of the perineal space. It arises by a small tendon from the inner and fore part of the tuberosity of the ischium, and, passing inwards, is inserted into the central line of the perinæum, joining in this situation with the muscle of the opposite side, the External sphincter ani behind, and the Sphincter vaginæ in front.

**Nerve-supply.**—The perineal branch of the internal pudic.

**Actions.**—By their contraction they serve to fix the central tendinous point of the perinæum.

The **Sphincter vaginæ** surrounds the orifice of the vagina, and is analogous to the Accelerator urinæ in the male. It is attached posteriorly to the central tendinous point of the perinæum, where it blends with the External sphincter ani. Its fibres pass forwards on each side of the vagina, to be inserted into the corpora cavernosa of the clitoris, a fasciculus crossing over the body of the organ so as to compress the dorsal vein.

**Nerve-supply.**—The perineal branch of the internal pudic.

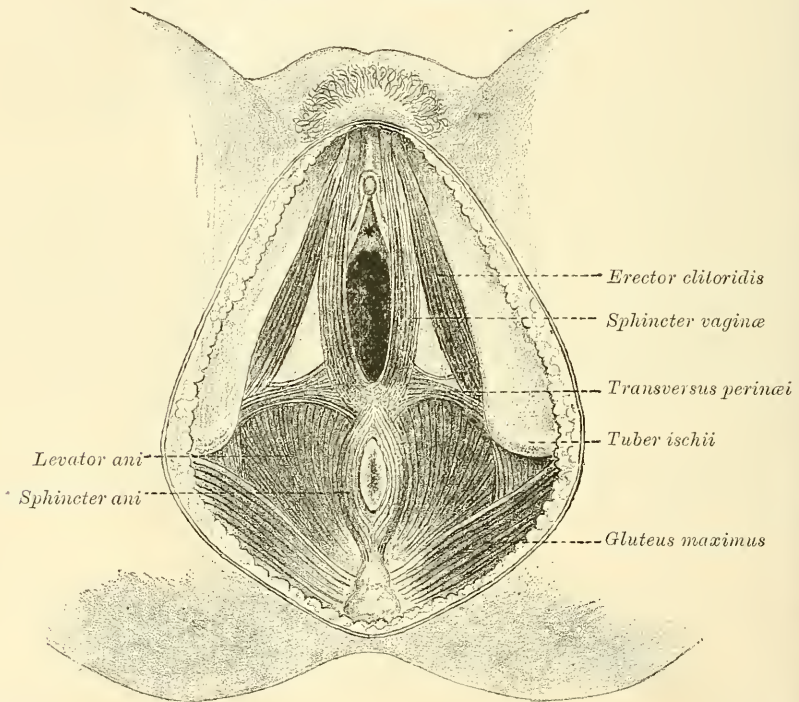


**Actions.**—It diminishes the orifice of the vagina. The anterior fibres contribute to the erection of the clitoris, as they are inserted into and are continuous with the fascia of the clitoris; compressing the dorsal vein during the contraction of the muscle.

The **Erector clitoridis** resembles the Erector penis in the male, but is smaller than it. It covers the unattached part of the crus clitoridis. It is an elongated muscle, broader at the middle than at either extremity, and situated on either side of the lateral boundary of the perinæum. It arises by tendinous and fleshy fibres from the inner surface of the tuberosity of the ischium, behind the crus clitoridis; from the surface of the crus; and from the adjacent portion of the ramus of the ischium. From these points fleshy fibres succeed, which end in an aponeurosis, which is inserted into the sides and under surface of the crus clitoridis.

**Nerve-supply.**—The perineal branch of the internal pudic.

FIG. 338.—Muscles of the female perinæum.



**Actions.**—It compresses the crus clitoridis and retards the return of blood through the veins, and thus serves to maintain the organ erect.

The **triangular ligament** (*deep perineal fascia*) in the female is not so strong as in the male. It is attached to the pubic arch, its apex being connected with the symphysis pubis. It is divided in the middle line by the aperture of the vagina, with the external coat of which it becomes blended, and in front of this is perforated by the urethra. Its posterior border is continuous, as in the male, with the deep layer of the superficial fascia around the *Transversus perinæi* muscle.

Like the triangular ligament in the male it consists of two layers, between which are to be found the following structures: the subpubic ligament above, the dorsal vein of the clitoris, a portion of the urethra and the *Compressor urethræ* muscle, the glands of Bartholin and their ducts; the pudic vessels and the dorsal nerve of the clitoris; the artery of the *bulbi vestibuli*, and a plexus of veins.

The **Compressor urethræ** (*Constrictor urethræ*) arises on each side from the margin of the descending ramus of the os pubis. The fibres, passing inwards, divide into two sets: those of the fore part of the muscle are directed across the subpubic arch in front of the urethra to blend with the muscular fibres of the opposite side; while those of the hinder and larger part pass inwards to blend with the wall of the vagina behind the urethra.

## MUSCLES AND FASCIÆ OF THE UPPER EXTREMITY

The Muscles of the Upper Extremity are divisible into groups, corresponding with the different regions of the limb.

## I. OF THE THORACIC REGION

1. *Anterior Thoracic Region*

Pectoralis major. Pectoralis minor.  
Subclavius.

2. *Lateral Thoracic Region*

Serratus magnus.

## II. OF THE SHOULDER AND ARM

3. *Acromial Region*

Deltoid.

4. *Anterior Scapular Region*

Subscapularis.

5. *Posterior Scapular Region*

Supraspinatus. Teres minor.  
Infraspinatus. Teres major.

6. *Anterior Humeral Region*

Coraco-brachialis. Biceps.  
Brachialis anticus.

7. *Posterior Humeral Region*

Triceps. Subanconeus.

## III. OF THE FOREARM

8. *Anterior Radio-Ulnar Region*

Superficial Layer.	{	Pronator radii teres.
		Flexor carpi radialis.
Deep Layer.	{	Palmaris longus.
		Flexor carpi ulnaris.
		Flexor sublimis digitorum.
		Flexor profundus digitorum.
		Flexor longus pollicis.
		Pronator quadratus.

9. *Radial Region*

Supinator longus.  
Extensor carpi radialis longior.  
Extensor carpi radialis brevior.

10. *Posterior Radio-Ulnar Region*

Superficial Layer.	{	Extensor communis digitorum.
		Extensor minimi digiti.
		Extensor carpi ulnaris.
		Anconeus.
Deep Layer.	{	Supinator brevis.
		Extensor ossis metacarpi pollicis.
		Extensor brevis pollicis.
		Extensor longus pollicis.
		Extensor indicis.

## IV. OF THE HAND

11. *Radial Region*

Abductor pollicis.  
Flexor ossis metacarpi pollicis (Opponens pollicis).  
Flexor brevis pollicis.  
Adductor pollicis.

12. *Ulnar Region*

Palmaris brevis.  
Abductor minimi digiti.  
Flexor brevis minimi digiti.  
Flexor ossis metacarpi minimi digiti (Opponens minimi digiti).

13. *Palmar Region*

Lumbricales.  
Interossei palmares.  
Interossei dorsales.

*Dissection of Pectoral Region and Axilla* (fig. 339).—The arm being drawn away from the side nearly at right angles with the trunk, and rotated outwards, make a vertical incision through the integument in the median line of the chest, from the upper to the lower part of the sternum; a second incision along the lower border of the Pectoral muscle, from the ensiform cartilage to the inner side of the axilla; a third, from the sternum along the clavicle, as far as its centre; and a fourth, from the middle of the clavicle obliquely downwards, along the interspace between the Pectoral and Deltoid muscles, as low as the fold of the armpit. The flap of integument is then to be dissected off in the direction indicated in the figure, but not entirely removed, as it should be replaced on completing the dissection. If a transverse incision is now made from the

lower end of the sternum to the side of the chest, as far as the posterior fold of the armpit, and the integument reflected outwards, the axillary space will be more completely exposed.

## I. MUSCLES AND FASCLE OF THE THORACIC REGION

### 1. Anterior Thoracic Region

Pectoralis major.

Pectoralis minor.

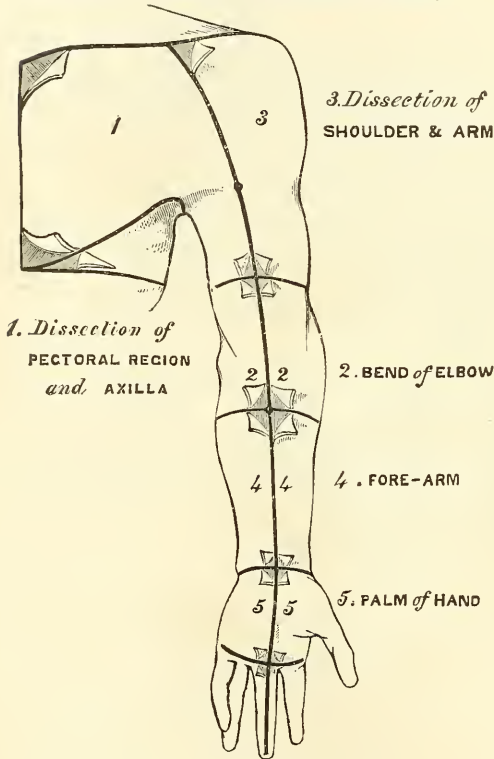
Subclavius.

The **superficial fascia** of the thoracic region is a loose cellulo-fibrous layer, enclosing masses of fat in its spaces. It is continuous with the superficial fascia of the neck and upper extremity above, and of the abdomen below. Opposite the mamma, it divides into two layers, one of which passes in front, the other behind that gland; and from both of these layers numerous septa pass into its substance, supporting its various lobes: from the anterior layer, fibrous processes

pass forwards to the integument and nipple. These processes were called by Sir A. Cooper the *ligamenta suspensoria*, from the support they afford to the gland in this situation.

The **deep fascia** of the thoracic region is a thin aponeurotic lamina, covering the surface of the great Pectoral muscle, and sending numerous prolongations between its fasciculi: it is attached, in the middle line, to the front of the sternum; and, above, to the clavicle; externally and below it becomes continuous with the fascia over the shoulder, axilla, and thorax. It is very thin over the upper part of the muscle, thicker in the interval between the Pectoralis major and Latissimus dorsi, where it closes in the axillary space, and divides at the outer margin of the latter muscle into two layers, one of which passes in front, and the other behind it; these proceed as far as the spinous processes of the dorsal vertebræ, to which they are attached. At the lower part of the thoracic region

FIG. 339.—Dissection of upper extremity.



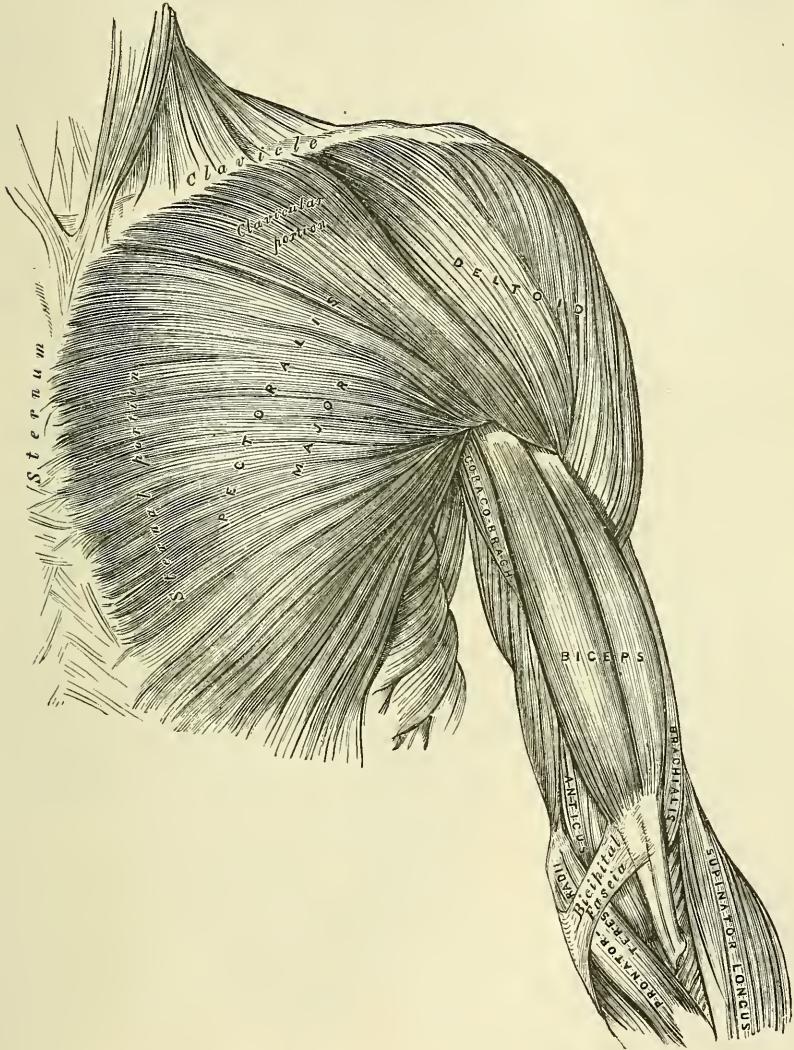
this fascia is well-developed, and is continuous with the fibrous sheath of the Recti muscles.

The **Pectoralis major** (fig. 340) is a broad, thick, triangular muscle, situated at the upper and fore part of the chest, in front of the axilla. It arises from the anterior surface of the sternal half of the clavicle; from half the breadth of the anterior surface of the sternum, as low down as the attachment of the cartilage of the sixth or seventh rib; this portion of its origin consists of aponeurotic fibres, which intersect with those of the opposite muscle; it also arises from the cartilages of all the true ribs, with the exception, frequently, of the first, or of the seventh, or both; and from the aponeurosis of the External oblique muscle of the abdomen. The fibres from this extensive origin converge towards its insertion, giving to the muscle a radiated appearance. Those fibres which arise from the clavicle pass obliquely outwards and downwards, and are usually separated from



the rest by a cellular interval: those from the lower part of the sternum, and the cartilages of the lower true ribs, pass upwards and outwards; whilst the middle fibres pass horizontally. They all terminate in a flat tendon, about two inches broad, which is inserted into the anterior bicipital ridge of the humerus. This tendon consists of two laminae, placed one in front of the other, and usually blended together below. The anterior, the thicker, receives the clavicular and upper half of the sternal portion of the muscle; and its fibres are inserted in the same order as that in which they arise; that is to say, the outermost fibres of

FIG. 340.—Muscles of the chest and front of the arm. Superficial view.



origin from the clavicle are inserted at the uppermost part of the tendon; the upper fibres of origin from the sternum pass down to the lowermost part of this anterior lamina of the tendon and extend as low as the tendon of the Deltoid and join with it. The posterior lamina of the tendon receives the attachment of the lower half of the sternal portion and the deeper part of the muscle from the costal cartilages. These deep fibres, and particularly those from the lower costal cartilages, ascend the higher, turning backwards successively behind the superficial and upper ones, so that the tendon appears to be twisted. The

posterior lamina reaches higher on the humerus than the anterior one, and from it an expansion is given off which covers the bicipital groove and blends with the capsule of the shoulder-joint. From the deepest fibres of this lamina at its insertion an expansion is given off which lines the bicipital groove of the humerus, whilst from the lower border of the tendon a third expansion passes downwards to the fascia of the arm.

**Relations.**—By its *anterior surface*, with the integument, the superficial fascia, the Platysma, the mammary gland, and the deep fascia. By its *posterior surface*; its *thoracic portion*, with the sternum, the ribs and costal cartilages, the costo-coracoid membrane, the Subclavius, Pectoralis minor, Serratus magnus, and the Intercostals; its *axillary portion* forms the anterior wall of the axillary space, and covers the axillary vessels and nerves, the Biceps and Coraco-brachialis muscles. Its *upper border* lies parallel with the Deltoid, from which it is separated by a slight interspace in which lie the cephalic vein and descending branch of the acromial thoracic artery. Its *lower border* forms the anterior margin of the axilla, being at first separated from the Latissimus dorsi by a considerable interval; but both muscles gradually converge towards the outer part of the space.

**Dissection.**—Detach the Pectoralis major by dividing the muscle along its attachment to the clavicle, and by making a vertical incision through its substance a little external to its line of attachment to the sternum and costal cartilages. The muscle should then be reflected outwards, and its tendon carefully examined. The Pectoralis minor is now exposed, and immediately above it, in the interval between its upper border and the clavicle, a strong fascia, the *costo-coracoid membrane*.

The **costo-coracoid membrane** is a strong fascia, placed between the clavicle and the upper border of the Pectoralis minor muscle, which protects the axillary vessels and nerves. Above, it is attached to the anterior margin of the Subclavian groove on the under surface of the clavicle, and is connected with a layer of cervical fascia which overlies the Omo-hyoid muscle, and forms the posterior layer of the sheath of the Subclavius muscle. Internally, it blends with the fascia covering the first two intercostal spaces, and is attached also to the first rib internal to the origin of the Subclavius muscle. Externally, it is very thick and dense, and is attached to the coracoid process. The portion extending from its attachment to the first rib to the coracoid process is often whiter and denser than the rest; this is sometimes called the *costo-coracoid ligament*. Below this, it is thin, and at the upper border of the Pectoralis minor it splits into two layers to invest the muscle; from the lower border of the Pectoralis minor it is continued downwards to join the axillary fascia, and outwards to join the fascia over the short head of the Biceps. The costo-coracoid membrane is pierced by the cephalic vein, the acromial thoracic artery and vein, superior thoracic artery, and anterior thoracic nerves.

The **Pectoralis minor** (fig. 341) is a thin, flat, triangular muscle, situated at the upper part of the thorax, beneath the Pectoralis major. It arises by three tendinous digitations, from the upper margin and outer surface of the third, fourth, and fifth ribs, near their cartilages, and from the aponeurosis covering the Intercostal muscles; the fibres pass upwards and outwards, and converge to form a flat tendon, which is inserted into the inner border and upper surface of the coracoid process of the scapula.

**Relations.**—By its *anterior surface*, with the Pectoralis major, and the superior thoracic vessels and nerves. By its *posterior surface*, with the ribs, Intercostal muscles, Serratus magnus, the axillary space, and the axillary vessels and brachial plexus of nerves. Its upper border is separated from the clavicle by a triangular interval, broad internally, narrow externally, bounded in front by the costo-coracoid membrane, and internally by the ribs. In this space are the first part of the axillary vessels and nerves.

The costo-coracoid membrane should now be removed, when the Subclavius muscle will be seen.

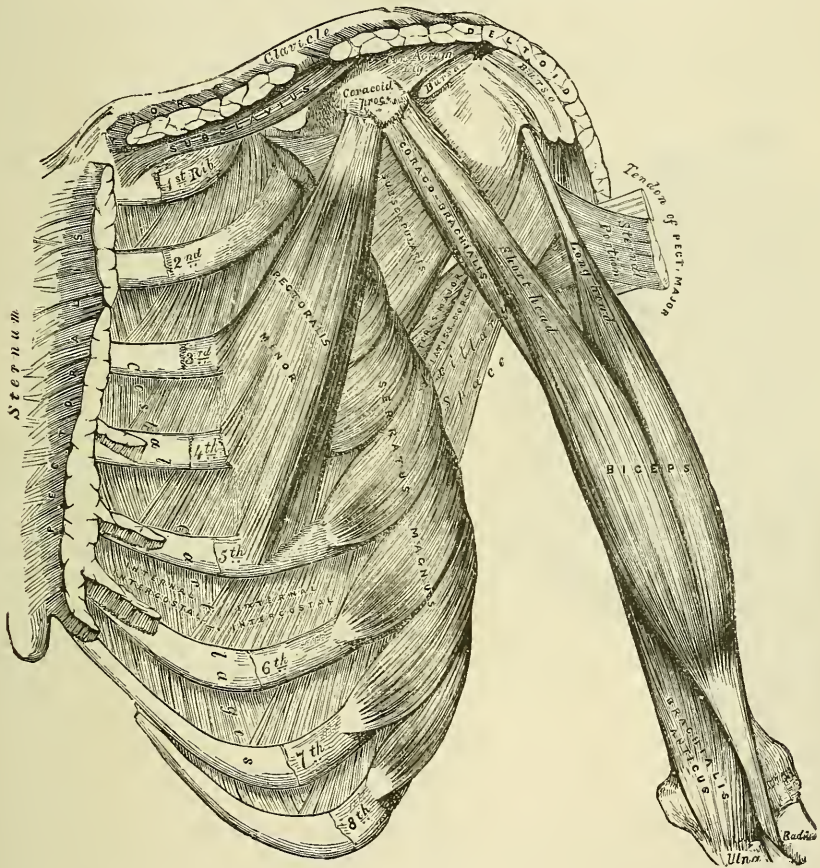


The **Subclavius** is a long, thin, spindle-shaped muscle, placed in the interval between the clavicle and the first rib. It arises by a short, thick tendon from the first rib and its cartilage at their junction, in front of the rhomboid ligament; the fleshy fibres proceed obliquely upwards and outwards, to be inserted into a deep groove on the under surface of the middle third of the clavicle.

**Relations.**—By its *upper surface*, with the clavicle. By its *under surface*, it is separated from the first rib by the subclavian vessels and brachial plexus of nerves. Its *anterior surface* is separated from the Pectoralis major by the costo-coracoid membrane, which, with the clavicle and a part of the cervical fascia, forms an osseo-fibrous sheath in which the muscle is enclosed.

If the costal attachment of the Pectoralis minor is divided across, and the muscle reflected outwards, the axillary vessels and nerves are brought fully into view, and should be examined.

FIG. 341.—Muscles of the chest and front of the arm, with the boundaries of the axilla.



**Nerves.**—The Pectoral muscles are supplied by the anterior thoracic nerves; the Pectoralis major through these nerves receives filaments from all the spinal nerves entering into the formation of the brachial plexus; the Pectoralis minor receives its fibres from the seventh and eighth cervical and first dorsal nerves. The Subclavius is supplied by a filament from the cord formed by the union of the fifth and sixth cervical nerves.

**Actions.**—If the arm has been raised by the Deltoid, the Pectoralis major will, conjointly with the Latissimus dorsi and Teres major, depress it to the side of the chest. If acting alone, it adducts and draws forwards the arm, bringing



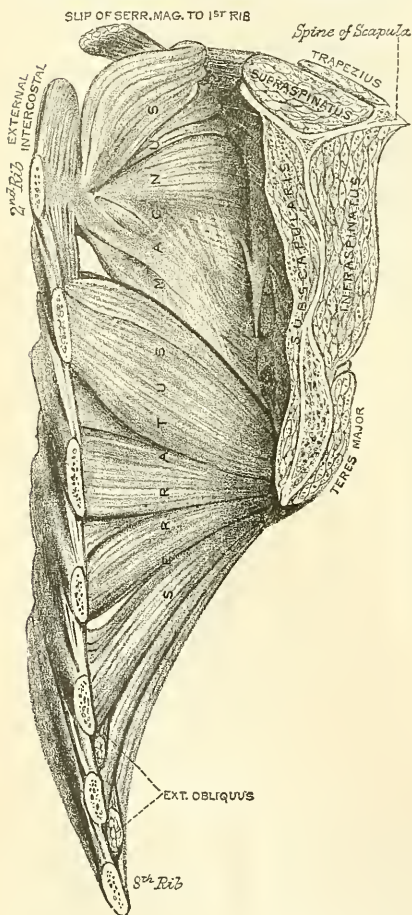
it across the front of the chest, and at the same time rotates it inwards. The Pectoralis minor depresses the point of the shoulder, drawing the scapula downwards and inwards to the thorax, and throwing the inferior angle backwards. The Subclavius depresses the shoulder, drawing the clavicle downwards and forwards. When the arms are fixed, all three muscles act upon the ribs, drawing them upwards and expanding the chest, and thus becoming very important agents in forced inspiration. Asthmatic patients always assume an attitude which fixes the shoulders, so that all these muscles may be brought into action to assist in dilating the cavity of the chest.

## 2. Lateral Thoracic Region

### Serratus magnus.

The **Serratus magnus** (fig. 342) is a broad, thin, and irregularly quadrilateral muscle, situated at the upper part and side of the chest. It consists of two triangular or fan-shaped portions: the upper one has the apex of the triangle attached to the first and second ribs, and the base to the upper angle and vertebral border of the scapula; the lower one has its apex behind, attached to the inferior angle of the scapula, and its base in front connected with the ribs from the second to the eighth.

FIG. 342.—Serratus magnus. (From a preparation in the Museum of the Royal College of Surgeons of England.)



It arises by nine fleshy digitations from the outer surface and upper border of the eight upper ribs (the second rib having two), and from the aponeurosis covering the upper Intercostal muscles, and is inserted into the whole length of the anterior aspect of the posterior border of the scapula. The upper fan-shaped portion is attached to the fore part of the outer surfaces of the first and second ribs; its fibres spread out, the upper ones forming a thick fasciculus, which passes upwards and backwards, and is attached to the triangular smooth surface on the anterior aspect of the superior angle of the scapula; the remaining fibres proceed backwards and downwards to be attached to the posterior border of the scapula between the superior and inferior angles. The lower fan-shaped portion is attached posteriorly by its apex to the anterior surface of the inferior angle of the scapula, partly by muscular, partly by tendinous fibres; it spreads out like a fan, the upper fibres passing forwards and upwards, the lower horizontally forwards to be inserted into the outer surface of the fore part of the ribs from the second to the eighth, by a series of muscular digitations. In the intervals between the four lower of these are received corre-

sponding processes of the External oblique.

**Relations.**—This muscle is covered, in front, by the Pectoral muscles; behind, by the Subscapularis; above, by the axillary vessels and nerves. Its *deep surface* rests upon the ribs and Intercostal muscles.

**Nerves.**—The Serratus magnus is supplied by the posterior thoracic nerve which is derived from the fifth, sixth and generally the seventh cervical nerves.

**Actions.**—The Serratus magnus, as a whole, carries the scapula forwards, and at the same time raises the vertebral border of the bone. It is therefore concerned in the action of pushing. Its lower and stronger fibres move forwards the lower angle and assist the Trapezius in rotating the bone round an axis through its centre, and thus assists this muscle in raising the acromion and supporting weights upon the shoulder. It is also an assistant to the Deltoid in raising the arm, inasmuch as during the action of this latter muscle it fixes the scapula and so the glenoid cavity on which the head of the humerus rotates. After the Deltoid has raised the arm to a right angle with the trunk, the Serratus magnus and the Trapezius, by rotating the scapula, raise the arm into an almost vertical position. It is possible that when the shoulders are fixed the lower fibres of the Serratus magnus may assist in raising and everting the ribs; but it is not the important inspiratory muscle which it was formerly believed to be.

*Surgical Anatomy.*—When the muscle is paralysed, the vertebral border, and especially the lower angle, leave the ribs and stand out prominently on the surface, giving a peculiar ‘winged’ appearance to the back. The patient is unable to raise the arm, and an attempt to do so is followed by a further projection of the lower angle of the scapula from the back of the thorax.

*Dissection.*—After completing the dissection of the axilla, if the muscles of the back have been dissected, the upper extremity should be separated from the trunk. Saw through the clavicle at its centre, and then cut through the muscles which connect the scapula and arm with the trunk, viz. the Pectoralis minor in front, Serratus magnus at the side, and the Levator anguli scapulæ, the Rhomboids, Trapezius, and Latissimus dorsi behind. These muscles should be cleaned and traced to their respective insertions. Then make an incision through the integument, commencing at the outer third of the clavicle, and extending along the margin of that bone, the acromion process, and spine of the scapula; the integument should be dissected from above downwards and outwards, when the fascia covering the Deltoid is exposed (fig. 339, 3).

## II. MUSCLES AND FASCIA OF THE SHOULDER AND ARM

The **superficial fascia** of the upper extremity is a thin cellulo-fibrous layer, containing the superficial veins and lymphatics, and the cutaneous nerves. It is most distinct in front of the elbow, and contains very large superficial veins and nerves; in the hand it is hardly demonstrable, the integument being closely adherent to the deep fascia by dense fibrous bands. Small subcutaneous bursæ are found in this fascia over the acromion, the olecranon, and the knuckles. The deep fascia of the upper extremity comprises the aponeurosis of the shoulder, arm, and forearm, the anterior and posterior annular ligaments of the carpus, and the palmar fascia. These will be considered in the description of the muscles of the several regions.

### 3. Acromial Region

#### Deltoid

The **deep fascia** covering the Deltoid (deltoid aponeurosis) is a fibrous layer, which covers the outer surface of the muscle, thick and strong behind, where it is continuous with the infraspinatus fascia, thinner over the rest of its extent. It sends down numerous prolongations between the fasciculi of the muscle. In front, it is continuous with the fascia covering the great Pectoral muscle; behind, with that covering the Infraspinatus; above, it is attached to the clavicle, the acromion, and spine of the scapula; below, it is continuous with the deep fascia of the arm.

The **Deltoid** (fig. 340) is a large, thick, triangular muscle, which gives the rounded outline to the shoulder, and has received its name from its resemblance to the Greek letter  $\Delta$  reversed. It surrounds the shoulder-joint in the greater part of its extent, covering it on its outer side, and in front and behind. It arises



from the outer third of the anterior border and upper surface of the clavicle ; from the outer margin and upper surface of the acromion process ; and from the lower lip of the posterior border of the spine of the scapula, as far back as the triangular surface at its inner end. From this extensive origin the fibres converge towards their insertion, the middle passing vertically, the anterior obliquely backwards, the posterior obliquely forwards ; they unite to form a thick tendon, which is inserted into a rough prominence on the middle of the outer side of the shaft of the humerus. At its insertion the muscle gives off an expansion to the deep fascia of the arm. This muscle is remarkably coarse in texture, and the arrangement of its muscular fibres is somewhat peculiar ; the central portion of the muscle—that is to say, the part arising from the acromion process—consists of oblique fibres, which arise in a bipenniform manner from the sides of tendinous intersections, generally four in number, which are attached above to the acromion process and pass downwards parallel to one another in the substance of the muscle. The oblique muscular fibres thus formed are inserted into similar tendinous intersections, generally three in number, which pass upwards from the insertion of the muscle into the humerus and alternate with the descending septa. The lateral portions of the muscle—that is to say, the fibres arising from the clavicle and spine of the scapula—are not arranged in this manner, but consist of parallel fasciculi passing from their origin above, to be inserted into the margins of the inferior tendon.

**Relations.**—By its *superficial surface*, with the integument, the superficial fascia, Platysma, and supra-acromial nerves. Its *deep surface* is separated from the head of the humerus by a large sacculated synovial bursa, and covers the coracoid process, coraco-acromial ligament, Pectoralis minor, Coraco-brachialis, both heads of the Biceps, the tendon of the Pectoralis major, the insertions of the Supraspinatus, Infraspinatus, and Teres minor, the scapular and external heads of the Triceps, the circumflex vessels and nerve, and the humerus. Its *anterior border* is separated at its upper part from the Pectoralis major by a cellular interspace, which lodges the cephalic vein and descending branch of the acromial thoracic artery : lower down the two muscles are in close contact. Its *posterior border* rests on the Infraspinatus and Triceps muscles.

**Nerves.**—The Deltoid is supplied by the fifth and sixth cervical through the circumflex nerve.

**Actions.**—The Deltoid raises the arm directly from the side, so as to bring it at right angles with the trunk. Its anterior fibres, assisted by the Pectoralis major, draw the arm forwards ; and its posterior fibres, aided by the Teres major and Latissimus dorsi, draw it backwards.

**Surgical Anatomy.**—The Deltoid is very liable to atrophy, and when in this condition simulates dislocation of the shoulder-joint, as there is flattening of the shoulder and apparent prominence of the acromion process ; upon examination, however, it will be found that the relative position of the great tuberosity of the humerus to the acromion and coracoid process is unchanged. Atrophy of the Deltoid may be due to disuse or loss of trophic influence, either from injury to the circumflex nerve or cord lesions, as in infantile paralysis.

**Dissection.**—Divide the Deltoid across, near its upper part, by an incision carried along the margin of the clavicle, the acromion process, and spine of the scapula, and reflect it downwards : the bursa will be seen on its under surface, as well as the circumflex vessels and nerve.

#### 4. Anterior Scapular Region

##### Subscapularis.

The **subscapular fascia** is a thin membrane attached to the entire circumference of the subscapular fossa, and affording attachment by its inner surface to some of the fibres of the Subscapularis muscle : when this is removed, the Subscapularis muscle is exposed.

The **Subscapularis** (fig. 341) is a large triangular muscle, which fills up the



subscapular fossa, arising from its internal two-thirds, with the exception of a narrow margin along the posterior border, and the surfaces at the superior and inferior angles which afford attachment to the Serratus magnus: it also arises from the lower two-thirds of the groove on the axillary border of the bone. Some fibres arise from tendinous laminae, which intersect the muscle, and are attached to ridges on the bone; and others from an aponeurosis, which separates the muscle from the Teres major and the long head of the Triceps. The fibres pass outwards, and, gradually converging, terminate in a tendon, which is inserted into the lesser tuberosity of the humerus. Those fibres which arise from the axillary border of the scapula are inserted into the neck of the humerus to the extent of an inch below the tuberosity. The tendon of the muscle is in close contact with the capsular ligament of the shoulder-joint, and glides over a large bursa, which separates it from the base of the coracoid process. This bursa communicates with the cavity of the joint by an aperture in the capsular ligament.

**Relations.**—By its *anterior surface* with the Serratus magnus, Coracobrachialis, and Biceps, the axillary vessels and brachial plexus of nerves, and the subscapular vessels and nerves. By its *posterior surface*, with the scapula and the capsular ligament of the shoulder-joint. Its *lower border* is contiguous with the Teres major and Latissimus dorsi.

**Nerves.**—It is supplied by the fifth and sixth cervical nerves through the upper and lower subscapular nerves.

**Actions.**—The Subscapularis rotates the head of the humerus inwards; when the arm is raised, it draws the humerus forwards and downwards. It is a powerful defence to the front of the shoulder-joint, preventing displacement of the head of the bone forwards.

#### 5. *Posterior Scapular Region* (fig. 343)

Supraspinatus.

Infraspinatus.

Teres minor.

Teres major.

**Dissection.**—To expose these muscles, and to examine their mode of insertion into the humerus, detach the Deltoid and Trapezius from their attachment to the spine of the scapula and acromion process. Remove the clavicle by dividing the ligaments connecting it with the coracoid process, and separate it at its articulation with the scapula: divide the acromion process near its root with a saw. The fragments being removed, the tendons of the posterior Scapular muscles will be fully exposed, and can be examined. A block should be placed beneath the shoulder-joint, so as to make the muscles tense.

The **supraspinous fascia** is a thick and dense membranous layer, which completes the osseo-fibrous case in which the Supraspinatus muscle is contained; affording attachment, by its inner surface, to some of the fibres of the muscle. It is thick internally, but thinner externally under the coraco-acromial ligament. When this fascia is removed, the Supraspinatus muscle is exposed.

The **Supraspinatus muscle** occupies the whole of the supraspinous fossa, arising from its internal two-thirds, and from the strong fascia which covers its surface. The muscular fibres converge to a tendon, which passes across the capsular ligament of the shoulder-joint, to which it is intimately adherent, and is inserted into the highest of the three facets on the great tuberosity of the humerus.

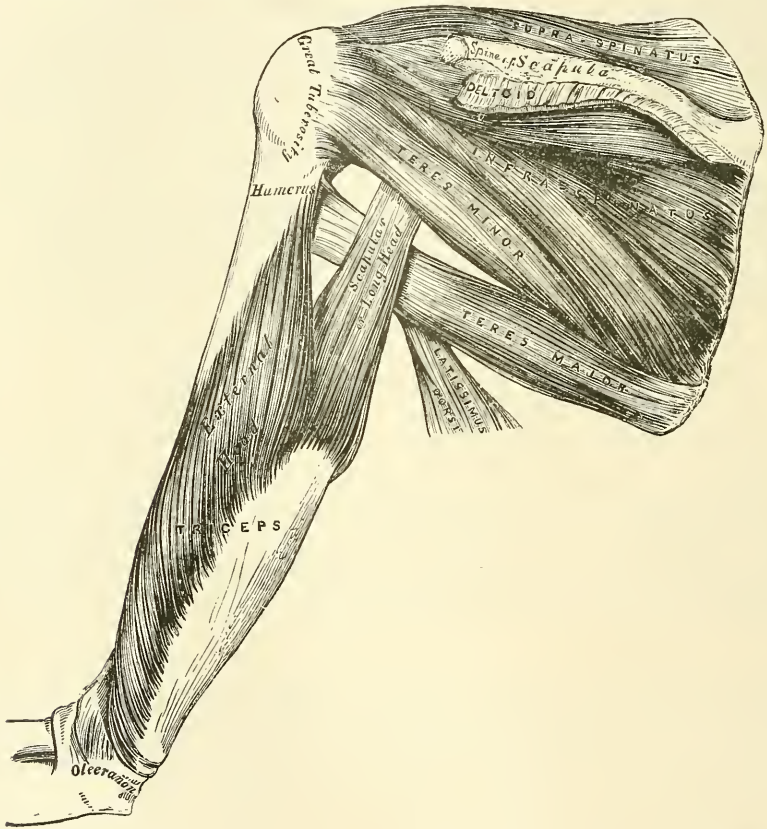
**Relations.**—By its *upper surface*, with the Trapezius, the clavicle, the acromion, the coraco-acromial ligament, and the Deltoid. By its *under surface*, with the scapula, the suprascapular vessels and nerve, and upper part of the shoulder-joint.

The **infraspinous fascia** is a dense fibrous membrane, covering in the Infraspinatus muscle and attached to the circumference of the infraspinous fossa; it affords attachment, by its inner surface, to some fibres of that muscle. At the point where the Infraspinatus commences to be covered by the Deltoid, this

fascia divides into two layers: one layer passes over the Deltoid muscle, helping to form the Deltoid fascia already described; the other passes beneath the Deltoid to the shoulder-joint.

The **Infraspinatus** is a thick triangular muscle, which occupies the chief part of the infraspinous fossa, arising by fleshy fibres from its internal two-thirds; and by tendinous fibres from the ridges on its surface: it also arises from a strong fascia which covers it externally, and separates it from the Teres major and minor. The fibres converge to a tendon, which glides over the external border of the spine of the scapula, and, passing across the capsular ligament of the shoulder-joint, is inserted into the middle facet on the great tuberosity of the humerus. The tendon of this muscle is occasionally separated from the spine of the scapula by a synovial bursa, which communicates with the synovial cavity of the shoulder-joint.

FIG. 343.—Muscles on the dorsum of the scapula and the Triceps.



**Relations.**—By its *posterior surface*, with the Deltoid, the Trapezius, Latissimus dorsi, and the integument. By its *anterior surface*, with the scapula, from which it is separated by the suprascapular and dorsalis scapulæ vessels, and with the capsular ligament of the shoulder-joint. Its *lower border* is in contact with the Teres minor, and occasionally united with it, and with the Teres major.

The **Teres minor** is a narrow, elongated muscle, which lies along the inferior border of the scapula. It arises from the dorsal surface of the axillary border of the scapula for the upper two-thirds of its extent, and from two aponeurotic laminae, one of which separates this muscle from the Infraspinatus, the other from the Teres major; its fibres pass obliquely upwards and outwards, and terminate in a tendon, which is inserted into the lowest of the three facets on

the great tuberosity of the humerus, and, by fleshy fibres, into the humerus immediately below it. The tendon of this muscle passes across the capsular ligament of the shoulder-joint.

**Relations.**—By its *posterior surface*, with the Deltoid, and the integument. By its *anterior surface*, with the scapula, the dorsal branch of the subscapular artery, the long head of the Triceps, and the shoulder-joint. By its *upper border*, with the Infraspinatus. By its *lower border*, with the Teres major, from which it is separated anteriorly by the long head of the Triceps.

The **Teres major** is a broad and somewhat flattened muscle, which arises from the flat oval surface on the dorsal aspect of the inferior angle of the scapula, and from the fibrous septa interposed between it and the Teres minor and Infraspinatus; the fibres are directed upwards and outwards, and terminate in a flat tendon, about two inches in length, which is inserted into the posterior bicipital ridge of the humerus. The tendon of this muscle, at its insertion into the humerus, lies behind that of the Latissimus dorsi, from which it is separated by a synovial bursa, the two tendons being, however, united along their lower borders for a short distance.

**Relations.**—By its *posterior surface*, with the integument, from which it is separated, internally, by the Latissimus dorsi; and externally, by the long head of the Triceps. By its *anterior surface*, with the Subscapularis, Latissimus dorsi, Coraco-brachialis, short head of the Biceps, the axillary vessels, and brachial plexus of nerves. Its *upper border* is at first in relation with the Teres minor, from which it is afterwards separated by the long head of the Triceps. Its *lower border* forms, in conjunction with the Latissimus dorsi, part of the posterior boundary of the axilla.

**Nerves.**—The Supra- and Infraspinatus muscles are supplied by the fifth and sixth cervical nerves through the suprascapular nerve; the Teres minor, by the fifth cervical, through the circumflex; and the Teres major, by the fifth and sixth cervical, through the lower subscapular.

**Actions.**—The Supraspinatus assists the Deltoid in raising the arm from the side, and fixes the head of the humerus in its socket. The Infraspinatus and Teres minor rotate the head of the humerus outwards: when the arm is raised, they assist in retaining it in that position and carrying it backwards. One of the most important uses of these three muscles is the great protection they afford to the shoulder-joint, the Supraspinatus supporting it above, and preventing displacement of the head of the humerus upwards, whilst the Infraspinatus and Teres minor protect it behind, and prevent dislocation backwards. The Teres major assists the Latissimus dorsi in drawing the humerus downwards and backwards, when previously raised, and rotating it inwards; when the arm is fixed it may assist the Pectoral and Latissimus dorsi muscles in drawing the trunk forwards.

#### 6. *Anterior Humeral Region* (fig. 341)

Coraco-brachialis.

Biceps.

Brachialis anticus.

**Dissection.**—The arm being placed on the table, with the front surface uppermost, make a vertical incision through the integument along the middle line, from the outer extremity of the anterior fold of the axilla, to about two inches below the elbow-joint, where it should be joined by a transverse incision, extending from the inner to the outer side of the forearm; the two flaps being reflected on either side, the fascia should be examined (fig. 339).

The **deep fascia** of the arm is continuous with that covering the shoulder and front of the great Pectoral muscle, by means of which it is attached, above, to the clavicle, acromion, and spine of the scapula; it forms a thin, loose, membranous sheath investing the muscles of the arm, sending down septa between them, and composed of fibres disposed in a circular or spiral direction, and connected together by vertical and oblique fibres. It differs in thickness at different parts, being thin over the Biceps, but thicker where it covers the



Triceps, and over the condyles of the humerus: it is strengthened by fibrous aponeuroses, derived from the Pectoralis major and Latissimus dorsi on the inner side, and from the Deltoid externally. On either side it gives off a strong intermuscular septum, which is attached to the condyloid ridge and condyle of the humerus. These septa serve to separate the muscles of the anterior from those of the posterior brachial region. The *external intermuscular septum* extends from the lower part of the anterior bicipital ridge, along the external condyloid ridge, to the outer condyle; it is blended with the tendon of the Deltoid, gives attachment to the Triceps behind, to the Brachialis anticus, Supinator longus, and Extensor carpi radialis longior, in front; and is perforated by the musculo-spiral nerve and superior profunda artery. The *internal intermuscular septum*, thicker than the preceding, extends from the lower part of the posterior lip of the bicipital groove below the Teres major, along the internal condyloid ridge to the inner condyle; it is blended with the tendon of the Coraco-brachialis, and affords attachment to the Triceps behind and the Brachialis anticus in front. It is perforated by the ulnar nerve and the inferior profunda and anastomotomic arteries. At the elbow, the deep fascia is attached to all the prominent points round the joint, viz. the condyles of the humerus and the olecranon process of the ulna, and is continuous with the deep fascia of the forearm. Just below the middle of the arm, on its inner side, in front of the internal intermuscular septum, is an oval opening in the deep fascia, which transmits the basilic vein and some lymphatic vessels. On the removal of this fascia, the muscles, vessels, and nerves of the anterior humeral region are exposed.

The **Coraco-brachialis**, the smallest of the three muscles in this region, is situated at the upper and inner part of the arm. It arises by fleshy fibres from the apex of the coracoid process, in common with the short head of the Biceps, and from the intermuscular septum between the two muscles; the fibres pass downwards, backwards, and a little outwards, to be inserted by means of a flat tendon into a rough ridge at the middle of the inner surface and internal border of the shaft of the humerus between the origins of the Triceps and Brachialis anticus. It is perforated by the musculo-cutaneous nerve. The inner border of the muscle forms a guide to the position of the brachial artery in tying the vessel in the upper part of its course.

**Relations.**—By its *anterior surface*, with the Pectoralis major above, and at its insertion with the brachial vessels and median nerve which cross it. By its *posterior surface*, with the tendons of the Subscapularis, Latissimus dorsi, and Teres major, the inner head of the Triceps, the humerus, and the anterior circumflex vessels. By its *inner border*, with the brachial artery and the median and musculo-cutaneous nerves. By its *outer border*, with the short head of the Biceps and Brachialis anticus.

The **Biceps** (*Biceps flexor cubiti*) is a long fusiform muscle, occupying the whole of the anterior surface of the arm, and divided above into two portions or heads, from which circumstance it has received its name. The short head arises by a thick flattened tendon from the apex of the coracoid process, in common with the Coraco-brachialis. The long head arises from the supraglenoid tubercle on the upper margin of the glenoid cavity, by a long rounded tendon, which is continuous with the glenoid ligament. This tendon arches over the head of the humerus, being enclosed in a special sheath of the synovial membrane of the shoulder-joint; it then passes through an opening in the capsular ligament at its attachment to the humerus, and descends in the bicipital groove, in which it is retained by a fibrous prolongation from the tendon of the Pectoralis major. The fibres from this tendon form a rounded belly, and, about the middle of the arm, join with the portion of the muscle derived from the short head. The belly of the muscle, narrow and somewhat flattened, terminates above the elbow in a flattened tendon, which is inserted into the back part of the tuberosity of the radius, a synovial bursa being interposed between the tendon and the front

of the tuberosity. The tendon of the muscle is thin and broad; as it approaches the radius it becomes narrow and twisted upon itself, so that its anterior surface becomes external and is applied to the tuberosity of the radius at its insertion: opposite the bend of the elbow the tendon gives off, from its inner side, a broad aponeurosis, the *bicipital fascia (semilunar fascia)*, which passes obliquely downwards and inwards across the brachial artery, and is continuous with the deep fascia of the forearm (fig. 340). The inner border of this muscle forms a guide to the position of the vessel, in tying the brachial artery in the middle of the arm.\*

**Relations.**—Its *anterior surface* is overlapped above by the Pectoralis major and Deltoid; in the rest of its extent it is covered by the superficial and deep fasciæ and the integument. Its *posterior surface* rests above on the shoulder-joint and upper part of the humerus; below it rests on the Brachialis anticus, with the musculo-cutaneous nerve intervening between the two, and on the Supinator brevis. Its *inner border* is in relation with the Coraco-brachialis, the brachial vessels, and median nerve; its *outer border*, with the Deltoid and Supinator longus.

The **Brachialis anticus** is a broad muscle, which covers the elbow-joint and the lower half of the front of the humerus. It is somewhat compressed from before backwards, and is broader in the middle than at either extremity. It arises from the lower half of the outer and inner surfaces of the shaft of the humerus; and commences above at the insertion of the Deltoid, which it embraces by two angular processes. Its origin extends below, to within an inch of the margin of the articular surface, and is limited on each side by the external and internal borders of the shaft of the humerus. It also arises from the intermuscular septa on each side, but more extensively from the inner than the outer, from which it is separated below by the Supinator longus and Extensor carpi radialis longior. Its fibres converge to a thick tendon, which is inserted into a rough depression on the anterior surface of the coronoid process of the ulna, being received into an interval between two fleshy slips of the Flexor digitorum profundus.

**Relations.**—By its *anterior surface*, with the Biceps, the brachial vessels, musculo-cutaneous, and median nerves. By its *posterior surface*, with the humerus and front of the elbow-joint. By its *inner border*, with the Triceps, ulnar nerve, and Pronator radii teres, from which it is separated by the intermuscular septum. By its *outer border*, with the musculo-spiral nerve, radial recurrent artery, the Supinator longus, and Extensor carpi radialis longior.

**Nerves.**—The muscles of this group are supplied by the musculo-cutaneous nerve. The Brachialis anticus usually receives an additional filament from the musculo-spiral. The Coraco-brachialis receives its supply primarily from the seventh cervical, the Biceps and Brachialis anticus from the fifth and sixth cervical nerves.

**Actions.**—The Coraco-brachialis draws the humerus forwards and inwards, and at the same time assists in elevating it towards the scapula. The Biceps is a flexor of the forearm: it is also a supinator, and serves to render tense the deep fascia of the forearm by means of the broad aponeurosis given off from its tendon. The Brachialis anticus is a flexor of the forearm, and forms an important defence to the elbow-joint. When the forearm is fixed, the Biceps and Brachialis anticus flex the arm upon the forearm, as is seen in efforts of climbing.

\* A third head to the Biceps is occasionally found (Theile says as often as once in eight or nine subjects), arising at the upper and inner part of the Brachialis anticus, with the fibres of which it is continuous, and inserted into the bicipital fascia and inner side of the tendon of the Biceps. In most cases this additional slip passes behind the brachial artery in its course down the arm. Occasionally the third head consists of two slips, which pass down, one in front, the other behind the artery, concealing the vessel in the lower half of the arm.

7. *Posterior Humeral Region*

## Triceps.

## Subanconeus.

The **Triceps** (*Triceps extensor cubiti*) (fig. 343) is situated on the back of the arm, extending the entire length of the posterior surface of the humerus. It is of large size, and divided above into three parts: hence its name. These three portions have been named (1) the middle, scapular, or long head; (2) the external, or long humeral; and (3) the internal, or short humeral head.

The *middle* or *scapular head* arises, by a flattened tendon, from a rough triangular depression on the scapula, immediately below the glenoid cavity, being blended at its upper part with the capsular ligament; the muscular fibres pass downwards between the two other portions of the muscle, and join with them in the common tendon of insertion.

The *external head* arises from the posterior surface of the shaft of the humerus, between the insertion of the Teres minor and the upper part of the musculo-spiral groove; from the external border of the humerus and the external intermuscular septum: the fibres from this origin converge towards the common tendon of insertion.

The *internal head* arises from the posterior surface of the shaft of the humerus, below the groove for the musculo-spiral nerve: commencing above, narrow and pointed, below the insertion of the Teres major, and extending to within an inch of the trochlear surface: it also arises from the internal border of the humerus and from the back of the whole length of the internal and lower part of the external intermuscular septa. The fibres of this portion of the muscle are directed, some downwards to the olecranon, whilst others converge to the common tendon of insertion.

The *common tendon* of the Triceps commences about the middle of the back part of the muscle: it consists of two aponeurotic laminae, one of which is subcutaneous and covers the posterior surface of the muscle for the lower half of its extent; the other is more deeply seated in the substance of the muscle; after receiving the attachment of the muscular fibres, they join together above the elbow, and are inserted, for the most part, into the back part of the upper surface of the olecranon process; a band of fibres is, however, continued downwards, on the outer side, over the Anconeus, to blend with the deep fascia of the forearm. A small bursa, occasionally multilocular, is situated on the front part of this surface, beneath the tendon.

The long head of the Triceps descends between the Teres minor and Teres major, dividing the triangular space between these two muscles and the humerus into two smaller spaces, one triangular, the other quadrangular (fig. 343). The triangular space contains the dorsalis scapulae vessels; it is bounded by the Teres minor above, the Teres major below, and the scapular head of the Triceps externally: the quadrangular space transmits the posterior circumflex vessels and the circumflex nerve; it is bounded by the Teres minor above, the Teres major below, the scapular head of the Triceps internally, and the humerus externally.

**Relations.**—By its *posterior surface*, with the Deltoid above: in the rest of its extent it is subcutaneous. By its *anterior surface*, with the humerus, musculo-spiral nerve, superior profunda vessels, and back part of the elbow-joint. Its *middle* or *long head* is in relation, behind, with the Deltoid and Teres minor; in front, with the Subscapularis, Latissimus dorsi, and Teres major.

The **Subanconeus** is a name given to a few fibres from the under surface of the lower part of the Triceps muscle, which are inserted into the posterior ligament of the elbow-joint. By some authors it is regarded as the analogue of the Subcrureus in the lower limb, but it is not a separate muscle.

**Nerves.**—The Triceps is supplied by the seventh and eighth cervical nerves through the musculo-spiral nerve.



**Actions.**—The Triceps is the great extensor muscle of the forearm, serving, when the forearm is flexed, to extend the elbow-joint. It is the direct antagonist of the Biceps and Brachialis anticus. When the arm is extended, the long head of the muscle may assist the Teres major and Latissimus dorsi in drawing the humerus backwards and in adducting it to the thorax. The long head of the Triceps protects the under part of the shoulder-joint, and prevents displacement of the head of the humerus downwards and backwards. The Subanconeus draws up the posterior ligament during extension of the forearm.

*Surgical Anatomy.*—The existence of the band of fibres from the Triceps to the fascia of the forearm is of importance in excision of the elbow, and should always be carefully preserved from injury by the operator, as by means of these fibres the patient is enabled to extend the forearm, a movement which would otherwise mainly be accomplished by gravity, that is to say, by allowing the forearm to drop from its own weight.

### III. MUSCLES AND FASCIAE OF THE FOREARM

*Dissection.*—To dissect the forearm, place the limb in the position indicated in fig. 339, make a vertical incision along the middle line from the elbow to the wrist, and a transverse incision at the extremity of this; the superficial structures being removed, the deep fascia of the forearm is exposed.

The **deep fascia** of the forearm, continuous above with that enclosing the arm, is a dense, highly glistening aponeurotic investment, which forms a general sheath enclosing the muscles in this region; it is attached, behind, to the olecranon and posterior border of the ulna, and gives off from its inner surface numerous intermuscular septa, which enclose each muscle separately. Below, it is continuous in front with the anterior annular ligament, and forms a sheath for the tendon of the Palmaris longus muscle, which passes over the annular ligament to be inserted into the palmar fascia. Behind, near the wrist-joint, it becomes much thickened by the addition of many transverse fibres, and forms the posterior annular ligament. It consists of circular and oblique fibres, connected together by numerous vertical fibres. It is much thicker on the dorsal than on the palmar surface, and at the lower than at the upper part of the forearm, and is strengthened by tendinous fibres derived from the Brachialis anticus and Biceps in front, and from the Triceps behind. Its inner surface gives origin to muscular fibres, especially at the upper part of the inner and outer sides of the forearm, and forms the boundaries of a series of conical-shaped cavities, in which the muscles are contained. Besides the vertical septa separating each muscle, transverse septa are given off both on the anterior and posterior surfaces of the forearm, separating the deep from the superficial layer of muscles. Numerous apertures exist in the fascia for the passage of vessels and nerves; one of these, of large size, situated at the front of the elbow, serves for the passage of a communicating branch between the superficial and deep veins.

The muscles of the forearm may be subdivided into groups corresponding to the region they occupy. One group occupies the inner and anterior aspect of the forearm, and comprises the Flexor and Pronator muscles. Another group occupies its outer side; and a third its posterior aspect. The two latter groups include all the Extensor and Supinator muscles.

#### 8. Anterior Radio-Ulnar Region

The muscles in this region are divided for convenience of description into two groups or layers, superficial and deep.

##### *Superficial layer*

Pronator radii teres.	Flexor carpi ulnaris.
Flexor carpi radialis.	Flexor sublimis digitorum.
Palmaris longus.	

These muscles take origin from the internal condyle of the humerus by a common tendon.

The **Pronator radii teres** arises by two heads. One, the larger and more superficial, arises from the humerus, immediately above the internal condyle, and from the tendon common to the origin of the other muscles; also from the fascia of the forearm, and intermuscular septum between it and the Flexor carpi radialis. The other head is a thin fasciculus, which arises from the inner side of the coronoid process of the ulna, joining the preceding at an acute angle. Between the two heads passes the median nerve. The muscle passes obliquely across the forearm from the inner to the outer side, and terminates in a flat tendon, which turns over the outer margin of the radius, and is inserted into a rough impression at the middle of the outer surface of the shaft of that bone.

**Relations.**—By its *anterior surface* throughout the greater part of its extent with the deep fascia; at its insertion it is crossed by the radial vessels and nerve and covered by the Supinator longus. By its *posterior surface*, with the Brachialis anticus, Flexor sublimis digitorum, the median nerve, and ulnar artery: the small, or deep, head being interposed between the two latter structures. Its *outer border* forms the inner boundary of a triangular space, in which is placed the brachial artery, median nerve, and tendon of the Biceps muscle. Its *inner border* is in contact with the Flexor carpi radialis.

*Surgical Anatomy.*—This muscle, when suddenly brought into very active use, as in the game of lawn tennis, is apt to be strained, producing slight swelling, tenderness, and pain on putting the muscle into action. This is known as ‘lawn-tennis arm.’

The **Flexor carpi radialis** lies on the inner side of the preceding muscle. It arises from the internal condyle by the common tendon, from the fascia of the forearm, and from the intermuscular septa between it and the Pronator radii teres, on the outside; the Palmaris longus, internally; and the Flexor sublimis digitorum, beneath. Slender and aponeurotic in structure at its commencement, it increases in size, and terminates in a tendon, which forms the lower two-thirds of its length. This tendon passes through a canal on the outer side of the annular ligament, runs through a groove in the os trapezium (which is converted into a canal by a fibrous sheath, and lined by a synovial membrane), and is inserted into the base of the metacarpal bone of the index finger, and by a slip into the base of the metacarpal bone of the middle finger. The radial artery lies between the tendon of this muscle and the Supinator longus, and may easily be tied in this situation.

**Relations.**—By its *superficial surface*, with the deep fascia and the integument. By its *deep surface*, with the Flexor sublimis digitorum, Flexor longus pollicis, and wrist-joint. By its *outer border*, with the Pronator radii teres and the radial vessels. By its *inner border*, with the Palmaris longus above, and the median nerve below.

The **Palmaris longus** is a slender, fusiform muscle, lying on the inner side of the preceding. It arises from the inner condyle of the humerus by the common tendon, from the deep fascia, and the intermuscular septa between it and the adjacent muscles. It terminates in a slender, flattened tendon, which passes over the annular ligament, to end in the palmar fascia, frequently sending a tendinous slip to the short muscles of the thumb. This muscle is often absent.

**Relations.**—By its *superficial surface*, with the deep fascia. By its *deep surface*, with the Flexor sublimis digitorum. *Internally*, with the Flexor carpi ulnaris. *Externally*, with the Flexor carpi radialis. The median nerve lies close to the tendon, just above the wrist, on its inner and posterior side.

The **Flexor carpi ulnaris** lies along the ulnar side of the forearm. It arises by two heads, connected by a tendinous arch, beneath which pass the ulnar nerve and posterior ulnar recurrent artery. One head arises from the inner condyle of the humerus by the common tendon; the other from the inner margin of the olecranon and from the upper two-thirds of the posterior border of the ulna by



an aponeurosis, common to it and the Extensor carpi ulnaris and Flexor profundus digitorum; and from the intermuscular septum between it and the Flexor sublimis digitorum. The fibres terminate in a tendon, which occupies the anterior part of the lower half of the muscle, and is inserted into the pisiform bone, and is prolonged from this to the fifth metacarpal and unciform bones, by the pisolmetacarpal and pisoluncinate ligaments: it is also attached by a few fibres to the annular ligament. The ulnar artery lies on the outer side of the tendon of this muscle, in the lower two-thirds of the forearm; the tendon forming a guide in tying the vessel in this situation.

**Relations.**—By its *superficial surface*, with the deep fascia, with which it is intimately connected for a considerable extent. By its *deep surface*, with the Flexor sublimis digitorum, the Flexor profundus digitorum, the Pronator quadratus, and the ulnar vessels and nerve. By its *outer or radial border*, with the Palmaris longus above, and the ulnar vessels and nerve below.

The **Flexor sublimis digitorum** (*perforatus*) is placed beneath the preceding muscles, which therefore must be removed in order to bring its attachment into view. It is the largest of the muscles of the superficial layer, and arises by three heads. One head arises from the internal condyle of the humerus by the common tendon, from the internal lateral ligament of the elbow-joint, and from the intermuscular septum common to it and the preceding muscles. The second head arises from the inner side of the coronoid process of the ulna, above the ulnar origin of the Pronator radii teres (fig. 211, p. 239). The third head arises from the oblique line of the radius, extending from the tubercle to the insertion of the Pronator radii teres. The fibres pass vertically downwards, forming a broad and thick muscle, which speedily divides into two planes of muscular fibres, superficial and deep: the superficial plane divides into two parts which end in tendons for the middle and ring fingers; the deep plane also divides into two parts, which end in tendons for the index and little fingers, but previously to having done so, it gives off a muscular slip, which joins that part of the superficial plane which is intended for the ring finger. As the four tendons thus formed pass beneath the annular ligament into the palm of the hand, they are arranged in pairs, the superficial pair corresponding to the middle and ring fingers, the deep pair to the index and little fingers. The tendons diverge from one another as they pass onwards. Opposite the bases of the first phalanges each tendon divides into two slips, to allow of the passage of the corresponding tendon of the Flexor profundus digitorum; the two portions of the tendon then unite and form a grooved channel for the reception of the accompanying deep flexor tendon. Finally they subdivide a second time, to be inserted into the sides of the second phalanges about their middle. After leaving the palm, these tendons accompan-

FIG. 344.—Front of the left forearm. Superficial muscles.

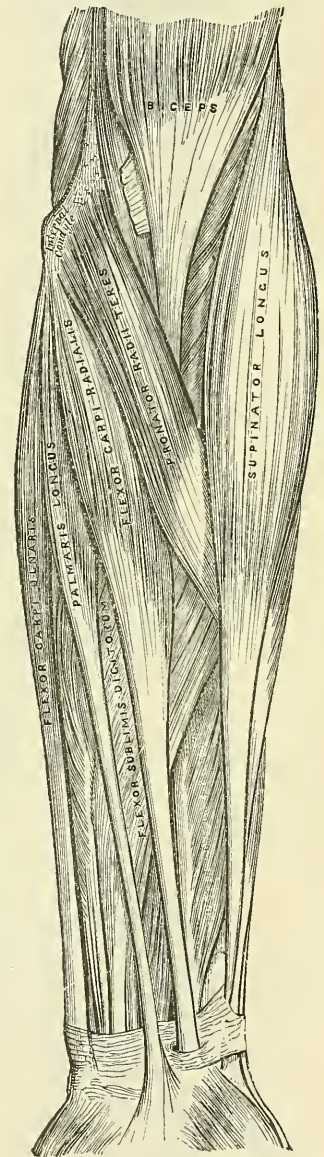
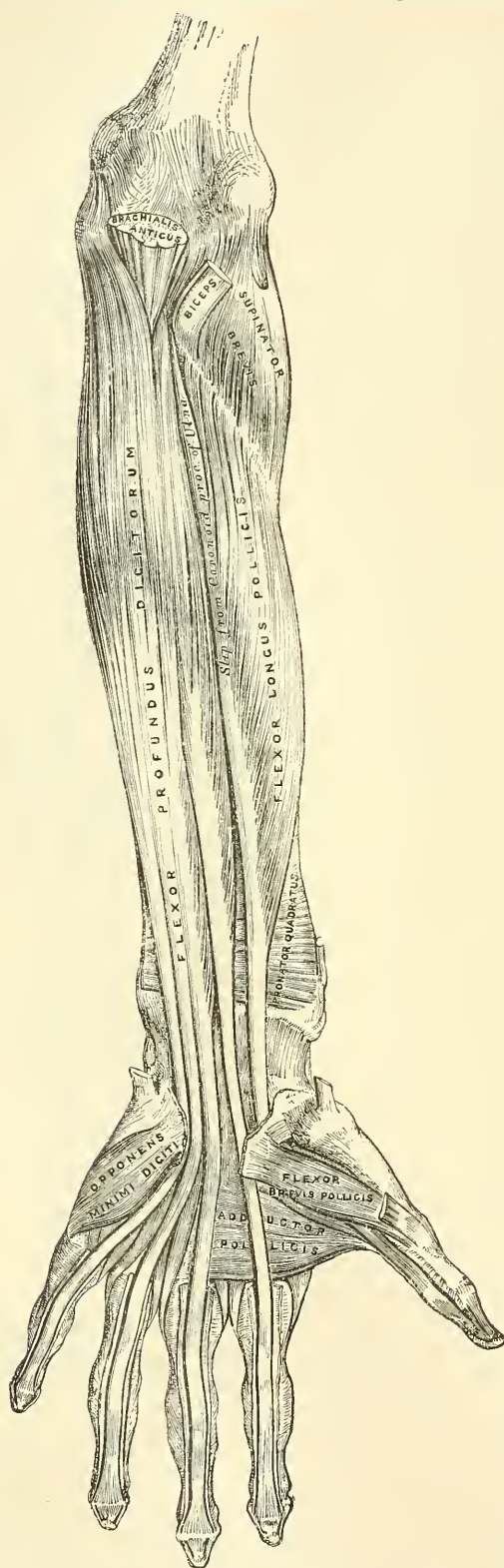




FIG. 345.—Front of the left forearm. Deep muscles.



by the deep flexor tendons lie in osseo-aponeurotic canals (fig. 345). These canals are formed by strong fibrous bands, which arch across the tendons, and are attached on each side to the margins of the phalanges. Opposite the middle of the proximal and second phalanges the sheath is very strong, and the fibres pass transversely; but opposite the joints it is much thinner, and the fibres pass obliquely. Each sheath is lined by a synovial membrane, which is reflected on the contained tendon.

**Relations.**—In the forearm, by its *superficial surface*, with the deep fascia and all the preceding superficial muscles; by its *deep surface*, with the Flexor profundus digitorum, Flexor longus pollicis, the ulnar vessels and nerve, and the median nerve. In the hand, its tendons are in relation, *in front*, with the palmar fascia, superficial palmar arch, and the branches of the median nerve; *behind*, with the tendons of the deep Flexor and the Lumbricales.

#### Deep Layer

Flexor profundus digitorum.  
Flexor longus pollicis.  
Pronator quadratus.

**Dissection.**—Divide each of the superficial muscles at its centre, and turn either end aside; the deep layer of muscles, together with the median nerve and ulnar vessels, will then be exposed.

The **Flexor profundus digitorum** (*perforans*) (fig. 345) is situated on the ulnar side of the forearm, immediately beneath the superficial Flexors. It arises from the upper three-fourths of the anterior and inner surfaces of the shaft of the ulna, embracing the insertion of the Brachialis anticus above, and

extending, below, to within a short distance of the Pronator quadratus. It also arises from a depression on the inner side of the coronoid process; by an aponeurosis from the upper three-fourths of the posterior border of the ulna, in common with the Flexor and Extensor carpi ulnaris; and from the ulnar half of the interosseous membrane. The fibres form a fleshy belly of considerable size, which divides into four tendons: these pass under the annular ligament beneath the tendons of the Flexor sublimis digitorum. Opposite the first phalanges, the tendons pass between the two slips of the tendons of the Flexor sublimis digitorum, and are finally inserted into the bases of the last phalanges. The tendon of the index finger is distinct; the rest are connected together by cellular tissue and tendinous slips, as far as the palm of the hand. The tendons of this and those of the Flexor sublimis digitorum, whilst contained in the osseo-aponeurotic canals of the fingers, are invested in a synovial sheath, and are connected to each other, and to the phalanges, by slender, tendinous filaments, called *vincula accessoria tendinum*. One of these connects the deep tendon to the bone, before it passes through the superficial tendon; a second connects the two tendons together, after the deep tendons have passed through; and a third connects the deep tendon to the head of the second phalanx. This last consists largely of yellow elastic tissue, and may assist in drawing down the tendon after flexion of the finger.\*

Four small muscles, the Lumbricales, are connected with the tendons of the Flexor profundus in the palm. They will be described with the muscles in that region.

**Relations.**—By its *superficial surface*, in the forearm, with the Flexor sublimis digitorum, the Flexor carpi ulnaris, the ulnar vessels and nerve, and the median nerve; and in the hand, with the tendons of the superficial Flexor. By its *deep surface*, in the forearm, with the ulna, the interosseous membrane, the Pronator quadratus; and in the hand, with the Interossei, Adductores pollicis, and deep palmar arch. By its *ulnar border*, with the Flexor carpi ulnaris. By its *radial border*, with the Flexor longus pollicis, the anterior interosseous vessels and nerve being interposed.

The **Flexor longus pollicis** is situated on the radial side of the forearm, lying on the same plane as the preceding. It arises from the grooved anterior surface of the shaft of the radius: commencing, above, immediately below the tuberosity and oblique line, and extending, below, to within a short distance of the Pronator quadratus. It also arises from the adjacent part of the interosseous membrane, and generally by a fleshy slip from the base of the coronoid process. The fibres pass downwards, and terminate in a flattened tendon, which passes beneath the annular ligament, is then lodged in the interspace between the outer head of the Flexor brevis pollicis and the Adductor obliquus pollicis, and, entering an osseo-aponeurotic canal similar to those for the other flexor tendons, is inserted into the base of the last phalanx of the thumb.

**Relations.**—By its *superficial surface*, with the Flexor sublimis digitorum, Flexor carpi radialis, Supinator longus, and radial vessels. By its *deep surface*, with the radius, interosseous membrane, and Pronator quadratus. By its *ulnar border*, with the Flexor profundus digitorum, from which it is separated by the anterior interosseous vessels and nerve.

The **Pronator quadratus** is a small, flat, quadrilateral muscle, extending transversely across the front of the radius and ulna, above their carpal extremities. It arises from the oblique or pronator ridge on the lower part of the anterior surface of the shaft of the ulna; from the lower fourth of the anterior surface, and the anterior border of the ulna; and from a strong aponeurosis which covers the inner third of the muscle. The fibres pass horizontally outwards, to be inserted into the lower fourth of the anterior surface and anterior border of the shaft of the radius.

**Relations.**—By its *superficial surface*, with the Flexor profundus digitorum,

\* Marshall, *Brit. and For. Med.-Chir. Rev.*, 1853.

the Flexor longus pollicis, Flexor carpi radialis, and the radial vessels. By its *deep surface*, with the radius, ulna, and interosseous membrane.

**Nerves.**—All the muscles of the superficial layer are supplied by the median nerve, excepting the Flexor carpi ulnaris, which is supplied by the ulnar. The Pronator radii teres and the Flexor carpi radialis derive their supply primarily from the sixth cervical; the Palmaris longus from the eighth cervical; the Flexor sublimis digitorum from the seventh and eighth cervical and first dorsal, and the Flexor carpi ulnaris from the eighth cervical and first dorsal nerves. Of the deep layer, the Flexor profundus digitorum is supplied by the eighth cervical and first dorsal through the ulnar and anterior interosseous branch of the median. The remaining two muscles, Flexor longus pollicis and Pronator quadratus, are also supplied by the eighth cervical and first dorsal through the anterior interosseous branch of the median.

**Actions.**—These muscles act upon the forearm, the wrist, and hand. The Pronator radii teres helps to rotate the radius upon the ulna, rendering the hand prone; when the radius is fixed, it assists the other muscles in flexing the forearm. The Flexor carpi radialis is one of the flexors of the wrist; when acting alone, it flexes the wrist, inclining it to the radial side. It can also assist in pronating the forearm and hand, and, by continuing its action, in bending the elbow. The Flexor carpi ulnaris is one of the flexors of the wrist; when acting alone, it flexes the wrist, inclining it to the ulnar side; and by continuing to contract, it bends the elbow. The Palmaris longus is a tensor of the palmar fascia. It also assists in flexing the wrist and elbow. The Flexor sublimis digitorum flexes first the middle, and then the proximal phalanx. It assists in flexing the wrist and elbow. The Flexor profundus digitorum is one of the flexors of the phalanges. After the Flexor sublimis has bent the second phalanx, the Flexor profundus flexes the terminal one; but it cannot do so until after the contraction of the superficial muscle. It also assists in flexing the wrist. The Flexor longus pollicis is a flexor of the phalanges of the thumb. When the thumb is fixed, it also assists in flexing the wrist. The Pronator quadratus helps to rotate the radius upon the ulna, rendering the hand prone.

#### 9. *Radial Region* (fig. 346)

Supinator longus.

Extensor carpi radialis longior.

Extensor carpi radialis brevior.

**Dissection.**—Divide the integument in the same manner as in the dissection of the anterior brachial region; and, after having examined the cutaneous vessels and nerves and deep fascia, remove all these structures. The muscles will then be exposed. The removal of the fascia will be considerably facilitated by detaching it from below upwards. Great care should be taken to avoid cutting across the tendons of the muscles of the thumb, which cross obliquely the larger tendons running down the back of the radius.

The **Supinator longus** (brachio-radialis) is the most superficial muscle on the radial side of the forearm: it is fleshy for the upper two-thirds of its extent, tendinous below. It arises from the upper two-thirds of the external condyloid ridge of the humerus, and from the external intermuscular septum, being limited above by the musculo-spiral groove. The fibres terminate above the middle of the forearm in a flat tendon, which is inserted into the outer side of the base of the styloid process of the radius.

**Relations.**—By its *superficial surface*, with the integument and fascia for the greater part of its extent; near its insertion it is crossed by the Extensor ossis metacarpi pollicis and the Extensor brevis pollicis. By its *deep surface*, with the humerus, the Extensor carpi radialis longior and brevior, the insertion of the Pronator radii teres, and the Supinator brevis. By its *inner border*, above the elbow, with the Brachialis anticus, the musculo-spiral nerve, and radial recurrent artery; and in the forearm with the radial vessels and nerve.



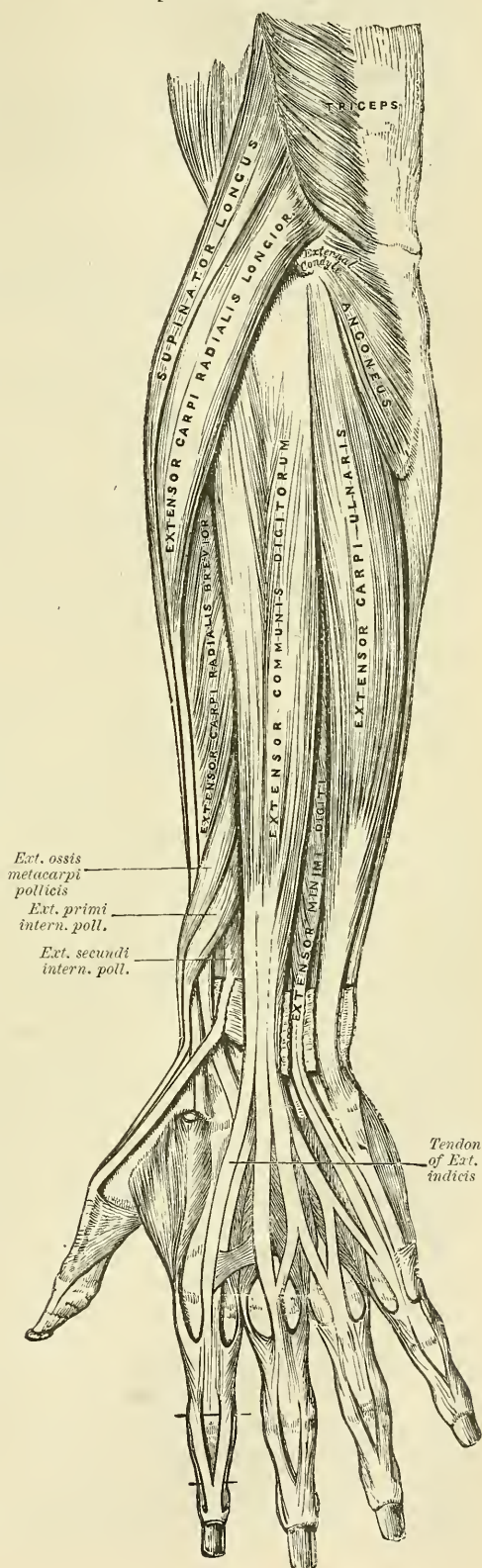
The **Extensor carpi radialis longior** is placed partly beneath the preceding muscle. It arises from the lower third of the external condyloid ridge of the humerus, from the external intermuscular septum, and by a few fibres from the common tendon of origin of the extensor muscles of the forearm. The fibres terminate at the upper third of the forearm in a flat tendon, which runs along the outer border of the radius, beneath the extensor tendons of the thumb; it then passes through a groove common to it and the Extensor carpi radialis brevior, immediately behind the styloid process, and is inserted into the base of the metacarpal bone of the index finger, on its radial side.

**Relations.**—By its *superficial surface*, with the Supinator longus, and fascia of the forearm. Its *outer side* is crossed obliquely by the extensor tendons of the thumb. By its *deep surface*, with the elbow-joint, the Extensor carpi radialis brevior, and back part of the wrist.

The **Extensor carpi radialis brevior** is shorter, as its name implies, and thicker than the preceding muscle, beneath which it is placed. It arises from the external condyle of the humerus, by a tendon common to it and the three following muscles: from the external lateral ligament of the elbow-joint; from a strong aponeurosis which covers its surface; and from the intermuscular septa between it and the adjacent muscles. The fibres terminate about the middle of the forearm in a flat tendon, which is closely connected with that of the preceding muscle, and accompanies it to the wrist, lying in the same groove on the posterior surface of the radius; it passes beneath the extensor tendons of the thumb, then beneath the annular ligament, and, diverging somewhat from its fellow, is inserted into the base of the metacarpal bone of the middle finger, on its radial side.

The tendons of the two preced-

FIG. 346.—Posterior surface of the forearm. Superficial muscles.



ing muscles pass through the same compartment of the annular ligament, and are lubricated by a single synovial membrane, but are separated from each other by a small vertical ridge of bone as they lie in the groove at the back of the radius.

**Relations.**—By its *superficial surface*, with the Extensor carpi radialis longior, and with the Extensor muscles of the thumb which cross it. By its *deep surface*, with the Supinator brevis, tendon of the Pronator radii teres, radius, and wrist-joint. By its *ulnar border*, with the Extensor communis digitorum.

#### 10. Posterior Radio-Ulnar Region (fig. 346)

The muscles in this region are divided for purposes of description into two groups or layers, superficial and deep.

##### *Superficial Layer*

Extensor communis digitorum.

Extensor carpi ulnaris.

Extensor minimi digiti.

Anconeus.

The **Extensor communis digitorum** is situated at the back part of the forearm. It arises from the external condyle of the humerus, by the common tendon; from the deep fascia, and the intermuscular septa between it and the adjacent muscles. Just below the middle of the forearm it divides into three fleshy masses, from which tendons proceed; these pass, together with the Extensor indicis, through a separate compartment of the annular ligament, lubricated by a synovial membrane. The tendons then diverge, the innermost one dividing into two; and all, after passing across the back of the hand, are inserted into the second and third phalanges of the fingers in the following manner: the outermost tendon, accompanied by the Extensor indicis, goes to the index finger; the second tendon is usually connected to the first by a thin transverse band, and receives a slip from the third tendon; it goes to the middle finger; the third tendon gives off the slip to the second, and receives a very considerable part of the fourth tendon on its way to the ring finger; the fourth, or innermost tendon, divides into two parts: one goes to join the third tendon, the other, reinforced by the Extensor minimi digiti, goes to the little finger. Each tendon opposite the metacarpophalangeal articulation becomes narrow and thickened, and gives off a thin fasciculus upon each side of the joint, which blends with the lateral ligaments and serves as the posterior ligament; after having passed the joint, it spreads out into a broad aponeurosis, which covers the whole of the dorsal surface of the first phalanx; and is reinforced, in this situation, by the tendons of the Interossei and Lumbricales. Opposite the first phalangeal joint this aponeurosis divides into three slips, a middle and two lateral: the former is inserted into the base of the second phalanx; and the two lateral, which are continued onwards along the sides of the second phalanx, unite by their contiguous margins, and are inserted into the dorsal surface of the last phalanx. As the tendons cross the phalangeal joints, they furnish them with posterior ligaments.

**Relations.**—By its *superficial surface*, with the fascia of the forearm and hand, the posterior annular ligament, and integument. By its *deep surface*, with the Supinator brevis, the Extensor muscles of the thumb and index finger, the posterior interosseous vessels and nerve, the wrist-joint, carpus, metacarpus, and phalanges. By its *radial border*, with the Extensor carpi radialis brevior. By its *ulnar border*, with the Extensor minimi digiti and Extensor carpi ulnaris.

The **Extensor minimi digiti** is a slender muscle placed on the inner side of the Extensor communis, with which it is generally connected. It arises from the common tendon by a thin, tendinous slip; and from the intermuscular septa between it and the adjacent muscles. Its tendon runs through a separate compartment in the annular ligament behind the inferior radio-ulnar joint, then



divides into two as it crosses the hand, one slip being joined by the slip from the innermost tendon of the common extensor. The three slips thus formed spread into a broad aponeurosis, which after receiving a slip from the Abductor minimi digiti is inserted into the second and third phalanges. The tendon is situated on the ulnar side of, and somewhat more superficial than, the common extensor.

The **Extensor carpi ulnaris** is the most superficial muscle on the ulnar side of the forearm. It arises from the external condyle of the humerus, by the common tendon; by an aponeurosis from the posterior border of the ulna in common with the Flexor carpi ulnaris and the Flexor profundus digitorum; and from the deep fascia of the forearm. This muscle terminates in a tendon, which runs through a groove behind the styloid process of the ulna, passes through a separate compartment in the annular ligament, and is inserted into the prominent tubercle on the ulnar side of the base of the metacarpal bone of the little finger.

**Relations.**—By its *superficial surface*, with the deep fascia of the forearm. By its *deep surface*, with the ulna, and the muscles of the deep layer.

The **Anconeus** is a small, triangular muscle, placed behind and below the elbow-joint, and appears to be a continuation of the external portion of the Triceps. It arises by a separate tendon from the back part of the outer condyle of the humerus, and is inserted into the side of the olecranon, and upper fourth of the posterior surface of the shaft of the ulna; its fibres diverge from their origin, the upper ones being directed transversely, the lower obliquely inwards.

**Relations.**—By its *superficial surface*, with a strong fascia derived from the Triceps. By its *deep surface*, with the elbow-joint, the orbicular ligament, the ulna, and a small portion of the Supinator brevis.

#### *Deep Layer* (fig. 348)

Supinator brevis.

Extensor brevis pollicis.

Extensor ossis metacarpi pollicis.

Extensor longus pollicis.

Extensor indicis.

The **Supinator brevis** (fig. 347) is a broad muscle, of a hollow cylindrical form, curved round the upper third of the radius. It consists of two distinct planes of muscular fibres, between which lies the posterior interosseous nerve. The two planes arise in common: the superficial one by tendinous, and the deeper by muscular fibres from the external condyle of the humerus; from the external lateral ligament of the elbow-joint, and the orbicular ligament of the radius; from the ridge on the ulna, which runs obliquely downwards from the posterior extremity of the lesser sigmoid cavity; from the triangular depression in front of it; and from a tendinous expansion which covers the surface of the muscle. The superficial fibres surround the upper part of the radius, and are inserted into the outer edge of the bicipital tuberosity and to the oblique line of the radius, as low down as the insertion of the Pronator radii teres. The upper fibres of the deeper plane form a sling-like fasciculus, which encircles the neck of the radius above the tuberosity and is attached to the back part of its inner surface: the greater part of this portion of the muscle is inserted into the posterior and external surface of the shaft, midway between the oblique line and the head of the bone. Between the insertion of the two planes, the posterior interosseous nerve lies on the shaft of the bone.

**Relations.**—By its *superficial surface*, with the superficial Extensor and Supinator muscles, and the radial vessels and nerve. By its *deep surface*, with the elbow-joint, the interosseous membrane, and the radius.

The **Extensor ossis metacarpi pollicis** is the most external and the largest of the deep extensor muscles; it lies immediately below the Supinator brevis, with which it is sometimes united. It arises from the posterior surface of the shaft of the ulna below the insertion of the Anconeus, from the interosseous membrane, and from the middle third of the posterior surface of the shaft of the



radius. Passing obliquely downwards and outwards, it terminates in a tendon, which runs through a groove on the outer side of the styloid process of the radius, accompanied by the tendon of the Extensor brevis pollicis, and is

FIG. 347.—Supinator brevis. (From a preparation in the Museum of the Royal College of Surgeons of England.)

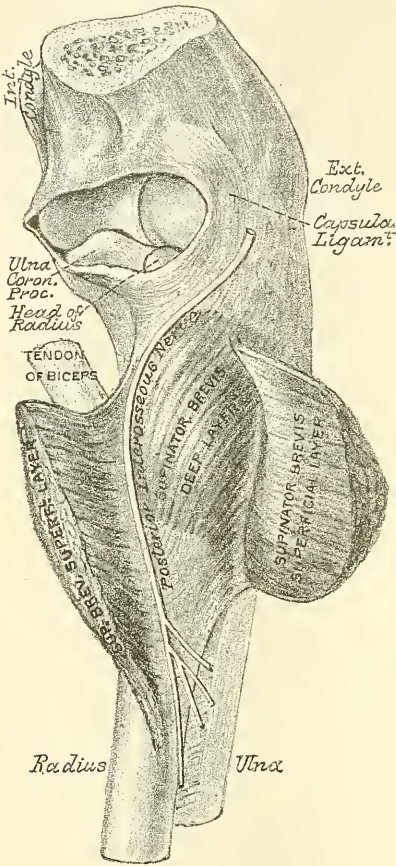
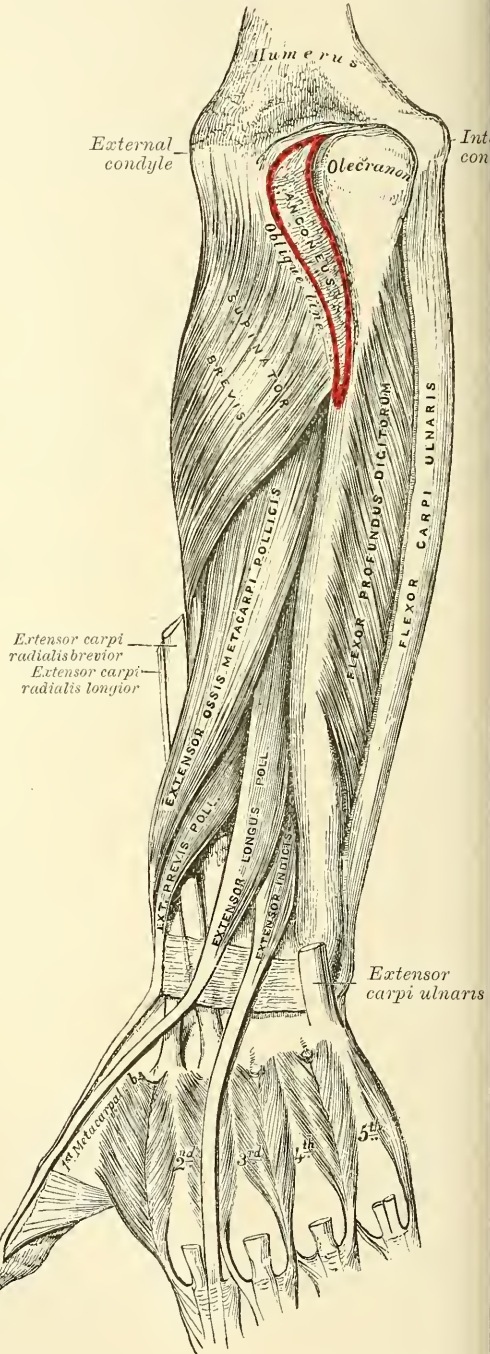


FIG. 348.—Posterior surface of the forearm. Deep muscles.



inserted into the base of the metacarpal bone of the thumb. It occasionally gives off two slips, near its insertion: one to the Trapezium, and the other to blend with the origin of the Abductor pollicis.

**Relations.**—By its *superficial surface*, with the Extensor communis digitorum, Extensor minimi digiti, and fascia of the forearm; and with the branches of the posterior interosseous artery and nerve which cross it. By its *deep surface*, with the ulna, interosseous membrane, radius, the tendons of the Extensor carpi radialis longior and brevior, which it crosses obliquely; and, at the outer side of the wrist, with the radial vessels. By its *upper border*, with the Supinator brevis. By its *lower border*, with the Extensor brevis pollicis.

The **Extensor brevis pollicis** (*Extensor primi internodii pollicis*), the smallest muscle of this group, lies on the inner side of the preceding. It arises from the posterior surface of the shaft of the radius, below the Extensor ossis metacarpi pollicis and from the interosseous membrane. Its direction is similar to that of the Extensor ossis metacarpi pollicis, its tendon passing through the same groove on the outer side of the styloid process, to be inserted into the base of the first phalanx of the thumb.

**Relations.**—The same as those of the Extensor ossis metacarpi pollicis.

The **Extensor longus pollicis** (*Extensor secundi internodii pollicis*) is much larger than the preceding muscle, the origin of which it partly covers in. It arises from the posterior surface of the shaft of the ulna, below the origin of the Extensor ossis metacarpi pollicis, and from the interosseous membrane. It terminates in a tendon, which passes through a separate compartment in the annular ligament, lying in a narrow, oblique groove at the back part of the lower end of the radius. It then crosses obliquely the tendons of the Extensor carpi radialis longior and brevior, being separated from the other extensor tendons of the thumb by a triangular interval, in which the radial artery is found; and is finally inserted into the base of the last phalanx of the thumb.

**Relations.**—By its *superficial surface*, with the same parts as the Extensor ossis metacarpi pollicis. By its *deep surface*, with the ulna, interosseous membrane, the posterior interosseous nerve, radius, the wrist, the radial vessels, and metacarpal bone of the thumb.

The **Extensor indicis** is a narrow, elongated muscle, placed on the inner side of, and parallel with, the preceding. It arises from the posterior surface of the shaft of the ulna, below the origin of the Extensor longus pollicis and from the interosseous membrane. Its tendon passes with the Extensor communis digitorum through the same canal in the annular ligament, and subsequently joins the tendon of the Extensor communis which belongs to the index finger, opposite the lower end of the corresponding metacarpal bone, lying to the ulnar side of the tendon from the common extensor.

**Relations.**—The relations are similar to those of the preceding muscles.

**Nerves.**—The Supinator longus is supplied by the sixth, the Extensor carpi radialis longior by the sixth and seventh, and the Anconeus by the seventh and eighth cervical nerves, all through the musculo-spiral nerve; the remaining muscles of the radial and posterior brachial region are supplied through the posterior interosseous nerve, the Supinator brevis being supplied by the sixth cervical, the Extensor carpi radialis brevior by the sixth and seventh cervicals, and all the other muscles by the seventh cervical.

**Actions.**—The muscles of the radial and posterior brachial regions, which comprise all the extensor and supinator muscles, act upon the forearm, wrist, and hand; they are the direct antagonists of the pronator and flexor muscles. The Anconeus assists the Triceps in extending the forearm. The chief action of the Supinator longus is that of a flexor of the elbow-joint, but in addition to this it may act both as a supinator or a pronator: that is to say, if the forearm is forcibly pronated, it will act as a supinator, and bring the bones into a position midway between supination and pronation; and, *vice versa*, if the arm is forcibly supinated, it will act as a pronator, and bring the bones into the same position, midway between supination and pronation. The action of the muscle is therefore to throw the forearm and hand into the position they naturally occupy when placed across the chest. The Supinator brevis is a supinator: that is to say, when the radius has been carried across the ulna in pronation, and the back of the hand is directed forwards, this muscle carries the radius back again to its normal position on the outer side of the ulna, and the palm of the hand is again directed forwards. The Extensor carpi radialis longior extends the wrist and abducts the hand. It may also assist in bending the elbow-joint; at all events it serves to fix or steady this articulation. The Extensor carpi radialis brevior assists the Extensor carpi radialis longior in extending the wrist, and







inserted into its anterior surface the tendon of the Palmaris longus and part of the tendon of the Flexor carpi ulnaris, and has arising from it, below, the small muscles of the thumb and little finger. Beneath it pass the tendons of the Flexor sublimis and profundus digitorum, the Flexor longus pollicis, and the median nerve.

**The Synovial Membranes of the Flexor Tendons at the Wrist.**

There are two synovial membranes which enclose all the tendons as they pass beneath this ligament, one for the Flexor sublimis and profundus digitorum, the other for the Flexor longus pollicis. They extend up into the forearm for about an inch above the annular ligament, and downwards about half-way along the metacarpal bone, where they terminate in a blind diverticulum around each pair of tendons, with the exception of the thumb and sometimes the little finger; in these two fingers the diverticulum is continued on and communicates with the synovial sheath of the tendons. In the other three fingers the synovial sheath of the tendons in the fingers begins as a blind pouch without communication with the large synovial sac (fig. 351).

*Surgical Anatomy.*—This arrangement of the synovial sheaths explains the fact that thecal abscess in the thumb and little finger is liable to be followed by abscesses in the forearm, from extension of the inflammation along the continuous synovial sheaths. Ganglion is apt to occur in this situation, constituting 'compound palmar ganglion': it presents an hour-glass outline, with a swelling in front of the wrist and in the palm of the hand, and a constriction corresponding to the annular ligament between the two. The fluid can be forced from the one swelling to the other under the ligament.

The **Posterior Annular Ligament** is a strong, fibrous band, extending transversely across the back of the wrist, and consisting of the deep fascia of the back of the forearm, strengthened by the addition of some transverse fibres. It forms a sheath for the extensor tendons in their passage to the fingers, being attached, internally, to the styloid process of the ulna, the cuneiform and pisiform bones; externally, to the margin of the radius; and, in its passage across the wrist, to

FIG. 350.—Transverse section through the carpus, showing the relative positions of the tendons, vessels, and nerves. (Henle.)

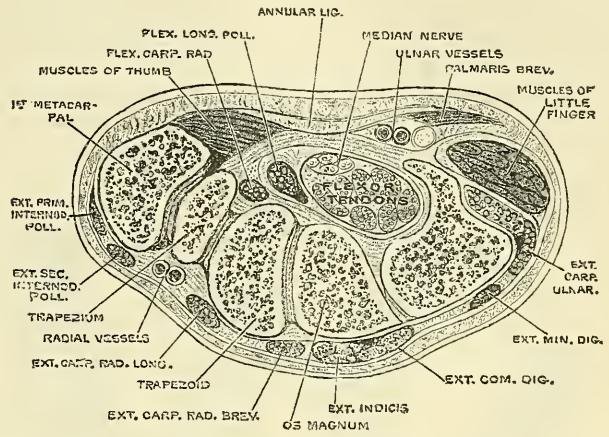
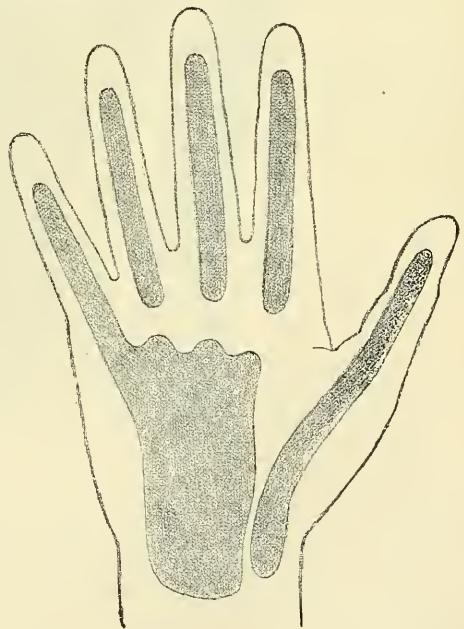
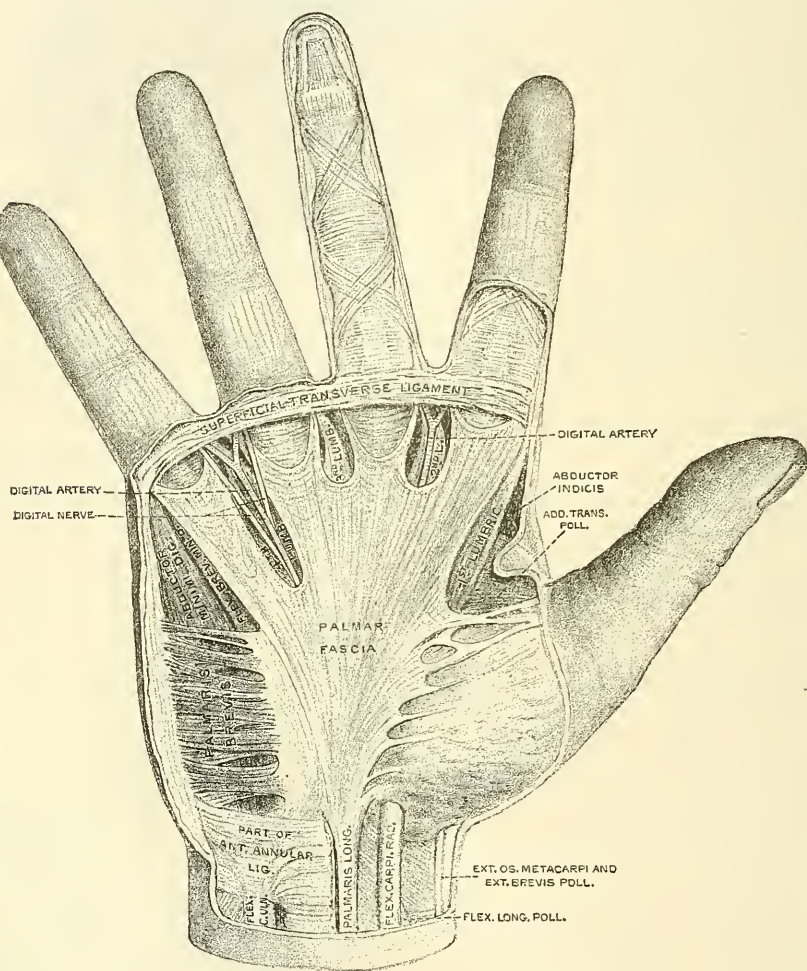


FIG. 351.—Diagram showing the arrangement of the synovial sheaths of the palm and fingers.



the elevated ridges on the posterior surface of the radius. Its presents six compartments for the passage of tendons, each of which is lined by a separate synovial membrane. These are, from without inwards:—1. On the outer side of the styloid process, for the tendons of the Extensor ossis metacarpi and Extensor brevis pollicis. 2. Behind the styloid process, for the tendons of the Extensor carpi radialis longior and brevior. 3. About the middle of the posterior surface of the radius, for the tendon of the Extensor longus pollicis. 4. To the inner side of the latter, for the tendons of the Extensor communis digitorum and Extensor indicis. 5. Opposite the interval between the radius

FIG. 352.—Palmar fascia. (Altered from a dissection in the Museum of the Royal College of Surgeons of England.)



and ulna, for the Extensor minimi digiti. 6. Grooving the back of the ulna, for the tendon of the Extensor carpi ulnaris. The synovial membranes lining these sheaths are usually very extensive, reaching from above the annular ligament, down upon the tendons for a variable distance on the back of the hand.

The **deep palmar fascia** (fig. 352) forms a common sheath which invests the muscles of the hand. It consists of a central and two lateral portions.

The *central portion* occupies the middle of the palm, is triangular in shape, of great strength and thickness, and binds down the tendons in this situation. It is narrow above, being attached to the lower margin of the annular ligament, and receives the expanded tendon of the Palmaris longus muscle. Below, it is broad



and expanded, and divides into four slips, for the four fingers. Each slip gives off superficial fibres, which are inserted into the skin of the palm and finger, those to the palm joining the skin at the furrow corresponding to the metacarpophalangeal articulation, and those to the fingers passing into the skin at the transverse fold at the base of the fingers. The deeper part of each slip subdivides into two processes, which are inserted into the lateral margins of the anterior (glenoid) ligament of the metacarpophalangeal joint. From the sides of these processes, offsets are sent backwards, to be attached to the borders of the lateral surfaces of the metacarpal bones at their distal extremities. By this arrangement short channels are formed on the front of the lower ends of the metacarpal bones, through which the flexor tendons pass. Dr. W. W. Keen describes a fifth slip as frequently found passing to the thumb. The intervals left in the fascia, between the four fibrous slips, transmit the digital vessels and nerves, and the tendons of the Lumbricales. At the points of division of the palmar fascia into the slips above mentioned, numerous strong, transverse fibres bind the separate processes together. The palmar fascia is intimately adherent to the integument by dense fibro-areolar tissue forming the superficial palmar fascia, and gives origin by its inner margin to the *Palmaris brevis*; it covers the superficial palmar arch, the tendons of the flexor muscles, and the branches of the median and ulnar nerves; and on each side it gives off a vertical septum, which is continuous with the interosseous aponeurosis, and separates the lateral from the middle palmar group of muscles.

The *lateral portions* of the palmar fascia are thin, fibrous layers, which cover, on the radial side, the muscles of the ball of the thumb, and, on the ulnar side, the muscles of the little finger: they are continuous with the dorsal fascia, and in the palm with the central portion of the palmar fascia.

The **Superficial Transverse Ligament of the Fingers** is a thin, fibrous band, which stretches across the roots of the four fingers, and is closely attached to the skin of the clefts, and internally to the fifth metacarpal bone, forming a sort of rudimentary web. Beneath it the digital vessels and nerves pass onwards to their destination.

*Surgical Anatomy.*—The palmar fascia is liable to undergo contraction, producing a very inconvenient deformity, known as ‘Dupuytren’s contraction.’ The ring and little fingers are most frequently implicated, but the middle, the index, and the thumb may be involved. The proximal phalanx is drawn down and cannot be straightened, and the two distal phalanges become similarly flexed as the disease advances.

## II. Radial Region (figs. 353, 354)

Abductor pollicis.

Flexor brevis pollicis.

Opponens (Flexor ossis metacarpi) pollicis.

Adductor obliquus pollicis.

Adductor transversus pollicis.

The **Abductor pollicis** is a thin, flat muscle, placed immediately beneath the integument. It arises from the ridge of the os trapezium and annular ligament; and, passing outwards and downwards, is inserted by a thin, flat tendon into the radial side of the base of the first phalanx of the thumb, sending a slip to join the tendon of the *Extensor longus pollicis*.

**Relations.**—By its *superficial surface*, with the palmar fascia. By its *deep surface*, with the *Opponens pollicis*, from which it is separated by a thin aponeurosis. Its *inner border* is separated from the *Flexor brevis pollicis* by a narrow cellular interval.

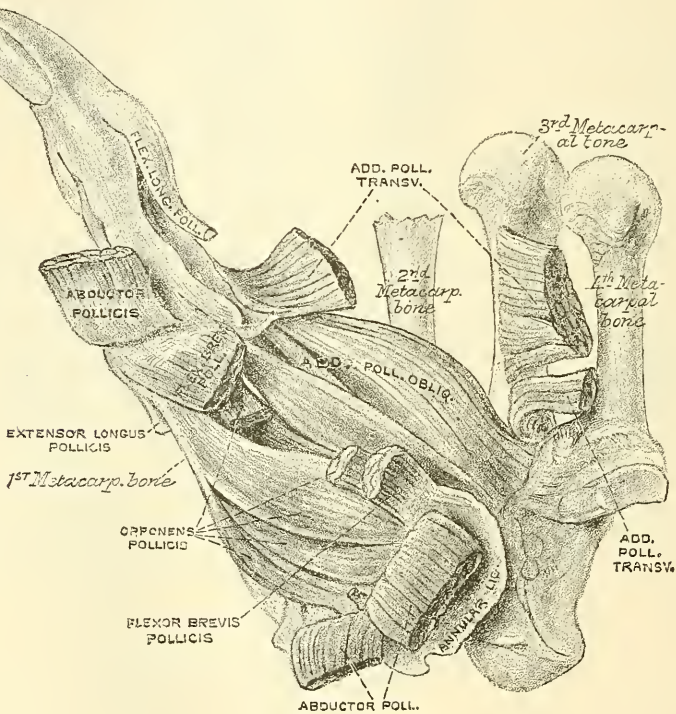
The **Opponens pollicis** is a small, triangular muscle, placed beneath the preceding. It arises from the palmar surface of the ridge on the trapezium and from the annular ligament, passes downwards and outwards, and is inserted into the whole length of the metacarpal bone of the thumb on its radial side.



**Relations.**—By its *superficial surface*, with the Abductor pollicis. By its *deep surface*, with the trapezio-metacarpal articulation. By its *inner border*, with the Flexor brevis pollicis.

The **Flexor brevis pollicis** is much larger than either of the two preceding muscles, beneath which it is placed. It consists of two portions, outer and inner. The outer and more superficial portion arises from the lower part of the ridge on the trapezium and outer two-thirds of the annular ligament, and passes along the outer side of the tendon of the Flexor longus pollicis; and, becoming tendinous, has a sesamoid bone developed in its tendon, and is inserted into the outer side of the base of the first phalanx of the thumb. The inner and deeper portion of the muscle is very small, and arises from the ulnar side of the first

FIG. 353.—Muscles of thumb. (From a preparation in the Museum of the Royal College of Surgeons of England.)



metacarpal bone, and is inserted into the inner side of the base of the first phalanx with the Adductor obliquus pollicis. A sesamoid bone is developed in the common tendon of insertion.

**Relations.**—By its *superficial surface*, with the palmar fascia. By its *deep surface*, with the tendon of the Flexor carpi radialis. By its *external surface*, with the Opposens pollicis. By its *internal surface*, with the Adductor obliquus pollicis.

The **Adductor obliquus pollicis** arises by several slips from the os magnum, the bases of the second and third metacarpal bones, the anterior carpal ligaments, and the sheath of the tendon of the Flexor carpi radialis. From this origin the greater number of fibres pass obliquely downwards and converge to a tendon, which, uniting with the tendons of the deeper portion of the Flexor brevis pollicis and the Adductor transversus, is inserted into the inner side of the base of the first phalanx of the thumb, a sesamoid bone being developed in the tendon of insertion. A considerable fasciculus, however, passes more obliquely outwards beneath the

tendon of the long flexor to join the superficial portion of the short flexor and the Abductor pollicis.\*

**Relations.**—By its *superficial surface*, with the Flexor longus pollicis and the outer head of the Flexor brevis pollicis. Its *deep surface* covers the Adductor transversus pollicis, and is in relation with the deep palmar arch, which passes between the two adductors.

The **Adductor transversus pollicis** (fig. 353) is the most deeply seated of this group of muscles. It is of a triangular form, arising by its broad base, from the lower two-thirds of the metacarpal bone of the middle finger on its palmar surface; the fibres, proceeding outwards, converge, to be inserted, with the inner tendon of the Flexor brevis pollicis, and the Adductor obliquus pollicis, into the ulnar side of the base of the first phalanx of the thumb. From the common tendon of insertion a slip is prolonged to the Extensor longus pollicis.

**Relations.**—By its *superficial surface*, with the Adductor obliquus pollicis, the tendons of the Flexor profundus, and the Lumbricales. Its *deep surface* covers the first two interosseous spaces, from which it is separated by a strong aponeurosis.

Three of these muscles of the thumb, the Abductor, the Adductor transversus, and the Flexor brevis pollicis, at their insertions, give off fibrous expansions which join the tendon of the Extensor longus pollicis. This permits of flexion of the proximal phalanx and extension of the terminal phalanx at the same time. These expansions, originally figured by Albinus, have been more recently described by M. Duchenne, 'Physiologie des Mouvements.'

**Nerves.**—The Abductor, Opponens, and outer head of the Flexor brevis pollicis are supplied by the sixth cervical through the median nerve; the inner head of the Flexor brevis, and the Adductors, by the eighth cervical through the ulnar nerve.

**Actions.**—The actions of the muscles of the thumb are almost sufficiently indicated by their names. This segment of the hand is provided with three extensors—an extensor of the metacarpal bone, an extensor of the first, and an extensor of the second phalanx; these occupy the dorsal surface of the forearm and hand. There are also three flexors on the palmar surface—a flexor of the metacarpal bone, a flexor of the proximal, and a flexor of the terminal phalanx; there is also an Abductor and two Adductors. The Abductor pollicis moves the metacarpal bone of the thumb outwards, that is, away from the index finger. The Flexor ossis metacarpi pollicis flexes the metacarpal bone, that is, draws it inwards over the palm, and at the same time rotates the bone, so as to turn the ball of the thumb towards the fingers, thus producing the movement of opposition. The Flexor brevis pollicis flexes the proximal phalanx of the thumb. The Adductores pollicis move the metacarpal bone of the thumb inwards, that is, towards the index finger. These muscles give to the thumb its extensive range of motion. It will be noticed, however, that in consequence of the position of the first metacarpal bone, these movements differ from the corresponding movements of the metacarpal bones of the other fingers. Thus extension of the thumb more nearly corresponds to the motion of abduction in the other fingers, and flexion to adduction.

## 12. Ulnar Region (fig. 354)

### Palmaris brevis

Abductor minimi digiti.

Flexor brevis minimi digiti.

Opponens (Flexor ossis metacarpi) minimi digiti.

The **Palmaris brevis** is a thin quadrilateral muscle, placed beneath the integument on the ulnar side of the hand. It arises by tendinous fasciculi, from the

\* This muscle was formerly described as the deep portion of the Flexor brevis pollicis.







ulnar side of the base of the first phalanx of the little finger. The other slip passes over the expansion, and is inserted into the ulnar border of the aponeurosis of the Extensor minimi digiti.

**Relations.**—By its *superficial surface*, with the inner portion of the palmar fascia, and the Palmaris brevis. By its *deep surface*, with the Flexor ossis metacarpi minimi digiti. By its *outer border*, with the Flexor brevis minimi digiti.

The **Flexor brevis minimi digiti** lies on the same plane as the preceding muscle, on its radial side. It arises from the tip of the unciform process of the unciform bone, and anterior surface of the annular ligament, and is inserted into the base of the first phalanx of the little finger. It is separated from the Abductor at its origin, by the deep branches of the ulnar artery and nerve. This muscle is sometimes wanting; the Abductor is then, usually, of large size.

**Relations.**—By its *superficial surface*, with the internal portion of the palmar fascia, and the Palmaris brevis. By its *deep surface*, with the Opponens.

The **Opponens minimi digiti** (fig. 345) is of a triangular form, and placed immediately beneath the preceding muscles. It arises from the unciform process of the unciform bone, and contiguous portion of the annular ligament; its fibres pass downwards and inwards, to be inserted into the whole length of the metacarpal bone of the little finger, along its ulnar margin.

**Relations.**—By its *superficial surface*, with the Flexor brevis, and Abductor minimi digiti. By its *deep surface*, with the Interossei muscles in the fourth metacarpal space, the metacarpal bone, and the Flexor tendons of the little finger.

**Nerves.**—All the muscles of this group are supplied by the eighth cervical nerve through the ulnar nerve.

**Actions.**—The Abductor minimi digiti abducts the little finger from the middle line of the hand. It corresponds to a dorsal interosseous muscle. It also assists in flexing the proximal phalanx. The Flexor brevis minimi digiti abducts the little finger from the middle line of the hand. It also assists in flexing the proximal phalanx. The Opponens minimi digiti draws forwards the fifth metacarpal bone, so as to deepen the hollow of the palm. The Palmaris brevis corrugates the skin on the inner side of the palm of the hand.

### 13. Middle Palmar Region

Lumbricales.                      Interossei palmares.  
Interossei dorsales.

The **Lumbricales** (fig. 354) are four small fleshy fasciculi, accessories to the deep Flexor muscle. They arise by fleshy fibres from the tendons of the deep Flexor: the first and second, from the radial side and palmar surface of the tendons of the index and middle fingers; the third, from the contiguous sides of the tendons of the middle and ring fingers; and the fourth, from the contiguous sides of the tendons of the ring and little fingers. They pass to the radial side of the corresponding fingers, and opposite the metacarpo-phalangeal articulation each tendon is inserted into the tendinous expansion of the Extensor communis digitorum, covering the dorsal aspect of each finger.

The **Interossei muscles** (figs. 355, 356) are so named from occupying the intervals between the metacarpal bones. They are divided into two sets, a dorsal and palmar: the former are four in number, one in each metacarpal space; the latter, three in number, lie upon the metacarpal bones.

The **Dorsal interossei** are four in number, larger than the palmar, and occupy the intervals between the metacarpal bones. They are bipenniform muscles, arising by two heads from the adjacent sides of the metacarpal bones, but more extensively from the metacarpal bone which corresponds to the side of the finger in which the muscle is inserted. They are inserted into the bases of the first phalanges and into the aponeurosis of the common extensor tendon. Between the double origin of each of these muscles is a narrow triangular interval,

through the first of which passes the radial artery; through the other three passes a perforating branch from the deep palmar arch.

The *First dorsal interosseous muscle*, or *Abductor indicis*, is larger than the others. It is flat, triangular in form, and arises by two heads, separated by a fibrous arch, for the passage of the radial artery from the dorsum to the palm of the hand. The outer head arises from the upper half of the ulnar border of the first metacarpal bone; the inner head, from almost the entire length of the radial border of the second metacarpal bone; the tendon is inserted into the radial side of the index finger. The *second* and *third dorsal interossei* are inserted into the middle finger, the former into its radial, the latter into its ulnar side. The *fourth* is inserted into the ulnar side of the ring finger.

The **Palmar interossei**, three in number, are smaller than the Dorsal, and placed upon the palmar surface of the metacarpal bones, rather than between them. They arise from the entire length of the metacarpal bone of one finger, and are inserted into the side of the base of the first phalanx and aponeurotic expansion of the common extensor tendon of the same finger.

The *first* arises from the ulnar side of the second metacarpal bone, and is inserted into the same side of the first phalanx of the index finger. The *second*

FIG. 355.—The Dorsal interossei of left hand.

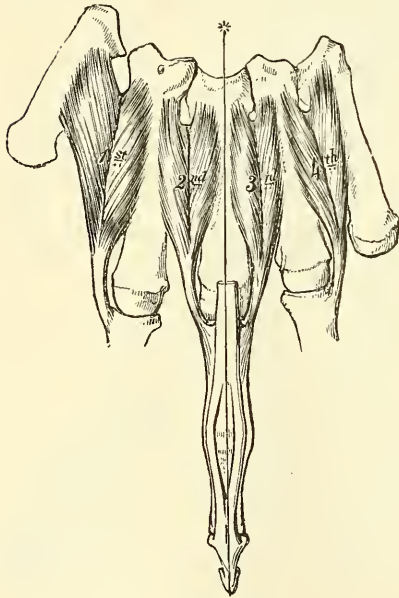
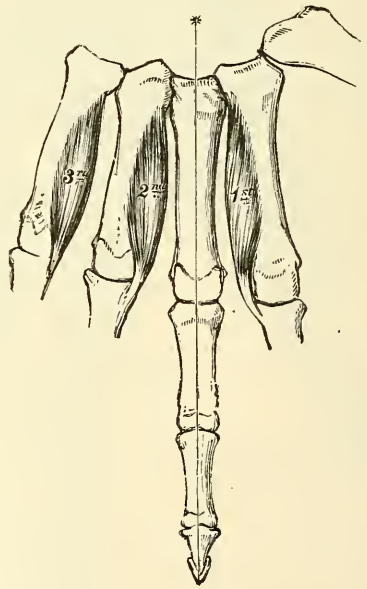


FIG. 356.—The Palmar interossei of left hand.



arises from the radial side of the fourth metacarpal bone, and is inserted into the same side of the ring finger. The *third* arises from the radial side of the fifth metacarpal bone, and is inserted into the same side of the little finger. From this account it may be seen that each finger is provided with two Interossei muscles, with the exception of the little finger, in which the Abductor muscle takes the place of one of the pair.

**Nerves.**—The two outer Lumbricales are supplied by the sixth cervical nerve, through the digital branches of the median nerve: the two inner Lumbricales and all the Interossei are supplied by the eighth cervical nerve, through the deep palmar branch of the ulnar nerve. Brooks states that the third lumbrical received a twig from the median in twelve out of twenty-one cases.

**Actions.**—The Palmar interossei muscles adduct the fingers to an imaginary line drawn longitudinally through the centre of the middle finger; and the Dorsal interossei abduct the fingers from that line. In addition to this the



Interossei, in conjunction with the Lumbricales, flex the first phalanx at the metacarpo-phalangeal joints, and extend the second and third phalanges in consequence of their insertion into the expansion of the extensor tendons. The Extensor communis digitorum is believed to act almost entirely on the first phalanges.

*Surface Form.*—The *Pectoralis major* largely influences surface form and conceals a considerable part of the thoracic wall in front. Its sternal origin presents a festooned border, which bounds and determines the width of the sternal furrow. Its clavicular origin is somewhat depressed and flattened, and between the two portions of the muscle is often an oblique depression, which differentiates the one from the other. The outer margin of the muscle is generally well marked above, and bounds the infraclavicular fossa, a triangular interval which separates the *Pectoralis major* from the Deltoid. It gradually becomes less marked as it approaches the tendon of insertion, and becomes more closely blended with the Deltoid muscle. The lower border of the *Pectoralis major* forms the rounded anterior axillary fold, and corresponds with the direction of the fifth rib. The *Pectoralis minor* influences surface form. When the arm is raised, its lowest slip of origin produces a local fulness just below the border of the anterior fold of the axilla, and so serves to break the sharp line of the lower border of the *Pectoralis major* muscle which is produced when the arm is in this position. The origin of the *Serratus magnus* produces a very characteristic surface marking. When the arm is raised from the side, in a well-developed subject, the five or six lower serrations are plainly discernible, forming a zigzag line, caused by the series of digitations, which diminish in size from above downwards, and have their apices arranged in the form of a curve. When the arm is lying by the side, the first serration to appear, at the lower margin of the *Pectoralis major*, is the one attached to the fifth rib. The *Deltoid*, with the prominence of the upper extremity of the humerus, produces the rounded outline of the shoulder. It is rounder and fuller in front than behind, where it presents a somewhat flattened form. Its anterior border, above, presents a rounded, slightly curved eminence, which bounds externally the infraclavicular fossa; below, it is closely united with the *Pectoralis major*. Its posterior border is thin, flattened, and scarcely marked above; below, it is thicker and more prominent. When the muscle is in action, the middle portion becomes irregular, presenting alternate longitudinal elevations and depressions: the elevations corresponding to the fleshy portions; the depressions, to the tendinous intersections of the muscle. The insertion of the Deltoid is marked by a depression on the outer side of the middle of the arm. Of the scapular muscles, the only one which materially influences surface form is the *Teres major*, which assists the *Latissimus dorsi* in forming the thick, rounded fold of the posterior boundary of the axilla. When the arm is raised, the *Coraco-brachialis* reveals itself as a long, narrow elevation, which emerges from under cover of the anterior fold of the axilla and runs downwards, internal to the shaft of the humerus. When the arm is hanging by the side, its front and inner part presents the prominence of the *Biceps*, bounded on either side by an intermuscular depression. This muscle determines the contour of the front of the arm, and extends from the anterior margin of the axilla to the bend of the elbow. Its upper tendons are concealed by the *Pectoralis major* and the *Deltoid*, and its lower tendon sinks into the space at the bend of the elbow. When the muscle is in a state of complete contraction—that is to say, when the forearm has been flexed and supinated—it presents a rounded convex form, bulged out laterally and its length is diminished. On each side of the *Biceps*, at the lower part of the arm, the *Brachialis anticus* is discernible. On the outer side it forms a narrow eminence, which extends some distance up the arm along the border of the *Biceps*. On the inner side it shows itself only as a little fulness just above the elbow. On the back of the arm the long head of the *Triceps* may be seen as a longitudinal eminence emerging from under cover of the *Deltoid*, and gradually merging into the longitudinal flattened plane of the muscle on the lower part of the back of the arm. On the anterior aspect of the elbow are to be seen two muscular elevations, one on each side, separated above, and converging below so as to form a triangular space. Of these, the inner elevation, consisting of the flexors and pronator, forms the prominence along the inner side and front of the forearm. It is a fusiform mass, pointed above at the internal condyle, and gradually tapering off below. The *Pronator radii teres*, the innermost muscle of the group, forms the boundary of the triangular space at the bend of the elbow. It is shorter, less prominent, and more oblique than the outer boundary. The most prominent part of the eminence is produced by the *Flexor carpi radialis*, the muscle next in order on the inner side of the preceding one. It forms a rounded prominence above, and can be traced downwards to its tendon, which can be felt lying on the front of the wrist, nearer to the radial than to the ulnar border and to the inner side of the radial artery. The *Palmaris longus* presents no surface marking above, but, below, is the most prominent tendon on the front of the wrist, standing out, when the muscle is in action, as a sharp tense cord beneath the skin. The *Flexor sublimis digitorum* does not directly influence surface form. The position of its four tendons on the front of the lower part of the forearm is indicated by an elongated depression between the tendons of the *Palmaris longus* and the *Flexor carpi ulnaris*. The *Flexor carpi ulnaris* occupies a small part of the posterior surface of the forearm, and is separated from the extensor and supinator



group, which occupies the greater part of this surface, by the ulnar furrow, produced by the subcutaneous posterior border of the ulna. Its tendon can be perceived along the ulnar border of the front of the forearm, and is most marked when the hand is flexed and adducted. The deep muscles of the front of the forearm have no direct influence on surface form. The external group of muscles of the forearm, consisting of the extensors and supinators, occupy the outer, and a considerable portion of the posterior, surface of this region. They form a fusiform mass, which is altogether on a higher level than the pronato-flexor group. Its apex emerges from between the Triceps and Brachialis anticus muscles some distance above the elbow-joint, and acquires its greatest breadth opposite the external condyle, and thence gradually shades off into a flattened surface. About the middle of the forearm it divides into two longitudinal eminences which diverge from each other, leaving a triangular interval between them. The outer of these two groups of muscles consists of the Supinator longus and the Extensor carpi radialis longior et brevior, which form a longitudinal eminence descending from the external condyloid ridge in the direction of the styloid process of the radius. The other and more posterior group consists of the Extensor communis digitorum, the Extensor minimi digiti, and the Extensor carpi ulnaris. It commences above as a tapering form at the external condyle of the humerus, and is separated behind at its upper part from the Anconeus by a well-marked furrow; and below, from the pronato-flexor mass, by the ulnar furrow. In the triangular interval left between these two groups, the extensors of the thumb and index finger are seen. The only two muscles of this region which require special mention, as independently influencing surface form, are the Supinator longus and the Anconeus. The inner border of the *Supinator longus* forms the outer boundary of the triangular space at the bend of the elbow. It commences as a rounded border above the condyle, and is longer, less oblique, and more prominent than the inner boundary. Lower down, the muscle forms a full fleshy mass on the outer side of the upper part of the forearm, and below tapers into a tendon, which may be traced down to the styloid process of the radius. The *Anconeus* presents a well-marked and characteristic surface form in the shape of a triangular, slightly elevated surface, immediately external to the subcutaneous posterior surface of the olecranon, and differentiated from the common extensor group by a well-marked oblique longitudinal depression. The upper angle of the triangle corresponds to the external condyle, and is marked by a depression or dimple in this situation. In the triangular interval, caused by the divergence from each other of the two groups of muscles into which the extensor and supinator group is divided at the lower part of the forearm, an oblique elongated eminence is seen, caused by the emergence of two of the extensors of the thumb from their deep origin at the back of the forearm. This eminence, full above, and becoming flattened out and partially subdivided below, runs downwards and outwards over the back and outer surface of the radius to the outer side of the wrist-joint, where it forms a ridge, especially marked when the thumb is extended, which passes onwards to the posterior aspect of the thumb. The tendons of most of the extensor muscles are to be seen and felt at the level of the wrist-joint. Most externally are the tendons of the Extensor ossis metacarpi pollicis and the Extensor brevis pollicis, forming a vertical ridge over the outer side of the joint from the styloid process of the radius to the thumb. Internal to this is the oblique ridge produced by the tendon of the Extensor longus pollicis, very noticeable when the muscle is in action. The Extensor carpi radialis longior is scarcely to be felt, but the Extensor carpi radialis brevior can be distinctly perceived, as a vertical ridge emerging from under the inner border of the tendon of the Extensor longus pollicis, when the hand is forcibly extended at the wrist. Internal to this, again, can be felt the tendons of the Extensor indicis, Extensor communis digitorum, and Extensor minimi digiti; the latter tendon being separated from those of the common extensor by a slight furrow. The muscles of the hand are principally concerned, as far as regards surface-form, in producing the thenar and hypothenar eminences, and individually are not to be distinguished, on the surface, from each other. The *Adductor transversus pollicis* is, however, an exception to this; its anterior border gives rise to a ridge across the web of skin connecting the thumb to the rest of the hand. The thenar eminence is much larger and rounder than the hypothenar one, which presents a longer and narrower eminence along the ulnar side of the hand. When the *Palmaris brevis* is in action it produces a wrinkling of the skin over the hypothenar eminence, and a deep dimple on the ulnar border of the hand. The anterior extremities of the *Lumbrical* muscles help to produce the soft eminences just behind the clefts of the fingers, separated from each other by depressions corresponding to the flexor tendons in their sheaths. Between the thenar and hypothenar eminences, at the wrist-joint, is a slight groove or depression, widening out as it approaches the fingers; beneath this we have the strong central part of the palmar fascia. Here we have some furrows, which are pretty constant in their arrangement, and bear some resemblance to the letter M. One of these furrows passes obliquely outwards from the groove between the thenar and hypothenar regions to the head of the metacarpal bone of the index finger. A second passes inwards, with a slight inclination upwards, from the termination of the first to the ulnar side of the hand. A third runs parallel with the second and about three-quarters of an inch below it. Lastly, crossing these two latter furrows is an oblique furrow parallel with the first. The skin of the palm of the hand differs considerably from that of the forearm. At the wrist it

suddenly becomes hard and dense, and covered with a thick layer of cuticle. The skin in the thenar region presents these characteristics less than elsewhere. In spite of this hardness and density the skin of the palm is exceedingly sensitive and very vascular. It is destitute of hair, and no sebaceous follicles have been found in this region. Over the fingers the skin again becomes thinner, especially at the flexures of the joints, and over the terminal phalanges it is thrown into numerous parallel ridges in consequence of the arrangement of the papillæ in it. The superficial fascia in the palm is made up of dense fibro-fatty tissue. This tissue binds down the skin so firmly to the deep palmar fascia that very little movement is permitted between the two. On the back of the hand the *Dorsal interossei* produce elongated swellings between the metacarpal bones. The first dorsal interosseous (*Abductor indicis*), when the thumb is closely adducted to the hand, forms a prominent fusiform bulging; the other interossei are not so marked.

*Surgical Anatomy.*—The student, having completed the dissection of the muscles of the upper extremity, should consider the effects likely to be produced by the action of the various muscles in fracture of the bones.

In considering the actions of the various muscles upon fractures of the upper extremity, I have selected the most common forms of injury, both for illustration and description.

Fracture of the *middle of the clavicle* (fig. 357) is always attended with considerable displacement, the inner end of the outer fragment is displaced inwards and backwards, while the outer end of the same fragment is rotated forwards. The whole outer fragment is somewhat depressed.

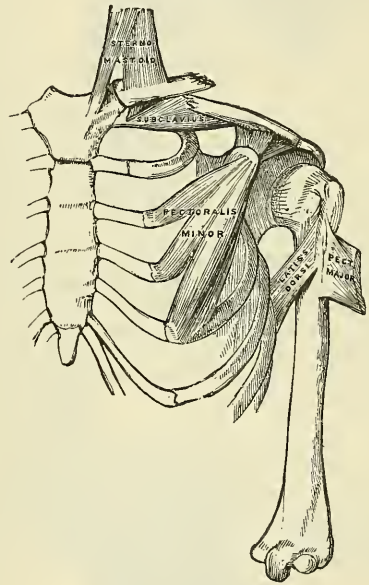
The displacement is produced as follows: *inwards*, by the muscles passing from the chest to the outer fragment of the clavicle, to the scapula, and to the humerus, viz. the *Subclavius* and the *Pectoralis minor* and, to a less extent, the *Pectoralis major* and the *Latissimus dorsi*; *backwards*, in consequence of the rotation of the outer fragment. The *Serratus magnus* causes the scapula to rotate on the wall of the chest, this carries the acromion and outer end of the outer fragment of the clavicle forwards, and causes the piece of bone to rotate round a vertical axis through its centre, and so carries the inner end of the outer portion backwards. The depression of the whole outer fragment is produced by the weight of the arm and by the contraction of the *Deltoid*. The outer end of the inner fragment appears to be elevated, the skin being drawn tensely over it; this is owing to the depression of the outer fragment, as the inner fragment is usually kept fixed by the *costo-clavicular ligament*, and by the antagonism between the *Sterno-mastoid* and *Pectoralis major* muscles. But it may be raised by an unusually strong *Sterno-mastoid*, or by the inner end of the outer fragment getting below and behind it. The causes of displacement having been ascertained, it is easy to apply the appropriate treatment. The outer fragment is to be drawn outwards, and, together with the scapula, raised upwards to a level with the inner fragment, and retained in that position.

In fracture of the *acromial end of the clavicle*, between the conoid and trapezoid ligaments, only slight displacement occurs, as these ligaments, from their oblique insertion, serve to hold both portions of the bone in apposition. Fracture, also, of the *sternal end*, internal to the *costo-clavicular ligament*, is attended with only slight displacement, this ligament serving to retain the fragments in close apposition.

Fracture of the *acromion process* usually arises from violence applied to the upper and outer part of the shoulder; it is generally known by the rotundity of the shoulder being lost, from the *Deltoid* drawing the fractured portion downwards and forwards; and the displacement may easily be discovered by tracing the margin of the clavicle outwards, when the fragment will be found resting on the front and upper part of the head of the humerus. In order to relax the anterior and outer fibres of the *Deltoid* (the opposing muscle), the arm should be drawn forwards across the chest, and the elbow well raised, so that the head of the bone may press the acromion process upwards, and retain it in its position.

Fracture of the *coracoid process* is an extremely rare accident, and is usually caused by a sharp blow on the point of the shoulder. Displacement is here produced by the combined actions of the *Pectoralis minor*, short head of the *Biceps*, and *Coraco-brachialis*, the former muscle drawing the fragment inwards, and the latter directly downwards, the

FIG. 357.—Fracture of the middle of the clavicle.

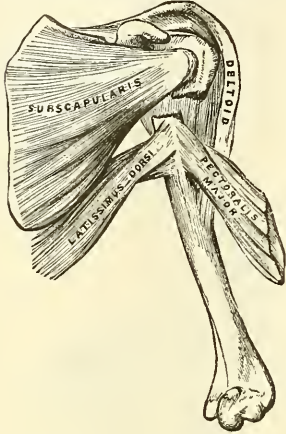




amount of displacement being limited by the connection of this process to the acromion by means of the coraco-acromial ligament. In many cases there appears to have been little or no displacement, from the fact that the coraco-clavicular ligament has remained intact, and has kept the separated fragment from displacement. In order to relax these muscles and replace the fragments in close apposition, the forearm should be flexed so as to relax the Biceps, and the arm drawn forwards and inwards across the chest so as to relax the Coraco-brachialis; the humerus should then be pushed upwards against the coraco-acromial ligament, and the arm retained in that position.

Fracture of the *surgical neck of the humerus* (fig. 358) is very common, is attended with considerable displacement, and its appearances correspond somewhat with those of dislocation of the head of the humerus into the axilla.

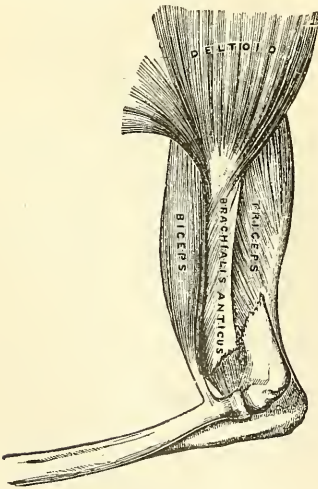
FIG. 358.—Fracture of the surgical neck of the humerus.



The upper fragment is slightly elevated under the coraco-acromial ligament by the muscles attached to the greater and lesser tuberosities; the lower fragment is drawn inwards by the Pectoralis major, Latissimus dorsi, and Teres major; and the humerus is thrown obliquely outwards from the side by the Deltoid, and occasionally elevated so as to cause the upper end of the lower fragment to project beneath and in front of the coracoid process. The deformity is reduced by fixing the shoulder, and drawing the arm outwards and downwards. To counteract the opposing muscles, and to keep the fragments in position, a small conical-shaped pad should be placed in the axilla, and the arm bandaged to the side by a broad roller passed round the chest, in such a manner that the elbow is carried slightly forwards, so as to throw the upper end of the lower fragment backwards and outwards towards the head of the bone. The whole is then covered with a carefully moulded gutta-percha or poroplastic shoulder cap.

In fracture of the *shaft of the humerus* below the insertion of the Pectoralis major, Latissimus dorsi, and Teres major, and above the insertion of the Deltoid, there is also considerable deformity, the upper fragment being drawn inwards by the first mentioned muscles, and the lower fragment upwards and outwards by the Deltoid, producing shortening of the limb, and a considerable prominence at the seat of fracture, from the fractured ends of the bone riding over one another, especially if the fracture takes place in an oblique direction. The fragments may be brought into apposition by extension from the elbow, and retained in that position by adopting the same means as in the preceding injury.

FIG. 359.—Fracture of the humerus above the condyles.



In fractures of the *shaft of the humerus* immediately below the insertion of the Deltoid, the amount of deformity depends greatly upon the direction of the fracture. If it occurs in a transverse direction, only slight displacement takes place, the upper fragment being drawn a little forwards; but in oblique fracture, the combined actions of the Biceps and Brachialis anticus muscles in front, and the Triceps behind, draw upwards the lower fragment, causing it to glide over the upper fragment, either backwards or forwards, according to the direction of the fracture. Simple extension reduces the deformity, and the application of splints on the four sides of the arm will retain the fragments in apposition. Care should be taken not to raise the elbow; but the forearm and hand may be supported in a sling.

Fracture of the *humerus* (fig. 359) immediately above the condyles deserves very attentive consideration, as the general appearances correspond somewhat with those produced by separation of the epiphysis of the humerus, and with those of dislocation of the radius and ulna backwards. If the direction of the fracture is oblique from above, downwards, and forwards, the lower fragment is drawn upwards by the Brachialis anticus and Biceps in

front, and the Triceps behind; and at the same time is drawn backwards behind the upper fragment by the Triceps. This injury may be diagnosed from dislocation by the increased mobility in fracture, the existence of crepitus, and the fact of the deformity being remedied by extension, on the discontinuance of which it is reproduced. The age of the patient is



of importance in distinguishing this form of injury from separation of the epiphysis. If fracture occurs in the opposite direction to that shown in the accompanying figure, the lower fragment is drawn upwards and forwards, causing a considerable prominence in front; and the upper fragment projects backwards beneath the tendon of the Triceps muscle.

Fracture of the *olecranon process* (fig. 360) is a frequent accident. The detached fragment is displaced upwards, by the action of the Triceps muscle, from half an inch to two inches; the prominence of the elbow is consequently lost, and a deep hollow is felt at the back part of the joint, which is much increased on flexing the limb. The patient at the same time loses, more or less, the power of extending the forearm. The treatment consists in relaxing the Triceps by extending the limb, and retaining it in the extended position by means of a long straight splint applied to the front of the arm; the fragments are thus brought into close apposition, and may be further approximated by drawing down the upper fragment. Union is generally ligamentous.

Fracture of the *neck of the radius* is an exceedingly rare accident, and is generally caused by direct violence. Its diagnosis is somewhat obscure, on account of the slight deformity visible, the injured part being surrounded by a large number of muscles; but the movements of pronation and supination are entirely lost. The upper fragment is drawn outwards by the Supinator brevis, its extent of displacement being limited by the attachment of the orbicular ligament. The lower fragment is drawn forwards and slightly upwards by the Biceps, and inwards by the Pronator radii teres, its displacement forwards and upwards being counteracted in some degree by the Supinator brevis. The treatment essentially consists in relaxing the Biceps, Supinator brevis, and Pronator radii teres muscles, by flexing the forearm, and placing it in a position midway between pronation and supination, extension having been previously made so as to bring the parts in apposition.

In fracture of the *radius* below the insertion of the Biceps, but above the insertion of the Pronator radii teres, the upper fragment is strongly supinated by the Biceps and Supinator brevis, and at the same time drawn forwards and flexed by the Biceps; the lower fragment is in a state of extreme pronation and drawn inwards towards the ulna by the pronator. Thus there is extreme displacement with very little deformity. In treating such a fracture the arm must be put up in a position of supination, otherwise union will take place with great impairment of the movements of the hand. In fractures of the radius below the insertion of the Pronator radii teres (fig. 361), the upper fragment is drawn upwards by the Biceps, and inwards by the Pronator radii teres, holding a position midway between pronation and supination, and a degree of fulness in the upper half of the forearm is thus produced: the lower fragment is drawn downwards and inwards towards the ulna by the Pronator quadratus, and thrown into a state of pronation by the same muscle; at the same time, the Supinator longus, by elevating the styloid process, into which it is inserted, will serve to depress the upper end of the lower fragment still more towards the ulna. In order to relax the opposing muscles the forearm should be bent, and the limb placed in a position midway between pronation and supination; the fracture is then easily reduced by extension from the wrist and elbow: well-padded splints should be applied on both sides of the forearm from the elbow to the wrist; the hand being allowed to fall, will, by its own weight, counteract the action of the Pronator quadratus and Supinator longus, and elevate the lower fragment to the level of the upper one.

In fracture of the *shaft of the ulna* the upper fragment retains its usual position, but the lower fragment is drawn outwards towards the radius by the Pronator quadratus, producing a well-marked depression at the seat of fracture, and some fulness on the dorsal and palmar surfaces of the forearm. The fracture is easily reduced by extension from the wrist and forearm. The forearm should be flexed, and placed in a position midway between pronation and supination, and well-padded splints applied from the elbow to the ends of the fingers.

FIG. 360.—Fracture of the olecranon.

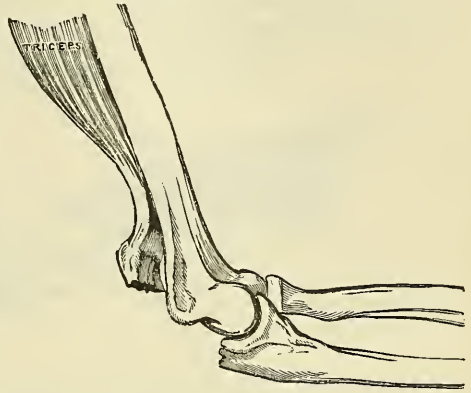
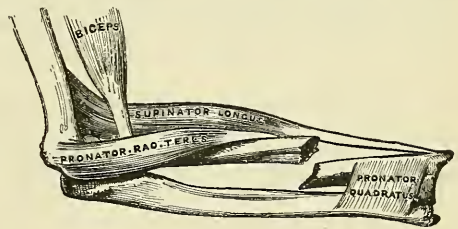


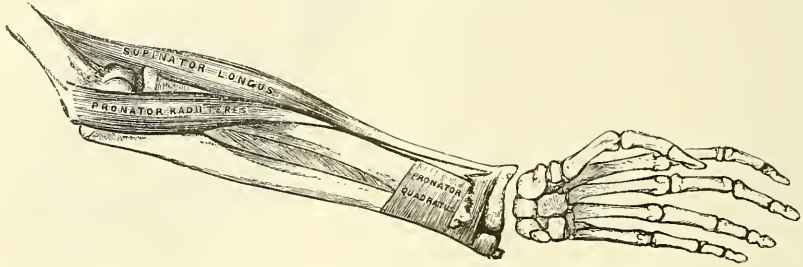
FIG. 361.—Fracture of the shaft of the radius.



In fracture of the *shafts of the radius and ulna together*, the lower fragments are drawn upwards, sometimes forwards, sometimes backwards, according to the direction of the fracture, by the combined actions of the Flexor and Extensor muscles, producing a degree of fulness on the dorsal or palmar surface of the forearm; at the same time the two fragments are drawn into contact by the Pronator quadratus, the radius being in a state of pronation: the upper fragment of the radius is drawn upwards and inwards by the Biceps and Pronator radii teres to a higher level than the ulna; the upper portion of the ulna is slightly elevated by the Brachialis anticus. The fracture may be reduced by extension from the wrist and elbow, and the forearm should be placed in the same position as in fracture of the ulna.

In fracture of the *lower end of the radius* (fig. 362) the displacement which is produced

FIG. 362.—Fracture of the lower end of the radius.



is very considerable, and bears some resemblance to dislocation of the carpus backwards, from which it should be carefully distinguished. The lower fragment is displaced backwards and upwards, but this displacement is probably due to the force of the blow driving the portion of bone into this position and not to any muscular influence. The upper fragment projects forwards, often lacerating the substance of the Pronator quadratus, and is drawn by this muscle into close contact with the lower end of the ulna, causing a projection on the anterior surface of the forearm, immediately above the carpus, from the flexor tendons being thrust forwards. This fracture may be distinguished from dislocation by the deformity being removed on making sufficient extension, when crepitus may be occasionally detected; at the same time, on extension being discontinued, the parts immediately resume their deformed appearance (see also page 246). The age of the patient will also assist in determining whether the injury is fracture or separation of the epiphysis. The treatment consists in flexing the forearm, and making powerful extension from the wrist and elbow, depressing at the same time the radial side of the hand, and retaining the parts in that position by well-padded *pistol-shaped* splints.

## MUSCLES AND FASCIAE OF THE LOWER EXTREMITY

The muscles of the Lower Extremity are subdivided into groups, corresponding with the different regions of the limb.

### I. ILIAC REGION

Psoas magnus.  
Psoas parvus.  
Iliacus.

Adductor longus.  
Adductor brevis.  
Adductor magnus.

### 3. Gluteal Region

Gluteus maximus.  
Gluteus medius.  
Gluteus minimus.  
Pyriformis.  
Gemellus superior.  
Obturator internus.  
Gemellus inferior.  
Obturator externus.  
Quadratus femoris.

### II. THIGH

#### 1. Anterior Femoral Region

Tensor vaginæ femoris.  
Sartorius.  
Rectus.  
Vastus externus.  
Vastus internus.  
Crureus.  
Suberureus.

#### 4. Posterior Femoral Region

#### 2. Internal Femoral Region

Gracilis  
Pectineus.

Biceps.  
Semitendinosus.  
Semimembranosus.

## III. LEG

5. *Anterior Tibio-fibular Region*

Tibialis anticus.  
 Extensor longus digitorum.  
 Extensor proprius hallucis.  
 Peroneus tertius.

6. *Posterior Tibio-fibular Region**Superficial Layer*

Gastrocnemius.  
 Plantaris.  
 Soleus.

*Deep Layer*

Popliteus.  
 Flexor longus hallucis.  
 Flexor longus digitorum.  
 Tibialis posticus.

7. *Fibular Region.*

Peroneus longus.  
 Peroneus brevis.

## IV. FOOT

8. *Dorsal Region*

Extensor brevis digitorum.

9. *Plantar Region**First Layer*

Abductor hallucis.  
 Flexor brevis digitorum.  
 Abductor minimi digiti.

*Second Layer*

Flexor accessorius.  
 Lumbricales.

*Third Layer*

Flexor brevis hallucis.  
 Adductor obliquus hallucis.  
 Flexor brevis minimi digiti.  
 Adductor transversus pedis.

*Fourth Layer*

The Interossei.

## I. MUSCLES AND FASCIAE OF THE ILIAC REGION

Psoas magnus.

Psoas parvus.

Iliacus.

*Dissection.*—No detailed description is required for the dissection of these muscles. On the removal of the viscera from the abdomen, they are exposed, covered by the peritoneum and a thin layer of fascia, the iliac fascia.

The **iliac fascia**\* is the aponeurotic layer which lines the back part of the abdominal cavity, and covers the Psoas and Iliacus muscles throughout their whole extent. It is thin above, and becomes gradually thicker below as it approaches the crural arch.

The *portion covering the Psoas* is attached, above, to the ligamentum arcuatum internum; internally, by a series of arched processes to the intervertebral substances, and prominent margins of the bodies of the vertebræ, and to the upper part of the sacrum; the intervals so left, opposite the constricted portions of the bodies, transmitting the lumbar arteries and filaments of the sympathetic nerve. Externally, above the crest of the ilium, this portion of the iliac fascia is continuous with the anterior lamella of the lumbar fascia (see page 432), but below the crest of the ilium it is continuous with the fascia covering the Iliacus.

The *portion investing the Iliacus* is connected, externally, to the whole length of the inner border of the crest of the ilium; and internally, to the brim of the true pelvis, where it is continuous with the periosteum, and at the ilio-pectineal eminence it receives the tendon of insertion of the Psoas parvus, when that muscle exists. External to the femoral vessels, this fascia is intimately connected to the posterior margin of Poupart's ligament, and is continuous with the fascia transversalis. Internal to the vessels it is attached to the ilio-pectineal line behind the conjoined tendon, where it is again continuous with the transversalis fascia; and corresponding to the point where the femoral vessels pass into the thigh, this fascia descends behind them forming the posterior wall of the crural sheath. This portion of the iliac fascia which passes behind the femoral vessels is also attached to the ilio-pectineal line beyond the limits

\* The student must not confound this fascia with the *iliac portion of the fascia lata* (see p. 512).



of the attachment of the conjoined tendon; at this part it is continuous with the pubic portion of the fascia lata of the thigh. The external iliac vessels lie in front of the iliac fascia, but all the branches of the lumbar plexus behind it; it is separated from the peritoneum by a quantity of loose areolar tissue.

The **Psoas magnus** (fig. 364) is a long fusiform muscle placed on the side of the lumbar region of the spine and margin of the pelvis. It arises from the front of the bases and lower borders of the transverse processes of the lumbar vertebræ by five fleshy slips; also from the sides of the bodies, and the corresponding intervertebral substances of the last dorsal and all the lumbar vertebræ. The muscle is connected to the bodies of the vertebræ by five slips; each slip is attached to the upper and lower margins of two vertebræ, and to the intervertebral substance between them; the slips themselves being connected by tendinous arches which extend across the constricted part of the bodies, and beneath which pass the lumbar arteries and sympathetic nerves. These tendinous arches also give origin to muscular fibres, and protect the blood-vessels and nerves from pressure during the action of the muscle. The first slip is attached to the contiguous margins of the last dorsal and first lumbar vertebræ; the last to the contiguous margins of the fourth and fifth lumbar, and to the intervertebral substance. From these points the muscle passes down across the brim of the pelvis, and, diminishing gradually in size, passes beneath Poupart's ligament, and terminates in a tendon, which, after receiving the fibres of the Iliacus, is inserted into the lesser trochanter of the femur.

**Relations.**—In the lumbar region. By its *anterior surface*, which is placed behind the peritoneum, with the iliac fascia, the ligamentum arcuatum internum, the kidney, Psoas parvus, renal vessels, ureter, spermatic vessels, genito-crural nerve, and the colon. By its *posterior surface*, with the transverse processes of the lumbar vertebræ, and the Quadratus lumborum, from which it is separated by the anterior lamella of the lumbar fascia. The anterior crural nerve is at first situated in the substance of the muscle, and emerges from its outer border at the lower part. The rest of the lumbar plexus is situated in the posterior part of the substance of the muscle. By its *inner side*, the muscle is in relation with the bodies of the lumbar vertebræ, the lumbar arteries, the ganglia of the sympathetic nerve, and their branches of communication with the spinal nerves; the lumbar glands; the vena cava inferior on the right, and the aorta on the left side, and along the brim of the pelvis with the external iliac artery. In the thigh it is in relation, in front, with the fascia lata; behind, with the capsular ligament of the hip, from which it is separated by a synovial bursa, which frequently communicates with the cavity of the joint through an opening of variable size; by its *inner border*, with the Pectineus and the femoral artery, which slightly overlaps it; by its *outer border*, with the anterior crural nerve and Iliacus muscle.

The **Psoas parvus** is a long slender muscle, placed in front of the Psoas magnus. It arises from the sides of the bodies of the last dorsal and first lumbar vertebræ and from the intervertebral substance between them. It forms a small flat muscular bundle, which terminates in a long flat tendon, inserted into the ilio-pectineal eminence and, by its outer border, into the iliac fascia. This muscle is often absent, and, according to Cruveilhier, sometimes double.

**Relations.**—It is covered by the peritoneum, and, at its origin, by the ligamentum arcuatum internum; it rests on the Psoas magnus.

The **Iliacus** is a flat, triangular muscle, which fills up the whole of the iliac fossa. It arises from the upper two-thirds of this fossa, and from the inner margin of the crest of the ilium; behind, from the ilio-lumbar ligament, and base of the sacrum; in front, from the anterior superior and anterior inferior spinous processes of the ilium, from the notch between them, and by a few fibres from the capsule of the hip-joint. The fibres converge to be inserted

into the outer side of the tendon of the Psoas, some of them being prolonged into the oblique line which extends from the lesser trochanter to the linea aspera.\*

**Relations.**—*Within the pelvis*: by its *anterior surface*, with the iliac fascia, which separates the muscle from the peritonéum, and with the external cutaneous nerve; on the right side, with the cæcum; on the left side with the sigmoid flexure of the colon. By its *posterior surface*, with the iliac fossa. By its *inner border*, with the Psoas magnus, and anterior crural nerve. In the thigh, it is in relation, by its *anterior surface*, with the fascia lata, Rectus, and Sartorius; behind, with the capsule of the hip-joint, a synovial bursa common to it and the Psoas magnus being interposed.

**Nerves.**—The Psoas magnus is supplied by the anterior branches of the second and third lumbar nerves; the Psoas parvus, when it exists, is supplied by the anterior branch of the first lumbar nerve; and the Iliacus by the anterior branches of the second and third lumbar nerves through the anterior crural.

**Actions.**—The Psoas and Iliacus muscles, acting from above, flex the thigh upon the pelvis: acting from below, the femur being fixed, the muscles of both sides bend the lumbar portion of the spine and pelvis forwards. They also serve to maintain the erect position, by supporting the spine and pelvis upon the femur, and assist in raising the trunk when the body is in the recumbent posture.

The *Psoas parvus* is a tensor of the iliac fascia.

**Surgical Anatomy.**—In the iliac fascia there is no definite septum between the portions of fascia covering the Psoas and Iliacus respectively, and the fascia is only connected to the subjacent muscles by a quantity of loose connective tissue. When abscess forms beneath this fascia, as it is very apt to do, the matter is contained in an osseo-fibrous cavity which is closed on all sides within the abdomen, and is open only at its lower part, where the fascia is prolonged over the muscle into the thigh.

Abscess within the sheath of the Psoas muscle (*Psoas abscess*) is generally due to tuberculous caries of the bodies of the lower dorsal and lumbar vertebræ. When the disease is in the dorsal region, the matter tracts down the posterior mediastinum, in front of the bodies of the vertebræ, and, passing beneath the ligamentum arcuatum internum, enters the sheath of the Psoas muscle, down which it passes as far as the pelvic brim; it then gets beneath the iliac portion of the fascia, and fills up the iliac fossa. In consequence of the attachment of the fascia to the pelvic brim, it rarely finds its way into the pelvis, but passes by a narrow opening under Poupart's ligament into the thigh, to the outer side of the femoral vessels. It thus follows that a Psoas abscess may be described as consisting of four parts: (1) a somewhat narrow channel at its upper part, in the Psoas sheath; (2) a dilated sac in the iliac fossa; (3) a constricted neck under Poupart's ligament; and (4) a dilated sac in the upper part of the thigh. When the lumbar vertebræ are the seat of the disease, the matter finds its way directly into the substance of the muscle. The muscular fibres are destroyed, and the nervous cords contained in the abscess are isolated and exposed in its interior; the femoral vessels which lie in front of the fascia remain intact, and the peritoneum seldom becomes implicated. All Psoas abscesses do not, however, pursue this course: the matter may leave the muscle above the crest of the ilium, and tracking backwards may point in the loin (*lumbar abscess*); or it may point above Poupart's ligament in the inguinal region; or it may follow the course of the iliac vessels into the pelvis, and, passing through the great sacro-sciatic notch, discharge itself on the back of the thigh; or it may open into the bladder, or find its way into the perinæum.

## II. MUSCLES AND FASCIAE OF THE THIGH

### 1. Anterior Femoral Region

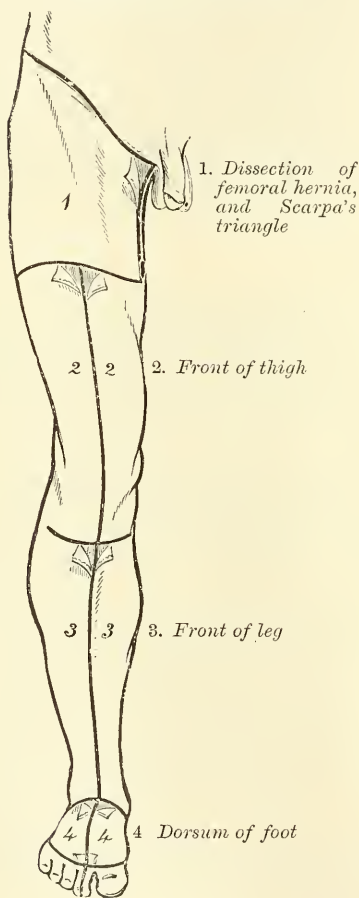
Tensor vaginæ femoris.	Vastus externus.
Sartorius.	Vastus internus.
Rectus.	Crureus.
	Suberureus.

\* The Psoas and Iliacus are sometimes regarded as a single muscle, the *Ilio-psoas*, having two heads of origin and a single insertion.

*Dissection.*—To expose the muscles and fasciæ in this region, make an incision along Poupart's ligament, from the anterior superior spine of the ilium to the spine of the os pubis; a vertical incision from the centre of this, along the middle of the thigh to below the knee-joint; and a transverse incision from the inner to the outer side of the leg, at the lower end of the vertical incision. The flaps of integument having been removed, the superficial and deep fasciæ should be examined. The more advanced student should commence the study of this region by an examination of the anatomy of femoral hernia, and Scarpa's triangle, the incisions for the dissection of which are marked out in fig. 363.

The **superficial fascia** forms a continuous layer over the whole of the thigh, consisting of areolar tissue, containing in its meshes much fat, and capable of being separated into two or more layers, between which are found the superficial

FIG. 363.—Dissection of lower extremity. Front view.



vessels and nerves. It varies in thickness in different parts of the limb; in the groin it is thick, and the two layers are separated from one another by the superficial inguinal lymphatic glands, the internal saphenous vein, and several smaller vessels. One of these two layers, the superficial, is continuous above with the superficial fascia of the abdomen. The deep layer of the superficial fascia is a very thin, fibrous layer, best marked on the inner side of the long saphenous vein and below Poupart's ligament. It is placed beneath the subcutaneous vessels and nerves and upon the surface of the fascia lata. It is intimately adherent to the fascia lata a little below Poupart's ligament. It covers the saphenous opening in the fascia lata, being closely united to its circumference, and is connected to the sheath of the femoral vessels, corresponding to its under surface. The portion of fascia covering this aperture is perforated by the internal saphenous vein and by numerous blood and lymphatic vessels, hence it has been termed the *cribriform fascia*, the openings for these vessels having been likened to the holes in a sieve. The cribriform fascia adheres closely both to the superficial fascia and to the fascia lata, so that it is described by some anatomists as part of the fascia lata, but is usually considered (as in this work) as belonging to the superficial fascia. It is not until the cribriform fascia has been cleared away that the saphenous opening is seen, so that this opening does

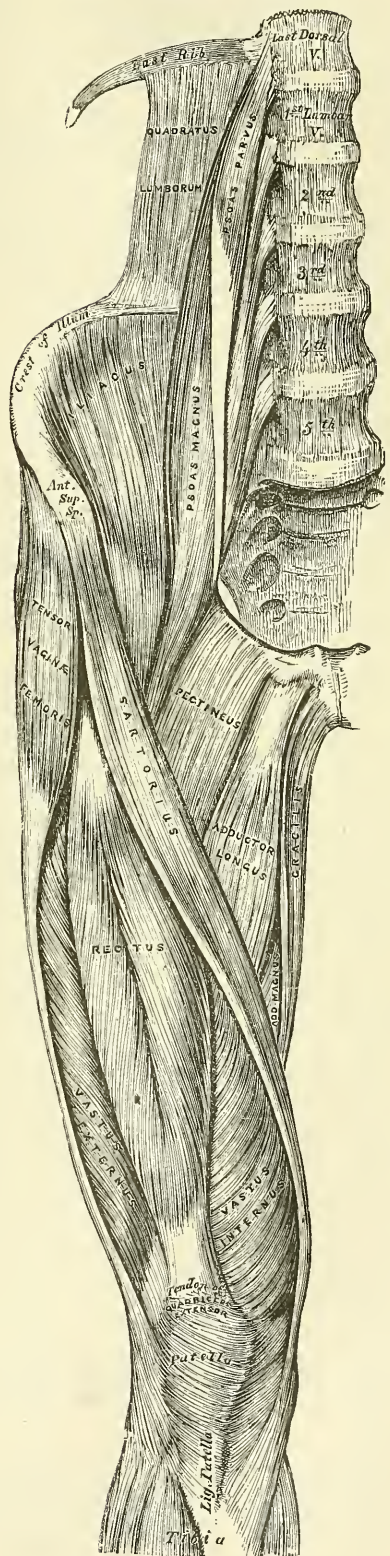
not in ordinary cases exist naturally, but is the result of dissection. Mr. Callender, however, speaks of cases in which, probably as the result of pressure from enlarged inguinal lymphatic glands, the fascia has become atrophied, and a saphenous opening exists independent of dissection. A femoral hernia in passing through the saphenous opening receives the cribriform fascia as one of its coverings. A large subcutaneous bursa is found in the superficial fascia over the patella.

The **deep fascia** of the thigh is exposed on the removal of the superficial fascia, and is named, from its great extent, the *fascia lata*; it forms a uniform investment for the whole of this region of the limb, but varies in thickness in



different parts; thus, it is thicker in the upper and outer part of the thigh, where it receives a fibrous expansion from the Gluteus maximus muscle, and where the Tensor vaginae femoris is inserted between its layers: it is very thin behind, and at the upper and inner part where it covers the Adductor muscles, and again becomes stronger around the knee, receiving fibrous expansions from the tendon of the Biceps externally, and from the Sartorius internally, and Quadriceps extensor cruris in front. The fascia lata is attached, above and behind, to the back of the sacrum and coccyx; externally, to the crest of the ilium; in front, to Poupart's ligament, and to the body of the os pubis; and internally, to the descending ramus of the os pubis, to the ascending ramus and tuberosity of the ischium, and to the lower border of the great sacro-sciatic ligament. From its attachment to the crest of the ilium it passes down over the Gluteus medius muscle to the upper border of the Gluteus maximus, where it splits into two layers, one passing superficial to and the other beneath this muscle. At the lower border of the muscle the two layers reunite. Externally, just below the great trochanter, the fascia lata receives the greater part of the tendon of insertion of the Gluteus maximus, and becomes proportionately thickened. The portion of the fascia lata arising from the front part of the crest of the ilium, corresponding to the origin of the Tensor vaginae femoris, passes down the outer side of the thigh as two layers, one superficial and the other beneath this muscle; these at its lower end become blended together into a thick and strong band, having first received the insertion of the muscle. This band is continued downwards, under the name of the *ilio-tibial band*, to be inserted into the external tuberosity of the tibia. Below, the fascia lata is attached to all the prominent points around the knee-joint, viz. the condyles of the femur, tuberosities of the tibia, and head of the fibula. On each side of the patella it is strengthened by transverse fibres given off from the lower part of the Vasti muscles, which are attached to and support this bone. Of these the outer is the stronger, and is continuous with the ilio-tibial band.

FIG. 364.—Muscles of the iliac and anterior femoral regions.



From the inner surface of the fascia lata are given off two strong intermuscular septa, which are attached to the whole length of the linea aspera and its prolongations above and below: the external and stronger one, which extends from the insertion of the Gluteus maximus to the outer condyle, separates the Vastus externus in front from the short head of the Biceps behind, and gives partial origin to these muscles; the inner one, the thinner of the two, separates the Vastus internus from the Adductor and Pectineus muscles. Besides these there are numerous smaller septa, separating the individual muscles, and enclosing each in a distinct sheath.

At the upper and inner part of the thigh, a little below Poupart's ligament, a large oval-shaped aperture is observed after the superficial fascia has been cleared off: it transmits the internal saphenous vein, and other smaller vessels, and is termed the *saphenous opening*. In order more correctly to consider the mode of formation of this aperture, the fascia lata in this part of the thigh is described as consisting of two portions, an iliac portion and a pubic portion.

The *iliac portion* is all that part of the fascia lata on the outer side of the saphenous opening. It is attached, externally, to the crest of the ilium and its anterior superior spine, to the whole length of Poupart's ligament as far internally as the spine of the os pubis, and to the pectineal line in conjunction with Gimbernat's ligament. From the spine of the os pubis it is reflected downwards and outwards, forming an arched margin, the *falciform process* or boundary (*superior cornu*) of the saphenous opening; this margin overlies and is adherent to the anterior layer of the sheath of the femoral vessels: to its edge is attached the cribriform fascia; and, below, it is continuous with the pubic portion of the fascia lata.

The *pubic portion* is situated at the inner side of the saphenous opening; at the lower margin of this aperture it is continuous with the iliac portion; traced upwards, it covers the surface of the Pectineus, Adductor longus, and Gracilis muscles, and, passing behind the sheath of the femoral vessels, to which it is closely united, is continuous with the sheath of the Psoas and Iliacus muscles, and is attached above to the ilio-pectineal line, where it becomes continuous with the iliac fascia. From this description it may be observed that the iliac portion of the fascia lata passes in front of the femoral vessels, and the pubic portion behind them, so that an apparent aperture exists between the two, through which the internal saphenous joins the femoral vein.\*

The fascia should now be removed from the surface of the muscles. This may be effected by pinching it up between the forceps, dividing it, and separating it from each muscle in the course of its fibres.

The **Tensor vaginæ femoris** arises from the anterior part of the outer lip of the crest of the ilium, from the outer surface of the anterior superior spinous process, and part of the outer border of the notch below it, between the Gluteus medius and Sartorius, and from the surface of the fascia covering the Gluteus medius. It is inserted between two layers of the fascia lata about one-fourth down the outer side of the thigh. From the point of insertion the fascia is continued downwards to the head of the tibia as a thickened band, the *ilio-tibial band*.

**Relations.**—By its *superficial surface*, with the fascia lata and the integument. By its *deep surface*, with the Gluteus medius, Rectus femoris, Vastus externus, and the ascending branches of the external circumflex artery. By its *anterior border*, with the Sartorius, from which it is separated below by a triangular space, in which is seen the Rectus femoris. By its *posterior border*, with the Gluteus medius.

The **Sartorius**, the longest muscle in the body, is flat, narrow, and ribbon-like; it arises by tendinous fibres from the anterior superior spinous process of the

\* These parts will be again more particularly described with the anatomy of Hernia.



ilium and the upper half of the notch below it, passes obliquely across the upper and anterior part of the thigh, from the outer to the inner side of the limb, then descends vertically, as far as the inner side of the knee, passing behind the inner condyle of the femur, and terminates in a tendon, which, curving obliquely forwards, expands into a broad aponeurosis, inserted into the upper part of the inner surface of the shaft of the tibia, nearly as far forwards as the crest. This expansion is inserted into the bone by an inverted U-shaped aponeurosis; part of it is inserted behind the attachment of the Gracilis and Semitendinosus, and another part, arching over the upper border of the tendon of the Gracilis, is inserted into the tibia in front of these muscles. An offset is derived from the upper margin of this aponeurosis, which blends with the fibrous capsule of the knee-joint, and another, given off from its lower border, blends with the fascia on the inner side of the leg.

The relations of this muscle to the femoral artery should be carefully examined, as it constitutes the chief guide in tying the vessel. In the upper third of the thigh it forms the outer side of a triangular space, *Scarpa's triangle*, the inner side of which is formed by the Adductor longus, and the base, turned upwards, by Poupart's ligament; the femoral artery passes perpendicularly through the middle of this space from its base to its apex. In the middle third of the thigh, the femoral artery lies first along the inner border, and then behind the Sartorius.

**Relations.**—By its *superficial surface*, with the fascia lata and integument. By its *deep surface*, with the Rectus, Iliacus, Psoas, Vastus internus, anterior crural nerve, sheath of the femoral vessels, Adductor longus, Adductor magnus, Gracilis, Semitendinosus, long saphenous nerve, and internal lateral ligament of the knee-joint.

The **Quadriceps extensor** includes the four remaining muscles on the front of the thigh. It is the great Extensor muscle of the leg, forming a large fleshy mass, which covers the front and sides of the femur, being united below into a single tendon, attached to the patella, and above, subdivided into separate portions, which have received distinct names. Of these, one occupying the middle of the thigh, connected above with the ilium, is called the *Rectus femoris*, from its straight course. The other divisions lie in immediate connection with the shaft of the femur, which they cover from the trochanters to the condyles. The portion on the outer side of the femur is termed the *Vastus externus*; that covering the inner side, the *Vastus internus*; and that covering the front of the femur, the *Crureus*. The two latter portions are, however, so intimately blended as to form but one muscle.

The **Rectus femoris** is situated in the middle of the anterior region of the thigh; it is fusiform in shape, and its superficial fibres are arranged in a bipenniform manner, the deep fibres running straight down to the deep aponeurosis. It arises by two tendons: one, the straight tendon, or short head, from the anterior inferior spinous process of the ilium; the other is flattened, and curves outwards, to be attached to a groove above the brim of the acetabulum; this is the reflected tendon, or long head, of the Rectus; it unites with the straight tendon at an acute angle, and then spreads into an aponeurosis, from which the muscular fibres arise.\* The muscle terminates in a broad and thick aponeurosis, which occupies the lower two-thirds of its posterior surface, and, gradually becoming narrowed into a flattened tendon, is inserted into the patella in common with the Vasti and Crureus.

**Relations.**—By its *superficial surface*, with the anterior fibres of the Gluteus minimus, the Tensor vaginæ femoris, the Sartorius, and the Psoas and Iliacus;

\* Mr. W. R. Williams, in an interesting paper in the *Journ. of Anat. and Phys.* vol. xiii. p. 204, points out that the reflected tendon is the real origin of the muscle, and is alone present in early foetal life. The direct tendon is merely an accessory band of condensed fascia. The paper will well repay perusal, though in some particulars I think the description in the text more generally accurate.—ED.



by its lower three-fourths, with the fascia lata. By its *posterior surface*, with the hip-joint, the external circumflex vessels, and the Crureus and Vasti muscles.

The three remaining muscles have been described collectively by some anatomists, separate from the Rectus, under the name of the *Triceps extensor cruris*.

The **Vastus externus** is the largest part of the Quadriceps extensor. It arises by a broad aponeurosis, which is attached to the tubercle of the femur, to the anterior and inferior borders of the great trochanter, to a rough line leading from the trochanter major to the linea aspera, and to the outer lip of the linea aspera: this aponeurosis covers the upper three-fourths of the muscle, and from its inner surface many fibres arise. A few additional fibres arise from the tendon of the Gluteus maximus, and from the external intermuscular septum between the Vastus externus and short head of the Biceps. The fibres form a large fleshy mass, which is attached to a strong aponeurosis, placed on the under surface of the muscle at its lower part: this becomes contracted and thickened into a flat tendon, which is inserted into the outer border of the patella, blending with the great extensor tendon.

**Relations.**—By its *superficial surface*, with the Rectus, the Tensor vaginae femoris, the fascia lata, and the Gluteus maximus, from which it is separated by a synovial bursa. By its *deep surface*, with the Crureus, some large branches of the external circumflex artery and anterior crural nerve being interposed.

The **Vastus internus** and **Crureus** are so inseparably connected together as to form but one muscle, as which it will be accordingly described. It is the smallest portion of the Quadriceps extensor. The anterior portion of it, covered by the Rectus, is called the Crureus; the internal portion, which lies immediately beneath the fascia lata, the Vastus internus. It arises by an aponeurosis, which is attached to the lower part of the line that extends from the inner side of the neck of the femur to the linea aspera, from the inner lip of the linea aspera, from the ridge leading from the linea aspera to the internal condyle and internal intermuscular septum. It also arises from nearly the whole of the internal, anterior, and external surfaces of the shaft of the femur, limited, above, by the line between the two trochanters, and extending, below, to within the lower fourth of the bone. From these different origins, the fibres converge to a broad aponeurosis, which covers the anterior surface of the middle portion of the muscle (the Crureus), and the deep surface of the inner division of the muscle (the Vastus internus), and which gradually narrows down to its insertion into the patella, where it blends with the other portions of the Quadriceps extensor. The muscular fibres of the Vastus internus extend lower down than those of the Vastus externus, so that the capsule of the joint is less covered with muscular fibres on the outer than on the inner side.

**Relations.**—By its *superficial surface*, with the Psoas and Iliacus, the Rectus, Sartorius, Pectineus, Adductors, and fascia lata, femoral vessels, and saphenous nerve. By its *deep surface*, with the femur, Subcrureus, and synovial membrane of the knee-joint.

The student will observe the striking analogy that exists between the Quadriceps extensor and the Triceps muscle in the upper extremity. So close is this similarity that M. Cruveilhier has described it under the name of the *Triceps femoralis*. Like the Triceps extensor cubiti, it consists of three distinct divisions, or heads: a middle or long head, the Rectus, analogous to the long head of the Triceps, attached to the ilium, and two other portions, which may be called the external and internal heads of the Triceps femoralis. These, it will be noticed, are strictly analogous to the outer and inner heads of the Triceps in the arm.

The *tendons* of the different portions of the Quadriceps extensor unite at the lower part of the thigh, so as to form a single strong tendon, which is inserted into the upper part of the patella, some few fibres passing over it to blend with the ligamentum patellæ. More properly, the patella may be regarded as a sesamoid bone, developed in the tendon of the Quadriceps; and the ligamentum

patellæ, which is continued from the lower part of the patella to the tuberosity of the tibia, as the proper tendon of insertion of the muscle. A synovial bursa, the *post-patellar bursa*, is interposed between the tendon and the upper part of the tuberosity of the tibia; and another, the *prepatellar bursa*, is placed over the patella itself. This latter bursa often becomes enlarged, constituting 'housemaid's knee.'

The **Subcrureus** is a small muscle, usually distinct from the Crureus, but occasionally blended with it, which arises from the anterior surface of the lower part of the shaft of the femur, and is inserted into the upper part of the *cul-de-sac* of the capsular ligament which projects upwards beneath the Quadriceps for a variable distance. It sometimes consists of several separate muscular bundles.

**Nerves.**—The Tensor vaginæ femoris is supplied by the fourth and fifth lumbar and first sacral nerves through the superior gluteal nerve; the other muscles of this region, by the second, third, and fourth lumbar nerves, through branches of the anterior crural.

**Actions.**—The Tensor vaginæ femoris is a tensor of the fascia lata; continuing its action, the oblique direction of its fibres enables it to abduct and to rotate the thigh inwards. In the erect posture, acting from below, it will serve to steady the pelvis upon the head of the femur; and by means of the ilio-tibial band it steadies the condyles of the femur on the articular surfaces of the tibia, and assists the Gluteus maximus in supporting the knee in the extended position. The Sartorius flexes the leg upon the thigh, and, continuing to act, flexes the thigh upon the pelvis; it next rotates the thigh outwards. It was formerly supposed to adduct the thigh, so as to cross one leg over the other, and hence received its name of Sartorius, or tailor's muscle (*sartor*, a tailor), because it was supposed to assist in crossing the legs in the squatting position. When the knee is bent, the Sartorius assists the Semitendinosus, Semimembranosus, and Popliteus in rotating the tibia inwards. Taking its fixed point from the leg, it flexes the pelvis upon the thigh, and, if one muscle acts, assists in rotating the pelvis. The Quadriceps extensor extends the leg upon the thigh. The Rectus muscle assists the Psoas and Iliacus in supporting the pelvis and trunk upon the femur, or in bending it forwards.

**Surgical Anatomy.**—A few fibres of the Rectus muscle are liable to be ruptured from severe strain. This accident is especially liable to occur during the games of football and cricket, and is sometimes known as 'cricket thigh.' The patient experiences a sudden pain in the part, as if he had been struck, and the Rectus muscle stands out and is felt to be tense and rigid. The accident is often followed by considerable swelling from inflammatory effusion. Occasionally the Quadriceps extensor may be torn away from its insertion into the patella; or the tendon of the patella may be ruptured about an inch above the bone. This accident is caused in the same manner as fracture of the patella by muscular action is produced, viz. by a violent muscular effort to prevent falling whilst the knee is in a position of semiflexion. A distinct gap can be felt above the patella, and, owing to the retraction of the muscular fibres, union may fail to take place.

## 2. Internal Femoral Region

Gracilis.	Adductor longus.
Pectineus.	Adductor brevis.
Adductor magnus.	

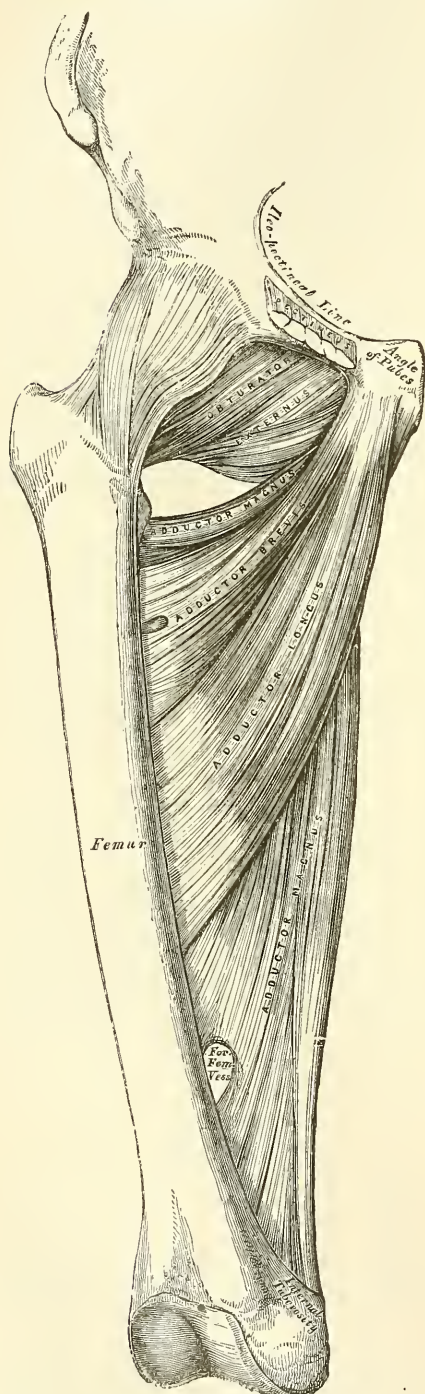
**Dissection.**—These muscles are at once exposed by removing the fascia from the fore part and inner side of the thigh. The limb should be abducted, so as to render the muscles tense and easier of dissection.

The **Gracilis** (figs. 364, 367) is the most superficial muscle on the inner side of the thigh. It is thin and flattened, broad above, narrow and tapering below. It arises by a thin aponeurosis between two and three inches in breadth, from the lower half of the margin of the symphysis and the inner margin of the descending ramus of the os pubis. The fibres pass vertically downwards, and terminate in



a rounded tendon, which passes behind the internal condylé of the femur, and, curving round the inner tuberosity of the tibia, becomes flattened, and is inserted

FIG. 365.—Deep muscles of the internal femoral region.



into the upper part of the inner surface of the shaft of the tibia, below the tuberosity. A few of the fibres of the lower part of the tendon are prolonged into the deep fascia of the leg. The tendon of this muscle is situated immediately above that of the Semitendinosus, and is surrounded by the tendon of the Sartorius with which it is in part blended. As it passes across the internal lateral ligament of the knee-joint, it is separated from it by a synovial bursa common to it and the Semitendinosus muscle.

**Relations.**—By its *superficial surface*, with the fascia lata and the Sartorius below; the internal saphenous vein crosses it obliquely near its lower part, lying superficial to the fascia lata. The internal saphenous nerve emerges between its tendon and that of the Sartorius. By its *deep surface*, with the Adductor brevis and the Adductor magnus, and the internal lateral ligament of the knee-joint.

The **Pectineus** (fig. 364) is a flat, quadrangular muscle, situated at the anterior part of the upper and inner aspect of the thigh. It arises from the linea ilio-pectinea, from the surface of bone in front of it, between the pectineal eminence and spine of the os pubis, and from the fascia covering the anterior surface of the muscle; the fibres pass downwards, backwards, and outwards, to be inserted into a rough line leading from the lesser trochanter to the linea aspera.

**Relations.**—By its *anterior surface*, with the pubic portion of the fascia lata, which separates it from the femoral vessels and internal saphenous vein. By its *posterior surface*, with the capsular ligament of the hip-joint, the Adductor brevis and Obturator externus muscles, the obturator vessels and nerve being interposed. By its *outer border*, with the Psoas, a cellular interval separating them, through which passes the internal circumflex vessels. By its *inner border*, with the margin of the Adductor longus.

The **Adductor longus**, the most superficial of the three Adductors, is a flat triangular muscle, lying on the same plane as the Pectineus. It arises, by a flat narrow tendon, from the front of the os pubis, at the angle of junction of the crest with the symphysis; and



soon expands into a broad fleshy belly, which, passing downwards, backwards, and outwards, is inserted, by an aponeurosis, into the linea aspera, between the Vastus internus and the Adductor magnus, with which it is usually blended.

**Relations.**—By its *anterior surface*, with the fascia lata, the Sartorius, and, near its insertion, with the femoral artery and vein. By its *posterior surface*, with the Adductor brevis and magnus, the anterior branches of the obturator nerve, and with the profunda artery and vein near its insertion. By its *outer border*, with the Pectineus. By its *inner border*, with the Gracilis.

The Pectineus and Adductor longus should now be divided near their origin, and turned downwards, when the Adductor brevis and Obturator externus will be exposed.

The **Adductor brevis** is situated immediately behind the two preceding muscles. It is somewhat triangular in form, and arises by a narrow origin from the outer surface of the body and descending ramus of the os pubis, between the Gracilis and Obturator externus. Its fibres, passing backwards, outwards, and downwards, are inserted, by an aponeurosis, into the lower part of the line leading from the lesser trochanter to the linea aspera and the upper part of the linea aspera, immediately behind the Pectineus and upper part of the Adductor longus.

**Relations.**—By its *anterior surface*, with the Pectineus, Adductor longus, profunda femoris artery, and anterior branches of the obturator nerve. By its *posterior surface*, with the Adductor magnus, and posterior branch of the obturator nerve. By its *outer border*, with the Obturator externus, and conjoined tendon of the Psoas and Iliacus. By its *inner border*, with the Gracilis and Adductor magnus. This muscle is pierced, near its insertion, by the middle perforating branch of the profunda femoris artery.

The Adductor brevis should now be cut away near its origin, and turned outwards, when the entire extent of the Adductor magnus will be exposed.

The **Adductor magnus** is a large triangular muscle, forming a septum between the muscles on the inner and those on the back of the thigh. It arises from a small part of the descending ramus of the os pubis, from the ascending ramus of the ischium, and from the outer margin and under surface of the tuberosity of the ischium. Those fibres which arise from the ramus of the os pubis are very short, horizontal in direction, and are inserted into the rough line leading from the great trochanter to the linea aspera, internal to the Gluteus maximus; those from the ramus of the ischium are directed downwards and outwards with different degrees of obliquity, to be inserted, by means of a broad aponeurosis, into the linea aspera and the upper part of its internal prolongation below. The internal portion of the muscle, consisting principally of those fibres which arise from the tuberosity of the ischium, forms a thick fleshy mass consisting of coarse bundles which descend almost vertically, and terminate about the lower third of the thigh in a rounded tendon, which is inserted into the Adductor tubercle on the inner condyle of the femur, being connected by a fibrous expansion to the line leading upwards from the tubercle to the linea aspera. Between the two portions of the muscle an interval is left, tendinous in front, fleshy behind, for the passage of the femoral vessels into the popliteal space. The external portion of the muscle at its attachment to the femur presents three or four osseo-aponeurotic openings, formed by tendinous arches attached to the bone, from which muscular fibres arise. The three superior of these apertures are for the three perforating arteries, and the fourth, when it exists, for the terminal branch of the profunda.

**Relations.**—By its *anterior surface*, with the Pectineus, Adductor brevis, Adductor longus, and the femoral and profunda vessels and obturator nerve. By its *posterior surface*, with the great sciatic nerve, the Gluteus maximus, Biceps, Semitendinosus, and Semimembranosus. By its *superior or shortest border* it lies parallel with the Quadratus femoris, the internal circumflex artery passing

between them. By its *internal* or *longest border*, with the Gracilis, Sartorius, and fascia lata. By its *external* or *attached border*, it is inserted into the femur behind the Adductor brevis and Adductor longus, which separate it from the Vastus internus; and in front of the Gluteus maximus and short head of the Biceps, which separate it from the Vastus externus.

**Nerves.**—The three Adductor muscles and the Gracilis are supplied by the third and fourth lumbar nerves through the Obturator nerve; the Adductor magnus receiving an additional branch from the sacral plexus through the great sciatic. The Pectineus is supplied by the second, third, and fourth lumbar nerves through the anterior crural; from the third and fourth lumbar nerves by the obturator and by the accessory obturator, from the third lumbar, when it exists.\*

**Actions.**—The Pectineus and three Adductors adduct the thigh powerfully; they are especially used in horse exercise, the flanks of the horse being grasped between the knees by the actions of these muscles. In consequence of the obliquity of their insertion into the linea aspera, they rotate the thigh outwards, assisting the external Rotators, and when the limb has been abducted, they draw it inwards, carrying the thigh across that of the opposite side. The Pectineus and Adductor brevis and longus assist the Psoas and Iliacus in flexing the thigh upon the pelvis. In progression, also, all these muscles assist in drawing forwards the hinder limb. The Gracilis assists the Sartorius in flexing the leg and rotating it inwards; it is also an adductor of the thigh. If the lower extremities are fixed, these muscles may take their fixed point from below and act upon the pelvis, serving to maintain the body in an erect posture; or, if their action is continued, to flex the pelvis forwards upon the femur.

*Surgical Anatomy.*—The Adductor longus is liable to be severely strained in those who ride much on horseback, or its tendon to be ruptured by suddenly gripping the saddle. And, occasionally, especially in cavalry soldiers, the tendon may become ossified, constituting the 'rider's bone.'

### 3. Gluteal Region

Gluteus maximus.	Gemellus superior.
Gluteus medius.	Obturator internus.
Gluteus minimus.	Gemellus inferior.
Pyriformis.	Obturator externus.
Quadratus femoris.	

*Dissection* (fig. 328).—The subject should be turned on its face, a block placed beneath the pelvis to make the buttocks tense, and the limbs allowed to hang over the end of the table, with the foot inverted, and the thigh abducted. Make an incision through the integument along the crest of the ilium to the middle of the sacrum and thence downwards to the tip of the coccyx, and carry a second incision from that point obliquely downwards and outwards to the outer side of the thigh, four inches below the great trochanter. The portion of integument included between these incisions is to be removed in the direction shown in the figure.

The **Gluteus maximus** (fig. 367), the most superficial muscle in the gluteal region, is a very broad and thick fleshy mass, of a quadrilateral shape, which forms the prominence of the nates. Its large size is one of the most characteristic points in the muscular system in man, connected as it is with the power he has of maintaining the trunk in the erect posture. In structure the muscle is remarkably coarse, being made up of muscular fasciculi lying parallel with one another, and collected together into large bundles, separated by deep cellular intervals. It arises from the superior curved line of the ilium, and the portion of bone, including the crest, immediately behind it; from the posterior surface

\* Professor Paterson describes the Pectineus as consisting of two incompletely separated strata, of which the outer or dorsal stratum, which is constant, is supplied by the anterior crural nerve, or in its absence by the accessory obturator, with which it is intimately related; while the inner or ventral stratum, when present, is supplied by the obturator nerve. *Journal of Anatomy and Physiology*, vol. xxvi. p. 43.

of the lower part of the sacrum, the side of the coccyx, the aponeurosis of the Erector spinæ muscle, and the great sacro-sciatic ligament. The fibres are directed obliquely downwards and outwards; those forming the upper and larger portion of the muscle, together with the superficial fibres of the lower portion, terminate in a thick tendinous lamina, which passes across the great trochanter, and is inserted into the fascia lata covering the outer side of the thigh; the deeper fibres of the lower portion of the muscle are inserted into the rough line leading from the great trochanter to the linea aspera between the Vastus externus and Adductor magnus.

Three *synovial bursæ* are usually found in relation with this muscle. One of these, of large size, and generally multilocular, separates it from the great trochanter. A second, often wanting, is situated on the tuberosity of the ischium. A third is found between the tendon of this muscle and the Vastus externus.

**Relations.**—By its *superficial surface*, with a thin fascia, which separates it from the subcutaneous tissue. By its *deep surface*, from above downwards, with the ilium, sacrum, coccyx, and great sacro-sciatic ligament, part of the Gluteus medius, Pyramiformis, Gemelli, Obturator internus, Quadratus femoris, the tuberosity of the ischium, great trochanter, the origin of the Biceps, Semitendinosus, Semimembranosus, and Adductor magnus muscles. The gluteal vessels and superior gluteal nerve are seen issuing from the pelvis above the Pyramiformis muscle, the sciatic and internal pudic vessels and nerves, and muscular branches from the sacral plexus below it. Its *upper border* is thin, and connected with the Gluteus medius by the fascia lata. Its *lower border* is free and prominent.

**Dissection.**—Now divide the Gluteus maximus near its origin by a vertical incision carried from its upper to its lower border; a cellular interval will be exposed, separating it from the Gluteus medius and External rotator muscles beneath. The upper portion of the muscle is to be altogether detached, and the lower portion turned outwards; the loose areolar tissue filling up the interspace between the trochanter major and tuberosity of the ischium being removed, the parts already enumerated as exposed by the removal of this muscle will be seen.

The **Gluteus medius** is a broad, thick, radiated muscle, situated on the outer surface of the pelvis. Its posterior third is covered by the Gluteus maximus; its anterior two-thirds by the fascia lata, which separates it from the integument. It arises from the outer surface of the ilium, between the superior and middle curved lines, and from the outer lip of that portion of the crest which is between them; it also arises from the dense fascia (Gluteal aponeurosis) covering its outer surface. The fibres converge to a strong flattened tendon, which is inserted into the oblique line which traverses the outer surface of the great trochanter. A synovial bursa separates the tendon of the muscle from the surface of the trochanter in front of its insertion.

FIG. 366.—Dissection of lower extremity. Posterior view.

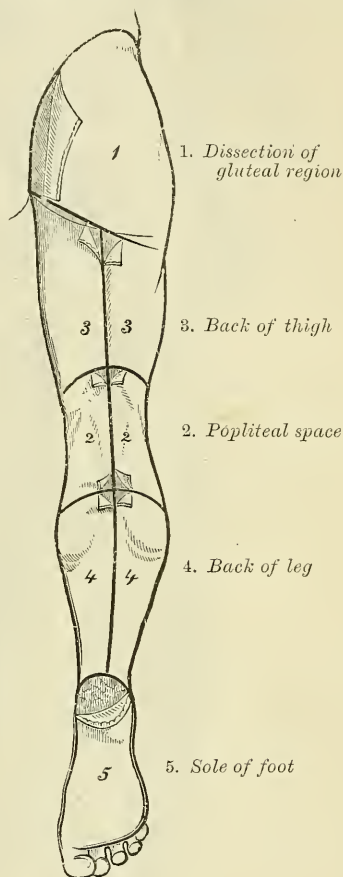
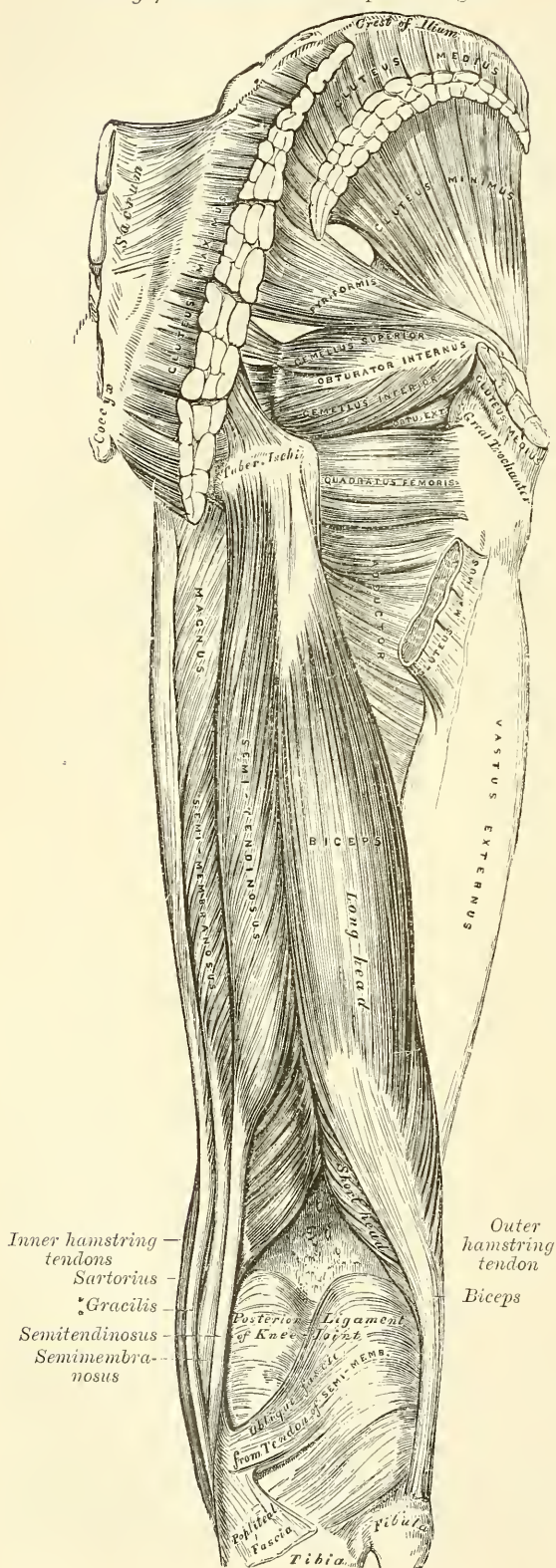




FIG. 367.—Muscles of the hip and thigh.



**Relations.**—By its *superficial surface*, with the Gluteus maximus behind, the Tensor vaginæ femoris and deep fascia in front. By its *deep surface*, with the Gluteus minimus and the gluteal vessels and superior gluteal nerve. Its *anterior border* is blended with the Gluteus minimus. Its *posterior border* lies parallel with the Piriformis, the gluteal vessels intervening.

This muscle should now be divided near its insertion and turned upwards, when the Gluteus minimus will be exposed.

The **Gluteus minimus**, the smallest of the three Glutei, is placed immediately beneath the preceding. It is fan-shaped, arising from the outer surface of the ilium, between the middle and inferior curved lines, and behind, from the margin of the great sacro-sciatic notch: the fibres converge to the deep surface of a radiated aponeurosis, which, terminating in a tendon, is inserted into an impression on the anterior border of the great trochanter. A synovial bursa is interposed between the tendon and the great trochanter.

**Relations.**—By its *superficial surface*, with the Gluteus medius, and the gluteal vessels and superior gluteal nerve. By its *deep surface*, with the ilium, the reflected tendon of the Rectus femoris, and capsular ligament of the hip-joint. Its *anterior margin* is blended with the Gluteus medius. Its *posterior margin* is in contact and sometimes joined with the tendon of the Piriformis.

The **Piriformis** is a flat muscle, pyramidal in shape, lying almost parallel with

the posterior margin of the *Gluteus medius*. It is situated partly within the pelvis at its posterior part, and partly at the back of the hip-joint. It arises from the front of the sacrum by three fleshy digitations, attached to the portions of bone between the first, second, third, and fourth anterior sacral foramina, and also from the grooves leading from the foramina: a few fibres also arise from the margin of the great sacro-sciatic foramen, and from the anterior surface of the great sacro-sciatic ligament. The muscle passes out of the pelvis through the great sacro-sciatic foramen, the upper part of which it fills, and is inserted by a rounded tendon into the upper border of the great trochanter, behind, but often blended with, the tendon of the *Obturator internus* and *Gemelli* muscles.

**Relations.**—By its *anterior surface, within the pelvis*, with the Rectum (especially on the left side), the sacral plexus of nerves, and the branches of the internal iliac vessels; *external to the pelvis*, with the os innominatum and capsular ligament of the hip-joint. By its *posterior surface, within the pelvis*, with the sacrum; and *external to it*, with the *Gluteus maximus*. By its *upper border*, with the *Gluteus medius*, from which it is separated by the gluteal vessels and superior gluteal nerve. By its *lower border*, with the *Gemellus superior* and *Coccygeus*; the sciatic vessels and nerves, the internal pudic vessels and nerve, and muscular branches from the sacral plexus, passing from the pelvis in the interval between the two muscles.

The **Obturator membrane** is a thin layer of interlacing fibres, which closes the obturator foramen. It is attached, externally, to the margin of the foramen; internally, to the posterior surface of the ischio-pubic ramus, internal to the inner margin of the foramen. It is occasionally incomplete, and presents at its upper and outer part a small canal, which is bounded below by a thickened band of fibres, for the passage of the obturator vessels and nerve. Each *Obturator* muscle is connected with this membrane.

**Dissection.**—The next muscle, as well as the origin of the *Pyriformis*, can only be seen when the pelvis is divided and the viscera removed.

The **Obturator internus**, like the preceding muscle, is situated partly within the cavity of the pelvis, and partly at the back of the hip-joint. It arises from the inner surface of the anterior and external wall of the pelvis, around the inner side of the obturator foramen, being attached to the descending ramus of the os pubis and the ascending ramus of the ischium, and at the side to the inner surface of the body of the ischium, between the margin of the obturator foramen in front, and the great sacro-sciatic notch behind, and to the inner surface of the ilium below the brim of the true pelvis. It also arises from the inner surface of the obturator membrane except at its lower part, from the tendinous arch which completes the canal for the passage of the obturator vessels and nerve and to a slight extent from the obturator layer of the pelvic fascia, which covers it. The fibres are directed backwards and downwards, and terminate in four or five tendinous bands, which are found on its deep surface; these bands are reflected at a right angle over the inner surface of the tuberosity of the ischium, which is grooved for their reception: the groove is covered with cartilage, and lined by a synovial bursa. The muscle leaves the pelvis by the lesser sacro-sciatic notch; and the tendinous bands unite into a single flattened tendon, which passes horizontally outwards, and, after receiving the attachment of the *Gemelli*, is inserted into the fore part of the inner surface of the great trochanter in front of the *Obturator externus*. A synovial bursa, narrow and elongated in form, is usually found between the tendon of this muscle and the capsular ligament of the hip: it occasionally communicates with the bursa between the tendon and the tuberosity of the ischium, the two forming a single sac.

In order to display the peculiar appearances presented by the tendon of this muscle, it must be divided near its insertion and reflected outwards.



**Relations.**—*Within the pelvis*, this muscle is in relation, by its *anterior surface*, with the obturator membrane and inner surface of the anterior wall of the pelvis; by its *posterior surface*, with the pelvic and obturator fasciæ, which separate it from the Levator ani; and it is crossed by the internal pudic vessels and nerve. This surface forms the outer boundary of the ischio-rectal fossa. *External to the pelvis*, it is covered by the great sciatic nerve and Gluteus maximus, and rests on the back part of the hip-joint.

The **Gemelli** are two small muscular fasciculi, accessories to the tendon of the Obturator internus, which is received into a groove between them. They are called *superior* and *inferior*.

The **Gemellus superior**, the smaller of the two, arises from the outer surface of the spine of the ischium, and passing horizontally outwards becomes blended with the upper part of the tendon of the Obturator internus, and is inserted with it into the inner surface of the great trochanter. This muscle is sometimes wanting.

**Relations.**—By its *superficial surface*, with the Gluteus maximus and the sciatic vessels and nerves. By its *deep surface*, with the capsule of the hip-joint. By its *upper border*, with the lower margin of the Pyliformis. By its *lower border*, with the tendon of the Obturator internus.

The **Gemellus inferior** arises from the upper part of the tuberosity of the ischium, where it forms the lower edge of the groove for the Obturator internus tendon, and, passing horizontally outwards, is blended with the lower part of the tendon of the Obturator internus, and inserted with it into the inner surface of the great trochanter.

**Relations.**—By its *superficial surface*, with the Gluteus maximus and the sciatic vessels and nerves. By its *deep surface*, with the capsular ligament of the hip-joint. By its *upper border*, with the tendon of the Obturator internus. By its *lower border*, with the tendon of the Obturator externus and Quadratus femoris.

The **Quadratus femoris** is a short, flat muscle, quadrilateral in shape (hence its name), situated between the Gemellus inferior and the upper margin of the Adductor magnus. It arises from the external lip of the tuberosity of the ischium, and, proceeding horizontally outwards, is inserted into the upper part of the linea quadrata, that is, the line which crosses the posterior intertrochanteric line. A synovial bursa is often found between the under surface of this muscle and the lesser trochanter, which it covers.

**Relations.**—By its *posterior surface*, with the Gluteus maximus and the sciatic vessels and nerves. By its *anterior surface*, with the tendon of the Obturator externus and trochanter minor, and with the capsule of the hip-joint. By its *upper border*, with the Gemellus inferior. Its *lower border* is separated from the Adductor magnus by the terminal branches of the internal circumflex vessels.

**Dissection.**—In order to expose the next muscle (the Obturator externus), it is necessary to remove the Psoas, Iliacus, Pectineus, and Adductor brevis and longus muscles from the front and inner side of the thigh; and the Gluteus maximus and Quadratus femoris from the back part. Its dissection should, consequently, be postponed until the muscles of the anterior and internal femoral regions have been examined.

The **Obturator externus** (fig. 368) is a flat, triangular muscle, which covers the outer surface of the anterior wall of the pelvis. It arises from the margin of bone immediately around the inner side of the obturator foramen, viz. from the body and ramus of the os pubis, and the ramus of the ischium; it also arises from the inner two-thirds of the outer surface of the obturator membrane, and from the tendinous arch which completes the canal for the passage of the obturator vessels and nerves. The fibres converging pass backwards, outwards and upwards, and terminate in a tendon which runs across the back part of the hip-joint, and is inserted into the digital fossa of the femur.

**Relations.**—By its *anterior surface*, with the Psoas, Iliacus, Pectineus,

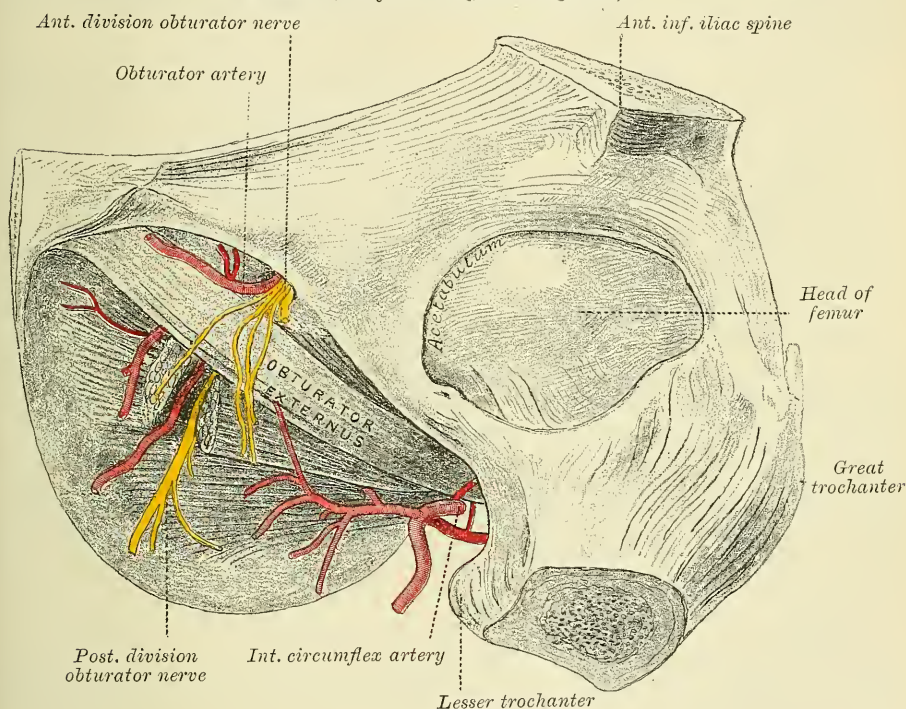


Adductor magnus, and Adductor brevis; and more externally, with the neck of the femur and capsule of the hip-joint. The obturator artery and vein lie between this muscle and the obturator membrane; the superficial part of the obturator nerve lies above the muscle and the deep branch perforates it. By its *posterior surface*, with the obturator membrane and Quadratus femoris.

**Nerves.**—The Gluteus maximus is supplied by the fifth lumbar and first and second sacral nerves through the inferior gluteal nerve from the sacral plexus; the Gluteus medius and minimus, by the fourth and fifth lumbar and first sacral nerves through the superior gluteal; the Piriformis is supplied by the second sacral nerve; the Gemellus inferior and Quadratus femoris by the last lumbar and first sacral nerve; the Gemellus superior and Obturator internus by the first and second sacral nerves, and the Obturator externus by the second, third, and fourth lumbar nerves through the Obturator.

**Actions.**—The Gluteus maximus, when it takes its fixed point from the pelvis,

FIG. 368.—Obturator externus muscle. (From a preparation in the Hunterian Museum, Royal College of Surgeons.)



extends the femur and brings the bent thigh into a line with the body. Taking its fixed point from below, it acts upon the pelvis, supporting it and the whole trunk upon the head of the femur, which is especially obvious in standing on one leg. Its most powerful action is to cause the body to regain the erect position after stooping, by drawing the pelvis backwards, being assisted in this action by the Biceps, Semitendinosus, and Semimembranosus. The Gluteus maximus is a tensor of the fascia lata, and by its connection with the ilio-tibial band it steadies the femur on the articular surface of the tibia during standing, when the extensor muscles are relaxed. The lower part of the muscle also acts as an adductor and external rotator of the limb. The Gluteus medius and minimus abduct the thigh, when the limb is extended, and are principally called into action in supporting the body on one limb, in conjunction with the Tensor vaginae femoris. Their anterior fibres, by drawing the great trochanter forwards, rotate the thigh inwards,

in which action they are also assisted by the Tensor vaginæ femoris. The remaining muscles are powerful rotators of the thigh outwards. In the sitting posture, when the thigh is flexed upon the pelvis, their action as rotators ceases, and they become abductors, with the exception of the Obturator externus, which still rotates the femur outwards. When the femur is fixed, the Piriformis and Obturator muscles serve to draw the pelvis forwards if it has been inclined backwards, and assist in steadying it upon the head of the femur.

#### 4. *Posterior Femoral Region*

Biceps.

Semitendinosus.

Semimembranosus.

*Dissection* (fig. 366).—Make a vertical incision along the middle of the thigh, from the lower fold of the nates to about three inches below the back of the knee-joint, and there connect it with a transverse incision, carried from the inner to the outer side of the leg. Make a third incision transversely at the junction of the middle with the lower third of the thigh. The integument having been removed from the back of the knee, and the boundaries of the popliteal space examined, the removal of the integument from the remaining part of the thigh should be continued, when the fascia and muscles of this region will be exposed.

The **Biceps** (*Biceps flexor cruris*) is a large muscle, of considerable length, situated on the posterior and outer aspect of the thigh (fig. 367). It arises by two heads. One, the long head, arises from the lower and inner facet on the back part of the tuberosity of the ischium, by a tendon common to it and the Semitendinosus, and from the lower part of the great sacro-sciatic ligament. The femoral, or short head, arises from the outer lip of the linea aspera, between the Adductor magnus and Vastus externus, extending up almost as high as the insertion of the Gluteus maximus; from the outer prolongation of the linea aspera to within two inches of the outer condyle; and from the external intermuscular septum. The fibres of the long head form a fusiform belly, which, passing obliquely downwards and a little outwards, terminates in an aponeurosis which covers the posterior surface of the muscle, and receives the fibres of the short head: this aponeurosis becomes gradually contracted into a tendon, which is inserted into the outer side of the head of the fibula, and by a small slip into the lateral surface of the external tuberosity of the tibia. At its insertion the tendon divides into two portions, which embrace the long external lateral ligament of the knee-joint. From the posterior border of the tendon a thin expansion is given off to the fascia of the leg. The tendon of this muscle forms the outer hamstring.

**Relations.**—By its *superficial surface*, with the Gluteus maximus above, with the fascia lata and integument in the rest of its extent. By its *deep surface*, with the Semimembranosus, Adductor magnus, and Vastus externus, the great sciatic nerve, and, near its insertion, with the external head of the Gastrocnemius, Plantaris, the superior external articular artery, and the external popliteal nerve.

The **Semitendinosus**, remarkable for the great length of its tendon, is situated at the posterior and inner aspect of the thigh. It arises from the lower and inner facet on the tuberosity of the ischium, by a tendon common to it and the long head of the Biceps; it also arises from an aponeurosis which connects the adjacent surfaces of the two muscles to the extent of about three inches after their origin. It forms a fusiform muscle, which, passing downwards and inwards, terminates a little below the middle of the thigh in a long round tendon which lies along the inner side of the popliteal space, then curves around the inner tuberosity of the tibia, and is inserted into the upper part of the inner surface of the shaft of that bone, nearly as far forwards as its anterior border. At its insertion it gives off from its lower border a prolongation to the deep fascia of the leg. This tendon is surrounded by the tendon of the Sartorius, and lies



below that of the Gracilis, to which it is united. A tendinous intersection is usually observed about the middle of the muscle.

**Relations.**—By its *superficial surface*, with the Gluteus maximus and fascia lata. By its *deep surface*, with the Semimembranosus, Adductor magnus, inner head of the Gastrocnemius, and internal lateral ligament of the knee-joint.

The **Semimembranosus**, so called from a membranous expansion on its anterior and posterior surfaces, is situated at the back part and inner side of the thigh. It arises by a thick tendon from the upper and outer facet on the back part of the tuberosity of the ischium, above and to the outer side of the Biceps and Semitendinosus, and is inserted into the groove on the inner and back part of the inner tuberosity of the tibia, beneath the internal lateral ligament. The tendon of the muscle at its origin expands into an aponeurosis, which covers the upper part of its anterior surface: from this aponeurosis muscular fibres arise, and converge to another aponeurosis which covers the lower part of its posterior surface and contracts into the tendon of insertion. The tendon of the muscle at its insertion gives off two fibrous expansions; one of these, of considerable size, passes upwards and outwards to be inserted into the back part of the outer condyle of the femur, forming part of the posterior ligament of the knee-joint. The second is continued downwards to the fascia which covers the Popliteus muscle. The tendon also sends a few fibres to join the internal lateral ligament of the joint.

The tendons of the two preceding muscles, with that of the Gracilis, form the inner hamstring.

**Relations.**—By its *superficial surface*, with the Semitendinosus, Biceps, and fascia lata. By its *deep surface*, with the popliteal vessels, Adductor magnus, and inner head of the Gastrocnemius, from which it is separated by a synovial bursa. By its *inner border*, with the Gracilis. By its *outer border*, with the great sciatic nerve, and its internal popliteal branch.

**Nerves.**—The muscles of this region are supplied by the first, second, and third sacral nerves through the great sciatic nerve.

**Actions.**—The hamstring muscles flex the leg upon the thigh. When the knee is semi-flexed, the Biceps, in consequence of its oblique direction downwards and outwards, rotates the leg slightly outwards; and the Semitendinosus, and to a slight extent the Semimembranosus, rotate the leg inwards, assisting the Popliteus. Taking their fixed point from below, these muscles serve to support the pelvis upon the head of the femur, and to draw the trunk directly backwards, as in feats of strength, when the body is thrown backwards in the form of an arch. When the leg is extended on the thigh they limit the amount of flexion of the trunk on the lower limbs.

*Surgical Anatomy.*—The tendons of these muscles occasionally require subcutaneous division in some forms of spurious ankylosis of the knee-joint dependent upon permanent contraction and rigidity of the flexor muscles, or from stiffening of the ligamentous and other tissues surrounding the joint, the result of disease. This is effected by putting the tendon upon the stretch, and inserting a narrow, sharp-pointed knife between it and the skin: the cutting edge being then turned towards the tendon, it should be divided, taking care that the wound in the skin is not at the same time enlarged. The relation of the external popliteal nerve to the tendon of the Biceps must always be borne in mind in dividing this tendon.

### III. MUSCLES AND FASCLE OF THE LEG

These may be divided into three groups: those on the anterior, those on the posterior, and those on the outer side of the leg.

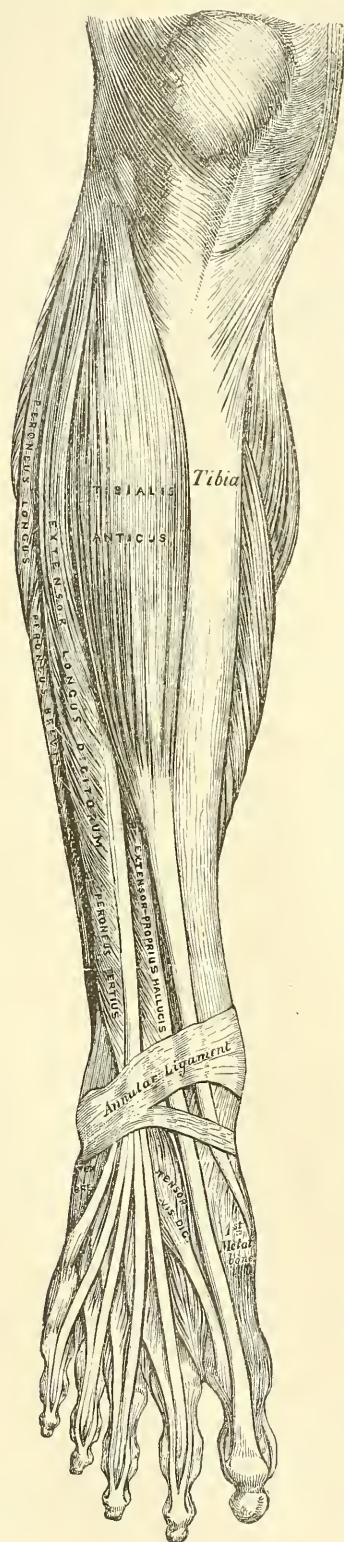
#### 5. Anterior Tibio-fibular Region

Tibialis anticus.	Extensor longus digitorum.
Extensor proprius hallucis.*	Peroneus tertius.

\* There is no such word as 'Hallux, -cis.' It is the result of some ignorant blunder, copied until it has become established by usage; it has been thought better, therefore, to



FIG. 369.—Muscles of the front of the leg.



*Dissection* (fig. 363).—The knee should be bent, a block placed beneath it, and the foot kept in an extended position; then make an incision through the integument in the middle line of the leg to the ankle, and continue it along the dorsum of the foot to the toes. Make a second incision transversely across the ankle, and a third in the same direction across the bases of the toes; remove the flaps of integument included between these incisions in order to examine the deep fascia of the leg.

The **Deep Fascia of the Leg** forms a complete investment to the muscles, but is not continued over the subcutaneous surfaces of the bones. It is continuous above with the fascia lata, receiving an expansion from the tendon of the Biceps on the outer side, and from the tendons of the Sartorius, Gracilis, and Semitendinosus on the inner side; in front, it blends with the periosteum covering the subcutaneous surface of the tibia, and with that covering the head and external malleolus of the fibula; below, it is continuous with the annular ligaments of the ankle. It is thick and dense in the upper and anterior part of the leg, and gives attachment, by its deep surface, to the Tibialis anticus and Extensor longus digitorum muscles: but thinner behind, where it covers the Gastrocnemius and Soleus muscles. Over the popliteal space it is much strengthened by transverse fibres, which stretch across from the inner to the outer hamstring muscles, and it is here perforated by the external saphenous vein. Its deep surface gives off, on the outer side of the leg, two strong intermuscular septa, which enclose the Peronei muscles, and separate them from the muscles on the anterior and posterior tibial regions and several smaller and more slender processes, which enclose the individual muscles in each region; at the same time a broad transverse intermuscular septum, called the *deep transverse fascia of the leg*, intervenes between the superficial and deep muscles in the posterior tibio-fibular region.

Now remove the fascia by dividing it in the same direction as the integument, excepting opposite the ankle, where it should be left entire. Commence

retain it. According to Lewis and Short the word is *ALEX*, masculine; genitive, *ALLICIS*, the great toe, and the correct rendering would be *Extensor proprius allicis*. It is a rare word, and is sometimes spelt, but not so correctly, 'Hallex.' It is used by Plautus, in the 'Pænulus' V. v. 31, of a little man, as we might say 'a hop-o'-my-thumb.' 'Tunc hic amator audes esse, *allex viri*' (To think of you daring to make up to her, you hop-o'-my-thumb!). The word 'alex,' sometimes spelt 'allex,' a fish sauce, is probably a different word altogether. It is used by Horace and Pliny.

the removal of the fascia from below, opposite the tendons, and detach it in the line of direction of the muscular fibres.

The **Tibialis anticus** is situated on the outer side of the tibia; it is thick and fleshy at its upper part, tendinous below. It arises from the outer tuberosity and upper two-thirds of the external surface of the shaft of the tibia; from the adjoining part of the interosseous membrane; from the deep surface of the fascia; and from the intermuscular septum between it and the Extensor longus digitorum: the fibres pass vertically downwards, and terminate in a tendon, which is apparent on the anterior surface of the muscle at the lower third of the leg. After passing through the innermost compartment of the anterior annular ligament, it is inserted into the inner and under surface of the internal cuneiform bone, and base of the metatarsal bone of the great toe.

**Relations.**—By its *anterior surface*, with the fascia, and with the annular ligament. By its *posterior surface*, with the interosseous membrane, tibia, ankle-joint, and inner side of the tarsus: this surface also overlaps the anterior tibial vessels and nerve in the upper part of the leg. By its *inner surface*, with the tibia. By its *outer surface*, with the Extensor longus digitorum, and Extensor proprius hallucis, and the anterior tibial vessels and nerve.

The **Extensor proprius hallucis** is a thin, elongated, and flattened muscle, situated between the Tibialis anticus and Extensor longus digitorum. It arises from the anterior surface of the fibula for about the middle two-fourths of its extent, its origin being internal to that of the Extensor longus digitorum; it also arises from the interosseous membrane to a similar extent. The fibres pass downwards, and terminate in a tendon, which occupies the anterior border of the muscle, passes through a distinct compartment in the horizontal portion of the annular ligament, crosses the anterior tibial vessels near the bend of the ankle, and is inserted into the base of the last phalanx of the great toe. Opposite the metatarso-phalangeal articulation, the tendon gives off a thin prolongation on each side, which covers the surface of the joint. It usually sends an expansion, from the inner side of the tendon, to be inserted into the base of the first phalanx.

**Relations.**—By its *anterior surface*, with the fascia, and the anterior annular ligament. By its *posterior surface*, with the interosseous membrane, fibula, tibia, ankle-joint, and Extensor brevis digitorum. By its *outer side*, with the Extensor longus digitorum above, the dorsalis pedis vessels and anterior tibial nerve below. By its *inner side*, with the Tibialis anticus and the anterior tibial vessels above. The muscle is external to the anterior tibial vessels in the upper part of the leg; but in the lower third its tendon crosses over them, so that it lies internal to them on the dorsum of the foot.

The **Extensor longus digitorum** is an elongated, flattened, penniform muscle, situated the most externally of all the muscles on the fore part of the leg. It arises from the outer tuberosity of the tibia; from the upper three-fourths of the anterior surface of the shaft of the fibula; from the interosseous membrane; from the deep surface of the fascia; and from the intermuscular septa between it and the Tibialis anticus on the inner, and the Peronei on the outer side. The tendon enters a canal in the annular ligament, with the Peroneus tertius, and divides into four slips, which run across the dorsum of the foot, and are inserted into the second and third phalanges of the four lesser toes. The mode in which the tendons are inserted is the following: the three inner tendons opposite the metatarso-phalangeal articulation are joined, on their outer side, by a tendon of the Extensor brevis digitorum. They all receive a fibrous expansion from the Interossei and Lumbricales, and then spread out into a broad aponeurosis, which covers the dorsal surface of the first phalanx: this aponeurosis, at the articulation of the first with the second phalanx, divides into three slips, a middle one, which is inserted into the base of the second phalanx; and two lateral slips, which, after uniting on the dorsal surface of the second phalanx, are continued onwards, to be inserted into the base of the third.



**Relations.**—By its *anterior surface*, with the fascia and the annular ligament. By its *posterior surface*, with the fibula, interosseous membrane, ankle-joint, and Extensor brevis digitorum. By its *inner side*, with the Tibialis anticus, Extensor proprius hallucis, and anterior tibial vessels and nerve. By its *outer side*, with the Peroneus longus and brevis.

The **Peroneus tertius** is a part of the Extensor longus digitorum, and might be described as its fifth tendon. The fibres belonging to this tendon arise from the lower fourth of the anterior surface of the fibula; from the lower part of the interosseous membrane; and from an intermuscular septum between it and the Peroneus brevis. The tendon, after passing through the same canal in the annular ligament as the Extensor longus digitorum, is inserted into the dorsal surface of the base of the metatarsal bone of the little toe, on its inner side. This muscle is sometimes wanting.

**Nerves.**—These muscles are supplied by the anterior tibial nerve.

**Actions.**—The Tibialis anticus and Peroneus tertius are the direct flexors of the tarsus upon the leg; the former muscle, from the obliquity in the direction of its tendon, raises the inner border of the foot; and the latter, acting with the Peroneus brevis and longus, draws the outer border of the foot upwards and the sole outwards. The extensor longus digitorum and Extensor proprius hallucis extend the phalanges of the toes, and, continuing their action, flex the tarsus upon the leg. Taking their fixed point from below, in the erect posture, all these muscles serve to fix the bones of the leg in the perpendicular position, and give increased strength to the ankle-joint.

#### 6. *Posterior Tibio-fibular Region*

*Dissection* (fig. 366).—Make a vertical incision along the middle line of the back of the leg, from the lower part of the popliteal space to the heel, connecting it below by a transverse incision extending between the two malleoli; the flaps of integument being removed, the fascia and muscles should be examined.

The muscles in this region of the leg are subdivided into two layers—superficial and deep. The superficial layer constitutes a powerful muscular mass, forming the calf of the leg. Their large size is one of the most characteristic features of the muscular apparatus in man, and bears a direct connection with his ordinary attitude and mode of progression.

#### *Superficial Layer*

Gastrocnemius.

Soleus.

Plantaris.

The **Gastrocnemius** is the most superficial muscle, and forms the greater part of the calf. It arises by two heads, which are connected to the condyles of the femur by two strong flat tendons. The inner head, the larger, and a little the more posterior, arises from a depression at the upper and back part of the inner condyle. The outer head arises from the upper and back part of the external condyle, immediately above the origin of the Popliteus. Both heads, also, arise by a few tendinous and fleshy fibres from the ridges which are continued upwards from the condyles to the *linea aspera*. Each tendon spreads out into an aponeurosis, which covers the posterior surface of that portion of the muscle to which it belongs; that covering the inner head being longer and thicker than the outer. From the anterior surface of these tendinous expansions, muscular fibres are given off. The fibres in the median line, which correspond to the accessory portions of the muscle derived from the bifurcations of the *linea aspera*, unite at an angle upon a median tendinous raphé below: the remaining fibres converge to the posterior surface of an aponeurosis which covers the anterior surface of the muscle, and this, gradually contracting, unites with the tendon of the Soleus, and forms with it the tendo Achillis.



**Relations.**—By its *superficial surface*, with the fascia of the leg, which separates it from the external saphenous vein and nerve. By its *deep surface*, with the posterior ligament of the knee-joint, the Popliteus, Scieus, Plantaris, popliteal vessels, and internal popliteal nerve. The tendon of the inner head corresponds with the back part of the inner condyle, from which it is separated by a synovial bursa, which, in some cases, communicates with the cavity of the knee-joint. The tendon of the outer head contains a sesamoid fibro-cartilage (rarely osseous), where it plays over the corresponding outer condyle; and one is occasionally found in the tendon of the inner head.

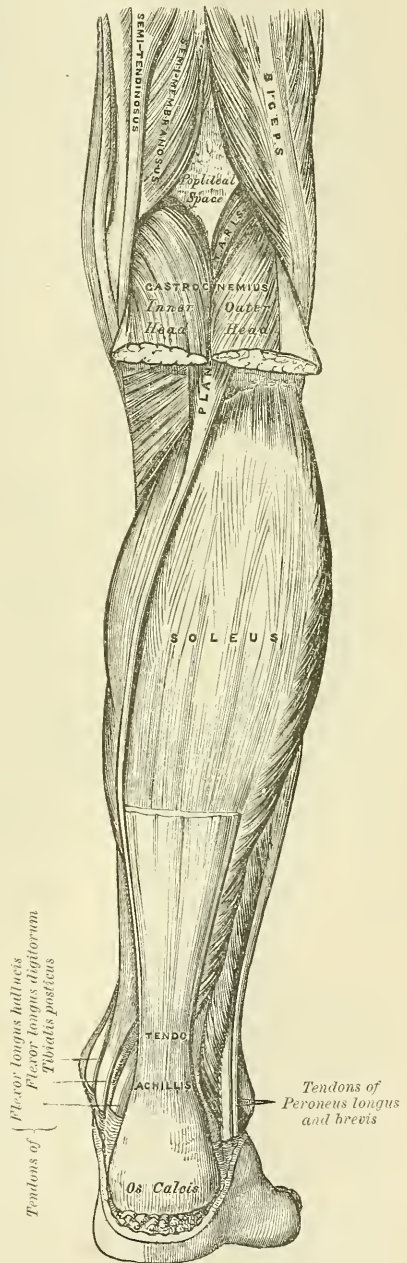
The Gastrocnemius should be divided across, just below its origin, and turned downwards, in order to expose the next muscles.

The **Soleus** is a broad flat muscle situated immediately beneath the Gastrocnemius. It has received its name from its resemblance in shape to a sole-fish. It arises by tendinous fibres from the back part of the head of the fibula, and from the upper third of the posterior surface of its shaft; from the oblique line of the tibia, and from the middle third of its internal border; some fibres also arise from a tendinous arch placed between the tibial and fibular origins of the muscle, beneath which the popliteal vessels and internal popliteal nerve pass. The fibres pass backwards to an aponeurosis which covers the posterior surface of the muscle, and this gradually becoming thicker and narrower, joins with the tendon of the Gastrocnemius, and forms with it the tendo Achillis.

**Relations.**—By its *superficial surface*, with the Gastrocnemius and Plantaris. By its *deep surface*, with the Flexor longus digitorum, Flexor longus hallucis, Tibialis posticus, and posterior tibial vessels and nerve, from which it is separated by the transverse intermuscular septum or deep transverse fascia of the leg.

The **tendo Achillis**, the common tendon of the Gastrocnemius and Soleus,\* is the thickest and strongest tendon in the body. It is about six inches in length, and commences about the middle of the leg, but receives fleshy fibres on its anterior surface, nearly to its lower

FIG. 370.—Muscles of the back of the leg. Superficial layer.



\* These two muscles with a common tendon are by some anatomists classed together as one muscle, the *Triceps suræ*, the two heads of origin of the Gastrocnemius and the Soleus constituting the three heads of the Triceps, and the tendo Achillis the single tendon of insertion.

end. Gradually becoming contracted below, it is inserted into the lower part of the posterior surface of the os calcis, a synovial bursa being interposed between the tendon and the upper part of this surface. The tendon spreads out somewhat at its lower end, so that its narrowest part is usually about an inch and a half above its insertion. The tendon is covered by the fascia and the integument, and is separated from the deep muscles and vessels by a considerable interval filled up with areolar and adipose tissue. Along its outer side, but superficial to it, is the external saphenous vein.

The **Plantaris** is an extremely diminutive muscle, placed between the Gastrocnemius and Soleus, and remarkable for its long and delicate tendon. It arises from the lower part of the outer prolongation of the linea aspera, and from the posterior ligament of the knee-joint. It forms a small fusiform belly, about three or four inches in length, terminating in a long slender tendon which crosses obliquely between the two muscles of the calf, and, running along the inner border of the tendo Achillis, is inserted with it into the posterior part of the os calcis. This muscle is occasionally double, and is sometimes wanting. Occasionally, its tendon is lost in the internal annular ligament, or in the fascia of the leg.

**Nerves.**—These muscles are supplied by the internal popliteal nerve. The Soleus receives an additional branch from the posterior tibial.

**Actions.**—The muscles of the calf possess considerable power, and are constantly called into use in standing, walking, dancing, and leaping; hence the large size they usually present. In walking, these muscles draw powerfully upon the os calcis, raising the heel, and with it the entire body, from the ground; the body being thus supported on the raised foot, the opposite limb can be carried forwards. In standing, the Soleus, taking its fixed point from below, steadies the leg upon the foot, and prevents the body from falling forwards, to which there is a constant tendency from the superincumbent weight. The Gastrocnemius, acting from below, serves to flex the femur upon the tibia, assisted by the Popliteus. The Plantaris is the rudiment of a large muscle which exists in some of the lower animals, and which is continued over the os calcis to be inserted into the plantar fascia. In man it is an accessory to the Gastrocnemius, extending the ankle if the foot is free, or bending the knee if the foot is fixed. Possibly, acting from below, by its attachment to the posterior ligament of the knee-joint, it may pull that ligament backwards during flexion, and so protect it from being compressed between the two articular surfaces.

*Deep Layer (fig. 371)*

Popliteus.

Flexor longus hallucis.

Flexor longus digitorum.

Tibialis posticus.

*Dissection.*—Detach the Soleus from its attachment to the fibula and tibia, and turn downwards, when the deep layer of muscles is exposed, covered by the deep transverse fascia of the leg.

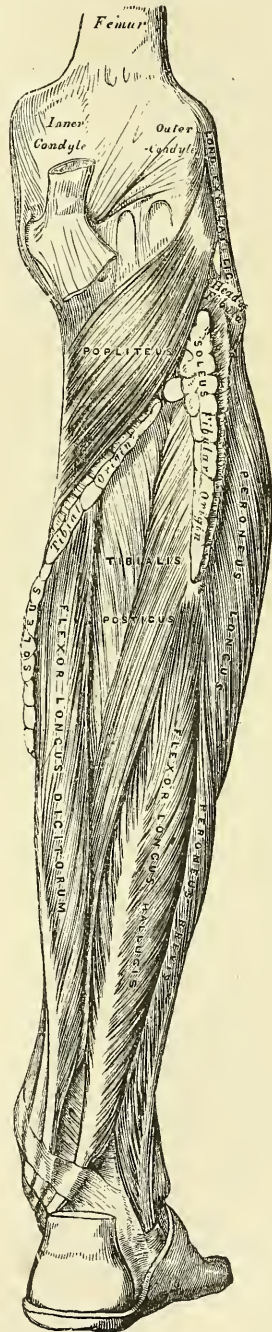
The **Deep Transverse Fascia** of the leg is a broad, transverse, intermuscular septum, interposed between the superficial and deep muscles in the posterior tibio-fibular region. On either side it is connected to the margins of the tibia and fibula. Above, where it covers the Popliteus, it is thick and dense, and receives an expansion from the tendon of the Semimembranosus; it is thinner in the middle of the leg; but below, where it covers the tendons passing behind the malleoli, it is thickened. It is continued onwards in the interval between the ankle and the heel, where it covers the vessels, and is blended with the internal annular ligament.

This fascia should now be removed, commencing from below opposite the tendons, and detaching it from the muscles in the direction of their fibres.



The **Popliteus** is a thin, flat, triangular muscle, which forms part of the floor of the popliteal space. It arises by a strong tendon about an inch in length, from a deep depression on the outer side of the external condyle of the femur and from the posterior ligament of the knee-joint; and is inserted into the inner two-thirds of the triangular surface above the oblique line on the posterior surface of the shaft of the tibia, and into the tendinous expansion covering the surface of the muscle. The tendon of the muscle is covered by that of the Biceps and the external lateral ligament of the knee-joint; it grooves the outer border of the external semilunar fibro-cartilage, and is invested by the synovial membrane of the knee-joint.

FIG. 371.—Muscles of the back of the leg. Deep layer.



**Relations.**—By its *superficial surface*, with the fascia covering it, which separates it from the Gastrocnemius, Plantaris, popliteal vessels, and internal popliteal nerve. By its *deep surface*, with the superior tibio-fibular articulation and back of the tibia.

The **Flexor longus hallucis** is situated on the fibular side of the leg, and is the most superficial and largest of the three next muscles. It arises from the lower two-thirds of the posterior surface of the shaft of the fibula, with the exception of an inch at its lowest part; from the lower part of the interosseous membrane; from an intermuscular septum between it and the Peronei, externally; and from the fascia covering the Tibialis posticus internally. The fibres pass obliquely downwards and backwards, and terminate in a tendon which occupies nearly the whole length of the posterior surface of the muscle. This tendon passes through a groove on the posterior surface of the tibia; it then passes through another groove on the posterior surface of the astragalus, and along a third groove, beneath the sustentaculum tali of the os calcis, into the sole of the foot, where it runs forwards between the two heads of the Flexor brevis hallucis, and is inserted into the base of the last phalanx of the great toe. The grooves in the astragalus and os calcis, which contain the tendon of the muscle, are converted by tendinous fibres into distinct canals, lined by synovial membrane; and as the tendon crosses the sole of the foot, it is connected to the common flexor by a tendinous slip.

**Relations.**—By its *superficial surface*, with the Soleus and tendo Achillis, from which it is separated by the deep transverse fascia. By its *deep surface*, with the fibula, Tibialis posticus, the peroneal vessels, the lower part of the interosseous membrane, and the ankle-joint. By its *outer border*, with the Peronei. By its *inner border*, with the Tibialis posticus, and posterior tibial vessels and nerve.



The **Flexor longus digitorum** (*perforans*) is situated on the tibial side of the leg. At its origin it is thin and pointed, but gradually increases in size as it descends. It arises from the posterior surface of the shaft of the tibia immediately below the oblique line, to within three inches of its extremity, internal to the tibial origin of the Tibialis posticus; some fibres also arise from the fascia covering the Tibialis posticus. The fibres terminate in a tendon, which runs nearly the whole length of the posterior surface of the muscle. This tendon passes behind the internal malleolus, in a groove, common to it and the Tibialis posticus, but separated from the latter by a fibrous septum; each tendon being contained in a special sheath lined by a separate synovial membrane. It then passes obliquely forwards and outwards, crossing over the internal lateral ligament into the sole of the foot (fig. 373), where, crossing superficially to the tendon of the Flexor longus hallucis,\* to which it is connected by a strong tendinous slip, it becomes expanded, is joined by the Flexor accessorius, and finally divides into four tendons, which are inserted into the bases of the last phalanges of the four lesser toes, each tendon passing through a fissure in the tendon of the Flexor brevis digitorum opposite the bases of the first phalanges.

**Relations.**—*In the leg:* by its *superficial surface*, with the posterior tibial vessels and nerve, and the deep transverse fascia, which separates it from the Soleus muscle; by its *deep surface*, with the tibia and Tibialis posticus. *In the foot*, it is covered by the Abductor hallucis and Flexor brevis digitorum, and crosses superficial to the Flexor longus hallucis.

The **Tibialis posticus** lies between the two preceding muscles, and is the most deeply seated of all the muscles in the leg. It commences above by two pointed processes, separated by an angular interval, through which the anterior tibial vessels pass forwards to the front of the leg. It arises from the whole of the posterior surface of the interosseous membrane, excepting its lowest part; from the outer portion of the posterior surface of the shaft of the tibia, between the commencement of the oblique line above and the junction of the middle and lower third of the shaft below; and from the upper two-thirds of the internal surface of the fibula; some fibres also arise from the deep transverse fascia, and from the intermuscular septa separating it from the adjacent muscles on each side. This muscle, in the lower fourth of the leg, passes in front of the Flexor longus digitorum, and terminates in a tendon, which passes through a groove behind the inner malleolus, with the tendon of that muscle, but enclosed in a separate sheath; it then passes through another sheath, over the internal lateral ligament into the foot, and then beneath the inferior calcaneo-navicular ligament, and is inserted into the tuberosity of the navicular and internal cuneiform bones. The tendon of this muscle contains a sesamoid fibro-cartilage, as it passes over the navicular bone, and gives off fibrous expansions, one of which passes backwards to the sustentaculum tali of the os calcis, others outwards to the middle and external cuneiform and cuboid, and some forwards to the bases of the second, third, and fourth metatarsal bones (fig. 374).

**Relations.**—By its *superficial surface*, with the Soleus, from which it is separated by the deep transverse fascia, the Flexor longus digitorum, the posterior tibial vessels and nerve, and the peroneal vessels. By its *deep surface*, with the interosseous ligament, the tibia, fibula, and ankle-joint.

**Nerves.**—The Popliteus is supplied by the internal popliteal nerve, the remaining muscles of this group by the posterior tibial nerve.

**Actions.**—The Popliteus assists in flexing the leg upon the thigh; when the leg is flexed, it will rotate the tibia inwards. It is especially called into action at the commencement of the act of bending the knee, inasmuch as it produces a slight inward rotation of the tibia, which is essential in the early stage of this movement. The Tibialis posticus is a direct extensor of the tarsus upon the leg; acting in conjunction with the Tibialis anticus, it turns the sole of the foot inwards,

\* That is, in the order of dissection of the sole of the foot.

antagonising the Peroneus longus, which turns it outwards. The Flexor longus digitorum and Flexor longus hallucis are the direct flexors of the phalanges, and, continuing their action, extend the foot upon the leg; they assist the Gastrocnemius and Soleus in extending the foot, as in the act of walking, or in standing on tiptoe. In consequence of the oblique direction of the tendon of the long flexor, the toes would be drawn inwards, were it not for the Flexor accessorius muscle, which is inserted into the outer side of its tendon, and draws it to the middle line of the foot during its action. Taking their fixed point from the foot, these muscles serve to maintain the upright posture by steadying the tibia and fibula, perpendicularly, upon the ankle-joint. They also serve to raise these bones from the oblique position they assume in the stooping posture.

### 7. Outer or Fibular Region

Peroneus longus.

Peroneus brevis.

*Dissection.*—The muscles are readily exposed, by removing the fascia covering their surface, from below upwards, in the line of direction of their fibres.

The **Peroneus longus** is situated at the upper part of the outer side of the leg, and is the more superficial of the two muscles. It arises from the head and upper two-thirds of the outer surface of the shaft of the fibula, from the deep surface of the fascia, and from the intermuscular septa, between it and the muscles on the front, and those on the back of the leg: occasionally also by a few fibres from the outer tuberosity of the tibia. Between its attachment to the head and to the shaft of the fibula there is a small interval of bone from which no muscular fibres arise; through this gap the external popliteal nerve passes beneath the muscle. It terminates in a long tendon, which passes behind the outer malleolus, in a groove common to it and the Peroneus brevis, the groove being converted into a canal by a fibrous band, and the tendons invested by a common synovial membrane; it is then reflected, obliquely forwards, across the outer side of the os calcis, being contained in a separate fibrous sheath, lined by a prolongation of the synovial membrane from that which lines the groove behind the malleolus. Having reached the outer side of the cuboid bone, it runs in a groove on the under surface of that bone, which is converted into a canal by the long calcaneo-cuboid ligament, and is lined by a synovial membrane: the tendon thus crosses obliquely the sole of the foot, and is inserted into the outer side of the base of the metatarsal bone of the great toe and the internal cuneiform bone. Occasionally it sends a slip to the base of the second metatarsal bone. The tendon changes its direction at two points: first, behind the external malleolus; secondly, on the outer side of the cuboid bone; in both of these situations the tendon is thickened, and, in the latter, a sesamoid fibro-cartilage, or sometimes a bone, is usually developed in its substance.

**Relations.**—By its *superficial surface*, with the fascia and integument; by its *deep surface*, with the fibula, external popliteal nerve, the Peroneus brevis, os calcis, and cuboid bone; by its *anterior border*, with an intermuscular septum, which intervenes between it and the Extensor longus digitorum; by its *posterior border*, with an intermuscular septum, which separates it from the Soleus above and the Flexor longus hallucis below.

The **Peroneus brevis** lies beneath the Peroneus longus, and is shorter and smaller than it. It arises from the lower two-thirds of the external surface of the shaft of the fibula, internal to the Peroneus longus; and from the intermuscular septa, separating it from the adjacent muscles on the front and back part of the leg. The fibres pass vertically downwards, and terminate in a tendon, which runs in front of that of the preceding muscle, through the same groove behind the external malleolus, being contained in the same fibrous sheath, and lubricated by the same synovial membrane. It then passes through a separate sheath on the outer side of the os calcis, above that for the tendon of the Peroneus longus;

and is finally inserted into the tuberosity at the base of the metatarsal bone of the little toe, on its outer side.

**Relations.**—By its *superficial surface*, with the Peroneus longus and the fascia of the leg and foot. By its *deep surface*, with the fibula and outer side of the os calcis.

**Nerves.**—The Peroneus longus and brevis are supplied by the musculocutaneous branch of the external popliteal nerve.

**Actions.**—The Peroneus longus and brevis extend the foot upon the leg, in conjunction with the Tibialis posticus, antagonising the Tibialis anticus and Peroneus tertius, which are flexors of the foot. The Peroneus longus also everts the sole of the foot; hence the extreme eversion occasionally observed in fracture of the lower end of the fibula, where that bone offers no resistance to the action of this muscle. Taking their fixed point below, the Peronei serve to steady the leg upon the foot. This is especially the case in standing upon one leg, when the tendency of the superincumbent weight is to throw the leg inwards: the Peroneus longus overcomes this tendency by drawing on the outer side of the leg, and thus maintains the perpendicular direction of the limb.

*Surgical Anatomy.*—The student should now consider the position of the tendons of the various muscles of the leg, their relation with the ankle-joint and surrounding blood-vessels, and especially their action upon the foot, as their rigidity and contraction give rise to one or other of the kinds of deformity known as *club foot*. The most simple and common deformity, and one that is rarely, if ever, congenital, is the *talipes equinus*, the heel being raised by rigidity and contraction of the Gastrocnemius muscle, and the patient walking upon the ball of the foot. In the *talipes varus*, the foot is forcibly adducted and the inner side of the sole raised, sometimes to a right angle with the ground, by the action of the Tibialis anticus and posticus. In the *talipes valgus*, the outer edge of the foot is raised by the Peronei muscles, and the patient walks on the inner ankle. In the *talipes calcaneus* the toes are raised by the Extensor muscles, the heel is depressed and the patient walks upon it. Other varieties of deformity are met with, as the *talipes equino-varus*, *equino-valgus*, and *calcaneo-valgus*, whose names sufficiently indicate their nature. Of these, the talipes equino-varus is the most common congenital form; the heel is raised by the tendo Achillis, the inner border of the foot drawn upwards by the Tibialis anticus, the anterior two-thirds twisted inwards by the Tibialis posticus, and the arch increased by the contraction of the plantar fascia, so that the patient walks on the middle of the outer border of the foot. Each of these deformities may sometimes be successfully relieved by division of the opposing tendons and fascia: by this means the foot regains its proper position, and the tendons heal by the organisation of lymph thrown out between the divided ends. The operation is easily performed by putting the contracted tendon upon the stretch, and dividing it by means of a narrow, sharp pointed knife inserted beneath it.

Rupture of a few of the fibres of the Gastrocnemius, or rupture of the Plantaris tendon not uncommonly occurs, especially in men somewhat advanced in life, from some sudden exertion, and frequently occurs during the game of lawn tennis, and is hence known as 'lawn-tennis leg.' The accident is accompanied by a sudden pain, and produces a sensation as if the individual had been struck a violent blow on the part. The tendo Achillis is also sometimes ruptured. It is stated that John Hunter ruptured his tendo Achillis whilst dancing, at the age of forty.

#### IV. MUSCLES AND FASCIÆ OF THE FOOT

The fibrous bands which bind down the tendons in front of and behind the ankle in their passage to the foot should now be examined; they are termed the *annular ligaments*, and are three in number—anterior, internal, and external.

The **anterior annular ligament** consists of a superior or vertical portion, which binds down the extensor tendons as they descend on the front of the tibia and fibula; and an inferior or horizontal portion, which retains them in connection with the tarsus, the two portions being connected by a thin intervening layer of fascia. The vertical portion is attached externally to the lower end of the fibula and internally to the tibia; above it is continuous with the fascia of the leg; it contains only one synovial sheath, for the tendon of the Tibialis anticus; the other tendons and the anterior tibial vessels and nerve passing beneath it, but without any distinct synovial sheath. The horizontal portion is



attached externally to the upper surface of the os calcis, in front of the depressor for the interosseous ligament; it passes upwards and inwards, as a double layer one lamina passing in front, and the other behind, the tendons of the Peroneus tertius and Extensor longus digitorum. At the inner border of the latter tendon these two layers join together, forming a sort of loop or sheath in which the tendons are enclosed, surrounded by a synovial membrane. From the inner extremity of this loop two bands are given off: one passes upwards and inwards, to be attached to the internal malleolus, passing over the Extensor proprius hallucis and vessels and nerves, but enclosing the Tibialis anticus and its synovial sheath by a splitting of its fibres. The other limb passes downwards and inwards to be attached to the inner border of the plantar fascia, and passes over both the tendon of the Extensor proprius hallucis and the Tibialis anticus and also the vessels and nerves. These two tendons are contained in separate synovial sheaths situated beneath the ligament. It will thus be seen that the horizontal portion of the ligament is like the letter Y, the foot of the letter being attached to the os calcis, and the two diverging arms to the tibia and plantar fascia respectively.

The **internal annular ligament** is a strong fibrous band, which extends from the inner malleolus above to the internal margin of the os calcis below, converting a series of grooves in this situation into canals, for the passage of the tendons of the Flexor muscles and vessels into the sole of the foot. It is continuous by its upper border with the deep fascia of the leg, and by its lower border with the plantar fascia and the fibres of origin of the Abductor hallucis muscle. The four canals which it forms transmit, from within outwards, first, the tendon of the Tibialis posticus; second, the tendon of the Flexor longus digitorum; third, the posterior tibial vessels and nerve, which run through a broad space beneath the ligament; lastly, in a canal formed partly by the astragalus, the tendon of the Flexor longus hallucis. The canals for the tendons are lined by separate synovial membranes.

The **external annular ligament** extends from the extremity of the outer malleolus to the outer surface of the os calcis: it binds down the tendons of the Peronei muscles in their passage beneath the outer ankle. The two tendons are enclosed in one synovial sac.

*Dissection of the Sole of the Foot.*—The foot should be placed on a high block with the sole uppermost, and firmly secured in that position. Carry an incision round the heel and along the inner and outer borders of the foot to the great and little toes. This incision should divide the integument and thick layer of granular fat beneath, until the fascia is visible; the skin and fat should then be removed from the fascia in a direction from behind forwards, as seen in fig. 366.

The **plantar fascia**, the densest of all the fibrous membranes, is of great strength, and consists of dense pearly-white glistening fibres, disposed, for the most part, longitudinally: it is divided into a central and two lateral portions.

The *central portion*, the thickest, is narrow behind and attached to the inner tubercle of the os calcis, behind the origin of the Flexor brevis digitorum; and becoming broader and thinner in front, divides near the heads of the metatarsal bones into five processes, one for each of the toes. Each of these processes divides opposite the metatarso-phalangeal articulation into two strata, superficial and deep. The superficial stratum is inserted into the skin of the transverse sulcus which divides the toes from the sole. The deeper stratum divides into two slips which embrace the sides of the flexor tendons of the toes, and blend with the sheaths of the tendons and laterally with the transverse metatarsal ligament, thus forming a series of arches through which the tendons of the short and long flexors pass to the toes. The intervals left between the five processes allow the digital vessels and nerves, and the tendons of the Lumbricales muscles, to become superficial. At the point of division of the fascia into processes and slips, numerous transverse fibres are superadded, which serve to increase the strength of the fascia at this part by binding the processes together, and

connecting them with the integument. The central portion of the plantar fascia is continuous with the lateral portions at each side, and sends upwards into the foot, at their point of junction, two strong vertical intermuscular septa, broader in front than behind, which separate the middle from the external and internal plantar group of muscles; from these again thinner transverse septa are derived, which separate the various layers of muscles in this region. The upper surface of this fascia gives attachment behind to the Flexor brevis digitorum muscle.

The *lateral portions* of the plantar fascia are thinner than the central piece, and cover the sides of the foot.

The *outer portion* covers the under surface of the Abductor minimi digiti; it is thick behind, thin in front, and extends from the outer tubercle of the os calcis, forwards, to the base of the fifth metatarsal bone, into the outer side of which it is attached; it is continuous internally with the middle portion of the plantar fascia, and externally with the dorsal fascia.

The *inner portion* is very thin, and covers the Abductor hallucis muscle; it is attached behind to the internal annular ligament, and is continuous around the side of the foot with the dorsal fascia, and externally with the middle portion of the plantar fascia.

### 8. Dorsal Region

#### Extensor brevis digitorum.

The *fascia* on the dorsum of the foot is a thin membranous layer, continuous above with the anterior margin of the annular ligament; it becomes gradually lost opposite the heads of the metatarsal bones, and on each side blends with the lateral portions of the plantar fascia; it forms a sheath for the tendons placed on the dorsum of the foot. On the removal of this fascia, the muscle and tendons of the dorsal region of the foot are exposed.

The **Extensor brevis digitorum** (fig. 369) is a broad thin muscle, which arises from the fore part of the upper and outer surfaces of the os calcis, in front of the groove for the Peroneus brevis; from the external calcaneo-astragaloid ligament; and from the horizontal portion of the anterior annular ligament. It passes obliquely across the dorsum of the foot, and terminates in four tendons. The innermost, which is the largest, is inserted into the dorsal surface of the base of the first phalanx of the great toe, crossing the Dorsalis pedis artery; the other three, into the outer sides of the long extensor tendons of the second, third, and fourth toes.

**Relations.**—By its *superficial surface*, with the fascia of the foot, the tendons of the Extensor longus digitorum and Peroneus tertius. By its *deep surface*, with the tarsal and metatarsal bones, and the Dorsal interossei muscles.

**Nerves.**—It is supplied by the anterior tibial nerve.

**Actions.**—The Extensor brevis digitorum is an accessory to the long Extensor, extending the phalanges of the four inner toes, but acting only on the first phalanx of the great toe. The obliquity of its direction counteracts the oblique movement given to the toes by the long Extensor, so that, both muscles acting together, the toes are evenly extended.

### 9. Plantar Region

The muscles in the plantar region of the foot may be divided into three groups, in a similar manner to those in the hand. Those of the internal plantar region are connected with the great toe, and correspond with those of the thumb; those of the external plantar region are connected with the little toe, and correspond with those of the little finger; and those of the middle plantar region are connected with the tendons intervening between the two former groups. But in order to facilitate the dissection of these muscles, it will be found more convenient to divide them into four layers, as they present themselves, in the order in which they are successively exposed.

*First Layer*

Abductor hallucis.

Flexor brevis digitorum.

Abductor minimi digiti.

*Dissection.*—Remove the fascia on the inner and outer sides of the foot, commencing in front over the tendons, and proceeding backwards. The central portion should be divided transversely in the middle of the foot, and the two flaps dissected forwards and backwards.

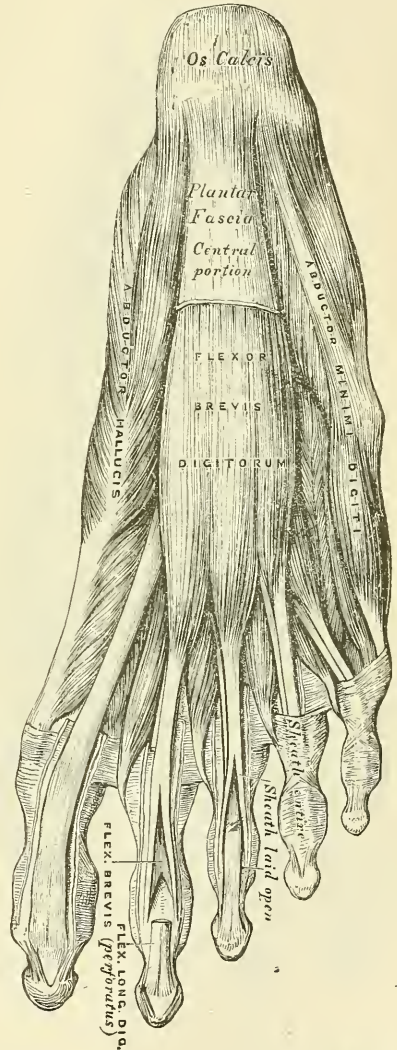
The **Abductor hallucis** lies along the inner border of the foot. It arises from the inner tubercle on the under surface of the os calcis; from the internal annular ligament; from the plantar fascia; and from the intermuscular septum between it and the Flexor brevis digitorum. The fibres terminate in a tendon, which is inserted, together with the innermost tendon of the Flexor brevis hallucis, into the inner side of the base of the first phalanx of the great toe.

**Relations.**—By its *superficial surface*, with the plantar fascia. By its *deep surface*, with the Flexor brevis hallucis, the Flexor accessorius, and the tendons of the Flexor longus digitorum and Flexor longus hallucis, the Tibialis anticus and posticus, the plantar vessels and nerves, and the articulations of the tarsus.

The **Flexor brevis digitorum** (*perforatus*) lies in the middle of the sole of the foot, immediately beneath\* the plantar fascia, with which it is firmly united. It arises by a narrow tendinous process, from the inner tubercle of the os calcis, from the central part of the plantar fascia, and from the intermuscular septa between it and the adjacent muscles. It passes forwards, and divides into four tendons. Opposite the bases of the first phalanges, each tendon divides into two slips, to allow of the passage of the corresponding tendon of the Flexor longus digitorum; the two portions of the tendon then unite and form a grooved channel for the reception of the accompanying long flexor tendon. Finally, they divide a second time, to be inserted into the sides of the second phalanges about their middle. The mode of division of the tendons of the Flexor brevis digitorum, and their insertion into the phalanges, is analogous to the Flexor sublimis digitorum in the hand.

**Relations.**—By its *superficial surface*, with the plantar fascia. By its *deep surface*, with the Flexor accessorius, the Lumbricales, the tendons of the Flexor longus digitorum, and the external plantar vessels and nerve, from which it is separated by a thin layer of fascia. The *outer* and *inner borders* are separated

FIG. 372.—Muscles of the sole of the foot. First layer.



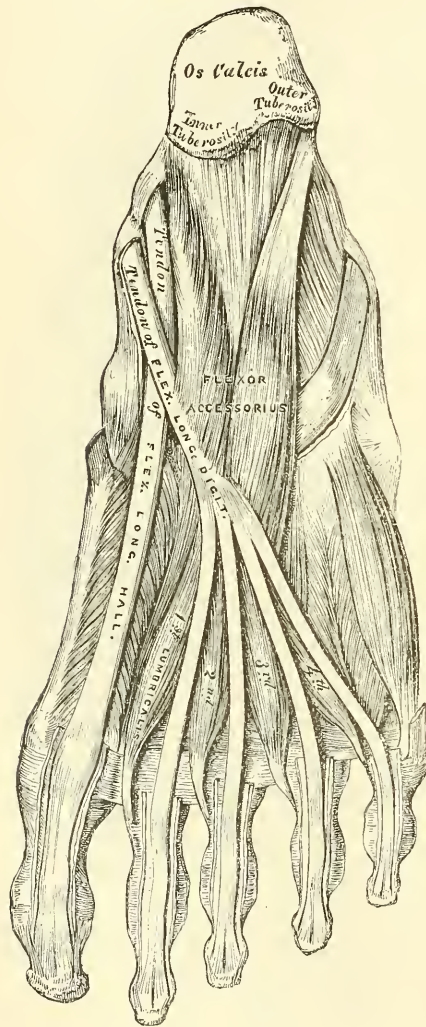
\* That is, in the order of dissection of the sole of the foot.



from the adjacent muscles by means of vertical prolongations of the plantar fascia.

**Fibrous sheaths of the flexor tendons.**—These are not so well marked as in the fingers. The flexor tendons of the toes as they run along the phalanges are retained against the bones by a fibrous sheath, forming osseo-aponeurotic canals. These sheaths are formed by strong fibrous bands, which arch across the tendons, and are attached on each side to the margins of the phalanges. Opposite the

FIG. 373.—Muscles of the sole of the foot.  
Second layer.



middle of the proximal and second phalanges the sheath is very strong, and the fibres pass transversely; but opposite the joints it is much thinner, and the fibres pass obliquely. Each sheath is lined by a synovial membrane, which is reflected on the contained tendon.

The **Abductor minimi digiti** lies along the outer border of the foot. It arises, by a very broad origin, from the outer tubercle of the os calcis, from the under surface of the os calcis in front of both tubercles, from the fore part of the inner tubercle, from the plantar fascia, and the intermuscular septum between it and the Flexor brevis digitorum. Its tendon, after gliding over a smooth facet on the under surface of the base of the fifth metatarsal bone, is inserted, with the short Flexor of the little toe, into the outer side of the base of the first phalanx of this toe.

**Relations.**—By its *superficial surface*, with the plantar fascia. By its *deep surface*, with the Flexor accessorius, the Flexor brevis minimi digiti, the long plantar ligament, and the tendon of the Peroneus longus. On its *inner side* are the external plantar vessels and nerve, and it is separated from the Flexor brevis digitorum by a vertical septum of fascia.

**Dissection.**—The muscles of the superficial layer should be divided at their origin, by inserting the knife beneath each, and cutting obliquely backwards, so as to detach them from the bone; they should then be drawn forwards, in order to expose the second layer, but not cut away at their insertion. The two layers are separated by a thin membrane, the *deep plantar fascia*, on the removal of which is seen the tendon of the Flexor longus digitorum, the Flexor acces-

#### Second Layer

Flexor accessorius.

Lumbricales.

The **Flexor accessorius** arises by two heads: the inner or larger, which is muscular, being attached to the inner concave surface of the os calcis, and to the inferior calcaneo-navicular ligament; the outer head, flat and tendinous, to

the under surface of the os calcis, in front of its outer tubercle, and to the long plantar ligament: the two portions join at an acute angle, and are inserted into the outer margin and upper and under surfaces of the tendon of the Flexor longus digitorum, forming a kind of groove, in which the tendon is lodged.\*

**Relations.**—By its *superficial surface*, with the muscles of the superficial layer, from which it is separated by the external plantar vessels and nerves. By its *deep surface*, with the os calcis, and long calcaneo-cuboid ligament.

The **Lumbricales** are four small muscles, accessory to the tendons of the Flexor longus digitorum: they arise from the tendons of the long flexor, as far back as their angle of division, each arising from two tendons, except the internal one. Each muscle terminates in a tendon, which passes forwards on the inner side of each of the lesser toes, and is inserted into the expansion of the long extensor tendon on the dorsum of the first phalanx of the corresponding toe.

**Dissection.**—The flexor tendons should be divided at the back part of the foot, and the Flexor accessorius at its origin, and drawn forwards, in order to expose the third layer.

### Third Layer

- Flexor brevis hallucis.
- Adductor obliquus hallucis.
- Flexor brevis minimi digiti.
- Adductor transversus hallucis.

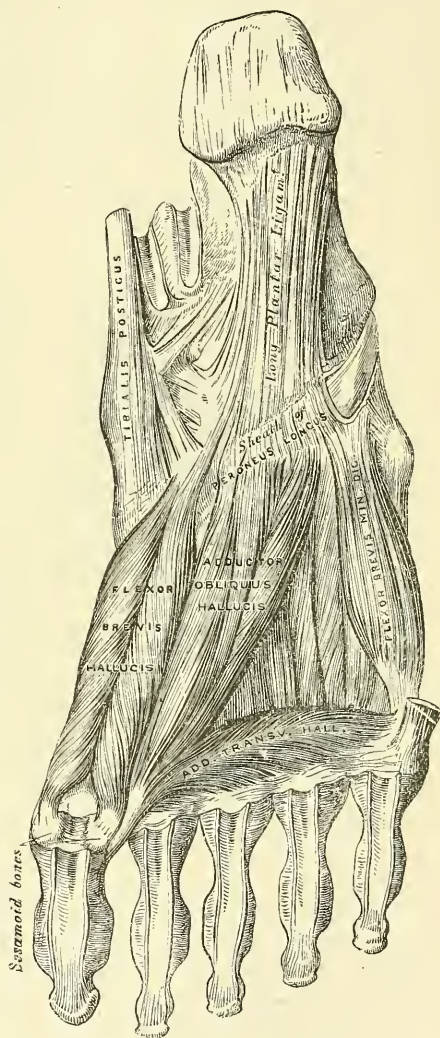The **Flexor brevis hallucis** arises, by a pointed tendinous process, from the inner part of the under surface of the cuboid bone, from the contiguous portion of the external cuneiform, and from the prolongation of the tendon of the Tibialis posticus, which is attached to that bone. The muscle divides, in front, into two portions, which are inserted into the inner and outer sides of the base of the first phalanx of the great toe, a sesamoid bone being developed in each tendon at its insertion. The inner portion of this muscle is blended with the Abductor hallucis previous to its insertion, the outer with the Adductor obliquus hallucis, and the tendon of the Flexor longus hallucis lies in a groove between them.

**Relations.**—By its *superficial surface*, with the Abductor hallucis, the tendon of the Flexor longus hallucis, and plantar fascia. By its *deep surface*, with the tendon of the Peroneus longus, and metatarsal bone of the great toe. By its *inner border*, with the Abductor hallucis. By its *outer border*, with the Adductor obliquus hallucis.

The **Adductor obliquus hallucis** is a large, thick, fleshy mass, passing obliquely across the foot, and occupying the hollow space between the four

\* According to Turner, the fibres of the Flexor accessorius end in aponeurotic bands, which contribute slips to the second, third, and fourth digits.

FIG. 374.—Muscles of the sole of the foot. Third layer.



inner metatarsal bones. It arises from the tarsal extremities of the second, third, and fourth metatarsal bones, and from the sheath of the tendon of the Peroneus longus, and is inserted, together with the outer portion of the Flexor brevis hallucis, into the outer side of the base of the first phalanx of the great toe.

The small muscles of the great toe, the Abductor, Flexor brevis, Adductor obliquus, and Adductor transversus, like the similar muscles of the thumb, give off fibrous expansions, at their insertions, to blend with the long Extensor tendon.

The **Flexor brevis minimi digiti** lies on the metatarsal bone of the little toe, and much resembles one of the Interossei. It arises from the base of the metatarsal bone of the little toe, and from the sheath of the Peroneus longus; its tendon is inserted into the base of the first phalanx of the little toe on its outer side. Occasionally some of the deeper fibres of the muscle are inserted into the outer part of the distal half of the fifth metatarsal bone; these are described by some as a distinct muscle, the Opponens minimi digiti.

**Relations.**—By its *superficial surface*, with the plantar fascia and tendon of the Abductor minimi digiti. By its *deep surface*, with the fifth metatarsal bone.

FIG. 375.—The Dorsal interossei.  
Left foot.

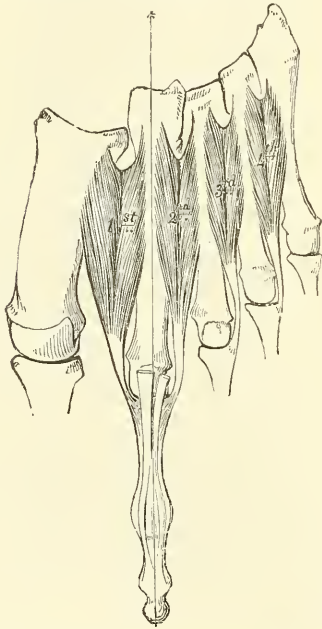
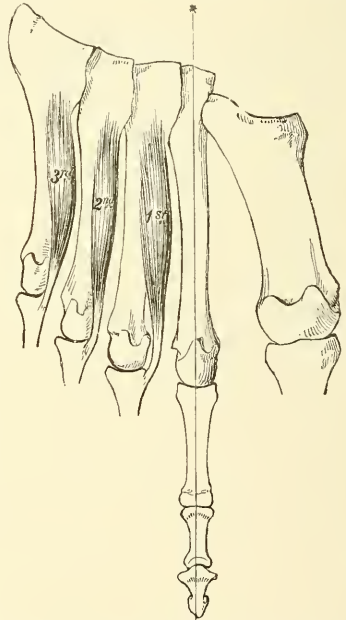


FIG. 376.—The Plantar interossei.  
Left foot.



The **Adductor transversus hallucis** (*Transversus pedis*) is a narrow, flat, muscular fasciculus, stretched transversely across the heads of the metatarsal bones, between them and the flexor tendons. It arises from the inferior metatarsophalangeal ligaments of the three outer toes, sometimes only from the third and fourth, and from the transverse ligament of the metatarsus; and is inserted into the outer side of the first phalanx of the great toe; its fibres being blended with the tendon of insertion of the Adductor obliquus hallucis.

**Relations.**—By its *superficial surface*, with the tendons of the long and short Flexors and Lumbricales. By its *deep surface*, with the Interossei.

#### *Fourth Layer*

#### The Interossei.

The **Interossei muscles** in the foot are similar to those in the hand, with this exception, that they are grouped around the middle line of the *second* toe, instead



of the middle line of the *third* finger, as in the hand. They are seven in number, and consist of two groups, dorsal and plantar.

The **Dorsal interossei**, four in number, are situated between the metatarsal bones. They are bipenniform muscles, arising by two heads from the adjacent sides of the metatarsal bones between which they are placed; their tendons are inserted into the bases of the first phalanges, and into the aponeurosis of the common extensor tendon. In the angular interval left between the heads of each muscle at its posterior extremity the perforating arteries pass to the dorsum of the foot; except in the First interosseous muscle, where the interval allows the passage of the communicating branch of the dorsalis pedis artery. The First dorsal interosseous muscle is inserted into the inner side of the second toe; the other three are inserted into the outer sides of the second, third, and fourth toes.

The **Plantar interossei**, three in number, lie beneath, rather than between, the metatarsal bones. They are single muscles, and are each connected with but one metatarsal bone. They arise from the base and inner sides of the shaft of the third, fourth, and fifth metatarsal bones, and are inserted into the inner sides of the bases of the first phalanges of the same toes, and into the aponeurosis of the common extensor tendon.

**Nerves.**—The Flexor brevis digitorum, the Flexor brevis and Abductor hallucis, and the inner Lumbrical\* are supplied by the internal plantar nerve. All the other muscles in the sole of the foot by the external plantar. The First and Second dorsal interossei muscles receive extra filaments from the ganglionic enlargement of the anterior tibial nerve on the dorsum of the foot.

**Actions.**—All the muscles of the foot act upon the toes, and for purposes of description as regards their action may be grouped as Abductors, Adductors, Flexors or Extensors. The *Abductors* are the Dorsal interossei, the Abductor hallucis, and the Abductor minimi digiti. The Dorsal interossei are abductors from an imaginary line passing through the axis of the second toe, so that the first muscle draws the second toe inwards, towards the great toe; the second muscle draws the same toe outwards; the third draws the third toe, and the fourth draws the fourth toe in the same direction. Like the interossei in the hand, they also assist in flexing the proximal phalanx and extending the two terminal phalanges. The Abductor hallucis abducts the great toe from the others, and also flexes the proximal phalanx of this toe. And in the same way the action of the Abductor minimi digiti is twofold, as an abductor of this toe from the others, and also as a flexor of the proximal phalanx. The *Adductors* are the Plantar interossei, the Adductor obliquus hallucis, and the Adductor transversus hallucis. The plantar interosseous muscles adduct the third, fourth, and fifth toes, towards the imaginary line passing through the second toe, and by means of their insertion into the aponeurosis of the extensor tendon they assist in flexing the proximal phalanx and extending the two terminal phalanges. The Adductor obliquus hallucis is chiefly concerned in adducting the great toe towards the second one, but also assists in flexing this toe. The Adductor transversus hallucis approximates all the toes and thus increases the curve of the transverse arch of the metatarsus. The *Flexors* are the Flexor brevis digitorum, the Flexor accessorius, the Flexor brevis hallucis, the Flexor brevis minimi digiti, and the Lumbricales. The Flexor brevis digitorum flexes the second phalanges upon the first, and, continuing its action, flexes the first phalanges also, and brings the toes together. The Flexor accessorius assists the long flexor of the toes and converts the oblique pull of the tendons of that muscle into a direct backward pull upon the toes. The Flexor brevis minimi

\* Formerly the two inner Lumbricales were described as being supplied by the internal plantar nerve. Brook, however (*Journal of Anatomy*, vol. xxi. p. 575), in ten dissections found that in nine of them only the inner Lumbrical obtained its nerve supply from this source. In the tenth instance both the first and second Lumbricales were supplied by both external and internal plantar.

digiti flexes the little toe and draws its metatarsal bone downwards and inwards. The Lumbricales, like the corresponding muscles in the hand, assist in flexing the proximal phalanx, and by their insertion into the long extensor tendon aid that muscle in straightening the two terminal phalanges. The only muscle in the *Extensor* group is the *Extensor brevis digitorum*. It extends the first phalanx of the great toe and assists the long extensor in extending the next three toes, and at the same time gives to the toes an outward direction when they are extended.

*Surface Form.*—Of the muscles of the thigh, those of the iliac region have no influence on surface form, while those of the anterior femoral region, being to a great extent superficial, largely contribute to the surface form of this part of the body. The *Tensor vaginæ femoris* produces a broad elevation immediately below the anterior portion of the crest of the ilium and behind the anterior superior spinous process. From its lower border, a longitudinal groove, corresponding to the ilio-tibial band, may be seen running down the outer side of the thigh to the outer side of the knee-joint. The *Sartorius* muscle, when it is brought into action by flexing the leg on the thigh, and the thigh on the pelvis, and rotating the thigh outwards, presents a well-marked surface form. At its upper part, where it constitutes the outer boundary of Scarpa's triangle, it forms a prominent oblique ridge, which becomes changed into a flattened plane below, and this gradually merges in a general fulness on the inner side of the knee-joint. When the *Sartorius* is not in action, a depression exists between the *Extensor quadriceps* and the *Adductor* muscles, running obliquely downwards and inwards from the apex of Scarpa's triangle to the inner side of the knee, which corresponds to this muscle. In the depressed angle formed by the divergence of the *Sartorius* and *Tensor vaginæ femoris* muscles, just below the anterior superior spinous process of the ilium, the *Rectus femoris* muscle appears, and, below this, determines to a great extent the convex form of the front of the thigh. In a well-developed subject, the borders of the muscle, when in action, are clearly to be defined. The *Vastus externus* forms a long flattened plane on the outer side of the thigh, traversed by the longitudinal groove formed by the ilio-tibial band. The *Vastus internus*, on the inner side of the lower half of the thigh, gives rise to a considerable prominence, which increases towards the knee and terminates somewhat abruptly in this situation with a full, curved outline. The *Crureus* and *Subcrureus* are completely hidden, and do not directly influence surface form. The *Adductor* muscles, constituting the internal femoral group, are not to be individually distinguished from each other, with the exception of the upper tendon of the *Adductor longus* and the lower tendon of the *Adductor magnus*. The upper tendon of the *Adductor longus*, when the muscle is in action, stands out as a prominent ridge, which runs obliquely downwards and outwards from the neighbourhood of the pubic spine, and forms the inner boundary of a flattened triangular space on the upper part of the front of the thigh, known as Scarpa's triangle. The lower tendon of the *Adductor magnus* can be distinctly felt as a short ridge extending down to the *Adductor* tubercle on the internal condyle, between the *Sartorius* and *Vastus internus*. The *Adductor* group of muscles fills in the triangular space at the upper part of the thigh, formed between the oblique femur and the pelvic wall, and to them is due the contour of the inner border of the thigh, the *Gracilis* largely contributing to the smoothness of the outline. These muscles are not marked off on the surface from those of the posterior femoral region by any intermuscular marking; but on the outer side of the thigh these latter muscles are defined from the *Vastus externus* by a distinct marking, corresponding to the external intermuscular septum. The *Gluteus maximus* and a part of the *Gluteus medius* are the only muscles of the buttock which influence surface form. The other part of the *Gluteus medius*, the *Gluteus minimus*, and the *External rotators* are completely hidden. The *Gluteus maximus* forms the full rounded outline of the buttock; it is more prominent behind, compressed in front, and terminates at its tendinous insertion in a depression immediately behind the great trochanter. Its lower border does not correspond to the gluteal fold, but is much more oblique, being marked by a line drawn from the side of the coccyx to the junction of the upper with the lower two-thirds of the thigh on the outer side. From beneath the fold of this muscle, the *Hamstring* muscles appear, at first narrow and not well marked, but as they descend, becoming more prominent and widened out, and eventually dividing into two well-marked ridges, which form the upper boundaries of the popliteal space, being formed by the tendons of the inner and outer *Hamstring* muscles respectively. In the upper part of the thigh these muscles are not to be individually distinguished from each other, but lower down, the separation between the *Semitendinosus* and *Semimembranosus* is denoted by a slight intermuscular marking. The external hamstring tendon formed by the *Biceps* is seen as a thick cord running down to the head of the fibula. The inner hamstring tendons comprise the *Semitendinosus*, the *Semimembranosus*, and the *Gracilis*. The *Semitendinosus* is the most internal of these, and can be felt, in certain positions of the limb, as a sharp cord; the *Semimembranosus* is thick, and the *Gracilis* is situated a little further forwards than the other two. All the muscles on the front of the leg appear to a certain extent somewhere on the surface, but the form of this region is mainly dependent upon the *Tibialis anticus* and the *Extensor longus digitorum*. The *Tibialis anticus* is well marked, and presents a fusiform



enlargement at the outer side of the tibia, and projects beyond the crest of the shin bone. From the muscular mass, its tendon may be traced downward, standing out boldly, when the muscle is in action, on the front of the tibia and ankle-joint, and coursing down to its insertion along the inner border of the foot. A well-marked groove separates this muscle externally from the *Extensor longus digitorum*, which fills up the rest of the space between the upper part of the shaft of the tibia and fibula. It does not present so bold an outline as the *Tibialis anticus*, and its tendon below, diverging from the tendon of the *Tibialis anticus*, forms a sort of plane, in which may be seen the tendon of the *Extensor proprius hallucis*. A groove on the outer side of the *Extensor longus digitorum*, seen most plainly when the muscle is in action, separates from it a slight eminence corresponding to the *Peroneus tertius*. The fleshy fibres of the *Peroneus longus* are strongly marked at the upper part of the outer side of the leg, especially when the muscle is in action. It forms a bold swelling, separated by furrows from the *Extensor longus digitorum* in front and the *Soleus* behind. Below, the fleshy fibres terminate abruptly in a tendon which overlaps the more flattened form of the *Peroneus brevis*. At the External malleolus the tendon of the *Peroneus brevis* is more marked than that of the *Peroneus longus*. On the dorsum of the foot the tendons of the *Extensor* muscles, emerging from beneath the anterior annular ligament, spread out and can be distinguished in the following order: the most internal and largest is the *Tibialis anticus*, then the *Extensor proprius hallucis*; next comes the *Extensor longus digitorum*, dividing into four tendons to the four outer toes; and lastly, most externally, is the *Peroneus tertius*. The flattened form of the dorsum of the foot is relieved by the rounded outline of the fleshy belly of the *Extensor brevis digitorum*, which forms a soft fulness on the outer side of the tarsus in front of the external malleolus, and by the *Dorsal interossei*, which bulge between the metatarsal bones. At the back of the knee is the popliteal space, bounded above by the tendons of the *Hamstring* muscles; below, by the two heads of the *Gastrocnemius*. Below this space is the prominent fleshy mass of the calf of the leg, produced by the *Gastrocnemius* and *Soleus*. When these muscles are in action, as in standing on tiptoe, the borders of the *Gastrocnemius* are well defined, presenting two curved lines, which converge to the tendon of insertion. Of these borders, the inner is more prominent than the outer. The fleshy mass of the calf terminates somewhat abruptly below in the tendo *Achillis*, which stands out prominently on the lower part of the back of the leg. It presents a somewhat tapering form in the upper three-fourths of its extent, but widens out slightly below. When the muscles of the calf are in action, the lateral portions of the *Soleus* may be seen, forming curved eminences, of which the outer is the longer, on either side of the *Gastrocnemius*. Behind the inner border of the lower part of the shaft of the tibia, a well-marked ridge, produced by the tendon of the *Tibialis posticus*, is visible when this muscle is in a state of contraction.

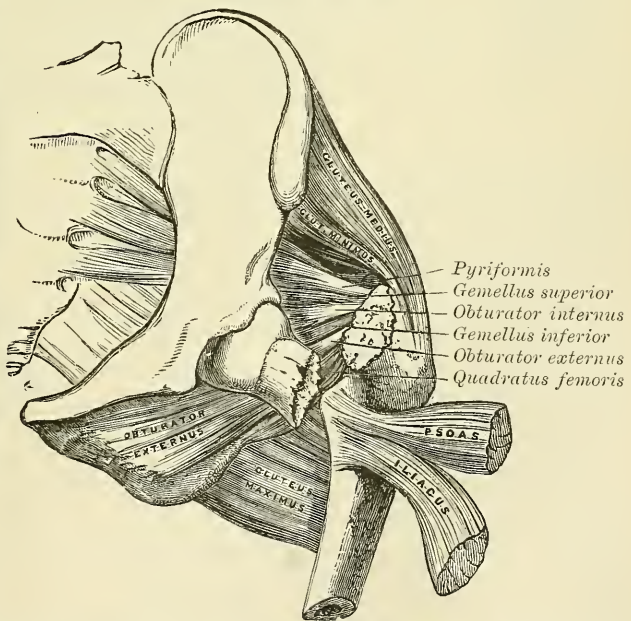
On the sole of the foot the superficial layer of muscles influences surface form; the *Abductor minimi digiti* most markedly. This muscle forms a narrow rounded elevation along the outer border of the foot, while the *Abductor hallucis* does the same, though to a less extent, on the inner side. The *Flexor brevis digitorum*, bound down by the plantar fascia, is not very apparent; it produces a flattened form, covered by the thickened skin of the sole, which is here thrown into numerous wrinkles.

#### Surgical Anatomy.—

The student should now consider the effects produced by the action of the various muscles in fractures of the bones of the lower extremity. The more common forms of fracture are selected for illustration and description.

In fracture of the neck of the femur internal to the capsular ligament (fig. 377), the characteristic marks are slight shortening of the limb, and eversion of the foot, neither of

FIG. 377.—Fracture of the neck of the femur within the capsular ligament.





which symptoms occurs, however, in some cases until some time after the injury. The eversion is caused by the weight of the limb rotating it outwards. The shortening is produced by the action of the Glutei, and by the Rectus femoris in front, and the Biceps Semitendinosus, and Semimembranosus behind.

FIG. 378.—Fracture of the femur below the trochanters.

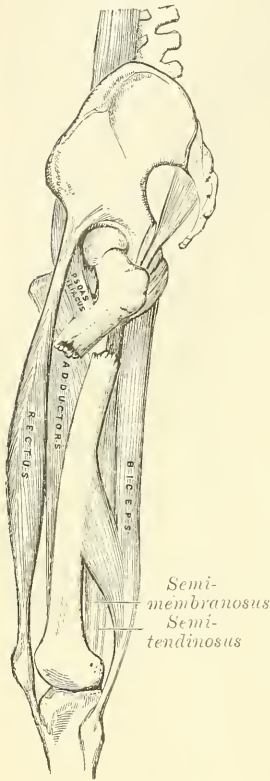


FIG. 379.—Fracture of the femur above the condyles.

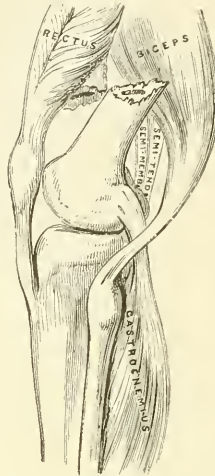
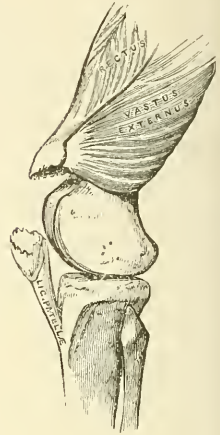
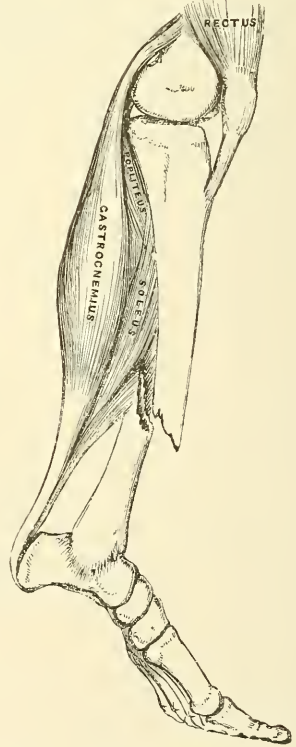


FIG. 380.—Fracture of the patella.



In fracture of the femur just below the trochanters (fig. 378), the upper fragment, the portion chiefly displaced, is tilted forwards almost at right angles with the pelvis, by the combined action of the Psoas and Iliacus; and, at the same time, everted and drawn outwards by the external rotator and Glutei muscles, causing

FIG. 381.—Oblique fracture of the shaft of the tibia.



a marked prominence at the upper and outer side of the thigh, and much pain from the bruising and laceration of the muscles. The limb is shortened, in consequence of the lower fragment being drawn upwards by the Rectus in front, and the Biceps, Semimembranosus, and Semitendinosus behind; and is, at the same time, everted. This fracture may be reduced in two different methods: either by direct relaxation of all the opposing muscles, to effect which the limb should be put up in such a manner that the thigh is flexed on the pelvis and the leg on the thigh; or by overcoming the contraction of the muscles, by continued extension, which may be effected by means of the long splint.

Oblique fracture of the femur immediately above the condyles (fig. 379) is a formidable injury, and attended with considerable displacement. On examination of the limb, the lower fragment may be felt deep in the popliteal space, being drawn backwards by the Gastrocnemius and Plantaris muscles; and upwards by the Hamstring and Rectus muscles. The pointed end of the upper fragment is drawn inwards by the Pectineus and Adductor muscles, and tilted forwards by the Psoas and Iliacus, piercing the Rectus muscle, and occasionally the integument. Relaxation of these muscles, and direct approximation of the broken fragments, are effected by placing the limb on a double inclined plane. The greatest care is requisite in keeping the pointed extremity

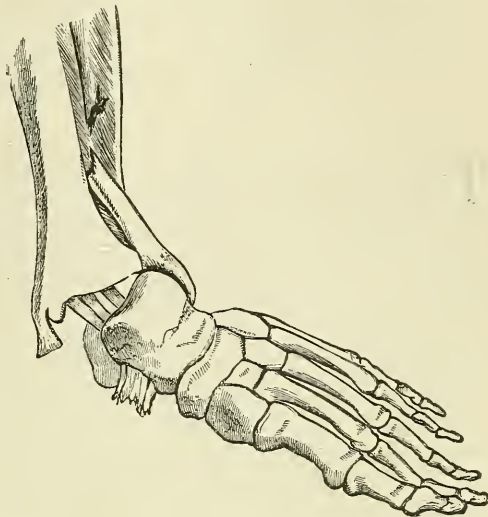
of the upper fragment in proper position; otherwise, after union of the fracture, the power of extension of the limb is partially destroyed, from the Rectus muscle being held down by the fractured end of the bone, and from the patella, when elevated, being drawn upwards against the projecting fragment.

In fracture of the *patella* (fig. 380) the fragments are separated by the effusion which takes place into the joint, and possibly by the action of the Quadriceps extensor; the extent of separation of the two fragments depending upon the degree of laceration of the ligamentous structures around the bone.

In oblique fracture of the *shaft of the tibia* (fig. 381), if the fracture has taken place obliquely from above, downwards and forwards, the fragments ride over one another, the lower fragments being drawn backwards and upwards by the powerful action of the muscles of the calf; the pointed extremity of the upper fragment projects forwards immediately beneath the integument, often protruding through it, and rendering the fracture a compound one. If the direction of the fracture is the reverse of that shown in the figure, the pointed extremity of the lower fragment projects forwards, riding upon the lower end of the upper one. By bending the knee, which relaxes the opposing muscles, and making extension from the ankle and counter-extension at the knee, the fragments may be brought into apposition. It is often necessary, however, in compound fracture, to remove a portion of the projecting bone with the saw before complete adaptation can be effected.

Fracture of the *fibula with dislocation of the foot outwards* (fig. 382), commonly known as 'Pott's Fracture,' is one of the most frequent injuries of the ankle-joint. The fibula is fractured about three inches above the ankle: in addition to this the internal malleolus is broken off, or the deltoid ligament torn through, and the end of the tibia displaced from the corresponding surface of the astragalus. The foot is markedly everted, and the sharp edge of the root of the inner malleolus presses strongly against the skin; at the same time, the heel is drawn up by the muscles of the calf. This injury may be at once reduced by flexing the leg at right angles with the thigh, which relaxes all the opposing muscles, and by making extension from the ankle and counter-extension at the knee.

FIG. 382.—Fracture of the fibula, with dislocation of the foot outwards—'Pott's Fracture.'



## OF THE ARTERIES

THE Arteries are cylindrical tubular vessels, which serve to convey blood from both ventricles of the heart to every part of the body. These vessels were named arteries (*ἀήρ*, *air*; *τηρεῖν*, *to contain*) from the belief entertained by the ancients that they contained air. To Galen is due the honour of refuting this opinion; he showed that these vessels, though for the most part empty after death, contain blood in the living body.

The pulmonary artery, which arises from the right ventricle of the heart, carries venous blood directly into the lungs, whence it is returned by the pulmonary veins into the left auricle. This constitutes the lesser or pulmonic circulation. The great artery which arises from the left ventricle, the *aorta*, conveys arterial blood to the body generally; whence it is brought back to the right side of the heart by means of the veins. This constitutes the greater or systemic circulation.

The distribution of the systemic arteries is like a highly ramified tree, the common trunk of which, formed by the aorta, commences at the left ventricle of the heart, the smallest ramifications corresponding to the circumference of the body and the contained organs. The arteries are found in nearly every part of the body, with the exception of the hairs, nails, epidermis, cartilages, and cornea; and the larger trunks usually occupy the most protected situations, running, in the limbs, along the flexor side, where they are less exposed to injury.

There is considerable variation in the mode of division of the arteries: occasionally a short trunk subdivides into several branches at the same point, as we observe in the cœliac and thyroid axes; or the vessel may give off several branches in succession, and still continue as the main trunk, as is seen in the arteries of the limbs; but the usual division is dichotomous, as, for instance, the aorta dividing into the two common iliacs; and the common carotid into the external and internal.

The branches of arteries arise at very variable angles; some, as the superior intercostal arteries from the aorta, arise at an obtuse angle; others, as the lumbar arteries, at a right angle; or, as the spermatic, at an acute angle. An artery from which a branch is given off is smaller in size, but retains a uniform diameter until a second branch is derived from it. A branch of an artery is smaller than the trunk from which it arises; but if an artery divides into two branches, the combined area of the two vessels is, in nearly every instance, somewhat greater than that of the trunk; and the combined area of all the arterial branches greatly exceeds the area of the aorta: so that the arteries collectively may be regarded as a cone, the apex of which corresponds to the aorta, the base to the capillary system.

The arteries, in their distribution, communicate freely with one another, forming what is called an *anastomosis* (*ἀνά*, *between*; *στόμα*, *mouth*), or inosculation: and this communication is very free between the large as well as between the smaller branches. The anastomosis between trunks of equal size is found



where great freedom and activity of the circulation are requisite, as in the brain; here the two vertebral arteries unite to form the basilar, and the two internal carotid arteries are connected by a short communicating trunk; it is also found in the abdomen, the intestinal arteries having very free anastomoses between their larger branches. In the limbs, the anastomoses are most frequent and of largest size around the joints; the branches of an artery above freely inosculating with branches from the vessels below. These anastomoses are of considerable interest to the surgeon, as it is by their enlargement that a *collateral circulation* is established after the application of a ligature to an artery for the cure of aneurism. The smaller branches of arteries anastomose more frequently than the larger; and between the smallest twigs these inosculations become so numerous as to constitute a close network that pervades nearly every tissue of the body.

Throughout the body generally the larger arterial branches pursue a perfectly straight course; but in certain situations they are tortuous; thus, the facial artery in its course over the face, and the arteries of the lips, are extremely tortuous in their course, to accommodate themselves to the movements of the parts. The uterine arteries are also tortuous, to accommodate themselves to the increase of size which the organ undergoes during pregnancy. Again, the internal carotid and vertebral arteries, previous to their entering the cavity of the skull, describe a series of curves, which are evidently intended to diminish the velocity of the current of blood, by increasing the extent of surface over which it moves, and adding to the amount of impediment which is produced by friction.

The arteries are dense in structure, of considerable strength, highly elastic, and, when divided, they preserve, although empty, their cylindrical form.

The minute structure of these vessels has been described in the chapter on General Anatomy.

In the description of the arteries, we shall first consider the efferent trunk of the pulmonic circulation, the pulmonary artery; and then the efferent trunk of the systemic circulation, the aorta, and its branches.

#### PULMONARY ARTERY (fig. 383)

The **pulmonary artery** conveys the venous blood from the right side of the heart to the lungs. It is a short, wide vessel, about two inches in length and  $1\frac{1}{5}$  inch (30 mm.) in diameter, arising from the left side of the base (conus arteriosus) of the right ventricle, in front of the aorta. It extends obliquely upwards and backwards, passing at first in front of and then to the left of the ascending aorta, as far as the under surface of the arch, where it divides, about on a level with the intervertebral substance between the fifth and sixth dorsal vertebræ, into two branches of nearly equal size, the *right* and *left pulmonary arteries*.

**Relations.**—The whole of this vessel is contained, together with the ascending aorta, in the pericardium. It is enclosed with the aorta in a single tube of the serous pericardium, which is continued upwards upon them from the base of the heart and connects them together. The fibrous layer of the pericardium becomes gradually lost upon the external coat of its two branches. In front, the pulmonary artery is separated from the anterior extremity of the second intercostal space by the pleura and left lung, in addition to the pericardium; it rests at first upon the ascending aorta, and higher up lies in front of the left auricle on a plane posterior to the ascending aorta. On each side of its origin is the appendix of the corresponding auricle and a coronary artery.

The **right pulmonary artery**, longer and larger than the left, runs horizontally outwards, behind the ascending aorta and superior vena cava, to the root of the



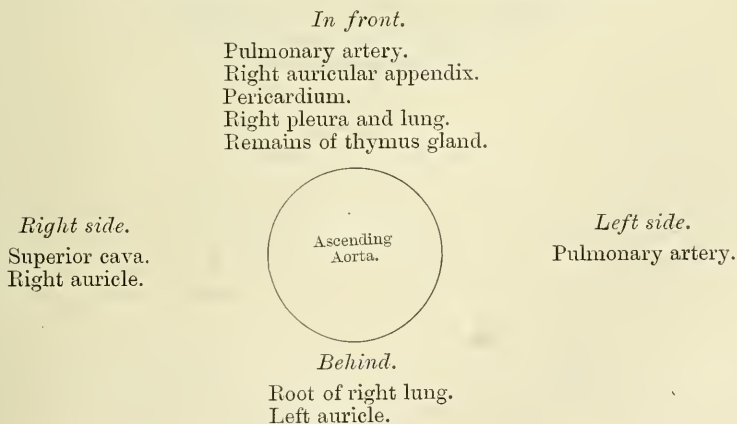
the left side, over the root of the left lung, then descends within the thorax on the left side of the vertebral column, passes through the aortic opening in the Diaphragm, and entering the abdominal cavity, terminates, considerably diminished in size (about  $\frac{7}{16}$  of an inch in diameter), opposite the fourth lumbar vertebra, where it divides into the right and left common iliac arteries. Hence its division into the *ascending aorta*, the *arch* of the aorta, and the *descending aorta*, which last is again divided into *thoracic aorta*, and *abdominal aorta*, from the position of these parts.

## ASCENDING AORTA

The **ascending aorta** is about two inches in length. It commences at the upper part of the base of the left ventricle, on a level with the lower border of the third costal cartilage behind the left half of the sternum; it passes obliquely upwards, forwards, and to the right in the direction of the heart's axis, as high as the upper border of the second right costal cartilage, describing a slight curve in its course, and being situated, when distended, about a quarter of an inch behind the posterior surface of the sternum. A little above its commencement it is somewhat enlarged, and presents three small dilatations called the *sinuses of the aorta* (sinuses of Valsalva), opposite to which are attached the three semilunar valves, which serve the purpose of preventing any regurgitation of blood into the cavity of the ventricle. These valves are placed one in front and two behind. A section of the aorta opposite this part has a somewhat triangular figure; but below the attachment of the valves it is circular. This portion of the aorta is contained in the cavity of the pericardium, and, together with the pulmonary artery, is invested in a tube of serous membrane, continued on to them from the surface of the heart.

**Relations.**—The ascending aorta is covered at its commencement by the trunk of the pulmonary artery and the right auricular appendix, and, higher up, is separated from the sternum by the pericardium, the right pleura, and anterior margin of right lung, some loose areolar tissue, and the remains of the thymus gland; *behind*, it rests upon the root of the right lung and left auricle. On the *right side*, it is in relation with the superior vena cava and right auricle; on the *left side*, with the pulmonary artery.

## PLAN OF THE RELATIONS OF THE ASCENDING AORTA



**Branches.**—The only branches of the ascending aorta are the coronary arteries. They supply the heart, and are two in number, right and left, arising



near the commencement of the aorta immediately above the free margin of the semilunar valves.

The **Right Coronary Artery**, about the size of a crow's quill, arises from the aorta immediately above the free margin of the anterior semilunar valve. It passes forwards between the pulmonary artery and the right auricular appendix, then runs obliquely to the right side, in the groove between the right auricle and ventricle, and curving around the right border of the heart, runs along its posterior surface as far as the posterior interventricular groove, where it divides into two branches, one of which continues onwards in the groove between the left auricle and ventricle, and anastomoses with the left coronary; the other descends along the posterior interventricular furrow, supplying branches to both ventricles and to the septum, and anastomosing at the apex of the heart with the descending branches of the left coronary.

This vessel sends a large branch along the thin margin of the right ventricle to the apex, and numerous small branches to the right auricle and ventricle, and the commencement of the pulmonary artery.

The **Left Coronary**, larger than the former, arises immediately above the free edge of the left anterior semilunar valve, a little higher than the right; it passes forwards between the pulmonary artery and the left auricular appendix, and divides into two branches. Of these, one passes transversely outwards in the left auriculo-ventricular groove, and winds around the left border of the heart to its posterior surface, where it anastomoses with the transverse branch of the right coronary; the other descends along the anterior interventricular groove to the apex of the heart, where it anastomoses with the descending branches of the right coronary. The left coronary supplies the left auricle and its appendix, both ventricles, and numerous small branches to the pulmonary artery, and commencement of the aorta.\*

*Peculiarities.*—These vessels occasionally arise by a common trunk, or their number may be increased to three; the additional branch being of small size. More rarely, there are two additional branches.

#### ARCH OF THE AORTA

The **arch**, or **transverse aorta**, commences at the upper border of the second chondro-sternal articulation of the right side, and passes from right to left, and from before backwards, to the left side of the lower border of the fourth dorsal vertebra behind. Its upper border is usually about an inch below the upper margin of the sternum.

**Relations.**—Its *anterior surface* is covered by the pleuræ and lungs and the remains of the thymus gland, and crossed towards the left side by the left pneumogastric and phrenic nerves, and superior cardiac branches of the left sympathetic, and by the left superior intercostal vein. Its *posterior surface* lies on the trachea, just above its bifurcation, on the great, or deep, cardiac plexus, the œsophagus, thoracic duct, and left recurrent laryngeal nerve. Its *upper border* is in relation with the left innominate vein; and from its upper part are given off the innominate, left common carotid, and left subclavian arteries. Its *lower border* is in relation with the bifurcation of the pulmonary artery, the remains of the ductus arteriosus, which is connected with the left division of that vessel, and the superficial cardiac plexus; the left recurrent laryngeal nerve winds round it from before backwards, whilst the left bronchus passes below it.

\* According to Dr. Samuel West, there is a very free and complete anastomosis between the two coronary arteries (*Lancet*, June 2, 1883, p. 945). This, however, is not the view generally held by anatomists, for, with the exception of the anastomosis mentioned above in the auriculo-ventricular and interventricular grooves, it is believed that the two arteries only communicate by very small vessels in the substance of the heart.

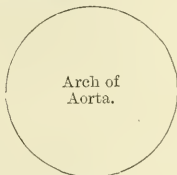PLAN OF THE RELATIONS OF THE ARCH OF THE AORTA

*Above.*

Left innominate vein.  
 Innominate artery.  
 Left carotid.  
 Left subclavian.

*In front.*

Pleurae and lungs.  
 Remains of thymus gland.  
 Left pneumogastric nerve.  
 Left phrenic nerve.  
 Left superior cardiac nerves.  
 Left superior intercostal vein.



*Behind.*

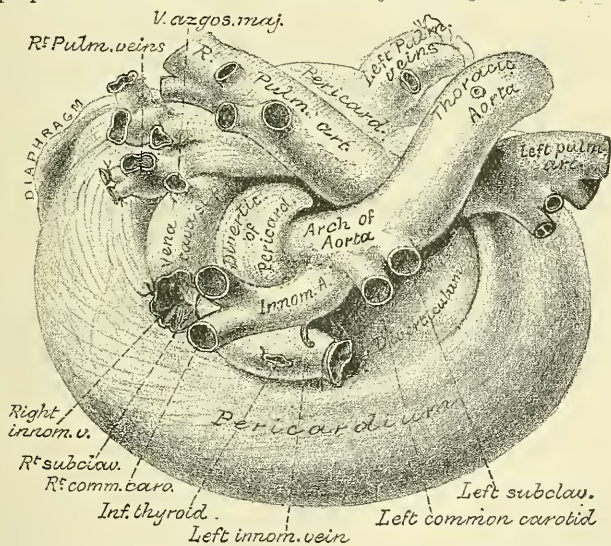
Trachea.  
 Deep cardiac plexus.  
 Oesophagus.  
 Thoracic duct.  
 Left recurrent nerve.

*Below.*

Bifurcation of pulmonary artery.  
 Remains of ductus arteriosus.  
 Superficial cardiac plexus.  
 Left recurrent nerve.  
 Left bronchus.

*Peculiarities.*—The height to which the aorta rises in the chest is usually about an inch below the upper border of the sternum; but it may ascend nearly to the top of that bone. Occasionally it is found an inch and a half, more rarely two or even three inches below this point.

FIG. 385.—Relation of great vessels at base of heart, seen from above. (From a preparation in the Museum of the Royal College of Surgeons.)



*In Direction.*—Sometimes the aorta arches over the root of the right instead of the left lung, as in birds, and passes down on the right side of the spine. In such cases all the viscera of the thoracic and abdominal cavities are transposed. Less frequently, the aorta, after arching over the root of the right lung, is directed to its usual position on the left side of the spine, this peculiarity not being accompanied by any transposition of the viscera.

*In Conformation.*—The aorta occasionally divides, as in some quadrupeds, into an ascending and a descending trunk, the former of which is directed vertically upwards, and subdivides into three branches, to supply the head and upper extremities. Sometimes the aorta subdivides soon after its origin into two branches, which soon reunite. In one of these cases the oesophagus and trachea were found to pass through the interval left by their division; this is the normal condition of the vessel in the reptilia.

*Surgical Anatomy.*—Of all the vessels of the arterial system, the aorta, and more especially its arch, is most frequently the seat of disease; hence it is important to consider some of the consequences that may ensue from aneurism of this part.

It will be remembered that the ascending aorta is contained in the pericardium, just behind the sternum, being crossed at its commencement by the pulmonary artery and

right auricular appendix, and having the root of the right lung behind, the vena cava on the right side, and the pulmonary artery and left auricle on the left side.

Aneurism of the ascending aorta, in the situation of the aortic sinuses, in the great majority of cases, affects the anterior sinus; this is mainly owing to the fact that the regurgitation of blood upon the sinuses takes place chiefly on the anterior aspect of the vessel. As the aneurismal sac enlarges, it may compress any or all of the structures in immediate proximity with it, but chiefly projects towards the right anterior side; and, consequently, interferes mainly with those structures that have a corresponding relation with the vessel. In the majority of cases, it bursts into the cavity of the pericardium, the patient suddenly drops down dead, and, upon a post-mortem examination, the pericardial sac is found full of blood; or it may compress the right auricle, or the pulmonary artery, and adjoining part of the right ventricle, and open into one or the other of these parts, or it may press upon the superior vena cava.

Aneurism of the ascending aorta, originating above the sinuses, most frequently implicates the right anterior wall of the vessel; this is probably mainly owing to the blood being impelled against this part. The direction of the aneurism is also chiefly towards the right of the median line. If it attains a large size and projects forwards, it may absorb the sternum and the cartilages of the ribs, usually on the right side, and appear as a pulsating tumour on the front of the chest, just below the manubrium; or it may burst into the pericardium, or may compress, or open into the right lung, the trachea, bronchi, or œsophagus.

Regarding the transverse aorta, the student is reminded that the vessel lies on the trachea, the œsophagus, and thoracic duct; that the recurrent laryngeal nerve winds around it; and that from its upper part are given off three large trunks, which supply the head, neck, and upper extremities. Now, an aneurismal tumour taking origin from the posterior part of the vessel, its most usual site, may press upon the trachea, impede the breathing, or produce cough, hæmoptysis, or stridulous breathing, or it may ultimately burst into that tube, producing fatal hæmorrhage. Again, its pressure on the laryngeal nerves may give rise to symptoms which so accurately resemble those of laryngitis, that the operation of tracheotomy has in some cases been resorted to, from the supposition that disease existed in the larynx; or it may press upon the thoracic duct and destroy life by inanition; or it may involve the œsophagus, producing dysphagia; or may burst into the œsophagus, when fatal hæmorrhage will occur. Again, the innominate artery, or the subclavian, or left carotid, may be so obstructed by clots as to produce a weakness, or even a disappearance, of the pulse in one or the other wrist, or in the left temporal artery; or the tumour may present itself at or above the manubrium, generally either in the median line, or to the right of the sternum, and may simulate an aneurism of one of the arteries of the neck.

**Branches** (figs. 383, 384).—The branches given off from the arch of the aorta are three in number: the innominate artery, the left common carotid, and the left subclavian.

*Peculiarities. Position of the Branches.*—The branches, instead of arising from the highest part of the arch (their usual position), may be moved more to the right, arising from the commencement of the transverse or upper part of the ascending portion; or the distance from one another at their origin may be increased or diminished, the most frequent change in this respect being the approximation of the left carotid towards the innominate artery.

*The Number* of the primary branches may be reduced to a single vessel, or more commonly two: the left carotid arising from the innominate artery; or (more rarely), the carotid and subclavian arteries of the left side arising from a left innominate artery. But the number may be increased to four, from the right carotid and subclavian arteries arising directly from the aorta, the innominate being absent. In most of these latter cases the right subclavian has been found to arise from the left end of the arch; in other cases it was the second or third branch given off instead of the first. Another common form in which there are four primary branches is that in which the left vertebral artery arises from the arch of the aorta between the left carotid and subclavian arteries. Lastly, the number of trunks from the arch may be increased to five or six; in these instances, the external and internal carotids arise separately from the arch, the common carotid being absent on one or both sides. In some cases, where six branches have been found, it has been due to a separate origin of the vertebral on both sides.

*Number usual, Arrangement different.*—When the aorta arches over to the right side, the three branches have an arrangement the reverse of what is usual, the innominate supplying the left side, and the carotid and subclavian (which arise separately) the right side. In other cases, where the aorta takes its usual course, the two carotids may be joined in a common trunk, and the subclavians arise separately from the arch, the right subclavian generally arising from the left end of the arch.\*

\* The anomalies of the aorta and its branches are minutely described by Krause in Henle's *Anatomy* (Brunswick, 1868), vol. iii. p. 203 *et seq.*



## INNOMINATE ARTERY

The **innominate artery (brachio-cephalic)** is the largest branch given off from the arch of the aorta. It arises, on a level with the upper border of the second right costal cartilage, from the commencement of the arch of the aorta in front of the left carotid, and, ascending obliquely to the upper border of the right sterno-clavicular articulation, divides into the right common carotid and right subclavian arteries. This vessel varies from an inch and a half to two inches in length.

**Relations.**—*In front*, it is separated from the first bone of the sternum by the Sterno-hyoid and Sterno-thyroid muscles, the remains of the thymus gland, the left innominate and right inferior thyroid veins which cross its root, and sometimes the inferior cervical cardiac branch of the right pneumogastric. *Behind*, it lies upon the trachea, which it crosses obliquely. On the *right side* is the right innominate vein, right pneumogastric nerve, and the pleura; and on the *left side*, the remains of the thymus gland, the origin of the left carotid artery, the left inferior thyroid vein, and the trachea.

**Branches.**—The innominate usually gives off no branches; but occasionally a small branch, the *thyroidea ima*, is given off from this vessel. It also sometimes gives off a *thymic* or *bronchial branch*. The **Thyroidea ima** ascends in front of the trachea to the lower part of the thyroid body, which it supplies. It varies greatly in size, and appears to compensate for deficiency or absence of one of the other thyroid vessels. It occasionally is found to arise from the right common carotid or from the aorta, the subclavian or internal mammary artery.

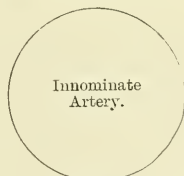
## PLAN OF THE RELATIONS OF THE INNOMINATE ARTERY

*In front.*

Sternum.  
Sterno-hyoid and Sterno-thyroid muscles.  
Remains of thymus gland.  
Left innominate and right inferior thyroid veins.  
Inferior cervical cardiac branch from right pneumogastric nerve.

*Right side.*

Right innominate vein.  
Right pneumogastric nerve.  
Pleura.

*Left side.*

Remains of thymus.  
Left carotid.  
Left inferior thyroid vein.  
Trachea.

*Behind.*

Trachea.

**Peculiarities in point of Division.**—When the bifurcation of the innominate artery varies from the point above mentioned, it sometimes ascends a considerable distance above the sternal end of the clavicle; less frequently it divides below it. In the former class of cases, its length may exceed two inches; and, in the latter, be reduced to an inch or less. These are points of considerable interest for the surgeon to remember in connection with the operation of tying this vessel.

**Position.**—When the aorta arches over to the right side, the innominate is directed to the left side of the neck instead of the right.

**Collateral Circulation.**—Allan Burns demonstrated, on the dead subject, the possibility of the establishment of the collateral circulation after ligation of the innominate artery, by tying and dividing that artery, after which, he says, 'Even coarse injection, impelled into the aorta, passing freely by the anastomosing branches into the arteries of the right arm, filling them and all the vessels of the head completely.' (*Surgical Anatomy of the Head and Neck*, p. 62.) The branches by which this circulation would be carried on are very numerous; thus, all the communications across the middle line between the branches of the carotid arteries of opposite sides would be available for the supply of blood to the right side of the head and neck; while the anastomosis between the superior intercostal of the subclavian and the first aortic intercostal (see *infra* on the collateral circulation after obliteration of the thoracic aorta) would bring the blood, by a free and direct

course, into the right subclavian: the numerous connections, also, between the intercostal arteries and the branches of the axillary and internal mammary arteries would, doubtless, assist in the supply of blood to the right arm, while the epigastric, from the external iliac, would, by means of its anastomosis with the internal mammary, compensate for any deficiency in the vascularity of the wall of the chest.

*Surgical Anatomy.*—Although the operation of tying the innominate artery has been performed by several surgeons, for aneurism of the right subclavian extending inwards as far as the Scalenus, in only two instances has the patient survived.\* Mott's patient, however, on whom the operation was first performed, lived nearly four weeks, and Graefe's more than two months. The main obstacles to the operation are, as the student will perceive from his dissection of this vessel, the deep situation of the artery behind and beneath the sternum, and the number of important structures which surround it in every part.

In order to apply a ligature to this vessel, the patient is to be placed upon his back with the thorax slightly raised, the head bent a little backwards, and the shoulder on the side of the aneurism strongly depressed, so as to draw out the artery from behind the sternum into the neck. An incision three or more inches long is then made along the anterior border of the Sterno-mastoid muscle, terminating at the sternal end of the clavicle. From this point, a second incision is carried about the same length along the upper border of the clavicle. The skin is then dissected back, and the Platysma divided on a director: the sternal end of the Sterno-mastoid is now brought into view, and a director being passed beneath it, and close to its under surface, so as to avoid any small vessels, it is to be divided; in like manner the clavicular origin is to be divided throughout the whole or greater part of its attachment. By pressing aside any loose cellular tissue or vessels that may now appear, the Sterno-hyoid and Sterno-thyroid muscles will be exposed, and must be divided, a director being previously passed beneath them. The inferior thyroid veins may come into view, and must be carefully drawn either upwards or downwards, by means of a blunt hook, or tied with double ligatures and divided. After tearing through a strong fibro-cellular lamina, the right carotid is brought into view, and being traced downwards, the arteria innominata is arrived at. The left innominate vein should now be depressed: the right innominate vein, the internal jugular vein, and the pneumogastric nerve drawn to the right side; and a curved aneurism needle may then be passed around the vessel, close to its surface, and in a direction from below upwards and inwards; care being taken to avoid the right pleural sac, the trachea, and cardiac nerves. The ligature should be applied to the artery as high as possible, in order to allow room between it and the aorta for the formation of the coagulum. The importance of avoiding the thyroid plexus of veins during the primary steps of the operation, and the pleural sac whilst including the vessel in the ligature, should be most carefully borne in mind. The most frequent cause of death after operation is secondary hæmorrhage, which has occurred in almost every case. Other causes are pleurisy, pericarditis, and suppurative cellulitis.

## ARTERIES OF THE HEAD AND NECK

The artery which supplies the head and neck is the Common Carotid, which ascends in the neck and divides into two branches: the External Carotid, which supplies the superficial parts of the head and face and the greater part of the neck, and the Internal Carotid, which supplies to a great extent the part within the cranial cavity.

### COMMON CAROTID ARTERIES

The **common carotid arteries**, although occupying a nearly similar position in the neck, differ in position, and, consequently, in their relations at their origin. The right carotid arises from the innominate artery, behind the right sterno-clavicular articulation; the left from the highest part of the arch of the aorta. The left carotid is, consequently, longer, and at its origin is contained within the thorax. The course and relation of that portion of the left carotid which intervenes between the arch of the aorta and the left sterno-clavicular articulation, will first be described (see fig. 383).

The *left carotid within the thorax* ascends obliquely outwards from the arch of the aorta to the root of the neck. *In front*, it is separated from the first piece of

\* In one of these, the operation was performed by Dr. Smyth of New Orleans. See the New Sydenham Society's *Biennial Retrospect* for 1865-6, p. 346. In the other, the operation was performed by Dr. Mitchell Banks, in the Liverpool Infirmary. The case is recorded by Mr. Jacobson in *Operations of Surgery*, p. 536.

the sternum by the Sterno-hyoid and Sterno-thyroid muscles, the left innominate vein, and the remains of the thymus gland; *behind*, it lies on the trachea, œsophagus, and thoracic duct. *Internally*, it is in relation with the innominate artery, inferior thyroid veins and remains of Thymus gland; *externally*, with the left pneumogastric nerve, left pleura, and lung. The left subclavian artery is posterior and external to it.

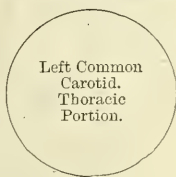PLAN OF THE RELATIONS OF THE LEFT COMMON CAROTID.  
THORACIC PORTION

*In front.*

Sternum.  
Sterno-hyoid and Sterno-thyroid muscles.  
Left innominate vein.  
Remains of thymus gland.

*Internally.*

Innominate artery.  
Inferior thyroid veins.  
Remains of thymus gland.



*Externally.*

Left pneumogastric nerve.  
Left pleura and lung.  
Left subclavian artery.

*Behind.*

Trachea.  
Esophagus.  
Thoracic duct.

*In the neck*, the two common carotids resemble each other so closely, that one description will apply to both. Each vessel passes obliquely upwards, from behind the sterno-clavicular articulation, to a level with the upper border of the thyroid cartilage, opposite the fourth cervical vertebra, where it divides into the external and internal carotid; these names being derived from the distribution of the arteries to the external parts of the head and face, and to the internal parts of the cranium and orbit respectively.

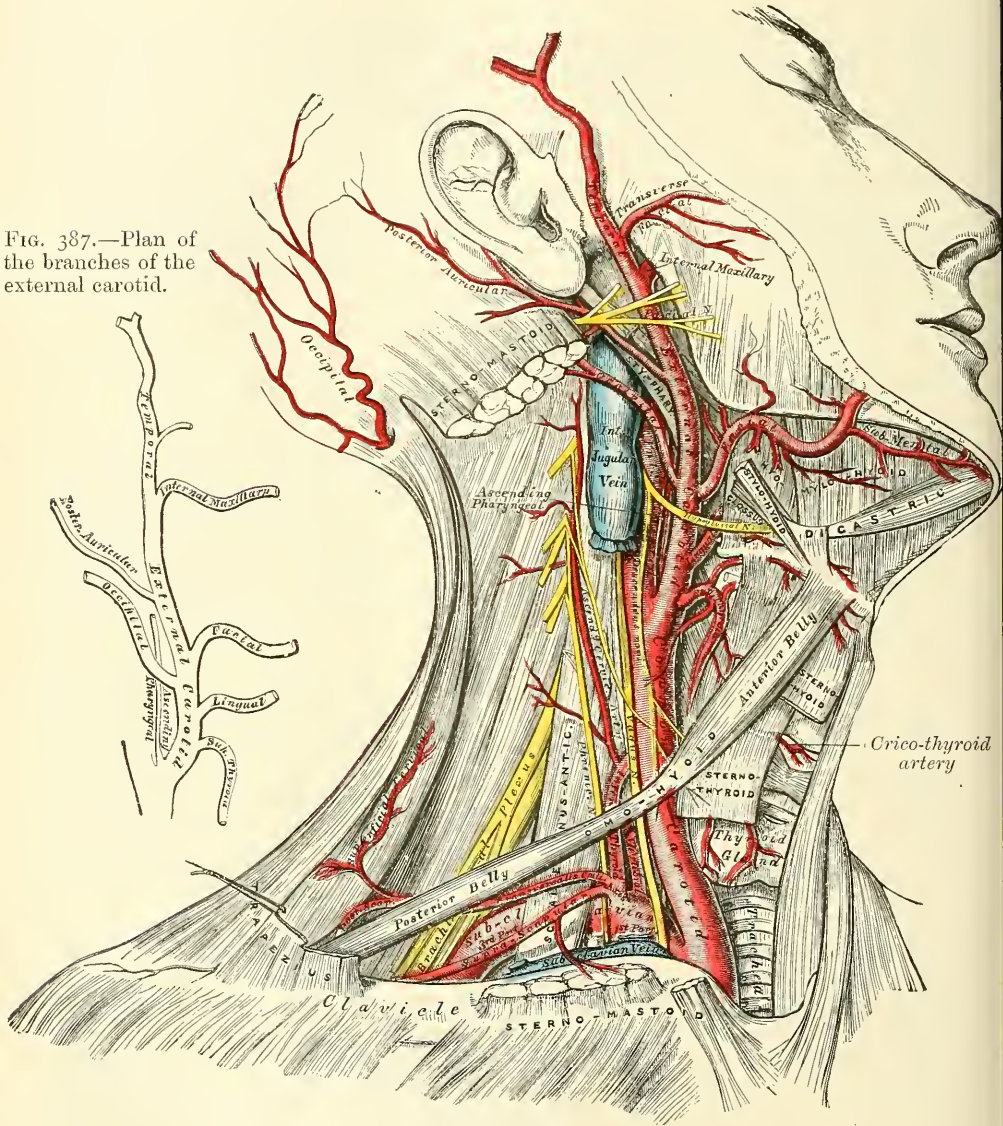
At the lower part of the neck the two common carotid arteries are separated from each other by a very small interval, which contains the trachea; but at the upper part, the thyroid body, the larynx and pharynx project forwards between the two vessels, and give the appearance of their being placed further back in that situation. The common carotid artery is contained in a sheath, derived from the deep cervical fascia, which also encloses the internal jugular vein and pneumogastric nerve, the vein lying on the outer side of the artery, and the nerve between the artery and vein, on a plane posterior to both. On opening the sheath, these three structures are seen to be separated from one another, each being enclosed in a separate fibrous investment.

**Relations.**—At the lower part of the neck the common carotid artery is very deeply seated, being covered by the integument, superficial fascia, Platysma, and deep cervical fascia, the Sterno-mastoid, Sterno-hyoid, and Sterno-thyroid muscles, and by the Omo-hyoid, opposite the cricoid cartilage; but in the upper part of its course, near its termination, it is more superficial, being covered merely by the integument, the superficial fascia, Platysma, deep cervical fascia, and inner margin of the Sterno-mastoid, and is contained in a triangular space, bounded behind by the Sterno-mastoid, above by the posterior belly of the Digastric, and below by the anterior belly of the Omo-hyoid. This part of the artery is crossed obliquely, from within outwards, by the sterno-mastoid artery; it is crossed also by one, or sometimes two superior thyroid veins, which terminate in the internal jugular; and descending on its sheath in front is seen the descendens hypoglossi nerve, this filament being joined by one or two branches from the cervical nerves, which cross the vessel from without inwards. Sometimes the descendens hypoglossi is



contained within the sheath. The middle thyroid vein crosses the artery about its middle, and the anterior jugular vein below. *Behind*, the artery lies in front of the cervical portion of the spine, resting first on the Longus colli muscle, then on the Rectus capitis anticus major, from which it is separated by the sympathetic nerve. The recurrent laryngeal nerve and inferior thyroid artery cross behind the vessel at its lower part. *Internally*, it is in relation with the trachea and thyroid gland, the inferior thyroid artery and recurrent laryngeal nerve being interposed:

FIG. 386.—Superficial dissection of the right side of the neck, showing the carotid and subclavian arteries.



higher up, with the larynx and pharynx. On its *outer side* are placed the internal jugular vein and pneumogastric nerve.

At the lower part of the neck, the internal jugular vein on the right side diverges from the artery, but on the left side it approaches it, and often crosses its lower part. This is an important fact to bear in mind during the performance of any operation on the lower part of the left common carotid artery.

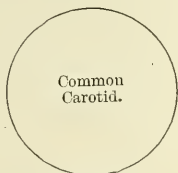
## PLAN OF THE RELATIONS OF THE COMMON CAROTID ARTERY

*In front.*

Integument, and superficial fascia.	Omo-hyoid.
Deep cervical fascia.	Descendens and Communicans hypoglossi
Platysma.	Sterno-mastoid artery. [nerves.
Sterno-mastoid.	Superior and middle thyroid veins.
Sterno-hyoid.	Anterior jugular vein.
Sterno-thyroid.	

*Externally.*

Internal jugular vein.  
Pneumogastric nerve.

*Behind.*

Longus colli.	Sympathetic nerve.
Rectus capitis anticus major.	Inferior thyroid artery.
Recurrent laryngeal nerve.	

*Internally.*

Trachea.  
Thyroid gland.  
Recurrent laryngeal nerve.  
Inferior thyroid artery.  
Larynx.  
Pharynx.

*Peculiarities as to Origin.*—The *right common carotid* may arise above or below its usual point, the upper border of the sterno-clavicular articulation. This variation occurs in one out of about eight cases and a half, and the origin is more frequently above than below the usual point: or the artery may arise as a separate branch from the arch of the aorta, or in conjunction with the left carotid. The *left common carotid* varies more frequently in its origin than the right. In the majority of abnormal cases it arises with the innominate artery, or, if the innominate artery is absent, the two carotids arise usually by a single trunk. The left carotid is occasionally the first branch given off from the arch of the aorta. It rarely joins with the left subclavian, except in cases of transposition of the arch.

*Peculiarities as to point of Division.*—The most important peculiarities of this vessel, in a surgical point of view, relate to its place of division in the neck. In the majority of abnormal cases, this occurs higher than usual, the artery dividing into two branches opposite the hyoid bone, or even higher; more rarely, it occurs below its usual place opposite the middle of the larynx, or the lower border of the cricoid cartilage; and one case is related by Morgagni, where the common carotid, only an inch and a half in length, divided at the root of the neck. Very rarely, the common carotid ascends in the neck without any subdivision, the internal carotid being wanting; and in a few cases the common carotid has been found to be absent, the external and internal carotids arising directly from the arch of the aorta. This peculiarity existed on both sides in some instances, on one side in others.

*Occasional Branches.*—The common carotid usually gives off no branch previous to its bifurcation; but it occasionally gives origin to the superior thyroid, or its laryngeal branch, the inferior thyroid, or, more rarely, the vertebral artery.

*Surface Marking.*—The carotid arteries are overlapped throughout their entire extent by the anterior border of the Sterno-mastoid muscle, but their course does not correspond to the border of the muscle, which passes in a somewhat curved direction from the mastoid process to the sterno-clavicular joint. The course of the artery is indicated more exactly by a line drawn from the sternal end of the clavicle below, to a point midway between the angle of the jaw and the mastoid process above. That portion of the line below the level of the upper border of the thyroid cartilage would represent the course of the vessel.

*Surgical Anatomy.*—The operation of tying the common carotid artery may be necessary in a case of wound of that vessel or its branches, in aneurism, or in a case of pulsating tumour of the orbit or skull. If the wound involves the trunk of the common carotid, it will be necessary to tie the artery above and below the wounded part. But in cases of aneurism, or where one of the branches of the common carotid is wounded in an inaccessible situation, it may be judged necessary to tie the trunk. In such cases, the whole of the artery is accessible, and any part may be tied, except close to either end. When the case is such as to allow of a choice being made, the lower part of the carotid should never be selected as the spot upon which to place a ligature, for not only is the artery in this situation placed very deeply in the neck, but it is covered by three layers of muscles, and, on the left side, the internal jugular vein, in the great majority of cases, passes obliquely in front of it. Neither should the upper end be selected, for here the superior thyroid vein and its tributaries would give rise to very considerable difficulty in the application of a ligature. The point most favourable for the operation is that part of the vessel which is at the level of the cricoid cartilage. It occasionally happens that the carotid artery bifurcates below its usual position: if the artery be exposed at its point of bifurcation,



both divisions of the vessel should be tied near their origin, in preference to tying the trunk of the artery near its termination; and if, in consequence of the entire absence of the common carotid, or from its early division, two arteries, the external and internal carotids, are met with, the ligature should be placed on that vessel which is found on compression to be connected with the disease.

In this operation, the direction of the vessel and the inner margin of the Sterno-mastoid are the chief guides to its performance. The patient should be placed on his back with the head thrown back and turned slightly to the opposite side: an incision is to be made, three inches long, in the direction of the anterior border of the Sterno-mastoid, so that the centre corresponds to the level of the cricoid cartilage: after dividing the integument, superficial fascia, and Platysma, the deep fascia must be cut through on a director, so as to avoid wounding numerous small veins that are usually found beneath. The head may now be brought forwards so as to relax the parts somewhat, and the margins of the wound held asunder by retractors. The descendens hypoglossi nerve may now be exposed, and must be avoided, and the sheath of the vessel having been raised by forceps, is to be opened to a small extent over the artery at its inner side. The internal jugular vein may present itself alternately distended and relaxed; this should be compressed, both above and below, and drawn outwards, in order to facilitate the operation. The aneurism needle is passed from the outside, care being taken to keep the needle in close contact with the artery, and thus avoid the risk of injuring the internal jugular vein, or including the vagus nerve. Before the ligature is tied, it should be ascertained that nothing but the artery is included in it.

*Ligature of the Common Carotid at the Lower Part of the Neck.*—This operation is sometimes required in cases of aneurism of the upper part of the carotid, especially if the sac is of large size. It is best performed by dividing the sternal origin of the Sterno-mastoid muscle, but may be done in some cases, if the aneurism is not of very large size, by an incision along the anterior border of the Sterno-mastoid, extending down to the sterno-clavicular articulation, and by then retracting the muscle. The easiest and best plan, however, is to make an incision two or three inches long down the lower part of the anterior border of the Sterno-mastoid muscle to the sterno-clavicular joint, and a second incision, starting from the termination of the first, along the upper border of the clavicle for about two inches. This incision is made through the superficial and deep fascia, and the sternal origin of the muscle exposed. This is to be divided on a director and turned up, with the superficial structures, as a triangular flap. Some loose connective tissue is to be divided or torn through, and the outer border of the Sterno-hyoid muscle exposed. In doing this, care must be taken not to wound the anterior jugular vein, which crosses the muscle to reach the external jugular or subclavian vein. The Sterno-hyoid, and with it the Sterno-thyroid, are to be drawn inwards by means of a retractor, and the sheath of the vessel is exposed. This must be opened with great care on its inner or tracheal side, so as to avoid the internal jugular vein. This is especially necessary on the left side, where the artery is commonly overlapped by the vein. On the right side there is usually an interval between the artery and the vein, and not the same risk of wounding the latter.

The common carotid artery, being a long vessel without any branches, is particularly suitable for the performance of Brasdor's operation for the cure of an aneurism of the lower part of the vessel. Brasdor's procedure consists in ligaturing the artery on the distal side of the aneurism, and in the case of the common carotid there are no branches given off from the vessel between the aneurism and the site of the ligature, hence the flow of blood through the sac of the aneurism is diminished and cure takes place in the usual way, by the deposit of laminated fibrin.

*Collateral Circulation.*—After ligature of the common carotid, the collateral circulation can be perfectly established, by the free communication which exists between the carotid arteries of opposite sides, both without and within the cranium, and by enlargement of the branches of the subclavian artery on the side corresponding to that on which the vessel has been tied—the chief communication outside the skull taking place between the superior and inferior thyroid arteries, and the profunda cervicis and arteria princeps cervicis of the occipital; the vertebral taking the place of the internal carotid within the cranium.

Sir A. Cooper had an opportunity of dissecting, thirteen years after the operation, the case in which he first successfully tied the common carotid (the second case in which he performed the operation).\* The injection, however, does not seem to have been a successful one. It showed merely that the arteries at the base of the brain (circle of Willis) were much enlarged on the side of the tied artery, and that the anastomosis between the branches of the external carotid on the affected side and those of the same artery on the sound side was free, so that the external carotid was pervious throughout.

\* *Guy's Hospital Reports*, i. 56.



## EXTERNAL CAROTID ARTERY

The **external carotid artery** (fig. 386) commences opposite the upper border of the thyroid cartilage, and, taking a slightly curved course, passes upwards and forwards, and then inclines backwards to the space between the neck of the condyle of the lower jaw and the external meatus, where it divides into the temporal and internal maxillary arteries. It rapidly diminishes in size in its course up the neck, owing to the number and large size of the branches given off from it. In the child, it is somewhat smaller than the internal carotid; but in the adult, the two vessels are of nearly equal size. At its commencement, this artery is more superficial, and placed nearer the middle line than the internal carotid, and is contained in the triangular space bounded by the Sterno-mastoid behind, the Omo-hyoid below, and the posterior belly of the Digastric and Stylo-hyoid above.

**Relations.**—It is covered by the skin, superficial fascia, Platysma, deep fascia, and anterior margin of the Sterno-mastoid, crossed by the hypoglossal nerve, and by the lingual and facial veins; it is afterwards crossed by the Digastric and Stylo-hyoid muscles, and higher up passes deeply into the substance of the parotid gland, where it lies beneath the facial nerve and the junction of the temporal and internal maxillary veins. *Internally* is the hyoid bone, wall of the pharynx, the superior laryngeal nerve, and the ramus of the jaw, from which it is separated by a portion of the parotid gland. *Externally*, in the lower part of its course, is the internal carotid artery. *Behind* it, near its origin, is the superior laryngeal nerve; and higher up, it is separated from the internal carotid by the Stylo-glossus and Stylo-pharyngeus muscles, the glosso-pharyngeal nerve, and part of the parotid gland.

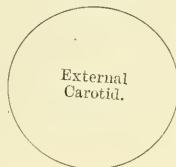## PLAN OF THE RELATIONS OF THE EXTERNAL CAROTID

*In front.*

Skin, superficial fascia.  
 Platysma and deep fascia.  
 Anterior border of Sterno-mastoid.  
 Hypoglossal nerve.  
 Lingual and facial veins.  
 Digastric and Stylo-hyoid muscles. [substance.  
 Parotid gland with facial nerve and temporo-maxillary vein in its

*Internally.*

Hyoid bone.  
 Pharynx.  
 Superior laryngeal nerve.  
 Parotid gland.  
 Ramus of jaw.

*Externally.*

Internal carotid artery.

*Behind.*

Superior laryngeal nerve.  
 Stylo-glossus.  
 Stylo-pharyngeus.  
 Glosso-pharyngeal nerve.  
 Parotid gland.

**Surface Marking.**—The position of the external carotid artery may be marked out with sufficient accuracy by a line drawn from the front of the meatus of the external ear to the side of the cricoid cartilage, slightly arching the line forwards.

**Surgical Anatomy.**—The application of a ligature to the external carotid may be required in cases of wounds of this vessel, or of its branches when these cannot be tied, and in some cases of pulsating tumours of the scalp or face. The operation has not received the attention which it deserves, owing to the fear which surgeons have entertained of secondary hæmorrhage, on account of the number of branches given off from the vessel. This fear, however, has been shown by Mr. Cripps not to be well founded.\* To tie this

\* *Med.-Chir. Trans.* lxi. 229.

vessel near its origin, below the point where it is crossed by the Digastric, an incision about three inches in length should be made along the margin of the Sterno-mastoid, from the angle of the jaw to the upper border of the thyroid cartilage. The ligature should be applied between the lingual and superior thyroid branches. To tie the vessel above the Digastric, between it and the parotid gland, an incision should be made, from the lobe of the ear to the great cornu of the os hyoides dividing successively the skin, Platysma, and fascia. By drawing the Sterno-mastoid outwards, and the posterior belly of the Digastric and Stylo-hyoid muscles downwards, and separating them from the parotid gland, the vessel will be exposed, and a ligature may be applied to it. The circulation is at once re-established by the free communication between most of the large branches of the artery (facial, lingual, superior thyroid, occipital) and the corresponding arteries of the opposite side, and by the anastomosis of its branches with those of the internal carotid, and of the occipital with branches of the subclavian, etc.

**Branches.**—The external carotid artery gives off eight branches, which, for convenience of description, may be divided into four sets. (See fig. 387, Plan of the Branches.)

<i>Anterior.</i>	<i>Posterior.</i>	<i>Ascending.</i>	<i>Terminal.</i>
Superior Thyroid.	Occipital.	Ascending Pha-	Superficial Temporal.
Lingual.	Posterior Auricular.	ryngeal.	Internal Maxillary.
Facial.			

The student is here reminded that many variations are met with in the number, origin, and course of these branches in different subjects; but the above arrangement is that which is found in the great majority of cases.

The **Superior Thyroid Artery** (figs. 386 and 391) is the first branch given off from the external carotid, being derived from that vessel just below the great cornu of the hyoid bone. At its commencement, it is quite superficial, being covered by the integument, fascia, and Platysma, and is contained in the triangular space bounded by the Sterno-mastoid, Digastric, and Omo-hyoid muscles. After running upwards and inwards for a short distance, it curves downwards and forwards, in an arched and tortuous manner, to the upper part of the thyroid gland, passing beneath the Omo-hyoid, Sterno-hyoid, and Sterno-thyroid muscles and supplying them. It distributes numerous branches to the upper part of the gland, anastomosing with its fellow of the opposite side, and with the inferior thyroid arteries. The branches supplying the gland are generally three in number: one, the largest, supplies principally the anterior surface of the gland: it courses along the inner border of the lobe as far as the upper border of the isthmus, and then passes in the substance of the isthmus to the middle line of the neck, where it anastomoses with the corresponding artery of the opposite side: a second branch courses along the external border of the lobe and supplies this portion of the gland, and the third passes to the posterior surface, the upper part of which it supplies. Besides the arteries distributed to the muscles by which it is covered and the substance of the gland, the branches of the superior thyroid are the following:—

Hyoid.	Superior Laryngeal.
Superficial descending branch (Sterno-mastoid).	Crico-thyroid.

The **hyoid (infra-hyoid)** is a small branch which runs along the lower border of the os hyoides beneath the Thyro-hyoid muscle; after supplying the muscles connected to that bone, it forms an arch, by anastomosing with the vessels of the opposite side.

The **superficial descending branch** runs downwards and outwards across the sheath of the common carotid artery, and supplies the Sterno-mastoid and neighbouring muscles and integument. There is also often a distinct branch from the external carotid distributed to the Sterno-mastoid muscle.

The **superior laryngeal**, larger than either of the preceding, accompanies the superior laryngeal nerve, beneath the Thyro-hyoid muscle; it pierces the thyro-hyoid membrane, and supplies the muscles, mucous membrane, and glands of the larynx, anastomosing with the branch from the opposite side.

The **crico-thyroid** is a small branch which runs transversely across the crico-thyroid membrane, communicating with the artery of the opposite side.

*Surgical Anatomy.*—The superior thyroid, or some of its branches, is often divided in cases of cut throat, giving rise to considerable hæmorrhage. In such cases, the artery should be secured, the wound being enlarged for that purpose, if necessary. The operation may be easily performed, the position of the artery being very superficial, and the only structures of importance covering it being a few small veins. The operation of tying the superior thyroid artery, in bronchocele, has been performed in numerous instances with partial or temporary success. When, however, the collateral circulation between this vessel and the artery of the opposite side, and the inferior thyroid, is completely re-established, the tumour usually regains its former size.

The position of the superficial descending branch is of importance in connection with the operation of ligature of the common carotid artery. It crosses and lies on the sheath of this vessel and may chance to be wounded in opening the sheath. The position of the crico-thyroid branch should be remembered, as it may prove the source of troublesome hæmorrhage during the operation of laryngotomy.

The **Lingual Artery** (fig. 391) arises from the external carotid between the superior thyroid and facial; it first runs obliquely upwards and inwards to the great cornu of the hyoid bone; it then curves downwards and forwards, forming a loop which is crossed by the hypoglossal nerve, and passing beneath the Digastric and Stylo-hyoid muscles, it runs horizontally forwards, beneath the Hyo-glossus, and finally, ascending perpendicularly to the tongue, turns forwards on its under surface as far as the tip, under the name of the *ranine artery*.

**Relations.**—Its first, or oblique, portion is superficial, being contained in the same triangular space as the superior thyroid artery, resting upon the Middle constrictor of the pharynx, and covered by the Platysma, and fascia of the neck. Its second, or curved, portion also lies upon the Middle constrictor, being covered at first by the tendon of the Digastric and the Stylo-hyoid muscle, and afterwards by the Hyo-glossus, the latter muscle separating it from the hypoglossal nerve. Its third, or horizontal, portion lies between the Hyo-glossus and Genio-hyo-glossus muscles. The fourth, or terminal, part, under the name of the *ranine*, runs along the under surface of the tongue to its tip: here it is very superficial, being covered only by the mucous membrane, and rests on the Lingualis, on the outer side of the Genio-hyo-glossus. The hypoglossal nerve crosses the lingual artery, and then becomes separated from it, in the second part of its course, by the Hyo-glossus muscle.

The branches of the lingual artery are, the

Hyoid.	Sublingual.
Dorsalis Linguae.	Ranine.

The **hyoid branch** (*supra-hyoid*) runs along the upper border of the hyoid bone, supplying the muscles attached to it and anastomosing with its fellow of the opposite side.

The **dorsalis linguæ** (fig. 391) arises from the lingual artery beneath the Hyo-glossus muscle (which, in the figure, has been partly cut away, to show the vessel); it ascends to the dorsum of the tongue, and supplies the mucous membrane, the tonsil, soft palate, and epiglottis; anastomosing with its fellow from the opposite side.

The **sublingual**, which may be described as a branch of bifurcation of the lingual artery, arises at the anterior margin of the Hyo-glossus muscle, and runs forward between the Genio-hyo-glossus and the sublingual gland. It supplies the substance of the gland, giving branches to the Mylo-hyoid and neighbouring muscles, the mucous membrane of the mouth and gums. One branch runs behind the alveolar process of the lower jaw in the substance of the gum to anastomose with a similar artery from the other side.

The **ranine** may be regarded as the other branch of bifurcation, or, as is more usual, as the continuation of the lingual artery; it runs along the under surface of the tongue, resting on the Inferior lingualis, and covered by the mucous



membrane of the mouth; it lies on the outer side of the Genio-hyo-glossus, accompanied by the lingual nerve. On arriving at the tip of the tongue, it has been said to anastomose with the artery of the opposite side; but this is denied by Hyrtl. These vessels in the mouth are placed one on each side of the frænum.

*Surgical Anatomy.*—The lingual artery may be divided near its origin in cases of cut throat, a complication that not unfrequently happens in this class of wounds; or severe hæmorrhage which cannot be restrained by ordinary means, may ensue from a wound, or deep ulcer, of the tongue. In the former case, the primary wound may be enlarged if necessary, and the bleeding vessel secured. In the latter case, it has been suggested that the lingual artery should be tied near its origin. Ligature of the lingual artery is also occasionally practised, as a palliative measure, in cases of cancer of the tongue, in order to check the progress of the disease by starving the growth, and it is sometimes tied, as a preliminary measure to removal of the tongue. The operation is a difficult one, on account of the depth of the artery, the number of important parts by which it is surrounded, the loose and yielding nature of the parts upon which it is supported, and its occasional irregularity of origin. An incision is to be made in a curved direction from a finger's breadth external to the symphysis of the jaw downwards to the cornu of the hyoid bone, and then upwards to near the angle of the jaw. Care must be taken not to carry this incision too far backwards, for fear of endangering the facial vein. In the first incision the skin, superficial fascia, and Platysma will be divided, and the deep fascia exposed. This is then to be incised and the submaxillary gland exposed and pulled upwards by retractors. A triangular space is now exposed, bounded internally by the posterior border of the Mylo-hyoid muscle; below and externally, by the tendon of the Digastric; and above, by the hypoglossal nerve. The floor of the space is formed by the Hyo-glossus muscle, beneath which the artery lies. The fibres of this muscle are now to be cut through horizontally, and the vessel exposed, care being taken, while near the vessel, not to open the pharynx.

Troublesome hæmorrhage may occur in the division of the frænum in children, if the ranine artery, which lies on each side of it, is wounded. The student should remember that the operation is always to be performed with a pair of blunt-pointed scissors, and the mucous membrane only is to be divided by a very superficial cut, which cannot endanger any vessel. The scissors, also, should be directed away from the tongue. Any further liberation of the tongue which may be necessary can be effected by tearing.

The **Facial Artery** (fig. 388) arises a little above the lingual, and passes obliquely upwards, beneath the Digastric and Stylo-hyoid muscles; it then runs forwards under cover of the body of the lower jaw, lodged in a groove on the posterior surface of the submaxillary gland; this may be called the cervical part of the artery. It then curves upwards over the body of the jaw at the anterior inferior angle of the Masseter muscle; passes forwards and upwards across the cheek to the angle of the mouth, then upwards along the side of the nose, and terminates at the inner canthus of the eye, under the name of the *angular artery*. This vessel, both in the neck and on the face, is remarkably tortuous: in the former situation, to accommodate itself to the movements of the pharynx in deglutition; and in the latter, to the movements of the jaw, and the lips and cheeks.

**Relations**—*In the neck*, its origin is superficial, being covered by the integument, Platysma, and fascia; it then passes beneath the Digastric and Stylo-hyoid muscles, and the submaxillary gland. *On the face*, where it passes over the body of the lower jaw, it is comparatively superficial, lying immediately beneath the Platysma. In this situation its pulsation may be distinctly felt, and compression of the vessel effectually made against the bone for a time. In its course over the face, it is covered by the integument, the fat of the cheek, and, near the angle of the mouth, by the Platysma, Risorius, and Zygomatici muscles. It rests on the Buccinator, the Levator anguli oris, and the Levator labii superioris (sometimes piercing or else passing under this last muscle). It is accompanied by the facial vein throughout its entire course; the vein is not tortuous like the artery, and, on the face, is separated from that vessel by a considerable interval, lying to its outer side. The branches of the facial nerve cross the artery, and the infra-orbital nerve lies beneath it.

The branches of this vessel may be divided into two sets: those given off below the jaw (cervical), and those on the face (facial).

*Cervical Branches.*

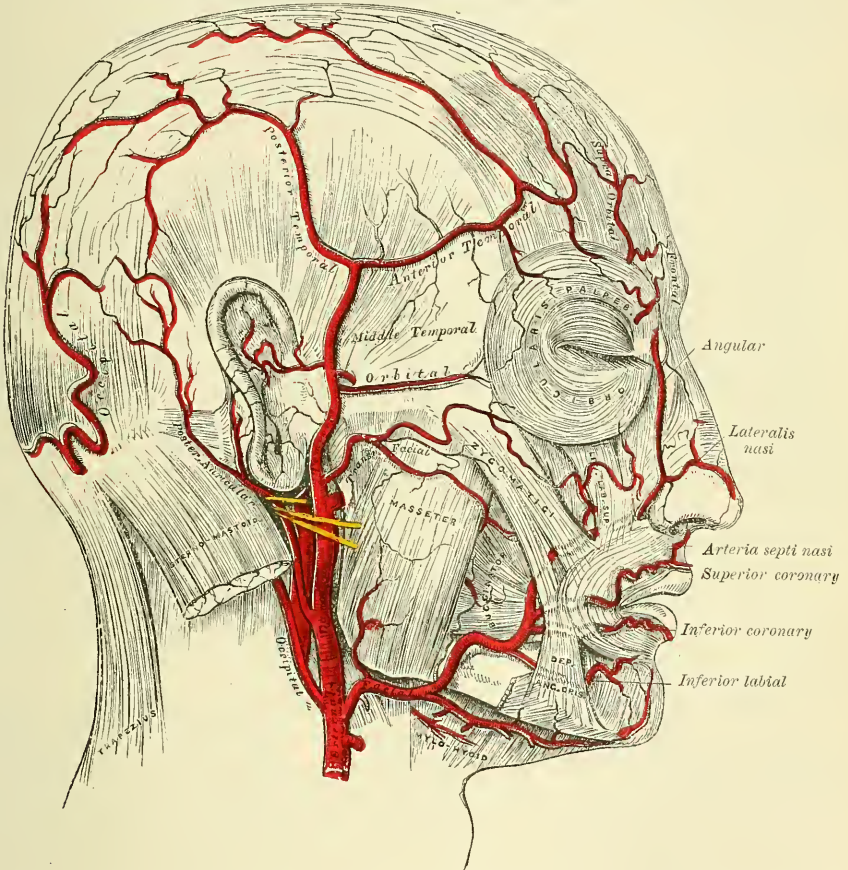
- Inferior or Ascending Palatine.
- Tonsillar.
- Submaxillary.
- Submental.
- Muscular.

*Facial Branches.*

- Muscular.
- Inferior Labial.
- Inferior Coronary.
- Superior Coronary.
- Lateralis Nasi.
- Angular.

The inferior or ascending palatine (fig. 391) passes up between the Stylo-glossus and Stylo-pharyngeus to the outer side of the pharynx, along which it is continued between the Superior constrictor and the Internal pterygoid to near the base of the skull. It supplies the neighbouring muscles, the tonsil, and

FIG. 388.—The arteries of the face and scalp.\*



Eustachian tube, and divides, near the Levator palati, into two branches: one follows the course of the Levator palati, and, winding over the upper border of the Superior constrictor, supplies the soft palate and the palatine glands, anastomosing with its fellow of the opposite side and with the posterior palatine branch of the internal maxillary artery; the other pierces the Superior constrictor and supplies the tonsil, anastomosing with the tonsillar artery.

The tonsillar branch (fig. 391) passes up between the Internal Pterygoid and Stylo-glossus, and then ascends along the side of the pharynx, perforating the Superior constrictor, to ramify in the substance of the tonsil and root of the tongue.

\* The muscular tissue of the lips must be supposed to have been cut away, in order to show the course of the coronary arteries.



The **submaxillary** consist of three or four large branches, which supply the submaxillary gland, some being prolonged to the neighbouring muscles, lymphatic glands, and integument.

The **submental**, the largest of the cervical branches, is given off from the facial artery just as that vessel quits the submaxillary gland: it runs forwards upon the Mylo-hyoid muscle, just below the body of the jaw, and beneath the Digastric; after supplying the surrounding muscles, and anastomosing with the sublingual artery by branches which perforate the Mylo-hyoid muscle, it arrives at the symphysis of the chin, where it turns over the border of the jaw and divides into a superficial and a deep branch; the former passes between the integument and Depressor labii inferioris, supplies both, and anastomoses with the inferior labial. The deep branch passes between the latter muscle and the bone, supplies the lip, and anastomoses with the inferior labial and mental arteries.

The **muscular branches** are distributed to the Internal pterygoid and Stylohyoid in the neck, and to the Masseter and Buccinator on the face.

The **inferior labial** passes beneath the Depressor anguli oris, to supply the muscles and integument of the lower lip, anastomosing with the inferior coronary and submental branches of the facial, and with the mental branch of the inferior dental artery.

The **inferior coronary** is derived from the facial artery, near the angle of the mouth; it passes upwards and inwards beneath the Depressor anguli oris, and, penetrating the Orbicularis oris muscle, runs in a tortuous course along the edge of the lower lip between this muscle and the mucous membrane, inosculating with the artery of the opposite side. This artery supplies the labial glands, the mucous membrane, and muscles of the lower lip; and anastomoses with the inferior labial and the mental branch of the inferior dental artery.

The **superior coronary** is larger and more tortuous in its course than the preceding. It follows the same course along the edge of the upper lip, lying between the mucous membrane and the Orbicularis oris, and anastomoses with the artery of the opposite side. It supplies the textures of the upper lip, and gives off in its course two or three vessels which ascend to the nose. One, named the *inferior artery of the septum*, ramifies on the septum of the nares as far as the point of the nose; another, the *artery of the ala*, supplies the ala of the nose.

The **lateralis nasi** is derived from the facial, as that vessel is ascending along the side of the nose; it supplies the ala and dorsum of the nose, anastomosing with its fellow, the nasal branch of the ophthalmic, the inferior artery of the septum, the artery of the ala, and the infra-orbital.

The **angular artery** is the termination of the trunk of the facial; it ascends to the inner angle of the orbit, embedded in the fibres of the Levator labii superioris aequae nasi, and accompanied by a large vein, the *angular*; it distributes some branches on the cheek which anastomose with the infra-orbital, and, after supplying the lachrymal sac and Orbicularis palpebrarum muscle, terminates by anastomosing with the nasal branch of the ophthalmic artery.

The anastomoses of the facial artery are very numerous, not only with the vessel of the opposite side, but, in the neck, with the sublingual branch of the lingual; with the ascending pharyngeal; with the posterior palatine, a branch of the internal maxillary, by its inferior or ascending palatine and tonsillar branches; on the face, with the mental branch of the inferior dental as it emerges from the mental foramen; with the transverse facial, a branch of the temporal; with the infra-orbital, a branch of the internal maxillary; and with the nasal branch of the ophthalmic.

*Peculiarities.*—The facial artery not unfrequently arises by a common trunk with the lingual. This vessel is also subject to some variations in its size, and in the extent to which it supplies the face. It occasionally terminates as the submental, and not unfrequently supplies the face only as high as the angle of the mouth or nose. The deficiency is then supplied by enlargement of one of the neighbouring arteries.



*Surgical Anatomy.*—The passage of the facial artery over the body of the jaw would appear to afford a favourable position for the application of pressure in cases of hæmorrhage from the lips, the result either of an accidental wound or during an operation; but its application is useless, except for a very short time, on account of the free communication of this vessel with its fellow, and with numerous branches from different sources. In a wound involving the lip, it is better to seize the part between the fingers, and evert it, when the bleeding vessel may be at once secured with pressure-forceps. In order to prevent hæmorrhage in cases of removal of diseased growths from the part, the lip should be compressed on each side between the fingers and thumb, or by a pair of specially devised clamp-forceps, whilst the surgeon excises the diseased part. In order to stop hæmorrhage where the lip has been divided in an operation, it is necessary, in uniting the edges of the wound, to pass the sutures through the cut edges, almost as deep as its mucous surface; by these means, not only are the cut surfaces more neatly and securely adapted to each other, but the possibility of hæmorrhage is prevented by including in the suture the divided artery. If the suture is, on the contrary, passed through merely the cutaneous portion of the wound, hæmorrhage occurs into the cavity of the mouth. The student should, lastly, observe the relation of the angular artery to the lachrymal sac, and it will be seen that, as the vessel passes up along the inner margin of the orbit, it ascends on its nasal side. In operating for fistula lachrymalis, the sac should always be opened on its outer side, in order that this vessel may be avoided.

The **Occipital Artery** (fig. 388) arises from the posterior part of the external carotid, opposite the facial, near the lower margin of the Digastric muscle. At its origin, it is covered by the posterior belly of the Digastric and Stylo-hyoid muscles, and the hypoglossal nerve winds around it from behind forwards; higher up, it passes across the internal carotid artery, the internal jugular vein, and the pneumogastric and spinal accessory nerves; it then ascends to the interval between the transverse process of the atlas and the mastoid process of the temporal bone, and passes horizontally backwards, grooving the surface of the latter bone, being covered by the Sterno-mastoid, Splenius, Trachelo-mastoid, and Digastric muscles, and resting upon the Rectus lateralis, the Superior oblique, and Complexus muscles; it then changes its course and passes vertically upwards, pierces the fascia which connects the cranial attachment of the Trapezius with the Sterno-mastoid, and ascends in a tortuous course over the occiput, as high as the vertex, where it divides into numerous branches. It is accompanied in the latter part of its course by the great occipital and a cutaneous filament from the suboccipital nerve.

The branches given off from this vessel are,—

Muscular.	Auricular.
Sterno-mastoid.	Meningeal.
Arteria Princeps Cervicis.	

The **muscular branches** supply the Digastric, Stylo-hyoid, Splenius, and Trachelo-mastoid muscles.

The **sterno-mastoid** is a large and constant branch, generally arising from the artery close to its commencement. It first passes upwards and backwards, and then turns downwards over the hypoglossal nerve, and enters the substance of the muscle, frequently in company with the spinal accessory nerve.

The **auricular branch** supplies the back part of the concha. It frequently gives off a branch, which enters the skull through the mastoid foramen and supplies the dura mater, the diploë, and the mastoid cells.

The **meningeal branch** ascends with the internal jugular vein, and enters the skull through the foramen lacerum posterius, to supply the dura mater in the posterior fossa.

The **arteria princeps cervicis** (fig. 391) is a large branch which descends along the back part of the neck, and divides into a superficial and deep portion. The former runs beneath the Splenius, giving off branches which perforate that muscle to supply the Trapezius, anastomosing with the superficial cervical artery, a branch of the transversalis colli: the latter passes beneath the Complexus, between it and the Semispinalis colli, and anastomoses with branches from the vertebral and with the deep cervical artery, a branch of the superior intercostal.

The anastomosis between these vessels serves mainly to establish the collateral circulation after ligation of the carotid or subclavian artery.

The cranial branches of the occipital artery are distributed upon the occiput: they are very tortuous, and lie between the integument and Occipito-frontalis, anastomosing with the artery of the opposite side, the posterior auricular and temporal arteries. They supply the back part of the Occipito-frontalis muscle, the integument, and pericranium.

The **Posterior Auricular Artery** (fig. 388) is a small vessel which arises from the external carotid, above the Digastric and Stylo-hyoid muscles, opposite the apex of the styloid process. It ascends, under cover of the parotid gland, to the groove between the cartilage of the ear and the mastoid process, immediately above which it divides into its two terminal branches, the auricular and mastoid. Just before arriving at the mastoid process, this artery is crossed by the portio dura, and has beneath it the spinal accessory nerve.

Besides several small branches to the Digastric, Stylo-hyoid, and Sternomastoid muscles, and to the parotid gland, this vessel gives off three branches:—

Stylo-mastoid.

Auricular.

Mastoid.

The **stylo-mastoid branch** enters the stylo-mastoid foramen, and supplies the tympanum, mastoid cells, and semicircular canals. In the young subject a branch from this vessel forms, with the tympanic branch from the internal maxillary, a vascular circle, which surrounds the auditory meatus, and from which delicate vessels ramify on the membrana tympani. It anastomoses with the petrosal branch of the middle meningeal artery by a twig, which enters the hiatus Fallopii.

The **auricular branch**, one of the terminal branches, ascends behind the ear, beneath the Retrahens aurem muscle, and is distributed to the back part of the cartilage of the ear, upon which it ramifies minutely, some branches curving round the margin of the fibro-cartilage, others perforating it, to supply its anterior surface. It anastomoses with the posterior branch of the superficial temporal and also with its anterior auricular branches.

The **mastoid branch** passes backwards, over the Sternomastoid muscle, to the scalp above and behind the ear. It supplies the posterior belly of the Occipito-frontalis muscle and the scalp in this situation. It anastomoses with the occipital artery.

The **Ascending Pharyngeal Artery** (fig. 391), the smallest branch of the external carotid, is a long, slender vessel, deeply seated in the neck, beneath the other branches of the external carotid and the Stylo-pharyngeus muscle. It arises from the back part of the external carotid, near the commencement of that vessel, and ascends vertically between the internal carotid and the side of the pharynx, to the under surface of the base of the skull, lying on the Rectus capitis anticus major. Its branches may be subdivided into four sets:—

Prevertebral.

Pharyngeal.

Tympanic.

Meningeal.

The **prevertebral branches** are numerous small vessels, which supply the Recti capitis antici and Longus colli muscles, the sympathetic, hypoglossal, and pneumogastric nerves, and the lymphatic glands of the neck, anastomosing with the ascending cervical artery.

The **pharyngeal branches** are three or four in number. Two of these descend to supply the middle and inferior Constrictors and the Stylo-pharyngeus, ramifying in their substance and in the mucous membrane lining them. The largest of the pharyngeal branches passes inwards, running upon the Superior constrictor, and sends ramifications to the soft palate and tonsil, which take the place of the ascending palatine branch of the facial artery, when that vessel is of small size. A twig from this branch supplies the Eustachian tube.

The **tympanic branch** is a small artery which passes through a minute foramen in the petrous portion of the temporal bone, in company with the tympanic

branch of the Glosso-pharyngeal nerve to supply the inner wall of the tympanum and anastomose with the other tympanic arteries.

The **meningeal branches** consist of several small vessels, which pass through foramina in the base of the skull, to supply the dura mater. One, the posterior meningeal, enters the cranium through the foramen lacerum posterius; a second passes through the foramen lacerum medium; and occasionally a third through the anterior condyloid foramen. They are all distributed to the dura mater.

*Surgical Anatomy.*—The ascending pharyngeal artery has been wounded from the throat; as in the case in which the stem of a tobacco-pipe was driven into the vessel, causing fatal hæmorrhage.

The **Superficial Temporal Artery** (fig. 388), the smaller of the two terminal branches of the external carotid, appears, from its direction, to be the continuation of that vessel. It commences in the substance of the parotid gland, in the interspace between the neck of the condyle of the lower jaw and the external auditory meatus, crosses over the posterior root of the zygoma, passes beneath the *Attrahens aurem* muscle, lying on the temporal fascia, and divides, about two inches above the zygomatic arch, into two branches, an anterior and a posterior.

The **anterior temporal** inclines forwards over the forehead, supplying the muscles, integument, and pericranium in this region, and anastomoses with the supra-orbital and frontal arteries.

The **posterior temporal**, larger than the anterior, curves upwards and backwards along the side of the head, lying superficial to the temporal fascia, and inosculates with its fellow of the opposite side, and with the posterior auricular and occipital arteries.

The superficial temporal artery, as it crosses the zygoma, is covered by the *Attrahens aurem* muscle, and by a dense fascia given off from the parotid gland: it is crossed by the temporo-facial division of the facial nerve and one or two veins, and is accompanied by the auriculo-temporal nerve, which lies behind it. Besides some twigs to the parotid gland, the articulation of the jaw, and the *Masseter* muscle, its branches are, the

Transverse Facial.

Middle Temporal.

Anterior Auricular.

The **transverse facial** is given off from the temporal before that vessel quits the parotid gland; running forwards through its substance, it passes transversely across the face, between Stenson's duct and the lower border of the zygoma, and divides on the side of the face into numerous branches, which supply the parotid gland, the *Masseter* muscle, and the integument, anastomosing with the facial, masseteric, and infra-orbital arteries. This vessel rests on the *Masseter*, and is accompanied by one or two branches of the facial nerve. It is sometimes a branch of the external carotid.

The **middle temporal artery** arises immediately above the zygomatic arch, and, perforating the temporal fascia, supplies the Temporal muscle, anastomosing with the deep temporal branches of the internal maxillary. It occasionally gives off an orbital branch, which runs along the upper border of the zygoma, between the two layers of the temporal fascia, to the outer angle of the orbit. This branch supplies the *Orbicularis palpebrarum*, and anastomoses with the lachrymal and palpebral branches of the ophthalmic artery.

The **anterior auricular branches** are distributed to the anterior portion of the pinna, the lobule, and part of the external meatus, anastomosing with branches of the posterior auricular.

*Surgical Anatomy.*—It occasionally happens that the surgeon is called upon to perform the operation of arteriotomy upon this vessel in cases of inflammation of the eye or brain. If the student will consider the relations of the trunk of this vessel, as it crosses the zygomatic arch, with the surrounding structures, he will observe that it is covered by a thick and dense fascia, crossed by one of the main divisions of the facial nerve and one



or two veins, and accompanied by the auriculo-temporal nerve. Bleeding should not be performed in this situation, as much difficulty may arise from the dense fascia over the vessel preventing a free flow of blood, and considerable pressure is requisite afterwards to arrest the hæmorrhage. Again, a varicose aneurism may be formed by the accidental opening of one of the veins in front of the artery; or severe neuralgic pain may arise from the operation implicating one of the nervous filaments in the neighbourhood. The anterior branch, on the contrary, is subcutaneous, is a large vessel, and is readily compressed; it should consequently always be selected for the operation.

The **Internal Maxillary** (fig. 389), the larger of the two terminal branches of the external carotid, arises from that vessel opposite the neck of the condyle of the lower jaw, and is at first embedded in the substance of the parotid gland; it passes

FIG. 389.—The internal maxillary artery, and its branches.

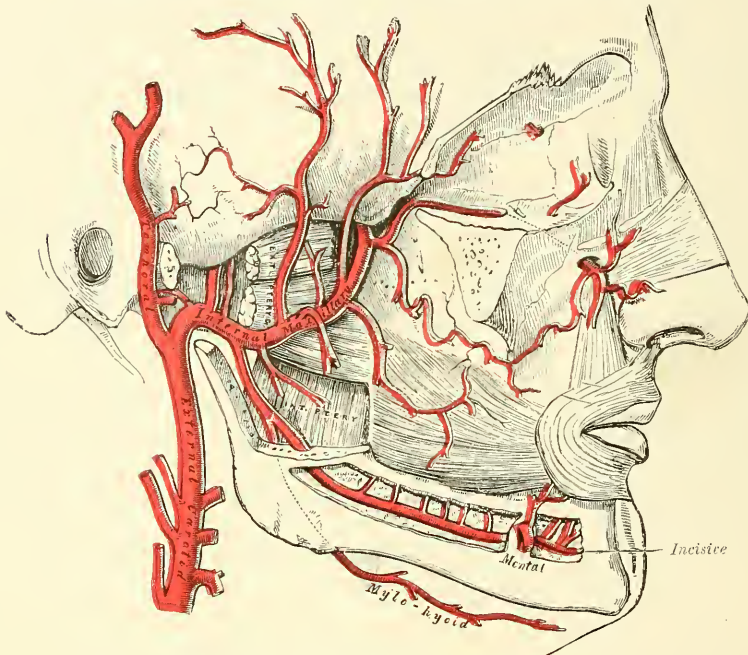
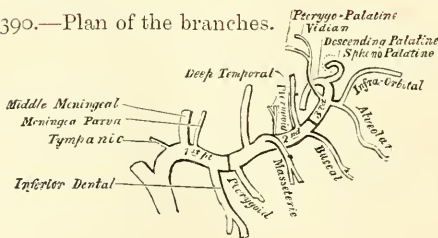


FIG. 390.—Plan of the branches.



inwards between the ramus of the jaw and the internal lateral ligaments, and then upon the outer surface of the External pterygoid muscle to the sphenomaxillary fossa to supply the deep structures of the face. For convenience of description, it is divided into three portions: a maxillary, a pterygoid, and a sphenomaxillary.

In the first part of its course (*maxillary portion*), the artery passes horizontally forwards and inwards, between the ramus of the jaw and the internal lateral ligament. The artery here lies parallel to and a little below the auriculo-temporal nerve; it crosses the inferior dental nerve, and lies along the lower border of the External pterygoid muscle.

In the second part of its course (*pterygoid portion*), it runs obliquely forwards and upwards upon the outer surface of the External pterygoid muscle, being

covered by the ramus of the lower jaw, and lower part of the Temporal muscle; or it may pass on the inner surface of the External pterygoid muscle to reach the interval between its two heads, between which it passes to reach the spheno-maxillary fossa.

In the third part of its course (*spheno-maxillary portion*), it approaches the superior maxillary bone, and enters the spheno-maxillary fossa in the interval between the two heads of the External pterygoid, where it lies in relation with Meckel's ganglion, and gives off its terminal branches.

The branches of this vessel may be divided into three groups, corresponding with its three divisions.

BRANCHES OF THE FIRST OR MAXILLARY PORTION (fig. 390)

Tympanic (anterior).	Small Meningeal.
Deep Auricular.	Inferior Dental.
Middle Meningeal.	

The **tympanic branch** passes upwards behind the articulation of the lower jaw, enters the tympanum through the Glaserian fissure, and ramifies upon the membrana tympani, forming a vascular circle around the membrane with the stylo-mastoid artery, and anastomosing with the Vidian and the tympanic branch from the internal carotid.

The **deep auricular branch** often arises in common with the preceding. It passes upwards in the substance of the parotid gland, behind the temporo-maxillary articulation, pierces the cartilaginous or bony wall of the external auditory meatus, and supplies its cuticular lining and the outer surface of the membrana tympani.

The **middle meningeal** is the largest of the branches which supply the dura mater. It arises from the internal maxillary, between the internal lateral ligament and the neck of the jaw, and passes vertically upwards between the two roots of the auriculo-temporal nerve to the foramen spinosum of the sphenoid bone. On entering the cranium, it divides into two branches, anterior and posterior. The *anterior branch*, the larger, crosses the great ala of the sphenoid, and reaches the groove, or canal, in the anterior inferior angle of the parietal bone: it then divides into branches which spread out between the dura mater and internal surface of the cranium, some passing upwards over the parietal bone as far as the vertex, and others backwards to the occipital bone. The *posterior branch* crosses the squamous portion of the temporal, and on the inner surface of the parietal bone divides into branches which supply the posterior part of the dura mater and cranium. The branches of this vessel are distributed partly to the dura mater, but chiefly to the bones; they anastomose with the arteries of the opposite side, and with the anterior and posterior meningeal.

The middle meningeal on entering the cranium gives off the following collateral branches: 1. Numerous small vessels to the Gasserian ganglion, and to the dura mater in this situation. 2. A branch (*petrosal branch*), which enters the hiatus Fallopii, supplies the facial nerve, and anastomoses with the stylo-mastoid branch of the posterior auricular artery. 3. Orbital branches, which pass through the sphenoidal fissure, or through separate canals in the great wing of the sphenoid to anastomose with the lachrymal or other branches of the ophthalmic artery. 4. Temporal branches, which pass through foramina in the great wing of the sphenoid, and anastomose in the temporal fossa with the deep temporal arteries.

*Surgical Anatomy.*—The middle meningeal is an artery of considerable surgical importance, as it may be injured in fractures of the temporal region of the skull, and the injury may be followed by considerable hæmorrhage between the bone and dura mater, which may cause compression of the brain, and require the operation of trephining for its relief. This artery crosses the anterior inferior angle of the parietal bone at a point  $1\frac{1}{2}$  inch behind the external angular process of the frontal bone, and  $1\frac{3}{4}$  inch above the

zygoma. From this point the anterior branch passes upwards and slightly backwards to the sagittal suture, lying about  $\frac{1}{2}$  inch to  $\frac{3}{4}$  inch behind the coronal suture. The posterior branch passes upwards and backwards over the squamous portion of the temporal bone. In order to expose the artery as it lies in the canal in the parietal bone, a semilunar incision, with its convexity upwards, should be made, commencing an inch behind the external angular process, and carried backwards for 2 inches. The structures cut through are: (1) skin; (2) superficial fascia, with branches of the superficial temporal vessels and nerves; (3) the fascia continued down from the aponeurosis of the Occipito-frontalis; (4) the two layers of the temporal fascia; (5) the temporal muscle; (6) the deep temporal vessels; (7) the pericranium; and (8) the bone.

The **small meningeal** is sometimes derived from the preceding. It enters the skull through the foramen ovale, and supplies the Gasserian ganglion and dura mater. Before entering the cranium it gives off a branch to the nasal fossæ, soft palate, and tonsil.

The **inferior dental** descends with the dental nerve to the foramen on the inner side of the ramus of the jaw. It runs along the dental canal in the substance of the bone, accompanied by the nerve, and opposite the first bicuspid tooth divides into two branches, incisor and mental; the *former* is continued forwards beneath the incisor teeth as far as the symphysis, where it anastomoses with the artery of the opposite side; the *mental* branch escapes with the nerve at the mental foramen, supplies the structures composing the chin, and anastomoses with the submental, inferior labial, and inferior coronary arteries. Near its origin the inferior dental artery gives off a *lingual* branch, which descends with the lingual (gustatory) nerve and supplies the mucous membrane of the mouth. As the inferior dental artery enters the foramen, it gives off a *mylo-hyoid* branch, which runs in the mylo-hyoid groove, and ramifies on the under surface of the Mylo-hyoid muscle. The dental and incisor arteries during their course through the substance of the bone give off a few twigs which are lost in the cancellous tissue, and a series of branches which correspond in number to the roots of the teeth: these enter the minute apertures at the extremities of the fangs, and supply the pulp of the teeth.

#### BRANCHES OF THE SECOND OR PTERYGOID PORTION

Deep Temporal.	Masseteric.
Pterygoid.	Buccal.

These branches are distributed, as their names imply, to the muscles in the maxillary region.

The **deep temporal branches**, two in number, anterior and posterior, each occupy that part of the temporal fossa indicated by its name. Ascending between the Temporal muscle and pericranium, they supply that muscle, and anastomose with the middle temporal artery; the anterior branch communicating with the lachrymal through small branches which perforate the malar bone and great wing of the sphenoid.

The **pterygoid branches**, irregular in their number and origin, supply the Pterygoid muscles.

The **masseteric** is a small branch which passes outwards, above the sigmoid notch of the lower jaw, to the deep surface of the Masseter. It supplies that muscle, and anastomoses with the masseteric branches of the facial and with the transverse facial artery.

The **buccal** is a small branch which runs obliquely forwards, between the Internal pterygoid and the ramus of the jaw, to the outer surface of the Buccinator, to which it is distributed, anastomosing with branches of the facial artery.

#### BRANCHES OF THE THIRD OR SPHENO-MAXILLARY PORTION

Alveolar.	Vidian.
Infra-orbital.	Pterygo-palatine.
Posterior or Descending Palatine.	Naso- or Spheno-palatine.



The **alveolar** or **posterior dental branch** is given off from the internal maxillary, frequently by a common branch with the infra-orbital, just as the trunk of the vessel is passing into the sphenomaxillary fossa. Descending upon the tuberosity of the superior maxillary bone, it divides into numerous branches, some of which enter the posterior dental canals, to supply the molar and bicuspid teeth and the lining of the antrum, and others are continued forwards on the alveolar process to supply the gums.

The **infra-orbital** appears, from its direction, to be the continuation of the trunk of the internal maxillary. It often arises from that vessel by a common trunk with the preceding branch, and runs along the infra-orbital canal with the superior maxillary nerve, emerging upon the face at the infra-orbital foramen, beneath the Levator labii superioris. Whilst contained in the canal, it gives off branches which ascend into the orbit, and supply the Inferior rectus and Inferior oblique muscles and the lachrymal gland. Other branches (*anterior dental*) descend through canals in the bone, to supply the mucous membrane of the antrum, and the front teeth of the upper jaw. On the face, some branches pass upwards to the inner angle of the orbit and the lachrymal sac, anastomosing with the angular branch of the facial artery; other branches pass inwards towards the nose, anastomosing with the nasal branch of the ophthalmic; and other branches descend beneath the Levator labii superioris, and anastomose with the transverse facial and buccal arteries.

The four remaining branches arise from that portion of the internal maxillary which is contained in the sphenomaxillary fossa.

The **descending palatine** passes down the posterior palatine canal with the anterior palatine branch of Meckel's ganglion, and, emerging from the posterior palatine foramen, runs forwards in a groove on the inner side of the alveolar border of the hard palate to the anterior palatine canal, where the terminal branch of the artery passes upwards through the foramen of Stenson to anastomose with the nasopalatine artery. Its branches are distributed to the gums, the mucous membrane of the hard palate, and the palatine glands. Whilst it is contained in the palatine canal, it gives off branches, which descend in the accessory palatine canals to supply the soft palate and tonsil, anastomosing with the ascending palatine artery.

*Surgical Anatomy.*—The position of the descending palatine artery on the hard palate should be borne in mind in performing an operation for the closure of a cleft in the hard palate, as it is in danger of being wounded, and may give rise to formidable hæmorrhage. In one case, in which it was wounded, it was necessary to plug the posterior palatine canal in order to arrest the bleeding.

The **Vidian branch** passes backwards along the Vidian canal with the Vidian nerve. It is distributed to the upper part of the pharynx and Eustachian tube, sending a small branch into the tympanum, which anastomoses with the anterior tympanic.

The **pterygo-palatine** is also a very small branch, which passes backwards through the pterygo-palatine canal with the pharyngeal nerve, and is distributed to the upper part of the pharynx and Eustachian tube.

The **spheno-palatine** passes through the spheno-palatine foramen into the cavity of the nose, at the back part of the superior meatus, and divides into two branches: one internal, the *naso-palatine* or *superior artery of the septum*, passes obliquely downwards and forwards along the septum nasi, supplies the mucous membrane, and anastomoses in front with the terminal branch of the descending palatine. The external branches, two or three in number, supply the mucous membrane covering the lateral wall of the nose, the antrum, and the ethmoid and sphenoid cells.

#### THE TRIANGLES OF THE NECK

The student having considered the relative anatomy of the large arteries of the neck and their branches, and the relations they bear to the veins and nerves,

should now examine these structures collectively, as they present themselves in certain regions of the neck, in each of which important operations are constantly being performed.

The side of the neck presents a somewhat quadrilateral outline, limited, above, by the lower border of the body of the jaw, and an imaginary line extending from the angle of the jaw to the mastoid process; below, by the prominent upper border of the clavicle; in front, by the median line of the neck; behind, by the anterior margin of the Trapezius muscle. This space is subdivided into two large triangles by the Sterno-mastoid muscle, which passes obliquely across the neck, from the sternum and clavicle below, to the mastoid process above. The triangular space in front of this muscle is called the *anterior triangle*; and that behind it, the *posterior triangle*.

#### ANTERIOR TRIANGLE OF THE NECK

The **anterior triangle** is bounded, in front, by a line extending from the chin to the sternum; behind, by the anterior margin of the Sterno-mastoid; its base, directed upwards, is formed by the lower border of the body of the jaw, and a line extending from the angle of the jaw to the mastoid process; its apex is below, at the sternum. This space is subdivided into three smaller triangles by the Digastric muscle above, and the anterior belly of the Omo-hyoid below. These smaller triangles are named, from below upwards, the inferior carotid, the superior carotid, and the submaxillary triangle.

The **Inferior Carotid Triangle** is bounded, in front, by the median line of the neck; behind, by the anterior margin of the Sterno-mastoid; above, by the anterior belly of the Omo-hyoid; and is covered by the integument, superficial fascia, Platysma, and deep fascia; ramifying between which are some of the descending branches of the superficial cervical plexus. Beneath these superficial structures are the Sterno-hyoid and Sterno-thyroid muscles, which, together with the anterior margin of the Sterno-mastoid, conceal the lower part of the common carotid artery.\*

This vessel is enclosed within its sheath, together with the internal jugular vein and pneumogastric nerve; the vein lying on the outer side of the artery on the right side of the neck, but overlapping it, or passing directly across it on the left side; the nerve lying between the artery and vein, on a plane posterior to both. In front of the sheath are a few filaments descending from the loop of communication between the descendens and communicans hypoglossi; behind the sheath are seen the inferior thyroid artery, the recurrent laryngeal nerve, and the sympathetic nerve; and on its inner side, the trachea, the thyroid gland—much more prominent in the female than in the male—and the lower part of the larynx. By cutting into the upper part of this space, and slightly displacing the Sterno-mastoid muscle, the common carotid artery may be tied below the Omo-hyoid muscle.

The floor of the inferior carotid triangle is formed by the Longus colli muscle below, and by the Scalenus anticus above (see fig. 321, page 423), between which muscles the vertebral artery and vein will be found passing into the foramen in the sixth transverse process; a small portion of the origin of the Rectus capitis anticus major may also be seen in the floor of the space.

The **Superior Carotid Triangle** is bounded, behind, by the Sterno-mastoid; below, by the anterior belly of the Omo-hyoid; and above, by the posterior belly of the Digastric muscle. It is covered by the integument, superficial fascia, Platysma, and deep fascia; ramifying between which are branches of the facial

\* Therefore the common carotid artery and internal jugular vein are not, strictly speaking, contained in this triangle, since they are covered by the Sterno-mastoid muscle; that is to say, lie behind the anterior border of that muscle, which forms the posterior border of the triangle. But as they lie very close to the structures which are really contained in the triangle, and whose position it is essential to remember in operating on this part of the artery, it has seemed expedient to study the relations of all these parts together.

nerve and superficial cervical plexus. Its floor is formed by parts of the Thyro-hyoid, Hyo-glossus, and the Inferior and Middle constrictor muscles of the pharynx. This space contains the upper part of the common carotid artery, which bifurcates opposite the upper border of the thyroid cartilage into the external and internal carotid. These vessels are occasionally somewhat concealed from view by the anterior margin of the Sterno-mastoid muscle, which overlaps them. The external and internal carotids lie side by side, the external being the more anterior of the two. The following branches of the external carotid are also met with in this space: the superior thyroid, running forwards and downwards; the lingual, directly forwards; the facial, forwards and upwards; the occipital, backwards; and the ascending pharyngeal directly upwards on the inner side of the internal carotid. The veins met with are: the internal jugular, which lies on the outer side of the common and internal carotid arteries; and veins corresponding to the above-mentioned branches of the external carotid—viz. the superior thyroid, the lingual, facial, ascending pharyngeal, and sometimes the occipital—all of which accompany their corresponding arteries, and terminate in the internal jugular. The nerves in this space are the following: In front of the sheath of the common carotid is the descendens hypoglossi. The hypoglossal nerve crosses both the internal and external carotid above, curving round the occipital artery at its origin. Within the sheath, between the artery and vein, and behind both, is the pneumogastric nerve; behind the sheath, the sympathetic. On the outer side of the vessels, the spinal accessory nerve runs for a short distance before it pierces the Sterno-mastoid muscle; and on the inner side of the external carotid, just below the hyoid bone, may be seen the superior laryngeal nerve; and, still more inferiorly, the external laryngeal nerve. The upper part of the larynx and lower part of the pharynx are also found in the front part of this space.

The **Submaxillary Triangle** corresponds to the part of the neck immediately beneath the body of the jaw. It is bounded, above, by the lower border of the body of the jaw, and a line drawn from its angle to the mastoid process; below, by the posterior belly of the Digastric and Stylo-hyoid muscles; in front, by the middle line of the neck. It is covered by the integument, superficial fascia, Platysma, and deep fascia; ramifying between which are branches of the facial and ascending filaments of the superficial cervical nerves. Its floor is formed by the anterior belly of the Digastric, the Mylo-hyoid, and Hyo-glossus muscles. This space contains, in front, the submaxillary gland, imbedded in the substance of which are the facial artery and vein, and their glandular branches; beneath this gland, on the surface of the Mylo-hyoid muscle, are the submental artery and the mylo-hyoid artery and nerve. The back part of this space is separated from the front part by the stylo-maxillary ligament; it contains the external carotid artery, ascending deeply in the substance of the parotid gland; this vessel here lies in front of, and superficial to, the internal carotid, being crossed by the facial nerve, and gives off in its course the posterior auricular, temporal, and internal maxillary branches: more deeply are the internal carotid, the internal jugular vein, and the pneumogastric nerve, separated from the external carotid by the Stylo-glossus and Stylo-pharyngeus muscles, and the glosso-pharyngeal nerve.\*

#### POSTERIOR TRIANGLE OF THE NECK

The **posterior triangle** is bounded, in front, by the Sterno-mastoid muscle; behind, by the anterior margin of the Trapezius; its base corresponds to the upper border of the clavicle; its apex, to the occiput. The space is crossed, about

\* The same remark will apply to this triangle as was made about the inferior carotid triangle. The structures enumerated as contained in the back part of the space lie, strictly speaking, beneath the muscles which form the posterior boundary of the triangle; but as it is very important to bear in mind their close relation to the parotid gland and its boundaries (on account of the frequency of surgical operations on this gland), all these parts are spoken of together.



an inch above the clavicle, by the posterior belly of the Omo-hyoid, which divides it unequally into two, an upper or occipital, and a lower or subclavian, triangle.

The **Occipital**, the larger of the two posterior triangles, is bounded, in front, by the Sterno-mastoid; behind, by the Trapezius; below, by the Omo-hyoid. Its floor is formed from above downwards by the Splenius, Levator anguli scapulae, and the Middle and Posterior scalmi muscles. It is covered by the integument, the Platysma below, the superficial and deep fasciæ, and by the spinal accessory nerve which is directed obliquely across the space from the Sterno-mastoid, which it pierces, to the under surface of the Trapezius; below, the descending branches of the cervical plexus and the transversalis colli artery and vein cross the space. A chain of lymphatic glands is also found running along the posterior border of the Sterno-mastoid, from the mastoid process to the root of the neck.

The **Subclavian**, the smaller of the two posterior triangles, is bounded, above, by the posterior belly of the Omo-hyoid; below, by the clavicle; its base, directed forwards, being formed by the Sterno-mastoid. The size of the subclavian triangle varies according to the extent of attachment of the clavicular portion of the Sterno-mastoid and Trapezius muscles, and also according to the height at which the Omo-hyoid crosses the neck above the clavicle. Its height also varies much, according to the position of the arm, being much diminished by raising the limb, on account of the ascent of the clavicle, and increased by drawing the arm downwards, when that bone is depressed. This space is covered by the integument, superficial and deep fasciæ; and crossed by the descending branches of the cervical plexus. Just above the level of the clavicle, the third portion of the subclavian artery curves outwards and downwards from the outer margin of the Scalenus anticus, across the first rib, to the axilla. Sometimes this vessel rises as high as an inch and a half above the clavicle, or to any point intermediate between this and its usual level. Occasionally, it passes in front of the Scalenus anticus, or pierces the fibres of that muscle. The subclavian vein lies behind the clavicle, and is usually not seen in this space; but it occasionally rises as high up as the artery, and has even been seen to pass with that vessel behind the Scalenus anticus. The brachial plexus of nerves lies above the artery, and in close contact with it. Passing transversely across the clavicular margin of the space, are the suprascapular vessels; and traversing its upper angle in the same direction, the transversalis colli artery and vein. The external jugular vein runs vertically downwards behind the posterior border of the Sterno-mastoid, to terminate in the subclavian vein; it receives the transverse cervical and suprascapular veins, which occasionally form a plexus in front of the artery, and a small vein which crosses the clavicle from the cephalic. The small nerve to the Subclavius muscle also crosses this triangle about its middle. A lymphatic gland is also found in the space. Its floor is formed by the first rib with the first digitation of the Serratus magnus.

#### INTERNAL CAROTID ARTERY

The **internal carotid artery** supplies the anterior part of the brain, the eye and its appendages, and sends branches to the forehead and nose. Its size, in the adult, is equal to that of the external carotid, though, in the child, it is larger than that vessel. It is remarkable for the number of curvatures that it presents in different parts of its course. In its cervical portion it occasionally presents one or two flexures near the base of the skull, whilst through the rest of its extent it describes a double curvature which resembles the italic letter *s* placed horizontally. These curvatures most probably diminish the velocity of the current of blood, by increasing the extent of surface over which it moves, and adding to the amount of impediment produced from friction.

In considering the course and relations of this vessel, it may be conveniently divided into four portions: a cervical, petrous, cavernous, and cerebral.

**Cervical Portion.**—This portion of the internal carotid commences at the bifurcation of the common carotid, opposite the upper border of the thyroid cartilage, and runs perpendicularly upwards, in front of the transverse processes of the three upper cervical vertebræ, to the carotid canal in the petrous portion of the temporal bone. It is superficial at its commencement, being contained in the superior carotid triangle, and lying on the same level as the external carotid, but behind that artery, overlapped by the Sterno-mastoid, and covered by the deep fascia, Platysma, and integument: it then passes beneath the parotid gland, being crossed by the hypoglossal nerve, the Digastric and Stylo-hyoid muscles, and the occipital and posterior auricular arteries. Higher up, it is separated from the external carotid by the Stylo-glossus and Stylo-pharyngeus muscles, the glosso-pharyngeal nerve, and pharyngeal branch of the pneumogastric. It is in relation, *behind*, with the Rectus capitis anticus major, the superior cervical ganglion of the sympathetic, and superior laryngeal nerve; *externally*, with the internal jugular vein and pneumogastric nerve; the nerve lying on a plane posterior to the artery; *internally*, with the pharynx, tonsil, the superior laryngeal nerve, and ascending pharyngeal artery.

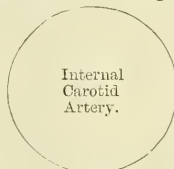
PLAN OF THE RELATIONS OF THE INTERNAL CAROTID ARTERY IN THE NECK

*In front.*

Skin, superficial and deep fasciæ.  
 Platysma.  
 Sterno-mastoid.  
 Occipital and posterior auricular arteries.  
 Hypoglossal nerve.  
 Parotid gland.  
 Stylo-glossus and Stylo-pharyngeus muscles.  
 Glosso-pharyngeal nerve.  
 Pharyngeal branch of the pneumogastric.

*Externally.*

Internal jugular vein.  
 Pneumogastric nerve.



*Internally*

Pharynx.  
 Superior laryngeal nerve.  
 Ascending pharyngeal artery.  
 Tonsil.

*Behind.*

Rectus capitis anticus major.  
 Sympathetic.  
 Superior laryngeal nerve.

**Petrous Portion.**—When the internal carotid artery enters the canal in the petrous portion of the temporal bone, it first ascends a short distance, then curves forwards and inwards, and again ascends as it leaves the canal to enter the cavity of the skull between the lingula and petrosal process. In this canal, the artery lies at first in front of the cochlea and tympanum; from the latter cavity it is separated by a thin, bony lamella, which is cribriform in the young subject, and often absorbed in old age. Farther forwards it is separated from the Gasserian ganglion by a thin plate of bone, which is sometimes perforated and forms the floor of the fossa for the ganglion and the roof of the horizontal portion of the canal. The artery is separated from the bony wall of the carotid canal by a prolongation of dura mater, and is surrounded by filaments of the carotid plexus and a number of small veins.

**Cavernous Portion.**—The internal carotid artery, in this part of its course, is situated between the layers of the dura mater forming the cavernous sinus, but covered by the lining membrane of the sinus. It at first ascends to the posterior clinoid process, then passes forwards by the side of the body of the sphenoid bone, and again curves upwards on the inner side of the anterior clinoid process, and perforates the dura mater forming the roof of the sinus. In this part of its course it is surrounded by filaments of the sympathetic nerve, and has in relation with it externally the sixth nerve.





internal carotid being replaced by two branches of the internal maxillary, which entered the skull through the foramen rotundum and ovale, and joined to form a single vessel.

*Surgical Anatomy.*—The cervical part of the internal carotid is very rarely wounded. Mr. Cripps, in an interesting paper in the 'Medico-Chirurgical Transactions,' compares the rareness of a wound of the internal carotid with one of the external carotid or its branches. It is, however, sometimes injured by a stab or gunshot wound in the neck, or even occasionally by a stab from within the mouth, as when a person receives a thrust from the end of a parasol, or falls down with a tobacco-pipe in his mouth. The relation of the internal carotid with the tonsil should be especially remembered, as instances have occurred in which the artery has been wounded during the operation of scarifying the tonsil, and fatal hæmorrhage has supervened. The indications for ligature are wounds, when the vessel should be exposed by a careful dissection and tied above and below the bleeding-point; and aneurism, which if non-traumatic may be treated by ligature of the common carotid; but if traumatic in origin, by exposing the sac and tying the vessel above and below. The incision for ligature of the cervical portion of the internal carotid should be made along the anterior border of the Sterno-mastoid, from the angle of the jaw to the upper border of the thyroid cartilage. The superficial structures being divided, and the Sterno-mastoid defined and drawn outwards, the cellular tissue must be carefully separated and the posterior belly of the Digastric and hypoglossal nerve sought for as guides to the vessel. When the artery is found, the external carotid should be drawn inwards and the Digastric muscle upwards, and the aneurism needle passed from without inwards.

**Branches.**—The branches given off from the internal carotid are :—

<i>From the Petrous portion</i>	Tympanic (internal or deep).
<i>From the Cavernous portion</i>	{ Arteriæ Receptaculi.
	{ Anterior Meningeal.
	{ Ophthalmic.
<i>From the Cerebral portion</i>	{ Anterior Cerebral.
	{ Middle Cerebral.
	{ Posterior Communicating.
	{ Anterior Choroid.

The cervical portion of the internal carotid gives off no branches.

The **tympanic** is a small branch which enters the cavity of the tympanum, through a minute foramen in the carotid canal, and anastomoses with the tympanic branch of the internal maxillary, and with the stylo-mastoid artery.

The **arteriæ receptaculi** are numerous small vessels, derived from the internal carotid in the cavernous sinus; they supply the pituitary body, the Gasserian ganglion, and the walls of the cavernous and inferior petrosal sinuses. Some of these branches anastomose with branches of the middle meningeal.

The **anterior meningeal** is a small branch which passes over the lesser wing of the sphenoid to supply the dura mater of the anterior fossa; it anastomoses with the meningeal branch from the posterior ethmoidal artery.

The **Ophthalmic Artery** arises from the internal carotid, just as that vessel is emerging from the cavernous sinus, on the inner side of the anterior clinoid process, and enters the orbit through the optic foramen, below and on the outer side of the optic nerve. It then passes over the nerve to the inner wall of the orbit, and thence horizontally forwards, beneath the lower border of the Superior oblique muscle to a point behind the internal angular process of the frontal bone, where it divides into two terminal branches, the *frontal* and *nasal*.

The branches of this vessel may be divided into an *orbital group*, which are distributed to the orbit and surrounding parts; and an *ocular group*, which supply the muscles and globe of the eye.

*Orbital Group.*

Lachrymal.  
Supra-orbital.  
Posterior Ethmoidal.  
Anterior Ethmoidal.  
Internal Palpebral.  
Frontal.  
Nasal.

*Ocular Group.*

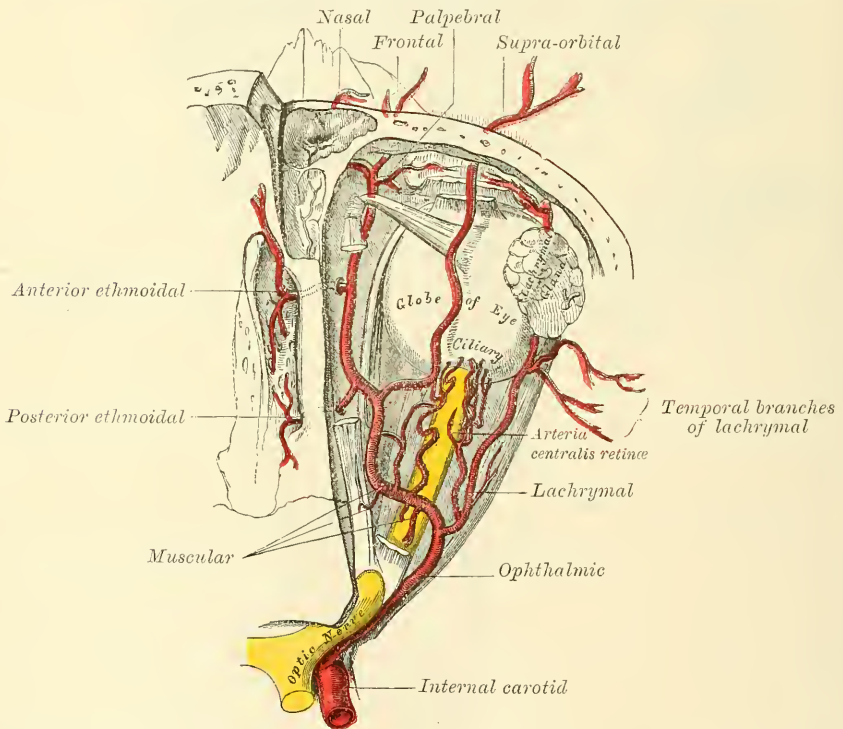
Muscular.  
Anterior Ciliary.  
Short Ciliary.  
Long Ciliary.  
Arteria Centralis Retinæ.

The *lacrimal* is the first, and one of the largest branches derived from the ophthalmic, arising close to the optic foramen: not unfrequently it is given off from the artery before it enters the orbit. It accompanies the lacrimal nerve along the upper border of the External rectus muscle, and is distributed to the lacrimal gland. Its terminal branches, escaping from the gland, are distributed to the eyelids and conjunctiva: of those supplying the eyelids, two are of considerable size and are named the *external palpebral*; they run inwards in the upper and lower lids respectively and anastomose with the internal palpebral arteries, forming an arterial circle in this situation. The lacrimal artery gives off one or two *malar branches*, one of which passes through a foramen in the malar bone, to reach the temporal fossa, and anastomoses with the deep temporal arteries; the other appears on the cheek, and anastomoses with the transverse facial. A branch is also sent backwards, through the sphenoidal fissure, to the dura mater, which anastomoses with a branch of the middle meningeal artery.

*Peculiarities.*—The lacrimal artery is sometimes derived from one of the anterior branches of the middle meningeal artery.

The *supra-orbital artery* arises from the ophthalmic as that vessel is crossing over the optic nerve. Ascending so as to rise above all the muscles of the orbit,

FIG. 392.—The ophthalmic artery and its branches, the roof of the orbit having been removed.



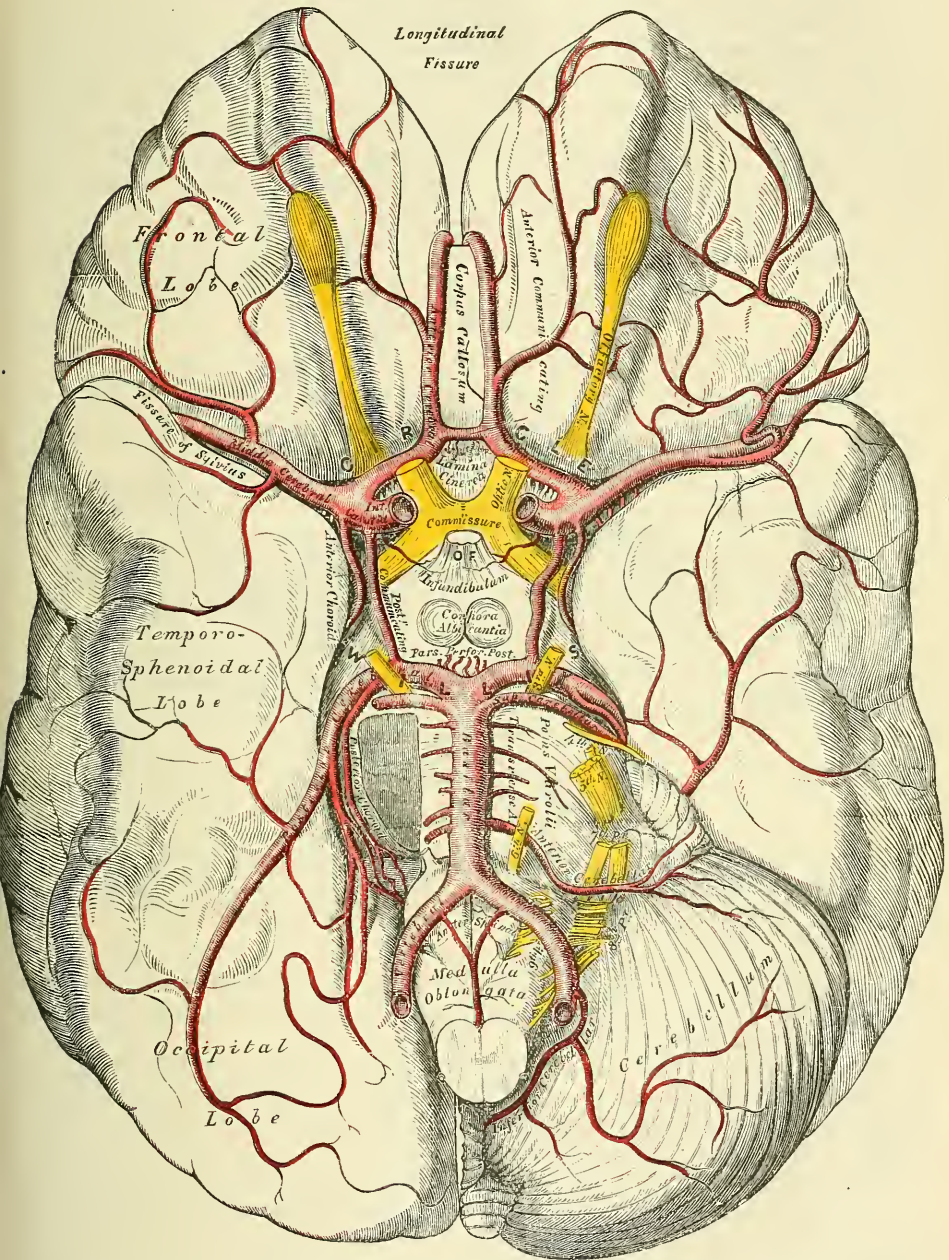
it passes forwards, with the supra-orbital nerve, between the periosteum and Levator palpebræ; and, passing through the supra-orbital foramen, divides into a superficial and deep branch, which supply the integument, the muscles, and the pericranium of the forehead, anastomosing with the frontal, the anterior branch of the temporal, and the artery of the opposite side. This artery in the orbit supplies the Superior rectus and the Levator palpebræ, and sends a branch inwards, across the pulley of the Superior oblique muscle, to supply the parts at the inner canthus. At the supra-orbital foramen it frequently transmits a branch to the diploë.

The *ethmoidal branches* are two in number: posterior and anterior. The



former, which is the smaller, passes through the posterior ethmoidal foramen, supplies the posterior ethmoidal cells, and, entering the cranium, gives off a meningeal branch, which supplies the adjacent dura mater; and nasal branches which descend into the nose through apertures in the cribriform plate, anasto-

FIG. 393.—The arteries of the base of the brain. The right half of the cerebellum and pons have been removed.



N.B.—It will be noticed that in the illustration the two anterior cerebral arteries have been drawn at a considerable distance from each other; this makes the anterior communicating artery appear very much longer than it really is.

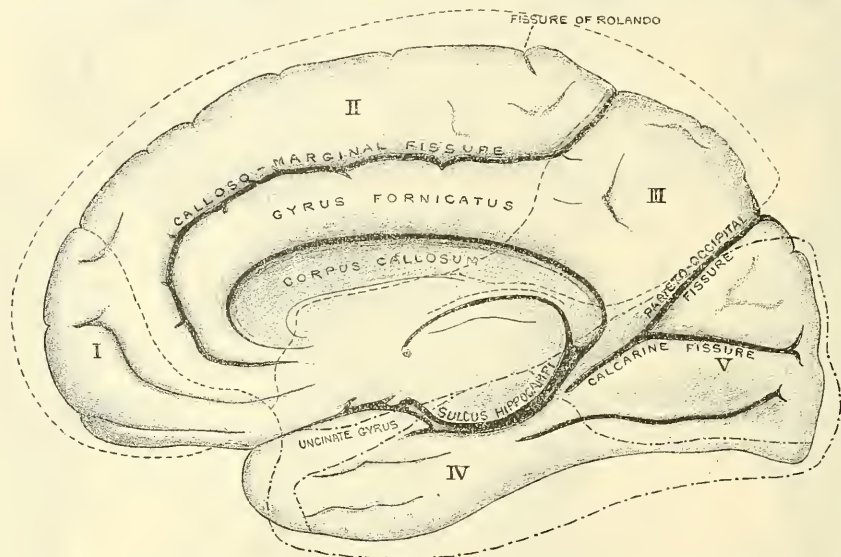
mosing with branches of the spheno-palatine. The anterior ethmoidal artery accompanies the nasal nerve through the anterior ethmoidal foramen, supplies



the anterior ethmoidal cells and frontal sinuses, and, entering the cranium, gives off a meningeal branch, which supplies the adjacent dura mater; and nasal branches, which descend into the nose, through the slit by the side of the crista galli; and running along the groove on the under surface of the nasal bone supplies the skin of the nose.

The *palpebral arteries*, two in number, superior and inferior, arise from the ophthalmic, opposite the pulley of the Superior oblique muscle; they leave the orbit to encircle the eyelids near their free margin, forming a superior and an inferior arch, which lie between the Orbicularis muscle and tarsal plates; the superior palpebral inosculating, at the outer angle of the orbit, with the orbital branch of the temporal artery, and with the upper of the two external palpebral branches from the lachrymal artery: the inferior palpebral inosculating, at the outer angle of the orbit, with the lower of the two external palpebral branches from the lachrymal and with the transverse facial artery, and, at the inner side

FIG. 394.—Vascular areae of the internal surface of the cerebrum. (After Charcot.)



The regions marked off by the line (---) represent the area of distribution of the anterior cerebral artery. I. Anterior and internal frontal arteries. II. Middle and internal frontal arteries. III. Posterior and internal frontal arteries. The regions marked off by the line (—) represent the area of distribution of the posterior cerebral arteries: IV. to the temporo-sphenoidal lobe; V. to the cuneus and occipital lobe; a third branch supplies the unciniate gyrus.

of the lid, with a branch from the angular artery. From this last anastomosis a branch passes to the nasal duct, ramifying in its mucous membrane, as far as the inferior meatus.

The *frontal artery*, one of the terminal branches of the ophthalmic, passes from the orbit at its inner angle, and, ascending on the forehead, supplies the integument, muscles, and pericranium, anastomosing with the supra-orbital artery, and with the artery of the opposite side.

The *nasal artery*, the other terminal branch of the ophthalmic, emerges from the orbit above the tendo oculi, and, after giving a branch to the upper part of the lachrymal sac, divides into two branches, one of which crosses the root of the nose, the *transverse nasal*, and anastomoses with the angular artery; the other, the *dorsalis nasi*, runs along the dorsum of the nose, supplies its outer surface, and anastomoses with the artery of the opposite side, and with the lateral nasal branch of the facial.

The *ciliary arteries* are divisible into three groups, the short, long, and anterior. The *short ciliary arteries*, from six to twelve in number, arise from the

ophthalmic, or some of its branches; they surround the optic nerve as they pass forwards to the posterior part of the eyeball, pierce the sclerotic coat around the entrance of the nerve, and supply the choroid coat and ciliary processes. The *long ciliary arteries*, two in number, also pierce the posterior part of the sclerotic, and run forwards, along each side of the eyeball, between the sclerotic and choroid, to the ciliary muscle, where they divide into two branches; these form an arterial circle around the circumference of the iris, from which numerous radiating branches pass forwards, in its substance, to its free margin, where they form a second arterial circle around its pupillary margin. The *anterior ciliary arteries* are derived from the muscular branches; they pass to the front of the eyeball in company with the tendons of the recti muscles, form a vascular zone beneath the conjunctiva and then pierce the sclerotic a short distance from the cornea and terminate in the great arterial circle of the iris.

The *arteria centralis retinae* is one of the smallest branches of the ophthalmic artery. It arises from the ophthalmic as that vessel is about to cross over the optic nerve; it pierces the optic nerve obliquely, and runs forward in the centre of its substance, and enters the globe of the eye through the porus opticus. Its mode of distribution will be described in the account of the anatomy of the eye.

The *muscular branches*, two in number, superior and inferior, supply the muscles of the eyeball. The superior, the smaller, often wanting, supplies the Levator palpebrae, Superior rectus, and Superior oblique. The inferior, more constant in its existence, passes forwards, between the optic nerve and Inferior rectus, and is distributed to the External, Internal, and Inferior recti, and Inferior oblique. This vessel gives off most of the anterior ciliary arteries.

The *anterior cerebral* arises from the internal carotid, at the inner extremity of the fissure of Sylvius. It passes forwards and inwards across the anterior perforated space, between the first and second cranial nerves, to the commencement of the great longitudinal fissure. Here it comes into close relationship with the artery of the opposite side, and the two vessels are connected together by a short anastomosing trunk, about two lines in length, the *anterior communicating* artery. From this point, the two vessels run side by side in the longitudinal fissure, curve round the anterior border of the corpus callosum, and turning backwards continue along its upper surface to its posterior part, where they terminate by anastomosing with the posterior cerebral arteries. In their course they give off the following branches:—

Antero-median Ganglionic.	Middle and Internal Frontal.
Anterior and Internal Frontal.	Posterior and Internal Frontal.

The *antero-median ganglionic* is a group of small arteries which arise at the commencement of the anterior cerebral artery; they pierce the anterior perforated space and lamina cinerea, and supply the head of the caudate nucleus.

The *anterior* and *internal frontal branches* supply the two inferior frontal convolutions. The *middle* and *internal frontal branches* supply the corpus callosum, the convolution of the corpus callosum, the inner surface of the first frontal convolution, and the upper part of the ascending frontal convolution. The *posterior* and *internal frontal branches* supply the lobus quadratus.

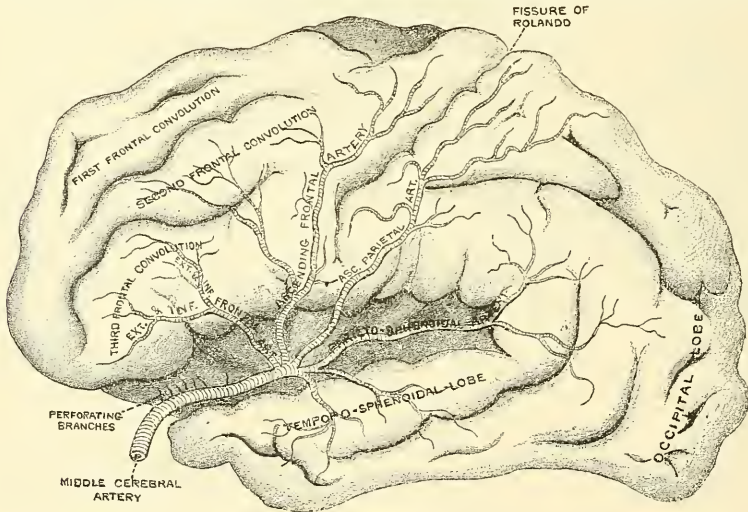
The *anterior communicating artery* is a short branch about two lines in length, but of moderate size, connecting together the two anterior cerebral arteries across the longitudinal fissure. Sometimes this vessel is wanting, the two arteries joining together to form a single trunk, which afterwards divides. Or the vessel may be wholly, or partially, divided into two; frequently, it is longer and smaller than usual. It gives off some of the antero-median ganglionic group of vessels, which are, however, principally derived from the anterior cerebral.

The **middle cerebral artery** (fig. 395), the largest branch of the internal carotid, passes obliquely outwards along the fissure of Sylvius, and, opposite the island of Reil, divides into its terminal branches. The branches of the middle cerebral artery are:—

Antero-lateral Ganglionic.	Ascending Frontal.
External and Inferior Frontal.	Ascending Parietal.
Parieto-sphenoidal.	

The *antero-lateral ganglionic branches* are a group of small arteries which arise at the commencement of the middle cerebral artery; they pierce the anterior perforated space and supply the greater part of the caudate nucleus, the lenticular nucleus, the internal capsule, and a part of the optic thalamus. One artery of this group, distributed to the lenticular nucleus, is of larger size than the rest, and is of special importance, as being the artery in the brain most frequently ruptured; it has been termed by Charcot, the '*artery of cerebral hæmorrhage.*' The *external and inferior frontal* supplies the third or inferior frontal convolution (Broca's convolution). The *ascending frontal* supplies the ascending frontal convolution. The *ascending parietal* supplies the ascending parietal convolution. The *parieto-sphenoidal* supplies the superior temporo-sphenoidal convolution and the angular gyrus.

FIG. 395.—The distribution of the middle cerebral artery. (After Charcot.)



The **posterior communicating artery** arises from the back part of the internal carotid, runs directly backwards, and anastomoses with the posterior cerebral, a branch of the basilar. This artery varies considerably in size, being sometimes small, and occasionally so large that the posterior cerebral may be considered as arising from the internal carotid rather than from the basilar. It is frequently larger on one side than on the other side. From the posterior half of this vessel are given off a number of small branches, the *postero-median ganglionic branches*, which, with similar vessels from the posterior cerebral, pierce the posterior perforated space and supply the internal surfaces of the optic thalami and the walls of the third ventricle.

The **anterior choroid** is a small but constant branch, which arises from the back part of the internal carotid, near the posterior communicating artery. Passing backwards and outwards between the temporal lobe and the crus cerebri, it enters the descending horn of the lateral ventricle through the transverse fissure and ends in the choroid plexus. It is distributed to the hippocampus major, corpus fimbriatum, velum interpositum, and choroid plexus.

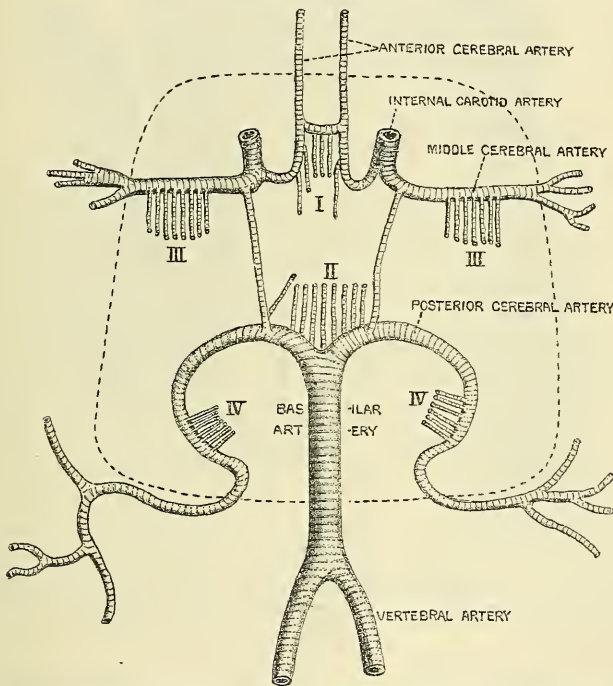


## THE BLOOD VESSELS OF THE BRAIN

Recent investigations have tended to show that the mode of distribution of the vessels of the brain has an important bearing upon a considerable number of the anatomical lesions of which this part of the nervous system may be the seat; it therefore becomes important to consider a little more in detail the way in which the cerebral vessels are distributed.

The cerebral arteries are derived from the internal carotid and the vertebral, which at the base of the brain form a remarkable anastomosis known as the *circle of Willis*. It is formed in front by the anterior cerebral arteries, branches of the internal carotid, which are connected together by the anterior communicating; behind by the two posterior cerebrals, branches of the basilar which are connected on each side with the internal carotid by the posterior communicating (fig. 393, p. 579). The parts of the brain included within this arterial circle are the lamina cinerea, the commissure of the optic nerves, the infundibulum, the tuber cinereum, the corpora albicantia, and the posterior perforated space.

FIG. 396.—Diagram of the arterial circulation at the base of the brain.  
(After Charcot.)



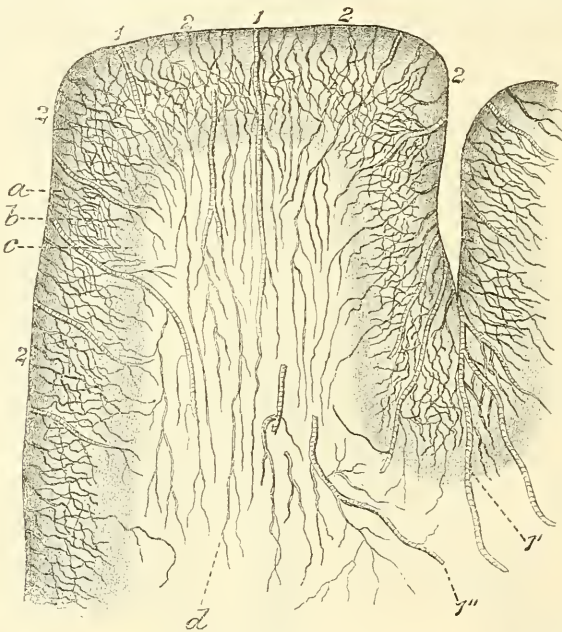
I. Antero-medial group of ganglionic branches. II. Postero-medial group. III. Right and left antero-lateral group. IV. Right and left postero-lateral group. The dotted line shows the limit of the ganglionic circle.

From the circle of Willis arise the three trunks which together supply each cerebral hemisphere. From its anterior part proceed the two anterior cerebrals; from its antero-lateral part the middle cerebral, and from its posterior part the posterior cerebrals. Each of these principal arteries gives origin to two very different systems of secondary vessels. One of these systems has been named the *central ganglionic system*, and the vessels belonging to it supply the central ganglia of the brain; the other has been named the *cortical arterial system*, and its vessels ramify in the pia mater and supply the cortex and subjacent medullary matter. These two systems, though they have a common origin, do not communicate at any point of their peripheral distribution, and are entirely independent of each other. Though some of the arteries of the cortical system

approach, at their terminations, the regions supplied by the central ganglionic system, no communication between the two sets of vessels takes place, and there is between the parts supplied by the two systems a borderland of diminished nutritive activity, where, it is said, softening is especially liable to occur in the brains of old people.

**The central ganglionic system.**—All the vessels belonging to this system are given off from the circle of Willis, or from the vessels immediately after their origin from it. So that if a circle is drawn at a distance of about an inch from the circle of Willis, it will include the origin of all the arteries belonging to this system (fig. 396). The vessels of this system form six principal groups: (i) The *antero-median group*, derived from the anterior cerebrals and anterior communicating; (ii) the *postero-median group*, from the posterior cerebrals and posterior communicating; (iii) the right and left *antero-lateral group* from the middle cerebrals; and (iv) the right and left *postero-lateral group* from the posterior cerebrals, after they have wound round the crura cerebri. The vessels

FIG. 397.—Distribution of the cortical arteries. (After Charcot.)



1. Medullary arteries. 1'. Group of medullary arteries in the sulcus between two adjacent convolutions. 1''. Arteries situated among Gratiolet's commissural fibres. 2. 2. Cortical arteries. a. Capillary network with fairly wide meshes, situated beneath the pia mater. b. Network with more compact, polygonal meshes, situated in the cortex. c. Transitional network with wider meshes. d. Capillary network in the white matter.

belonging to this system are larger than those of the cortical system, and are what Cohnheim has termed 'terminal' arteries—that is to say, vessels which from their origin to their termination neither supply nor receive any anastomotic branch, so that, by one of the small vessels, only a limited area of the central ganglia can be injected, and the injection cannot be driven beyond the area of the part supplied by the particular vessel which is the subject of the experiment.

**The cortical arterial system.**—The vessels forming this system are the terminal branches of the anterior, middle, and posterior cerebral arteries, described above. These vessels divide and ramify in the substance of the pia mater, and give off nutrient arteries which penetrate the cortex perpendicularly. These nutrient vessels are divisible into two classes, the long and short. The *long*, or, as they are sometimes called, the *medullary arteries* pass through the grey matter to penetrate the centrum ovale to the depth of about an inch and a

half, without intercommunicating otherwise than by very fine capillaries, and thus constitute so many independent small systems. The *short vessels* are confined to the cortex, where they form with the long vessels a compact network in the middle zone of the grey matter, the outer and inner zones being sparingly supplied with blood (fig. 397). The vessels of the cortical arterial system are not so strictly 'terminal' as those of the central ganglionic system, but they approach this type very closely, so that injection of one area from the vessel of another area, though it may be possible, is frequently very difficult, and is only effected through vessels of small calibre. As a result of this, obstruction of one of the main branches, or its divisions, may have the effect of producing softening in a very limited area of the cortex.\*

## ARTERIES OF THE UPPER EXTREMITY

The artery which supplies the upper extremity continues as a single trunk from its commencement down to the elbow; but different portions of it have received different names, according to the region through which it passes. That part of the vessel which extends from its origin to the outer border of the first rib, is termed the subclavian; beyond this point to the lower border of the axilla, it is termed the axillary; and from the lower margin of the axillary space to the bend of the elbow, it is termed brachial; here, the single trunk terminates by dividing into two branches, the radial and ulnar, an arrangement precisely similar to what occurs in the lower limb.

### SUBCLAVIAN ARTERIES (fig. 398)

The **subclavian artery** on the right side arises from the innominate artery opposite the right sterno-clavicular articulation; on the left side it arises from the arch of the aorta. It follows, therefore, that these two vessels must, in the first part of their course, differ in their length, their direction, and their relation with neighbouring parts.

In order to facilitate the description of these vessels, more especially from a surgical point of view, each subclavian artery has been divided into three parts. The first portion, on the right side, passes upwards and outwards from the origin of the vessel to the inner border of the *Scalenus anticus*. On the left side it ascends nearly vertically, to gain the inner border of that muscle. The second part passes outwards, behind the *Scalenus anticus*; and the third part passes from the outer margin of that muscle, beneath the clavicle, to the outer border of the first rib, where it becomes the axillary artery. The first portion of these two vessels differs so much in its course, and in its relation with neighbouring parts, that it will be described separately. The second and third parts are alike on the two sides.

### FIRST PART OF THE RIGHT SUBCLAVIAN ARTERY (figs. 383, 386, 398)

The **right subclavian artery** arises from the *arteria innominata*, opposite the upper part of the right sterno-clavicular articulation, and passes upwards and outwards to the inner margin of the *Scalenus anticus* muscle. In this part of its course it ascends a little above the clavicle, the extent to which it does so varying in different cases. It is covered, *in front*, by the integument, superficial fascia, *Platysma*, deep fascia, the clavicular origin of the *Sterno-mastoid*, the *Sterno-hyoid*, and *Sterno-thyroid* muscles, and another layer of the deep fascia. It is crossed by the internal jugular and vertebral veins, and by the *pneumo-gastric*, the cardiac branches of the sympathetic, and the phrenic nerve. *Beneath*, the artery is invested by the pleura; and *behind*, it is separated by a cellular

\* The student who desires further information on this subject is referred to Charcot's *Localisation of Cerebral and Spinal Diseases*, p. 42 *et seq.*, whence the facts above given have been principally derived.



interval from the Longus colli, the neck of the first rib, and the cord of the sympathetic nerve; the recurrent laryngeal nerve winds round the lower and back part of the vessel. The subclavian vein lies below the subclavian artery, immediately behind the clavicle.

PLAN OF RELATIONS OF FIRST PORTION OF THE RIGHT SUBCLAVIAN ARTERY

*In front.*

Skin, superficial fascia.  
 Platysma, deep fascia.  
 Clavicular origin of Sterno-mastoid.  
 Sterno-hyoid, and Sterno-thyroid.  
 Internal jugular and vertebral veins.  
 Pneumogastric, cardiac, and phrenic nerves.



*Beneath.*  
 Pleura.

*Behind.*

Recurrent laryngeal nerve.  
 Sympathetic.  
 Longus colli.  
 Neck of first rib.

FIRST PART OF THE LEFT SUBCLAVIAN ARTERY (fig. 383)

The **left subclavian artery** arises from the end of the arch of the aorta, opposite the fourth dorsal vertebra, and ascends nearly vertically to the inner margin of the Scalenus anticus muscle. This part of the vessel is, therefore, longer than the right, situated more deeply in the cavity of the chest, and directed nearly vertically upwards instead of arching outwards like the vessel of the opposite side.

It is in relation, *in front*, with the pleura, the left lung, the pneumogastric, cardiac, and phrenic nerves, which lie parallel with it, the left carotid artery, left internal jugular and vertebral veins, and the commencement of the left innominate vein, and is covered by the Sterno-thyroid, Sterno-hyoid, and Sterno-mastoid muscles; it has the left carotid in front of, but not in contact with it; *behind*, it is in relation with the œsophagus, thoracic duct, inferior cervical ganglion of the sympathetic, Longus colli, and vertebral column. To its *inner side* are the œsophagus, trachea, and thoracic duct; to its *outer side*, the pleura.

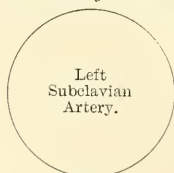
PLAN OF RELATIONS OF FIRST PORTION OF THE LEFT SUBCLAVIAN ARTERY

*In front.*

Pleura and left lung.  
 Pneumogastric, cardiac, and phrenic nerves.  
 Left carotid artery.  
 Left internal jugular, vertebral, and innominate veins.  
 Sterno-thyroid, Sterno-hyoid, and Sterno-mastoid muscles.

*Inner side.*

Trachea.  
 Œsophagus.  
 Thoracic duct.



*Outer side.*  
 Pleura.

*Behind.*

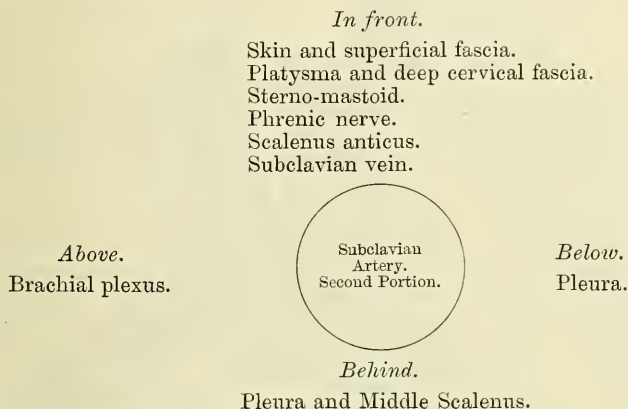
Œsophagus and thoracic duct.  
 Inferior cervical ganglion of sympathetic.  
 Longus colli and vertebral column.

## SECOND AND THIRD PARTS OF THE SUBCLAVIAN ARTERY (fig. 386)

The **Second Portion of the Subclavian Artery** lies behind the Scalenus anticus muscle; it is very short, and forms the highest part of the arch described by that vessel.

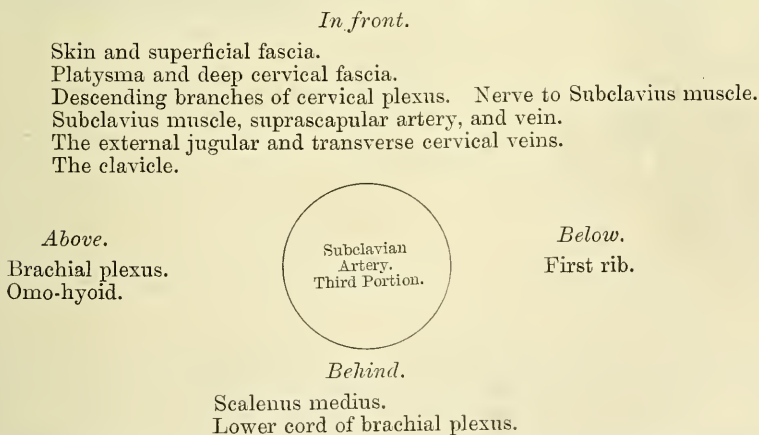
**Relations.**—It is covered, *in front*, by the skin, superficial fascia, Platysma, deep cervical fascia, Sterno-mastoid, and by the phrenic nerve, which is separated from the artery by the Scalenus anticus muscle. *Behind*, it is in relation with the pleura and the Middle scalenus. *Above*, with the brachial plexus of nerves. *Below*, with the pleura. The subclavian vein lies below and in front of the artery, separated from it by the Scalenus anticus.

## PLAN OF RELATIONS OF SECOND PORTION OF THE SUBCLAVIAN ARTERY



The **Third Portion of the Subclavian Artery** passes downwards and outwards from the outer margin of the Scalenus anticus to the outer border of the first rib, where it becomes the axillary artery. This portion of the vessel is the most superficial, and is contained in a triangular space, the base of which is formed in front by the Sterno-mastoid, and the two sides by the Omo-hyoid above and the clavicle below.

## PLAN OF RELATIONS OF THIRD PORTION OF THE SUBCLAVIAN ARTERY



**Relations.**—It is covered, *in front*, by the skin, the superficial fascia, the Platysma, deep cervical fascia; by the clavicle, the Subclavius muscle, and the suprascapular artery and vein, and the transverse cervical vein; the clavicular descending branches of the cervical plexus and the nerve to the Subclavius muscle pass vertically downwards in front of the artery. The external jugular





vessel arises from the thoracic aorta, as low down as the fourth dorsal vertebra. Occasionally, it perforates the anterior Scalenus; more rarely it passes in front of that muscle. Sometimes the subclavian vein passes with the artery behind the Scalenus. The artery sometimes ascends as high as an inch and a half above the clavicle, or any intermediate point between this and the upper border of the bone, the right subclavian usually ascending higher than the left.

The left subclavian is occasionally joined at its origin with the left carotid.

*Surface Marking.*—The course of the subclavian artery in the neck may be mapped out, by describing a curve, with its convexity upwards at the base of the posterior triangle. The inner end of this curve corresponds to the sterno-clavicular joint, the outer end to the centre of the lower border of the clavicle. The curve is to be drawn with such an amount of convexity that its mid-point reaches half an inch above the upper border of the clavicle. The left subclavian artery is more deeply placed than the right in the first part of its course, and, as a rule, does not reach quite as high a level in the neck. It should be borne in mind that the posterior border of the Sterno-mastoid muscle corresponds to the outer border of the Scalenus anticus, so that the third portion of the artery, that part most accessible for operation, lies immediately external to the posterior border of the Sterno-mastoid.

*Surgical Anatomy.*—The relations of the subclavian arteries of the two sides having been examined, the student should direct his attention to a consideration of the best position in which compression of the vessel may be effected, or in what situation a ligature may be best applied in cases of aneurism or wound.

*Compression of the subclavian artery* is required in cases of operations about the shoulder, in the axilla, or at the upper part of the arm; and the student will observe that there is only one situation in which it can be effectually applied, viz. where the artery passes across the upper surface of the first rib. In order to compress the vessel in this situation, the shoulder should be depressed, and the surgeon grasping the side of the neck should press with his thumb in the angle formed by the posterior border of the Sterno-mastoid with the upper border of the clavicle, downwards, backwards, and inwards against the rib; if from any cause the shoulder cannot be sufficiently depressed, pressure may be made from before backwards, so as to compress the artery against the Middle scalenus and transverse process of the seventh cervical vertebra. In appropriate cases, a preliminary incision may be made through the cervical fascia, and the finger may be pressed down directly upon the artery.

*Ligature of the subclavian artery* may be required in cases of wounds, or of aneurism in the axilla, or in cases of aneurism on the cardiac side of the point of ligature; and the third part of the artery is that which is most favourable for an operation, on account of its being comparatively superficial, and most remote from the origin of the large branches. In those cases where the clavicle is not displaced, this operation may be performed with comparative facility; but where the clavicle is pushed up by a large aneurismal tumour in the axilla, the artery is placed at a great depth from the surface, which materially increases the difficulty of the operation. Under these circumstances, it becomes a matter of importance to consider the height to which this vessel reaches above the bone. In ordinary cases, its arch is about half an inch above the clavicle, occasionally as high as an inch and a half, and sometimes so low as to be on a level with its upper border. If the clavicle is displaced, these variations will necessarily make the operation more or less difficult, according as the vessel is more or less accessible.

The chief points in the operation of tying the third portion of the subclavian artery are as follows: the patient being placed on a table in the supine position, with the head drawn over to the opposite side, and the shoulder depressed as much as possible, the integument should be drawn downwards over the clavicle, and an incision made through it, upon that bone, from the anterior border of the Trapezius to the posterior border of the Sterno-mastoid, to which may be added a short vertical incision meeting the preceding in its centre. The object in drawing the skin downwards is to avoid any risk of wounding the external jugular vein, for as it perforates the deep fascia above the clavicle, it cannot be drawn downwards with the skin. The soft parts should now be allowed to glide up, and the cervical fascia divided upon a director, and if the interval between the Trapezius and Sterno-mastoid muscles be insufficient for the performance of the operation, a portion of one or both may be divided. The external jugular vein will now be seen towards the inner side of the wound: this and the suprascapular and transverse cervical veins which terminate in it should be held aside. If the external jugular vein is at all in the way and exposed to injury, it should be tied in two places and divided. The suprascapular artery should be avoided, and the Omo-hyoid muscle held aside if necessary. In the space beneath this muscle, careful search must be made for the vessel; a deep layer of fascia and some connective tissue having been divided carefully, the outer margin of the Scalenus anticus muscle must be felt for, and the finger being guided by it to the first rib, the pulsation of the subclavian artery will be felt as it passes over the rib. The sheath of the vessels having been opened, the aneurism needle may then be passed around the artery from above downwards and inwards so as to avoid including any of the branches of the brachial plexus. If the clavicle is so raised by the tumour that the application of the ligature cannot be effected in this situation, the artery may be tied above the first rib, or

even behind the Scalenus anticus muscle; the difficulties of the operation in such a case will be materially increased, on account of the greater depth of the artery, and the alteration in position of the surrounding parts.

The second part of the subclavian artery, from being that portion which rises highest in the neck, has been considered favourable for the application of the ligature, when it is difficult to tie the artery in the third part of its course. There are, however, many objections to the operation in this situation. It is necessary to divide the Scalenus anticus muscle, upon which lies the phrenic nerve, and at the inner side of which is situated the internal jugular vein; and a wound of either of these structures might lead to the most dangerous consequences. Again, the artery is in contact, below, with the pleura, which must also be avoided; and, lastly, the proximity of so many of its large branches arising internal to this point must be a still further objection to the operation. In cases, however, where the sac of an axillary aneurism encroaches on the neck, it may be necessary to divide the outer half or two-thirds of the Scalenus anticus muscle, so as to place the ligature on the vessel at a greater distance from the sac. The operation is performed exactly in the same way as ligature of the third portion, until the Scalenus anticus is exposed, when it is to be divided on a director (never to a greater extent than its outer two-thirds), and it immediately retracts. The operation is therefore merely an extension of ligature of the third portion of the vessel.

In those cases of aneurism of the axillary or subclavian artery which encroach upon the outer portion of the Scalenus muscle to such an extent that a ligature cannot be applied in that situation, it may be deemed advisable, as a last resource, to tie the first portion of the subclavian artery. On the left side, this operation is almost impracticable; the great depth of the artery from the surface, its intimate relation with the pleura, and its close proximity to the thoracic duct and to so many important veins and nerves, present a series of difficulties which it is next to impossible to overcome.\* On the right side, the operation is practicable, and has been performed, though never with success. The main objection to the operation in this situation is the smallness of the interval which usually exists between the commencement of the vessel and the origin of the nearest branch. The operation may be performed in the following manner:—The patient being placed on the table in the supine position, with the neck extended, an incision should be made along the upper border of the inner part of the clavicle, and a second along the inner border of the Sterno-mastoid, meeting the former at an angle. The sternal attachment of the Sterno-mastoid must now be divided on a director, and turned outwards; a few small arteries and veins, and occasionally the anterior jugular, must be avoided, or, if necessary, ligatured in two places and divided, and the Sterno-hyoid and Sterno-thyroid muscles divided in the same manner as the preceding muscle. After tearing through the deep fascia with the finger-nail, the internal jugular vein will be seen crossing the subclavian artery; this should be pressed aside, and the artery secured by passing the needle from below upwards, by which the pleura is more effectually avoided. The exact position of the vagus, the recurrent laryngeal, the phrenic and sympathetic nerves should be remembered, and the ligature should be applied near the origin of the vertebral, in order to afford as much room as possible for the formation of a coagulum between the ligature and the origin of the vessel. It should be remembered, that the right subclavian artery is occasionally deeply placed in the first part of its course, when it arises from the left side of the aortic arch, and passes in such cases behind the œsophagus, or between it and the trachea.

*Collateral Circulation.*—After ligature of the third part of the subclavian artery, the collateral circulation is mainly established by three sets of vessels, thus described in a dissection:—

1. A posterior set, consisting of the suprascapular and posterior scapular branches of the subclavian, anastomosing with the median branch from the subscapular from the axillary.

2. An internal set produced by the connection of the internal mammary on the one hand, with the superior and long thoracic arteries, and the branches from the subscapular on the other.

3. A middle or axillary set, which consisted of a number of small vessels derived from branches of the subclavian, above; and, passing through the axilla, terminated either in the main trunk, or some of the branches of the axillary below. This last set presented most conspicuously the peculiar character of newly-formed or, rather, dilated arteries, being excessively tortuous, and forming a complete plexus.

‘The chief agent in the restoration of the axillary artery below the tumour was the subscapular artery, which communicated most freely with the internal mammary, suprascapular, and posterior scapular branches of the subclavian, from all of which it received so great an influx of blood as to dilate it to three times its natural size.’ †

\* The operation was, however, performed in New York by Dr. J. K. Rodgers, and the case is related in *A System of Surgery*, edited by T. Holmes, 2nd ed. vol. iii. pp. 620, &c.

† *Guy's Hospital Reports*, vol. i. 1836. Case of axillary aneurism, in which Mr. Aston Key had tied the subclavian artery on the outer edge of the Scalenus muscle, twelve years previously.



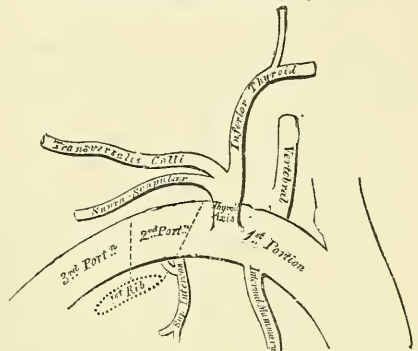
When a ligature is applied to the first part of the subclavian artery, the collateral circulation is carried on by: 1, the anastomosis between the superior and inferior thyroid; 2, the anastomosis of the two vertebrals; 3, the anastomosis of the internal mammary with the deep epigastric and the aortic intercostals; 4, the superior intercostal anastomosing with the aortic intercostals; 5, the profunda cervicis anastomosing with the princeps cervicis; 6, the scapular branches of the thyroid axis anastomosing with the branches of the axillary; and 7, the thoracic branches of the axillary anastomosing with the aortic intercostals.

**Branches.**—The branches given off from the subclavian artery are:—

- |                   |                       |
|-------------------|-----------------------|
| Vertebral.        | Thyroid axis.         |
| Internal mammary. | Superior intercostal. |

On the left side all four branches generally arise from the first portion of the vessel; but on the right side, the superior intercostal usually arises from the second portion of the vessel. On both sides of the body, the first three branches arise close together at the inner margin of the Scalenus anticus; in the majority of cases, a free interval of half an inch to an inch existing between the commencement of the artery and the origin of the nearest branch; in a smaller number of cases, an interval of more than an inch exists, never exceeding an inch and three-quarters. In a very few instances, the interval had been found to be less than half an inch. The vertebral artery arises from the upper part of the artery, slightly behind the middle line; the internal mammary from the lower part of the artery; the thyroid axis from in front, and the superior intercostal from behind.

FIG. 399.—Plan of the branches of the right subclavian artery.



The **Vertebral Artery** (fig. 391) is generally the first and largest branch of the subclavian; it arises from the upper and back part of the first portion of the vessel, and, passing upwards, enters the foramen in the transverse process of the sixth cervical vertebra,\* and ascends through the foramina in the transverse processes of all the vertebræ above this. Above the upper border of the axis, it inclines outwards and upwards to the foramen in the transverse process of the atlas, through which it passes; it then winds backwards behind its articular process, runs in a deep groove on the upper surface of the posterior arch of this bone, and, passing beneath the posterior occipito-atlantal ligament, pierces the dura mater and arachnoid, and enters the skull through the foramen magnum. It then passes forwards and upwards, and inclining to the middle line to the front of the medulla oblongata, it unites with the vessel of the opposite side at the lower border of the pons Varolii to form the *basilar artery*.

**Relations.**—At its origin, it is situated behind the internal jugular and vertebral veins, and is crossed by the inferior thyroid artery: it lies between the Longus colli and Scalenus anticus muscles, having the thoracic duct in front of it on the left side. It rests on the transverse process of the seventh cervical vertebra and the sympathetic nerve. Within the foramina formed by the transverse processes of the vertebræ, it is accompanied by a plexus of nerves from the inferior cervical ganglion of the sympathetic, and is surrounded by a dense plexus of veins which unite to form the vertebral vein at the lower part of the neck. It is situated in front of the cervical nerves, as they issue from the intervertebral foramina. Whilst winding round the articular process of the atlas, it

\* The vertebral artery sometimes enters the foramen in the transverse process of the fifth vertebra. Dr. Smyth, who tied this artery in the living subject, found it, in one of his dissections, passing into the foramen in the seventh vertebra.



is contained in a triangular space (*suboccipital triangle*) formed by the *Rectus capitis posticus major*, the *Superior* and the *Inferior oblique* muscles; and at this point is covered by the *Complexus* muscle. The *suboccipital nerve* here lies between the artery and the bone. Within the skull, as it winds round the *medulla oblongata*, it is placed between the *hypoglossal nerve* and the anterior root of the *suboccipital nerve*, beneath the first digitation of the *ligamentum denticulatum*, and finally lies between the *dura mater* and *arachnoid* covering the *basilar process* of the *occipital bone* and the anterior surface of the *medulla oblongata*.

The branches given off from this vessel may be divided into two sets—those given off in the neck, and those within the cranium.

*Cervical Branches.*

Lateral Spinal.

Muscular.

*Cranial Branches.*

Posterior Meningeal.

Anterior Spinal.

Posterior Spinal.

Posterior Inferior Cerebellar.

The **lateral spinal branches** enter the spinal canal through the *intervertebral foramina*, and divide into two branches. Of these, one passes along the roots of the nerves to supply the spinal cord and its membranes, anastomosing with the other arteries of the spinal cord; the other divides into an ascending and a descending branch, which unite with similar branches from the artery above and below, so that two lateral anastomotic chains are formed on the posterior surface of the bodies of the *vertebræ*, near the attachment of the pedicles. From these anastomotic chains branches are given off, to supply the periosteum and the bodies of the *vertebræ*, and to communicate with similar branches from the opposite side; from these latter small branches are given off which join similar branches above and below, so that a central anastomotic chain is formed on the posterior surface of the bodies of the *vertebræ*.

**Muscular branches** are given off to the deep muscles of the neck, where the vertebral artery curves round the articular process of the atlas. They anastomose with the occipital, and with the ascending and deep cervical arteries.

The **posterior meningeal** are one or two small branches given off from the vertebral opposite the foramen magnum. They ramify between the bone and *dura mater* in the cerebellar fossæ, and supply the *falx cerebelli*.

The **anterior spinal** is a small branch, though larger than the posterior spinal which arises near the termination of the vertebral, and, descending in front of the *medulla oblongata*, unites with its fellow of the opposite side at about the level of the foramen magnum. One of these vessels is usually of much larger size than the other, but occasionally they are about equal in size. The single trunk, thus formed, descends on the front of the spinal cord, and is reinforced by a succession of small branches which enter the spinal canal through the *intervertebral foramina*; these branches are derived from the vertebral and ascending cervical of the inferior thyroid in the neck; from the intercostal in the dorsal region; and from the lumbar, ilio-lumbar, and lateral sacral arteries in the lower part of the spine. They unite, by means of ascending and descending branches, to form a single anterior median artery, which extends as far as the lower part of the spinal cord. This vessel is placed in the *pia mater* along the anterior median fissure; it supplies that membrane, and the substance of the cord, and sends off branches at its lower part to be distributed to the *cauda equina*, and ends on the central fibrous prolongation of the cord.

The **posterior spinal** arises from the vertebral, at the side of the *medulla oblongata*; passing backwards to the posterior aspect of the spinal cord, it descends on each side, lying behind the posterior roots of the spinal nerves; and is reinforced by a succession of small branches, which enter the spinal canal through the *intervertebral foramina*, and by which it is continued to the lower part of the cord, and to the *cauda equina*. Branches from these vessels form a

free anastomosis round the posterior roots of the spinal nerves, and communicate, by means of very tortuous transverse branches, with the vessel of the opposite side. At its commencement it gives off an ascending branch, which terminates at the side of the fourth ventricle.

The **posterior inferior cerebellar artery** (fig. 393), the largest branch of the vertebral, winds backwards round the upper part of the medulla oblongata, passing between the origin of the pneumogastric and spinal accessory nerves, over the restiform body to the under surface of the cerebellum, where it divides into two branches: an internal one, which is continued backwards to the notch between the two hemispheres of the cerebellum; and an external one, which supplies the under surface of the cerebellum, as far as its outer border, where it anastomoses with the anterior inferior cerebellar and the superior cerebellar branches of the basilar artery. Branches from this artery supply the choroid plexus of the fourth ventricle.

*Surgical Anatomy.*—The vertebral artery has been tied in several instances: 1, for wounds or traumatic aneurism; 2, after ligature of the innominate, either at the same time to prevent hæmorrhage, or later on to arrest bleeding where it has occurred at the seat of ligature; and 3, in epilepsy. In these latter cases the treatment has been recommended by Dr. Alexander, of Liverpool, in the hope that by diminishing the supply of blood to the posterior part of the brain and the spinal cord, a diminution or cessation of the epileptic fits would result. The operation of ligature of the vertebral is performed by making an incision along the posterior border of the Sterno-mastoid muscle, just above the clavicle. The muscle is pulled to the inner side and the anterior tubercle of the transverse process of the sixth cervical vertebra sought for. A deep layer of fascia being now divided, the interval between the Scalenus anticus and the Longus colli, just below their attachment to the tubercle, is defined, and the artery and vein found in the interspace. The vein is to be drawn to the outer side, and the aneurism needle passed from without inwards. Drs. Ramskill and Bright have pointed out that severe pain at the back of the head may be symptomatic of disease of the vertebral artery just before it enters the skull. This is explained by the close connection of the artery with the suboccipital nerve in the groove on the posterior arch of the atlas. Disease of the same artery has been also said to affect speech, from pressure on the hypoglossal, where it is in relation with the vessel, leading to paralysis of the muscles of the tongue.

The **Basilar Artery** (fig. 393), so named from its position at the base of the skull, is a single trunk formed by the junction of the two vertebral arteries; it extends from the posterior to the anterior border of the pons Varolii, lying in its median groove, under cover of the arachnoid. It ends by dividing into two branches, the *posterior cerebral arteries*. Its branches are, on each side, the following:—

Transverse.	Superior Cerebellar.
Anterior Inferior Cerebellar.	Posterior Cerebral.

The **transverse branches** supply the pons Varolii and adjacent parts of the brain; one branch, the *internal auditory*, accompanies the auditory nerve into the internal auditory meatus.

The **anterior inferior cerebellar artery** passes backwards across the crus cerebelli, to be distributed to the anterior border of the under surface of the cerebellum, anastomosing with the posterior inferior cerebellar branch of the vertebral.

The **superior cerebellar arteries** arise near the termination of the basilar. They pass outwards, immediately behind the third nerve, which separates them from the posterior cerebral, wind round the crus cerebri, close to the fourth nerve, and arriving at the upper surface of the cerebellum, divide into branches which ramify in the pia mater and, reaching the circumference of the cerebellum, anastomose with the branches of the inferior cerebellar arteries. Several branches are given to the pineal gland, the valve of Vieussens, and the velum interpositum.

The **posterior cerebral arteries**, the two terminal branches of the basilar, are larger than the preceding, from which they are separated near their origin by the third nerves. Passing outwards, parallel to the superior cerebellar artery

and receiving the posterior communicating, they wind round the crura cerebri, and pass to the under surface of the occipital lobes of the cerebrum, and break up into branches for the supply of the temporo-sphenoidal and occipital lobes. The branches of the posterior cerebral artery are:—

Postero-median Ganglionic.	Postero-lateral Ganglionic.
Posterior Choroid.	Three Terminal.

The *postero-median ganglionic branches* (fig. 396) are a group of small arteries which arise at the commencement of the posterior cerebral artery; these, with similar branches from the posterior communicating, pierce the posterior perforated space, and supply the internal surfaces of the optic thalami and the walls of the third ventricle. The *posterior choroid* enters the interior of the brain beneath the posterior border of the corpus callosum, and supplies the velum interpositum and the choroid plexus. The *postero-lateral ganglionic branches* are a group of small arteries which arise from the posterior cerebral artery, after it has turned round the crus cerebri; they supply a considerable portion of the optic thalamus. The *terminal branches* are distributed as follows: the first to the uncinata gyrus; the second to the temporo-sphenoidal lobe; and the third to the cuneus or the occipital lobule.

**Circle of Willis.**—The remarkable anastomosis which exists between the branches of the internal carotid and vertebral arteries at the base of the brain constitutes the *circle of Willis*. It is formed, in front, by the anterior cerebral arteries, branches of the internal carotid, which are connected together by the anterior communicating; behind, by the two posterior cerebrals, branches of the basilar, which are connected on each side with the internal carotid by the posterior communicating arteries (fig. 393). It is by this anastomosis that the cerebral circulation is equalised, and provision made for effectually carrying it on if one or more of the branches are obliterated. The parts of the brain included within this arterial circle are: the lamina cinerea, the commissure of the optic nerves, the infundibulum, the tuber cinereum, the corpora albicantia, and the posterior perforated space.

The **Thyroid Axis** (fig. 386) is a short thick trunk, which arises from the fore part of the first portion of the subclavian artery, close to the inner border of the Scalenus anticus muscle, and divides, almost immediately after its origin, into three branches, the *inferior thyroid*, *suprascapular*, and *transversalis colli*.

The **Inferior Thyroid Artery** passes upwards, in front of the vertebral artery, recurrent laryngeal nerve and Longus colli muscle; then turns inwards behind the sheath of the common carotid artery and internal jugular vein, and also behind the sympathetic nerve, the middle cervical ganglion resting upon the vessel, and reaching the lower border of the lateral lobe of the thyroid gland it divides into two branches, which supply the posterior and under part of the organ, and anastomose in its substance with the superior thyroid, and with the corresponding artery of the opposite side. Its branches are, the

Inferior Laryngeal.	Œsophageal.
Tracheal.	Ascending Cervical.
Muscular.	

The **inferior laryngeal branch** ascends upon the trachea to the back part of the larynx, in company with the recurrent laryngeal nerve, and supplies the muscles and mucous membrane of this part, anastomosing with the branch from the opposite side, and with the laryngeal branch from the superior thyroid artery.

The **tracheal branches** are distributed upon the trachea, anastomosing below with the bronchial arteries.

The **œsophageal branches** are distributed to the œsophagus, and anastomose with the œsophageal branches of the aorta.

The **ascending cervical** is a small branch which arises from the inferior



thyroid, just where that vessel is passing behind the common carotid artery, and runs up on the anterior tubercles of the transverse processes of the cervical vertebræ in the interval between the Scalenus anticus and Rectus capitis anticus major. It gives branches to the muscles of the neck, which anastomose with branches of the vertebral, and sends one or two branches into the spinal canal through the intervertebral foramina to be distributed to the spinal cord and its membranes, and to the bodies of the vertebræ in the same manner as the lateral spinal branches from the vertebral. It anastomoses with the ascending pharyngeal and occipital arteries.

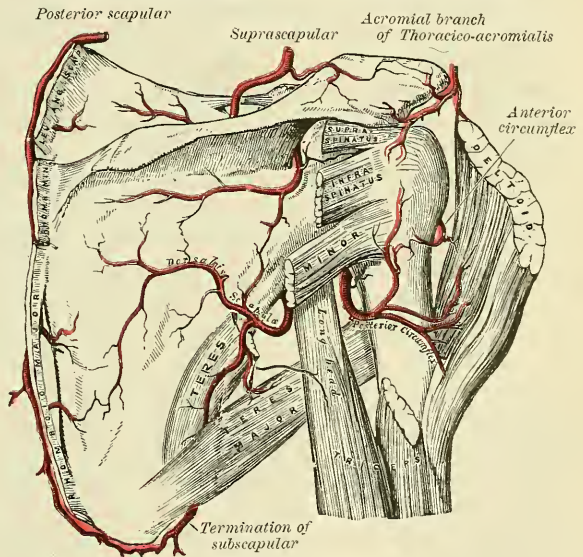
The **muscular branches** supply the depressors of the hyoid bone, the Longus colli, the Scalenus anticus, and the Inferior constrictor of the pharynx.

*Surgical Anatomy.*—This artery is sometimes tied, in conjunction with the superior thyroid, in cases of bronchocele. An incision is made along the anterior border of the Sterno-mastoid down to the clavicle. After the deep fascia has been divided, the Sterno-mastoid and carotid vessels are drawn outwards, and the carotid (Chassaignac's) tubercle sought for. The vessel will be found just below this tubercle, between the carotid sheath on the outer side and the trachea and œsophagus on the inner side. In passing the ligature, great care must be exercised to avoid including the recurrent laryngeal nerve, which is occasionally found crossing in *front* of the vessel.

The **Suprascapular Artery (transversalis humeri)**, smaller than the transversalis colli, passes obliquely from within outwards, across the root of the neck.

It at first lies on the lower part of the Scalenus anticus, being covered by the Sterno-mastoid; it then crosses the subclavian artery and runs outwards, behind and parallel with the clavicle and Subclavius muscle, and beneath the posterior belly of the Omo-hyoid, to the superior border of the scapula, where it passes over the transverse ligament of the scapula, to the supraspinous fossa. In this situation it lies close to the bone, and ramifies between it and the Supraspinatus muscle, to which it is mainly distributed, giving off a communicating branch, which crosses

FIG. 400.—The scapular and circumflex arteries.



the neck of the scapula, to reach the infraspinous fossa, where it anastomoses with the dorsal branch of the subscapular artery. Besides distributing branches to the Sterno-mastoid, Subclavius, and neighbouring muscles, it gives off a *suprasternal branch*, which crosses over the sternal end of the clavicle to the skin of the upper part of the chest; and a *supra-acromial branch*, which, piercing the Trapezius muscle, supplies the cutaneous surface of the acromion, anastomosing with the acromial thoracic artery. As the artery passes over the transverse ligament of the scapula, a branch descends into the subscapular fossa, ramifies beneath that muscle, and anastomoses with the posterior and subscapular arteries. It also sends branches to the acromio-clavicular joint and the shoulder-joint, and a nutrient artery to the clavicle.

The **Transversalis Colli** passes transversely outwards, across the upper part of the subclavian triangle, to the anterior margin of the Trapezius muscle, beneath which it divides into two branches, the *superficial cervical* and the

*posterior scapular*. In its passage across the neck, it crosses in front of the Scaleni muscles and the brachial plexus, between the divisions of which it sometimes passes, and is covered by the Platysma, Sterno-mastoid, Omo-hyoid, and Trapezius muscles.

The **superficial cervical** ascends beneath the anterior margin of the Trapezius, distributing branches to it, and to the neighbouring muscles and glands in the neck, and anastomoses with the superficial branch of the *arteria princeps cervicis*.

The **posterior scapular** passes beneath the Levator anguli scapulæ to the superior angle of the scapula. It now descends along the posterior border of that bone as far as the inferior angle, where it anastomoses with the subscapular branch of the axillary. In its course it is covered by the Rhomboid muscles, supplying them and the Latissimus dorsi and Trapezius, and anastomosing with the suprascapular and subscapular arteries, and with the posterior branches of some of the intercostal arteries.

*Peculiarities*.—The *superficial cervical* frequently arises as a separate branch from the thyroid axis; and the *posterior scapular*, from the third, more rarely from the second, part of the subclavian.

The **Internal Mammary** (fig. 401) arises from the under surface of the first portion of the subclavian artery, opposite the thyroid axis. It descends behind the costal cartilage of the first rib to the inner surface of the anterior wall of the chest, resting against the costal cartilages about half an inch from the margin of the sternum; and, at the interval between the sixth and seventh cartilages, divides into two branches, the *musculo-phrenic* and *superior epigastric*.

**Relations**.—At its origin it is covered by the internal jugular and subclavian veins, and crossed by the phrenic nerve. In the upper part of the thorax, it lies against the costal cartilages and Internal intercostal muscles in front, and is covered by the pleura behind. At the lower part of the thorax, the *Triangularis sterni* separates the artery from the pleura. It has two *venæ comites*, which unite into a single vein before joining the innominate vein of its own side.

The branches of the internal mammary are—

Comes Nervi Phrenici (Superior Phrenic).	Anterior Intercostal.
Mediastinal.	Perforating.
Pericardiac.	Musculo-phrenic.
Sternal.	Superior Epigastric.

The **comes nervi phrenici (superior phrenic)** is a long slender branch, which accompanies the phrenic nerve, between the pleura and pericardium, to the Diaphragm, to which it is distributed; anastomosing with the other phrenic arteries from the internal mammary, and abdominal aorta.

The **mediastinal branches** are small vessels, which are distributed to the areolar tissue and lymphatic glands in the anterior mediastinum, and the remains of the thymus gland.

The **pericardiac branches** supply the upper part of the anterior surface of the pericardium, the lower part receiving branches from the musculo-phrenic artery.

The **sternal branches** are distributed to the *Triangularis sterni*, and to the posterior surface of the sternum.

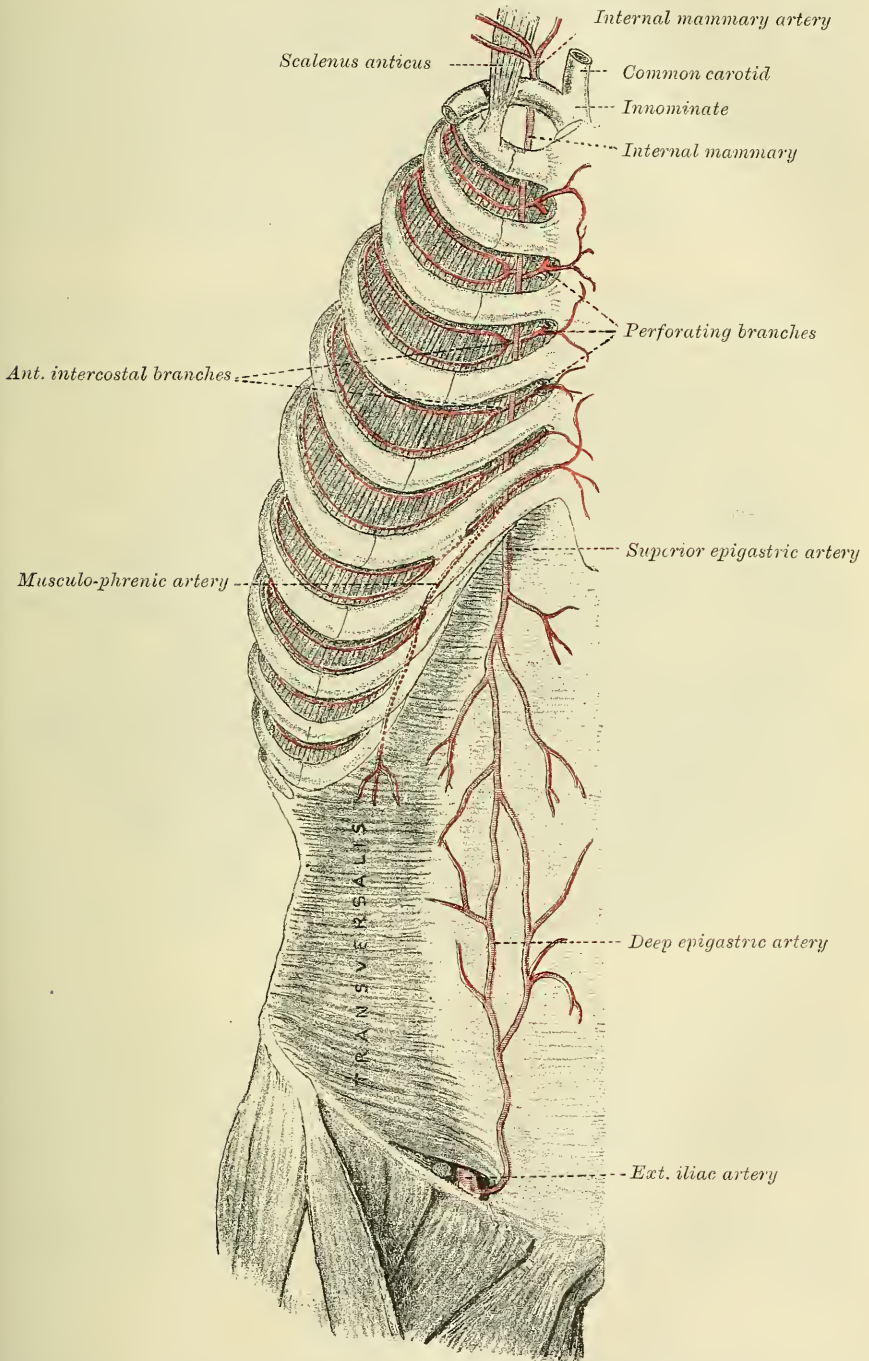
The mediastinal, pericardiac, and sternal branches, together with some twigs from the *comes nervi phrenici*, anastomose with branches from the intercostal and bronchial arteries, and form a minute plexus beneath the pleura which has been named by Turner the *subpleural mediastinal plexus*.

The **anterior intercostal arteries** supply the five or six upper intercostal spaces. The branch corresponding to each space soon divides into two; or the two branches may come off separately from the parent trunk. These small vessels pass outwards in the intercostal spaces, one lying near the lower margin of the rib above, and the other near the upper margin of the rib below, and anastomose



with the intercostal arteries from the aorta. They are at first situated between the pleura and the Internal intercostal muscles, and then between the Internal and External intercostal muscles. They supply the Intercostal muscles and, by

FIG. 401.—The internal mammary artery and its branches.



branches which perforate the External intercostal muscle, the Pectoral muscles and the mammary gland.

The **perforating arteries** correspond to the five or six upper intercostal spaces.



They arise from the internal mammary, pass forwards through the intercostal spaces, and, curving outwards, supply the Pectoralis major, and the integument. Those which correspond to the second, third, and fourth spaces are distributed to the mammary gland. In females, during lactation, these branches are of large size.

The **musculo-phrenic artery** is directed obliquely downwards and outwards, behind the cartilages of the false ribs, perforating the Diaphragm at the eighth or ninth rib, and terminating, considerably reduced in size, opposite the last intercostal space. It gives off anterior intercostal arteries to each of the intercostal spaces across which it passes; these diminish in size as the spaces decrease in length, and are distributed in a manner precisely similar to the anterior intercostals from the internal mammary. The musculo-phrenic also gives branches to the lower part of the pericardium, and others which run backwards to the Diaphragm, and downwards to the abdominal muscles.

The **superior epigastric** continues in the original direction of the internal mammary; it descends through the cellular interval between the costal and sternal attachments of the Diaphragm, and enters the sheath of the Rectus abdominis muscle, at first lying behind the muscle, and then perforating it and supplying it, and anastomosing with the deep epigastric artery from the external iliac. Some vessels perforate the sheath of the Rectus, and supply the muscles of the abdomen and the integument, and a small branch, which passes inwards upon the side of the ensiform appendix, anastomoses in front of that cartilage with the artery of the opposite side.

*Surgical Anatomy.*—The course of the internal mammary artery may be defined by drawing a line across the six upper intercostal spaces, half an inch from and parallel with the sternum. The position of the vessel must be remembered, as it is liable to be wounded in stabs of the chest-wall. It is most easily reached by a transverse incision in the second intercostal space.

The **Superior Intercostal** (fig. 391) arises from the upper and back part of the subclavian artery, behind the Anterior scalenus on the right side, and to the inner side of the muscle on the left side. Passing backwards, it gives off the *deep cervical branch*, and then descends behind the pleura in front of the necks of the first two ribs, and inosculates with the first aortic intercostal. In the first intercostal space, it gives off a branch which is distributed in a manner similar to the distribution of the aortic intercostals. The branch for the second intercostal space usually joins with one from the aortic intercostals. Each intercostal gives off a branch to the posterior spinal muscles, and a small one which passes through the corresponding intervertebral foramen to the spinal cord and its membranes.

The *deep cervical branch* (*profunda cervicis*) arises, in most cases, from the superior intercostal, and is analogous to the posterior branch of an aortic intercostal artery: occasionally it arises as a separate branch from the subclavian artery. Passing backwards, between the transverse process of the seventh cervical vertebra and the first rib, it runs up the back part of the neck, between the Complexus and Semispinalis colli muscles, as high as the axis, supplying these and adjacent muscles, and anastomosing with the deep branch of the arteria princeps cervicis of the occipital, and with branches which pass outwards from the vertebral. It gives off a special branch which enters the spinal canal through the intervertebral foramen between the seventh cervical and first dorsal vertebra.

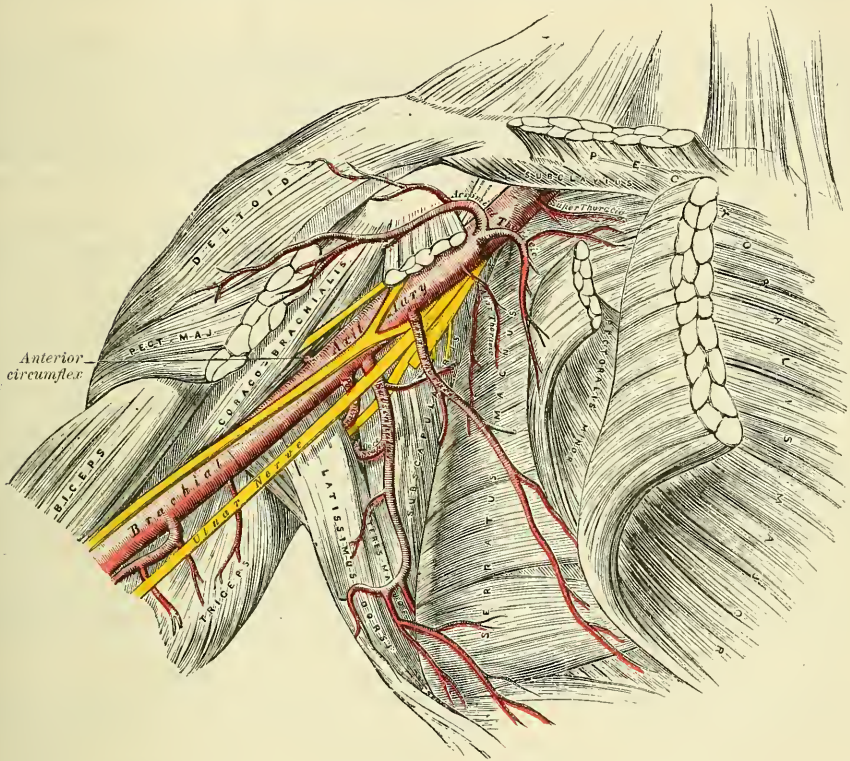
#### ANATOMY OF THE AXILLA

The **Axilla** is a pyramidal space, situated between the upper and lateral part of the chest and the inner side of the arm.

**Boundaries.**—Its *apex*, which is directed upwards towards the root of the neck, corresponds to the interval between the first rib, the upper edge of

the scapula, and the clavicle, through which the axillary vessels and nerves pass. The *base*, directed downwards, is formed by the integument, and a thick layer of fascia, extending between the lower border of the Pectoralis major in front, and the lower border of the Latissimus dorsi behind; it is broad internally, at the chest, but narrow and pointed externally, at the arm. The *anterior boundary* is formed by the Pectoralis major and minor muscles, the former covering the whole of the anterior wall of the axilla, the latter covering only its central part. The *posterior boundary*, which extends somewhat lower than the anterior, is formed by the Subscapularis above, the Teres major and Latissimus dorsi below. On the *inner side* are the first four ribs with their corresponding Intercostal muscles, and part of the Serratus magnus. On the *outer side*, where the anterior and posterior boundaries con-

FIG. 402.—The axillary artery and its branches.



verge, the space is narrow, and bounded by the humerus, the Coraco-brachialis and Biceps muscles.

**Contents.**—This space contains the axillary vessels, and brachial plexus of nerves, with their branches; some branches of the intercostal nerves, and a large number of lymphatic glands, all connected together by a quantity of fat and loose areolar tissue.

**Their Position.**—The axillary artery and vein, with the brachial plexus of nerves, extend obliquely along the outer boundary of the axillary space, from its apex to its base, and are placed much nearer the anterior than the posterior wall, the vein lying to the inner or thoracic side of the artery, and partially concealing it. At the fore part of the axillary space, in contact with the Pectoral muscles, are the thoracic branches of the axillary artery, and along the anterior margin of the axilla the long thoracic artery extends to the side of the chest. At the back part, in contact with the lower margin of the Subscapularis muscle, are the subscapular vessels and nerves; winding around the lower border of this



muscle is the dorsalis scapulæ artery and veins; and towards the outer extremity of the muscle, the posterior circumflex vessels and the circumflex nerve are seen curving backwards to the shoulder.

Along the inner or thoracic side no vessel of any importance exists, the upper part of the space being crossed merely by a few small branches from the superior thoracic artery. There are some important nerves, however, in this situation, viz. the posterior thoracic or external respiratory nerve, descending on the surface of the Serratus magnus, to which it is distributed; and perforating the upper and anterior part of this wall, the intercosto-humeral nerve or nerves, passing across the axilla to the inner side of the arm.

The cavity of the axilla is filled by a quantity of loose areolar tissue, and a large number of small arteries and veins, all of which are, however, of inconsiderable size, and numerous lymphatic glands: these are from ten to twelve in number, and situated chiefly on the thoracic side, and lower and back part of this space.

*Surgical Anatomy.*—The axilla is a space of considerable surgical importance. It transmits the large vessels and nerves to the upper extremity, and these may be the seat of injury or disease: it contains numerous lymphatic glands which may require removal when diseased; in it is a quantity of loose connective and adipose tissue which may be readily infiltrated with blood or inflammatory exudation, and it may be the seat of rapidly growing tumours. Moreover, it is covered at its base by thin skin, largely supplied with sebaceous and sweat glands, which is frequently the seat of small cutaneous abscesses and boils, and of eruptions due to irritation.

In suppuration in the axilla, the arrangement of the fasciæ plays a very important part in the direction which the pus takes. As described on page 470, the costo-ccracoïd membrane, after covering in the space between the clavicle and the upper border of the Pectoralis minor, splits to enclose this muscle, and, reblending at its lower border, becomes incorporated with the fascia covering the Pectoralis major muscle at the anterior fold of the axilla. This is known as the clavi-pectoral fascia. Suppuration may take place either superficial to or beneath this layer of fascia; that is, either between the Pectorals or below the Pectoralis minor: in the former case, it would point either at the anterior border of the axillary fold, or in the groove between the Deltoid and the Pectoralis major; in the latter, the pus would have a tendency to surround the vessels and nerves, and ascend into the neck, that being the direction in which there is least resistance. Its progress towards the skin is prevented by the axillary fascia; its progress backwards, by the Serratus magnus; forwards, by the clavi-pectoral fascia; inwards, by the wall of the thorax; and outwards, by the upper limb. The pus in these cases, after extending into the neck, has been known to spread through the superior opening of the thorax into the mediastinum.

In opening an axillary abscess, the knife should be entered in the floor of the axilla, midway between the anterior and posterior margins and near the thoracic side of the space. It is well to use a director and dressing forceps, after an incision has been made through the skin and fascia, in the manner directed by the late Mr. Hilton.

The student should attentively consider the relation of the vessels and nerves in the several parts of the axilla; for it not unfrequently happens that the surgeon is called upon to extirpate diseased glands, or to remove a tumour from this situation. In performing such an operation, it will be necessary to proceed with much caution in the direction of the outer wall and apex of the space, as here the axillary vessels will be in danger of being wounded. Towards the posterior wall, it will be necessary to avoid the subscapular, dorsalis scapulæ, and posterior circumflex vessel. Along the anterior wall, it will be necessary to avoid the thoracic branches. It is only along the inner or thoracic wall, and in the centre of the axillary cavity, that there are no vessels of any importance; a fortunate circumstance, for it is in this situation more especially that tumours requiring removal are usually situated.

#### THE AXILLARY ARTERY

The **Axillary Artery**, the continuation of the subclavian, commences at the outer border of the first rib, and terminates at the lower border of the tendon of the Teres major muscle, where it takes the name of brachial. Its direction varies with the position of the limb: when the arm lies by the side of the chest, the vessel forms a gentle curve, the convexity being upwards and outwards; when it is directed at right angles with the trunk, the vessel is nearly straight; and when it is elevated still higher, the artery describes a curve, the concavity of which is directed upwards. At its commencement the artery is very deeply



situated, but near its termination is superficial, being covered only by the skin and fascia. The description of the relations of this vessel is facilitated by its division into three portions: the first portion being that above the Pectoralis minor; the second portion, behind; and the third below, that muscle.

The **first portion of the axillary artery** is in relation, *in front*, with the clavicular portion of the Pectoralis major, the costo-coracoid membrane, the external anterior thoracic nerve, and the acromio-thoracic and cephalic veins; *behind*, with the first intercostal space, the corresponding Intercostal muscle, the second and a portion of the third serration of the Serratus magnus, and the posterior thoracic and internal anterior thoracic nerves; on its *outer side*, with the brachial plexus, from which it is separated by a little cellular interval; on its *inner*, or thoracic side, with the axillary vein.

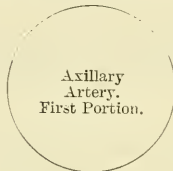RELATIONS OF THE FIRST PORTION OF THE AXILLARY ARTERY

*In front.*

Pectoralis major.  
Costo-coracoid membrane.  
External anterior thoracic nerve.  
Acromio-thoracic and Cephalic veins.

*Outer side.*

Brachial plexus.



*Inner side.*

Axillary vein.

*Behind.*

First intercostal space, and Intercostal muscle.  
Second and third serrations of Serratus magnus.  
Posterior thoracic and internal anterior thoracic nerves.

The **second portion of the axillary artery** lies behind the Pectoralis minor. It is covered, *in front*, by the Pectoralis major and minor muscles; *behind*, it is separated from the Subscapularis by a cellular interval; on the *inner side* is the axillary vein, separated from the artery by the inner cord of the plexus and the internal anterior thoracic nerve. The brachial plexus of nerves surrounds the artery, and separates it from direct contact with the vein and adjacent muscles.

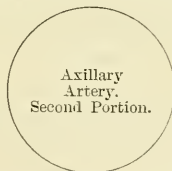RELATIONS OF THE SECOND PORTION OF THE AXILLARY ARTERY

*In front.*

Pectoralis major and minor.

*Outer side.*

Outer cord of plexus.



*Inner side.*

Axillary vein.  
Inner cord of plexus.  
Internal anterior thoracic nerve.

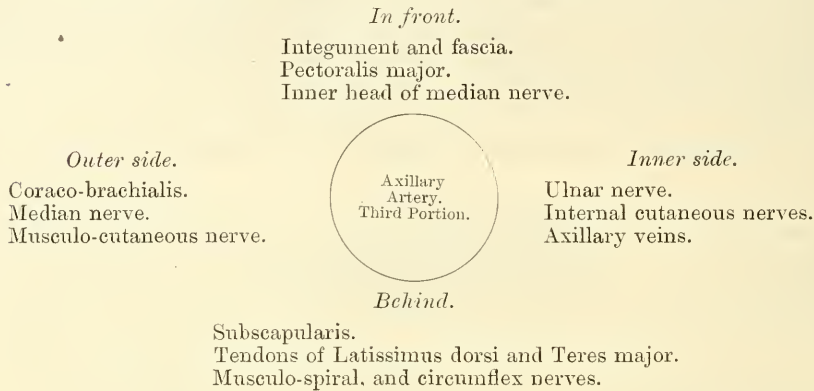
*Behind.*

Subscapularis.  
Posterior cord of plexus.

The **third portion of the axillary artery** lies below the Pectoralis minor. It is in relation, *in front*, with the lower part of the Pectoralis major above, being covered only by the integument and fascia below, where it is crossed by the inner head of the median nerve; *behind*, with the lower part of the Subscapularis, and the tendons of the Latissimus dorsi and Teres major; on its *outer side*, with the

Coraco-brachialis; on its *inner*, or thoracic side, with the axillary vein. The nerves of the brachial plexus bear the following relation to the artery in this part of its course: on the *outer side* is the median nerve, and the musculo-cutaneous for a short distance; on the *inner side*, the ulnar, the internal, and lesser internal cutaneous nerves; and *behind*, the musculo-spiral and circumflex, the latter extending only to the lower border of the Subscapularis muscle.

#### RELATIONS OF THE THIRD PORTION OF THE AXILLARY ARTERY



*Peculiarities.*—The axillary artery, in about one case out of every ten, gives off a large branch, which forms either one of the arteries of the forearm, or a large muscular trunk. In the first set of cases, this artery is most frequently the radial (1 in 33), sometimes the ulnar (1 in 72), and, very rarely, the interosseous (1 in 506). In the second set of cases, the trunk has been found to give origin to the subscapular, circumflex, and profunda arteries of the arm. Sometimes, only one of the circumflex, or one of the profunda arteries, arose from the trunk. In these cases the brachial plexus surrounded the trunk of the branches, and not the main vessel.

*Surface Marking.*—The course of the axillary artery may be marked out by raising the arm to a right angle and drawing a line from the middle of the clavicle to the point where the tendon of the Pectoralis major crosses the prominence caused by the Coraco-brachialis as it emerges from under cover of the anterior fold of the axilla. The third portion of the artery can be felt pulsating beneath the skin and fascia, at the junction of the anterior with the middle third of the space between the anterior and posterior folds of the axilla, close to the inner border of the Coraco-brachialis.

*Surgical Anatomy.*—The student, having carefully examined the relations of the axillary artery in its various parts, should now consider in what situation compression of this vessel may be most easily effected, and the best position for the application of a ligature to it when necessary.

*Compression* of the vessel may be required in the removal of tumours, or in amputation of the upper part of the arm; and the only situation in which this can be effectually made is in the lower part of its course; by pressing on it in this situation from within outwards against the humerus, the circulation may be effectually arrested.

The axillary artery is perhaps more frequently lacerated than any other artery in the body, with the exception of the popliteal, by violent movements of the upper extremity, especially in those cases where its coats are diseased. It has occasionally been ruptured in attempts to reduce old dislocations of the shoulder-joint. This lesion is most likely to occur during the preliminary breaking down of adhesions, in consequence of the artery having contracted adhesions to the capsule of the joint. Aneurism of the axillary artery is of frequent occurrence: a large percentage of the cases being traumatic in their origin, due to the violence to which it is exposed in the varied, extensive, and often violent movement of the limb.

The *application of a ligature to the axillary artery* may be required in cases of aneurism of the upper part of the brachial, or as a distal operation for aneurism of the subclavian; and there are only two situations in which it can be secured, viz. in the first and in the third parts of its course; for the axillary artery at its central part is so deeply seated, and, at the same time, so closely surrounded with large nervous trunks, that the application of a ligature to it in that situation would be almost impracticable.

In the *third part* of its course the operation is most simple, and may be performed in the following manner:—The patient being placed on a bed, and the arm separated from the side, with the hand supinated, an incision is made through the integument forming the floor of the axilla, about two inches in length, a little nearer to the anterior than the





*descending branch* passes in the space between the Pectoralis major and Deltoid, in the same groove as the cephalic vein, and supplies both muscles. The artery also gives off a very small branch, the *clavicular*, which passes upwards to the Subclavius muscle.

The **long thoracic** passes downwards and inwards along the lower border of the Pectoralis minor to the side of the chest, supplying the Serratus magnus, the Pectoral muscles, and mammary gland, and sending branches across the axilla to the axillary glands and Subscapularis; it anastomoses with the internal mammary and intercostal arteries.

The **alar thoracic** is a small branch, which supplies the glands and areolar tissue of the axilla. Its place is frequently supplied by branches from some of the other thoracic arteries.

The **subscapular**, the largest branch of the axillary artery, arises opposite the lower border of the Subscapularis muscle, and passes downwards and backwards along its lower margin to the inferior angle of the scapula, where it anastomoses with the long thoracic and intercostal arteries and with the posterior scapular, a branch of the transversalis colli, from the thyroid axis of the subclavian. About an inch and a half from its origin it gives off a large branch, the *dorsalis scapulae*, and terminates by supplying branches to the muscles in the neighbourhood.

The *dorsalis scapulae* is given off from the subscapular about an inch and a half from its origin, and is generally larger than the continuation of the vessel. It curves round the axillary border of the scapula, leaving the axilla through the space between the Teres minor above, the Teres major below, and the long head of the Triceps externally (fig. 400), and enters the infraspinous fossa, where it anastomoses with the posterior scapular and suprascapular arteries. In its course it gives off two sets of branches: one enters the subscapular fossa beneath the Subscapularis, which it supplies, anastomosing with the posterior scapular and suprascapular arteries; the other is continued along the axillary border of the scapula, between the Teres major and minor, and, at the dorsal surface of the inferior angle of the bone, anastomoses with the posterior scapular. In addition to these, small branches are distributed to the back part of the Deltoid muscle and the long head of the Triceps, anastomosing with an ascending branch of the superior profunda of the brachial.

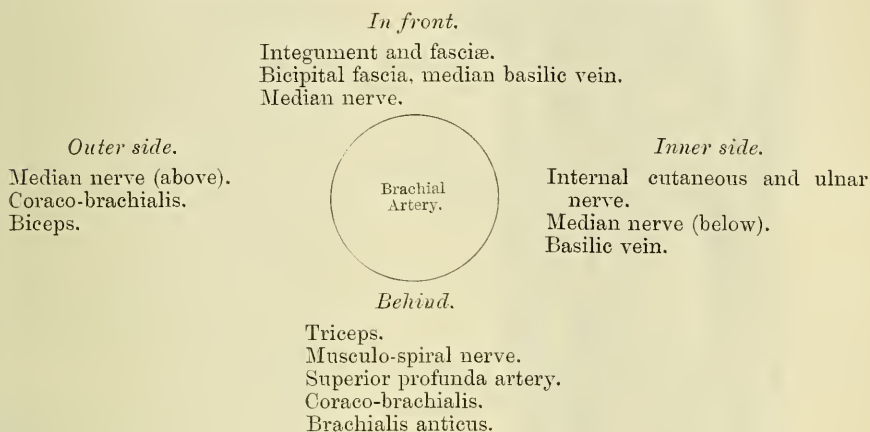
The **circumflex arteries** wind round the neck of the humerus. The *posterior circumflex* (fig. 400), the larger of the two, arises from the back part of the axillary opposite the lower border of the Subscapularis muscle, and, passing backwards with the circumflex veins and nerve through the quadrangular space bounded by the Teres major and minor, the scapular head of the Triceps and the humerus, winds round the neck of that bone and is distributed to the Deltoid muscle and shoulder-joint, anastomosing with the anterior circumflex, and acromial thoracic arteries, and with the superior profunda branch of the brachial artery. The *anterior circumflex* (figs. 400, 402), considerably smaller than the preceding, arises just below that vessel, from the outer side of the axillary artery. It passes horizontally outwards, beneath the Coraco-brachialis and short head of the Biceps, lying upon the fore part of the neck of the humerus, and, on reaching the bicipital groove, gives off an ascending branch which passes upwards along the groove to supply the head of the bone and the shoulder-joint. The trunk of the vessel is then continued outwards beneath the Deltoid, which it supplies, and anastomoses with the posterior circumflex artery.

#### BRACHIAL ARTERY (fig. 403)

The **Brachial Artery** commences at the lower margin of the tendon of the Teres major, and, passing down the inner and anterior aspect of the arm, terminates about half an inch below the bend of the elbow, where it divides into the *radial* and *ulnar* arteries. At first the brachial artery lies internal to the humerus; but as it passes down the arm it gradually gets in front of the bone, and at the bend of the elbow it lies midway between the two condyles.

**Relations.**—This artery is superficial throughout its entire extent, being covered, *in front*, by the integument, the superficial and deep fascia; the bicipital fascia separates it opposite the elbow from the median basilic vein; the median nerve crosses it at its middle. *Behind*, it is separated from the inner side of the humerus above, by the long and inner heads of the Triceps, the musculo-spiral nerve and superior profunda artery intervening; and from the front of the bone below, by the insertion of the Coraco-brachialis muscle, and by the Brachialis anticus. By its *outer side*, it is in relation with the commencement of the median nerve, and the Coraco-brachialis and Biceps muscles, which slightly overlap the artery. By its *inner side*, its upper half is in relation with the internal cutaneous and ulnar nerves, its lower half with the median nerve. The basilic vein lies on the inner side of the artery, but is separated from it in the lower part of the arm by the deep fascia. It is accompanied by two venæ comites, which lie in close contact with the artery, being connected together at intervals by short transverse communicating branches.

#### PLAN OF THE RELATIONS OF THE BRACHIAL ARTERY



#### ANATOMY OF THE BEND OF THE ELBOW

At the bend of the elbow the brachial artery sinks deeply into a triangular interval, the base of which is directed upwards towards the humerus, and the sides of which are bounded, externally, by the Supinator longus; internally, by the Pronator radii teres; its floor is formed by the Brachialis anticus and Supinator brevis. This space contains the brachial artery, with its accompanying veins; the radial and ulnar arteries; the median and musculo-spiral nerves; and the tendon of the Biceps. The brachial artery occupies the middle line of this space, and divides opposite the neck of the radius into the radial and ulnar arteries; it is covered, *in front*, by the integument, the superficial fascia, and the median basilic vein, the vein being separated from direct contact with the artery by the bicipital fascia. *Behind*, it lies on the Brachialis anticus, which separates it from the elbow-joint. The median nerve lies on the inner side of the artery, close to it above; but separated from it below by the coronoid origin of the Pronator radii teres. The tendon of the Biceps lies to the outer side of the space, and the musculo-spiral nerve still more externally, lying upon the Supinator brevis, and partly concealed by the Supinator longus.

*Peculiarities of the Brachial Artery as regards its Course.*—The brachial artery, accompanied by the median nerve, may leave the inner border of the Biceps, and descend towards the inner condyle of the humerus, where it usually curves round a prominence of bone, to which it is connected by a fibrous band; it then inclines outwards, beneath or through the substance of the Pronator radii teres muscle, to the bend of the elbow. The variation bears considerable analogy with the normal condition of the artery in some of the carnivora: it has been referred to, above, in the description of the humerus (page 234).



As regards its Division.—Occasionally, the artery is divided for a short distance at its upper part into two trunks, which are united above and below. A similar peculiarity occurs in the main vessel of the lower limb.

The point of bifurcation may be above or below the usual point, the former condition being by far the more frequent. Out of 481 examinations recorded by Mr. Quain, some made on the right, and some on the left side of the body, in 386 the artery bifurcated in its normal position. In one case only was the place of division lower than usual, being

two or three inches below the elbow-joint. 'In 94 cases out of 481, or about one in 5 $\frac{1}{2}$ , there were two arteries instead of one in some part, or in the whole of the arm.'

There appears, however, to be no correspondence between the arteries of the two arms, with respect to their irregular division; for in sixty-one bodies it occurred on one side only in forty-three; on both sides, in different positions, in thirteen; on both sides, in the same position, in five.

The point of bifurcation takes place at different parts of the arm, being most frequent in the upper part, less so in the lower part, and least so in the middle, the most usual point for the application of a ligature; under any of these circumstances, two large arteries would be found in the arm instead of one. The most frequent (in three out of four) of these peculiarities is the high division of the radial. That artery often arises from the inner side of the brachial, and runs parallel with the main trunk to the elbow, where it crosses it, lying beneath the fascia; or it may perforate the fascia, and pass over the artery immediately beneath the integument.

The ulnar sometimes arises from the brachial high up, and then occasionally leaves that vessel at the lower part of the arm, and descends towards the inner condyle. In the forearm it generally lies beneath the deep fascia, superficial to the flexor muscles; occasionally between the integument and deep fascia, and very rarely beneath the flexor muscles.

The interosseous artery sometimes arises from the upper part of the brachial or axillary: as it passes down the arm, it lies behind the main trunk, and at the bend of the elbow regains its usual position.

In some cases of high division of the radial, the remaining trunk (ulnar-interosseous) occasionally passes, together with the median nerve, along the inner margin of the arm to the inner condyle, and then passing from

within outwards, beneath or through the Pronator radii teres, regains its usual position at the bend of the elbow.

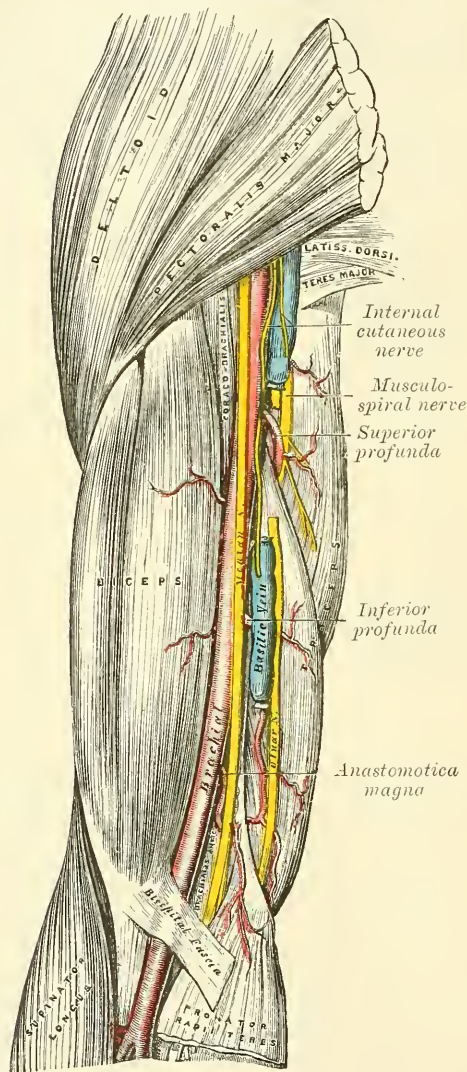
Occasionally, the two arteries representing the brachial are connected at the bend of the elbow by a short transverse branch, and are even sometimes reunited.

Sometimes, long slender vessels, *vasa aberrantia*, connect the brachial or axillary arteries with one of the arteries of the forearm, or a branch from them. These vessels usually join the radial.

*Varieties in Muscular Relations.*\*—The brachial artery is occasionally concealed, in some part of its course, by muscular or tendinous slips derived from the Coraco-brachialis, Biceps, Brachialis anticus, and Pronator radii teres muscles.

\* See Struthers's *Anatomical and Physiological Observations*

FIG. 403.—The brachial artery.





*Surface Marking.*—The direction of the brachial artery is marked by a line drawn along the inner edge of the Biceps from the insertion of the Teres major muscle to the point midway between the condyles of the humerus.

*Surgical Anatomy.*—Compression of the brachial artery is required in cases of amputation and some other operations in the arm and forearm; and it will be observed that it may be effected in almost any part of the course of the artery. If pressure is made in the upper part of the limb, it should be directed from within outwards; and if in the lower part, from before backwards, as the artery lies on the inner side of the humerus above, and in front of it below. The most favourable situation is about the middle of the arm, where it lies on the tendon of the Coraco-brachialis on the inner flat side of the humerus.

The application of a ligature to the brachial artery may be required in cases of wound of the vessel, and in some cases of wound of the palmar arch. It is also sometimes necessary in cases of aneurism of the brachial, the radial, ulnar, or interosseous arteries. The artery may be secured in any part of its course. The chief guides in determining its position are the surface-markings produced by the inner margin of the Coraco-brachialis and Biceps, the known course of the vessel, and its pulsation, which should be carefully felt for before any operation is performed, as the vessel occasionally deviates from its usual position in the arm. In whatever situation the operation is performed, great care is necessary, on account of the extreme thinness of the parts covering the artery, and the intimate connection which the vessel has throughout its whole course with important nerves and veins. Sometimes a thin layer of muscular fibre is met with concealing the artery; if such is the case, it must be cut across in order to expose the vessel.

*In the upper third of the arm* the artery may be exposed in the following manner:—The patient being placed supine upon a table, the affected limb should be raised from the side, and the hand supinated. An incision about two inches in length should be made on the inner side of the Coraco-brachialis muscle, and the subjacent fascia cautiously divided, so as to avoid wounding the internal cutaneous nerve or basilic vein, which sometimes runs on the surface of the artery as high as the axilla. The fascia having been divided, it should be remembered that the ulnar and internal cutaneous nerves lie on the inner side of the artery, the median on the outer side, the latter nerve being occasionally superficial to the artery in this situation, and that the *venæ comites* are also in relation with the vessel, one on either side. These being carefully separated, the aneurism needle should be passed round the artery from the inner to the outer side.

If two arteries are present in the arm, in consequence of a high division, they are usually placed side by side; and if they are exposed in an operation, the surgeon should endeavour to ascertain, by alternately pressing on each vessel, which of the two communicates with the wound or aneurism, when a ligature may be applied accordingly; or if pulsation or hæmorrhage ceases only when both vessels are compressed, both vessels may be tied, as it may be concluded that the two communicate above the seat of disease, or are reunited.

It should also be remembered that two arteries may be present in the arm in a case of high division, and that one of these may be found along the inner intermuscular septum, in a line towards the inner condyle of the humerus; or in the usual position of the brachial, but deeply placed beneath the common trunk; a knowledge of these facts will suggest the precautions necessary in every case, and indicate the measures to be adopted when anomalies are met with.

*In the middle of the arm* the brachial artery may be exposed by making an incision along the inner margin of the Biceps muscle. The forearm being bent so as to relax the muscle, it should be drawn slightly aside, and, the fascia being carefully divided, the median nerve will be exposed lying upon the artery (sometimes beneath); this being drawn inwards and the muscle outwards, the artery should be separated from its accompanying veins and secured. In this situation the inferior profunda may be mistaken for the main trunk, especially if enlarged, from the collateral circulation having become established; this may be avoided by directing the incision externally towards the Biceps, rather than inwards or backwards towards the Triceps.

*The lower part of the brachial artery* is of interest in a surgical point of view, on account of the relation which it bears to the veins most commonly opened in venesection. Of these vessels, the median basilic is the largest and most prominent, and, consequently, the one usually selected for the operation. It should be remembered, that this vein runs parallel with the brachial artery, from which it is separated by the bicipital fascia, and that care should be taken, in opening the vein, not to carry the incision too deeply, so as to endanger the artery.

*Collateral Circulation.*—After the application of a ligature to the brachial artery in the upper third of the arm, the circulation is carried on by branches from the circumflex and subscapular arteries, anastomosing with ascending branches from the superior profunda. If the brachial is tied *below* the origin of the profunda arteries, the circulation is maintained by the branches of the profunda, anastomosing with the recurrent radial, ulnar, and interosseous arteries. In two cases described by Mr. South,\* in which the brachial

\* Chelius's *Surgery*, vol. ii. p. 254. See also White's engraving, referred to by Mr. South, of the anastomosing branches after ligature of the brachial, in White's *Cases in Surgery*. Porta also gives a case (with drawings) of the circulation after ligature of both brachial and radial.—*Alterazioni Patologiche delle Arterie*.

artery had been tied some time previously : in one ' a long portion of the artery had been obliterated, and sets of vessels are descending on either side from above the obliteration, to be received into others which ascend in a similar manner from below it. In the other the obliteration is less extensive, and a single curved artery about as big as a crow-quill passes from the upper to the lower open part of the artery.'

The branches of the brachial artery are, the

Superior Profunda.

Inferior Profunda.

Nutrient.

Anastomotica Magna.

Muscular.

The **superior profunda** arises from the inner and back part of the brachial, just below the lower border of the *Teres major*, and passes backwards to the interval between the outer and inner heads of the *Triceps* muscle, accompanied by the musculo-spiral nerve : it winds round the back part of the shaft of the humerus in the spiral groove, between the *Triceps* and the bone, to the outer side of the humerus, just above the external condyle, where it divides into two terminal branches. One of these pierces the external intermuscular septum, and descends to the space between the *Brachialis anticus* and *Supinator longus*, where it anastomoses with the recurrent branch of the radial artery ; while the other, the *posterior articular*, descends along the back of the external intermuscular septum to the back of the elbow-joint, where it anastomoses with the posterior interosseous recurrent, and across the back of the humerus with the posterior ulnar recurrent, the *anastomotica magna*, and inferior profunda (fig. 406). The superior profunda supplies the *Triceps* muscle and gives off a nutrient artery which enters the bone at the upper end of the musculo-spiral groove. Near its commencement it sends off a branch which passes upwards between the external and long heads of the *Triceps* muscle to anastomose with the posterior circumflex artery ; and, while in the groove, a small branch which accompanies a branch of the musculo-spiral nerve through the substance of the *Triceps* muscle and ends in the *Anconeus* below the outer condyle of the humerus.

The **nutrient artery** of the shaft of the humerus arises from the brachial, about the middle of the arm. Passing downwards, it enters the nutrient canal of that bone, near the insertion of the *Coraco-brachialis* muscle.

The **inferior profunda**, of small size, arises from the brachial, a little below the middle of the arm ; piercing the internal intermuscular septum, it descends on the surface of the inner head of the *Triceps* muscle, to the space between the inner condyle and olecranon, accompanied by the ulnar nerve, and terminates by anastomosing with the posterior ulnar recurrent and *anastomotica magna*. It also supplies a branch to the front of the internal condyle, which anastomoses with the anterior ulnar recurrent.

The **anastomotica magna** arises from the brachial, about two inches above the elbow-joint. It passes transversely inwards upon the *Brachialis anticus*, and piercing the internal intermuscular septum, winds round the back part of the humerus between the *Triceps* and the bone, forming an arch above the olecranon fossa, by its junction with the posterior articular branch of the superior profunda. As this vessel lies on the *Brachialis anticus*, branches ascend to join the inferior profunda ; and others descend in front of the inner condyle, to anastomose with the anterior ulnar recurrent. Behind the internal condyle an offset is given off which anastomoses with the inferior profunda and posterior ulnar recurrent arteries and supplies the *Triceps*.

The **muscular** are three or four large branches, which are distributed to the muscles in the course of the artery. They supply the *Coraco-brachialis*, *Biceps*, and *Brachialis anticus* muscles.

**The Anastomosis around the Elbow-joint** (fig. 406).—The vessels engaged in this anastomosis may be conveniently divided into those situated *in front* and *behind* the internal and external condyles. The branches anastomosing *in front*



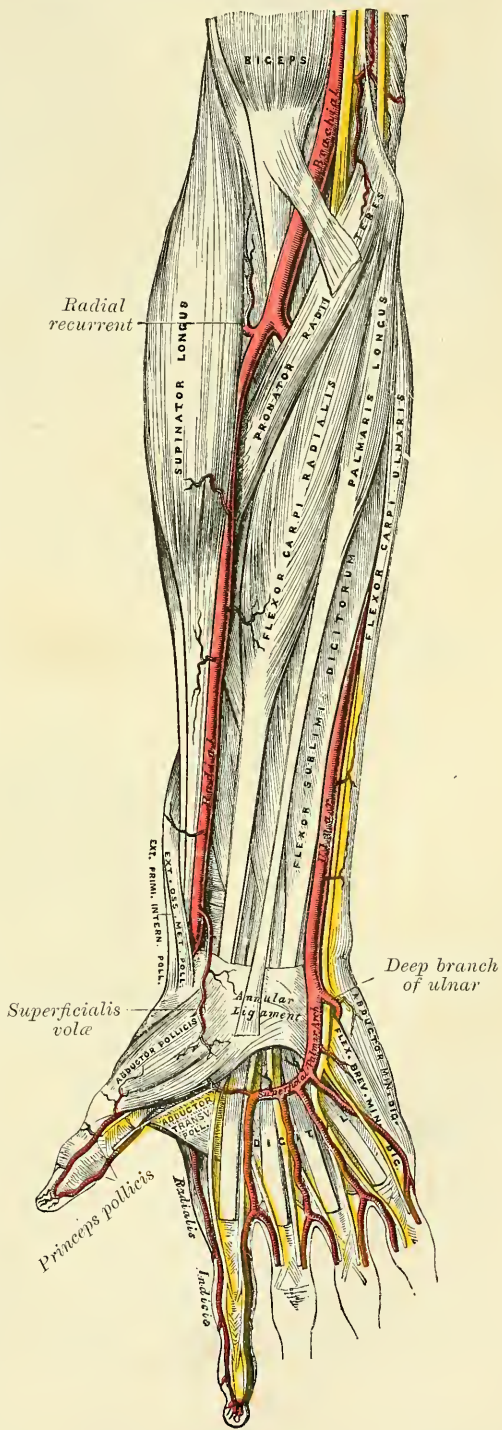
of the internal condyle are:—The anastomotica magna, the anterior ulnar recurrent, and the anterior terminal branch of the inferior profunda. Those *behind* the internal condyle are:—The anastomotica magna, the posterior ulnar recurrent, and the posterior terminal branch of the inferior profunda. The branches anastomosing *in front* of the external condyle are:—The radial recurrent and one of the terminal branches of the superior profunda. Those *behind* the external condyle (perhaps more properly described as being situated between the external condyle and the olecranon) are:—The anastomotica magna, the interosseous recurrent, and one of the terminal branches of the superior profunda. There is also a large arch of anastomosis above the olecranon, formed by the interosseous recurrent joining with the anastomotica magna and posterior ulnar recurrent (fig. 406).

From this description it will be observed that the anastomotica magna is the vessel most engaged, the only part of the anastomosis in which it is not employed being that *in front* of the external condyle.

RADIAL ARTERY (fig. 404)

The **Radial Artery** appears, from its direction, to be the continuation of the brachial, but, in size, it is smaller than the ulnar. It commences at the bifurcation of the brachial, just below the bend of the elbow, and passes along the radial side of the forearm to the wrist; it then winds backwards, round the outer side of the carpus, beneath the extensor tendons of the thumb to the upper end of the space between the metacarpal bones of the thumb and index finger, and, finally, passes forwards between the two heads of the First dorsal interosseous muscle, into the palm of the hand, where it crosses the metacarpal bones to the ulnar border of the hand, to form the deep palmar arch. At its termination, it inosculates with the deep branch of the ulnar artery. The

FIG. 404.—The radial and ulnar arteries.

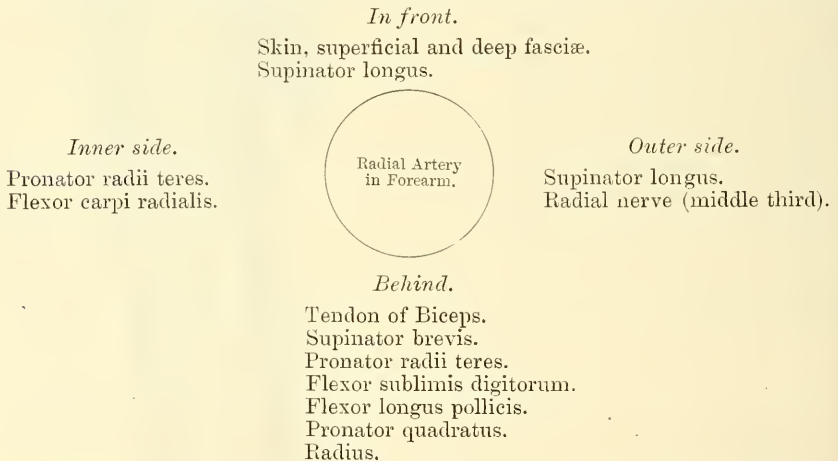




relations of this vessel may thus be conveniently divided into three parts, viz. in the forearm, at the back of the wrist, and in the hand.

**Relations.**—*In the forearm*, this vessel extends from opposite the neck of the radius, to the fore part of the styloid process, being placed to the inner side of the shaft of the bone above, and in front of it below. It is overlapped in the upper part of its course by the fleshy belly of the Supinator longus muscle; throughout the rest of its course it is superficial, being covered by the integument, the superficial and deep fasciæ. In its course downwards, it lies upon the tendon of the Biceps, the Supinator brevis, the Pronator radii teres, the radial origin of the Flexor sublimis digitorum, the Flexor longus pollicis, the Pronator quadratus, and the lower extremity of the radius. In the upper third of its course, it lies between the Supinator longus and the Pronator radii teres; in its lower two-thirds, between the tendons of the Supinator longus and the Flexor carpi radialis. The radial nerve lies along the outer side of the artery in the middle third of its course; and some filaments of the musculo-cutaneous nerve, after piercing the deep fascia, run along the lower part of the artery as it winds round the wrist. The vessel is accompanied by venæ comites throughout its whole course.

#### PLAN OF THE RELATIONS OF THE RADIAL ARTERY IN THE FOREARM



**At the wrist**, as it winds round the outer side of the carpus, from the styloid process to the first interosseous space, it lies upon the external lateral ligament, and then upon the scaphoid bone and trapezium, being covered by the extensor tendons of the thumb, subcutaneous veins, some filaments of the radial nerve, and the integument. It is accompanied by two veins, and a filament of the musculo-cutaneous nerve.

**In the hand**, it passes from the upper end of the first interosseous space, between the heads of the Abductor indicis or First dorsal interosseous muscle, transversely across the palm, to the base of the metacarpal bone of the little finger, where it inosculates with the communicating branch from the ulnar artery, forming the *deep palmar arch*. It lies upon the carpal extremities of the metacarpal bones and the Interossei muscles, being covered by the Adductor obliquus pollicis, the flexor tendons of the fingers, the Lumbricales, the Opponens and Flexor brevis minimi digiti. Alongside of it is the deep branch of the ulnar nerve, but running in the opposite direction, that is to say, from within outwards.

**Peculiarities.**—The origin of the radial artery, according to Quain, is, in nearly one case in eight, higher than usual; more frequently arising from the axillary or upper part of the brachial, than from the lower part of this vessel. The variations in the position of this vessel in the arm, and at the bend of the elbow, have been already mentioned. In the forearm it deviates less frequently from its position than the ulnar. It has been found

lying over the fascia instead of beneath it. It has also been observed on the surface of the Supinator longus, instead of under its inner border; and in turning round the wrist, it has been seen lying over, instead of beneath, the extensor tendons.

*Surface Marking.*—The position of the radial artery in the forearm is represented by a line drawn from the outer border of the tendon of the Biceps in the centre of the hollow in front of the elbow-joint with a straight course to the inner side of the fore part of the styloid process of the radius.

*Surgical Anatomy.*—The radial artery is much exposed to injury in its lower third, and is frequently wounded by the hand being driven through a pane of glass, by the slipping of a knife or chisel held in the other hand, and such-like accidents. The injury is often followed by a traumatic aneurism, for which the old operation of laying open the sac and securing the vessel above and below is required.

The operation of tying the radial artery is required in cases of wounds either of its trunk, or of some of its branches, or for aneurism: and it will be observed, that the vessel may be exposed in any part of its course through the forearm without the division of any muscular fibres. The operation in the middle or inferior third of the forearm is easily performed; but in the upper third, near the elbow, it is attended with some difficulty, from the greater depth of the vessel, and from its being overlapped by the Supinator longus muscle.

To tie the artery in the upper third, an incision three inches in length should be made through the integument, in a line drawn from the centre of the bend of the elbow to the front of the styloid process of the radius, avoiding the branches of the median vein; the fascia of the arm being divided, and the Supinator longus drawn a little outwards, the artery will be exposed. The venæ comites should be carefully separated from the vessel, and the ligature passed from the radial to the ulnar side.

In the middle third of the forearm the artery may be exposed by making an incision of similar length on the inner margin of the Supinator longus. In this situation, the radial nerve lies in close relation with the outer side of the artery, and should, as well as the veins, be carefully avoided.

In the lower third, the artery is easily secured by dividing the integument and fascia in the interval between the tendons of the Supinator longus and Flexor carpi radialis muscles.

The branches of the radial artery may be divided into three groups, corresponding with the three regions in which the vessel is situated.

<i>In the forearm.</i>	<i>Wrist.</i>	<i>Hand.</i>
Radial Recurrent.	Posterior Carpal.	Princeps Pollicis.
Muscular.	Metacarpal.	Radialis Indicis.
Anterior Carpal.	Dorsales Pollicis.	Perforating.
Superficialis Volæ.	Dorsalis Indicis.	Interosseous.
		Palmar Recurrent.

The **radial recurrent** is given off immediately below the elbow. It ascends between the branches of the musculo-spiral nerve lying on the Supinator brevis, and then between the Supinator longus and Brachialis anticus, supplying these muscles and the elbow-joint, and anastomosing with one of the terminal branches of the superior profunda.

The **muscular branches** are distributed to the muscles on the radial side of the forearm.

The **anterior carpal** is a small vessel which arises from the radial artery near the lower border of the Pronator quadratus, and, running inwards in front of the radius, anastomoses with the anterior carpal branch of the ulnar artery. In this way an arterial anastomosis, *anterior carpal arch*, is formed in front of the wrist: it is joined by branches from the anterior interosseous above, and by recurrent branches from the deep carpal arch below, and gives off branches which descend to supply the articulations of the wrist and carpus.

The **superficialis volæ** arises from the radial artery, just where this vessel is about to wind round the wrist. Running forwards, it passes between the muscles of the thumb, which it supplies, and sometimes anastomoses with the palmar portion of the ulnar artery, completing the superficial palmar arch. This vessel varies considerably in size: usually it is very small, and terminates in the muscles of the thumb; sometimes it is as large as the continuation of the radial.

The **posterior carpal** is a small vessel which arises from the radial artery





The **radialis indicis** arises close to the preceding, descends between the Abductor indicis and Adductor transversus pollicis, and runs along the radial side of the index finger to its extremity, where it anastomoses with the collateral digital artery from the superficial palmar arch. At the lower border of the Adductor transversus pollicis, this vessel anastomoses with the princeps pollicis, and gives a communicating branch to the superficial palmar arch.

The **perforating arteries**, three in number, pass backwards between the heads of the last three Dorsal interossei muscles, to inosculate with the dorsal interosseous arteries.

The **palmar interosseous**, three or four in number, are branches of the deep palmar arch; they run forwards upon the Interossei muscles, and anastomose at the clefts of the fingers with the digital branches of the superficial arch.

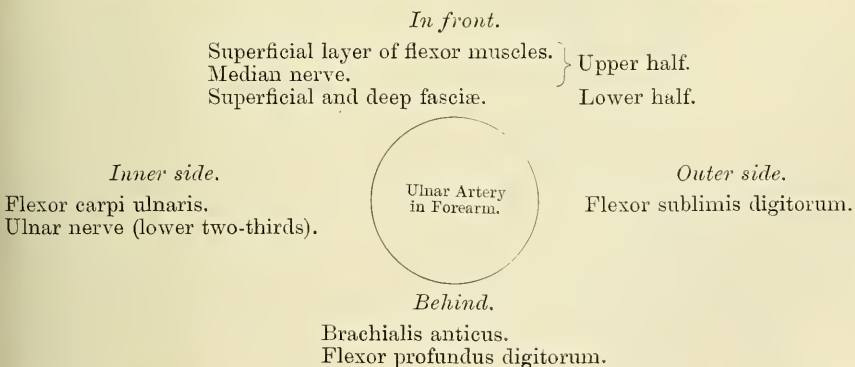
The **palmar recurrent branches** arise from the concavity of the deep palmar arch. They pass upwards in front of the wrist, supplying the carpal articulations and anastomosing with the anterior carpal arch.

ULNAR ARTERY

The **Ulnar Artery**, the larger of the two terminal branches of the brachial, commences a little below the bend of the elbow, and crosses obliquely the inner side of the forearm, to the commencement of its lower half; it then runs along its ulnar border to the wrist, crosses the annular ligament on the radial side of the pisiform bone, and immediately beyond this bone divides into two branches, which enter into the formation of the superficial and deep palmar arches.

**Relations in the Forearm.**—In its *upper half*, it is deeply seated, being covered by all the superficial flexor muscles, excepting the Flexor carpi ulnaris; it is crossed by the median nerve, which lies to its inner side for about an inch, and it lies upon the Brachialis anticus and Flexor profundus digitorum muscles. In the *lower half* of the forearm, it lies upon the Flexor profundus, being covered by the integument, the superficial and deep fasciæ, and is placed between the Flexor carpi ulnaris and Flexor sublimis digitorum muscles. It is accompanied by two venæ comites; the ulnar nerve lies on its inner side for the lower two-thirds of its extent, and a small branch from the nerve descends on the lower part of the vessel to the palm of the hand.

PLAN OF RELATIONS OF THE ULNAR ARTERY IN THE FOREARM



**At the wrist** (fig. 404) the ulnar artery is covered by the integument and fascia, and lies upon the anterior annular ligament. On its inner side is the pisiform bone. The ulnar nerve lies at the inner side, and somewhat behind the artery.

**Peculiarities.**—The ulnar artery has been found to vary in its origin nearly in the proportion of one in thirteen cases, in one case arising lower than usual, about two or three inches below the elbow, and in all other cases much higher, the brachial being a more frequent source of origin than the axillary.

Variations in the position of this vessel are more frequent than in the radial. When its origin is normal, the course of the vessel is rarely changed. When it arises high up, it is almost invariably superficial to the flexor muscles in the forearm, lying commonly beneath the fascia, more rarely between the fascia and integument. In a few cases, its position was subcutaneous in the upper part of the forearm, subaponeurotic in the lower part.

*Surface Marking.*—On account of the curved direction of the ulnar artery, the line on the surface of the body which indicates its course is somewhat complicated. First, draw a line from the front of the internal condyle of the humerus to the radial side of the pisiform bone; the lower two-thirds of this line represents the course of the middle and lower third of the ulnar artery. Secondly, draw a line from the centre of the hollow in front of the elbow-joint to the junction of the upper and middle third of the first line; this represents the course of the upper third of the artery.

*Surgical Anatomy.*—The application of a ligature to this vessel is required in cases of wound of the artery, or of its branches, or in consequence of aneurism. In the upper half of the forearm, the artery is deeply seated beneath the superficial flexor muscles, and the application of a ligature in this situation is attended with some difficulty. An incision is to be made in the course of a line drawn from the front of the internal condyle of the humerus to the outer side of the pisiform bone, so that the centre of the incision is three fingers' breadth below the internal condyle. The skin and superficial fascia having been divided, and the deep fascia exposed, the white line which separates the Flexor carpi ulnaris from the other flexor muscles is to be sought for, and the fascia incised in this line. The Flexor carpi ulnaris is now to be carefully separated from the other muscles, when the ulnar nerve will be exposed and must be drawn aside. Some little distance below the nerve, the artery will be found accompanied by its venæ comites, and may be ligatured by passing the needle from within outwards. In the middle and lower third of the forearm, this vessel may be easily secured by making an incision on the radial side of the tendon of the Flexor carpi ulnaris: the deep fascia being divided, and the Flexor carpi ulnaris and its companion muscle, the Flexor sublimis, being separated from each other, the vessel will be exposed, accompanied by its venæ comites, the ulnar nerve lying on its inner side. The veins being separated from the artery, the ligature should be passed from the ulnar to the radial side, taking care to avoid the ulnar nerve.

The branches of the ulnar artery may be arranged in the following groups:—

	{	Anterior Ulnar Recurrent.
		Posterior Ulnar Recurrent.
<i>Forearm.</i>	{	Interosseous { Anterior Interosseous.
		{ Posterior Interosseous.
		Muscular.
<i>Wrist.</i>	{	Anterior Carpal.
		Posterior Carpal.
<i>Hand.</i>	{	Deep Palmar or Communicating.
		Superficial Palmar Arch.

The **anterior ulnar recurrent** (fig. 405) arises immediately below the elbow-joint, passes upwards and inwards between the Brachialis anticus and Pronator radii teres, supplies those muscles, and, in front of the inner condyle, anastomoses with the anastomotica magna and inferior profunda.

The **posterior ulnar recurrent** is much larger, and arises somewhat lower than the preceding. It passes backwards and inwards, beneath the Flexor sublimis, and ascends behind the inner condyle of the humerus. In the interval between this process and the olecranon, it lies beneath the Flexor carpi ulnaris, ascending between the heads of that muscle, in relation with the ulnar nerve; it supplies the neighbouring muscles and joint, and anastomoses with the inferior profunda, anastomotica magna, and interosseous recurrent arteries (fig. 406).

The **interosseous artery** (fig. 405) is a short trunk about an inch in length, and of considerable size, which arises immediately below the tuberosity of the radius, and, passing backwards to the upper border of the interosseous membrane, divides into two branches, the *anterior* and *posterior interosseous*.

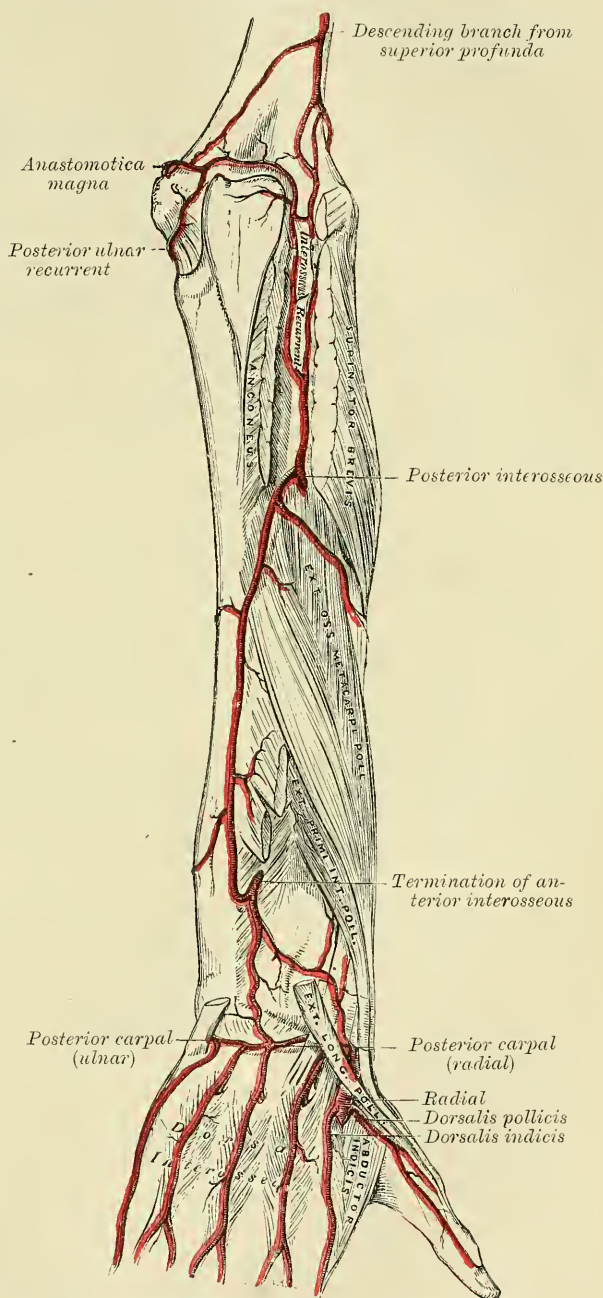
The **anterior interosseous** passes down the forearm on the anterior surface of the interosseous membrane, to which it is connected by a thin aponeurotic arch. It is accompanied by the interosseous branch of the median nerve, and overlapped by the contiguous margins of the Flexor profundus digitorum and Flexor

longus pollicis muscles, giving off in this situation muscular branches, and the nutrient arteries of the radius and ulna. At the upper border of the Pronator quadratus, a branch descends beneath the muscle, to anastomose in front of the carpus with the anterior carpal arch. The continuation of the artery passes behind the Pronator quadratus, and, piercing the interosseous membrane, gets to the back of the forearm, and anastomoses with the posterior interosseous artery (fig. 406). It then descends to the back of the wrist to join the posterior carpal arch. The anterior interosseous gives off a long, slender branch, the *median artery*, which accompanies the median nerve, and gives offsets to its substance. This artery is sometimes much enlarged. It also gives off nutrient branches to the radius and ulna about the middle of the forearm.

The **posterior interosseous artery** passes backwards through the interval between the oblique ligament and the upper border of the interosseous membrane. It appears between the contiguous borders of the Supinator brevis and the Extensor ossis metacarpi pollicis, and runs down the back part of the forearm, between the superficial and deep layer of muscles, to both of which it distributes branches. At the lower part of the forearm it anastomoses with the termination of the anterior interosseous artery. Then, continuing its course over the head of the ulna, it joins the posterior carpal branch of the ulnar artery.

This artery gives off, near its origin, the *interosseous recurrent branch*. The **interosseous recurrent artery** is a large vessel which ascends to the interval between the external condyle and olecranon, on or through the fibres of the Supinator brevis, but beneath the Anconeus, anastomosing with a branch

FIG. 406.—Arteries of the back of the forearm and hand.



This artery gives off, near its origin, the *interosseous recurrent branch*.

The **interosseous recurrent artery** is a large vessel which ascends to the interval between the external condyle and olecranon, on or through the fibres of the Supinator brevis, but beneath the Anconeus, anastomosing with a branch



from the superior profunda, and with the posterior ulnar recurrent and anastomotica magna.

The **muscular branches** are distributed to the muscles along the ulnar side of the forearm.

The **anterior carpal** is a small vessel which crosses the front of the carpus beneath the tendons of the Flexor profundus, and inosculates with a corresponding branch of the radial artery.

The **posterior carpal** arises immediately above the pisiform bone, and winds backwards beneath the tendon of the Flexor carpi ulnaris; it passes across the dorsal surface of the carpus beneath the extensor tendons, anastomosing with a corresponding branch of the radial artery, and forming the *posterior carpal arch*. Immediately after its origin, it gives off a small branch, which runs along the ulnar side of the metacarpal bone of the little finger, forming one of the *metacarpal arteries*, and supplies the ulnar side of the dorsal surface of the little finger.

The **branch to the deep palmar arch** or **communicating branch** (fig. 405) passes deeply inwards between the Abductor minimi digiti and Flexor brevis minimi digiti, near their origins; it anastomoses with the termination of the radial artery, completing the deep palmar arch.

The **branch to the superficial palmar arch** appears to be the direct continuation of the ulnar artery in the hand; it forms the greater part of the superficial palmar arch.

#### THE SUPERFICIAL PALMAR ARCH


The **Superficial Palmar arch** is formed by the ulnar artery in the hand, and is completed on the outer side by this vessel anastomosing with a branch from the radialis indicis, though sometimes the arch is completed by the ulnar anastomosing with the superficialis volæ branch of the radial artery. The arch passes across the palm, describing a curve, with its convexity forwards, to the space between the ball of the thumb and the index finger, where the above mentioned anastomosis takes place.

**Relations.**—The superficial palmar arch is covered by the skin, the Palmaris brevis, and the palmar fascia. It lies upon the annular ligament, origin of the muscles of the little finger, the tendons of the superficial flexor of the fingers, and the divisions of the median and ulnar nerves.

#### PLAN OF RELATIONS OF THE SUPERFICIAL PALMAR ARCH

*In front.*

Skin.  
Palmaris brevis.  
Palmar fascia.



*Behind.*

Annular ligament.  
Origin of muscles of little finger.  
Superficial flexor tendons.  
Divisions of median and ulnar nerves.

The branches of the superficial palmar arch are the digital.

The **digital branches** (fig. 404), four in number, are given off from the convexity of the superficial palmar arch. They supply the ulnar side of the little

finger, and the adjoining sides of the little, ring, middle, and index fingers; the radial side of the index finger and thumb being supplied from the radial artery. The digital arteries at first lie superficial to the flexor tendons, but as they pass forwards with the digital nerves to the clefts between the fingers, they lie between them, and are there joined by the interosseous branches from the deep palmar arch. The digital arteries on the sides of the fingers lie beneath the digital nerves; and, about the middle of the last phalanx, the two branches for each finger form an arch, from the convexity of which branches pass to supply the pulp of the finger.

*Surface Marking.*—The superficial palmar arch is represented by a curved line, starting from the outer side of the pisiform bone, and carried downwards as far as the middle third of the palm, and then curved outwards on a level with the upper end of the cleft between the thumb and index finger.

The deep palmar arch is situated about half an inch nearer to the carpus.

*Surgical Anatomy.*—Wounds of the palmar arches are of special interest, and are always difficult to deal with. When the wound in the superficial tissues is extensive, it may be possible to secure the bleeding ends of the vessel; but when there is a small punctured wound, as from a penknife or piece of glass, pressure systematically applied is probably the best course of treatment, as there is difficulty in reaching the wounded vessel without damaging important structures. At the same time it must be admitted that pressure applied to the palm of the hand, to arrest hæmorrhage from a wound of one of the palmar arches, especially the deep arch, is apt to be followed by sloughing, owing to the rigidity of the parts and the facility with which a considerable amount of pressure can be applied. In wounds of the deep palmar arch, a ligature may be applied to the bleeding points, from the dorsum of the hand, by resection of the upper part of the third metacarpal bone. It is useless in these cases to ligature one of the arteries of the forearm alone, and indeed simultaneous ligature of both radial and ulnar arteries above the wrist is often unsuccessful, on account of the anastomosis carried on by the carpal arches. Therefore, upon the failure of pressure to arrest hæmorrhage, it is expedient to apply a ligature to the brachial artery.

## ARTERIES OF THE TRUNK

### THE DESCENDING AORTA

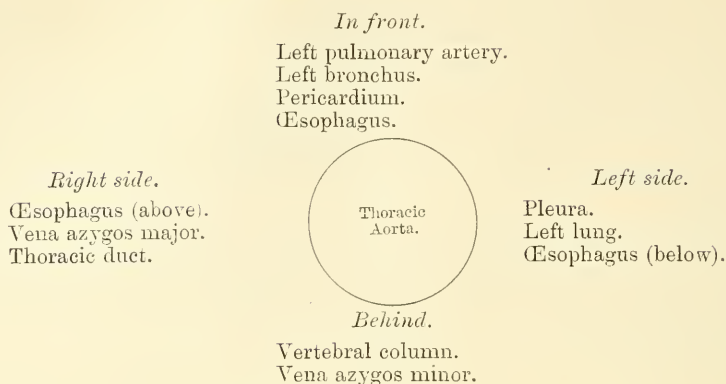
The **Descending Aorta** is divided into two portions, the *thoracic* and *abdominal*, in correspondence with the two great cavities of the trunk in which it is situated.

### THE THORACIC AORTA

The **Thoracic Aorta** commences at the lower border of the fourth dorsal vertebra, on the left side, and terminates at the aortic opening in the Diaphragm, in front of the lower border of the last dorsal vertebra. At its commencement, it is situated on the left side of the spine; it approaches the median line as it descends; and, at its termination, lies directly in front of the column. The direction of this vessel being influenced by the spine, upon which it rests, it describes a curve which is concave forwards in the dorsal region. As the branches given off from it are small, the diminution in the size of the vessel is inconsiderable. It is contained in the back part of the posterior mediastinum.

**Relations.**—It is in relation, *in front*, from above downwards, with the left pulmonary artery, the left bronchus, the pericardium, and the œsophagus; *behind*, with the vertebral column, and the vena azygos minor; on the *right side*, with the vena azygos major, and thoracic duct; on the *left side*, with the left pleura and lung. The œsophagus, with its accompanying nerves, lies on the right side of the aorta *above*; but at the lower part of the thorax it gets in front of the aorta, and close to the Diaphragm is situated to its left side.

## PLAN OF THE RELATIONS OF THE THORACIC AORTA



The aorta is occasionally found to be obliterated at a particular spot, viz. at the junction of the arch with the thoracic aorta, just below the ductus arteriosus. Whether this is the result of disease, or of congenital malformation, is immaterial to our present purpose; it affords an interesting opportunity of observing the resources of the collateral circulation. The course of the anastomosing vessels, by which the blood is brought from the upper to the lower part of the artery, will be found well described in an account of two cases in the *Pathological Transactions*, vols. viii. and x. In the former (p. 162), Mr. Sydney Jones thus sums up the detailed description of the anastomosing vessels:—The principal communications by which the circulation was carried on, were—Firstly, the internal mammary, anastomosing with the intercostal arteries, with the phrenic of the abdominal aorta by means of the musculo-phrenic and comes nervi phrenici, and largely with the deep epigastric. Secondly, the superior intercostal, anastomosing anteriorly by means of a large branch with the first aortic intercostal, and posteriorly with the posterior branch of the same artery. Thirdly, the inferior thyroid, by means of a branch about the size of an ordinary radial, formed a communication with the first aortic intercostal. Fourthly, the transversalis colli, by means of very large communications with the posterior branches of the intercostals. Fifthly, the branches (of the subclavian and axillary) going to the side of the chest were large, and anastomosed freely with the lateral branches of the intercostals.’ In the second case also (vol. x. p. 97), Mr. Wood describes the anastomoses in a somewhat similar manner, adding the remark, that ‘the blood which was brought into the aorta through the anastomoses of the intercostal arteries appeared to be expended principally in supplying the abdomen and pelvis; while the supply to the lower extremities had passed through the internal mammary and epigastries.’

*Surgical Anatomy.*—The student should now consider the effects likely to be produced by aneurism of the thoracic aorta, a disease of common occurrence. When we consider the great depth of the vessel from the surface, and the number of important structures which surround it on every side, it may easily be conceived what a variety of obscure symptoms may arise from disease of this part of the arterial system, and how they may be liable to be mistaken for those of other affections. Aneurism of the thoracic aorta most usually extends backwards, along the left side of the spine, producing absorption of the bodies of the vertebræ, with curvature of the spine; whilst the irritation or pressure on the cord will give rise to pain, either in the chest, back, or loins, with radiating pain in the left upper intercostal spaces, from pressure on the intercostal nerves; at the same time the tumour may project backwards on each side of the spine, beneath the integument, as a pulsating swelling, simulating abscess connected with diseased bone; or it may displace the œsophagus, and compress the lung on one or the other side. If the tumour extend forward, it may press upon and displace the heart, giving rise to palpitation and other symptoms of disease of that organ; or it may displace, or even compress, the œsophagus, causing pain and difficulty of swallowing, as in stricture of that tube; and ultimately even open into it by ulceration, producing fatal hæmorrhage. If the disease extends to the right side, it may press upon the thoracic duct; or it may burst into the pleural cavity, or into the trachea or lung; and lastly, it may open into the posterior mediastinum.

## BRANCHES OF THE THORACIC AORTA

Pericardiac.	Œsophageal.
Bronchial.	Posterior Mediastinal.
Intercostal.	

The **pericardiac** are a few small vessels, irregular in their origin, distributed to the pericardium.



The **bronchial arteries** are the nutrient vessels of the lungs, and vary in number, size, and origin. That of the right side arises from the first aortic intercostal, or by a common trunk with the left bronchial, from the front of the thoracic aorta. Those of the left side, usually two in number, arise from the thoracic aorta, one a little lower than the other. Each vessel is directed to the back part of the corresponding bronchus along which it runs, dividing and subdividing upon the bronchial tubes, supplying them, the cellular tissue of the lungs, the bronchial glands, and the œsophagus.

The **œsophageal arteries**, usually four or five in number, arise from the front of the aorta, and pass obliquely downwards to the œsophagus, forming a chain of anastomoses along that tube, anastomosing with the œsophageal branches of the inferior thyroid arteries above, and with ascending branches from the phrenic and gastric arteries below.

The **posterior mediastinal arteries** are numerous small vessels which supply the glands and loose areolar tissue in the mediastinum.

The **Intercostal arteries** arise from the back of the aorta. They are usually ten in number on each side, the two superior intercostal spaces being supplied by the superior intercostal, a branch of the subclavian. The second space usually receives a considerable branch from the first aortic intercostal, which joins with the branch from the superior intercostal of the subclavian. The lowest or tenth intercostal branch from the aorta runs along the lower border of the last rib, and is named the *subcostal artery*. The right intercostals are longer than the left, on account of the position of the aorta on the left side of the spine: they pass outwards, across the bodies of the vertebræ, to the intercostal spaces, being covered by the pleura, the œsophagus, thoracic duct, sympathetic nerve, and the vena azygos major; the left passing outwards are crossed by the sympathetic; the upper two are also crossed by the superior intercostal vein, the lower by the vena azygos minor. In each intercostal space the artery passes outwards, at first lying upon the External intercostal muscle, covered in front by the pleura and a thin fascia. It then passes between the two layers of Intercostal muscles, and having ascended obliquely to the lower border of the rib above it is continued forwards in the groove on its lower border and anastomoses with the anterior intercostal branches of the internal mammary. The first aortic intercostal anastomoses with the superior intercostal, and the last three pass between the abdominal muscles, inosculating with the epigastric in front, and with the phrenic and lumbar arteries. Each intercostal artery is accompanied by a vein and nerve, the former being above, and the latter below, except in the upper intercostal spaces, where the nerve is at first above the artery. The arteries are protected from pressure during the action of the Intercostal muscles, by fibrous arches thrown across, and attached by each extremity to the bone. The lower intercostal arteries are continued anteriorly from the intercostal spaces into the abdominal wall, except the last, the *subcostal*, which lies throughout its whole course in the abdominal wall, since it is placed below the last rib. They pass behind the costal cartilages between the Internal oblique and Transversalis muscle to the sheath of the Rectus, where they anastomose with the internal mammary and the deep epigastric arteries. Behind, the subcostal artery anastomoses with the first lumbar artery.

Each intercostal artery gives off the following branches:—

Posterior or dorsal branch.	Spinal.
Collateral intercostal.	

The *posterior or dorsal branch* of each intercostal artery passes backwards to the inner side of the anterior costo-transverse ligament, and divides into an external and internal branch, which are distributed to the muscles and integument of the back.

The *spinal branch*, which enters the spinal canal through the intervertebral foramen, is distributed to the spinal cord and its membranes, and to the bodies





a little to the left side of the vertebral column, terminates on the body of the fourth lumbar vertebra, commonly a little to the left of the middle line,\* where it divides into the two common iliac arteries. It diminishes rapidly in size, in consequence of the many large branches which it gives off. As it lies upon the bodies of the vertebræ, the curve which it describes is convex forwards, the greatest convexity corresponding to the third lumbar vertebra, which is a little above and to the left side of the umbilicus.

**Relations.**—It is covered, *in front*, by the lesser omentum and stomach, behind which are the branches of the cœliac axis, and the solar plexus: below these, by the splenic vein, the pancreas, the left renal vein, the transverse portion of the duodenum, the mesentery, and aortic plexus. *Behind*, it is separated from the lumbar vertebræ by the left lumbar veins, the receptaculum chyli, and thoracic duct. On the *right side* it is in relation with the inferior vena cava (the right crus of the Diaphragm being interposed above), the vena azygos major, thoracic duct, and right semilunar ganglion; on the *left side*, with the sympathetic nerve, and left semilunar ganglion.


PLAN OF THE RELATIONS OF THE ABDOMINAL AORTA

*In front.*

Lesser omentum and stomach.  
 Branches of the cœliac axis and solar plexus.  
 Splenic vein.  
 Pancreas.  
 Left renal vein.  
 Transverse duodenum.  
 Mesentery.  
 Aortic plexus.

*Right side.*

Right crus of Diaphragm.  
 Inferior vena cava.  
 Vena azygos major.  
 Thoracic duct.  
 Right semilunar ganglion.



*Left side.*

Sympathetic nerve.  
 Left semilunar ganglion.

*Behind.*

Left lumbar veins.  
 Receptaculum chyli.  
 Thoracic duct.  
 Vertebral column.

**Surface Marking.**—In order to map out the abdominal aorta on the surface of the abdomen, a line must be drawn from the middle line of the body, on a level with the distal extremity of the seventh costal cartilage, downwards and slightly to the left, so that it just skirts the umbilicus, to a zone drawn round the body opposite the highest point of the crest of the ilium. This point is generally half an inch below and to the left of the umbilicus, but as the position of this structure varies with the obesity of the individual, it is not a reliable landmark as to the situation of the bifurcation of the aorta.

**Surgical Anatomy.**—Aneurisms of the abdominal aorta near the cœliac axis communicate in nearly equal proportion with the anterior and posterior parts of the artery.

When an aneurismal sac is connected with the back part of the abdominal aorta, it usually produces absorption of the bodies of the vertebræ, and forms a pulsating tumour, that presents itself in the left hypochondriac or epigastric regions, and is accompanied by symptoms of disturbance in the alimentary canal. Pain is invariably present, and is usually of two kinds—a fixed and constant pain in the back, caused by the tumour pressing on or displacing the branches of the solar plexus and splanchnic nerves; and a sharp lancinating pain, radiating along those branches of the lumbar nerves which are pressed on by the tumour; hence the pain in the loins, the testes, the hypogastrium, and in the lower limb (usually of the left side). This form of aneurism usually bursts into the peritoneal cavity, or behind the peritoneum, in the left hypochondriac region; or it may form a large aneurismal sac, extending down as low as Poupart's ligament;

\* Lord Lister, having accurately examined 30 bodies in order to ascertain the exact point of termination of this vessel, found it 'either absolutely, or almost absolutely, mesial in 15, while in 13 it deviated more or less to the left, and in 2 was slightly to the right.'—*System of Surgery*, edited by T. Holmes, 2nd ed. vol. v. p. 652.



hæmorrhage in these cases being generally very extensive, but slowly produced, and not rapidly fatal.

When an aneurismal sac is connected with the front of the aorta near the cœliac axis, it forms a pulsating tumour in the left hypochondriac or epigastric regions, usually attended with symptoms of disturbance of the alimentary canal, as sickness, dyspepsia, or constipation, and accompanied by pain, which is constant, but nearly always fixed, in the loins, epigastrium, or some part of the abdomen; the radiating pain being rare, as the lumbar nerves are seldom implicated. This form of aneurism may burst into the peritoneal cavity, or behind the peritoneum, between the layers of the mesentery, or, more rarely, into the duodenum; it rarely extends backwards so as to affect the spine.

The abdominal aorta has been tied several times, and although none of the patients permanently recovered, still, as one of them lived as long as ten days, the possibility of the re-establishment of the circulation may be considered to be proved. In the lower animals this artery has been often successfully tied. The vessel may be reached in several ways. In the original operation, performed by Sir A. Cooper, an incision was made in the linea alba, the peritoneum opened in front, the finger carried down amongst the intestines, towards the spine, the peritoneum again opened behind, by scratching through the mesentery, and the vessel thus reached. Or either of the operations, described below, for securing the common iliac artery, may, by extending the dissection a sufficient distance upwards, be made use of to expose the aorta. The chief difficulty in the dead subject consists in isolating the artery, in consequence of its great depth; but in the living subject, the embarrassment resulting from the proximity of the aneurismal tumour, and the great probability of disease in the vessel itself, add to the dangers and difficulties of this formidable operation so greatly, that it is very doubtful whether it ought ever to be performed.

The collateral circulation would be carried on by the anastomosis between the internal mammary and the deep epigastric; by the free communication between the superior and inferior mesenterics, if the ligature were placed above the latter vessel; or by the anastomosis between the inferior mesenteric and the internal pudic. when (as is more common) the point of ligature is below the origin of the inferior mesenteric; and possibly by the anastomoses of the lumbar arteries with the branches of the internal iliac.

The circulation through the abdominal aorta may be commanded, in thin persons, by firm pressure with the fingers. A tourniquet has been invented for this purpose, which is sometimes used in amputation at the hip-joint and some other operations.

#### BRANCHES OF THE ABDOMINAL AORTA

Phrenic.		Renal.
Cœliac axis.	{	Gastric.
		Hepatic.
		Splenic.
Superior Mesenteric.		Lumbar.
Suprarenal.		Sacra Media.

The branches may be divided into two sets: 1. Those supplying the viscera.  
2. Those distributed to the walls of the abdomen.

<i>Visceral Branches.</i>		Renal.
Cœliac Axis.	{	Gastric.
		Hepatic.
		Splenic.
Superior Mesenteric.		<i>Parietal Branches.</i>
Inferior Mesenteric.		Phrenic.
Suprarenal.		Lumbar.
		Sacra Media.

#### CŒLIAC AXIS (fig. 408)

To expose this artery, raise the liver, draw down the stomach, and then tear through the layers of the lesser omentum.

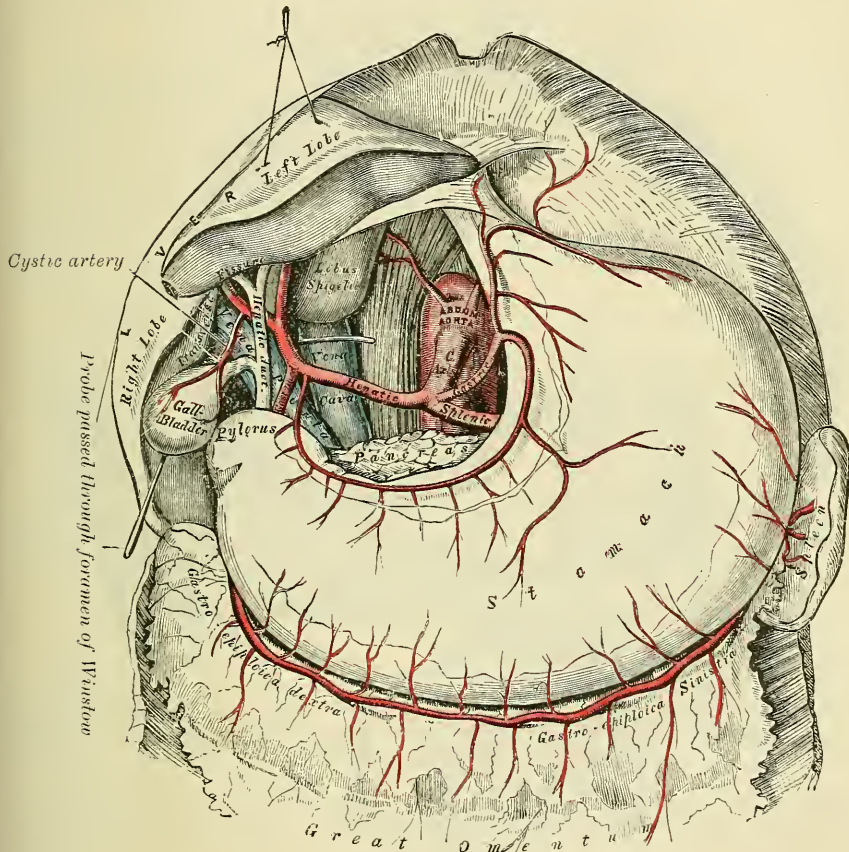
The **Cœliac Axis** is a short thick trunk, about half an inch in length, which arises from the aorta, close to the margin of the opening in the Diaphragm, and passing nearly horizontally forwards (in the erect posture), divides into three large branches, the *gastric*, *hepatic*, and *splenic*, occasionally giving off one of the phrenic arteries.

**Relations.**—It is covered by the lesser omentum. On the *right side*, it is in

relation with the right semilunar ganglion, and the lobus Spigelii; on the *left side* with the left semilunar ganglion and cardiac end of the stomach. *Below*, it rests upon the upper border of the pancreas.

The **Gastric or Coronary Artery**, the smallest of the three branches of the cœliac axis, passes upwards and to the left side, to the cardiac orifice of the stomach, distributing branches to the œsophagus, which anastomose with the aortic œsophageal arteries; others supply the cardiac end of the stomach, inosculating with branches of the splenic artery: it then passes from left to right, along the lesser curvature of the stomach to the pylorus, lying in its course between the layers of the lesser omentum, and giving branches to both surfaces of the organ: at its termination it anastomoses with the pyloric branch of the hepatic.

FIG. 408.—The cœliac axis and its branches, the liver having been raised, and the lesser omentum removed.



The **Hepatic Artery** in the adult is intermediate in size between the gastric and splenic; in the fœtus, it is the largest of the three branches of the cœliac axis. It is first directed forwards and to the right, to the upper margin of the pyloric end of the stomach, forming the lower boundary of the foramen of Winslow. It then passes upwards between the layers of the lesser omentum, and in front of the foramen of Winslow, to the transverse fissure of the liver, where it divides into two branches, right and left, which supply the corresponding lobes of that organ, accompanying the ramifications of the vena portæ and hepatic duct. The hepatic artery, in its course along the right border of the lesser omentum, is in relation with the ductus communis choledochus and portal veins, the duct lying to the right of the artery, and the vena portæ behind.







of the duodenum and pancreas. It supplies both these organs, and anastomoses with the inferior pancreatico-duodenal branch of the superior mesenteric artery, and with the pancreatic branches of the splenic.

The **cystic artery** (fig. 408), usually a branch of the right hepatic, passes upwards and forwards along the neck of the gall-bladder, and divides into two branches, one of which ramifies on its free surface, the other between it and the substance of the liver.

The **Splenic Artery**, in the adult, is the largest of the three branches of the celiac axis, and is remarkable for the extreme tortuosity of its course. It passes horizontally to the left side along the upper border of the pancreas, accompanied by the splenic vein, which lies below it; and, on arriving near the spleen, divides into branches, some of which enter the hilum of that organ to be distributed to its structure, whilst others are distributed to the great end of the stomach. Its branches are, the

Pancreaticæ Parvæ.	Gastric (Vasa Brevia).
Pancreatica Magna.	Gastro-epiploica Sinistra.

The **pancreatic** are numerous small branches derived from the splenic as it runs behind the upper border of the pancreas, supplying its middle and left parts. One of these, larger than the rest, is given off from the splenic near the left extremity of the pancreas; it runs from left to right near the posterior surface of the gland, following the course of the pancreatic duct, and is called the **pancreatica magna**. These vessels anastomose with the pancreatic branches of the pancreatico-duodenal arteries, derived from the hepatic on the one hand and superior mesenteric on the other.

The **gastric (vasa brevia)** consist of from five to seven small branches, which arise either from the termination of the splenic artery, or from its terminal branches; and, passing from left to right, between the layers of the gastro-splenic omentum, are distributed to the great curvature of the stomach; anastomosing with branches of the gastric and gastro-epiploica sinistra arteries.

The **gastro-epiploica sinistra**, the largest branch of the splenic, runs from left to right along the great curvature of the stomach, between the layers of the great omentum, and anastomoses with the gastro-epiploica dextra. In its course it distributes several branches to the stomach, which ascend upon both surfaces; others descend to supply the omentum.

#### SUPERIOR MESENTERIC ARTERY (fig. 410)

In order to expose this vessel, raise the great omentum and transverse colon, draw down the small intestines, and cut through the peritoneum where the transverse mesocolon and mesentery join: the artery will then be exposed, just as it issues from beneath the lower border of the pancreas.

The **Superior Mesenteric Artery** supplies the whole length of the small intestine, except the first part of the duodenum; it also supplies the cæcum, ascending and transverse colon; it is a vessel of large size, arising from the fore part of the aorta, about a quarter of an inch below the celiac axis; being covered at its origin by the splenic vein and pancreas. It passes forwards, between the pancreas and transverse portion of the duodenum, crosses in front of this portion of the intestine, and descends between the layers of the mesentery to the right iliac fossa, where it terminates, considerably diminished in size. In its course it forms an arch, the convexity of which is directed forwards and downwards to the left side, the concavity backwards and upwards to the right. It is accompanied by the superior mesenteric vein, and is surrounded by the superior mesenteric plexus of nerves. Its branches are, the

Inferior Pancreatico-duodenal.	Ileo-colic.
Vasa Intestini Tenuis.	Colica Dextra.
Colica Media.	





the right iliac fossa, where it divides into two branches. Of these, the inferior division inosculates with the lowest branches of the vasa intestini tenuis, from the convexity of which branches proceed to supply the termination of the ileum, the cæcum and appendix cæci, and the ileo-cæcal valve. The superior division inosculates with the colica dextra, and supplies the commencement of the colon.

The **colica dextra** arises from about the middle of the concavity of the superior mesenteric artery, and, passing behind the peritoneum to the middle of the ascending colon, divides into two branches: a descending branch, which inosculates with the ileo-colic; and an ascending branch, which anastomoses with the colica media. These branches form arches, from the convexity of which vessels are distributed to the ascending colon. The branches of this vessel are covered with peritoneum only on their anterior aspect.

The **colica media** arises from the upper part of the concavity of the superior mesenteric, and, passing forwards between the layers of the transverse meso-colon, divides into two branches: the one on the right side inosculating with the colica dextra; that on the left side with the colica sinistra, a branch of the inferior mesenteric. From the arches formed by their inosculation, branches are distributed to the transverse colon. The branches of this vessel lie between two layers of peritoneum.

#### INFERIOR MESENTERIC ARTERY (fig. 411)

In order to expose this vessel, draw the small intestines and mesentery over to the right side of the abdomen, raise the transverse colon towards the thorax, and divide the peritoneum covering the left side of the aorta.

The **Inferior Mesenteric Artery** supplies the descending and sigmoid flexure of the colon, and the greater part of the rectum. It is smaller than the superior mesenteric; and arises from the left side of the aorta, between one and two inches above its division into the common iliacs. It passes downwards to the left iliac fossa, and then descends, between the layers of the meso-rectum, into the pelvis, under the name of the *superior hæmorrhoidal artery*. It lies at first in close relation with the left side of the aorta, and then passes as the superior hæmorrhoidal in front of the left common iliac artery. Its branches are, the

Colica Sinistra.

Sigmoid.

Superior Hæmorrhoidal.

The **colica sinistra** passes behind the peritoneum, in front of the left kidney, to reach the descending colon, and divides into two branches: an ascending branch, which inosculates with the colica media; and a descending branch, which anastomoses with the sigmoid artery. From the arches formed by these inosculations, branches are distributed to the descending colon.

The **sigmoid artery** runs obliquely downwards across the Psoas muscle to the sigmoid flexure of the colon, and divides into branches which supply that part of the intestine; anastomosing above, with the colica sinistra; and below, with the superior hæmorrhoidal artery. This vessel is sometimes replaced by three or four small branches.

The **superior hæmorrhoidal artery**, the continuation of the inferior mesenteric, descends into the pelvis between the layers of the meso-rectum, crossing, in its course, the ureter and left common iliac vessels. It divides into two branches, which descend one on each side of the rectum, and about five inches from the anus break up into several small branches, which pierce the muscular coat of the bowel and run downwards, as straight vessels, placed at regular intervals from each other in the wall of the gut between its muscular and mucous coat, to the level of the internal sphincter; here they form a series of loops around the lower end of the rectum, and communicate with the middle hæmorrhoidal arteries, branches of the internal iliac, and with the inferior hæmorrhoidal branches of the internal pudic.



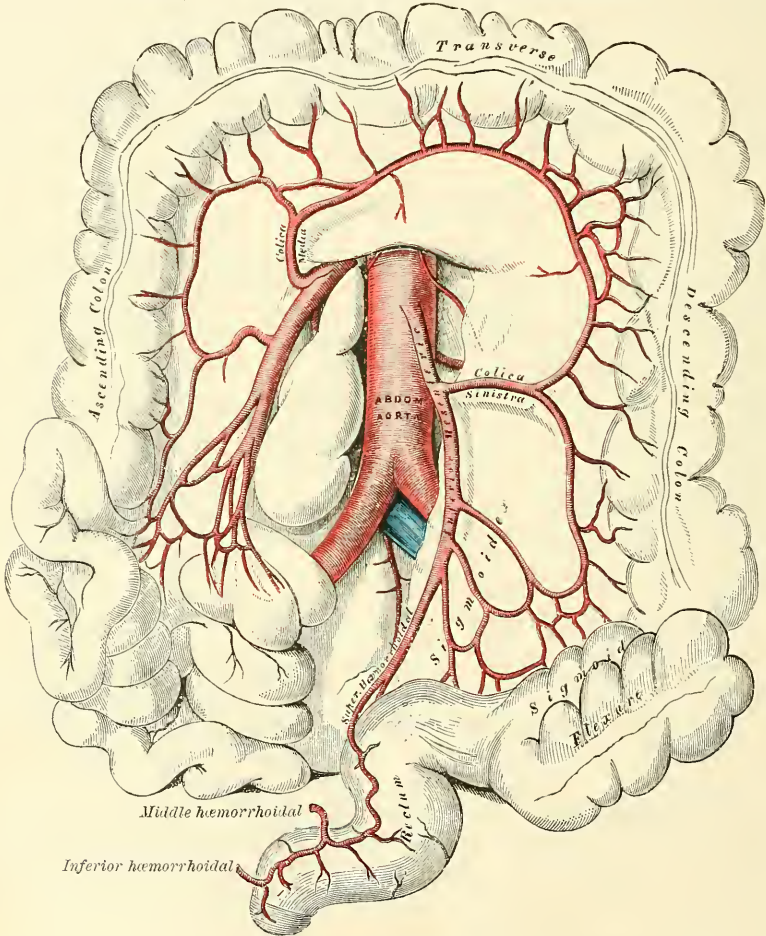
## SUPRARENAL ARTERIES (fig. 407)

The **Suprarenal Arteries** are two small vessels which arise, one on each side of the aorta, opposite the superior mesenteric artery. They pass obliquely upwards and outwards, over the crura of the Diaphragm, to the under surface of the suprarenal capsules, to which they are distributed, anastomosing with capsular branches from the phrenic and renal arteries. In the adult these arteries are of small size; in the foetus they are as large as the renal arteries.

## RENAL ARTERIES (fig. 407)

The **Renal Arteries** are two large trunks, which arise from the sides of the aorta, immediately below the superior mesenteric artery. Each is directed

FIG. 411.—The inferior mesenteric and its branches.



outwards, across the crus of the Diaphragm, so as to form nearly a right angle with the aorta. The right is longer than the left, on account of the position of the aorta; it passes behind the inferior vena cava. The left is somewhat higher than the right. Previously to entering the kidney, each artery divides into four or five branches which are distributed to its substance. At the hilum, these branches lie between the renal vein and ureter, the vein being in front, the ureter behind. Each vessel gives off some small branches to the suprarenal capsule, the ureter, and the surrounding cellular tissue and muscles. Frequently there is a second renal artery, which is given off from the abdominal aorta at a lower level and supplies the lower portion of the kidney. It is termed the *inferior renal artery*.

## SPERMATIC ARTERIES

The **Spermatic Arteries** are distributed to the testes. They are two slender vessels, of considerable length, which arise from the front of the aorta, a little below the renal arteries. Each artery passes obliquely outwards and downwards, behind the peritoneum, resting on the Psoas muscle, the right spermatic lying in front of the inferior vena cava, the left behind the sigmoid flexure of the colon. It then crosses obliquely over the ureter and the lower part of the external iliac artery to reach the internal abdominal ring, through which it passes, and accompanies the other constituents of the spermatic cord along the inguinal canal to the scrotum, where it becomes tortuous, and divides into several branches, two or three of which accompany the vas deferens, and supply the epididymis, anastomosing with the artery of the vas deferens; others pierce the back part of the tunica albuginea, and supply the substance of the testis.

The **Ovarian Arteries** (fig. 413) are the corresponding arteries in the female to the spermatic in the male. They supply the ovaries, are shorter than the spermatic, and do not pass out of the abdominal cavity. The origin and course of the first part of the artery are the same as the spermatic in the male, but on arriving at the margin of the pelvis the ovarian artery passes inwards, between the two layers of the broad ligament of the uterus, to be distributed to the ovary. One or two small branches supply the Fallopian tube; another passes on to the side of the uterus, and anastomoses with the uterine arteries. Other offsets are continued along the round ligament, through the inguinal canal, to the integument of the labium and groin.

At an early period of foetal life, when the testes or ovaries lie by the side of the spine, below the kidneys, the spermatic or ovarian arteries are short; but as these organs descend from the abdomen into the scrotum or pelvis, the arteries become gradually lengthened.

## PHRENIC ARTERIES

The **Phrenic Arteries** are two small vessels, which present much variety in their origin. They may arise separately from the front of the aorta, immediately above the cœliac axis, or by a common trunk, which may spring either from the aorta or from the cœliac axis. Sometimes one is derived from the aorta, and the other from one of the renal arteries. In only one out of thirty-six cases examined did these arteries arise as two separate vessels from the aorta. They diverge from one another across the crura of the Diaphragm, and then pass obliquely upwards and outwards upon its under surface. The left phrenic passes behind the œsophagus, and runs forwards on the left side of the œsophageal opening. The right phrenic passes behind the inferior vena cava, and ascends along the right side of the aperture for transmitting that vein. Near the back part of the central tendon each vessel divides into two branches. The internal branch runs forwards to the front of the thorax, supplying the Diaphragm, and anastomosing with its fellow of the opposite side, and with the musculo-phrenic and comes nervi phrenici, branches of the internal mammary. The external branch passes towards the side of the thorax, and inosculates with the intercostal arteries. The internal branch of the right phrenic gives off a few vessels to the inferior vena cava; and the left one some branches to the œsophagus. Each vessel also sends capsular branches to the suprarenal capsule of its own side. The spleen on the left side, and the liver on the right, also receive a few branches from these vessels.

## LUMBAR ARTERIES

The **Lumbar Arteries** are analogous to the intercostal. They are usually four in number on each side, and arise from the back part of the aorta, nearly at right

angles with that vessel. They pass outwards and backwards, around the sides of the bodies of the lumbar vertebræ, behind the sympathetic nerve and the Psoas magnus muscle; those on the right side being covered by the inferior vena cava, and the two upper ones on each side by the crura of the Diaphragm. In the interval between the transverse processes of the vertebræ each artery divides into a *dorsal* and an *abdominal branch*.

The *dorsal branch* gives off, immediately after its origin, a *spinal branch*, which enters the spinal canal; it then continues its course backwards, between the transverse processes, and is distributed to the muscles and integument of the back, anastomosing with the similar branches of the adjacent lumbar arteries, and with the posterior branches of the intercostal arteries. The *spinal branch* enters the spinal canal through the intervertebral foramen, to be distributed to the spinal cord and its membranes and to the bodies of the vertebræ in the same manner as the lateral spinal branches from the vertebral (see page 592).

The *abdominal branches* pass outwards, having a variable relation to the Quadratus lumborum muscle. Most frequently the first branch passes in front of the muscle and the others behind it; sometimes the order is reversed and the lowest branch passes in front of the muscle. At the outer border of the Quadratus they are continued between the abdominal muscles, anastomose with branches of the epigastric and internal mammary *in front*, the intercostals *above*, and those of the ilio-lumbar and circumflex iliac *below*.

#### MIDDLE SACRAL ARTERY

The **Middle Sacral Artery** is a small vessel, which arises from the back part of the aorta, just at its bifurcation. It descends upon the last lumbar vertebra, and along the middle line of the front of the sacrum, to the upper part of the coccyx, where it anastomoses with the lateral sacral arteries, and terminates in a minute branch, which runs down to the situation of the body immediately to be described as 'Luschka's gland.' From it, branches arise which run through the meso-rectum, to supply the posterior surface of the rectum. Other branches are given off on each side, which anastomose with the lateral sacral arteries, and send off small offsets, which enter the anterior sacral foramina.

The artery is the representative of the caudal prolongation of the aorta of animals, and its lateral branches correspond to the intercostal and lumbar arteries in the dorsal and lumbar regions.

**Coccygeal Gland, or Luschka's Gland.**—Lying near the tip of the coccyx in a small tendinous interval formed by the union of the Levator ani muscle of each side, and just above the coccygeal attachment of the Sphincter ani, is a small conglobate body, about as large as a lentil or a pea, first described by Luschka,\* and named by him the *coccygeal gland*. Its most obvious connections are with the arteries of the part.

**Structure.**—It consists of a congeries of small arteries, with little aneurismal dilatations, derived from the middle sacral, and freely communicating with each other. These vessels are enclosed in one or more layers of polyhedral granular cells, and the whole structure is invested in a capsule of connective tissue which sends in trabeculæ, dividing the interior into a number of spaces in which the vessels and cells are contained. Nerves pass into this little body from the sympathetic, but their mode of termination is unknown. Macalister believes the glomerulus of vessels 'consists of the condensed and convoluted metameric dorsal arteries of the caudal segments embedded in tissue which is possibly a small persisting fragment of the neurenteric canal.'

\* *Der Hirnanhang und die Steissdrüse des Menschen*, Berlin, 1860; *Anatomie des Menschen*, Tübingen, 1864, vol. ii. pt. 2, p. 187.



## COMMON ILIAC ARTERIES

The abdominal aorta divides into the two **common iliac arteries**. The bifurcation usually takes place on the left side of the body of the fourth lumbar vertebra. The common iliac arteries are about two inches in length; diverging from the termination of the aorta, they pass downwards and outwards to the margin of the pelvis, and divide opposite the intervertebral substance, between the last lumbar vertebra, and the sacrum, into two branches, the *external* and *internal iliac arteries*: the former supplying the lower extremity; the latter, the viscera and parietes of the pelvis.

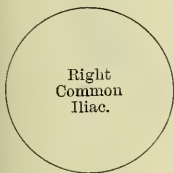The **right common iliac** is somewhat larger than the left, and passes more obliquely across the body of the last lumbar vertebra. In front of it are the peritoneum, the small intestines, branches of the sympathetic nerve, and, at its point of division, the ureter. *Behind*, it is separated from the fourth and fifth lumbar vertebrae, with the intervening intervertebral disc, by the two common iliac veins. On its *outer side*, it is in relation with the inferior vena cava, and the right common iliac vein, above; and the Psoas magnus muscle below.

The **left common iliac** is in relation, in front, with the peritoneum, branches of the sympathetic nerve, and the superior hæmorrhoidal artery; and is crossed at its point of bifurcation by the ureter. It rests on the bodies of the fourth and fifth lumbar vertebrae, with the intervening intervertebral disc. The left common iliac vein lies partly on the inner side, and partly beneath the artery; on its outer side, the artery is in relation with the Psoas magnus muscle.

## PLAN OF THE RELATIONS OF THE COMMON ILIAC ARTERIES

*In front.*

Peritoneum.  
Small intestines.  
Sympathetic nerves.  
Ureter.

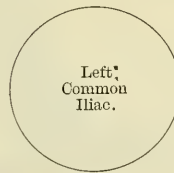

*Outer side.*  
Vena cava.  
Right common iliac vein.  
Psoas muscle.

*Inner side.*  
Left common iliac vein.

*In front.*

Peritoneum.  
Sympathetic nerves.  
Superior hæmorrhoidal artery.  
Ureter.



*Outer side.*  
Psoas magnus muscle.

*Behind.*

Fourth and fifth lumbar vertebrae.  
Right and left common iliac veins.

*Behind.*

Fourth and fifth lumbar vertebrae.  
Left common iliac vein.

**Branches.**—The common iliac arteries give off small branches to the peritoneum, Psoas magnus, ureters, and the surrounding cellular tissue, and occasionally give origin to the ilio-lumbar, or renal arteries.

**Peculiarities.**—The *point of origin* varies according to the bifurcation of the aorta. In three-fourths of a large number of cases, the aorta bifurcated either upon the fourth lumbar vertebra, or upon the intervertebral disc between it and the fifth; the bifurcation being, in one case out of nine below, and in one out of eleven above this point. In ten out of every thirteen cases, the vessel bifurcated within half an inch above or below the level of the crest of the ilium: more frequently below than above.

The *point of division* is subject to great variety. In two-thirds of a large number of cases it was between the last lumbar vertebra and the upper border of the sacrum; being above that point in one case out of eight, and below it in one case out of six. The left common iliac artery divides lower down more frequently than the right.

The *relative length*, also, of the two common iliac arteries varies. The right common iliac was the longer in sixty-three cases; the left in fifty-two; whilst they were both equal in fifty-three. The length of the arteries varied in five-sevenths of the cases examined, from an inch and a half to three inches; in about half of the remaining cases, the artery was longer, and in the other half, shorter: the minimum length being less than half an inch,





operation, by making an incision partly in the abdomen, partly in the loin. The incision is commenced at the anterior extremity of the last rib, proceeding directly downwards to the ilium; it is then curved forwards along the crest of the ilium, and a little above it, to the anterior superior spine of that bone. The abdominal muscles having been cautiously divided in succession, the transversalis fascia must be carefully cut through, and the peritoneum, together with the ureter, separated from the artery, and pushed aside; the sacro-iliac articulation must then be felt for, and upon it the vessel will be felt pulsating, and may be fully exposed in close connection with its accompanying vein. On the right side, both common iliac veins, as well as the inferior vena cava, are in close connection with the artery, and must be carefully avoided. On the left side, the vein usually lies on the inner side, and behind the artery; but it occasionally happens that the two common iliac veins are joined on the left instead of the right side, which would add much to the difficulty of an operation in such a case. The common iliac artery may be so short that danger may be apprehended from secondary hæmorrhage if a ligature is applied to it. It would be preferable, in such a case, to tie both the external and internal iliacs near their origin.

*Collateral Circulation.*—The principal agents in carrying on the collateral circulation after the application of a ligature to the common iliac are: the anastomoses of the hæmorrhoidal branches of the internal iliac with the superior hæmorrhoidal from the inferior mesenteric; the anastomoses of the uterine and ovarian arteries, and of the vesical arteries of opposite sides; of the lateral sacral with the middle sacral artery; of the epigastric with the internal mammary, inferior intercostal, and lumbar arteries; of the circumflex iliac with the lumbar arteries; of the ilio-lumbar with the last lumbar artery; of the obturator artery, by means of its pubic branch, with the vessel of the opposite side, and with the deep epigastric.

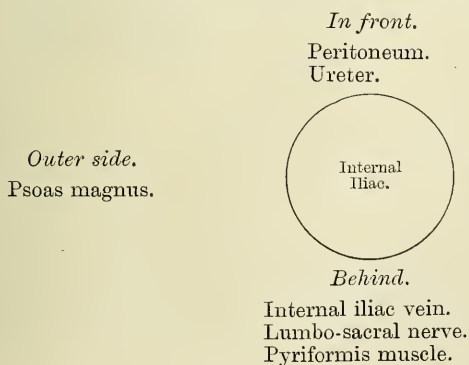
*Compression of the Common Iliac Arteries.*—The common iliac arteries are most efficiently compressed by Davy's lever. The instrument consists of a gum-elastic tube, about two feet long, in which fits a round wooden 'lever' considerably longer than the tube. A small quantity of olive oil having been injected into the rectum, the gum-elastic tube, softened in hot water, is passed into the bowel sufficiently far to permit its pressing upon the common iliac artery as it lies in the groove between the last lumbar vertebra and the Psoas muscle. The wooden lever is then inserted into the tube, and the projecting end carried towards the opposite thigh and raised, when it acts as a lever of the first order, the anus being the fulcrum. In cases where the meso-rectum is abnormally short it may be impossible, without unjustifiable force, to compress the artery on the right side.

## INTERNAL ILIAC ARTERY (fig. 412)

The **internal iliac artery** supplies the walls and viscera of the pelvis, the generative organs, and inner side of the thigh. It is a short, thick vessel, smaller in the adult than the external iliac, and about an inch and a half in length. It arises at the point of bifurcation of the common iliac, and, passing downwards to the upper margin of the great sacro-sciatic foramen, divides into two large trunks, an *anterior* and *posterior*; from its point of bifurcation a partially obliterated cord, the *hypogastric artery*, extends forwards to the bladder.

**Relations.**—*In front*, with the ureter, which separates it from the peritoneum. *Behind*, with the internal iliac vein, the lumbo-sacral nerve, and Pyriformis muscle. By its *outer side*, near its origin, with the Psoas magnus muscle.

## PLAN OF THE RELATIONS OF THE INTERNAL ILIAC ARTERY





In the *foetus*, the internal iliac artery (*hypogastric*) is twice as large as the external iliac, and appears to be the continuation of the common iliac. Instead of dipping into the pelvis, it passes forwards to the bladder, and ascends along the sides of that viscus to its summit, to which it gives branches; it then passes upwards along the back part of the anterior wall of the abdomen to the umbilicus, converging towards its fellow of the opposite side. Having passed through the umbilical opening, the two arteries twine round the umbilical vein, forming with it the umbilical cord; and, ultimately, ramify in the placenta. The portion of the vessel within the abdomen is called the *hypogastric artery*; and that external to that cavity, the *umbilical artery*.

At birth, when the placental circulation ceases, the upper portion of the hypogastric artery, extending from the summit of the bladder to the umbilicus, contracts, and ultimately dwindles to a solid fibrous cord; but the lower portion, extending from its origin (in what is now the internal iliac artery) for about an inch and a half to the wall of the bladder, and thence to the summit of that organ, is not totally impervious, though it becomes considerably reduced in size, and serves to convey blood to the bladder, under the name of the *superior vesical artery*.

*Peculiarities as regards Length.*—In two-thirds of a large number of cases, the length of the internal iliac varied between an inch and an inch and a half; in the remaining third, it was more frequently longer than shorter, the maximum length being three inches, the minimum half an inch.

The lengths of the common and internal iliac arteries bear an inverse proportion to each other, the internal iliac artery being long when the common iliac is short, and *vice versa*.

*As regards its Place of Division.*—The place of division of the internal iliac varies between the upper margin of the sacrum and the upper border of the sacro-sciatic foramen.

The arteries of the two sides in a series of cases often differed in length, but neither seemed constantly to exceed the other.

*Surgical Anatomy.*—The application of a ligature to the internal iliac artery may be required in cases of aneurism or hæmorrhage affecting one of its branches. The vessel may be secured by making an incision through the abdominal parietes in the iliac region, in a direction and to an extent similar to that for securing the common iliac; the transversalis fascia having been cautiously divided, and the peritoneum pushed inwards from the iliac fossa towards the pelvis, the finger may feel the pulsation of the external iliac at the bottom of the wound; and, by tracing this vessel upwards, the internal iliac is arrived at, opposite the sacro-iliac articulation. It should be remembered that the vein lies behind, and on the right side, a little external to the artery, and in close contact with it; the ureter and peritoneum, which lie in front, must also be avoided. The degree of facility in applying a ligature to this vessel will mainly depend upon its length. It has been seen that, in the great majority of the cases examined, the artery was short, varying from an inch to an inch and a half; in these cases, the artery is deeply seated in the pelvis; when, on the contrary, the vessel is longer, it is found partly above that cavity. If the artery is very short, as occasionally happens, it would be preferable to apply a ligature to the common iliac, or upon the external and internal iliacs at their origin.

Probably a better method of tying the internal iliac artery is by an abdominal section in the median line and reaching the vessel through the peritoneal cavity. This plan has been advocated by Dennis, of New York, on the following grounds: (1) It no way increases the danger of the operation; (2) it prevents a series of accidents which have occurred during ligature of the artery by the older methods; (3) it enables the surgeon to ascertain the exact extent of disease in the main arterial trunk, and select his spot for the application of the ligature; and (4) it occupies much less time.

*Collateral Circulation.*—In Professor Owen's dissection of a case in which the internal iliac artery had been tied by Stevens ten years before death, for aneurism of the sciatic artery, the internal iliac was found impervious for about an inch above the point where the ligature had been applied; but the obliteration did not extend to the origin of the external iliac, as the ilio-lumbar artery arose just above this point. Below the point of obliteration, the artery resumed its natural diameter, and continued so for half an inch; the obturator, lateral sacral, and gluteal arising in succession from the latter portion. The obturator artery was entirely obliterated. The lateral sacral artery was as large as a crow's quill, and had a very free anastomosis with the artery of the opposite side, and with the middle sacral artery. The sciatic artery was entirely obliterated as far as its point of connection with the aneurismal tumour; but, on the distal side of the sac, it was continued down along the back of the thigh nearly as large in size as the femoral, being pervious about an inch below the sac by receiving an anastomosing vessel from the profunda. The circulation

\* *Medico-Chirurgical Trans.*, vol. xvi.

was carried on by the anastomoses of the uterine and ovarian arteries; of the opposite vesical arteries; of the hæmorrhoidal branches of the internal iliac with those from the inferior mesenteric; of the obturator artery, by means of its pubic branch, with the vessel of the opposite side, and with the epigastric and internal circumflex; of the circumflex and perforating branches of the profunda femoris with the sciatic; of the gluteal with the posterior branches of the sacral arteries; of the ilio-lumbar with the last lumbar; of the lateral sacral with the middle sacral; and of the circumflex iliac with the ilio-lumbar and gluteal.

## BRANCHES OF THE INTERNAL ILIAC

From the Anterior Trunk.

Superior Vesical.  
Middle Vesical.  
Inferior Vesical.  
Middle Hæmorrhoidal.  
Obturator.  
Internal Pudic.  
Sciatic.

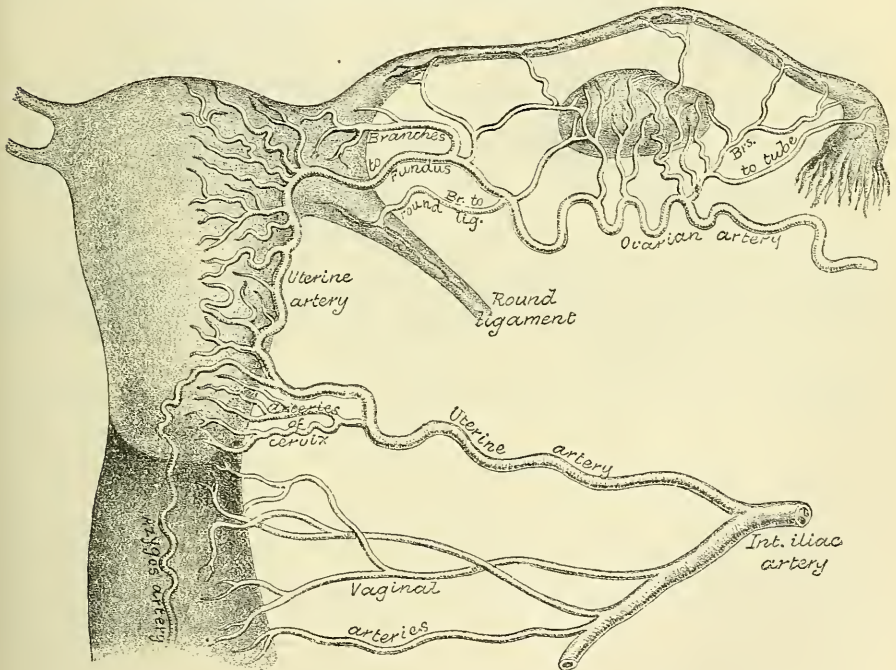
In female { Uterine.  
          { Vaginal.

From the Posterior Trunk.

Ilio-lumbar.  
Lateral Sacral.  
Gluteal.

The **superior vesical** is that part of the foetal hypogastric artery which remains pervious after birth. It extends to the side of the bladder, distributing numerous

FIG. 413.—The arteries of the internal organs of generation of the female, seen from behind. (After Hyrtl.)



branches to the apex and body of the organ. From one of these a slender vessel is derived, which accompanies the vas deferens in its course to the testis, where it anastomoses with the spermatic artery. This is the *artery of the vas deferens*. Other branches supply the ureter.

The **middle vesical**, usually a branch of the superior, is distributed to the base of the bladder and under surface of the vesiculæ seminales.

The **inferior vesical** arises from the anterior division of the internal iliac, frequently in common with the middle hæmorrhoidal, and is distributed to the base of the bladder, the prostate gland, and vesiculæ seminales. The branches



distributed to the prostate communicate with the corresponding vessel of the opposite side.

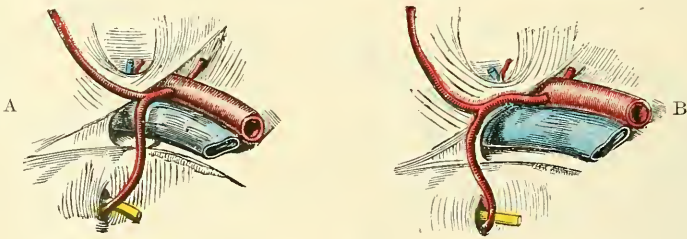
The **middle hæmorrhoidal artery** usually arises together with the preceding vessel. It supplies the anus and parts outside the rectum, anastomosing with the other hæmorrhoidal arteries.

The **uterine artery** passes inwards from the anterior trunk of the internal iliac to the neck of the uterus. Ascending, in a tortuous course on the side of this viscus, between the layers of the broad ligament, it distributes branches to its substance, anastomosing, near its termination, with a branch from the ovarian artery. It gives off branches to the cervix uteri (*cervical*), and branches which descend on to the vagina, and, joining with branches from the vaginal arteries, form a median longitudinal vessel both in front and behind, which descend on the anterior and posterior surfaces of the vagina, and are named the *azygos arteries of the vagina*.

The **vaginal artery** is analogous to the inferior vesical in the male; it descends upon the vagina, supplying its mucous membrane, and sending branches to the neck of the bladder and contiguous part of the rectum. It assists in forming the azygos arteries of the vagina.

The **obturator artery** usually arises from the anterior trunk of the internal iliac, sometimes from the posterior. It passes forwards, below the brim of the pelvis, to the upper part of the obturator foramen, and escaping from the pelvic cavity through a short canal, formed by a groove on the under surface of the

FIG. 414.—Variations in origin and course of obturator artery.



ascending ramus of the os pubis, and the arched border of the obturator membrane, it divides into an internal and an external branch. In the pelvic cavity this vessel lies upon the pelvic fascia, beneath the peritoneum, and a little below the obturator nerve.

**Branches.**—*Within the pelvis*, the obturator artery gives off an *iliac branch* to the iliac fossa, which supplies the bone and the Iliacus muscle, and anastomoses with the ilio-lumbar artery; a *vesical branch*, which runs backwards to supply the bladder; and a *pubic branch*, which is given off from the vessel just before it leaves the pelvic cavity. This branch ascends upon the back of the os pubis, communicating with offsets from the deep epigastric artery, and with the corresponding vessel of the opposite side. It is placed on the inner side of the femoral ring. *External to the pelvis*, the obturator artery divides into an *internal* and an *external branch*, which are deeply situated beneath the Obturator externus muscle.

The *internal branch* curves downwards along the inner margin of the obturator foramen, lying beneath the Obturator externus muscle; it distributes branches to the Obturator externus muscle, Pectineus, Adductors, and Gracilis, and anastomoses with the external branch, and with the internal circumflex artery.

The *external branch* curves round the outer margin of the foramen, also lying beneath the Obturator externus muscle, to the space between the Gemellus inferior and Quadratus femoris, where it divides into two branches: one, the smaller, courses inwards around the lower margin of the foramen and anastomoses with the internal branch and with the internal circumflex; the other inclines outwards in the groove below the acetabulum, and supplies the muscles attached



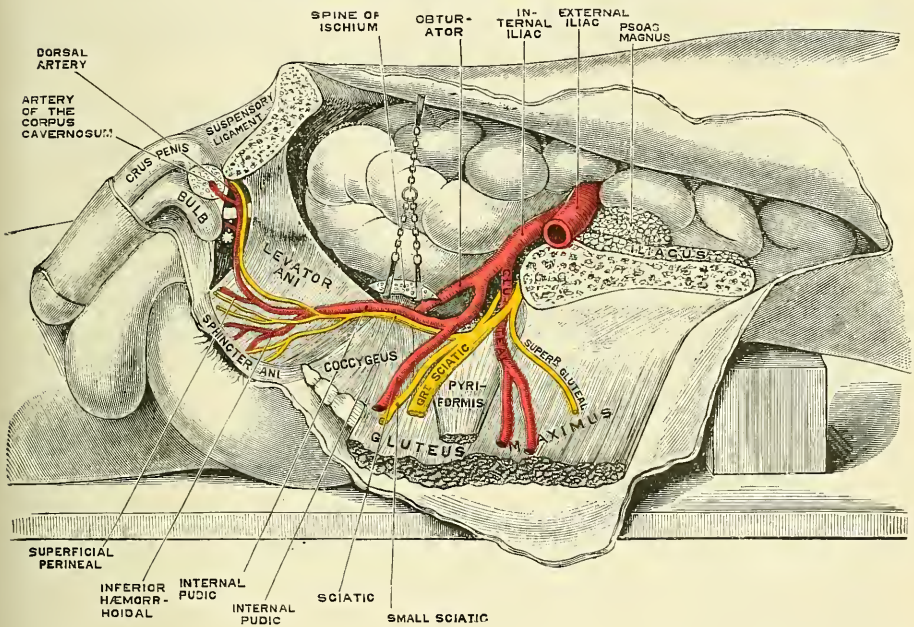
to the tuberosity of the ischium and anastomoses with the sciatic artery. It sends a branch to the hip-joint through the cotyloid notch, which ramifies on the round ligament as far as the head of the femur.

*Peculiarities.*—In two out of every three cases the obturator arises from the internal iliac; in one case in  $3\frac{1}{2}$  from the epigastric; and in about one in seventy-two cases by two roots from both vessels. It arises in about the same proportion from the external iliac artery. The origin of the obturator from the epigastric is not commonly found on both sides of the same body.

When the obturator artery arises at the front of the pelvis from the epigastric, it descends almost vertically to the upper part of the obturator foramen. The artery in this course usually lies in contact with the external iliac vein, and on the outer side of the femoral ring (fig. 414, A); in such cases it would not be endangered in the operation for femoral hernia. Occasionally, however, it curves inwards along the free margin of Gimbernat's ligament (fig. 414, B), and under such circumstances would almost completely encircle the neck of a hernial sac (supposing a hernia to exist in such a case), and would be in great danger of being wounded if an operation were performed.

The **Internal Pudic** is the smaller of the two terminal branches of the anterior trunk of the internal iliac, and supplies the external organs of generation.

FIG. 415.—The internal pudic artery and its branches in the male.



Though the course of the artery is the same in the two sexes, the vessel is much smaller in the female than in the male, and the distribution of its branches somewhat different. The description of its arrangement in the male will first be given, and subsequently the differences which it presents in the female will be mentioned.

The **Internal Pudic Artery in the Male** passes downwards and outwards to the lower border of the great sacro-sciatic foramen, and emerges from the pelvis between the Piriformis and Coccygeus muscles: it then crosses the spine of the ischium, and re-enters the pelvis through the lesser sacro-sciatic foramen. The artery now crosses the Obturator internus muscle, along the outer wall of the ischio-rectal fossa, being situated about an inch and a half above the lower margin of the ischial-tuberosity. It is here contained in a sheath of the obturator fascia, and gradually approaches the margin of the ramus of the ischium, along which it passes forwards and upwards, pierces the superior layer of the deep perineal fascia, and runs forwards along the inner margin of the ramus of the os pubis;

finally, it perforates the inferior layer of the deep perineal fascia, and divides into its two terminal branches, the *dorsal artery of the penis* and the *artery of the corpus cavernosum*.

**Relations.**—In the first part of its course, within the pelvis, it lies in front of the Piriformis muscle and sacral plexus of nerves, and on the outer side of the rectum (on the left side). As it crosses the spine of the ischium, it is covered by the Gluteus maximus. In the pelvis, it lies on the outer side of the ischio-rectal fossa, upon the surface of the Obturator internus muscle, contained in a fibrous canal (canal of Alcock) formed by the obturator fascia and the falciform process of the great sacro-sciatic ligament. It is accompanied by the pudic veins and the internal pudic nerve.

**Peculiarities.**—The internal pudic is sometimes smaller than usual, or fails to give off one or two of its usual branches; in such cases the deficiency is supplied by branches derived from an additional vessel, the *accessory pudic*, which generally arises from the internal pudic artery before its exit from the great sacro-sciatic foramen. It passes forwards along the lower part of the bladder and across the side of the prostate gland to the root of the penis, where it perforates the triangular ligament, and gives off the branches usually derived from the pudic artery. The deficiency most frequently met with is that in which the internal pudic ends as the artery of the bulb; the artery of the corpus cavernosum and arteria dorsalis penis being derived from the accessory pudic. Or the pudic may terminate as the superficial perineal, the artery of the bulb being derived, with the other two branches, from the accessory vessel. Occasionally the accessory pudic artery is derived from one of the other branches of the internal iliac, most frequently the inferior vesical or the obturator.

**Surgical Anatomy.**—The relation of the accessory pudic to the prostate gland and urethra is of the greatest interest in a surgical point of view, as this vessel is in danger of being wounded in the lateral operation of lithotomy. The student should also study the position of the internal pudic artery and its branches, when running a normal course, with regard to the same operation. The superficial and the transverse perineal arteries are, of necessity, divided in this operation, but the hæmorrhage from these vessels is seldom excessive; should a ligature be required, it can readily be applied on account of their superficial position. The artery of the bulb may be divided if the incision be carried too far forwards, and injury of this vessel may be attended with serious or even fatal consequences. The main trunk of the internal pudic artery may be wounded if the incision be carried too far outwards; but, being bound down by the strong obturator fascia, and under cover of the ramus of the ischium, the accident is not very likely to occur unless the vessel runs an anomalous course.

**Branches.**—The branches of the internal pudic artery are—

Muscular.	Transverse Perineal.
Inferior Hæmorrhoidal.	Artery of the Bulb.
Superficial Perineal.	Artery of the Corpus Cavernosum.
	Dorsal Artery of the Penis.

The *muscular branches* consist of two sets: one given off in the pelvis; the other, as the vessel crosses the ischial spine. The former are several small offsets which supply the Levator ani, the Obturator internus, the Piriformis, and the Coccygeus muscles. The branches given off outside the pelvis are distributed to the adjacent part of the Gluteus maximus and External rotator muscles. They anastomose with branches of the sciatic artery.

The *inferior hæmorrhoidal* are two or three small arteries which arise from the internal pudic as it passes above the tuberosity of the ischium. Crossing the ischio-rectal fossa, they are distributed to the muscles and integument of the anal region.

The *superficial perineal artery* supplies the scrotum and muscles and integument of the perinæum. It arises from the internal pudic, in front of the preceding branches, and turns upwards, crossing either over or under the Transversus perinæi muscle, and runs forwards, parallel to the pubic arch, in the interspace between the Accelerator urinæ and Erector penis muscles, both of which it supplies, and is finally distributed to the skin and dartos of the scrotum. In its passage through the perinæum, it lies beneath the superficial perineal fascia.

The *transverse perineal* is a small branch which arises either from the internal



pubic, or from the superficial perineal artery as it crosses the *Transversus perinæi* muscle. It runs transversely inwards along the cutaneous surface of the *Transversus perinæi* muscle, which it supplies, as well as the structures between the anus and bulb of the urethra, and anastomoses with the one of the opposite side.

The *artery of the bulb* is a large but very short vessel, which arises from the internal pudic between the two layers of the deep perineal fascia, and, passing nearly transversely inwards between the fibres of the *Compressor urethræ* muscle, it pierces the bulb of the urethra, in which it ramifies. It gives off a small branch which descends to supply Cowper's gland.

*Surgical Anatomy.*—This artery is of considerable importance in a surgical point of view, as it is in danger of being wounded in the lateral operation of lithotomy, an accident usually attended in the adult with alarming hæmorrhage. The vessel is sometimes very small, occasionally wanting, or even double. It sometimes arises from the internal pudic earlier than usual, and crosses the perinæum to reach the back part of the bulb. In such a case the vessel could hardly fail to be wounded in the performance of the lateral operation of lithotomy. If, on the contrary, it should arise from an accessory pudic, it lies more forward than usual, and is out of danger in the operation.

The *artery of the corpus cavernosum*, one of the terminal branches of the internal pudic, arises from that vessel while it is situated between the crus penis and the ramus of the os pubis; piercing the crus penis obliquely, it runs forwards in the centre of the corpus cavernosum, to which its branches are distributed.

The *dorsal artery of the penis* ascends between the crus and pubic symphysis, and, piercing the suspensory ligament, runs forwards on the dorsum of the penis to the glans, where it divides into two branches, which supply the glans and prepuce. On the dorsum of the penis, it lies immediately beneath the integument, parallel with the dorsal vein and the corresponding artery of the opposite side. It supplies the integument and fibrous sheath of the corpus cavernosum, sending branches through the sheath to anastomose with the preceding vessel.

The **Internal Pudic Artery in the Female** is smaller than in the male. Its origin and course are similar, and there is considerable analogy in the distribution of its branches. The superficial artery supplies the labia pudendi; the artery of the bulb supplies the bulbi vestibuli and the erectile tissue of the vagina; the artery of the corpus cavernosum supplies the cavernous body of the clitoris; and the *arteria dorsalis clitoridis* supplies the dorsum of that organ, and terminates in the glans and in the membranous fold corresponding to the prepuce of the male.

The **Sciatic Artery** (fig. 416), the larger of the two terminal branches of the anterior trunk of the internal iliac, is distributed to the muscles at the back of the pelvis. It passes down to the lower part of the great sacro-sciatic foramen, behind the internal pudic artery, resting on the sacral plexus of nerves and *Pyriformis* muscle, and escapes from the pelvis through this foramen between the *Pyriformis* and *Coccygeus*. It then descends in the interval between the trochanter major and tuberosity of the ischium, accompanied by the sciatic nerves, and covered by the *Gluteus maximus*, and is continued down the back of the thigh supplying the skin, and anastomosing with branches of the perforating arteries.

*Within the pelvis*, it distributes branches to the *Pyriformis*, *Coccygeus*, and *Levator ani* muscles; some hæmorrhoidal branches, which supply the rectum, and occasionally take the place of the middle hæmorrhoidal artery; and vesical branches to the base and neck of the bladder, *vesiculæ seminales*, and prostate gland. *External to the pelvis*, it gives off the following branches:—

Coccygeal.	Comes Nervi Ischiadici.
Inferior Gluteal.	Muscular.
Anastomotie.	Articular.

The *coccygeal branch* runs inwards, pierces the great sacro-sciatic ligament,

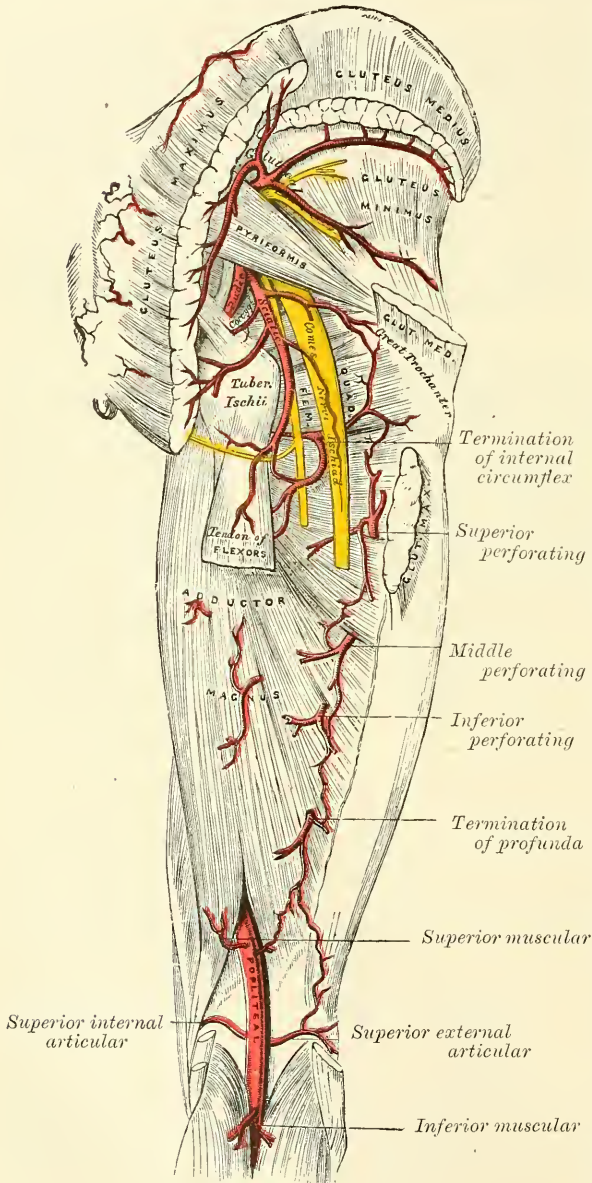


and supplies the Gluteus maximus, the integument, and other structures on the back of the coccyx.

The *inferior gluteal branches*, three or four in number, supply the Gluteus maximus muscle, anastomosing with the gluteal artery in the substance of the muscle.

The *comes nervi ischiadici* is a long, slender vessel, which accompanies the great sciatic nerve for a short distance; it then penetrates it, and runs in its substance to the lower part of the thigh.

FIG. 416.—The arteries of the gluteal and posterior femoral regions.



The *muscular branches* supply the Gluteus maximus, anastomosing with the Gluteal artery in the substance of the muscle: the external rotators, anastomosing with the internal pudic artery; and the muscles attached to the tuberosity of the ischium, anastomosing with the external branch of the obturator and the internal circumflex arteries.

The *anastomotic artery* is directed downwards across the external rotators and assists in forming the so-called *crucial anastomosis* by anastomosing with the superior perforating and the internal and external circumflex.

The *articular branch*, generally derived from the anastomotic, is distributed to the capsule of the hip-joint.

The **Ilio-lumbar Artery**, given off from the posterior trunk of the internal iliac, turns upwards and outwards between the obturator nerve and lumbosacral cord, to the inner margin of the Psoas muscle, behind which it divides into a lumbar and an iliac branch.

The *lumbar branch* supplies the Psoas and Quadratus lumborum muscles, anastomosing with the last lumbar artery, and

sends a small spinal branch through the intervertebral foramen, between the last lumbar vertebra and the sacrum, into the spinal canal, to supply the spinal cord and its membranes.

The *iliac branch* descends to supply the Iliacus muscle; some offsets, running

between the muscle and the bone, anastomose with the iliac branch of the obturator; one of these enters an oblique canal to supply the diploë, whilst others run along the crest of the ilium, distributing branches to the gluteal and abdominal muscles, and anastomose in their course with the gluteal, circumflex iliac, and external circumflex arteries.

The **Lateral Sacral Arteries** (fig. 412) are usually two in number on each side, superior and inferior.

The *superior*, which is of large size, passes inwards, and, after anastomosing with branches from the middle sacral, enters the first or second anterior sacral foramen, is distributed to the contents of the sacral canal in the same manner as the lateral spinal branches from the vertebral, and escaping by the corresponding posterior sacral foramen, supplies the skin and muscles on the dorsum of the sacrum, anastomosing with the gluteal.

The *inferior* passes obliquely across the front of the Piriformis muscle and sacral nerves to the inner side of the anterior sacral foramina, descends on the front of the sacrum, and anastomoses over the coccyx with the sacra media and opposite lateral sacral artery. In its course it gives off branches, which enter the anterior sacral foramina; these, after giving off branches to be distributed to the contents of the sacral canal in the same manner as the lateral spinal branches from the vertebral, escape by the posterior sacral foramina, and are distributed to the muscles and skin on the dorsal surface of the sacrum, anastomosing with the gluteal.

The **Gluteal Artery** is the largest branch of the internal iliac, and appears to be the continuation of the posterior division of that vessel. It is a short, thick trunk, which passes out of the pelvis above the upper border of the Piriformis muscle, and immediately divides into a *superficial* and *deep branch*. Within the pelvis, it gives off a few muscular branches to the Iliacus, Piriformis, and Obturator internus, and just previous to quitting that cavity, a nutrient artery, which enters the ilium.

The *superficial branch* passes beneath the Gluteus maximus, and divides into numerous branches, some of which supply that muscle, whilst others perforate its tendinous origin, and supply the integument covering the posterior surface of the sacrum, anastomosing with the posterior branches of the sacral arteries.

The *deep branch* runs between the Gluteus medius and minimus, and subdivides into two. Of these, the *superior division*, continuing the original course of the vessel, passes along the upper border of the Gluteus minimus to the anterior superior spine of the ilium, anastomosing with the circumflex iliac and ascending branches of the external circumflex artery. The *inferior division* crosses the Gluteus minimus obliquely to the trochanter major, distributing branches to the Glutei muscles, and inosculates with the external circumflex artery. Some branches pierce the Gluteus minimus to supply the hip-joint.

*Surface Marking.*—The position of the three main branches of the internal iliac, the sciatic, internal pudic, and gluteal, which may occasionally be the object of surgical interference, is indicated on the surface in the following way: a line is to be drawn from the posterior superior iliac spine to the posterior superior angle of the great trochanter, with the limb slightly flexed and rotated inwards: the point of emergence of the *gluteal artery* from the upper part of the sciatic notch will correspond with the junction of the upper with the middle third of this line. A second line is to be drawn from the same point to the middle of the tuberosity of the ischium; the junction of the lower with the middle third marks the point of emergence of the *sciatic and pudic arteries* from the great sciatic notch.

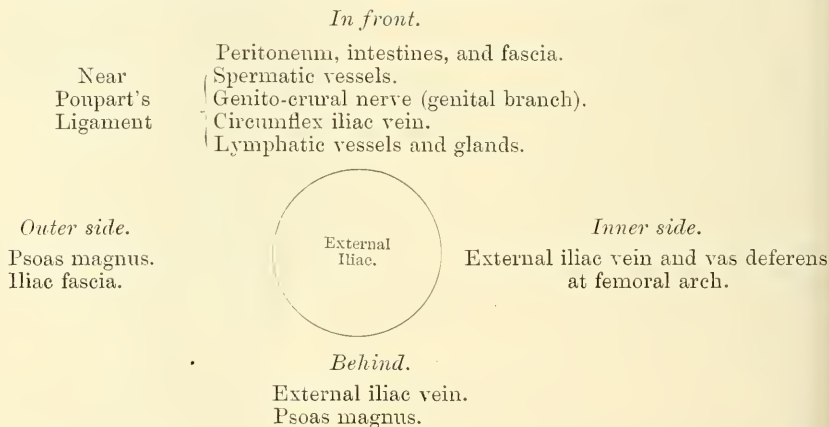
*Surgical Anatomy.*—Any of these three vessels may require ligaturing for a wound or for aneurism, which is generally traumatic, and the operation may be performed by an incision, three or four inches long, in the direction of the fibres of the Gluteus maximus muscle, the middle of the cut corresponding to the point indicating their respective positions.

## EXTERNAL ILIAC ARTERY (fig. 412)

The **external iliac artery** is larger in the adult than the internal iliac, and passes obliquely downwards and outwards along the inner border of the Psoas muscle, from the bifurcation of the common iliac to Poupart's ligament, where it enters the thigh and becomes the femoral artery.

**Relations.**—*In front*, with the peritoneum, subperitoneal areolar tissue, the termination of the ileum on the right side, and the sigmoid flexure on the left, and a thin layer of fascia, derived from the iliac fascia, which surrounds the artery and vein. At its origin it is occasionally crossed by the ureter. The spermatic vessels descend for some distance upon it near its termination, and it is crossed in this situation by the genital branch of the genito-crural nerve and the circumflex iliac vein; the vas deferens curves down along its inner side. *Behind*, it is in relation with the external iliac vein, which, at Poupart's ligament, lies at its inner side; on the left side the vein is altogether internal to the artery. *Externally*, it rests against the Psoas muscle, from which it is separated by the iliac fascia. The artery rests upon this muscle, near Poupart's ligament. Numerous lymphatic vessels and glands are found lying on the front and inner side of the vessel.

## PLAN OF THE RELATIONS OF THE EXTERNAL ILIAC ARTERY



**Surface Marking.**—The surface line indicating the course of the external iliac artery has been already given (see page 632).

**Surgical Anatomy.**—The application of a ligature to the external iliac may be required in cases of aneurism of the femoral artery, or for a wound of the artery. This vessel may be secured in any part of its course, excepting near its upper end, which is to be avoided on account of the proximity of the great stream of blood in the internal iliac, and near its lower end, which should also be avoided, on account of the proximity of the epigastric and circumflex iliac vessels. The patient having been placed in the supine position, an incision should be made, commencing below at a point about three-quarters of an inch above Poupart's ligament, and a little external to its middle, and running upwards and outwards, parallel to Poupart's ligament, to a point one inch internal and one inch above the anterior superior spine of the ilium. When the artery is deeply seated, more room will be required, and may be obtained by curving the incision from the point last named inwards towards the umbilicus for a short distance. Another mode of ligaturing the vessel is the plan advocated by Sir Astley Cooper, by making an incision close to Poupart's ligament from about half an inch outside the external abdominal ring to one inch internal to the anterior superior spine of the ilium. This incision, being made in the course of the fibres of the aponeurosis of the external oblique, is less likely to be followed by a ventral hernia, but there is danger of wounding the epigastric artery, and only the lower end of the vessel can be ligatured. Abernethy, who first tied this artery, made his incision in the course of the vessel. The abdominal muscles and transversalis fascia having been cautiously divided, the peritoneum should be separated from the iliac fossa and raised towards the pelvis; and on introducing the finger to the bottom of the wound the artery may be felt pulsating along the inner border of the Psoas muscle. The external iliac vein



is generally found on the inner side of the artery, and must be cautiously separated from it by the finger-nail, or handle of the knife, and the aneurism needle should be introduced on the inner side, between the artery and vein.

Ligature of the external iliac artery has recently been performed by a transperitoneal method. An incision four inches in length is made in the semilunar line, commencing about an inch below the umbilicus, and carried through the abdominal wall into the peritoneal cavity. The intestines are then pushed upwards and held out of the way by a broad abdominal retractor, and an incision made through the peritoneum at the margin of the pelvis in the course of the artery; the vessel is secured in any part of its course which may seem desirable to the operator. The advantages of this operation appear to be, that if it is found necessary the common iliac artery can be ligatured instead of the external iliac without extension or modification of the incision; and secondly, that the vessel can be ligatured without in any way interfering with the coverings of the sac. Possibly a disadvantage may exist in the greater risk of hernia after this method.

*Collateral Circulation.*—The principal anastomoses in carrying on the collateral circulation, after the application of a ligature to the external iliac, are—the ilio-lumbar with the circumflex iliac; the gluteal with the external circumflex; the obturator with the internal circumflex; the sciatic with the superior perforating and circumflex branches of the profunda artery; and the internal pudic with the external pudic. When the obturator arises from the epigastric, it is supplied with blood by branches, either from the internal iliac, the lateral sacral, or the internal pudic. The epigastric receives its supply from the internal mammary and inferior intercostal arteries, and from the internal iliac by the anastomoses of its branches with the obturator.

In the dissection of a limb, eighteen years after the successful ligature of the external iliac artery, by Sir A. Cooper, which is to be found in Guy's Hospital Reports, vol. i. p. 50, the anastomosing branches are described in three sets: *An anterior set.*—1. A very large branch from the ilio-lumbar artery to the circumflex iliac; 2. another branch from the ilio-lumbar, joined by one from the obturator, and breaking up into numerous tortuous branches to anastomose with the external circumflex; 3. two other branches from the obturator, which passed over the brim of the pelvis, communicated with the epigastric, and then broke up into a plexus to anastomose with the internal circumflex. *An internal set.*—Branches given off from the obturator, after quitting the pelvis, which ramified among the adductor muscles on the inner side of the hip-joint, and joined most freely with branches of the internal circumflex. *A posterior set.*—1. Three large branches from the gluteal to the external circumflex; 2. several branches from the sciatic around the great sciatic notch to the internal and external circumflex, and the perforating branches of the profunda.

**Branches.**—Besides several small branches to the Psoas muscle and the neighbouring lymphatic glands, the external iliac gives off two branches of considerable size, the

#### Deep Epigastric and Deep Circumflex Iliac.

The **Deep Epigastric Artery** arises from the external iliac, a few lines above Poupart's ligament. It at first descends to reach this ligament, and then ascends obliquely along the inner margin of the internal abdominal ring, lying between the transversalis fascia and peritoneum, and, continuing its course upwards, it pierces the transversalis fascia, and, passing over the semilunar fold of Douglas, enters the sheath of the Rectus muscle. It then ascends on the posterior surface of the muscle, and finally divides into numerous branches, which anastomose, above the umbilicus, with the terminal branches of the internal mammary and inferior intercostal arteries (fig. 401). The deep epigastric artery bears a very important relation to the internal abdominal ring as it passes obliquely upwards and inwards from its origin from the external iliac. In this part of its course it lies along the lower and inner margin of the ring, and beneath the commencement of the spermatic cord. As it winds round the internal abdominal ring, it is crossed by the vas deferens in the male and the round ligament in the female.

**Branches.**—The branches of this vessel are the following: the *cremasteric*, which accompanies the spermatic cord, and supplies the Cremaster muscle and other coverings of the cord, anastomosing with the spermatic artery; a *pubic branch*, which runs along Poupart's ligament, and then descends behind the os pubis to the inner side of the femoral ring, and anastomoses with offsets from the obturator artery; *muscular branches*, some of which are distributed to

the abdominal muscles and peritoneum, anastomosing with the lumbar and circumflex iliac arteries: others perforate the tendon of the External oblique, and supply the integument, anastomosing with branches of the superficial epigastric.

*Peculiarities.*—The origin of the epigastric may take place from any part of the external iliac between Poupart's ligament and two inches and a half above it; or it may arise below this ligament, from the femoral, or from the deep femoral.

*Union with branches.*—It frequently arises from the external iliac, by a common trunk with the obturator. Sometimes the epigastric arises from the obturator, the latter vessel being furnished by the internal iliac, and the course of the vessel is directly upwards in the line of junction of the inner third with the outer two-thirds of the Rectus muscle. It has important surgical relations, in addition to the fact that it is one of the principal means, through its anastomosis with the internal mammary, in establishing the collateral circulation after ligation of either the common or external iliac arteries. It lies close to the internal abdominal ring, and is therefore *internal* to an oblique inguinal hernia, but *external* to a direct inguinal hernia, as it emerges from the abdomen. It forms the outer boundary of Hesselbach's triangle. It is in close relationship with the spermatic cord, which lies in front of it in the inguinal canal, separated only by the transversalis fascia. The vas deferens hooks round its outer side.

*Surgical Anatomy.*—The deep epigastric artery follows a line drawn from the middle of Poupart's ligament towards the umbilicus; but shortly after this line crosses the linea semilunaris, the direction changes, and the course of the vessel is directly upwards in the line of junction of the inner third with the outer two-thirds of the Rectus muscle. It has important surgical relations, in addition to the fact that it is one of the principal means, through its anastomosis with the internal mammary, in establishing the collateral circulation after ligation of either the common or external iliac arteries. It lies close to the internal abdominal ring, and is therefore *internal* to an oblique inguinal hernia, but *external* to a direct inguinal hernia, as it emerges from the abdomen. It forms the outer boundary of Hesselbach's triangle. It is in close relationship with the spermatic cord, which lies in front of it in the inguinal canal, separated only by the transversalis fascia. The vas deferens hooks round its outer side.

The **Deep Circumflex Iliac Artery** arises from the outer side of the external iliac nearly opposite the epigastric artery. It ascends obliquely outwards behind Poupart's ligament, contained in a fibrous sheath formed by the junction of the transversalis and iliac fasciæ, to the anterior superior spinous process of the ilium. It then runs along the inner surface of the crest of the ilium to about its middle, where it pierces the Transversalis, and runs backwards between that muscle and the Internal oblique, to anastomose with the ilio-lumbar and gluteal arteries. Opposite the anterior superior spine of the ilium it gives off a large branch, which ascends between the Internal oblique and Transversalis muscles, supplying them, and anastomosing with the lumbar and epigastric arteries.

## ARTERIES OF THE LOWER EXTREMITY

The artery which supplies the greater part of the lower extremity is the direct continuation of the external iliac. It continues as a single trunk from Poupart's ligament to the lower border of the Popliteus muscle, and here divides into two branches, the anterior and posterior tibial, an arrangement exactly similar to what occurs in the upper limb. For convenience of description, the upper part of the main trunk is named femoral, the lower part popliteal.

### FEMORAL ARTERY (fig. 417)

The **femoral artery** commences immediately behind Poupart's ligament, midway between the anterior superior spine of the ilium and the symphysis pubis, and, passing down the fore part and inner side of the thigh, terminates at the opening in the Adductor magnus, at the junction of the middle with the lower third of the thigh, where it becomes the popliteal artery. The vessel, at the upper part of the thigh, lies in front of the hip-joint, just on a line with the innermost part of the head of the femur; in the lower part of its course it is in close relation with the inner side of the shaft of the bone, and between these two parts, the vessel is far away from the bone. In the upper third of the thigh it is contained in a triangular space, called Scarpa's triangle. In the middle third of the thigh it is contained in an aponeurotic canal, called Hunter's canal.

**Scarpa's Triangle.**—Scarpa's triangle corresponds to the depression seen immediately below the fold of the groin. It is a triangular space, the apex of

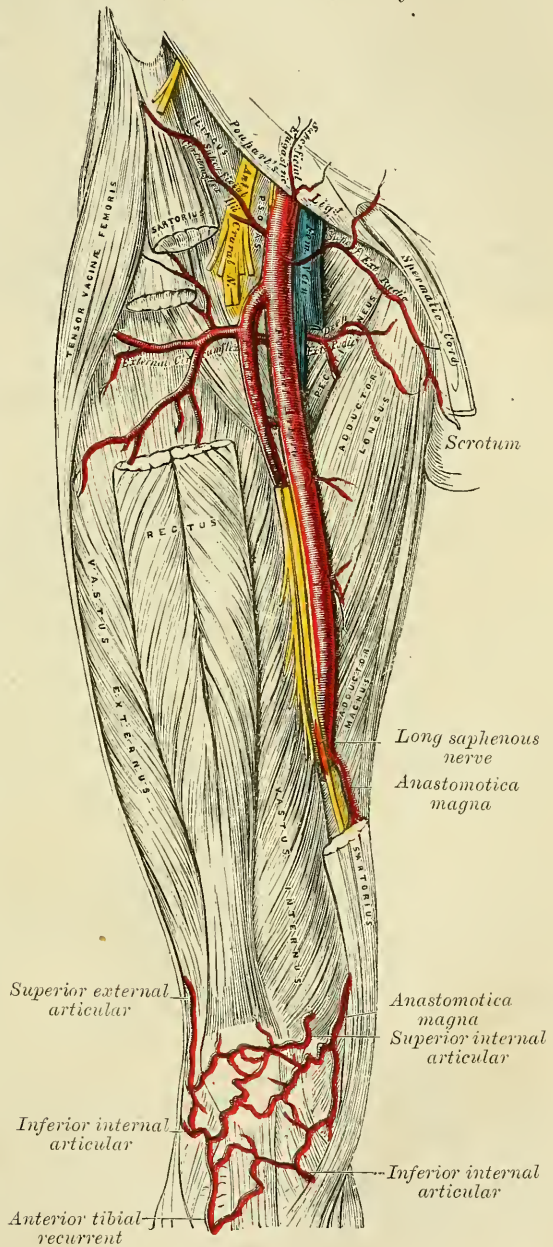


which is directed downwards, and the sides formed externally by the Sartorius, internally by the Adductor longus, and above by Poupart's ligament. The floor of the space is formed from without inwards by the Iliacus, Psoas, Pectineus, a small part of the Adductor brevis and the Adductor longus muscles; and it is divided into two nearly equal parts by the femoral vessels, which extend from the middle of its base to its apex: the artery giving off in this situation its cutaneous and profunda branches, the vein receiving the deep femoral and internal saphenous. On the outer side of the femoral artery is the anterior crural nerve dividing into its branches. Besides the vessels and nerves, this space contains some fat and lymphatics.

**Hunter's Canal.**—This is the aponeurotic space in the middle third of the thigh, extending from the apex of Scarpa's triangle to the femoral opening in the Adductor magnus muscle. It is bounded, externally, by the Vastus internus; internally, by the Adductor longus and magnus muscles; and covered in by a strong aponeurosis which extends transversely from the Vastus internus, across the femoral vessels to the Adductor longus and magnus muscles; lying on which aponeurosis is the Sartorius muscle. It contains the femoral artery and vein enclosed in their own sheath of areolar tissue, the vein being behind and on the outer side of the artery and the internal or long saphenous nerve lying on the outer side of the vessels.

For convenience of description and also in reference to its surgical anatomy, the femoral artery is divided into a short trunk, about an inch and a half or two inches long, which is known as the *common femoral artery*, and the remainder of the vessel, known as the *superficial femoral*, to distinguish it from the *deep femoral* (*profunda femoris*); a large branch given off from the common femoral at its termination, and which by its derivation from the parent trunk marks the commencement of the superficial femoral artery.

FIG. 417.—The femoral artery.





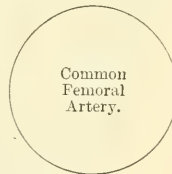
The **common femoral artery** is very superficial, being covered by the skin and superficial fascia, superficial inguinal lymphatic glands, the iliac portion of the fascia lata, and the prolongation downwards of the Transversalis fascia, which forms the sheath of the vessels. It has in front of it filaments from the crural branch of the genito-crural nerve, the superficial circumflex iliac vein, and occasionally the superficial epigastric vein. It rests on the inner margin of the Psoas muscle, which separates it from the capsular ligament of the hip-joint, and a little lower on the Pectineus muscle; and crossing behind it is the branch to the Pectineus from the anterior crural nerve. Separating the artery from the Psoas and Pectineus muscles is the pubic portion of the fascia lata and the prolongation from the fascia covering the Iliacus muscle which forms the posterior layer of the sheath of the vessels. The anterior crural nerve lies about half an inch to the outer side of the common femoral artery, lying between the Psoas and Iliacus muscles. To the inner side of the artery is the femoral vein, between the margins of the Pectineus and Psoas muscles. The two vessels are enclosed in a strong fibrous sheath, formed by the proper sheath of the vessels, strengthened by the fascia lata (see page 512); the artery and vein are separated, however, from one another by a thin fibrous partition.

#### PLAN OF RELATIONS OF THE COMMON FEMORAL ARTERY

##### *In front.*

Skin and superficial fascia.  
 Superficial inguinal glands.  
 Iliac portion of fascia lata.  
 Prolongation of transversalis fascia.  
 Crural branch of genito-crural nerve.  
 Superficial circumflex iliac vein.  
 Superficial epigastric vein.

*Inner side.*  
 Femoral vein.



*Outer side.*  
 Anterior crural nerve.

##### *Behind.*

Prolongation of fascia covering Iliacus muscle.  
 Pubic portion of fascia lata.  
 Nerve to Pectineus.  
 Psoas muscle.  
 Pectineus muscle.  
 Capsule of hip-joint.

The **superficial femoral artery** is only superficial where it lies in Scarpa's triangle. Here it is covered by the skin, superficial and deep fascia, and crossed by the internal cutaneous branch of the anterior crural nerve. In Hunter's canal it is more deeply seated, being covered by the integument, the superficial and deep fascia, the Sartorius and aponeurotic covering of Hunter's canal. The internal saphenous nerve crosses the artery from without inwards. Behind, the artery lies at its upper part on the femoral vein and the profunda artery and vein, which separate it from the Pectineus muscle, and lower down on the Adductor longus and Adductor magnus muscles. To the outer side is the long saphenous nerve and the nerve to the Vastus internus; the Vastus internus muscle and, at its lower part, the femoral vein. To the inner side is the Adductor longus above, and the Adductor magnus and Sartorius below.

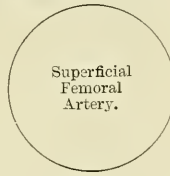
## PLAN OF RELATIONS OF THE SUPERFICIAL FEMORAL ARTERY

*In front.*

Skin, superficial and deep fasciæ.  
 Internal cutaneous nerve.  
 Sartorius.  
 Aponeurotic covering of Hunter's canal.  
 Internal saphenous nerve.

*Inner side.*

Adductor longus.  
 Adductor magnus.  
 Sartorius.

*Outer side.*

Long saphenous nerve.  
 Nerve to Vastus internus.  
 Vastus internus.  
 Femoral vein (below).

*Behind.*

Femoral vein.  
 Profunda artery and vein.  
 Pectineus muscle.  
 Adductor longus.  
 Adductor magnus.

The *femoral vein* at Poupart's ligament lies close to the inner side of the artery, separated from it by a thin fibrous partition; but, lower down, it is behind it, and then to its outer side.

The *internal saphenous nerve* is situated on the outer side of the artery, in the middle third of the thigh, beneath the aponeurotic covering of Hunter's canal; but not usually within the sheath of the vessels. The internal cutaneous nerve passes obliquely across the upper part of the sheath of the femoral artery.

*Peculiarities.*—*Double femoral reunited.*—Several cases are recorded in which the femoral artery divided into two trunks below the origin of the profunda, and became reunited near the opening in the Adductor magnus, so as to form a single popliteal artery. One of them occurred in a patient operated upon for popliteal aneurism.

*Change of Position.*—A few cases have been recorded in which the femoral artery was situated at the back of the thigh, the vessel being continuous above with the internal iliac, escaping from the pelvis through the great sacro-sciatic foramen, and accompanying the great sciatic nerve to the popliteal space, where its division occurred in the usual manner. The external iliac in these cases was small, and terminated in the profunda.

*Position of the Vein.*—The femoral vein is occasionally placed along the inner side of the artery, throughout the entire extent of Scarpa's triangle; or it may be slit so that a large vein is placed on each side of the artery for a greater or less extent.

*Origin of the Profunda.*—This vessel occasionally arises from the inner side, and, more rarely, from the back of the common trunk; but the more important peculiarity, in a surgical point of view, is that which relates to the height at which the vessel arises from the femoral. In three-fourths of a large number of cases it arose between one or two inches below Poupart's ligament; in a few cases the distance was less than an inch; more rarely, opposite the ligament; and in one case above Poupart's ligament, from the external iliac. Occasionally, the distance between the origin of the vessel and Poupart's ligament exceeds two inches, and in one case it was found to be as much as four inches.

*Surface Marking.*—The upper two-thirds of a line drawn from a point midway between the anterior superior spine of the ilium and the symphysis pubis to the prominent tuberosity on the inner condyle of the femur, with the thigh abducted and rotated outwards, will indicate the course of the femoral artery.

*Surgical Anatomy.*—*Compression* of the femoral artery, which is constantly requisite in amputations and other operations on the lower limb, and also for the cure of popliteal aneurism, is most effectually made immediately below Poupart's ligament. In this situation the artery is very superficial, and is merely separated from the horizontal ramus of the os pubis by the Psoas muscle; so that the surgeon, by means of his thumb or a compressor, may effectually control the circulation through it. This vessel may also be compressed in the middle third of the thigh by placing a compress over the artery, beneath the tourniquet, and directing the pressure from within outwards, so as to compress the vessel against the inner side of the shaft of the femur.

The *application of a ligature* to the femoral artery may be required in cases of

wound or aneurism of the arteries of the leg, the popliteal or femoral; and the vessel may be exposed and tied in any part of its course. The great depth of this vessel at its lower part, its close connection with important structures, and the density of its sheath, render the operation in this situation one of much greater difficulty than the application of a ligature at its upper part, where it is more superficial.

Ligature of the common femoral artery is usually considered unsafe, on account of the connection of large branches with it: viz. the deep epigastric and the deep circumflex iliac arising just above Poupart's ligament; on account of the number of small branches which arise from it, in its short course, and on account of the uncertainty of the origin of the profunda femoris, which, if it arise high up, would be too close to the ligature for the formation of a firm coagulum. The profunda sometimes arises higher than the point above mentioned, and rarely between two or three inches (in one case four) below Poupart's ligament. It would appear, then, that the most favourable situation for the application of a ligature to the femoral is between four and five inches from its point of origin. In order to expose the artery in this situation, an incision, between three and four inches long, should be made in the course of the vessel, the patient lying in the recumbent position, with the limb slightly flexed and abducted, and rotated outwards. A large vein is frequently met with, passing in the course of the artery to join the internal saphenous vein; this must be avoided, and the fascia lata having been cautiously divided, and the Sartorius exposed, that muscle must be drawn outwards, in order to fully expose the sheath of the vessels. The finger being introduced into the wound, and the pulsation of the artery felt, the sheath should be opened on the outer side of the vessel to a sufficient extent to allow of the introduction of the ligature, but no further; otherwise the nutrition of the coats of the vessel may be interfered with, or muscular branches which arise from the vessel at irregular intervals may be divided. In this part of the operation the long saphenous nerve and the nerve to the Vastus internus, which is in close relation with the sheath, should be avoided. The aneurism needle must be carefully introduced and kept close to the artery, to avoid the femoral vein, which lies behind the vessel in this part of its course.

To expose the artery, in Hunter's canal, an incision should be made through the integument, between three and four inches in length, a finger's breadth internal to the line of the artery, in the middle of the thigh—*i.e.* midway between the groin and the knee. The fascia lata having been divided, and the outer border of the Sartorius muscle exposed, it should be drawn inwards, when the strong fascia which is stretched across from the Adductors to the Vastus internus will be exposed, and must be freely divided; the sheath of the vessels is now seen, and must be opened, and the artery secured by passing the aneurism needle between the vein and artery, in the direction from without inwards. The femoral vein in this situation lies on the outer side of the artery, the long saphenous nerve on its anterior and outer side.

It has been seen that the femoral artery occasionally divides into two trunks below the origin of the profunda. If, in the operation for tying the femoral, two vessels are met with, the surgeon should alternately compress each, in order to ascertain which vessel is connected with the aneurismal tumour, or with the bleeding from the wound, and that one only should be tied which controls the pulsation or hæmorrhage. If, however, it is necessary to compress both vessels before the circulation in the tumour is controlled, both should be tied, as it would be probable that they became reunited, as in the instances referred to above.

In wounds of the femoral artery the question of the mode of treatment is of considerable importance. If the wound in the superficial structures is a large one, the injured vessel must be exposed and tied; but if the wound is a punctured one and the bleeding has ceased, the question will arise whether to cut down upon the artery or to trust to pressure. Mr. Cripps † advises, that if the wound is in the upper part of the thigh—that is to say, in a position where the femoral artery is comparatively superficial—the surgeon may enlarge the opening with a good prospect of finding the wounded vessel without an extensive or prolonged operation. If the wound be in the lower half of the thigh, owing to the greater depth of the artery, and the possibility of its being the popliteal that is wounded, the search is rendered a far more severe and hazardous operation, and it should not be undertaken until a thorough trial of pressure has proved ineffectual.

Great care and attention are necessary for the successful application of pressure. The limb should be carefully bandaged from the foot upwards to the wound, which is not covered, and then onwards to the groin. The wound is then dusted with iodoform or boracic powder, and a conical pad applied over it. Rollers the thickness of the index finger are then placed along the course of the vessel above and below the wound, and the whole carefully bandaged to a back splint with a foot-piece.

*Collateral Circulation.*—When the common femoral is tied, the main channels for carrying on the circulation are the anastomoses of the gluteal and circumflex iliac arteries above with the external circumflex below; of the obturator and sciatic above with the internal circumflex below; and of the comes nervi ischiadici with the arteries in the ham.

\* Ligature of the femoral artery has been also recommended and performed for elephantiasis of the leg and acute inflammation of the knee-joint.—Maunder, *Clin. Soc. Trans.*, vol. ii. p. 37.

† Heath's *Dictionary of Practical Surgery*, vol. i. p. 525.



The principal agents in carrying on the collateral circulation after ligature of the superficial femoral artery are, according to Sir A. Cooper, as follows:—

'The arteria profunda formed the new channel for the blood.' 'The first artery sent off passed down close to the back of the thigh-bone, and entered the two superior articular branches of the popliteal artery.'

'The second new large vessel, arising from the profunda at the same part with the former, passed down by the inner side of the Biceps muscle, to a branch of the popliteal which was distributed to the Gastrocnemius muscle; whilst a third artery, dividing into several branches, passed down with the sciatic nerve behind the knee-joint, and some of its branches united with the inferior articular arteries of the popliteal, with some recurrent branches of those arteries, with arteries passing to the Gastrocnemius, and, lastly, with the origin of the anterior and posterior tibial arteries.'

'It appears then that it is those branches of the profunda which accompany the sciatic nerve that are the principal supporters of the new circulation.'

In Porta's work † (tab. xii. xiii.) is a good representation of the collateral circulation after ligature of the femoral artery. The patient had survived the operation three years. The lower part of the artery, is at least as large as the upper; about two inches of the vessel appear to have been obliterated. The external and internal circumflex arteries are seen anastomosing by a great number of branches with the lower branches of the femoral (muscular and anastomotica magna), and with the articular branches of the popliteal. The branches from the external circumflex are extremely large and numerous. One very distinct anastomosis can be traced between this artery on the outside and the anastomotica magna on the inside, through the intervention of the superior external articular artery, with which they both anastomose; and blood reaches even the anterior tibial recurrent from the external circumflex by means of anastomosis with the same external articular artery. The perforating branches of the profunda are also seen bringing blood round the obliterated portion of the artery into long branches (muscular) which have been given off just below that portion. The termination of the profunda itself anastomoses most freely with the superior external articular. A long branch of anastomosis is also traced down from the internal iliac by means of the comes nervi ischiadici of the sciatic which anastomoses on the popliteal nerves with branches from the popliteal and posterior tibial arteries. In this case the anastomosis had been too free, since the pulsation and growth of the aneurism recurred, and the patient died after ligature of the external iliac.

There is an interesting preparation in the Museum of the Royal College of Surgeons of a limb on which John Hunter had tied the femoral artery fifty years before the patient's death. The whole of the superficial femoral and popliteal artery seems to have been obliterated. The anastomosis by means of the comes nervi ischiadici, which is shown in Porta's plate, is distinctly seen: the external circumflex, and the termination of the profunda artery, seem to have been the chief channels of anastomosis; but the injection has not been a very successful one.

**Branches.**—The branches of the femoral artery are, the

Superficial Epigastric.		(External Circumflex.
Superficial Circumflex Iliac.	Profunda	- Internal Circumflex.
Superficial External Pudic.		(Three Perforating.
Deep External Pudic.	Muscular.	
	Anastomotica Magna.	

The **superficial epigastric** arises from the femoral, about half an inch below Poupart's ligament, and, passing through the saphenous opening in the fascia lata, ascends on to the abdomen, in the superficial fascia covering the External oblique muscle, nearly as high as the umbilicus. It distributes branches to the superficial inguinal glands, the superficial fascia, and the integument, anastomosing with branches of the deep epigastric.

The **superficial circumflex iliac**, the smallest of the cutaneous branches, arises close to the preceding, and, piercing the fascia lata, runs outwards, parallel with Poupart's ligament, as far as the crest of the ilium, dividing into branches which supply the integument of the groin, the superficial fascia, and the superficial inguinal lymphatic glands, anastomosing with the deep circumflex iliac, and with the gluteal and external circumflex arteries.

The **superficial external pudic** (superior) arises from the inner side of the femoral artery, close to the preceding vessels, and, after passing through the saphenous opening, courses inwards, across the spermatic cord or round ligament, to be distributed to the integument on the lower part of the abdomen, the penis

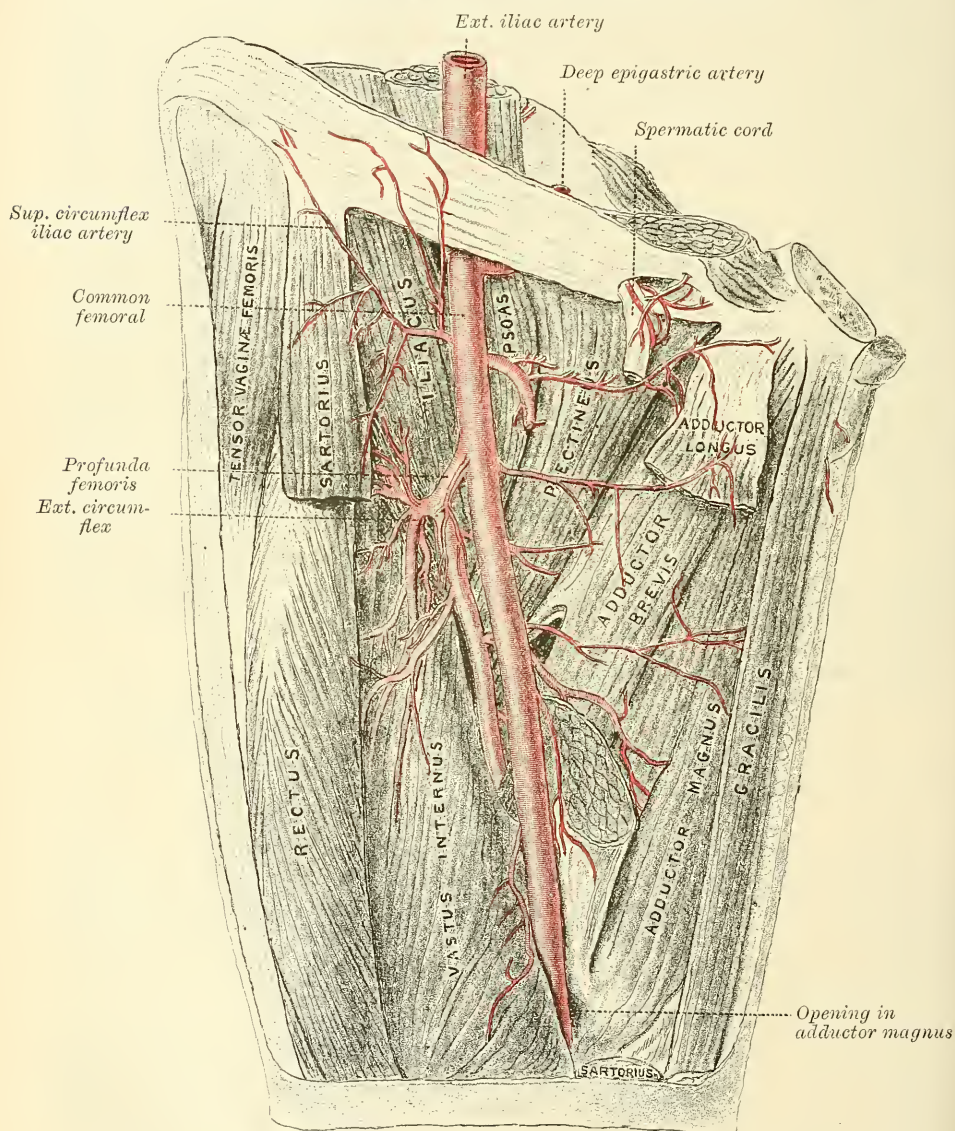
\* *Med.-Chir. Trans.*, vol. ii. 1811.

† *Alterazioni patologiche delle Arterie.*

and scrotum in the male, and the labium in the female, anastomosing with branches of the internal pudic.

The **deep external pudic** (inferior), more deeply seated than the preceding, passes inwards across the Pectineus and Adductor longus muscles, covered by the fascia lata, which it pierces at the inner border of the thigh, its branches being distributed, in the male, to the integument of the scrotum and perinæum; and in the female to the labium, anastomosing with branches of the superficial perineal artery.

FIG. 418.—Femoral artery and its branches, showing profunda. (From a preparation in the Hunterian Museum, Royal College of Surgeons.)



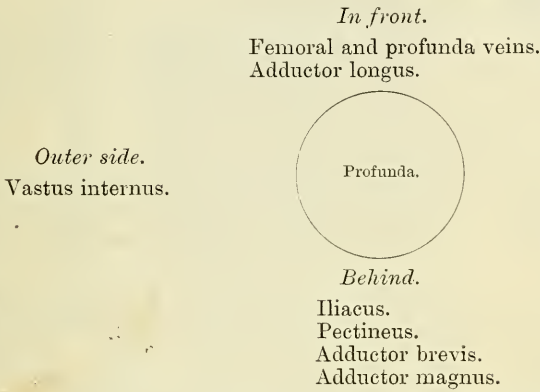
The **Profunda Femoris** (*deep femoral artery*) (fig. 418) nearly equals the size of the superficial femoral. It arises from the outer and back part of the femoral artery, from one to two inches below Poupart's ligament. It at first lies on the outer side of the superficial femoral, and then passes behind it and the femoral vein to the inner side of the femur, and, passing downwards beneath the Adductor longus, terminates at the lower third of the thigh in a small branch, which



pierces the Adductor magnus (and from this circumstance is sometimes called the fourth perforating artery), and is distributed to the Flexor muscles on the back of the thigh, anastomosing with branches of the popliteal and inferior perforating arteries.

**Relations.**—*Behind*, it lies first upon the Iliacus, and then on the Pectineus, Adductor brevis, and Adductor magnus muscles. *In front*, it is separated from the femoral artery, above by the femoral and profunda veins, and below by the Adductor longus. On its *outer side*, the origin of the Vastus internus separates it from the femur.

PLAN OF RELATIONS OF THE PROFUNDA ARTERY



The profunda gives off the following named branches :—

External circumflex.      Internal circumflex.      Three perforating.

The **External Circumflex Artery** supplies the muscles on the front of the thigh. It arises from the outer side of the profunda, passes horizontally outwards, between the divisions of the anterior crural nerve, and behind the Sartorius and Rectus muscles, and divides into three sets of branches, ascending, transverse, and descending.

The *ascending branches* pass upwards, beneath the Tensor vaginæ femoris muscle, to the outer side of the hip, anastomosing with the terminal branches of the gluteal and deep circumflex iliac arteries.

The *descending branches*, three or four in number, pass downwards, behind the Rectus, upon the Vasti muscles to which they are distributed, one or two passing beneath the Vastus externus as far as the knee, anastomosing with the superior articular branches of the popliteal artery. These are accompanied by the branch of the anterior crural nerve to the Vastus externus.

The *transverse branches*, the smallest and least numerous, pass outwards over the Crureus, pierce the Vastus externus, and wind round the femur to its back part, just below the great trochanter, anastomosing at the back of the thigh with the internal circumflex, sciatic, and superior perforating arteries.

The **Internal Circumflex Artery**, smaller than the external, arises from the inner and back part of the profunda, and winds round the inner side of the femur, between the Pectineus and Psoas muscles. On reaching the upper border of the Adductor brevis, it gives off two branches, one of which passes inwards to be distributed to the Adductor muscles, the Gracilis, and Obturator externus, anastomosing with the obturator artery; the other descends, and passes beneath the Adductor brevis, to supply it and the great Adductor; while the continuation of the vessel passes backwards, between the Quadratus femoris and upper border of the Adductor magnus, anastomosing with the sciatic, external circumflex, and superior perforating arteries ('the crucial anastomosis'). Opposite the hip-joint, this branch gives off an articular vessel, which enters the joint beneath the



transverse ligament; and, after supplying the adipose tissue, passes along the round ligament to the head of the bone.

The **Perforating Arteries** (fig. 416), usually three in number, are so called from their perforating the tendon of the Adductor magnus muscle to reach the back of the thigh. The first is given off above the Adductor brevis, the second in front of that muscle, and the third immediately below it.

The *first or superior perforating artery* passes backwards between the Pectineus and Adductor brevis (sometimes perforates the latter); it then pierces the Adductor magnus close to the *linea aspera*, and divides into branches which supply the Adductor brevis, the Adductor magnus, the Biceps, and Gluteus maximus muscle: anastomosing with the sciatic, internal and external circumflex, and middle perforating arteries.

The *second or middle perforating artery*, larger than the first, pierces the tendons of the Adductor brevis and Adductor magnus muscles; and divides into ascending and descending branches, which supply the flexor muscles of the thigh, anastomosing with the superior and inferior perforating. The nutrient artery of the femur is usually given off from this branch.

The *third or inferior perforating artery* is given off below the Adductor brevis; it pierces the Adductor magnus, and divides into branches which supply the flexor muscles of the thigh; anastomosing above with the perforating arteries, and below with the terminal branches of the profunda and the muscular branches of the popliteal.

**Muscular branches** are given off from the superficial femoral throughout its entire course. They vary from two to seven in number, and supply chiefly the Sartorius and Vastus internus.

The **Anastomotica Magna** (fig. 419) arises from the femoral artery just before it passes through the tendinous opening in the Adductor magnus muscle, and immediately divides into a superficial and deep branch.

The *superficial branch* pierces the aponeurotic covering of Hunter's canal, and accompanies the long saphenous nerve to the inner side of the thigh. It passes between the Sartorius and Gracilis muscles, and, piercing the fascia lata, is distributed to the integument of the upper and inner part of the leg, anastomosing with the inferior internal articular.

The *deep branch* descends in the substance of the Vastus internus, lying in front of the tendon of the Adductor magnus, to the inner side of the knee, where it anastomoses with the superior internal articular artery and anterior recurrent branch of the anterior tibial. A branch from this vessel crosses outwards above the articular surface of the femur, forming an anastomotic arch with the superior external articular artery, and supplies branches to the knee-joint.

#### POPLITEAL ARTERY

The **popliteal artery** commences at the termination of the femoral at the opening in the Adductor magnus, and, passing obliquely downwards and outwards behind the knee-joint to the lower border of the Popliteus muscle, divides into the *anterior* and *posterior tibial arteries*. A portion of the artery lies in the popliteal space; but above and below, to a considerable extent, it is covered by the muscles which form the boundaries of the space, and is therefore beyond the confines of the hollow.

#### THE POPLITEAL SPACE (fig. 420)

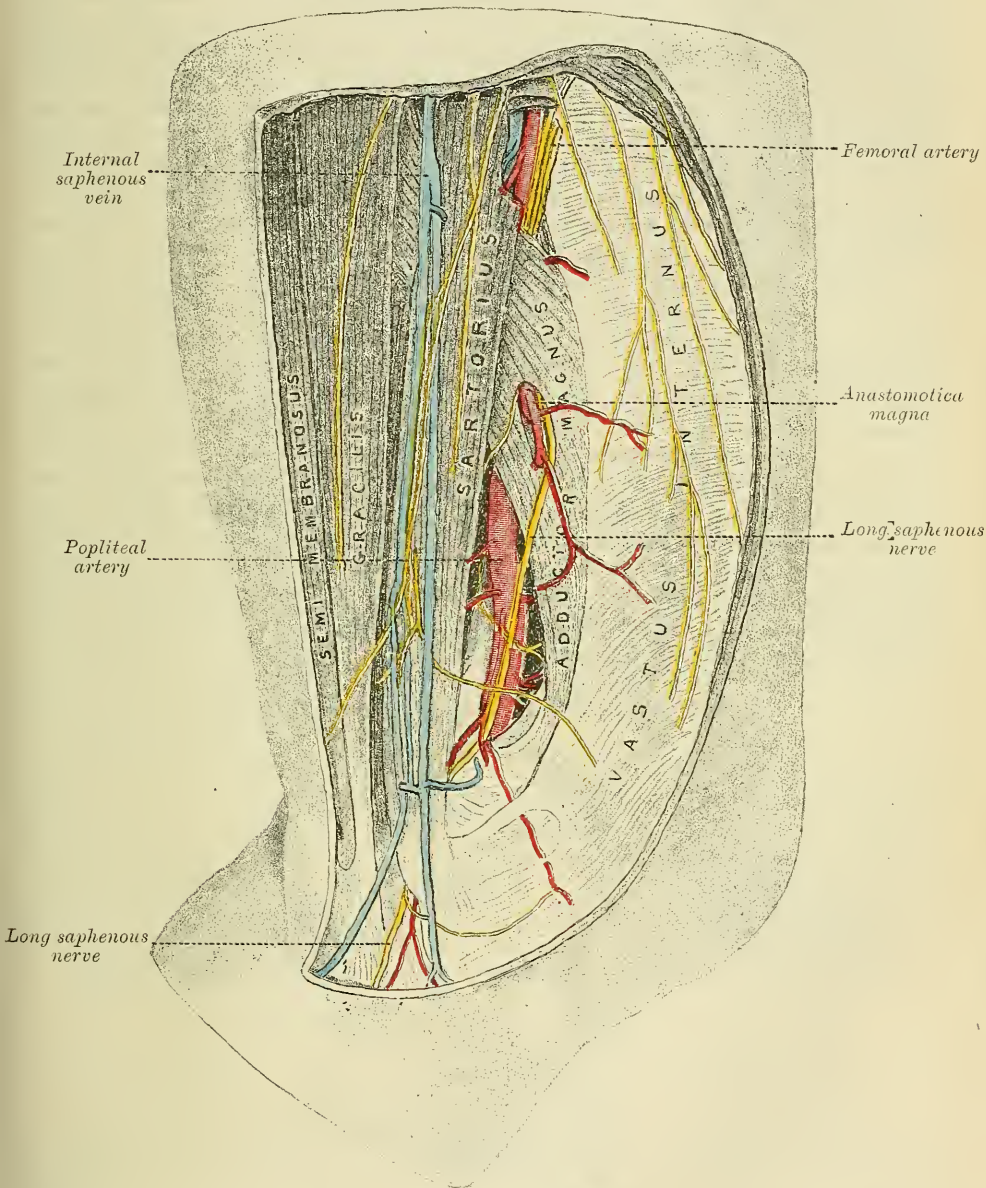
*Dissection.*—A vertical incision about eight inches in length should be made along the back part of the knee-joint, connected above and below by a transverse incision from the inner to the outer side of the limb. The flaps of integument included between these incisions should be reflected in the direction shown in fig. 366, p. 519.

**Boundaries.**—The **popliteal space**, or the **ham**, is a lozenge-shaped space, widest at the back part of the knee-joint, and deepest above the articular end of

the femur. It is bounded externally, above the joint, by the Biceps, and, below the joint, by the Plantaris and external head of the Gastrocnemius. Internally, above the joint, by the Semimembranosus, Semitendinosus, Gracilis, and Sartorius; below the joint, by the inner head of the Gastrocnemius.

Above, it is limited by the apposition of the inner and outer hamstring muscles; below, by the junction of the two heads of the Gastrocnemius. The

FIG. 419.—Side view of the popliteal artery. (From a preparation in the Hunterian Museum, Royal College of Surgeons.)



floor is formed by the lower part of the posterior surface of the shaft of the femur, the posterior ligament of the knee-joint, the upper end of the tibia, and the fascia covering the Popliteus muscle, and the space is covered in by the fascia lata.

**Contents.**—It contains the popliteal vessels and their branches, together with the termination of the external saphenous vein, the internal and external popliteal nerves and some of their branches, the lower extremity of the small sciatic

nerve, the articular branch from the obturator nerve, a few small lymphatic glands, and a considerable quantity of loose adipose tissue.

**Position of contained parts.**—The internal popliteal nerve descends in the middle line of the space, lying superficial and crossing the artery from without inwards. The external popliteal nerve descends on the outer side of the space, lying close to the tendon of the Biceps muscle. More deeply at the bottom of the space are the popliteal vessels, the vein lying superficial to the artery, to which it is closely united by dense areolar tissue; it lies at first to the outer side of the artery, and then crosses it to gain the inner side below; sometimes the vein is double, the artery lying between the two venæ comites, which are usually connected by short transverse branches. More deeply, and, at its upper part, close to the surface of the bone, is the popliteal artery, and passing off from it at right angles are its articular branches. The articular branch from the obturator nerve descends upon the popliteal artery to supply the knee; and occasionally there is found deep in the space an articular filament from the great sciatic nerve. The popliteal lymphatic glands, four or five in number, are found surrounding the artery: one usually lies superficial to the vessel; another is situated between it and the bone; and the rest are placed on either side of it.

The **Popliteal Artery**, in its course downwards from the aperture in the Adductor magnus to the lower border of the Popliteus muscle, rests first on the inner surface of the femur, and is then separated by a little fat from the hollowed popliteal surface of the bone; in the middle of its course, it rests on the posterior ligament of the knee-joint; and below, on the fascia covering the Popliteus muscle. *Superficially*, it is covered above by the Semimembranosus; in the middle of its course, by a quantity of fat, which separates it from the deep fascia and integument: and below, it is overlapped by the Gastrocnemius, Plantaris, and Soleus muscles, the popliteal vein, and the internal popliteal nerve. The popliteal vein, which is intimately attached to the artery, lies superficial and external to it above; it then crosses it and lies to its inner side. The popliteal nerve is still more superficial and external above, but below the joint it crosses the artery and lies on its inner side. *Laterally*, the artery is bounded by the muscles which are situated on either side of the popliteal space.

#### PLAN OF RELATIONS OF THE POPLITEAL ARTERY

*In front.*

Femur.  
Ligamentum posticum.  
Popliteus.

*Inner side.*

Semimembranosus.  
Internal condyle.  
Gastrocnemius (inner head).



*Outer side.*

Biceps.  
Outer condyle.  
Gastrocnemius (outer head).  
Plantaris.

*Behind.*

Semimembranosus.  
Fascia.  
Popliteal vein.  
Internal popliteal nerve.  
Gastrocnemius.  
Plantaris.  
Soleus.

*Peculiarities in point of Division.*—Occasionally the popliteal artery divides prematurely into its terminal branches; this unusual division occurs most frequently opposite the knee-joint.

*Unusual Branches.*—The artery sometimes divides into the anterior tibial and peroneal, the posterior tibial being wanting, or very small. Occasionally the popliteal is found to divide into three branches, the anterior and posterior tibial, and peroneal.



*Surface Marking.*—The course of the upper part of the popliteal artery is indicated by a line drawn from the outer border of the Semimembranosus muscle at the junction of the middle and lower third of the thigh obliquely downwards to the middle of the popliteal space exactly behind the knee-joint. From this point it passes vertically downwards to the level of a line drawn through the lower part of the tubercle of the tibia.

*Surgical Anatomy.*—The popliteal artery is not infrequently the seat of injury. It may be torn by direct violence, as by the passage of a cart-wheel over the knee, or by hyper-extension of the knee; and in the dead body, at all events, the middle and internal coats may be ruptured by extreme flexion. It may also be lacerated by fracture of the lower part of the shaft of the femur, or by antero-posterior dislocation of the knee-joint. It has been torn in breaking down adhesions in cases of fibrous ankylosis of the knee, and is in danger of being wounded, and in fact has been wounded, in performing Macewen's operation of osteotomy of the lower end of the femur for genu valgum. In addition, Spencer records a case in which the popliteal artery was wounded from in front by a stab just below the knee, the knife passing through the interosseous space. The popliteal artery is more frequently the seat of aneurism than is any other artery in the body, with the exception of the thoracic aorta. This is due no doubt in a great measure to the amount of movement to which it is subjected, and to the fact that it is supported by loose and lax tissue only, and not by muscles as is the case with most arteries.

Ligature of the popliteal artery is required in cases of wound of that vessel, but for aneurism of the posterior tibial, it is preferable to tie the superficial femoral. The popliteal may be tied in the upper or lower part of its course; but in the middle of the ham the operation is attended with considerable difficulty, from the great depth of the artery, and from the extreme degree of tension of the lateral boundaries of the space.

In order to expose the vessel in the upper part of its course, the patient should be placed in the prone position, with the limb extended. An incision about three inches in length should then be made through the integument, along the posterior margin of the Semimembranosus, and the fascia lata having been divided, this muscle must be drawn inwards. The internal popliteal nerve will be first exposed, lying very superficial and external to the artery; beneath this will be seen the popliteal vein, and still deeper, and to its inner side, the artery. The vein and nerve must be cautiously separated from the artery, and the aneurism needle passed around the vessel from without inwards.

To expose the vessel in the lower part of its course, where the artery lies between the two heads of the Gastrocnemius, the patient should be placed in the same position as in the preceding operation. An incision should then be made through the integument in the middle line, commencing opposite the bend of the knee-joint, care being taken to avoid the external saphenous vein and nerve. After dividing the deep fascia, and separating some dense cellular membrane, the artery, vein, and nerve will be exposed, descending between the two heads of the Gastrocnemius. Some muscular branches of the popliteal should be avoided if possible, or, if divided, tied immediately. The leg being now flexed, in order the more effectually to separate the two heads of the Gastrocnemius, the nerve should be drawn inwards and the vein outwards, and the aneurism needle passed between the artery and vein from without inwards.

In cases where the artery has been wounded during an osteotomy of the lower end of the femur, it would be most conveniently secured from the front at the inner side of the thigh. The knee is flexed and the limb placed on its outer side. An incision, three inches long, is made parallel to and immediately behind the tendon of the Adductor magnus from the junction of the middle and lower third of the thigh. Skin, superficial and deep fascia are to be divided, care being taken of the internal saphenous vein; the Adductor magnus is to be drawn forwards, and the inner hamstring tendons backwards, and the artery will be found surrounded by fat. The nerve and vein are usually not seen, as they lie to the outer side of the artery.

The branches of the popliteal artery are, the

Muscular	{ Superior.	Superior Internal Articular.
	{ Inferior or Sural.	Azygos Articular.
Cutaneous.		Inferior External Articular.
Superior External Articular.		Inferior Internal Articular.

The **superior muscular branches**, two or three in number, arise from the upper part of the popliteal artery, and are distributed to the lower part of the Adductor magnus and flexor muscles of the thigh; anastomosing with the inferior perforating and terminal branches of the profunda.

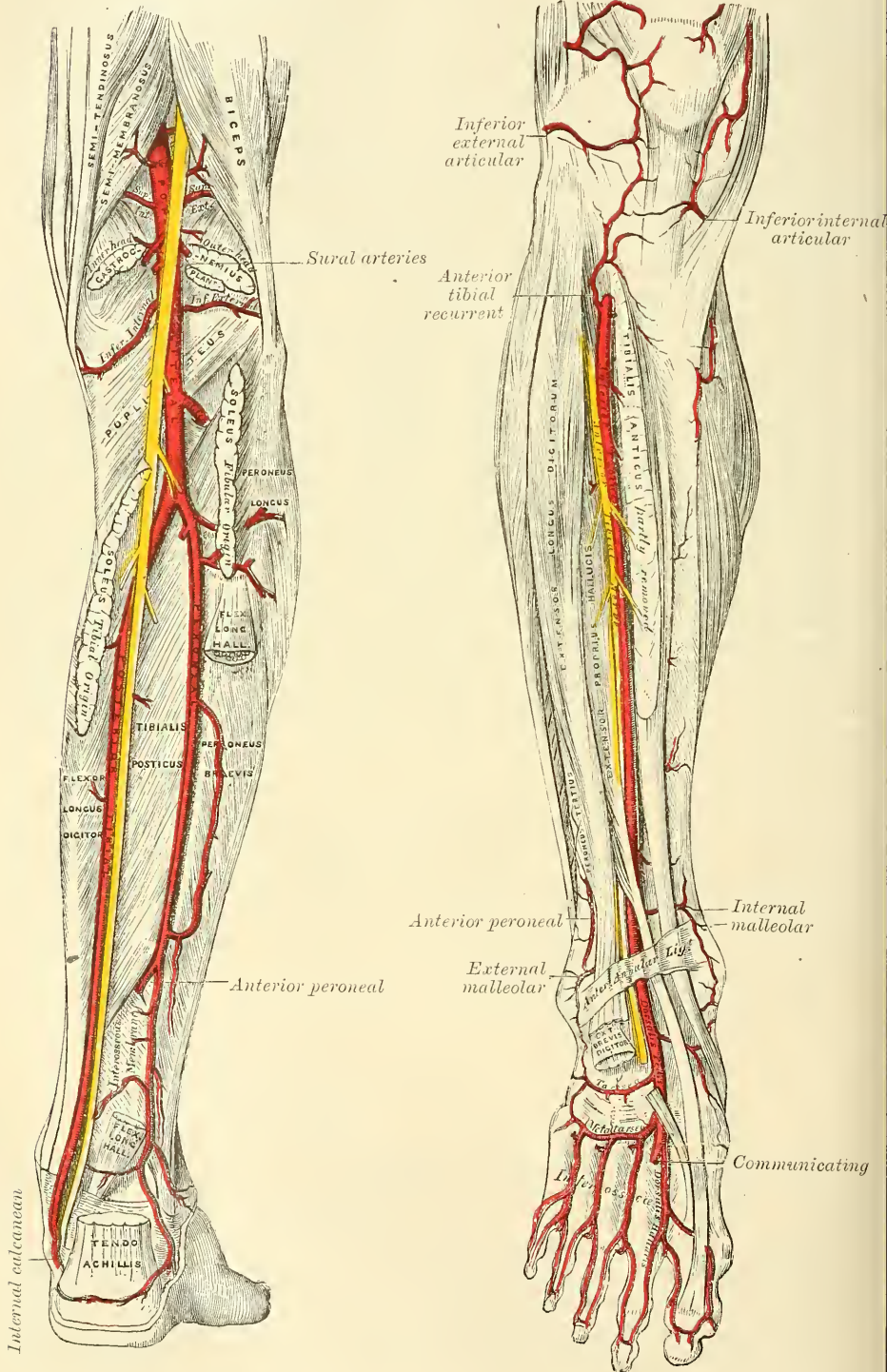
The **inferior muscular (sural)** are two large branches, which are distributed to the two heads of the Gastrocnemius and to the Plantaris muscle. They arise from the popliteal artery opposite the knee-joint.

The **cutaneous branches** arise separately from the popliteal artery or from some of its branches; they descend between the two heads of the Gastrocnemius

muscle, and, piercing the deep fascia, are distributed to the integument of the calf. One branch usually accompanies the short, or external, saphenous vein.

FIG. 420.—The popliteal, posterior tibial, and peroneal arteries.

FIG. 421.—Anterior tibial and dorsalis pedis arteries.





The **superior articular arteries**, two in number, arise one on each side of the popliteal, and wind round the femur immediately above its condyles to the front of the knee-joint. The *internal branch* winds inwards beneath the hamstring muscles, to which it supplies branches, above the inner head of the Gastrocnemius, and passing beneath the tendon of the Adductor magnus, divides into two branches, one of which supplies the Vastus internus, inosculating with the anastomotica magna and inferior internal articular; the other ramifies close to the surface of the femur, supplying it and the knee-joint, and anastomosing with the superior external articular artery. The *external branch* passes above the outer condyle, beneath the tendon of the Biceps, and divides into a superficial and deep branch: the superficial branch supplies the Vastus externus, and anastomoses with the descending branch of the external circumflex, and the inferior external articular arteries; the deep branch supplies the lower part of the femur and knee-joint, and forms an anastomotic arch across the bone with the anastomotica magna and the inferior internal articular arteries.

The **azygos articular** is a small branch, arising from the popliteal artery opposite the bend of the knee-joint. It pierces the posterior ligament, and supplies the ligaments and synovial membrane in the interior of the articulation.

The **inferior articular arteries**, two in number, arise from the popliteal beneath the Gastrocnemius, and wind round the head of the tibia, below the joint. The *internal* one first descends along the upper margin of the Popliteus muscle, to which it gives branches; it then passes below the inner tuberosity, beneath the internal lateral ligament, at the anterior border of which it ascends to the front and inner side of the joint, to supply the head of the tibia and the articulation of the knee, anastomosing with the inferior external articular and superior internal articular arteries. The *external* one passes outwards above the head of the fibula, to the front of the knee-joint, passing in its course beneath the outer head of the Gastrocnemius, the external lateral ligament, and the tendon of the Biceps muscle, and divides into branches, which anastomose with the inferior internal articular artery, the superior external articular artery, and the anterior recurrent branch of the anterior tibial.

**Circumpatellar Anastomosis.**—Around and above the patella, and on the contiguous ends of the femur and tibia, is a large network of vessels, forming a superficial and deep plexus. The superficial plexus is situated between the fascia and skin round about the patella; the deep plexus, which forms a close network of vessels, lies on the surface of the lower end of the femur and upper end of the tibia around their articular surfaces, and sends numerous offsets into the interior of the joint. The arteries from which this plexus is formed are the two internal and two external articular branches of the popliteal: the anastomotica magna; the terminal branch of the profunda; the descending branch from the external circumflex, and the anterior recurrent branch of the anterior tibial.

#### ANTERIOR TIBIAL ARTERY (fig. 421)

The **anterior tibial artery** commences at the bifurcation of the popliteal, at the lower border of the Popliteus muscle, passes forwards between the two heads of the Tibialis posticus, and through the large oval aperture above the upper border of the interosseous membrane, to the deep part of the front of the leg: it here lies close to the inner side of the neck of the fibula; it then descends on the anterior surface of the interosseous membrane, gradually approaching the tibia; and, at the lower part of the leg, lies on this bone, and then on the anterior ligament of the ankle, to the bend of the ankle-joint, where it lies more superficially, and becomes the *dorsalis pedis*.

**Relations.**—In the upper two-thirds of its extent, it rests upon the interosseous membrane, to which it is connected by delicate fibrous arches thrown across it. In the lower third, upon the front of the tibia, and the anterior ligament of the ankle-joint. In the upper third of its course, it lies between the Tibialis anticus



and Extensor longus digitorum; in the middle third, between the Tibialis anticus and Extensor proprius hallucis. At the bend of the ankle, it is crossed by the tendon of the Extensor proprius hallucis, and lies between it and the innermost tendon of the Extensor longus digitorum. It is covered, in the upper two-thirds of its course, by the muscles which lie on either side of it, and by the deep fascia; in the lower third, by the integument, anterior annular ligament, and fascia.

The anterior tibial artery is accompanied by two veins (*venæ comites*) which lie one on each side of the artery; the anterior tibial nerve, coursing round the outer side of the neck of the femur, gets into relation with the outer side of the artery shortly after it has passed through the opening of the interosseous membrane; about the middle of the leg it is placed superficial to it; at the lower part of the artery the nerve is generally again on the outer side.

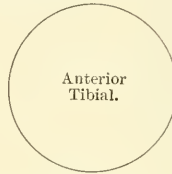#### PLAN OF THE RELATIONS OF THE ANTERIOR TIBIAL ARTERY

*In front.*

Integument, superficial and deep fasciæ.  
 Anterior tibial nerve.  
 Tibialis anticus (overlaps it in the upper part of the leg).  
 Extensor longus digitorum } (overlap it slightly).  
 Extensor proprius hallucis }  
 Anterior annular ligament.

*Inner side.*

Tibialis anticus.  
 Extensor proprius hallucis  
 (crosses it at its lower  
 part).



*Outer side.*

Anterior tibial nerve.  
 Extensor longus digitorum.  
 Extensor proprius hallucis.

*Behind.*

Interosseous membrane.  
 Tibia.  
 Anterior ligament of ankle-joint.

*Peculiarities in Size.*—This vessel may be diminished in size, may be deficient to a greater or less extent, or may be entirely wanting, its place being supplied by perforating branches from the posterior tibial, or by the anterior division of the peroneal artery.

*Course.*—The artery occasionally deviates in its course towards the fibular side of the leg, regaining its usual position beneath the annular ligament at the front of the ankle. In two instances the vessel has been found to approach the surface in the middle of the leg, being covered merely by the integument and fascia below that point.

*Surface Marking.*—A line drawn from the inner side of the head of the fibula to midway between the two malleoli, will mark the course of the artery; the point where the artery comes in front of the interosseous membrane being in this line, one and a quarter inch below the level of the head of the fibula.

*Surgical Anatomy.*—The anterior tibial artery may be tied in the upper or lower part of the leg. In the upper part the operation is attended with great difficulty, on account of the depth of the vessel from the surface. An incision, about four inches in length, should be made through the integument, midway between the spine of the tibia and the outer margin of the fibula, the fascia and intermuscular septum between the Tibialis anticus and Extensor longus digitorum being divided to the same extent. The foot must be flexed to relax these muscles, and they must be separated from each other by the finger. The artery is then exposed, deeply seated, lying upon the interosseous membrane, the nerve lying externally, and one of the *venæ comites* on either side; these must be separated from the artery before the aneurism needle is passed round it.

To tie the vessel in the lower third of the leg above the ankle-joint, an incision about three inches in length should be made through the integument between the tendons of the Tibialis anticus, and Extensor proprius hallucis muscles, the deep fascia being divided to the same extent. The tendon on either side should be held aside, when the vessel will be seen lying upon the tibia, with the nerve on the outer side, and one of the *venæ comites* on either side.

The branches of the anterior tibial artery are, the

Posterior Recurrent Tibial.	Muscular.
Superior Fibular.	Internal Malleolar.
Anterior Recurrent Tibial.	External Malleolar.

The **posterior recurrent tibial** is not a constant branch, and is given off from the anterior tibial before that vessel passes through the interosseous space. It ascends beneath the Popliteus muscle, which it supplies, and anastomoses with the lower articular branches of the popliteal artery, giving off an offset to the superior tibio-fibular joint.

The **superior fibular** is sometimes given off from the anterior tibial, sometimes from the posterior tibial. It passes outwards, round the neck of the fibula, through the Soleus, which it supplies, and ends in the substance of the Peroneus longus muscle.

The **anterior recurrent tibial** arises from the anterior tibial, as soon as that vessel has passed through the interosseous space; it ascends in the Tibialis anticus muscle, and ramifies on the front and sides of the knee-joint, anastomosing with the articular branches of the popliteal, and with the anastomotica magna assisting in the formation of the circumpatellar plexus.

The **muscular branches** are numerous: they are distributed to the muscles which lie on each side of the vessel, some piercing the deep fascia to supply the integument, others passing through the interosseous membrane, and anastomosing with branches of the posterior tibial and peroneal arteries.

The **malleolar arteries** supply the ankle-joint. The *internal* arises about two inches above the articulation, and passes beneath the tendons of the Extensor proprius hallucis and Tibialis anticus, to the inner ankle, upon which it ramifies, anastomosing with branches of the posterior tibial and internal plantar arteries and with the internal calcanean from the posterior tibial. The *external* passes beneath the tendons of the Extensor longus digitorum and Peroneus tertius, and supplies the outer ankle, anastomosing with the anterior peroneal artery, and with ascending branches from the tarsal branch of the dorsalis pedis.

#### DORSALIS PEDIS ARTERY (fig. 421)

The **dorsalis pedis**, the continuation of the anterior tibial, passes forwards from the bend of the ankle along the tibial side of the foot to the back part of the first intermetatarsal space, where it divides into two branches, the *dorsalis hallucis* and *communicating*.

**Relations.**—This vessel, in its course forwards, rests upon the astragalus, navicular, and internal cuneiform bones and the ligaments connecting them, being covered by the integument and fascia, anterior annular ligament, and crossed near its termination by the innermost tendon of the Extensor brevis digitorum. On its *tibial side* is the tendon of the Extensor proprius hallucis; on its *fibular side*, the innermost tendon of the Extensor longus digitorum, and the termination of the anterior tibial nerve. It is accompanied by two veins.

#### PLAN OF THE RELATIONS OF THE DORSALIS PEDIS ARTERY

*In front.*

Integument and fascia.  
Anterior annular ligament.  
Innermost tendon of Extensor brevis digitorum.

*Tibial side.*

Extensor proprius hallucis



*Fibular side.*

Extensor longus digitorum.  
Anterior tibial nerve.

*Behind.*

Astragalus.  
Navicular.  
Internal cuneiform,  
and their ligaments.

*Peculiarities in Size.*—The dorsal artery of the foot may be larger than usual, to compensate for a deficient plantar artery; or it may be deficient in its terminal branches to the toes, which are then derived from the internal plantar; or its place may be supplied altogether by a large anterior peroneal artery.

*Position.*—This artery frequently curves outwards, lying external to the line between the middle of the ankle and the back part of the first interosseous space.

*Surface Marking.*—The dorsalis pedis artery is indicated on the surface of the dorsum of the foot by a line drawn from the centre of the space between the two malleoli to the back of the first intermetatarsal space.

*Surgical Anatomy.*—This artery may be tied, by making an incision through the integument, between two and three inches in length, on the fibular side of the tendon of the Extensor proprius hallucis, in the interval between it and the inner border of the short Extensor muscle. The incision should not extend further forwards than the back part of the first intermetatarsal space, as the artery divides in that situation. The deep fascia being divided to the same extent, the artery will be exposed, the nerve lying upon its outer side.

**Branches.**—The branches of the dorsalis pedis are, the

Tarsal.	Dorsalis Hallucis.
Metatarsal—Interosseous.	Communicating.

The **tarsal artery** arises from the dorsalis pedis, as that vessel crosses the navicular bone; it passes in an arched direction outwards, lying upon the tarsal bones, and covered by the Extensor brevis digitorum; it supplies that muscle and the articulations of the tarsus, and anastomoses with branches from the metatarsal, external malleolar, peroneal, and external plantar arteries.

The **metatarsal** arises a little anterior to the preceding; it passes outwards to the outer part of the foot, over the bases of the metatarsal bones, beneath the tendons of the short Extensor, its direction being influenced by its point of origin; and it anastomoses with the tarsal and external plantar arteries. This vessel gives off three branches, the *interosseous arteries*, which pass forwards upon the three outer Dorsal interossei muscles, and, in the clefts between the toes, divide into two dorsal collateral branches for the adjoining toes. At the back part of each interosseous space these vessels receive the posterior perforating branches from the plantar arch; and at the fore part of each interosseous space, they are joined by the anterior perforating branches, from the digital arteries. The outermost interosseous artery gives off a branch which supplies the outer side of the little toe.

The **dorsalis hallucis**, or **first dorsal interosseous artery**, runs forwards along the outer border of the first metatarsal bone, and at the cleft between the first and second toes divides into two branches, one of which passes inwards, beneath the tendon of the Extensor proprius hallucis, and is distributed to the inner border of the great toe; the outer branch bifurcates, to supply the adjoining sides of the great and second toes.

The **communicating artery** dips down into the sole of the foot, between the two heads of the First dorsal interosseous muscle, and inosculates with the termination of the external plantar artery, to complete the plantar arch. It here gives off two digital branches: one runs along the inner side of the great toe, on its plantar surface; the other passes forwards along the first interosseous space, and bifurcates for the supply of the adjacent sides of the great and second toes.

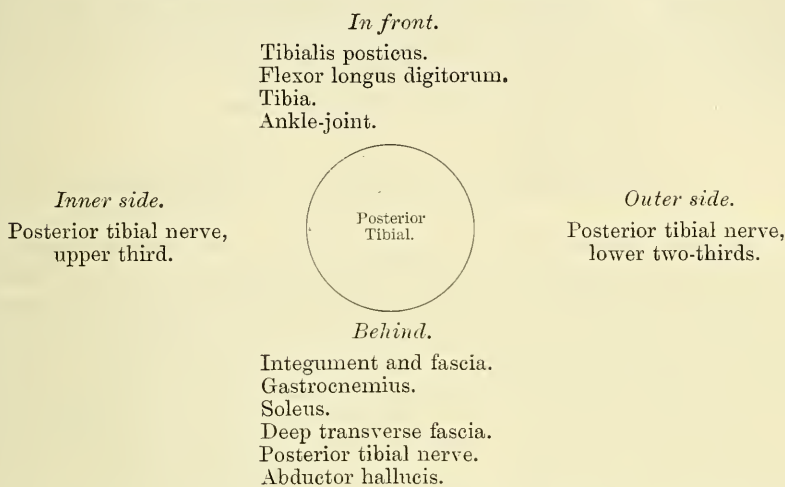
#### POSTERIOR TIBIAL ARTERY

The **posterior tibial** is an artery of large size, which extends obliquely downwards from the lower border of the Popliteus muscle, along the tibial side of the leg, to the fossa between the inner ankle and the heel, where it divides beneath the origin of the Abductor hallucis, on a level with a line drawn from the point of the internal malleolus to the centre of the convexity of the heel, into the *internal* and *external plantar arteries*. At its origin it lies opposite the interval between the tibia and fibula; as it descends, it approaches the inner side of the leg, lying behind the tibia, and, in the lower part of its course, is situated midway between the inner malleolus and the tuberosity of the os calcis.



**Relations.**—It lies successively upon the Tibialis posticus, the Flexor longus digitorum, the tibia, and the back part of the ankle-joint. It is covered by the deep transverse fascia, which separates it above from the Gastrocnemius and Soleus muscles: at its termination it is covered by the Abductor hallucis muscle. In the lower third, where it is more superficial, it is covered only by the integument and fascia, and runs parallel with the inner border of the tendo Achillis. It is accompanied by two veins, and by the posterior tibial nerve, which lies at first to the inner side of the artery, but soon crosses it, and is, in the greater part of its course, on its outer side.

PLAN OF THE RELATIONS OF THE POSTERIOR TIBIAL ARTERY



*Behind the Inner Ankle*, the tendons and blood-vessels are arranged in the following order, from within outwards:—First, the tendons of the Tibialis posticus and Flexor longus digitorum, lying in the same groove, behind the inner malleolus, the former being the most internal. External to these is the posterior tibial artery, having a vein on either side; and, still more externally, the posterior tibial nerve. About half an inch nearer the heel is the tendon of the Flexor longus hallucis.

*Peculiarities in Size.*—The posterior tibial is not unfrequently smaller than usual, or absent, its place being supplied by a large peroneal artery, which passes inwards at the lower end of the tibia, and either joins the small tibial artery, or continues alone to the sole of the foot.

*Surface Marking.*—The course of the posterior tibial artery is indicated by a line drawn from a point one inch below the centre of the popliteal space to midway between the tip of the internal malleolus and the centre of the convexity of the heel.

*Surgical Anatomy.*—The application of a ligature to the posterior tibial may be required in cases of wound of the sole of the foot, attended with great hæmorrhage, when the vessel should be tied at the inner ankle. In cases of wound of the posterior tibial, it will be necessary to enlarge the opening so as to expose the vessel at the wounded point, excepting where the vessel is injured by a punctured wound from the front of the leg. In cases of aneurism from wound of the artery low down, the vessel should be tied in the middle of the leg. But in aneurism of the posterior tibial high up, it would be better to tie the femoral artery.

To tie the posterior tibial artery at the ankle, a semilunar incision should be made through the integument, about two inches and a half in length, midway between the heel and inner ankle, or a little nearer the latter. The subcutaneous cellular tissue having been divided, a strong and dense fascia, the internal annular ligament, is exposed. This ligament is continuous above with the deep fascia of the leg, covers the vessels and nerves, and is intimately adherent to the sheaths of the tendons. This having been cautiously divided upon a director, the sheath of the vessels is exposed, and, being opened, the artery is seen with one of the venæ comites on each side. The aneurism needle should be passed round the vessel from the heel towards the ankle, in order to avoid the posterior tibial nerve, care being at the same time taken not to include the venæ comites.

The vessel may also be tied in the lower third of the leg by making an incision about three inches in length, parallel with the inner margin of the tendo Achillis. The internal saphenous vein being carefully avoided, the two layers of fascia must be divided upon a director, when the artery is exposed along the outer margin of the Flexor longus digitorum, with one of its venæ comites on either side, and the nerve lying external to it.

To tie the posterior tibial in the middle of the leg is a very difficult operation, on account of the great depth of the vessel from the surface. The patient being placed in the recumbent position, the injured limb should rest on its outer side, the knee being partially bent, and the foot extended, so as to relax the muscles of the calf. An incision about four inches in length should then be made through the integument, a finger's breadth behind the inner margin of the tibia, taking care to avoid the internal saphenous vein. The deep fascia having been divided, the margin of the Gastrocnemius is exposed, and must be drawn aside, and the tibial attachment of the Soleus divided, a director being previously passed beneath it. The artery may now be felt pulsating beneath the deep fascia, about an inch from the margin of the tibia. The fascia having been divided, and the limb placed in such a position as to relax the muscles of the calf as much as possible, the veins should be separated from the artery, and the aneurism needle passed round the vessel from without inwards, so as to avoid wounding the posterior tibial nerve.

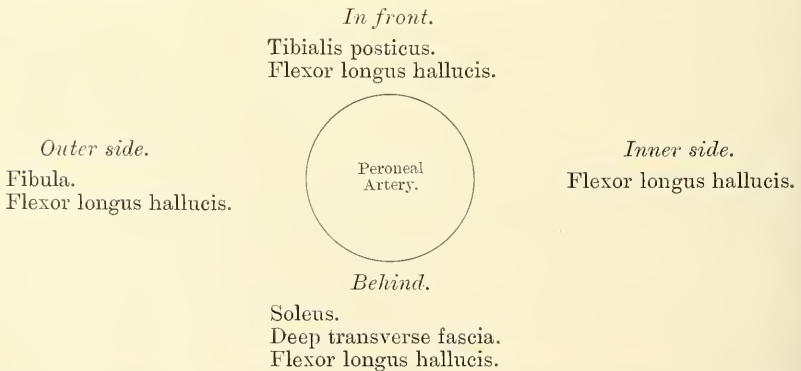
The branches of the posterior tibial artery are, the

Peroneal.	Nutrient.
Muscular.	Communicating.
Internal Calcanean.	

The **Peroneal Artery** lies, deeply seated, along the back part of the fibular side of the leg. It arises from the posterior tibial, about an inch below the lower border of the Popliteus muscle, passes obliquely outwards to the fibula, and then descends along the inner border of that bone, contained in a fibrous canal between the Tibialis posticus and the Flexor longus hallucis, to the lower third of the leg, where it gives off the *anterior peroneal*. It then passes across the articulation between the tibia and fibula to the outer side of the os calcis, where it gives off its terminal branches, the *external calcanean*.

**Relations.**—This vessel rests at first upon the Tibialis posticus, and then, for the greater part of its course, in a fibrous canal between the origins of the Flexor longus hallucis and Tibialis posticus, covered or surrounded by the fibres of the Flexor longus hallucis. It is *covered*, in the upper part of its course, by the Soleus and deep transverse fascia; *below*, by the Flexor longus hallucis.

#### PLAN OF THE RELATIONS OF THE PERONEAL ARTERY



*Peculiarities in Origin.*—The peroneal artery may arise three inches below the Popliteus, or from the posterior tibial high up, or even from the popliteal.

*Its size* is more frequently increased than diminished; and then it either reinforces the posterior tibial by its junction with it, or altogether takes the place of the posterior tibial in the lower part of the leg and foot, the latter vessel only existing as a short muscular branch. In those rare cases where the peroneal artery is smaller than usual, a branch from the posterior tibial supplies its place; and a branch from the anterior tibial compensates for the diminished anterior peroneal artery. In one case the peroneal artery has been found entirely wanting.

The anterior peroneal is sometimes enlarged, and takes the place of the dorsal artery of the foot.

The branches of the peroneal are, the

Muscular.	Communicating.
Nutrient.	Posterior Peroneal.
Anterior Peroneal.	External Calcanean.

*Muscular branches.*—The peroneal artery, in its course, gives off branches to the Soleus, Tibialis posticus, Flexor longus hallucis, and Peronei muscles.

The *nutrient* artery supplies the fibula.

The *Anterior peroneal* pierces the interosseous membrane, about two inches above the outer malleolus, to reach the fore part of the leg, and, passing down beneath the Peroneus tertius, to the outer ankle, ramifies on the front and outer side of the tarsus, anastomosing with the external malleolar and tarsal arteries.

The *communicating* is given off from the peroneal about an inch from its lower end, and, passing inwards, joins the communicating branch of the posterior tibial.

The *Posterior peroneal* passes down behind the outer ankle to the back of the external malleolus, to terminate in branches which ramify on the outer surface and back of the os calcis.

The *External calcanean* are the terminal branches of the peroneal artery; they pass to the outer side of the heel, and communicate with the external malleolar and, on the back of the heel, with the internal calcanean arteries.

The **nutrient artery** of the tibia arises from the posterior tibial, near its origin, and after supplying a few muscular branches, enters the nutrient canal of that bone, which it traverses obliquely from above downwards. This is the largest nutrient artery of bone in the body.

The **muscular branches** of the posterior tibial are distributed to the Soleus and deep muscles along the back of the leg.

The **communicating branch**, to join a similar branch of the peroneal, runs transversely across the back of the tibia, about two inches above its lower end, passing beneath the Flexor longus hallucis.

The **internal calcanean** are several large arteries, which arise from the posterior tibial just before its division; they are distributed to the fat and integument behind the tendo Achillis and about the heel, and to the muscles on the inner side of the sole, anastomosing with the peroneal and internal malleolar and, on the back of the heel, with the external calcanean arteries.

The **Internal Plantar Artery** (figs. 422, 423), much smaller than the external, passes forwards along the inner side of the foot. It is at first situated above\* the Abductor hallucis, and then between it and the Flexor brevis digitorum, both of which it supplies. At the base of the first metatarsal bone, where it has become much diminished in size, it passes along the inner border of the great toe, insinuating with its digital branch.

The **External Plantar Artery**, much larger than the internal, passes obliquely outwards and forwards to the base of the fifth metatarsal bone. It then turns obliquely inwards to the interval between the bases of the first and second metatarsal bones, where it anastomoses with the communicating branch from the dorsalis pedis artery, thus completing the *plantar arch*. As this artery passes outwards, it is first placed between the os calcis and Abductor hallucis, and then between the Flexor brevis digitorum and Flexor accessorius; and as it passes forwards to the base of the little toe, it lies more superficially between the Flexor brevis digitorum and Abductor minimi digiti, covered by the deep fascia and integument. The remaining portion of the vessel is deeply situated; it extends from the base of the metatarsal bone of the little toe to the back part of the first interosseous space, and forms the plantar arch; it is convex forwards, lies

\* This refers to the erect position of the body. In the ordinary position for dissection, the artery is deeper than the muscle.



upon the Interossei muscles, opposite the tarsal ends of the metatarsal bones, and is covered by the Adductor obliquus hallucis, the flexor tendons of the toes, and the Lumbricales.

*Surface Marking.*—The course of the internal plantar artery is represented by a line drawn from the mid-point between the tip of the internal malleolus and the centre of the convexity of the heel to the middle of the under surface of the great toe. The external plantar by a line from the same point to within a finger's breadth of the tuberosity of the fifth metatarsal bone. The plantar arch is indicated by a line drawn from this point: i.e. a finger's breadth internal to the tuberosity of the fifth metatarsal bone transversely across the foot to the back of the first interosseous space.

*Surgical Anatomy.*—Wounds of the plantar arch are always serious, on account of the depth of the vessel and the important structures which must be interfered with in an attempt to ligature it. Delorme has shown that it may be ligatured from the dorsum of the foot in almost any part of its course by removing a portion of one of the three middle metatarsal bones.

**Branches.**—The plantar arch, besides distributing numerous branches to the muscles, integument, and fasciæ in the sole, gives off the following branches:—

Posterior Perforating.

Digital—Anterior Perforating.

The **Posterior Perforating** are three small branches, which ascend through the back part of the three outer interosseous spaces, between the heads of the Dorsal

FIG. 422.—The plantar arteries.  
Superficial view.

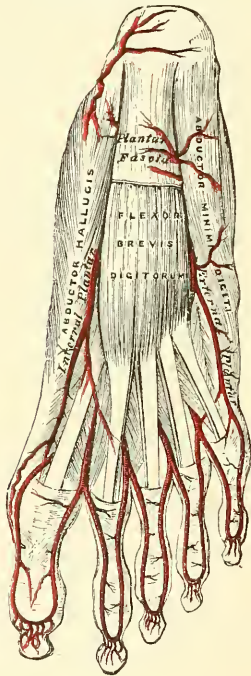
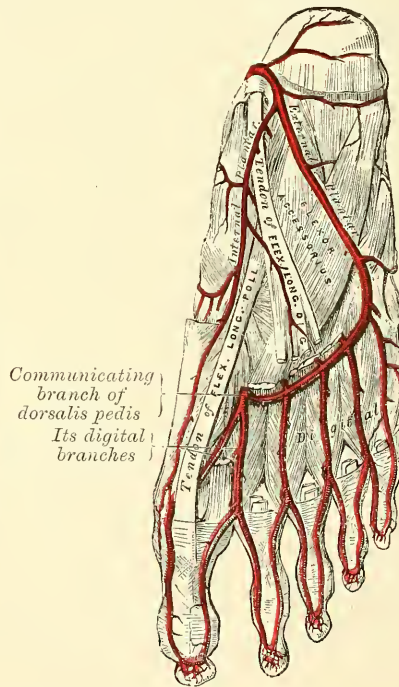


FIG. 423.—The plantar arteries.  
Deep view.



interossei muscles, and anastomose with the interosseous branches from the metatarsal artery.

The **Digital Branches** are four in number, and supply the three outer toes and half the second toe. The *first* passes outwards from the outer side of the plantar arch, and is distributed to the outer side of the little toe, passing in its course beneath the abductor and short flexor muscles. The *second*, *third*, and *fourth* run forwards along the interosseous spaces, and on arriving at the clefts between the toes divide into collateral branches, which supply the adjacent sides of the three outer toes and the outer side of the second. At the bifurcation of the toes, each digital artery sends upwards, through the fore part

of the corresponding interosseous space, a small branch, which inosculates with the interosseous branches of the metatarsal artery. These are the *anterior perforating branches*.

From the arrangement already described of the distribution of the vessels to the toes, it will be seen that both sides of the three outer toes, and the outer side of the second toe, are supplied by branches from the plantar arch ; both sides of the great toe, and the inner side of the second, are supplied by the communicating branch of the dorsalis pedis.

## OF THE VEINS

**T**HE Veins are the vessels which serve to return the blood from the capillaries of the different parts of the body to the heart. They consist of two distinct sets of vessels, the *pulmonary* and *systemic*.

The **Pulmonary Veins** are concerned in the circulation in the lungs. Unlike other vessels of this kind, they contain arterial blood, which they return from the lungs to the left auricle of the heart.

The **Systemic Veins** are concerned in the general circulation; they return the venous blood from the body generally to the right auricle of the heart.

The **Portal Vein**, an appendage to the systemic venous system, is confined to the abdominal cavity, returning the venous blood from the viscera of digestion, and carrying it to the liver by a single trunk of large size, the *vena portæ*. This vessel ramifies in the substance of the liver and breaks up into a minute network of capillaries. These capillaries then re-collect to form the hepatic veins, by which the blood is conveyed to the inferior vena cava.

The veins, like the arteries, are found in nearly every tissue of the body. They commence by minute plexuses which receive the blood from the capillaries. The branches which have their commencement in these plexuses unite together into trunks, and these, in their passage towards the heart, constantly increase in size as they receive tributaries, or join other veins. The veins are larger and altogether more numerous than the arteries; hence, the entire capacity of the venous system is much greater than that of the arterial; the pulmonary veins excepted, which only slightly exceed in capacity the pulmonary arteries. From the combined area of the smaller venous branches being greater than the main trunks, it results that the venous system represents a cone, the summit of which corresponds to the heart, its base to the circumference of the body. In form, the veins are perfectly cylindrical like the arteries, their walls being collapsed when empty, and the uniformity of their surface being interrupted at intervals by slight constrictions, which indicate the existence of valves in their interior. They usually retain, however, the same calibre as long as they receive no branches.

The veins communicate very freely with one another, especially in certain regions of the body; and this communication exists between the larger trunks as well as between the smaller branches. Thus, in the cavity of the cranium, and between the veins of the neck, where obstruction would be attended with imminent danger to the cerebral venous system, we find that the sinuses and larger veins have large and very frequent anastomoses. The same free communication exists between the veins throughout the whole extent of the spinal canal, and between the veins composing the various venous plexuses in the abdomen and pelvis, as the spermatic, uterine, vesical, and prostatic.

The systemic veins are subdivided into three sets: superficial, deep, and sinuses.

The **Superficial or Cutaneous Veins** are found between the layers of the superficial fascia, immediately beneath the integument; they return the blood from these structures, and communicate with the deep veins by perforating the deep fascia.



The **Deep Veins** accompany the arteries, and are usually enclosed in the same sheath with those vessels. With the smaller arteries—as the radial, ulnar, brachial, tibial, peroneal—they exist generally in pairs, one lying on each side of the vessel, and are called *venæ comites*. The larger arteries—as the axillary, subclavian, popliteal, and femoral—have usually only one accompanying vein. In certain organs of the body, however, the deep veins do not accompany the arteries; for instance, the veins in the skull and spinal canal, the hepatic veins in the liver, and the larger veins returning blood from the osseous tissue.

**Sinuses** are venous channels, which, in their structure and mode of distribution, differ altogether from the veins. They are found only in the interior of the skull, and are formed by a separation of the layers of the dura mater; their outer coat consisting of fibrous tissue, their inner of an endothelial layer continuous with the lining membrane of the veins.

Veins have thinner walls than arteries, the difference in thickness being due to the small amount of elastic and muscular tissues which the veins contain. The superficial veins usually have thicker coats than the deep veins, and the veins of the lower limb are thicker than those of the upper.

The minute structure of these vessels has been described in the section on General Anatomy

### THE PULMONARY VEINS

The *Pulmonary Veins* return the arterial blood from the lungs to the left auricle of the heart. They are four in number, two for each lung. The pulmonary differ from other veins in several respects:—1. They carry arterial instead of venous blood. 2. They are destitute of valves. 3. They are only slightly larger than the arteries they accompany. 4. They accompany those vessels singly. They commence in a capillary network, upon the walls of the air-cells, where they are continuous with the ramifications of the pulmonary artery, and, uniting together, form a single trunk for each lobule. These branches, uniting successively, form a single trunk for each lobe, three for the right, and two for the left lung. The vein from the middle lobe of the right lung unites with that from the upper lobe, in most cases, forming two trunks on each side, which open separately into the left auricle. Occasionally, they remain separate; there are then three veins on the right side. Not unfrequently, the two left pulmonary veins terminate by a common opening.

*Within the lung*, the branches of the pulmonary artery are *in front*, the veins *behind*, and the bronchi *between* the two.

*At the root of the lung*, the veins are *in front*, the artery *in the middle*, and the bronchus *behind*.

*Within the pericardium*, their anterior surface is invested by the serous layer of this membrane. The right pulmonary veins pass behind the right auricle and ascending aorta; the left pass in front of the thoracic aorta, with the left pulmonary artery.

### THE SYSTEMIC VEINS

The systemic veins may be arranged into three groups:—1. Those of the head and neck, upper extremity, and thorax, which terminate in the superior vena cava. 2. Those of the lower limb, pelvis, and abdomen, which terminate in the inferior vena cava. 3. The cardiac veins, which open directly into the right auricle of the heart.

### VEINS OF THE HEAD AND NECK

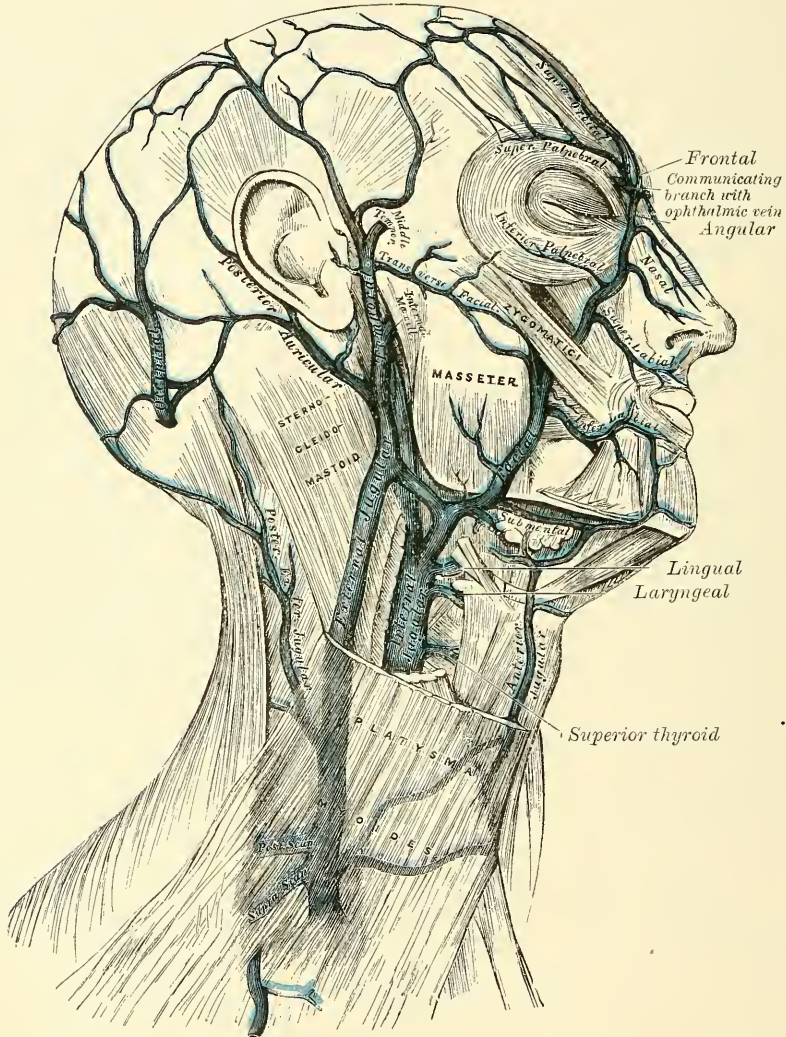
The veins of the head and neck [may be subdivided into three groups:—  
1. The veins of the exterior of the head and face. 2. The veins of the neck.  
3. The veins of the diploë and the interior of the cranium.

The veins of the exterior of the head and face are, the

Frontal.	Temporal.
Supra-orbital.	Internal Maxillary.
Angular.	Temporo-maxillary.
Facial.	Posterior Auricular.
	Occipital.

The **frontal vein** commences on the anterior part of the skull by a venous plexus which communicates with the anterior tributaries of the temporal vein.

FIG. 424.—Veins of the head and neck.



The veins converge to form a single trunk, which runs downwards near the middle line of the forehead parallel with the vein of the opposite side, and unites with it at the root of the nose, by a transverse branch, called the *nasal arch*. Occasionally the frontal veins join to form a single trunk, which bifurcates at the root of the nose into the two angular veins. At the root of the nose the veins diverge, and join the *supra-orbital vein*, at the inner angle of the orbit, to form the *angular vein*.

The **supra-orbital vein** commences on the forehead, communicating with the anterior temporal vein, and runs downwards and inwards, superficial to the



Occipito-frontalis muscle, receiving tributaries from the neighbouring structures, and joins the frontal vein at the inner angle of the orbit to form the *angular vein*.

The **angular vein** formed by the junction of the frontal and supra-orbital veins runs obliquely downwards and outwards, on the side of the root of the nose, and receives the veins of the ala nasi on its inner side, and the superior palpebral veins on its outer side; it moreover communicates with the ophthalmic vein, thus establishing an important anastomosis between this vessel and the cavernous sinus. Some small veins from the dorsum of the nose terminate in the nasal arch.

The **facial vein** commences at the side of the root of the nose, being a direct continuation of the angular vein. It passes obliquely downwards and outwards, beneath the Zygomaticus major and minor muscles, descends along the anterior border of the Masseter, crosses over the body of the lower jaw, with the facial artery, and, passing obliquely outwards and backwards, beneath the Platysma and cervical fascia, unites with a branch of communication from the temporo-maxillary vein, to form a trunk of large size (*common facial vein*) which enters the internal jugular. From near its termination a communicating branch often runs down the anterior border of the Sterno-mastoid to join the lower part of the anterior jugular.

*Tributaries.*—The facial vein receives, near the angle of the mouth, communicating tributaries of considerable size (the *deep facial* or *anterior internal maxillary vein*) from the pterygoid plexus. It is also joined by the inferior palpebral, the superior and inferior labial veins, the buccal veins from the cheek, and the masseteric veins. Below the jaw it receives the submental, the inferior palatine, which returns the blood from the plexus around the tonsil and soft palate; the submaxillary vein, which commences in the submaxillary gland; and, generally, the ranine vein.

*Surgical Anatomy.*—There are some points about the facial vein which render it of great importance in surgery. It is not so flaccid as are most superficial veins, and, in consequence of this, remains more patent when divided. It has, moreover, no valves. It communicates freely with the intracranial circulation, not only at its commencement by its tributaries, the angular and supra-orbital veins, communicating with the ophthalmic vein, a tributary of the cavernous sinus; but also by its deep branch, which communicates through the pterygoid plexus with the cavernous sinus by branches which pass through the foramen ovale and foramen lacerum medium (see page 678). These facts have an important bearing upon the surgery of some diseases of the face. For on account of its patency the facial vein favours septic absorption, and therefore any phlegmonous inflammation of the face following a poisoned wound is liable to set up thrombosis in the facial vein, and detached portions of the clot may give rise to purulent foci in other parts of the body. And on account of its communications with the cerebral sinuses, these thrombi are apt to extend upwards into them, and so induce a fatal issue.

The **Temporal Vein** commences by a minute plexus on the side and vertex of the skull, which communicates with the frontal and supra-orbital veins in front, the corresponding vein of the opposite side, and the posterior auricular and occipital veins behind. From this network, anterior and posterior branches are formed which unite above the zygoma, forming the trunk of the vein. This trunk is joined in this situation by a large vein, the *middle temporal*, which receives the blood from the substance of the Temporal muscle and pierces the fascia at the upper border of the zygoma. The temporal vein then descends between the external auditory meatus and the condyle of the jaw, enters the substance of the parotid gland, and unites with the internal maxillary vein to form the temporo-maxillary vein.

*Tributaries.*—The temporal vein receives in its course some parotid veins, an articular branch from the articulation of the jaw, anterior auricular veins from the external ear, and a vein of large size, the *transverse facial*, from the side of the face. The middle temporal vein, previous to its junction with the temporal vein, receives a branch, the *orbital vein*, which is formed by some external



palpebral branches, and passes backwards between the layers of the temporal fascia.

The **Internal Maxillary Vein** is a vessel of considerable size, receiving branches which correspond with those of the internal maxillary artery. Thus it receives the middle meningeal veins, the deep temporal, the pterygoid, masseteric, buccal, alveolar, some palatine veins, and the inferior dental. These branches form a large plexus, the *pterygoid*, which is placed between the Temporal and External pterygoid, and partly between the Pterygoid muscles. This plexus communicates very freely with the facial vein, and with the cavernous sinus, by branches through the foramen Vesalii at the base of the skull. The trunk of the vein then passes backwards, behind the neck of the lower jaw, and unites with the temporal vein, forming the temporo-maxillary vein.

The **Temporo-maxillary Vein**, formed by the union of the temporal and internal maxillary veins, descends in the substance of the parotid gland on the outer surface of the external carotid artery, between the ramus of the jaw and the Sterno-mastoid muscle, and divides into two branches, one of which passes inwards to join the facial vein; the other is joined by the posterior auricular vein and becomes the external jugular.

The **Posterior Auricular Vein** commences upon the side of the head, by a plexus which communicates with the tributaries of the temporal and occipital veins. The vein descends behind the external ear and joins the temporo-maxillary vein, forming the external jugular. This vessel receives the stylo-mastoid vein, and some tributaries from the back part of the external ear.

The **Occipital Veins** commence at the back part of the vertex of the skull, by a plexus, in a similar manner to the other veins. These unite and form one or two veins, which follow the course of the occipital artery, passing deeply beneath the muscles of the back part of the neck, and terminate in the internal jugular, occasionally in the external jugular vein. As these veins pass across the mastoid portion of the temporal bone, one of them receives the mastoid vein, which thus establishes a communication with the lateral sinus.

#### VEINS OF THE NECK

The veins of the neck, which return the blood from the head and face, are the

External Jugular.	Anterior Jugular.
Posterior External Jugular.	Internal Jugular.
	Vertebral.

The **External Jugular Vein** receives the greater part of the blood from the exterior of the cranium and deep parts of the face, being formed by the junction of the posterior division of the temporo-maxillary and posterior auricular veins. It commences in the substance of the parotid gland, on a level with the angle of the lower jaw, and runs perpendicularly down the neck, in the direction of a line drawn from the angle of the jaw to the middle of the clavicle. In its course it crosses the Sterno-mastoid muscle, and runs parallel with its posterior border as far as its attachment to the clavicle, where it perforates the deep fascia, and terminates in the subclavian vein, on the outer side of or in front of the Scalenus anticus muscle. In the neck it is separated from the Sterno-mastoid by the anterior layer of the deep cervical fascia, and is covered by the Platysma, the superficial fascia, and the integument. This vein is crossed about its middle by the superficialis colli nerve, and its upper half is accompanied by the auricularis magnus nerve. The external jugular vein varies in size, bearing an inverse proportion to that of the other veins of the neck; it is occasionally double. It is provided with two pairs of valves, the lower pair being placed at its entrance into the subclavian vein, the upper pair in most cases about an inch and a half above the clavicle. The portion of vein between the two sets of valves is often

dilated, and is termed the *sinus*. These valves do not prevent the regurgitation of the blood, or the passage of injection from below upwards.\*

*Surgical Anatomy.*—Venesection used formerly to be performed on the external jugular vein, but is now probably never resorted to. The anatomical point to be remembered in performing this operation is to cut across the fibres of the *Platysma myoides* in opening the vein, so that by their contraction they will expose the orifice in the vein and so allow the flow of blood.

*Tributaries.*—This vein receives the occipital occasionally, the posterior external jugular, and, near its termination, the suprascapular and transverse cervical veins. It communicates with the anterior jugular, and, in the substance of the parotid, receives a large branch of communication from the internal jugular.

The **Posterior External Jugular Vein** commences in the occipital region and returns the blood from the integument and superficial muscles in the upper and back part of the neck, lying between the *Splenius* and *Trapezius* muscles. It runs down the back part of the neck, and opens into the external jugular just below the middle of its course.

The **Anterior Jugular Vein** commences near the hyoid bone from the convergence of several superficial veins from the submaxillary region. It passes down between the median line and the anterior border of the *Sterno-mastoid* and, at the lower part of the neck, passes beneath that muscle to open into the termination of the external jugular, or into the subclavian vein (fig. 431). This vein varies considerably in size, bearing almost always an inverse proportion to the external jugular. Most frequently there are two anterior jugulars, a right and left; but occasionally only one. This vein receives some laryngeal veins, and occasionally a small thyroid vein. Just above the sternum, the two anterior jugular veins communicate by a transverse trunk, which receives tributaries from the inferior thyroid veins. It also communicates with the internal jugular. There are no valves in this vein.

The **Internal Jugular Vein** collects the blood from the interior of the cranium, from the superficial parts of the face, and from the neck. It commences just external to the jugular foramen, at the base of the skull, being formed by the coalescence of the lateral and inferior petrosal sinuses (fig. 429). At its origin it is somewhat dilated, and this dilatation is called the *sinus*, or *gulf*, of the internal jugular vein. It runs down the side of the neck in a vertical direction, lying at first on the outer side of the internal carotid, and then on the outer side of the common carotid, and at the root of the neck unites with the subclavian vein to form the innominate vein. The internal jugular vein, at its commencement, lies upon the *Rectus capitis lateralis*, and behind the internal carotid and the nerves passing through the jugular foramen; lower down, the vein and artery lie upon the same plane, the *glosso-pharyngeal* and *hypoglossal* nerves passing forwards between them; the *pneumogastric* descends between and behind them in the same sheath, and the *spinal accessory* passes obliquely outwards, behind the vein. At the root of the neck the vein of the right side is placed at a little distance from the artery; on the left side, it usually lies over the artery at its lower part. The right internal jugular vein crosses the first part of the subclavian artery. The vein is of considerable size, but varies in different individuals, the left one being usually the smaller. It is provided with a pair of valves, which are placed at its point of termination, or from half to three-quarters of an inch above it.

*Tributaries.*—This vein receives in its course the facial, lingual, pharyngeal, superior and middle thyroid veins, and sometimes the occipital. At its point of junction with the common facial vein it becomes greatly increased in size.

\* The student may refer to an interesting paper by Dr. Struthers, 'On Jugular Venesection in Asphyxia, anatomically and experimentally considered, including the Demonstration of Valves in the Veins of the Neck,' in the *Edinburgh Medical Journal* for November 1856.



The **lingual veins** commence on the dorsum, sides, and under surface of the tongue, and, passing backwards, following the course of the lingual artery and its branches, terminate in the internal jugular. Sometimes the ranine vein, which is a branch of considerable size, commencing below the tip of the tongue, joins the lingual. Generally, however, it passes backwards, crosses the Hyo-glossus muscle in company with the hypoglossal nerve, and joins the facial.

The **pharyngeal vein** commences in a minute plexus, the *pharyngeal*, at the back part and sides of the pharynx, and, after receiving meningeal tributaries, and the Vidian and sphenopalatine veins, terminates in the internal jugular. It occasionally opens into the facial, lingual, or superior thyroid vein.

The **superior thyroid vein** commences in the substance and on the surface of the thyroid gland, by tributaries corresponding with the branches of the superior thyroid artery, and terminates in the upper part of the internal jugular vein.

The **middle thyroid vein** collects the blood from the lower part of the lateral lobe of the thyroid gland, and, being joined by some veins from the larynx and trachea, terminates in the lower part of the internal jugular vein.

The **facial and occipital veins** have been described above.

*Surgical Anatomy.*—The internal jugular vein occasionally requires ligature in cases of septic thrombosis of the lateral sinus from suppuration in the middle ear, in order to prevent septic emboli being carried into the general circulation. This operation has been performed recently in several cases, with the most satisfactory results. The cases are generally those of chronic disease of the middle ear, with discharge of pus which perhaps has existed for many years. The patient is seized with acute septic inflammation, spreading to the mastoid cells, and consequent on this, septic thrombosis of the lateral sinus extending to the internal jugular vein. Such cases are always extremely grave, for there is a danger of a portion of the septic clot being detached and causing septic embolism in the thoracic viscera. This may be mechanically prevented by ligature of the internal jugular vein in the middle of the neck. The operation is a comparatively simple one, and may be performed by an incision similar to that employed in ligature of the common carotid artery.

The **Vertebral Vein** commences in the occipital region, by numerous small tributaries, from the deep muscles at the upper and back part of the neck; these pass outwards and enter the foramen in the transverse process of the atlas, and descend, forming a dense plexus around the vertebral artery, in the canal formed by the transverse processes of the cervical vertebræ. This plexus unites at the lower part of the neck into two main trunks, one of which emerges from the foramen in the transverse process of the sixth cervical vertebra, and the other through that of the seventh, and, uniting, form a single vessel, which terminates at the root of the neck in the back part of the innominate vein near its origin, its mouth being guarded by a pair of valves. On the right side, it crosses the first part of the subclavian artery.

*Tributaries.*—The vertebral vein receives in its course a vein from the inside of the skull through the posterior condyloid foramen; muscular veins, from the muscles in the prevertebral region; dorsi-spinal veins, from the back part of the cervical portion of the spine; meningo-rachidian veins, from the interior of the spinal canal; the anterior and posterior vertebral veins; and close to its termination it is joined by a small vein from the first intercostal space which accompanies the superior intercostal artery.

The **anterior vertebral vein** commences in a plexus around the transverse processes of the upper cervical vertebræ, descends in company with the ascending cervical artery between the Scalenus anticus and Rectus capitis anticus major muscles, and opens into the vertebral vein just before its termination.

The **posterior vertebral vein** (the **deep cervical**) accompanies the profunda cervicis artery, lying between the Complexus and Semispinalis colli. It commences in the suboccipital region by communicating branches from the occipital vein and tributaries from the deep muscles at the back of the neck. It receives



tributaries from the plexuses around the spinous processes of the cervical vertebræ, and terminates in the lower end of the vertebral vein.

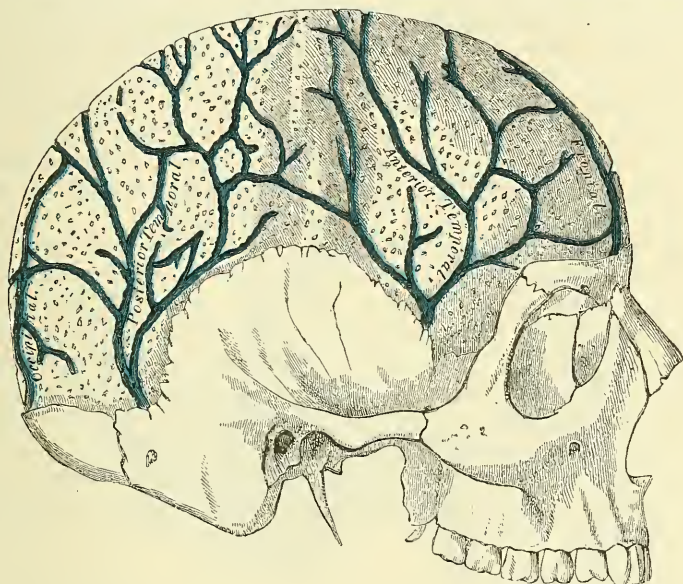
### VEINS OF THE DIPLOË

The diploë of the cranial bones is channelled in the adult by a number of tortuous canals, which are lined by a more or less complete layer of compact tissue.

The veins they contain are large and capacious, their walls being thin, and formed only of endothelium resting upon a layer of elastic tissue, and they present, at irregular intervals, pouch-like dilatations, or *culs-de-sac*, which serve as reservoirs for the blood. These are the veins of the diploë; they can only be displayed by removing the outer table of the skull.

In adult life, as long as the cranial bones are distinct and separable, these veins are confined to the particular bones; but in old age, when the sutures are

FIG. 425.—Veins of the diploë as displayed by the removal of the outer table of the skull.



united, they communicate with each other, and increase in size. These vessels communicate, in the interior of the cranium, with the meningeal veins, and with the sinuses of the dura mater; and, on the exterior of the skull, with the veins of the pericranium. They are divided into the *frontal*, which opens, into the supra-orbital vein, by an aperture in the supra-orbital notch; the *anterior temporal*, which is confined chiefly to the frontal bone, and opens into one of the deep temporal veins, after escaping by an aperture in the great wing of the sphenoid; the *posterior temporal*, which is confined to the parietal bone, and terminates in the lateral sinus by an aperture at the posterior inferior angle of the parietal bone; and the *occipital*, the largest of the four, which is confined to the occipital bone, and opens either into the occipital vein, or internally into the lateral sinus or torcular Herophili.

### CEREBRAL VEINS

The **Cerebral Veins** are remarkable for the extreme thinness of their coats in consequence of the muscular tissue in them being wanting, and for the absence of valves. They may be divided into two sets: the superficial which are placed on the surface, and the deep veins which occupy the interior of the organ.

The **Superficial Cerebral Veins** ramify upon the surface of the brain, being lodged in the sulci, between the convolutions, a few running across the convolutions. They receive branches from the substance of the brain, and terminate in the sinuses. They are named, from the position they occupy, superior, median, and inferior cerebral veins.

The **Superior Cerebral Veins**, eight to twelve in number on each side, return the blood from the convolutions on the superior surface of the hemisphere; they pass forwards and inwards towards the great longitudinal fissure, where they receive the *median cerebral veins*; near their termination, they become invested with a tubular sheath of the arachnoid membrane, and open into the superior longitudinal sinus, in the opposite direction to the course of the current of the blood.

The **Median Cerebral Veins** return the blood from the convolutions of the mesial surface of the corresponding hemisphere; they open into the superior cerebral veins; or occasionally into the inferior longitudinal sinus.

The **Inferior Cerebral Veins** ramify on the lower part of the outer and on the under surface of the cerebral hemisphere. Some, collecting tributaries from the under surface of the anterior lobes of the brain, terminate in the cavernous sinus. One vein of large size, the *middle cerebral vein*, commences on the under surface of the temporo-sphenoidal lobe, and, running along the fissure of Sylvius, opens into the cavernous sinus. Another large vein, the *great anastomotic vein of Trolard*, commences on the parietal lobe, runs along the horizontal limb of the fissure of Sylvius, and opens into the anterior part of the cavernous sinus under the lesser wing of the sphenoid. Others commence on the under surface of the base of the brain, and unite to form from three to five veins, which open into the superior petrosal and lateral sinuses from before backwards.

The **Deep Cerebral, or Ventricular Veins** (*venæ Galeni*), are two in number. They are formed by the union of two veins, the *vena corporis striati*, and the *choroid vein*, on either side. They run backwards, parallel with one another, between the layers of the velum interpositum, and pass out of the brain at the great transverse fissure, between the posterior extremity, or *splenium*, of the corpus callosum and the tubercula quadrigemina, to enter the straight sinus. The two veins usually unite to form one before opening into the straight sinus. Just before their union they receive the basilar vein.

The *vena corporis striati* commences in the groove between the corpus striatum and thalamus opticus, receives numerous veins from both of these parts, and unites behind the anterior pillar of the fornix with the choroid vein, to form one of the *venæ Galeni*.

The **choroid vein** runs along the whole length of the outer border of the choroid plexus, receiving veins from the hippocampus major, the fornix and corpus callosum, and unites, at the anterior extremity of the choroid plexus, with the vein of the corpus striatum.

The **Basilar Vein** commences at the anterior perforated space at the base of the brain by the union of a small anterior cerebral vein, which courses backwards between the anterior lobes of the cerebrum, with the deep Sylvian vein, which descends through the lower part of the Sylvian fissure. It passes backwards round the crus cerebri, receiving the inferior striate vein from the corpus striatum, interpeduncular veins from the interpeduncular space, ventricular veins from the middle cornu of the lateral ventricles, and tributaries from the uncinate convolution, and enters the vein of Galen just before its junction with the vein of the opposite side.

The **Cerebellar Veins** occupy the surface of the cerebellum, and are disposed in three sets, superior, inferior, and lateral. The *superior* pass forwards and inwards, across the superior vermiform process, and terminate in the straight sinus; some open into the *venæ Galeni*. The *inferior cerebellar veins*, of large size, run transversely outwards, and terminate by two or three trunks in the lateral sinuses. The *lateral anterior cerebellar veins* terminate in the superior petrosal sinuses.



The perivascular lymphatics alluded to above (see page 58) are especially found in connection with the vessels of the brain. These vessels are enclosed in a sheath, which acts as a lymphatic channel, through which the lymph is carried to the subarachnoid and subdural spaces, from which it is returned into the general circulation.

## SINUSES OF THE DURA MATER

The sinuses of the dura mater are venous channels, analogous to the veins, their outer coat being formed by the dura mater; their inner, by a continuation of the lining membrane of the veins. They are fourteen in number, and are divided into two sets: 1. Those situated at the upper and back part of the skull: 2. those at the base of the skull. The former are, the

Superior Longitudinal Sinus.

Straight Sinus.

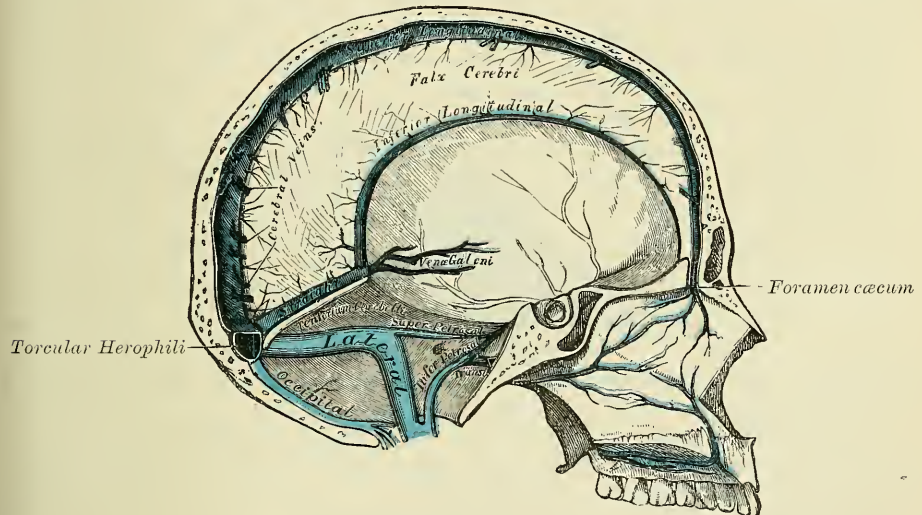
Inferior Longitudinal Sinus.

Lateral Sinuses.

Occipital Sinus.

The **Superior Longitudinal Sinus** occupies the attached margin of the falx cerebri. Commencing at the foramen cæcum, through which it constantly communicates by a small branch with the veins of the nasal fossæ, it runs from before

FIG. 426.—Vertical section of the skull, showing the sinuses of the dura mater.



backwards, grooving the inner surface of the frontal, the adjacent margins of the two parietal, and the superior division of the crucial ridge of the occipital bone, and terminates by opening into the torcular Herophili. The sinus is triangular in form, narrow in front, and gradually increasing in size as it passes backwards. On examining its inner surface, it presents the internal openings of the superior cerebral veins, which run, for the most part, from behind forwards, and open chiefly at the back part of the sinus, their orifices being concealed by fibrous folds; numerous fibrous bands (*chordæ Willisii*) are also seen, extending transversely across the inferior angle of the sinus; and, lastly, some small, white, projecting bodies, the *glandula Pacchioni*. This sinus receives the superior cerebral veins, numerous veins from the diploë and dura mater, and, at the posterior extremity of the sagittal suture, veins from the pericranium, which pass through the parietal foramen.

The *torcular Herophili* is the dilated extremity of the superior longitudinal sinus. It is of irregular form, and is lodged on one side (generally the right) of the internal occipital protuberance. From it the lateral sinus of the side to



which it is deflected is derived. It receives also the blood from the occipital sinus.

The **Inferior Longitudinal Sinus**, more correctly described as the *inferior longitudinal vein*, is contained in the posterior part of the free margin of the falx cerebri. It is of a cylindrical form, increases in size as it passes backwards, and terminates in the straight sinus. It receives several veins from the falx cerebri, and occasionally a few from the mesial surface of the hemispheres.

The **Straight Sinus** is situated at the line of junction of the falx cerebri with the tentorium. It is triangular in form, increases in size as it proceeds backwards, and runs obliquely downwards and backwards from the termination of the inferior longitudinal sinus to the lateral sinus of the opposite side to that into which the superior longitudinal sinus is prolonged. It communicates by a cross branch with the torcular Herophili. Beside the inferior longitudinal sinus, it receives the venæ Galeni and the superior cerebellar veins. A few transverse bands cross its interior.

The **Lateral Sinuses** are of large size, and are situated in the attached margin of the tentorium cerebelli. They commence at the internal occipital protuberance; the one, generally the right, being the direct continuation of the superior longitudinal sinus, the other of the straight sinus. They pass outwards and forwards, describing a slight curve with its convexity upwards, to the base of the petrous portion of the temporal bone, then curve downwards and inwards on each side to reach the jugular foramen, where they terminate in the internal jugular vein. Each sinus rests, in its course, upon the inner surface of the occipital, the posterior inferior angle of the parietal, the mastoid portion of the temporal, and on the occipital, again, just before its termination. These sinuses are frequently of unequal size, that formed by the superior longitudinal sinus being the larger, and they increase in size as they proceed from behind forwards. The horizontal portion is of a triangular form, the curved portion semicylindrical. Their inner surface is smooth, and not crossed by the fibrous bands found in the other sinuses. These sinuses receive the blood from the superior petrosal sinuses at the base of the petrous portion of the temporal bone, and they unite with the inferior petrosal sinus, just external to the jugular foramen, to form the internal jugular vein (fig. 429). They communicate with the veins of the pericranium by means of the mastoid and posterior condyloid veins, and they receive some of the inferior cerebral and inferior cerebellar veins, and some veins from the diploë.

The **Occipital** is the smallest of the cranial sinuses. It is generally single, but occasionally there are two. It is situated in the attached margin of the falx cerebelli. It commences by several small veins around the margin of the foramen magnum, one of which joins the termination of the lateral sinus; it communicates with the posterior spinal veins, and terminates in the torcular Herophili.

The sinuses at the base of the skull are, the

Cavernous Sinuses.	Superior Petrosal Sinuses.
Circular Sinus.	Inferior Petrosal Sinuses.
Transverse Sinus.	

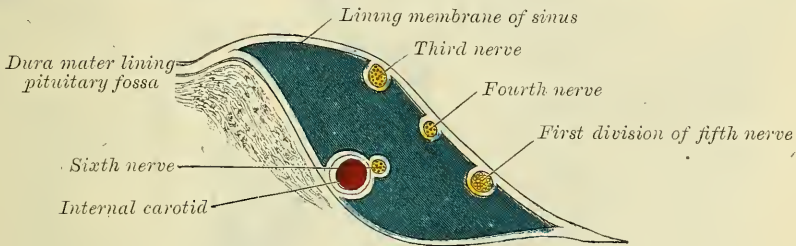
The **Cavernous Sinuses** are named from their presenting a reticulated structure, due to their being traversed by numerous interlacing filaments. They are two in number, of irregular form, larger behind than in front, and are placed one on each side of the sella turcica, extending from the sphenoidal fissure to the apex of the petrous portion of the temporal bone; they receive anteriorly the ophthalmic vein through the sphenoidal fissure, and open behind into the petrosal sinuses. On the inner wall of each sinus is found the internal carotid artery, accompanied by filaments of the carotid plexus and by the sixth nerve; and on its outer wall, the third, fourth, and ophthalmic division of the fifth nerve. These parts are separated from the blood flowing along the sinus by the lining membrane, which

is continuous with the inner coat of the veins. The cavernous sinuses receive some of the cerebral veins; they communicate with the lateral sinuses by means of the superior and inferior petrosal sinuses, and with the facial vein through the ophthalmic vein. They also communicate with each other by means of the circular sinus.

*Surgical Anatomy.*—An arterio-venous communication may be established between the cavernous sinus and the carotid artery, as it lies in it, giving rise to a pulsating tumour in the orbit. These communications may be the result of injury, such as a bullet wound, a stab, or a blow or fall sufficiently severe to cause a fracture of the base of the skull in this situation; or they may occur idiopathically, from the rupture of an aneurism or a diseased condition of the internal carotid artery. The disease begins with sudden noise and pain in the head, followed by exophthalmos, and development of a pulsating tumour at the margin of the orbit, with thrill and the characteristic bruit. In some cases the opposite orbit becomes affected by the passage of the arterial blood into the opposite sinus by means of the circular sinus. Or the arterial blood may find its way through the emissary veins (see page 678) into the pterygoid plexus, and thence into the veins of the face. Pulsating tumours of the orbit may also be due to traumatic aneurism of one of the orbital arteries, and symptoms resembling those of pulsating tumour may be produced by pressure on the ophthalmic vein, as it enters the sinus, by an aneurism of the internal carotid artery.

The **ophthalmic** is a large vein, which connects the angular vein at the inner angle of the orbit with the cavernous sinus; it pursues the same course as the ophthalmic artery, and receives tributaries corresponding to the branches derived

FIG. 427.—Plan showing the relative position of the structures in the right cavernous sinus, viewed from behind.



from that vessel. Forming a short single trunk, it passes through the inner extremity of the sphenoidal fissure, and terminates in the cavernous sinus.

*The Inferior Ophthalmic Vein.*—Sometimes the veins from the floor of the orbit collect into a separate trunk, the *inferior ophthalmic vein*, which either passes out of the orbit through the sphenomaxillary fissure to join the pterygoid plexus of veins; or else, passing backwards through the sphenoidal fissure, it enters the cavernous sinus, either by a separate opening, or in common with the ophthalmic vein.

The **Circular Sinus** is formed by two transverse vessels, which connect together the two cavernous sinuses; the one passing in front and the other behind the pituitary body, and thus forming with the cavernous sinuses a venous circle around that body. The anterior one is usually the larger of the two, and one or other is occasionally found to be absent.

The **Superior Petrosal Sinus** is situated along the superior border of the petrous portion of the temporal bone, in the front part of the attached margin of the tentorium. It is small and narrow, and connects together the cavernous and lateral sinuses at each side. It receives a cerebellar vein (*anterior lateral cerebellar*) from the anterior border of the cerebellum, and a vein from the internal ear.

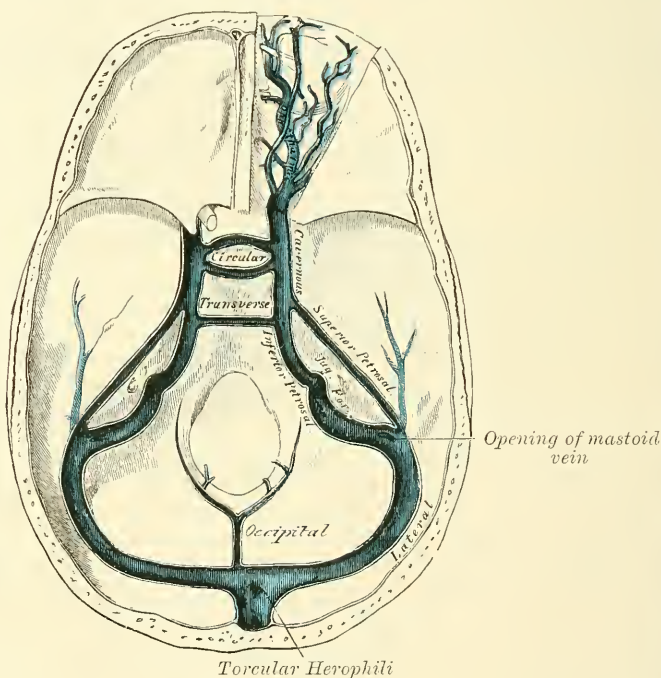
The **Inferior Petrosal Sinus** is situated in the groove formed by the junction of the posterior border of the petrous portion of the temporal with the basilar process of the occipital. It commences in front at the termination of the cavernous sinus, and behind joins the lateral sinus after it has passed through

the jugular foramen; the junction of these two sinuses forming the commencement of the internal jugular vein.

The junction of the two sinuses takes place at the lower border of, or just external to, the jugular foramen. The exact relation of the parts to one another in the foramen is as follows: the inferior petrosal sinus is in front, with the meningeal branch of the ascending pharyngeal artery, and is directed obliquely downwards and backwards; the lateral sinus is situated at the back part of the foramen with a meningeal branch of the occipital artery, and between the two are the glosso-pharyngeal, pneumogastric, and spinal accessory nerves. These three sets of structures are divided from each other by two processes of fibrous tissue. The junction of the sinuses takes place superficial to the nerves, so that these latter lie a little internal to the venous channels in the foramen (see fig. 429). These sinuses are semicylindrical in form.

The **Transverse Sinus**, or **basilar sinus**, consists of several interlacing veins between the layers of the dura mater over the basilar process of the occipital

FIG. 428.—The sinuses at the base of the skull.



bone, which serve to connect the two inferior petrosal sinuses. With them the anterior spinal veins communicate.

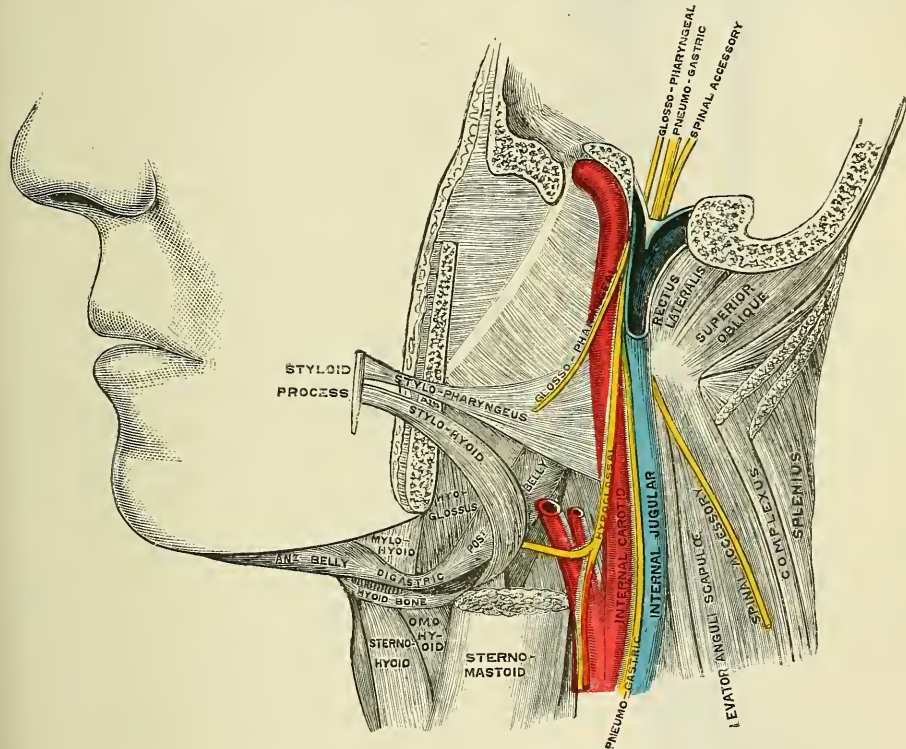
**Emissary Veins.**—The emissary veins are vessels which pass through apertures in the cranial wall and establish communications between the sinuses inside the skull and the veins external to it. Some of these are always present, others only occasionally so. They vary much in size in different individuals. The principal emissary veins are the following:—1. A vein, almost always present, which passes through the mastoid foramen and connects the lateral sinus with the posterior auricular or with an occipital vein. 2. A vein, which passes through the parietal foramen and connects the superior longitudinal sinus with the veins of the scalp. 3. A plexus of minute veins, which pass through the anterior condyloid foramen and connect the occipital sinus with the vertebral vein and deep veins of the neck. 4. An inconstant vein, which passes through the posterior condyloid foramen and connects the lateral sinus with the deep veins of the



neck. 5. One or two veins of considerable size, which pass through the foramen ovale and connect the cavernous sinus with the pterygoid and pharyngeal plexuses. 6. Two or three small veins, which pass through the foramen lacerum medium and connect the cavernous sinus with the pterygoid and pharyngeal plexuses. 7. There is sometimes a small vein passing through the foramen of Vesalius connecting the same parts. 8. A plexus of veins passing through the carotid canal and connecting the cavernous sinus with the internal jugular vein.

*Surgical Anatomy.*—These emissary veins are of great importance in surgery. In addition to them there are, however, other communications between the intra- and extra-cranial circulation. As, for instance, the communication of the angular and supra-orbital veins with the ophthalmic vein, at the inner angle of the orbit (page 669) and the communication of the veins of the scalp with the diploic veins (page 673). Through these communications inflammatory processes commencing on the outside of the skull may travel inwards, leading to osteo-phlebitis of the diploë and inflammation of the membranes of the brain. To this must be attributed one of the principal dangers of scalp wounds and other injuries of the scalp.

FIG. 429.—Relation of structures in jugular foramen.



By means of these emissary veins blood may be abstracted almost directly from the intra-cranial circulation. For instance, leeches applied behind the ear abstract blood almost directly from the lateral sinus, through the vein passing through the mastoid foramen. Again, epistaxis in children will frequently relieve severe headache, the blood which flows from the nose being derived from the longitudinal sinus by means of the vein which passes through the foramen cæcum, which is another communication between the intra-cranial and extra-cranial circulation which is constantly found in children.

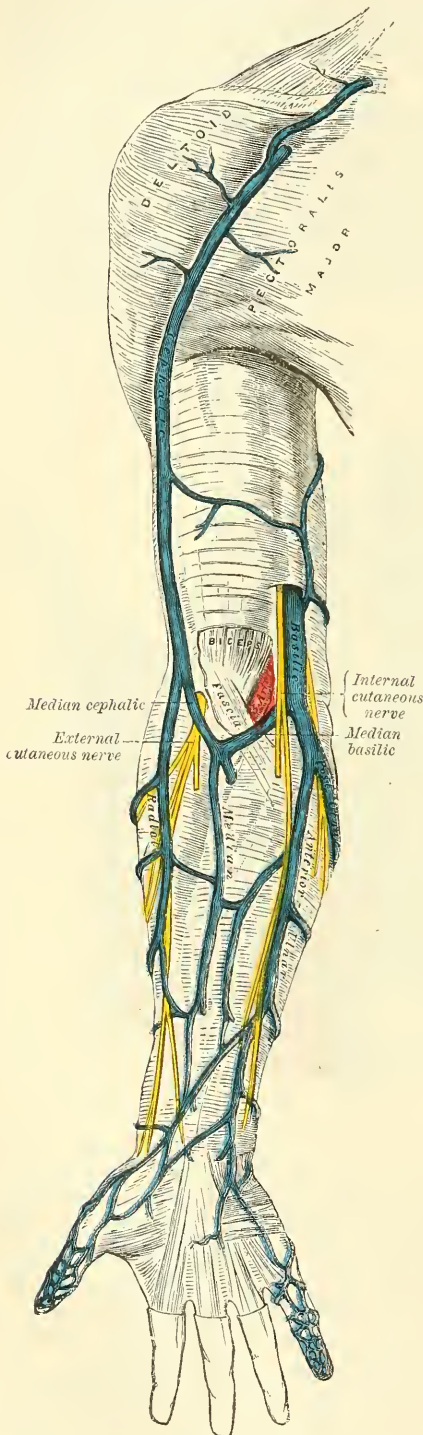
## VEINS OF THE UPPER EXTREMITY AND THORAX

The Veins of the Upper Extremity are divided into two sets, *superficial* and *deep*.

The **Superficial Veins** are placed immediately beneath the integument between the two layers of superficial fascia.

The **Deep Veins** accompany the arteries, and constitute the *venæ comites* of those vessels.

FIG. 430.—The superficial veins of the upper extremity.



Both sets of vessels are provided with valves which are more numerous in the deep than in the superficial.

The superficial veins of the upper extremity are, the

**Superficial Veins of the Hand.**

- Anterior Ulnar.
- Posterior Ulnar.
- Common Ulnar.
- Radial.
- Median.
- Median Basilic.
- Median Cephalic.
- Basilic.
- Cephalic.

The **Superficial Veins of the Hand and Fingers** are principally situated on the dorsal surface, and form two plexuses, an inner and outer, on the back of the hand. The inner plexus is formed by the veins from the little finger (*vena salvatella*), the ring finger, and the ulnar side of the middle finger; from it the anterior and posterior ulnar veins are derived. The outer plexus is formed by veins from the thumb, the index finger, and radial side of the middle finger; from it the radial vein is derived. These two plexuses communicate on the back of the hand, forming the superficial arch of veins in this situation. The superficial veins from the palm of the hand form a plexus in front of the wrist, from which the median vein is derived.

The **Anterior Ulnar Vein** commences on the anterior surface of the ulnar side of the hand and wrist, and ascends along the anterior surface of the ulnar side of the forearm to the bend of the elbow, where it joins with the posterior ulnar vein to form the common ulnar. Occasionally it opens separately into the median basilic vein. It communicates with branches of the median vein in front, and with the posterior ulnar behind.

The **Posterior Ulnar Vein** commences on the posterior surface of the ulnar side of the wrist. It runs on the posterior surface of the ulnar side of the forearm, and just below the elbow unites with the anterior ulnar vein to form the common ulnar, or else joins the median

basilic to form the basilic. It communicates with the deep veins of the palm by a branch which emerges from beneath the *Abductor minimi digiti* muscle.



The **Common Ulnar** is a short trunk which is not constant. When it exists it is formed by the junction of the two preceding veins, and, passing upwards and outwards, joins the median basilic to form the basilic vein. When it does not exist, the anterior and posterior ulnar veins open separately into the median basilic vein.

The **Radial Vein** commences from the dorsal surface of the wrist, communicating with the deep veins of the palm by a branch which passes through the first interosseous space. It forms a large vessel, which ascends along the radial side of the forearm, and receives numerous veins from both its surfaces. At the bend of the elbow it unites with the median cephalic to form the cephalic vein.

The **Median Vein** ascends on the front of the forearm, and communicates with the anterior ulnar and radial veins. At the bend of the elbow it receives a branch of communication from the deep veins, and divides into two branches, the median cephalic and median basilic, which diverge from each other as they ascend.

The **Median Cephalic**, usually the smaller of the two, passes outwards in the groove between the Supinator longus and Biceps muscles, and joins with the radial to form the cephalic vein. The branches of the external cutaneous nerve pass beneath this vessel.

The **Median Basilic Vein** passes obliquely inwards, in the groove between the Biceps and Pronator radii teres, and joins the common ulnar to form the basilic. This vein passes in front of the brachial artery, from which it is separated by a fibrous expansion (the *bicipital fascia*) which is given off from the tendon of the Biceps to the fascia covering the Flexor muscles of the forearm. Filaments of the internal cutaneous nerve pass in front as well as behind this vessel.\*

*Venesection* is usually performed at the bend of the elbow, and as a matter of practice the largest vein in this situation is commonly selected. This is usually the median basilic, and there are anatomical advantages and disadvantages in selecting this vein. The advantages are, that in addition to its being the largest, and therefore yielding a greater supply of blood, it is the least movable and can be easily steadied on the bicipital fascia on which it rests. The disadvantages are, that it is in close relationship with the brachial artery, separated only by the bicipital fascia; and formerly, when venesection was frequently practised, arterio-venous aneurism was no uncommon result of this practice. Another disadvantage is, that the median basilic is crossed by some of the branches of the internal cutaneous nerve, and these may be divided in the operation, giving rise to 'traumatic neuralgia of extreme intensity' (Tillaux).

The **Basilic Vein** is of considerable size, formed by the coalescence of the common ulnar vein with the median basilic. It passes upwards along the inner side of the Biceps muscle, pierces the deep fascia a little below the middle of the arm, and, ascending in the course of the brachial artery, to the lower border of the tendons of the Latissimus dorsi and Teres major muscles, it is continued onwards as the axillary vein.

The **Cephalic Vein** courses along the outer border of the Biceps muscle, lying in the same groove with the upper external cutaneous branch of the musculospiral nerve, to the upper third of the arm; it then passes in the interval between the Pectoralis major and Deltoid muscles, lying in the same groove with the descending branch of the acromial-thoracic artery. It pierces the costo-coracoid membrane, and crossing the axillary artery, it terminates in the axillary vein just below the clavicle. This vein is occasionally connected with the external jugular or subclavian, by a branch which passes from it upwards in front of the clavicle.

The **Deep Veins of the Upper Extremity** follow the course of the arteries,

\* Cruveilhier says: 'Numerous varieties are observed in the disposition of the veins of the elbow; sometimes the common median vein is wanting; but in those cases, its two branches are furnished by the radial vein, and the cephalic is almost always in a rudimentary condition. In other cases, only two veins are found at the bend of the elbow, the radial and ulnar, which are continuous, without any demarcation, with the cephalic and basilic.'



forming their venæ comites. They are generally two in number, one lying on each side of the corresponding artery, and they are connected at intervals by short transverse branches.

There are two digital veins, accompanying each artery along the sides of the fingers: these, uniting at their base, pass along the interosseous spaces in the palm, and terminate in the two venæ comites which accompany the superficial palmar arch. Branches from these vessels on the radial side of the hand accompany the superficialis volæ, and on the ulnar side terminate in the deep ulnar veins. The deep ulnar veins, as they pass in front of the wrist, communicate with the interosseous and superficial veins, and, at the elbow, unite with the deep radial veins to form the venæ comites of the brachial artery.

The **Interosseous Veins** accompany the anterior and posterior interosseous arteries. The anterior interosseous veins commence in front of the wrist, where they communicate with the deep radial and ulnar veins; at the upper part of the forearm they receive the posterior interosseous veins, and terminate in the venæ comites of the ulnar artery.

The **Deep Palmar Veins** accompany the deep palmar arch, being formed by tributaries which accompany the ramifications of that vessel. They communicate with the deep ulnar veins at the inner side of the hand, and on the outer side terminate in the venæ comites of the radial artery. At the wrist, they receive a dorsal and a palmar tributary from the thumb, and unite with the deep radial veins. Accompanying the radial artery, these vessels terminate in the venæ comites of the brachial artery.

The **Brachial Veins** are placed one on each side of the brachial artery, receiving tributaries corresponding with the branches given off from that vessel: at the lower margin of the Subscapularis, they join the axillary vein.

These deep veins have numerous anastomoses, not only with each other, but also with the superficial veins.

The **Axillary Vein** is of large size, and is the continuation upwards of the basilic vein. It commences at the lower border of the tendons of the Teres major and Latissimus dorsi, increases in size as it ascends, by receiving tributaries corresponding with the branches of the axillary artery, and terminates immediately beneath the clavicle at the outer border of the first rib, where it becomes the subclavian vein. This vessel is covered in front by the Pectoral muscles and costo-coracoid membrane, and lies on the thoracic side of the axillary artery, which it partially overlaps. Near its termination it receives the cephalic vein. This vein is provided with a pair of valves, opposite the lower border of the Subscapularis muscle; valves are also found at the termination of the cephalic and subscapular veins.

*Surgical Anatomy.*—There are several points of surgical interest in connection with the axillary vein. Being more superficial, larger, and slightly overlapping the axillary artery, it is more liable to be wounded in the operation of extirpation of the axillary glands, especially as these glands, when diseased, are apt to become adherent to the vessel. When wounded, there is always a danger of air being drawn into its interior, and death resulting. This is due not only to the fact that it is near the thorax and therefore liable to be influenced by the respiratory movements, but also because it is adherent by its anterior surface to the costo-coracoid membrane, and therefore if wounded is likely to remain patulous and favour the chance of air being sucked in. This adhesion of the vein to the fascia prevents its collapsing, and therefore favours the furious bleeding which takes place in these cases.

To avoid wounding the axillary vein in the extirpation of cancerous glands from the axilla, no sharp cutting instruments should be used after the axillary cavity has been freely exposed, and care should be taken to use no undue force in isolating the glands. Should the vein be so embedded in the malignant deposit that the latter cannot be removed without taking away a part of the vein, this must be done, the vessel having been first ligatured above and below.

The **Subclavian Vein**, the continuation of the axillary, extends from the outer border of the first rib to the inner end of the clavicle, where it unites with the internal jugular to form the innominate vein. It is in relation, in front, with the clavicle and Subclavius muscle; behind, with the subclavian artery, from





cava. It lies superficial and external to the innominate artery; on its right side the pleura is interposed between it and the apex of the lung. This vein, at the angle of junction of the internal jugular with the subclavian, receives the right vertebral vein; and, lower down, the right internal mammary, right inferior thyroid, and sometimes the right superior intercostal veins.

The **Left Innominate Vein**, about two and a half inches in length, and larger than the right, passes from left to right across the upper and front part of the chest, at the same time inclining downwards, to unite with its fellow of the opposite side, forming the *superior vena cava*. It is in relation, in front, with the first piece of the sternum, from which it is separated by the Sterno-hyoid and Sterno-thyroid muscles, the thymus gland or its remains, and some loose areolar tissue. Behind, it lies across the roots of the three large arteries arising from the arch of the aorta. This vessel is joined by the left vertebral, left internal mammary, left inferior thyroid, and the left superior intercostal veins, and occasionally some thymic and pericardiac veins. There are no valves in the innominate veins.

*Peculiarities.*—Sometimes the innominate veins open separately into the right auricle; in such cases the right vein takes the ordinary course of the superior vena cava; but the left vein, after communicating by a small branch with the right one, passes in front of the root of the left lung, and, turning to the back of the heart, receives the cardiac veins, and terminates in the back of the right auricle. This occasional condition of the veins in the adult is a regular one in the fetus at an early period, and the two vessels are persistent in birds and some mammalia. The subsequent changes which take place in these vessels are the following: The communicating branch between the two trunks enlarges and forms the future left innominate vein; the remaining part of the left trunk is obliterated as far as the heart, where it remains pervious, and forms the coronary sinus: a remnant of the obliterated vessel is seen in adult life as a fibrous band passing along the back of the left auricle and in front of the root of the left lung, called by Mr. Marshall the *vestigial fold of the pericardium*.

The **internal mammary veins**, two in number to each artery, follow the course of that vessel, and receive branches corresponding with those derived from it. The two veins of each side unite into a single trunk, which terminates in the innominate vein.

The **inferior thyroid veins**, two, frequently three or four, in number, arise in the venous plexus on the thyroid body, communicating with the middle and superior thyroid veins. They form a plexus in front of the trachea, behind the Sterno-thyroid muscle. From this plexus, a left vein descends and joins the left innominate trunk, and a right vein passes obliquely downwards and outwards across the innominate artery to open into the right innominate vein, just at its junction with the superior vena cava. These veins receive œsophageal, tracheal, and inferior laryngeal veins, and are provided with valves at their termination in the innominate veins.

The **Superior Intercostal Veins** return the blood from the upper intercostal spaces.

The *right superior intercostal*, much smaller than the left, closely corresponds with the superior intercostal artery, receiving the blood from the first, or first and second intercostal spaces, and, passing downwards, terminates in the vena azygos major. Occasionally it opens into the right innominate vein.

The *left superior intercostal* is always larger than the right, but varies in size in different subjects, being small when the left upper azygos vein is large, and *vice versâ*. It is usually formed by branches from the two or three upper intercostal spaces, and, passing across the arch of the aorta, terminates in the left innominate vein. The left bronchial vein and the left superior phrenic open into it.

The **Superior Vena Cava** receives the blood which is conveyed to the heart from the whole of the upper half of the body. It is a short trunk, varying from two inches and a half to three inches in length, formed by the junction of the two innominate veins. It commences immediately below the cartilage of the first rib close to the sternum on the right side, and, descending vertically, enters



the pericardium about an inch and a half above the heart, and terminates in the upper part of the right auricle opposite the upper border of the third left costal cartilage. In its course it describes a slight curve, the convexity of which is turned to the right side.

**Relations.**—*In front*, with the pericardium and process of cervical fascia which is continuous with it; this separates it from the thymus gland, and from the sternum; *behind*, with the root of the right lung. On its *right side*, with the phrenic nerve and right pleura; on its *left side*, with the commencement of the innominate artery and the ascending part of the aorta. The portion contained within the pericardium is covered by the serous layer of that membrane, in its anterior three-fourths. It receives the vena azygos major just before it enters the pericardium, and several small veins from the pericardium and parts in the mediastinum. The superior vena cava has no valves.

The **Azygos Veins** connect together the superior and inferior venæ cavæ, supplying the place of those vessels in the part of the chest which is occupied by the heart.

The larger, or *right azygos vein* (vena azygos major), commences opposite the first or second lumbar vertebra, by a branch from the right lumbar veins (the *ascending lumbar*); sometimes by a branch from the right renal vein, or from the inferior vena cava. It enters the thorax through the aortic opening in the Diaphragm, and passes along the right side of the vertebral column to the fourth dorsal vertebra, where it arches forward over the root of the right lung, and terminates in the superior vena cava, just before that vessel enters the pericardium. Whilst passing through the aortic opening of the Diaphragm, it lies with the thoracic duct on the right side of the aorta; and in the thorax, it lies upon the intercostal arteries, on the right side of the aorta and thoracic duct, and is partly covered by pleura.

**Tributaries.**—It receives nine or ten lower intercostal veins of the right side, the vena azygos minor, several œsophageal, mediastinal, and pericardial veins; near its termination, the right bronchial vein; and generally the right superior intercostal vein. A few imperfect valves are found in this vein; but its tributaries are provided with complete valves.

The intercostal veins on the left side, below the two or three upper intercostal spaces, usually form two trunks, named the left lower, and the left upper, azygos veins.

The *left lower*, or *smaller azygos vein* (vena azygos minor), commences in the lumbar region, by a branch from one of the lumbar veins (*ascending lumbar*), or from the left renal. It passes into the thorax, through the left crus of the Diaphragm, and, ascending on the left side of the spine, as high as the eighth dorsal vertebra, passes across the column, behind the aorta and thoracic duct, to terminate in the right azygos vein. It receives the four or five lower intercostal veins of the left side, and some œsophageal and mediastinal veins.

The *left upper azygos vein* varies according to the size of the left superior intercostal. It receives veins from the intercostal spaces between the left superior intercostal vein and highest tributary of the left lower azygos. They are usually two or three in number, and join to form a trunk which ends in the right azygos vein, or in the left lower azygos. It sometimes receives the left bronchial vein. When this vein is small, or altogether wanting, the left superior intercostal vein will extend as low as the fifth or sixth intercostal space.\*

\* For an account of the arrangement of the azygos and superior intercostal veins in a number of consecutive cases from the same dissecting-room, see a paper by Mr. B. G. Morison, *Journ. of Anat. and Phys.* vol. xiii. p. 346. The most important difference between his description and that in the text is, that he always found two superior intercostal veins on both sides; the vein from the first space being separate, and joining the corresponding innominate vein. The lower (and larger) superior intercostal vein he describes as opening into the azygos on the right, and innominate on the left side.

*Surgical Anatomy.*—In obstruction of the inferior vena cava, the azygos veins are one of the principal means by which the venous circulation is carried on, connecting as they do the superior and inferior venæ cavæ and communicating with the common iliac veins by the ascending lumbar veins and with many of the tributaries of the inferior vena cava.

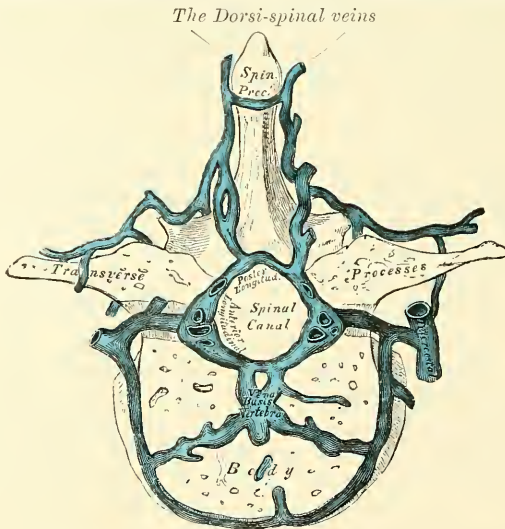
The *bronchial veins* return the blood from the substance of the lungs; that of the right side opens into the vena azygos major, near its termination; that of the left side, into the left superior intercostal vein or left upper azygos vein.

### THE SPINAL VEINS

The numerous venous plexuses placed upon and within the spine may be arranged into four sets.

1. Those placed on the exterior of the spinal column (*the dorsi-spinal veins*).
  2. Those situated in the interior of the spinal canal, between the vertebræ and the theca vertebralis (*meningo-rachidian veins*).
  3. The veins of the bodies of the vertebræ (*venæ basis vertebrarum*).
  4. The veins of the spinal cord (*medulli-spinal*).
1. The **Dorsi-spinal Veins** commence by small branches, which receive their blood from the integument of the back of the spine, and from the muscles in the vertebral grooves. They form a complicated network, which surrounds the spinous processes, the laminæ, and the transverse and articular processes of all the vertebræ. At the bases of the transverse processes, they communicate, by

FIG. 432.—Transverse section of a dorsal vertebra, showing the spinal veins.



means of ascending and descending branches, with the veins surrounding the contiguous vertebræ, and they join with the veins in the spinal canal by branches which perforate the ligamenta subflava. Other branches pass obliquely forwards between the transverse processes, and communicate with the intraspinal veins through the intervertebral foramina. They terminate by joining the vertebral veins in the neck, the intercostal veins in the thorax, and the lumbar and sacral veins in the loins and pelvis.

2. The **Meningo-rachidian Veins**.—The principal veins contained in the spinal canal are situated between the theca vertebralis and the vertebræ. They consist of two longitudinal plexuses, one of which runs along the posterior surface of the bodies of the vertebræ (*anterior longitudinal spinal veins*). The other plexus (*posterior longitudinal spinal veins*) is placed on the inner or anterior surface of the laminæ of the vertebræ.

The *Anterior Longitudinal Spinal Veins* consist of two large, tortuous veins which extend along the whole length of the vertebral column, from the foramen

magnum, where they communicate by a venous ring around that opening, to the base of the coccyx, being placed one on each side of the posterior surface of the bodies of the vertebræ, along the margin of the posterior common ligament. These veins communicate together opposite each vertebra by transverse trunks, which pass beneath the ligament, and receive the large *venæ basis vertebrarum* from the interior of the body of each vertebra. The anterior longitudinal spinal veins are least developed in the cervical and sacral regions. They are not of uniform size throughout, being alternately enlarged and constricted. At the intervertebral foramina they communicate with the dorsi-spinal veins, and with the vertebral veins in the neck, with the intercostal veins in the dorsal region, and with the lumbar and sacral veins in the corresponding regions.

The *Posterior Longitudinal Spinal Veins*, smaller than the anterior, are situated one on each side, between the inner surface of the laminae and the theca vertebralis. They communicate (like the anterior), opposite each vertebra, by transverse trunks; and with the anterior longitudinal veins, by lateral transverse branches, which pass from behind forwards. These veins, by branches which perforate the ligamenta subflava, join with the dorsi-spinal veins. From them branches are given off, which pass through the intervertebral foramina and join the vertebral, intercostal, lumbar, and sacral veins.

### 3. The Veins of the Bodies of the Vertebræ (*venæ basis vertebrarum*)

emerge from the foramina on their posterior surface, and join the transverse trunk connecting the anterior longitudinal spinal veins. They are contained in large, tortuous channels in the substance of the bones, similar in every respect to those found in the diploë of the cranial bones. These canals lie parallel to the upper and lower surface of the bones. They commence by small openings on the front and sides of the bodies of the vertebræ, through which communicating branches from the veins external to the bone pass into its substance, and converge to the principal canal, which is sometimes double towards its posterior part, and open into the corresponding transverse branch uniting the anterior longitudinal veins. They become greatly developed in advanced age.

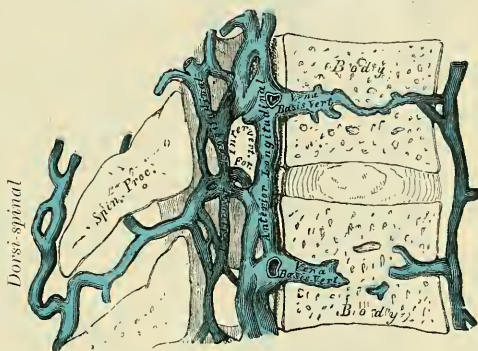
4. The *Veins of the Spinal Cord* (*medulli-spinal*) consist of a minute, tortuous, venous plexus which covers the entire surface of the cord, being situated between the pia mater and arachnoid. These vessels emerge chiefly from the median furrows, and are largest in the lumbar region. Near the base of the skull they unite, and form two or three small trunks, which communicate with the vertebral veins, and then terminate in the inferior cerebellar veins, or in the inferior petrosal sinuses. Each of the spinal nerves is accompanied by a branch as far as the intervertebral foramina, where they join the other veins from the spinal canal.

There are no valves in the spinal veins.

## VEINS OF THE LOWER EXTREMITY, ABDOMEN, AND PELVIS

The Veins of the Lower Extremity are subdivided, like those of the upper, into two sets, superficial and deep: the superficial veins being placed beneath the integument, between the two layers of superficial fascia; the deep veins accompanying the arteries, and forming the *venæ comites* of those vessels. Both sets

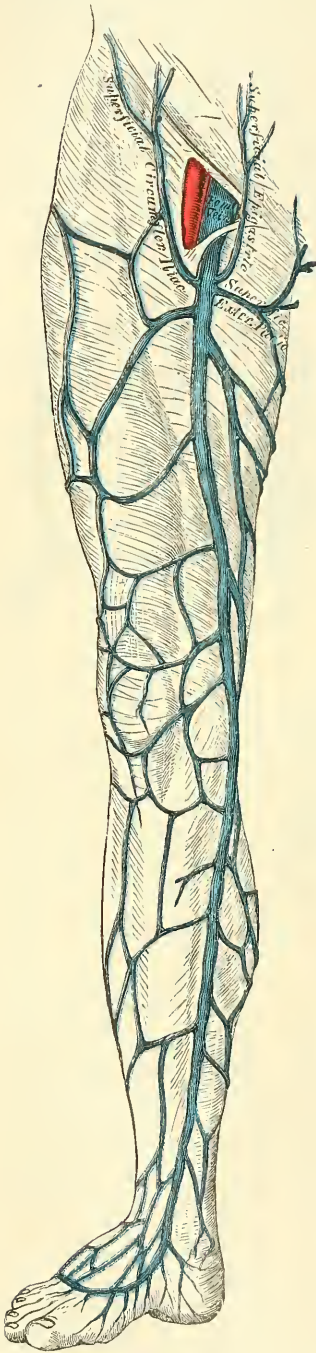
FIG. 433.—Vertical section of two dorsal vertebræ, showing the spinal veins.





of veins are provided with valves, which are more numerous in the deep than in the superficial set. These valves are also more numerous in the lower than in the upper limb.

FIG. 434.—The internal or long saphenous vein and its branches.

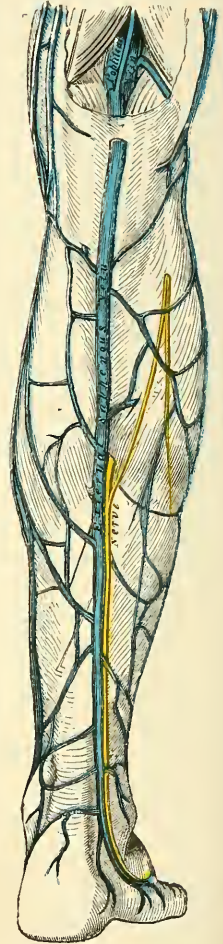


The **Superficial Veins of the Lower Extremity** are the *internal or long saphenous*, and the *external or short saphenous*.

On the dorsum of the foot is a venous arch, situated in the superficial structures over the anterior extremities of the metatarsal bones. It has its convexity directed forwards, and receives digital tributaries from the upper surface of the toes; at its concavity it is joined by numerous small veins, which form a plexus on the dorsum of the foot. The arch terminates internally in the long saphenous, externally in a short saphenous vein.

The **internal or long saphenous vein** (fig. 434) commences at the inner side of the arch on the dorsum of the foot; it descends in front of the inner malleolus, and along the inner side of the leg, behind the inner margin of the tibia, accompanied by the internal saphenous nerve. At the knee, it passes backwards behind the inner condyle of the femur, ascends along the inside of the thigh, and, passing through the saphenous opening in the fascia lata, terminates in the femoral vein about an inch and a half below Poupart's ligament. This vein receives in its course cutaneous tributaries from the leg and thigh, and at the saphenous opening the superficial epigastric, superficial circumflex iliac, and external pudic veins. The veins from the inner and back part of the thigh frequently unite to form a large vessel, which enters the main trunk near the saphenous opening; and sometimes those on the outer side of the thigh join to form another large vessel; so that occasionally three large veins are seen converging from

FIG. 435.—External or short saphenous vein.



different parts of the thigh towards the saphenous opening. The internal saphenous vein communicates in the foot with the internal plantar vein; in the leg, with the posterior tibial veins, by branches which perforate the tibial

origin of the Soleus muscle, and also with the anterior tibial veins; at the knee, with the articular veins; in the thigh, with the femoral vein by one or more branches. The valves in this vein vary from two to six in number; they are more numerous in the thigh than in the leg.

The **external or short saphenous vein** (fig. 435) commences at the outer side of the arch on the dorsum of the foot; it ascends behind the outer malleolus, and along the outer border of the tendo Achillis, across which it passes at an acute angle to reach the middle line of the posterior aspect of the leg. Passing directly upwards, it perforates the deep fascia in the lower part of the popliteal space, and terminates in the popliteal vein, between the heads of the Gastrocnemius muscle.\* It receives numerous large tributaries from the back part of the leg, and communicates with the deep veins on the dorsum of the foot, and behind the outer malleolus. Before it perforates the deep fascia, it gives off a communicating branch, which passes upwards and inwards to join the internal saphenous vein. This vein has a variable number of valves, from three to nine (Gay), one of which is always found near its termination in the popliteal vein. The external saphenous nerve lies close beside this vein.

*Surgical Anatomy.*—The saphena veins are of considerable surgical importance, since a varicose condition of these vessels is more frequently met with than those in other parts of the body, except perhaps the spermatic and hæmorrhoidal veins. The course of the internal saphenous is in front of the tip of the malleolus, over the subcutaneous surface of the lower end of the tibia, and then along the internal border of this bone, to the back part of the internal condyle of the femur, whence it follows the course of the Sartorius muscle and is represented on the surface by a line drawn from the posterior border of the Sartorius, on a level with the internal condyle, to the saphenous opening. The short saphenous lies behind the external malleolus, and from this follows the middle line of the calf to just below the ham. It is not generally so apparent beneath the skin as the internal saphenous. Both these veins in the leg are accompanied by nerves, the internal saphenous being joined by its companion nerve just below the level of the knee-joint. No doubt much of the pain of varicose veins in the leg is due to this fact. On the Continent the internal saphenous vein as it rests on the tibia just above the malleolus is sometimes selected for venesection.

The **Deep Veins of the Lower Extremity** accompany the arteries and their branches, and are called the *venæ comites* of those vessels.

The **external and internal plantar veins** unite to form the **posterior tibial veins**. These latter accompany the posterior tibial artery, and are joined by the *peroneal veins*.

The **anterior tibial veins** are formed by a continuation upwards of the *venæ comites* of the dorsalis pedis artery. They pass between the tibia and fibula, through the large oval aperture above the interosseous membrane, and form, by their junction with the posterior tibial, the popliteal vein.

The valves in the deep veins are very numerous.

The **Popliteal Vein** is formed by the junction of the *venæ comites* of the anterior and posterior tibial vessels; it ascends through the popliteal space to the tendinous aperture in the Adductor magnus, where it becomes the femoral vein. In the lower part of its course, it is placed internal to the artery; between the heads of the Gastrocnemius, it is superficial to that vessel; but above the knee-joint, it is close to its outer side. It receives the sural veins from the Gastrocnemius muscle, the articular veins, and the external saphenous. The valves in this vein are usually four in number.

The **Femoral Vein** accompanies the femoral artery through the upper two-thirds of the thigh. In the lower part of its course it lies external to the artery; higher up, it is behind it; and at Poupert's ligament, it lies to its inner side, and

\* Mr. Gay calls attention to the fact that the external saphenous vein often (he says invariably) penetrates the fascia at or about the point where the tendon of the Gastrocnemius commences, and runs below the fascia in the rest of its course, or sometimes among the muscular fibres, to join the popliteal vein. See Gay on *Varicose Disease of the Lower Extremities*, p. 24, where there is also a careful and elaborate description of the branches of the saphena veins.



on the same plane. It receives numerous muscular tributaries: the profunda femoris and deep external pudic veins join it near Poupart's ligament, and about an inch and a half below the internal saphenous vein. The valves in this vein are four or five in number.

The **External Iliac Vein** commences at the termination of the femoral, beneath the crural arch, and passing upwards along the brim of the pelvis, terminates opposite the sacro-iliac synchondrosis, by uniting with the internal iliac to form the common iliac vein. On the right side, it lies at first along the inner side of the external iliac artery; but as it passes upwards, gradually inclines behind it. On the left side, it lies altogether on the inner side of the artery. It receives, immediately above Poupart's ligament, the deep epigastric and deep circumflex iliac veins and a small pubic vein, corresponding to the pubic branch of the obturator artery. According to Friedreich, it frequently contains one and sometimes two valves.

*The Deep Epigastric Veins.*—Two veins accompany the deep epigastric artery; they usually unite into a single trunk before their termination in the external iliac vein.

*The Deep Circumflex Iliac Veins.*—Two veins accompany the deep circumflex iliac artery. These unite into a single trunk which crosses the external iliac artery just above Poupart's ligament, and terminates in the external iliac vein.

The **Internal Iliac Vein** is formed by the venæ comites of the branches of the internal iliac artery, the umbilical arteries excepted. It receives the blood from the exterior of the pelvis by the gluteal, sciatic, internal pudic, and obturator veins; and from the organs in the cavity of the pelvis by the hæmorrhoidal and vesico-prostatic plexuses in the male, and the uterine and vaginal plexuses in the female. The vessels forming these plexuses are remarkable for their large size, their frequent anastomoses, and the number of valves which they contain. The internal iliac vein lies at first on the inner side, and then behind the internal iliac artery, and terminates opposite the sacro-iliac articulation, by uniting with the external iliac to form the common iliac vein. This vessel has no valves.

The *internal pudic veins (venæ comites)* have the same course as the internal pudic artery. They receive tributaries corresponding to the branches of the artery except the tributary corresponding to the dorsal artery of the penis, that is, the dorsal vein of the penis, which opens into the prostatic plexus.

The *hæmorrhoidal plexus* surrounds the lower end of the rectum, being formed by the superior hæmorrhoidal veins, tributaries of the inferior mesenteric. It commences as a series of dilated pouches, about twelve in number, which are arranged circularly at the verge of the anus and are connected by transverse branches. From these pouches veins, about six in number, pass upwards in a straight direction in the submucous tissue for about three inches; they then pierce the muscular coat and become arranged in a circular manner at right angles to the long axis of the gut, and eventually unite to form the superior hæmorrhoidal vein.

*Surgical Anatomy.*—The veins of this plexus are apt to become dilated and varicose, and form piles. This is due to several anatomical reasons: the vessels are contained in very loose, lax connective tissue, so that they get less support from surrounding structures than most other veins, and are less capable of resisting increased blood pressure: the condition is favoured by gravitation, being influenced by the erect posture, either sitting or standing, and by the fact that the superior hæmorrhoidal and portal veins have no valves: the veins pass through muscular tissue and are liable to be compressed by its contraction, especially during the act of defecation: they are affected by every form of portal obstruction.

The *vesico-prostatic plexus* surrounds the neck and base of the bladder and prostate gland. It communicates with the hæmorrhoidal plexus behind, and receives the dorsal vein of the penis, which enters the pelvis beneath the sub-pubic ligament. This plexus is supported upon the sides of the bladder by a



reflection of the pelvic fascia. The veins composing it are very liable to become varicose, and often contain hard, earthy concretions, called *phleboliths*.

*Surgical Anatomy.*—This plexus is wounded in the lateral operation of lithotomy, and it is through it that septic matter finds its way into the general circulation after this operation.

The *dorsal vein of the penis* is a vessel of large size, which returns the blood from the body of that organ. At first it consists of two branches, which are contained in the groove on the dorsum of the penis, and it receives veins from the glands, the corpus spongiosum, and numerous superficial veins; these unite near the root of the penis into a single trunk, which passes through the suspensory ligament of the penis, pierces the triangular ligament beneath the pubic arch, and divides into two branches, which enter the prostatic plexus.

The *vaginal plexus* surrounds the vagina, being especially developed at the orifice of the canal; it communicates with the vesical plexus in front, and with the hæmorrhoidal plexus behind.

The *uterine plexus* is situated along the sides and superior angles of the uterus, between the layers of the broad ligament, receiving large venous canals (the *uterine sinuses*) from the substance of the uterus. The veins composing this plexus anastomose frequently with each other and with the ovarian veins. They are not tortuous like the arteries.

The **Common Iliac Veins** are formed by the union of the external and internal iliac veins in front of the sacro-iliac articulation; passing obliquely upwards towards the right side, they terminate upon the intervertebral substance between the fourth and fifth lumbar vertebræ, where the veins of the two sides unite at an acute angle to form the inferior vena cava. The *right common iliac* is shorter than the left, nearly vertical in its direction, and ascends behind and then to the outer side of its corresponding artery. The *left common iliac*, longer and more oblique in its course, is at first situated on the inner side of the corresponding artery, and then behind the right common iliac. Each common iliac receives the ilio-lumbar, and sometimes the lateral sacral veins. The left receives, in addition, the middle sacral vein. No valves are found in these veins.

The **middle sacral veins** accompany the corresponding artery along the front of the sacrum, and terminate in the left common iliac vein; occasionally in the angle of junction of the two iliac veins.

*Peculiarities.*—The left common iliac vein, instead of joining with the right in its usual position, occasionally ascends on the left side of the aorta as high as the kidney, where, after receiving the left renal vein, it crosses over the aorta, and then joins with the right vein to form the vena cava. In these cases, the two common iliacs are connected by a small communicating branch at the spot where they are usually united.\*

The **Inferior Vena Cava** returns to the heart the blood from all the parts below the Diaphragm. It is formed by the junction of the two common iliac veins on the right side of the intervertebral substance between the fourth and fifth lumbar vertebræ. It passes upwards along the front of the spine, on the right side of the aorta, and, having reached the under surface of the liver, is contained in a groove in its posterior surface. It then perforates the central tendon of the Diaphragm, enters the pericardium, where it is covered by its serous layer, and terminates in the lower and back part of the right auricle. At its termination in the auricle it is provided with a valve, the *Eustachian*, which is of large size during foetal life.

**Relations.**—*In front*, from below upwards, with the mesentery, right spermatic artery, transverse portion of the duodenum, the pancreas, portal vein, and the posterior surface of the liver, which partly and occasionally completely surrounds it; *behind*, with the vertebral column, the right crus of the Diaphragm, the right renal and lumbar arteries, right semilunar ganglion; on the *left side* with the aorta.

\* See two cases which have been described by Mr. Walsham in the *St. Bartholomew's Hospital Reports*, vols. xvi. and xvii.

*Peculiarities.*—*In Position.*—This vessel is sometimes placed on the left side of the aorta, as high as the left renal vein, after receiving which it crosses over to its usual position on the right side; or it may be placed altogether on the left side of the aorta, as far upwards as its termination in the heart: in such cases, the abdominal and thoracic viscera, together with the great vessels, are all transposed.

*Point of Termination.*—Occasionally the inferior vena cava joins the right azygos vein, which is then of large size. In such cases, the superior cava receives the whole of the blood from the body before transmitting it to the right auricle, except the blood from the hepatic veins, which passes directly into the right auricle.

**Tributaries.**—It receives in its course the following veins:—

Lumbar.	Suprarenal.
Right Spermatic.	Phrenic.
Renal.	Hepatic.

The **lumbar veins**, four in number on each side, collect the blood by dorsal tributaries from the muscles and integument of the loins, and by abdominal tributaries from the walls of the abdomen, where they communicate with the epigastric veins. At the spine, they receive veins from the spinal plexuses, and then pass forwards, round the sides of the bodies of the vertebræ beneath the Psoas magnus, and terminate at the back part of the inferior cava. The left lumbar veins are longer than the right, and pass behind the aorta. The lumbar veins are connected together by a longitudinal vein which passes in front of the transverse processes of the lumbar vertebræ, and is called the *ascending lumbar*. It forms the most frequent origin of the corresponding vena azygos, and serves to connect the common iliac, ilio-lumbar, lumbar, and azygos veins of the corresponding side of the body.

The **spermatic veins** emerge from the back of the testis, and receive tributaries from the epididymis; they unite and form a convoluted plexus, called the *spermatic plexus* (*plexus pampiniformis*), which forms the chief mass of the cord; the vessels composing this plexus are very numerous, and ascend along the cord in front of the vas deferens; below the external abdominal ring they unite to form three or four veins, which pass along the spermatic canal, and, entering the abdomen through the internal abdominal ring, coalesce to form two veins, which ascend on the Psoas muscle, behind the peritoneum, lying one on each side of the spermatic artery, and unite to form a single vein, which opens on the right side into the inferior vena cava, at an acute angle; on the left side into the left renal vein, at a right angle. The spermatic veins are provided with valves.\* The left spermatic vein passes behind the sigmoid flexure of the colon, and is thus exposed to pressure from the contents of that bowel.

*Surgical Anatomy.*—The spermatic veins are very frequently varicose, constituting the disease known as varicocele. Though it is quite possible that the originating cause of this affection may be a congenital abnormality either in the size or number of the veins of the pampiniform plexus, still it must be admitted that there are many anatomical reasons why these veins should become varicose: viz. the imperfect support afforded to them by the loose tissue of the scrotum; their great length; their vertical course; their dependent position; their plexiform arrangement in the scrotum, with their termination in one small vein in the abdomen; their few and imperfect valves; and the fact that they may be subjected to pressure in their passage through the abdominal wall.

The **ovarian veins** are analogous to the spermatic in the male; they form a plexus near the ovary and in the broad ligament and Fallopian tube, communicating with the uterine plexus. They terminate in the same way as the spermatic veins in the male. Valves are occasionally found in these veins. These vessels, like the uterine veins, become much enlarged during pregnancy.

\* Rivington has pointed out that a valve is usually found at the orifices of both the right and left spermatic veins. When no valves exist at the opening of the left spermatic vein into the left renal vein, valves are generally present in the left renal vein within a quarter of an inch from the orifice of the spermatic vein. (*Journal of Anatomy and Physiology*, vol. vii. p. 163.)

The **renal veins** are of large size, and placed in front of the renal arteries.\* The left is longer than the right, and passes in front of the aorta, just below the origin of the superior mesenteric artery. It receives the left spermatic, the left inferior phrenic, and, generally, the left suprarenal veins. It opens into the vena cava, a little higher than the right.

The **suprarenal veins** terminate, on the right side, in the vena cava; on the left side, in the left renal or phrenic vein.

The **phrenic veins** follow the course of the phrenic arteries. The *two superior*, of small size, accompany the phrenic nerve and come from the phrenic artery, and join the internal mammary. The *two inferior phrenic veins* follow the course of the phrenic arteries, and terminate, the right in the inferior vena cava, the left in the left renal vein.

The **hepatic veins** commence in the substance of the liver, in the capillary terminations of the portal vein and hepatic artery: these tributaries, gradually uniting, usually form three large veins, which converge towards the posterior surface of the liver, and open into the inferior vena cava, whilst that vessel is situated in the groove at the back part of this organ. Of these three veins, one from the right, and another from the left lobe, open obliquely into the inferior vena cava; that from the middle of the organ and lobulus Spigelii having a straight course. The hepatic veins run singly, and are in direct contact with the hepatic tissue. They are destitute of valves.

#### PORTAL SYSTEM OF VEINS

The portal venous system is composed of four large veins which collect the venous blood from the viscera of digestion. The trunk formed by their union (*vena portæ*) enters the liver and ramifies throughout its substance; and its branches, again emerging from that organ as the hepatic veins, terminate in the inferior vena cava. The branches in this vein are in all cases single, and destitute of valves.

The veins forming the portal system are, the

Superior Mesenteric.	Inferior Mesenteric.
Splenic.	Gastric.

The **superior mesenteric vein** returns the blood from the small intestines, and from the cæcum and ascending and transverse portions of the colon, corresponding with the distribution of the branches of the superior mesenteric artery. The large trunk formed by the union of these branches ascends along the right side and in front of the corresponding artery, passes in front of the transverse portion of the duodenum, and unites, behind the upper border of the pancreas, with the splenic vein to form the vena portæ. It receives the right gastro-epiploic vein.

The **splenic vein** commences by five or six large branches, which return the blood from the substance of the spleen. These uniting form a single vessel, which passes from left to right, grooving the upper and back part of the pancreas, below the artery, and terminates at its greater end by uniting at a right angle with the superior mesenteric to form the vena portæ. The splenic vein is of large size, and not tortuous like the artery. It receives the vasa brevia from the left extremity of the stomach, the left gastro-epiploic vein, pancreatic branches from the pancreas, the pancreatico-duodenal vein, and the inferior mesenteric vein.

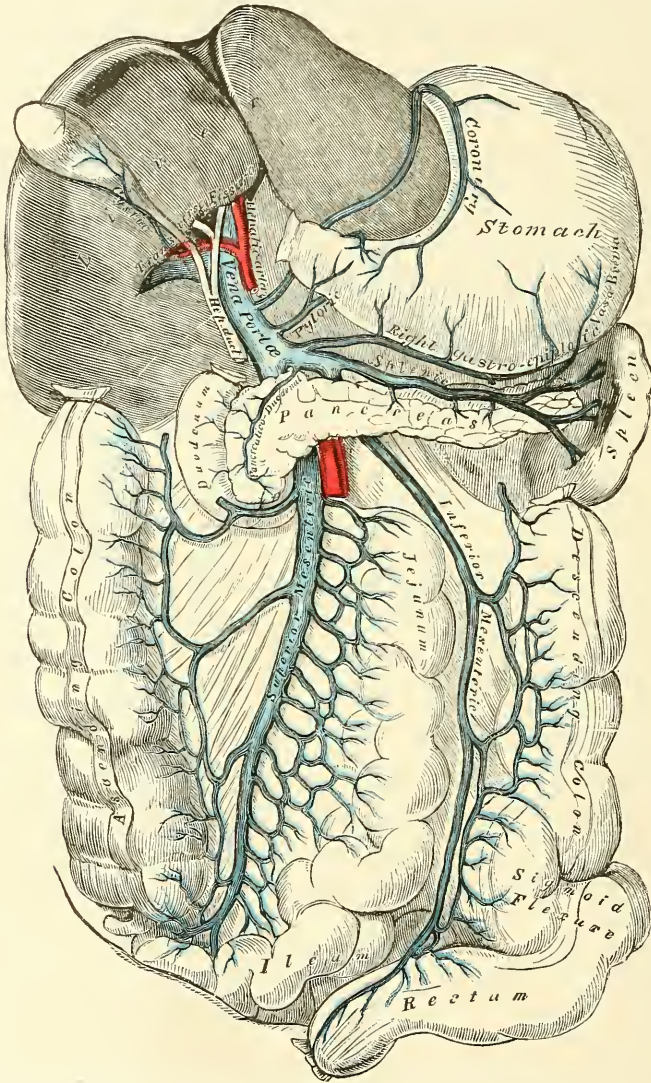
The **inferior mesenteric vein** returns the blood from the rectum, sigmoid flexure, and descending colon, corresponding with the ramifications of the

\* The student may observe that all veins above the Diaphragm, which do not lie on the same plane as the arteries which they accompany, lie in front of them: and that all veins below the Diaphragm, which do not lie on the same plane as the arteries which they accompany, lie behind them, except the renal and profunda femoris vein.



branches of the inferior mesenteric artery. Ascending beneath the peritoneum in the lumbar region, it passes behind the transverse portion of the duodenum and pancreas, and terminates in the splenic vein. Its hæmorrhoidal branches inosculate with those of the internal iliac, and thus establish a communication between the portal and the general venous system.\*

FIG. 436.—Portal vein and its branches.



NOTE.—In this diagram the right gastro-epiploic vein opens into the splenic vein; generally it empties itself into the superior mesenteric, close to its termination.

The **gastric veins** are two in number: one, a small vein, corresponds to the pyloric branch of the hepatic artery; the other, considerably larger, corresponds

\* Besides this anastomosis between the portal vein and the branches of the vena cava other anastomoses between the portal and systemic veins are formed by the communication between the gastric veins and the œsophageal veins which empty themselves into the vena azygos minor; between the left renal vein and the veins of the intestines, especially of the colon and duodenum; between the veins of the round ligament of the liver and the portal veins; and between the superficial branches of the portal veins of the liver and the phrenic veins, as pointed out by Mr. Kiernan. (See *Physiological Anatomy*, by Todd and Bowman, 1859, vol. ii. p. 348.)

to the gastric artery. The former (*pyloric*, Walsham) runs along the lesser curvature of the stomach towards the pyloric end, receives branches from the pylorus and duodenum, and ends in the vena portæ. The latter (*coronary*, Walsham) begins near the pylorus, runs along the lesser curvature of the stomach, towards the œsophageal opening, and then curves downwards and backwards between the folds of the lesser omentum to end in the vena portæ.

The **Portal Vein** is formed by the junction of the superior mesenteric and splenic veins, their union taking place in front of the vena cava, and behind the upper border of the great end of the pancreas. Passing upwards through the right border of the lesser omentum to the under surface of the liver, it enters the transverse fissure, where it is somewhat enlarged, forming the *sinus* of the portal vein, and divides into two branches, which accompany the ramifications of the hepatic artery and hepatic duct throughout the substance of the liver. Of these two branches the right is the larger, but the shorter, of the two. The portal vein is about three or four inches in length, and, whilst contained in the lesser omentum, lies behind and between the hepatic duct and artery, the former being to the right, the latter to the left. These structures are accompanied by filaments of the hepatic plexus of nerves, and numerous lymphatics, surrounded by a quantity of loose areolar tissue (*capsule of Glisson*), and placed between the layers of the lesser omentum. The vena portæ receives the gastric and cystic veins: the latter vein sometimes terminates in the right branch of the vena portæ. Within the liver, the portal vein receives the blood from the branches of the hepatic artery.

#### CARDIAC VEINS

The veins which return the blood from the substance of the heart are, the

Anterior Cardiac Vein.

Right Cardiac Veins.

Posterior Cardiac Vein.

Right or Small Coronary Sinus.

Left Cardiac Veins.

Left or Great Coronary Sinus.

Venæ Thebesii.

The **Anterior Cardiac Vein** (sometimes called *Great Cardiac Vein*) is a vessel of considerable size, which commences at the apex of the heart, and ascends along the anterior interventricular groove to the base of the ventricles. It then curves to the left side, around the auriculo-ventricular groove, between the left auricle and ventricle, to the back part of the heart, and opens into the great coronary sinus, its aperture being guarded by two valves. It receives, in its course, tributaries from both ventricles, but especially the left, and also from the left auricle; one of these, ascending along the thick margin of the left ventricle, is of considerable size. The vessels joining it are provided with valves.

The **Posterior Cardiac Vein** commences by small tributaries, at the apex of the heart, communicating with those of the preceding. It ascends along the posterior interventricular groove to the base of the heart, and terminates in the great coronary sinus, its orifice being guarded by a valve. It receives the veins from the posterior surface of both ventricles.

The **Left Cardiac Veins** are three or four small vessels, which collect the blood from the posterior surface of the left ventricle, and open into the lower border of the great coronary sinus.

The **Right Cardiac Veins** are three or four small vessels, which collect the blood from the anterior surface of the right ventricle. One of these (the *vein of Galen*), larger than the rest, runs along the right border of the heart. They open separately into the lower part of the right auricle.

The **Right or Small Coronary Sinus** runs along the groove between the right auricle and ventricle, to open into the right extremity of the great coronary sinus. It receives blood from the back part of the right auricle and ventricle.

The **Left or Great Coronary Sinus** is that portion of the anterior cardiac vein which is situated in the posterior part of the left auriculo-ventricular groove. It

is about an inch in length, presents a considerable dilatation, and is covered by the muscular fibres of the left auricle. It receives the veins enumerated above, and an *oblique vein* from the back part of the left auricle, the remnant of the obliterated left innominate trunk of the fœtus, described by Mr. Marshall. The great coronary sinus terminates in the right auricle, between the inferior vena cava and the auriculo-ventricular aperture, its orifice being guarded by a semilunar fold of the lining membrane of the heart, the *coronary valve*. All the veins joining this vessel, excepting the oblique vein above mentioned, are provided with valves.

The **Venæ Thebesii** are numerous minute veins, which return the blood directly from the muscular substance, without entering the venous current. They open by minute orifices (*foramina Thebesii*) on the inner surface of the right auricle.



## OF THE LYMPHATICS

**T**HE Lymphatics have derived their name from the appearance of the fluid contained in their interior (*lymph*a, water). They are also called *absorbents*, from the property they possess of absorbing certain materials from the tissues and conveying them into the circulation.

The lymphatic system includes not only the lymphatic vessels and the glands through which they pass, but also the *lacteal* or *chyliferous vessels*. The lacteals are the lymphatic vessels of the small intestine, and differ in no respect from the lymphatics generally, excepting that they contain a milk-white fluid, the *chyle*, during the process of digestion, and convey it into the blood through the thoracic duct.

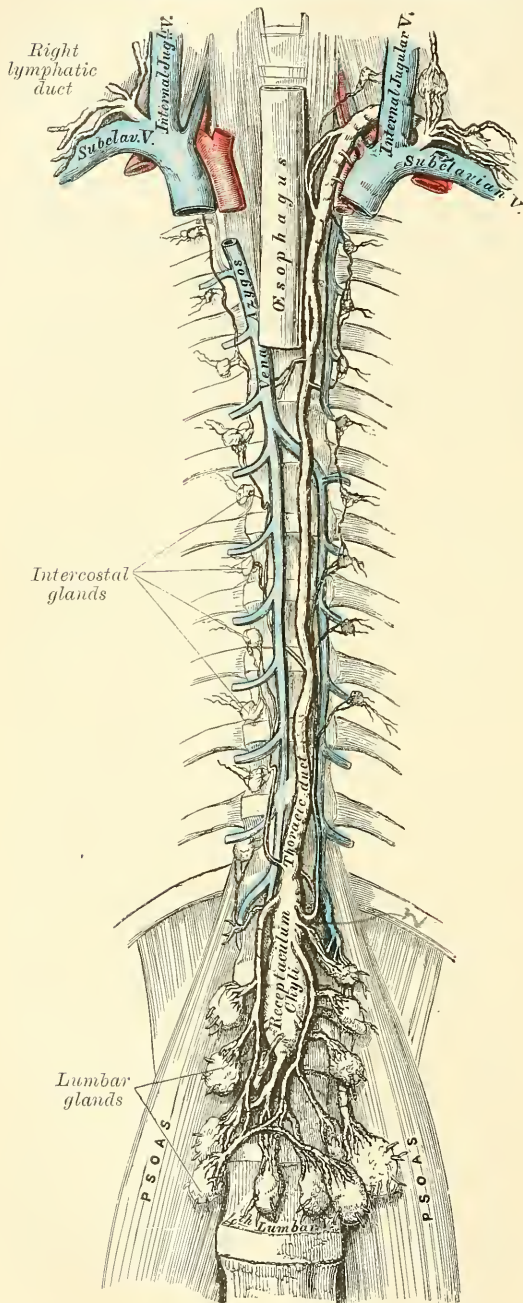
The lymphatics are exceedingly delicate vessels, the coats of which are so transparent that the fluid they contain is readily seen through them. They retain a nearly uniform size, being interrupted at intervals by constrictions, which give them a knotted or beaded appearance. These constrictions are due to the presence of valves in their interior. Lymphatics have been found in nearly every texture and organ of the body which contain blood-vessels. Such non-vascular structures as cartilage, the nails, cuticle, and hair have none, but with these exceptions it is probable that eventually all parts will be found to be permeated by these vessels.

The lymphatics are arranged into a superficial and deep set. The superficial lymphatics, on the surface of the body, are placed immediately beneath the integument, accompanying the superficial veins; they join the deep lymphatics in certain situations by perforating the deep fascia. In the interior of the body they lie in the submucous areolar tissue, throughout the whole length of the gastro-pulmonary and genito-urinary tracts; and in the subserous tissue in the cranial, thoracic, and abdominal cavities. The method of their origin has been described along with the other details of their minute anatomy (page 58). Here it will be sufficient to say that a plexiform network of minute lymphatics may be found interspersed among the proper elements and blood-vessels of the several tissues; the vessels composing which, as well as the meshes between them, are much larger than those of the capillary plexus. From these networks small vessels emerge, which pass, either to a neighbouring gland, or to join some larger lymphatic trunk. The deep lymphatics, fewer in number, and larger than the superficial, accompany the deep blood-vessels. Their mode of origin is probably similar to that of the superficial vessels. The lymphatics of any part or organ exceed the veins in number, but in size they are much smaller. Their anastomoses also, especially those of the large trunks, are more frequent, and are effected by vessels equal in diameter to those which they connect, the continuous trunks retaining the same diameter.

The **lymphatic** or **absorbent glands**, named also *conglobate glands*, are small, solid, glandular bodies, situated in the course of the lymphatic and lacteal vessels. In size they vary from a hemp-seed to an almond, and their colour, on section, is of a pinkish-grey tint, excepting the bronchial glands, which in the adult are mottled with black. Each gland has a layer or capsule of cellular tissue investing it, from which prolongations dip into its substance, forming partitions. The

lymphatic and lacteal vessels pass through these bodies in their passage to the thoracic and lymphatic ducts. A lymphatic or lacteal vessel, previous to entering a gland, divides into several small branches, which are named *afferent vessels*. As

Fig. 437.—The thoracic and right lymphatic duct.



they enter, their external coat becomes continuous with the capsule of the gland, and the vessels, much thinned, and consisting only of their internal or endothelial coat, pass into the gland, and branch out upon and in the tissue of the capsule; these branches opening into the lymph sinuses of the gland. From these sinuses fine branches proceed to form a plexus, the vessels of which unite to form a single *efferent vessel*, which, on emerging from the gland, is again invested with an external coat. Further details on the minute anatomy of the lymphatic vessels and glands will be found in the chapter on General Anatomy.

#### THORACIC DUCT

The **thoracic duct** (fig. 437) conveys the great mass of the lymph and chyle into the blood. It is the common trunk of all the lymphatic vessels of the body, excepting those of the right side of the head, neck, and thorax, and right upper extremity, the right lung, right side of the heart, and the convex surface of the liver. It varies in length from fifteen to eighteen inches in the adult, and extends from the second lumbar vertebra to the root of the neck. It commences in the abdomen by a triangular dilatation, the *receptaculum chyli* (*reservoir or cistern of Pecquet*), which is situated upon the front of the body of the second lumbar vertebra, to the

right side and behind the aorta, by the side of the right crus of the Diaphragm. It ascends into the thorax through the aortic opening in the Diaphragm, lying to the right of the aorta, and is placed in the posterior mediastinum in front of the vertebral column, lying between the aorta and vena azygos major. Opposite the fourth dorsal vertebra, it inclines towards the left side and ascends behind the

arch of the aorta, on the left side of the œsophagus, and behind the first portion of the left subclavian artery to the upper orifice of the thorax. Opposite the seventh cervical vertebra, it turns outwards, and then curves downwards over the subclavian artery, and in front of the Scalenus anticus muscle, so as to form an arch; and terminates in the left subclavian vein, at its angle of junction with the left internal jugular vein. The thoracic duct, at its commencement, is about equal in size to the diameter of a goose-quill, diminishes considerably in its calibre in the middle of the thorax, and is again dilated just before its termination. It is generally flexuous in its course, and constricted at intervals so as to present a varicose appearance. The thoracic duct not unfrequently divides in the middle of its course into two branches of unequal size, which soon reunite, or into several branches which form a plexiform interlacement. It occasionally divides, at its upper part, into two branches, of which the one on the left side terminates in the usual manner, while that on the right opens into the right subclavian vein, in connection with the right lymphatic duct. The thoracic duct has numerous valves throughout its whole course, but they are more numerous in the upper than in the lower part: at its termination it is provided with a pair of valves, the free borders of which are turned towards the vein, so as to prevent the passage of venous blood into the duct.

**Tributaries.**—The thoracic duct, at its commencement, receives four or five large trunks from the abdominal lymphatic glands, and also the trunk of the lacteal vessels. Within the thorax, it is joined by the lymphatic vessels from the left half of the wall of the thoracic cavity, the lymphatics from the sternal and intercostal glands, those of the left lung, left side of the heart, trachea, and œsophagus; and, just before its termination, it receives the lymphatics of the left side of the head and neck, and left upper extremity.

**Structure** (fig. 63).—The thoracic duct is composed of three coats, which differ in some respects from those of the lymphatic vessels. The *internal coat* consists of a single layer of flattened lanceolate-shaped endothelial cells, with serrated borders; of a subendothelial layer similar to that found in the arteries; and an elastic fibrous coat, the fibres of which run in a longitudinal direction. The *middle coat* consists of a longitudinal layer of white connective tissue with elastic fibres, external to which are several laminae of muscular tissue, the fibres of which are for the most part disposed transversely, but some are oblique or longitudinal, and intermixed with elastic fibres. The *external coat* is composed of areolar tissue, with elastic fibres and isolated fasciculi of muscular fibres.

The **Right Lymphatic Duct** is a short trunk, about half an inch in length, and a line or a line and a half in diameter. It terminates in the right subclavian vein, at its angle of junction with the right internal jugular vein. Its orifice is guarded by two semilunar valves, which prevent the passage of venous blood into the duct.

**Tributaries.**—It receives the lymph from the right side of the head and neck, the right upper extremity, the right side of the thorax, the right lung and right side of the heart, and from part of the convex surface of the liver.

#### LYMPHATICS OF THE HEAD, FACE, AND NECK

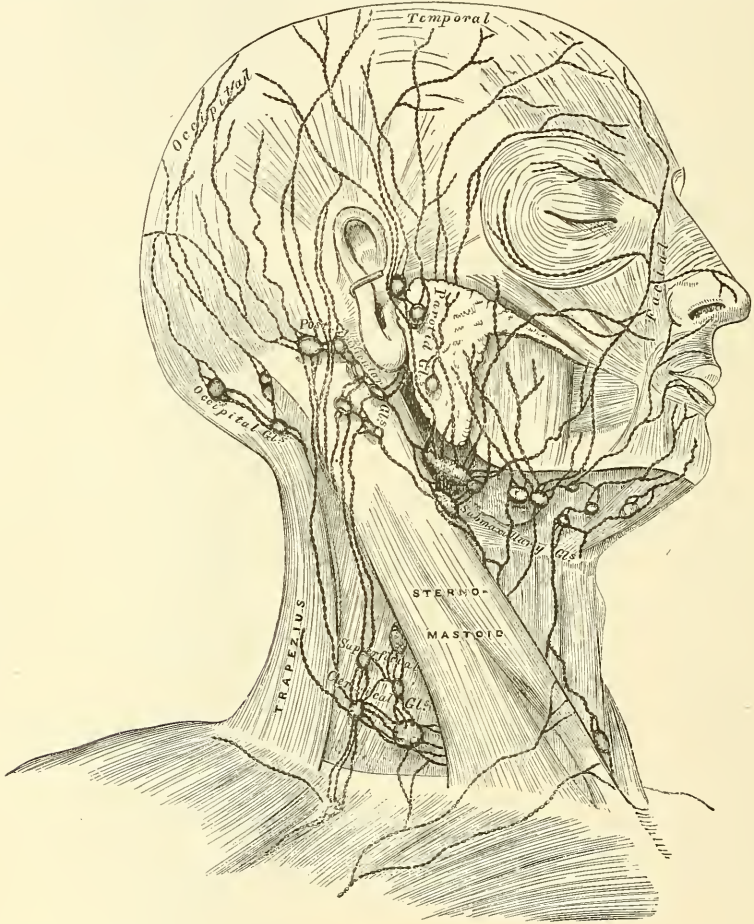
The **Lymphatic Glands of the Head** (fig. 438) are of small size, few in number, and confined to its posterior region. They are the *occipital*, and *posterior auricular*. The *occipital* are placed at the back of the head along the attachment of the Occipito-frontalis muscle. The *posterior auricular* are placed near the upper end of the Sterno-mastoid muscle. Both these sets of glands are affected in cutaneous eruptions and other diseases of the scalp. In the face, the superficial lymphatic glands are more numerous: they are the *parotid*, some of which are superficial and others deeply placed in the substance of the parotid gland; the *zygomatic*, situated under the zygoma; the *buccal*, on the surface of the Buccinator muscle; and the *internal maxillary*, the largest, beneath the ramus of the lower jaw.



The **lymphatic vessels of the scalp** are divided into an *anterior* and a *posterior set*, which follow the course of the temporal and occipital vessels. The *temporal* accompany the temporal artery in front of the ear, to the parotid lymphatic glands, from which they proceed to the lymphatic glands of the neck. The *occipital* follow the course of the occipital artery, descend to the occipital and posterior auricular lymphatic glands, and from thence join the cervical glands.

The **Lymphatic Vessels of the Face** are divided into two sets, *superficial* and *deep*.

FIG. 438.—The superficial lymphatics and glands of the head, face, and neck.

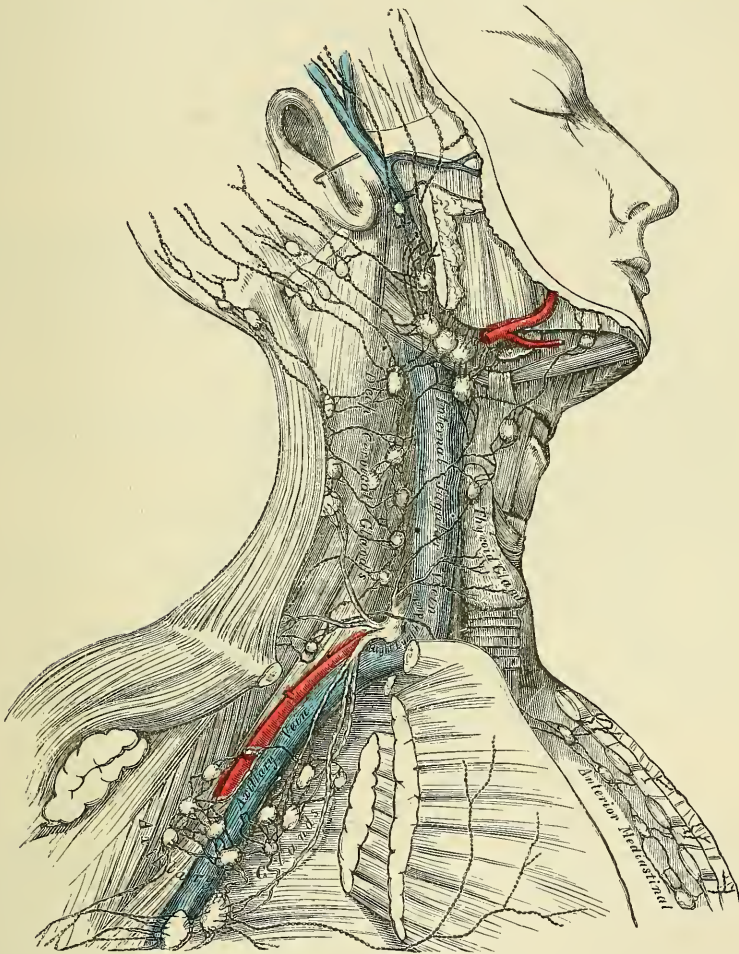


The **superficial lymphatic vessels of the face** are more numerous than those of the head, and commence over its entire surface. Those from the frontal region accompany the frontal vessels; they then pass obliquely across the face, running with the facial vein, pass through the buccal glands on the surface of the Buccinator muscle, and join the submaxillary lymphatic glands. The latter receive the lymphatic vessels from the lips, and are often found enlarged in cases of malignant disease of those parts.

The **deep lymphatic vessels of the face** are derived from the pituitary membrane of the nose, the mucous membrane of the mouth and pharynx, and the contents of the temporal and orbital fossæ; they accompany the branches of the internal maxillary artery, and terminate in the internal maxillary and cervical lymphatic glands.

The **lymphatic vessels of the cranium** consist of two sets, the *meningeal* and *cerebral*. The *meningeal lymphatics* accompany the meningeal vessels, escape through foramina at the base of the skull, and join the deep cervical lymphatic glands. The *cerebral lymphatics* are described by Eismann as being situated between the arachnoid and pia mater, as well as in the choroid plexuses of the lateral ventricles; they accompany the trunks of the carotid and vertebral arteries, and probably pass through foramina at the base of the skull, to terminate in the deep cervical glands. They have not at present been demonstrated in the dura mater, or in the substance of the brain.

FIG. 439.—The deep lymphatics and glands of the neck and thorax.



The **Lymphatic Glands of the Neck** are divided into two sets, *superficial* and *deep*.

The **superficial cervical glands** may be arranged in three sets:—(1) The *submaxillary*, ten to fifteen in number, situated beneath the body of the lower jaw in the submaxillary triangle; (2) *suprahyoid*, situated in the middle line of the neck, between the anterior bellies of the two digastric muscles; and (3) *cervical*, placed in the course of the external jugular vein between the Platysma and deep fascia. They are most numerous at the root of the neck, in the triangular interval between the clavicle, the Sterno-mastoid, and the Trapezius, where they are continuous with the axillary glands. A few small glands are also found on the front and sides of the larynx.



The **deep cervical glands** (fig. 439) are numerous and of large size ; they form a chain along the sheath of the carotid artery and internal jugular vein, lying by the side of the pharynx, œsophagus, and trachea, and extending from the base of the skull to the thorax, where they communicate with the lymphatic glands in that cavity. They are subdivided into two sets : an *upper*, ten to twenty in number, situated about the bifurcation of the common carotid and along the upper part of the internal jugular vein ; and a *lower*, ten to fifteen in number, clustered around the lower part of the internal jugular vein, and extending outwards into the supra-clavicular fossa, where they are continuous with the axillary glands. Internally, this set is continuous with the mediastinal glands.

The **superficial and deep cervical lymphatic vessels** are a continuation of those already described on the cranium and face. After traversing the glands in those regions, they pass through the chain of glands which lie along the sheath of the carotid vessels, being joined by the lymphatics from the pharynx, œsophagus, larynx, trachea, and thyroid gland. At the lower part of the neck, after receiving some lymphatics from the thorax, they unite into a single trunk, which terminates, on the left side, in the thoracic duct ; on the right side, in the right lymphatic duct.

*Surgical Anatomy.*—The cervical glands are very frequently the seat of tuberculous trouble. This condition is most usually set up by some lesion in those parts from which they receive their lymph. This excites some inflammation, which subsequently takes on a tuberculous character. It is very desirable therefore for the surgeon, in dealing with these cases, to possess a knowledge of the relation of the respective groups of glands to the periphery. The following table is extracted from Mr. Treves's work on 'Scrofula and its Gland Diseases.'

*Scalp.*—Posterior part = suboccipital and mastoid glands. Frontal and parietal portions = parotid glands.

Lymphatic vessels from the scalp also enter the superficial cervical set of glands.

*Skin of face and neck* = submaxillary, parotid, and superficial cervical glands.

*External ear* = superficial cervical glands.

*Lower lip* = submaxillary and suprahyoid glands.

*Buccal cavity* = submaxillary and upper set of deep cervical glands.

*Gums of lower jaw* = submaxillary glands.

*Tongue.*—Anterior portion = suprahyoid and submaxillary glands. Posterior portion = upper set of deep cervical glands.

*Tonsils and palate* = upper set of deep cervical glands.

*Pharynx.*—Upper part = parotid and retro-pharyngeal glands. Lower part = upper set of deep cervical glands.

*Larynx, orbit, and roof of mouth* = upper set of deep cervical glands.

*Nasal fossæ* = retro-pharyngeal glands, upper set of deep cervical glands. Some lymphatic vessels from posterior part of the fossæ enter the parotid glands.

#### LYMPHATICS OF THE UPPER EXTREMITY

The **Lymphatic Glands of the Upper Extremity** (fig. 440) are divided into two sets, *superficial* and *deep*.

The **superficial lymphatic glands** are few and of small size. There are occasionally two or three in front of the elbow, and one or two above the internal condyle of the humerus, near the basilic vein.

The **deep lymphatic glands** are few in number and are subdivided into those in the forearm, the arm, and the axilla. In the *forearm*, a few small ones are occasionally found in the course of the radial and ulnar vessels. In the *arm*, there is a chain of small glands along the inner side of the brachial artery. One, sometimes two, fairly constant glands are situated a little above and in front of the inner condyle of the humerus. In the *axilla* they are of large size, and usually ten or twelve in number. A chain of these glands surrounds the axillary vessels, embedded in a quantity of loose areolar tissue ; they receive the lymphatic vessels from the arm ; others are dispersed in the areolar tissue of the axilla : the remainder are arranged in two series, a small chain running along the lower border of the Pectoralis major, receiving the lymphatics from the front of the chest and mamma ; and others are placed along the lower margin of

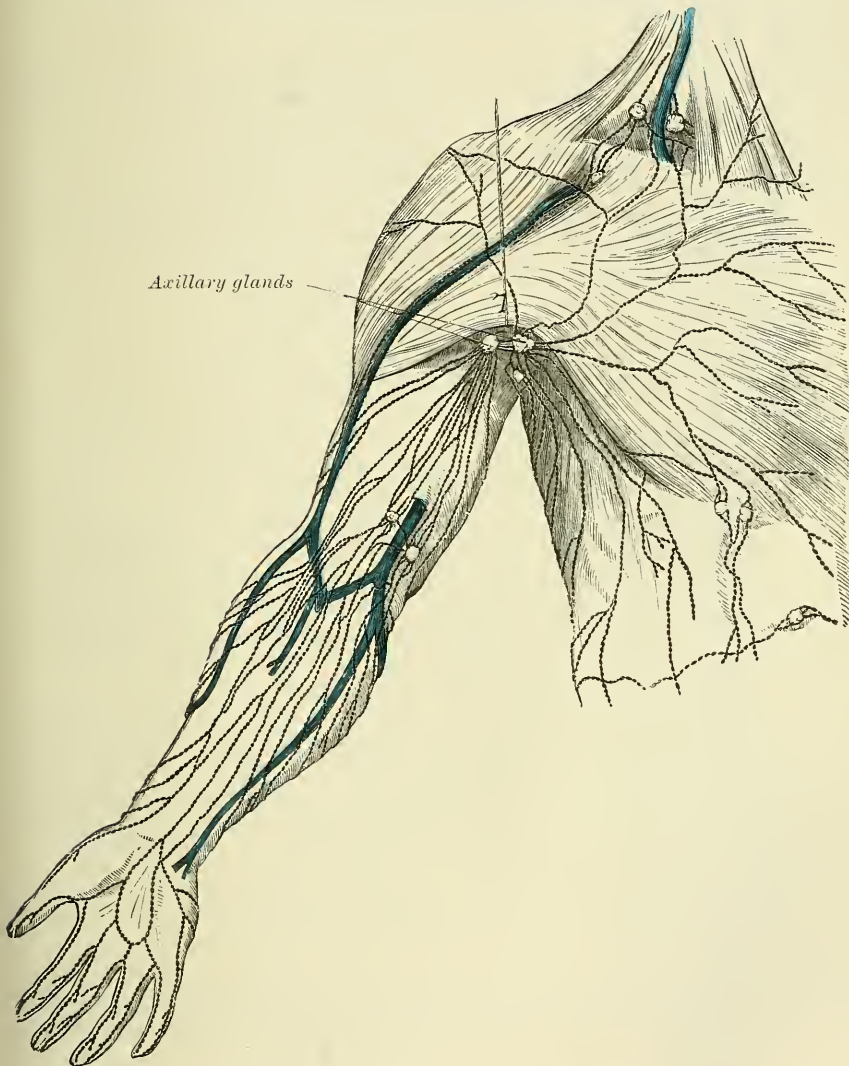


the posterior wall of the axilla, which receive the lymphatics from the integument of the back. Two or three subclavian lymphatic glands are placed immediately beneath the clavicle; it is through these that the axillary and deep cervical glands communicate with each other.

*Surgical Anatomy.*—In malignant diseases, tumours, or other affections implicating the upper part of the back and shoulder, the front of the chest and mamma, the upper part of the front and side of the abdomen, or the hand, forearm, and arm, the axillary glands are liable to be found enlarged.

The **lymphatic vessels of the upper extremity** are divided into two sets, *superficial* and *deep*.

FIG. 440.—The superficial lymphatics and glands of the upper extremity.



The **superficial lymphatic vessels of the upper extremity** commence on the fingers; two vessels running along either side of each finger, one on the palmar and the other on the dorsal surface. Those on the palmar surface form an arch in the palm of the hand, from which are derived two sets of vessels, which pass up the forearm, taking the course of the subcutaneous veins. The lymphatics from the dorsal surface of the fingers form a plexus on the back of the hand,

and, winding around the inner and outer borders of the forearm, unite with those in front. Those from the inner border of the hand accompany the ulnar veins along the inner side of the forearm to the bend of the elbow, where they are joined by some lymphatics from the outer side of the forearm; they then follow the course of the basilic vein, communicate with the glands immediately above the elbow, and terminate in the axillary glands, joining with the deep lymphatics. The superficial lymphatics from the outer and back part of the hand accompany the radial veins to the bend of the elbow. They are less numerous than the preceding. At the bend of the elbow, the greater number join the basilic group; the rest ascend with the cephalic vein on the outer side of the arm, some crossing the upper part of the Biceps obliquely, to terminate in the axillary glands, whilst one or two accompany the cephalic vein in the cellular interval between the Pectoralis major and Deltoid, and enter the subclavian lymphatic glands.

The **deep lymphatic vessels of the upper extremity** accompany the deep blood-vessels. In the forearm they consist of four sets, corresponding with the radial, ulnar, and interosseous arteries; they pass through the glands occasionally found in the course of those vessels, and communicate at intervals with the superficial lymphatics. In their course upwards, some of them pass through the glands which lie upon the brachial artery; they then enter the axillary and subclavian glands, and at the root of the neck terminate, on the left side, in the thoracic duct, and on the right side in the right lymphatic duct.

#### LYMPHATICS OF THE LOWER EXTREMITY

The **Lymphatic Glands of the Lower Extremity** are divided into two sets, *superficial* and *deep*. The superficial are confined to the inguinal region, forming the *superficial inguinal lymphatic glands*.

The **superficial inguinal lymphatic glands**, placed immediately beneath the integument, are of large size, and vary from eight to ten in number. They are divisible into two groups: an upper *oblique* set, disposed irregularly along Poupart's ligament, which receive the lymphatic vessels from the integument of the scrotum, penis, parietes of the abdomen, perineal and gluteal regions, and the mucous membrane of the urethra; and an inferior *vertical* set, which surround the saphenous opening in the fascia lata; a few being sometimes continued along the saphenous vein to a variable extent. This latter group receive the superficial lymphatic vessels from the lower extremity.

*Surgical Anatomy.*—These glands frequently become enlarged in diseases implicating the parts from which their lymphatics originate. Thus in malignant or syphilitic affections of the prepuce and penis, or of the labia majora in the female, in cancer scroti, in abscess in the perinæum, or in any other diseases affecting the integument and superficial structures in those parts, or the subumbilical part of the abdominal wall, or the gluteal region, the upper chain of glands is almost invariably enlarged, the lower chain being implicated in diseases affecting the lower limb.

The **deep lymphatic glands** are, the anterior tibial, popliteal, deep inguinal, gluteal, and ischiatic.

The **anterior tibial gland** is not constant in its existence. It is generally found by the side of the anterior tibial artery, upon the interosseous membrane at the upper part of the leg. Occasionally, two glands are found in this situation.

The **popliteal glands**, four or five in number, are of small size; they surround the popliteal vessels, embedded in the cellular tissue and fat of the popliteal space.

The **deep inguinal glands** are placed beneath the deep fascia around the femoral artery and vein. They are of small size, and communicate with the superficial inguinal glands through the saphenous opening.

The **gluteal and ischiatic glands** are placed, the former above, the latter

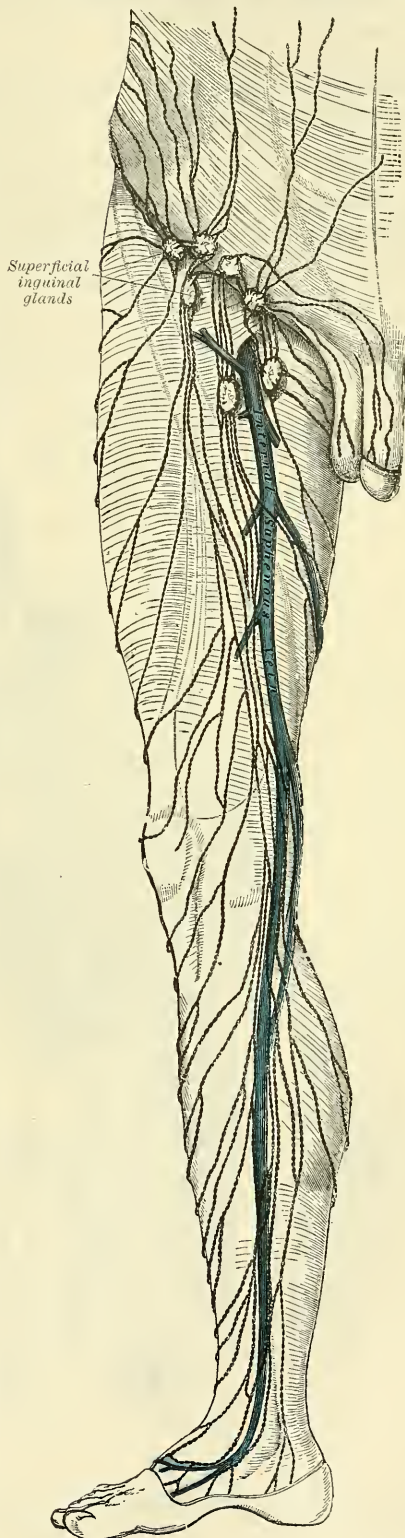
below, the Piriformis muscle, resting on their corresponding vessels as they pass through the great sacro-sciatic foramen.

The **Lymphatic Vessels of the Lower Extremity**, like the veins, may be divided into two sets, *superficial* and *deep*.

The **superficial lymphatic vessels** are placed beneath the integument in the superficial fascia, and are divisible into two groups: an internal group, which follow the course of the internal saphenous vein; and an external group, which accompany the external saphenous. The *internal group*, the larger, commence on the inner side and dorsum of the foot; they pass, some in front, and some behind the inner ankle, run up the leg with the internal saphenous vein, pass with it behind the inner condyle of the femur, and accompany it to the groin, where they terminate in the group of superficial inguinal lymphatic glands which surround the saphenous opening. Some of the efferent vessels from these glands pierce the cribriform fascia and sheath of the femoral vessels, and terminate in a lymphatic gland contained in the femoral canal, thus establishing a communication between the lymphatics of the lower extremity and those of the trunk; others pierce the fascia lata, and join the deep inguinal glands. The *external group* arise from the outer side of the foot, ascend in front of the leg, and, just below the knee, cross the tibia from without inwards, to join the lymphatics on the inner side of the thigh. Others commence on the outer side of the foot, pass behind the outer malleolus, and accompany the external saphenous vein along the back of the leg, where they enter the popliteal glands.

The **deep lymphatic vessels of the lower extremity** are few in number, and accompany the deep blood-vessels. In the leg, they consist of three sets, the anterior tibial, peroneal, and posterior tibial, which accompany the corresponding blood-vessels, two or three to each artery; they ascend with the blood-vessels, and enter the lymphatic glands in the popliteal

FIG. 441.—The superficial lymphatics and glands of the lower extremity.





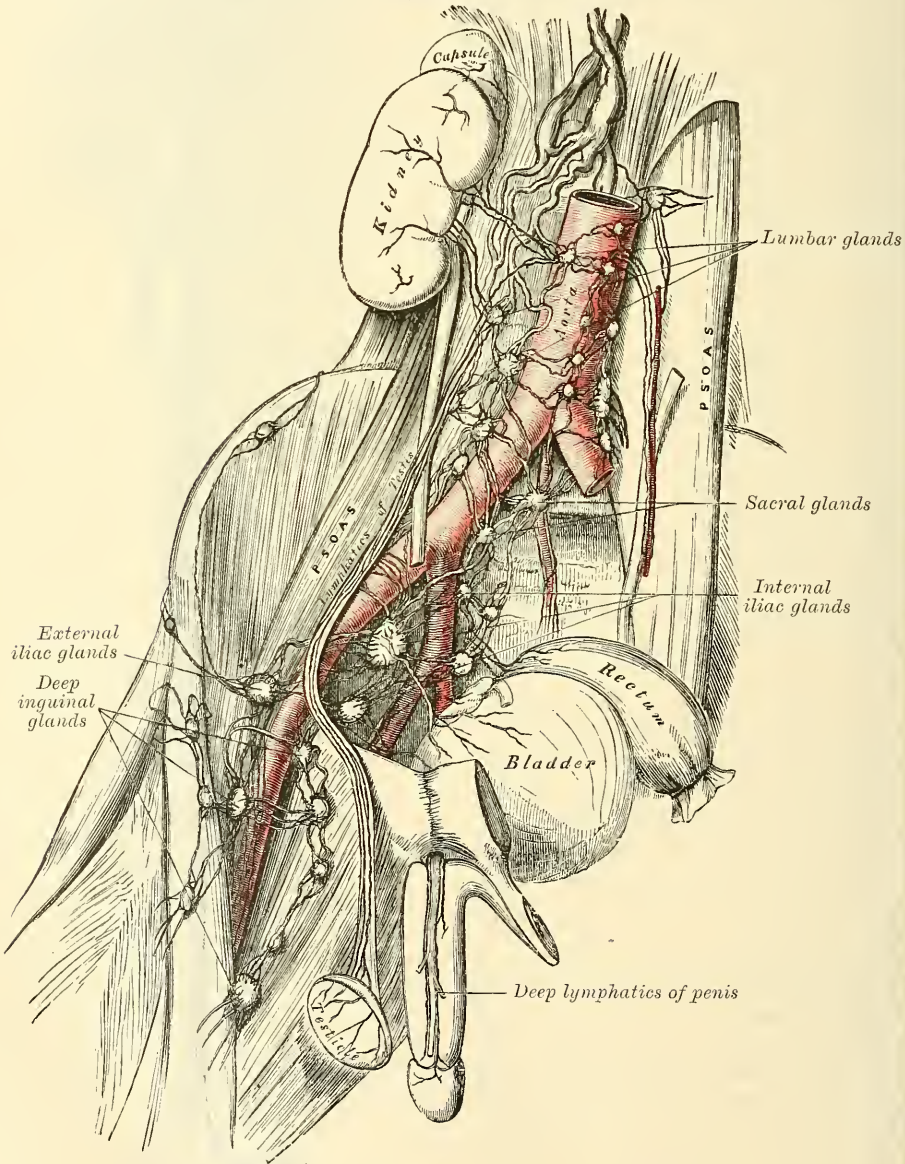
space; the efferent vessels from these glands accompany the femoral vein, and join the deep inguinal glands; from these, the vessels pass beneath Poupart's ligament, and communicate with the chain of glands surrounding the external iliac vessels.

The deep lymphatic vessels of the gluteal and ischiatic regions follow the course of the blood-vessels, and join the gluteal and ischiatic glands at the great sacro-sciatic foramen.

#### LYMPHATICS OF THE PELVIS AND ABDOMEN

The **Lymphatic Glands in the Pelvis** are, the external iliac, the internal iliac, and the sacral. Those of the abdomen are the lumbar glands.

FIG. 442.—The deep lymphatic vessels and glands of the abdomen and pelvis.



The **external iliac glands** form an uninterrupted chain round the external iliac vessels, three being placed round the commencement of the vessels just

behind the crural arch. They communicate below with the deep inguinal lymphatic glands, and above with the lumbar glands.

The **internal iliac glands** surround the internal iliac vessels; they receive the lymphatic vessels corresponding to the branches of the internal iliac artery, and communicate with the lumbar glands.

The **sacral glands** occupy the sides of the anterior surface of the sacrum, some being situated in the meso-rectal fold. These and the internal iliac glands are affected in malignant disease of the bladder, rectum, or uterus.

The **lumbar glands** are very numerous; they are situated on the front of the lumbar vertebræ, surrounding the common iliac vessels, the aorta, and vena cava; they receive the lymphatic vessels from the lower extremities and pelvis, as well as from the testes and some of the abdominal viscera; the efferent vessels from these glands unite into a few large trunks, which, with the lacteals, form the commencement of the thoracic duct. In addition to these there are a few small *lateral lumbar glands*, which lie between the transverse processes of the vertebræ, behind the Psoas muscle, and receive lymphatics from the back. In some cases of malignant disease these glands become enormously enlarged, completely surrounding the aorta and vena cava, and occasionally greatly contracting the calibre of those vessels. In all cases of malignant disease of the testis, and in malignant disease of the lower limb, before any operation is attempted, careful examination of the abdomen should be made, in order to ascertain if any enlargement exists; and if any should be detected, all operative measures should be avoided as fruitless.

The **Lymphatic Vessels of the Abdomen and Pelvis** may be divided into two sets, *superficial* and *deep*.

The **superficial lymphatic vessels of the walls of the abdomen and pelvis** follow the course of the superficial blood-vessels. Those derived from the integument of the lower part of the abdomen below the umbilicus follow the course of the superficial epigastric vessels and converge to the superior group of the superficial inguinal glands; a deeper set accompany the deep epigastric vessels, and communicate with the external iliac glands. The superficial lymphatics from the sides of the lumbar part of the abdominal wall wind round the crest of the ilium, accompanying the superficial circumflex iliac vessels, to join the superior group of the superficial inguinal glands; the greater number, however, run backwards along with the ilio-lumbar and lumbar vessels, to join the lateral lumbar glands.

The **superficial lymphatic vessels of the gluteal region** turn horizontally round the outer side of the nates, and join the superficial inguinal glands.

The **superficial lymphatic vessels of the scrotum and perinæum** follow the course of the external pudic vessels, and terminate in the superficial inguinal glands.

The **superficial lymphatic vessels of the penis** occupy the sides and dorsum of the organ, the latter receiving the lymphatics from the skin covering the glans penis; they all converge to the upper chain of the superficial inguinal glands. The **deep lymphatic vessels of the penis** follow the course of the internal pudic vessels, and join the internal iliac glands.

In the female, the lymphatic vessels of the mucous membrane of the labia, nymphæ, and clitoris terminate in the upper chain of the inguinal glands.

The **deep lymphatic vessels of the abdomen and pelvis** take the course of the principal blood-vessels. Those of the parietes of the pelvis, which accompany the gluteal, ischiatic, and obturator vessels, follow the course of the internal iliac artery, and ultimately join the lumbar lymphatics.

The efferent vessels from the inguinal glands enter the pelvis beneath Poupart's ligament, where they lie in close relation with the femoral vein; they then pass through the chain of glands surrounding the external iliac vessels, and finally terminate in the lumbar glands. They receive the deep epigastric and circumflex iliac lymphatics.



The **lymphatic vessels of the bladder** arise from the entire surface of the organ \*; the greater number run beneath the peritoneum on its posterior surface and, after passing through the lymphatic glands in that situation, join with the lymphatics from the prostate and vesiculæ seminales, and enter the internal iliac glands.

The **lymphatic vessels of the rectum** are of large size; after passing through some small glands that lie upon its outer wall and in the meso-rectum, they pass to the sacral glands.

The **lymphatic vessels of the uterus** consist of two sets, *superficial* and *deep*; the former being placed beneath the peritoneum, the latter in the substance of the organ. The lymphatics of the cervix uteri, together with those from the vagina, enter the internal iliac and sacral glands; those from the body and fundus of the uterus pass outwards in the broad ligaments, and, being joined by the lymphatics from the ovaries, broad ligaments, and Fallopian tubes, ascend with the ovarian vessels to open into the lumbar glands. In the unimpregnated uterus they are small; but during gestation they become very greatly enlarged.

The **lymphatic vessels of the testicle** consist of two sets, *superficial* and *deep*; the former commence on the surface of the tunica vaginalis, the latter in the epididymis and body of the testis. They form several large trunks, which ascend with the spermatic cord, and, accompanying the spermatic vessels into the abdomen, terminate in the lumbar glands; hence the enlargement of these glands in malignant disease of the testis.

The **lymphatic vessels of the kidney** arise on the surface, and also in the interior of the organ; they join at the hilum, and, after receiving the lymphatic vessels from the ureter and suprarenal capsules, open into the lumbar glands.

The **lymphatic vessels of the liver** are divisible into two sets, *superficial* and *deep*. The former arise in the subperitoneal areolar tissue over the entire surface of the organ. Those on the convex surface may be divided into four groups:—  
 1. Those which pass from behind forwards, consisting of three or four branches, which ascend in the longitudinal ligament, and unite to form a single trunk, which passes up between the fibres of the Diaphragm, behind the ensiform cartilage, to enter the anterior mediastinal glands, and finally ascends to the root of the neck, to terminate in the right lymphatic duct. 2. Another group, which also incline from behind forwards, are reflected over the anterior margin of the liver, to its under surface, and from thence pass along the longitudinal fissure to the glands in the gastro-hepatic omentum. 3. A third group incline outwards to the right lateral ligament, and, uniting into one or two large trunks, pierce the Diaphragm, and run along its upper surface to enter the anterior mediastinal glands; or, instead of entering the thorax, turn inwards across the crus of the Diaphragm, and open into the commencement of the thoracic duct. 4. The fourth group incline outwards from the surface of the left lobe of the liver to the left lateral ligament, pierce the Diaphragm, and, passing forwards, terminate in the glands in the anterior mediastinum.

The *superficial lymphatics on the under surface of the liver* are divided into three sets:—1. Those on the right side of the gall-bladder enter the lumbar glands. 2. Those surrounding the gall-bladder form a remarkable plexus; they accompany the hepatic vessels, and open into the glands in the gastro-hepatic omentum. 3. Those on the left of the gall-bladder pass to the œsophageal glands, and to the glands which are situated along the lesser curvature of the stomach.

The *deep lymphatics* accompany the branches of the portal vein and the hepatic artery and duct through the substance of the liver; passing out at the transverse fissure, they enter the lymphatic glands along the lesser curvature of the stomach and behind the pancreas, or join with one of the lacteal vessels previous to its termination in the thoracic duct.

\* Curnow states that they are confined to the base of the organ.



The **lymphatic glands of the stomach** are of small size ; they are placed along the lesser and greater curvatures, some within the gastro-splenic omentum, whilst others surround the cardiac and pyloric orifices.

The **lymphatic vessels of the stomach** consist of two sets, *superficial* and *deep* ; the former originating in the subserous, and the latter in the submucous coat. They follow the course of the blood-vessels, and may consequently be arranged into three groups. The *first group* accompany the gastric vessels along the lesser curvature, receiving branches from both surfaces of the organ, and pass to the glands around the pylorus. The *second group* pass from the great end of the stomach, accompanying the vasa brevia, and enter the splenic lymphatic glands. The *third group* run along the greater curvature with the right gastro-epiploic vessels, and terminate at the root of the mesentery in one of the principal lacteal vessels.

The **lymphatic glands of the spleen** occupy the hilum. Its *lymphatic vessels* consist of two sets, superficial and deep ; the former are placed beneath its peritoneal covering, the latter in the substance of the organ ; they accompany the blood-vessels, passing through a series of small glands, and, after receiving the lymphatics from the pancreas, ultimately pass into the thoracic duct.

#### THE LYMPHATIC SYSTEM OF THE INTESTINES

The **lymphatic glands of the small intestine** are placed between the layers of the mesentery, occupying the meshes formed by the superior mesenteric vessels, and hence called *mesenteric glands*. They vary in number from a hundred to a hundred and fifty ; and in size, from that of a pea to that of a small almond. These glands are most numerous, and largest above, near the duodenum, and below, opposite the termination of the ileum in the colon. This latter group becomes enlarged and infiltrated with deposit in cases of fever accompanied with ulceration of the intestines.

The **lymphatic glands of the large intestine** are much less numerous than the mesenteric glands ; they are situated along the vascular arches formed by the arteries previous to their distribution, and even sometimes upon the intestine itself. They are fewest in number along the transverse colon, where they form an uninterrupted chain with the mesenteric glands.

The **lymphatic vessels of the small intestine** are called **lacteals** from the milk-white fluid they usually contain ; they consist of two sets, superficial and deep : the former lie between the layers of the muscular coat and between the muscular and peritoneal coats, taking a longitudinal course along the outer side of the intestine ; the latter occupy the submucous tissue, and course transversely round the intestine, accompanied by the branches of the mesenteric vessels ; they pass between the layers of the mesentery, enter the mesenteric glands, and finally unite to form two or three large trunks which terminate in the thoracic duct.

The **lymphatic vessels of the large intestine** consist of two sets : those of the cæcum, ascending and transverse colon, which after passing through their proper glands, enter the mesenteric glands ; and those of the descending colon, sigmoid flexure, and rectum, which pass to the lumbar glands.

#### THE LYMPHATICS OF THE THORAX

The **Lymphatic Glands of the Thoracic Wall** are, the intercostal, internal mammary, anterior mediastinal, and posterior mediastinal.

The **intercostal glands** are small, irregular in number, and situated on each side of the spine, near the costo-vertebral articulations, some being placed between the two planes of intercostal muscles.

The **internal mammary glands** are placed at the anterior extremity of each intercostal space, by the side of the internal mammary vessels.

The **anterior mediastinal glands** are placed in the loose areolar tissue of the anterior mediastinum, some lying upon the Diaphragm in front of the pericardium, and others round the great vessels at the base of the heart.

The **posterior mediastinal glands** are situated in the areolar tissue in the posterior mediastinum, forming a continuous chain by the side of the aorta and œsophagus; they communicate on each side with the intercostal, below with the lumbar, and above with the deep cervical glands.

The **Superficial Lymphatic Vessels of the Front of the Thorax** run across the great Pectoral muscle, and those on the back part of this cavity lie upon the Trapezius and Latissimus dorsi; they all converge to the axillary glands. The lymphatics from the greater part of the mammary gland pass outwards to the lower border of the Pectoralis major muscle, where they enter a chain of small glands, situated in the axillary space along the lower border of its anterior boundary. Some few lymphatics from the inner side of the mammary gland pass through the intercostal spaces to reach the anterior mediastinal glands.

The **Deep Lymphatic Vessels of the Thoracic Wall** are, the intercostal, internal mammary, and diaphragmatic.

The **intercostal lymphatic vessels** follow the course of the intercostal vessels, receiving lymphatics from the intercostal muscles and pleura; they pass backwards to the spine, and unite with lymphatics from the back part of the thorax and spinal canal. After traversing the intercostal glands, they pass down the spine, and terminate in the thoracic duct.

The **internal mammary lymphatic vessels** follow the course of the internal mammary vessels; they commence in the muscles of the abdomen above the umbilicus, communicating with the epigastric lymphatics, ascend between the fibres of the Diaphragm at its attachment to the ensiform appendix, and in their course behind the costal cartilages are joined by the intercostal lymphatics; they terminate on the right side in the right lymphatic duct, on the left side in the thoracic duct.

The **lymphatic vessels of the Diaphragm** follow the course of their corresponding vessels, and terminate, some in front in the anterior mediastinal and internal mammary glands, some behind in the intercostal and posterior mediastinal lymphatics.

The **Lymphatic Glands of the Viscera of the Thorax** are the bronchial glands.

The **bronchial glands** are situated round the bifurcation of the trachea and roots of the lungs. They are ten or twelve in number, the largest being placed opposite the bifurcation of the trachea, the smallest round the bronchi and their primary divisions for some little distance within the substance of the lungs. In infancy they present the same appearance as lymphatic glands in other situations; in the adult they assume a brownish tinge, and in old age a deep black colour. Occasionally, they become sufficiently enlarged to compress and narrow the canal of the bronchi; and they are often the seat of tubercle or cretaceous deposits.

The **lymphatic vessels of the lung** consist of two sets, *superficial* and *deep*: the former are placed beneath the pleura, forming a minute plexus, which covers the outer surface of the lung; the latter accompany the blood-vessels, and run along the bronchi: they both terminate at the root of the lungs in the bronchial glands. The efferent vessels from these glands, two or three in number, ascend upon the trachea to the root of the neck, traverse the tracheal and œsophageal glands, and terminate on the left side in the thoracic duct, and on the right side in the right lymphatic duct.

The **cardiac lymphatic vessels** consist of two sets, *superficial* and *deep*: the former arise in the subserous areolar tissue of the surface, and the latter in the deeper tissues of the heart. They follow the course of the coronary vessels: those of the right side unite into a trunk at the root of the aorta, which, ascending across the arch of that vessel, passes backwards to the trachea, upon which it ascends, to terminate at the root of the neck in the right lymphatic duct. Those

of the left side unite into a single vessel at the base of the heart, which, passing along the pulmonary artery, and traversing some glands at the root of the aorta, ascends on the trachea to terminate in the thoracic duct.

The **thymic lymphatic vessels** arise from the under surface of the thymus gland, and terminate on each side in the internal jugular veins.

The **thyroid lymphatic vessels** arise from either lateral lobe of this organ ; they converge to form a short trunk, which terminates on the right side in the right lymphatic duct, on the left side in the thoracic duct.

The **lymphatic vessels of the œsophagus** form a plexus round that tube, traverse the glands in the posterior mediastinum, and after communicating with the pulmonary lymphatic vessels near the roots of the lungs, terminate in the thoracic duct.



## NERVOUS SYSTEM

THE Nervous System is composed: 1. Of a series of large centres of nerve-matter, called, collectively, the *cerebro-spinal centres* or *axis*. 2. Of smaller centres, termed *ganglia*. 3. Of *nerves*, connected either with the cerebro-spinal axis or the ganglia. And 4. Of certain modifications of the peripheral terminations of the nerves, forming the organs of the external senses.

The **Cerebro-spinal Centre** consists of two parts, the spinal cord and the encephalon: the latter may be subdivided into the cerebrum, the cerebellum, the pons Varolii, and the medulla oblongata.

### THE SPINAL CORD AND ITS MEMBRANES

*Dissection.*—To dissect the cord and its membranes, it will be necessary to lay open the whole length of the spinal canal. For this purpose, the muscles must be separated from the vertebral grooves, so as to expose the spinous processes and laminae of the vertebræ; and the latter must be sawn through on each side, close to the roots of the transverse processes, from the third or fourth cervical vertebra above, to the sacrum below. The vertebral arches having been displaced by means of a chisel, and the separate fragments removed, the dura mater will be exposed, covered by a plexus of veins and a quantity of loose areolar tissue, often infiltrated with serous fluid. The arches of the upper vertebræ are best divided by means of a strong pair of cutting bone-forceps.

### MEMBRANES OF THE CORD

The membranes which envelop the spinal cord are three in number. The most external is the *dura mater*, a strong fibrous membrane, which forms a loose sheath around the cord. The most internal is the *pia mater*, a cellulo-vascular membrane which closely invests the entire surface of the cord. Between the two is the *arachnoid membrane*, a non-vascular membrane, which envelops the cord, and is connected to the pia mater by slender filaments of connective tissue.

The **Dura Mater** of the cord, continuous with that which invests the brain, is a loose sheath which surrounds the cord, and is separated from the bony walls of the spinal canal by a quantity of loose areolar tissue, and a plexus of veins. It is attached to the circumference of the foramen magnum, and to the posterior common ligament, especially at the lower end of the spinal canal, by fibrous slips; and extends below as far as the second or third piece of the sacrum; here it converges to form a blunt cone, from the apex of which it descends as a sheath for the *filum terminale* to the back of the coccyx, where it blends with the periosteum. The sheath is much larger than is necessary for its contents, and its size is greater in the cervical and lumbar regions than in the dorsal. Its inner surface is smooth. On each side may be seen the double openings which transmit the two roots of the corresponding spinal nerve, the fibrous layer of the dura mater being continued in the form of a tubular prolongation on them as they pass through these apertures. These prolongations of the dura mater are short in the upper part of the spine, but become gradually longer below, forming a number of tubes of fibrous membrane, which enclose the sacral nerves, and are contained in the spinal canal.

The chief peculiarities of the dura mater of the cord, as compared with that investing the brain, are the following:—

The dura mater of the cord is not adherent to the bones of the spinal canal, which have an independent periosteum.

It does not send partitions into the fissures of the cord, as in the brain.

Its fibrous laminae do not separate, to form venous sinuses, as in the brain.

**Structure.**—The dura mater consists of white fibrous and elastic tissue, arranged in bands or lamellae, which, for the most part, are parallel with one another and have a longitudinal arrangement. Its internal surface is covered by a layer of endothelial cells, which gives this surface its smooth appearance. It is sparingly supplied with vessels; and some few nerves have been traced into it.

The **Arachnoid** is exposed by slitting up the dura mater, and reflecting that membrane to either side (fig. 443). It is a thin, delicate, tubular membrane, which invests the surface of the cord, and is connected to the pia mater by slender filaments of connective tissue. Above, it is continuous with the cerebral arachnoid; on each side it is continued on the various nerves, so as to form a sheath for them as they pass outwards to the intervertebral foramina. The outer surface of the arachnoid is in contact with the inner surface of the dura mater, and the two are, here and there, connected together by isolated connective-tissue trabeculae, especially on the posterior surface of the cord. For the most part, however, the membranes are not connected together, and the interval between them is named the *subdural space*. The inner surface of the arachnoid is separated from the pia mater by a considerable interval, which is called the *subarachnoid space*. The space is largest at the lower part of the spinal canal, and encloses the mass of nerves which form the cauda equina. Superiorly it is continuous with the cranial subarachnoid space, and communicates with the general ventricular cavity of the brain, by means of an opening in the pia mater, at the inferior boundary of the fourth ventricle (*foramen of Majendie*). It contains an abundant serous secretion, the *cerebro-spinal fluid*. This secretion is sufficient in amount

to expand the arachnoid membrane, so as to completely fill up the whole of the space included in the dura mater. The subarachnoid space is occupied by trabeculae of delicate connective tissue, connecting the pia mater on the one hand with the arachnoid membrane on the other. This is named *subarachnoid tissue*. In addition to this it is partially subdivided by a longitudinal membranous partition, which serves to connect the arachnoid with the pia mater, opposite the posterior median fissure. This partition is incomplete, and cribriform in structure, consisting of bundles of white fibrous tissue, interlacing with each other. This space is to be regarded as, in reality, a great lymph-space, from which the lymph carried to it by the perivascular lymphatics (see page 58) is conveyed back into the circulation.

**Structure.**—The arachnoid is a delicate membrane, made up of closely arranged interlacing bundles of connective tissue in several layers.

The **Pia Mater** of the cord is exposed on the removal of the arachnoid

Fig. 443.—The spinal cord and its membranes.

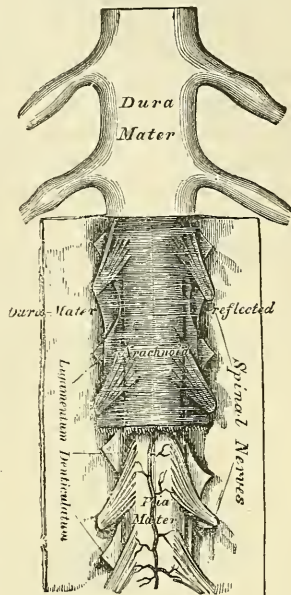
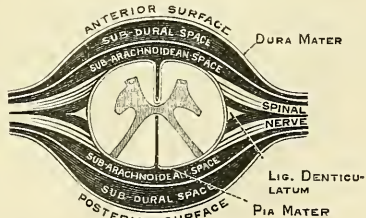


Fig. 444.—Transverse section of the spinal cord and its membranes.



(fig. 443). It covers the entire surface of the cord, to which it is very intimately adherent, forming its neurilemma, and sending a process downwards into its anterior fissure. It also forms a sheath for each of the filaments of the spinal nerves, and invests the nerves themselves. A longitudinal fibrous band extends along the middle line on its anterior surface, called by Haller the *linea splendens*; and a somewhat similar band, the *ligamentum denticulatum*, is situated on each side. At the point where the cord terminates, the pia mater becomes contracted, and is continued down as a long, slender filament (*filum terminale*), which descends through the centre of the mass of nerves forming the cauda equina, and is blended with the sheath of dura mater, on a level with the second or third sacral vertebra. It assists in maintaining the cord in its position during the movements of the trunk, and is from this circumstance called the *central ligament* of the spinal cord. It contains a little grey nervous substance, which may be traced for some distance into its upper part, and is accompanied by a small artery and vein. At the upper part of the cord, the pia mater presents a greyish, mottled tint, which is owing to yellow or brown pigment-cells scattered among the elastic fibres.

**Structure.**—The pia mater of the cord is less vascular in structure, but thicker and denser, than the pia mater of the brain, with which it is continuous. It consists of two layers: an outer composed of bundles of connective-tissue fibres, arranged for the most part longitudinally; and an inner consisting of stiff bundles of the same tissue, which present peculiar angular bends, and is covered on both surfaces by a layer of endothelium. Between the two layers are a number of cleft-like lymphatic spaces, which communicate with the subarachnoid cavity, and a number of blood-vessels, which are enclosed in a perivascular sheath, derived from the inner layer of the pia mater, into which the lymphatic spaces open. It is also supplied with nerves, which are derived from the sympathetic.

The **Ligamentum Denticulatum** (fig. 443) is a narrow fibrous band, situated on each side of the spinal cord, throughout its entire length, and separating the anterior from the posterior roots of the spinal nerves. It has received its name from the serrated appearance which it presents. Its inner border is continuous with the pia mater, at the side of the cord. Its outer border presents a series of triangular, dentated serrations, the points of which are fixed at intervals to the dura mater. These serrations are twenty-one in number, on each side, the first being attached to the dura mater, opposite the margin of the foramen magnum between the vertebral artery and the hypoglossal nerve; and the last near the lower end of the cord. Its use is to support the cord in the fluid by which it is surrounded.

*Surgical Anatomy.*—Evidence of great value in the diagnosis of meningitis may be obtained by puncturing the theca of the cord and withdrawing some of the cerebro-spinal fluid, and the operation is regarded by some as curative, under the supposition that the draining away of the cerebro-spinal fluid would relieve the patient by diminishing the intra-cranial pressure. The operation is performed by inserting a trocar, of the smallest size, between the lamina of the third and fourth or the fourth and fifth lumbar vertebrae through the ligamentum subflava. The spinal cord even of a child at birth does not reach below the third lumbar vertebra, and therefore the canal may be punctured between the third and fourth vertebra without any risk of injuring its contents. The point of puncture is indicated by laying the child on its side and dropping a perpendicular line from the highest point of the crest of the ilium; this will cross the upper border of the spine of the fourth lumbar vertebra, and will indicate the level at which the trocar should be inserted a little to one side of the median line.

#### THE SPINAL CORD

The **Spinal Cord** (*medulla spinalis*) is the cylindrical elongated part of the cerebro-spinal axis which is contained in the vertebral canal. Its length is usually about seventeen or eighteen inches, and its weight, when divested of its membranes and nerves, about one ounce and a half; its proportion to the



encephalon being about 1 to 33. It does not nearly fill the canal in which it is contained, its investing membranes being separated from the surrounding walls by areolar tissue and a plexus of veins. It occupies, in the adult, the upper two-thirds of the vertebral canal, extending from the upper border of the atlas to the lower border of the body of the first lumbar vertebra, where it terminates in a slender filament of grey substance, which is continued for some distance into the *filum terminale*. In the foetus, before the third month it extends to the bottom of the sacral canal; but after this period it gradually recedes from below, as the growth of the bones composing the canal is more rapid in proportion than that of the cord; so that in the child at birth the cord extends as far as the third lumbar vertebra. Its position varies also according to the degree of curvature of the spinal column, being raised somewhat in flexion of the spine. On examining its surface, it presents a difference in its diameter in different parts, being marked by two enlargements, an upper or cervical, and a lower or lumbar. The cervical enlargement, which is the larger, extends from about the third cervical to the first or second dorsal vertebra: its greatest diameter is in the transverse direction, and it corresponds with the origin of the nerves which supply the upper extremities. The lower, or lumbar, enlargement is situated opposite the last two or three dorsal vertebrae, its greatest diameter being from before backwards. It corresponds with the origin of the nerves which supply the lower extremities. In form, the spinal cord is a flattened cylinder.

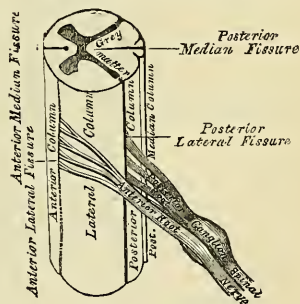
**Fissures.**—It presents on its anterior surface, along the middle line, a longitudinal fissure, the *anterior median fissure*; and, on its posterior surface, another fissure, which also extends along the entire length of the cord, the *posterior median fissure*. These fissures penetrate through the greater part of the thickness of the cord, and incompletely divide it into two symmetrical halves, united in the middle line by a transverse band of nervous substance, the *commissure*.

The **Anterior Median Fissure** is wider, but of less depth than the posterior, extending into the cord for about one-third of its thickness, and is deepest at the lower part of the cord. It contains a prolongation from the pia mater; and its floor is formed by the *anterior white commissure*, which is perforated by numerous blood-vessels, passing to the centre of the cord.

The **Posterior Median Fissure** is not an actual fissure, as the space between the lateral halves of the posterior part of the cord is crossed by connective tissue and numerous blood-vessels, so that no actual hiatus exists, and there is consequently no prolongation of the pia mater into it. It extends into the cord to about one half its depth, and its floor is formed by the *posterior grey commissure*.

**Lateral Fissures.**—On each side of the posterior median fissure, along the line of attachment of the posterior roots of the nerves, a delicate fissure may be seen, leading down to the grey matter which approaches the surface in this situation; this is called the *postero-lateral fissure* of the spinal cord. On the posterior surface of the spinal cord, between the posterior median fissure and the postero-lateral fissure on each side, is a slight longitudinal furrow, marking off two slender tracts, the *posterior median columns*. These are most distinct in the cervical region, but are stated by Foville to exist throughout the whole length of the cord. On each side of the anterior median fissure is the place of origin of the anterior roots of the spinal nerves as they emerge from the cord. This is called, by some anatomists, the *antero-lateral fissure* of the cord, although no actual fissure exists in this situation, for the anterior roots enter the cord in several bundles, which spread over a longitudinal strip of some breadth.

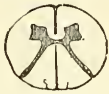FIG. 445.—Spinal cord. Side view. Plan of the fissures and columns.



**Columns of the Cord.**—Each half of the spinal cord is thus divided into four columns: an anterior column, a lateral column, a posterior column, and a posterior median column. This division, however, is very imperfect, since the limit between the so-called anterior and lateral columns cannot be defined on account of the bundles of the anterior roots being spread over a considerable area. It is therefore customary to divide each half of the spinal cord into a small *posterior column*, which is bounded internally by the posterior median fissure, and externally by the postero-lateral fissure and a large *antero-lateral column*, which comprises the rest of the cord.

**Structure of the Cord.**—If a transverse section of the spinal cord be made, it will be seen to consist of white and grey nervous substance. The white matter is situated externally, and constitutes the greater part. The grey substance occupies the centre, and is so arranged as to present on the surface of the section two crescentic masses, placed one in each lateral half of the cord, united together by a transverse band of grey matter, the *grey commissure*. Each crescentic mass has an anterior (ventral) and posterior (dorsal) horn. The posterior horn is long

FIG. 446.—Transverse sections of the cord.



Opposite middle of cervical region.

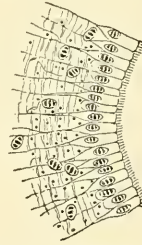


Opposite middle of dorsal region.



Opposite lumbar region.

FIG. 447.—From a transverse section through the spinal cord of a calf. Magnified about 180 diameters, showing part of the central canal and the tissue immediately around it, viz. the central grey nucleus. (Klein and Noble Smith.)



The canal is lined with epithelium, composed of ciliated, more or less conical, cells; in most instances a filamentous process passes from the cell into the tissue underneath. This tissue contains, in a hyaline matrix, a network of fibrils; most of these run horizontally; others have a longitudinal course, and appear therefore here cut transversely, i.e. as small dots. The nuclei correspond to the cells of the neuroglia, the cell-substance not being shown. Both the nuclei of the neuroglia cells and those of the epithelium contain three or more large disc-shaped particles.

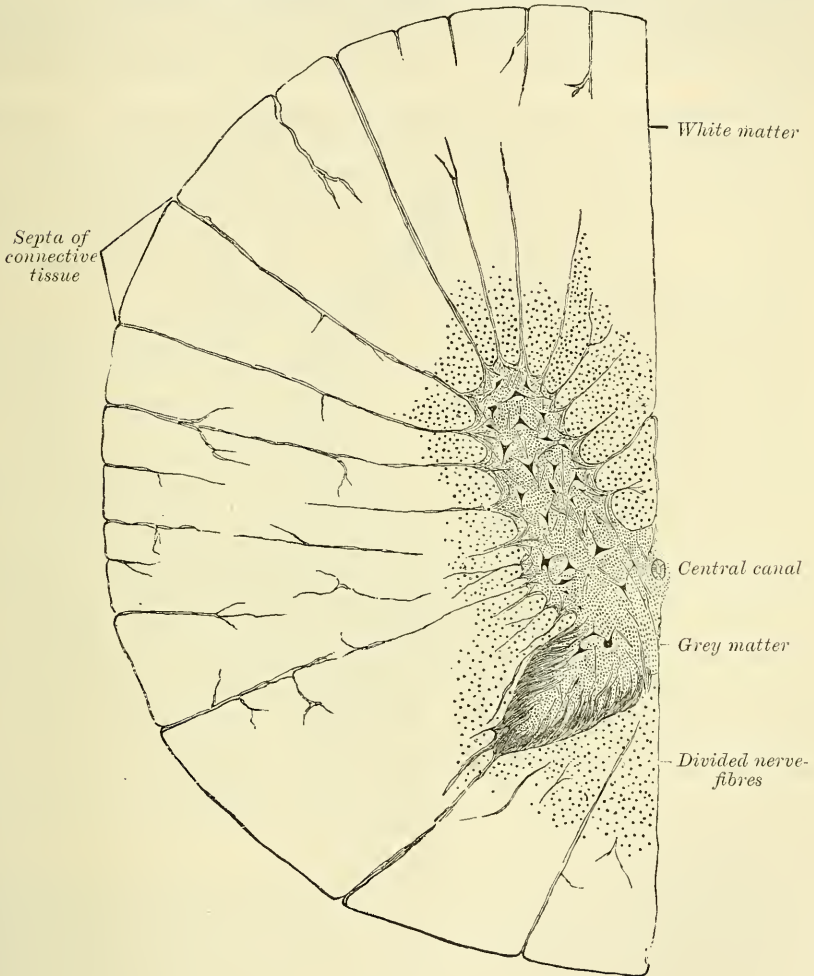
and narrow, and approaches the surface of the postero-lateral fissure, near which it presents a slight enlargement, the *caput cornu*: from this it tapers, to form the *apex cornu*, which at the surface of the cord becomes continuous with the fibres of the posterior roots of the spinal nerves. The anterior horn is short and thick, and does not quite reach the surface, but extends towards the point of attachment of the anterior roots of the nerves. Its margin presents a dentate or stellate appearance. Owing to the projections towards the surface of the anterior and posterior horns of the grey matter, each half of the cord is divided, more or less completely, into three columns, anterior, middle, and posterior: the anterior and middle being joined to form the antero-lateral column, as the anterior horn does not quite reach the surface.

The **commissure of the spinal cord** is composed of white and grey fibres, hence called the white and grey commissures. The *white commissure* is formed of medullated nerve-fibres, which pass horizontally between the grey matter of the anterior horn and the anterior white column of the one side into similar parts on the other. The fibres are oblique in direction; many which enter at the posterior part of the commissure on the one side leave it at the anterior part of

the commissure on the other, and *vice versâ*, a decussation taking place in the middle line.

The *grey commissure*, which connects the two crescentic masses of grey matter, is separated from the bottom of the anterior median fissure by the anterior white commissure. It consists of transverse medullated nerve-fibres, with a considerable quantity of neuroglia between them. The fibres when they reach the lateral crescents diverge: some pass backwards to the posterior roots; others spread out, at various angles, into the crescent.

FIG. 448.—Transverse section through the cervical portion of the spinal cord of a calf. Magnified 40 diameters. (Klein and Noble Smith.)



Running through the grey commissure of the whole length of the cord is a minute canal, which is barely visible to the naked eye in the human cord, but is proportionally larger in some of the lower vertebrata. It is called the *central canal*, and opens above into the fourth ventricle, and terminates below in a somewhat dilated extremity. It is surrounded by an area of neuroglia, which, in a recent state, has a gelatinous appearance, and in which there are no fibres. This is sometimes called the *substantia gelatinosa centralis*. When hardened in alcohol or chromic salts it has a finely reticulated appearance. The canal is lined in the fœtus by columnar ciliated epithelium, but in the adult the cilia have disappeared, and the canal is filled with their remains.



The mode of arrangement of the grey matter, and its amount in proportion to the white, vary in different parts of the cord. Thus, the posterior horns are long and narrow, in the cervical region; short and narrower, in the dorsal; short, but wider, in the lumbar region. In the cervical region, the crescentic portions are small, and the white matter more abundant than in any other region of the cord. In the dorsal region, the grey matter is least developed, the white matter being also small in quantity. In the lumbar region, the grey matter is more abundant than in any other region of the cord. Towards the lower end of the cord, the white matter gradually ceases. The crescentic portions of the grey matter soon blend into a single mass, which forms the only constituent of the extreme point of the cord.

**Minute Anatomy of the Cord.**—The cord consists of an outer part, composed of medullated nerve-fibres, which is the *white substance*; and of a central part, the *grey matter*: both supported in a peculiar kind of connective tissue, called *neuroglia*.

The **neuroglia** consists of a homogeneous transparent matrix, of a network of very delicate fibrillæ, and of stellate or branched cells, the *neuroglia cells*.

In addition to forming a ground substance, in which the nerve-fibres, nerve-cells, and blood-vessels are embedded, a considerable accumulation of neuroglia takes place in three situations—(1) on the surface of the cord, beneath the pia mater; (2) around the central canal; and (3) in the posterior part of the posterior horn, forming the *substantia cinerea gelatinosa*.

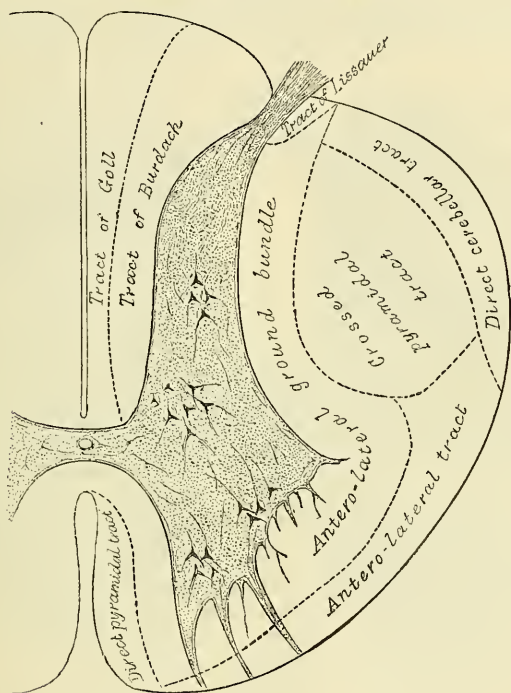
The **white substance of the cord** consists of medullated nerve-fibres, disposed longitudinally, with blood-vessels and neuroglia. On transverse section of the white substance of the cord, stained with carmine, a very striking object is presented. It is seen to be studded all over with minute dots, surrounded by a white area, and this again by a dark circle (fig. 453). This is due to the longitudinal medullated fibres seen on section. The dot is the axis-cylinder, the white area the substance of Schwann, and the dark circle the tubular membrane of the fibres, which seems to consist of several laminae. Externally, the neuroglia is seen to form a sheath closely investing the outer surface of the cord immediately beneath the pia mater, from which numerous septa pass inwards and separate the respective bundles of fibres and extend between the individual nerve-fibres, acting as a supporting medium, in which they are embedded.

There are, however, also oblique and transverse fibres in the white substance. These are principally found (1) at the bottom of the anterior median fissure, forming the white commissure; the fibres passing from the grey matter of the anterior horn and the white matter of the anterior column of the one side to that of the other; (2) horizontal or oblique fibres passing from the roots of the nerves into the grey matter; and (3) fibres leaving the grey matter and pursuing a longer or shorter horizontal course between the bundles of longitudinal fibres with which many of them are continuous.

**Conducting tracts.**—It is impossible to trace the course of the nerve-fibres in their passage through the cord; but the investigation of pathological lesions has shown that the white matter of the cord consists of certain columns or tracts of fibres; for it has been found that separate lesions are strictly limited to certain well-determined parts of the cord without involving neighbouring regions. That these parts or fasciculi correspond to so many distinct anatomical systems, each endowed with special functions, seems abundantly proved by the researches of Flechsig and others on the development of the spinal cord during the later periods of utero-gestation and in the newly born infant. By these researches several tracts can be traced along the greater part of the cord and into or from the encephalon. Thus (1) in the antero-lateral column of the cord, on either side of the anterior median fissure, a portion of the column may be divided off as the *direct pyramidal tract* (*Fasciculus of Türck*). This tract is only found in the upper part of the cord, it gradually diminishes as it is traced downwards, and disappears about the middle of the dorsal region of the cord. It consists of

centrifugal or descending fibres, which can be traced downwards from the pyramid of the medulla of the same side, and which are derived from the motor area of the cerebral cortex. It is believed that the fibres of this tract decussate in their course down the cord, and gradually pass through the anterior white commissure and through the grey matter of the opposite side to the crossed pyramidal tract, and that this explains the gradual diminution and eventual disappearance of the tract. (2) In the hinder part of the antero-lateral column is a somewhat triangular area, larger than the preceding, which is named the *crossed pyramidal tract*. This also consists of descending fibres, which are derived from the pyramid of the medulla of the opposite side, decussation taking place at the upper part of the cord. The fibres are derived from the motor area of the cerebral cortex of the opposite side to the tract. Thus it will be seen that all the fibres from the motor area, which descend through the internal capsule, the crus cerebri and the pons Varolii to the pyramidal body of the medulla,

FIG. 449.—Columns of the cord.



decussate; some at the upper part of the cord, and these descend through it as the crossed pyramidal tract; and others, which descend as the direct pyramidal tract and cross through the anterior commissure of the cord to reach the crossed pyramidal tract of the opposite side. (3) The *antero-lateral tract* (Gower's tract) is an extensive tract which skirts the circumference of the anterior three-quarters of the antero-lateral column of the cord. It extends from the front of the crossed pyramidal tract where it is thickest, and gradually narrows off as it reaches the direct pyramidal tract. It consists of centripetal or ascending fibres derived from the posterior roots of the spinal nerves, and can be traced upwards through the medulla and pons to the cerebellum. If the spinal cord is divided in the cervical region some scattered fibres in this column degenerate in a downward direction. This would seem to prove therefore that it contains some descending fibres, which are believed to be derived from the cerebellum of the same side. (4) The *direct cerebellar tract* is situated at the circumference of the cord behind the preceding and external to the crossed pyramidal tract,

occupying a narrow area which extends backwards as far as the postero-lateral fissure, or nearly so. It commences at the level of the upper lumbar region, and increases in size as it ascends and passes through the restiform body of the medulla to the cerebellum. Its fibres are derived from the cells of the posterior vesicular column of Clarke in the grey matter of the cord. (5) Close to the point where the posterior roots enter the cord, in the antero-lateral column, is a small collection of fibres, which is known as the *tract of Lissauer*; it is formed by some of the fibres of the posterior roots which run upwards in the tract for a short distance, and then enter the posterior horn of the grey matter. (6) The rest of the antero-lateral column of the spinal cord is occupied by the *antero-lateral ground bundle*. It surrounds the anterior cornu and separates the antero-lateral tract and the crossed pyramidal tract from the grey matter of the cord. It consists of

(a) longitudinal commissural fibres, which unite the groups of cells in the anterior horn with one another; (b) of fibres which pass across the anterior commissure from the grey matter of the opposite side; and (c) fibres belonging to the anterior roots of the nerves, which pass through it before leaving the cord.

In the posterior column of the cord there are two tracts. They are marked off from each other by the slight longitudinal furrow on the surface of the cord. The part which has been described previously as the posterior median column pretty nearly corresponds to the one tract, the *tract of Goll*, and the remainder of the posterior column corresponding to the other, the *tract of Burdach*. (7) The *tract of Goll* consists of long, small fibres derived from the posterior roots of

the spinal nerves, which ascend to the medulla oblongata, where they end in the nucleus gracilis. The tract increases as it ascends. (8) The *tract of Burdach* consists of shorter, but larger, fibres than the preceding; they are, however, derived from the same source, the posterior roots; they ascend only for a short distance in the tract, and then enter the grey matter and come into close relationship with the posterior vesicular column of Clarke.

The **grey substance of the cord** occupies its central part in the shape of two crescentic horns, joined together by a commissure. Each of these crescents has an anterior and posterior cornu.

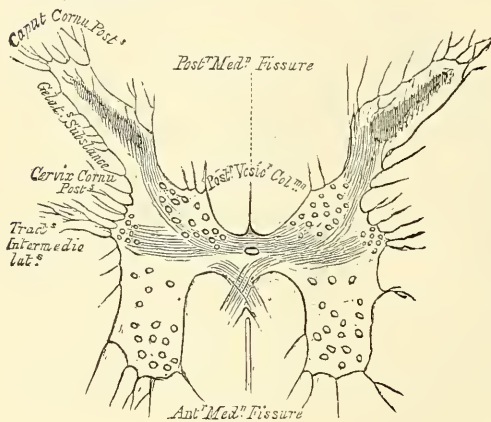
The *posterior horn* consists of a slightly narrowed portion, at its base, where it is connected with the rest of the grey substance—this is the *cervix cornu*; from this it gradually expands into the main part of the horn, the *caput cornu*; around its extremity is a lamina or layer of gelatinous material, which covers the head like a cap, and from this it tapers almost to a point, which approaches the surface of the cord at the postero-lateral groove.

The gelatinous substance is a peculiar accumulation of neuroglia (Klein) similar to that found around the central canal (page 717), and has been named by Rolando the *substantia cinerea gelatinosa*.

The *anterior horn of the grey substance* in the cervical and lumbar swellings, where it gives origin to the nerves of the extremities, is much larger than in any other region, and contains several distinct groups of large and variously shaped cells.

In addition to this, in certain parts of the cord, other horns or projections of

FIG. 450.—Transverse section of the grey substance of the spinal cord, near the middle of the dorsal region. Magnified 13 diameters.





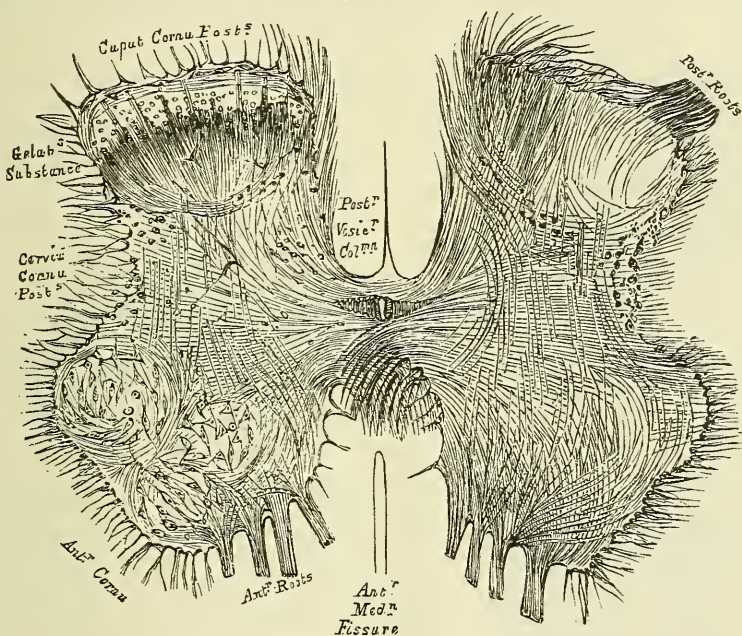
the grey matter may be seen on transverse section. One of these, the *lateral horn*, is found projecting outwards from the lateral region of the grey matter on a level with the grey commissure in the cervical and upper part of the dorsal region of the cord; and a second, *Clarke's vesicular column*, is found on the inner side of the posterior horn near the grey commissure, in the upper cervical or dorsal regions, or at the point of exit of the lower lumbar nerves.

The grey commissure is situated behind the white commissure, which separates it from the bottom of the anterior median fissure.

The **grey substance of the cord** consists of—(1) nerve-fibres of variable but smaller average diameter than those of the columns; (2) nerve-cells of various shapes and sizes, with from two to eight processes; (3) blood vessels and connective tissue.

The *nerve-fibres* of the grey matter of the posterior horn are for the most part composed of a minute and dense network of minute fibrils, which is termed

FIG. 451.—Transverse section of the grey substance of the spinal cord through the middle of the lumbar enlargement. On the left side of the figure groups of large cells are seen; on the right side, the course of the fibres is shown without the cells. Magnified 13 diameters.



'Gerlach's nerve network,' intermingled with nerves of a larger size. This network is continuous with the medullated fibres of the posterior nerve-roots on the one hand (Dieters), and with the branched processes of the ganglion-cells on the other (Gerlach), so that the ganglion-cells are connected with the medullated fibres of the posterior nerve-roots only indirectly through the nerve network. The arrangement of the fibres in the anterior horn of the grey matter appears to be somewhat different; here the medullated fibres of the anterior nerve-roots are directly continuous with some of the processes of the ganglion cells, others of the processes of the ganglion-cells communicating with Gerlach's nerve network.

The *nerve-cells* of the grey matter are of two kinds, (1) large branched nerve-vesicles which are collected into groups as seen on transverse section, but which are really columns of cells placed longitudinally in the grey matter; and (2) small round cells which resemble free nuclei, and are found scattered throughout the whole of the grey matter.

In the anterior horn is a constant group, situated at the anterior part of the

cornu, and sometimes termed the *vesicular column of the anterior cornu*. It consists of two groups of cells: one mesial, near the anterior column; the other lateral, near the lateral column. At the base of the posterior horn on its inner side, and joining the grey commissure, is a group of nerve-cells, which give rise to the projection mentioned above as being seen on transverse section in the upper part of the cord, which is called *Clarke's posterior vesicular column*.

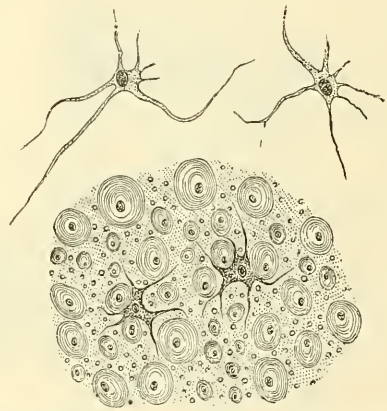
At the junction of the anterior and posterior cornu, in the outer portion of the grey matter, is a third group of cells, the *tractus intermedio-lateralis*. In certain regions of the cord these cells extend in amongst the fibres of the white matter of the lateral column, and give rise to the lateral horn. In addition to these groups a few large scattered cells are found in the posterior horn, extending into the *substantia cinerea gelatinosa*.

**Origin of the Spinal Nerves.**—The roots of the spinal nerves are attached to the surface of the cord, opposite the horns of grey matter, and the deep origin of

FIG. 452.—Longitudinal section of the white and grey substance of the spinal cord, through the middle of the lumbar enlargement. Magnified 14 diameters.

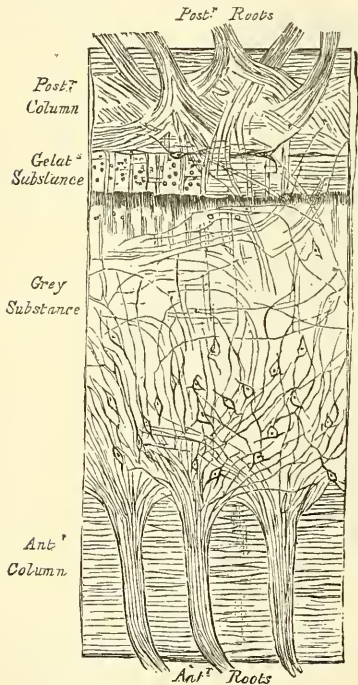

FIG. 453.—Transverse section through the white matter of the spinal cord of a calf. Magnified about 300 diameters. (Klein and Noble Smith.)



In the upper part are shown two isolated flattened nucleated cells of the neuroglia, under a somewhat higher power than the rest. In the bulk of the figure the nerve-fibres are seen in transverse section. They are of different sizes, and possess a laminated medullary sheath surrounding the axis-cylinder; which was deeply stained in the preparation, and is here represented by a black dot. The nerve-fibres are embedded in the neuroglia. This contains, in a matrix, which appears sometimes granular, sometimes homogeneous, numerous elastic fibrils, seen here in transverse section as minute dots, on account of their having a course parallel to the long axis of the cord. Amongst the neuroglia are also seen two branched connective-tissue cells—neuroglia cells.

their fibres is from nerve-cells embedded in the grey matter, either directly or through Gerlach's nerve network. The fibres of the anterior roots after traversing the white matter enter the anterior horn of grey matter; here they join cells and eventually pass in four different directions, (1) some to the direct pyramidal tract of the same side, (2) others to the crossed pyramidal of the same side, (3) a third set, across the commissure to the opposite side, and (4) a last set, into the tractus intermedio-lateralis. The fibres of the posterior root consist of two sets (1) one, the lateral fibres pass upwards in the tract of Lissauer and then enter the posterior horn; (2) the other, or mesial set, enter Burdach's column and pass in different directions, some to the nerve-cells in the posterior horn, others to the cells in Clarke's column, and others to Goll's column, either of the same or opposite side of the body.



## THE BRAIN AND ITS MEMBRANES

*Dissection.*—To examine the brain with its membranes, the skull-cap must be removed. In order to effect this, saw through the external table, the section commencing, in front, about an inch above the margin of the orbit, and extending, behind, to a level with the occipital protuberance. Then break the internal table with the chisel and hammer, to avoid injuring the investing membranes or brain; loosen, and forcibly detach the skull-cap, when the dura mater will be exposed. The adhesion between the bone and the dura mater is very intimate, and much more so in the young subject than in the adult.

The membranes of the brain are, the dura mater, arachnoid membrane, and pia mater.

## DURA MATER

The **Dura Mater** is a thick and dense inelastic fibrous membrane, which lines the interior of the skull. Its outer surface is rough and fibrillated, and adheres closely to the inner surface of the bones, forming their internal periosteum, this adhesion being most marked opposite the sutures and at the base of the skull. Its inner surface is smooth, and lined by a layer of epithelial cells. It sends three processes inwards, into the cavity of the skull, for the support and protection of the different parts of the brain: and is prolonged to the outer surface of the skull, through the various foramina which exist at the base, and thus becomes continuous with the pericranium; its fibrous layer forms sheaths for the nerves which pass through these apertures. At the base of the skull, it sends a fibrous prolongation into the foramen cæcum; it sends a series of tubular prolongations round the filaments of the olfactory nerves as they pass through the cribriform plate, and also round the nasal nerve as it passes through the nasal slit; a prolongation is also continued through the sphenoidal fissure into the orbit, and another is continued into the same cavity through the optic foramen forming a sheath for the optic nerve, which is continued as far as the eyeball. In the posterior fossa it sends a process down the internal auditory meatus, ensheathing the facial and auditory nerves; another through the jugular foramen, forming a sheath for the structures which pass through this opening, and a third through the anterior condyloid foramen. Around the margin of the foramen magnum it is closely adherent to the bone, and is continuous with the dura mater lining the spinal canal. In certain situations, as already mentioned (page 667), the fibrous layers of this membrane separate, to form sinuses for the passage of venous blood. Upon the outer surface of the dura mater, in the situation of the longitudinal sinus, may be seen numerous small whitish bodies, the *glandule Pacchioni*.

**Structure.**—The dura mater consists of white fibrous and elastic tissues, arranged in flattened laminae, which are divisible into two layers, the fibres of the two layers intersecting each other obliquely. A layer of nucleated epithelial cells, similar to those found on serous membranes, lines its inner surface; these were formerly regarded as belonging to the arachnoid membrane.

Its *arteries* are very numerous, but are chiefly distributed to the bones. Those found in the anterior fossa are the anterior meningeal branches of the anterior and posterior ethmoidal and internal carotid, and a branch from the middle meningeal. In the middle fossa are the middle and small meningeal branches of the internal maxillary, a branch from the ascending pharyngeal, which enters the skull through the foramen lacerum medium basis cranii; branches from the internal carotid, and a recurrent branch from the lachrymal. In the posterior fossa are meningeal branches from the occipital: one of which enters the skull through the jugular foramen, and the other through the mastoid foramen; the posterior meningeal, from the vertebral; occasionally meningeal branches from the ascending pharyngeal, which enter the skull, one at the jugular foramen, the other at the anterior condyloid foramen; and a branch from the middle meningeal.

The *veins*, which return the blood from the dura mater, and partly from the



bones, anastomose with the diploic veins. These vessels terminate in the various sinuses, with the exception of two which accompany the middle meningeal artery, and pass out of the skull at the foramen spinosum to join the internal maxillary vein.

The *nerves* of the dura mater are, the recurrent branch of the fourth, and filaments from the Gasserian ganglion, from the ophthalmic and hypoglossal nerves, and from the sympathetic.

**Processes of the Dura Mater.**—The processes of the dura mater, sent inwards into the cavity of the skull, are three in number: the falx cerebri, the tentorium cerebelli, and the falx cerebelli.

The *falx cerebri*, so named from its sickle-like form, is a strong arched process of the dura mater, which descends vertically in the longitudinal fissure between the two hemispheres of the brain. It is narrow in front, where it is attached to the crista galli of the ethmoid bone; and broad behind, where it is connected with the upper surface of the tentorium. Its upper margin is convex, and attached to the inner surface of the skull as far back as the internal occipital protuberance. In this situation it is broad, and contains the superior longitudinal sinus. Its lower margin is free, concave, and presents a sharp curved edge, which contains the inferior longitudinal sinus.

The *tentorium cerebelli* is an arched lamina of dura mater, elevated in the middle, and inclining downwards towards the circumference. It covers the upper surface of the cerebellum, and supports the occipital lobes of the brain, and prevents them pressing upon the cerebellum. It is attached, behind, by its convex border to the transverse ridges upon the inner surface of the occipital bone, and there encloses the lateral sinuses; in front, to the superior margin of the petrous portion of the temporal bone on either side, enclosing the superior petrosal sinuses; and at the apex of this bone, the free or internal border and the attached or external border meet, and, forming two processes, cross one another and are continued forwards, to be attached to the anterior and posterior clinoid processes respectively. Along the middle line of its upper surface the posterior border of the falx cerebri is attached, the straight sinus being placed at their point of junction. Its anterior border is free and concave, and presents a large oval opening for the transmission of the crura cerebri.

The *falx cerebelli* is a small triangular process of dura mater, received into the indentation between the two lateral lobes of the cerebellum behind. Its base is attached, above, to the under and back part of the tentorium; its posterior margin to the lower division of the vertical crest on the inner surface of the occipital bone. As it descends, it sometimes divides into two smaller folds, which are lost on the sides of the foramen magnum.

#### GLANDULÆ PACCHIONI OR ARACHNOIDAL VILLI

The so-called glandulæ Pacchioni are numerous small whitish granulations usually collected into clusters of variable size, which are found in the following situations:—1. Upon the outer surface of the dura mater, in the vicinity of the superior longitudinal sinus, being received into little depressions on the inner surface of the calvarium. 2. On the inner surface of the dura mater. 3. In the superior longitudinal sinus. 4. On the pia mater, near the margin of the hemispheres.

These bodies are not glandular in structure, but simply enlarged normal villi of the arachnoid. In their growth they perforate the dura mater, and are thus found on its outer surface, and when of large size they cause absorption of the bone, and come to be lodged in pits or depressions on the inner table of the skull. The manner in which they perforate the dura mater is as follows:—at an early period of their growth they project through minute holes in the inner layer of the dura mater, which open into large venous spaces situated in the tissues of the membrane, on either side of the longitudinal sinus and communicating with it.

In their onward growth the villi push the outer layer of the dura mater before them, and this forms over them a delicate membranous sheath. In structure they consist of spongy trabecular tissue, covered over by a membrane, which is continuous with the arachnoid. The space between these two coverings, derived from the dura mater and arachnoid respectively, corresponds to and is continuous with the subdural space. The spongy tissue of which they are composed is continuous with the trabecular tissue of the subarachnoid space; so that fluid injected into the subarachnoid space finds its way into the Pacchionian bodies; and through their coverings filters into the superior longitudinal sinus. They are supposed to be the means by which excess of cerebro-spinal fluid is got rid of, when its quantity is increased above normal.

These bodies are not found in infancy, and very rarely until the third year. They are usually found after the seventh year; and from this period they increase in number as age advances. Occasionally they are wanting.

#### ARACHNOID MEMBRANE

The arachnoid (*ἀράχνη εἶδος, like a spider's web*), so named from its extreme thinness, is a delicate membrane which envelops the brain, lying between the pia mater internally and the dura mater externally; from this latter membrane it is separated by a space, the *subdural space*.

It invests the brain loosely, being separated from direct contact with the cerebral substance by the pia mater, and a quantity of loose areolar tissue, the *subarachnoidean*. On the upper surface of the cerebrum the arachnoid is thin and transparent, and may be easily demonstrated by injecting a stream of air beneath it by means of a blowpipe; it passes over the convolutions without dipping down into the sulci between them. At the base of the brain the arachnoid is thicker, and slightly opaque towards the central part; it covers the anterior lobes, and extends across between the two temporo-sphenoidal lobes so as to leave a considerable interval between it and the brain, the *anterior subarachnoidean space* (Cisterna pontis); it is in contact with the pons and under surface of the cerebellum; but between the hemispheres of the cerebellum and the medulla oblongata another considerable interval is left between it and the brain, called the *posterior subarachnoidean space* (Cisterna magna). These two spaces communicate together across the crura cerebelli. The arachnoid membrane surrounds the nerves which arise from the brain, and encloses them in loose sheaths as far as their point of exit from the skull.

The *subarachnoid space* is the interval between the arachnoid and pia mater. It is not, properly speaking, a *space*, for it is occupied everywhere by a spongy tissue consisting of trabeculæ of delicate connective tissue, which pass from the pia mater to the arachnoid, and in the meshes of which the subarachnoid fluid is contained. This so-called space is small on the surface of the hemispheres; but at the base of the brain the subarachnoid tissue is less abundant and its meshes larger, where it forms the Cisterna pontis et magna mentioned above. In addition to these two large spaces, a third is formed on the upper surface of the corpus callosum, for the arachnoid stretches across from one cerebral hemisphere to the other immediately beneath the free border of the falx cerebri, and thus leaves a space in which the anterior cerebral arteries are contained. Another space is found in the fissure of Sylvius, for the arachnoid stretches across from the anterior to the middle lobe of the brain, without dipping down to the bottom of the fissure, and in this space the middle cerebral artery ramifies. The subarachnoid space communicates with the general ventricular cavity of the brain by means of three openings: one of these is in the middle line at the inferior boundary of the fourth ventricle, where an opening in the pia-matral covering of this cavity, the *foramen of Majendie*, exists and permits the passage of fluid from the one space to the other. The other two communications are at the extremities of the lateral recesses of the fourth ventricle, behind the upper roots

of the glosso-pharyngeal nerves; they are named the *foramina of Key and Retzius*. It is stated by Merkel that the lateral ventricles also communicate with the subarachnoid space at the apices of their descending horns.

The subdural space also contains fluid; this is, however, small in quantity compared with the cerebro-spinal fluid and is probably of the nature of lymph.

The *cerebro-spinal fluid* fills up the subarachnoid space. It is a clear, limpid fluid, having a saltish taste, and a slightly alkaline reaction. According to Lassaigne, it consists of 98·5 parts of water, the remaining 1·5 per cent. being solid matters, animal and saline. It varies in quantity, being most abundant in old persons, and is quickly reproduced. Its chief use is probably to afford mechanical protection to the nervous centres, and to prevent the effects of concussions communicated from without.

**Structure.**—The arachnoid consists of bundles of white fibrous and elastic tissue intimately blended together. Its outer surface is covered with a layer of endothelium. From its inner surface are given off a number of bundles of fine connective tissue, which form a sponge-like trabecular network in the subarachnoid space, in the interstices of which the cerebro-spinal fluid is contained. Vessels of considerable size, but few in number, and, according to Boehdalek, a rich plexus of nerves derived from the motor division of the fifth, the facial, and the spinal accessory nerves, are found in the arachnoid.

#### PIA MATER

The pia mater is a vascular membrane, and derives its blood from the internal carotid and vertebral arteries. It consists of a minute plexus of blood-vessels, held together by an extremely fine areolar tissue. It invests the entire surface of the brain, dipping down between the convolutions and laminae, and is prolonged into the interior, forming the velum interpositum and choroid plexuses of the fourth ventricle. Upon the surfaces of the hemispheres, where it covers the grey matter of the convolutions, it is very vascular, and gives off from its inner surface a multitude of minute vessels, which extend perpendicularly for some distance into the cerebral substance. At the base of the brain, in the situation of the anterior and posterior perforated spaces, a number of long straight vessels are given off, which pass through the white matter to reach the grey substance in the interior. On the cerebellum the membrane is more delicate, and the vessels from its inner surface are shorter. The pia mater of the spinal cord is thicker, firmer, and less vascular than that of the brain, and as it is traced upwards over the medulla it is seen to preserve these characters. At the upper border of the medulla it is prolonged over the lower half of the fourth ventricle, forming a covering for it (*tela choroidea inferior*) before it is reflected on to the under surface of the cerebellum.

According to Fohmann and Arnold, this membrane contains numerous lymphatic vessels. Its nerves are derived from the sympathetic, and also from the third, fifth, sixth, facial, glosso-pharyngeal, pneumogastric, and spinal accessory. They accompany the branches of the arteries.

#### DIVISIONS OF THE BRAIN

The **brain** (*encephalon*) is that portion of the cerebro-spinal axis which is contained in the cranial cavity. It is divided into four principal parts: viz. the cerebrum, the cerebellum, the pons Varolii, and the medulla oblongata.

The **cerebrum** forms the largest portion of the encephalon, and occupies a considerable part of the cavity of the cranium, resting in the anterior and middle fossae of the base of the skull, and separated posteriorly from the cerebellum by the tentorium cerebelli. About the middle of its under surface is a narrow constricted portion, part of which, the *crura cerebri*, is continued onwards into the



pons Varolii below, and through it to the medulla oblongata and spinal cord; whilst another portion, the *crura cerebelli*, passes down into the cerebellum.

The **cerebellum** (*little-brain*, or *after-brain*) is situated in the inferior occipital fossæ, being separated from the under surface of the occipital lobes of the cerebrum by the tentorium cerebelli. It is connected to the rest of the encephalon by means of connecting bands, called *crura*: of these, two ascend to the cerebrum, two descend to the medulla oblongata, and two blend together in front, forming the pons Varolii.

The **pons Varolii** is that portion of the encephalon which rests upon the upper part of the basilar process of the occipital bone and body of the sphenoid bone. It constitutes the bond of union of the various segments above named, receiving, above, the *crura* from the cerebrum; at the sides, the *crura* from the cerebellum; and below, the medulla oblongata.

The **medulla oblongata** extends from the lower border of the pons Varolii to the upper part of the spinal cord. It lies beneath the cerebellum, resting on the lower part of the basilar groove of the occipital bone.

**Weight of the Encephalon.**—The average weight of the brain, in the adult male, is  $49\frac{1}{2}$  oz., or a little more than 3 lb. avoirdupois; that of the female, 44 oz.; the average difference between the two being from 5 to 6 oz. The prevailing weight of the brain, in the male, ranges between 46 oz. and 53 oz.; and, in the female, between 41 oz. and 47 oz. In the male, the maximum weight out of 278 cases was 65 oz. and the minimum weight 34 oz. The maximum weight of the adult female brain, out of 191 cases, was 56 oz., and the minimum weight 31 oz. According to Luschka, the average weight of a man's brain is 1,424 grammes (about 45 oz.), of a woman's 1,272 grammes (about 41 oz.); and according to Krause, 1,570 grammes (about  $48\frac{1}{2}$  oz.) for the male, and 1,350 grammes (about 43 oz.) for the female. It appears that the weight of the brain increases rapidly up to the seventh year, more slowly to between sixteen and twenty, and still more slowly to between thirty and forty, when it reaches its maximum. Beyond this period, as age advances and the mental faculties decline, the brain diminishes slowly in weight, about an ounce for each subsequent decennial period. These results apply alike to both sexes.

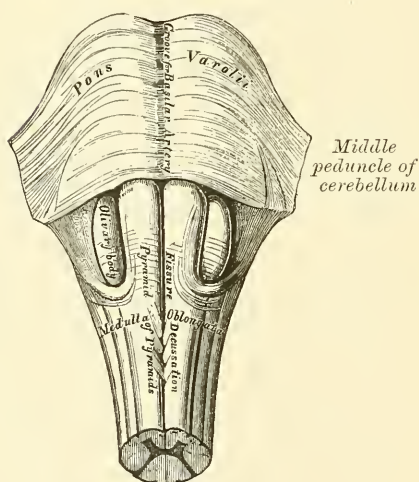
The size of the brain was formerly said to bear a general relation to the intellectual capacity of the individual. Cuvier's brain weighed rather more than 64 oz., that of the late Dr. Abercrombie 63 oz., and that of Dupuytren  $62\frac{1}{2}$  oz. On the other hand, the brain of an idiot seldom weighs more than 23 oz. But these facts are by no means conclusive, and it is well known that these weights have been equalled by the brains of persons who never displayed any remarkable intellect. Dr. Haldennan, of Cincinnati, has recorded the case of a mulatto, aged 45, whose brain weighed  $68\frac{3}{8}$  oz.; he had been a slave, and was never regarded as particularly intelligent; he was illiterate, but is said to have been reserved, meditative, and economical. Dr. Ensor, district medical officer at Port Elizabeth, reports that the brain of Carey, the Irish informer, weighed 61 oz. M. Nikiforoff has published an article on the subject of the weight of brains in the *Novosti*. According to him, the weight of the brain has no influence whatever on the mental faculties. It ought to be remembered that the significance of the weight of the brain should depend upon the proportion it bears to the dimensions of the whole body and to the age of the individual. It is equally important to know what was the cause of death, for long illness or old age exhausts the brain. To define the real degree of development of the brain, it is therefore necessary to have a knowledge of the condition of the whole body; and, as this is usually lacking, the mere record of weight possesses little significance.

The human brain is heavier than that of all the lower animals, excepting the elephant and whale. The brain of the former weighs from eight to ten pounds; and that of a whale, in a specimen seventy-five feet long, weighed rather more than five pounds.

## MEDULLA OBLONGATA

The **medulla oblongata**, or **bulb**, is the upper enlarged part of the spinal cord, and extends from the lower margin of the foramen magnum to the lower border of the pons Varolii. It is directed from above obliquely downwards and backwards; its anterior surface rests on the basilar groove of the occipital bone, its posterior surface is received into the fossa between the hemispheres of the cerebellum, forming the floor of the fourth ventricle. It is pyramidal in form, its broad extremity directed upwards, its lower end being narrow at its point of connection with the cord. It measures an inch in length, three-quarters of an inch in breadth at its widest part, and half an inch in thickness. Its surface is marked, in the median line, in front and behind, by an *anterior* and *posterior median fissure*, which are continuous with those of the spinal cord. The anterior fissure contains a fold of pia mater, and terminates just below the pons in a *cul-de-sac*, the *foramen cecum*. It is interrupted at its lower part by some bundles of fibres, which cross obliquely from one side to the other, forming the decussation of the pyramids. The posterior is a deep but narrow fissure, continued upwards to about the middle of the medulla, where it expands into the fourth ventricle. These two fissures divide the medulla into two symmetrical halves, each lateral half presenting elongated eminences which are

FIG. 454.—Medulla oblongata and pons Varolii. Anterior surface.



continuous with the columns of the cord. By taking the lines along which some of the cranial nerves emerge from the medulla, as landmarks, we may divide the surface of this portion of the nervous system into three columns, just in the same way as the spinal cord is divided into three columns by the lines corresponding to the points of exit of the anterior and posterior roots of the spinal nerves. The anterior column comprises that portion which is situated between the anterior median fissure and the fibres of origin of the hypoglossal nerve: this column is called the *pyramid*. The lateral column comprises that portion which is situated between the fibres of origin of the hypoglossal nerve and the fibres of origin of the glosso-pharyngeal, pneumogastric, and spinal accessory

nerves. In the lower part of the medulla this column is single, and is called the lateral tract; but in the upper part an oval-shaped body comes forward between it and the pyramid, pushing aside the lateral tract. This is called the *olivary body*. The posterior column comprises that portion which is situated between the fibres of origin of the glosso-pharyngeal, pneumogastric, and spinal accessory nerves, and the posterior median fissure. This column is marked by slight furrows marking off smaller columns, and these in the lower part of the medulla are named, from without inwards, the *funiculus of Rolando*, the *funiculus cuneatus*, and the *funiculus gracilis*; in the upper part of the medulla, the funiculus of Rolando and the funiculus cuneatus appear to become fused together, forming a single body called the *restiform body*.

The **pyramids** are two pyramidal bundles of white matter, placed one on either side of the anterior median fissure, and separated from the olivary body, which is external to them, by a slight depression. At the lower border of the pons they are somewhat constricted; they then become enlarged, and taper as



they descend, being continuous below, by their outer portion, with the anterior columns of the cord (*direct pyramidal tract*), and by their inner portion with the decussating fibres, seen in the anterior median fissure, which are derived from the lateral column of the cord (*crossed pyramidal tract*). For, on separating the pyramids below, it will be observed that their innermost fibres form from four to five bundles on each side, which decussate with one another across the anterior median fissure; this decussation, however, is not formed of fibres from the anterior column of the cord, but from the deep portion of the lateral columns (*crossed pyramidal tract*) which pass forwards to the surface on the inner side of the anterior columns. The outermost fibres do not decussate; they are derived, as just stated, from the anterior column of the cord.

The **lateral column**, in the lower part of the medulla, is of the same width as the lateral column of the cord, and appears on the surface to be a direct continuation of it. As a matter of fact it is only a part of the lateral column of the spinal cord which is continued upwards into this column; for, as we have just seen, the crossed pyramidal tract passes into the pyramid of the opposite side, and the direct cerebellar tract of the cord passes into the restiform body. The rest of the lateral column of the cord can be traced vertically upwards into this area. In the upper part of the medulla, the lateral tract, on account of the interpolation of the olivary body, becomes concealed by this body.

The **olivary body** is a prominent oval mass, situated behind the pyramid, from which it is separated by a slight groove, along which the hypoglossal nerve arises. It is separated externally from the restiform body by a longitudinal narrow band of fibres, prolonged upwards from the lateral tract, and by a groove, from which the glosso-pharyngeal, pneumogastric, and spinal accessory nerves arise. It is equal in breadth to the pyramid; is a little broader above than below, and is about half an inch in length, being separated above from the pons Varolii by a slight depression, in which is sometimes to be seen a band of arched fibres. Numerous white fibres (*superficial arciform fibres*) are seen winding across the lower half of the pyramid and the olivary body to enter the restiform body.

The **funiculus of Rolando** is a longitudinal prominence, on the outer side of the lateral tract. It begins at the lower end of the medulla by a tapering extremity, and gradually enlarging as it ascends, forms at a level with the lower border of the olivary body a slight prominence, known as the *tubercle of Rolando*. It is caused by the *substantia gelatinosa* of Rolando of the cord gradually finding its way to the surface, so as to form a prominence there. About half an inch below the pons it appears to blend with the funiculus cuneatus. In front, it is separated from the lateral tract by a distinct groove, the continuation upwards of the postero-lateral groove of the cord; behind, the separation from the funiculus cuneatus is much less distinct.

The **funiculus cuneatus** is the direct continuation upwards of the posterior lateral column (tract of Burdach) of the cord. It is situated between the funiculus of Rolando and the funiculus gracilis; it enlarges as it ascends, and forms, opposite the lower extremity of the fourth ventricle, a slight eminence or enlargement, the *tuberculum cuneatum*, which is best marked in children. About half an inch below the pons it appears to blend with the funiculus of Rolando.

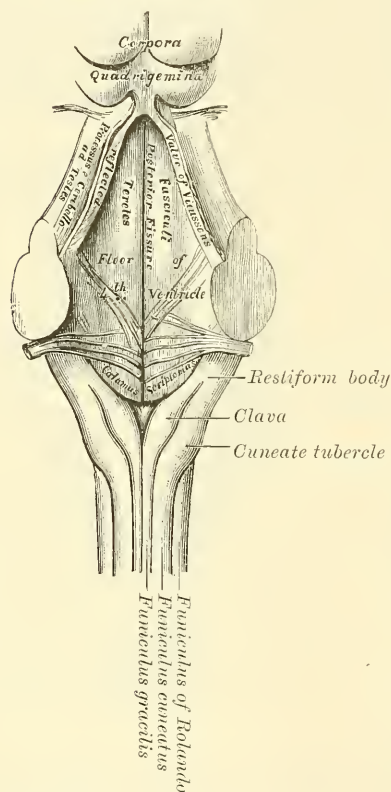
The **restiform bodies** appear on the surface to be the direct continuation upwards of the funiculus of Rolando and the funiculus cuneatus. But they also receive the arched fibres (arciform), presently to be described, and fibres derived from the lateral column of the cord, or the *direct cerebellar tract*. The restiform bodies are the largest prominences of the medulla, and are placed between the lateral tracts in front and the funiculus gracilis behind, from both of which they are separated by slight grooves. As they ascend they diverge from each other, assist in forming the lower part of the lateral boundaries of the fourth ventricle, and then enter the corresponding hemisphere of the cerebellum, forming its inferior peduncles.



The **funiculus gracilis** is the direct continuation upwards of the posterior median column of the cord (tract of Goll). It is a narrow white cord, placed parallel to and along the side of the posterior median fissure. It is separated from the funiculus cuneatus below and the restiform body above by a slight groove, which is continuous with the groove on the surface of the cord, which marks off the posterior median column. At first the funiculi of the two sides lie in close contact on either side of the posterior median fissure. Opposite the apex of the fourth ventricle they form an enlargement (*clava*), and then diverging, form the lateral boundaries of the lower part of the fourth ventricle, and gradually tapering off they soon become no longer traceable.

The **posterior surface of the medulla oblongata** forms part of the floor of the fourth ventricle. This portion is of a triangular form, bounded on each side by the

FIG. 455.—Posterior surface of the medulla oblongata.



diverging funiculi graciles and restiform bodies, and is that part of the ventricle which, from its resemblance to the point of a pen, is called *calamus scriptorius*. The divergence of the funiculi graciles and restiform bodies opens to view the grey matter of the medulla, which is continuous below with the grey matter of the cord. In the middle line is seen a longitudinal furrow, which ends below near the point of the calamus, in a somewhat cleft-like space, the *ventricle of Arantius*, which opens by a minute hole into the central canal of the cord.

The **arciform** or **arcuate fibres**, which have been mentioned as forming part of the restiform body, are found in the upper half of the medulla, both crossing its surface and traversing its substance. They are divided for the purpose of description into two sets—superficial and deep. The *superficial arciform fibres* have already been alluded to as crossing the pyramid and olivary body on each side. They emerge from the anterior median fissure, in which they can be traced to enter the raphé and cross it, after which they become no longer traceable. After emerging from the anterior median fissure they cross the pyramid and olivary body, and enter the restiform body. As they cross the olivary

body they are reinforced by some of the deep arciform fibres which come to the surface on the inner side of, or through, this structure. The *deep arciform fibres* are described with the Microscopic Anatomy of the Medulla.

**Structure.**—The medulla oblongata, like the spinal cord, consists of both grey and white matter, and exhibits in section both these structures arranged in certain definite masses. The fibres of the several columns of the cord enter the medulla, and in it undergo a rearrangement, some of them passing through it to the pons Varolii, the cerebrum, and the cerebellum, while others end in its grey substance. Some fibres take origin in the medulla, and are continued onwards to the cerebrum and cerebellum. The structure of the medulla will be best understood by tracing its several parts upwards from the spinal cord.

The **pyramid** is composed of fibres derived from the direct pyramidal tract of the anterior column of the cord of its own side, and from the crossed pyramidal

tract of the lateral column of the opposite half of the cord. Those fibres which are derived from the direct pyramidal tract, and which in the cord lie close to the median fissure, are in the medulla placed to the outer side of the pyramid, being pushed aside, as it were, by the interpolation of the fibres derived from the crossed pyramidal tract, which are much more numerous. The crossed pyramidal fibres ascend from the lateral column of the spinal cord, and, passing through the anterior grey cornua and across the median fissure, form the inner part of the pyramid. The fibres of the pyramid may be traced upwards through the pons to the *crus cerebri* of its own side. All the fibres of the anterior column of the cord are not continued into the pyramid of the medulla; some of them pass backwards, and enter the *formatio reticularis*, which is described with the Microscopic Anatomy of the Medulla.

The **olivary body** when cut across obliquely is seen to be composed, externally of white fibres, internally of a grey layer, the *corpus dentatum*, which is arranged in the form of a hollow capsule, open at its upper and inner part and presenting a zigzag or dentated outline. White fibres enter the interior of this capsule by the aperture at its upper and inner part, constituting the *olivary peduncle*.

The **lateral tract of the medulla** is the continuation upwards of part of the lateral column of the cord. The fibres from it divide into three sets: one set, the most numerous, pass deeply behind the olivary body, and ascend through the *formatio reticularis* to the pons; a second set pass across the anterior median fissure to join the pyramid, forming the *crossed pyramidal set*; the third set, few in number, form a small band, which passes backwards to the restiform body to enter the cerebellum, forming the *lateral cerebellar tract*.

The **funiculus of Rolando**, which is a longitudinal prominence on the outer side of the lateral tract, is now seen to be the enlarged head of the posterior cornu of the grey matter which is displaced laterally in consequence of the increase in size of the posterior columns of the medulla, so that it lies almost at right angles to the posterior median fissure, and approaching the surface forms a prominence which is covered over by a very thin layer of white matter, derived from the funiculus cuneatus. Its most prominent part on the surface is called the *tubercle of Rolando*.

The **funiculus cuneatus** is the direct continuation upwards of the postero-lateral column of the cord. Its white fibres are derived from this region of the cord. The fibres appear to end in the grey matter which forms the so-called nucleus of this column; this nucleus, at first narrow, gradually enlarges, and produces, externally, the eminence mentioned above as the *tuberculum cuneatum*.

The **funiculus gracilis** is the direct continuation upwards of the posterior median column of the cord. It consists entirely of white fibres, which are continuous with those of this region of the cord. Like the funiculus cuneatus its fibres appear to end in its so-called nucleus, which produces externally the prominence mentioned above as the *clava*.

The **restiform body** is mainly constituted by the fusing together of the funiculus of Rolando and the funiculus cuneatus, to which are added the arciform fibres of the medulla and the direct cerebellar tract from the lateral column of the cord. In addition to these, a bundle of fibres has been described by Solly as passing from the anterior column of the cord obliquely upwards below the olivary body to the restiform body. The white fibres of the restiform body are continued upwards to the cerebellum, forming its inferior peduncle.

**Microscopic Anatomy of the Medulla.**—If the cranial nerves emerging from the medulla are traced into its substance, it will be seen that they divide each hemisphere of the medulla into three wedge-shaped areas, which have been named the anterior, lateral, and posterior areas of the medulla.

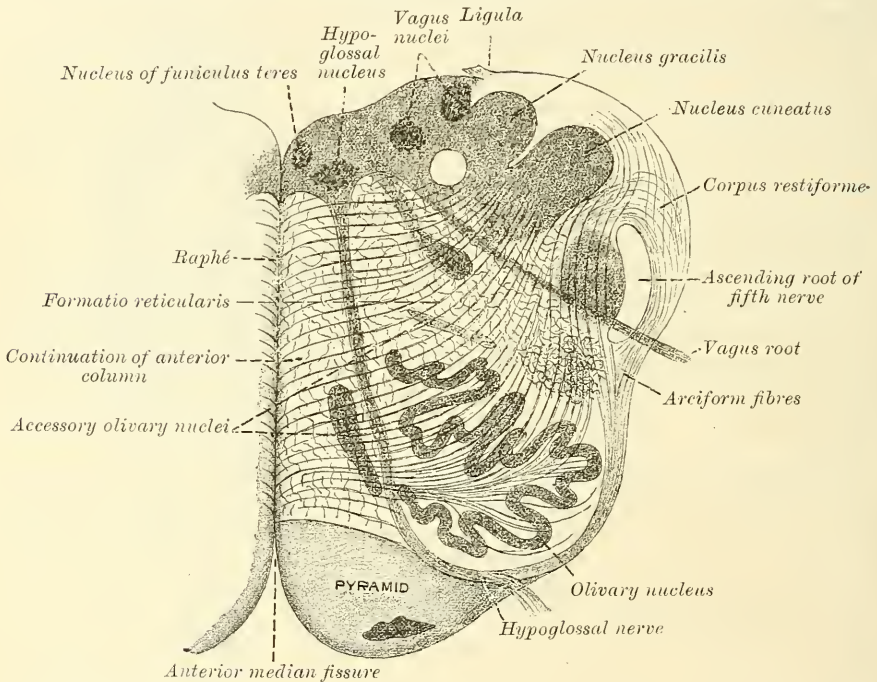
The *anterior area* comprises that portion which is situated between the anterior median fissure and the fibres of origin of the hypoglossal nerve. On the surface of the medulla this area corresponds to the pyramid.

The *lateral area* comprises that portion which is situated between the fibres of

origin of the hypoglossal nerve and the fibres of origin of the glosso-pharyngeal, pneumogastric, and spinal accessory nerves. On the surface of the medulla, in its lower part, this area is single, and is called the lateral tract; but in the upper part an oval-shaped body comes forward between it and the pyramid, pushing aside the lateral tract. This oval-shaped body is the olivary body.

The *posterior area* comprises that portion which is situated between the fibres of origin of the glosso-pharyngeal, pneumogastric, and spinal accessory nerves and the posterior median fissure. On the surface of the medulla, this area is marked by slight furrows marking off smaller columns; these, in the lower part of the medulla, are named, from without inwards, the funiculus of Rolando, the funiculus cuneatus, and the funiculus gracilis; in the upper part of the medulla, the funiculus of Rolando and the funiculus cuneatus appear to become fused together, forming a single body, called the restiform body.

FIG. 456.—Section of the medulla oblongata at about the middle of the olivary body. (Schwalbe.)



**The Arciform fibres.**—*Deep set.*—The deep arciform fibres are more numerous than the superficial set; they traverse the whole area of the upper half of the medulla, except the pyramid. They pass from the raphé; some become superficial and join the superficial arciform fibres; while others remain deep and pass to the restiform body and to the nuclei of the funiculus cuneatus and funiculus gracilis.

**The raphé.**—The raphé is situated in the middle line of the medulla, above the decussation of the pyramids. It consists of nerve-fibres intermingled with nerve-cells. The fibres have different directions which can only be seen in suitable microscopic sections; thus—

1. Some are antero-posterior; these are continuous in front with the superficial arciform fibres.
2. Some are longitudinal; these are derived from the arciform fibres, which on entering the raphé change their direction and become longitudinal.
3. Some are oblique; these are continuous with the deep arciform fibres which pass from the raphé.



Some of the fibres of the raphé arise from the nuclei on the floor of the fourth ventricle.

**The formatio reticularis.**—In the substance of the medulla behind the pyramid and olivary body is a peculiar reticulated structure; which has received the name of *formatio reticularis*; the appearance it presents in sections of the medulla is due to its being composed of bundles of fibres running at right angles to each other, some being longitudinal, others transverse.

The longitudinal fibres are derived—

1. From the anterior column of the cord after the direct pyramidal tract has passed into the pyramid.
2. From the olivary body.
3. From the lateral column of the cord after the crossed pyramidal tract has passed into the pyramid.
4. From the funiculus cuneatus and funiculus gracilis.

The transverse fibres are the deep arciform fibres.

In the lateral part of this reticular structure grey matter containing large nerve-cells is found.

**The Grey Matter of the Medulla oblongata.**—The grey matter of the medulla oblongata is partly continuous with the grey matter of the cord, and partly arranged in independent masses. It contains many multipolar ganglion-cells. In the lower part of the medulla, the grey matter, which is continuous with that of the cord, is arranged in the shape of two crescentic horns with their convexities towards each other and connected by a central commissure; but in the upper part it loses its crescentic arrangement, becomes more abundant, and is disposed with less regularity.

The caput of the posterior horns becomes enlarged, and gradually shifted outwards, so that they form rounded masses, close under the lateral tract, and produce the prominence on the surface called the funiculus of Rolando. The neck of the cornu diminishes in size, and is broken up into a reticular formation by the passage of longitudinal and transverse fibres through it, so that the caput is separated from the rest of the grey matter.

As the central canal expands into the fourth ventricle, the rest of the posterior horn of grey matter is pushed outwards into the funiculus cuneatus and funiculus gracilis; in each of these funiculi it forms a distinct accumulation of grey matter, constituting the nucleus cuneatus and the nucleus gracilis.

The anterior horn of grey matter is broken up by the passage through it of the crossed pyramidal tract from the lateral column of the cord. By this means the anterior portion of the horn is completely isolated from the remainder, and constitutes the lateral nucleus of grey matter which is situated near the surface of the lateral tract.

The greater part of the rest of the anterior horn being permeated by the decussating fibres presents a reticular formation. A small part of the base of the anterior cornu comes to the surface of the floor of the fourth ventricle, and is exposed to view by the divergence of the funiculus cuneatus and funiculus gracilis. It forms a continuous mass, which gradually increases in size and forms the eminence of the fasciculus teres.

In it is a group of nerve-cells, which form the nucleus from which the roots of the hypoglossal nerve arise.

At the base of the posterior cornu, in the lower part of the medulla, is a group of cells, which, if traced upwards, are found to be pushed on one side; so that in the floor of the fourth ventricle they are outside the hypoglossal nucleus and form a second eminence, the *ala cinerea*: from it arise the roots of the accessory portion of the spinal accessory, pneumogastric, and glosso-pharyngeal nerves. Outside this again, and towards the upper part of the medulla, is another group of cells from which most of the fibres of the auditory nerve take origin.

Another independent mass of grey matter is found in the olivary body forming the corpus dentatum. It consists of a grey layer arranged in the form of a hollow

capsule, open at its upper and inner part, and presenting a zigzag or dentated outline. White fibres enter the interior of this capsule by the aperture at its upper and inner part, constituting the olivary peduncles. Some of these fibres terminate in the cells of the corpus dentatum, while others are continued through the grey layer to join the arciform fibres. Furthermore, two small isolated bands of grey matter are seen, one on the dorsal and the other on the mesial aspect of the corpus dentatum: these are known as *accessory olivary nuclei*.

#### PONS VAROLII

The **pons Varolii** (*tuber annulare*) is the bond of union of the various segments of the encephalon, connecting the cerebrum above, the medulla oblongata below, and the cerebellum behind. It is situated above the medulla oblongata, below the crura cerebri, and between the hemispheres of the cerebellum.

Its *anterior ventral surface* presents a broad transverse band of white fibres, which arches like a bridge across the upper part of the medulla, extending between the two hemispheres of the cerebellum. This surface projects considerably beyond the level of these parts, is of quadrangular form, rests upon the clivus of the sphenoid bone, and is limited before and behind by very prominent margins. It presents along the middle line a longitudinal groove, wider in front than behind, which lodges the basilar artery: numerous transverse striæ are also observed on each side, which indicate the course of its superficial fibres.

Its *posterior dorsal surface* forms a part of the floor of the fourth ventricle.

At each side its fibres become contracted into a thick rounded cord, the *crus cerebelli*, which enters the substance of the cerebellum, constituting its middle peduncle.

**Structure.**—The pons Varolii consists of two parts, which differ in appearance and structure from each other: the anterior or ventral half consists for the most part of fibres arranged in transverse and longitudinal bundles with a small amount of grey matter; the posterior or dorsal half is a continuation of the reticular formation of the medulla with the grey matter of the floor of the fourth ventricle. The anterior or ventral half consists of three layers of fibres: (1) superficial transverse fibres; (2) superficial longitudinal fibres; (3) deep transverse fibres. These three layers are not, however, completely differentiated from each other, for some transverse fibres may be seen between the bundles of the longitudinal fibres. The superficial transverse fibres (fig. 457) pass from the crus or middle peduncle of the cerebellum to the median raphe of the pons, where they meet and interlace with those coming from the opposite side. They then dip deeply into the substance of the pons and pass to the crus cerebri of the opposite side. The superficial longitudinal fibres enter the pons below as a single mass, being the continuation upwards of the fibres of the pyramids of the medulla; as they ascend they become broken up into bundles by some of the transverse fibres passing through them, and are continued into the superficial portion of the crus cerebri, much increased in number from being reinforced by the fibres derived from the nerve-cells in the deep transverse strata.

The deep transverse fibres form a much thicker layer than the superficial set, and contain much grey matter between them. The fibres pass from the crus or middle peduncle of the cerebellum to the median raphe of the pons, where they meet and interlace with those coming from the opposite side.

The posterior or dorsal portion of the pons is chiefly constituted by a continuation upwards of the reticular formation of the medulla and by the grey matter of the floor of the fourth ventricle.

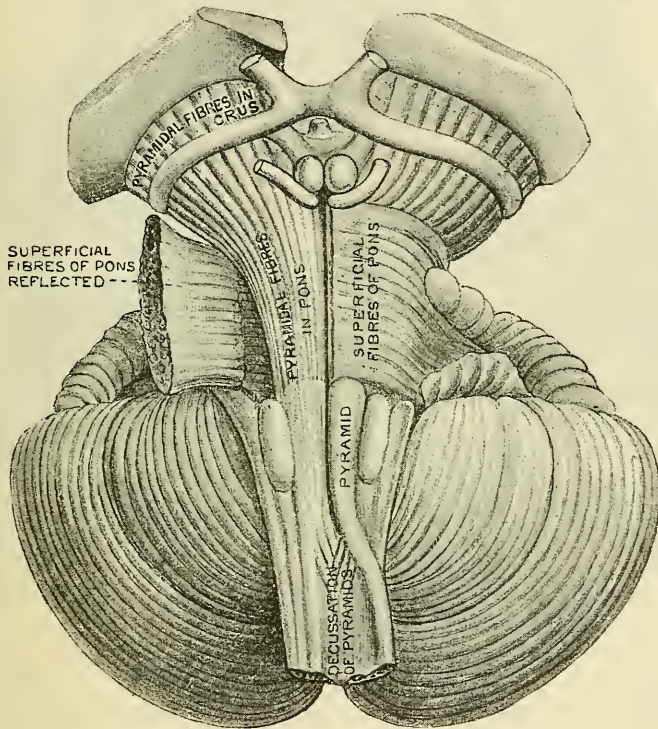
**Microscopic Anatomy of the Pons.**—This presents the same reticular structure as in the medulla, consisting of longitudinal fibres continued upwards from the medulla, with interlacing transverse fibres between which is interspersed grey matter with nerve-cells, especially in the deeper layers. Many of the deep transverse fibres join the nerve-cells, which are situated in the grey matter (*nuclei*



*pontis*) of this layer. From these cells other fibres are given off which ascend through the pons to the crus cerebri.

In the lower part of this portion of the pons is a small isolated collection of grey matter, the *superior olivary nucleus*, enclosed by some of the deep transverse fibres, called the *trapezium*. It is situated close to the medulla, behind the superficial longitudinal fibres from the pyramid and immediately above the olivary body. The fibres of the trapezium, which are probably connected with the cells of the nucleus, pass to the middle peduncle of the cerebellum. Near the floor of the fourth ventricle important collections of nerve-cells are found, from which some of the cranial nerves arise. One of these forms the nucleus of the sensory root of the fifth nerve; a second, the nucleus of the motor part of the same nerve; a third, the nucleus of the sixth nerve; and a fourth, the nucleus of the facial nerve. The nucleus of the auditory nerve, situated just at the junction of the pons and medulla, is prolonged upwards into the pons.

FIG. 457.—Superficial dissection of the medulla oblongata and pons. (Ellis.)



**Septum.**—The posterior part of the pons is subdivided into lateral halves by a medium septum, but this does not extend into the anterior half, being here obliterated by the transverse fibres. It is formed mainly by the decussation and change in the direction of fibres as they cross the middle line.

#### CEREBRUM

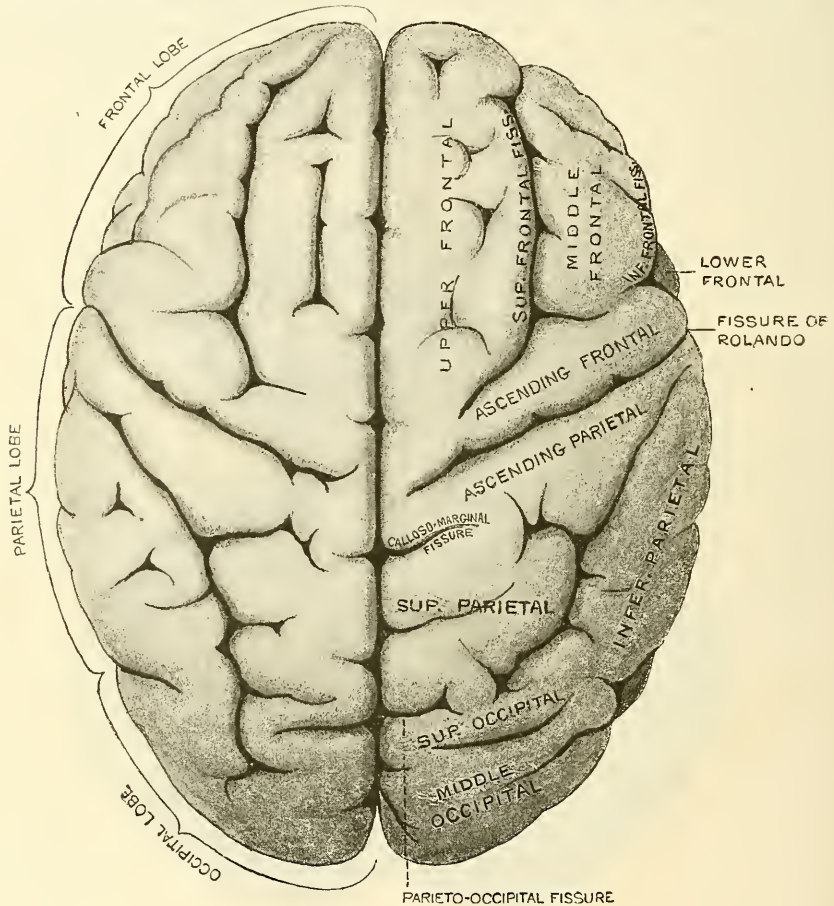
The **cerebrum** constitutes the largest portion of the encephalon. Its under surface or base is of an irregular form, resting in front on the anterior and middle fossæ of the skull, and behind upon the tentorium cerebelli. Its upper surface is of an ovoid form, broader behind than in front, convex in its general outline, and divided into lateral halves or hemispheres, right and left, by the *great longitudinal fissure*, which extends throughout the entire length of the cerebrum in the middle



line, reaching down to the base of the brain in front and behind, but interrupted in the middle by a broad transverse commissure of white matter, the *corpus callosum*, which connects the two hemispheres together. This fissure lodges the *falx cerebri*, and indicates the original development of the brain by two lateral halves.

Each hemisphere presents an outer surface, which is convex to correspond with the vault of the cranium; an inner surface, which is flattened, and in contact with the opposite hemisphere (the two inner surfaces forming the sides of the

FIG. 458.—Upper surface of the brain, the arachnoid having been removed.



longitudinal fissure); and an under surface or base, of an irregular form, which rests in front on the anterior and middle fossæ of the base of the skull, and behind upon the tentorium cerebelli.

#### UPPER SURFACE OF THE CEREBRUM (fig. 458)

If the arachnoid and pia mater are removed, the entire surface of each hemisphere will be seen to present a number of depressions (*fissures* and *sulci*) separating a number of convoluted eminences (the *convolutions* or *gyri*).

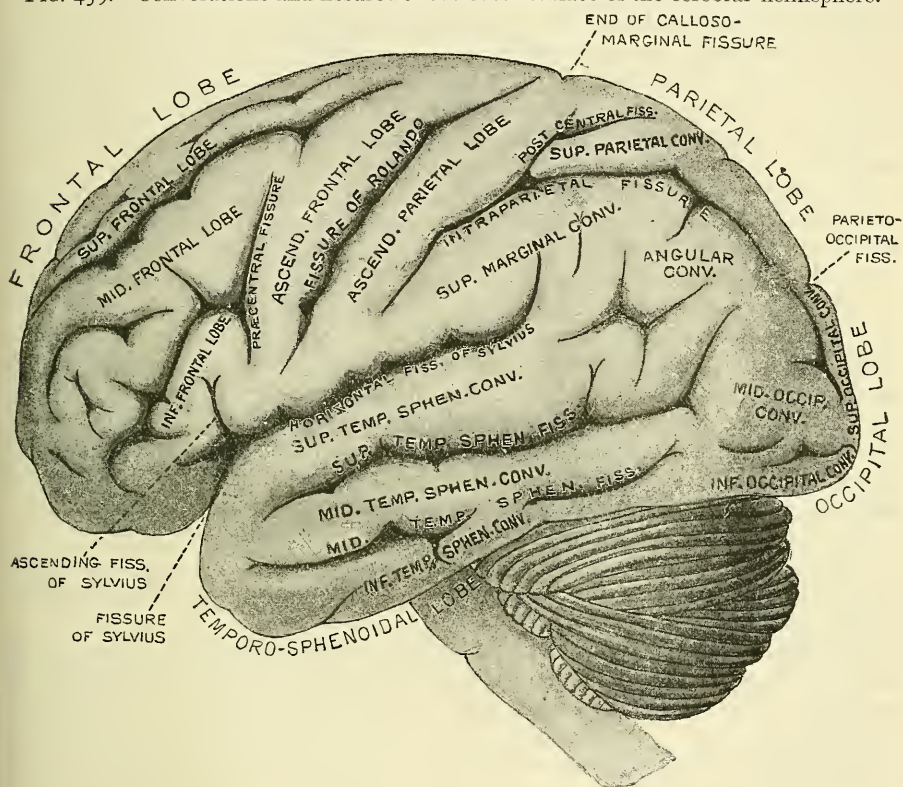
The depressions are of two kinds, *fissures* and *sulci*. The *fissures* are few in number; they are constant in their arrangement, and are produced by the foldings of the cerebrum during the process of development. They involve both grey and white matter. The *sulci* are more numerous; they are superficial depressions of the grey matter, which is folded inwards and only indents the central

white substance; they vary in different brains and in different parts of the same brain.

**The Convolution.**—There is no accurate resemblance between the convolutions in different brains, nor are they exactly symmetrical on the two sides of the same brain, but their general arrangement or plan is fairly constant. Certain infoldings of the cerebrum take place at an early period of development and form important landmarks, which are constant and can without difficulty be recognised; but the secondary depressions and convolutions vary considerably.

The number and extent of the convolutions, as well as their depth, appear to bear a close relation to the intellectual power of the individual, as is shown in their increasing complexity of arrangement as we ascend from the lowest mammalia up to man. Thus they are absent in some of the lower orders of mammalia, and they increase in number and extent through the higher orders.

FIG. 459.—Convolution and fissures of the outer surface of the cerebral hemisphere.



In man they present the most complex arrangement. Again, in the child, at birth, before the intellectual faculties are exercised, the convolutions have a very simple arrangement, presenting few undulations; and the sulci between them are less deep than in the adult. In old age, when the mental faculties have diminished in activity, the convolutions become much less prominently marked.

The convolutions on the outer convex surface of the hemisphere are the largest and most complicated convolutions of the brain; their general direction is more or less oblique; they frequently branch like the letter Y in their course upwards and backwards, towards the longitudinal fissure: these convolutions attain their greatest development in man, and are especially characteristic of the human brain.

**Structure of the Convolution.**—The outer surface of each convolution, as



well as the sides and bottom of the sulci between them, are composed of grey matter, which is here called the *cortical substance*. The interior of each convolution is composed of white matter; and white fibres also blend with the grey matter at the sides and bottom of the sulci. By this arrangement the convolutions are adapted to increase the amount of grey matter without occupying much additional space, while they also afford a greater extent of surface for the termination of the white fibres in grey matter.

**The Lobes and Fissures of the Brain.**—Each hemisphere of the brain on its external surface is divided into five lobes, the division being made by the main fissures and by imaginary lines drawn to connect them (fig. 459).

The fissures dividing the five lobes on the external surface of the hemispheres are three in number, and are named: *fissure of Sylvius*, *fissure of Rolando*, and *parieto-occipital fissure*.

The **fissure of Sylvius** begins at the base of the brain at the anterior perforated space, and passes outwards to the external surface of the hemisphere. It gives off a short *anterior limb*, which passes forwards; and another, *ascending limb*, which passes upwards into the inferior frontal convolution. It is then continued backwards, as the *horizontal limb*, and terminates in the parietal lobe after curving upwards for a short distance. It separates the frontal and parietal lobes from the temporo-sphenoidal, and occupies the middle third of the lateral surface of the hemisphere.

The **fissure of Rolando** is situated about the middle of the outer surface of the hemisphere. It commences at or near the longitudinal fissure, and runs downwards and forwards to terminate a little above the horizontal limb of the fissure of Sylvius, and about half an inch behind the ascending limb of the same fissure. It separates the frontal from the parietal lobe.

The **parieto-occipital fissure** is only seen to a slight extent on the outer surface of the hemisphere, and is not so distinctly marked as the others. The portion on the outer surface of the hemisphere is sometimes called the *external parieto-occipital fissure*, to distinguish it from the continuation of the sulcus on the internal surface of the hemisphere, which would then be termed the *internal parieto-occipital fissure*. It commences about midway between the posterior extremity of the brain and the fissure of Rolando, and runs downwards and forwards for about an inch. It divides the parietal and occipital lobes.

These three fissures divide the external surface of the hemisphere into five lobes: the *frontal*, the *parietal*, the *occipital*, the *temporo-sphenoidal*, and the *central* or *island of Reil*.

The **frontal lobe** is that portion of the brain which is situated in front of the fissure of Rolando and above the horizontal limb of the fissure of Sylvius. Its under surface rests on the orbital plate of the frontal bone, and is termed the *orbital lobe*.

The outer surface of the frontal lobe presents three sulci, which divide it into four primary convolutions. 1. The *precentral sulcus* runs upwards through this lobe, parallel to the lower half of the fissure of Rolando. It divides off a convolution, which lies between it and the fissure of Rolando, and which is called the *ascending frontal convolution*. 2 and 3. From it two sulci, the *superior* and *inferior frontal sulci*, run forwards and downwards and divide the remainder of the outer surface of the lobe—namely, that part in front of the precentral sulcus—into three principal convolutions, named respectively the *superior*, *middle*, and *inferior frontal convolutions*.

The under surface of the frontal lobe, which rests on the orbital plate of the frontal bone, is named the *orbital lobe* (fig. 460). It presents a well-marked groove or sulcus for the olfactory tract. The convolution internal to this sulcus forms part of the marginal gyrus, hereafter to be described. External to the sulcus this surface of the frontal lobe is divided into three convolutions by a well-marked sulcus, the *orbital* or *tri-radiate sulcus*. These are named, from their positions, the *internal*, *anterior*, and *posterior orbital convolutions*, and are



the continuation respectively of the superior, middle, and inferior frontal convolutions.

The *ascending frontal convolution* is a simple convolution, bounded in front by the precentral sulcus, behind by the fissure of Rolando, and extending from the upper margin of the hemisphere above to a little behind the bifurcation of the fissure of Sylvius below.

The *superior frontal convolution* is situated between the margin of the longitudinal fissure and the superior frontal sulcus. It extends above on to the inner aspect of the hemisphere, forming the marginal convolution, and in front on to the orbital surface, forming the internal orbital convolution. It is much divided by secondary sulci.

The *middle frontal convolution* is situated between the superior and inferior frontal sulci, and extends from the precentral sulcus to the lower margin of the lobe, where it forms the anterior orbital convolution.

The *inferior frontal convolution* is situated below the inferior frontal sulcus, and extends from the lower part of the precentral sulcus, circling round the ascending and anterior limbs of the fissure of Sylvius to the under surface of the lobe, where it forms the posterior orbital convolution.

The **parietal lobe** is situated between the frontal and occipital lobes, and is not much more than half the size of the former. It is bounded in front by the fissure of Rolando; behind, by the external parieto-occipital fissure, and a line drawn in continuation of that sulcus over the hemisphere; and below, by the horizontal limb of the fissure of Sylvius, and a line connecting this with the lower end of the superior occipital sulcus. Above, it extends to the longitudinal fissure. It presents for examination two sulci and three convolutions.

The *intraparietal sulcus* commences close to the horizontal limb of the fissure of Sylvius, about midway between the fissure of Rolando and the upturned extremity of the fissure of Sylvius. It first runs upwards parallel to and behind the lower half of the fissure of Rolando, and then turns backwards, extending nearly to the termination of the external parieto-occipital fissure, where it sometimes becomes continuous with the superior occipital sulcus. The ascending portion of this sulcus separates off a convolution, the *ascending parietal*, which lies between it and the fissure of Rolando, whilst the horizontal portion divides the remainder of the parietal lobe into two other convolutions, the *superior* and *inferior parietal*.

The *post-central sulcus* is a slightly marked groove, which is sometimes a branch of the intraparietal sulcus, being given off where the ascending portion of this sulcus turns backwards. It lies parallel to and behind the upper part of the fissure of Rolando, and separates the ascending from the superior parietal convolution.\*

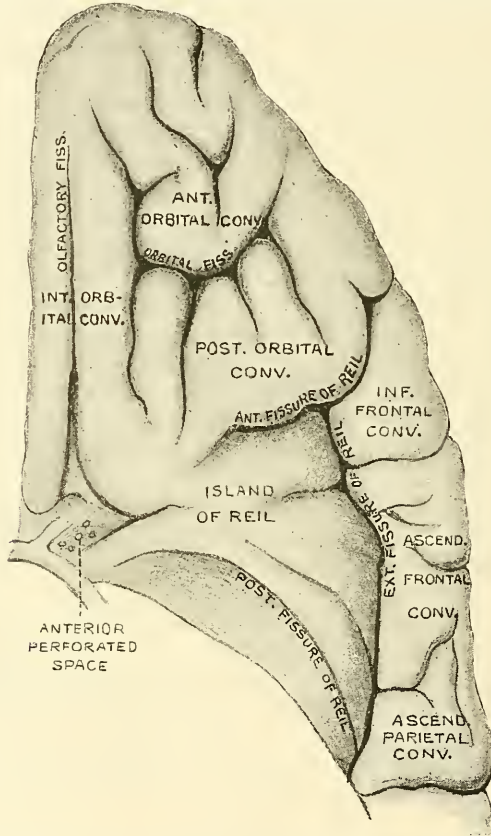
The *ascending parietal convolution* is bounded in front by the fissure of Rolando, behind by the ascending portion of the intraparietal and the post-

\* Professor Cunningham describes these two sulci, the intraparietal and post-central, somewhat differently. He regards them as both belonging to the intraparietal sulcus, which he divides into three parts: the ascending portion of the intraparietal, as described above, he terms the *ramus verticalis inferior*; the horizontal portion as the *ramus horizontalis*; while the post-central sulcus he denominates the *ramus verticalis superior*. He states that considerable variability is exhibited in the relation to each other of these different parts of the intraparietal sulcus, but that the one in which the three parts of the sulcus are confluent is by far the most constant condition. Sometimes, however, the three parts of the sulcus may be all separate, or the *ramus horizontalis* confluent with the *ramus verticalis inferior*, the *ramus verticalis superior* remaining separate; or, again, the vertical limbs may be confluent and the horizontal limb separate; or, finally, the *ramus horizontalis* may be joined to the lower end of the *ramus verticalis superior*, while the lower vertical limb is separate. The connection which sometimes exists between the intraparietal sulcus and the occipital lobe he calls the *ramus occipitalis*. In the majority of cases, however, the occipital ramus is separated from the main portion of the intraparietal sulcus by a superficial or deep bridging convolution. *Journal of Anatomy and Physiology*, vol. xxiv. part ii. p. 135.

central sulci. It extends from the great longitudinal fissure above to the horizontal limb of the fissure of Sylvius below. It lies parallel with the ascending frontal convolution, with which it is connected below, and also generally above, the termination of the fissure of Rolando.

The *superior parietal convolution* is bounded in front by the post-central sulcus which separates it from the previous convolution, but with which it is usually connected above the upper extremity of the sulcus; behind, it is bounded by the external parieto-occipital fissure, below the termination of which it is connected with the occipital lobe by a narrow convolution, the *first annectant gyrus*; below, it is separated from the inferior parietal convolution by the horizontal portion of the intraparietal sulcus; and above, it is continuous on the inner surface of the hemisphere with the quadrate lobe.

FIG. 460.—Convulsions and fissures of the under surface of the anterior lobe.



The *inferior parietal convolution* is that portion of the parietal lobe which is situated between the ascending portion of the intraparietal sulcus in front, the horizontal portion of the same sulcus above, the horizontal limb of the fissure of Sylvius below, and the posterior boundary of the parietal lobe behind. It is subdivided into two convulsions by an indistinct groove. One, the *supra-marginal*, lies behind the lower end of the intraparietal sulcus and above the horizontal limb of the fissure of Sylvius. It is connected, in front, with the ascending parietal convolution beneath the intraparietal sulcus, and with the superior temporo-sphenoidal convolution behind, round the posterior extremity of the fissure of Sylvius. The other, the *angular*, is connected in front with the foregoing, and with the middle temporo-sphenoidal convolution by a process which curves round the superior temporo-sphenoidal or parallel sulcus. It is connected with the occipital lobe by the *second annectant gyrus*.

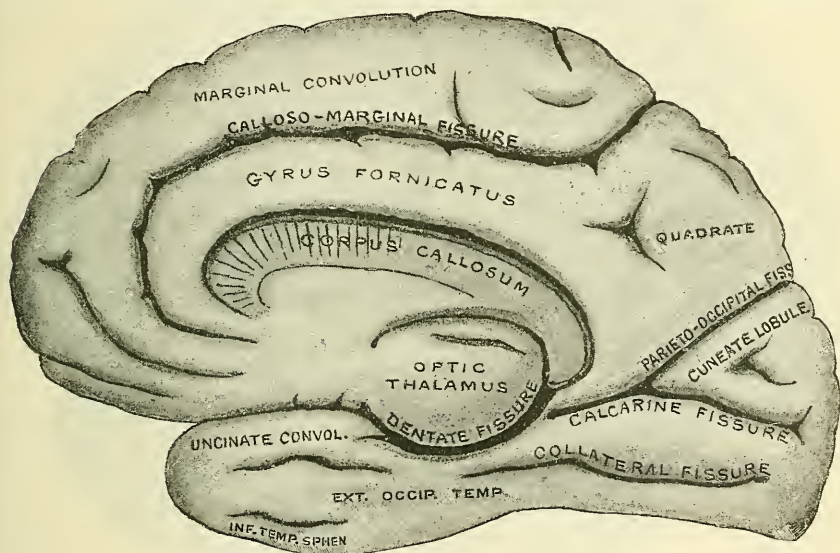
The **occipital lobe** is triangular in shape and forms the posterior extremity of the hemisphere. It is bounded in front by the external parieto-occipital fissure and a line drawn from the extremity of this in the direction of the fissure across the outer surface of the hemisphere. It is continuous below and in front with the temporo-sphenoidal lobe, and above with the parietal. It is divided on the outer surface of the hemisphere into three convolutions by two indistinct sulci, the *superior* and *middle occipital sulci*. They are directed backwards across the lobe, being frequently small and ill-marked; the superior is sometimes continuous with the horizontal portion of the intraparietal sulcus.

The *superior occipital convolution* is situated above the superior sulcus, and is connected to the superior parietal convolution by the *first annectant gyrus*.

The *middle occipital convolution* is situated between the superior and middle occipital sulci, and is connected to the angular convolution by the *second annectant gyrus*, and to the middle temporo-sphenoidal by the *third annectant gyrus*.

The *inferior occipital convolution* is situated below the middle occipital sulcus, and is sometimes separated from the external occipito-temporal convolution on

FIG. 461.—Convolution and fissures of the inner surface of the cerebral hemisphere.



the under surface of the hemisphere by an inconstant sulcus, the *inferior occipital sulcus*. It is connected to the inferior temporo-sphenoidal convolution by the *fourth annectant gyrus*.

The **temporo-sphenoidal lobe** is that portion of the hemisphere which is lodged in the middle fossa of the base of the skull. In front and above, it is limited by the fissure of Sylvius; behind, it is connected with the parietal and occipital lobes, and is limited artificially by a line continuing the direction of the external parieto-occipital fissure across the outer surface of the hemisphere. It is divided into three convolutions by two sulci. The superior of these runs parallel to the horizontal limb of the fissure of Sylvius. It is named the *superior temporo-sphenoidal* or *parallel sulcus*, and is well marked and constant. The second, the *middle temporo-sphenoidal*, is not so well marked or constant; it takes the same course at a lower level.

The *superior temporo-sphenoidal convolution* is situated between the horizontal limb of the fissure of Sylvius and the superior temporo-sphenoidal sulcus. It is continuous behind with the supramarginal convolution.

The *middle temporo-sphenoidal convolution* is situated between the superior

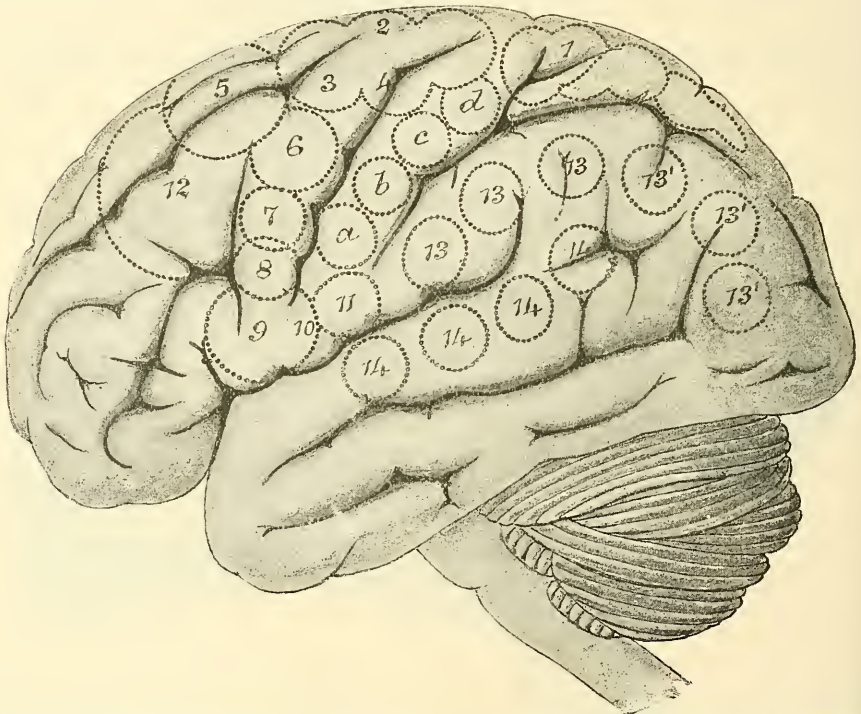


and middle sulci of the same name, and is continuous behind with the angular and middle occipital convolutions.

The *inferior temporo-sphenoidal convolution* is situated below the middle temporo-sphenoidal sulcus, and is separated from the external occipito-temporal convolution, on the under surface of the hemisphere, by a sulcus which is called the *inferior temporo-sphenoidal sulcus*. It is connected with the inferior occipital convolution.

The **central lobe**, or **island of Reil** (fig. 46o), is situated in the fissure of Sylvius, at the base of the brain; it is separated, in front, from the posterior orbital convolution by a nearly transverse sulcus, the *anterior sulcus of Reil*; externally, from the inferior frontal convolution and the lower ends of the ascending frontal and parietal convolutions, by another deep sulcus, the *external sulcus of Reil*; and posteriorly, from the temporo-sphenoidal lobe, by a third sulcus, the *posterior*

FIG. 462.—Side view of the brain of man, showing the localisation of various functions. (After Ferrier.)



1. Centre for movements of opposite leg and foot. 2, 3, 4. Centres for complex movements of the arms and legs, as in swimming. 5. Extension forwards of the arm and hand. 6. Supination of the hand and flexion of the forearm. 7, 8. Elevators and depressors of the angle of the mouth. 9, 10. Movements of the lips and tongue. 11. Retraction of the angle of the mouth. 12. Movements of the eyes. 13, 13'. Vision. 14. Hearing. a, b, c, d. Movements of the wrists and fingers.

*sulcus of Reil*. It is a triangular-shaped prominent cluster of about six convolutions, the *gyri operi*, so called from being covered in by the fissure. By the removal of these convolutions the extraventricular part of the corpus striatum would be reached.

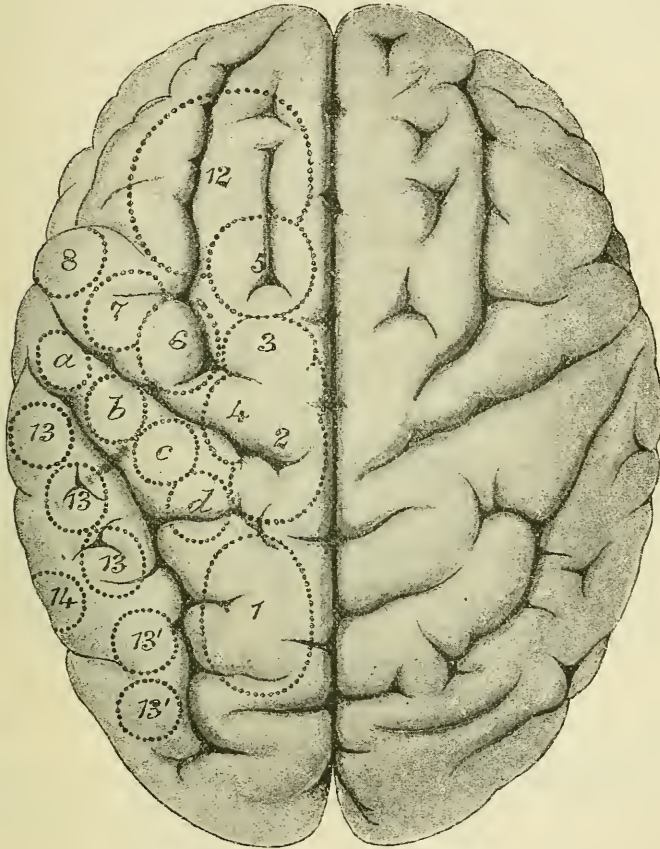
On the **inner or median surface of the hemispheres** the arrangement of the convolutions is less complex; they are generally well defined, and some of them being of great length, there is not the same subdivision into smaller lobes as on the external surface (fig. 46r). The fissures on the internal surface are five in number, and are named the *calloso-marginal*, the *parieto-occipital*, the *calcarine*, the *collateral*, and the *dentate*.

The **calloso-marginal fissure** is seen in front, commencing below the anterior extremity of the corpus callosum; it at first runs forwards and upwards parallel

with the rostrum of the corpus callosum, and, winding round the genu of that body, it continues from before backwards, between the upper margin of the hemisphere and the convolution of the corpus callosum, to about midway between the anterior and posterior extremities of the brain, where it turns upwards to reach the upper margin of the inner surface of the hemisphere a short distance behind the superior extremity of the furrow of Rolando. It separates the marginal convolution from the gyrus fornicatus or convolution of the corpus callosum.

The **parieto-occipital fissure** (*internal parieto-occipital*) is the continuation of the fissure of the same name seen on the outer surface of the hemisphere. It

FIG. 463.—Top view of the brain of man, showing the localisation of various functions. (After Ferrier.)



References the same as in the preceding figure.

extends in an oblique direction downwards and forwards to join the calcarine fissure on a level with the hinder end of the corpus callosum. It separates the quadrate from the cuneate lobe.

The **calcarine fissure** commences, usually by two branches, at the back of the hemisphere, runs nearly horizontally forwards, and is joined by the parieto-occipital fissure, and continues nearly as far as the posterior extremity of the corpus callosum, to terminate a little below the level of this commissure. It separates the cuneate lobe from the uncinate gyrus, and causes the prominence known as the hippocampus minor or calcar avis, whence its name.

The **collateral fissure** is situated below the preceding, being separated from it by the uncinate gyrus. It runs forwards, from the posterior extremity of the brain, nearly as far as the commencement of the fissure of Sylvius. It runs between the internal and external occipito-temporal convolutions. It lies below



the posterior and middle horn of the lateral ventricle, and causes the prominence known as the *eminentia collateralis*.

The **dentate or hippocampal fissure** commences immediately below the posterior extremity of the corpus callosum, and runs forward to terminate at the recurved part of the uncinat gyrus. It corresponds with the prominence of the hippocampus major in the descending horn of the lateral ventricle.

The lobes or convolutions seen on the internal surface of the hemisphere are six in number, and are named: *gyrus fornicatus*, *marginal*, *quadrate*, *cuneate*, *uncinate* or *internal occipito-temporal*, and the *external occipito-temporal*.

The **gyrus fornicatus**, or convolution of the corpus callosum, is a well-marked lobe which begins just in front of the anterior perforated space at the base of the brain; it ascends in front of the genu of the corpus callosum, and runs backwards along the upper surface of this body to its posterior extremity, where it joins the uncinat convolution. It is bounded above in the greater part of its extent by the calloso-marginal fissure, which separates it from the marginal convolution; behind the spot where this fissure turns upwards it is continuous with the quadrate lobe.

The **marginal convolution** is situated above the preceding, and has received its name from its position along the border of the hemisphere. It commences in front of the anterior perforated space, runs along the margin of the longitudinal fissure on the under surface of the orbital lobe, being bounded externally by the sulcus for the olfactory tract; it then turns upwards to the upper surface of the hemisphere, and runs backwards, forming the marginal convolution, on the inner surface, to the point where the calloso-marginal fissure turns upwards to reach the superior border of the hemisphere.

The **quadrate lobe** (*precuneus*) is the marginal convolution of the longitudinal fissure behind the calloso-marginal sulcus, lying between this fissure in front and the internal parieto-occipital behind. It joins the gyrus fornicatus below, and is continuous above with the superior parietal convolution.

The **cuneate or occipital lobule** is triangular in shape, being situated between the internal parieto-occipital and calcarine fissures, which, as above mentioned, meet behind the posterior extremity of the gyrus fornicatus.

The **uncinate or internal occipito-temporal convolution** extends from the posterior extremity of the hemisphere to the fissure of Sylvius, being bounded above by the calcarine and dentate fissure and separated below from the external occipito-temporal convolution by the collateral fissure. From the anterior extremity a narrow portion is recurved or bent backwards in the form of a hook, which is sometimes called the *crochet* or *uncus*. The back part of this convolution—that is, the part below the calcarine fissure—is sometimes known as the *lingual lobule* or *gyrus*.

The **external occipito-temporal convolution** is of considerable length, and lies between the collateral fissure and the inferior temporo-sphenoidal sulcus, which latter separates it from the inferior temporo-sphenoidal convolution on the outer surface of the hemisphere.

Besides the great primary convolutions above named and described, and which can be recognised in almost any well-developed brain, there are a great number of secondary convolutions which pass from one primary convolution to another, and often render the arrangement of the latter somewhat obscure; of these, the connections of the occipital lobe, above mentioned, and which are named *annectant convolutions*, may be taken as examples.

*Cerebral Localisation and Topography.*—Within the last few years physiological and pathological research have gone far to prove that the surface of the brain may be mapped out into series of definite areas, each one of which is intimately connected with some well-defined function. And this is especially true with regard to the convolutions on either side of the fissure of Rolando, which are believed by most physiologists of the present day to be concerned in motion, those grouped around the fissure being associated with movements of the extremities of the opposite side of the body, and those around the lower end of the fissure being related to movements of the mouth and tongue.

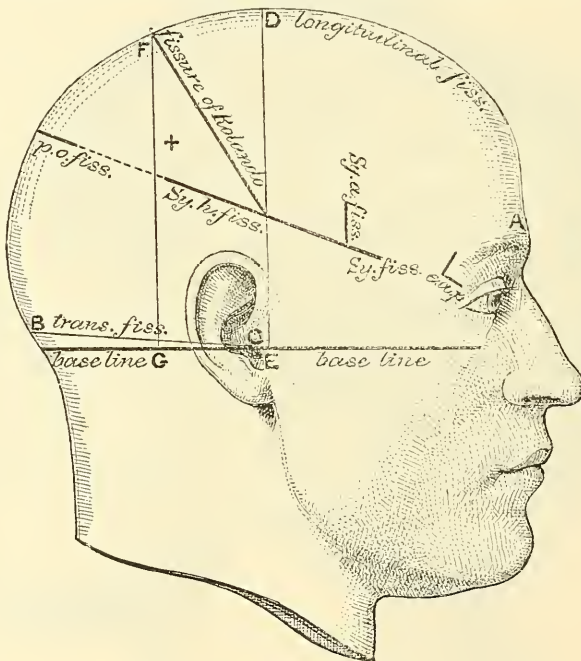
This is not the place, nor can space be given, to describe these localities. But the two





the top of the sulcus will be, measuring from in front, 55·6 per cent. of the whole distance from the glabella to the external occipital protuberance. Professor Thane adopts a somewhat simpler method. He divides the distance from the glabella to the external occipital protuberance over the top of the head into two equal parts, and having thus defined the middle point of the vertex, he takes half an inch behind it as the top of the sulcus. This is not quite so accurate as the former method, but it is sufficiently so for all practical purposes, and, on account of its simplicity, is very generally adopted. From this point the fissure runs downwards and forwards for  $3\frac{3}{4}$  inches, its axis making an angle of  $67^\circ$  with the middle line. Cunningham states that this angle more nearly averages  $71\cdot5^\circ$ . In order to mark this groove, two strips of metal may be employed: one, the shorter, being fixed to the middle of the other at the angle mentioned. If the longer strip is now placed along the sagittal suture so that the junction of the two strips is over the point corresponding to the top of the furrow, the shorter, oblique strip will indicate the direction, and  $3\frac{3}{4}$  inches will mark the length of the furrow. Dr. Wilson has devised an instrument, called a cystometer, which combines the scale of measurements for localising the fissure, with data for representing its length and direction.\* Professor Thane gives the lower end of the furrow as 'close to the posterior limb, and about half an inch behind the bifurcation of the fissure of Sylvius.' So that, according to this anatomist, a line drawn from a point

FIG. 465.—Relation of the principal fissures and convolutions of the cerebrum to the outer surface of the scalp. (Reid.)



half an inch behind the mid-point between the glabella and external occipital protuberance to this spot would mark out the fissure of Rolando. Dr. Reid adopts a different method (fig. 465). He first indicates, on the surface, the longitudinal fissure and the horizontal limb of the fissure of Sylvius (as above). He then draws two perpendicular lines from his 'base-line' (that is, a line from the lowest part of the infra-orbital margin through the middle of the external auditory meatus to the back of the head) to the top of the cranium, one (D E, fig. 465) from the depression in front of the external auditory meatus, and the other (F G, fig. 465) from the posterior border of the mastoid process at its root. He has thus described on the surface of the head a four-sided figure (F D G E, fig. 465), and a diagonal line from the posterior superior angle to the anterior perpendicular line where it is crossed by the fissure of Sylvius will represent the furrow.

The *parieto-occipital fissure* on the upper surface of the cerebrum runs outwards at right angles to the great longitudinal fissure for about an inch, from a point  $\frac{1}{3}$ th of an inch in front of the lambda (posterior fontanelle). Reid states that if the horizontal limb of the fissure of Sylvius be continued onwards to the sagittal suture, the last inch of this line will indicate the position of the sulcus.

The *precentral sulcus* lies in a line drawn vertically downwards from the point of

\* *Lancet*, vol. i. 1888, p. 408.



junction of the sagittal and coronal sutures. It begins four-fifths of an inch in front of the middle of the fissure of Rolando, and extends nearly, but not quite, to the horizontal limb of the fissure of Sylvius.

The *superior frontal fissure* runs backwards from the supra-orbital notch, parallel with the line of the longitudinal fissure to  $\frac{2}{3}$ th of an inch in front of the line indicating the position of the fissure of Rolando.

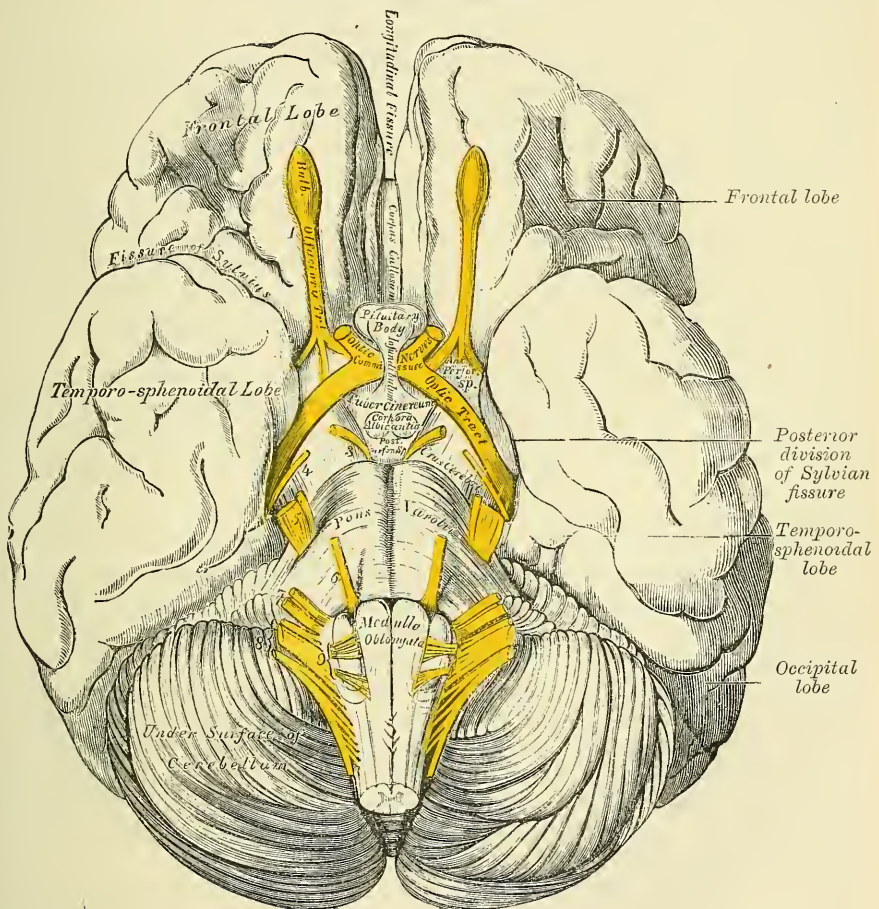
The *inferior frontal fissure* follows the course of the superior temporal ridge on the frontal bone.

The *intraparietal fissure* begins on a level with the junction of the middle and lower third of the fissure of Rolando, on a line carried across the head from the back of the root of one auricle to that of the other. After passing upwards, it curves backwards, lying parallel to the longitudinal fissure, midway between it and the parietal eminence; it then curves downwards to end midway between the posterior fontanelle and the parietal eminence.

### CEREBRUM. UNDER SURFACE OR BASE (fig. 466)

The under surface of each hemisphere presents a subdivision into three lobes, named, from their position, *anterior*, *middle*, and *posterior*.

FIG. 466.—Base of the brain.



The **anterior** or **frontal lobe**, of a triangular form, with its apex backwards, is somewhat concave, and rests upon the convex surface of the roof of the orbit, being separated from the middle lobe by the fissure of Sylvius. The **middle lobe**, which is more prominent, is received into the middle fossa of the base of the skull, and comprises the under part of the temporo-sphenoidal lobe. The **posterior** or **occipital lobe** rests upon the tentorium, its extent forwards being limited by the anterior margin of the cerebellum.



The various objects exposed to view on the under surface of the cerebrum, in and near the middle line, are here arranged in the order in which they are met with from before backwards.

Longitudinal fissure.	Optic commissure.
Corpus callosum and its peduncles.	Tuber cinereum.
Lamina cinerea.	Infundibulum.
Olfactory tract.	Pituitary body.
Fissure of Sylvius.	Corpora albicantia.
Anterior perforated space.	Posterior perforated space.
Crura cerebri.	

The **longitudinal fissure** partially separates the two hemispheres from each other: it divides the two frontal lobes in front; and on raising the cerebellum and pons, it will be seen completely separating the two occipital lobes. Of these two portions of the longitudinal fissure, that which separates the occipital lobes is the longer. The intermediate portion of the fissure is filled up by the great transverse band of white matter, the *corpus callosum*. In the fissure between the two frontal lobes the anterior cerebral arteries ascend on the corpus callosum.

The **corpus callosum** terminates at the base of the brain by a concave margin, which is connected with the tuber cinereum through the intervention of a thin layer of grey substance, the *lamina cinerea*. This may be exposed by gently raising and drawing back the optic commissure. A white band may be observed on each side, passing from the under surface of the corpus callosum, backwards across the posterior margin of the anterior space to the temporo-sphenoidal lobe; here they join the inner root of the olfactory tract: these bands are called the *peduncles of the corpus callosum*. They may be traced upwards around the genu to become continuous with the *striae longitudinales*, or *nerves of Lancisi*, on the upper surface of the corpus callosum (page 751). Laterally, this portion of the corpus callosum extends into the frontal lobe.

The **lamina cinerea** is a thin layer of grey substance, extending backwards above the optic commissure from the termination of the corpus callosum to the tuber cinereum; it is continuous on each side with the grey matter of the anterior perforated space, and forms the anterior part of the inferior boundary of the third ventricle.

The **olfactory tract**, with its bulb, is seen on each side of the longitudinal fissure upon the under surface of each frontal lobe.

The **fissure of Sylvius** separates the frontal from the temporo-sphenoidal lobe, and lodges the middle cerebral artery. It begins at the outer side of a depression, at the bottom of which is the anterior perforated space. This depression is called the *vallecula Sylvii*. At its commencement is seen a point of medullary substance, corresponding to a subjacent band of white fibres, connecting the frontal and temporo-sphenoidal lobes, and called the *fasciculus unciformis*. On following this fissure outwards, it divides into two branches, enclosing portions of the frontal and parietal lobes, which overhang and cover the upper part of a prominent cluster of isolated convolutions called the *island of Reil*, or *central lobe*. The overhanging portion of the frontal and parietal lobe is called the *operculum of the insula*.

The **anterior perforated space** is situated at the inner side of the fissure of Sylvius. It is of a triangular shape, bounded, in front, by the orbital convolutions of the frontal lobe and the roots of the olfactory tract; behind, by the optic tract; externally, by the temporo-sphenoidal lobe and commencement of the fissure of Sylvius; internally, it is continuous with the lamina cinerea, and crossed by the peduncle of the corpus callosum. It is of a greyish colour, and corresponds to the under surface of the corpus striatum, a large mass of grey matter, situated in the interior of the brain; it has received its name from being perforated by numerous minute apertures for the transmission of small straight vessels into

the substance of the corpus striatum, constituting the antero-median and antero-lateral ganglionic branches of the anterior and middle cerebral arteries.

The **optic commissure** is situated in the middle line, immediately in front of the tuber cinereum and below the lamina cinerea.\* It is the point of junction between the two optic nerves.

Immediately behind the diverging optic tracts, and between them and the peduncles of the cerebrum (*crura cerebri*), is a lozenge-shaped interval, the *interpeduncular space*, in which are found the following parts: the tuber cinereum, infundibulum, pituitary body, corpora albicantia, and the posterior perforated space.

The **tuber cinereum** is an eminence of grey matter, situated between the optic tracts and extending from the corpora albicantia to the optic commissure, to which it is attached; it is connected with the surrounding parts of the cerebrum, forms part of the floor of the third ventricle, and is continuous with the grey substance in that cavity. From the middle of its under surface a conical tubular process of grey matter, about two lines in length, is continued downwards and forwards, to be attached to the posterior lobe of the pituitary body: this is the *infundibulum*. Its canal, which is funnel-shaped, communicates with the third ventricle.

The **pituitary body** (*hypophysis cerebri*) is a small reddish-grey vascular mass, weighing from five to ten grains, and of an oval form, situated in the sella Turcica, in connection with which it is retained by a process of dura mater derived from the inner wall of the cavernous sinus. This process covers in the pituitary fossa, enclosing the pituitary body, and having a small hole in its centre through which the infundibulum passes.

**Structure.**—The pituitary body is very vascular, and consists of two lobes, separated from one another by a fibrous lamina. Of these, the anterior is the larger, of an oblong form, and somewhat concave behind, where it receives the posterior lobe, which is round. The two lobes differ both in development and structure. The *anterior lobe*, of a dark, yellowish-grey colour, is developed from the ectoderm of the buccal cavity, and resembles to a considerable extent, in microscopic structure, the thyroid body. It consists of a number of isolated vesicles and slightly convoluted alveoli, lined by epithelium and united together by connective tissue. The epithelium is columnar and occasionally ciliated. The alveoli sometimes contain a colloid material, similar to that found in the thyroid body, and their walls are surrounded by a close network of lymphatics and capillary blood-vessels. The *posterior lobe* is developed by an outgrowth from the embryonic brain, and during foetal life contains a cavity which communicates through the infundibulum with the cavity of the third ventricle. In the adult it becomes firmer and more solid, and consists of a sponge-like connective tissue arranged in the form of reticulating bundles, between which are branched cells, some of them containing pigment. In the lower animals the two lobes are quite distinct, and it is only in the mammalia that they become connected together.

The **corpora albicantia**, or **mammillaria**, are two small, round, white masses, each about the size of a pea, placed side by side immediately behind the tuber cinereum. They are formed by the anterior crura of the fornix, hence called the *bulbs of the fornix*, which, after descending to the base of the brain, are folded upon themselves before passing upwards to the thalami optici. They are composed externally of white substance, and internally of grey matter; the grey matter of the two being connected by a transverse commissure of the same material. At an early period of fetal life they are blended together into one large mass, but become separated about the seventh month.

The **posterior perforated space** (*pons Varolii*) corresponds to a whitish-grey substance placed between the corpora albicantia in front, the pons Varolii behind,

\* That is to say, the commissure is superficial to the lamina in the order of dissection when the base is uppermost.



and the *crura cerebri* on each side. It forms the back part of the floor of the third ventricle. It is perforated by numerous small orifices for the passage of the postero-median ganglionic branches of the posterior cerebral and posterior communicating arteries.

The *crura cerebri* (*peduncles of the cerebrum*) are two thick cylindrical bundles of white matter, which emerge from the anterior border of the pons, and diverge as they pass forwards and outwards to enter the under part of either hemisphere. Each crus is about three-quarters of an inch in length, and somewhat broader in front than behind. They are marked upon their surface with longitudinal striæ, and each is crossed, just before entering the hemisphere, by a flattened white band, the *optic tract*, which is adherent by its upper border to the peduncle. The third nerve may be seen emerging from a groove on the inner side of each crus, and the fourth nerve winding round its outer side from above.

**Structure of the Crura.**—Each crus consists of a superficial layer of longitudinal white fibres, the *crusta*, continued upwards from the pons; of a deeper layer, a prolongation of the reticular formation, termed the *tegmentum*; and of an intermediate stratum of grey matter, the *locus niger*.

The *crusta*, or the superficial layer of longitudinal fibres, consists of coarse bundles of nerve-fibres, which are collected on the under or free surface of the crus. It is formed almost entirely of longitudinal fibres continuous with the pyramidal fibres of the medulla and pons, those derived from the medulla occupying the central portion of the crusta, those added in the pons being placed laterally. The fibres pass to the cerebral hemispheres, entering the internal capsule.

The *tegmentum* forms the deeper part of the crus cerebri, and is united below with its fellow of the opposite side by a prolongation of the septum of the pons but separated above by the posterior perforated space. It consists of longitudinal bundles of white fibres, interlaced by transverse fibres, together with a quantity of grey matter with scattered nerve-cells. It forms a well-marked *formatio reticularis* similar to that found in the pons and medulla, with which it is continuous, receiving, however, a bundle of fibres (*superior peduncle*) from the cerebellum. Above, the fibres enter the optic thalamus.

The *locus niger* is a mass of grey matter, situated between the crusta and tegmentum, and projecting here and there between the bundles of the former. It is thicker at the inner than at the outer side, and is traversed in its mesial part by the fibres of origin of the third nerve. It contains irregular nerve-cells, in which are lodged numerous dark pigment-granules.

The posterior lobes of the cerebrum are concealed from view by the upper surface of the cerebellum and pons Varolii. When these parts are raised, the two hemispheres are seen to be separated by the great longitudinal fissure, this fissure being interrupted by the posterior rounded border of the corpus callosum.

#### GENERAL ARRANGEMENT OF THE PARTS COMPOSING THE CEREBRUM

As the peduncles or crura of the cerebrum enter the hemispheres, they diverge from one another, so as to leave an interval between them, the *interpeduncular space*. As they ascend, the component fibres of each pass through two large masses of grey matter, the ganglia of the brain, called the *thalamus opticus* and *corpus striatum*, which project as rounded eminences from the upper and inner side of each peduncle. The hemispheres are connected together, above these masses, by the great transverse commissure, the *corpus callosum*; the interval left between its under surface, the upper surface of the ganglia, and the parts closing the interpeduncular space, forms the general ventricular cavity. The upper part of this cavity is subdivided into two by a vertical septum, the *septum lucidum*; and thus the two lateral ventricles are formed. The lower part of the cavity forms the third ventricle, which communicates with the lateral ventricles above, and with the fourth ventricle behind. The fifth ventricle is the interval left between the two layers composing the septum lucidum.



## INTERIOR OF THE CEREBRUM

If the upper part of either hemisphere is removed with a scalpel, about half an inch above the level of the corpus callosum, its internal white matter will be exposed. It is an oval-shaped centre, of white substance, surrounded on all sides by a narrow convoluted margin of grey matter which presents an equal thickness in nearly every part. This white central mass has been called the *centrum ovale minus*. Its surface is studded with numerous, minute red dots (*puncta vasculosa*), produced by the escape of blood from divided blood-vessels. In inflammation or great congestion of the brain, these are very numerous, and of a dark colour. If the remaining portion of one hemisphere is slightly separated from the other, a broad band of white substance will be observed connecting them at the bottom of the longitudinal fissure; this is the *corpus callosum*. The margins of the hemispheres which overlap this portion of the brain are called the *labia cerebri*. Each labium is part of the convolution of the corpus callosum (*gyrus fornicatus*) already described; and the space between it and the upper surface of the corpus callosum has been termed the *ventricle of the corpus callosum* or *callosal fissure* (fig. 470).

The hemispheres should now be sliced off, to a level with the corpus callosum, when the white substance of that structure will be seen connecting the two hemispheres. The large expanse of medullary matter now exposed, surrounded by the convoluted margin of grey substance, is called the *centrum ovale majus* of Vieussens.

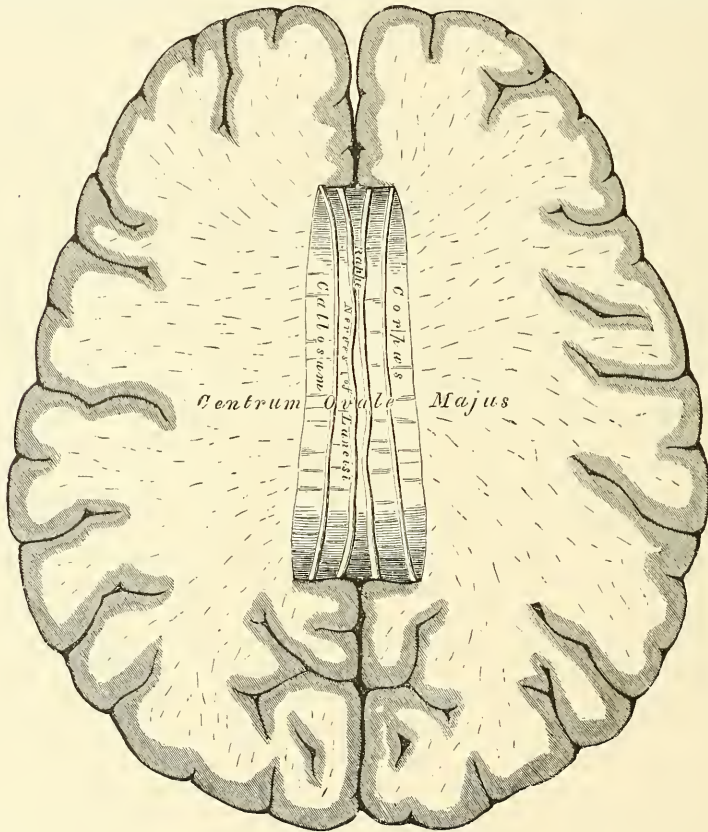
The **corpus callosum** is a thick stratum of transverse fibres, exposed at the bottom of the longitudinal fissure. It connects the two hemispheres of the brain, forming their great transverse commissure; and forms the roof of the space in the interior of each hemisphere, the *lateral ventricle*. It is about four inches in length, extending to within an inch and a half of the anterior, and to within two inches and a half of the posterior, part of the brain. It is somewhat broader behind than in front, and is thicker at either end than in its central part, being thickest behind. It presents a somewhat arched form (figs. 474, 5), from before backwards, and in front forms a distinct bend, named the *genu*, and is then continued downwards and backwards between the frontal lobes to the base of the brain, where it is connected, through the lamina cinerea, with the tuber cinereum. The reflected portion of the corpus callosum is called the *beak* or *rostrum*; it becomes gradually narrower as it descends, and is attached by its lateral margins to the frontal lobes. At its termination the corpus callosum gives off two bundles of white substance, which, diverging from one another, pass backwards, across the anterior perforated space, temporo-sphenoidal lobe, where they join the inner root of the olfactory tract. They are called the *peduncles of the corpus callosum*. Posteriorly, the corpus callosum forms a thick rounded fold, called the *splenium*, or *pad*, which is free for a little distance, as it curves forwards, and is then continuous with the fornix. On its upper surface, the structure of the corpus callosum is very apparent, being collected into coarse transverse bundles. Along the middle line is a linear depression, the *raphé*, bounded laterally by two or more slightly elevated longitudinal bands, called the *striæ longitudinales* or *nerves of Lancisi*; and, still more externally, other longitudinal striæ are seen, beneath the convolutions which rest on the corpus callosum. These are the *striæ longitudinales laterales* or *taniæ tectæ*. The under surface of the corpus callosum is continuous behind with the fornix, being separated from it in front by the septum lucidum, which forms a vertical partition between the two ventricles. On each side, the fibres of the corpus callosum extend into the substance of the hemispheres, connecting them together. The greater thickness of the two extremities of this commissure is explained by the fact that the fibres from the anterior and posterior parts of each hemisphere cannot pass directly across, but have to take a curved direction.

An incision should now be made through the corpus callosum, on either side of the raphé, when two large irregular-shaped cavities will be exposed, which extend through a great part of the length of each hemisphere. These are the lateral ventricles.

The **lateral ventricles** are serous cavities, formed by the upper part of the general ventricular space in the interior of the brain. They are lined by a thin diaphanous lining membrane (the *ependyma*), covered by nucleated epithelium, with cilia scattered here and there in patches. It is moistened by a serous fluid, which is sometimes, even in health, secreted in considerable quantity. These cavities are two in number, one in each hemisphere, and they are separated from each other by a vertical septum, the *septum lucidum*.

Each lateral ventricle consists of a central cavity, or *body*, and three smaller cavities or *cornua*, which extend from it in different directions. The anterior cornua curves forwards and outwards into the substance of the frontal lobe. The posterior cornu, called the *digital cavity*, curves backwards into the occipital lobe. The middle cornu descends into the temporo-sphenoidal lobe.

FIG. 467.—Section of the brain. Made on a level with the corpus callosum.



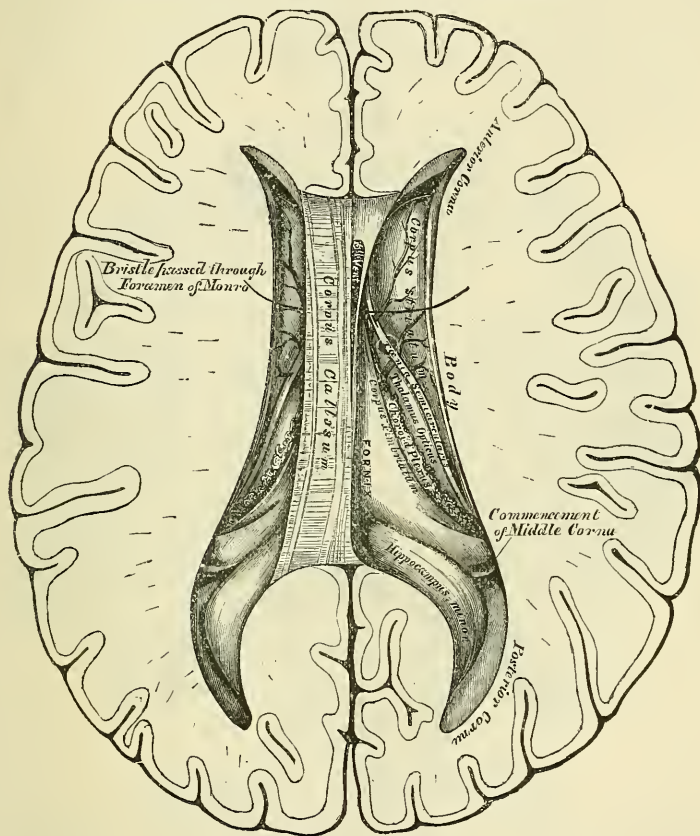
The *central cavity*, or body of the lateral ventricle, is triangular in form. It is bounded, above, by the under surface of the corpus callosum, which forms the roof of the cavity. Internally is a vertical partition, the *septum lucidum*, which separates it from the opposite ventricle, and connects the under surface of the corpus callosum with the fornix. Its floor is formed by the following parts, enumerated in their order of position, from before backwards: the *corpus striatum*, *tania semicircularis*, *optic thalamus*, *choroid plexus*, *fornix*, and commencement of its *corpus fimbriatum*.

The *anterior cornu* is triangular in form, passing outwards into the frontal lobe, and curving round the anterior extremity of the corpus striatum. It is bounded, above, by the corpus callosum; below and externally, by the corpus striatum; and in front, by the reflected portion of the corpus callosum.

The *posterior cornu*, or *digital cavity*, curves backwards into the substance of the occipital lobe, its direction being backwards and outwards, and then inwards. On its inner wall is seen a longitudinal eminence, which is produced by the extension inwards of the calcarine sulcus; this is called the *hippocampus minor*, or *calcar avis*. Between the middle and posterior horns a smooth eminence is observed, which varies considerably in size in different subjects. It is called the *eminencia collateralis*.

The *middle* or *descending cornu*, the largest of the three, traverses the middle lobe of the brain, forming in its course a remarkable curve round the back of the optic thalamus. It passes, at first, backwards, outwards, and downwards, and then curves round the crus cerebri, forwards and inwards, nearly to the point of

FIG. 468.—The lateral ventricles of the brain.



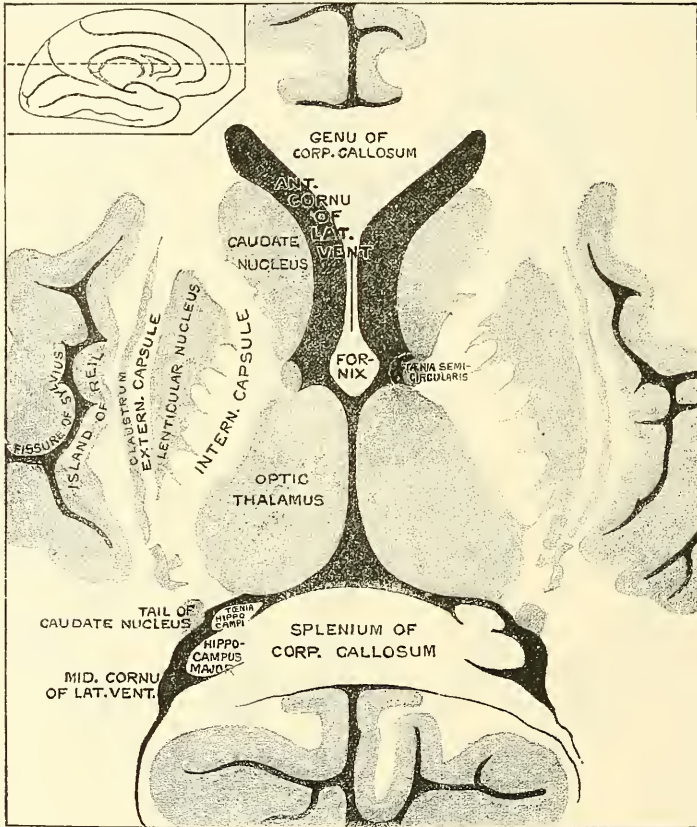
the middle lobe, close to the fissure of Sylvius. Its upper boundary, or roof, is formed by the fibres of the corpus callosum, passing downwards and outwards into the temporo-sphenoidal lobe, with which are incorporated the posterior fibres of the nucleus caudatus and tænia semicircularis, which are prolonged into it. Its lower boundary, or floor, presents for examination the following parts: the *hippocampus major*, *pes hippocampi*, *eminencia collateralis*, or *pes accessorius*, *corpus fimbriatum* of the fornix, *choroid plexus*, *fascia dentata*, *transverse fissure*.

The **corpus striatum** has received its name from the striped appearance which its section presents, in consequence of diverging white fibres being mixed with the grey matter which forms the greater part of its substance. The greater portion of this body is embedded in the white substance of the hemisphere, and is therefore external to the ventricle. It is termed the *extraventricular portion*,



or the *nucleus lenticularis*; a part, however, is visible in the ventricle and its anterior cornu; this is the *intraventricular portion*, or the *nucleus caudatus*. The intraventricular portion is a pear-shaped mass of grey matter; its broad extremity is directed forwards into the fore part of the body and anterior cornu of the lateral ventricle; its narrow end is directed outwards and backwards, and lies on the outer side of the optic thalamus, and is continued into the roof of the descending cornu: it is covered by the serous lining of the cavity, and crossed by some veins of considerable size. It is separated from the extraventricular portion by a lamina of white matter, which is called the *internal capsule*, in contradistinction to a lamina of white matter which covers the outer surface of the extraventricular portion of the corpus striatum, and which is called the

Fig. 469.—Middle part of a horizontal section through the cerebrum at the level of the dotted line in the small figure of one hemisphere. (From Ellis, after Dalton.)

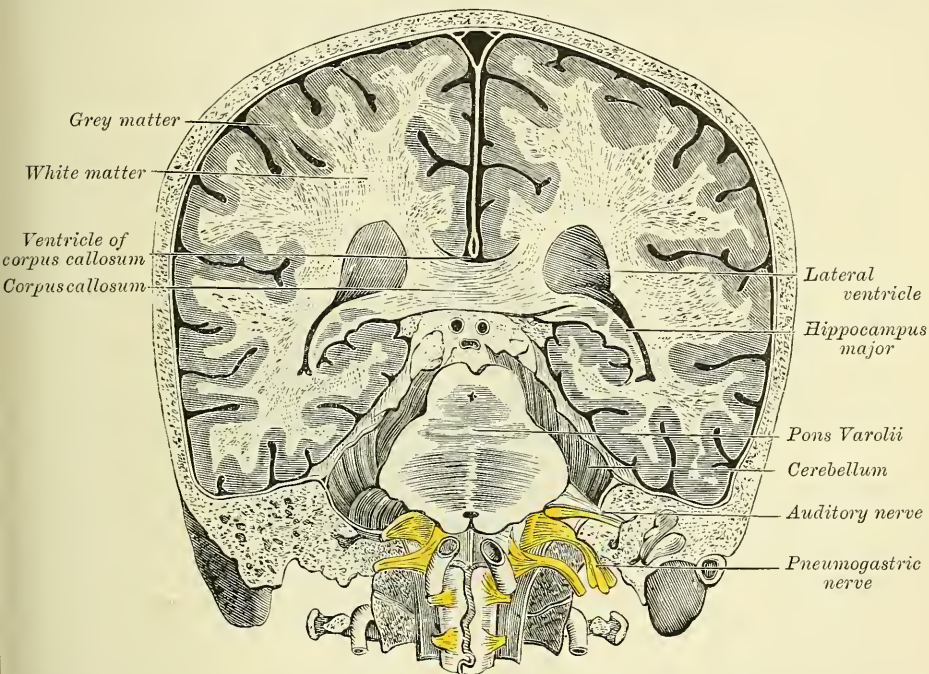


*external capsule*. The internal capsule is formed by fibres of the crista of the crus cerebri, supplemented by fibres derived from the nuclei on each side. In horizontal section it is seen to be somewhat abruptly curved, with its convexity inwards; the prominence of the curve is called the *genu*, and projects between the intraventricular portion of the corpus striatum and the optic thalamus (fig. 469). The extraventricular portion of the corpus striatum, or nucleus lenticularis, is oval in form. It does not extend as far forwards or backwards as the nucleus caudatus. It is bounded externally by a lamina of white matter called the *external capsule*, which is covered on its outer surface by a thin layer of grey matter termed the *claustrum*. The claustrum presents ridges and furrows on its outer surface, corresponding to the convolutions and sulci of the island of Reil, with the white matter of which it is in immediate relation.

The *tænia semicircularis* is a narrow, whitish, semi-transparent band of medullary substance, situated in the depression between the nucleus caudatus and optic thalamus. Anteriorly its connections are somewhat obscure, but probably some of its fibres, if not all, are continued into the anterior pillar of the fornix. It passes upwards and backwards through the lateral ventricle, and is continued into the roof of its middle or descending horn, at the extremity of which it enters a mass of grey matter, the nucleus amygdalæ. Beneath it is a large vein (*vena corporis striati*), which receives numerous small veins from the surface of the corpus striatum and optic thalamus, and joins the *venæ Galeni*.

The *choroid plexus* is a highly vascular, fringe-like structure, which borders a triangular fold of pia mater, the *velum interpositum*, which lies on the under surface of the fornix and forms the roof of the third ventricle. As this mem-

FIG. 470.—Transverse vertical section of the brain, through the fore part of the foramen magnum, looked at from the front. (After Hirschfeld and Leveillé.)



brane reaches the lateral borders of the fornix it projects from under its edge, and, becoming fringed, it forms the choroid plexus, which is seen on the floor of the lateral ventricle. In front, the choroid plexus is small and tapering, and communicates with the choroid plexus of the opposite side, through an oval aperture, the *foramen of Monro*. Posteriorly, it descends into the middle horn of the lateral ventricle, where it joins with the pia mater through the transverse fissure. In structure, it consists of minute and highly vascular villous processes, containing an afferent and efferent vessel, and covered by a single layer of flattened epithelium, the cells of which often contain a yellowish fat molecule. The arteries of the choroid plexus enter the ventricle at the descending cornu, and, after ramifying through its substance, send branches into the substance of the brain. The veins of the choroid plexus terminate in the *venæ Galeni*.

The *corpus fimbriatum* (*tænia hippocampi*) is a narrow, white, tape-like band, situated immediately behind the choroid plexus. It is the thin lateral edge of the posterior pillar of the fornix, and is attached along the inner border of



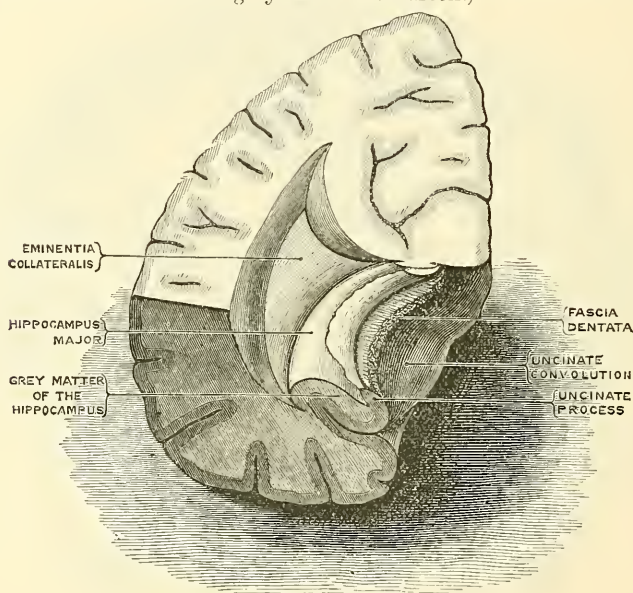
the hippocampus major as it descends into the middle horn of the lateral ventricle. It may be traced as far as the crochet or hook of the uncinatè convolution.

The *optic thalamus* and *fornix* will be described on a subsequent page.

The middle cornu should now be exposed, throughout its entire extent, by introducing the little finger gently into it, and cutting outwards along the finger through the substance of the hemisphere, which should be removed, to an extent sufficient to expose the entire cavity.

The **hippocampus major**, or **cornu Ammonis** (fig. 471), is a white eminence, of a curved elongated form, extending throughout the entire length of the floor of the middle horn of the lateral ventricle. At its lower extremity it becomes enlarged, and presents a number of rounded elevations with intervening depressions, which, from presenting some resemblance to the paw of an animal, is called the *pes hippocampi*. If a transverse section is made through the hippocampus major it will be seen that this eminence is produced by the

FIG. 471.—Transverse section of the middle horn of the lateral ventricle. (From a drawing by Mr. F. A. Barton.)



extension inwards of the dentate (hippocampal) sulcus on the exterior of the brain. This sulcus is filled with grey substance, which projects along the free margin of the hippocampus major, forming a notched ridge, the *fascia dentata*. The hippocampus is covered on its ventricular surface by a thin lamina of grey matter, which is continuous with the corpus fimbriatum of the fornix.

The **eminèntia collateralis**, or **pes accessorius**, has already been mentioned, as a white eminence, varying in size, placed between the hippocampus major and hippocampus minor, at the junction of the posterior with the descending cornu. It is formed by the protrusion inwards of the collateral fissure.

**Fascia dentata.**—On separating the inner border of the corpus fimbriatum from the choroid plexus, and raising the edge of the former, a serrated band of grey substance, the edge of the grey substance in the dentate fissure, will be seen beneath it: this is the *fascia dentata*. Correctly speaking, it is placed external to the cavity of the descending cornu.

The **transverse fissure** is of a horseshoe shape, extending from the end of the descending cornu on one side to the same point on the opposite side. Its horizontal portion (which extends from the commencement of the descending



cornu on one side to the same point on the opposite side) is bounded, above, by the splenium, or rounded posterior extremity of the corpus callosum, and the fornix; below, by the corpora quadrigemina, pineal gland, and the posterior extremity of the optic thalamus. Its lateral portions curve downwards, forwards, and inwards, and are bounded above by the crura cerebri and optic thalamus, and below by the hippocampus major and the corpus fimbriatum of the fornix. Through this fissure the pia mater passes from the exterior of the brain into the ventricles, to form the velum interpositum and the choroid plexuses. Where the pia mater projects into the lateral ventricle, beneath the edge of the fornix, it pushes the lining membrane of these cavities before it so as to exclude all communication with the exterior of the brain.

The **septum lucidum** (fig. 474, 6) forms the internal boundary of the lateral ventricles. It is a thin, semi-transparent septum, attached, above, to the under surface of the corpus callosum; below, to the anterior part of the fornix; and, in front of this, to the reflected portion of the corpus callosum. It is triangular in form, broad in front, and narrow behind, its surfaces looking towards the cavities of the ventricles. The septum consists of two laminæ, separated by a narrow interval, the *fifth ventricle*.

**Fifth Ventricle.**—The fifth ventricle was originally a part of the great longitudinal fissure, which has become shut off by the union of the hemispheres in the formation of the corpus callosum above, and the fornix below. Its walls are therefore formed by the median wall of the hemispheres, and consist of an internal layer of grey matter, derived from the grey matter of the cortex and an external layer of white substance continuous with the white matter of the cerebral hemispheres. This is lined on its external surface by the ependyma of the lateral ventricles. The fifth ventricle is not lined by epithelium. In the fœtus, and in some animals, this space communicates, below, with the third ventricle; but in the adult, it forms a separate cavity. In cases of serous effusion into the ventricles, the septum is often found softened and partially broken down.

The fifth ventricle may be exposed by cutting through the septum and attached portion of the corpus callosum, with scissors: after its examination the corpus callosum should be cut across, towards its anterior part, and the two portions carefully dissected, the one forwards, the other backwards, when the fornix will be exposed.

The **fornix** (figs. 468, 474) is a longitudinal lamella of white fibrous matter, situated beneath the corpus callosum, with which it is continuous behind, but separated in front by the septum lucidum. It may be described as consisting of two symmetrical halves, one for either hemisphere. These two portions are joined together in the middle line, where they form the *body*, but are separated from one another in front and behind; forming the *anterior* and *posterior crura*.

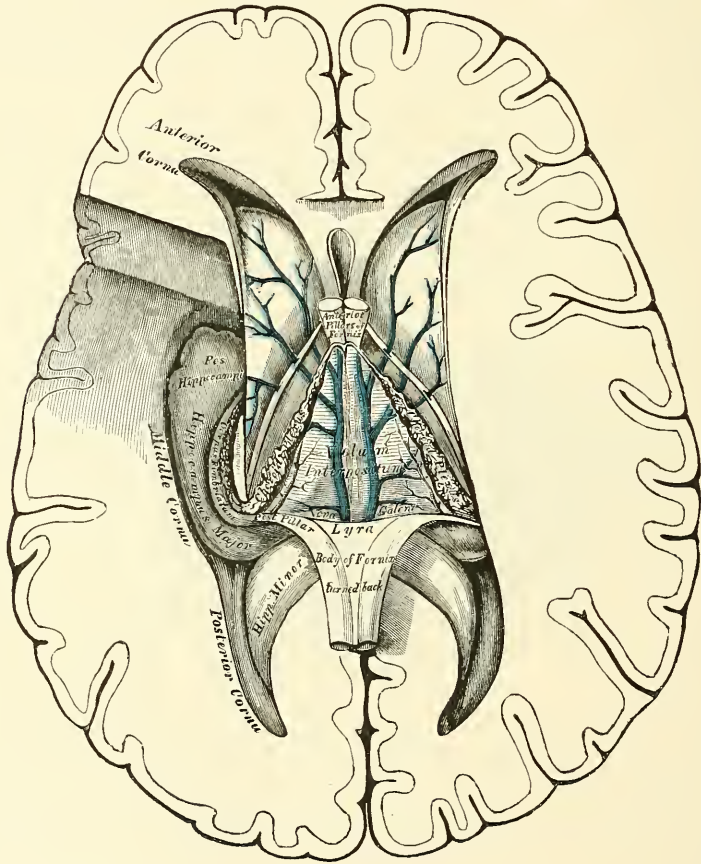
The *body of the fornix* is triangular; narrow in front, broad behind. Its upper surface is connected, in the median line, to the septum lucidum in front, and the corpus callosum behind, while laterally this surface forms part of the floor of each lateral ventricle. Its under surface rests upon the velum interpositum, which separates it from the third ventricle, and the inner portion of the optic thalami. Its outer edge, on each side, is free and is in contact with the choroid plexuses.

The *anterior crura* arch downwards towards the base of the brain, separated from each other by a narrow interval. They are composed of white fibres, which descend through a quantity of grey matter in the lateral walls of the third ventricle, and are placed immediately behind the anterior commissure. At the base of the brain, the white fibres of each crus form a sudden curve upon themselves, and spread out and form the outer part of the corresponding *corpus albicans*, from which point they may be traced upwards into the substance of the corresponding optic thalamus (fig. 474). The anterior crura of the fornix are connected in their course with the peduncle of the pineal gland and the superficial fibres of the tænia semicircularis, and receive fibres from the septum lucidum.

Between the anterior crura or pillars of the fornix and the anterior extremities of the optic thalami, an oval aperture is seen on each side: this is the *foramen of Monro* (fig. 473). The two openings descend towards the middle line, and lead into the upper part of the third ventricle. Through these openings the lateral ventricles on each side communicate with the third ventricle, and consequently with each other.

The *posterior crura*, at their commencement, are intimately connected by their upper surfaces with the corpus callosum; diverging from one another, they pass downwards into the descending horn of the lateral ventricle, being continuous with the concave border of the hippocampus major. The lateral thin edges of the posterior crura have received the name of *corpus fimbriatum*. Upon examining the under surface of the fornix, between its diverging posterior crura, a

FIG. 472.—The fornix, velum interpositum, and middle or descending cornu of the lateral ventricle.



triangular portion of the under surface of the corpus callosum may be seen. On it are a number of lines: some transverse, others longitudinal or oblique. This portion has been termed the *lyra*, from the fancied resemblance it bears to the strings of a harp.

Divide the fornix across anteriorly, and reflect the two portions, the one forwards, the other backwards, when the velum interpositum will be exposed.

The **velum interpositum** or *tela choroidea superior* (fig. 472) is a vascular membrane, a prolongation from the pia mater into the interior of the brain through the transverse fissure, passing beneath the posterior rounded border of the corpus callosum and fornix, and above the corpora quadrigemina, pineal



gland, and optic thalami. It is of a triangular form, and separates the under surface of the body of the fornix from the cavity of the third ventricle. Its posterior border forms an almost complete investment for the pineal gland, and is continuous with the general pia mater at the back and sides of the brain. Its anterior extremity, or apex, ends just behind the anterior pillars of the fornix, where it is connected with the smaller anterior extremities of the choroid plexuses, which are united through the foramen of Monro. On its under surface are the *choroid plexuses of the third ventricle*. Its lateral margins form the choroid plexuses of the lateral ventricles. Of the arteries of the velum interpositum, some branches from the superior cerebellar and posterior cerebral enter from behind, beneath the corpus callosum; another constant branch, the anterior choroid, enters the velum interpositum at the extremity of the middle horn of the lateral ventricle, and supplies this structure and the choroid plexus. The veins of the velum interpositum, the *venæ Galeni*, two in number, run between its layers; they are formed by the *venæ corporis striati* and the veins of the choroid plexuses; the *venæ Galeni* unite posteriorly into a single trunk, which terminates in the straight sinus (fig. 426).

The velum interpositum should now be removed. This must be effected carefully, especially at its posterior part, where it invests the pineal gland; the optic thalami will then be exposed with the cavity of the third ventricle between them (fig. 473).

The **optic thalami** are two large oblong masses, placed between the diverging portions of the corpora striata; they are of a white colour superficially; internally they are composed chiefly of grey matter. Each thalamus rests upon its corresponding crus cerebri, which it embraces. *Externally*, it is separated from the corpus striatum by the tænia semicircularis. *Internally*, it forms the lateral boundary of the third ventricle; and running along its upper and inner border is the peduncle of the pineal gland. Its *upper surface* is free, being partly seen in the lateral ventricle; it is partially covered by the velum interpositum and fornix, and corresponding to the free margin of the fornix, presents a groove, which runs inwards and forwards, and terminates in front in an eminence, the *anterior tubercle*. Its *under surface* is united with the tegmentum of the crus cerebri. Its *posterior extremity* projects above the level of the corpora quadrigemina and crus cerebri, and internally forms a well-marked prominence, the *posterior tubercle* or *pulvinar*, and below and outside this it presents two small rounded eminences, the *internal* and *external geniculate bodies*. Between the pulvinar and the posterior part of the peduncle of the pineal gland is a depressed area, triangular in shape, which is called the *trigonum habenulæ*. It contains a collection of nerve cells, to which fibres pass from the peduncle of the pineal glands, and from which fibres pass to the tegmentum. Its *anterior extremity*, which is narrow, forms the posterior boundary of the foramen of Monro.

The **Third Ventricle** is the narrow oblong fissure placed between the optic thalami, and extending to the base of the brain. It is bounded, above, by the under surface of the velum interpositum, from which are suspended the choroid plexuses of the third ventricle. Its floor, somewhat oblique in its direction, is formed, from before backwards, by the parts which are contained in the interpeduncular space, viz. the lamina cinerea, the tuber cinereum and infundibulum, the corpora albicantia and the locus perforatus posticus, and behind these by the tegmenta of the crura cerebri; its sides are formed by the optic thalami, along the upper and inner border of which are two white tracts, one on each side, the *peduncles of the pineal gland*. It is bounded, in front, by the anterior crura of the fornix, and part of the anterior commissure; behind, by the posterior commissure, and the iter a tertio ad quartum ventriculum. The cavity is much deeper in front than behind, and presents a deep recess at its anterior part, which lies over the optic commissure and is therefore termed the *optic recess*. At its posterior extremity the cavity forms another smaller recess, which extends into the stalk of the pineal gland, and is termed the *pineal recess*.

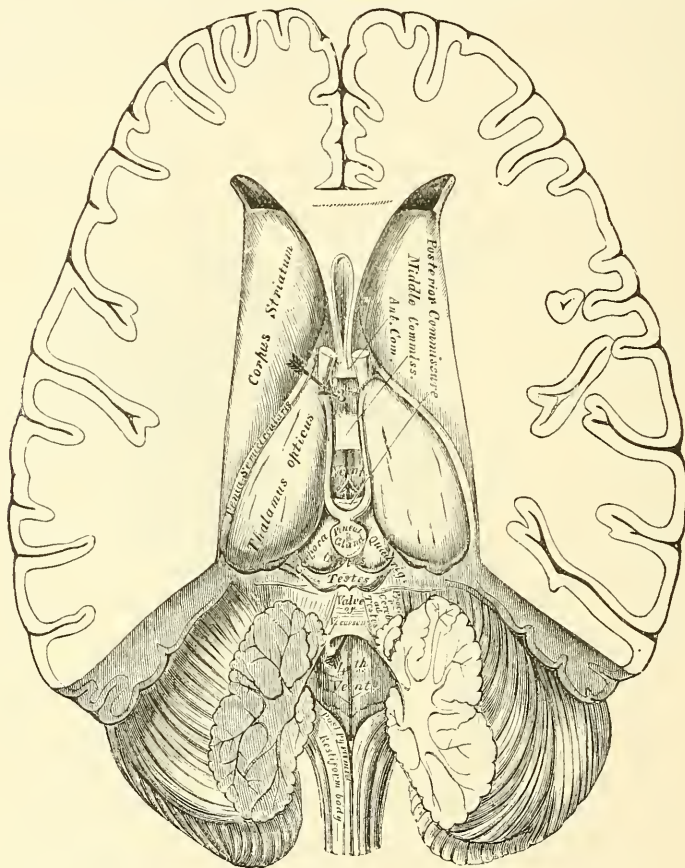


The cavity of the third ventricle is crossed by three commissures, named, from their position, *anterior*, *middle*, and *posterior*.

The *anterior commissure* is a round bundle of white fibres, placed in front of the anterior crura of the fornix, and appears to connect together the corpora striati. Its fibres can be traced through the corpus striatum on each side, and then backwards into the substance of the temporo-sphenoidal lobe.

The *middle* or *soft commissure* consists almost entirely of grey matter. It connects together the optic thalami, and is continuous with the grey matter lining the anterior part of the third ventricle. It is frequently broken in examining the brain, and might then be supposed to be wanting.

FIG. 473.—The third and fourth ventricles.



An arrow has been placed in the position of the foramen of Monro.

The *posterior commissure*, smaller than the anterior, is a flattened white band of fibres, and appears to connect together the optic thalami posteriorly. It consists of decussating fibres which come from the tegmentum of the crus cerebri on one side, and pass through the optic thalami, across the back part of the third ventricle, to the white substance of the temporo-sphenoidal lobe of the other side. Some of the fibres may also serve as commissural fibres between the optic thalami. It bounds the third ventricle posteriorly, above the opening of the Sylvian aqueduct. The pineal gland is placed above it and connected to its upper surface.

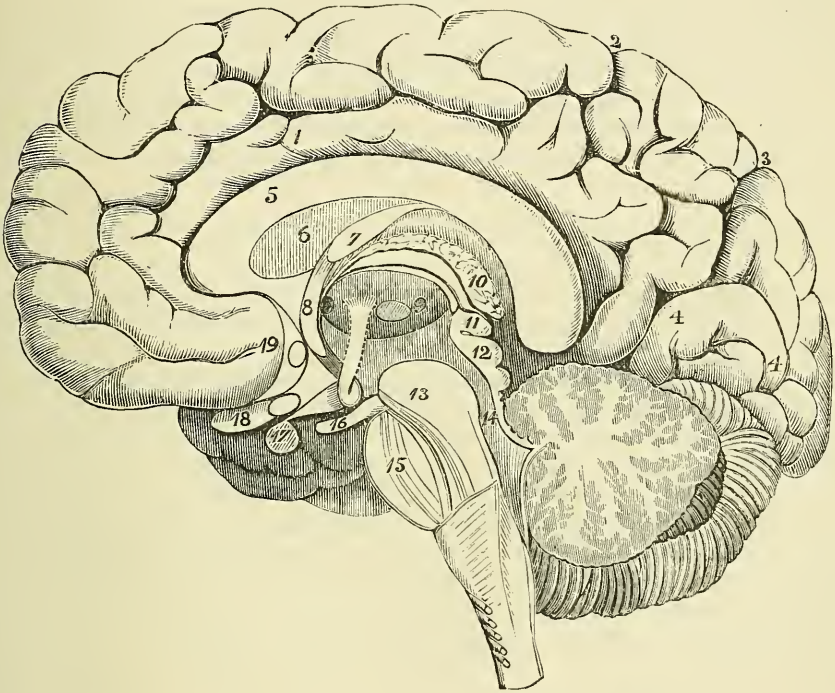
The third ventricle has four openings connected with it. In front are the two oval apertures of the foramina of Monro, one on each side, through which the third communicates with the lateral ventricles. Behind is a third opening

leading into the fourth ventricle by a canal, the *aqueduct of Sylvius*, or *iter a tertio ad quartum ventriculum*. The fourth, situated in the anterior part of the floor of the ventricle, is a conical recess, which leads to the infundibulum.

The lining membrane of the lateral ventricles is continued through the foramen of Monro into the third ventricle, and extends along the *iter a tertio* into the fourth ventricle.

The **foramen of Monro** is a foramen by which each lateral ventricle communicates with the third ventricle. It is formed by the anterior extremity of the body of the fornix, which, dividing into its two crura, arches downwards in front of the anterior extremity of the optic thalami; the crus is not, however, in contact with the thalamus, but an interval is left between the two, which is the foramen of Monro. Its boundaries are, therefore, in front, the anterior pillar of the fornix;

FIG. 474.—Vertical median section of the encephalon, showing the parts in the middle line.



1. Convolution of the corpus callosum. Above it is the callosal-marginal fissure, running out at 2 to join the fissure of Rolando.
3. The parieto-occipital fissure.
4. 4 point to the calcarine fissure, which is just above the numbers. Between 2 and 3 are the convolutions of the quadrate lobe. Between 3 and 4 is the cuneate lobe.
5. The corpus callosum.
6. The septum lucidum.
7. The fornix.
8. Anterior crus of the fornix, descending to the base of the brain, and turning on itself to form the corpus albicans. Its course to the optic thalamus is indicated by a dotted line.
9. The optic thalamus. Behind the anterior crus of

the fornix, a shaded part indicates the foramen of Monro; in front of the number an oval mark shows the position of the grey matter continuous with the middle commissure.

10. The velum interpositum.
11. The pineal gland.
12. The corpora quadrigemina.
13. The crus cerebri.
14. The valve of Vieussens (above the number).
15. The pons Varolii.
16. The third nerve.
17. The pituitary body.
18. The optic nerve.
19. 19 points to the anterior commissure, indicated by an oval mark behind the number.

behind, the anterior extremity of the optic thalamus; above, the body of the fornix; and below, the groove between the anterior pillar of the fornix and the optic thalamus.

Behind the third ventricle, and in front of the cerebellum, are the corpora quadrigemina; and, resting upon these, the pineal gland.

The **pineal gland** (*epiphysis cerebri*), so named from its peculiar shape (pinus, a fir-cone), is a small reddish-grey body, conical in form (hence its synonym,



*conarium*), placed immediately behind the posterior commissure, and between the nates, upon which it rests. It is retained in its position by a duplicature of pia mater, derived from the under surface of the velum interpositum, which almost completely invests it. The pineal gland is about four lines in length, and from two to three in width, at its base, and is said to be larger in the child than in the adult, and in the female than in the male. Its base is connected to the cerebrum by a stalk on either side. This stalk consists of two flattened bands of fibre, separated from each other by the pineal recess of the third ventricle (see page 759). The lower of these bands is prolonged into the posterior commissure; the upper one (the *peduncle of the pineal gland*) passes forwards upon the upper and inner margin of the optic thalamus to the anterior crus of the fornix, with which it becomes blended. The two stalks join together at their posterior extremity, in front of the pineal gland, forming a sort of festoon, and the base of the gland is connected to their posterior margin at the point of junction.

**Structure.**—The pineal gland consists of a number of follicles, lined by epithelium, and connected together by ingrowths of connective tissue. The follicles contain a transparent viscid fluid, and a quantity of sabulous matter, named *acervulus cerebri*, composed of phosphate and carbonate of lime, phosphate of magnesia and ammonia, with a little animal matter. These concretions are almost constant in their existence, and are found at all periods of life. They are frequently to be found upon the surface of the body, and occasionally upon its peduncles.

On the removal of the pineal gland and adjacent portion of pia mater, the corpora quadrigemina are exposed.

The **corpora or tubercula quadrigemina** (*optic lobes*) are four rounded eminences placed in pairs, two in front, and two behind, and separated from one another by a crucial depression. They are situated immediately behind the third ventricle and posterior commissure, and beneath the posterior border of the corpus callosum. Below, they are separated in the middle line from the crura cerebri by the aqueduct of Sylvius, but on each side are continuous with the tegmentum of the crura. The anterior or upper pair, the *nates*, are the larger, oblong from before backwards, and of a grey colour. The posterior or lower pair, the *testes*, are hemispherical in form, and lighter in colour than the preceding. From the outer side of each of these eminences, a prominent white band, termed *brachium*, is continued forwards and outwards. Those from the nates (*brachia anteriora*) are the larger, and pass obliquely outwards, between the inner and outer geniculate bodies, into the optic tract. Those from the testes (*brachia posteriora*) pass beneath an oval prominence, the internal geniculate body, and are no longer traceable. Both pairs, in the adult, are quite solid, being composed of white matter externally, and grey matter within. These bodies are larger in the lower animals than in man. In fishes, reptiles, and birds, they are only two in number, are called the *optic lobes*, from their connection with the optic nerves, and are hollow in their interior; but in mammalia they are four in number, as in man, and quite solid. In the human fœtus they are developed at a very early period, and form a large proportion of the cerebral mass; at first they are only two in number, as in the lower vertebrata, and hollow in their interior.

These bodies are connected with the cerebellum by means of a large white cord on each side, the *processus ad testes*, or superior peduncles of the cerebellum, which is continued onwards to the optic thalami, through the tegmentum of the crus cerebri. Beneath the corpora quadrigemina, the fibres decussate with those of the opposite side across the middle line.

The **Fillet**.—Arching over these peduncles is a flattish band of white fibres which was formerly known as the fillet, but is now known as the *inferior or lateral fillet*, inasmuch as there are other fibres, which are more deeply placed, which are known as the *superior or mesial fillet*. The inferior or lateral fillet issues from beneath the transverse fibres of the pons, and arises chiefly from the superior



olivary nucleus and from a collection of nerve cells at the anterior extremity of this nucleus. If these fibres are traced upwards through the pons, they will be seen to become superficial at its upper border, to pass obliquely round the superior peduncle of the cerebellum, and become lost in the posterior quadrigeminal body. The *superior* or *mesial fillet* forms a conspicuous band of fibres seen in transverse sections of the pons, and is derived from the opposite posterior columns of the medulla. Some of its fibres pass to the anterior quadrigeminal body, and others to the cerebrum through the crusta.

The **corpora geniculata** are two small, flattened, oblong masses, placed on the under and back part of each optic thalamus, and named, from their position, *corpus geniculatum externum* and *internum*. The two bodies are separated from one another by one of the roots of the optic tract, the brachia anterior, from the nates.

#### STRUCTURE OF THE CEREBRUM

The **cerebrum**, like the other parts of the great nerve-centre, is composed of grey and white matter. In order to give some general idea of its construction, at all events in part, it may be compared, for the sake of illustration, to a tree, the trunk of which divides into two main branches, and these break up into smaller branches, which finally end in twigs to which are attached the leaves, forming an investment to the branches and covering the whole tree. The trunk is represented by the medulla oblongata as it passes through the foramen magnum; the two main branches by the crura cerebri, which break up into smaller branches, which diverge from each other, dividing and subdividing, until they reach the surface of the hemispheres, where they terminate in single nerve-fibres, to which are attached the basal axial cylinder processes of the nerve cells, represented by the leaves. These cells are arranged on the surface, resembling a cap covering the hemispheres, and constitute the cerebral cortex. But here the analogy ends, for in the cerebrum we have, in addition to this cortex, other masses of grey matter situated in the middle of the brain, and other white fibres beside these diverging ones which have been mentioned, and which serve either to connect the two hemispheres, of which the cerebrum consists, or else serve to connect different structures in the same hemisphere.

The **white matter of the cerebrum** consists of medullated fibres, varying in size and arranged in bundles, separated by neuroglia. They may be divided into three distinct systems, according to the course which they take. 1. Diverging or peduncular fibres, which connect the hemispheres with the medulla oblongata and cord. 2. Transverse commissural fibres, which connect together the two hemispheres. 3. Commissural fibres, which connect different structures in the same hemisphere.

1. The **diverging** or **peduncular fibres** consist of a main body, which originates in the cord and medulla oblongata, forms the longitudinal fibres of the pons, and divides into two main branches, which, diverging from each other, constitute the *crura cerebri* or *cerebral peduncles*. In the crura cerebri, as has been before described, the diverging fibres derived from the longitudinal fibres of the pons Varolii are arranged in two strata, which are separated by the locus niger; the anterior or superficial stratum forming the *crusta* of these bodies, and the posterior or deeper stratum, the *tegmentum*. The fibres derived from these two sources take a different course, and will have to be separately considered.

The fibres of the *crusta* are derived from the pyramid of the medulla, which fibres are continued upwards through the pons to form the crusta; they are reinforced in their passage through the crus by accessory fibres derived from the central grey matter around the Sylvian aqueduct and from the locus niger. When they emerge from the crus, (1) some of the fibres pass directly upwards as radiating fibres to the grey matter of the cerebral hemisphere, forming the corona radiata; (2) some of the fibres pass to the internal capsule, between the nucleus caudatus and lenticularis, where they give off fibres to these ganglia and receive

others from them, and then, issuing from the capsule, diverge to form a part of the corona radiata, passing to the cerebral cortex. The fibres which arise from the ganglia are more numerous than those which terminate in the ganglia, so that more fibres pass out of the ganglia than pass into them.

The fibres of the *tegmentum* are continuous with those longitudinal fibres of the pons which are derived from the *formatio reticularis* of the medulla, which is formed by fibres (1) from the anterior column of the cord; (2) from the olivary body; (3) from the lateral column of the cord; and (4) from the *funiculus cuneatus* and *funiculus gracilis*. They are reinforced by fibres from the *corpora quadrigemina* and *corpora geniculata*, and from the superior peduncle of the cerebellum, and enter the optic thalamus. Some of these fibres pass through the optic thalamus, and, being augmented by other fibres arising within this body, pass out of it and spread out to form part of the corona radiata, especially joining the ganglion-cells of the cortex of the temporo-sphenoidal and occipital lobes; other fibres terminate in the optic thalamus.

2. The **transverse commissural fibres** connect the two hemispheres. They include: (a) the transverse fibres of the corpus callosum; (b) the anterior commissure; (c) the posterior commissure.

The *corpus callosum*, which has already been described, connects the two hemispheres of the brain, forming their great transverse commissure, penetrating into the substance of the convolutions and intersecting the fibres of the corona radiata.

The *anterior commissure* is a round bundle of white fibres, which is placed in front of the anterior crura of the fornix, and appears to connect the *corpora striata*. It passes outwards through the corpus striatum on each side, and then curves backwards into the substance of the temporo-sphenoidal lobe.

The *posterior commissure*, smaller than the anterior, is a flattened white band of fibres, which appears to connect the optic thalami posteriorly. It consists of decussating fibres which come from the *tegmentum* of the *crus cerebri* on one side, and pass through the optic thalamus, across the back part of the third ventricle, to the white substance of the temporo-sphenoidal lobe of the other. Some of the fibres may also serve as commissural fibres between the optic thalami.

3. **Commissural fibres connecting different structures in the same hemisphere.** These fibres are of two kinds: (1) those which connect adjacent convolutions, and which are termed *arcuate* or *association fibres*; (2) those which connect more distant parts in the same hemisphere—the *longitudinal* or *collateral fibres*.

The *arcuate* or *association fibres* are situated immediately beneath the grey substance of the cortex of the hemispheres, and connect together adjacent convolutions.

The *longitudinal* or *collateral fibres* include the following: (a) the uncinat fasciculus; (b) the fillet of the gyrus fornicatus; (c) the longitudinal fibres of the corpus callosum; (d) the *tænia semicircularis*; (e) the fornix; (f) the inferior longitudinal fasciculus.

(a) The *uncinate fasciculus* connects the convolutions of the frontal and temporo-sphenoidal lobes. It passes across the bottom of the Sylvian fissure and traverses the claustrum.

(b) The *fillet of the gyrus fornicatus* (*Cingulum*) is a band of white matter, which encircles the hemisphere in an antero-posterior direction, lying in the substance of the convolution of the corpus callosum. Commencing in front at the anterior perforated space, it passes forwards and upwards parallel with the rostrum, winds round the genu, runs in the convolution from before backwards, immediately above the corpus callosum, turns round its posterior extremity, and passes into the hippocampus major, through which it courses to its anterior extremity. In its course it is connected with the secondary convolutions of the gyrus fornicatus by short arcuate fibres.

(c) The *longitudinal fibres of the corpus callosum* or *nerves of Lancisi* connect



the anterior and posterior extremities of the gyrus fornicatus or convolution of the corpus callosum.

(d) The *tænia semicircularis* is a narrow whitish semitransparent band of medullary substance, situated in the depression between the nucleus caudatus and the optic thalamus. Anteriorly, its connections are somewhat obscure, but probably most of its fibres, if not all, are continued into the anterior pillar of the fornix; behind, it is continued into the roof of the middle or descending horn of the lateral ventricle, at the extremity of which it enters a mass of grey matter, the nucleus amygdalæ.

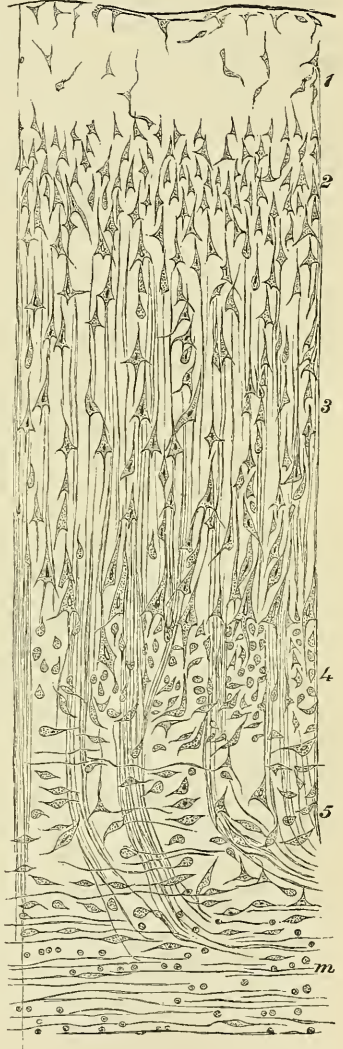
(e) The *fornix* connects the optic thalamus with the hippocampus major and uncinate convolution. It has already been described as arising from the grey matter of the optic thalamus; it then emerges from the under surface of this body, forms the corpus albicans, where the fibres are arranged in loops, between which nerve-cells are to be found; it then passes upwards into the third ventricle and joins with the fibres of the other side forming the body of the fornix; from this the posterior pillars diverge, and, entering the middle cornu of the lateral ventricle, part of its fibres are distributed to the hippocampus major, and the remainder end as the *tænia hippocampi* or *fimbria*, which is continued as a distinct piece to the *crochet* or *uncus* of the uncinate convolution.

(f) The *inferior longitudinal fasciculus* is a collection of fibres which connects the temporo-sphenoidal and occipital lobes, running along the outer wall of the middle and posterior cornu.

The **grey matter of the cerebrum** is disposed in three great groups: 1. The grey matter of the cerebral cortex. 2. The grey matter of the basal ganglia, that is, the great ganglia of the base of the cerebrum. 3. The grey matter which lines the internal surface of the upper part of the cerebro-spinal tube, that is, the remains of the cavity in the original vesicles from which the brain was formed, and which constitutes the central cavities of the organ.

1. The **grey matter of the cortex** (fig. 475) invests the surface of the hemispheres and gives them external form. When vertical sections are made through it, and examined microscopically, it is found to consist of five separate layers, but to this there are some exceptions. According to Meynert these exceptions are to be found: (1) in the posterior portion of the occipital lobe; (2) in the grey cortex of the hippocampus major; (3) in the wall of the fissure of Sylvius; and (4) in the olfactory bulb. The five layers in the common type are as follows: (1) The first layer is principally composed of a matrix or neuroglia, through which a few small ganglion-cells are irregularly distributed, and a nerve-fibre network. (2) The second layer consists of numerous small pyramidal cells, which have their long axes vertical to the surface of the convolutions, and are closely aggregated together so as to completely fill the layer with a number of closely compressed cells. (3) The third layer is named by

FIG. 475.—Grey matter of the cerebral cortex. (Meynert.)





Meynert the *formation of the cornu Ammonis*, as it is made up of cells, which are the only morphological element found in this part. It consists of the same sort of pyramidal cells, arranged vertically to the surface, as was found in the preceding layer, but they are of very much larger size, and increase progressively towards the deeper parts of the layer, and they are much more widely separated from each other. This layer is the principal and broadest one of the series, and is at least twice as deep as the preceding layer. (4) The fourth layer is termed the *granular formation* by Meynert, and consists of numerous small, irregular, rarely triangular or elongated, cells, which resemble the nerve-corpuscles found in the internal granule layer of the retina, and which are closely aggregated together. (5) The fifth layer is termed the *claustral formation*, and consists of a very large proportion of spindle-shaped cells, which are the peculiar elements of this layer. They are especially numerous in the inner half, and are arranged horizontally, extending parallel to the surface. They have received their name from the fact that the claustrum is made up almost entirely of an accumulation of these cells. It will be seen, therefore, that the differences in these layers depend upon the varying form and size of the cells and the closeness of their arrangement, and that the typical form of cell, and the only one which is admitted by some observers, is the pyramidal cell or nerve-corpuscle.

*Character of the pyramidal cell or nerve-corpuscle.*—These nerve-corpuscles are destitute of a cell wall; they present a nucleus, sometimes round or oval, sometimes angular, and give off many processes. One of these, which, in the cells arranged vertically to the surface, projects outwards and is named the *process of the apex*, is strong and branched, and according to Cleland is continuous with the nerve-fibre network in the first or superficial layer of the cortex. Another process projects inwards towards the white matter of the hemisphere and from the opposite extremity of the cell. It is termed the *process of the centre of the base*. It is more slender than the preceding and remains unbranched. It is an axis-cylinder process, and, becoming invested with a medullary sheath, constitutes a nerve-fibre, extending into the central white matter. In addition to these, lateral processes are given off, forming the *processes of the basal angle*, which can be traced for a longer or shorter distance, and break up into a network of extremely minute nerve-fibres.

*Special types of the grey matter of the cortex.*—The special types of grey matter of the cortex are the following: (1) On the posterior portion of the occipital lobe the grey matter consists of eight layers. This is produced by the intercalation of intermediate granule layers, similar to those forming the fourth layer of the typical cortex. (2) In the grey matter of the cortex of the hippocampus major or cornu Ammonis, pyramidal cells are alone found, such as have been described in the third layer of the typical cortex. This constitutes the greater part of the structure in this situation, the fourth and fifth layers being absent, and the second layer containing no cells. (3) In the wall of the Sylvian fissure the grey matter is termed the *claustrum*; it separates the white matter of the convolutions of the island of Reil from the external capsule of the corpus striatum. This presents peculiarities of structure, consisting mainly of spindle-shaped cells, such as constitute the fifth layer. (4) In the olfactory bulb, which may be regarded as a portion of the cerebral hemispheres, forming 'a cap superimposed upon a conical process of the cerebrum,' is another variety of structure, differing from the type of the cortex of the hemispheres. The bulb consists of both grey and white matter, and sometimes retains a central cavity lined by epithelium. The lower part is grey matter, and consists of the following layers from below upwards. (1) The *olfactory nerve-layer*, consisting of a layer of non-medullated nerve-fibres derived from the nerves which supply the olfactory region. (2) The *stratum glomerulosum*, consisting of nodulated masses, containing small nuclear cells, and a convoluted olfactory nerve-fibre amongst the cells. (3) The *stratum gelatinosum*, consisting of pyramidal or spindle-shaped nerve-cells and a fine network of nerve-fibre. (4) The *granular layer*, consisting

of small irregular nerve-cells resembling the fourth layer of the cerebrum or the granular layer of the retina.

2. The **grey matter of the basal ganglia**.—The great ganglia of the base of the brain are, the corpus striatum, the optic thalamus, the corpora quadrigemina, the corpora geniculata, and the locus niger. Only a part, however, of the grey matter of the corpora quadrigemina—that found on the periphery of this body—belongs to this group; the remainder, that contained in its centre around the Sylvian aqueduct, belongs properly to the third group, which will be discussed immediately.

The *corpus striatum* presents two distinct and separate masses, the *nucleus caudatus*, which is the intraventricular portion of the corpus striatum, and the *nucleus lenticularis*, which is the extraventricular portion. The two are separated from each other by a distinct lamina of white matter, the *internal capsule*, which also separates the nucleus lenticularis from the outer part of the optic thalamus. The grey matter of the corpus striatum is permeated by tracts of medullated nerve-fibres, some of which probably originate in it, though the actual connection of the nerve-fibres with the cells has not been demonstrated. The nerve-cells are multipolar, both large and small, the larger being principally found in the lenticular nucleus.

The *optic thalamus* is chiefly formed of grey matter, covered over by a superficial layer of white, which on the outer side separates it from the internal capsule. The grey matter is arranged in two masses, the outer and inner nuclei, partially divided by a vertical white septum. It is traversed by numerous nerve-fibres, which for the most part have no definite direction; some, however, converge and form a bundle which passes downwards to form the anterior root of the fornix. It contains comparatively large nerve-cells, both multipolar and fusiform. The inner nucleus is connected across the middle line with the inner nucleus of the opposite side by the middle commissure of the third ventricle, which, however, belongs to the third group of grey matter.

The *corpora quadrigemina* consist of two distinct and separate collections of grey matter, one at or near the surface, which belongs to the basal ganglia, and one in the centre around the aqueduct of Sylvius. The former will only be considered at present. The *peripheral grey matter of the corpora quadrigemina* differs somewhat in the posterior and anterior lobes. The posterior lobes or testes are composed almost entirely of grey matter, covered over by a thin stratum of white matter, and separated from the *central grey matter* by tracts of transverse white fibres derived from, and forming part of, the fillet. The anterior lobes or nates are covered superficially by a thin stratum of white matter; beneath this is a layer of grey matter, termed the *stratum cinereum*, and consisting, as well as the grey matter of the posterior lobes, of small multipolar cells embedded in a fine network of nerves. Beneath this again is a characteristic mass of grey matter, termed the *stratum opticum*, which is made up of fine nerve-fibres, coursing in a longitudinal direction, and containing between them small masses of grey substance, consisting of small multipolar nerve-cells embedded in grey matter. Lastly, between this body and the central grey matter around the Sylvian aqueduct is a thin lamina of white matter, derived from the fillet.

The *geniculate bodies* are continuous with the grey substance of the optic thalamus, and the external one (*corpus geniculatum externum*) is peculiar on account of its dark colour, due to its cells containing pigment. It presents a laminated arrangement, and consists of alternate thick layers of grey matter and thin layers of white matter. Its cells are multipolar. The internal body (*corpus geniculatum internum*) is of lighter colour, does not present a laminated arrangement, and its cells are smaller in size and fusiform in shape.

The *locus niger*, or grey matter of the crus cerebri, like the external geniculate body, is peculiar from the large amount of dark pigment-granules which are contained in its ganglion-cells, and which give to it its dark colour, from which it has derived its name. Its cells are small and multipolar.



3. The **central grey matter of the cerebrum** lines the upper part of the cerebro-spinal tube, which is the remains of the cavity in the original vesicles from which the brain was formed, and is continuous with the grey matter of the floor of the fourth ventricle, and through it with the grey matter of the cord. This central grey matter is found lining the aqueduct of Sylvius, by which the third communicates with the fourth ventricle; it covers the inner wall of each optic thalamus, forming the middle or grey commissure of the third ventricle; it also lines the floor of the third ventricle; it covers behind the upper surface of the tegmentum of the crus, and in front it approaches the surface of the brain, forming the posterior perforated space and the lamina cinerea. It forms also the tuber cinereum and the infundibulum, and in the lower vertebrata, especially fishes, the posterior lobe of the pituitary body. In the higher vertebrates this lobe does not present any nervous structure, being encroached upon and obliterated by an ingrowth of connective tissue and vessels.

The grey matter surrounding the Sylvian aqueduct, which has been before mentioned as the central grey matter of the corpora quadrigemina, presents some features requiring especial mention. It forms a tolerably thick layer surrounding the canal, but is thicker on the lower wall; that is, below the canal, than above. The cells, which are multipolar, are here collected into groups, and form nuclei for the origin of the third and fourth cranial nerves. The nucleus for the third and fourth consists of a column of cells of large size on either side of, and close to, the median line. In addition to these cells there are found at the periphery of the zone of grey matter surrounding the aqueduct, some other, and larger, cells: sometimes single, sometimes grouped in twos or threes, or even more. They are globular, and lie in the midst of well-marked nerve-fibres, with which their processes appear to be continuous.

#### THE CEREBELLUM

The **Cerebellum**, or little brain, is that portion of the encephalon which is contained in the inferior occipital fossæ. It is situated beneath the occipital lobes of the cerebrum, from which it is separated by the tentorium. In form, the cerebellum is oblong, and flattened from above downwards, its great diameter being from side to side. It measures from three and a half to four inches transversely, and from two to two and a half inches from before backwards, being about two inches thick in the centre, and about six lines at the circumference, which is the thinnest part. It consists of grey and white matter: the former, darker than that of the cerebrum, occupies the surface; the latter, the interior. The surface of the cerebellum is not convoluted like the cerebrum, but traversed by numerous curved furrows or sulci, which vary in depth at different parts, and separate the laminae of which its exterior is composed.

**Weight of the Cerebellum.**—Its average weight in the male is 5 oz. 4 drs. It attains its maximum weight between the twenty-fifth and fortieth year; its increase in weight after the fourteenth year being relatively greater in the female than in the male. The proportion between the cerebellum and cerebrum is, in the male, as 1 to  $8\frac{1}{2}$ ; and in the female, as 1 to  $8\frac{1}{4}$ . In the infant, the cerebellum is proportionately much smaller than in the adult, the relation between it and the cerebrum being, according to Chaussier, between 1 to 13, and 1 to 26; by Cruveilhier the proportion was found to be 1 to 20.

**Lobes of the Cerebellum.**—The cerebellum consists of two lateral portions, or hemispheres, joined together by a median narrower part, the vermiform process. This central portion on the upper surface of the cerebellum forms a slight elevation, which is termed the *superior vermiform process*; whilst on the under surface it forms a well-marked projection, the *inferior vermiform process*, at the bottom of a deep recess between the two hemispheres. This recess or fossa is known as the *valley* or *vallecula*, and in it is lodged the medulla; it terminates in front at the fourth ventricle and behind in a deep notch, the *incisura cerebelli posterior*



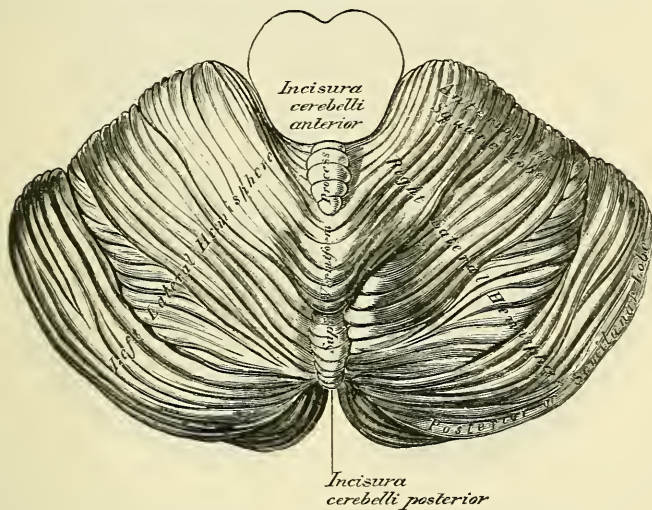
(*incisura marsupialis*), which separates the posterior part of the two hemispheres from each other, and is occupied by the falx cerebelli. The two hemispheres are also separated in front and above by a broader, shallower notch, the *incisura cerebelli anterior* (*incisura semi-lunaris*), which encircles the posterior part of the corpora quadrigemina.

The cerebellum is connected to the rest of the encephalon by three pairs of peduncles, which will be described in the sequel: a *superior* pair, which connect it with the cerebrum; a *middle* pair, which connect it with the pons; and an *inferior* pair, which connect it with the medulla.

The cerebellum is divided into an upper and a lower portion by a great horizontal fissure, which commences in front at the pons and passes horizontally round the free margin of the hemisphere to the middle line behind. From this primary fissure numerous secondary fissures proceed, which separate the cerebellum into lobes, and in these lobes are curved furrows or sulci, which separate individual folia or laminae from each other.

The *superior surface of the cerebellum* (fig. 476) is somewhat elevated in the middle line and sloped towards its circumference; it consists of the two lateral hemispheres connected together by an elevated median portion or lobe, the

FIG. 476.—Upper surface of the cerebellum.



*superior vermiform process*. The principal fissure on the lateral parts of this surface starts from the great horizontal fissure near its commencement, passes backwards and inwards in a curved direction, with its convexity backwards and upwards, to the back part of the superior vermiform process. It divides the upper surface of the hemisphere into two lobes, an *anterior* or *square* lobe and a *posterior* or *semi-lunar* lobe. The anterior or square lobe is subdivided by another fissure into an *anterior* and *posterior crescentic portions*. A small part of the anterior crescentic portion is by some differentiated off from the rest by another fissure, which is situated near the anterior border of this surface. This small part is known as the *ala lobuli centralis*, because it is continuous internally with the central lobe of the superior vermiform process.

The *superior vermiform process* is the elevated median portion which connects the two lateral hemispheres. It begins at the valve of Vieussens, between the two superior peduncles of the cerebellum, and terminates at the bottom of the posterior notch. The process is divided by fissures, which are continuous with the fissures on the lateral hemispheres, into the following parts, enumerated in their order from before backwards: the lobulus centralis, the monticulus cerebelli and the folium cacuminis.

The *lobulus centralis* is a small, square lobe situated below and behind the testes, from which it is separated by a fold of pia mater. It rests on a tongue-shaped process of the cerebellum, the *lingula*, which separates the central lobe from the valve of Vieussens. Laterally the lobulus centralis expands and forms the anterior part of the square lobe under the name of the *ala lobuli centralis*.

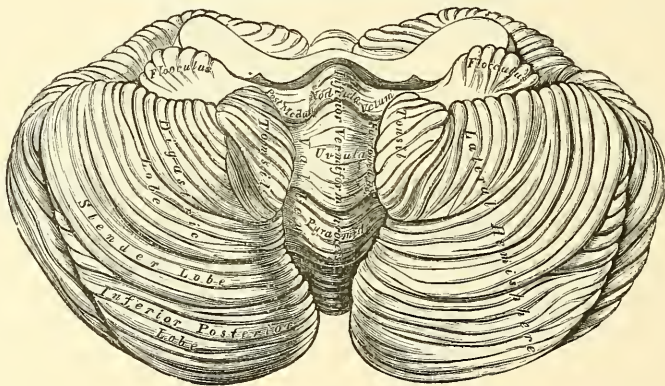
The *monticulus cerebelli* consists of two parts, the *lobus culminis* (*culmen*) and the *lobus clivi* (*clivus*), which are continuous on each side with the anterior and posterior crescentic parts of the square lobe of the lateral hemispheres; the fissure which separates the culmen from the clivus being the continuation of the fissure which separates the anterior crescentic portion from the posterior.

The *folium cacuminis* is a short and narrow concealed band, which connects the posterior superior or semi-lunar lobes of the lateral hemispheres.

The under surface of the cerebellum, (fig. 477) is subdivided into two lateral hemispheres by a depression, the *vallecula* or *valley*, which extends from before backwards in the middle line. These lateral hemispheres are lodged in the inferior occipital fossæ; the median depression, or valley, receives the back part of the medulla oblongata, is broader in the centre than at either extremity, and has, projecting from its floor, part of the median lobe of the cerebellum, called the *inferior vermiform process*.

Upon the under surface of each hemisphere there are five lobes, separated by sulci; these are, from before backwards: (1) the *flocculus* or *subpeduncular lobe*,

FIG. 477.—Under surface of the cerebellum.



a prominent tuft, situated behind and below the middle peduncle of the cerebellum; its surface is composed of grey matter, subdivided into a few small laminae; it is sometimes called the *pneumogastric lobule*, from being situated behind the pneumogastric nerve: (2) the *amygdala* or *tonsil*, situated on either side of the great median fissure or valley, and projecting into the fourth ventricle: (3) the *digastric* or *biventral lobe*, situated on the outside of the tonsil, and connected in part with the pyramid: (4) the *slender lobe*, behind the digastric, and connected with the back part of the pyramid and the commissura brevis: and more posteriorly (5) the *inferior posterior lobe*, which also joins the commissura brevis in the valley.

**The inferior vermiform process.**—The parts entering into the composition of the inferior vermiform process, from behind forwards, are: the *tuber valvulae* or *commissura brevis*, a transverse lamina uniting the inferior posterior and slender lobes of the two sides; in front of this, a laminated conical projection, the *pyramid*, which is connected to the digastric lobe by a narrow ridge; more anteriorly, a larger eminence, the *uvula*, which is placed between two rounded lobes, the *amygdalæ* or *tonsils*, which occupy the sides of the valley, and which is connected with them by a commissure of grey matter, indented on the surface, called the *furrowed band*. In front of the uvula is the *nodule*; it is the anterior pointed termination of the inferior vermiform process, and projects into the cavity of the

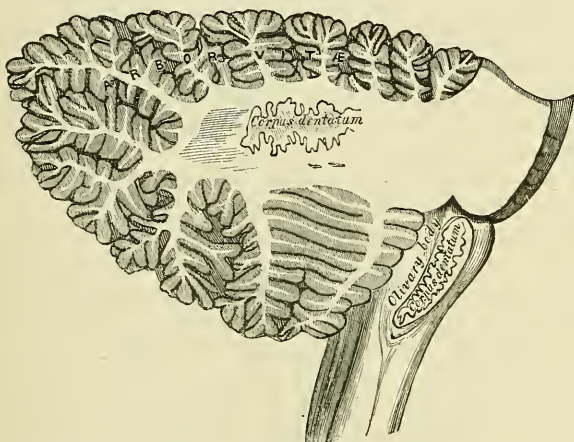


fourth ventricle; it has been named by Malacarne the *laminated tubercle*. On each side of the nodule is a thin layer of white substance, attached externally to the flocculus, and internally to the nodule; these form together the *inferior medullary velum*, or commissure of the flocculus. It is usually covered in and concealed by the amygdalæ, and cannot be seen until they are drawn aside. This band is of a semi-lunar form on each side, its anterior margin being free and concave, its posterior attached just in front of the furrowed band. Between it and the nodule and uvula behind is a deep fossa, called the *swallow's nest* (*nidus hirundinis*).

**Internal structure of the cerebellum.**—The cerebellum consists both of white and grey matter.

If a vertical section (fig. 478) is made through either hemisphere of the cerebellum, midway between its centre and the superior vermiform process, the interior will be found to consist of a central stem of white matter, which contains in its interior a grey mass, the *corpus dentatum*. From the surface of this central stem a series of plates of medullary matter are detached, which, covered with grey matter, form the laminae. In consequence of the main branches from the

FIG. 478.—Vertical section of the cerebellum.



central stem dividing and subdividing, the section presents a characteristic appearance which is named the *arbor vite*. If a vertical section is made in the median plane of the cerebellum it will be found that the central stem divides into two main branches, named respectively, from their direction, the vertical and the horizontal branch. The *vertical* branch passes upwards to the superior vermiform process, most of its secondary branches breaking up in the column, but some passing forwards and upwards to the central lobe and the lingula. The *horizontal* branch passes backwards to the folium cacuminis considerably diminished in size, in consequence of having given off two large secondary branches; one, from its upper surface, which ascends to the clivus; the other, which descends, and breaking up into branches, enters the lobes in the inferior vermiform process, the tuber valvulæ, the pyramid, the uvula and the nodule.

From the anterior part of each hemisphere arise three large processes or peduncles—superior, middle, and inferior—by which the cerebellum is connected with the rest of the encephalon.

The **white matter** includes two varieties of nerve matter: (1) the *peduncular fibres*, which are directly continuous with the fibres of the peduncles of the cerebellum; (2) the fibres (*fibræ propriae*) proper to the cerebellum itself.

The *peduncles of the cerebellum*—superior, middle, and inferior—serve to connect it with the rest of the encephalon.

The *superior peduncles* (*processus e cerebello ad testes*) arise from the middle



of the white matter of the cerebral hemispheres; they run beneath the testes of the corpora quadrigemina and, emerging at its posterior border, pass outwards and backwards to the cerebellum. Each peduncle forms the upper part of the lateral boundary of the fourth ventricle, and is connected with its fellow of the opposite side by the *valve of Vieussens*. Beneath the corpora quadrigemina the innermost fibres of each peduncle decussate with each other, so that some fibres from the one half of the cerebrum are continued into the other half of the cerebellum. Upon entering the cerebellum the fibres of this peduncle pass to a great extent into the interior of the corpus dentatum, though some wind round it and reach the grey cortical matter, especially on its inferior surface.

The *valve of Vieussens*, or *superior medullary velum*, is a thin, translucent lamina of white matter, marked superficially by a few transverse streaks of grey substance, stretched between the two processus cerebello ad testes; it forms part of the roof of the fourth ventricle. It is narrow in front, where it is connected with the testes; and broader behind, at its connection with the superior vermiform process of the cerebellum. A slight elevated ridge, the *frænulum*, descends upon the upper part of the valve from the corpora quadrigemina, and on either side of it may be seen the fourth nerve, which is connected with its fellow of the opposite side by a transverse band of fibres forming a partial decussation. Its lower half is streaked by three or four grey bands, with intervening furrows. These bands are prolonged from the anterior border of the cerebellum; they are called the *lingula*.

The *middle peduncles* (*processus ad pontem*) the largest of the three, connect together the two hemispheres of the cerebellum, forming their great transverse commissure. They consist of a large mass of curved fibres, which arise in the grey matter of the foliated cortex of the hemispheres of the cerebellum, and pass across the pons Varolii, forming its transverse fibres.

The *inferior peduncles* (*processus ad medullam*) connect the cerebellum with the medulla oblongata. As the restiform bodies, they pass upwards and outwards, forming part of the lateral wall of the fourth ventricle; entering the cerebellum, they end in the grey cortex of the upper surface of this organ.

The *fibræ propriæ of the cerebellum* are of two kinds: (1) *commissural fibres*, which cross the middle line to connect the opposite halves of the hemispheres, some at the anterior part, and others at the posterior part of the vermiform process; (2) *arcuate or association fibres*, which connect one lamina with another, arching across the fissures between the laminæ.

The **grey matter of the cerebellum** is found in two situations: (1) on the surface, forming the cortex; (2) as independent masses in the interior.

1. The *grey matter of the cortex* presents a characteristic foliated appearance, due to the series of laminæ which are given off from the central white matter; these laminæ give off secondary laminæ which are covered with grey matter. This arrangement gives to the cut surface of the organ a foliated appearance, to which the name *arbor vitæ* has been applied (fig. 478). Externally the cortex is covered by pia mater, and internally is the medullary centre, consisting mainly of nerve-fibres.

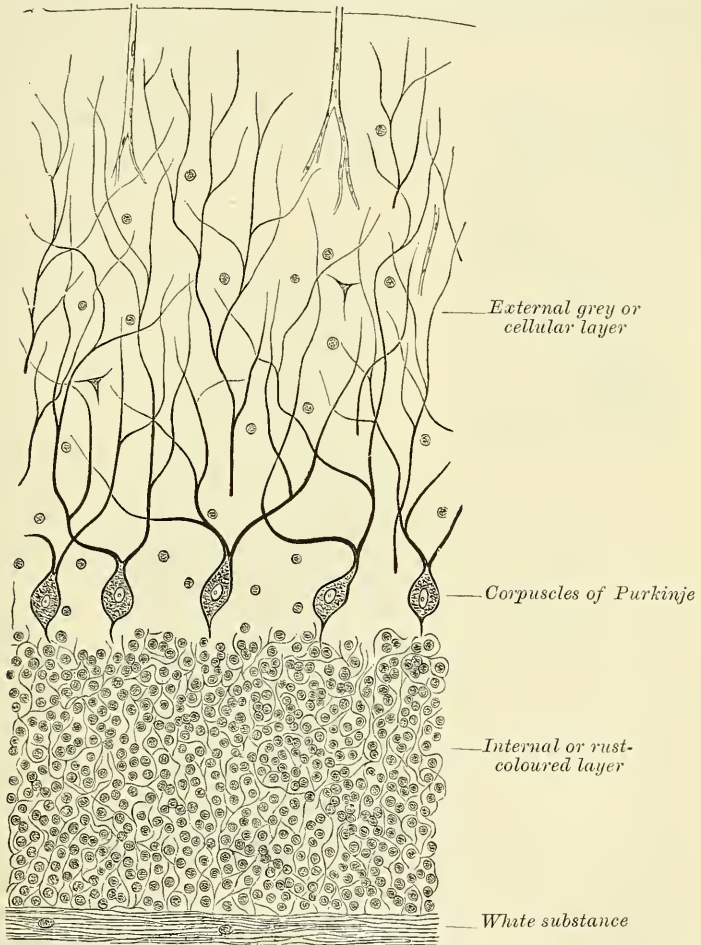
*Microscopical appearance of the cortex.*—The cortex presents a remarkable structure, consisting of two distinct layers, viz. an external grey or cellular layer and an internal rust-coloured granular layer. Between the two layers, or rather situated in the deepest part of the grey or cellular layer, is an incomplete stratum of the characteristic cells of the cerebellum, the *corpuscles of Purkinje*.

The *external grey or cellular layer* (fig. 479) consists of a transparent tissue-like neuroglia, containing fibres and cells. The fibres are delicate fibrillæ running at right angles to the surface, and many of them connected with the processes of the large nerve-cells immediately below; others are delicate supporting connective tissue-like fibres, which spread out into a broad base against the inner surface of the pia mater.

The cells are granular bodies, some very small, and probably belonging to the neuroglia; others, according to Lockhart Clarke, connected with the processes of the corpuscles of Purkinje which lie immediately beneath.

The *corpuscles of Purkinje* (fig. 479) are flask-shaped cells, in the deepest part of the external grey or cellular layer, resting against the internal rust-coloured layer. From their under service a slight slender process arises, which passes through the internal layer, and becomes continuous with the axial cylinder of a medullated nerve-fibre in the medullary substance beneath. From the other

FIG. 479.—Vertical section through the grey matter of the human cerebellum. Magnified about 100 diameters. (Klein and Noble Smith.)



extremity two peripheral processes are given off, which branch in an antler-like manner in the external layer, some of the finer processes becoming connected with the cells in this layer.

The *internal or rust-coloured layer* (fig. 479) is characterised by containing multitudes of granular-looking bodies embedded in a gelatinous matrix. They are minute stellate cells, consisting of a well-defined nucleus with a thin protoplasmic envelope. Between the cells is a fine nerve-network, with which the processes of the cells are supposed to be continuous.

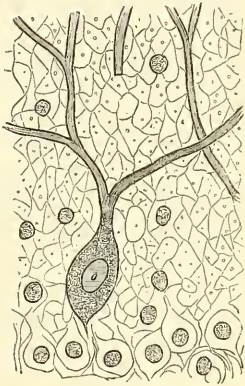
2. The *independent centres of grey matter in the cerebellum* are four in number: one, situated in each hemisphere, is of large size, and is known as the corpus dentatum; the other three, much smaller, are situated near the middle of

the cerebellum, and are known as the nucleus emboliformis, nucleus globosus, and nucleus fastigii.

The *corpus dentatum* or *ganglion of the cerebellum* is situated a little to the inner side of the centre of the stem of white matter. It consists of an open bag or capsule of grey matter, the section of which presents a grey dentated outline, open at its anterior part. It is surrounded by white fibres; white fibres are also contained in its interior which issue from it to join the superior peduncles.

The *nucleus emboliformis* is a mass of grey matter placed on the inner side of the corpus dentatum, and partly covering the opening at its anterior part. The *nucleus globosus* is an elongated clump of grey matter placed to the inner side of the preceding. The *nucleus fastigii* is somewhat larger than the other two, and is situated close to the middle line at the anterior end of the superior vermiform process, and immediately over the roof of the fourth ventricle, from which it is separated by a thin layer of white matter. It was formerly known as the roof nucleus of Stilling.

FIG. 480.—A corpuscle of Purkinje, with its dichotomously branched processes.



#### FOURTH VENTRICLE (figs. 455, 473)

The **Fourth Ventricle**, or *ventricle of the cerebellum*, is the space between the posterior surface of the medulla oblongata and pons in front and the cerebellum behind. It is lozenge- or diamond-shaped; that is to say, it is composed of two triangles, with their bases opposed to each other. The lower triangle is formed by the divergence of the funiculi graciles and cuneati of the medulla oblongata on either side. These columns, as they pass upwards in the medulla, about the middle of its length, bend outwards, and, diverging from each other, form a triangular space, which is the lower half of the fourth ventricle. In like manner the upper triangle is formed by the divergence of the superior peduncles (*processus e cerebello ad testes*) of the cerebellum. These crura as they emerge from the corpora quadrigemina are in contact by their lateral margins, but they gradually diverge, passing downwards, backwards, and outwards, to reach the cerebellum, thus enclosing a triangular space, which forms the upper half of the fourth ventricle. This cavity is therefore bounded laterally by the *processus e cerebello ad testes* in its upper half, and by the funiculi graciles, the funiculi cuneati, and the restiform bodies in its lower half. It presents four angles. The upper angle reaches as high as the upper border of the pons; it presents the lower opening of the aqueduct of Sylvius, by which this ventricle communicates with the third ventricle. The lower angle is on a level with the lower border of the olivary body. From the resemblance that it bears to the nib of a writing pen it has been named the *calamus scriptorius*. In the point of the angle is a somewhat cleft-like space, the *ventricle of Arantius*, which opens by a minute hole into the central canal of the spinal cord. At its lateral angles the fourth ventricle is extended for a short distance between the side of the medulla and the cerebellum, where these two structures come in contact, forming a pointed *lateral recess*.

The roof is formed from above downwards by the following structures: a part of the superior peduncles of the cerebellum, the superior medullary velum, the inferior medullary vena, the tela choroidea inferior, the obex, and the ligula.

The *superior peduncles of the cerebellum*, when they emerge from the medullary substance of its hemispheres, pass upwards and forwards, forming the lateral boundaries of the upper half of the fourth ventricle, but as they approach the corpora quadrigemina the mesial portion of the peduncle forms a

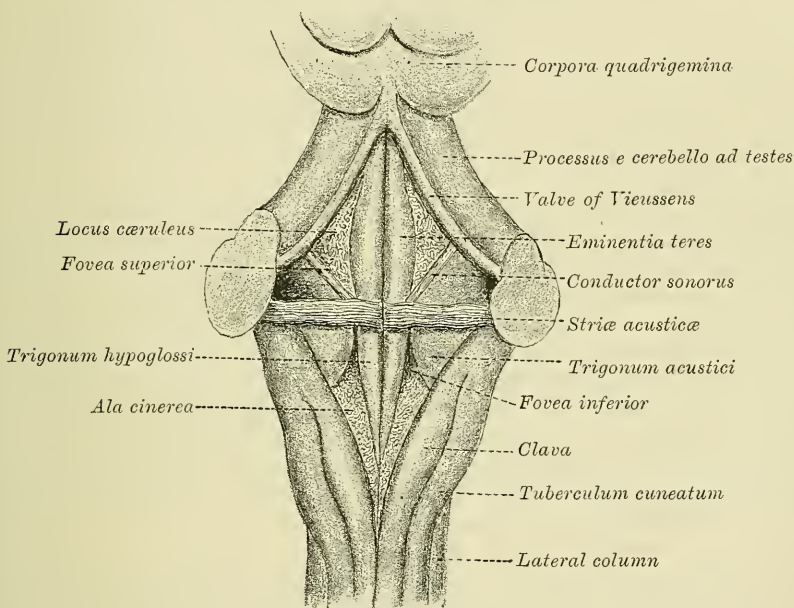


part of the roof of the cavity, in consequence of the ventricle extending to a slight extent underneath the peduncle.

*The superior medullary velum (Valve of Vieussens).*—In the angular interval left between the two superior peduncles is a thin lamina of white matter, which bridges across from one peduncle to the other, and so completes the roof of the superior part of the ventricle. This is the superior medullary velum (see p. 772). It is marked on its upper surface by three or four transverse grey bands, separated by sulci. These bands are continued laterally into the grey matter of the cerebellar hemispheres, and are termed the *ligula*. The *inferior medullary vela* are thin layers of white substance, attached on either side externally to the flocculus, and internally to the nodule, which assist in forming a part of the roof of the fourth ventricle (see p. 771). They are attached to the cerebellum by thin convex edges, and by thin concave margins are apparently free, but are connected with the epithelium of the ventricle.

The *tela choroidea inferior* is a layer of pia mater which covers in the lower part of the fourth ventricle below the inferior medullary vela. It extends from the choroid plexuses of the fourth ventricle in front to the lower and posterior

FIG. 481.—Floor of the fourth ventricle. Diagrammatic.



part of the cavity, where it becomes continuous with the pia mater, covering the posterior surface of the lower part of the medulla. It does not form a complete membrane, for there are contained in it three openings, one in the middle line at the inferior angle of the ventricle, just above the position of the opening of the central canal of the cord; this is the *foramen of Majendie*; the other two are at the extremities of the lateral recesses of the ventricle, and are named the *foramina of Key and Retzius* (see p. 726). The *obex* is a thin, triangular lamina of white matter which fills in the angle between the two diverging funiculi graciles for a short distance, and covers over the ventricle of Arantius. The *ligula (tænia)* are narrow bands of white matter which project from the internal border of the funiculi graciles. They at first run upwards and forwards, and then turn outwards over the restiform bodies. Their inner borders are continuous with the epithelial roof of the ventricle.

The *floor of the fourth ventricle* (fig. 481) is rhomboidal in shape, and is

traversed in its longer diameter by a median fissure, the *sulcus longitudinalis medianus*. At its widest part, at the level of the lateral recesses, it is marked by some transverse white lines, the *striæ medullaris* or *striæ acusticae*. These consist of white fibres, which arise on the under surface of the medulla, emerge from the longitudinal sulcus, and pass to the flocculus of the cerebellum. They were formerly described as passing into the root of the auditory nerve, hence their name.

These striæ divide the floor of the ventricle into two triangles, inferior and superior. The inferior triangle, or lower half of the floor, presents above a triangular depression, the *fovea inferior*, the apex of which is at the striæ. As this depression widens out it cuts off two triangular areas, one to the inner side and one to the outer. The one to the inner side is bounded internally by the median sulcus, and outside by the groove which forms the inner boundary of the fovea inferior; its base is directed upwards and limited by the striæ medullaris. It is termed the *trigonum hypoglossi*, because it corresponds in position to the tract of nerve-cells from which the hypoglossal nerve takes origin. The triangular area to the outer side of the fovea inferior is named the *trigonum acustici*. It lies between the groove forming the outer boundary of the fovea inferior and the lateral wall of the ventricle, and, like the trigonum hypoglossi, has its base directed upwards. Here it is continuous with a prominence, the *tuberculum acusticum*, which extends into the anterior part of the floor of the ventricle, and from which the greater part of the auditory nerve arises. As the fovea inferior widens out it marks off a triangular depression, with its base directed downwards. This is of a darker colour than the rest of the floor of the ventricle, and is therefore named the *ala cinerea*, and from the fact that it contains the nuclei of the vagus and glosso-pharyngeal nerves it is sometimes called the *trigonum vagi*.

The superior half of the floor of the fourth ventricle, i.e. the part above the striæ medullaris, presents in the middle line the continuation of the median longitudinal sulcus. On either side of this is a spindle-shaped longitudinal eminence, prominent in its centre, but less so above and below. This is the *eminentia teres*, and is produced by an underlying bundle of white fibres, the *funiculus teres*, formed, at all events in part, by the fibres of the facial nerve. Outside the *eminentia teres* is an angular depression, the *fovea superior*, which is sometimes crossed by a whitish band of fibres, the *conductor sonorus*, which below is connected with the striæ medullaris. Above the fovea is a bluish depressed area, the *locus cæruleus*. Its colour is due to some pigmented nerve-cells, showing through the white covering of the floor. These pigmented cells are named the *substantia ferruginea*.

The *lining membrane of the fourth ventricle* is continuous with that of the third, through the aqueduct of Sylvius, and its cavity communicates below with the subarachnoidean space of the brain and cord through an aperture in the layer of pia mater extending between the cerebellum and medulla oblongata. Laterally, this membrane is reflected outwards a short distance between the cerebellum and medulla.

The *choroid plexuses* of the fourth ventricle are two in number: they are delicate vascular fringes, which project into the ventricle on each side, though excluded from the ventricular cavity by a layer of epithelium. They pass from the inferior vermiform process, where they lie close together on each side of the middle line, in a direction outwards to the apertures in the pia mater of the lateral recesses of the ventricle.

## CRANIAL NERVES

The cranial nerves arise from some part of the cerebro-spinal centre, and are transmitted through foramina in the base of the cranium. They have been named numerically, according to the order in which they pass through the dura

mater lining the base of the skull. Other names are also given to them derived from the parts to which they are distributed, or from their functions. Taken in their order, from before backwards, they are as follows:—

- |                              |                                  |
|------------------------------|----------------------------------|
| 1st. Olfactory.              | 7th. Facial (Portio dura).       |
| 2nd. Optic.                  | 8th. Auditory (Portio mollis).   |
| 3rd. Motor oculi.            | 9th. Glosso-pharyngeal.          |
| 4th. Trochlear (Pathetic).   | 10th. Pneumogastric (Par vagum). |
| 5th. Trifacial (Trigeminus). | 11th. Spinal accessory.          |
| 6th. Abducent.               | 12th. Hypoglossal.               |

All the cranial nerves are connected to some part of the surface of the brain. This is termed their *superficial* or *apparent origin*. But their fibres may, in all cases, be traced deeply into the substance of the brain to some special centre of grey matter, termed a *nucleus*. This is called their *deep* or *real origin*. The nerves, after emerging from the brain at their *apparent origin*, pass through foramina or tubular prolongations in the dura mater, leave the skull through foramina in its base, and pass to their final distribution.

#### FIRST NERVE (fig. 466, page 747)

The **First Cranial or Olfactory Nerves**, the special nerves of the sense of smell, are about twenty in number. They are given off from the under surface of the olfactory bulb, an oval mass of a greyish colour, which rests on the cribriform plate of the ethmoid bone, and forms the anterior expanded extremity of a slender process of brain-substance, named the *olfactory tract* (see page 738). The olfactory tract is the remains of a hollow projection of the fore-brain of the fœtus, in which the cavity becomes obliterated in man, though persistent in many mammals and other vertebrates. It is an elongated body, triangular in section, and capped at its extremity by a layer of grey matter, forming the olfactory bulb. It contains in its centre a core of neuroglia, which is the remains of the obliterated cavity; above this the tract consists of grey matter, which is continuous with the cerebral cortex; below, it consists of white matter, which divides posteriorly into two roots. Of these, the external, which is the larger, passes outwards round the anterior perforated space, across the fissure of Sylvius, to the temporo-sphenoidal lobe. The other, or internal root, passes inwards and joins the lower end of the corpus callosum. Between these two diverging roots a triangular interval is left, in which is seen an elevation, which is sometimes described as the middle or grey root of the tract. It passes backwards into the anterior commissure.

As the olfactory tract passes forwards, it is contained in a deep sulcus, the *olfactory sulcus*, between two convolutions, lying on the under surface of the frontal lobe, on either side of the longitudinal fissure, and is retained in position by the arachnoid membrane which covers it. On reaching the cribriform plate of the ethmoid bone, it forms the *olfactory bulb*. From the under part of this bulb are given off the olfactory nerves, which pass through the cribriform foramina, and are distributed to the mucous membrane of the nose. Each nerve is surrounded by a tubular prolongation from the dura mater and pia mater; the former being lost on the periosteum lining the nose; the latter, in the neurilemma of the nerve. The nerves, as they enter the nares, are divisible into two groups: an inner group, larger than those on the outer wall, spread out over the upper third of the septum; and an outer set, which are distributed over the superior turbinated bone, and the surface of the ethmoid in front of it. As the filaments descend, they unite in a plexiform network, and are believed by most observers to terminate in the *cells of Schultze*.

The olfactory differs in structure from other nerves, in being composed exclusively of non-medullated fibres. They are deficient in the white substance



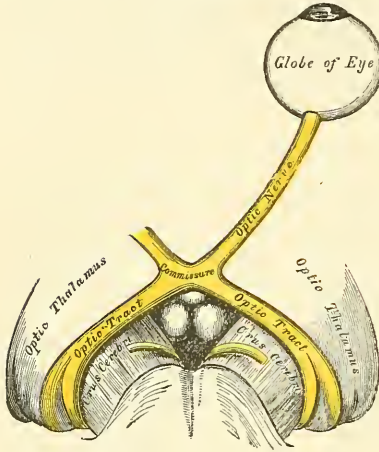
of Schwann, and consist of axis-cylinders, with a distinct nucleated sheath, in which there are, however, fewer nuclei than in ordinary non-medullated fibres.

*Surgical Anatomy.*—In severe injuries to the head, the olfactory bulb may become separated from the olfactory nerves, thus producing loss of the sense of smelling (*anosmia*), and with this a considerable loss in the sense of taste, as much of the perfection of the sense of taste is due to the sapid substances being also odorous, and simultaneously exciting the sense of smell.

### SECOND NERVE (fig. 482)

The **Second** or **Optic Nerve**, the special nerve of the sense of sight, is distributed exclusively to the eyeball. The nerves of opposite sides are connected together

FIG. 482.—The left optic nerve and optic tracts.



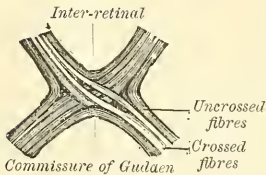
at the commissure, and from the back of the commissure they may be traced to the brain, under the name of the *optic tracts*.

The *optic tract*, at its connection with the brain, is divided into two bands. One of these arises from a greyish white layer (*stratum opticum*) in the interior of the anterior or upper lobes of the corpora quadrigemina, and emerges from the nates of this body as the anterior brachium, and passes obliquely outwards between the inner and outer geniculate bodies; the second arises from the pulvinar of the optic thalamus, and passes through the inner geniculate body, from which it derives fibres, and joins with the other band to form the optic tract. From this origin the tract winds obliquely across the under surface of the crus cerebri, in the form of a flattened band, destitute of neurilemma, and is at-

tached to the crus by its anterior margin. It then assumes a cylindrical form, and, as it passes forwards, is connected with the tuber cinereum and lamina cinerea, with both of which it is connected. It finally joins with the tract of the opposite side to form the *optic commissure*.

The *commissure* or *chiasma*, somewhat quadrilateral in form, rest upon the optic groove of the sphenoid bone, being bounded, above, by the lamina cinerea; behind, by the tuber cinereum; on either side, by the anterior perforated space.

FIG. 483.—Course of the fibres in the optic commissure.



Within the commissure, the optic nerves of the two sides undergo a partial decussation. The fibres which form the inner margin of each tract and posterior part of the commissure have no connection with the optic nerves. They simply pass across from one side of the brain to the other, and connect the internal geniculated bodies of the two sides. They are known as the *commissure of Gudden*. Some fibres are continued across the anterior border of the chiasma, and connect the optic nerves of the two sides, having no relation with the optic tracts.\* They may be regarded as commissural fibres between the two retinae (*inter-retinal fibres*). The remainder and principal part of the commissure consists of two sets of fibres, crossed and uncrossed. The *crossed*, which are the more numerous, occupy the mesial part of the chiasma, and pass from the optic tract of one side to the optic nerve of the other, decussating in the commissure with similar fibres of the opposite tract.

\* The presence of these fibres has been doubted by some observers, but they have been recently asserted to exist by Stilling.

The uncrossed fibres occupy the outer part of the chiasma, and pass from the tract of one side to the nerve of the same side.\*

The *optic nerves* arise from the fore part of the commissure, and, diverging from one another, become rounded in form and firm in texture, and are enclosed in a sheath derived from the arachnoid. As each nerve passes through the corresponding optic foramen, it receives a sheath from the dura mater; and as it enters the orbit this sheath divides into two layers, one of which becomes continuous with the periosteum of the orbit; the other forms the proper sheath of the nerve, and surrounds it as far as the sclerotic. The nerve passes through the cavity of the orbit, pierces the sclerotic and choroid coats at the back part of the eyeball, a little to the nasal side of its centre, and expands into the retina. Arnold describes a communication between the optic nerve in the orbit and the ascending branches of Meckel's ganglion. A small artery, the *arteria centralis retinae*, perforates the optic nerve a little behind the globe, and runs along its interior in a tubular canal of fibrous tissue. It supplies the inner surface of the retina, and is accompanied by corresponding veins.

*Surgical Anatomy.*—The optic nerve is peculiarly liable to become the seat of neuritis or undergo atrophy in affections of the central nervous system, and as a rule the pathological relationship between the two affections is exceedingly difficult to trace. There are, however, certain points in connection with the anatomy of this nerve which tend to throw light upon the frequent association of these affections with intracranial disease: (1) From its mode of development (see page 97), and from its structure, the optic nerve must be regarded as a prolongation of the brain-substance, rather than as an ordinary cerebro-spinal nerve. (2) As it passes from the brain, it receives sheaths from the three cerebral membranes, a perineural sheath from the pia mater; an intermediate sheath from the arachnoid, and an outer sheath from the dura mater, which is also connected with the periosteum, as it passes through the optic foramen. These sheaths are separated from each other by spaces, which communicate with the subdural and subarachnoid spaces respectively. The innermost or perineural sheath sends a process around the *arteria centralis retinae* into the interior of the nerve, and enters intimately into the structure of the nerve. Thus inflammatory affection of the meninges or of the brain may readily extend themselves along these spaces, or along the interstitial connective tissue in the nerve.

The course of the fibres in the optic commissure has an important pathological bearing, and has been the subject of much controversy. Microscopic examination, experiments, and pathology all seem to point to the fact that there is a partial decussation of the fibres, each tract supplying the corresponding half of each eye, so that the right tract supplies the right half of each eye, and the left tract the left half of each eye. At the same time Charcot believes, and his view has met with general acceptance, that the fibres which do not decussate at the optic commissure have already decussated in the *corpora quadrigemina*, so that lesion of the cerebral centre of one side causes complete blindness of the opposite eye, because both sets of decussating fibres are destroyed. Whereas should one tract, say the right, be destroyed by disease, there will be blindness of the right half of both retinae.

An antero-posterior section through the commissure would divide the decussating fibres, and would therefore produce blindness of the inner half of each eye; while a section at the margin of the side of the optic commissure would produce blindness of the external half of the retina of the same side.

The optic nerve may also be affected in injuries or diseases involving the orbit; in fractures of the anterior fossa of the base of the skull; in tumours of the orbit itself, or those invading this cavity from neighbouring parts.

### THIRD NERVE (figs. 484, 485, 486)

The **Third or Motor Oculi Nerve** supplies all the muscles of the orbit, except the Superior oblique and External rectus; it also supplies, through its connection with the ciliary ganglion, the sphincter muscle of the iris and the ciliary muscle. It is a rather large nerve, of rounded form and firm texture.

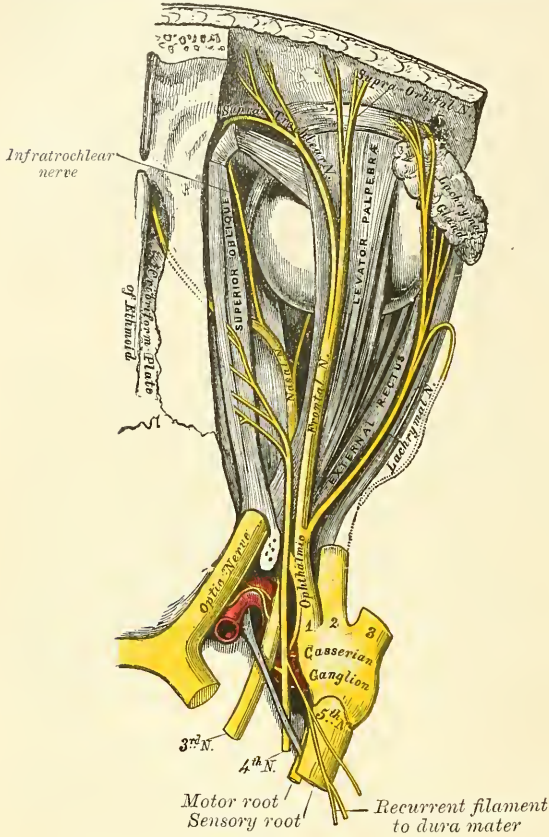
Its apparent origin is from the inner surface of the *crus cerebri*, immediately in front of the pons Varolii. The *deep origin* may be traced through the locus

\* A specimen of congenital absence of the optic commissure is to be found in the Museum of the Westminster Hospital. See also Henle, *Nervenlehre*, p. 393, ed. 2.



niger and tegmentum of the crus to a nucleus situated on either side of the median line beneath the floor of the aqueduct of Sylvius.

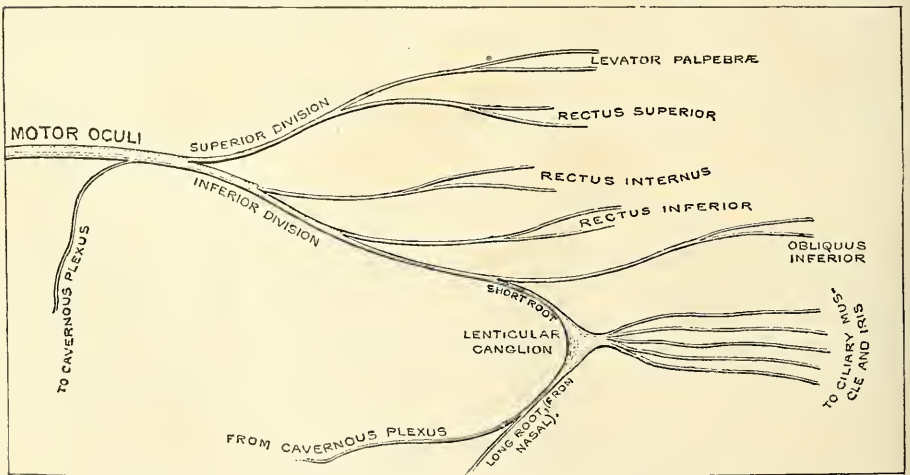
FIG. 484.—Nerves of the orbit. Seen from above.



On emerging from the brain, the nerve is invested with a sheath of pia mater, and enclosed in a prolongation from the arachnoid. It passes between the superior cerebellar and posterior cerebral arteries, and then pierces the dura mater in front of and external to the posterior clinoid process, passing between the two processes from the free and attached borders of the tentorium, which are prolonged forwards to be connected with the anterior and posterior clinoid processes of the sphenoid bone. It passes along the outer wall of the cavernous sinus, above the other orbital nerves, receiving in its course one or two filaments from the cavernous plexus of the sympathetic, and a communicating branch from the first division of the fifth. It then divides into two branches, which enter the orbit through the sphenoidal fissure, between the two heads of the External rectus muscle. On passing through the fissure, the nerve is placed below the fourth and the frontal and lach-

rymal branches of the ophthalmic nerve, and has passing between its two divisions the nasal nerve.

FIG. 485.—Plan of the motor oculi nerve. (After Flower.)





The *superior division*, the smaller, passes inwards over the optic nerve, and supplies the Superior rectus and Levator palpebræ. The *inferior division*, the larger, divides into three branches. One passes beneath the optic nerve to the Internal rectus; another, to the Inferior rectus; and the third, the longest of the three, passes forwards between the Inferior and External recti to the Inferior oblique. From this latter a short, thick branch is given off to the lower part of the lenticular ganglion, which forms its inferior root. It also gives off one or two filaments to the Inferior rectus. All these branches enter the muscles on their ocular surface.

*Surgical Anatomy.*—Paralysis of the third nerve may be the result of many causes: as cerebral disease; conditions causing pressure on the cavernous sinus; periostitis of the bones entering into the formation of the sphenoidal fissure. It results, when complete, in (1) ptosis, or drooping of the upper eyelid, in consequence of the Levator palpebræ being paralysed; (2) external strabismus, on account of the unopposed action of the External rectus muscle, which is not supplied by the third nerve, and is not therefore paralysed; (3) dilatation of the pupil, because the sphincter fibres of the iris are paralysed; (4) loss of power of accommodation, as the sphincter pupillæ, the ciliary muscle, and the Internal rectus are paralysed; (5) slight prominence of the eyeball, from the compressing action of the Superior oblique, which is not paralysed. Occasionally paralysis may affect only a part of the nerve, that is to say, there may be, for example, a dilated and fixed pupil, with ptosis, but no other signs. Irritation of the nerve causes spasm of one or other of the muscles supplied by it; thus, there may be internal strabismus from spasm of the Internal rectus; accommodation for near objects only from spasm of the ciliary muscle; or myosis, contraction of the pupil, from irritation of the sphincter of the pupil.

#### FOURTH NERVE (fig. 484)

The **Fourth** or **Trochlear Nerve** (*pathetic*), the smallest of the cranial nerves, supplies the Superior oblique muscle.

Its *apparent origin*, at the base of the brain, is on the outer side of the crus cerebri, just in front of the pons Varolii, but the fibres can be traced backwards behind the corpora quadrigemina to the valve of Vieussens, on the upper surface of which the two nerves decussate. Its *deep origin* may be traced to a nucleus in the floor of the aqueduct of Sylvius immediately below that of the third nerve, with which it is continuous.

The nerve winds round the outer side of the crus cerebri, immediately above the pons Varolii, pierces the dura mater in the free border of the tentorium cerebelli, just behind, and external to, the posterior clinoid process, and passes forwards in the outer wall of the cavernous sinus, between the third nerve and the ophthalmic division of the fifth. It crosses the third nerve and enters the orbit, through the sphenoidal fissure. It now becomes the highest of all the nerves, lying at the inner extremity of the fissure internal to the frontal nerve. In the orbit it passes inwards, above the origin of the Levator palpebræ, and finally enters the orbital surface of the Superior oblique muscle.

In the outer wall of the cavernous sinus this nerve is not unfrequently blended with the ophthalmic division of the fifth. *Branches of communication.*—In the outer wall of the cavernous sinus it receives some filaments from the cavernous plexus of the sympathetic. In the sphenoidal fissure it occasionally gives off a branch to assist in the formation of the lachrymal nerve. *Branches of distribution.*—It gives off a recurrent branch, which passes backwards between the layers of the tentorium, dividing into two or three filaments which may be traced as far back as the wall of the lateral sinus.

*Surgical Anatomy.*—The fourth nerve when paralysed causes loss of function in the Superior oblique, so that the patient is unable to turn his eye downwards and outwards. Should the patient attempt to do this, the eye on the affected side is twisted inwards, producing diplopia or double vision. Accordingly, it is said that the first symptom of loss of function in this muscle is giddiness when going down hill or in descending stairs, owing to the double vision induced by the patient looking at his steps whilst descending.

## FIFTH NERVE

The **Fifth** or **Trifacial Nerve** (*trigeminus*) is the largest cranial nerve. It resembles a spinal nerve: (1) in arising by two roots; (2) in having a ganglion developed on its posterior root; and (3) in its function, since it is a compound nerve. It is the great sensory nerve of the head and face, and the motor nerve of the muscles of mastication. Its upper two divisions are entirely sensory, the third division is partly sensory and partly motor.

It arises by two roots: of these the anterior is the smaller, and is the motor root; the posterior, the larger and sensory. Its *superficial origin* is from the side of the pons Varolii, nearer to the upper than the lower border. The smaller root consists of three or four bundles; the larger root consists of numerous bundles of fibres, varying in number from seventy to a hundred. The two roots are separated from one another by a few of the transverse fibres of the pons. The *deep origin* of the larger or sensory root is chiefly from a long tract in the medulla, the so-called *ascending root*; the fibres from which pass upwards through the pons and join with those derived from a nucleus in the floor of the fourth ventricle, placed deeper and to the outer side of the nucleus from which the small or motor root is derived. The *deep origin* of the smaller or motor root is derived partly from a nucleus embedded in the grey matter of the floor of the fourth ventricle and partly from a collection of nerve-cells situated at the side of the aqueduct of Sylvius, which pass downwards to join the nerve, and are known as the descending root.

The two roots of the nerve pass forwards through an oval opening in the dura mater, on the superior border of the petrous portion of the temporal bone, above the internal auditory meatus: they then run between the bone and the dura mater to the apex of the petrous portion of the temporal bone, where the fibres of the sensory root form a large semilunar ganglion (*Gasserian*), while the motor root passes beneath the ganglion without having any connection with it, and joins outside the cranium with one of the trunks derived from it.

The *Gasserian* or **semilunar ganglion**\* is lodged in a depression near the apex of the petrous portion of the temporal bone. It is of somewhat crescentic form, with its convexity turned forwards. Its upper surface is intimately adherent to the dura mater. Besides the small or motor root, the large superficial petrosal nerve lies underneath the ganglion.

*Branches of communication.*—This ganglion receives, on its *inner side*, filaments from the carotid plexus of the sympathetic. *Branches of distribution.*—It gives off minute branches to the tentorium cerebelli and the dura mater, in the middle fossa of the cranium. From its *anterior border*, which is directed forwards and outwards, three large branches proceed: the *ophthalmic*, *superior maxillary*, and *inferior maxillary*. The ophthalmic and superior maxillary consist exclusively of fibres derived from the larger root and ganglion, and are solely nerves of common sensation. The third division, or inferior maxillary, is joined outside the cranium by the motor root. This, therefore, strictly speaking, is the only portion of the fifth nerve which can be said to resemble a spinal nerve.

## OPHTHALMIC NERVE (figs. 484, 486, 487)

The **Ophthalmic**, or first division of the fifth, is a sensory nerve. It supplies the eyeball, the lachrymal gland, the mucous lining of the eye and nasal fossæ, and the integument of the eyebrow, forehead, and nose. It is the smallest of the three divisions of the fifth, rising from the upper part of the Gasserian ganglion.

\* A Viennese anatomist, Raimund Balthasar Hirsch (1765), was the first who recognised the ganglionic nature of the swelling on the sensory root of the fifth nerve, and called it, in honour of his otherwise unknown teacher, Jon. Laur. Gasser, the 'Ganglion Gasseri.' Julius Casserius, whose name is given to the musculo-cutaneous nerve of the arm, was Professor at Padua, 1545-1605. See Hyrtl, *Lehrbuch der Anatomie*, p. 895 and p. 55.



It is a short, flattened band, about an inch in length, which passes forwards along the outer wall of the cavernous sinus, below the other nerves, and just before entering the orbit, through the sphenoidal fissure, divides into three branches, *lachrymal, frontal and nasal*.

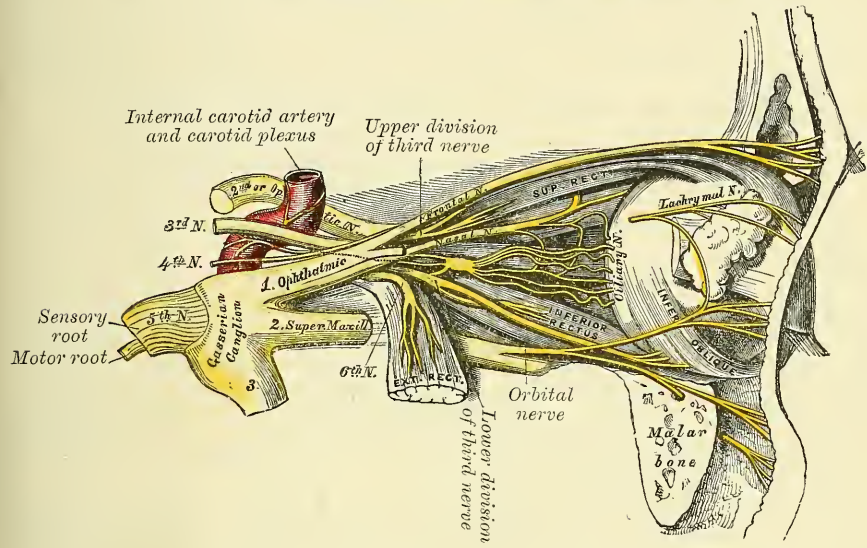
*Branches of communication.*—The ophthalmic nerve is joined by filaments from the cavernous plexus of the sympathetic, communicates with the third and sixth nerves, and is not unfrequently joined with the fourth.

*Branches of distribution.*—It gives off recurrent filaments which pass between the layers of the tentorium along with a branch from the fourth nerve, and then divides into

Lachrymal.                      Frontal.                      Nasal.

The **Lachrymal** is the smallest of the three branches of the ophthalmic. Not unfrequently it arises by two filaments, one from the ophthalmic, the other from the fourth. It passes forwards in a separate tube of dura mater, and enters the orbit through the narrowest part of the sphenoidal fissure. In the orbit it runs

FIG. 486.—Nerves of the orbit and ophthalmic ganglion. Side view.



along the upper border of the External rectus muscle, with the lachrymal artery, and sends off a recurrent branch which joins the orbital branch of the superior maxillary nerve, and occasionally takes the place of the temporal branch of this nerve, which is then absent. Within the lachrymal gland it gives off several filaments, which supply the gland and the conjunctiva. Finally, it pierces the tarsal ligaments, and terminates in the integument of the upper eyelid, joining with filaments of the facial nerve.

The **Frontal** is the largest division of the ophthalmic, and may be regarded, both from its size and direction, as the continuation of the nerve. It enters the orbit above the muscles, through the highest and broadest part of the sphenoidal fissure, and runs forwards along the middle line, between the Levator palpebræ and the periosteum. Midway between the apex and base of the orbit it divides into two branches, supratrochlear and supra-orbital.

The *supratrochlear branch*, the smaller of the two, passes inwards, above the pulley of the Superior oblique muscle, and gives off a descending filament, which joins with the infratrochlear branch of the nasal nerve. It then escapes from the orbit between the pulley of the Superior oblique and the supra-orbital foramen, curves up on to the forehead close to the bone, and descends beneath the Corrugator supercilii and Occipito-frontalis muscles, and dividing into branches,



which pierce these muscles, it supplies the integument of the lower part of the forehead on either side of the middle line.

The *supra-orbital branch* passes forwards through the supra-orbital foramen, and gives off, in this situation, palpebral filaments to the upper eyelid. It then ascends upon the forehead, and terminates in cutaneous and pericranial branches. The *cutaneous branches*, two in number, an inner and an outer, supply the integument of the cranium as far back as the occiput. They are at first situated beneath the Occipito-frontalis, the inner branch perforating the frontal portion of the muscle, the outer branch its tendinous aponeurosis. The *pericranial branches* are distributed to the pericranium over the frontal and parietal bones.

The **Nasal nerve** is intermediate in size between the frontal and lachrymal, and more deeply placed than the other branches of the ophthalmic. It enters the orbit between the two heads of the External rectus, and passes obliquely inwards across the optic nerve, beneath the Levator palpebræ and Superior rectus muscles, to the inner wall of the orbit, where it enters the anterior ethmoidal foramen, immediately below the Superior oblique. It then enters the cavity of the cranium, traverses a shallow groove on the front of the cribriform plate of the ethmoid bone, and passes down, through the slit by the side of the crista galli, into the nose, where it divides into two branches, an internal and an external. The *internal branch* supplies the mucous membrane near the fore part of the septum of the nose. The *external branch* descends in a groove on the inner surface of the nasal bone, and supplies a few filaments to the mucous membrane covering the fore part of the outer wall of the nares as far as the inferior spongy bone; it then leaves the cavity of the nose, between the lower border of the nasal bone and the upper lateral cartilage of the nose, and, passing down beneath the Compressor nasi, supplies the integument of the ala and the tip of the nose, joining with the facial nerve.

The branches of the nasal nerve are, the *ganglionic*, *ciliary*, and *infra-trochlear*.

The *ganglionic* is a slender branch, about half an inch in length, which usually arises from the nasal, between the two heads of the External rectus. It passes forwards on the outer side of the optic nerve, and enters the superior and posterior angle of the ciliary ganglion, forming its superior or long root. It is sometimes joined by a filament from the cavernous plexus of the sympathetic, or from the superior division of the third nerve.

The *long ciliary nerves*, two or three in number, are given off from the nasal as it crosses the optic nerve. They join the short ciliary nerves from the ciliary ganglion, pierce the posterior part of the sclerotic, and, running forwards between it and the choroid, are distributed to the ciliary muscle, iris, and cornea.

The *infratrochlear branch* is given off just before the nasal nerve passes through the anterior ethmoidal foramen. It runs forwards along the upper border of the Internal rectus, and is joined, beneath the pulley of the Superior oblique, by a filament from the supratrochlear nerve. It then passes to the inner angle of the eye, and supplies the integument of the eyelids and side of the nose, the conjunctiva, lachrymal sac, and caruncula lachrymalis.

#### OPHTHALMIC GANGLION (figs. 486, 487)

Connected with the three divisions of the fifth nerve are four small ganglia. With the first division is connected the *ophthalmic ganglion*; with the second division, the *spheno-palatine* or *Meckel's ganglion*; and with the third, the *otic* and *submaxillary ganglia*. All the four receive sensory filaments from the fifth, and motor and sympathetic filaments from various sources; these filaments are called the *roots of the ganglia*.

The **Ophthalmic, Lenticular, or Ciliary Ganglion** is a small, quadrangular, flattened ganglion, of a reddish-grey colour, and about the size of a pin's head, situated at the back part of the orbit between the optic nerve and the External



rectus muscle, lying generally on the outer side of the ophthalmic artery. It is enclosed in a quantity of loose fat, which makes its dissection somewhat difficult.

Its *branches of communication*, or *roots*, are three, all of which enter its posterior border. One, the long or sensory root, is derived from the nasal branch of the ophthalmic, and joins its superior angle. The second, the short or motor root, is a short, thick nerve, occasionally divided into two parts, which is derived from the branch of the third nerve to the Inferior oblique muscle, and is connected with the inferior angle of the ganglion. The third, the sympathetic root, is a slender filament from the cavernous plexus of the sympathetic. This is frequently blended with the long root, though it sometimes passes to the ganglion separately. According to Tiedemann, this ganglion receives a filament of communication from the spheno-palatine ganglion.

Its *branches of distribution* are the short ciliary nerves. These are delicate filaments, from six to ten in number, which arise from the fore part of the ganglion in two bundles, connected with its superior and inferior angles; the lower bundle is the larger. They run forwards with the ciliary arteries in a wavy course, one set above and the other below the optic nerve, and are joined by the long ciliary nerves from the nasal. They pierce the sclerotic at the back part of the globe, pass forwards in delicate grooves on its inner surface, and are distributed to the ciliary muscle, iris, and cornea. Tiedemann has described one small branch as penetrating the optic nerve with the arteria centralis retinae.

#### SUPERIOR MAXILLARY NERVE (fig. 488)

The **Superior Maxillary**, or second division of the fifth, is a sensory nerve. It is intermediate, both in position and size, between the ophthalmic and inferior maxillary. It commences at the middle of the Gasserian ganglion as a flattened plexiform band, and passing horizontally forwards, it leaves the skull through the foramen rotundum, where it becomes more cylindrical in form, and firmer in texture. It then crosses the spheno-maxillary fossa, enters the orbit through the spheno-maxillary fissure, traverses the infra-orbital canal in the floor of the orbit, and appears upon the face at the infra-orbital foramen.\* At its termination, the nerve lies beneath the Levator labii superioris muscle, and divides into a leash of branches, which spread out upon the side of the nose, the lower eyelid, and upper lip, joining with filaments of the facial nerve.

*Branches of distribution.*—The branches of this nerve may be divided into four groups: 1. Those given off in the cranium. 2. Those given off in the spheno-maxillary fossa. 3. Those in the infra-orbital canal. 4. Those on the face.

In the cranium . . .	Meningeal
Spheno-maxillary fossa	{ Orbital or temporo-malar.
	{ Spheno-palatine.
Infra-orbital canal . . .	{ Posterior superior dental.
	{ Middle superior dental.
	{ Anterior superior dental.
On the face . . . . .	{ Palpebral.
	{ Nasal.
	{ Labial.

The **meningeal branch** is given off directly after its origin from the Gasserian ganglion, and supplies the dura mater, communicating with a meningeal branch from the inferior maxillary nerve.

The **orbital or temporo-malar branch** arises in the spheno-maxillary fossa, enters the orbit by the spheno-maxillary fissure, and divides at the back of that cavity into two branches, temporal and malar.

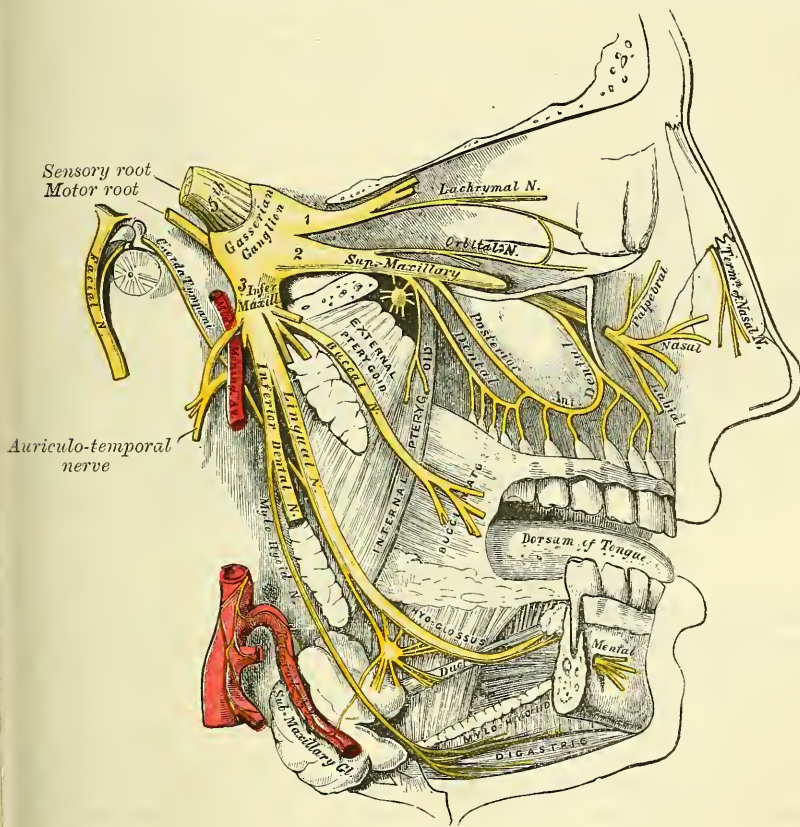
\* After it enters the infra-orbital canal, the nerve is frequently called the *infra-orbital*.



The *temporal branch* runs in a groove along the outer wall of the orbit (in the malar bone), receives a branch of communication from the lachrymal, and, passing through a foramen in the malar bone, enters the temporal fossa. It ascends between the bone and substance of the Temporal muscle, pierces this muscle and the temporal fascia about an inch above the zygoma, and is distributed to the integument covering the temple and side of the forehead, communicating with the facial and auriculo-temporal branch of the inferior maxillary nerve. As it pierces the temporal fascia, it gives off a slender twig, which runs between the two layers of the fascia to the outer angle of the orbit.

The *malar branch* passes along the external inferior angle of the orbit, emerges upon the face through a foramen in the malar bone, and, perforating

FIG. 488.—Distribution of the second and third divisions of the fifth nerve and submaxillary ganglion.



the Orbicularis palpebrarum muscle, supplies the skin on the prominence of the cheek, and is named *subcutaneous male*. It joins with the facial and the palpebral branches of the superior maxillary.

The **spheno-palatine branches**, two in number, descend to the spheno-palatine ganglion.

The **posterior superior dental branches** arise from the trunk of the nerve just as it is about to enter the infra-orbital canal; they are generally two in number, but sometimes arise by a single trunk, and immediately divide and pass downwards on the tuberosity of the superior maxillary bone. They give off several twigs to the gums and neighbouring parts of the mucous membrane of the cheek (*superior gingival branches*). They then enter the posterior dental canals on the zygomatic surface of the superior maxillary bone, and, passing from behind

forwards in the substance of the bone, communicate with the middle dental nerve, and give off branches to the lining membrane of the antrum and three twigs to each of the molar teeth. These twigs enter the foramina at the apices of the fangs, and supply the pulp.

The **middle superior dental branch** is given off from the superior maxillary nerve in the back part of the infra-orbital canal, and runs downwards and forwards in a special canal in the outer wall of the antrum to supply the two bicuspid teeth. It communicates with the posterior and anterior dental branches. At its point of communication with the posterior branch is a slight thickening which has received the name of the *ganglion of Valentin*; and at its point of communication with the anterior branch is a second enlargement, which is called the *ganglion of Bochdalek*. Neither of these is probably a true ganglion.

The **anterior superior dental branch**, of large size, is given off from the superior maxillary nerve just before its exit from the infra-orbital foramen; it enters a special canal in the anterior wall of the antrum, and, coursing from before backwards, divides into a series of branches which supply the incisor and canine teeth. It communicates with the middle dental branch and gives off a *nasal branch*, which passes through a minute canal into the nasal fossa, and supplies the mucous membrane of the fore part of the inferior meatus and the floor of this cavity, communicating with the naso-palatine nerve from Meckel's ganglion.

The **palpebral branches** pass upwards beneath the *Orbicularis palpebrarum*. They supply the integument and conjunctiva of the lower eyelid with sensation, joining at the outer angle of the orbit with the facial nerve and malar branch of the orbital.

The **nasal branches** pass inwards; they supply the integument of the side of the nose, and join with the nasal branch of the ophthalmic.

The **labial branches**, the largest and most numerous, descend beneath the *Levator labii superioris*, and are distributed to the integument of the upper lip, the mucous membrane of the mouth, and labial glands.

All these branches are joined, immediately beneath the orbit, by filaments from the facial nerve, forming an intricate plexus, the *infra-orbital*.

#### SPHENO-PALATINE GANGLION (fig. 489)

The **spheno-palatine ganglion** (*Meckel's*), the largest of the cranial ganglia, is deeply placed in the spheno-maxillary fossa, close to the spheno-palatine foramen. It is triangular or heart-shaped, of a reddish-grey colour, and is situated just below the superior maxillary nerve as it crosses the fossa.

*Its branches of communication.*—Like the other ganglia of the fifth nerve, it possesses a motor, a sensory, and a sympathetic root. Its *sensory root* is derived from the superior maxillary nerve through its two spheno-palatine branches. These branches of the nerve, given off in the spheno-maxillary fossa, descend to the ganglion. Their fibres, for the most part, pass in front of the ganglion, as they proceed to their destination, in the palate and nasal fossa, and are not incorporated in the ganglionic mass; some few of the fibres, however, enter the ganglion, constituting its sensory root. Its *motor root* is derived from the facial nerve through the large superficial petrosal nerve; and its *sympathetic root*, from the carotid plexus, through the large deep petrosal nerve. These two nerves join together to form a single nerve, the *Vidian*, before their entrance into the ganglion.

The *large superficial petrosal branch* (*nervus petrosus superficialis major*) is given off from the intumescencia ganglioformis in the aqueductus Fallopii; it passes through the hiatus Fallopii; enters the cranial cavity, and runs forwards contained in a groove on the anterior surface of the petrous portion of the temporal bone, lying beneath the dura mater and the Gasserian ganglion. It then enters the cartilaginous substance which fills in the foramen lacerum



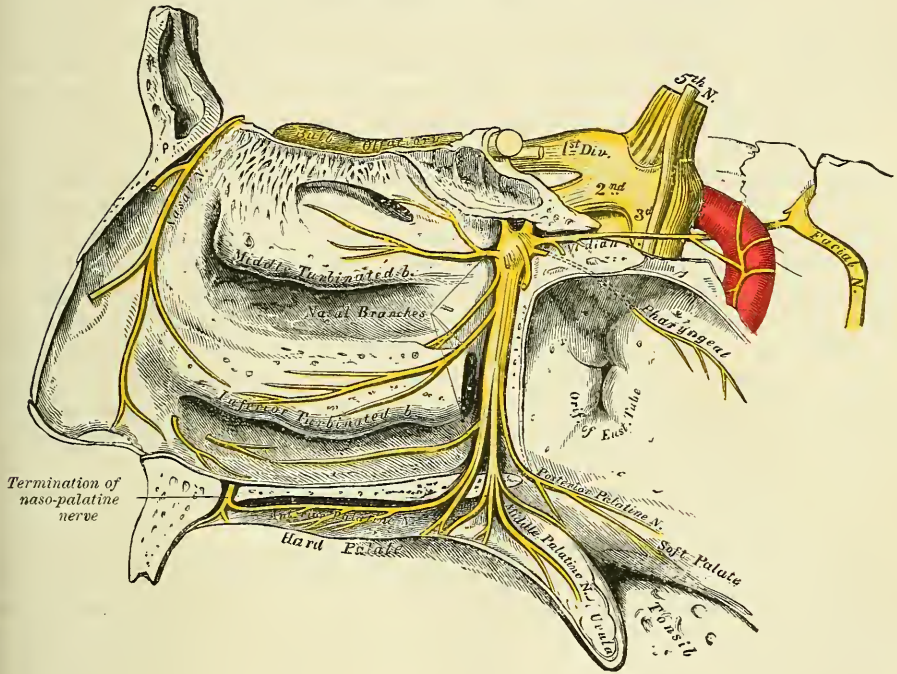
medium basis cranii, and joining with the large deep petrosal branch forms the Vidian nerve.

The *large deep petrosal branch* (*nervus petrosus profundus*) is given off from the carotid plexus, and runs through the carotid canal on the outer side of the internal carotid artery. It then enters the cartilaginous substance which fills in the foramen lacerum medium, and joins with the large superficial petrosal nerve to form the Vidian.

The *Vidian nerve*, formed in the cartilaginous substance which fills in the middle lacerated foramen by the junction of the two preceding nerves, passes forwards, through the Vidian canal, with the artery of the same name, and, entering the sphenomaxillary fossa, joins the posterior angle of Meckel's ganglion.

Its *branches of distribution* are divisible into four groups: *ascending*, which pass to the orbit; *descending*, to the palate; *internal*, to the nose; and *posterior branches*, to the pharynx and nasal fossæ.

FIG. 489.—The sphenopalatine ganglion and its branches.



The *ascending branches* are two or three delicate filaments, which enter the orbit by the sphenomaxillary fissure, and supply the periosteum. According to Luschka, some filaments pass through foramina in the suture between the os planum of the ethmoid and frontal bones to supply the mucous membrane of the posterior ethmoidal and sphenoidal sinuses.

The *descending or palatine branches* are distributed to the roof of the mouth, the soft palate, tonsil, and lining membrane of the nose. They are almost a direct continuation of the sphenopalatine branches of the superior maxillary nerve, and are three in number: anterior, middle, and posterior.

The *anterior or large palatine nerve* descends through the posterior palatine canal, emerges upon the hard palate, at the posterior palatine foramen, and passes forwards through a groove in the hard palate, nearly as far as the incisor teeth. It supplies the gums, the mucous membrane and glands of the hard palate, and communicates in front with the termination of the naso-palatine nerve. While in the posterior palatine canal, it gives off *inferior nasal branches*, which enter the nose through openings in the palate bone, and ramify over the



middle meatus and the middle and inferior spongy bones; and, at its exit from the canal, a palatine branch is distributed to both surfaces of the soft palate.

The *middle* or *external palatine nerve* descends, through one of the accessory palatine canals, distributing branches to the uvula, tonsil, and soft palate. It is occasionally wanting.

The *posterior* or *small palatine nerve* descends with a small artery through the small posterior palatine canal, emerging by a separate opening behind the posterior palatine foramen. It supplies the Levator palati and Azygos uvulæ muscles,\* the soft palate, tonsil, and uvula. The middle and posterior palatine join with the tonsillar branches of the glosso-pharyngeal to form the plexus around the tonsil (*circulus tonsillaris*).

The *internal branches* are distributed to the septum and outer wall of the nasal fossæ. They are the superior nasal (anterior) and the naso-palatine.

The *superior nasal branches* (*anterior*), four or five in number, enter the back part of the nasal fossa by the sphenopalatine foramen. They supply the mucous membrane covering the superior and middle spongy bones, and that lining the posterior ethmoidal cells, a few being prolonged to the upper and back part of the septum. One branch is continued on to the inner surface of the anterior wall of the antrum, and there forms a communication with the anterior dental nerve. At the point of communication a swelling exists, denominated 'the ganglion of Bochdalek,' the nature of which seems to be, however, uncertain.

The *naso-palatine nerve* (*Cotunnii*) also enters the nasal fossa through the sphenopalatine foramen, and passes inwards across the roof of the nose, below the orifice of the sphenoidal sinus, to reach the septum; it then runs obliquely downwards and forwards along the lower part of the septum, to the anterior palatine foramen, lying between the periosteum and mucous membrane. It descends to the roof of the mouth through the anterior palatine canal. The two nerves are here contained in separate and distinct canals, situated in the intermaxillary suture, and termed the foramina of Scarpa, the left nerve being usually anterior to the right one. In the mouth, they become united, supply the mucous membrane behind the incisor teeth, and join with the anterior palatine nerve. The naso-palatine nerve occasionally furnishes a few small filaments to the mucous membrane of the septum.

The *posterior branches* are, the pharyngeal (pterygo-palatine), and the upper posterior nasal branches.

The *pharyngeal nerve* (*pterygo-palatine*) is a small branch arising from the back part of the ganglion, being generally blended with the Vidian nerve. It passes through the pterygo-palatine canal with the pterygo-palatine artery, and is distributed to the mucous membrane of the upper part of the pharynx, behind the Eustachian tube.

The *upper posterior nasal branches* are a few twigs given off from the posterior part of the ganglion, which run backwards in the sheath of the Vidian nerve to the mucous membrane at the back part of the roof, septum, and superior meatus of the nose and that covering the end of the Eustachian tube.

#### INFERIOR MAXILLARY NERVE (fig. 488)

The **Inferior Maxillary Nerve** distributes branches to the teeth and gums of the lower jaw, the integument of the temple and external ear, the lower part of the face and lower lip, and the muscles of mastication: it also supplies the tongue with a large branch. It is the largest of the three divisions of the fifth, and is made up of two roots: a large or sensory root proceeding from the inferior angle of the Gasserian ganglion; and a small or motor root, which passes beneath the ganglion, and unites with the sensory root, just after its exit from the skull through the foramen ovale. Immediately beneath the base of the skull, this

\* It is probable that this is not the true motor supply to these muscles, but that they are supplied by the spinal accessory through the pharyngeal plexus.

nerve divides into two trunks, anterior and posterior. Previous to its division, the primary trunk gives off from its inner side a recurrent (meningeal) branch, and the nerve to the Internal pterygoid muscle.

The **recurrent branch** is given off directly after its exit from the foramen ovale. It passes backwards into the skull through the foramen spinosum with the middle meningeal artery. It divides into two branches, anterior and posterior, which accompany the main divisions of the artery and supply the dura mater. The posterior branch also supplies the mucous lining of the mastoid cells. The anterior branch communicates with the meningeal branch of the superior maxillary nerve.

The **Internal Pterygoid Nerve**, given off from the inferior maxillary, previous to its division, is intimately connected at its origin with the otic ganglion, to which it furnishes a motor root. It is a long and slender branch, which passes inwards to enter the deep surface of the Internal pterygoid muscle.

The *anterior* and smaller division, which receives nearly the whole of the motor root, divides into branches, which supply the muscles of mastication. They are, the masseteric, deep temporal, buccal, and external pterygoid.

The **masseteric branch** passes outwards, above the External pterygoid muscle, in front of the temporo-maxillary articulation, and crosses the sigmoid notch with the masseteric artery, to the Masseter muscle, in which it ramifies nearly as far as its anterior border. It occasionally gives a branch to the Temporal muscle, and a filament to the articulation of the jaw.

The **deep temporal branches**, two in number, anterior and posterior, supply the deep surface of the Temporal muscle. The *posterior branch*, of small size, is placed at the back of the temporal fossa. It is sometimes joined with the masseteric branch. The *anterior branch* is frequently given off from the buccal nerve, it is reflected upwards, at the pterygoid ridge of the sphenoid, to the front of the temporal fossa. Sometimes there are three deep temporal branches, the third branch (*middle deep temporal*) passing outwards over the External pterygoid muscle to enter the deep surface of the Temporal muscle.

The **buccal branch** passes forwards between the two heads of the External pterygoid, and downwards beneath the inner surface of the coronoid process of the lower jaw, or through the fibres of the Temporal muscle, to reach the surface of the Buccinator, upon which it divides into a superior and an inferior branch. It gives a branch to the External pterygoid during its passage through that muscle, and a few ascending filaments to the Temporal muscle, one of which occasionally joins with the anterior branch of the deep temporal nerve. The *upper branch* supplies the integument and upper part of the Buccinator muscle, joining with the facial nerve round the facial vein. The *lower branch* passes forwards to the angle of the mouth; it supplies the integument and Buccinator muscle, as well as the mucous membrane lining the inner surface of that muscle, and joins the facial nerve.\*

The **External Pterygoid Nerve** is most frequently derived from the buccal, but it may be given off separately from the anterior trunk of the nerve. It enters the muscle on its inner surface.

The *posterior* and larger division of the inferior maxillary nerve is for the most part sensory, but receives a few filaments from the motor root. It divides into three branches: auriculo-temporal, lingual (gustatory), and inferior dental.

The **Auriculo-temporal Nerve** generally arises by two roots, between which the middle meningeal artery passes. It runs backwards beneath the External pterygoid muscle to the inner side of the neck of the lower jaw. It then turns upwards with the temporal artery, between the external ear and condyle of the jaw, under cover of the parotid gland, and, escaping from beneath this structure, ascends over the zygoma, and divides into two temporal branches.

\* There seems to be no reason to doubt that the branch supplying the Buccinator muscle is entirely a nerve of ordinary sensation, and that the true motor supply of this muscle is from the facial.



The *branches of communication* are with the facial and with the otic ganglion. The branches of communication with the facial, usually two in number, pass forwards, from behind the neck of the condyle of the jaw, to join this nerve at the posterior border of the Masseter muscle. They form one of the principal branches of communication between the facial and the fifth nerve. The filaments of communication with the otic ganglion are derived from the commencement of the auriculo-temporal nerve.

The *branches of distribution* are :—

Anterior auricular.	Articular.
Branches to the meatus auditorius.	Parotid.
Superficial temporal.	

The *anterior auricular branches* are usually two in number. They supply the front of the upper part of the pinna, being distributed principally to the skin covering the front of the helix and tragus.

*Branches to the meatus auditorius*, two in number, enter the canal between the bony and cartilaginous portion of the meatus. They supply the skin lining the meatus; the upper one sending a filament to the membrana tympani.

A *branch to the temporo-maxillary articulation* is usually derived from the auriculo-temporal nerve.

The *parotid branches* supply the parotid gland.

The *superficial temporal* accompanies the temporal artery to the vertex of the skull, and supplies the integument of the temporal region, communicating with the facial nerve, and the temporal branch of the temporo-malar, from the superior maxillary.

The **Lingual Nerve (gustatory)** supplies the papillæ and mucous membrane of the tongue. It is deeply placed throughout the whole of its course. It lies at first beneath the External pterygoid muscle, together with the inferior dental nerve, being placed to the inner side of the latter nerve, and is occasionally joined to it by a branch which crosses the internal maxillary artery. The chorda tympani also joins it at an acute angle in this situation. The nerve then passes between the Internal pterygoid muscle and the inner side of the ramus of the jaw, and crosses obliquely to the side of the tongue over the Stylo-glossus muscle, and then between the Hyo-glossus muscle and deep part of the submaxillary gland; the nerve lastly runs across Wharton's duct, and along the side of the tongue to its apex, lying immediately beneath the mucous membrane.

The *branches of communication* are with the facial through the chorda tympani, the inferior dental and hypoglossal nerves, and the submaxillary ganglion. The branches to the submaxillary ganglion are two or three in number; those connected with the hypoglossal nerve form a plexus at the anterior margin of the Hyo-glossus muscle.

The *branches of distribution* are few in number. They supply the mucous membrane of the mouth, the gums, the sublingual gland, the filiform and fungiform papillæ and mucous membrane of the tongue; the terminal filaments communicate, at the tip of the tongue, with the hypoglossal nerve.

The **Inferior Dental** is the largest of the three branches of the inferior maxillary nerve. It passes downwards with the inferior dental artery, at first beneath the External pterygoid muscle, and then between the internal lateral ligament and the ramus of the jaw to the dental foramen. It then passes forwards in the dental canal of the inferior maxillary bone, lying beneath the teeth, as far as the mental foramen, where it divides into two terminal branches, incisor and mental.

The branches of the inferior dental are, the mylo-hyoid, dental, incisive and mental.

The *mylo-hyoid* is derived from the inferior dental just as that nerve is about to enter the dental foramen. It descends in a groove on the inner surface of the ramus of the jaw, in which it is retained by a process of fibrous membrane. It reaches the under surface of the Mylo-hyoid muscle, and supplies it and the anterior



belly of the Digastric, occasionally sending one or two filaments to the submaxillary gland.

The *dental branches* supply the molar and bicuspid teeth. They correspond in number to the fangs of those teeth : each nerve entering the orifice at the point of the fang, and supplying the pulp of the tooth.

The *incisive branch* is continued onwards within the bone to the middle line, and supplies the canine and incisor teeth.

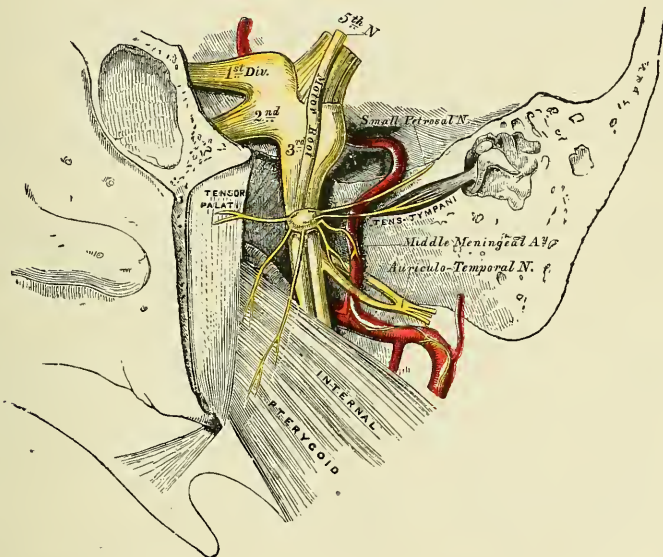
The *mental branch* emerges from the bone at the mental foramen, and divides beneath the Depressor anguli oris into two or three branches ; one descends to supply the skin of the chin, and another (sometimes two) ascends to supply the skin and mucous membrane of the lower lip. These branches communicate freely with the facial nerve.

Two small ganglia are connected with the inferior maxillary nerve : the otic with the trunk of the nerve ; and the submaxillary with its lingual branch.

#### OTIC GANGLION (fig. 490)

The **Otic Ganglion** (*Arnold's*) is a small, oval-shaped, flattened ganglion of a reddish-grey colour, situated immediately below the foramen ovale, on the inner

FIG. 490.—The otic ganglion and its branches.



surface of the inferior maxillary nerve, surrounding the origin of the internal pterygoid nerve. It is in relation, *externally*, with the trunk of the inferior maxillary nerve, at the point where the motor root joins the sensory portion ; *internally*, with the cartilaginous part of the Eustachian tube, and the origin of the Tensor palati muscle ; *behind* it is the middle meningeal artery.

*Branches of communication.*—This ganglion is connected with the internal pterygoid branch of the inferior maxillary nerve, by two or three short, delicate filaments. From this it may obtain a motor root, and possibly also a sensory root, as these filaments from the nerve to the Internal pterygoid may contain sensory fibres. It communicates with the glosso-pharyngeal and facial nerves, through the small superficial petrosal nerve continued from the tympanic plexus, and through this communication it probably receives its sensory root from the glosso-pharyngeal and its motor root from the facial ; its communication with the sympathetic is effected by a filament from the plexus surrounding the middle meningeal artery. The ganglion also communicates with the auriculo-temporal

nerve. This is probably a branch from the glosso-pharyngeal which passes to the ganglion, and through it and the auriculo-temporal nerve to the parotid gland.

Its *branches of distribution* are, a filament to the Tensor tympani, and one to the Tensor palati. The former passes backwards, on the outer side of the Eustachian tube; the latter arises from the ganglion, near the origin of the internal pterygoid nerve, and passes forwards. The fibres of these nerves are, however, mainly derived from the nerve to the Internal pterygoid muscle. It also gives off a small communicating branch to the chorda tympani.

#### SUBMAXILLARY GANGLION (fig. 488)

The **submaxillary ganglion** is of small size, fusiform in shape, and situated above the deep portion of the submaxillary gland, near the posterior border of the Mylo-hyoid muscle, being connected by filaments with the lower border of the lingual (gustatory) nerve.

*Branches of communication.*—This ganglion is connected with the lingual (gustatory) nerve by a few filaments which join it separately, at its fore and back part. It also receives a branch from the chorda tympani, by which it communicates with the facial; and communicates with the sympathetic by filaments from the sympathetic plexus around the facial artery.

*Branches of distribution.*—These are five or six in number; they arise from the lower part of the ganglion, and supply the mucous membrane of the mouth and Wharton's duct, some being lost in the submaxillary gland. The branch of communication from the lingual to the fore part of the ganglion is by some regarded as a branch of distribution, by which filaments of the chorda tympani pass from the ganglion to the nerve, and by it are conveyed to the sublingual gland and the tongue.

*Surface Marking.*—It will be seen from the above description that the three terminal branches of the three divisions of the fifth nerve emerge from foramina in the bones of the skull and face on to the face: the terminal branch of the first division emerging through the supra-orbital foramen; that of the second through the infra-orbital foramen; and the third through the mental foramen. The supra-orbital foramen is situated at the junction of the internal and middle third of the supra-orbital arch between the internal and external angular processes. If a straight line is drawn from this point to the lower border of the inferior maxillary bone, so that it passes between the two bicuspid teeth of the lower jaw, it will pass over the infra-orbital and mental foramina; the former being situated about one centimetre ( $\frac{3}{8}$  of an inch) below the margin of the orbit, and the latter varying in position according to the age of the individual. In the adult it is midway between the upper and lower borders of the inferior maxillary bone; in the child it is nearer the lower border, and in the edentulous jaw of old age it is close to the upper margin.

*Surgical Anatomy.*—The fifth nerve may be affected in its entirety; or its sensory or motor root may be affected; or one of its primary main divisions. In injury to the sensory root there is anæsthesia of the whole of the side of the face on the side of the lesion, with the exception of the skin over the parotid gland; insensibility of the conjunctiva, followed by destructive inflammation of the cornea, partly from loss of trophic influence, and partly from the irritation produced by the presence of foreign bodies on it, which are not perceived by the patient, and therefore not expelled by the act of winking; dryness of the nose, loss to a considerable extent of the sense of taste, and diminished secretion of the lachrymal and salivary glands. In injury to the motor root, there is impaired action of the lower jaw, from paralysis of the muscles of mastication on the affected side.

The fifth nerve is often the seat of neuralgia, and each of the three divisions has been divided, or a portion of the nerve excised, for this affection. The supra-orbital nerve may be exposed by making an incision an inch and a half in length along the supra-orbital margin below the eyebrow, which is to be drawn upwards, the centre of the incision corresponding to the supra-orbital notch. The skin and Orbicularis palpebrarum having been divided, the nerve can be easily found emerging from the notch, and lying in some loose cellular tissue. It should be drawn up by a blunt hook and divided, or, what is better, a portion of it removed. The infra-orbital nerve has been divided at its exit by an incision on the cheek; or the floor of the orbit has been exposed, the infra-orbital canal opened up, and the anterior part of the nerve resected; or the whole nerve, together with Meckel's ganglion as far back as the foramen rotundum, has been removed. This latter



operation, though undoubtedly a severe proceeding, appears to have been followed by the best results. The operation is performed as follows: the superior maxillary bone is first exposed by a T-shaped incision, one limb passing along the lower margin of the orbit, the other from the centre of this vertically down the cheek to the angle of the mouth. The nerve is then found, divided, and a piece of silk tied to it as a guide. A small trephine ( $\frac{1}{2}$ -inch) is then applied to the bone, below, but including the infra-orbital foramen, and the antrum opened. The trephine is now applied to the posterior wall of the antrum, and the sphenomaxillary fossa exposed. The infra-orbital canal is opened up from below by fine cutting-pliers or a chisel, and the nerve drawn down into the trephine hole, it being held on the stretch by means of the piece of silk; it is severed with fine curved scissors as near the foramen rotundum as possible, any branches coming off from the ganglion being also divided.\* The inferior dental nerve has been divided at its exit from the foramen by an incision made through the mucous membrane where it is reflected from the alveolar process on to the lower lip; or a portion of the nerve has been resected by an incision on the cheek through the Masseter muscle, exposing the outer surface of the ramus of the jaw. A trephine was then applied over the position of the inferior dental foramen and the outer table removed, so as to expose the inferior dental canal. The nerve was dissected out of the portion of the canal exposed, and, having been divided after its exit from the mental foramen, it was by traction on the end exposed in the trephine hole, drawn out entire, and cut off as high up as possible.† The inferior dental nerve has also been divided by an incision within the mouth, the bony point guarding the inferior dental foramen forming the guide to the nerve. The buccal nerve may be divided by an incision through the mucous membrane of the mouth and the Buccinator just in front of the anterior border of the ramus of the lower jaw (Stimson).

The lingual (gustatory) nerve is occasionally divided with the view of relieving the pain in cancerous disease of the tongue. This may be done in that part of its course where it lies below and behind the last molar tooth. If a line is drawn from the middle of the crown of the last molar tooth to the angle of the jaw it will cross the nerve, which lies about half an inch behind the tooth, parallel to the bulging alveolar ridge on the inner side of the body of the bone. If the knife is entered three-quarters of an inch behind and below the last molar tooth, and carried down to the bone, the nerve will be divided. Hilton divided it opposite the second molar tooth, where it is covered only by the mucous membrane, and Lucas pulls the tongue forwards and over to the opposite side, when the nerve can be seen standing out as a firm cord under the mucous membrane by the side of the tongue, and can be easily seized with a sharp hook and divided, or a portion excised. This is a simple enough operation on the cadaver, but when the disease is extensive and has extended to the floor of the mouth, as is generally the case when division of the nerve is required, the operation is not practicable.

#### SIXTH NERVE (fig. 486)

The **Sixth** or **Abducent Nerve** supplies the External rectus muscle.

Its *superficial origin* is by several filaments from the constricted part of the pyramid, close to the pons, or from the lower border of the pons itself, in the groove between this body and the medulla. Its *deep origin* is from the floor of the fourth ventricle, close to the median line, beneath the eminentia teres.

The nerve pierces the dura mater on the basilar surface of the sphenoid bone, runs through a notch immediately below the posterior clinoid process, and enters the cavernous sinus. It passes forwards through the sinus, lying on the outer side of the internal carotid artery. It enters the orbit through the sphenoidal fissure, and lies above the ophthalmic vein, from which it is separated by a lamina of dura mater. It then passes between the two heads of the External rectus, and is distributed to that muscle on its ocular surface.

*Branches of communication.*—It is joined by several filaments from the carotid and cavernous plexus, and by one from the ophthalmic nerve.

The above-mentioned nerve, as well as the third, fourth, and the ophthalmic division of the fifth, as they pass to the orbit, bear a certain relation to each other in the cavernous sinus, at the sphenoidal fissure, and in the cavity of the orbit, which will now be described.

In the *cavernous sinus* (fig. 427), the third, fourth, and ophthalmic division of the fifth are placed on the outer wall of the sinus, in their numerical order, both from above downwards, and from within outwards. The sixth nerve lies at the outer side of the internal carotid artery. As these nerves pass forwards to the

\* Camochan, *Amer. Journ. Med. Science*, 1858, p. 136.

† Mears, *Trans. Amer. Surg. Assoc.*, vol. ii. p. 469.

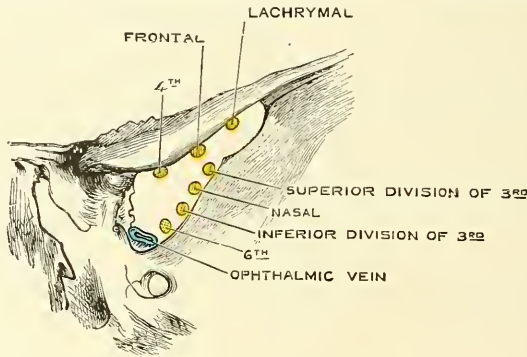


sphenoidal fissure, the third and fifth nerves become divided into branches, and the sixth approaches the rest; so that their relative position becomes considerably changed.

In the *sphenoidal fissure* (fig. 491), the fourth, and the frontal and lachrymal divisions of the ophthalmic lie upon the same plane, the former being most internal, the latter external; and they enter the cavity of the orbit above the muscles. The remaining nerves enter the orbit between the two heads of the External rectus. The superior division of the third is the highest of these; beneath this lies the nasal branch of the ophthalmic; then the inferior division of the third; and the sixth lowest of all.

In the *orbit*, the fourth, and the frontal and lachrymal divisions of the ophthalmic, lie on the same plane immediately beneath the periosteum, the fourth nerve being internal and resting on the Superior oblique, the frontal resting on the Levator palpebræ, and the lachrymal on the External rectus. Next in order comes the superior division of the third nerve lying immediately beneath the Superior rectus, and then the nasal branch of the ophthalmic, crossing the optic nerve from the outer to the inner side of the orbit. Beneath these is found the

FIG. 491.—Relations of structures passing through the sphenoidal fissure.



optic nerve, surrounded in front by the ciliary nerves, and having the lenticular ganglion on its outer side, between it and the External rectus. Below the optic is the inferior division of the third, and the sixth, which lies on the outer side of the orbit.

*Surgical Anatomy.*—The sixth nerve is more frequently involved in fractures of the base of the skull than any other of the cranial nerves. The result of paralysis of this nerve is internal or convergent squint. When injured so that its function is destroyed, there is, in addition to the paralysis of the External rectus muscle, often a certain amount of contraction of the pupil, because some of the sympathetic fibres to the radiating muscle of the iris pass along with this nerve.

#### SEVENTH NERVE (figs. 492, 493, 494)

The **Seventh** or **Facial Nerve** (*portio dura*) is the motor nerve of all the muscles of expression in the face, and of the Platysma and Buccinator; the muscles of the External ear; the posterior belly of the Digastric, and the Stylohyoid. Through its chorda tympani it supplies the Lingualis; by its tympanic branch, the Stapedius.

Its *superficial origin* is from the lateral tract of the medulla oblongata, in the groove between the olivary and restiform bodies. Its *deep origin* is from a nucleus situated in the reticular formation of the lower part of the pons. From this origin the fibres pursue a tortuous course in the substance of the pons. They first pass backwards and inwards, and then turn upwards and forwards forming the funiculus teres, which produces an eminence (*eminencia teres*) on the floor of the fourth ventricle, and finally bend sharply downwards and outwards

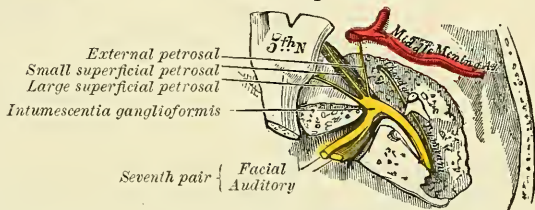
round the upper end of the nucleus of origin of the sixth nerve, to reach their superficial origin between the olivary and restiform bodies.

The auditory nerve (*portio mollis*) lies to its outer side; and between the two is a small fasciculus (*portio inter duram et mollem* of Wrisberg, or *pars intermedia*), which arises from the medulla and joins the facial nerve in the internal auditory meatus. It arises from the upper end of the nucleus of the glossopharyngeal nerve, and at its emergence it is frequently connected with both the nerves, between which it lies.

The facial nerve, firmer, rounder, and smaller than the auditory, passes forwards and outwards upon the middle peduncle of the cerebellum, and enters the internal auditory meatus with the auditory nerve. Within the meatus, the facial nerve lies first to the inner side of the auditory, and then in a groove upon that nerve. The *pars intermedia* is placed between the facial and auditory nerves in the internal auditory meatus, and at the commencement of the geniculate ganglion it joins the facial nerve. Occasionally a few of its fibres pass into the auditory nerve.

At the bottom of the meatus, the facial nerve enters the aqueductus Fallopii, and follows the serpentine course of that canal through the petrous portion of the

FIG. 492.—The course and connections of the facial nerve in the temporal bone.



temporal bone, from its commencement at the internal meatus, to its termination at the stylo-mastoid foramen. It is at first directed backwards and outwards between the cochlea and vestibule towards the inner wall of the tympanum; it then bends suddenly backwards and forms a reddish gangliform swelling (*intumescentia gangliiformis*, or *geniculate ganglion*), and from this arches downwards behind the tympanum to the stylo-mastoid foramen. On emerging from this aperture, it runs forwards in the substance of the parotid gland, crosses the external carotid artery, and divides behind the ramus of the lower jaw into two primary branches, *temporo-facial* and *cervico-facial*, from which numerous offsets are distributed over the side of the head, face, and upper part of the neck supplying the superficial muscles in these regions. As the primary branches and their offsets diverge from each other, they present somewhat the appearance of a bird's claw; hence the name of *pes anserinus* is given to the divisions of the facial nerve in and near the parotid gland.

The communications of the facial nerve may be thus arranged:—

In the internal auditory meatus . . . . .	With the auditory nerve.
In the aqueductus Fallopii . . . . .	With Meckel's ganglion by the large superficial petrosal nerve.
	With the otic ganglion by the small superficial petrosal nerve.
	With the sympathetic on the middle meningeal by the external superficial petrosal nerve.
At its exit from the stylo-mastoid foramen . . . . .	With the glossal-pharyngeal.
	„ pneumogastric.
	„ carotid plexus.
	„ auricularis magnus.
On the face . . . . .	„ auriculo-temporal.
	With the three divisions of the fifth.

In the internal auditory meatus some minute filaments pass between the facial and auditory nerves.

Opposite the hiatus Fallopii, the gangliform enlargement on the facial nerve

communicates with Meckel's ganglion by means of the large superficial petrosal nerve, which forms its motor root; with the otic ganglion, by the small superficial petrosal nerve: and with the sympathetic filaments accompanying the middle meningeal artery, by the external petrosal (Bidder). From the gangliform enlargement, according to Arnold, a twig is sent back to the auditory nerve.

At its exit from the stylo-mastoid foramen, it sends a twig to the glosso-pharyngeal, another to the pneumogastric nerve, and communicates with the carotid plexus of the sympathetic, with the great auricular branch of the cervical plexus, with the auriculo-temporal branch of the inferior maxillary nerve in the parotid gland, and on the face with the terminal branches of the three divisions of the fifth.

#### BRANCHES OF DISTRIBUTION

Within the aqueductus Fallopii . . . . .	}	Tympanic. Chorda Tympani.	}	
At its exit from the stylo-mastoid foramen . . . . .				
On the face . . . . .	}	Temporo-facial	}	Temporal.
				Cervico-facial

The **tympanic branch** arises from the nerve opposite the pyramid; it passes through a small canal in the pyramid, and supplies the Stapedius muscle.

The **chorda tympani** is given off from the facial as it passes vertically downwards at the back of the tympanum, about a quarter of an inch before its exit from the stylo-mastoid foramen. It passes from below upwards and forwards in a distinct canal, and enters the cavity of the tympanum, through an aperture (*iter chorda posterior*) on its posterior wall between the opening of the mastoid cells and the attachment of the membrana tympani, and becomes invested with mucous membrane. It passes forwards through the cavity of the tympanum, between the fibrous and mucous layers of the membrana tympani, to its anterior inferior angle, and emerges from that cavity through a foramen at the inner end of the Glaserian fissure, which is called the *iter chorda anterior*, or *canal of Huguier*. It then descends between the two Pterygoid muscles, meets the lingual nerve at an acute angle, and accompanies it to the submaxillary gland; part of it then joins the submaxillary ganglion; the rest is continued onwards into the tongue. A few of its fibres probably pass through the submaxillary ganglion to the sublingual gland. Before joining the lingual nerve it receives a small communicating branch from the otic ganglion.

The **Posterior auricular nerve** arises close to the stylo-mastoid foramen, and passes upwards in front of the mastoid process, where it is joined by a filament from the auricular branch of the pneumogastric, and communicates with the mastoid branch of the auricularis magnus and with the small occipital. As it ascends between the meatus and mastoid process it divides into two branches. The *auricular branch* supplies the Retrahens aurem and the small muscles on the cranial surface of the pinna. The *occipital branch*, the larger, passes backwards along the superior curved line of the occipital bone, and supplies the occipital portion of the Occipito-frontalis.

The **digastric branch** usually arises by a common trunk with the Stylo-hyoid branch; it divides into several filaments, which supply the posterior belly of the Digastric; one of these perforates that muscle to join the glosso-pharyngeal nerve.

The **stylo-hyoid** is a long slender branch, which passes inwards, entering the

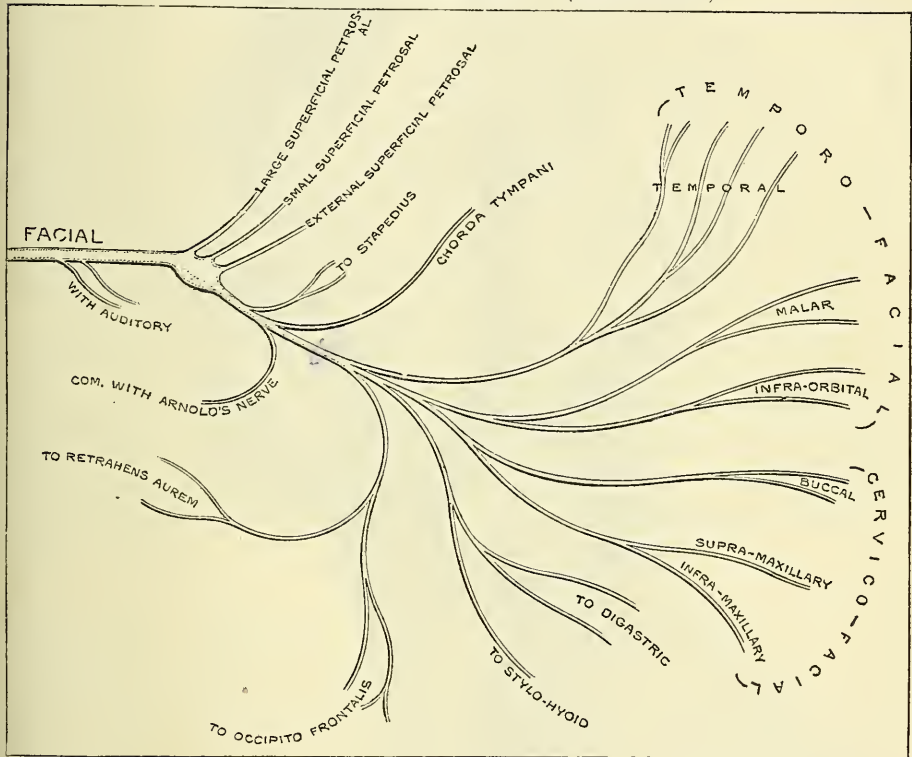


Stylo-hyoid muscle about its middle; it communicates with the sympathetic filaments on the external carotid artery.

The **Temporo-facial**, the larger of the two terminal branches, passes upwards and forwards through the parotid gland, crosses the external carotid artery and temporo-maxillary vein, and passes over the neck of the condyle of the jaw, being connected in this situation with the auriculo-temporal branch of the inferior maxillary nerve, and divides into branches, which are distributed over the temple and upper part of the face; these are divided into three sets: temporal, malar, and infra-orbital.

The *temporal branches* cross the zygoma to the temporal region, supplying the *Retrahens* and *Attollens aurem* muscles, and join with the temporal branch of the temporo-maxillary, a branch of the superior maxillary, and with the auriculo-temporal branch of the inferior maxillary. The more anterior branches supply the

FIG. 493.—Plan of the facial nerve. (After Flower.)



frontal portion of the Occipito-frontalis, the Orbicularis palpebrarum, and Corrugator supercillii muscles, joining with the supra-orbital and lachrymal branches of the ophthalmic.

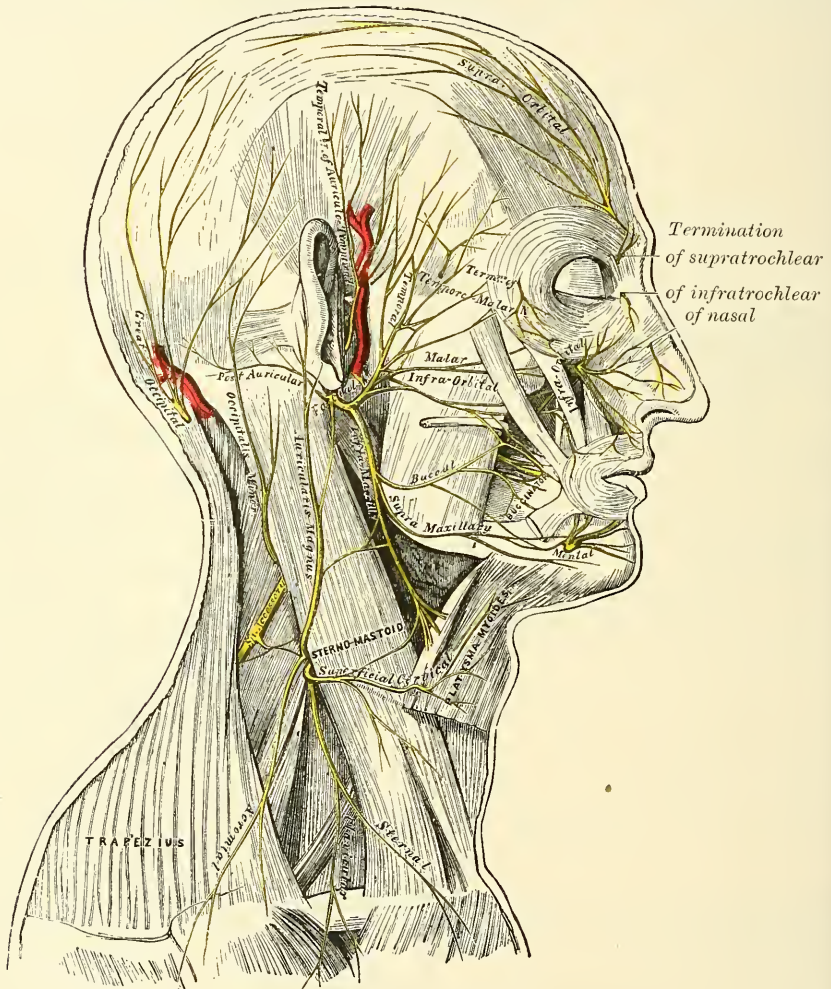
The *malar branches* pass across the malar bone to the outer angle of the orbit, where they supply the Orbicularis palpebrarum muscle, joining with filaments from the lachrymal nerve; others supply the lower eyelid, joining with filaments of the malar branch (*subcutaneous malæ*) of the superior maxillary nerve.

The *infra-orbital*, of larger size than the rest, pass horizontally forwards to be distributed between the lower margin of the orbit and the mouth. The *superficial branches* run beneath the skin and above the superficial muscles of the face which they supply: some branches are distributed to the Pyramidalis nasi, joining at the inner angle of the orbit with the infratrochlear and nasal branches of the ophthalmic. The *deep branches* pass beneath the Zygomatici and the Levator labii superioris, supplying them and the Levator anguli oris, and form a plexus (*infra-*

*orbital*) by joining with the infra-orbital branch of the superior maxillary nerve and the buccal branches of the cervico-facial. This branch also supplies the Levator labii superioris alæque nasi and the small muscles of the nose.

The **Cervico-facial division of the facial nerve** passes obliquely downwards and forwards through the parotid gland, crossing the external carotid artery. In this situation it is joined by branches from the great auricular nerve. Opposite the angle of the lower jaw it divides into branches which are distributed on the lower half of the face and upper part of the neck. These may be divided into three sets: buccal, supramaxillary, and inframaxillary.

FIG. 494.—The nerves of the scalp, face, and side of the neck.



The *buccal branches* cross the Masseter muscle. They supply the Buccinator and Orbicularis oris, and join with the infra-orbital branches of the temporo-facial division of the nerve, and with filaments of the buccal branch of the inferior maxillary nerve.

The *supramaxillary (mandibular) branches* pass forwards beneath the Platysma and Depressor anguli oris, supplying the muscles of the lower lip and chin, and communicating with the mental branch of the inferior dental nerve.

The *inframaxillary (cervical) branches* run forward beneath the Platysma, and form a series of arches across the side of the neck over the suprahyoid region.



One of these branches descends vertically to join with the superficialis colli nerve from the cervical plexus; others supply the Platysma.

*Surgical Anatomy.*—The facial nerve is more frequently paralysed than any of the other of the cranial nerves. The paralysis may depend either upon (1) central causes, i.e. blood clots or intracranial tumours pressing on the nerve before its entrance into the internal auditory meatus. It is also one of the nerves involved in 'bulbar paralysis.' Or (2) it may be paralysed in its passage through the petrous bone, by damage due to middle ear disease, or by fractures of the base. Or (3) it may be affected at or after its exit from the stylo-mastoid foramen. This is commonly known as 'Bell's paralysis.' It may be due to exposure to cold or to injury of the nerve, either from accidental wounds of the face, or during some surgical operation, as removal of parotid tumours, opening of abscesses, or operations on the lower jaw.

When the cause is central, the sixth nerve is usually also paralysed, and there is hemiplegia on the opposite side. In these cases the electrical reactions are the same as in health; whereas, when the paralysis is in the course of the nerve, the reaction is usually lost. When the nerve is paralysed in the petrous bone, in addition to the paralysis of the muscles of expression, there is loss of taste in the anterior part of the tongue, and the patient is unable to recognise the difference between bitters and sweets, acids and salines, from involvement of the chorda tympani. The mouth is dry, because the salivary glands are not secreting; and the sense of hearing is affected from paralysis of the Stapedius. When the cause of the paralysis is from fracture of the base of the skull, the auditory nerve and the petrosal nerves, which are connected with the intumescencia gangliiformis, are also involved. When the injury is after the exit of the nerve from the stylo-mastoid foramen, all the muscles of expression, except the Levator palpebræ, together with the posterior belly of the Digastric and Stylo-hyoid, are paralysed. There is smoothness of the forehead, and the patient is unable to frown; the eyelids cannot be closed and the lower lid droops, so that the punctum is no longer in contact with the globe, and the tears run down the cheek; there is smoothness of the cheek and loss of the naso-labial furrow; the nostril cannot be dilated; the mouth is drawn to the sound side, and there is inability to whistle; food collects between the cheek and gum from paralysis of the Buccinator. The facial nerve is at fault in cases of so-called 'histrionic spasm,' which consists in an almost constant and uncontrollable twitching of the muscles of the face. This twitching is sometimes so severe as to cause great discomfort and annoyance to the patient, and to interfere with sleep, and for its relief the facial nerve has been stretched. The operation is performed by making an incision behind the ear, from the root of the mastoid process to the angle of the jaw. The parotid is turned forwards and the dissection carried along the anterior border of the Sterno-mastoid muscle and mastoid process, until the upper border of the posterior belly of the Digastric is found. The nerve is parallel to this on about a level of the middle of the mastoid process. When found, the nerve must be stretched by passing a blunt hook beneath it and pulling it forwards and outwards. Too great force must not be used, for fear of permanent injury to the nerve.

#### EIGHTH NERVE

The **Eighth** or **Auditory Nerve** (*portio mollis*) is the special nerve of the sense of hearing, being distributed exclusively to the internal ear.

Its *superficial origin* is from the groove between the olivary and restiform bodies at the lower border of the pons. It lies external to the facial nerve. Its *deep origin* is by two roots, mesial and lateral, which embrace the restiform body. The lateral or posterior root arises partly from the tuberculum acusticum on the floor of the fourth ventricle, is partly continued into the striæ medullaris, and partly also arises from the accessory auditory nucleus, a group of cells placed in front of the restiform body in the angular interspace between the two roots. This root is believed to be connected with the cochlear nerve, and is the true nerve of hearing. The mesial or anterior root arises from a collection of cells, the dorsal auditory nucleus, corresponding to the trigonum acustici in the floor of the fourth ventricle to the inner side of the restiform body. This root is supposed to be connected with the vestibular nerve, and to be concerned in the maintenance of equilibrium.

The auditory nerve after leaving the medulla passes forwards across the posterior border of the middle peduncle of the cerebellum, in company with the facial nerve, from which it is partially separated by a small artery (auditory). It then enters the internal auditory meatus with the facial nerve. At the bottom of the meatus it receives one or two filaments from the facial nerve, and then divides



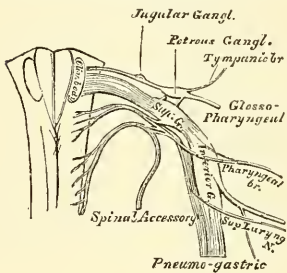
into two branches, *cochlear* and *vestibular*, which are distributed, the former to the cochlear, the latter to the vestibule and semicircular canals. The auditory nerve is soft in texture (hence the name *portio mollis*), and is destitute of neurilemma. The distribution of the auditory nerve in the internal ear will be found described along with the anatomy of that organ in a subsequent page.

*Surgical Anatomy.*—The auditory nerve is frequently injured, together with the facial nerve, in fractures of the middle fossa of the base of the skull implicating the internal auditory meatus. The nerve may be either torn across, producing permanent deafness, or it may be bruised or pressed upon by extravasated blood or inflammatory exudation, when the deafness will in all probability be temporary. The nerve may also be injured by violent blows on the head without fracture, and deafness may arise from loud explosions from dynamite, etc., probably from some lesion of this nerve, which is more liable to be injured than the other cranial nerves on account of its structure. The test that the nerve is destroyed, and that the deafness is not due to some lesion of the auditory apparatus, is obtained by placing a vibrating tuning-fork on the head. The vibrations will be heard in cases where the auditory apparatus is at fault, but not in cases of destruction of the auditory nerve.

#### NINTH PAIR (figs. 495, 496, 497)

The **Ninth or Glosso-pharyngeal Nerve** (figs. 495, 496, 497) is distributed, as its name implies, to the tongue and pharynx, being the nerve of sensation to the mucous membrane of the pharynx, fauces, and tonsil; and a special nerve of taste to all the parts of the tongue to which it is distributed.

FIG. 495.—Origin, ganglia, and communications of the eighth, ninth and tenth cranial nerves.



Its *superficial origin* is by three or four filaments closely connected together, from the upper part of the medulla oblongata, in the groove between the olivary and the restiform body.

Its *deep origin* may be traced through the fasciculi of the lateral tract, to three different sources, (1) some of the fibres may be traced to a nucleus of grey matter at the lower part of the floor of the fourth ventricle beneath the inferior fovea; these are regarded as the fibres conducting the special sense of taste.

(2) Others may be traced downwards into the *funiculus solitarius*, a rounded bundle of fibres in the lower part of the medulla, commencing immediately above the decussation of the pyramids. These fibres have not yet been distinctly traced to cells: they are probably efferent. (3) A third set of fibres pass forward to a collection of cells, the *nucleus ambiguus*, which is directly continuous with the nucleus of the vagus.

From its superficial origin, it passes outwards across the flocculus, and leaves the skull at the central part of the jugular foramen, in a separate sheath of the dura mater, in front of the pneumogastric and spinal accessory nerves (fig. 429). In its passage through the jugular foramen, it grooves the lower border of the petrous portion of the temporal bone; and, at its exit from the skull, passes forwards between the jugular vein and internal carotid artery, and descends in front of the latter vessel, and beneath the styloid process and the muscles connected with it, to the lower border of the Stylo-pharyngeus. The nerve now curves inwards, forming an arch on the side of the neck and lying upon the Stylo-pharyngeus and Middle constrictor of the pharynx, above the superior laryngeal nerve. It then passes beneath the Hyo-glossus, and is finally distributed to the mucous membrane of the fauces and base of the tongue, and the mucous glands of the mouth and tonsil.

In passing through the jugular foramen, the nerve presents, in succession, two gangliiform enlargements. The superior, the smaller, is called the *jugular ganglion*; the inferior and larger, the *petrous ganglion*, or the *ganglion of Andersch*.

The **superior, or jugular, ganglion** is situated in the upper part of the groove in which the nerve is lodged during its passage through the jugular foramen. It is of very small size, and involves only the lower part of the trunk of the nerve. It is usually regarded as a segmentation from the lower ganglion.

The **inferior, or petrous, ganglion** is situated in a depression in the lower border of the petrous portion of the temporal bone; it is larger than the former, and involves the whole of the fibres of the nerve. From this ganglion arise those filaments which connect the glosso-pharyngeal with the pneumogastric and sympathetic nerves.

The *branches of communication* are with the pneumogastric, sympathetic and facial.

The branches to the pneumogastric are two filaments, arising from the petrous ganglion, one to its auricular branch, and one to the upper ganglion of the pneumogastric.

The branch to the sympathetic, also arising from the petrous ganglion, is connected with the superior cervical ganglion.

The branch of communication with the facial perforates the posterior belly of the Digastric. It rises from the trunk of the nerve below the petrous ganglion, and joins the facial just after its exit from the stylo-mastoid foramen.

The *branches of distribution* are, the tympanic, carotid, pharyngeal, muscular, tonsillar, and lingual.

The **tympanic branch** (*Jacobson's nerve*) arises from the petrous ganglion, and enters a small bony canal in the lower surface of the petrous portion of the temporal bone; the lower opening of which is situated on the bony ridge which separates the carotid canal from the jugular fossa. It ascends to the tympanum, enters that cavity by an aperture in its floor close to the inner wall, and divides into branches, which are contained in grooves upon the surface of the promontory, forming the tympanic plexus. This will be described in connection with the anatomy of the ear.

The **carotid branches** descend along the trunk of the internal carotid artery as far as its commencement, communicating with the pharyngeal branch of the pneumogastric, and with branches of the sympathetic.

The **pharyngeal branches** are three or four filaments which unite opposite the Middle constrictor of the pharynx with the pharyngeal branches of the pneumogastric, the external laryngeal, and sympathetic nerves, to form the pharyngeal plexus, branches from which perforate the muscular coat of the pharynx to supply the muscles and mucous membrane.

The **muscular branch** is distributed to the Stylo-pharyngeus.

The **tonsillar branches** supply the tonsil, forming a plexus (*circulus tonsillaris*) around this body, from which branches are distributed to the soft palate and fauces, where they communicate with the palatine nerves.

The **lingual branches** are two in number: one supplies the circumvallate papillæ and the mucous membrane covering the surface of the base of the tongue; the other perforates its substance, and supplies the mucous membrane and follicular glands of the tongue and anterior surface of the epiglottis.

#### TENTH PAIR (figs. 496, 497)

The **Tenth or Pneumogastric Nerve** (*nervus vagus* or *par vagum*) has a more extensive distribution than any of the other cranial nerves, passing through the neck and thorax to the upper part of the abdomen. It is composed of both motor and sensory fibres. It supplies the organs of voice and respiration with motor and sensory fibres; and the pharynx, œsophagus, stomach, and heart with motor fibres.

Its *superficial origin* is by eight or ten filaments from the groove between the olivary and the restiform body below the glosso-pharyngeal; its *deep origin* may

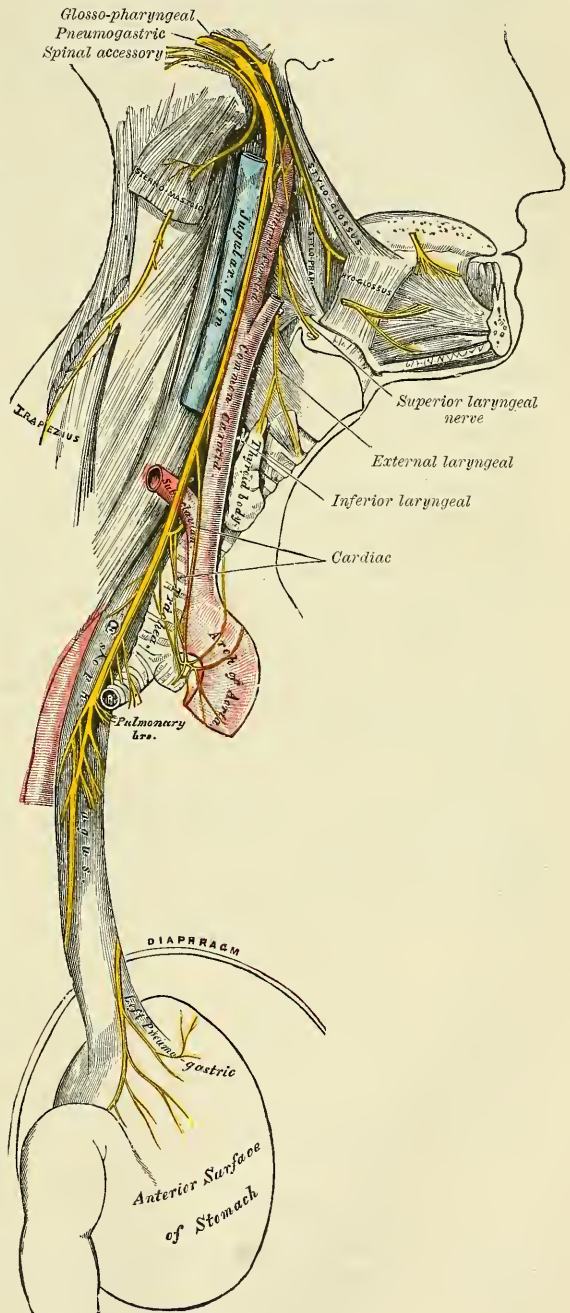




be traced through the fasciculi of the medulla, to terminate in a nucleus of grey matter, the nucleus vagus, at the lower part of the floor of the fourth ventricle, beneath the ala cinerea, below and continuous with the nucleus of origin of the glosso-pharyngeal. In addition to this a few fibres pass into the funiculus solitarius, and others into the nucleus ambiguus or accessory vagal nucleus.

The filaments become united, and form a flat cord, which passes outwards beneath the flocculus to the jugular foramen, through which it emerges from the cranium. In passing through this opening, the pneumogastric accompanies the spinal accessory, being contained in the same sheath of dura mater with it, a membranous septum separating it from the glosso-pharyngeal, which lies in front (fig. 429). The nerve in this situation presents a well-marked ganglionic enlargement, which is called *jugular ganglion*, or the *ganglion of the root of the pneumogastric*: to it the accessory part of the spinal accessory nerve is connected by one or two filaments. After the exit of the nerve from the jugular foramen, the nerve is joined by the accessory portion of the spinal accessory, and enlarges into a second gangliform swelling, called the *ganglion inferius* or the *ganglion of the trunk of the nerve*; through which the fibres of the spinal accessory pass unchanged, being principally distributed to the pharyngeal and superior laryngeal branches of the vagus, but some of the filaments from it are continued into the trunk of the vagus below the ganglion, to be distributed with the recurrent laryngeal nerve and probably also with the cardiac nerves. The nerve passes vertically down the neck within the sheath of the carotid vessels lying between the internal carotid artery and internal jugular vein as far as the thyroid cartilage, and then between the same vein and the common carotid to

FIG. 497.—Course and distribution of the eighth, ninth and tenth cranial nerves.



the root of the neck. Here the course of the nerve becomes different on the two sides of the body.

On the *right side*, the nerve passes across the subclavian artery between it and the right innominate vein, and descends by the side of the trachea to the back part of the root of the lung, where it spreads out in a plexiform network (*posterior pulmonary*), from the lower part of which two cords descend upon the œsophagus, on which they divide, forming, with branches from the opposite nerve, the œsophageal plexus (*plexus gulæ*); below, these branches are collected into a single cord, which runs along the back part of the œsophagus, enters the abdomen, and is distributed to the posterior surface of the stomach, joining the left side of the solar plexus, and sending filaments to the splenic plexus and a considerable branch to the cœliac plexus.

On the *left side*, the pneumogastric nerve enters the chest between the left carotid and subclavian arteries, behind the left innominate vein. It crosses the arch of the aorta, and descends behind the root of the left lung, forming the *posterior pulmonary plexus*, and along the anterior surface of the œsophagus, where it unites with the nerve of the right side in forming the *plexus gulæ*, to the stomach, distributing branches over its anterior surface, some extending over the great *cul-de-sac*, and others along the lesser curvature. Filaments from these branches enter the gastro-hepatic omentum, and join the hepatic plexus.

The *ganglion of the root* is of a greyish colour, circular in form, about two lines in diameter, and resembles the ganglion on the large root of the fifth nerve.

*Connecting branches*.—To this ganglion the accessory portion of the spinal accessory nerve is connected by several delicate filaments; it also has a communicating twig with the petrous ganglion of the glosso-pharyngeal, with the facial nerve by means of its auricular branch, and with the sympathetic by means of an ascending filament from the superior cervical ganglion.

The *ganglion of the trunk* (inferior) is a plexiform cord, cylindrical in form, of a reddish colour, and about an inch in length; it involves the whole of the fibres of the nerve, and passing through it is the accessory portion of the spinal accessory nerve, which blends with the pneumogastric below the ganglion, and is then principally continued into its pharyngeal and superior laryngeal branches.

*Connecting branches*.—This ganglion is connected with the hypoglossal, the superior cervical ganglion of the sympathetic, and the loop between the first and second cervical nerves.

The *branches of the pneumogastric* are—

In the jugular fossa . . . . .	{ Meningeal.
	{ Auricular.
In the neck . . . . .	{ Pharyngeal.
	{ Superior laryngeal.
	{ Recurrent laryngeal.
	{ Cervical cardiac.
In the thorax . . . . .	{ Thoracic cardiac.
	{ Anterior pulmonary.
	{ Posterior pulmonary.
	{ Œsophageal.
In the abdomen . . . . .	{ Gastric.

The **meningeal branch** is a recurrent branch given off from the ganglion of the root in the jugular foramen. It passes backwards, and is distributed to the dura mater covering the posterior fossa of the base of the skull.

The **auricular branch** (*Arnold's*) arises from the ganglion of the root, and is joined soon after its origin by a filament from the petrous ganglion of the glosso-pharyngeal; it passes outwards behind the jugular vein, and enters a small

canal on the outer wall of the jugular fossa. Traversing the substance of the temporal bone, it crosses the aqueductus Fallopii about two lines above its termination at the stylo-mastoid foramen; here it gives off an ascending branch, which joins the facial: the continuation of the nerve reaches the surface by passing through the auricular fissure between the mastoid process and the external auditory meatus, and divides into two branches, one of which communicates with the posterior auricular nerve, while the other supplies the integument at the back part of the pinna and the posterior part of the external auditory meatus.

The **pharyngeal branch**, the principal motor nerve of the pharynx, arises from the upper part of the inferior ganglion of the pneumogastric. It consists principally of filaments from the accessory portion of the spinal accessory; it passes across the internal carotid artery (in front or behind), to the upper border of the Middle constrictor, where it divides into numerous filaments, which join with those from the glosso-pharyngeal, superior laryngeal (its external branch), and sympathetic, to form the pharyngeal plexus, from which branches are distributed to the muscles and mucous membrane of the pharynx and the muscles of the soft palate. From the pharyngeal plexus a minute filament is given off, which descends and joins the hypoglossal nerve as it winds round the occipital artery.

The **superior laryngeal** is the nerve of sensation to the larynx. It is larger than the preceding, and arises from the middle of the inferior ganglion of the pneumogastric. It consists principally of filaments from the accessory portion of the spinal accessory. In its course it receives a branch from the superior cervical ganglion of the sympathetic. It descends, by the side of the pharynx, behind the internal carotid, where it divides into two branches, the external and internal laryngeal.

The *external laryngeal branch*, the smaller, descends by the side of the larynx, beneath the Sterno-thyroid, to supply the Crico-thyroid muscle. It gives branches to the pharyngeal plexus and the Inferior constrictor, and communicates with the superior cardiac nerve, behind the common carotid.

The *internal laryngeal branch* descends to the opening in the thyro-hyoid membrane, through which it passes with the superior laryngeal artery, and is distributed to the mucous membrane of the larynx. A small branch communicates with the recurrent laryngeal nerve. The branches to the mucous membrane are distributed, some in front to the epiglottis, the base of the tongue, and the epiglottidean glands; while others pass backwards, in the aryteno-epiglottidean fold, to supply the mucous membrane surrounding the superior orifice of the larynx, as well as the membrane which lines the cavity of the larynx as low down as the vocal cord. The filament which joins with the recurrent laryngeal descends beneath the mucous membrane on the inner surface of the thyroid cartilage, where the two nerves become united.

The **inferior or recurrent laryngeal**, so called from its reflected course, is the motor nerve of the larynx. It arises on the right side, in front of the subclavian artery; winds from before backwards round that vessel, and ascends obliquely to the side of the trachea, behind the common carotid and inferior thyroid arteries. On the left side, it arises in front of the arch of the aorta, and winds from before backwards round the aorta at the point where the remains of the ductus arteriosus are connected with it, and then ascends to the side of the trachea. The nerves on both sides ascend in the groove between the trachea and œsophagus, and, passing under the lower border of the Inferior constrictor muscle, enter the larynx behind the articulation of the inferior cornu of the thyroid cartilage with the cricoid, being distributed to all the muscles of the larynx, excepting the Crico-thyroid. It communicates with the superior laryngeal nerve.

The recurrent laryngeal, as it winds round the subclavian artery and aorta, gives off several cardiac filaments, which unite with the cardiac branches from the pneumogastric and sympathetic. As it ascends in the neck it gives off œsophageal



branches, more numerous on the left than on the right side, which supply the mucous membrane and muscular coat of the œsophagus; tracheal branches to the mucous membrane and muscular fibres of the trachea; and some pharyngeal filaments to the Inferior constrictor of the pharynx.

The **cervical cardiac branches**, two or three in number, arise from the pneumogastric, at the upper and lower part of the neck.

The *superior branches* are small, and communicate with the cardiac branches of the sympathetic. They can be traced to the great or deep cardiac plexus.

The *inferior branches*, one on each side, arise at the lower part of the neck, just above the first rib. On the right side, this branch passes in front or by the side of the arteria innominata, and communicates with one of the cardiac nerves proceeding to the great or deep cardiac plexus. On the left side, it passes in front of the arch of the aorta, and joins the superficial cardiac plexus.

The **thoracic cardiac branches**, on the right side, arise from the trunk of the pneumogastric, as it lies by the side of the trachea, and from its recurrent laryngeal branch; but on the left side from the recurrent nerve only; passing inwards, they terminate in the deep cardiac plexus.

The **anterior pulmonary branches**, two or three in number, and of small size, are distributed on the anterior aspect of the root of the lungs. They join with filaments from the sympathetic, and form the *anterior pulmonary plexus*.

The **posterior pulmonary branches**, more numerous and larger than the anterior, are distributed on the posterior aspect of the root of the lung: they are joined by filaments from the third and fourth (sometimes also first and second) thoracic ganglia of the sympathetic, and form the *posterior pulmonary plexus*. Branches from both plexuses accompany the ramifications of the air-tubes through the substance of the lungs.

The **œsophageal branches** are given off from the pneumogastric both above and below the pulmonary branches. The lower are more numerous and larger than the upper. They form, together with branches from the opposite nerve, the *œsophageal plexus* or *plexus gulæ*. From this plexus branches are distributed to the back of the pericardium.

The **gastric branches** are the terminal filaments of the pneumogastric nerve. The nerve on the right side is distributed to the posterior surface of the stomach, and joins the left side of the cœliac plexus and the splenic plexus. The nerve on the left side is distributed over the anterior surface of the stomach, some filaments passing across the great *cul-de-sac*, and others along the lesser curvature. They unite with branches of the right nerve and with the sympathetic, some filaments passing through the lesser omentum to the hepatic plexus.

*Surgical Anatomy.*—The laryngeal nerves are of considerable importance in considering some of the morbid conditions of the larynx. When the peripheral terminations of the superior laryngeal nerve are irritated by some foreign body passing over them, reflex spasm of the glottis is the result. When the trunk of this same nerve is pressed upon, by, for instance, a goitre or an aneurism of the upper part of the carotid, we have a peculiar dry, brassy cough. When the nerve is paralysed, we have anæsthesia of the mucous membrane of the larynx, so that foreign bodies can readily enter the cavity, and, in consequence of its supplying the Crico-thyroid muscle, the vocal cords cannot be made tense, and the voice is deep and hoarse. Paralysis of the superior laryngeal nerves may be the result of bulbar paralysis; may be a sequel to diphtheria when both nerves are usually involved; or it may, though less commonly, be caused by the pressure of tumours or aneurisms, when the paralysis is generally unilateral. Irritation of the inferior laryngeal nerves produces spasm of the muscles of the larynx. When both these recurrent nerves are paralysed, the vocal cords are motionless, in the so-called ‘cadaveric position’—that is to say, in the position in which they are found in ordinary tranquil respiration; neither closed as in phonation, nor open as in deep inspiratory efforts. When one recurrent nerve is paralysed, the cord of the same side is motionless, while the opposite one crosses the middle line to accommodate itself to the affected one; hence phonation is present, but the voice is altered and weak in timbre. The recurrent laryngeal nerves may be paralysed in bulbar paralysis or after diphtheria, when it usually affects both sides; or they may be affected by the pressure of aneurisms of the aorta, innominate or subclavian arteries; by mediastinal tumours; by bronchocele; or by cancer of the upper part of the œsophagus, when the paralysis is often unilateral.

## ELEVENTH PAIR (figs. 496, 497)

The **Eleventh** or **Spinal Accessory Nerve** consists of two parts: one, the accessory part to the vagus, and the other the spinal portion.

The **bulbar** or **accessory part** is the smaller of the two. Its *superficial origin* is by four or five delicate filaments from the side of the medulla, below the roots of the vagus. Its *deep origin* may be traced to a nucleus of grey matter at the back of the medulla, extending from the level of the top of the calamus scriptorius as far down as the intermedio-lateral tract of the spinal cord. It passes outwards to the jugular foramen, where it joins with the spinal portion and with the upper ganglion of the vagus by one or two filaments: and is then continued over the surface of this ganglion to join the trunk of the vagus, after its exit from the jugular foramen. The fibres of the accessory part then pass unchanged through the inferior ganglion, or ganglion of the trunk of the vagus, to be distributed principally to the pharyngeal and superior laryngeal branches of the pneumogastric. Through the pharyngeal branch it probably supplies the muscles of the soft palate (see page 422). Some few filaments from it are continued into the trunk of the vagus below the ganglion, to be distributed with the recurrent laryngeal nerve and probably also with the cardiac nerves.

The **spinal portion** is firm in texture. Its *superficial origin* is by several filaments from the lateral tract of the cord, as low down as the sixth cervical nerve. Its *deep origin* may be traced to the intermedio-lateral tract of the grey matter of the cord. This portion of the nerve ascends between the ligamentum denticulatum and the posterior roots of the spinal nerves, enters the skull through the foramen magnum, and is then directed outwards to the jugular foramen, through which it passes, lying in the same sheath as the pneumogastric, but separated from it by a fold of the arachnoid. In the jugular foramen, it receives one or two filaments from the accessory portion. At its exit from the jugular foramen, it passes backwards, either in front of or behind the internal jugular vein, and descends obliquely behind the Digastric and Stylo-hyoid muscles to the upper part of the Sterno-mastoid. It pierces that muscle, and passes obliquely across the occipital triangle, to terminate in the deep surface of the Trapezius. This nerve gives several branches to the Sterno-mastoid during its passage through it, and joins in its substance with branches from the second cervical, which supply the muscle. In the occipital triangle it joins with the second and third cervical nerves and assists in the formation of the cervical plexus. Beneath the Trapezius it joins with the third and fourth cervical nerves to form a sort of plexus, from which fibres are distributed to the muscle.

*Surgical Anatomy.*—In cases of spasmodic torticollis in which all previous palliative treatment has failed, and the spasms are so severe as to undermine the patient's health, division or excision of a portion of the spinal accessory nerve has been resorted to. This may be done either along the anterior or posterior border of the Sterno-mastoid muscle. The former operation is performed by making an incision from the apex of the mastoid process, three inches in length, along the anterior border of the Sterno-mastoid muscle. The anterior border of the muscle is defined and pulled backwards, so as to stretch the nerve, which is then to be sought for, beneath the Digastric muscle, about two inches below the apex of the mastoid process. The other operation consists in making an incision along the posterior border of the muscle, so that the centre of the incision corresponds to the middle of this border of the muscle. The superficial structures having been divided and the border of the muscle defined, the nerve is to be sought for as it emerges from the muscle to cross the occipital triangle. When found, it is to be traced upwards through the muscle, and a portion of it excised above the point where it gives off its branches to the Sterno-mastoid. In this operation one of the descending branches of the superficial cervical plexus is liable to be mistaken for the nerve.

## TWELFTH PAIR (figs. 497, 498)

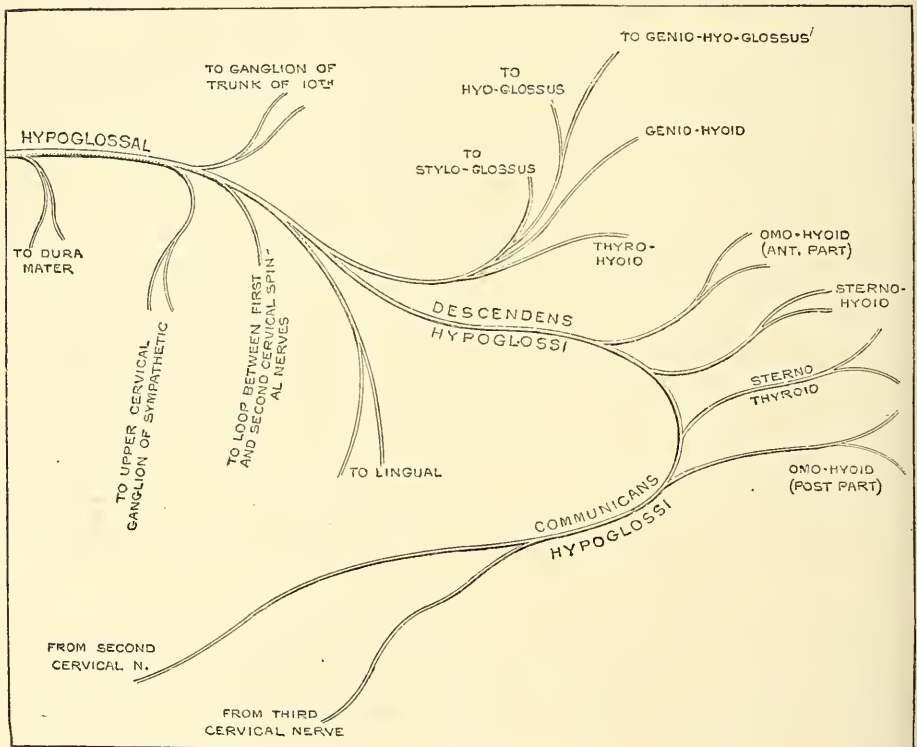
The **Twelfth** or **Hypoglossal Nerve** is the motor nerve of the tongue.

Its *superficial origin* is by several filaments, from ten to fifteen in number,

from the groove between the pyramidal and olivary bodies, in a continuous line with the anterior roots of the spinal nerves. Its *deep origin* can be traced to a nucleus of grey matter on the floor of the fourth ventricle, on either side of the median line, extending from the level of the auditory striæ to the lowest point of the ventricle of Arantius.

The filaments of this nerve are collected into two bundles, which perforate the dura mater separately, opposite the anterior condyloid foramen, and unite together after their passage through it. In those cases in which the anterior condyloid foramen in the occipital bone is double, these two portions of the nerve are separated by the small piece of bone which divides the foramen. The nerve descends almost vertically to a point corresponding with the angle of the jaw. It is at first deeply seated beneath the internal carotid artery and internal jugular vein, and intimately connected with the pneumogastric nerve; it then passes forwards between the vein and artery, and lower down in the neck becomes superficial below the Digastric muscle. The nerve then loops round the occipital

Fig. 498.—Plan of the hypoglossal nerve. (After Flower.)



artery, and crosses the external carotid below the tendon of the Digastric muscle. It passes beneath the Mylo-hyoid muscle, lying between it and the Hyo-glossus, and communicates at the anterior border of the latter muscle with the lingual (gustatory) nerve; it is then continued forwards in the fibres of the Genio-hyo-glossus muscle as far as the tip of the tongue, distributing branches to its substance.

The branches of communication are, with the

Pneumogastric.	First and second cervical nerves.
Sympathetic.	Lingual (gustatory).

The communication with the pneumogastric takes place close to the exit of the nerve from the skull, numerous filaments passing between the hypoglossal



and lower ganglion of the pneumogastric; sometimes the two nerves are united so as to form one mass. It also communicates with the pharyngeal plexus by a minute filament as it winds round the occipital artery.

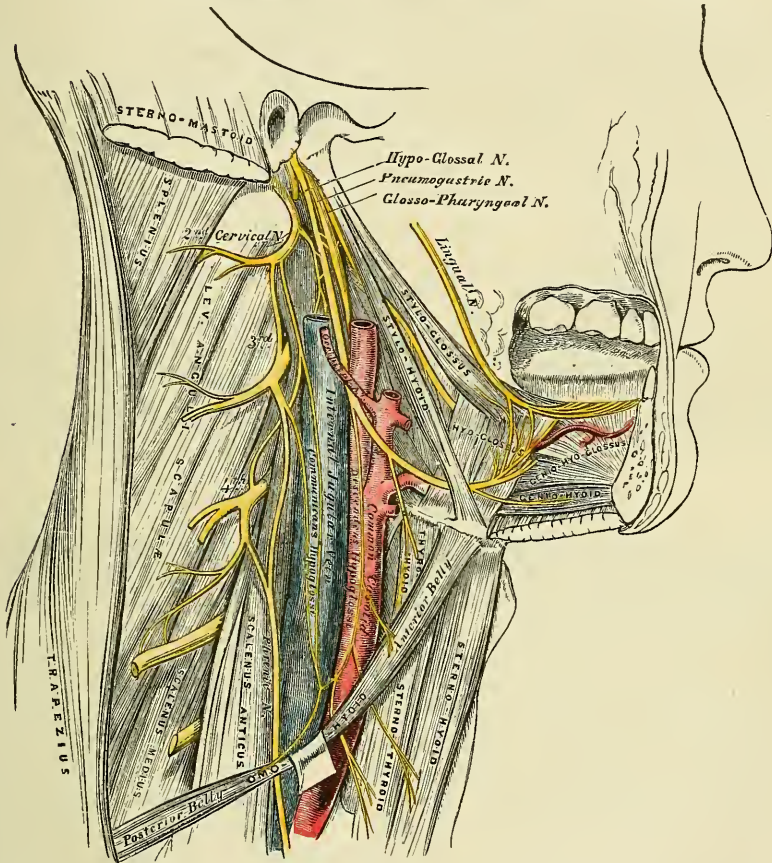
The communication with the sympathetic takes place opposite the atlas by branches derived from the superior cervical ganglion, and in the same situation the nerve is joined by a filament derived from the loop connecting the first two cervical nerves.

The communication with the lingual (gustatory) takes place near the anterior border of the Hyo-glossus muscle by numerous filaments which ascend upon it.

The branches of distribution are, the

- |                        |              |
|------------------------|--------------|
| Meningeal.             | Thyro-hyoid. |
| Descendens hypoglossi. | Muscular.    |

FIG. 499.—Hypoglossal nerve, cervical plexus, and their branches.



**Meningeal branches.**—As the hypoglossal nerve passes through the anterior condyloid foramen it gives off, according to Luschka, several filaments to the dura mater in the posterior fossa of the base of the skull.

The **descendens hypoglossi** is a long slender branch, which quits the hypoglossal where it turns round the occipital artery. It descends obliquely across the sheath of the carotid vessels, and joins the communicating branches from the second and third cervical nerves, just below the middle of the neck, to form a loop. From the convexity of this loop branches pass forwards to supply the Sternohyoid, Sternothyroid, and both bellies of the Omo-hyoid. According to Arnold, another filament descends in front of the vessels into the chest, and joins the cardiac and phrenic nerves. The descendens hypoglossi is occasionally

contained in the sheath of the carotid vessels, being sometimes placed over, and sometimes beneath the internal jugular vein.

The **thyro-hyoid** is a small branch, arising from the hypoglossal near the posterior border of the Hyo-glossus; it passes obliquely across the great cornu of the hyoid bone, and supplies the Thyro-hyoid muscle.

The **muscular branches** are distributed to the Stylo-glossus, Hyo-glossus, Genio-hyoid, and Genio-hyo-glossus muscles. At the under surface of the tongue numerous slender branches pass upwards into the substance of the organ to supply its muscular structure.

*Surgical Anatomy.*—The hypoglossal nerve is an important guide in the operation of ligature of the lingual artery (see page 562). It runs forwards just above the great cornu of the hyoid bone, and forms the upper boundary of the triangular space in which the artery is to be sought for.

### THE SPINAL NERVES

The **spinal nerves** are so called because they take their origin from the spinal cord, and are transmitted through the intervertebral foramina on either side of the spinal column. There are thirty-one pairs of spinal nerves, which are arranged into the following groups, corresponding to the region of the spine through which they pass :

Cervical . . . . .	8 pairs
Dorsal . . . . .	12 „
Lumbar . . . . .	5 „
Sacral . . . . .	5 „
Coccygeal . . . . .	1 pair

It will be observed that each group of nerves corresponds in number with the vertebræ in that region, except the cervical and coccygeal.

Each spinal nerve arises by two roots, an anterior or motor root, and a posterior or sensory root.

### ROOTS OF THE SPINAL NERVES

**The Anterior Roots.**—The *superficial origin* is from a longitudinal area upon the antero-lateral column of the cord, opposite to the anterior cornu of grey matter, by an almost continuous series of filaments; each nerve root being comprised of from four to eight filaments.

The *deep origin* can be traced to the anterior part of the antero-lateral column; the roots, after penetrating horizontally through the longitudinal fibres of this tract, enter the grey substance, where their fibrils diverge in several directions: some, passing *inwards*, are continued across the anterior commissure in front of the central canal, to become continuous with the axis-cylinder processes of the large cells of the anterior cornu of the opposite side; others terminate in the mesial group of cells of the anterior column of the same side; other fibrils pass *outwards*, some to become continuous with the axis-cylinder processes of the group of cells in the lateral part of the anterior column; and others enter the lateral column of the same side, where, turning upwards, they pursue their course as longitudinal fibres. The remaining fibrils pass *backwards* to the posterior horn, where they are continuous with the axis-cylinders of the cells at the base of the posterior cornu.

**The Posterior Roots.**—The *superficial origin* is from the postero-lateral fissure of the cord. The *deep origin* is from the grey substance of the posterior cornu, either directly through the substantia gelatinosa, or indirectly, by first passing through the white matter of the posterior column and winding round in front of the caput cornu. Those which enter the grey matter at once, for the most part turn upwards and downwards, and become continuous with the fine nerve-plexus in the central portion of the grey matter; some few fibres pass transversely

through the posterior commissure to the opposite side, and others into the anterior cornu of the same side. Those fibres which enter the grey matter in front of the caput cornu reach the posterior vesicular column (Clarke's column) and blend with it; a few fibres passing through it, to become longitudinal in the posterior column of the cord.

The *anterior roots* are smaller than the posterior, devoid of ganglionic enlargement, and their component fibrils are collected into two bundles, near the intervertebral foramina.

The *posterior roots* of the nerves are larger, but the individual filaments are finer and more delicate than those of the anterior. As their component fibrils pass outwards, towards the aperture in the dura mater, they coalesce into two bundles, receive a tubular sheath from that membrane, and enter the ganglion which is developed upon each root.

The posterior root of the first cervical nerve forms an exception to these characters. It is smaller than the anterior, has frequently no ganglion developed upon it, and when the ganglion exists it is often situated within the dura mater.

#### GANGLIA OF THE SPINAL NERVES

A **ganglion** is developed upon the posterior root of each of the spinal nerves. These ganglia are of an oval form, and of a reddish colour; they bear a proportion in size to the nerves upon which they are formed, and are placed in the intervertebral foramina, external to the point where the nerves perforate the dura mater. Each ganglion is bifid internally, where it is joined by the two bundles of the posterior root, the two portions being united into a single mass externally. The ganglion upon the first and second cervical nerves forms an exception to these characters, being placed on the arches of the vertebræ over which the nerves pass. The ganglia, also, of the sacral nerves are placed within the spinal canal; and that on the coccygeal nerve, also in the canal, about the middle of its posterior root.

#### DISTRIBUTION OF THE SPINAL NERVES

Immediately beyond the ganglion the two roots coalesce, their fibres intermingle, and the trunk thus formed passes out of the intervertebral foramen, and divides into a posterior division for the supply of the posterior part of the body, and an anterior division for the supply of the anterior part of the body; each containing fibres from both roots.

The **posterior divisions of the spinal nerves** are generally smaller than the anterior; they arise from the trunk resulting from the union of the roots, in the intervertebral foramina; and, passing backwards, divide into internal and external branches, which are distributed to the muscles and integument behind the spine. The first cervical, the fourth and fifth sacral, and the coccygeal, do not divide into external and internal branches.

The **anterior divisions of the spinal nerves** supply the parts of the body in front of the spine, including the limbs. They are for the most part larger than the posterior divisions; this increase of size being proportioned to the larger extent of structures they are required to supply. Each division is connected by slender filaments with the sympathetic. In the dorsal region the anterior divisions of the spinal nerves are completely separate from each other, and are uniform in their distribution; but in the cervical, lumbar, and sacral regions they form intricate plexuses previous to their distribution.

#### POINTS OF EMERGENCE OF THE SPINAL NERVES

The roots of the spinal nerves from their origin in the cord run obliquely downwards to their point of exit from the intervertebral foramina: the amount of



obliquity varying in different regions of the spine, and being greater in the lower than the upper part. The level of their emergence from the cord is within certain limits variable, and of course does not correspond to the point of emergence of the nerve from the intervertebral foramina. The accompanying table, from Macalister, shows as accurately as can be shown the relation of these points of origin from the spinal cord to the bodies and spinous processes of the vertebræ.

Level of Body of	No. of Nerve	Level of tip of Spine of	Level of Body of	No. of Nerve	Level of tip of Spine of
C. 1	C. 1	—	D. 8	9	7 d.
2	2	—	9	10	8 d.
3	3	1 c.	10	11	9 d.
4	4	2 c.	—	12	10 d.
5	5	3 c.	11	L. 1	11 d.
6	6	4 c.	—	2	—
—	7	5 c.	12	3	} 12 d.
7	8	6 c.	—	4	
D. 1	D. 1	7 c.	—	5	
2	2	1 d.	L. 1	S. 1	—
3	3	—	—	2	} 1 L.
4	4	2 d.	—	3	
5	5	3 d.	—	4	
6	6	4 d.	—	5	} 1 L.
7	7	5 d.	—	G. 1	
—	8	6 d.	L. 2	—	—

### CERVICAL NERVES

The **roots of the cervical nerves** increase in size from the first to the fifth, and then remain the same size to the eighth. The posterior roots bear a proportion to the anterior as 3 to 1, which is much greater than in any other region, the individual filaments being also much larger than those of the anterior roots. In direction, the roots of the cervical are less oblique than those of the other spinal nerves. The first cervical nerve is directed a little upwards and outwards; the second is horizontal; the others are directed obliquely downwards and outwards, the lowest being the most oblique, and consequently longer than the upper, the distance between their place of origin and their point of exit from the spinal canal never exceeding the depth of one vertebra.

The *trunk of the first cervical nerve (suboccipital)* leaves the spinal canal, between the occipital bone and the posterior arch of the atlas; the second, between the posterior arch of the atlas and the lamina of the axis; and the eighth (the last), between the last cervical and first dorsal vertebræ.

Each nerve, at its exit from the intervertebral foramen, divides into a posterior and an anterior division. The anterior divisions of the four upper cervical nerves form the cervical plexus. The anterior divisions of the four lower cervical nerves, together with the first dorsal, form the brachial plexus.

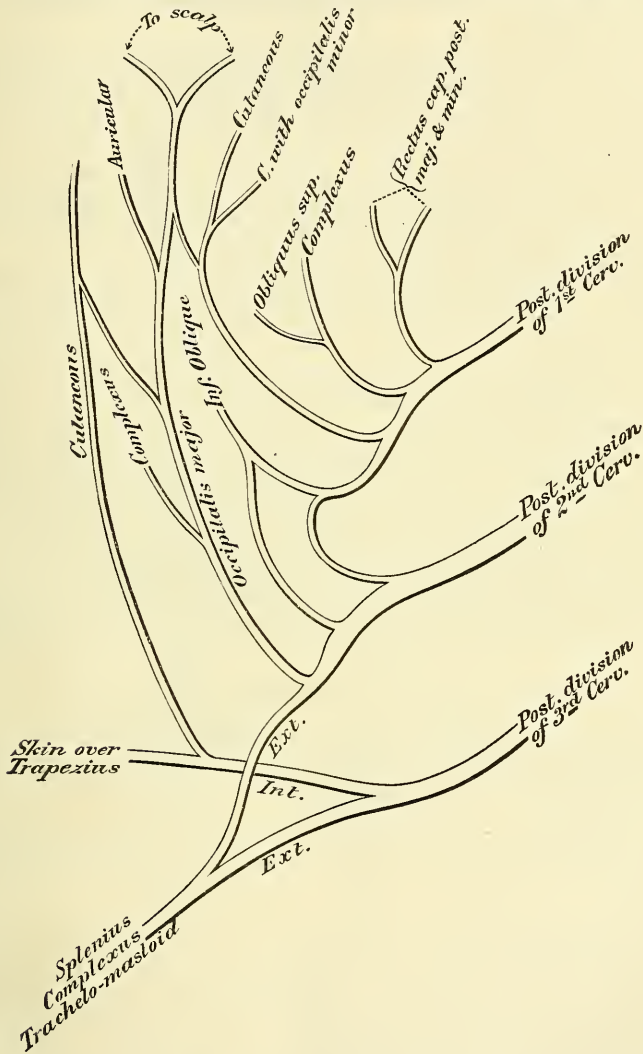
#### POSTERIOR DIVISIONS OF THE CERVICAL NERVES (fig. 500)

The **posterior division of the first cervical (suboccipital) nerve** differs from the posterior divisions of the other cervical nerves in not dividing into an internal and external branch. It is larger than the anterior division, and escapes from the spinal canal between the occipital bone and the posterior arch of the atlas, lying behind the vertebral artery. It enters the suboccipital triangle formed by the Rectus capitis posticus major, the Obliquus superior, and Obliquus inferior, and supplies the Recti and Obliqui muscles, and the Complexus. From the branch which supplies the Inferior oblique a filament is given off which joins the second cervical nerve. This nerve also occasionally gives off a cutaneous

filament, which accompanies the occipital artery, and communicates with the occipitalis major and minor nerves.

The posterior division of the second cervical nerve is three or four times greater than the anterior division, and the largest of all the posterior cervical divisions. It emerges from the spinal canal between the posterior arch of the atlas and lamina of the axis, below the Inferior oblique. It supplies this muscle, and receives a communicating filament from the first cervical. It then divides into an internal and an external branch.

FIG. 500.—Posterior divisions of the upper cervical nerves.



The internal branch, called, from its size and distribution, the *occipitalis major*, ascends obliquely inwards between the Obliquus inferior and Complexus, and pierces the latter muscle and the Trapezius near their attachments to the cranium. It is now joined by a filament from the posterior division of the third cervical nerve, and, ascending on the back part of the head with the occipital artery, divides into two branches, which supply the integument of the scalp as far forwards as the vertex, communicating with the occipitalis minor. It gives off an auricular branch to the back part of the ear, and muscular branches to the

Complexus. The *external branch* is often joined by the external branch of the posterior division of the third, and supplies the Splenius, Trachelo-mastoid, and Complexus.

The **posterior division of the third cervical** is smaller than the preceding, but larger than the fourth; it differs from the posterior divisions of the remaining cervical nerves in its supplying an additional filament, the third occipital nerve, to the integument of the occiput. The posterior division of the third nerve, like the others, divides into an internal and external branch. The *internal branch* passes between the Complexus and Semispinalis, and, piercing the Splenius and Trapezius, supplies the skin over the latter muscle; the *external branch* joins with that of the posterior division of the second to supply the Splenius, Trachelo-mastoid, and Complexus.

The *third occipital nerve* arises from the internal or cutaneous branch beneath the Trapezius; it then pierces that muscle, and supplies the skin on the lower and back part of the head. It lies to the inner side of the occipitalis major, with which it is connected.

The posterior division of the suboccipital nerve and the internal branches of the posterior divisions of the second and third cervical nerves are occasionally joined beneath the Complexus by communicating branches. This communication is described by Cruveilhier as the *posterior cervical plexus*.

The **posterior divisions of the fourth, fifth, sixth, seventh, and eighth cervical nerves** (fig. 507) pass backwards, and divide, behind the Intertransversales muscles, into internal and external branches. The *internal branches*, the larger, are distributed differently in the upper and lower part of the neck. Those derived from the fourth and fifth nerves pass between the Complexus and Semispinalis muscles, and, having reached the spinous processes, perforate the aponeurosis of the Splenius and Trapezius, and are continued outwards to the integument over the Trapezius, whilst those derived from the three lowest cervical nerves are the smallest, and are placed beneath the Semispinalis colli, which they supply, and then pass into the Interspinales, Multifidus spinæ and Complexus, and send twigs through this latter muscle to supply the integument near the spinous processes (Hirschfeld). The *external branches* supply the muscles at the side of the neck, viz. the Cervicalis ascendens, Transversalis colli, and Trachelo-mastoid.

#### ANTERIOR DIVISIONS OF THE CERVICAL NERVES

The **anterior division of the first or suboccipital nerve** is of small size. It escapes from the spinal canal through a groove upon the posterior arch of the atlas. In this groove it lies beneath the vertebral artery, to the inner side of the Rectus capitis lateralis. As it crosses the foramen in the transverse process of the atlas, it receives a filament from the sympathetic. It then descends, in front of this process, to communicate with an ascending branch from the second cervical nerve.

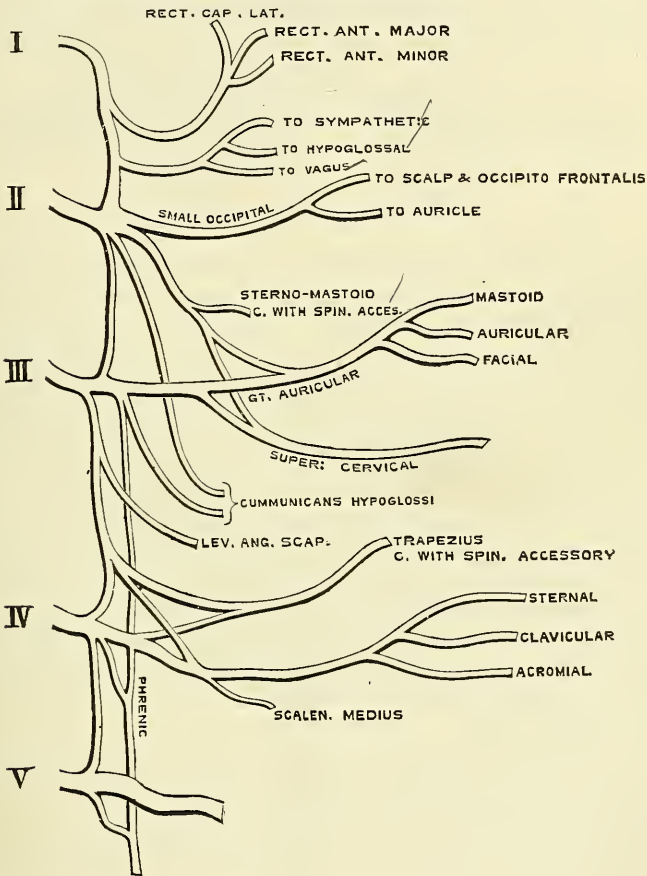
Communicating filaments from this nerve join the pneumogastric, the hypoglossal, and sympathetic, and some branches are distributed to the Rectus lateralis and the two Anterior recti. According to Valentin, the anterior division of the suboccipital also distributes filaments to the occipito-atlantal articulation, and mastoid process of the temporal bone.

The **anterior division of the second cervical nerve** escapes from the spinal canal, between the posterior arch of the atlas and the lamina of the axis, and, passing forwards on the outer side of the vertebral artery, divides in front of the Intertransverse muscle, into an ascending branch, which joins the first cervical; and one or two descending branches which join the third. It gives off the small occipital; a branch to assist in forming the great auricular; another to assist in forming the superficial cervical; one of the communicantes hypoglossi, and a filament to the Sterno-mastoid, which communicates in the substance of the muscle with the spinal accessory.



The anterior division of the third cervical nerve is double the size of the preceding. At its exit from the intervertebral foramen, it passes downwards and outwards beneath the Sterno-mastoid, and divides into two branches. The ascending branch joins the anterior division of the second cervical; the descending branch passes down in front of the Scalenus anticus, and communicates with the fourth. It gives off the greater part of the great auricular and superficial cervical nerves; one of the communicantes hypoglossi; a branch to the supraclavicular nerves; a filament to assist in forming the phrenic; and muscular branches to the Levator anguli scapulæ and Trapezius; this latter nerve communicates beneath the muscle with the spinal accessory. Sometimes the nerve to the Scalenus medius is derived from this source.

FIG. 501.—Plan of the cervical plexus.



The anterior division of the fourth cervical is of the same size as the preceding. It receives a branch from the third, sends a communicating branch to the fifth cervical, and, passing downwards and outwards, divides into numerous filaments, which cross the posterior triangle of the neck, forming the supraclavicular nerves. It gives a branch to the phrenic nerve, whilst it is contained in the intertransverse space, and sometimes a branch to the Scalenus medius muscle. It also gives a branch to the Levator anguli scapulæ and to the Trapezius, which unites with the branch given off from the third nerve, and communicates beneath the muscle with the spinal accessory.

The anterior divisions of the fifth, sixth, seventh, and eighth cervical nerves are remarkable for their large size. They are much larger than the preceding

nerves, and are all of equal size. They assist in the formation of the brachial plexus.

#### CERVICAL PLEXUS

The cervical plexus (fig. 501) is formed by the anterior divisions of the four upper cervical nerves. It is situated opposite the four upper cervical vertebræ, resting upon the Levator anguli scapulæ and Scalenus medius muscles, and covered in by the Sterno-mastoid.

Its branches may be divided into two groups, *superficial* and *deep*, which may be thus arranged :—

<i>Superficial</i>	{	Ascending .	{	Occipitalis minor.	{	Auricularis magnus.
				Superficialis colli.		
		Descending .	{	Supraclavicular .	{	Suprasternal.
						Supra-acromial.
<i>Deep</i>	{	Internal .	{	Communicating.	{	Muscular.
				Communicans hypoglossi.		
		External .	{	Phrenic.	{	Communicating.
				Muscular.		

#### SUPERFICIAL BRANCHES OF THE CERVICAL PLEXUS

The **Occipitalis minor** (fig. 507, page 833) arises from the second cervical nerve; it curves round the posterior border of the Sterno-mastoid, and ascends, running parallel to the posterior border of the muscle, to the back part of the side of the head. Near the cranium it perforates the deep fascia, and is continued upwards along the side of the head behind the ear, supplying the integument, and communicating with the occipitalis major, the auricularis magnus, and with the posterior auricular branch of the facial.

This nerve gives off an *auricular branch*, which supplies the integument of the upper and back part of the auricle, communicating with the mastoid branch of the auricularis magnus. This branch is occasionally derived from the great occipital nerve. The occipitalis minor varies in size; it is occasionally double.

The **Auricularis Magnus** is the largest of the ascending branches. It arises from the second and third cervical nerves, winds round the posterior border of the Sterno-mastoid, and, after perforating the deep fascia, ascends upon that muscle beneath the Platysma to the parotid gland, where it divides into facial, auricular, and mastoid branches.

The *facial branches* pass across the parotid, and are distributed to the integument of the face over the parotid gland; others penetrate the substance of the gland, and communicate with the facial nerve.

The *auricular branches* ascend to supply the integument of the back part of the pinna, except at its upper part, communicating with the auricular branches of the facial and pneumogastric nerves.

The *mastoid branch* communicates with the occipitalis minor and the posterior auricular branch of the facial, and is distributed to the integument behind the ear.

The **Superficialis Colli** arises from the second and third cervical nerves, turns round the posterior border of the Sterno-mastoid about its middle, and, passing obliquely forwards beneath the external jugular vein to the anterior border of that muscle, perforates the deep cervical fascia, and divides beneath the Platysma into two branches, which are distributed to the antero-lateral parts of the neck.

The *ascending branch* gives a filament which accompanies the external jugular vein; it then passes upwards to the submaxillary region, and divides into branches, some of which form a plexus with the cervical branches of the facial

nerve beneath the Platysma; others pierce that muscle, supply it, and are distributed to the integument of the upper half of the neck, at its fore part, as high as the chin.

The *descending branch* (occasionally represented by two or more filaments) pierces the Platysma, and is distributed to the integument of the side and front of the neck, as low as the sternum.

The **Descendign** or **supraclavicular** branches arise from the third and fourth cervical nerves: emerging beneath the posterior border of the Sterno-mastoid, they descend in the interval between that muscle and the Trapezius, and divide into branches, which are arranged, according to their position, into three groups.

The *inner* or *suprasternal branches* cross obliquely over the clavicular and sternal attachments of the Sterno-mastoid, and supply the integument as far as the median line.

The *middle* or *supraclavicular branches* cross the clavicle, and supply the integument over the Pectoral and Deltoid muscles, communicating with the cutaneous branches of the upper intercostal nerves.

The *external* or *supra-acromial branches* pass obliquely across the outer surface of the Trapezius and the acromion, and supply the integument of the upper and back part of the shoulder.

#### DEEP BRANCHES OF THE CERVICAL PLEXUS. INTERNAL SERIES

The **communicating branches** consist of several filaments, which pass from the loop between the first and second cervical nerves in front of the atlas to the pneumogastric, hypoglossal, and sympathetic; and a communicating branch between the fourth and fifth cervical.

**Muscular branches** supply the Anterior recti and Rectus lateralis muscles; they proceed from the first cervical nerve, and from the loop formed between it and the second.

The **Communicans Hypoglossi** (fig. 499) consists usually of two filaments, one being derived from the second, and the other from the third cervical. These filaments pass downwards on the outer side of the internal jugular vein, cross in front of the vein a little below the middle of the neck, and form a loop with the descendens hypoglossi in front of the sheath of the carotid vessels (see page 811). Occasionally, the junction of these nerves takes place within the sheath.

The **Phrenic Nerve** (*internal respiratory of Bell*) arises chiefly from the fourth cervical nerve with a few filaments from the third and a communicating branch from the fifth. It descends to the root of the neck, running obliquely across the front of the Scalenus anticus, passes over the first part of the subclavian artery, between it and the subclavian vein, and, as it enters the chest, crosses the internal mammary artery near its origin. Within the chest, it descends nearly vertically in front of the root of the lung, and by the side of the pericardium, between it and the mediastinal portion of the pleura, to the Diaphragm, where it divides into branches, which separately pierce that muscle, and are distributed to its under surface.

The two phrenic nerves differ in their length, and also in their relations at the upper part of the thorax.

The *right nerve* is situated more deeply, and is shorter and more vertical in direction than the left; it lies on the outer side of the right vena innominata and superior vena cava.

The *left nerve* is rather longer than the right, from the inclination of the heart to the left side, and from the Diaphragm being lower on this than on the opposite side. At the upper part of the thorax, it crosses in front of the arch of the aorta to the root of the lung.

Each nerve supplies filaments to the pericardium and pleura, and near the chest is joined by a filament from the sympathetic, and, occasionally, by one from



the union of the descendens hypoglossi with the spinal nerves: this filament is found, according to Swan, only on the left side. It is also usually connected by a filament with the nerve to the Subclavius muscle. Branches have been described as passing to the peritoneum.

From the *right nerve*, one or two filaments pass to join in a small ganglion with phrenic branches of the solar plexus: and branches from this ganglion are distributed to the hepatic plexus, the suprarenal capsule, and inferior vena cava. From the *left nerve*, filaments pass to join the phrenic plexus of the sympathetic, but without any ganglionic enlargement.

#### DEEP BRANCHES OF THE CERVICAL PLEXUS. EXTERNAL SERIES

**Communicating branches.**—The deep branches of the external series of the cervical plexus communicate with the spinal accessory nerve, in the substance of the Sterno-mastoid muscle, in the occipital triangle, and beneath the Trapezius.

**Muscular branches** are distributed to the Sterno-mastoid, Trapezius, Levator anguli scapulæ, and Scalenus medius.

The branch for the Sterno-mastoid is derived from the second cervical, the Trapezius and Levator anguli scapulæ receive branches from the third and fourth. The Scalenus medius is supplied sometimes from the third, sometimes the fourth, and occasionally from both nerves.

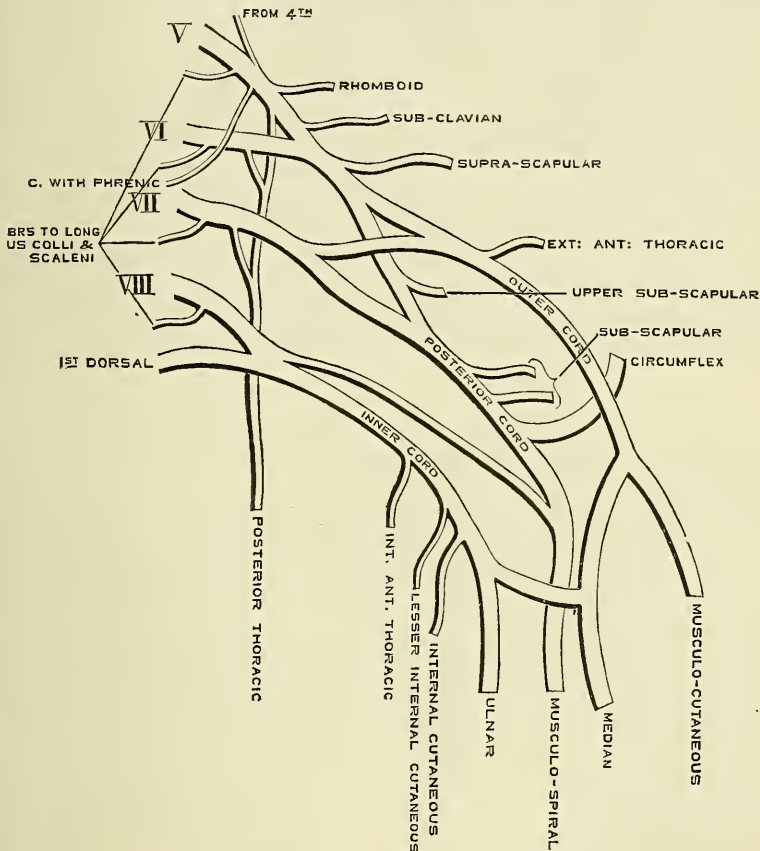
#### THE BRACHIAL PLEXUS (fig. 502)

The **Brachial Plexus** is formed by the union of the anterior branches of the four lower cervical and the greater part of the first dorsal nerves, receiving also a fasciculus from the fourth cervical nerve. It extends from the lower part of the side of the neck to the axilla. It is very broad, and presents little of a plexiform arrangement at its commencement. It is narrow opposite the clavicle, becomes broad, and forms a more dense interlacement in the axilla, and divides opposite the coracoid process into numerous branches for the supply of the upper limb. The nerves which form the plexus are all similar in size, and their mode of communication is subject to considerable variation, so that no one plan can be given as applying to every case. The following appears, however, to be the most constant arrangement. The fifth and sixth cervical unite together soon after their exit from the intervertebral foramina to form a common trunk. The eighth cervical and first dorsal also unite to form one trunk. So that the nerves forming the plexus, as they lie on the Scalenus medius, external to the outer border of the Scalenus anticus, are blended into three trunks: an outer one formed by the junction of the fifth and sixth cervical nerves; a middle one, consisting of the seventh cervical nerve; and an inner one formed by the junction of the eighth cervical and first dorsal nerves. As they pass beneath the clavicle, each of these three trunks divides into two branches, an *anterior* and a *posterior*. The anterior divisions of the outer and middle trunks then unite to form a common cord, which is situated on the outer side of the middle part of the axillary artery, and is called the *outer cord* of the brachial plexus. The anterior division of the inner trunk, formed by the union of the eighth cervical and first dorsal, passes down on the inner side of the axillary artery in the middle of the axilla, and forms the *inner cord* of the brachial plexus. The posterior divisions of the outer trunk (formed by the junction of the fifth and sixth nerves) and of the middle trunk (the seventh nerve) unite together to form the *posterior cord* of the brachial plexus, which is situated behind the second portion of the axillary artery. From this posterior cord are given off the two lower subscapular nerves; the upper subscapular nerve being given off from the posterior division of the outer trunk prior to its junction with the posterior division of the middle trunk. The posterior cord divides into the circumflex and musculo-spiral nerves. The musculo-spiral nerve is subsequently joined by the posterior division of the inner trunk, formed by the union of the eighth cervical and first dorsal.

The brachial plexus communicates with the cervical plexus by a branch from the fourth to the fifth nerve, and with the phrenic nerve by a branch from the fifth cervical, which joins that nerve on the Anterior scalenus muscle: the cervical and first dorsal nerves are also joined by filaments from the middle and inferior cervical ganglia of the sympathetic, close to their exit from the intervertebral foramina.

**Relations.**—*In the neck*, the brachial plexus lies at first between the Anterior and Middle scaleni muscles, and then above and to the outer side of the sub-clavian artery: it then passes behind the clavicle and Subclavius muscle, lying upon the first serration of the Serratus magnus, and the Subscapularis muscles. *In the axilla* it is placed on the outer side of the first portion of the axillary artery; it surrounds the artery in the second part of its course, one cord lying

FIG. 502.—Plan of the brachial plexus.



upon the outer side of that vessel, one on the inner side, and one behind it; and at the lower part of the axillary space gives off its terminal branches to the upper extremity.

**Branches.**—The branches of the brachial plexus are arranged into two groups, viz. those given off above the clavicle, and those below that bone.

#### BRANCHES ABOVE THE CLAVICLE

Communicating.  
Muscular.

Posterior thoracic.  
Suprascapular.

The **communicating branch** with the phrenic is derived from the fifth cervical nerve or from the loop between the fifth and sixth; it joins the phrenic on the Anterior scalenus muscle.

The **muscular branches** supply the Longus colli, Scaleni, Rhomboidei, and Subclavius muscles. Those for the Longus colli and Scaleni arise from the lower cervical nerves at their exit from the intervertebral foramina. The rhomboid branch arises from the fifth cervical, pierces the Scalenus medius, and passes beneath the Levator anguli scapulae, which it occasionally supplies, to the Rhomboid muscles. The nerve to the Subclavius is a small filament, which arises from the fifth cervical at its point of junction with the sixth nerve; it descends in front of the subclavian artery to the Subclavius muscle, and is usually connected by a filament with the phrenic nerve.

The **posterior thoracic nerve** (*long thoracic, external respiratory of Bell*) (fig. 505) supplies the Serratus magnus, and is remarkable for the length of its course. It sometimes arises by two roots, from the fifth and sixth cervical nerves immediately after their exit from the intervertebral foramina, but generally by three roots from the fifth, sixth, and seventh nerves. These unite in the substance of the Middle scalenus muscle, and, after emerging from it, the nerve passes down behind the brachial plexus and the axillary vessels, resting on the outer surface of the Serratus magnus. It extends along the side of the chest to the lower border of that muscle, supplying filaments to each of its digitations.

The **suprascapular nerve** (fig. 506) arises from the cord formed by the fifth and sixth cervical nerves; passing obliquely outwards beneath the Trapezius, it enters the supraspinous fossa, through the notch in the upper border of the scapula; and, passing beneath the Supraspinatus muscle, curves in front of the spine of the scapula to the infraspinous fossa. In the supraspinous fossa it gives off two branches to the Supraspinatus muscle, and an articular filament to the shoulder-joint; and in the infraspinous fossa it gives off two branches to the Infraspinatus muscle, besides some filaments to the shoulder-joint and scapula.

BRANCHES BELOW THE CLAVICLE

The branches given off below the clavicle are derived from the three cords of the brachial plexus, in the following manner:

*From the outer cord* arise the external of the two anterior thoracic nerves, the musculo-cutaneous nerve, and the outer head of the median.

*From the inner cord* arise the internal of the two anterior thoracic nerves, the internal cutaneous, the lesser internal cutaneous (nerve of Wrisberg), the ulnar and inner head of the median.

*From the posterior cord* arise two of the three subscapular nerves, the third arising from the posterior division of the trunk formed by the fifth and sixth cervical nerves; the cord then divides into the musculo-spiral and circumflex nerves.

These may be arranged according to the parts they supply:

To the chest . . . . .	Anterior thoracic.
To the shoulder . . . . .	{ Subscapular.
	{ Circumflex.
	{ Musculo-cutaneous.
	{ Internal cutaneous.
To the arm, forearm, and hand . . . . .	{ Lesser internal cutaneous.
	{ Median.
	{ Ulnar.
	{ Musculo-spiral.

The fasciculi of which these nerves are composed may be traced through the plexus to the spinal nerves from which they originate. They are as follows:

- External anterior thoracic from 5th, 6th, and 7th cervical.
- Internal anterior thoracic „ 8th cervical and 1st dorsal.
- Subscapular „ 5th, 6th, 7th, and 8th cervical.



Circumflex	from 5th, 6th, 7th, and 8th cervical.
Musculo-cutaneous	„ 5th, 6th, and 7th cervical.
Internal cutaneous	„ 8th cervical and 1st dorsal.
Lesser internal cutaneous	„ 1st dorsal.
Median	„ 6th, 7th, and 8th cervical, and 1st dorsal.
Ulnar	„ 8th cervical and 1st dorsal.
Musculo-spiral	„ 6th, 7th, and 8th cervical; sometimes also from the 5th.

The **Anterior Thoracic Nerves** (fig. 505), two in number, supply the Pectoral muscles.

The *external* or superficial nerve, the larger of the two, arises from the outer cord of the brachial plexus, through which its fibres may be traced to the fifth, sixth, and seventh cervical nerves. It passes inwards, across the axillary artery and vein, pierces the costo-coracoid membrane, and is distributed to the under surface of the Pectoralis major. It sends down a communicating filament to join the internal nerve, which forms a loop round the inner side of the axillary artery.

The *internal* or deep nerve arises from the inner cord, and through it from the eighth cervical and first dorsal. It passes upwards between the axillary artery and vein, and joins with the filament from the superficial nerve. It then passes to the under surface of the Pectoralis minor muscle, where it divides into a number of branches, which supply the muscle on its under surface. Some of the branches pass through the muscle; others wind round its upper border and pierce the costo-coracoid membrane to supply the Pectoralis major.

The **Subscapular Nerves**, three in number, supply the Subscapularis, Teres major, and Latissimus dorsi muscles. The fasciculi of which they are composed may be traced to the fifth, sixth, seventh, and eighth cervical nerves.

The *upper subscapular nerve*, the smallest, enters the upper part of the Subscapularis muscle.

The *lower subscapular nerve* enters the axillary border of the Subscapularis, and terminates in the Teres major. The latter muscle is sometimes supplied by a separate branch.

The *middle* or *long subscapular*, the largest of the three, follows the course of the subscapular artery, along the posterior wall of the axilla to the Latissimus dorsi, through which it may be traced as far as its lower border.

The **Circumflex Nerve** (fig. 506) supplies some of the muscles, and the integument of the shoulder, and the shoulder-joint. It arises from the posterior cord of the brachial plexus, in common with the musculo-spiral nerve, and its fibres may be traced through the posterior cord to the fifth, sixth, seventh, and eighth cervical nerves. It is at first placed behind the axillary artery, between it and the Subscapularis muscle, and passes downwards and outwards to the lower border of that muscle. It then winds backwards, in company with the posterior circumflex artery, through a quadrilateral space, bounded above by the Teres minor, below by the Teres major, internally by the long head of the Triceps, and externally by the neck of the humerus, and divides into two branches.

The *upper branch* winds round the surgical neck of the humerus, beneath the Deltoid, with the posterior circumflex vessels, as far as the anterior border of that muscle, supplying it, and giving off cutaneous branches, which pierce the muscle and ramify in the integument covering its lower part.

The *lower branch*, at its origin, distributes filaments to the Teres minor and back part of the Deltoid muscles. Upon the filament to the former muscle a gangliform enlargement usually exists. The nerve then pierces the deep fascia, and supplies the integument over the lower two-thirds of the posterior surface of the Deltoid, as well as that covering the long head of the Triceps.

The circumflex nerve, before its division, gives off an articular filament, which enters the shoulder-joint below the Subscapularis.

The **Musculo-cutaneous Nerve** (fig. 505) (*external cutaneous* or *perforans*

*Casseri*)\* supplies some of the muscles of the arm, and the integument of the forearm. It arises from the outer cord of the brachial plexus, opposite the lower border of the Pectoralis minor, receiving filaments from the fifth, sixth, and seventh cervical nerves. It perforates the Coraco-brachialis muscle, passes obliquely between the Biceps and Brachialis anticus, to the outer side of the

FIG. 503.—Cutaneous nerves of right upper extremity. Anterior view.

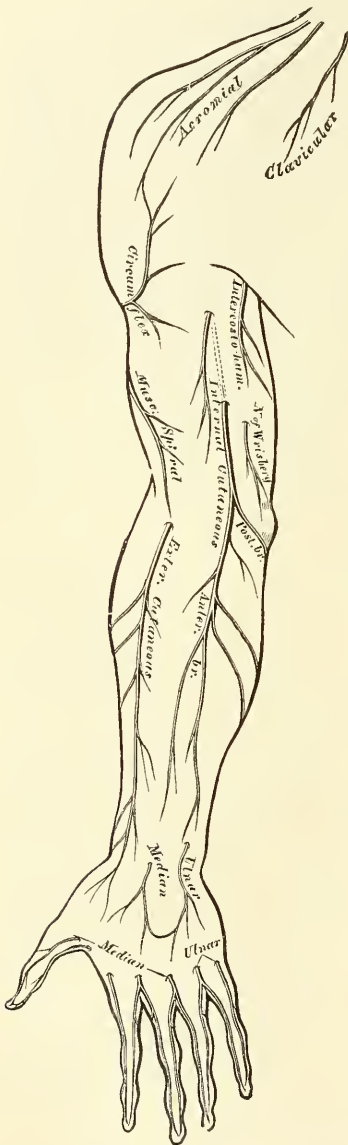
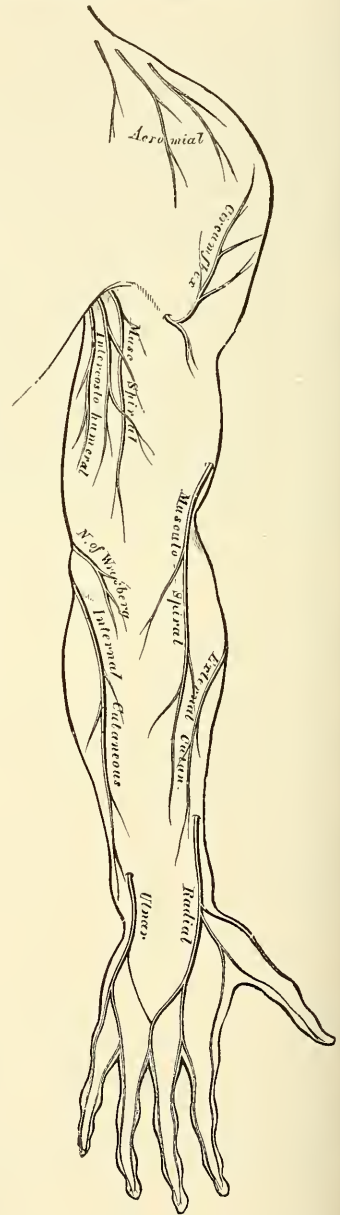


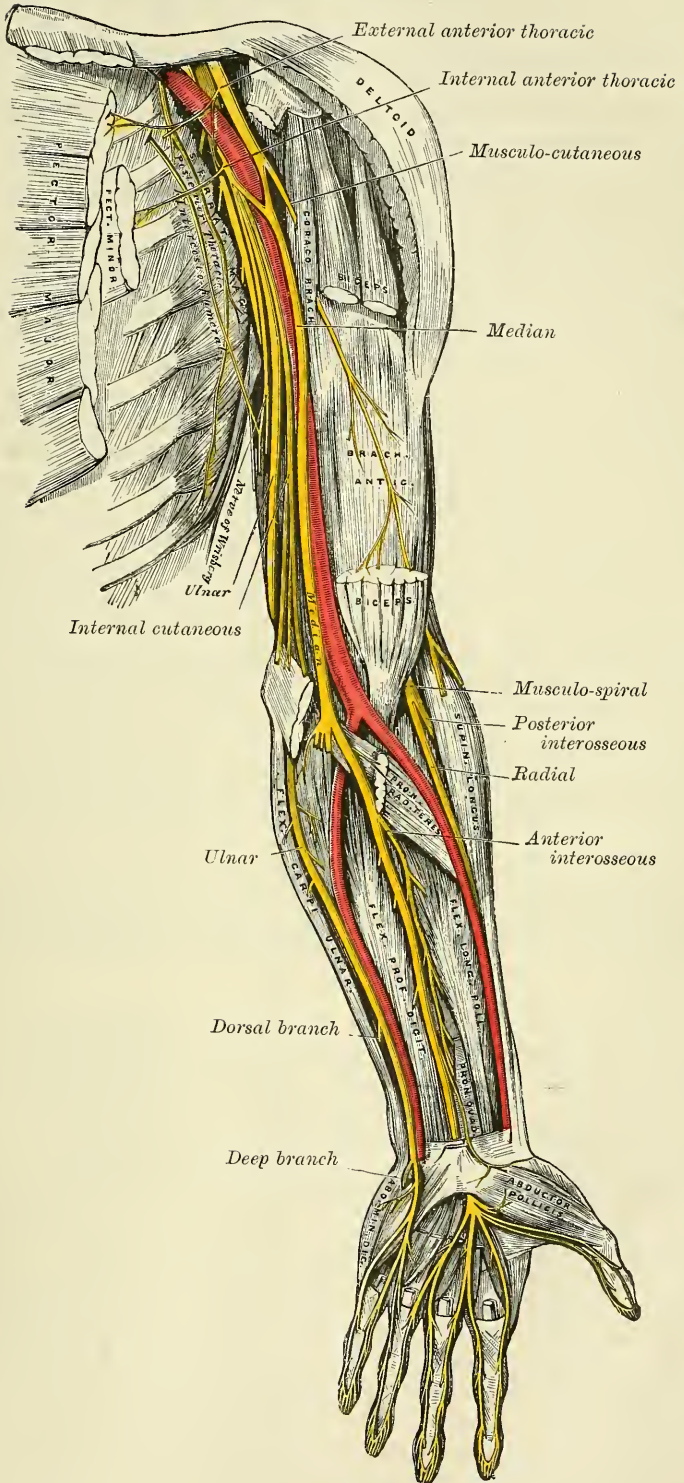
FIG. 504.—Cutaneous nerves of right upper extremity. Posterior view.



arm, and, a little above the elbow, winds round the outer border of the tendon of the Biceps, and, perforating the deep fascia, becomes cutaneous. This nerve, in its course through the arm, supplies the Coraco-brachialis, Biceps, and part of the Brachialis anticus muscles. The branch to the Coraco-brachialis is given

\* See foot-note, p. 782.

FIG. 505.—Nerves of the left upper extremity.





off from the nerve close to its origin, and in some instances as a separate filament from the outer cord of the plexus. The branches to the Biceps and Brachialis anticus are given off after the nerve has pierced the Coracobrachialis. The nerve also sends a small branch to the bone, which enters the nutrient foramen with the accompanying artery, and a filament, from the branch supplying the Brachialis anticus, to the elbow-joint.

The cutaneous portion of the nerve passes behind the median cephalic vein, and divides, opposite the elbow-joint, into an anterior and a posterior branch.

The *anterior branch* descends along the radial border of the forearm to the wrist, and supplies the integument over the outer half of the anterior surface. At the wrist-joint it is placed in front of the radial artery, and some filaments, piercing the deep fascia, accompany that vessel to the back of the wrist, supplying the carpus. The nerve then passes downwards to the ball of the thumb, where it terminates in cutaneous filaments. It communicates with a branch from the radial nerve, and the palmar cutaneous branch of the median.

The *posterior branch* passes downwards, along the back part of the radial side of the forearm, to the wrist. It supplies the integument of the lower third of the forearm, communicating with the radial nerve and the external cutaneous branch of the musculo-spiral.

The **Internal Cutaneous Nerve** (fig. 505) is one of the smallest branches of the brachial plexus. It arises from the inner cord in common with the ulnar and internal head of the median, and, at its commencement, is placed on the inner side of the axillary, and afterwards of the brachial artery. It derives its fibres from the eighth cervical and first dorsal nerves. It passes down the inner side of the arm, pierces the deep fascia with the basilic vein, about the middle of the limb, and, becoming cutaneous, divides into two branches, anterior and posterior.

This nerve gives off, near the axilla, a cutaneous filament, which pierces the fascia and supplies the integument covering the Biceps muscle, nearly as far as the elbow. This filament lies a little external to the common trunk, from which it arises.

The *anterior branch*, the larger of the two, passes usually in front of, but occasionally behind, the median basilic vein. It then descends on the anterior surface of the ulnar side of the forearm, distributing filaments to the integument as far as the wrist, and communicating with a cutaneous branch of the ulnar nerve.

The *posterior branch* passes obliquely downwards on the inner side of the basilic vein, passes in front of, or over, the internal condyle of the humerus to the back of the forearm, and descends on the posterior surface of its ulnar side as far as the wrist, distributing filaments to the integument. It communicates, above the elbow, with the lesser internal cutaneous, and above the wrist with the dorsal cutaneous branch of the ulnar nerve (Swan).

The **Lesser Internal Cutaneous Nerve** (*nerve of Wrisberg*) is distributed to the integument on the inner side of the arm (fig. 505). It is the smallest of the branches of the brachial plexus, and arising from the inner cord, with the internal cutaneous and ulnar nerves, receives its fibres from the first dorsal nerve. It passes through the axillary space, at first lying behind, and then on the inner side of the axillary vein, and communicates with the intercosto-humeral nerve. It descends along the inner side of the brachial artery to the middle of the arm, where it pierces the deep fascia, and is distributed to the integument of the back part of the lower third of the arm, extending as far as the elbow, where some filaments are lost in the integument in front of the inner condyle, and others over the olecranon. It communicates with the posterior branch of the internal cutaneous nerve.

In some cases the nerve of Wrisberg and intercosto-humeral are connected

by two or three filaments, which form a plexus at the back part of the axilla. In other cases, the intercosto-humeral is of large size, and takes the place of the nerve of Wrisberg, receiving merely a filament of communication from the brachial plexus, which represents the latter nerve. In other cases, this filament is wanting, the place of the nerve of Wrisberg being supplied entirely from the intercosto-humeral.

The **Median Nerve** (fig. 505) has received its name from the course it takes along the middle of the arm and forearm to the hand, lying between the ulnar and the musculo-spiral and radial nerves. It arises by two roots, one from the outer, and one from the inner cord of the brachial plexus; these embrace the lower part of the axillary artery, uniting either in front or on the outer side of that vessel. It receives filaments from the sixth, seventh, and eighth cervical and the first dorsal. As it descends through the arm, it lies at first on the outer side of the brachial artery, crosses that vessel in the middle of its course, usually in front, but occasionally behind it, and lies on its inner side to the bend of the elbow, where it is placed beneath the bicipital fascia, and is separated from the elbow-joint by the *Brachialis anticus*. In the forearm it passes between the two heads of the *Pronator radii teres*, and descends beneath the *Flexor sublimis*, lying on the *Flexor profundus*, to within two inches above the annular ligament, where it becomes more superficial, lying between the tendons of the *Flexor sublimis* and *Flexor carpi radialis*, beneath, and rather to the radial side of, the tendon of the *Palmaris longus*, covered by the integument and fascia. It then passes beneath the annular ligament into the hand. In its course through the forearm it is accompanied by a small artery.

*Branches.*—No branches are given off from the median nerve in the arm. In the forearm its branches are, muscular, anterior interosseous, and palmar cutaneous, and, according to Rüdinger and Macalister, two articular twigs to the elbow-joint.

The *muscular branches* supply all the superficial muscles on the front of the forearm, except the *Flexor carpi ulnaris*. These branches are derived from the nerve near the elbow. The branch furnished to the *Pronator radii teres* often arises above the joint.

The *anterior interosseous* supplies the deep muscles on the front of the forearm, except the inner half of the *Flexor profundus digitorum*. It accompanies the anterior interosseous artery along the interosseous membrane, in the interval between the *Flexor longus pollicis* and *Flexor profundus digitorum* muscles, both of which it supplies, and terminates below in the *Pronator quadratus*.

The *palmar cutaneous branch* arises from the median nerve at the lower part of the forearm. It pierces the fascia above the annular ligament, and descending over that ligament, divides into two branches: of which the *outer* supplies the skin over the ball of the thumb, and communicates with the anterior cutaneous branch of the musculo-cutaneous nerve; and the *inner* supplies the integument of the palm of the hand, communicating with the cutaneous branch of the ulnar.

In the palm of the hand, the median nerve is covered by the integument and palmar fascia, and crossed by the superficial palmar arch. It rests upon the tendons of the flexor muscles. In this situation it becomes enlarged, somewhat flattened, of a reddish colour, and divides into two branches. Of these, the *external* supplies a muscular branch to some of the muscles of the thumb, and digital branches to the thumb and index finger; the *internal* supplies digital branches to the contiguous sides of the index and middle, and of the middle and ring fingers.

The *branch to the muscles of the thumb* is a short nerve, which divides to supply the *Abductor*, *Opponens*, and outer head of the *Flexor brevis pollicis* muscles; the remaining muscles of this group being supplied by the ulnar nerve.

The *digital branches* are five in number. The *first* and *second* pass along the borders of the thumb, the external branch communicating with branches of the radial nerve. The *third* passes along the radial side of the index finger, and supplies the First lumbrical muscle. The *fourth* subdivides to supply the adjacent sides of the index and middle fingers, and sends a branch to the Second lumbrical muscle. The *fifth* supplies the adjacent sides of the middle and ring fingers, and communicates with a branch from the ulnar nerve.

Each digital nerve, opposite the base of the first phalanx, gives off a dorsal branch, which joins the dorsal digital nerve from the radial, and runs along the side of the dorsum of the finger, to end in the integument over the last phalanx. At the end of the finger, the digital nerve divides into a palmar and a dorsal branch: the former of which supplies the extremity of the finger, and the latter ramifies round and beneath the nail. The digital nerves, as they run along the fingers, are placed superficial to the digital arteries.

The **Ulnar Nerve** (fig. 505) is placed along the inner or ulnar side of the upper limb, and is distributed to the muscles and integument of the forearm and hand. It is smaller than the median, behind which it is placed, diverging from it in its course down the arm. It arises from the inner cord of the brachial plexus, in common with the inner head of the median and the internal cutaneous nerve, and derives its fibres from the eighth cervical and first dorsal nerves. At its commencement it lies at the inner side of the axillary artery, and holds the same relation with the brachial artery to the middle of the arm. From this point it runs obliquely across the internal head of the Triceps, pierces the internal inter-muscular septum, and descends to the groove between the internal condyle and the olecranon, accompanied by the inferior profunda artery. *At the elbow*, it rests upon the back of the inner condyle, and passes into the forearm between the two heads of the Flexor carpi ulnaris. *In the forearm*, it descends in a perfectly straight course along its ulnar side, lying upon the Flexor profundus digitorum, its upper half being covered by the Flexor carpi ulnaris, its lower half lying on the outer side of the muscle, covered by the integument and fascia. The ulnar artery, in the upper third of its course, is separated from the ulnar nerve by a considerable interval; but in the rest of its extent the nerve lies to its inner side. *At the wrist* the ulnar nerve crosses the annular ligament on the outer side of the pisiform bone, to the inner side, and a little behind the ulnar artery, and immediately beyond this bone divides into two branches, superficial and deep palmar.

The branches of the ulnar nerve are:

In the forearm	{	Articular (elbow).	In the hand	{	Superficial palmar.
		Muscular.			Deep palmar.
		Cutaneous.			
		Dorsal cutaneous.			
		Articular (wrist).			

The *articular branches* distributed to the elbow-joint consist of several small filaments. They arise from the nerve as it lies in the groove between the inner condyle and olecranon.

The *muscular branches* are two in number: one supplying the Flexor carpi ulnaris; the other, the inner half of the Flexor profundus digitorum. They arise from the trunk of the nerve near the elbow.

The *cutaneous branch* arises from the ulnar nerve about the middle of the forearm, and divides into two branches.

One branch (frequently absent) pierces the deep fascia near the wrist, and is distributed to the integument, communicating with a branch of the internal cutaneous nerve.

The second branch (*palmar cutaneous*) lies on the ulnar artery, which it accompanies to the hand, some filaments entwining round the vessel; it ends in the integument of the palm, communicating with branches of the median nerve.



The *dorsal cutaneous branch* arises about two inches above the wrist; it passes backwards beneath the Flexor carpi ulnaris, perforates the deep fascia, and, running along the ulnar side of the back of the wrist and hand, divides into branches; one of these supplies the inner side of the little finger; a second supplies the adjoining sides of the little and ring fingers; a third joins the branch of the radial nerve which supplies the adjoining sides of the middle and ring fingers, and assists in supplying them; a fourth is distributed to the metacarpal region of the hand, communicating with a branch of the radial nerve.

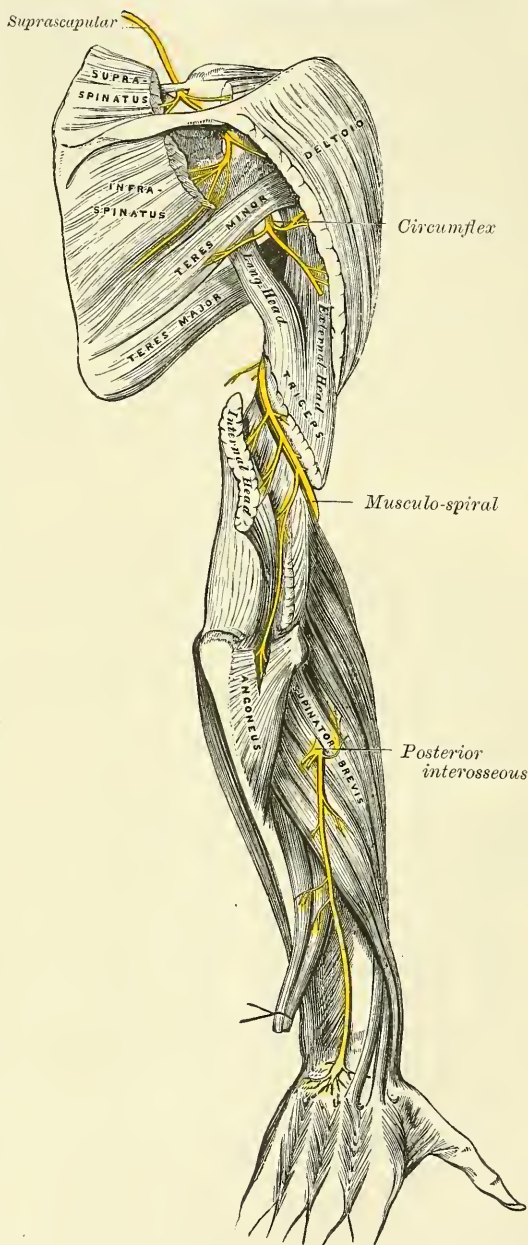
The *articular filaments to the wrist* are also supplied by the ulnar nerve.

The *superficial palmar branch* supplies the Palmaris brevis, and the integument on the inner side of the hand, and terminates in two digital branches, which are distributed, one to the ulnar side of the little finger, the other to the adjoining sides of the little and ring fingers, the latter communicating with a branch from the median. The digital branches are distributed to the fingers in the same manner as the digital branches of the median.

The *deep palmar branch* passes between the Abductor and Flexor brevis minimi digiti muscles, and follows the course of the deep palmar arch beneath the flexor tendons. At its origin it supplies the muscles of the little finger. As it crosses the deep part of the hand, it sends two branches to each interosseous space, one for the Dorsal and one for the Palmar interosseous muscle, the branches to the Second and Third palmar interossei supplying filaments to the two inner Lumbrical muscles. At its termination between the thumb and index finger, it supplies the Adductores transversus et obliquus pollicis and the inner head of the Flexor brevis pollicis.

It will be remembered that the inner part of the Flexor profundus digitorum

FIG. 506.—The suprascapular, circumflex, and musculo-spiral nerves.



is supplied by the ulnar nerve; the two inner Lumbricales, which are connected with the tendons of this part of the muscle, are therefore supplied by the same nerve. The outer part of the Flexor profundus is supplied by the median nerve: the two outer Lumbricales, which are connected with the tendons of this part of the muscle, are therefore supplied by the same nerve. Brooks states that in twelve instances out of twenty-one he found that the third lumbrical received a twig from the median nerve, in addition to its branch from the ulnar.

The **Musculo-spiral Nerve** (fig. 506), the largest branch of the brachial plexus, supplies the muscles of the back part of the arm and forearm, and the integument of the same parts, as well as that of the back of the hand. It arises from the posterior cord of the brachial plexus by a common trunk with the circumflex nerve, and is afterwards joined by the posterior division of the trunk formed by the junction of the eighth cervical and first dorsal nerves. It receives filaments from the sixth, seventh, and eighth, and sometimes also from the fifth cervical nerves. At its commencement it is placed behind the axillary and upper part of the brachial arteries, passing down in front of the tendons of the Latissimus dorsi and Teres major. It winds round the humerus in the musculo-spiral groove with the superior profunda artery, passing from the inner to the outer side of the bone, between the internal and external heads of the Triceps muscle. It pierces the external intermuscular septum, and descends between the Brachialis anticus and Supinator longus to the front of the external condyle, where it divides into the radial and posterior interosseous nerves.

The branches of the musculo-spiral nerve are:

Muscular.	Radial.
Cutaneous.	Posterior interosseous.

The *muscular branches* are divided into internal, posterior, and external; they supply the Triceps, Anconeus, Supinator longus, Extensor carpi radialis longior, and Brachialis anticus. These branches are derived from the nerve, at the inner side, back part, and outer side of the arm.

The internal muscular branches supply the inner and middle heads of the Triceps muscle. That to the inner head of the Triceps is a long, slender filament, which lies close to the ulnar nerve, as far as the lower third of the arm, and is often intimately connected with it.

The posterior muscular branch, of large size, arises from the nerve in the groove between the Triceps and the humerus. It divides into branches, which supply the outer head of the Triceps and Anconeus muscles. The branch for the latter muscle is a long, slender filament, which descends in the substance of the Triceps to the Anconeus.

The external muscular branches supply the Supinator longus, Extensor carpi radialis longior, and (usually) the outer part of the Brachialis anticus.

The *cutaneous branches* are three in number, one internal and two external.

The internal cutaneous branch arises in the axillary space, with the inner muscular branch. It is of small size, and passes through the axilla to the inner side of the arm, supplying the integument on its posterior aspect nearly as far as the olecranon. In its course it crosses beneath the intercosto-humeral, with which it communicates.

The two external cutaneous branches perforate the outer head of the Triceps, at its attachment to the humerus. The upper and smaller one passes to the front of the elbow, lying close to the cephalic vein, and supplies the integument of the lower half of the arm on its anterior aspect. The lower branch pierces the deep fascia below the insertion of the Deltoid, and passes down along the outer side of the arm and elbow, and then along the back part of the radial side of the forearm to the wrist, supplying the integument in its course, and joining, near its termination, with the posterior cutaneous branch of the musculo-cutaneous nerve.

The **radial nerve** passes along the front of the radial side of the forearm to



the commencement of its lower third. It lies at first a little to the outer side of the radial artery, concealed beneath the Supinator longus. In the middle third of the forearm, it lies beneath the same muscle, in close relation with the outer side of the artery. It quits the artery about three inches above the wrist, passes beneath the tendon of the Supinator longus, and, piercing the deep fascia at the outer border of the forearm, divides into two branches.

The external branch, the smaller of the two, supplies the integument of the radial side and ball of the thumb, joining with the anterior branch of the musculo-cutaneous nerve.

The internal branch communicates, above the wrist, with the posterior cutaneous branch from the musculo-cutaneous, and, on the back of the hand, forms an arch with the dorsal cutaneous branch of the ulnar nerve. It then divides into three digital nerves, which are distributed as follows: the first supplies the ulnar side of the thumb and the radial side of the index finger; the second, the adjoining sides of the index and middle fingers; and the third, the adjacent borders of the middle and ring fingers.\* The latter nerve communicates with a filament from the dorsal branch of the ulnar nerve.

The **Posterior Interosseous Nerve** winds to the back of the forearm round the outer side of the radius, passes between the two planes of fibres of the Supinator brevis, and is prolonged downwards between the superficial and deep layer of muscles, to the middle of the forearm. Considerably diminished in size, it descends on the interosseous membrane, beneath the Extensor longus pollicis, to the back of the carpus, where it presents a gangliform enlargement from which filaments are distributed to the ligaments and articulations of the carpus. It supplies all the muscles of the radial and posterior brachial regions, excepting the Anconeus, Supinator longus, and Extensor carpi radialis longior.

*Surgical Anatomy.*—The brachial plexus may be ruptured by traction on the limb, leading to complete paralysis. In these cases the lesion would appear to be rather a tearing away of the nerves from the spinal cord, than a solution of continuity of the nerve-fibres themselves. In the axilla, any of the nerves forming the brachial plexus may be injured in a wound of this part, the median being the one which is most frequently damaged from its exposed position; and the musculo-spiral, on account of its sheltered and deep position, being the least often wounded. The brachial plexus in the axilla is often damaged from the pressure of a crutch, producing the condition known as ‘crutch paralysis.’ In these cases the musculo-spiral appears to be the nerve which is most frequently implicated to the greatest extent; the ulnar nerve being the one that appears to suffer next in frequency.

The *circumflex nerve* is of particular surgical interest. On account of its course round the joint, it is liable to be torn in fractures of the surgical neck of the humerus and in dislocations of the shoulder-joint, leading to paralysis of the deltoid, and, according to Erb, inflammation of the shoulder-joint is liable to be followed by a neuritis of this nerve from extension of the inflammation to it.

Mr. Hilton takes the circumflex nerve as an illustration of a law which he lays down, that ‘the same trunks of nerves whose branches supply the groups of muscles moving a joint, furnish also a distribution of nerves to the skin over the insertions of the same muscles, and the interior of the joint receives its nerves from the same source.’ In this way he explains the fact that an inflamed joint becomes rigid, because the same nerves which supply the interior of the joint supply the muscles also which move that joint.

The *median nerve* is liable to injury in wounds of the forearm. When paralysed, there is loss of flexion of the second phalanges of all the fingers, and of the terminal phalanges of the index and middle fingers. Flexion of the terminal phalanges of the ring and middle fingers is effected by that portion of the Flexor profundus digitorum which is supplied by the ulnar nerve. There is power to flex the proximal phalanges through the Interossei. The thumb cannot be flexed or opposed, and is maintained in a position of extension and adduction. All power of pronation is lost. The wrist can be flexed, if the hand is first adducted, by the action of the Flexor carpi ulnaris. There is loss or impairment of sensation on the palmar surface of the thumb, index, middle, and outer half of ring fingers, and on the dorsal surface of the same fingers over the last two phalanges; except in the thumb, where the loss of sensation would be limited to the back of the last

\* According to Hutchinson, the digital nerve to the thumb reaches only as high as the root of the nail: the one to the forefinger as high as the middle of the second phalanx; and the one to the middle and ring fingers not higher than the first phalangeal joint.—*London Hos. Gaz.* vol. iii. p. 319.



phalanx. In order to expose the median nerve, for the purpose of stretching, an incision should be made along the radial side of the tendon of the *Palmaris longus*, which serves as a guide to the nerve.

The *ulnar nerve* is also liable to be injured in wounds of the forearm. When paralysed, there is loss of power of flexion in the ring and little fingers; there is impaired power of ulnar flexion and adduction; there is inability to spread out the fingers from paralysis of the *Interossei*; and there is inability to adduct the thumb. Sensation is lost, or impaired, in the skin supplied by the nerve. In order to expose the nerve in the lower part of the forearm, an incision should be made along the outer border of the tendon of the *Flexor carpi ulnaris*, and the nerve will be found lying on the ulnar side of the ulnar artery.

The *musculo-spiral nerve* is probably more frequently injured than any other nerve of the upper extremity. In consequence of its close relationship to the humerus, as it lies in the musculo-spiral groove, it is frequently torn or injured in fractures of this bone, or subsequently involved in the callus that may be thrown out around a fracture and thus pressed upon and its functions interfered with. It is also liable to be contused against the bone by kicks or blows, or to be divided by wounds of the arm. When paralysed, the hand is flexed at the wrist and lies flaccid. This is known as 'drop wrist.' The fingers are also flexed, and on an attempt being made to extend them, the last two phalanges only will be extended, through the action of the *Interossei*; the first phalanges remaining flexed. There is no power of extending the wrist. Supination is completely lost when the forearm is extended on the arm, but is possible to a certain extent if the forearm is flexed so as to allow of the action of the *Biceps*. The power of extension of the forearm is lost on account of paralysis of the *Triceps*. The best position in which to expose the nerve, for the purpose of stretching, is to make an incision along the inner border of the *Supinator longus*, just above the level of the elbow-joint. The skin and superficial structures are to be divided and the deep fascia exposed. The white line in this structure indicating the border of the muscle is to be defined, and the deep fascia divided in this line. By now raising the *Supinator longus*, the nerve will be found lying beneath it, on the *Brachialis anticus*.

### DORSAL NERVES (fig. 507)

The **dorsal nerves** are twelve in number on each side. The first appears between the first and second dorsal vertebræ, and the last between the last dorsal and first lumbar.

The *roots of the dorsal nerves* are of small size, and vary but slightly from the second to the last. Both roots are very slender; the posterior roots only slightly exceeding the anterior in thickness. They gradually increase in length from above downwards, and pass down in contact with the spinal cord for a distance equal to the height of, at least, two vertebræ, in the lower part of the dorsal region, before they emerge from the spinal canal. They then join in the intervertebral foramen, and, at their exit, divide into two primary divisions, a posterior (dorsal) and an anterior (intercostal).

The first and last dorsal nerves are peculiar in some respects.

### POSTERIOR DIVISIONS OF THE DORSAL NERVES

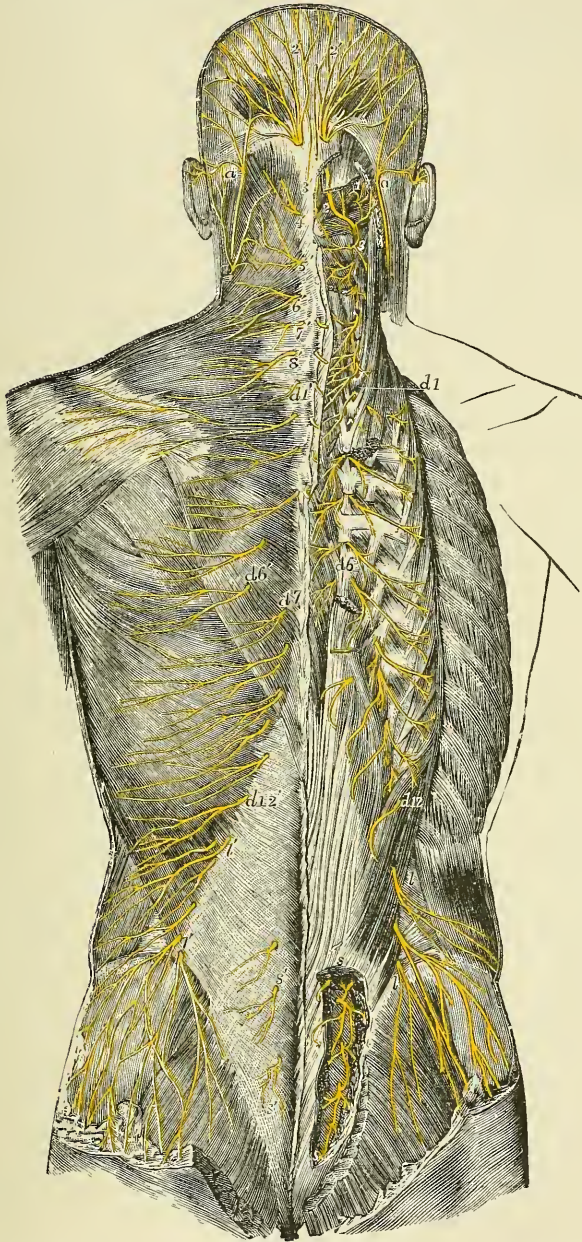
The **posterior divisions of the dorsal nerves**, which are smaller than the anterior, pass backwards between the transverse processes, and divide into internal and external branches.

The *internal branches of the six upper nerves* pass inwards between the *Semispinalis dorsi* and *Multifidus spinæ* muscles, which they supply; and then, piercing the origins of the *Rhomboidei* and *Trapezius* muscles, become cutaneous by the side of the spinous processes and ramify in the integument. The internal branches of the six lower nerves are distributed to the *Multifidus spinæ*, without giving off any cutaneous filaments.

The *external branches* increase in size from above downwards. They pass through the *Longissimus dorsi*, to the cellular interval between it and the *Iliocostalis*, and supply those muscles, as well as their continuations upwards to the head, and the *Levatores costarum*; the five or six lower nerves also give off cutaneous filaments, which pierce the *Serratus posticus inferior* and *Latissimus dorsi*, in a line with the angles of the ribs, and then ramify in the integument.

The *cutaneous branches of the dorsal nerves* are twelve in number. The six

FIG. 507.—Superficial and deep distribution of the posterior branches of the spinal nerves (after Hirschfeld and Leveillé). On the left side the cutaneous branches are represented lying on the superficial layer of muscles. On the right side the superficial muscles have been removed, the Splenius capitis and Complexus divided in the neck, and the Erector spinæ divided and partly removed in the back, so as to expose the posterior divisions of the spinal nerves near their origin.



*a a.* Lesser occipital nerve from the cervical plexus. *1.* External muscular branches of the first cervical nerve, and union by a loop with the second. *2.* Placed on the Rectus capitis posterior major muscle, marks the great occipital nerve, passing round the short muscles and piercing the Complexus: the external branch is seen to the outside. *3.* External branch from the posterior division of the third nerve. *3'.* Its internal branch, sometimes called the third occipital. *4' to 8'.* The internal branches of the several corresponding nerves on the left side. The external branches of these nerves, proceeding to muscles, are displayed on the right side. *d 1 to d 6* and thence to *d 12.* External muscular branches of the posterior divisions of the 12 dorsal nerves on the right side. *d 1' to d 6'.* The internal cutaneous branches of the six upper dorsal nerves on the left side. *d 7' to d 12'.* Cutaneous twigs from the external branches of the six lower dorsal nerves. *l l.* External branches from the posterior divisions of several lumbar nerves on the right side, piercing the muscles, the lower descending over the gluteal region. *l' l'.* The same, more superficially, on the left side. *s s.* The issue and union by loops of the posterior divisions of four sacral nerves on the right side. *s' s'.* Some of those distributed to the skin on the left side.



upper cutaneous nerves are derived from the internal branches of the posterior divisions of the dorsal nerves. They pierce the origins of the Rhomboidei and Trapezius muscles, and become cutaneous by the side of the spinous processes, and then ramify in the integument. They are frequently furnished with gangli-form enlargements. The six lower cutaneous nerves are derived from the external branches of the posterior divisions of the dorsal nerves. They pierce the Serratus posticus inferior and Latissimus dorsi, in a line with the angles of the ribs, and then ramify in the integument.

#### ANTERIOR DIVISIONS OF THE DORSAL NERVES

The **anterior divisions of the dorsal nerves** (*intercostal nerves*) are twelve in number on each side. They are, for the most part, distributed to the parietes of the thorax and abdomen, separately from each other, without being joined in a plexus; in which respect they differ from the other spinal nerves. Each nerve is connected with the adjoining ganglia of the sympathetic by one or two filaments. The intercostal nerves may be divided into two sets, from the difference they present in their distribution. The six upper, with the exception of the first and the intercosto-humeral branch of the second, are limited in their distribution to the parietes of the chest. The six lower supply the parietes of the chest and abdomen, the last one sending a cutaneous filament to the hip.

**The first dorsal nerve.**—The anterior division of the first dorsal nerve divides into two branches: one, the larger, leaves the thorax in front of the neck of the first rib, and enters into the formation of the brachial plexus; the other and smaller branch runs along the first intercostal space, forming the *first intercostal nerve*, and terminates on the front of the chest, by forming the first anterior cutaneous nerve of the thorax. Occasionally this anterior cutaneous branch is wanting. The first intercostal nerve as a rule gives off no lateral cutaneous branch; but sometimes a small branch is given off, which communicates with the intercosto-humeral. It frequently receives a connecting twig from the second dorsal nerve, which passes upwards over the neck of the second rib.

**The upper dorsal nerves.**—The anterior divisions of the second, third, fourth, fifth, and sixth dorsal nerves and the small branch from the first dorsal are confined to the parietes of the thorax, and are named *upper or pectoral intercostal nerves*. They pass forwards in the intercostal spaces with the intercostal vessels, being situated below them. At the back of the chest they lie between the pleura and the External intercostal muscles, but are soon placed between the two planes of Intercostal muscles as far as the middle of the rib. They then enter the substance of the Internal intercostal muscles, and, running amidst their fibres as far as the costal cartilages, they gain the inner surface of the muscles and lie between them and the pleura. Near the sternum, they cross the internal mammary artery and Triangularis sterni muscle, pierce the Internal intercostal and Pectoralis major muscles, and supply the integument of the front of the chest and over the mammary gland, forming the anterior cutaneous nerves of the thorax; the branch from the second nerve becoming joined with the supraclavicular nerves of the cervical plexus.

*Branches.*—Numerous slender muscular filaments supply the Intercostals, the Infracostales, the Levatores costarum, Serratus posticus superior, and Triangularis sterni muscles. Some of these branches, at the front of the chest, cross the costal cartilages from one to another intercostal space.

*Lateral cutaneous nerves.*—These are derived from the intercostal nerves, midway between the vertebræ and sternum; they pierce the External intercostal and Serratus magnus muscles, and divide into two branches, anterior and posterior.

The *anterior branches* are reflected forwards to the side and the fore part of the chest, supplying the integument of the chest and mamma, and the upper digitations of the External oblique.



The *posterior branches* are reflected backwards, to supply the integument over the scapula and over the Latissimus dorsi.

The lateral cutaneous branch of the second intercostal nerve is of large size, and does not divide, like the other nerves, into an anterior and posterior branch. It is named, from its origin and distribution, the *intercosto-humeral nerve* (fig. 505). It pierces the External intercostal muscle, crosses the axilla to the inner side of the arm, and joins with a filament from the nerve of Wrisberg. It then pierces the fascia, and supplies the skin of the upper half of the inner and back part of the arm, communicating with the internal cutaneous branch of the musculo-spiral nerve. The size of this nerve is in inverse proportion to the size of the other cutaneous nerves, especially the nerve of Wrisberg. A second intercosto-humeral nerve is frequently given off from the third intercostal. It supplies filaments to the armpit and inner side of the arm.

**The lower dorsal nerves.**—The anterior divisions of the seventh, eighth, ninth, tenth, and eleventh dorsal nerves are continued anteriorly from the intercostal spaces into the abdominal wall, and the twelfth dorsal is continued throughout its whole course in the abdominal wall, since it is placed below the last rib; hence these nerves are named *lower* or *abdominal intercostal nerves*. They have (with the exception of the last) the same arrangement as the upper ones as far as the anterior extremities of the intercostal spaces, where they pass behind the costal cartilages, and between the Internal oblique and Transversalis muscles, to the sheath of the Rectus, which they perforate. They supply the Rectus muscle, and terminate in branches which become subcutaneous near the linea alba. These branches are named the anterior cutaneous nerves of the abdomen. They are directed outwards as far as the lateral cutaneous nerves, supplying the integument of the front of the belly. The lower intercostal nerves supply the Intercostals, Serratus posticus inferior, and Abdominal muscles, and, about the middle of their course, give off lateral cutaneous branches, which pierce the External intercostal and External oblique muscles, in the same line as the lateral cutaneous nerves of the thorax, and divide into anterior and posterior branches, which are distributed to the integument of the abdomen and back, the anterior branches passing nearly as far forwards as the margin of the Rectus: the posterior branches passing backwards to supply the skin over the Latissimus dorsi, where they join the dorsal cutaneous nerves.

The **last dorsal** is larger than the other dorsal nerves. Its anterior division runs along the lower border of the last rib in front of the Quadratus lumborum, perforates the Transversalis, and passes forwards between it and the Internal oblique, to be distributed in the same manner as the lower intercostal nerves. It communicates with the ilio-hypogastric branch of the lumbar plexus, and is frequently connected with the first lumbar nerve by a slender branch, the *dorsilumbar nerve*, which descends in the substance of the Quadratus lumborum.

The *lateral cutaneous branch of the last dorsal* is remarkable for its large size; it perforates the Internal and External oblique muscles, passes downwards over the crest of the ilium in front of the iliac branch of the ilio-hypogastric (fig. 514), and is distributed to the integument of the front of the hip, some of its filaments extending as low down as the trochanter major. It does not divide into an anterior and posterior branch like the other lateral cutaneous branches of the intercostal nerves.

*Surgical Anatomy.*—The lower seven intercostal nerves and the ilio-hypogastric from the first lumbar nerve, supply the skin of the abdominal wall. They run downwards and inwards fairly equidistant from each other. The sixth and seventh supply the skin over the 'pit of the stomach'; the eighth corresponds to about the position of the middle linea transversa; the tenth to the umbilicus; and the ilio-hypogastric supplies the skin over the pubes and external abdominal ring. There are several points of surgical importance about the distribution of these nerves, and it is important to remember their origin and course, for in many diseases affecting the nerve-trunks at or near the origin, the pain is referred to their peripheral terminations. Thus, in Pott's disease of the spine, children will often be brought to the surgeon suffering from pain in the belly. This is due to the

fact that the nerves are irritated at the seat of disease as they issue from the spinal canal. When the irritation is confined to a single pair of nerves, the sensation complained of is often a feeling of constriction, as if a cord were tied round the abdomen, and in these cases the situation of the sense of constriction may serve to localise the disease in the spinal column. In other cases where the bone disease is more extensive, and two or more nerves are involved, a more general diffused pain in the abdomen is complained of. A similar condition is sometimes present in affections of the cord itself, as in *tabes dorsalis*.

Again, it must be borne in mind that the same nerves which supply the skin of the abdomen supply also the planes of muscle, which constitute the greater part of the abdominal wall. Hence it follows that any irritation applied to the peripheral terminations of the cutaneous branches in the skin of the abdomen is immediately followed by reflex contraction of the abdominal muscles. A good practical illustration of this may sometimes be seen in watching two surgeons examine the abdomen of the same patient. One, whose hand is cold, causes the muscles of the abdominal wall to at once contract and the belly to become rigid, and thus not nearly so suitable for examination; the other, who has taken the precaution to warm his hand, examines the abdomen without exciting any reflex contraction. The supply of both muscles and skin from the same source is of importance in protecting the abdominal viscera from injury. A blow on the abdomen, even of a severe character, will do no injury to the viscera if the muscles are in a condition of firm contraction; whereas in cases where the muscles have been taken unawares, and the blow has been struck while they were in a state of rest, an injury insufficient to produce any lesion of the abdominal wall has been attended with rupture of some of the abdominal contents. The importance therefore of immediate reflex contraction upon the receipt of an injury cannot be over estimated, and the intimate association of the cutaneous and muscular fibres in the same nerve produces a much more immediate response on the part of the muscles to any peripheral stimulation of the cutaneous filaments than would be the case if the two sets of fibres were derived from independent sources.

Again, the nerves supplying the abdominal muscles and skin derived from the lower intercostal nerves are intimately connected with the sympathetic supplying the abdominal viscera, through the lower thoracic ganglia from which the splanchnic nerves are derived. In consequence of this, in laceration of the abdominal viscera and in acute peritonitis, the muscles of the belly wall become firmly contracted, and thus as far as possible preserve the abdominal contents in a condition of rest.

## LUMBAR NERVES

The **lumbar nerves** are five in number on each side. The first appears between the first and second lumbar vertebræ, and the last between the last lumbar and the base of the sacrum.

The **roots of the lumbar nerves** are the largest, and their filaments the most numerous, of all the spinal nerves, and they are closely aggregated together upon the lower end of the cord. The anterior roots are the smaller; but there is not the same disproportion between them and the posterior roots as in the cervical nerves. The roots of these nerves have a vertical direction, and are of considerable length, more especially the lower ones, since the spinal cord does not extend beyond the first lumbar vertebra. The roots become joined in the intervertebral foramina; and the nerves, so formed, divide at their exit into two divisions, posterior and anterior.

### POSTERIOR DIVISIONS OF THE LUMBAR NERVES

The **posterior divisions of the lumbar nerves** (fig. 507) diminish in size from above downwards; they pass backwards between the transverse processes, and divide into internal and external branches.

The *internal branches*, the smaller, pass inwards close to the articular processes of the vertebræ, and supply the *Multifidus spinæ* and *Interspinales* muscles.

The *external branches* supply the *Erector spinæ* and *Intertransverse* muscles. From the three upper branches, cutaneous nerves are derived which pierce the aponeurosis of the *Latissimus dorsi* muscle, and descend over the back part of the crest of the ilium, to be distributed to the integument of the gluteal region; some of the filaments passing as far as the *trochanter major*.

## ANTERIOR DIVISIONS OF THE LUMBAR NERVES

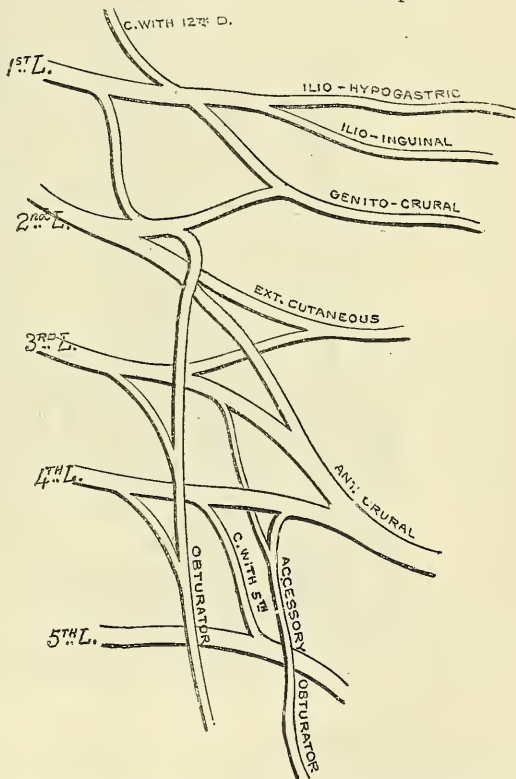
The anterior divisions of the lumbar nerves increase in size from above downwards. At their origin, they communicate with the lumbar ganglia of the sympathetic by long, slender filaments, which accompany the lumbar arteries round the sides of the bodies of the vertebræ, beneath the Psoas muscle. The nerves pass obliquely outwards behind the Psoas magnus, or between its fasciculi, distributing filaments to it and the Quadratus lumborum. The anterior divisions of the four upper nerves are connected together in this situation by anastomotic loops, and form the *lumbar plexus*. The anterior division of the fifth lumbar, joined with a branch from the fourth, descends across the base of the sacrum to join the anterior division of the first sacral nerve, and assist in the formation of the sacral plexus. The cord resulting from the union of the fifth lumbar and the branch from the fourth is called the *lumbo-sacral nerve*.

## LUMBAR PLEXUS

The lumbar plexus is formed by the loops of communication between the anterior divisions of the four upper lumbar nerves. The plexus is narrow above, and often connected with the last dorsal by a slender branch, the *dorsi-lumbar nerve*; it is broad below, where it is joined to the sacral plexus by the lumbo-sacral cord. It is situated in the substance of the Psoas muscle near its posterior part, in front of the transverse processes of the lumbar vertebræ.

The mode in which the plexus is formed is the following:—The first lumbar nerve receives a branch from the last dorsal, and gives off a larger branch, which subdivides into the ilio-hypogastric and ilio-inguinal; a communicating branch which passes down to the second lumbar nerve; and a third branch which unites with a branch of the second lumbar to form the genito-crural nerve. The second, third, and fourth lumbar nerves divide into an anterior and posterior division. The anterior division of the second divides into two branches, one of which joins with the above-mentioned branch of the first nerve to form the genito-crural; the other unites with the anterior division of the third nerve, and a part of the anterior division of the fourth nerve to form the obturator nerve. The remainder of the anterior division of the fourth nerve passes down to communicate with the fifth lumbar nerve. The posterior divisions of the second and third nerve divide into two branches, a smaller branch from each uniting to form the external cutaneous nerve, and a larger branch from each, which join with the whole of the posterior division of the fourth lumbar nerve to form the anterior crural. The accessory obturator, when it exists, is formed

FIG. 508.—Plan of the lumbar plexus.





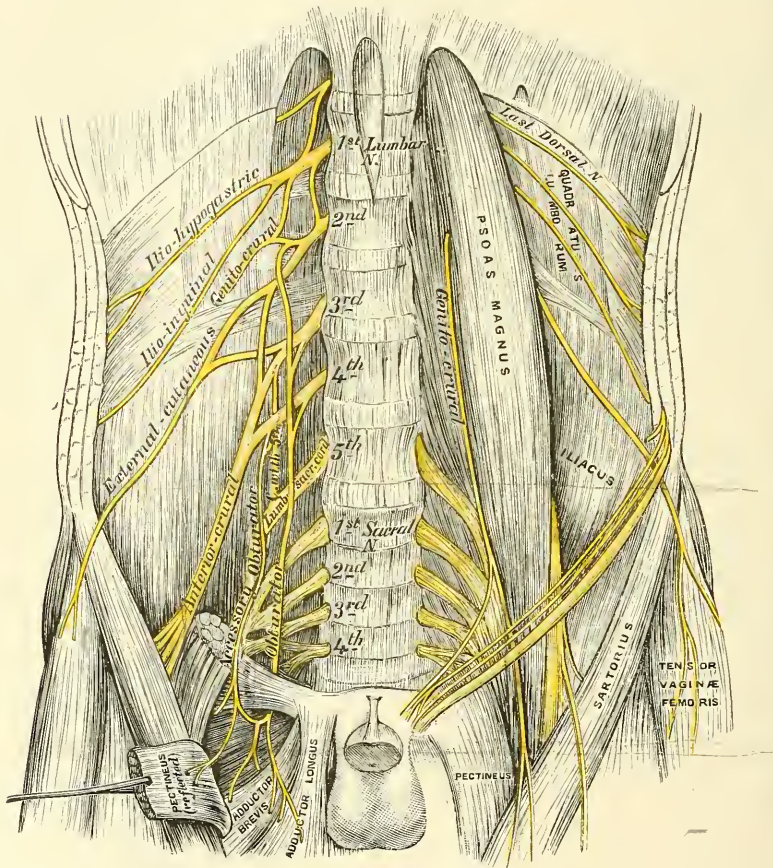
by a small branch from the third nerve joining with a small branch from the fourth.

From this arrangement it follows that the ilio-hypogastric and ilio-inguinal are derived entirely from the first lumbar nerve. The genito-crural from the first and second nerves. The external cutaneous from the second and third. The anterior crural and obturator by fibres derived from the second, third, and fourth. And the accessory obturator, when it exists, from the third and fourth.

The branches of the lumbar plexus are, the

Ilio-hypogastric.	External cutaneous.
Ilio-inguinal.	Anterior crural.
Genito-crural.	Obturator.
Accessory obturator.	

FIG. 509.—The lumbar plexus and its branches.



The **Ilio-hypogastric Nerve** (*superior musculo-cutaneous*) arises from the first lumbar nerve. It emerges from the outer border of the Psoas muscle at its upper part, and crosses obliquely in front of the Quadratus lumborum to the crest of the ilium. It then perforates the Transversalis muscle at its posterior part, near the crest of the ilium, and divides between it and the Internal oblique into two branches, iliac and hypogastric.

The *iliac branch* pierces the Internal and External oblique muscles immediately above the crest of the ilium, and is distributed to the integument of the gluteal region, behind the lateral cutaneous branch of the last dorsal nerve (fig. 514). The size of this nerve bears an inverse proportion to that of the cutaneous branch of the last dorsal nerve.

The *hypogastric branch* (fig. 510) continues onwards between the Internal oblique and Transversalis muscles. It then pierces the Internal oblique, and near the middle line perforates the aponeurosis of the External oblique, about an inch above, and a little to the outer side of the external abdominal ring, and is distributed to the integument of the hypogastric region.

The ilio-hypogastric nerve communicates with the last dorsal and ilio-inguinal nerves.

The **Ilio-inguinal Nerve** (*inferior musculo-cutaneous*), smaller than the preceding, arises with it from the first lumbar nerve. It emerges from the outer border of the Psoas just below the ilio-hypogastric, and, passing obliquely across the Quadratus lumborum and Iliacus muscles, perforates the Transversalis, near the fore part of the crest of the ilium, and communicates with the ilio-hypogastric nerve between that muscle and the Internal oblique. The nerve then pierces the Internal oblique, distributing filaments to it, and accompanying the spermatic cord through the inguinal canal, it escapes at the external abdominal ring, and is distributed to the integument of the upper and inner part of the thigh; and to the scrotum in the male, and to the labium in the female. The size of this nerve is in inverse proportion to that of the ilio-hypogastric. Occasionally it is very small, and ends by joining the ilio-hypogastric; in such cases, a branch from the ilio-hypogastric takes the place of the ilio-inguinal, or the latter nerve may be altogether absent.

The **Genito-crural Nerve** arises from the first and second lumbar nerves. It passes obliquely through the substance of the Psoas, and emerges from its inner border, close to the vertebral column, opposite the disc between the third and fourth lumbar vertebræ; it then descends on the surface of the Psoas muscle, under cover of the peritoneum, and divides into a genital and crural branch.

The *genital branch* passes outwards on the Psoas magnus, and pierces the fascia transversalis, or passes through the internal abdominal ring; it then descends along the back part of the spermatic cord to the scrotum, and supplies, in the male, the Cremaster muscle. In the female, it accompanies the round ligament, and is lost upon it.

The *crural branch* descends on the external iliac artery, sending a few filaments round it, and, passing beneath Poupart's ligament to the thigh, enters the sheath of the femoral vessels, lying superficial and a little external to the femoral artery. It pierces the anterior layer of the sheath of the vessels, and, becoming superficial by passing through the fascia lata, it supplies the skin of the anterior aspect of the thigh as far as midway between the pelvis and knee. On the front of the thigh it communicates with the outer branch of the middle cutaneous nerve, derived from the anterior crural.

A few filaments from this nerve may be traced on to the femoral artery; they are derived from the nerve as it passes beneath Poupart's ligament.

The **External Cutaneous Nerve** arises from the second and third lumbar nerves. It emerges from the outer border of the Psoas muscle about its middle, and crosses the Iliacus muscle obliquely, to the notch immediately beneath the anterior superior spine of the ilium, where it passes under Poupart's ligament into the thigh, and divides into two branches, anterior and posterior.

The *anterior branch* descends in an aponeurotic canal formed in the fascia lata, becomes superficial about four inches below Poupart's ligament, and divides into branches which are distributed to the integument along the anterior and outer part of the thigh, as far down as the knee. This nerve occasionally communicates with a branch of the long saphenous nerve in front of the knee-joint.

The *posterior branch* pierces the fascia lata, and subdivides into branches which pass backwards across the outer and posterior surface of the thigh, supplying the integument from the crest of the ilium as far as the middle of the thigh.

The **Obturator Nerve** supplies the Obturator externus and Adductor muscles of the thigh, the articulations of the hip and knee, and occasionally the integument of the thigh and leg. It arises by three branches: from the second, the

FIG. 510.—Cutaneous nerves of lower extremity. Front view.

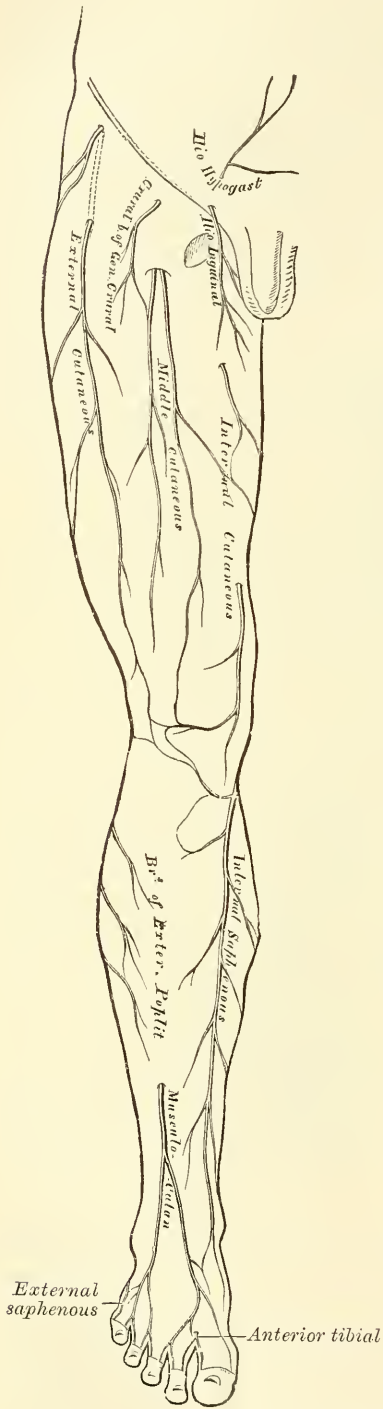
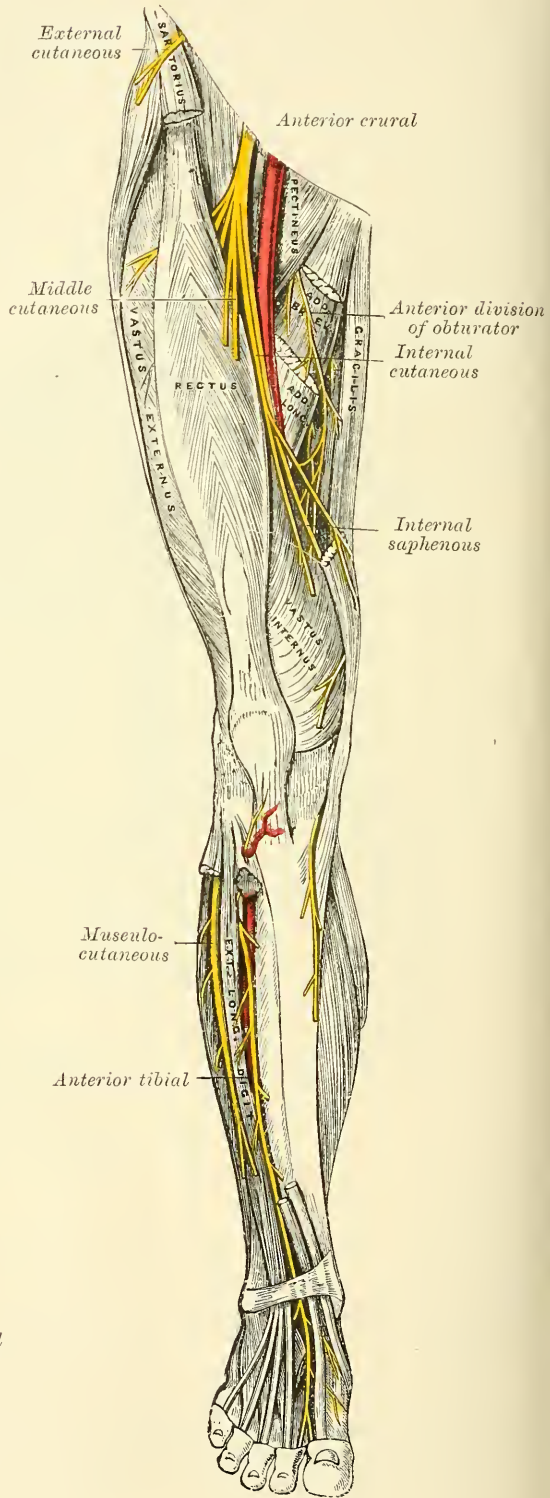


FIG. 511.—Nerves of the lower extremity. Front view.





third, and the fourth lumbar nerves. Of these the branch from the third is the largest, whilst that from the second is often very small. It descends through the inner fibres of the Psoas muscle, and emerges from its inner border near the brim of the pelvis; it then runs along the lateral wall of the pelvis, above the obturator vessels, to the upper part of the obturator foramen, where it enters the thigh, and divides into an anterior and a posterior branch, separated by some of the fibres of the Obturator externus (fig. 368), and lower down by the Adductor brevis muscle.

The *anterior branch* (fig. 511) passes down in front of the Adductor brevis, being covered by the Pectineus and Adductor longus; and at the lower border of the latter muscle communicates with the internal cutaneous and internal saphenous nerves, forming a kind of plexus. It then descends upon the femoral artery, upon which it is finally distributed. The nerve, near the obturator foramen, gives off an articular branch to the hip-joint. Behind the Pectineus, it distributes muscular branches to the Adductor longus and Gracilis, and occasionally to the Adductor brevis, and in rare cases to the Pectineus, and receives a communicating branch from the accessory obturator nerve.

Occasionally the communicating branch to the internal cutaneous and internal saphenous nerves is continued down, as a cutaneous branch, to the thigh and leg. When this is so, this occasional cutaneous branch emerges from beneath the lower border of the Adductor longus, descends along the posterior margin of the Sartorius to the inner side of the knee, where it pierces the deep fascia, communicates with the long saphenous nerve, and is distributed to the integument of the inner side of the leg as low down as its middle. When this communicating branch is small, its place is supplied by the internal cutaneous nerve.

The *posterior branch of the obturator nerve* pierces the Obturator externus, sending branches to supply it, and passes behind the Adductor brevis on the front of the Adductor magnus, where it divides into numerous muscular branches, which supply the Adductor magnus, and occasionally the Adductor brevis. One of the branches gives off a filament to the knee-joint.

The *anterior branch for the knee-joint* perforates the lower part of the Adductor magnus, and enters the popliteal space; it then descends upon the popliteal artery, as far as the back part of the knee-joint, where it perforates the posterior ligament, and is distributed to the synovial membrane. It gives filaments to the artery in its course.

**Accessory Obturator Nerve** (fig. 509) is not constantly present. It is of small size, and arises by separate filaments from the third and fourth lumbar nerves. It descends along the inner border of the Psoas muscle, crosses the ascending ramus of the os pubis, and passes under the outer border of the Pectineus muscle, where it divides into numerous branches. One of these supplies the Pectineus, penetrating its under surface; another is distributed to the hip-joint; while a third communicates with the anterior branch of the obturator nerve. When this nerve is absent, the hip-joint receives two branches from the obturator nerve. Occasionally it is very small and becomes lost in the capsule of the hip-joint.

The **Anterior Crural Nerve** (figs. 509, 511) is the largest branch of the lumbar plexus. It supplies muscular branches to the Iliacus, Pectineus, and all the muscles on the front of the thigh, excepting the Tensor vaginae femoris; cutaneous filaments to the front and inner side of the thigh, and to the leg and foot: and articular branches to the hip and knee. It arises from the second, third, and fourth lumbar nerves. It descends through the fibres of the Psoas muscle, emerging from it at the lower part of its outer border; and passes down between it and the Iliacus, and beneath Poupart's ligament, into the thigh, where it becomes somewhat flattened, and divides into an anterior part, which passes superficially to the external circumflex vessels, and a posterior part which passes beneath these vessels. Under Poupart's ligament, it is separated from the femoral artery by the Psoas muscle, and lies beneath the iliac fascia.

*Within the pelvis* the anterior crural nerve gives off from its outer side some

small branches to the Iliacus, and a branch to the femoral artery, which is distributed upon the upper part of that vessel. The origin of this branch varies: it occasionally arises higher than usual, or it may arise lower down in the thigh.

*External to the pelvis* the following branches are given off:

*From the Anterior Division*

Middle cutaneous.  
Internal cutaneous.

*From the Posterior Division*

Long saphenous.  
Muscular.  
Articular.

The *middle cutaneous nerve* (fig. 510) pierces the fascia lata (generally the Sartorius also) about three inches below Poupart's ligament, and divides into two branches, which descend in immediate proximity along the fore part of the thigh, distributing numerous branches to the integument as low as the front of the knee, where it communicates with the *nervus cutaneus patellæ*, a branch of the internal saphenous nerve, helping to form the patellar plexus. Its outer branch communicates, above, with the crural branch of the genito-crural nerve; and the inner branch with the internal cutaneous nerve below. The Sartorius muscle is supplied by this or the following nerve.

The *internal cutaneous nerve* passes obliquely across the upper part of the sheath of the femoral artery, and divides in front, or at the inner side of that vessel, into two branches, anterior and posterior or internal.

The *anterior branch* runs downwards on the Sartorius, perforates the fascia lata at the lower third of the thigh, and divides into two branches: one of which supplies the integument as low down as the inner side of the knee; the other crosses to the outer side of the patella, communicating in its course with the *nervus cutaneus patellæ*, a branch of the internal saphenous nerve.

The *posterior or internal branch* descends along the inner border of the Sartorius muscle to the knee, where it pierces the fascia lata, communicates with the long saphenous nerve, and gives off several cutaneous branches. The nerve then passes down the inner side of the leg, to the integument of which it is distributed. This nerve, beneath the fascia lata, at the lower border of the Adductor longus, joins in a plexiform network by uniting with branches of the long saphenous and obturator nerves (fig. 511). When the communicating branch from the obturator nerve is large and continued to the integument of the leg, the inner branch of the internal cutaneous is small, and terminates at the plexus, occasionally giving off a few cutaneous filaments.

The internal cutaneous nerve, before dividing, gives off a few filaments, which pierce the fascia lata, to supply the integument of the inner side of the thigh, accompanying the long saphenous vein. One of these filaments passes through the saphenous opening; a second becomes subcutaneous about the middle of the thigh; and a third pierces the fascia at its lower third.

The *long or internal saphenous nerve* is the largest of the cutaneous branches of the anterior crural. It approaches the femoral artery where this vessel passes beneath the Sartorius, and lies on its outer side, beneath the aponeurotic covering of Hunter's canal, as far as the opening in the lower part of the Adductor magnus. It then quits the artery, and descends vertically along the inner side of the knee, beneath the Sartorius, pierces the fascia lata, opposite the interval between the tendons of the Sartorius and Gracilis, and becomes subcutaneous. The nerve then passes along the inner side of the leg, accompanied by the internal saphenous vein, descends behind the internal border of the tibia, and, at the lower third of the leg, divides into two branches: one continues its course along the margin of the tibia, terminating at the inner ankle; the other passes in front of the ankle, and is distributed to the integument along the inner side of the foot, as far as the great toe, communicating with the internal branch of the musculo-cutaneous nerve.

*Branches.*—The long saphenous nerve about the middle of the thigh gives off

a communicating branch, which joins the plexus formed by the obturator and internal cutaneous nerves.

At the inner side of the knee it gives off a large branch (*nervus cutaneus patellæ*) which pierces the Sartorius and fascia lata, and is distributed to the integument in front of the patella. This nerve communicates above the knee with the anterior branch of the internal cutaneous and with the middle cutaneous; below the knee, with other branches of the long saphenous; and, on the outer side of the joint, with branches of the external cutaneous nerve, forming a plexiform network, the *plexus patellæ*. The cutaneous nerve of the patella is occasionally small, and terminates by joining the internal cutaneous, which supplies its place in front of the knee.

Below the knee, the branches of the long saphenous nerve are distributed to the integument of the front and inner side of the leg, communicating with the cutaneous branches from the internal cutaneous, or from the obturator nerve.

The *muscular branches* supply the Pectineus and all the muscles on the front of the thigh, except the Tensor vaginae femoris which is supplied from the superior gluteal nerve, and the Sartorius which is supplied by filaments from the middle or internal cutaneous nerves.

The *branches to the Pectineus*, usually two in number, pass inwards behind the femoral vessels, and enter the muscle on its anterior surface. Sometimes one of these nerves is given off in the pelvis, and is then often united with the accessory obturator.

The *branch to the Rectus muscle* enters its under surface high up, sending off a small filament to the hip-joint.

The *branch to the Vastus externus*, of large size, follows the course of the descending branch of the external circumflex artery to the lower part of the muscle. It gives off an articular filament to the knee-joint.

The *branch to the Vastus internus* is a long branch which runs down on the outer side of the femoral vessels in company with the internal saphenous nerve for its upper part. It enters the muscle about its middle, and gives off a filament, which can usually be traced downwards on the surface of the muscle to the knee-joint.

The *branch to the Crureus* enters the muscle on its anterior surface about the middle of the thigh, and sends a filament through the muscle to the Subcrureus.

The *articular branch to the hip-joint* is derived from the nerve to the Rectus.

The *articular branches to the knee-joint* are two in number. One, a long, slender filament, is derived from the nerve to the Vastus externus. It penetrates the capsular ligament of the joint on its anterior aspect. The other is derived from the nerve to the Vastus internus. It can usually be traced downwards on the surface of this muscle to near the joint; it then penetrates the muscular fibres, and accompanies the deep branch of the anastomotica magna artery, pierces the capsular ligament of the joint on its inner side, and supplies the synovial membrane.

## THE SACRAL AND COCCYGEAL NERVES

The *sacral nerves* are five in number on each side. The four upper ones pass from the sacral canal, through the sacral foramina; the fifth through the foramen between the sacrum and coccyx.

The *roots of the upper sacral (and lumbar) nerves* are the largest of all the spinal nerves; whilst those of the lowest sacral and coccygeal nerve are the smallest. They are of very considerable length, being longer than those of any of the other spinal nerves, on account of the spinal cord not extending beyond the first lumbar vertebra. From their great length, and the appearance they



present in connection with the spinal cord, the roots of origin of these nerves are called collectively the *cauda equina*.

Each sacral and coccygeal nerve separates into two divisions, posterior and anterior.

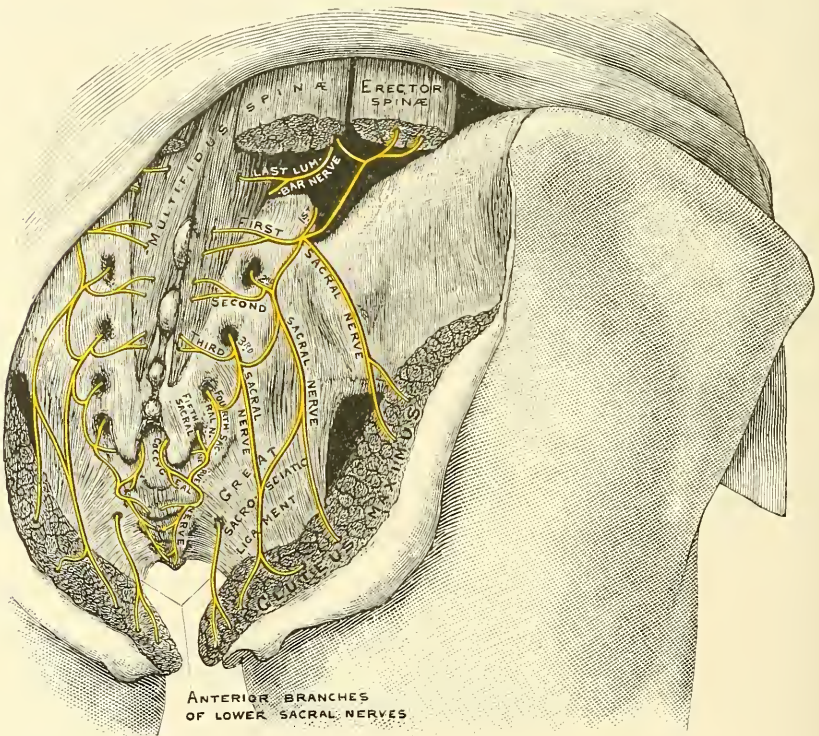
The **posterior divisions of the sacral nerves** (fig. 512) are small, diminish in size from above downwards, and emerge, except the last, from the sacral canal by the posterior sacral foramina.

The *three upper ones* are covered, at their exit from the sacral canal, by the Multifidus spinæ, and divide into internal and external branches.

The *internal branches* are small, and supply the Multifidus spinæ.

The *external branches* join with one another, and with the last lumbar and fourth sacral nerves, by means of communicating loops. These branches pass outwards to the outer surface of the great sacro-sciatic ligament, where they form a second series of loops beneath the Gluteus maximus. Cutaneous branches from

FIG. 512.—The posterior sacral nerves.



this second series of loops, usually three in number, pierce the Gluteus maximus: one near the posterior inferior spine of the ilium; another opposite the end of the sacrum; and the third midway between the other two. They supply the integument over the posterior part of the gluteal region.

The *posterior divisions of the two lower sacral nerves* are situated below the Multifidus spinæ. They are of small size, and do not divide into internal and external branches, but join with each other, and with the coccygeal nerve, so as to form loops on the back of the sacrum, filaments from which supply the Extensor coccygis and the integument over the coccyx.

The **coccygeal nerve** divides into its anterior and posterior division in the spinal canal. The *posterior division* is the smaller. It does not divide, but receives, as already mentioned, a communicating branch from the last sacral, and is lost in the integument over the back of the coccyx.

The **anterior divisions of the sacral nerves** diminish in size from above down-

wards. The four upper ones emerge from the anterior sacral foramina: the anterior division of the fifth, after emerging from the spinal canal through its terminal opening, curves forwards between the sacrum and the coccyx. All the anterior sacral nerves communicate with the sacral ganglia of the sympathetic, at their exit from the sacral foramina. The *first nerve*, of large size, unites with the lumbo-sacral cord, formed by the fifth lumbar, and a branch from the fourth. The *second*, equal in size to the preceding, and a *third*, about one-fourth the size of the second, unite with this trunk, and form, with a small fasciculus from the fourth, the *sacral plexus*, a visceral branch being given off from the third nerve to the bladder.

The **fourth anterior sacral nerve** sends a branch to join the sacral plexus. The remaining portion of the nerve divides into visceral and muscular branches; and a communicating filament descends to join the fifth sacral nerve. The *visceral branches* are distributed to the viscera of the pelvis, communicating with the sympathetic nerve. These branches ascend upon the rectum and bladder, and in the female upon the vagina, communicating with branches of the sympathetic from the pelvic plexus. The *muscular branches* are distributed to the Levator ani, Coccygeus, and Sphincter ani. The branch to the Sphincter ani pierces the Levator ani, so as to reach the ischio-rectal fossa, where it is found lying in front of the coccyx. Cutaneous filaments arise from the latter branch, which supply the integument between the anus and coccyx. Another cutaneous branch is frequently given off from this nerve, though sometimes from the pudic (Schwalbe). It perforates the great sacro-sciatic ligament, and, winding round the lower border of the Gluteus maximus, supplies the skin over the lower and inner part of this muscle.

The **fifth anterior sacral nerve**, after passing from the lower end of the sacral canal, curves forwards through the fifth sacral foramen, formed between the lower part of the sacrum and the transverse process of the first piece of the coccyx. It pierces the Coccygeus muscle, and descends upon its anterior surface to near the tip of the coccyx, where it again perforates the muscle, to be distributed to the integument over the back part and side of the coccyx. This nerve communicates above with the fourth sacral, and below with the coccygeal nerve, and supplies the Coccygeus muscle.

The **anterior division of the coccygeal nerve** is a delicate filament which escapes at the termination of the sacral canal; it passes downwards behind the rudimentary transverse process of the first piece of the coccyx, and curves forwards, through the notch between the first and second pieces, piercing the Coccygeus muscle and descending on its anterior surface to near the tip of the coccyx, where it again pierces the muscle, to be distributed to the integument over the back part and side of the coccyx. It is joined by a branch from the fifth anterior sacral as it descends on the surface of the Coccygeus muscle.

#### SACRAL PLEXUS (fig. 513)

The **sacral plexus** is formed by the lumbo-sacral cord, the anterior divisions of the three upper sacral nerves, and part of that of the fourth. These nerves proceed in different directions: the upper ones obliquely downwards and outwards, the lower one nearly horizontally, and they all unite into two cords: an *upper* and larger which is formed by the lumbo-sacral cord with the first, second, and the greater part of the third sacral nerves; and a *lower* and smaller formed by the remainder of the third, with a portion of the fourth sacral nerve. The upper cord is prolonged into the great sciatic nerve and the lower into the pudic. Frequently a small filament is given off from the second sacral nerve to join the lower cord.

The sacral plexus is triangular in form, its base corresponding with the exit of the nerves from the sacrum, its apex with the lower part of the great sacro-sciatic foramen. It rests upon the anterior surface of the Pyriformis, and is



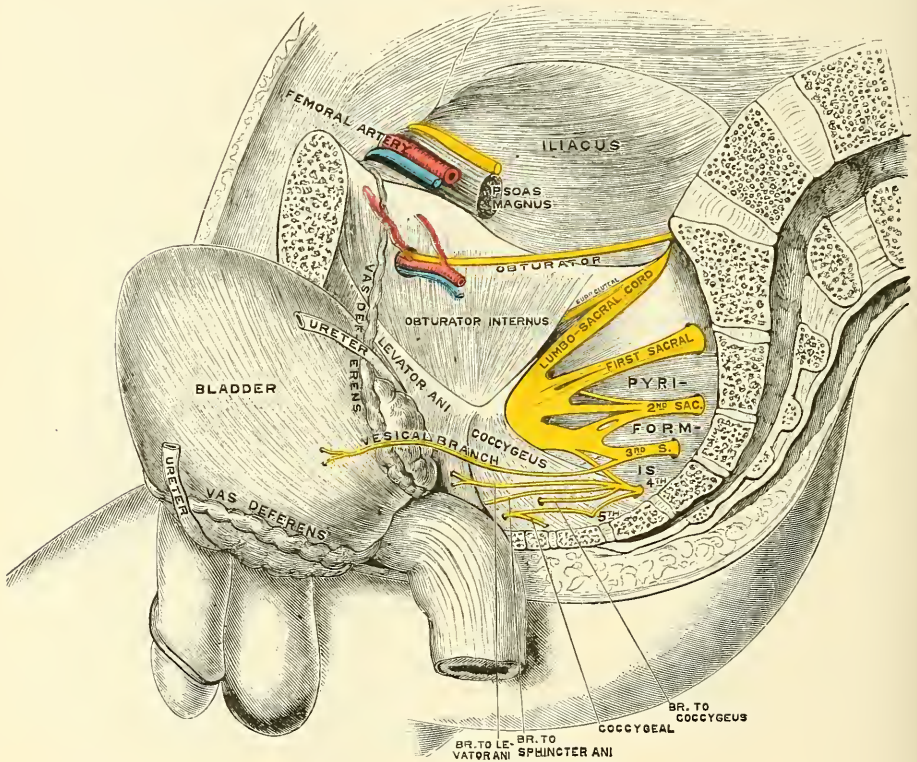
covered in front by the pelvic fascia, which separates it from the sciatic and pudic branches of the internal iliac artery, and from the viscera of the pelvis.

The branches of the sacral plexus are :

	Collateral branches	{	Muscular
			Superior Gluteal
			Inferior Gluteal
			Small Sciatic
	Terminal branches	{	Pudic
			Great Sciatic

The **muscular branches** supply the Piriformis, Obturator internus, the two Gemelli, and the Quadratus femoris. The branch to the Piriformis arises from

FIG. 513.—Side view of pelvis, showing sacral nerves.



the upper two sacral nerves before they enter the plexus ; the branch to the Obturator internus arises at the junction of the lumbo-sacral and first sacral nerves : it passes out of the pelvis through the great sacro-sciatic foramen, crosses the spine of the ischium, and re-enters the pelvis through the lesser sacro-sciatic foramen to enter the inner surface of the Obturator internus ; the branch to the Gemellus superior arises in common with the nerve to the Obturator internus : it enters the muscle at the upper part of its posterior surface ; the small branch to the Gemellus inferior and Quadratus femoris also arises from the upper part of the plexus : it passes through the great sacro-sciatic foramen, and courses down beneath the Gemelli and tendon of the Obturator internus, and supplies the muscles on their deep or anterior surface. It gives off an articular branch to the hip-joint. A second articular branch is occasionally derived from the upper part of the sacral plexus.

The **Superior Gluteal Nerve** (fig. 515) arises from the back part of the lumbo-sacral cord, with some filaments from the first sacral nerve ; it passes from the



pelvis through the great sacro-sciatic foramen above the Piriformis muscle, accompanied by the gluteal vessels, and divides into a superior and an inferior branch.

The *superior branch* follows the line of origin of the Gluteus minimus, and supplies the Gluteus medius.

The *inferior branch* crosses obliquely between the Gluteus minimus and medius, distributing filaments to both these muscles, and terminates in the Tensor vaginæ femoris, extending nearly to its lower end.

The **Inferior Gluteal** arises from the lumbo-sacral cord, and first and second sacral nerves, and is intimately connected with the small sciatic at its origin. It passes out of the pelvis through the great sciatic notch, beneath the Piriformis muscle, and dividing into a number of branches enters the Gluteus maximus muscle, on its under surface. It gives off a cutaneous branch, which winds round the lower border of the Gluteus maximus muscle to supply the skin of the buttock. This cutaneous filament frequently comes off as a separate branch from the sacral plexus, and is termed the perforating cutaneous nerve.

The **Small Sciatic Nerve** (fig. 515) supplies the integument of the perinæum and back part of the thigh and leg. It is usually formed by the union of two branches, which arise from the second and third nerves of the sacral plexus. It issues from the pelvis through the great sacro-sciatic foramen below the Piriformis muscle, descends beneath the Gluteus maximus with the sciatic artery, and at the lower border of that muscle passes along the back part of the thigh, beneath the fascia lata, to the lower part of the popliteal region, where it pierces the fascia and becomes cutaneous. It then accompanies the external saphenous vein to about the middle of the leg, its terminal filaments communicating with the external saphenous nerve.

The branches of the small sciatic nerve are all cutaneous, and consist of four groups: internal, external, ascending, and descending.

The *internal cutaneous branches* are distributed to the skin at the upper and inner side of the thigh, on its posterior aspect. One branch, longer than the rest, the *inferior pudendal*, curves forward below the tuber ischii, pierces the fascia lata, and passes forwards beneath the superficial fascia of the perinæum to be distributed to the integument of the scrotum in the male and the labium in the female, communicating with the superficial perineal and inferior hæmorrhoidal nerves.

The *external cutaneous branches* consist of two or three filaments, which are distributed to the skin at the upper and outer side of the thigh on its posterior aspect, as far down as the middle of that region.

The *ascending cutaneous branches* consist of two or three filaments, which turn upwards round the lower border of the Gluteus maximus, to supply the integument covering its surface.

The *descending cutaneous branches* are given off from the lesser sciatic nerve as it descends beneath the fascia of the thigh; they supply the integument of the back part of the thigh, popliteal region, and upper part of the leg.

The **Pudic nerve** is the direct continuation of the lower cord of the sacral plexus, and derives its fibres from the third and fourth sacral nerves and frequently from the second also. It leaves the pelvis, through the great sacro-sciatic foramen, below the Piriformis. It then crosses the spine of the ischium, and re-enters the pelvis through the lesser sacro-sciatic foramen. It accompanies the pudic vessels upwards and forwards along the outer wall of the ischio-rectal fossa, being contained in a sheath of the obturator fascia, and divides into two terminal branches, the perineal nerve, and the dorsal nerve of the penis or clitoris. Before its division, it gives off the inferior hæmorrhoidal nerve.

The *inferior hæmorrhoidal nerve* is occasionally derived separately from the sacral plexus. It passes across the ischio-rectal fossa, with its accompanying vessels, towards the lower end of the rectum, and is distributed to the integument round the anus. Branches of this nerve communicate with the inferior pudendal and superficial perineal nerves at the fore part of the perinæum.

FIG. 514.—Cutaneous nerves of lower extremity. Posterior view.

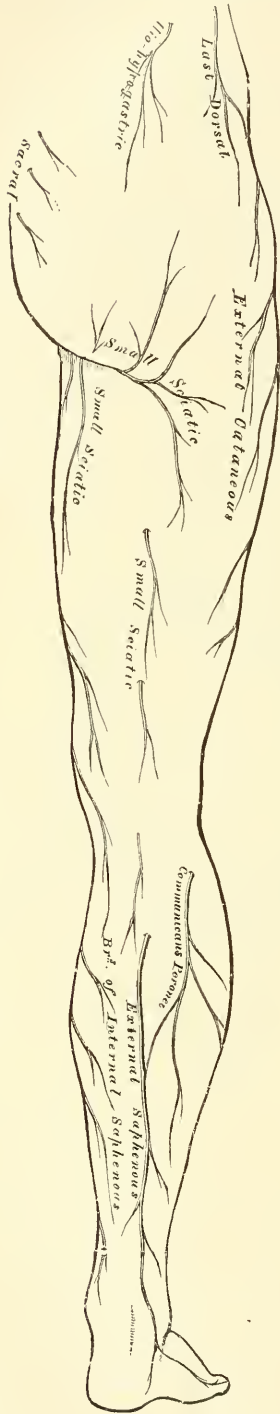
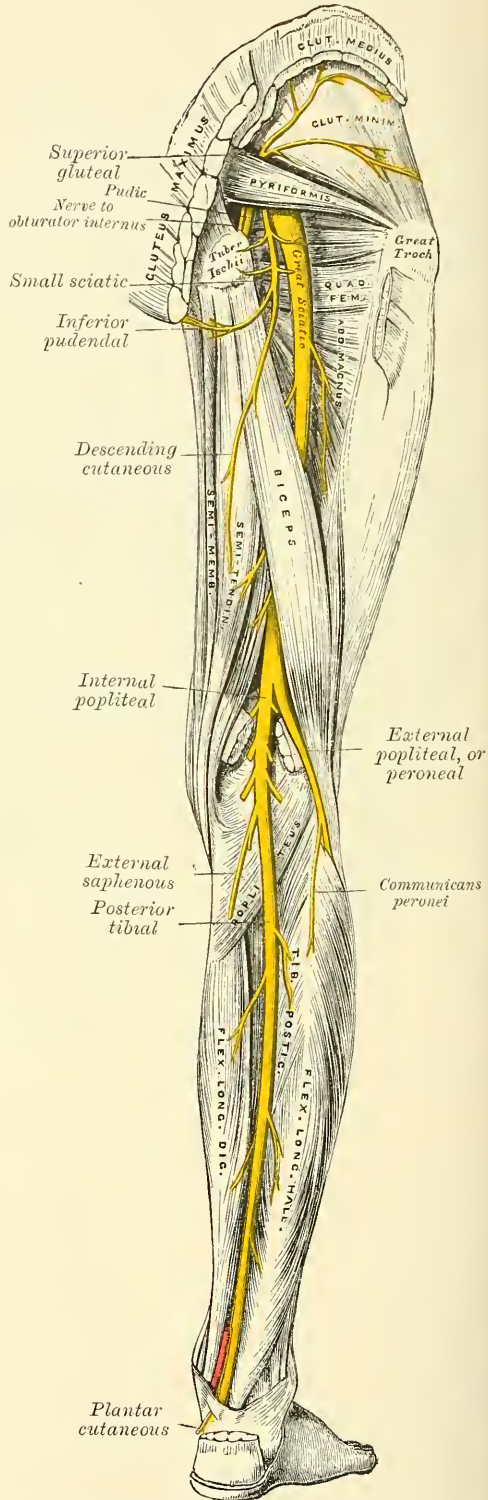


FIG. 515.—Nerves of the lower extremity.\* Posterior view.



\* N.B.—In this diagram the external saphenous and communicans peronei are not in their normal position. They have been displaced by the removal of the superficial muscles.

The *perineal nerve*, the inferior and larger of the two terminal branches of the pudic, is situated below the pudic artery. It accompanies the superficial perineal artery in the perinæum, dividing into cutaneous and muscular branches.

The cutaneous branches (superficial perineal) are two in number, posterior and anterior. The *posterior* or *external branch* passes forwards along the outer side of the perineal space parallel to the inferior pudendal nerve, and is distributed to the skin of the scrotum. It communicates with the inferior hæmorrhoidal, the inferior pudendal, and the other superficial perineal nerve. The *anterior* or *internal branch* passes forwards nearer to the middle line, to be distributed to the inner and back part of the scrotum. Both these nerves supply the labia majora in the female.

The muscular branches are distributed to the Transversus perinæi, Accelerator urinæ, Erector penis, and Compressor urethræ. A distinct branch is given off from the nerve to the Accelerator urinæ, which pierces this muscle, and supplies the corpus spongiosum, ending in the mucous membrane of the urethra. This is the nerve to the bulb.

The *dorsal nerve of the penis* is the deepest division of the pudic nerve; it accompanies the pudic artery along the ramus of the ischium; piercing the superior layer of the deep perineal fascia, it runs forward along the inner margin of the ramus of the os pubis, between the two layers of the deep fascia. It then pierces the inferior layer, and, in company with the dorsal artery of the penis, passes through the suspensory ligament, and, running forwards, is distributed to the glans. On the penis, this nerve gives off a cutaneous branch, which runs along the side of the organ; it is joined with branches of the sympathetic, and supplies the integument of the upper surface and sides of the penis and prepuce, giving a large branch to the corpus cavernosum.

In the female the dorsal nerve is very small, and supplies the clitoris.

The **Great Sciatic Nerve** (fig. 515) supplies nearly the whole of the integument of the leg, the muscles of the back of the thigh, and those of the leg and foot. It is the largest nervous cord in the body, measuring three-quarters of an inch in breadth, and is the continuation of the upper division of the sacral plexus. It passes out of the pelvis through the great sacro-sciatic foramen, below the Piriformis muscle. It descends between the trochanter major and tuberosity of the ischium, along the back part of the thigh to about its lower third, where it divides into two large branches, the *internal* and *external popliteal nerves*.

This division may take place at any point between the sacral plexus and the lower third of the thigh. When the division occurs at the plexus, the two nerves descend together, side by side; or they may be separated, at their commencement, by the interposition of part or the whole of the Piriformis muscle. As the nerve descends along the back of the thigh, it rests at first upon the External rotator muscles, in company with the small sciatic nerve and artery, being covered by the Gluteus maximus; lower down, it lies upon the Adductor magnus, and is covered by the long head of the Biceps.

The *branches* of the nerve, before its division, are articular and muscular.

The *articular branches* arise from the upper part of the nerve; they supply the hip-joint, perforating its fibrous capsule posteriorly. These branches are sometimes derived from the sacral plexus.

The *muscular branches* are distributed to the Flexors of the leg: viz. the Biceps, Semitendinosus, and Semimembranosus, and a branch to the Adductor magnus. These branches are given off beneath the Biceps muscle.

The **Internal Popliteal Nerve**, the larger of the two terminal branches of the great sciatic, descends along the back part of the thigh, through the middle of the popliteal space to the lower part of the Popliteus muscle, where it passes with the artery beneath the arch of the Soleus, and becomes the posterior tibial. It is overlapped by the hamstring muscles above, and then becomes more superficial, and lies to the outer side of, and some distance from, the popliteal vessels;



opposite the knee-joint, it is in close relation with the vessels, and crosses to the inner side of the artery. Below, it is overlapped by the Gastrocnemius.

The *branches* of this nerve are, articular, muscular, and a cutaneous branch the *communicans poplitei* nerve.

The *articular branches*, usually three in number, supply the knee-joint; two of these branches accompany the superior and inferior internal articular arteries; and a third, the azygos articular artery.

The *muscular branches*, four or five in number, arise from the nerve as it lies between the two heads of the Gastrocnemius muscle; they supply that muscle, the Plantaris, Soleus, and Popliteus. The filaments which supply the Popliteus turn round its lower border and are distributed to its deep surface.

The *communicans poplitei* descends between the two heads of the Gastrocnemius muscle, and, about the middle of the back of the leg, pierces the deep fascia, and joins a communicating branch (*communicans peronei*) from the external popliteal nerve to form the external, or short, saphenous (fig. 514).

The *external saphenous nerve*, formed by the cutaneous branches of the internal and external popliteal nerves, passes downwards and outwards near the outer margin of the tendo Achillis, lying close to the external saphenous vein, to the interval between the external malleolus and the os calcis. It winds round the outer malleolus, and is distributed to the integument along the outer side of the foot and little toe, communicating on the dorsum of the foot with the musculocutaneous nerve. In the leg, its branches communicate with those of the small sciatic.

The **Posterior Tibial Nerve** (fig. 515) commences at the lower border of the Popliteus muscle, and passes along the back part of the leg with the posterior tibial vessels to the interval between the inner malleolus and the heel, where it divides into the *external* and *internal plantar nerves*. It lies upon the deep muscles of the leg, and is covered in the upper part by the muscles of the calf, lower down by the skin and fascia. In the upper part of its course, it lies to the inner side of the posterior tibial artery; but it soon crosses that vessel, and lies to its outer side as far as the ankle. In the lower third of the leg, it is placed parallel with the inner margin of the tendo Achillis.

The *branches of the posterior tibial nerve* are muscular, plantar cutaneous, and articular.

The *muscular branches* arise either separately or by a common trunk from the upper part of the nerve. They supply the Tibialis posticus, Flexor longus digitorum, and Flexor longus hallucis muscles; the branch to the latter muscle accompanying the peroneal artery.

The *plantar cutaneous branch* perforates the internal annular ligament, and supplies the integument of the heel and inner side of the sole of the foot.

The *articular branch* is given off just above the bifurcation of the nerve, and supplies the ankle-joint.

The **internal plantar nerve** (fig. 516), the larger of the two terminal branches of the posterior tibial, accompanies the internal plantar artery along the inner side of the foot. From its origin at the inner ankle it passes beneath the Abductor hallucis, and then forwards between this muscle and the Flexor brevis digitorum, divides opposite the bases of the metatarsal bones into four digital branches, and communicates with the external plantar nerve.

*Branches.*—In its course, the internal plantar nerve gives off *cutaneous branches*, which pierce the plantar fascia, and supply the integument of the sole of the foot; *muscular branches*, which supply the Abductor hallucis and Flexor brevis digitorum; *articular branches* to the articulations of the tarsus and metatarsus; and *four digital branches*. These pass between the divisions of the plantar fascia in the clefts between the toes, and are distributed in the following manner: The *first* supplies the inner border of the great toe, and sends a filament to the Flexor brevis hallucis muscle; the *second* bifurcates, to supply the adjacent sides of the great and second toes, sending a filament to the First

lumbrical muscle; the *third digital branch* supplies the adjacent sides of the second and third toes\*; the *fourth* supplies the corresponding sides of the third and fourth toes, and receives a communicating branch from the external plantar nerve. Each digital nerve gives off cutaneous and articular filaments; and opposite the last phalanx sends a dorsal branch, which supplies the structure round the nail, the continuation of the nerve being distributed to the ball of the toe. It will be observed, that the distribution of these branches is precisely similar to that of the median nerve in the hand.

The **external plantar nerve**, the smaller of the two, completes the nervous supply to the structures of the sole of the foot, being distributed to the little toe and one-half of the fourth, as well as to most of the deep muscles, its distribution being similar to that of the ulnar in the hand. It passes obliquely forwards with the external plantar artery to the outer side of the foot, lying between the Flexor brevis digitorum and Flexor accessorius; and, in the interval between the former muscle and Abductor minimi digiti, divides into a superficial and a deep branch. Before its division, it supplies the Flexor accessorius and Abductor minimi digiti.

The *superficial branch* separates into two digital nerves: one, the smaller of the two, supplies the outer side of the little toe, the Flexor brevis minimi digiti, and the two Interosseous muscles of the fourth metatarsal space; the other and larger digital branch supplies the adjoining sides of the fourth and fifth toes, and communicates with the internal plantar nerve.

The *deep or muscular branch* accompanies the external plantar artery into the deep part of the sole of the foot, beneath the tendons of the Flexor muscles and Adductor transversus hallucis, and supplies all the Interossei (except those in the fourth metatarsal space), the three outer Lumbricales, the Adductor obliquus hallucis, and the Adductor transversus hallucis.

#### The External Popliteal or Peroneal

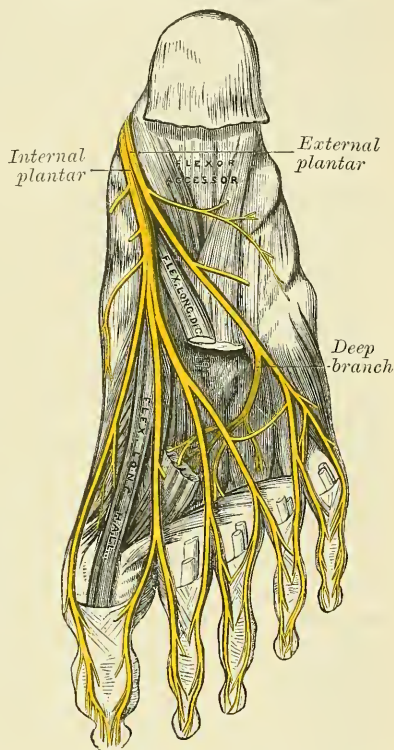
**Nerve** (fig. 515), about one-half the size of the internal popliteal, descends obliquely along the outer side of the popliteal space to the head of the fibula, close to the inner margin of the Biceps muscle. It is easily felt beneath the skin behind the head of the fibula, at the inner side of the tendon of the Biceps. It passes between the tendon of the Biceps and outer head of the Gastrocnemius muscle, winds round the neck of the fibula, between the Peroneus longus and the bone, and divides beneath the muscle into the anterior tibial and musculo-cutaneous nerves.

The *branches of the peroneal nerve*, previous to its division, are articular and cutaneous.

The *articular branches* are three in number; two of these accompany the superior and inferior external articular arteries to the outer side of the knee. The upper one occasionally arises from the great sciatic nerve before its bifurcation. The third (*recurrent*) articular nerve is given off at the point of division of the peroneal nerve; it ascends with the anterior recurrent tibial artery through the Tibialis anticus muscle to the front of the knee, which it supplies.

The *cutaneous branches*, two or three in number, supply the integument along

FIG. 516.—The plantar nerves.



\* See footnote, p. 541.



the back part and outer side of the leg, as far as its middle or lower part; one of these, larger than the rest, the *communicans peronei*, arises near the head of the fibula, crosses the external head of the Gastrocnemius to the middle of the leg, and joins with the *communicans poplitei* to form the external saphenous. This nerve occasionally exists as a separate branch, which is continued down as far as the heel.

The **Anterior Tibial Nerve** (fig. 511) commences at the bifurcation of the peroneal nerve, between the fibula and upper part of the Peroneus longus, passes obliquely forwards beneath the Extensor longus digitorum to the fore part of the interosseous membrane, and reaches the other side of the anterior tibial artery above the middle of the leg; it then descends with the artery to the front of the ankle-joint, where it divides into an external and an internal branch. This nerve lies at first on the outer side of the anterior tibial artery, then in front of it, and again at its outer side at the ankle-joint.

The *branches of the anterior tibial nerve*, in its course through the leg, are the muscular branches to the Tibialis anticus, Extensor longus digitorum, Peroneus tertius, and Extensor proprius hallucis muscles, and an *articular branch* to the ankle-joint.

The *external or tarsal branch of the anterior tibial* passes outwards across the tarsus, beneath the Extensor brevis digitorum, and, having become ganglionic like the posterior interosseous nerve at the wrist, supplies the Extensor brevis digitorum. From the ganglion are given off three minute *interosseous branches* which supply the tarsal joints and the metatarso-phalangeal joints of the second, third, and fourth toes. The first of these sends a filament to the second dorsal interosseous muscle.

The *internal branch*, the continuation of the nerve, accompanies the dorsalis pedis artery along the inner side of the dorsum of the foot, and, at the first interosseous space, divides into two branches, which supply the adjacent sides of the great and second toes, communicating with the internal branch of the musculo-cutaneous nerve. Before it divides it gives off an *interosseous branch* to the first space, which supplies the metatarso-phalangeal joint of the great toe and sends a filament to the First dorsal interosseous muscle.

The **Musculo-cutaneous Nerve** (fig. 511) supplies the muscles on the fibular side of the leg, and the integument of the dorsum of the foot. It passes forwards between the Peronei muscles and the Extensor longus digitorum, pierces the deep fascia at the lower third of the leg, on its front and outer side, and divides into two branches. This nerve, in its course between the muscles, gives off muscular branches to the Peroneus longus and brevis, and cutaneous filaments to the integument of the lower part of the leg.

The *internal branch of the musculo-cutaneous nerve* passes in front of the ankle-joint, and along the dorsum of the foot, supplying the inner side of the great toe, and the adjoining sides of the second and third toes. It also supplies the integument of the inner ankle and inner side of the foot, communicating with the internal saphenous nerve, and joins with the anterior tibial nerve, between the great and second toes.

The *external branch*, the larger, passes along the outer side of the dorsum of the foot, to be distributed to the adjoining sides of the third, fourth, and fifth toes. It also supplies the integument of the outer ankle and outer side of the foot, communicating with the short saphenous nerve.

The distribution of these branches of the musculo-cutaneous nerve will be found to vary; together, they supply all the toes excepting the outer side of the little toe, and the adjoining sides of the great and second toes, the former being supplied by the external saphenous, and the latter by the internal branch of the anterior tibial.

*Surgical Anatomy.*—The lumbar plexus passes through the Psoas muscle, and, therefore, in psoas abscess, any or all of its branches may be irritated, causing severe pain in the



part to which the irritated nerves are distributed. The genito-crural nerve is the one which is most frequently implicated. This nerve is also of importance as it is concerned in one of the principal reflexes employed in the investigation of diseases of the spine. If the skin over the inner side of the thigh just below Poupart's ligament, the part supplied by the crural branch of the genito-crural nerve, be gently tickled in a male child, the testicle will be noticed to be drawn upwards, through the action of the Cremaster muscle, supplied by the genital branch of the same nerve. The same result may sometimes be noticed in adults, and can almost always be produced by severe stimulation. This reflex, when present, shows that the portion of the cord from which the first and second lumbar nerves are derived is in a normal condition.

The anterior crural nerve is in danger of being injured in fractures of the true pelvis, since the fracture most commonly takes place through the ascending ramus of the os pubis, at or near the point where this nerve crosses the bone. It is also liable to be injured in fractures and dislocations of the femur, and is likely to be pressed upon, and its functions impaired, in some tumours growing in the pelvis. Moreover, on account of its superficial position, it is exposed to injury in wounds and stabs in the groin. When this nerve is paralysed, the patient is unable to flex his hip completely, on account of the loss of motion in the Iliacus; or to extend the knee on the thigh, on account of paralysis of the Quadriceps extensor cruris; there is complete paralysis of the Sartorius, and partial paralysis of the Pectineus. There is loss of sensation down the front and inner side of the thigh, except in that part supplied by the crural branch of the genito-crural, and by the ilio-inguinal. There is also loss of sensation down the inner side of the leg and foot as far as the ball of the great toe.

The obturator nerve is of special surgical interest. It is rarely paralysed alone, but occasionally in association with the anterior crural. The principal interest attached to it is in connection with its supply to the knee; pain in the knee being symptomatic of many diseases in which the trunk of this nerve, or one of its branches, is irritated. Thus it is well known that in the earlier stages of hip-joint disease the patient does not complain of pain in that articulation, but on the inner side of the knee, or in the knee-joint itself, both these articulations being supplied by the obturator nerve, the final distribution of the nerve being to the knee-joint. Again, the same thing occurs in sacro-iliac disease: pain is complained of in the knee-joint, or on its inner side. The obturator nerve is in close relationship with the sacro-iliac articulation, passing over it, and, according to some anatomists, distributing filaments to it. Again, in cancer of the sigmoid flexure, and even in cases where masses of hardened feces are impacted in this portion of the gut, pain is complained of in the knee. The obturator nerve lies beneath the sigmoid flexure, and is readily pressed upon and irritated when disease exists in this part of the intestine. Finally, pain in the knee forms an important diagnostic sign in obturator hernia. The hernial protrusion as it passes out through the opening in the obturator membrane presses upon the nerve and causes pain in the parts supplied by its peripheral filaments. When the obturator nerve is paralysed, the patient is unable to press his knees together or to cross one leg over the other, on account of paralysis of the Adductor muscles. Rotation outwards of the thigh is impaired from paralysis of the Obturator externus. Sometimes there is loss of sensation in the upper half of the inner side of the leg.

The great sciatic nerve is liable to be pressed upon by various forms of pelvic tumours, giving rise to pain along its trunk, to which the term sciatica is applied. Tumours growing from the pelvic viscera, or bones, aneurisms of some of the branches of the internal iliac artery, calculus in the bladder when of large size, accumulation of feces in the rectum, may all cause pressure on the nerve inside the pelvis, and give rise to sciatica. Outside the pelvis exposure to cold, violent movements of the hip-joint, exostoses or other tumours growing from the margin of the sacro-sciatic foramen, may also give rise to the same condition. When paralysed there is loss of motion in all the muscles below the knee, and loss of sensation in the same situation, except the upper half of the back of the leg, supplied by the small sciatic and the upper half of the inner side of the leg, when the communicating branch of the obturator is large (see page 841).

The sciatic nerve has been frequently cut down upon and stretched, or has been acupunctured for the relief of sciatica. The nerve has also been stretched in cases of locomotor ataxy, the anæsthesia of leprosy, etc. In order to define it on the surface, a point is taken at the junction of the middle and lower third of a line stretching from the posterior superior spine of the ilium to the outer part of the tuber ischii, and a line drawn from this to the middle of the upper part of the popliteal space. The line must be slightly curved with its convexity outwards, and as it passes downwards to the lower border of the Gluteus maximus is slightly nearer the tuber ischii than the great trochanter, as it crosses a line drawn between these two points. The operation of stretching the sciatic nerve is performed by making an incision over the course of the nerve about the centre of the thigh. The skin, superficial structures, and deep fascia having been divided, the interval between the inner and outer hamstrings is to be defined, and these muscles pulled inwards and outwards with retractors. The nerve will be found a little to the inner side of the Biceps. It is to be separated from the surrounding structures, hooked up with the finger, and stretched by steady and continuous traction for two or three minutes. The sciatic nerve may also be stretched by what is known as the 'dry' plan. The patient is laid on

his back, the foot is extended, the leg flexed on the thigh, and the thigh strongly flexed on the abdomen. While the thigh is maintained in this position, the leg is forcibly extended to its full extent, and the foot as fully flexed on the leg.

The position of the external popliteal, close behind the tendon of the Biceps on the outer side of the ham, should be remembered in subcutaneous division of the tendon. After it is divided, a cord often rises up close beside it, which might be mistaken for a small undivided portion of the tendon, and the surgeon might be tempted to reintroduce his knife and divide it. This must never be done, as the cord is the external popliteal nerve, which becomes prominent as soon as the tendon is divided.

## THE SYMPATHETIC NERVE

The **Sympathetic Nervous System** consists of (1) a series of ganglia, connected together by intervening cords, extending from the base of the skull to the coccyx, one on each side of the middle line of the body, partly in front and partly on each side of the vertebral column; (2) of three great gangliated plexuses, or aggregations of nerves and ganglia, situated in front of the spine in the thoracic, abdominal, and pelvic cavities respectively; (3) of smaller ganglia situated in relation with the abdominal viscera; and (4) of numerous nerve-fibres. These latter are of two kinds: *communicating*, by which the ganglia communicate with each other and with the cerebro-spinal nerves; and *distributory*, supplying, in general, all the internal viscera and the coats of the blood-vessels.

Each **gangliated cord** may be traced upwards from the base of the skull into its cavity by an ascending branch, which passes through the carotid canal, forms a plexus on the internal carotid artery, and communicates with the ganglia on the first and second divisions of the fifth nerve. According to some anatomists, the two cords are joined, at their cephalic extremities, by these ascending branches communicating in a small ganglion (the *ganglion of Ribes*), situated upon the anterior communicating artery. The ganglia of these cords are distinguished as cervical, dorsal, lumbar, and sacral, and except in the neck they correspond pretty nearly in number to the vertebræ against which they lie. They may be thus arranged:

Cervical portion	.	.	3	pairs of ganglia.
Dorsal	„	.	12	„ „
Lumbar	„	.	4	„ „
Sacral	„	.	4 OR 5	„ „

In the neck they are situated in front of the transverse processes of the vertebræ; in the dorsal region, in front of the heads of the ribs; in the lumbar region, on the sides of the bodies of the vertebræ; and in the sacral region, in front of the sacrum. As the two cords pass into the pelvis, they converge and unite together in a single ganglion (*ganglion impar*), placed in front of the coccyx. Each ganglion may be regarded as a distinct centre, and, in addition to its branches of distribution, possesses also branches of communication, which communicate with other ganglia and with the cerebro-spinal nerves.

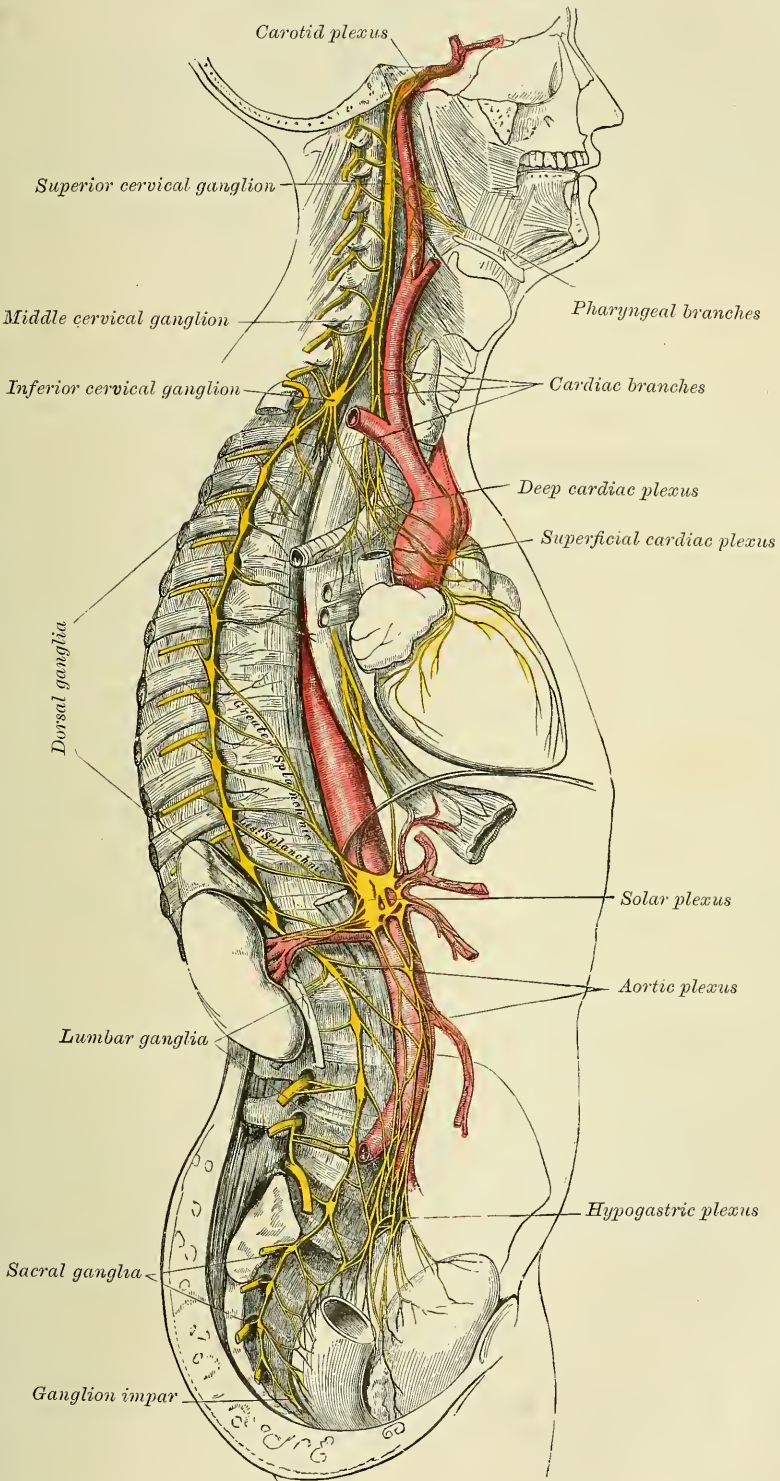
The branches of communication between the ganglia are composed of grey and white nerve-fibres, the latter being continuous with those fibres of the spinal nerves which pass to the ganglia.

The branches of communication between the ganglia and the cerebro-spinal nerves also consist of a white and grey portion; the former proceeding from the spinal nerve *to* the ganglion, the latter passing *from* the ganglion to the spinal nerve, so that a double interchange takes place between the two systems.

The **three great gangliated plexuses** are situated in front of the spine in the thoracic, abdominal, and pelvic regions, and are named respectively, the *cardiac*, the *solar* or *epigastric*, and the *hypogastric plexus*. They consist of collections of nerves and ganglia; the nerves being derived from the gangliated cords, and from the cerebro-spinal nerves. They distribute branches to the viscera.



FIG. 517.—The sympathetic nerve.





Smaller ganglia are also found lying amidst the nerves, some of them of microscopic size, in certain viscera—as, for instance, in the heart, the stomach, and the uterus. They serve as additional centres for the origin of nerve-fibres.

The **branches of distribution** derived from the gangliated cords, from the prevertebral plexuses, and also from the smaller ganglia, are principally destined for the blood-vessels and thoracic and abdominal viscera, supplying the involuntary muscular fibre of the coats of the vessels and the hollow viscera, and the secreting cells, as well as the muscular coats of the vessels in the glandular viscera.

In addition to these various divisions of the sympathetic, the ganglia connected with the three branches of the fifth cranial nerve are believed by some to constitute a part of the sympathetic system. These ganglia have already been described (page 784 *et seq.*).

#### CERVICAL PORTION OF THE GANGLIATED CORD

The cervical portion of the gangliated cord consists of three ganglia on each side, which are distinguished, according to their position, as the superior, middle, and inferior cervical.

The **Superior Cervical Ganglion**, the largest of the three, is placed opposite the second and third cervical vertebræ, and sometimes as low as the fourth or fifth. It is of a reddish-grey colour, and usually fusiform in shape; sometimes broad, and occasionally constricted at intervals, so as to give rise to the opinion that it consists of the coalescence of several smaller ganglia; and it is usually believed that it is formed by the coalescence of the four ganglia, corresponding to the four upper cervical nerves. It is in relation, in front, with the sheath of the internal carotid artery, and internal jugular vein; behind, it lies on the *Rectus capitis anticus major* muscle.

Its branches may be divided into superior, inferior, external, internal, and anterior.

The *superior branch* appears to be a direct prolongation of the ganglion. It is soft in texture, and of a reddish colour. It ascends by the side of the internal carotid artery, and, entering the carotid canal in the temporal bone, divides into two branches, which lie, one on the outer, and the other on the inner side of that vessel.

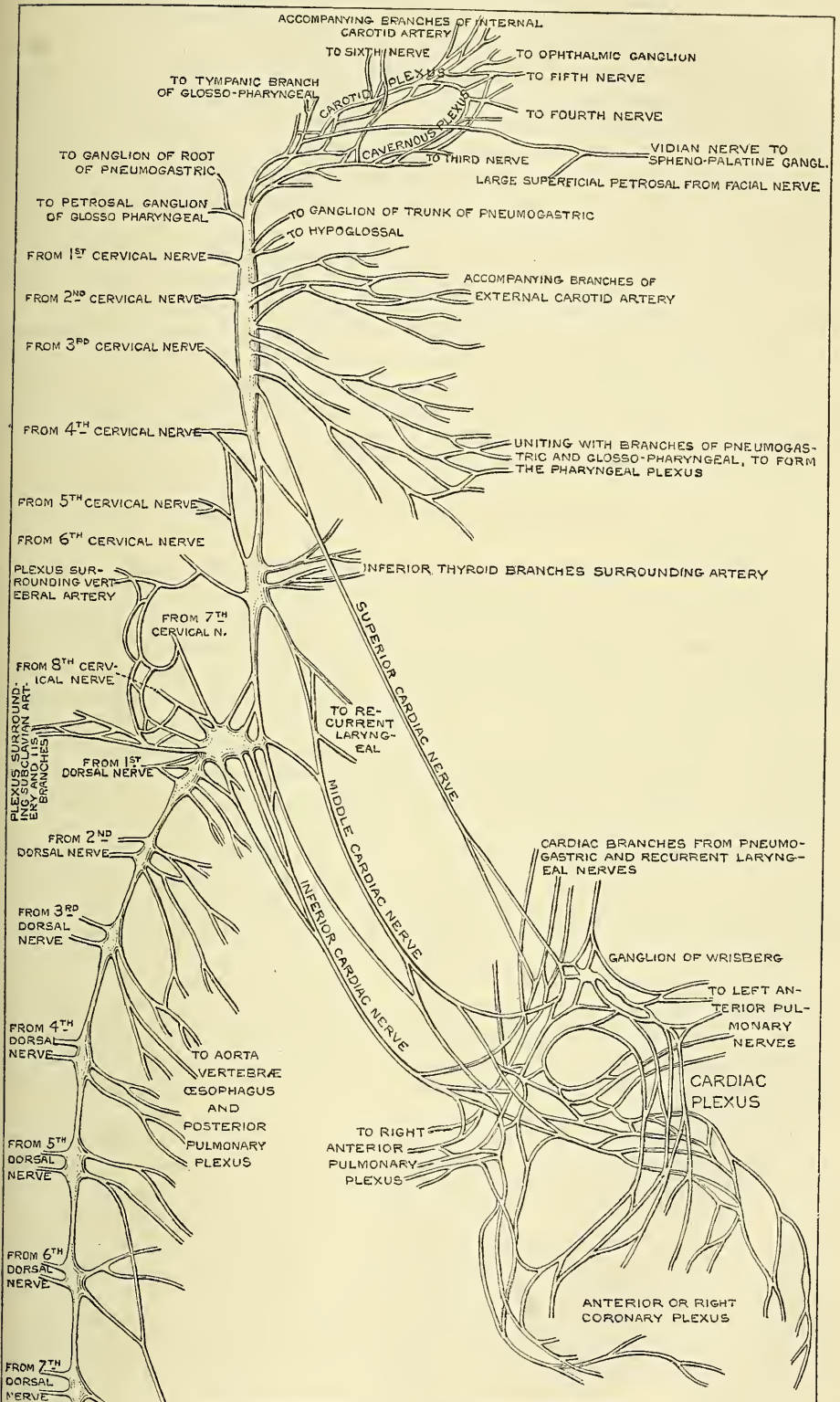
The *outer branch*, the larger of the two, distributes filaments to the internal carotid artery, and forms the *carotid plexus*.

The *inner branch* also distributes filaments to the internal carotid, and, continuing onwards, forms the *cavernous plexus*.

The **carotid plexus** is situated on the outer side of the internal carotid. Filaments from this plexus occasionally form a small gangliform swelling on the under surface of the artery, which is called the carotid ganglion. The carotid plexus communicates with the Gasserian ganglion, with the sixth nerve, and the spheno-palatine ganglion, and distributes filaments to the wall of the carotid artery, and to the *dura mater* (Valentin); while in the carotid canal it communicates with Jacobson's nerve, the tympanic branch of the glosso-pharyngeal.

The *communicating branches with the sixth nerve* consist of one or two filaments which join that nerve as it lies upon the outer side of the internal carotid. Other filaments are also connected with the Gasserian ganglion. The communication with the spheno-palatine ganglion is effected by a branch, the *large deep petrosal*, which is given off from the plexus on the outer side of the artery, and which passes through the cartilage filling up the foramen lacerum medium, and joins the great superficial petrosal to form the Vidian nerve. The Vidian nerve then proceeds along the pterygoid or Vidian canal to the spheno-palatine ganglion. The communication with Jacobson's nerve is effected by two branches, one of which is called the *small deep petrosal nerve*, and the other the *long petrosal*.

FIG. 518.—Plan of the cervical portion of the sympathetic. (After Flower.)



The **cavernous plexus** is situated below, and internal to that part of the internal carotid which is placed by the side of the sella Turcica, in the cavernous sinus, and is formed chiefly by the internal division of the ascending branch from the superior cervical ganglion. It communicates with the third, the fourth, the ophthalmic division of the fifth, and the sixth nerves, and with the ophthalmic ganglion, and distributes filaments to the wall of the internal carotid. The branch of communication with the third nerve joins it at its point of division; the branch to the fourth nerve joins it as it lies on the outer wall of the cavernous sinus; other filaments are connected with the under surface of the trunk of the ophthalmic nerve; and a second filament of communication joins the sixth nerve.

The filament of connection with the ophthalmic ganglion arises from the anterior part of the cavernous plexus; it accompanies the nasal nerve, or continues forwards as a separate branch.

The terminal filaments from the carotid and cavernous plexuses are prolonged along the internal carotid, forming plexuses which entwine round the cerebral and ophthalmic arteries; along the former vessel they may be traced on to the pia mater; along the latter, into the orbit, where they accompany each of the subdivisions of the vessel, a separate plexus passing, with the arteria centralis retinae, into the interior of the eyeball. The filaments prolonged on to the anterior communicating artery form a small ganglion, the *ganglion of Ribes*,\* which serves, as mentioned above, to connect the sympathetic nerves of the right and left sides.

The **inferior or descending branch of the superior cervical ganglion** communicates with the middle cervical ganglion.

The **external branches** are numerous, and communicate with the cranial nerves, and with the four upper spinal nerves. Sometimes the branch to the fourth spinal nerve may come from the cord connecting the upper and middle cervical ganglia. The branches of communication with the cranial nerves consist of delicate filaments, which pass from the superior cervical ganglion to the ganglion of the trunk of the pneumogastric, and to the hypoglossal nerve. A separate filament from the cervical ganglion subdivides and joins the petrosal ganglion of the glosso-pharyngeal, and the ganglion of the root of the pneumogastric in the jugular foramen.

The **internal branches** are three in number: the *pharyngeal*, *laryngeal*, and *superior cardiac nerve*. The *pharyngeal branches* pass inwards to the side of the pharynx, where they join with branches from the glosso-pharyngeal, pneumogastric, and external laryngeal nerves to form the *pharyngeal plexus*. The *laryngeal branches* unite with the superior laryngeal nerve and its branches.

The *superior cardiac nerve* (*nervus superficialis cordis*) arises by two or more branches from the superior cervical ganglion, and occasionally receives a filament from the cord of communication between the first and second cervical ganglia. It runs down the neck behind the common carotid artery, lying upon the Longus colli muscle; and crosses in front of the inferior thyroid artery, and recurrent laryngeal nerve.

The *right superior cardiac nerve*, at the root of the neck, passes either in front of or behind the subclavian artery, and along the arteria innominata, to the back part of the arch of the aorta, where it joins the deep cardiac plexus. This nerve, in its course, is connected with other branches of the sympathetic; about the middle of the neck it receives filaments from the external laryngeal nerve; lower down, one or two twigs from the pneumogastric; and as it enters the thorax it is joined by a filament from the recurrent laryngeal. Filaments from this nerve communicate with the thyroid branches from the middle cervical ganglion.

The *left superior cardiac nerve*, in the chest, runs by the side of the left common carotid artery, and in front of the arch of the aorta, to the superficial

\* The existence of this ganglion is doubted by some observers.



cardiac plexus ; but occasionally it passes behind the aorta, and terminates in the deep cardiac plexus.

The **anterior branches** ramify upon the external carotid artery and its branches, forming round each a delicate plexus, on the nerves composing which small ganglia are occasionally found. These ganglia have been named, according to their position, intercarotid\* (placed at the angle of bifurcation of the common carotid), lingual, temporal, and pharyngeal. The plexuses accompanying some of these arteries have important communications with other nerves. That surrounding the external carotid is connected with the branch of the facial nerve to the stylo-hyoid muscle ; that surrounding the facial communicates with the submaxillary ganglion by one or two filaments ; and that accompanying the middle meningeal artery sends offsets which pass to the otic ganglion and to the intumescencia ganglioformis of the facial nerve (external petrosal).

The **Middle Cervical Ganglion** (*thyroid ganglion*) is the smallest of the three cervical ganglia, and is occasionally altogether wanting. It is placed opposite the sixth cervical vertebra, usually upon, or close to, the inferior thyroid artery ; hence the name 'thyroid ganglion,' assigned to it by Haller. It is probably formed by the coalescence of two ganglia corresponding to the fifth and sixth cervical nerves.

Its *superior branches* ascend to communicate with the superior cervical ganglion.

Its *inferior branches* descend to communicate with the inferior cervical ganglion.

Its *external branches* pass outwards to join the fifth and sixth spinal nerves. These branches are not constantly found.

Its *internal branches* are the thyroid and the middle cardiac nerve.

The *thyroid branches* are small filaments, which accompany the inferior thyroid artery to the thyroid gland ; they communicate, on the artery, with the superior cardiac nerve, and, in the gland, with branches from the recurrent and external laryngeal nerves.

The *middle cardiac nerve* (*nervus cardiacus magnus*), the largest of the three cardiac nerves, arises from the middle cervical ganglion, or from the cord between the middle and inferior ganglia. On the right side it descends behind the common carotid artery ; and at the root of the neck passes either in front of or behind the subclavian artery ; it then descends on the trachea, receives a few filaments from the recurrent laryngeal nerve, and joins the right side of the deep cardiac plexus. In the neck, it communicates with the superior cardiac and recurrent laryngeal nerves. On the left side, the middle cardiac nerve enters the chest between the left carotid and subclavian arteries, and joins the left side of the deep cardiac plexus.

The **Inferior Cervical Ganglion** is situated between the base of the transverse process of the last cervical vertebra and the neck of the first rib, on the inner side of the superior intercostal artery. Its form is irregular ; it is larger in size than the preceding, and frequently joined with the first thoracic ganglion. It is probably formed by the coalescence of two ganglia which correspond to the two last cervical nerves.

Its *superior branches* communicate with the middle cervical ganglion.

Its *inferior branches* descend, some in front of, others behind the subclavian artery, to join the first thoracic ganglion.

Its *internal branch* is the inferior cardiac nerve.

The *inferior cardiac nerve* (*nervus cardiacus minor*) arises from the inferior cervical or first thoracic ganglion. It passes down behind the subclavian artery and along the front of the trachea, to join the deep cardiac plexus. It communicates freely behind the subclavian artery with the recurrent laryngeal and middle cardiac nerves.

\* This ganglion is of the same structure as the coccygeal gland (Luschka).

The *external branches* consist of several filaments, some of which communicate with the seventh and eighth spinal nerves; others accompany the vertebral artery along the vertebral canal, forming a plexus round the vessel, supplying it with filaments, which are continued up the vertebral and basilar to the cerebral arteries. The branches communicate with the cervical spinal nerves.

#### THORACIC PORTION OF THE GANGLIATED CORD

The thoracic portion of the gangliated cord consists of a series of ganglia, which usually correspond in number to that of the vertebræ; but, from the occasional coalescence of two, their number is uncertain. These ganglia are placed on each side of the spine, resting against the heads of the ribs, and covered by the pleura costalis; the last two are, however, anterior to the rest, being placed on the side of the bodies of the eleventh and twelfth dorsal vertebræ. The ganglia are small in size, and of a greyish colour. The first, larger than the rest, is of an elongated form, and frequently blended with the last cervical. They are connected together by cord-like prolongations from their substance.

The *external branches* from each ganglion, usually two in number, communicate with each of the dorsal spinal nerves.

The *internal branches from the five or six upper ganglia* are very small; they supply filaments to the thoracic aorta and its branches, besides small branches to the bodies of the vertebræ and their ligaments. Branches from the third and fourth, and sometimes, also, from the first and second ganglia form part of the posterior pulmonary plexus.

The *internal branches from the six or seven lower ganglia* are large and white in colour; they distribute filaments to the aorta, and unite to form the three splanchnic nerves. These are named the *great*, the *lesser*, and the *smallest or renal splanchnic*.

The *great splanchnic nerve* is of a white colour, firm in texture, and bears a marked contrast to the ganglionic nerves. It is formed by branches from the thoracic ganglia between the fifth or sixth and the ninth or tenth, receiving filaments (according to Dr. Beck) from all the thoracic ganglia above the sixth. These roots unite to form a large round cord of considerable size. It descends obliquely inwards in front of the bodies of the vertebræ along the posterior mediastinum, perforates the crus of the Diaphragm, and terminates in the semilunar ganglion of the solar plexus, distributing filaments to the renal and suprarenal plexus.

The *lesser splanchnic nerve* is formed by filaments from the tenth and eleventh ganglia, and from the cord between them. It pierces the Diaphragm with the preceding nerve, and joins the solar plexus. It communicates in the chest with the great splanchnic nerve, and occasionally sends filaments to the renal plexus.

The *smallest, or renal splanchnic nerve* arises from the last ganglion, and, piercing the Diaphragm, terminates in the renal plexus and lower part of the solar plexus. It occasionally communicates with the preceding nerve.

A striking analogy appears to exist between the splanchnic and the cardiac nerves. The cardiac nerves are three in number; they arise from the three cervical ganglia, and are distributed to a large and important organ in the thoracic cavity. The splanchnic nerves, also three in number, are connected probably with all the dorsal ganglia, and are distributed to important organs in the abdominal cavity.

#### THE LUMBAR PORTION OF THE GANGLIATED CORD

The lumbar portion of the gangliated cord is situated in front of the vertebral column, along the inner margin of the Psoas muscle. It consists usually of four ganglia, connected together by interganglionic cords. The ganglia are of small size, of a greyish colour, shaped like a barleycorn, and placed much nearer the median line than the thoracic ganglia.

The *superior* and *inferior branches of the lumbar ganglia* serve as communicating branches between the chain of ganglia in this region. They are usually single, and of a white colour.

The *external branches* communicate with the lumbar spinal nerves. From the situation of the lumbar ganglia, these branches are longer than in the other regions. They are usually two in number from each ganglion, but their connection with the spinal nerves is not so uniform as in other regions. They accompany the lumbar arteries around the sides of the bodies of the vertebræ, passing beneath the fibrous arches from which some of the fibres of the Psoas muscle arise.

Of the *internal branches*, some pass inwards, in front of the aorta, and help to form the aortic plexus. Other branches descend in front of the common iliac arteries, and join over the promontory of the sacrum, helping to form the hypogastric plexus. Numerous delicate filaments are also distributed to the bodies of the vertebræ, and the ligaments connecting them.

#### PELVIC PORTION OF THE GANGLIATED CORD

The pelvic portion of the gangliated cord is situated in front of the sacrum, along the inner side of the anterior sacral foramina. It consists of four or five small ganglia on each side, connected together by interganglionic cords. Below, these cords converge and unite on the front of the coccyx, by means of a small ganglion (the *coccygeal ganglion*, or *ganglion impar*).

The *superior* and *inferior branches* are the cords of communication between the ganglia above and below.

The *external branches*, exceedingly short, communicate with the sacral nerves. They are two in number from each ganglion. The coccygeal nerve communicates either with the last sacral, or coccygeal ganglion.

The *internal branches* communicate, on the front of the sacrum, with the corresponding branches from the opposite side; some, from the first two ganglia, pass to join the pelvic plexus, and others form a plexus, which accompanies the middle sacral artery and sends filaments to the coccygeal gland.

#### THE GREAT PLEXUSES OF THE SYMPATHETIC

The great plexuses of the sympathetic are the large aggregations of nerves and ganglia, above alluded to, situated in the thoracic, abdominal, and pelvic cavities respectively. From them are derived the branches which supply the viscera.

##### THE CARDIAC PLEXUS

The cardiac plexus is situated at the base of the heart, and is divided into a *superficial part*, which lies in the concavity of the arch of the aorta, and a *deep part*, which lies between the trachea and aorta. The two plexuses are, however, closely connected.

The **great** or **deep cardiac plexus** (*plexus magnus profundus*, Scarpa) is situated in front of the trachea at its bifurcation, above the point of division of the pulmonary artery, and behind the arch of the aorta. It is formed by the cardiac nerves derived from the cervical ganglia of the sympathetic, and the cardiac branches of the recurrent laryngeal and pneumogastric. The only cardiac nerves which do not enter into the formation of this plexus are the left superior cardiac nerve, and the inferior cervical cardiac branch from the left pneumogastric.

The branches from the *right side* of this plexus pass, some in front of, and others behind, the right pulmonary artery; the former, the more numerous, transmit a few filaments to the anterior pulmonary plexus, and are then



continued onwards to form part of the anterior coronary plexus; those behind the pulmonary artery distribute a few filaments to the right auricle, and are then continued onwards to form part of the posterior coronary plexus.

The branches from the *left side* of the deep cardiac plexus distribute a few filaments to the superficial cardiac plexus, to the left auricle of the heart, and to the anterior pulmonary plexus, and then pass on to form the greater part of the posterior coronary plexus.

The **superficial (anterior) cardiac plexus** lies beneath the arch of the aorta, in front of the right pulmonary artery. It is formed by the left superior cardiac nerve, the inferior cervical cardiac branches of the left (and occasionally the right) pneumogastric, and filaments from the deep cardiac plexus. A small ganglion (*cardiac ganglion of Wrisberg*) is occasionally found connected with these nerves at their point of junction. This ganglion, when present, is situated immediately beneath the arch of the aorta, on the right side of the ductus arteriosus. The superficial cardiac plexus forms the chief part of the anterior coronary plexus, and several filaments pass along the pulmonary artery to the left anterior pulmonary plexus.

The **posterior or right coronary plexus** is chiefly formed by filaments prolonged from the left side of the deep cardiac plexus, and by a few from the right side. It surrounds the branches of the coronary artery at the back of the heart, and its filaments are distributed with those vessels to the muscular substance of the ventricles.

The **anterior or left coronary plexus** is formed chiefly from the superficial cardiac plexus, but receives filaments from the deep cardiac plexus. Passing forwards between the aorta and pulmonary artery, it accompanies the left coronary artery on the anterior surface of the heart.

Valentin has described nervous filaments ramifying under the endocardium; and Remak has found, in several mammalia, numerous small ganglia on the cardiac nerves, both on the surface of the heart and in its muscular substance.

#### THE EPIGASTRIC OR SOLAR PLEXUS (figs. 517, 519)

The **Epigastric or Solar plexus** supplies all the viscera in the abdominal cavity. It consists of a great network of nerves and ganglia situated behind the stomach and in front of the aorta and crura of the Diaphragm. It surrounds the celiac axis and root of the superior mesenteric artery, extending downwards as low as the pancreas, and outwards to the suprarenal capsules. This plexus, and the ganglia connected with it, receive the great and small splanchnic nerves of both sides, and some filaments from the right pneumogastric. It distributes filaments, which accompany, under the name of plexuses, all the branches from the front of the abdominal aorta.

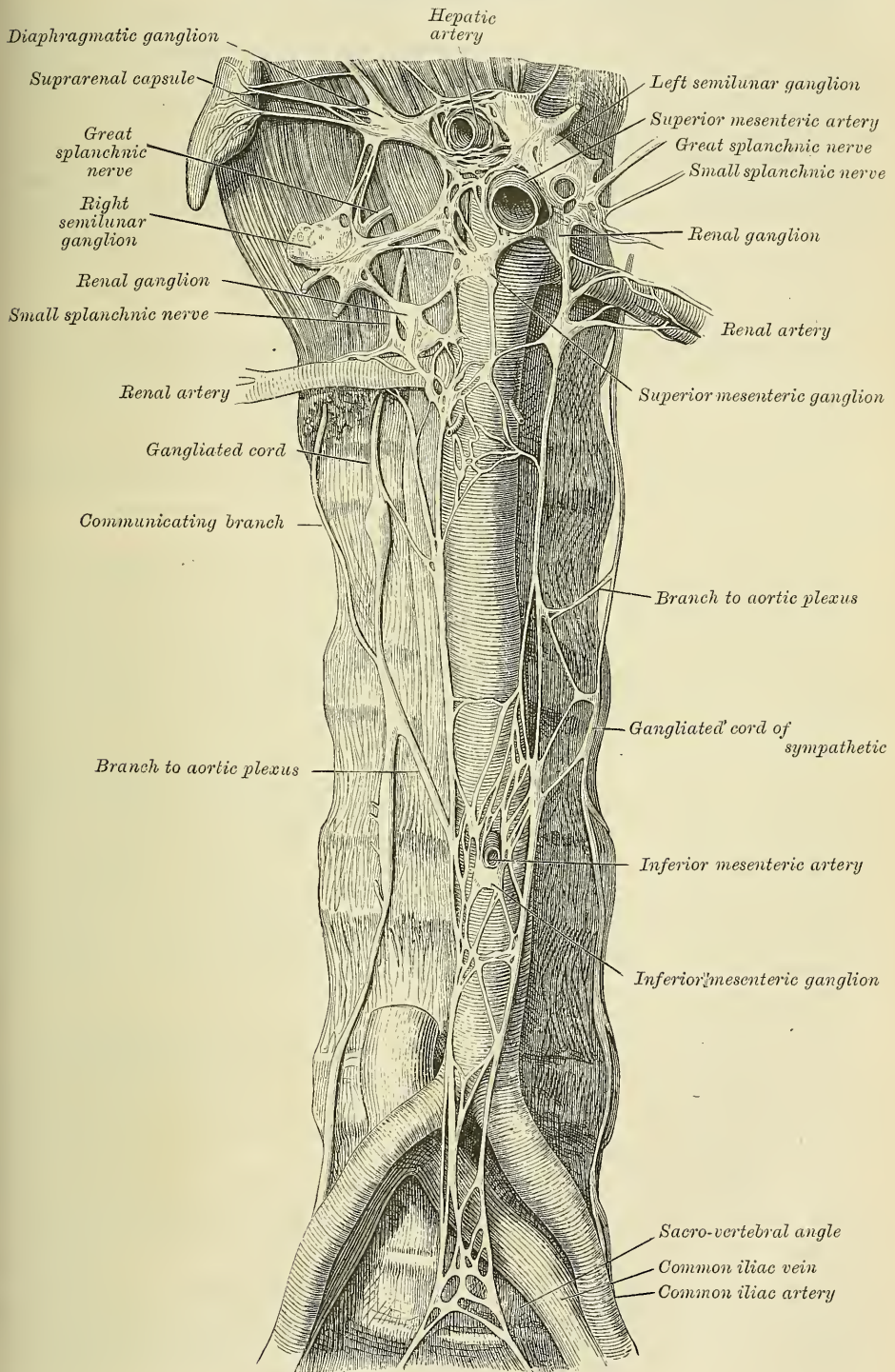
Of the ganglia of which the solar plexus is partly composed the principal are the two **semilunar ganglia**, which are situated one on each side of the plexus, and are the largest ganglia in the body. They are large irregular gangliform masses, formed by the aggregation of smaller ganglia, having interspaces between them. They are situated in front of the crura of the Diaphragm, close to the suprarenal capsules: the one on the right side lies beneath the inferior vena cava; the upper part of each ganglion is joined by the greater splanchnic nerve, and to the inner side of each the branches of the solar plexus are connected.

From the epigastric or solar plexus are derived the following:

Phrenic or Diaphragmatic plexus.	Celiac plexus	(Gastric plexus.
Suprarenal plexus.		(Splenic plexus.
Renal plexus.		(Hepatic plexus.
Spermatic plexus.	Superior mesenteric plexus.	
	Aortic plexus.	

The **phrenic plexus** accompanies the phrenic artery to the Diaphragm, which it supplies; some filaments passing to the suprarenal capsule. It arises from the upper part of the semilunar ganglion, and is larger on the right than on the left

FIG. 519.—Lumbar portion of the gangliated cord, with the solar and hypogastric plexuses. (After Henle.)





side. It receives one or two branches from the phrenic nerve. In connection with this plexus, on the right side, at its point of junction with the phrenic nerve, is a small ganglion (*ganglion diaphragmaticum*). This ganglion is placed on the under surface of the Diaphragm, near the suprarenal capsule. Its branches are distributed to the inferior vena cava, suprarenal capsule, and the hepatic plexus. There is no ganglion on the left side.

The **suprarenal plexus** is formed by branches from the solar plexus, from the semilunar ganglion, and from the phrenic and great splanchnic nerves, a ganglion being formed at the point of junction of the latter nerve. It supplies the suprarenal capsule. The branches of this plexus are remarkable for their large size, in comparison with the size of the organ they supply.

The **renal plexus** is formed by filaments from the solar plexus, the outer part of the semilunar ganglion, and the aortic plexus. It is also joined by filaments from the lesser and smallest splanchnic nerves. The nerves from these sources, fifteen or twenty in number, have numerous ganglia developed upon them. They accompany the branches of the renal artery into the kidney; some filaments on the right side being distributed to the inferior vena cava, and others to the spermatic plexus, on both sides.

The **spermatic plexus** is derived from the renal plexus, receiving branches from the aortic plexus. It accompanies the spermatic vessels to the testes.

In the female, the **ovarian plexus** is distributed to the ovaries and fundus of the uterus.

The **cœliac plexus**, of large size, is a direct continuation from the solar plexus: it surrounds the cœliac axis, and subdivides into the gastric, hepatic, and splenic plexuses. It receives branches from the lesser splanchnic nerves, and, on the left side, a filament from the right pneumogastric.

The *gastric* or *coronary plexus* accompanies the gastric artery along the lesser curvature of the stomach, and joins with branches from the left pneumogastric nerve. It is distributed to the stomach.

The *hepatic plexus*, the largest offset from the cœliac plexus, receives filaments from the left pneumogastric and right phrenic nerves. It accompanies the hepatic artery, ramifying in the substance of the liver upon its branches, and upon those of the vena portæ.

Branches from this plexus accompany all the divisions of the hepatic artery. Thus there is a *pyloric plexus* accompanying the pyloric branch of the hepatic, which joins with the gastric plexus and pneumogastric nerves. There is also a *gastro-duodenal plexus*, which subdivides into the *pancreatico-duodenal plexus*, which accompanies the pancreatico-duodenal artery, to supply the pancreas and duodenum, joining with branches from the mesenteric plexus; and a *gastro-epiploic plexus*, which accompanies the right gastro-epiploic artery along the greater curvature of the stomach, and anastomoses with branches from the splenic plexus. A *cystic plexus*, which supplies the gall-bladder, also arises from the hepatic plexus, near the liver.

The *splenic plexus* is formed by branches from the cœliac plexus, the left semilunar ganglia, and from the right pneumogastric nerve. It accompanies the splenic artery and its branches to the substance of the spleen, giving off, in its course, filaments to the pancreas (*pancreatic plexus*), and the *left gastro-epiploic plexus*, which accompanies the gastro-epiploica sinistra artery along the convex border of the stomach.

The **superior mesenteric plexus** is a continuation of the lower part of the great solar plexus, receiving a branch from the junction of the right pneumogastric nerve with the cœliac plexus. It surrounds the superior mesenteric artery, which it accompanies into the mesentery, and divides into a number of secondary plexuses, which are distributed to all the parts supplied by the artery, viz. pancreatic branches to the pancreas; intestinal branches, which supply the whole of the small intestine; and ileo-colic, right colic, and middle colic branches, which supply the corresponding parts of the great intestine. The nerves com-



posing this plexus are white in colour and firm in texture, and have numerous ganglia developed upon them near their origin.

The **aortic plexus** is formed by branches derived, on each side, from the solar plexus and the semilunar ganglia, receiving filaments from some of the lumbar ganglia. It is situated upon the sides and front of the aorta, between the origins of the superior and inferior mesenteric arteries. From this plexus arise part of the spermatic, the inferior mesenteric, and the hypogastric plexuses; and it distributes filaments to the inferior vena cava.

The *inferior mesenteric plexus* is derived chiefly from the left side of the aortic plexus. It surrounds the inferior mesenteric artery, and divides into a number of secondary plexuses, which are distributed to all the parts supplied by the artery, viz. the left colic and sigmoid plexuses, which supply the descending and sigmoid flexure of the colon: and the superior hæmorrhoidal plexus, which supplies the upper part of the rectum, and joins in the pelvis with branches from the pelvic plexus.

#### HYPOGASTRIC PLEXUS

The **Hypogastric Plexus** supplies the viscera of the pelvic cavity. It is situated in front of the promontory of the sacrum, between the two common iliac arteries, and is formed by the union of numerous filaments, which descend on each side from the aortic plexus, and from the lumbar ganglia. This plexus contains no ganglia; and bifurcates, below, into two lateral portions, which form the *pelvic plexus*.

#### PELVIC PLEXUS

The **Pelvic Plexus** (sometimes called *inferior hypogastric*) supplies the viscera of the pelvic cavity, is situated at the sides of the rectum in the male, and at the sides of the rectum and vagina in the female. It is formed by a continuation of the hypogastric plexus, by branches from the second, third, and fourth sacral nerves, and by a few filaments from the first two sacral ganglia. At the point of junction of these nerves, small ganglia are found. From this plexus numerous branches are distributed to all the viscera of the pelvis. They accompany the branches of the internal iliac artery.

The **inferior hæmorrhoidal plexus** arises from the back part of the pelvic plexus. It supplies the rectum, joining with branches of the superior hæmorrhoidal plexus.

The **vesical plexus** arises from the fore part of the pelvic plexus. The nerves composing it are numerous, and contain a large proportion of spinal nerve-fibres. They accompany the vesical arteries, and are distributed to the side and base of the bladder. Numerous filaments also pass to the vesiculæ seminales and vas deferens; those accompanying the vas deferens join, on the spermatic cord, with branches from the spermatic plexus.

The **prostatic plexus** is continued from the lower part of the pelvic plexus. The nerves composing it are of large size. They are distributed to the prostate gland, vesiculæ seminales, and erectile structure of the penis. The nerves supplying the erectile structure of the penis consist of two sets, the small and large cavernous nerves. They are slender filaments, which arise from the fore part of the prostatic plexus, and, after joining with branches from the internal pudic nerve, pass forwards beneath the pubic arch.

The *small cavernous nerves* perforate the fibrous covering of the penis, near its root.

The *large cavernous nerve* passes forwards along the dorsum of the penis, joins with the dorsal branch of the pudic nerve, and is distributed to the corpus cavernosum and spongiosum.

The **vaginal plexus** arises from the lower part of the pelvic plexus. It is lost

on the walls of the vagina, being distributed to the erectile tissue at its anterior part and to the mucous membrane. The nerves composing this plexus contain, like the vesical, a large proportion of spinal nerve-fibres.

The **uterine plexus** arises from the upper part of the pelvic plexus, above the point where the branches from the sacral nerves join the plexus. Its branches accompany the uterine arteries to the side of the organ between the layers of the broad ligament, and are distributed to the cervix and lower part of the body of the uterus, penetrating its substance.

Other filaments pass separately to the body of the uterus and Fallopian tube.

Branches from the plexus accompany the uterine arteries into the substance of the uterus. Upon these filaments ganglionic enlargements are found.

## ORGANS OF SENSE

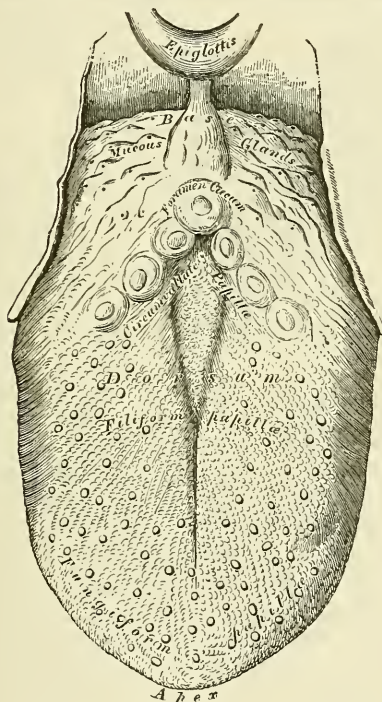
THE Organs of the Senses are five in number : viz. those of Touch, of Taste, of Smell, of Hearing, and of Sight. The skin, which is the principal seat of the sense of touch, has been described in the chapter on General Anatomy.

### THE TONGUE

The tongue is the organ of the special sense of taste. It is situated in the floor of the mouth, in the interval between the two lateral portions of the body of the lower jaw.

Its base, or root, is directed backwards, and connected with the os hyoides by the *Hyo-glossi* and *Genio-hyo-glossi* muscles and the *hyo-glossal* membrane ;

FIG. 520.—Upper surface of the tongue.



with the epiglottis by three folds of mucous membrane, which form the *glosso-epiglottic ligaments* ; with the soft palate by means of the anterior pillars of the fauces ; and with the pharynx by the Superior constrictors and the mucous membrane. Its apex, or tip, thin and narrow, is directed forwards against the inner surface of the lower incisor teeth. The under surface of the tongue is connected with the lower jaw by the *Genio-hyo-glossi* muscles ; from its sides, the mucous membrane is reflected to the inner surface of the gums ; and, in front, a distinct fold of that membrane, the *frænum linguæ*, is formed beneath its under surface.



The tip of the tongue, part of the under surface, its sides, and dorsum are free.

The dorsum of the tongue is convex, marked along the middle line by a raphé, which divides it into symmetrical halves; this raphé terminates behind, about an inch from the base of the organ, in a depression, the *foramen cæcum*. The anterior two-thirds of this surface are rough and covered with papillæ; the posterior third is smoother, and covered by the projecting orifices of numerous muciparous glands.

**Structure of the tongue.**—The tongue is partly invested by mucous membrane and a submucous fibrous layer. It consists of symmetrical halves, separated from each other, in the middle line, by a fibrous septum. Each half is composed of muscular fibres arranged in various directions (page 415), containing much interposed fat, and supplied by vessels and nerves.

The **mucous membrane** invests the entire extent of the free surface of the tongue. On the dorsum it is thicker behind than in front, and is continuous with the sheaths of the muscles attached to it, through the submucous fibrous layer. On the under surface of the organ, where it is thin and smooth, it can be traced on each side of the frænum, through the ducts of the submaxillary and the sublingual glands. As it passes over the borders of the organ, it gradually assumes its papillary character.

The **structure of the mucous membrane of the tongue** differs in different parts. That covering the under surface of the organ is thin, smooth, and identical in

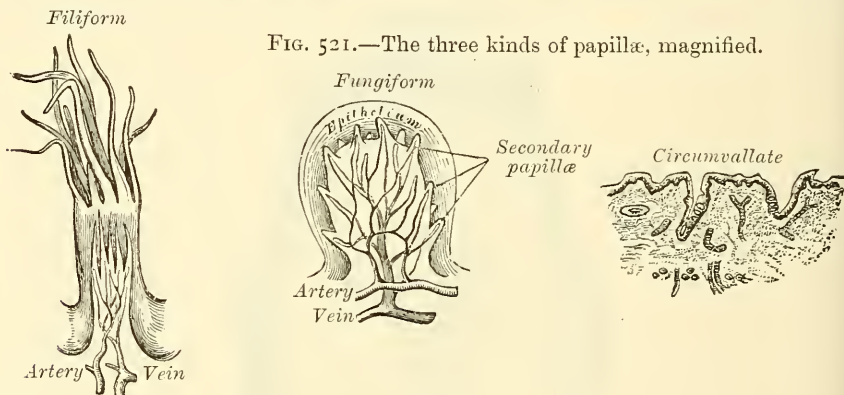


FIG. 521.—The three kinds of papillæ, magnified.

structure with that lining the rest of the oral cavity. The mucous membrane on the anterior part of the dorsum of the tongue is thin and intimately adherent to the muscular tissue, whilst that at the root is much thicker and looser. It consists of a layer of connective tissue, the *corium* or *mucosa*, supporting numerous *papillæ*, and covered, as well as the papillæ, with *epithelium*.

The epithelium is of the scaly variety, like that of the epidermis. It covers the free surface of the tongue, as may be easily demonstrated by maceration or boiling, when it can be easily detached entire: it is much thinner than on the skin: the intervals between the large papillæ are not filled up by it, but each papilla has a separate investment from root to summit. The deepest cells may sometimes be detached as a separate layer, corresponding to the rete mucosum, but they never contain colouring matter.

The *corium* consists of a dense felt-work of fibrous connective tissue, with numerous elastic fibres, firmly connected with the fibrous tissue forming the septa between the muscular bundles of the tongue. It contains the ramifications of the numerous vessels and nerves from which the papillæ are supplied, large plexuses of lymphatic vessels, and the glands of the tongue.

**The papillæ of the tongue.**—These are papillary projections of the corium. They are thickly distributed over the anterior two-thirds of its upper surface, giving to it its characteristic roughness. The varieties of papillæ met with are the

papillæ maximæ (*circumvallatæ*), papillæ mediæ (*fungiformes*), papillæ minimæ (*conicæ* or *filiformes*), and papillæ simplices.

The *papillæ maximæ* (*circumvallatæ*) are of large size, and vary from eight to twelve in number. They are situated at the back part of the dorsum of the tongue, near its base, forming a row on each side, which, running backwards and inwards, meet in the middle line, like the two lines of the letter V inverted. Each papilla consists of a projection of mucous membrane from  $\frac{1}{20}$  to  $\frac{1}{12}$  of an inch wide, attached to the bottom of a cup-shaped depression of the mucous membrane; the papilla is in shape like a truncated cone; the smaller end being directed downwards and attached to the tongue, the broader part or base projecting on the surface and being studded with numerous small secondary papillæ, which, however, are covered by a smooth layer of the epithelium. The cup-shaped depression forms a kind of fossa round the papilla, having a circular margin of about the same elevation, covered with smaller papillæ. At the point of junction of the two rows of papillæ is the deep depression, the *foramen cæcum*, mentioned above.

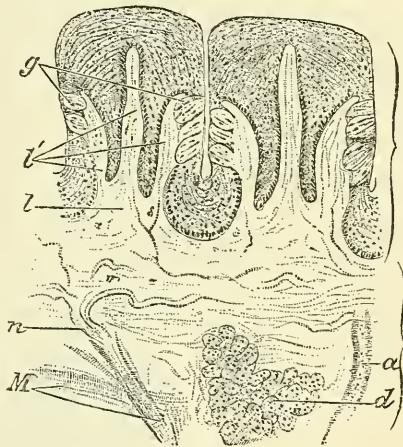
The *papillæ mediæ* (*fungiformes*), more numerous than the preceding, are scattered irregularly and sparingly over the dorsum of the tongue; but are found chiefly at its sides and apex. They are easily recognised, among the other papillæ, by their large size, rounded eminences, and deep red colour. They are narrow at their attachment to the tongue, but broad and rounded at their free extremities, and covered with secondary papillæ. Their epithelial investment is very thin.

The *papillæ minimæ* (*conicæ* or *filiformes*) cover the anterior two-thirds of the dorsum of the tongue. They are very minute, more or less conical or filiform in shape, and arranged in lines corresponding in direction with the two rows of the papillæ *circumvallatæ*; excepting at the apex of the organ, where their direction is transverse. They have projecting from their apices numerous filiform processes, or secondary papillæ, which are of a whitish tint, owing to the thickness and density of the epithelium of which they are composed, and which has here undergone a peculiar modification, the cells having become cornified and elongated into dense, imbricated, brush-like processes. They contain also a number of elastic fibres, which render them firmer and more elastic than the papillæ of mucous membrane generally.

*Simple papillæ*, similar to those of the skin, cover the whole of the mucous membrane of the tongue, as well as the larger papillæ. They consist of closely set, microscopic elevations of the corium, containing a capillary loop, covered by a layer of epithelium.

*Structure of the papillæ*.—The papillæ apparently resemble in structure those of the cutis, consisting of a cone-shaped projection of connective tissue, covered with a thick layer of squamous epithelium, and contain one or more capillary loops, amongst which nerves are distributed in great abundance. If the epithelium is removed, it will be found that they are not simple elevations like the papillæ of the skin, for the surface of each is studded with minute conical processes of the mucous membrane, which form secondary papillæ (Todd and Bowman). In the papillæ *circumvallatæ*, the nerves are numerous and of large size; in the papillæ *fungiformes*, they are also numerous, and terminate in a plexiform network, from

FIG. 522.—Circumvallate papillæ of tongue of rabbit, showing position of taste-goblets. (Stöhr.)

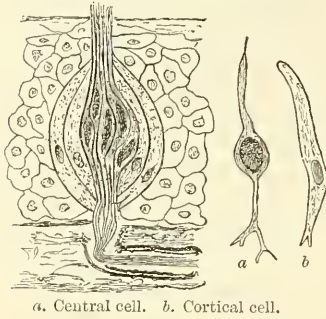


a. Duct of gland. d. Serous gland. g. Taste-goblets. l. Primary septa, and l', secondary septa, of papillæ. n. Medullated nerve. M. Muscular fibres.



which brush-like branches proceed; in the papillæ filiformes, their mode of termination is uncertain. Buried in the epidermis of the papillæ circumvallatæ, and in some of the fungiformes, certain peculiar bodies called *taste-goblets* have been described.\* They are flask-like in shape, their broad base resting on the corium, and their neck opening by an orifice between the cells of the epithelium. They are formed by two kinds of cells: the external (cortical) are arranged in several layers; they are long and flattened, with tapering ends, and in contact by their

FIG. 523.—Taste-goblets.



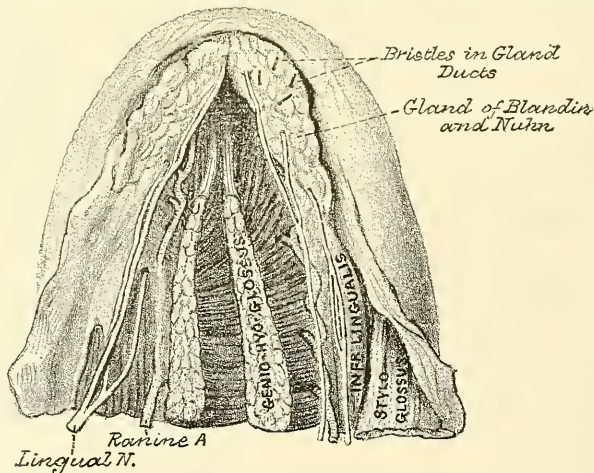
edges; the tapering extremities extending from the base to the apex of the organ. They thus enclose the central cells (gustatory cells), which are spindle-shaped, and have a large spherical nucleus about the middle of the cell. Both extremities are filamentous, the outer or peripheral passes to the orifice of the taste-goblet, where it ends in an extremely fine projection, the *taste-hair*: the inner or central process is often branched, and was supposed by Engelmann to be continuous with the terminal fibril of a nerve; the investigations of Lenhossék and others would seem to prove, however, that this is not so, but that the nerve fibrils after losing their medullary sheaths enter the taste-goblet, and terminate in a

fine extremity between the gustatory cells. Other nerve fibrils may be seen ramifying between the cortical cells and terminating in fine extremities; these, however, are believed to be nerves of ordinary sensation and not gustatory.

*Glands of the tongue.*—The tongue is provided with mucous and serous glands and lymphoid follicles.

The *mucous glands* are similar in structure to the labial and buccal glands. They are found all over the surface of the mucous membrane of the tongue,

FIG. 524.—Under surface of tongue, showing position and relations of gland of Blandin and Nuhn. (From a preparation in the Museum of the Royal College of Surgeons.)



especially at the back part behind the circumvallate papillæ, but also at the apex and marginal parts. In connection with these glands, a special one has been described by Blandin and Nuhn. It is situated near the apex of the tongue on either side of the frænum, and is covered over by a fasciculus of muscular fibre derived from the Stylo-glossus and Inferior lingualis. It is from half an inch to

\* These bodies are also found in considerable numbers at the side of the base of the tongue, just in front of the anterior pillars of the fauces, and on the posterior surface of the epiglottis and anterior surface of the soft palate.

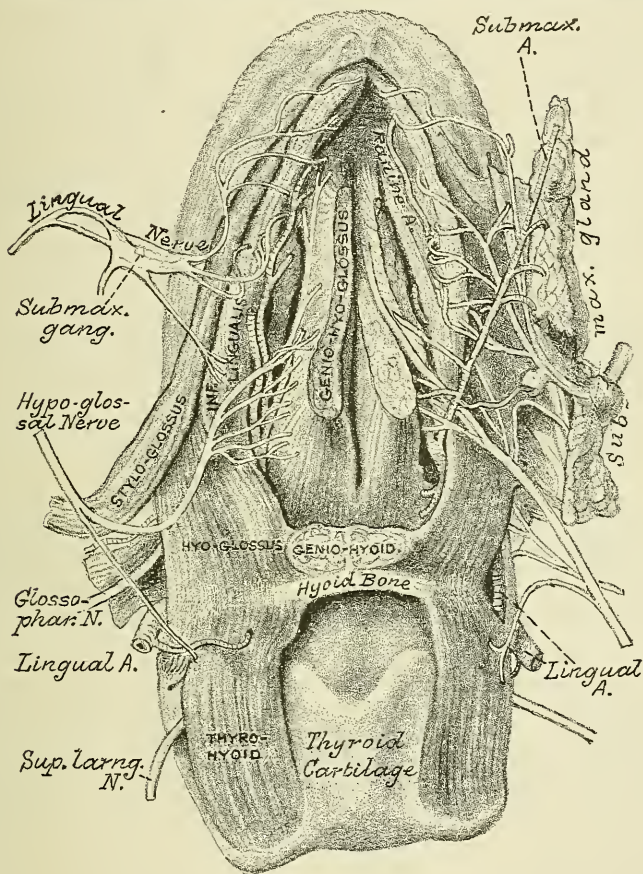


nearly an inch long, and about the third of an inch broad. It has from four to six ducts, which open on the under surface of the apex.

The *serous glands* occur only at the back of the tongue in the neighbourhood of the taste-goblets, their ducts opening for the most part into the fossæ of the circumvallate papillæ. These glands are racemose, the duct branching into several minute ducts, which terminate in alveoli, lined by a single layer of more or less columnar epithelium. Their secretion is of a watery nature, and probably assists in the distribution of the substance to be tasted over the taste area. (Ebner.)

The *lymphoid follicles*.—The *lymphoid tissue* is situated, for the most part, at the back of the tongue, between the epiglottis and the circumvallate papillæ, and

FIG. 525.—Under surface of tongue, showing the distribution of nerves to this organ. (From a preparation in the Museum of the Royal College of Surgeons.)



is collected at numerous points into distinct masses known as *lymphoid follicles*. Here and there in this situation are depressions in the mucous membrane surrounded by nodules of lymphoid tissue, similar to the structure found in the tonsil: into them open some of the ducts of the mucous glands.

The *fibrous septum* consists of a vertical layer of fibrous tissue, extending throughout the entire length of the middle line of the tongue, from the base to the apex, though not quite reaching the dorsum. It is thicker behind than in front, and occasionally contains a small fibro-cartilage, about a quarter of an inch in length. It is well displayed by making a vertical section across the organ.

The **Hyo-glossal membrane** is a strong fibrous lamina, which connects the

under surface of the base of the tongue to the body of the hyoid bone. This membrane receives, in front, some of the fibres of the Genio-hyo-glossi.

**Vessels of the tongue.**—The *arteries of the tongue* are derived from the lingual, the facial, and ascending pharyngeal. The *veins of the tongue* accompany the arteries.

**Muscles of the Tongue.**—The muscular fibres of the tongue run in various directions. These fibres are divided into two sets, Extrinsic and Intrinsic.

The *Extrinsic muscles of the tongue* are those which have their origin external to it, and only their terminal fibres contained in the substance of the organ. They are the Stylo-glossus, the Hyo-glossus, the Palato-glossus, the Genio-hyo-glossus, and part of the Superior constrictor of the pharynx (Pharyngo-glossus).

The *Intrinsic muscles* are those which are contained entirely within the tongue, and form the greater part of its substance. Both sets have been already described (page 413 *et seq.*).

The *lymphatic vessels from the tongue* pass to one or two small glands situated on the Hyo-glossus muscle in the submaxillary region, and from thence to the deep glands of the neck.

The *nerves of the tongue* are five in number in each half: the lingual branch of the fifth, which is distributed to the papillæ at the fore part and sides of the tongue; the lingual branch of the glosso-pharyngeal, which is distributed to the mucous membrane at the base and side of the tongue, and to the papillæ circumvallatæ; the hypoglossal nerve, which is distributed to the muscular substance of the tongue; the chorda tympani from the facial which joins the lingual and accompanies it to the fore part and sides of the tongue, to which parts it probably serves as a nerve of taste; and the superior laryngeal, which sends some fine branches to the root near to the epiglottis. Sympathetic filaments also pass to the tongue from the nervi molles on the lingual and other arteries supplying it. The glosso-pharyngeal branch is the special nerve of the sense of taste; the lingual (gustatory) is the nerve of common sensation; and the hypoglossal is the motor nerve of the tongue.

*Surgical Anatomy.*—The diseases to which the tongue is liable are numerous, and its surgical anatomy of importance, since any or all the structures of which it is composed—muscles, connective tissue, mucous membrane, glands, vessels, nerves, and lymphatics—may be the seat of morbid changes. It is not often the seat of congenital defects, though a few cases of vertical cleft have been recorded, and it is occasionally, though much more rarely than is commonly supposed, the seat of 'tongue tie,' from shortness of the frænum (see page 562).

There is, however, one condition, which must be regarded as congenital, though it does not sometimes evidence itself until a year or two after birth, which is not uncommon. This is an enlargement of the tongue which is due primarily to a dilatation of the lymph-channels and a greatly increased development of the lymphatic tissue throughout the organ. This is often aggravated by inflammatory changes induced by injury or exposure, and the tongue may assume enormous dimensions and hang out of the mouth, giving the child an imbecile expression. The treatment consists in excising a V-shaped portion and bringing the cut surfaces together with deeply placed silver sutures. Compression has been resorted to in some cases and with success, but it is difficult to apply. Acute inflammation of the tongue, which may be caused by injury and the introduction of some septic or irritating matter, is attended by great swelling from infiltration of its connective tissue, which is in considerable quantity. This renders the patient incapable of swallowing or speaking, and may seriously impede respiration. It may run on to suppuration, and the formation of an acute abscess. Chronic abscess, which has been mistaken for cancer, may also occur in the substance of the tongue.

The mucous membrane of the tongue may become chronically inflamed, and presents different appearances in different stages of the disease, to which the terms leucoplakia, psoriasis, and ichthyosis have been given.

The tongue, being very vascular, is often the seat of nævoid growths, and these have a tendency to grow rapidly.

The tongue is frequently the seat of ulceration, which may arise from many causes, as from the irritation of jagged teeth, dyspepsia, tubercle, syphilis, and cancer. Of these the cancerous ulcer is the most important and probably also the most common. The variety is the squamous epithelioma, which soon develops into an ulcer with an indurated base.



It produces great pain, which speedily extends to all parts supplied with sensation by the fifth nerve, especially to the region of the ear. The pain in these cases is conducted to the ear and temporal region by the lingual nerve, and from it to the other branches of the inferior maxillary nerve, especially the auriculo-temporal. Possibly pain in the ear itself may be due to implication of the fibres of the glosso-pharyngeal nerve, which by its tympanic branch is conducted to the tympanic plexus.

Cancer of the tongue may necessitate removal of a part or the whole of the organ, and many different methods have been adopted for its excision. It may be removed from the mouth by the *écraseur* or the scissors. Probably the better method is by the scissors, usually known as Whitehead's method. The mouth is widely opened with a gag; the tongue transfixed with a stout silk ligature, by which to hold and make traction on it, and the reflexion of mucous membrane from the tongue to the jaw, and the insertion of the Genio-hyo-glossus first divided with a pair of curved, blunt scissors. The Palato-glossus is also divided. The tongue can now be pulled well out of the mouth. The base of the tongue is cut through by a series of short snips, each bleeding vessel being dealt with as soon as divided, until the situation of the ranine artery is reached. The remaining undivided portion of tissue is to be seized with a pair of Wells' forceps; the tongue removed, and the vessel secured. In the event of the ranine artery being accidentally injured, hæmorrhage can be at once controlled, by passing two fingers over the dorsum of the tongue as far as the epiglottis, and dragging the root of the tongue forcibly forwards.

In cases where the disease is confined to one side of the tongue, this operation may be modified by splitting the tongue down the centre and removing only the affected half. In cases where the submaxillary glands are involved, Kocher's operation should be performed. He removes the tongue from the neck, having performed a preliminary tracheotomy, by an incision from near the lobule of the ear, down the anterior border of the Sterno-mastoid to the level of the great cornu of the hyoid bone, then forwards to the body of the hyoid bone, and upwards to near the symphysis of the jaw. The lingual artery is now secured, and by a careful dissection the submaxillary lymphatic glands and the tongue removed. Regnoli advocated the removal of the tongue by a semilunar incision in the submaxillary triangle, along the line of the lower jaw, and a vertical incision from the centre of the semilunar one backwards to the hyoid bone. Care must be taken not to carry the first incision too far backwards, so as to wound the facial arteries. The tongue is thus reached through the floor of the mouth, pulled out through the external incision, and removed with the *écraseur* or knife. The great objection to this operation is that all the muscles which raise the hyoid bone and larynx are divided, and that therefore the movements of deglutition and respiration are interfered with.

Finally, where both sides of the floor of the mouth are involved in the disease, or where very free access is required on account of the extension backwards of the disease to the pillars of the fauces and the tonsil, or where the lower jaw is involved, the operation recommended by Syme must be performed. This is done by an incision through the central line of the lip, across the chin, and down as far as the hyoid bone. The lower jaw is sawn through at the symphysis, and the two halves of the bone forcibly separated from each other. The mucous membrane is separated from the bone, and the Genio-hyo-glossi detached from the bone, and the Hyo-glossi divided. The tongue is then drawn forwards, and removed close to its attachment to the hyoid bone. Any glands which are enlarged can be removed, and if the bone is implicated in the disease, it can also be removed by freeing it from the soft parts externally and internally, and making a second section with the saw beyond the diseased part.

Formerly many surgeons before removing the tongue performed a preliminary tracheotomy: (1) to prevent blood entering the air passages; and (2) to allow the patient to breathe through the tube and not inspire air which had passed over a sloughy wound, and which was loaded with septic organisms and likely to induce septic pneumonia. By the judicious use of iodoform, this secondary evil may be obviated, and the preliminary tracheotomy is now usually dispensed with.

## THE NOSE

The nose is the special organ of the sense of smell: by means of the peculiar properties of its nerves, it protects the lungs from the inhalation of deleterious gases, and assists the organ of taste in discriminating the properties of food.

The organ of smell consists of two parts; one external, the *nose*; the other internal, the *nasal fossæ*.

The *nose* is the more anterior and prominent part of the organ of smell. It is of a triangular form, directed vertically downwards, and projects from the centre of the face, immediately above the upper lip. Its summit, or root, is connected directly with the forehead. Its inferior part, the base of the nose, presents two elliptical orifices, the nostrils, separated from each other by an antero-posterior



septum, the *columna*. The margins of these orifices are provided with a number of stiff hairs, or *vibrissæ*, which arrest the passage of foreign substances carried with the current of air intended for respiration. The lateral surfaces of the nose form, by their union, the *dorsum*, the direction of which varies considerably in different individuals. The dorsum terminates below in a rounded eminence, the *lobe of the nose*.

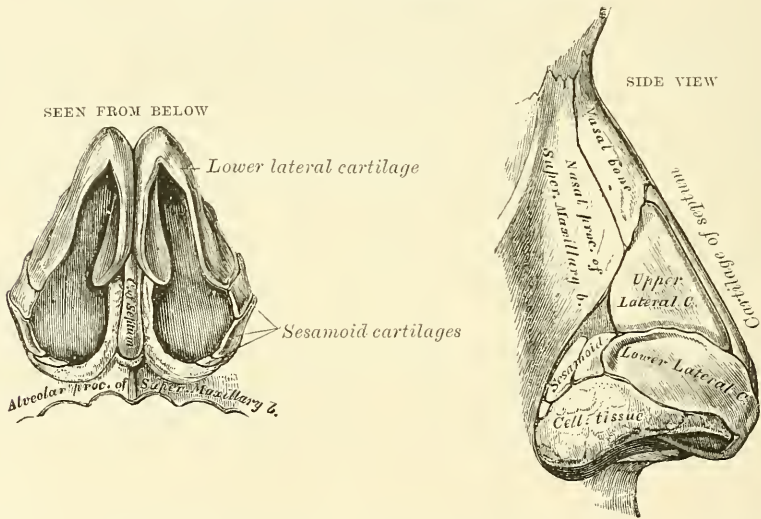
The nose is composed of a framework of bones and cartilages, the latter being slightly acted upon by certain muscles. It is covered externally by the integument, internally by mucous membrane, and supplied with vessels and nerves.

The *bony framework* occupies the upper part of the organ: it consists of the nasal bones, and the nasal processes of the superior maxillary.

The *cartilaginous framework* consists of five pieces, the two upper and the two lower lateral cartilages, and the cartilage of the septum.

The *upper lateral cartilages* are situated below the free margin of the nasal bones; each cartilage is flattened, and triangular in shape. Its anterior margin is thicker than the posterior, and connected with the cartilage of the septum. Its posterior margin is attached to the nasal process of the superior maxillary and

Figs. 526, 527.—Cartilages of the nose.



nasal bones. Its inferior margin is connected by fibrous tissue with the lower lateral cartilage: one surface is turned outwards, the other inwards towards the nasal cavity.

The *lower lateral cartilages* are two thin, flexible plates, situated immediately below the preceding, and bent upon themselves in such a manner as to form the inner and outer walls of each orifice of the nostril. The portion which forms the inner wall, thicker than the rest, is loosely connected with the same part of the opposite cartilage, and forms a small part of the *columna*. Its inferior border, free, rounded, and projecting, forms, with the thickened integument and subjacent tissue, and the corresponding parts of the opposite side, the tip of the nose. The part which forms the outer wall is curved to correspond with the ala of the nose; it is oval and flattened, narrow behind, where it is connected with the nasal process of the superior maxilla by a tough fibrous membrane, in which are found three or four small cartilaginous plates (sesamoid cartilages), *cartilaginee minores*. Above, it is connected to the upper lateral cartilage and front part of the cartilage of the septum; below, it is separated from the margin of the nostril by dense cellular tissue; and in front, it forms, with its fellow, the lobe of the nose.

The *cartilage of the septum* is somewhat quadrilateral in form, thicker at its margins than at its centre, and completes the separation between the nasal fossæ in front. Its anterior margin, thickest above, is connected from above downwards with the nasal bones, the anterior margin of the two upper lateral cartilages, and the inner portion of the two lower lateral cartilages. Its posterior margin is connected with the perpendicular lamella of the ethmoid; its inferior margin with the vomer and the palate processes of the superior maxillary bones.

These various cartilages are connected to each other, and to the bones, by a tough fibrous membrane, which allows the utmost facility of movement between them.

The *muscles of the nose* are situated immediately beneath the integument: they are (on each side) the *Pyramidalis nasi*, the *Levator labii superioris alæque nasi*, the *Dilatator naris*, anterior and posterior, the *Compressor nasi*, the *Compressor narium minor*, and the *Depressor alæ nasi*. They have been described above (page 395).

The *integument* covering the dorsum and sides of the nose is thin, and loosely connected with the subjacent parts: but where it forms the tip, or lobe, and the alæ of the nose, it is thicker and more firmly adherent. It is furnished with a large number of sebaceous follicles, the orifices of which are usually very distinct.

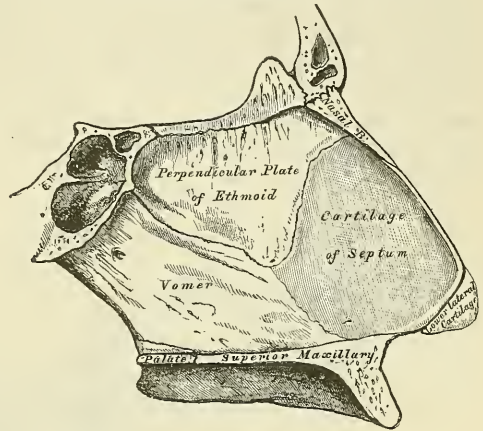
The *mucous membrane*, lining the interior of the nose, is continuous with the skin externally, and with that which lines the nasal fossæ within.

The *arteries of the nose* are the *lateralis nasi* from the facial, and the inferior artery of the septum from the superior coronary, which supply the alæ and septum; the sides and dorsum being supplied from the nasal branch of the ophthalmic and the infra-orbital.

The *veins of the nose* terminate in the facial and ophthalmic.

The *nerves of the nose* are branches from the facial, infra-orbital, and infra-trochlear, and a filament from the nasal branch of the ophthalmic.

FIG. 528.—Bones and cartilages of septum of nose. Right side.



## NASAL FOSSÆ

The nasal fossæ are two irregular cavities situated in the middle of the face, and extending from before backwards. They open in front by the two anterior nares, and terminate in the pharynx, behind, by the posterior nares. The *anterior nares* are somewhat pear-shaped apertures, each measuring about one inch vertically and half an inch transversely at their widest part. The *posterior nares* are two oval openings, situated at the upper part of the anterior wall of the pharynx. They are smaller in the body than in the skeleton, because narrowed by the mucous membrane. Each opening measures an inch in the vertical, and half an inch in the transverse direction in a well-developed adult skull.

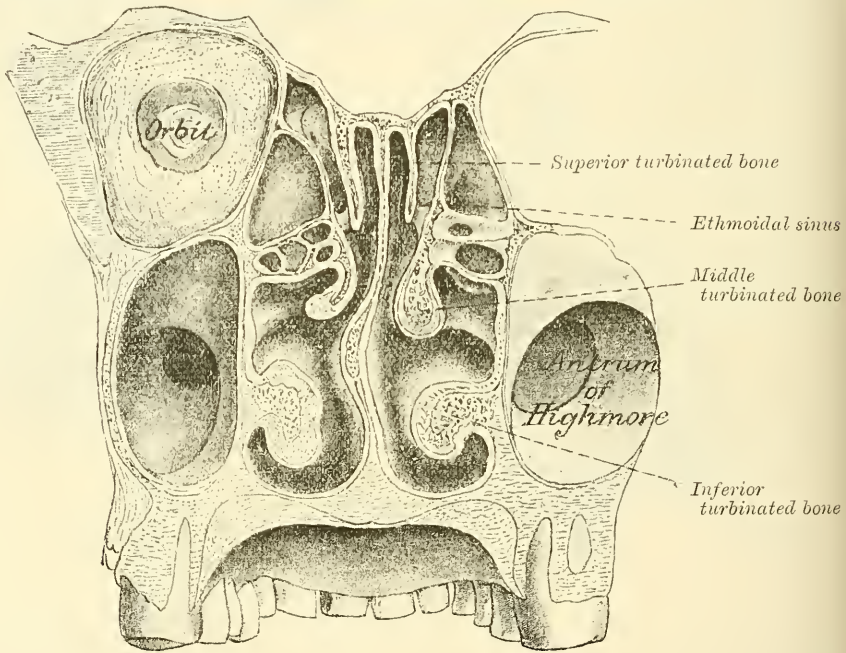
The *mucous membrane* lining the nasal fossæ is called the *pituitary* from the nature of its secretion; or *Schneiderian*, from Schneider, the first anatomist who showed that the secretion proceeded from the mucous membrane, and not, as was formerly imagined, from the brain. It is intimately adherent to the periosteum or perichondrium, over which it lies. It is continuous externally with the skin through the anterior nares, and with the mucous membrane of the pharynx through the posterior nares. From the nasal fossæ its continuity may be traced

with the conjunctiva, through the nasal duct and lachrymal canals; with the lining membrane of the tympanum and mastoid cells, through the Eustachian tube; and with the frontal, ethmoidal, and sphenoidal sinuses, and the antrum of Highmore, through the several openings in the meatuses. The mucous membrane is thickest, and most vascular, over the turbinated bones. It is also thick over the septum; but, in the intervals between the spongy bones, and on the floor of the nasal fossæ, it is very thin. Where it lines the various sinuses and the antrum of Highmore, it is thin and pale.

Owing to the great thickness of this membrane, the nasal fossæ are much narrower, and the turbinated bones, especially the lower ones, appear larger and more prominent than in the skeleton. From the same circumstance, also, the various apertures communicating with the meatuses are either narrowed or completely closed.

In the *superior meatus*, the aperture of communication with the posterior ethmoidal cells is considerably diminished in size, and the spheno-palatine foramen completely covered in.

FIG. 529.—Transverse vertical section of the nasal fossæ. (Henle.)



In the *middle meatus*, the opening of the infundibulum is partially hidden by a projecting fold of mucous membrane, and the orifice of the antrum is contracted to a small circular aperture, much narrower than in the skeleton.

In the *inferior meatus*, the orifice of the nasal duct is partially hidden by either a single or double valvular mucous fold, and the anterior palatine canal either completely closed in, or a tubular *cul-de-sac* of mucous membrane is continued a short distance into it. This *cul-de-sac* is termed the *organ of Jacobson*, and is present in all mammals as well as man. In the former it consists of a bilateral tube, situated in the nasal septum and supported by hyaline cartilage, the *cartilage of Jacobson*.

In the *roof*, the opening leading to the sphenoidal sinuses is narrowed, and the apertures in the cribriform plate of the ethmoid completely closed in.

*Structure of the mucous membrane.*—The epithelium covering the mucous membrane differs in its character according to the functions of the part of the



nose in which it is found. Near the orifice of the nostril, the *vestibule*, where common sensation is chiefly or alone required, the epithelium is of the ordinary pavement or scaly variety. In the rest of the cavity, below the distribution of the olfactory nerves, i.e. in the respiratory portion of the nasal cavity, the epithelium is columnar and ciliated. This is the case also in the meatuses of the nose. In this region, beneath the epithelium and its basement membrane, is a fibrous layer infiltrated with lymph-corpuscles, so as to form in many parts a diffuse adenoid tissue, and beneath this a nearly continuous layer of smaller and larger glands, some mucous and some serous, the ducts of which open upon the surface. In the olfactory region, i.e. the region in which the terminal filaments from the olfactory nerves are distributed (see page 777), the epithelial cells are columnar and non-ciliated, and contain an oval nucleus, situated in the deeper part of the cell: their free surface presents a sharp outline, and their deep extremity is prolonged into a process which runs inwards, branching to communicate with similar processes from neighbouring cells, so as to form a network in the deep part of the mucous membrane. Lying between these central processes of the columnar cells are a large number of spindle-shaped cells (termed by Max Schultze, *olfactory cells*), which consist of a large spherical nucleus surrounded by a small amount of granular protoplasm, and possessing two processes, of which one runs outwards between the columnar epithelial cells, and projects on the surface of the mucous membrane; the other (the deep) process runs inwards, is frequently beaded like a nerve-fibre, and is believed by most observers to be in connection with one of the terminal filaments of the olfactory nerve. Amongst the branched ends of the columnar cells there is a deep layer of epithelial cells, of a conical shape, their broad end resting on the basement membrane, and their tapering extremity projecting between the other cells. Beneath the epithelium, extending through the thickness of the mucous membrane, is a layer of glands, the *glands of Bowman*, identical in structure with serous glands.

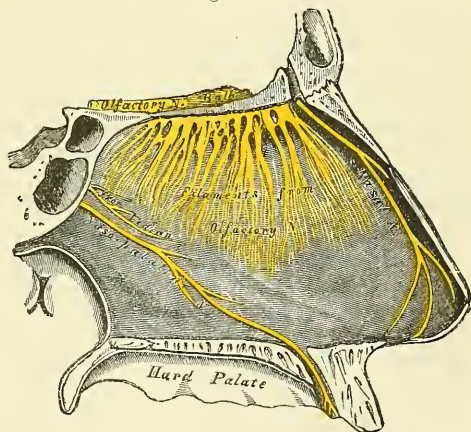
The mucous membrane is pigmented in the olfactory, but not in the other regions, being of a light yellow colour, at least in the white races.\*

The *arteries of the nasal fossæ* are the anterior and posterior ethmoidal, from the ophthalmic, which supply the ethmoidal cells, frontal sinuses, and roof of the nose; a minute twig from the small meningeal; the sphenopalatine, from the internal maxillary, which supplies the mucous membrane covering the spongy bones, the meatuses and septum; the inferior artery of the septum from the superior coronary of the facial; and the alveolar branch of the internal maxillary, which supplies the lining membrane of the antrum. The ramifications of these vessels form a close, plexiform network, beneath and in the substance of the mucous membrane.

The *veins of the nasal fossæ* form a close network beneath the mucous membrane. They pass, some with the veins accompanying the sphenopalatine artery, through the sphenopalatine foramen; and others, through the alveolar branch, to join the facial vein; some accompany the ethmoidal arteries, and

\* An interesting speculation has been suggested by Dr. W. Ogle (*Med.-Chir. Trans.* vol. liii. p. 277) as to the possible connection between the presence and abundance of this pigment and the perfection of the sense of smell.

FIG. 530.—Nerves of septum of nose.  
Right side.



terminate in the ophthalmic vein; and, lastly, a few communicate with the veins in the interior of the skull, through the foramina in the cribriform plate of the ethmoid bone, and the foramen cæcum.

The *nerves* are: the olfactory, the nasal branch of the ophthalmic, filaments from the anterior dental branch of the superior maxillary, the Vidian, the naso-palatine, descending anterior palatine, and nasal branches of Meckel's ganglion.

The *olfactory*, the special nerve of the sense of smell, is distributed over the upper third of the septum, and over the surface of the superior and middle spongy bones.

The *nasal branch of the ophthalmic* distributes filaments to the fore part of the septum, and outer wall of the nasal fossæ.

*Filaments from the anterior dental branch of the superior maxillary* supply the inferior meatus and inferior turbinated bone.

The *Vidian nerve* supplies the upper and back part of the septum, and superior spongy bone; and the *upper anterior nasal branches* from the sphenopalatine ganglion have a similar distribution.

The *naso-palatine nerve* supplies the middle of the septum.

The *larger, or anterior palatine nerve* supplies the middle and lower spongy bones.

*Surgical Anatomy.*—Instances of congenital deformity of the nose are occasionally met with, such as complete absence of the nose, an aperture only being present; or perfect development on one side, and suppression or malformation on the other; or there may be imperfect apposition of the nasal bones, so that the nose presents a median cleft or furrow. Deformities which have been acquired are much more common, such as flattening of the nose, the result of syphilitic necrosis; or imperfect development of the nasal bones in cases of congenital syphilis; or a lateral deviation of the nose may result from fracture.

The skin over the ala and tip of the nose is thick and closely adherent to subjacent parts. Inflammation of this part is therefore very painful, on account of the tension. It is largely supplied with blood, and, the circulation here being terminal, vascular engorgement is liable to occur, especially in women at the menopause, and in both sexes from disorders of digestion, exposure to cold, etc. The skin of the nose also contains a large number of sebaceous follicles, and these, as the result of intemperance, are apt to become affected and the nose reddened, congested, and irregularly swollen. To this the term '*grog-blossom*' is popularly applied. In some of these cases there is enormous hypertrophy of the skin and subcutaneous tissues, producing pendulous masses, termed *lipomata nasi*. Epithelioma and rodent ulcer may attack the nose, the latter being the more common of the two. Lupus and syphilitic ulceration frequently attack the nose, and may destroy the whole of the cartilaginous portion. In fact, *lupus vulgaris* begins more frequently on the ala of the nose than in any other situation.

Cases of congenital occlusion of one or both nostrils, or adhesion between the ala and septum, may occur and may require immediate operation, since the obstruction much interferes with sucking. Bony closure of the posterior nares may also occur.

To examine the nasal cavities, the head should be thrown back and the nose drawn upwards, the parts being dilated by some form of speculum. It can also be examined with the little finger or a probe, and in this way foreign bodies detected. A still more extensive examination can be made by Rouge's operation, which was introduced for the cure of ozæna, by the removal of any dead bone which may be present in this disease. The whole framework of the nose is lifted up by an incision made inside the mouth, through the junction of the upper lip with the bone; the septum nasi and the lateral cartilages are divided with strong scissors till the anterior nares are completely exposed. The posterior nares can be explored by reflected light from the mouth, by which the posterior nares can be illuminated. The examination is very difficult to carry out, and, as a rule, sufficient information regarding the presence of foreign bodies or tumours in the naso-pharynx can be obtained by the introduction of the finger behind the soft palate through the mouth. The septum of the nose may be displaced or deviate from the middle line: this may be the result of an injury or from some congenital defect in its development. Sometimes the deviation may be so great that the septum may come in contact with the outer wall of the nasal fossæ, and may even become adherent to it, thus producing complete obstruction. Perforation of the septum is not an uncommon affection, and may arise from several causes: syphilitic or tuberculous ulceration, blood tumour or abscess of the septum, and especially in workmen exposed to the vapour of bichromate of potash, from the irritating and corrosive action of the fumes. When small, the perforation may cause a peculiar whistling sound during respiration. When large, it may lead to the falling in of the bridge of the nose.



Epistaxis is a very common affection in children. It is rarely of much consequence, and will almost always subside, but in the more violent hæmorrhages of later life it may be necessary to plug the posterior nares. In performing this operation it is desirable to remember the size of the posterior nares. A ready method of regulating the size of the plug to fit the opening is to make it of the same size as the terminal phalanx of the thumb of the patient to be operated on.

Nasal polypus is a very common disease, and presents itself in three forms: the gelatinous, the fibrous, and the malignant. The first is by far the most common. It grows from the mucous membrane of the outer wall of the nasal fossa, where there is an abundant layer of highly vascular submucous tissue; rarely from the septum, where the mucous membrane is closely adherent to the cartilage and bone, without the intervention of much, if any, submucous tissue. Their most common seat is probably the middle turbinated bone. The fibrous polypus generally grows from the base of the skull behind the posterior nares, or from the roof of the nasal fossæ. The malignant polypi, both sarcomatous or carcinomatous, may arise in the nasal cavities and the nasopharynx; or they may originate in the antrum, and protrude through its inner wall into the nasal fossa.

Rhinoliths, or nose-stones, may sometimes be found in the nasal cavities, from the formation of phosphate of lime, upon either a foreign body or a piece of inspissated secretion.

## THE EYE

The eyeball is contained in the cavity of the orbit. In this situation it is securely protected from injury, whilst its position is such as to ensure the most extensive range of sight. It is acted upon by numerous muscles, by which it is capable of being directed to any part; it is supplied by vessels and nerves, and is additionally protected in front by several appendages, such as the eyebrow, eyelids, etc.

The eyeball is embedded in the fat of the orbit, but is surrounded by a thin membranous sac, the *capsule of Tenon*, which isolates it, so as to allow of free movement.

The **capsule of Tenon** (*tunica vaginalis oculi*) may be regarded as a distinct serous membrane, consisting of a parietal and visceral layer. The latter invests the posterior part of the globe from the ciliary margin of the cornea backwards to the entrance of the optic nerve, and is connected to it by very delicate connective tissue; the former (parietal) lines the hollow in the fat in which the eyeball is embedded, and is continued in front into the conjunctiva. It is strengthened in front at its lower part by a band of fibrous tissue, the *ligamentum suspensorium oculi*, which stretches across the orbit from its inner to its outer wall and forms a sort of sling for the eyeball. Both layers are lined on their free surfaces by endothelial cells. The cavity between them is continuous with the spaces between the different layers of the sheath of the optic nerve—that is to say, with the *subarachnoidean* between the pia-matral and the arachnoid sheath, and the *subdural* between the arachnoid and dural sheath—and into it empty the lymphatic vessels of the sclerotic. The capsule is pierced by the muscles of the eyeball near their insertion, and sends tubular prolongations on them, which become continuous with the sheath of the muscles. From the outer surface of these sheaths, expansions, consisting of elastic fibres and muscle cells, are given off to the margin of the orbit, which serve to limit the degree of contraction of the muscles.\*

The eyeball is composed of segments of two spheres of different sizes. The anterior segment is one of a small sphere, and forms about one-sixth of the eyeball. It is more prominent than the posterior segment, which is one of a much larger sphere, and forms about five-sixths of the globe. The segment of the larger sphere is opaque, and formed by the sclerotic, the tunic of protection to the eyeball; the smaller sphere is transparent, and formed by the cornea. The axes of the eyeballs are nearly parallel, and do not correspond to the axes of the orbits which are directed outwards. The optic nerves follow the direction of the

\* See a paper by Mr. C. B. Lockwood, *Journal of Anatomy and Physiology*, vol. xx. part i. p. 1.



axes of the orbits and are therefore not parallel; they enter the eyeball a little to their inner or nasal side. The eyeball measures rather more in its transverse than in its antero-posterior and vertical diameters, the former amounting to about an inch, the latter to about nine-tenths of an inch.

The eyeball is composed of several investing tunics, and of fluid and solid refracting media, called *humours*.

### TUNICS OF THE EYE

The tunics are three in number :

1. Sclerotic and Cornea.
2. Choroid, Iris, and Ciliary Processes.
3. Retina.

#### I. THE SCLEROTIC AND CORNEA

The sclerotic and cornea (fig. 531) form the external tunic of the eyeball; they are essentially fibrous in structure, the sclerotic being opaque, and forming the posterior five-sixths of the globe; the cornea, which forms the remaining sixth, being transparent.

The **Sclerotic** (*σκληρός*, *hard*) has received its name from its extreme density and hardness; it is a firm, unyielding, fibrous membrane, serving to maintain the form of the globe. It is much thicker behind than in front. Its *external surface* is of a white colour, quite smooth, except at the points where the Recti and Obliqui muscles are inserted into it, and covered for part of its extent by the conjunctival membrane: hence the whiteness and brilliancy of the front of the eyeball. Its *inner surface* is stained of a brown colour, marked by grooves, in which are lodged the ciliary nerves, and connected by an exceedingly fine cellular tissue (*lamina fusca*) with the outer surface of the choroid. Behind, it is pierced by the optic nerve a little to its inner or nasal side, and is continuous with the fibrous sheath of the nerve, which is derived from the dura mater. At the point where the optic nerve passes through the sclerotic, this membrane forms a thin cribriform lamina (the *lamina cribrosa*); the minute orifices in this layer serve for the transmission of the nervous filaments, and the fibrous septa dividing them from one another are continuous with the membranous processes which separate the bundles of nerve-fibres. One of these openings, larger than the rest, occupies the centre of the lamella; it is called the *porus opticus*, and transmits the arteria centralis retinae to the interior of the eyeball. Around the cribriform lamella are numerous small apertures for the transmission of the ciliary vessels and nerves, and about midway between the margin of the cornea and the entrance of the optic nerve are four or five large apertures, for the transmission of veins (*vena vorticosæ*). In front the sclerotic is continuous with the cornea by direct continuity of tissue, but the opaque sclerotic overlaps the cornea rather more on its outer than on its inner surface.

*Structure.*—The sclerotic is formed of white fibrous tissue intermixed with fine elastic fibres, and of flattened connective-tissue corpuscles, some of which are pigmented, contained in cell-spaces between the fibres. These fibres are aggregated into bundles, which are arranged chiefly in a longitudinal direction. It yields gelatin on boiling. Its vessels are not numerous, the capillaries being of small size, uniting at long and wide intervals. The existence of nerves in it is doubtful.

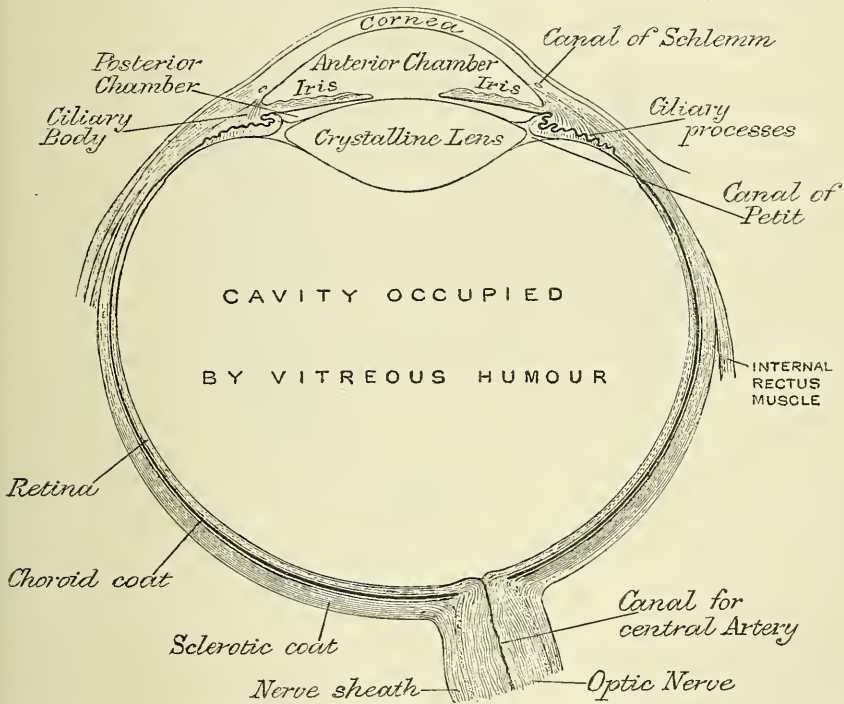
The **Cornea** is the projecting transparent part of the external tunic of the eyeball, and forms the anterior sixth of the globe. It is almost circular in shape, occasionally a little broader in the transverse than in the vertical direction. It is convex anteriorly, and projects forwards from the sclerotic in the same manner that a watch-glass does from its case. Its degree of curvature varies in different individuals, and in the same individual at different periods of life, it being more

prominent in youth than in advanced life, when it becomes flattened. The cornea is dense and of uniform thickness throughout; its posterior surface is perfectly circular in outline, and exceeds the anterior surface slightly in extent, from the latter being overlapped by the sclerotic.

*Structure.*—The cornea consists of four layers: namely (1) several strata of epithelial cells, continuous with those of the conjunctiva; (2) a thick central fibrous structure, the *cornea proper*; (3) a homogeneous elastic lamina; and (4) a single layer of epithelial cells, forming part of the lining membrane of the anterior chamber of the eyeball. The name of *membrane of Descemet* or *Demours* is given to this posterior elastic lamina and its endothelial coating.

The *conjunctival epithelium*, which covers the front of the cornea proper, consists of several strata of epithelial cells. The lowermost cells are columnar: then follow two or three layers of polyhedral cells, some of which present ridges and furrows, similar to those found in the cuticle. Lastly, there are three or four layers of scaly epithelium, with flattened nuclei.

FIG. 531.—A horizontal section of the eyeball. (Allen.)



The *proper substance of the cornea* is fibrous, tough, unyielding; perfectly transparent, and continuous with the sclerotic, with which it is identical in structure. It is composed of about sixty flattened lamellæ, superimposed one on another. These lamellæ are made up of bundles of fibrous connective tissue, the fibres of which are directly continuous with the fibres of the sclerotic. The fibres of each lamella are for the most part parallel with each other; those of alternating lamellæ at right angles to each other. Fibres, however, frequently pass from one lamella to the next.

The lamellæ are connected with each other by an interstitial cement-substance, in which are spaces, the *corneal spaces*. The spaces are stellate in shape and have numerous offsets, by which they communicate with other spaces. Each space contains a cell, the *corneal corpuscle*, which resembles in form the space in which it is contained, but does not entirely fill it.

Immediately beneath the conjunctival epithelium, the cornea proper presents

certain characteristic differences, which have led some anatomists to regard it as a distinct membrane, and it has been named by Bowman the *anterior elastic lamina*. It differs, however, from the true elastic lamina or membrane of Descemet in many essential particulars, presenting evidence of fibrillar structure, and not having the same tendency to curl inwards, or to undergo fracture, when detached from the other layers of the cornea. It consists of extremely closely interwoven fibrils, similar to those found in the rest of the cornea proper, but contains no corneal corpuscles. It seems therefore more proper to regard it as a part of the proper tissue of the cornea.\*

The *posterior elastic lamina*, which covers the proper structure of the cornea behind, presents no structure recognisable under the microscope. It consists of a hard, elastic, and perfectly transparent homogeneous membrane, of extreme thinness, which is not rendered opaque by either water, alcohol, or acids. It is very brittle, but its most remarkable property is its extreme elasticity, and the tendency which it presents to curl up, or roll upon itself, with the attached surface innermost, when separate from the proper substance of the cornea. Its use appears to be (as suggested by Dr. Jacob) 'to preserve the requisite permanent correct curvature of the flaccid cornea proper.'

At the margin of the cornea this posterior elastic membrane breaks up into fibres to form a reticular structure at the outer angle of the anterior chamber, the intervals between the fibres forming small cavernous spaces, the *spaces of Fontana*. These little recesses communicate with a somewhat larger space in the substance of the sclerotic close to its junction with the cornea. This is the *canal of Schlemm*, or *sinus circularis iridis*, and, according to some authors, is a lymph canal, but according to others is a venous sinus. Some of the fibres of this reticulated structure are continued into the front of the iris, forming the *ligamentum pectinatum iridis*; while others are connected with the fore part of the sclerotic and choroid.

The *endothelial lining of the aqueous chamber* covers the posterior surface of the posterior elastic lamina. It consists of a single layer of polygonal flattened transparent nucleated cells, similar to those found lining other serous cavities.

*Arteries and Nerves*.—The cornea is a non-vascular structure, the capillary vessels terminating in loops at its circumference. Lymphatic vessels have not as yet been demonstrated in it, but are represented by the channels in which the bundles of nerves run; these are lined by an endothelium, and are continuous with the cell-spaces. The nerves are numerous, twenty-four to thirty-six in number (Kölliker); forty to forty-five (Waldeyer and Sümisch); they are derived from the ciliary nerves, and enter the laminated tissue of the cornea. They ramify throughout its substance in a delicate network, and their terminal filaments form a firm and closer plexus on the surface of the cornea proper beneath the epithelium. This is termed the *subepithelial plexus*, and from it fibrils are given off which ramify between the epithelial cells, forming a network which is termed the *intra-epithelial plexus*.

*Dissection*.—In order to separate the sclerotic and cornea, so as to expose the second tunic, the eyeball should be immersed in a small vessel of water, and held between the finger and thumb. The sclerotic is then carefully incised, in the equator of the globe, till the choroid is exposed. One blade of a pair of probe-pointed scissors is now introduced through the opening thus made, and the sclerotic divided around its entire circumference, and removed in separate portions. The front segment being then drawn forwards, the handle of the scalpel should be pressed gently against it at its connection with the iris, and these being separated, a quantity of perfectly transparent fluid will escape; this is the aqueous humour. In the course of the dissection, the ciliary nerves may be seen lying in the loose cellular tissue between the choroid and sclerotic, or contained in delicate grooves on the inner surface of the latter membrane.

\* This layer has been called by Reichert the 'anterior limiting layer,' a name which appears more applicable to it than that of 'anterior elastic lamina.'



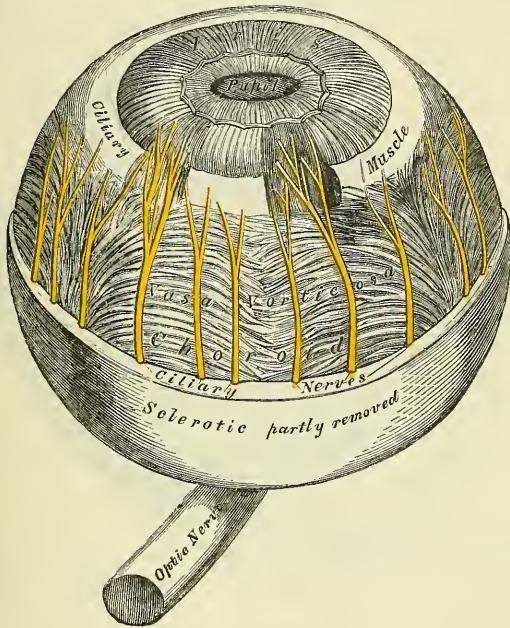
## II. THE CHOROID, IRIS, AND CILIARY PROCESSES

The Second Tunic of the Eye is formed by the choroid behind; the iris and ciliary processes in front; and by the ciliary muscle, opposite the junction of the sclerotic and cornea.

The choroid is the vascular and pigmentary tunic of the eyeball, investing the posterior five-sixths of the globe, and extending as far forwards as the cornea; the ciliary processes being appendages of the choroid developed from its inner surface in front. The iris is the circular muscular septum, which hangs vertically behind the cornea, presenting in its centre a large circular aperture, the *pupil*. The ciliary muscle forms the white ring observed at the point where the choroid and iris join with each other, and with the sclerotic and cornea.

The **Choroid** is a thin, highly vascular membrane, of a dark brown or chocolate colour, which invests the posterior five-sixths of the central part of the globe.

FIG. 532.—The choroid and iris. (Enlarged.)



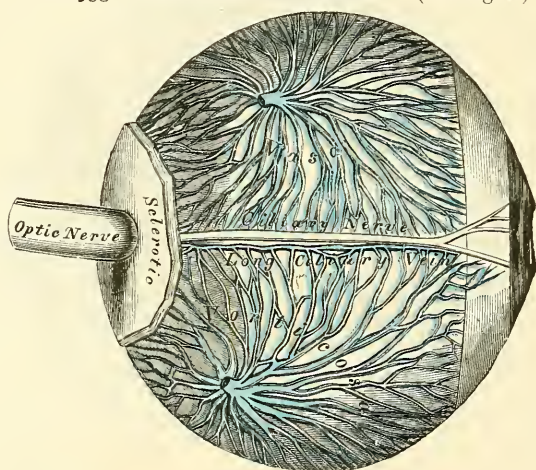
It is pierced behind by the optic nerve, and extends in front as far forwards as the ciliary ligament, where it is connected with the iris, and bends inwards, forming on its inner surface a series of folds or plaitings, the *ciliary processes*. It is thicker behind than in front. Externally, it is connected by a fine cellular web with the inner surface of the sclerotic. Its inner surface is attached to the retina.

**Structure.**—The choroid consists mainly of a dense capillary plexus and of small arteries and veins, carrying the blood to and returning it from this plexus. On its external surface, i.e. the surface next the sclerotic, is a thin membrane of fine elastic fibres, arranged in lamellæ, which are covered with endothelium, and form spaces, which communicate by perforations in the sclerotic, through which the vessels and nerves enter, with the capsule of Tenon. This layer is named the *lamina suprachoroidea*, and is loosely connected with the lamina fusca of the sclerotic.

Internal to this is the *choroid proper*, and in consequence of the small arteries and veins being arranged on the outer surface of the capillary network, it is customary to describe this as consisting of two layers: the outermost composed

of small arteries and veins, with pigment-cells interspersed between them, and the inner consisting of a capillary plexus. The *external layer* consists, in part, of the larger branches of the short ciliary arteries which run forwards between the veins, before they bend inwards to terminate in the capillaries; but is formed principally of veins, which are named, from their arrangement, *venæ vorticosæ*. They converge to four or five equidistant trunks, which pierce the sclerotic midway between the margin of the cornea and the entrance of the optic nerve. Interspersed between the vessels are lodged dark star-shaped pigment-cells, the fibrous offsets from which, communicating with similar branchings from neighbouring cells, form a delicate network or stroma, which towards the inner surface of the choroid loses its pigmentary character. The *internal layer* consists of an exceedingly fine capillary plexus, formed by the short ciliary vessels, and is known as the *tunica Ruyschiana*. The network is close, and finer at the hinder part of the choroid than in front. About half an inch behind the cornea its meshes become larger, and are continuous with those of the ciliary processes. On the inner surface of this tunic is a very thin, structureless, or, according to Kölliker,

FIG. 533.—The veins of the choroid. (Enlarged.)



faintly fibrous membrane, called the *lamina vitrea*; it is closely connected with the stroma of the choroid, and separates it from the pigmentary layer of the retina.

The ciliary processes should now be examined. They may be exposed, either by detaching the iris from its connection with the Ciliary muscle, or by making a transverse section of the globe, and examining them from behind.

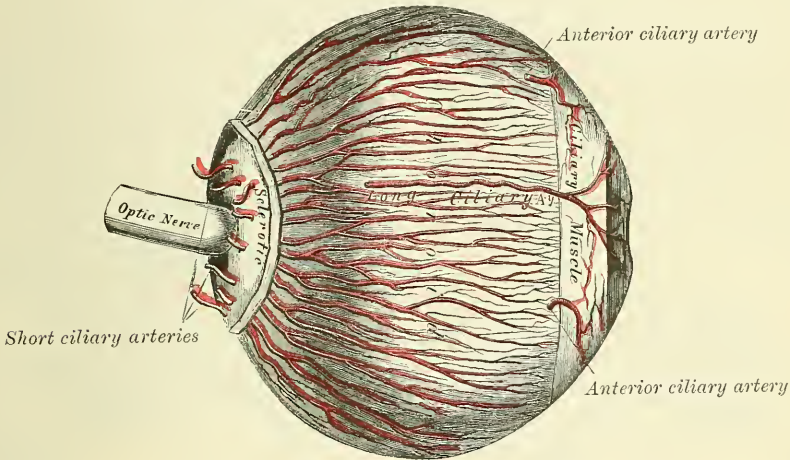
The *ciliary processes* are formed by the plaiting and folding inwards of the various layers of the choroid (i.e. the choroid proper and the lamina vitrea) at its anterior margin, and are received between corresponding foldings of the suspensory ligament of the lens, thus establishing a connection between the choroid and inner tunic of the eye. They are arranged in a circle, and form a sort of plaited frill behind the iris, round the margin of the lens. They vary between sixty and eighty in number, lie side by side, and may be divided into large and small; the latter, consisting of about one-third of the entire number, are situated in the spaces between the former, but without regular alternation. The larger processes are each about one-tenth of an inch in length, and are attached by their periphery to the ciliary muscle, and are continuous with the layers of the choroid: the opposite margin is free, and rests upon the circumference of the lens. Their anterior surface is turned towards the back of the iris, with the circumference of which they are continuous. The posterior surface is closely connected with the suspensory ligament of the lens.



**Structure.**—The ciliary processes are similar in structure to the choroid, but the vessels are larger, and have chiefly a longitudinal direction. They are covered on their inner surface with a layer of black pigment-cells, continuous with the cells of the pigmentary layer of the retina, and in their stroma are also other, stellate, pigment-cells, which, however, are not so numerous as in the choroid itself, and towards the free extremities of the folds are devoid of pigment.

The **Iris** (*iris*, a rainbow) has received its name from its various colours in different individuals. It is a thin, circular-shaped, contractile curtain, suspended in the aqueous humour behind the cornea, and in front of the lens, being perforated a little to the nasal side of its centre by a circular aperture, the *pupil*, for the transmission of light. By its circumference it is intimately connected with the choroid; externally to this is the ciliary muscle, by which it is connected to the sclerotic and cornea; its inner edge forms the margin of the pupil; its surfaces are flattened, and look forwards and backwards, the anterior surface towards the cornea, the posterior towards the ciliary processes and lens. The circumference of the iris is connected to the cornea by a reticular structure denominated the *ligamentum pectinatum iridis*. The anterior surface of the iris is variously coloured in different individuals, and marked by lines which converge towards

FIG. 534.—The arteries of the choroid and iris.  
The sclerotic has been mostly removed. (Enlarged.)



the pupil. The posterior surface is of a deep purple tint, from being covered by dark pigment; it is hence named *uvea*, from its resemblance in colour to a ripe grape.

**Structure.**—The iris is composed of the following structures:

1. In front is a layer of polyhedral cells on a delicate hyaline basement-membrane. This layer is continuous with the epithelial layer of the membrane of Descemet, and in men with dark coloured irides the cells contain pigment-granules.

2. *Stroma.*—The stroma consists of fibres and cells. The former are made up of fine delicate bundles of fibrous tissue, of which some few fibres have a circular direction at the circumference of the iris; but the chief mass consists of fibres radiating towards the pupil. They form, by their interlacement, a delicate mesh, in which the vessels and nerves are contained. Interspersed between the bundles of connective tissue are numerous branched cells with fine processes. Many of them in dark eyes contain pigment-granules, but in blue eyes and the pink eyes of albinos they are unpigmented.

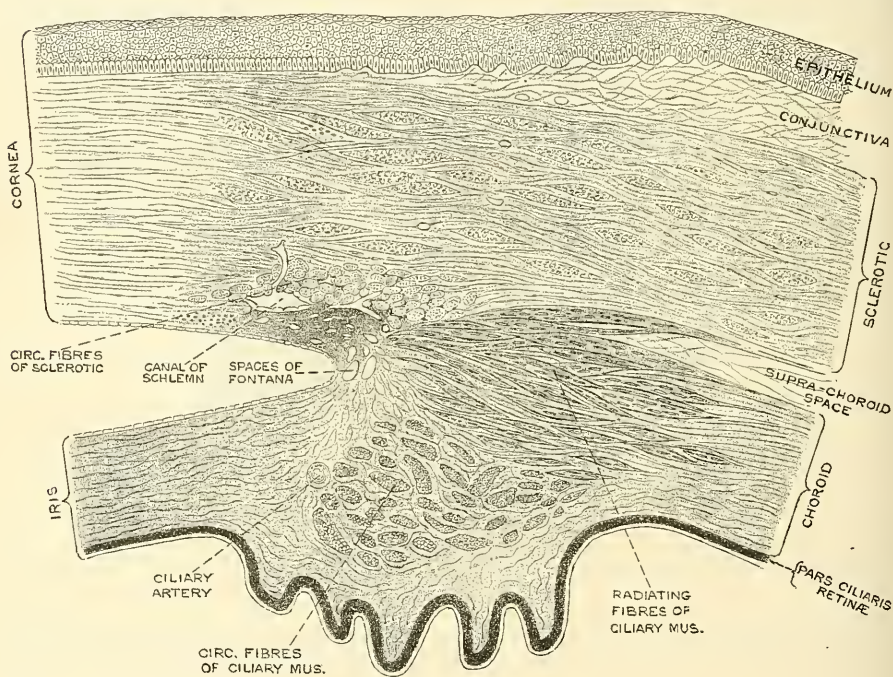
3. The *muscular fibre* is involuntary, and consists of circular and radiating fibres. The *circular fibres* (sphincter of the pupil) surround the margin of the



pupil on the posterior surface of the iris, like a sphincter, forming a narrow band about one-thirtieth of an inch in width; those near the free margin being closely aggregated; those more external somewhat separated, and forming less complete circles. The *radiating fibres* (dilator of the pupil) converge from the circumference towards the centre, and blend with the circular fibres near the margin of the pupil.

4. *Pigment.*—The situation of the pigment-cells differs in different irides. In the various shades of blue eyes, the only pigment-cells are several layers of small round or polyhedral cells, filled with dark pigment, situated on the posterior surface of the iris, and continuous with the pigmentary lining of the ciliary processes. The colour of the eye in these individuals is due to this colouring matter showing more or less through the texture of the iris. In the albino, even this pigment is absent. In the grey, brown, and black eye there are, as mentioned

FIG. 535.—Section of the eye, showing the relations of the cornea, sclerotic, and iris, together with the Ciliary muscle and the cavernous spaces near the angle of the anterior chamber. (Waldeyer.)



above, pigment-granules to be found in the cells of the stroma and in the epithelial layer on the front of the iris, to which the colour of the eye is due.

The *arteries of the iris* are derived from the long and anterior ciliary, and from the vessels of the ciliary processes (see page 580). The long ciliary arteries having reached the attached margin of the iris divide into an upper and lower branch, and encircling the iris anastomose with corresponding branches from the opposite side; into this vascular zone (circulus major) the anterior ciliary pour their blood. From this zone vessels radiate to the free margin of the iris, and these communicate by branches from one to another and thus form a second zone (circulus minor) in this situation.

The *nerves of the iris* are derived from the ciliary branches of the lenticular ganglion, and the long ciliary from the nasal branch of the ophthalmic division of the fifth. After reaching the iris in the manner described above (page 786) they form a plexus around the attached margin of the iris; from this are derived non-medullated fibres which terminate in the circular and radiating muscular

fibres. Their exact mode of termination has not been ascertained. Other fibres from the plexus terminate in a network on the anterior surface of the iris. The fibres derived from the motor root of the lenticular ganglion (third nerve) supply the circular fibres, while those derived from the sympathetic supply the radiating fibres.

*Membrana pupillaris*.—In the foetus, the pupil is closed by a delicate transparent vascular membrane, the *membrana pupillaris*, which divides the space into which the iris is suspended into two distinct chambers. This membrane contains numerous minute vessels, continued from the margin of the iris to those on the front part of the capsule of the lens. These vessels have a looped arrangement, and converge towards each other without anastomosing. Between the seventh and eighth month the membrane begins to disappear by its gradual absorption, from the centre towards the circumference, and at birth only a few fragments remain. It is said sometimes to remain permanent and produce blindness.

The *Ciliary muscle* (Bowman) consists of unstriated fibres: it forms a greyish, semitransparent, circular band, about one-eighth of an inch broad, on the outer surface of the fore part of the choroid. It is thickest in front, and gradually becomes thinner behind. It consists of two sets of fibres, radiating and circular. The former, much the more numerous, arise at the point of junction of the cornea and sclerotic, and, passing backwards, are attached to the choroid opposite to the ciliary processes. One bundle, according to Waldeyer, is continued backwards to be inserted into the sclerotic. The circular fibres are internal to the radiating ones and to some extent unconnected with them, and have a circular course around the attachment of the iris. They are sometimes called the 'ring muscle' of Müller, and were formerly described as the ciliary ligament. The Ciliary muscle is admitted to be the chief agent in accommodation, i.e. in adjusting the eye to the vision of near objects. Mr. Bowman believed that this was effected by its compressing the vitreous body, and so causing the lens to advance; but the view which now prevails is that the contraction of the muscle, by drawing on the ciliary processes, relaxes the suspensory ligament of the lens, thus allowing the anterior surface of the lens to become more convex. The pupil is at the same time slightly contracted.\*

### III. THE RETINA

The **Retina** is a delicate nervous membrane, upon the surface of which the images of external objects are received. Its outer surface is in contact with the choroid; the inner surface with the vitreous body. Behind, it is continuous with the optic nerve; it gradually diminishes in thickness from behind forwards; and, in front, extends nearly as far forwards as the ciliary muscle, where it terminates by a jagged margin, the *ora serrata*. It is soft, semitransparent and of a pinkish tint in the fresh state; but soon becomes clouded, opaque, and bleached when exposed to sunlight. Exactly in the centre of the posterior part of the retina, and at a point, corresponding to the axis of the eye, in which the sense of vision is most perfect, is a round, elevated, yellowish spot, called, after its discoverer, the *yellow spot* or *limbus luteus* (*macula lutea*) of Sömmerring; having a central depression at its summit, the *fovea centralis*. The retina in the situation of the fovea centralis is exceedingly thin; so much so that the dark colour of the choroid is distinctly seen through it; so that it presents more the appearance of a foramen, and hence the name 'foramen of Sömmerring' at first given to it. It exists only in man, the quadruped, and some saurian reptiles. About one-tenth of an inch to the inner side of the yellow spot is the point of entrance of the optic nerve (*porus opticus*); here the nervous substance is slightly raised so as to form an eminence (*colliculus nervi optici*); the *arteria centralis retinae* pierces its centre. This is the only part of the surface of the retina from which the power of vision is absent.

\* See explanation and diagram in Power's *Illustrations of some of the Principal Diseases of the Eye*, p. 590.

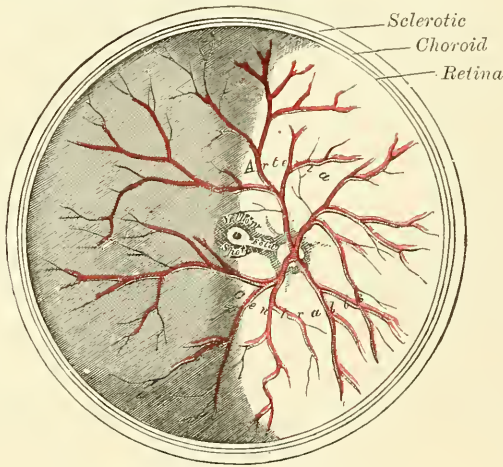


**Structure.**—The retina is an exceedingly complex structure, and, when examined microscopically by means of sections made perpendicularly to its surface, is found to consist of ten layers, which are named from within outwards, as follows :

1. Membrana limitans interna.
2. Fibrous layer, consisting of nerve-fibres.
3. Vesicular layer, consisting of nerve-cells.
4. Inner molecular, or granular, layer.
5. Inner nuclear layer.
6. Outer molecular, or granular, layer.
7. Outer nuclear layer.
8. Membrana limitans externa.
9. Layer of rods and cones (Jacob's membrane).
10. Pigmentary layer.

1. The *membrana limitans interna* is the most internal layer of the retina, and is in contact with the hyaloid membrane of the vitreous humour. It is derived

FIG. 536.—The arteria centralis retinae, yellow spot, etc., the anterior half of the eyeball being removed. (Enlarged.)



from the supporting framework of the retina, with which tissue it will be described.

2. The *fibrous layer* is made up of nerve-fibres, the direct continuation of the fibres of the optic nerve. This nerve therefore passes through all the other layers of the retina, except the one previously mentioned, to reach its destination in the fibrous layer. As the nerve passes through the lamina cribrosa of the sclerotic coat, the fibres of which it is composed lay aside their medullary sheaths and are continued onwards, through the choroid and retina, as simple axis-cylinders. When these non-medullated fibres reach the internal surface of the retina, they radiate from their point of entrance over the surface of the retina, grouped in bundles, and in many places, according to Michel, arranged in plexuses. The layer is thickest at the optic nerve entrance, and gradually diminishes in thickness towards the ora serrata.

3. The *vesicular layer* consists of a single layer of large ganglion-cells; except in the macula lutea, where there are several layers. The cells are somewhat flask-shaped; their rounded internal margin resting on the preceding layer and sending off a single process, which is prolonged into the fibrous layer, and is believed to be continuous with a nerve-fibre. From the opposite extremity of the cell one or more thicker processes extend into the inner molecular layer,



where they divide dichotomously and become lost in its reticulum, or, according to some, pass through this layer to reach the inner nuclear layer.

4. The *inner molecular layer* consists of a stratum of granular-looking substance, from which circumstance it is sometimes called the 'inner granular' layer. It is made up of a dense reticulum of minute fibrils, derived from the branched processes of the ganglion-cells and from processes derived from certain cells contained in the next layer, immediately to be described. Within the reticulum formed by these fibrils a few branched cells are embedded.

5. The *inner nuclear layer* is made up of a number of closely packed cells, of which there are three different kinds. (1) A large number of oval cells, which are commonly regarded as bipolar nerve-cells, and are much more numerous than either of the other kind. They consist of a large oval nuclear body placed vertically to the surface, containing a distinct nucleus: they are surrounded by a small amount of protoplasm, which is prolonged into two processes, one of these passes inwards into the inner molecular layer, is varicose in appearance,

FIG. 537.

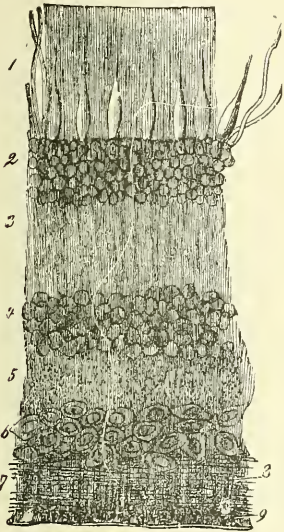
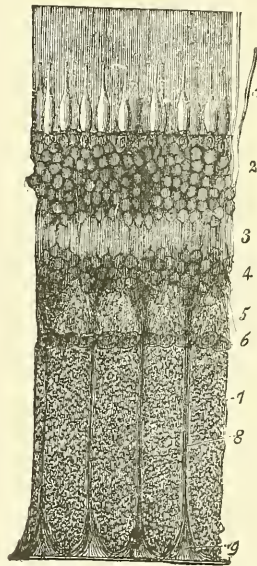


FIG. 538.



Vertical sections of the human retina. Fig. 537, half an inch from the entrance of the optic nerve. Fig. 538, close to the latter. 1. Layer of rods and cones (*columnar layer*), bounded underneath by the *membrana limitans externa*. 2. External nuclear layer. 3. Outer molecular layer. 4. Internal nuclear layer. 5. Inner molecular layer. 6. Layer of the ganglion-cells. 7. Expansion of optic fibres. 8. Sustentacular fibres of Müller. 9. Their attachment to the *membrana limitans interna*.

and, as stated above, is continuous with the processes of the ganglion-cells. The other process passes outwards, into the outer molecular layer, and there breaks up into a number of branches. According to some observers the divisions thus formed communicate with the rod and cone-fibres (Merkel). (2) At the innermost part of this inner nuclear layer is a stratum of cells, which possess protoplasmic processes, which ramify in the inner molecular layer; while at the outermost part of the layer is a second stratum of cells, whose processes ramify in the outer molecular layer. (3) Some few cells are also found in this layer, connected with the fibres of Müller, and will be described with those structures.

6. The *outer molecular layer* is much thinner than the inner molecular layer; but, like it, consists of a dense network of minute fibrils, derived from the processes of the cells of the preceding layer, and presents the same granular appearance. It differs, however, from the inner molecular layer in containing branched stellate cells, the processes of which are extremely fine and exhibit varicosities, like nerve-fibrils. They are therefore considered by Schultze to be ganglion-cells.

7. *The outer nuclear layer.*—Like the inner nuclear layer, this layer contains several strata of clear oval nuclear bodies; they are of two kinds, and on account of their being respectively connected with the rods and cones of Jacob's membrane, are named rod-granules and cone-granules. The *rod-granules* are much the more numerous, and are placed at different levels throughout the layer. They present a peculiar cross-striped appearance, and have prolonged from either extremity a fine process: the outermost is continuous with a single rod of Jacob's membrane; the innermost passes inwards towards the outer molecular layer and terminates in an enlarged extremity, from which are given off a number of minute fibrils, which enter the outer molecular layer. In its course it presents numerous varicosities. The *cone-granules*, fewer in number than the rod-granules, are placed close to the *membrana limitans externa*, and are closely connected with the cones of Jacob's membrane. They do not present any cross-striping, but contain a pyriform nucleus, which almost completely fills the cell. From their inner extremity a thick process passes inwards to the outer molecular layer; where, like the processes of the rod-cells, it terminates in an enlargement, from which are given off numerous fine fibrils, which enter the outer molecular layer.

8. *The membrana limitans externa.*—This layer, like the *membrana limitans interna*, is derived from the fibres of Müller, with which structures it will be described.

9. *Jacob's membrane (bacillary layer).*—The elements which compose this layer are of two kinds, *rods* and *cones*, the former being much more numerous than the latter. The *rods* are solid, of nearly uniform size, and arranged perpendicularly to the surface. Each rod consists of two portions, an outer and inner, which are joined together by a cement-substance and are of about equal length. They differ from each other as regards refraction and in their behaviour with colouring reagents, the inner portion becoming stained by carmine, iodine, &c., the outer portion remaining unstained with these reagents, but staining yellowish-brown with osmic acid. The outer portion of each rod is marked by transverse striæ, and is made up of a number of thin discs superimposed on one another. It also exhibits faint longitudinal markings. The inner portion of each rod, at its inner extremity where it is joined to the processes of the rod-granules, is indistinctly granular; at its outer extremity it presents a fine longitudinal striation, being composed of fine, bright, highly refracting fibrils.

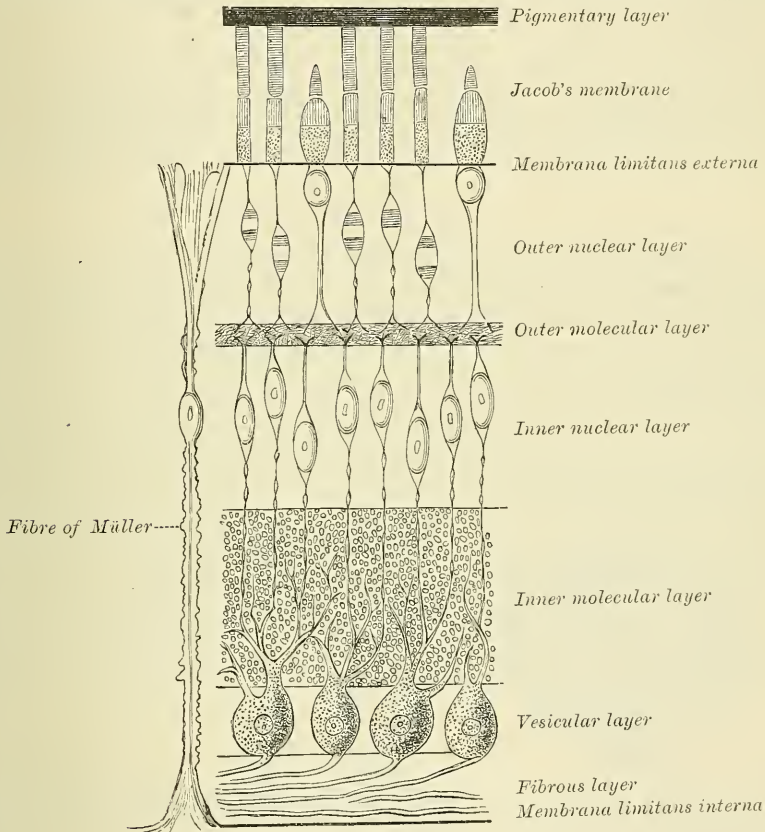
The *cones* are conical or flask-shaped, their broad ends resting upon the *membrana limitans externa*, the narrow pointed extremity being turned to the choroid. Like the rods, they are made up of two portions, outer and inner; the outer portion being a short conical process, which, like the outer segment of the rods, presents transverse striæ. The inner portion resembles the inner portion of the rods in structure, presenting an outer striated and an inner granular appearance; but differs from it in size, being bulged out laterally and presenting a flask shape. The chemical and optical character of the two portions is identical with that of the rods.

10. *The pigmentary layer, or tapetum nigrum.*—The most external layer of the retina, formerly regarded as a part of the choroid, consists of a single layer of hexagonal epithelium cells, loaded with pigment-granules (fig. 23). In the eyes of albinos, the cells of the pigmentary layer are present, but they contain no colouring matter. In many of the mammals also, as in the horse, and many of the carnivora, there is no pigment in the cells of this layer, and the choroid possesses a beautiful iridescent lustre, which is termed the *tapetum lucidum*.

*Connective-tissue framework of the retina.*—Almost all these layers of the retina are connected together by a sort of supporting connective tissue, which has been named the *fibræ of Müller*, or *radiating fibres*, from which the *membrana limitans interna et externa* are derived. These fibres are found stretched between the two limiting layers, 'as columns between a floor and a ceiling,' and passing through all the nervous layers, except Jacob's membrane. They commence on the inner surface of the retina by a conical hollow base, which sometimes contains

a spheroidal body, which stains deeply with hæmatoxylin, the edges of the bases of adjoining fibres being united and thus forming a boundary line, which is the *membrana limitans interna*. As they pass through the various layers, they present a roughness on their surface, as if a number of membranous processes had been abruptly broken off. By these they are continuous with the reticulum of the inner and outer molecular layer and with a sponge-like stroma, in which the nuclei of the inner nuclear layer are embedded. In the inner nuclear layer each fibre of Müller presents a clear oval nucleus, referred to above, which is sometimes situated at the side of, sometimes altogether within the fibre. In the outer nuclear layer the fibre breaks up into fine lamellæ, which form a fenestrated or sponge-like tissue, in which the rod and cone granules are enclosed, and at

FIG. 539.—The layers of the retina (diagrammatic). (After Schultze.)



the outer border of this layer these lamellæ unite along a definite line, forming the *membrana limitans externa*.

*Macula lutea and fovea centralis.*—The structure of the retina at the yellow spot presents some modifications. In the *macula lutea* (1) the nerve-fibres are wanting as a continuous layer; (2) the vesicular layer consists of several strata of cells, instead of a single layer; (3) in Jacob's membrane there are no rods, but only cones, and these are longer and narrower than in other parts; and (4) in the outer nuclear layer there are only cone-fibres, which are very long and arranged in curved lines. At the *fovea centralis* the only parts which exist are the cones of Jacob's membrane; the outer nuclear layer, the cone-fibres of which are almost horizontal in direction; and an exceedingly thin inner granular layer. The colour of the spot seems to imbue all the layers except Jacob's membrane;



it is of a rich yellow, deepest towards the centre, and does not appear to consist of pigment-cells, but simply a staining of the constituent parts.

At the *ora serrata* the layers of the retina terminate abruptly, and the retina is continued onwards as a single layer of elongated columnar cells covered by the pigmentary layer. This prolongation is known as the *pars ciliaris retinae*, and can be traced forwards to the tips of the ciliary processes, and there gives place to the uvea or layer of pigment on the posterior surface of the iris.

The *arteria centralis retinae* and its accompanying vein pierce the optic nerve, and enter the globe of the eye through the porus opticus. It immediately divides into four or five branches, which at first run between the hyaloid membrane and the nervous layer; but they soon enter the latter membrane, and pass forwards, dividing dichotomously. From these branches a minute capillary plexus is given off, which does not extend beyond the inner nuclear layer. In the foetus, a small vessel passes forwards, through the vitreous humour, to the posterior surface of the capsule of the lens.

## HUMOURS OF THE EYE

The Refracting media, or Humours of the Eye, are three in number :

Aqueous.	Vitreous.	Crystalline lens.
----------	-----------	-------------------

### I. THE AQUEOUS HUMOUR

The **aqueous humour** completely fills the anterior and posterior chambers of the eyeball. It is small in quantity (scarcely exceeding, according to Petit, four or five grains in weight), has an alkaline reaction, in composition is little more than water, less than one-fiftieth of its weight being solid matter, chiefly chloride of sodium.

The *anterior chamber* is the space bounded in front by the cornea; behind, by the front of the iris. The *posterior chamber* was the name formerly given to a space which was believed to exist between the iris in front and the capsule of the lens, its suspensory ligament and the ciliary processes, behind. It is now known that the posterior surface of the iris is in immediate contact with the lens throughout the greater part of its extent. The only space which remains, to represent the posterior chamber, is a narrow chink between the peripheral part of the iris, the suspensory ligament and the ciliary processes.

In the adult, these two chambers communicate through the pupil; but in the foetus in the seventh month, when the pupil is closed by the *membrana pupillaris*, the two chambers are quite separate.

### II. VITREOUS BODY

The **vitreous body** forms about four-fifths of the entire globe. It fills the concavity of the retina, and is hollowed in front for the reception of the lens and its capsule. It is perfectly transparent, of the consistence of thin jelly, and is composed of an albuminous fluid enclosed in a delicate transparent membrane, the *hyaloid*. This membrane invests the outer surface of the vitreous body; it is intimately connected in front with the suspensory ligament of the lens; and is continued into the back part of the capsule of the lens. It has been supposed, by Hannover, that from its inner surface numerous thin lamellæ are prolonged inwards in a radiating manner, forming spaces in which the fluid is contained. In the adult, these lamellæ cannot be detected even after careful microscopic examination in the fresh state, but in preparations hardened in weak chromic acid, it is possible to make out a distinct lamellation at the periphery of the body; and in the foetus a peculiar fibrous texture pervades the mass, the fibres joining at numerous points, and presenting minute nuclear granules at their point of junction. In the centre of the vitreous humour, running from the

position of the entrance of the optic nerve on the retina to the posterior surface of the lens, is a canal, filled with fluid and lined by a prolongation of the hyaloid membrane. This is the *canal of Stilling*, and is the canal which in the embryonic vitreous humour conveyed the minute artery from the central artery of the retina to the back of the lens. The fluid from the vitreous body resembles nearly pure water; it contains, however, some salts, and a little albumen.

The hyaloid membrane encloses the whole of the vitreous humour. At the situation of the ora serrata it splits into two layers, one of which passes over the anterior surface of the vitreous body, where it is hollowed out for the reception of the lens; the other passes over the ciliary body to be attached to the margin of the lens, forming the *suspensory ligament*. It is a delicate structureless membrane, except where it forms the suspensory ligament, where it contains longitudinal elastic fibres. Immediately beneath the hyaloid membrane are found small, granular, nucleated cells, which are said to be possessed of amœboid movements.

*In the fœtus*, the centre of the vitreous humour presents a tubular canal, through which a minute artery passes along the vitreous body to the capsule of the lens. *In the adult*, no vessels penetrate its substance; so that its nutrition must be carried on by the vessels of the retina and ciliary processes, situated upon its exterior.

### III. CRYSTALLINE LENS

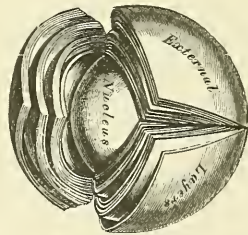
The crystalline lens, enclosed in its capsule, is situated immediately behind the pupil, in front of the vitreous body, and surrounded by the ciliary processes, which slightly overlap its margin.

The *capsule of the lens* is a transparent, highly elastic, and brittle membrane, which closely surrounds the lens. It rests, behind, in a depression in the fore part of the vitreous body; in front, it is in contact with the free border of the iris, this latter receding from it at the circumference, thus forming the posterior chamber of the eye; and it is retained in its position chiefly by the suspensory ligament of the lens. The capsule is much thicker in front than behind, structureless in texture; and when ruptured, the edges roll up with the outer surface innermost, like the elastic lamina of the cornea. The anterior surface of the lens is connected to the inner surface of the capsule by a single layer of transparent, polygonal, nucleated cells. At the circumference of the lens, these cells undergo a change in form: they become elongated, and Babucin states that he can trace the gradual transition of the cells into proper lens-fibres, with which they are directly continuous. There is no epithelium on the posterior surface.

In the fœtus, a small branch from the arteria centralis retinae runs forwards, as already mentioned, through the vitreous humour to the posterior part of the capsule of the lens, where its branches radiate and form a plexiform network, which covers its surface, and they are continuous round the margin of the capsule with the vessels of the pupillary membrane, and with those of the iris. In the adult no vessels enter its substance.

The *lens* is a transparent, double-convex body, the convexity being greater on the posterior than on the anterior surface. It measures about a third of an inch in the transverse diameter, and about one-fourth in the antero-posterior. It consists of concentric layers, of which the external in the fresh state are soft and

FIG. 540.—The crystalline lens, hardened and divided. (Enlarged.)



easily detached; those beneath are firmer, the central ones forming a hardened nucleus. These laminae are best demonstrated by boiling, or immersion in alcohol. The same reagents demonstrate that the lens consists of three triangular segments, the sharp edges of which are directed towards the centre, the bases towards the circumference. The laminae consist of minute parallel fibres, which are hexagonal prisms, the edges being dentated, and the dentations fitting accurately into each other; their breadth is about  $\frac{1}{3000}$ th of an inch. They run from the sutures or lines of junction of the triangular segments, on the one surface, to the periphery of the lens, and, curving round its margin, they terminate at the line of junction of the segments on the other. No fibres pass from pole to pole, but they are arranged in such a way that fibres which commence near the pole on the one aspect of the lens—that is to say, near the apex of the triangular segment—terminate near the peripheral extremity of the plane on the other, or near the base of the triangular segment, and *vice versa*. The fibres of the outer layers of the lens each contain a nucleus, which together form a layer (nuclear layer) on the surface of the lens, most distinct towards its circumference. The meridians, or lines of junction of the three segments, are composed of an amorphous granular substance which sometimes becomes opaque, when the lines are seen forming a distinct star on the lens. The lines on one surface do not lie immediately opposite those on the other, but are intermediate.

The changes produced in the lens by age are the following:

*In the fœtus*, its form is nearly spherical, its colour of a slightly reddish tint, it is not perfectly transparent, and is so soft as to break down readily on the slightest pressure.

*In the adult*, the posterior surface is more convex than the anterior; it is colourless, transparent, and firm in texture.

*In old age* it becomes flattened on both surfaces, slightly opaque, of an amber tint, and increases in density.

The *suspensory ligament of the lens* is a thin, transparent, membranous structure, placed between the vitreous body and the ciliary processes of the choroid; it connects the anterior margin of the vitreous humour with the anterior surface of the lens near its circumference. It assists in retaining the lens in its position. Its outer surface presents a number of folds or plaitings in which the corresponding folds of the ciliary processes are received. These plaitings are arranged round the lens in a radiating form, and are stained by the pigment of the ciliary processes. The suspensory ligament is a part of the hyaloid membrane, which, as described above, is continued forwards to the anterior part of the margin of the lens. It is covered on its outer surface by the pars ciliaris, or connective-tissue framework of the retina, prolonged forwards from the ora serrata. That portion of this membrane which intervenes between the ciliary processes and the capsule of the lens forms part of the boundary of the posterior chamber of the eye. The posterior surface of this layer is turned towards the vitreous humour, being separated from it at the circumference of the lens by a space called the canal of Petit.

The *canal of Petit* is about one-tenth of an inch wide. It is bounded, in front, by the suspensory ligament; behind, by the vitreous humour, its base being formed by the capsule of the lens. When inflated with air, it is sacculated at intervals, owing to the foldings on its anterior surface.

The *arteries of the globe of the eye* are the short, long, and anterior ciliary arteries, and the arteria centralis retinae. They have been already described (see page 580).

The *ciliary veins* are seen on the outer surface of the choroid, and are named, from their arrangement, the *vena vorticosæ*. They converge to four or five equidistant trunks which pierce the sclerotic midway between the margin of the cornea and the entrance of the optic nerve. Another set of veins accompany the anterior ciliary arteries and open into the ophthalmic vein.



The *ciliary nerves* are derived from the nasal branch of the ophthalmic and from the ciliary or ophthalmic ganglion.

*Surgical Anatomy.*—From a surgical point of view the cornea may be regarded as consisting of three layers: (1) of an external epithelial layer, developed from the epiblast, and continuous with the external epithelial covering of the rest of the body, and therefore in its lesions resembling those of the epidermis and superficial layers of the derma; (2) of the cornea proper, derived from the mesoblast, and associated in its diseases with the fibro-vascular structures of the body; and (3) the posterior elastic layer with its endothelium, also derived from the mesoblast and having the characters of a serous membrane, so that inflammation of it resembles inflammation of the other serous and synovial membranes of the body.

The cornea contains no blood-vessels except at its periphery, where numerous delicate loops, derived from the anterior ciliary arteries, may be demonstrated on the anterior surface of the cornea. The rest of the cornea is nourished by lymph, which gains access to the proper substance of the cornea and the posterior layer through the spaces of Fontana. This lack of a direct blood-supply renders the cornea very apt to inflame in the cachectic and ill-nourished. In cases of granular lids, there is a peculiar affection of the cornea, called *pannus*, in which the anterior layers of the cornea becomes vascularised, and a rich network of blood-vessels may be seen upon it; and in interstitial keratitis new vessels extend into the cornea, giving it a pinkish hue, to which the term 'salmon patch' is applied. The cornea is richly supplied with nerves, derived from the ciliary, which enter the cornea through the fore part of the sclerotic and form plexuses in the stroma, terminating between the epithelial cells by free ends or in corpuscles. In cases of glaucoma the ciliary nerves may be pressed upon as they course between the choroid and sclerotic, and the cornea becomes anæsthetic. The sclerotic has very few blood-vessels and nerves. The blood-vessels are derived from the anterior ciliary, and form an open plexus in its substance. As they approach the corneal margin this arrangement is peculiar. Some branches pass through the sclerotic to the ciliary body; others become superficial and lie in the episcleral tissue, and form arches, by anastomosing with each other, some little distance behind the corneal margin. From these arches numerous straight vessels are given off, which run forwards to the cornea, forming its marginal plexus. In inflammation of the sclerotic and episcleral tissue these vessels become conspicuous, and form a pinkish zone of straight vessels radiating from the corneal margin, commonly known as the zone of ciliary injection. In inflammation of the iris and ciliary body this zone is present, since the sclerotic speedily becomes involved when these structures are inflamed. But in inflammation of the cornea the sclerotic is seldom much affected, though the cornea and sclerotic are structurally continuous. This would appear to be due to the fact, that the nutrition of the cornea is derived from a different source from that of the sclerotic. The sclerotic may be ruptured subcutaneously without any laceration of the conjunctiva, and the rupture usually occurs near the corneal margin, where the tunic is thinnest. It may be complicated with lesions of adjacent parts—laceration of the choroid, retina, iris, or suspensory ligament of the lens—and is then often attended with hæmorrhage into the anterior chamber, which masks the nature of the injury. In some cases the lens has escaped through the rent in the sclerotic and has been found under the conjunctiva. Wounds of the sclerotic are always dangerous, and are often followed by inflammation, suppuration, and by sympathetic ophthalmia.

One of the functions of the choroid is to provide nutrition for the retina, and to convey vessels and nerves to the ciliary body and iris. Inflammation of the choroid is therefore followed by grave disturbance in the nutrition of the retina, and is attended with early interference with vision. In its diseases it bears a considerable analogy to those which affect the skin, and, like it, is one of the places from which melanotic sarcomata may grow. These tumours contain a large amount of pigment in their cells, and grow only from those parts where pigment is naturally present. The choroid may be ruptured, without injury to the other tunics, as well as participating in general injuries of the eyeball. In cases of uncomplicated rupture, the injury is usually at its posterior part, and is the result of a blow on the front of the eye. It is attended by considerable hæmorrhage, which for a time may obscure vision, but, in most cases, this is restored, as soon as the blood is absorbed.

The iris is the seat of a malformation, termed *coloboma*, which consists in a deficiency or cleft, which in a great number of cases is clearly due to an arrest in development. In these cases it is found at the lower aspect, extending directly downwards from the pupil, and the gap frequently extends through the choroid to the entrance of the optic nerve. In some rarer cases the gap is found in other parts of the iris, and is then not associated with any deficiency of the choroid. The iris is abundantly supplied with blood-vessels and nerves, and is therefore very prone to become inflamed. And when inflamed, in consequence of the intimate relationship which exists between the vessels of the iris and choroid, this latter tunic is very apt to participate in the inflammation. And, in addition, inflammation of adjacent structures, the cornea and sclerotic, is apt to spread into the iris. The iris is covered with epithelium, and partakes of the character of a serous membrane, and, like these structures, is liable to pour out a plastic exudation, when inflamed, and contract adhesions, either to the cornea in front (*synechia anterior*), or to the capsule of the lens

behind (*synechia posterior*). In iritis the lens may become involved, and the condition known as secondary cataract may be set up. Tumours occasionally commence in the iris; of these, cysts, which are usually congenital, and sarcomatous tumours, are the most common and require removal. Gummata are not unfrequently found in this situation. In some forms of injury of the eyeball, as the impact of a spent shot, the rebound of a twig, or a blow with a whip, the iris may be detached from the Ciliary muscle, the amount of detachment varying from the slightest degree to separation of the whole iris from its ciliary connection.

The retina, with the exception of its pigment-layer and its vessels, is perfectly transparent, so as to be invisible when examined by the ophthalmoscope, so that its diseased conditions are recognised by its loss of transparency. In retinitis, for instance, there is more or less dense and extensive opacity of its structure, and not unfrequently extravasations of blood into its substance. Hæmorrhages may also take place into the retina, from rupture of a blood-vessel without inflammation.

The retina may become displaced from effusion of serum between it and the choroid, or by blows on the eyeball, or may occur without apparent cause in progressive myopia, and in this case the ophthalmoscope shows an opaque, tremulous cloud. Glioma, a form of sarcoma, and essentially a disease of early life, is occasionally met with in connection with the retina.

The lens has no blood-vessels, nerves, or connective tissue in its structure, and therefore is not subject to those morbid changes to which tissues containing these structures are liable. It does however present certain morbid or abnormal conditions of various kinds. Thus, variations in shape, absence of the whole or a part of the lens, and displacements are amongst its congenital defects. Opacities may occur from injury, senile changes, malnutrition, or errors in growth or development. Senile changes may take place in the lens, impairing its elasticity and rendering it harder than in youth, so that its curvature can only be altered to a limited extent by the Ciliary muscle. And, finally, the lens may be dislocated or displaced by blows upon the eyeball: and its relations to surrounding structures altered by adhesions or the pressure of new growths.

There are two particular regions of the eye which require special notice: one of these is known as the 'filtration area,' and the other as the 'dangerous area.' The *filtration area* is the circumcorneal zone immediately in front of the iris. Here are situated the cavernous spaces of Fontana, which communicate with the canal of Schlemm, through which the chief transudation of fluid from the eye is now believed to take place. The *dangerous area of the eye* is the region in the neighbourhood of the ciliary body, and wounds or injuries in this situation are peculiarly dangerous. For inflammation of the ciliary body is liable to spread to many of the other structures of the eye, especially to the iris and choroid, which are intimately connected by nervous and vascular supplies. Moreover, wounds which involve the ciliary region are especially liable to be followed by sympathetic ophthalmia, in which destructive inflammation of one eye is excited by some irritation in the other.

#### APPENDAGES OF THE EYE

The appendages of the eye (*tutamina oculi*) include the eyebrows, the eyelids, the conjunctiva, and the lachrymal apparatus, viz. the lachrymal gland, the lachrymal sac, and the nasal duct.

The **eyebrows** (*supercilia*) are two arched eminences of integument, which surmount the upper circumference of the orbit on each side, and support numerous short, thick hairs, directed obliquely on the surface. In structure, the eyebrows consist of thickened integument, connected beneath with the Orbicularis palpebrarum, Corrugator supercilii, and Occipito-frontalis muscles. These muscles serve, by their action on this part, to control to a certain extent the amount of light admitted into the eye.

The **eyelids** (*palpebræ*) are two thin, movable folds, placed in front of the eye, protecting it from injury by their closure. The upper lid is the larger, and the more movable of the two, and is furnished with a separate elevator muscle, the *Levator palpebræ superioris*. When the eyelids are open, an elliptical space (*fissure palpebrarum*) is left between their margins, the angles of which correspond to the junction of the upper and lower lids, and are called *canthi*.

The *outer canthus* is more acute than the inner, and the lids here lie in close contact with the globe: but the *inner canthus* is prolonged for a short distance inwards towards the nose, and the two lids are separated by a triangular space, the *lacus lachrymalis*. At the commencement of the lacus lachrymalis, on the margin of each eyelid, is a small conical elevation, the *lachrymal papilla*, or tubercle, the apex of which is pierced by a small orifice, the *punctum lachrymale*, the commencement of the lachrymal canal.



The *eyelashes (cilia)* are attached to the free edges of the eyelids; they are short, thick, curved hairs, arranged in a double or triple row at the margin of the lids: those of the upper lid, more numerous and longer than the lower, curve upwards; those of the lower lid curve downwards, so that they do not interlace in closing the lids. Near the attachment of the eyelashes are the openings of a number of glands, *glands of Mohl*, arranged in several rows close to the free margin of the lid. They resemble in structure a portion of a sweat-gland, and are regarded as the modified sweat-glands of this region.

**Structure of the eyelids.**—The eyelids are composed of the following structures taken in their order from without inwards:

Integument, areolar tissue, fibres of the Orbicularis muscle, tarsal plate (cartilage), and its ligament, Meibomian glands and conjunctiva. The upper lid has, in addition, the aponeurosis of the Levator palpebræ.

The *integument* is extremely thin, and continuous at the margin of the lids with the conjunctiva.

The *subcutaneous areolar tissue* is very lax and delicate, seldom contains any fat, and is extremely liable to serous infiltration.

The *fibres of the Orbicularis muscle*, where they cover the palpebræ, are thin, pale in colour, and possess an involuntary action.

The *tarsal plates (cartilages)\** are two thin elongated plates of dense connective tissue, about an inch in length. They are placed one in each lid, contributing to their form and support.

The *superior*, the larger, is of a semilunar form, about one-third of an inch in breadth at the centre, and becoming gradually narrowed at each extremity. To the anterior surface of this plate the aponeurosis of the Levator palpebræ is attached.

The *inferior tarsal plate*, the smaller, is thinner, and of an elliptical form.

The *free or ciliary margin* of these plates is thick, and presents a perfectly straight edge. The *attached orbital margin* is connected to the circumference of the orbit by the fibrous membrane of the lids with which it is continuous. The outer angle of each plate is attached to the malar bone by the external palpebral or tarsal ligament. The inner angles of the two plates terminate at the commencement of the lacus lachrymalis, being fixed to the margins of the orbit by the tendo oculi.

The *tarsal ligament, or fibrous membrane of the lids*, is a layer of fibrous membrane, beneath the Orbicularis, attached marginally to the edge of the orbit, where it becomes continuous with the periosteum, and centrally to the tarsal plate, near its ciliary margin, with the tissue of which it is continuous. It is thickest and densest at the outer part of the orbit. Upon its under surface is a layer of unstriped muscle, which in the upper lid passes from the aponeurosis of the Levator palpebræ muscle to the tarsal plate. This ligament serves to support the eyelids, and retains the tarsal plates in their position.

The *Meibomian glands* (fig. 541) are situated upon the inner surface of the eyelids, between the tarsal plates and conjunctiva, and may be distinctly seen through the mucous membrane on everting the eyelids, presenting the appearance of parallel strings of pearls. They are about thirty in number in the upper eyelid, and somewhat fewer in the lower. They are embedded in grooves in the inner surface of the tarsal plates, and correspond in length with the breadth of each plate; they are, consequently, longer in the upper than in the lower eyelid. Their ducts open on the free margin of the lids by minute foramina, which correspond in number to the follicles. The peculiar parallel arrangement of these glands, side by side, forms a smooth layer adapted to the surface of the globe, over which they constantly glide. The use of their secretion is to prevent adhesions of the lids.

*Structure of the Meibomian glands.*—These glands are a variety of the

\* Recent observations have proved that the so-called 'tarsal cartilages' do not contain any cartilage-cells, and that the name is a misnomer.

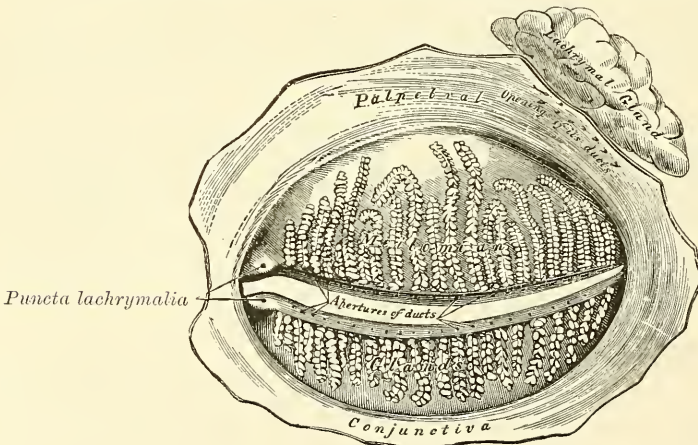


cutaneous sebaceous glands, each consisting of a single straight tube or follicle, having a cæcal termination, and with numerous small secondary follicles opening into it. The tubes consist of basement-membrane, covered by a layer of scaly epithelium; the secondary follicles are lined by a layer of polyhedral cells, continuous with the cells of the tube. The remainder of the follicle is filled with large polyhedral cells, charged with fat. They are thus identical in structure with the sebaceous glands.

The **conjunctiva** is the mucous membrane of the eye. It lines the inner surface of the eyelids, and is reflected over the fore part of the sclerotic and cornea. In each of these situations, its structure presents some peculiarities.

The *palpebral portion of the conjunctiva* is thick, opaque, highly vascular, and covered with numerous papillæ, its deeper parts presenting a considerable amount of lymphoid tissue. At the margin of the lids it becomes continuous with the lining membrane of the ducts of the Meibomian glands, and, through the lachrymal canals, with the lining membrane of the lachrymal sac and nasal duct. At the outer angle of the upper lid it may be traced along the lachrymal ducts into the lachrymal gland; and at the inner angle of the eye it forms a semilunar fold, the *plica semilunaris*. The folds formed by the reflection of the conjunctiva from the lids on to the eye are called the *superior* and *inferior palpebral folds*, the

FIG. 541.—The Meibomian glands, etc., seen from the inner surface of the eyelids.



former being the deeper of the two. Upon the *sclerotic*, the conjunctiva is loosely connected to the globe: it becomes thinner, loses its papillary structure, is transparent, and only slightly vascular in health. Upon the *cornea*, the conjunctiva consists only of epithelium, constituting the anterior layer of the cornea (conjunctival epithelium) already described (see page 881). *Lymphatics* arise in the conjunctiva in a delicate zone around the cornea, from which the vessels run to the ocular conjunctiva.

At the point of reflection of the conjunctiva from the lid on to the globe of the eye, termed the *fornix conjunctivæ*, are a number of mucous glands, which are much convoluted. They are chiefly found in the upper lid. Other glands, analogous to lymphoid follicles, and called by Henle *trachoma glands*, are found in the conjunctiva, and, according to Strohmeyer, are chiefly situated near the inner canthus of the eye. They were first described by Brush, in his description of Peyer's patches of the small intestines, as 'identical structures existing in the under eyelid of the ox.'

The nerves in the conjunctiva are numerous and form rich plexuses. According to Krause, they terminate in a peculiar form of tactile corpuscle, which he terms 'terminal bulb.'

The *caruncula lachrymalis* is a small, reddish, conical-shaped body, situated at the inner canthus of the eye, and filling up the small triangular space in this situation, the *lacus lachrymalis*. It consists of a cluster of follicles similar in structure to the Meibomian, covered with mucous membrane, and is the source of the whitish secretion which constantly collects at the inner angle of the eye. A few slender hairs are attached to its surface. On the outer side of the caruncula is a slight semilunar fold of mucous membrane, the concavity of which is directed towards the cornea; it is called the *plica semilunaris*. Müller found smooth muscular fibres in this fold, and in some of the domesticated animals a thin plate of cartilage has been discovered. This structure is considered to be the rudiment of the third eyelid in birds, the *membrana nictitans*.

## LACHRYMAL APPARATUS (fig. 542)

The lachrymal apparatus consists of the lachrymal gland, which secretes the tears, and its excretory ducts, which convey the fluid to the surface of the eye. This fluid is carried away by the lachrymal canals into the lachrymal sac, and along the nasal duct into the cavity of the nose.

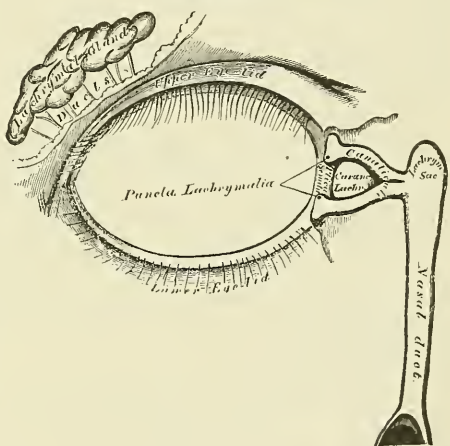
The **lachrymal gland** is lodged in a depression at the outer angle of the orbit, on the inner side of the external angular process of the frontal bone. It is of an oval form, about the size and shape of an almond. Its upper convex surface is in contact with the periosteum of the orbit, to which it is connected by a few fibrous bands. Its under concave surface rests upon the convexity of the eyeball, and upon the Superior and External recti muscles. Its vessels and nerves enter its posterior border, whilst its anterior margin is closely adherent to the back part of the upper eyelid, where it is covered to a slight extent by the reflection of the conjunctiva. The fore part of the gland is separated from the rest by a fibrous septum; hence it is sometimes described as a separate lobe, called the *palpebral portion of the gland* (*accessory gland of Rosenmüller*). Its ducts, about seven in number, run obliquely beneath the mucous membrane for a short distance, and, separating from each other, open by a series of minute orifices on the upper and outer half of the conjunctiva, near its reflection on to the globe. These orifices are arranged in a row, so as to disperse the secretion over the surface of the membrane.

The fore part of the gland is separated from the rest by a fibrous septum; hence it is sometimes described as a separate lobe, called the *palpebral portion of the gland* (*accessory gland of Rosenmüller*). Its ducts, about seven in number, run obliquely beneath the mucous membrane for a short distance, and, separating from each other, open by a series of minute orifices on the upper and outer half of the conjunctiva, near its reflection on to the globe. These orifices are arranged in a row, so as to disperse the secretion over the surface of the membrane.

*Structure of the lachrymal gland.*—In structure and general appearance the lachrymal resembles the serous salivary glands (page 939). In the recent state the cells are so crowded with granules that their limits can hardly be defined. They contain an oval nucleus, and the cell protoplasm is finely fibrillated.

The **lachrymal canals** commence at the minute orifices, *puncta lachrymalia*, on the summit of a small conical elevation, the *lachrymal papilla*, seen on the margin of the lids, at the outer extremity of the lacus lachrymalis. The *superior canal*, the smaller and shorter of the two, at first ascends, and then bends at an acute angle, and passes inwards and downwards to the lachrymal sac. The *inferior canal* at first descends, and then, abruptly changing its course, passes almost horizontally inwards to the lachrymal sac. They are dense and elastic

FIG. 542.—The lachrymal apparatus. Right side.





in structure and somewhat dilated at their angle. The mucous membrane is covered with scaly epithelium.

The **lachrymal sac** is the upper dilated extremity of the nasal duct, and is lodged in a deep groove formed by the lachrymal bone and nasal process of the superior maxillary. It is oval in form, its upper extremity being closed in and rounded, whilst below it is continued into the nasal duct. It is covered by a fibrous expansion derived from the *tendo oculi*, and on the inner side it is crossed by the Tensor tarsi muscle (Horner's muscle, page 392) which is attached to the ridge on the lachrymal bone.

**Structure.**—It consists of a fibrous elastic coat, lined internally by mucous membrane: the latter being continuous, through the lachrymal canals, with the mucous lining of the conjunctiva, and through the nasal duct with the pituitary membrane of the nose.

The **nasal duct** is a membranous canal, about three-quarters of an inch in length, which extends from the lower part of the lachrymal sac to the inferior meatus of the nose, where it terminates by a somewhat expanded orifice, provided with an imperfect valve, the *valve of Hasner*, formed by the mucous membrane. It is contained in an osseous canal, formed by the superior maxillary, the lachrymal, and the inferior turbinated bones, is narrower in the middle than at each extremity, and takes a direction downwards, backwards, and a little outwards. It is lined by mucous membrane, which is continuous below with the pituitary lining of the nose. This membrane in the lachrymal sac and nasal duct is covered with columnar epithelium as in the nose. This epithelium is in places ciliated.

**Surface Form.**—The palpebral fissure, or opening between the eyelids, is elliptical in shape, and differs in size in different individuals and in different races of mankind. In the Mongolian races, for instance, the opening is very small, merely a narrow fissure, and this makes the eyeball appear small in these races, whereas the size of the eye is relatively very constant. The normal direction of the fissure is slightly oblique, in a direction upwards and outwards, so that the outer angle is on a slightly higher level than the inner. This is especially noticeable in the Mongolian races, in whom, owing to the upward projection of the malar bone and the shortness of the external angular process of the frontal bone, the tarsal plate of the upper lid is raised at its outer part, and gives an oblique direction to the palpebral fissure.

When the eyes are directed forwards, as in ordinary vision, the upper part of the cornea is covered by the upper lid, and the lower margin of the cornea corresponds to the level of the lower lid, so that about the lower three-fourths of the cornea is exposed under ordinary circumstances. On the margins of the lids, about a quarter of an inch from the inner canthus, are two small openings, the *puncta lachrymalia*, the commencement of the lachrymal canals. They are best seen by everting the eyelids. In the natural condition they are in contact with the conjunctiva of the eyeball, and are maintained in this position by the Tensor tarsi muscle, so that the tears running over the surface of the globe easily find their way into the lachrymal canals. The position of the lachrymal sac into which the canals open is indicated by a little tubercle (page 206), which is plainly to be felt on the lower margin of the orbit. The lachrymal sac lies immediately above and to the inner side of this tubercle, and a knife passed through the skin in this situation would open the cavity. The position of the lachrymal sac may also be indicated by the *tendo oculi*, or internal tarsal ligament. If both lids be drawn outwards so as to tense the skin at the inner angle, a prominent cord will be seen beneath the tightened skin. This is the *tendo oculi*, which lies immediately over the lachrymal sac, bisecting it, and thus forming a useful guide to its situation. A knife entered immediately beneath the tense cord would open the lower part of the sac. A probe introduced through this opening can be readily passed downwards through the duct into the inferior meatus of the nose. The direction of the duct is downwards, outwards, and backwards, and this course should be borne in mind in passing the probe, otherwise the point may be driven through the thin bony walls of the canal. A convenient plan is to direct the probe in such a manner, that if it were pushed onwards it would strike the first molar tooth of the lower jaw on the same side of the body. In other words, the surgeon standing in front of his patient should carry in his mind the position of the first molar tooth, and should push his probe onwards in such a way as if he desired to reach this structure.

Beneath the internal angular process of the frontal bone, the pulley of the Superior oblique muscle of the eye can be plainly felt by pushing the finger backwards between the upper and inner angle of the eye and the roof of the orbit; passing backwards and outwards from this pulley the tendon can be felt for a short distance.



*Surgical Anatomy.*—The eyelids are composed of various tissues, and consequently are liable to a variety of diseases. The skin which covers them is exceedingly thin and delicate, and is supported on a quantity of loose and lax subcutaneous tissue, which contains no fat. In consequence of this it is very freely movable, and is liable to be drawn down by the contraction of neighbouring cicatrices, and thus produce an eversion of the lid, known as *ectropion*. Inversion of the lids (*entropion*) from spasm of the *Orbicularis palpebrarum* or from chronic inflammation of the palpebral conjunctiva may also occur. The eyelids are richly supplied with blood, and are often the seat of vascular growths, such as *nævi*. Rodent ulcer also frequently commences in this situation. The loose cellular tissue beneath the skin is liable to become extensively infiltrated either with blood or inflammatory products, producing very great swelling. Even from very slight injuries to this tissue, the extravasation of blood may be so great as to produce considerable swelling of the lids and complete closure of the eye, and the same is the case when inflammatory products are poured out. The follicles of the eyelashes or the sebaceous glands associated with these follicles may be the seat of inflammation, constituting the ordinary 'sty.' The Meibomian glands are affected in the so-called 'tarsal tumour': the tumour, according to some, being caused by the retained secretion of these glands; by others it is believed to be a neoplasm connected with the gland. The ciliary follicles are liable to become inflamed, constituting the disease known as *blepharitis ciliaris* or 'blear eye.' Irregular or disorderly growth of the eyelashes not unfrequently occurs; some of them being turned towards the eyeball and producing inflammation and ulceration of the cornea, and possibly eventually complete destruction of the eye. The *Orbicularis palpebrarum* may be the seat of spasm, either in the form of slight quivering of the lids; or repeated twitchings, most commonly due to errors of refraction in children; or more continuous spasm, due to some irritation of the fifth or seventh cranial nerve. The *Orbicularis* may be paralysed, generally associated with paralysis of the other facial muscles. Under these circumstances, the patient is unable to close the lids, and, if he attempts to do so, rolls the eyeball upwards under the upper lid. The tears overflow from displacement of the lower lid, and the conjunctiva and cornea, being constantly exposed and the patient being unable to wink, become irritated from dust and foreign bodies. In paralysis of the *Levator palpebræ superioris* there is drooping of the upper eyelid and other symptoms of implication of the third nerve. The eyelids may be the seat of bruises, wounds, or burns. In these latter injuries, adhesions of the margins of the lids to each other, or adhesion of the lids to the globe may take place. The eyelids are sometimes the seat of emphysema, after fracture of some of the thin bones forming the inner wall of the orbit. If shortly after such an injury the patient blows his nose, air is forced from the nostril through the lacerated structures into the connective tissue of the eyelids, which suddenly swell up and present the peculiar crackling characteristic of this affection.

Foreign bodies frequently get into the conjunctival sac and cause great pain, especially if they come in contact with the corneal surface, during the movements of the lid and the eye on each other. The conjunctiva is frequently involved in severe injuries of the eyeball, but is seldom ruptured alone; the most common form of injury to the conjunctiva alone is from a burn, either from fire, strong acids, or lime. In these cases union is liable to take place between the eyelid and the eyeball. The conjunctiva is often the seat of inflammation arising from many different causes, and the arrangement of the conjunctival vessels should be remembered as affording a means of diagnosis between this condition and injection of the sclerotic, which is present in inflammation of the deeper structures of the globe. The inflamed conjunctiva is bright red; the vessels are large and tortuous, and greatest at the circumference, shading off towards the corneal margin; they anastomose freely and form a dense network, and they can be emptied or displaced by gentle pressure.

The lachrymal gland is occasionally, though rarely, the seat of inflammation, either acute or chronic; it is also sometimes the seat of tumours, benign or malignant, and for these may require removal. This may be done by an incision through the skin, just below the eyebrow; and the gland, being invested with a special capsule of its own, may be isolated and removed, without opening the general cavity of the orbit. The canaliculi may be obstructed, either as a congenital defect, or by some foreign body, as an eyelash or a dacryolith, causing the tears to run over the cheek. The canaliculi may also become occluded as a result of burns or injury; overflow of the tears may in addition result from deviation of the puncta, or from chronic inflammation of the lachrymal sac. This latter condition is set up by some obstruction to the nasal duct, frequently occurring in tuberculous subjects. In consequence of this the tears and mucus accumulate in the lachrymal sac, distending it. Suppuration in the lachrymal sac is sometimes met with; this may be the sequel of a chronic inflammation; or may occur after some of the eruptive fevers, in cases where the lachrymal passages were previously quite healthy. It may lead to lachrymal fistula.

## THE EAR

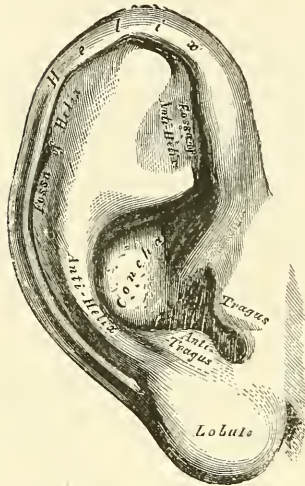
The organ of hearing is divisible into three parts: the external ear, the middle ear or tympanum, and the internal ear or labyrinth.

## THE EXTERNAL EAR

The **external ear** consists of an expanded portion named *pinna* or *auricle*, and the auditory canal, or *meatus*. The former serves to collect the vibrations of the air by which sound is produced; the latter conducts those vibrations to the tympanum.

The **pinna** or *auricle* (fig. 543) is of an ovoid form, with its larger end directed upwards. Its outer surface is irregularly concave, directed slightly forwards, and presents numerous eminences and depressions which result from the foldings of its fibro-cartilaginous element. To each of these, names have been assigned. Thus the external prominent rim of the auricle is called the *helix*. Another curved prominence, parallel with and in front of the helix, is called the *antihelix*; this bifurcates above, so as to enclose a triangular depression, the *fossa of the antihelix* (*fossa triangularis*). The narrow curved depression between the helix and antihelix is called the *fossa of the helix* (*fossa innominata* or *scaphoidea*); the antihelix describes a curve round a deep, capacious cavity, the *concha*, which is partially divided into two parts by the commencement of the helix. In front of the concha, and projecting backwards over the meatus, is a small pointed eminence, the *tragus*: so called from its being generally covered on its under surface with a tuft of hair, resembling a goat's beard. Opposite the tragus, and separated from it by a deep notch (*incisura intertragica*), is a small tubercle, the *antitragus*. Below this is the *lobule*, com-

FIG. 543.—The pinna, or auricle.  
Outer surface.



posed of tough areolar and adipose tissue, wanting the firmness and elasticity of the rest of the pinna.

composed of tough areolar and adipose tissue, wanting the firmness and elasticity of the rest of the pinna.

*Structure of the pinna.*—The pinna is composed of a thin plate of yellow fibro-cartilage, covered with integument, and connected to the surrounding parts by the extrinsic ligaments and muscles; and to the commencement of the external auditory canal.

The *integument* is thin, closely adherent to the cartilage, and covered with hairs furnished with sebaceous glands, which are most numerous in the concha and scaphoid fossa. The hairs are most numerous and largest on the tragus and antitragus.

The *cartilage of the pinna* consists of one single piece: it gives form to this part of the ear, and upon its surface are found all the eminences and depressions above described. It does not enter into the construction of all parts of the auricle; thus it does not form a constituent part of the lobule; it is deficient, also, between the tragus and beginning of the helix, the notch between them being filled up by dense fibrous tissue. At the front part of the pinna, where the helix bends upwards, is a small projection of cartilage, called the *process of the helix*. The cartilage of the pinna presents several intervals or fissures in its substance, which partially separate the different parts. The fissure of the helix is a short vertical slit, situated at the fore part of the pinna, immediately behind a small conical projection of cartilage, opposite the first curve of the helix (*process of the helix*). Another fissure, the *fissure of the tragus*, is seen upon the anterior surface of the tragus. The antihelix is divided below, by a deep fissure, into two parts: one part terminates by a pointed, tail-like extremity (*processus caudatus*); the other is continuous with the antitragus. The carti-



lage of the pinna is very pliable, elastic, of a yellowish colour, and belongs to that form of cartilage which is known under the name of yellow fibro-cartilage.

The *ligaments of the pinna* consist of two sets:—1. The extrinsic set, or those connecting it to the side of the head. 2. The intrinsic set, or those connecting various parts of its cartilage together.

The *extrinsic ligaments*, the most important, are two in number, anterior and posterior. The *anterior ligament* extends from the process of the helix to the root of the zygoma. A few fibres connect the tragus to the root of the zygoma. The *posterior ligament* passes from the posterior surface of the concha to the outer surface of the mastoid process of the temporal bone.

The *intrinsic ligaments* are also two in number. Of these, one is a strong fibrous band, stretching across from the tragus to the commencement of the helix, completing the meatus in front, and partly encircling the boundary of the concha; the other extends between the concha and the process caudatus.

The *muscles of the pinna* (fig. 544) consist of two sets:—1. The *extrinsic*, which connect it with the side of the head, moving the pinna as a whole, viz. the Attollens, Attrahens, and Retrahens aurem (page 390); and 2. the *intrinsic*, which extend from one part of the auricle to another, viz.:

Helicis major.  
Helicis minor.  
Tragicus.

Antitragicus.  
Transversus auriculæ.  
Obliquus auris.

The *Musculus helicis major* is a narrow vertical band of muscular fibres, situated upon the anterior margin of the helix. It arises, below, from the process of the helix, and is inserted into the anterior border of the helix, just where it is about to curve backwards. It is pretty constant in its existence.

The *Musculus helicis minor* is an oblique fasciculus, attached to that part of the helix which commences from the bottom of the concha.

The *Tragicus* is a short, flattened band of muscular fibres situated upon the outer surface of the tragus, the direction of its fibres being vertical.

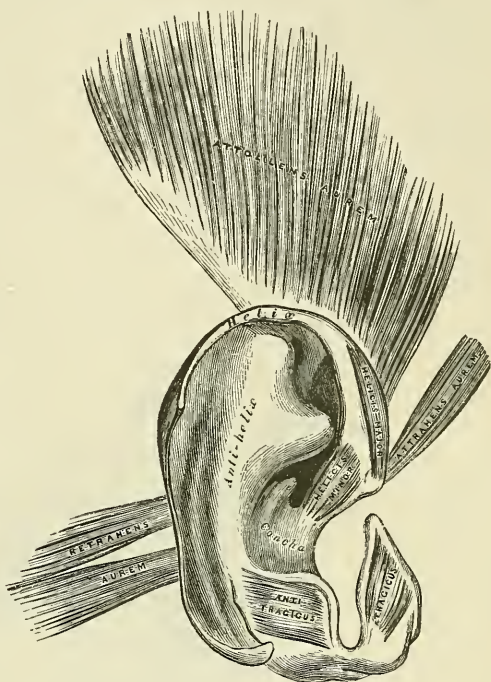
The *Antitragicus* arises from the outer part of the antitragus: its fibres are inserted into the processus caudatus of the helix. This muscle is usually very distinct.

The *Transversus auriculæ* is placed on the cranial surface of the pinna. It consists of radiating fibres, partly tendinous and partly muscular, extending from the convexity of the concha to the prominence corresponding with the groove of the helix.

The *Obliquus auris* (Tod) consists of a few fibres extending from the upper and back part of the concha to the convexity immediately above it.

The *arteries of the pinna* are the posterior auricular from the external carotid,

FIG. 544.—The muscles of the pinna.





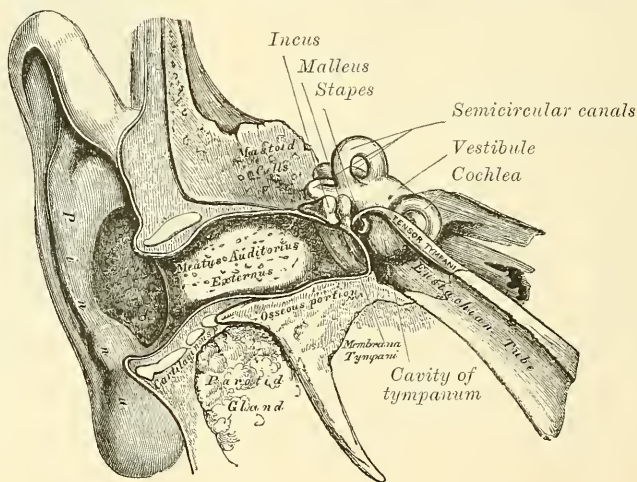
the anterior auricular from the temporal, and an auricular branch from the occipital artery.

The *veins* accompany the corresponding arteries.

The *nerves* are: the auricularis magnus, from the cervical plexus; the posterior auricular, from the facial to the muscles of the pinna; the auricular branch of the pneumogastric; the auriculo-temporal branch of the inferior maxillary nerve; the occipitalis minor from the cervical plexus, and the occipitalis major or internal branch of the posterior division of the second cervical nerve.

The **Auditory Canal** (*meatus auditorius externus*) extends from the bottom of the concha to the membrana tympani (fig. 545). It is about an inch and a quarter in length, its direction is obliquely forwards and inwards, and it is slightly curved upon itself, so as to be higher in the middle than at either extremity. It forms an oval cylindrical canal, the greatest diameter being in the vertical direction at the external orifice, but in the transverse direction at the tympanic end. The calibre of the canal is narrowest about the middle. The membrana tympani, which occupies the termination of the meatus, is

FIG. 545.—A front view of the organ of hearing. Right side.



obliquely directed, in consequence of which the floor of the canal is longer than the roof, and the anterior wall longer than the posterior. The auditory canal is formed partly by cartilage and membrane, and partly by bone, and is covered by skin.

The *cartilaginous portion* is about half an inch in length, being rather less than half the canal; it is formed by the cartilage of the concha and tragus, prolonged inwards, and firmly attached to the circumference of the auditory process of the temporal bone. The cartilage is deficient at its upper and back part, its place being supplied by fibrous membrane. This part of the canal is rendered extremely movable by two or three deep fissures (*incisuræ Santorini*), which extend through the cartilage in a vertical direction.

The *osseous portion* is about three-quarters of an inch in length, and narrower than the cartilaginous portion. It is directed inwards and a little forwards, forming a slight curve in its course, the convexity of which is upwards and backwards. Its inner end, which communicates, in the dry bone, with the cavity of the tympanum, is smaller than the outer and sloped, the anterior wall projecting beyond the posterior about two lines; it is marked, except at its upper part, by a narrow groove for the insertion of the membrana tympani. Its outer end is dilated and rough in the greater part of its circumference, for the attachment of

the cartilage of the pinna. Its vertical transverse section is oval, the greatest diameter being from above downwards. The front and lower parts of this canal are formed by a curved plate of bone, which, in the fœtus, exists as a separate ring (*tympanic plate*), incomplete at its upper part.

The *skin* lining the meatus is very thin, adheres closely to the cartilaginous and osseous portion of the tube, and covers the surface of the *membrana tympani*, forming its outer layer. After maceration, the thin pouch of epidermis, when withdrawn, preserves the form of the meatus. In the thick subcutaneous tissue of the cartilaginous part of the meatus are numerous ceruminous glands, which secrete the ear-wax. They resemble in structure sweat-glands, and their ducts open on the surface of the skin.

The *arteries* supplying the meatus are branches from the posterior auricular, internal maxillary, and temporal.

The *nerves* are chiefly derived from the auriculo-temporal branch of the inferior maxillary nerve and the auricular branch of the pneumogastric.

*Surface Form.*—At the point of junction of the osseous and cartilaginous portions, the tube forms an obtuse angle, which projects into the tube at its antero-inferior wall. This produces a sort of constriction in this situation, and renders it the narrowest portion of the canal—an important point to be borne in mind in connection with the presence of foreign bodies in the ears. The cartilaginous is connected to the bony part by fibrous tissue, which renders the outer part of the tube very movable, and therefore by drawing the pinna upwards and backwards the canal is rendered almost straight. At the external orifice are a few short, crisp hairs, which serve to prevent the entrance of small particles of dust, or flies or other insects. In the external auditory meatus the secretion of the ceruminous glands serves to catch any small particles which may find their way into the canal, and prevent their reaching the *membrana tympani*, where their presence might excite irritation. In young children the meatus is very short, the osseous part being very deficient, and consisting merely of a bony ring (the *tympanic plate*), which supports the *membrana tympani*. In the fœtus, the osseous part is entirely absent. The shortness of the canal in children should be borne in mind in introducing the aural speculum, so that it be not pushed in too far, at the risk of injuring the *membrana tympani*; indeed, even in the adult the speculum should never be introduced beyond the constriction which marks the junction of the osseous and cartilaginous portions. In using this instrument it is advisable that the pinna should be drawn upwards, backwards, and a little outwards, so as to render the canal as straight as possible, and thus assist the operator in obtaining, by the aid of reflected light, a good view of the *membrana tympani*. Just in front of the membrane is a well-marked depression, situated on the floor of the canal, and bounded by a somewhat prominent ridge; in this foreign bodies may become lodged. By aid of the speculum, combined with traction of the auricle upwards and backwards, the whole of the *membrana tympani* is rendered visible. It is a pearly-grey membrane, slightly glistening in the adult, placed obliquely, so as to form with the floor of the meatus a very acute angle, while with the roof it forms an obtuse angle. At birth it is more horizontal, situated in almost the same plane as the base of the skull. About midway between the anterior and posterior margins of the membrane, and extending from the centre obliquely upwards, is a reddish-yellow streak; this is the handle of the malleus, which is inserted into the membrane. At the upper part of this streak, close to the roof of the meatus, a little white, rounded prominence is plainly to be seen; this is the *processus brevis* of the malleus, projecting against the membrane. The *membrana tympani* does not present a plane surface; on the contrary, its centre is drawn inwards, on account of its connection with the handle of the malleus, and thus the external surface is rendered concave.

#### MIDDLE EAR, OR TYMPANUM

The **middle ear**, or **tympanum**, is an irregular cavity, compressed from without inwards, and situated within the petrous bone. It is placed above the jugular fossa; the carotid canal lying in front, the mastoid cells behind, the meatus auditorius externally, and the labyrinth internally. It is filled with air, and communicates with the pharynx by the Eustachian tube. The tympanum is traversed by a chain of movable bones, which connect the *membrana tympani* with the labyrinth, and serve to convey the vibrations communicated to the *membrana tympani* across the cavity of the tympanum to the internal ear.

The *cavity of the tympanum* measures about five lines from before backwards, three lines in the vertical direction, and between two and three in the transverse,



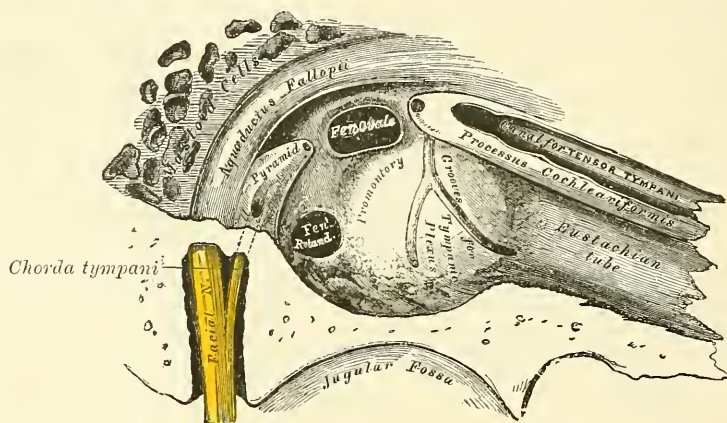
being a little broader behind and above than it is below and in front. It is bounded externally by the membrana tympani and meatus; internally, by the outer surface of the internal ear; and communicates, behind, with the mastoid cells; and in front with the Eustachian tube and canal for the Tensor tympani. Its roof and floor are formed by thin osseous laminae, the one forming the roof being a thin plate situated on the anterior surface of the petrous portion of the temporal bone, close to its angle of junction with the squamous portion of the same bone.

The **roof** is broad, flattened, and formed of a thin plate of bone (*tegmen tympani*), which separates the cranial and tympanic cavities.

The **floor** is narrow, and corresponds to the jugular fossa, which lies beneath. It presents, near the inner wall, a small aperture for the passage of Jacobson's nerve.

The **outer wall** is formed mainly by the membrana tympani, partly by the ring of bone into which this membrane is inserted. This ring of bone is incomplete at its upper and front part, forming a notch (*incisura Rivini*), and here the

FIG. 546.—View of inner wall of tympanum. (Enlarged.)



membrane is extended outwards, and is united to the wall of the tympanum. Close to it are three small apertures: the iter chordæ posterioris, the Glaserian fissure, and the iter chordæ anterioris.

The *aperture of the iter chordæ posterioris* is in the angle of junction between the posterior and external walls of the tympanum, immediately behind the membrana tympani and on a level with its centre; it leads into a minute canal, which descends in front of the aqueductus Fallopii, and terminates in that canal near the stylo-mastoid foramen. Through it the chorda tympani nerve enters the tympanum.

The *Glaserian fissure* opens just above and in front of the ring of bone into which the membrana tympani is inserted; in this situation it is a mere slit about a line in length. It lodges the long process of the malleus, and gives passage to some tympanic vessels.

The *aperture of the iter chordæ anterioris* is seen just above the preceding fissure; it leads into a canal (*canal of Huguier*), which runs parallel with the Glaserian fissure. Through it the chorda tympani nerve leaves the tympanum.

The **internal wall of the tympanum** (fig. 546) is vertical in direction, and looks directly outwards. It presents for examination the following parts:

Fenestra ovalis.	Ridge of the aqueductus Fallopii.
Fenestra rotunda.	Pyramid.
Promontory.	Opening for the Stapedius.



The *fenestra ovalis* is a reniform opening, leading from the tympanum into the vestibule; its long diameter is directed horizontally, and its convex border is upwards. The opening in the recent state is occupied by the base of the stapes, which is connected to the margin of the foramen by an annular ligament.

The *fenestra rotunda* is an aperture placed at the bottom of a funnel-shaped depression leading into the cochlea. It is situated below and rather behind the *fenestra ovalis*, from which it is separated by a rounded elevation, the *promontory*; it is closed in the recent state by a membrane (*membrana tympani secundaria*, Scarpa). This membrane is concave towards the tympanum, convex towards the cochlea. It consists of three layers: the external, or mucous, derived from the mucous lining of the tympanum; the internal from the lining membrane of the cochlea; and an intermediate, or fibrous layer.

The *promontory* is a rounded hollow prominence, formed by the projection outwards of the first turn of the cochlea; it is placed between the fenestræ, and is furrowed on its surface by three small grooves, which lodge branches of the tympanic plexus.

The *rounded eminence of the aqueductus Fallopii*, the prominence of the bony canal in which the portio dura is contained, traverses the inner wall of the tympanum above the *fenestra ovalis*, and behind that opening curves nearly vertically downwards along the posterior wall.

The *pyramid* is a conical eminence, situated immediately behind the *fenestra ovalis*, and in front of the vertical portion of the eminence above described; it is hollow in the interior, and contains the Stapedius muscle; its summit projects forwards towards the *fenestra ovalis*, and presents a small aperture, which transmits the tendon of the muscle. The cavity in the pyramid is prolonged into a minute canal, which communicates with the aqueductus Fallopii, and transmits the nerve which supplies the Stapedius.

The **posterior wall of the tympanum** is wider above than below, and presents for examination the

#### Opening of the antrum.

This opening is a large irregular aperture, situated at the upper part of the posterior wall, leading into a considerable air space, the *antrum mastoideum* (see p. 154). The antrum communicates with large irregular cavities contained in the interior of the mastoid process. These cavities vary considerably in number, size, and form; they are lined by mucous membrane, continuous with that lining the cavity of the tympanum.

The **anterior wall of the tympanum** is wider above than below; it corresponds with the carotid canal, from which it is separated by a thin plate of bone, perforated by the tympanic branch of the internal carotid. It presents for examination the

Canal for the Tensor tympani.

Orifice of the Eustachian tube.

The *processus cochleariformis*.

The orifice of the canal for the Tensor tympani and the orifice of the Eustachian tube are situated at the upper part of the anterior wall, being separated from each other by a thin, delicate, horizontal plate of bone, the *processus cochleariformis*. These canals run from the tympanum forwards, inwards, and a little downwards, to the retiring angle between the squamous and petrous portions of the temporal bone.

The *canal for the Tensor tympani* is the superior and the smaller of the two; it is rounded, and lies beneath the upper surface of the petrous bone, close to the hiatus Fallopii. The tympanic end of this canal forms a conical eminence, which is prolonged backwards into the cavity of the tympanum, and is perforated at its summit by an aperture, which transmits the tendon of the muscle contained in it. This eminence is sometimes called the *anterior pyramid*. The canal contains the Tensor tympani muscle.

The *Eustachian tube* is the channel through which the tympanum communicates with the pharynx. Its length is from an inch and a half to two inches, and its direction downwards, forwards, and inwards. It is formed partly of bone, partly of cartilage and fibrous tissue.

The *osseous portion* is about half an inch in length. It commences in the lower part of the anterior wall of the tympanum, below the *processus cochleariformis*, and, gradually narrowing, terminates in an oval dilated opening, at the angle of junction of the petrous and squamous portions, its extremity presenting a jagged margin which serves for the attachment of the cartilaginous portion.

The *cartilaginous portion*, about an inch in length, is formed of a triangular plate of elastic fibro-cartilage, curled upon itself, an interval being left below, between the margins of the cartilage, which is completed by fibrous and muscular tissue. Its canal is narrow behind, wide, expanded, and somewhat trumpet-shaped in front, terminating by an oval orifice, at the upper part and side of the pharynx, behind the back part of the inferior meatus. Through this canal the mucous membrane of the pharynx is continuous with that which lines the tympanum. The mucous membrane is covered with ciliated epithelium.

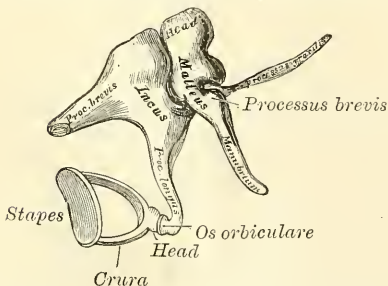
The **membrana tympani** separates the cavity of the tympanum from the bottom of the external meatus. It is a thin, semi-transparent membrane, nearly oval in form, somewhat broader above than below, and directed very obliquely downwards and inwards. Its circumference is contained in a groove at the inner end of the meatus, which skirts the circumference of this part, excepting above. The handle of the malleus descends vertically between the inner and middle layers of this membrane as far down as its centre, where it is firmly attached, drawing the membrane inwards, so that its outer surface is concave, its inner convex.

**Structure.**—This membrane is composed of three layers, an external (cuticular), a middle (fibrous), and an internal (mucous). The *cuticular lining* is derived from the integument lining the meatus. The *fibrous layer* consists of fibrous and elastic tissues; some of the fibres radiate from near the centre to the circumference; others are arranged, in the form of a dense circular ring, round the attached margin of the membrane. The *mucous lining* is derived from the mucous lining of the tympanum. The vessels pass to the *membrana tympani* along the handle of the malleus, and are distributed between its layers.

#### OSSICLES OF THE TYMPANUM (fig. 547)

The tympanum is traversed by a chain of movable bones, three in number, the *malleus*, *incus*, and *stapes*. The former is attached to the *membrana tympani*, the latter to the *fenestra ovalis*, the *incus* being placed between the two, to both of which it is connected by delicate articulations.

FIG. 547.—The small bones of the ear seen from the outside. (Enlarged.)



The **Malleus**, so named from its fancied resemblance to a hammer, consists of a head, neck, and three processes: the handle or manubrium, the processus gracilis, and the processus brevis.

The head is the large upper extremity of the bone; it is oval in shape, and articulates posteriorly with the incus, being free in the rest of its extent.

The neck is the narrow contracted part just beneath the head; and below this is a prominence, to which the various processes are attached.

The *manubrium* is a vertical process of bone, which is connected by its outer margin with the *membrana tympani*. It decreases in size towards its extremity, where it is curved slightly forwards, and flattened from within outwards. On the

inner side, near its upper end, is a slight projection, into which the tendon of the Tensor tympani is inserted.

The *processus gracilis* is a long and very delicate process, which passes from the eminence below the neck forwards and outwards to the Glaserian fissure, to which it is connected by bone and ligamentous fibres.

The *processus brevis* is a slight conical projection, which springs from the root of the manubrium, and lies in contact with the membrana tympani.

The **Incus** has received its name from its supposed resemblance to an anvil, but it is more like a bicuspid tooth, with two roots, which differ in length, and are widely separated from each other. It consists of a body and two processes.

The *body* is somewhat quadrilateral but compressed laterally. On the anterior surface of its summit is a deeply concavo-convex facet, which articulates with the malleus; in the fresh state it is covered with cartilage and lined with synovial membrane.

The two processes diverge from one another nearly at right angles.

The *short process*, somewhat conical in shape, projects nearly horizontally backwards, and is attached to the margin of the opening leading into the mastoid cells, by ligamentous fibres.

The *long process*, longer and more slender than the preceding, descends nearly vertically behind and parallel to the handle of the malleus, and, bending inwards, terminates in a rounded globular projection, the *os orbiculare*, or *lenticular process* which is tipped with cartilage, and articulates with the head of the stapes. In the fœtus the os orbiculare exists as a separate bone.

The **Stapes**, so called from its close resemblance to a stirrup, consists of a head, neck, two branches, and a base.

The *head* presents a depression, tipped with cartilage, which articulates with the os orbiculare.

The *neck*, the constricted part of the bone below the head, receives the insertion of the Stapedius muscle.

The *two branches (crura)* diverge from the neck and are connected at their extremities by a flattened oval-shaped plate (the *base*), which forms the foot of the stirrup and is fixed to the margin of the fenestra ovalis by ligamentous fibres.

**Ligaments of the Ossicula.**—These small bones are connected with each other, and with the walls of the tympanum, by ligaments, and moved by small muscles. The articular surfaces of the malleus and incus, and the orbicular process of the incus and head of the stapes, are covered with cartilage, connected together by delicate capsular ligaments, and lined by synovial membrane. The ligaments connecting the ossicula with the walls of the tympanum are four in number: two for the malleus, one for the incus, and one for the stapes.

The *anterior ligament of the malleus* was formerly described by Sömmerring as a muscle (*Laxator tympani*). It is now, however, believed by most observers to consist of ligamentous fibres only. It is attached by one extremity to the neck of the malleus, just above the *processus gracilis*, and by the other to the anterior wall of the tympanum, close to the Glaserian fissure, some of its fibres being prolonged through the fissure.

The *suspensory ligament of the malleus* is a delicate, round bundle of fibres which descends perpendicularly from the roof of the tympanum to the head of the malleus.

The *external ligament of the malleus* is a triangular plane of fibres passing from the notch in the tympanic ring (*incisura Rivini*) to the short process of the malleus.

The *posterior ligament of the incus* is a short, thick, ligamentous band which connects the extremity of the short process of the incus to the posterior wall of the tympanum, near the margin of the opening of the mastoid cells.

The *annular ligament of the stapes* connects the circumference of the base of this bone to the margin of the fenestra ovalis.



A *suspensory ligament of the incus* has been described by Arnold, descending from the roof of the tympanum to the upper part of the incus, near its articulation with the malleus.

The **muscles of the tympanum** are two :

Tensor tympani.

Stapedius.

The *Tensor tympani*, the larger, is contained in the bony canal, above the osseous portion of the Eustachian tube, from which it is separated by the *processus cochleariformis*. It arises from the under surface of the petrous bone, from the cartilaginous portion of the Eustachian tube, and from the osseous canal in which it is contained. Passing backwards through the canal, it terminates in a slender tendon which enters the tympanum and makes a sharp bend outward round the extremity of the *processus cochleariformis*, and is inserted into the handle of the malleus, near its root. It is supplied by a branch from the otic ganglion.

The *Stapedius* arises from the side of a conical cavity, hollowed out of the interior of the pyramid; its tendon emerges from the orifice at the apex of the pyramid, and, passing forwards, is inserted into the neck of the stapes. Its surface is aponeurotic, its interior fleshy; and its tendon occasionally contains a slender bony spine, which is constant in some mammalia. It is supplied by the tympanic branch of the facial nerve.

*Actions.*—The *Tensor tympani* draws the *membrana tympani* inwards, and thus heightens its tension. The *Stapedius* draws the head of the stapes backwards, and thus causes the base of the bone to rotate on a vertical axis drawn through its own centre: in doing this the back part of the base would be pressed inwards towards the vestibule, while the fore part would be drawn from it. It probably compresses the contents of the vestibule.

The **mucous membrane of the tympanum** is continuous with the mucous membrane of the pharynx, through the Eustachian tube. It invests the ossicula, and the muscles and nerves contained in the tympanic cavity; forms the internal layer of the *membrana tympani*; covers the *foramen rotundum*, and is reflected into the mastoid cells, which it lines throughout. It forms several vascular folds, which extend from the walls of the tympanum to the ossicles; of these one descends from the roof of the tympanum to the head of the malleus and upper margin of the body of the incus, a second passes backwards from the posterior crura of the stapes and invests the *Stapedius* muscle: other folds invest the *cordi tympani* nerve to the *Tensor tympani* muscle. These folds separate off pouch-like cavities, and give the interior of the tympanum a somewhat honeycomb appearance. In the tympanum this membrane is pale, thin, slightly vascular, and covered for the most part with columnar ciliated epithelium, but that covering the pyramid, ossicula, and *membrana tympani* possesses a flattened non-ciliated epithelium. In the antrum and mastoid cells its epithelium is also non-ciliated. In the osseous portion of the Eustachian tube the membrane is thin; but in the cartilaginous portion it is very thick, highly vascular, covered with laminated ciliated epithelium, and provided with numerous mucous glands.

The **arteries supplying the tympanum** are six in number. Three of them are larger than the rest, viz. the tympanic branch of the internal maxillary, which supplies the *membrana tympani*; the Vidian, and the stylo-mastoid branch of the posterior auricular, which supplies the back part of the tympanum and mastoid cells. The smaller branches are—the petrosal branch of the middle meningeal, which enters through the *hiatus Fallopii*; a branch from the ascending pharyngeal and another from the Vidian, which pass up the Eustachian tube; and the tympanic branch from the internal carotid, given off in the carotid canal and perforating the thin anterior wall of the tympanum.

The **veins of the tympanum** terminate in the temporo-maxillary vein and in the superior petrosal sinus.

The **nerves of the tympanum** constitute the tympanic plexus, which ramifies

upon the surface of the promontory. The plexus is formed by the (1) tympanic branch of the glosso-pharyngeal; (2) the small deep petrosal nerve; (3) the long petrosal nerve; and (4) the small superficial petrosal nerve.

The *tympanic branch of the glosso-pharyngeal* (Jacobson's nerve) enters the tympanum by an aperture in its floor close to the inner wall and divides into branches, which ramify on the promontory and enter into the formation of the plexus. The *small deep petrosal nerve* from the carotid plexus of the sympathetic, passes through the wall of the carotid canal and joins the branches of Jacobson's nerve. The *long petrosal nerve* from the great superficial petrosal is given off in the foramen lacerum medium and passes through an opening on the inner wall of the tympanum in front of the fenestra ovalis. It joins with the other branches of the plexus. The *small superficial petrosal nerve*, derived from the otic ganglion, passes through a foramen in the middle fossa of the base of the skull (sometimes the foramen ovale), passes backwards and enters the petrous bone through a small aperture, situated external to the hiatus Fallopii on the anterior surface of this bone; it then courses downwards through the bone, and, passing by the gangliform enlargement of the facial nerve, receives a connecting filament from it and enters the tympanic cavity, where it communicates with Jacobson's nerve, and assists in forming the tympanic plexus.

The *branches of distribution* of the tympanic plexus are distributed to the mucous membrane of the tympanum; one special branch passing to the fenestra ovalis, another to the fenestra rotunda, and a third to the Eustachian tube.

In addition to the tympanic plexus there are the nerves supplying the muscles. The Tensor tympani is supplied by a branch from the internal pterygoid of the third division of the fifth through the otic ganglion, and the Stapedius by the tympanic branch of the facial.

The *chorda tympani* nerve crosses the tympanic cavity. It is given off from the facial, as it passes vertically downwards at the back of the tympanum, about a quarter of an inch before its exit from the stylo-mastoid foramen. It passes from below upwards and forwards in a distinct canal, and enters the cavity of the tympanum through an aperture, *iter chordæ posterius*, on its posterior wall between the opening of the mastoid cells and the attachment of the membrana tympani, and becomes invested with mucous membrane. It passes forwards through the cavity of the tympanum, crossing behind the membrana tympani and over the handle of the malleus to the anterior inferior angle of the tympanum, and emerges from that cavity through a foramen at the inner end of the Glaserian fissure, which is called the *iter chordæ anterioris*, or *canal of Huguier*. It is invested by the fold of mucous membrane already mentioned, and therefore lies between the mucous and fibrous layers of the membrana tympani.

#### INTERNAL EAR, OR LABYRINTH

The **internal ear** is the essential part of the organ, receiving the ultimate distribution of the auditory nerve. It is called the **labyrinth**, from the complexity of its shape, and consists of two parts: the *osseous labyrinth*, a series of cavities channelled out of the substance of the petrous bone, and the *membranous labyrinth*, the latter being contained within the former.

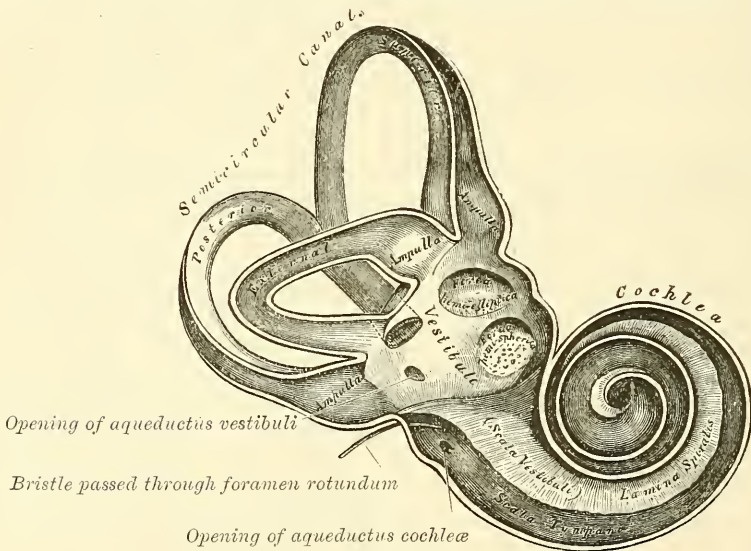
#### THE OSSEOUS LABYRINTH

The **osseous labyrinth** consists of three parts: the *vestibule*, *semicircular canals*, and *cochlea*. These are cavities hollowed out of the substance of the bone, and lined by periosteum, and containing a clear fluid, perilymph, or liquor Cotunnii, in which the membranous labyrinth is contained.

The **Vestibule** (fig. 548) is the common central cavity of communication

between the parts of the internal ear. It is situated on the inner side of the tympanum, behind the cochlea, and in front of the semicircular canals. It is somewhat ovoidal in shape from before backwards, flattened from within outwards, and measures about one-fifth of an inch from before backwards, as well as from above downwards, being narrower from without inwards. On its *outer* or *tympanic wall* is the fenestra ovalis, closed, in the recent state, by the base of the stapes, and its annular ligament. On its *inner wall*, at the fore part, is a small circular depression, *fovea hemispherica*, which is perforated, at its anterior and inferior part, by several minute holes (*macula cribrosa*) for the passage of filaments of the auditory nerve; and behind this depression is a vertical ridge, the *pyramidal eminence (crista vestibuli)*. This ridge bifurcates below to enclose a small depression, the *fossa cochlearis*, which is perforated by a number of holes for the passage of filaments of the auditory nerve. At the hinder part of the inner wall is the orifice of the *aqueductus vestibuli*, which extends to the posterior surface of the petrous portion of the temporal bone. It transmits a small vein, and, according to some, contains a tubular prolongation

FIG. 548.—The osseous labyrinth laid open. Enlarged.)



of the lining membrane of the vestibule, the *ductus endo-lymphaticus*, which ends in a *cul-de-sac* between the layers of the dura mater within the cranial cavity. On the *upper wall* or *roof* is a transversely oval depression, *fovea semi-elliptica*, separated from the fovea hemispherica by the pyramidal eminence already mentioned. *Behind*, the semicircular canals open into the vestibule by five orifices. In *front* is a large oval opening, which communicates with the scala vestibuli of the cochlea by a single orifice, *apertura scalæ vestibuli cochleæ*.

The **Semicircular canals** are three bony canals, situated above and behind the vestibule. They are of unequal length, compressed from side to side, and describe the greater part of a circle. They measure about one-twentieth of an inch in diameter, and each presents a dilatation at one end, called the *ampulla*, which measures more than twice the diameter of the tube. These canals open into the vestibule by five orifices, one of the apertures being common to two of the canals.

The *superior semicircular canal* is vertical in direction, and stretches across the petrous portion of the temporal bone, at right angles to its posterior surface; its arch forms a round projection on the anterior surface of the petrous bone. It



describes about two-thirds of a circle. Its outer extremity, which is ampullated, commences by a distinct orifice in the upper part of the vestibule; the opposite end of the canal, which is not dilated, joins with the corresponding part of the posterior canal, and opens by a common orifice with it in the back part of the vestibule.

The *posterior semicircular canal*, also vertical in direction, is directed backwards, nearly parallel to the posterior surface of the petrous bone; it is the longest of the three, its ampullated end commences at the lower and back part of the vestibule, its opposite end joining to form the common canal already mentioned.

The *external or horizontal canal* is the shortest of the three, its arch being directed outwards and backwards; thus each semicircular canal stands at right angles to the other two. Its ampullated end corresponds to the upper and outer angle of the vestibule, just above the fenestra ovalis; its opposite end opens by a distinct orifice at the upper and back part of the vestibule.

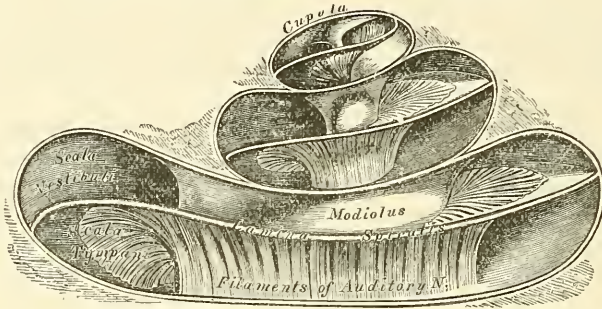
The **Cochlea** bears some resemblance to a common snail-shell: it forms the anterior part of the labyrinth, is conical in form, and placed almost horizontally in front of the vestibule; its apex is directed forwards and outwards, with a slight inclination downwards, towards the upper and front part of the inner wall of the tympanum; its base corresponds with the anterior depression at the bottom of the internal auditory meatus, and is perforated by numerous apertures, for the passage of the cochlear branch of the auditory nerve. It measures about a quarter of an inch in length, and its breadth towards the base is somewhat greater. It consists of a conical-shaped central axis, the *modiolus* or *columella*; of a canal, the inner wall of which is formed by the central axis, wound spirally around it for two turns and a half, from the base to the apex, and of a delicate lamina (the *lamina spiralis*) which projects from the modiolus, and, following the windings of the canal, partially subdivides into two. In the recent state certain membranous layers are attached to the free border of this lamina, which project into the canal and completely separate it into two passages, which, however, communicate with each other at the apex of the modiolus by a small opening, named the *helicotrema*.

The *modiolus* or *columella* is the central axis or pillar of the cochlea. It is conical in form, and extends from the base to the apex of the cochlea. Its base is broad, corresponds with the first turn of the cochlea, and appears at the bottom of the internal auditory meatus; it is perforated by numerous orifices, which transmit filaments of the cochlear branch of the auditory nerve; the axis diminishes rapidly in size in the second coil, and terminates within the last half-coil in an expanded, delicate, bony lamella, the *infundibulum*, which blends with the termination of the spiral canal. The outer surface of the modiolus is dense in structure, but its interior is spongy as far as the last half-coil, and is channelled by numerous branching canals, which transmit nervous filaments in regular succession into the canal of the cochlea, or on to the surface of the lamina spiralis. One of these, larger than the rest, occupies the centre of the modiolus, and is named the *canalis centralis modioli*; it extends from the base to the apex of the modiolus, and transmits a small nerve and artery (*arteria centralis modioli*).

The *spiral canal* (fig. 549) takes two turns and a half round the modiolus. It is about an inch and a half in length, measured along its outer wall, and diminishes gradually in size from the base to the summit, where it terminates in a *cul-de-sac*, the *cupola*, which forms the apex of the cochlea, and is continuous with the infundibulum of the modiolus. The commencement of this canal is about the tenth of an inch in diameter; it diverges from the modiolus towards the tympanum and vestibule, and presents three openings. One, the *fenestra rotunda*, communicates with the tympanum; in the recent state this aperture is closed by a membrane, the *membrana tympani secundaria*. Another aperture, of an oval form, enters the vestibule. The third is the aperture of the

aqueductus cochlea, leading to a minute funnel-shaped canal, which opens on the basilar surface of the petrous bone and transmits a small vein, and also forms a communication between the subarachnoidean space of the skull and the perilymph contained in the scala tympani.

FIG. 549.—The cochlea laid open. (Enlarged.)



The *osseous lamina spiralis* is a bony shelf or ledge which projects outwards from the modiolus into the interior of the spiral canal, and, like the canal, takes two and a half turns round the modiolus. It reaches about halfway towards the outer wall of the spiral tube, and partially divides its cavity into two portions, as it follows its winding from base to apex. Near the summit of the cochlea the lamina terminates in a hook-shaped process, the *hamulus*, which forms the boundary of a small opening, the *helicotrema*, by which the two scalæ, into which the spiral canal is divided, communicate with each other. These scalæ are named *scala vestibuli* and *scala tympani*.

#### THE MEMBRANOUS LABYRINTH (fig. 550)

The **membranous labyrinth** is contained within the bony cavities just described. In the vestibule and semicircular canals it consists of a membranous sac, having the same general form as the cavities in which it is contained, though considerably smaller, being separated from the bony walls by a quantity of fluid, the *perilymph*. It does not, however, float loosely in this fluid, but in places is fixed to the walls of the cavity. The membranous sac contains fluid, the *endo-lymph*, and on it the ramifications of the auditory nerve are distributed. The membranous labyrinth of the cochlea consists of a tube containing endo-lymph, and partly surrounded by perilymph, which occupies the spiral canal of the osseous cochlea; but in addition to this it completes the septum between the scala vestibuli and the scala tympani, and also shuts off a small portion of the first-named scala, as a separate canal, the *canalis cochleæ*.

Within the osseous vestibule the membranous labyrinth does not quite preserve the form of the bony cavity, but presents two membranous sacs, the *utricle* and the *sacculæ*. The *utricle* is the larger of the two, of an oblong form, compressed laterally, and occupies the upper and back part of the vestibule, lying in contact with the fovea semi-elliptica and the part below it. That portion which is lodged in the fovea forms a sort of pouch or *cul-de-sac*, the wall of which is much thicker than elsewhere, and has attached to its internal surface a layer of calcareous particles (otoliths). Here numerous filaments of the auditory nerve are distributed to the wall of the sac. Its cavity communicates behind with the membranous semicircular canals by five orifices.

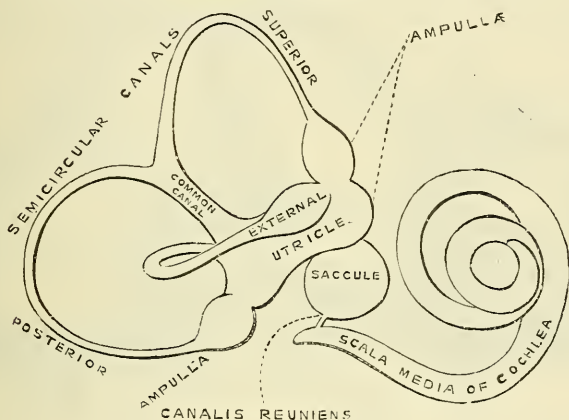
The *sacculæ* is the smaller of the two vestibular sacs; it is globular in form, lies in the fovea hemispherica near the opening of the scala vestibuli of the cochlea, and receives numerous nervous filaments, which enter from the bottom of the depression in which it is contained. Its cavity does not directly com-

municate with that of the utricle. From the lower part of the saccule a funnel-shaped tube passes downwards and outwards to open into the spiral canal of the cochlea. This is known by the name of the *canalis reuniens* (fig. 550). The *membranous semicircular canals* are about one-third the diameter of the osseous canals, but in number, shape, and general form they are precisely similar, and present at one end an ampullary enlargement. They are hollow and open by five orifices into the utricle, one opening being common to two canals. Their ampullæ are thicker than the rest of the tubes, and nearly fill the cavities in which they are contained.

The membranous labyrinth is held in its position by numerous fibrous bands which stretch across the space between the membranous and bony labyrinths. These fibrous bands convey the blood vessels and nervous filaments distributed to the utricle, to the saccule, and to the ampullæ of each canal.

**Structure.**—The wall of the membranous labyrinth is semi-transparent and consists of three layers. The *outer layer* is a loose and flocculent structure, apparently composed of ordinary fibrous tissue, containing blood vessels and pigment cells analogous to those in the pigment coat of the retina. The *middle layer*, thicker and more transparent, bears some resemblance to the hyaloid membrane, but it presents on its internal surface numerous papilliform projec-

FIG. 550.—The membranous labyrinth. (Enlarged.)



tions, and, on the addition of acetic acid, presents an appearance of longitudinal fibrillation and elongated nuclei. The *inner layer* is formed of polygonal nucleated epithelial cells. In the utricle, the saccule and the ampullæ of the canals at the part where they are connected to the bony walls, the middle coat is thickened and the epithelium is columnar, each epithelial cell being surmounted by a long, tapering filament (auditory hair) which projects into the cavity. The filaments of the auditory nerve enter this part, and having pierced the outer and thickened middle layer, they lose their medullary sheath, and their axis cylinders ramify between those columnar cells which bare the auditory hairs.

The *endo-lymph* (*liquor Scarpæ*) is a limpid serous fluid which fills the membranous labyrinth; in composition it closely resembles the perilymph.

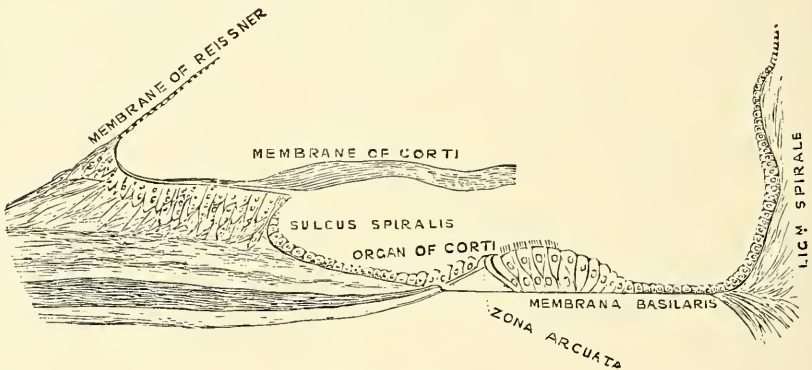
The *otoliths* are two small rounded bodies, consisting of a mass of minute crystalline grains of carbonate of lime, held together in a mesh of delicate fibrous tissue, and contained in the walls of the utricle and saccule opposite the distribution of the nerves. A calcareous material is also, according to Bowman, sparingly scattered in the cells lining the ampullæ of the semicircular canals.

The **membranous labyrinth of the cochlea** consists of a tube enclosed in the spiral canal, which is divided into three compartments by certain other membranous structures, which will now be described.



The osseous lamina, as above stated, extends only part of the distance between the modiolus and the outer bony wall of the cochlea. Near its outer end it becomes somewhat thickened, and this thickened part is known as the *limbus laminae spiralis*. It terminates abruptly in a grooved extremity, the *sulcus spiralis*, which presents the form of the letter C: the upper part of the letter, being formed by the overhanging extremity of the limbus, is named the *labium vestibulare*; the lower part, prolonged and tapering, is called the *labium tympanicum* (fig. 551). From the labium tympanicum a thin membrane extends over to the bony wall of the cochlea, completing the *scala tympani*. This membrane is called the *membrana basilaris*. At its outer attachment it swells out so as to form a thick, triangular structure, which was regarded as a muscle by Tod and Bowman (cochlearis), but is now recognised as ligamentous—the *ligamentum spirale*. Between the labium vestibulare and the attachment of the membrane of Reissner, presently to be described, a very delicate membrane extends over towards the outer wall of the cochlea, running nearly parallel to the *membrana basilaris*. It was described by Corti, and covers over the organ which is called after his name, and is therefore called the *membrane of Corti* or *membrana tectoria*. When this membrane passes over the specialised epithelium known as the rods of Corti, it swells out and forms a thick fibrillated membrane, which rests on the rods; beyond these structures it again thins out and forms a delicate membrane over

FIG. 551.—Floor of scala media, showing the organ of Corti, etc.



the outer hair-cells. Farther inwards, near the commencement of the *limbus laminae spiralis*, another delicate membrane, the *membrane of Reissner*, is attached to the vestibular surface of the periosteum of the osseous lamina, and stretches across to the outer wall of the cochlea. The canal which lies below the osseous lamina and *membrana basilaris* is the *scala tympani*; that which is bounded by the osseous lamina and *membrane of Reissner* the *scala vestibuli*; while the space between the *membrane of Reissner* and *membrana basilaris* is generally described as the *Scala media*, *Canalis membranacea*, or *Canalis cochleæ*. The latter is the space in which the *organ of Corti*\* is contained. This organ (fig. 551) is situated upon the *membrana basilaris*, and appears at first sight as a papilla, winding spirally with the turns of this membrane throughout the whole length of the cochlea, from which circumstance it has been designated the *papilla spiralis*. More accurately viewed, it is seen to be composed of a remarkable arrangement of cells, which may be likened to the keyboard of a pianoforte. Of these cells, the two central ones are rodlike bodies, and are called the inner and outer *rods of Corti*. They are placed erect on the *basilar membrane*, at some little distance from each other, the space between them being denominated the *zona arcuata*; they are inclined towards each other, so as to meet at their opposite extremities, and form a series of arches roofing over the *zona arcuata*,

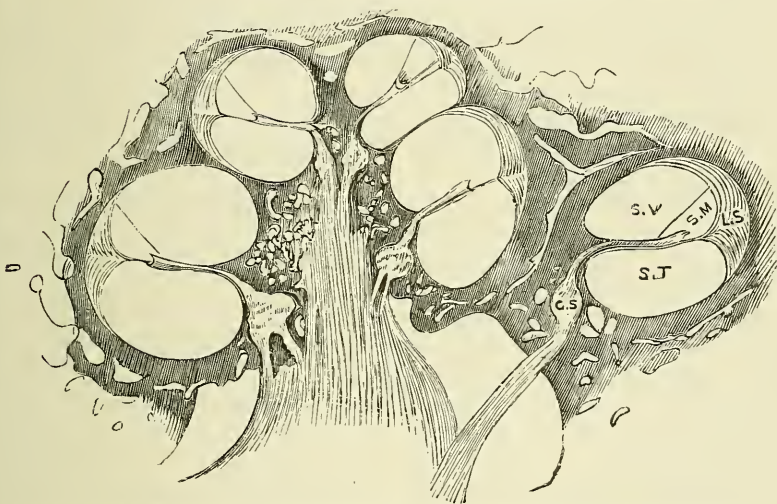
\* Corti's original paper is in the *Zeitschrift f. Wissen. Zool.* iii. 109.

thus forming a minute tunnel between them and the basilar membrane, which ascends spirally through the whole length of the cochlea. They are estimated at over three thousand in number.

The inner rods, which are more numerous than the outer ones, rest on the basilar membrane, close to the labium tympanicum; they project obliquely forwards and outwards, and terminate above in expanded extremities, which resemble in shape the upper end of the ulna, with its sigmoid cavity, coronoid and olecranon processes. On the outer side of the rod, in the angle formed between it and the basilar membrane, is a protoplasmic cell; whilst on the inner side is a row of epithelial cells, surmounted by a brush of fine, stiff, hairlike processes, these cells being continuous with the cubical cells lining the sulcus spiralis.

The outer rods also rest by a broad foot on the basilar membrane; they incline forwards and inwards, and their upper extremity resembles the head and bill of a swan; the head fitting into the concavity—the analogue of the sigmoid cavity—of one or more of the internal rods, and the bill resting against the phalanges of the lamina reticularis, presently to be described.

FIG. 552.—Longitudinal section of the cochlea, showing the relations of the scalæ, the ganglion spirale, etc.



S. V. Scala vestibuli. S. T. Scala tympani. S. M. Scala media. L. S. Ligamentum spirale.  
G. S. Ganglion spirale.

In the head of these outer rods is an oval portion, where the fibres of which the rod appears to be composed are deficient, and which stains more deeply with carmine than the rest of the rod. This is supposed to represent the nucleus of the cell from which the rod was originally developed. At the base of the rod, on its internal side—that is to say, in the angle formed by the rod with the basilar membrane—is a similar protoplasmic cell to that found on the outer side of the base of the inner rod; whilst external to the outer rod are three or four successive rows of epithelial cells, more elongated than those found on the internal side of the inner rod, but, like them, furnished with minute hairs or cilia. These are termed the *outer hair-cells*, in contradistinction to the inner set, which are termed the *inner hair-cells*. They are attached by their bases to the basilar membrane, whilst from the opposite extremity a brush of hairs or cilia projects through the reticular membrane. They are continuous externally with the cubical cells on the lateral part of the basilar membrane.

The *reticular lamina* or *membrane of Kölliker* is a delicate framework perforated by rounded holes. It extends from the inner rods of Corti to the external row



of the outer hair-cells, and is formed by several rows of 'minute fiddle-shaped cuticular structures,' called *phalanges*, between which are holes for the projection of the ciliae of the outer hair-cells.

Covering over these structures, but not touching them, is the *membrana tectoria*, or membrane of Corti, which is attached to the vestibular surface of the lamina spiralis close to the attachment of the membrane of Reissner; it courses over the denticulate lamina, and, passing outwards parallel to the basilar membrane, is blended with the *ligamentum spirale* on the outer wall of the spiral canal.\*

The *inner surface of the osseous labyrinth* is lined by an exceedingly thin fibro-serous membrane, analogous to a periosteum, from its close adhesion to the inner surfaces of these cavities, and performing the office of a serous membrane by its free surface. It lines the vestibule, and from this cavity is continued into the semicircular canals and the *scala vestibuli* of the cochlea, and through the *helicotrema* into the *scala tympani*. A delicate tubular process is prolonged along the aqueduct of the vestibule to the inner surface of the dura mater. This membrane is continued across the *fenestra ovalis* and *rotunda*, and consequently has no communication with the lining membrane of the tympanum. Its attached surface is rough and fibrous, and closely adherent to the bone; its free surface is smooth and pale, covered with a layer of epithelium, and secretes a thin, limpid fluid, the *aqua labyrinthi*, *liquor Cotunnii*, or *perilymph* (Blainville).

The *scala media* is closed above and below. The upper blind extremity is attached to the cupola at the upper part of the *helicotrema*; the lower end fits into the angle at the commencement of the osseous lamina on the floor of the vestibule. Near this blind extremity, the *scala media* receives the *canalis reuniens* (fig. 550), a very delicate canal, by which the *ductus cochlearis* is brought into continuity with the saccule.

The **arteries of the labyrinth** are the internal auditory, from the basilar; the stylo-mastoid, from the posterior auricular; and, occasionally, branches from the occipital. The internal auditory divides at the bottom of the internal meatus into two branches: cochlear and vestibular.

The cochlear branch subdivides into from twelve to fourteen twigs, which traverse the canals in the modiolus, and are distributed, in the form of a capillary network, in the substance of the lamina spiralis.

The vestibular branches accompany the nerves, and are distributed, in the form of a minute capillary network, in the substance of the membranous labyrinth.

The **veins** (auditory) of the vestibule and semicircular canals accompany the arteries, and, receiving those of the cochlea at the base of the modiolus, terminate in the superior petrosal sinus.

The **auditory nerve**, the special nerve of the sense of hearing, divides, at the bottom of the internal auditory meatus, into two branches, the cochlear and vestibular. The trunk of the nerve, as well as the branches, contains numerous ganglion-cells with caudate prolongations.

The *vestibular nerve*, the posterior of the two, divides into three branches: superior, middle, and inferior.

The superior vestibular branch, the largest, divides into numerous filaments, which pass through minute openings at the upper and back part of the *cul-de-sac* at the bottom of the meatus, and, entering the vestibule, are distributed to the utricle and to the ampulla of the external and superior semicircular canals.

The middle vestibular branch consists of numerous filaments, which enter the vestibule by a smaller cluster of foramina, placed below those above-mentioned, and which correspond to the bottom of the fovea hemispherica; they are distributed to the saccule.

The inferior and smallest branch passes backwards in a canal behind the foramina for the nerves of the saccule, and is distributed to the ampulla of the posterior semicircular canal.

\* In fig. 551 only the inner half of the membrane is represented.



The nervous filaments enter the ampullary enlargements at a deep depression seen on their external surface, with a corresponding elevation when seen from within; the nerve-fibres ending in loops and in free extremities. In the utricle and saccule the nerve-fibres spread out, some blending with the calcareous matter; others, radiating on the inner surface of the wall of each cavity, become blended with a layer of nucleated cells, and terminate in a thin fibrous film.

The *cochlear nerve* divides into numerous filaments at the base of the modiolus, which ascend along its canals, and then, bending outwards at right angles, pass through the substance of the bony lamina spiralis, close to its tympanic surface. During their passage through the spiral lamina the nerves form a plexus, which contains ganglion cells forming the ganglion spirale. From this ganglion delicate filaments pass through the osseous lamina to the sulcus spiralis and pass outwards to the organ of Corti. Their exact termination is uncertain. Waldeyer describes them as collected into two groups, one group ending in the outer and the other in the inner hair-cells.

*Surgical Anatomy.*—Malformations, such as imperfect development of the external parts, absence of the meatus, or supernumerary auricles, are occasionally met with. Or the pinna may present a congenital fistula, which is due to defective closure of the first visceral cleft, or rather of that portion of it which is not concerned in the formation of the Eustachian tube, tympanum, and meatus. The skin of the auricle is thin and richly supplied with blood, but in spite of this it is frequently the seat of frost-bite, due to the fact that it is much exposed to cold, and lacks the usual covering of subcutaneous fat found in most other parts of the body. A collection of blood is sometimes found between the cartilage and perichondrium (*hæmatoma auris*), usually the result of traumatism, but not necessarily due to this cause. It is said to occur most frequently in the ears of the insane. Keloid sometimes grows in the auricle around the puncture made for earrings, and epithelioma occasionally affects this part. Deposits of urate of soda are often met with in the pinna in gouty subjects.

The external auditory meatus can be most satisfactorily examined by light reflected down a funnel-shaped speculum; by gently moving the latter in different directions the whole of the canal and membrana tympani can be brought into view. The points to be noted are, the presence of wax or foreign bodies; the size of the canal; and the condition of the membrana tympani. Accumulation of wax is often the cause of deafness, and may give rise to very serious consequences, causing ulceration of the membrane and even absorption of the bony wall of the canal. Foreign bodies are not infrequently introduced into the ear by children, and, when situated in the first portion of the canal, may be removed with tolerable facility by means of a minute hook or loop of fine wire, aided by reflected light; but when they have slipped beyond the narrow middle part of the meatus, their removal is in no wise easy, and attempts to effect it, in inexperienced hands, may be followed by destruction of the membrana tympani and possibly the contents of the tympanum. The calibre of the external auditory canal may be narrowed by inflammation of its lining membrane, running on to suppuration; by periostitis; by polypi, sebaceous tumours, and exostoses. The membrana tympani, when seen in a healthy ear, 'reflects light strongly, and, owing to its peculiar curvature, presents a bright spot of triangular shape at its lower and anterior portion.' From the apex of this, proceeding upwards and slightly forwards, is a white streak formed by the handle of the malleus, while at the upper and middle part of the membrane may be seen a slight projection, caused by the short process of the malleus. In disease, alterations in colour, lustre, curvature or inclination, and perforation must be noted. Such perforations may be caused by a blow, a loud report, or a wound.

The upper wall of the meatus is separated from the cranial cavity by a thin plate of bone; the anterior wall is separated from the temporo-maxillary joint and parotid gland by the bone forming the glenoid fossa; and the posterior wall is in relation with the mastoid cells, hence inflammation of the external auditory meatus may readily extend to the membranes of the brain, to the temporo-maxillary joint, or to the mastoid cells; and, in addition to this, blows on the chin may cause fracture of the wall of the meatus.

The nerves supplying the meatus are, the auricular branch of the pneumogastric, the auriculo-temporal, and the auricularis magnus. The connections of these nerves explain the fact of the occurrence, in cases of any irritation of the meatus, of constant coughing and sneezing, from implication of the pneumogastric, or of yawning from implication of the auriculo-temporal. No doubt also the association of earache, with toothache, in cancer of the tongue is due to implication of the same nerve, a branch of the fifth, which supplies also the teeth and the tongue. The vessels of the meatus and membrana tympani are derived from the posterior auricular, temporal, and internal maxillary arteries. The upper half of the membrana tympani is much more richly supplied with blood than the lower half. For this reason, and also to avoid the chorda tympani nerve and ossicles, incisions through the membrane should be made at the lower and posterior part.

The principal point in connection with the surgical anatomy of the tympanum is its relations to other parts. Its roof is formed by a thin plate of bone, which, with the dura mater, is all that separates it from the temporo-sphenoidal lobe of the brain. Its floor is immediately above the jugular fossa behind and the carotid canal in front. Its posterior wall presents the openings of the mastoid cells. On its anterior wall is the opening of the Eustachian tube. Thus it follows that in disease of the middle ear we may get subdural abscess, septic meningitis, or abscess of the cerebrum or cerebellum, from extension of the inflammation through the bony roof; thrombosis of the lateral sinus, with or without pyæmia, by extension through the floor; or mastoid abscess, by extension backwards. In addition to this we may get fatal hæmorrhage from the internal carotid in destructive changes of the middle ear. And in throat disease we may get the inflammation extending up the Eustachian tube to the middle ear. The Eustachian tube is accessible from the nose. If the nose and mouth be closed, and an attempt made to expire air, a sense of pressure with dulness of hearing is produced in both ears, from the air finding its way up the Eustachian tube and bulging out the membrana tympani. During the act of swallowing, the pharyngeal orifice of the tube, which is normally closed, is opened, probably by the action of the Tensor tympani. This fact was employed by Politzer in devising an easy method of inflating the tube. The nozzle of an indiarubber syringe is inserted into the nostril; the patient takes a mouthful of water and holds it in his mouth; both nostrils are closed with the finger and thumb to prevent the escape of air, and the patient is then requested to swallow; as he does so, the air is forced out of the syringe into his nose, and is driven into the Eustachian tube, which is now open. The impact of the air against the membrana tympani can be heard, if the membrane is sound, by means of a piece of indiarubber tubing, one end of which is inserted into the meatus of the patient's ear, the other into that of the surgeon. The direct examination of the Eustachian tube is made by the Eustachian catheter. This is passed along the floor of the nostril, with the curve downwards, to the posterior wall of the pharynx. When this is felt, the catheter is to be withdrawn about half an inch, and the point rotated outwards through a quarter of a circle and pushed again slightly backwards, when it will enter the orifice of the tube, and will be found to be caught, and air forced into the catheter will be heard impinging on the tympanic membrane, if the ear of the patient and surgeon are connected by an indiarubber tube.





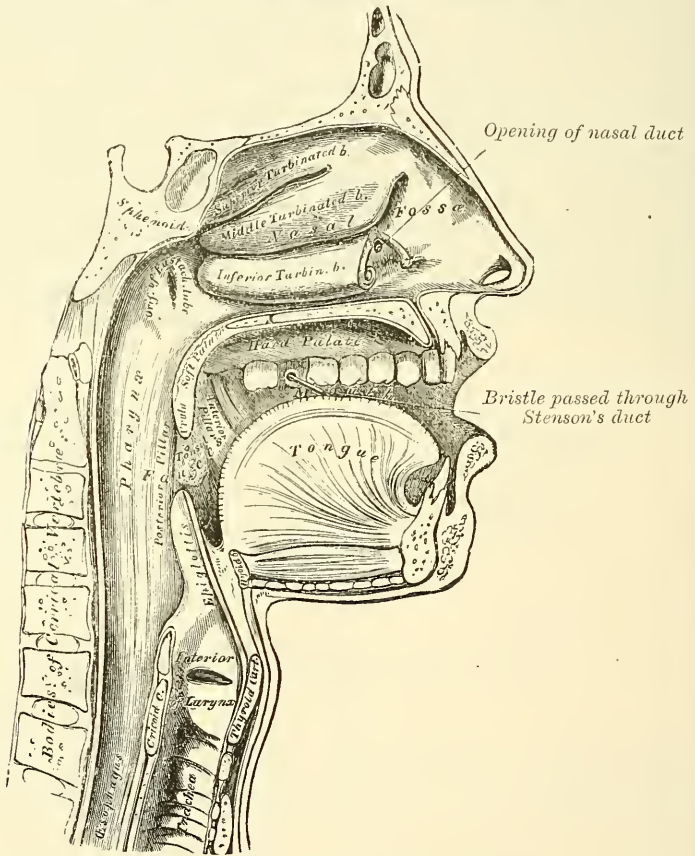
mucous membrane, the *frænum labii superioris* and *inferioris*—the former being the larger of the two.

The *labial glands* are situated between the mucous membrane and the Orbicularis oris, round the orifice of the mouth. They are rounded in form, about the size of small peas, their ducts opening by small orifices upon the mucous membrane. In structure they resemble the salivary glands.

The **cheeks** form the sides of the face, and are continuous in front with the lips. They are composed externally of integument; internally of mucous membrane; and between the two of a muscular stratum, besides a large quantity of fat, areolar tissue, vessels, nerves, and buccal glands.

The *mucous membrane* lining the cheek is reflected above and below upon the gums, and is continuous behind with the lining membrane of the soft palate.

FIG. 553.—Sectional view of the nose, mouth, pharynx, etc.



Opposite the second molar tooth of the upper jaw is a papilla, the summit of which presents the aperture of the duct of the parotid gland. The principal muscle of the cheek is the Buccinator; but numerous other muscles enter into its formation: viz. the Zygomatici, Risorius Santorini, and Platysma myoides.

The *buccal glands* are placed between the mucous membrane and Buccinator muscle: they are similar in structure to the labial glands, but smaller. Two or three of larger size than the rest are placed between the Masseter and Buccinator muscles; their ducts open in the mouth opposite the last molar tooth. They are called *molar glands*.

The **gums** are composed of a dense fibrous tissue, closely connected to the periosteum of the alveolar processes, and surrounding the necks of the teeth. They are covered by smooth and vascular mucous membrane, which is remark-

able for its limited sensibility. Around the necks of the teeth this membrane presents numerous fine papillæ; and from this point it is reflected into the alveolus, where it is continuous with the periosteal membrane lining that cavity.

### THE TEETH

The human subject is provided with two sets of teeth, which make their appearance at different periods of life. The first set appear in childhood, and are called the *temporary, deciduous, or milk teeth*. The second set, which also appear at an early period, continue until old age, and are named *permanent*.

The *temporary teeth* are twenty in number: four incisors, two canine, and four molars, in each jaw.

The *permanent teeth* are thirty-two in number: four incisors (two central and two lateral), two canines, four bicuspid, and six molars, in each jaw.

*General Characters.*—Each tooth consists of three portions: the *crown, or body*, projecting above the gum; the *root, or fang*, entirely concealed within the alveolus; and the *neck*, the constricted portion, between the other two.

The *roots of the teeth* are firmly implanted within the alveoli; these depressions are lined with periosteum, which is reflected on to the tooth at the point of the fang, and covers it as far as the neck. At the margin of the alveolus, the periosteum becomes continuous with the fibrous structure of the gums.

In consequence of the curve of the dental arch, such terms as anterior, posterior, internal and external, as applied to the teeth, are misleading and confusing. Special terms are therefore applied to the different surfaces of a tooth: that surface which is directed towards the lips or cheek is known as the *labial surface*; that which is directed towards the tongue is described as the *lingual surface*; that surface which is directed towards the mesial line, supposing the teeth were arranged in a straight line outwards from the central incisor, is known as the *proximal surface*; whilst that which is directed away from the mesial line is called the *distal surface*.

The teeth in the upper jaw form a larger arch than those in the lower jaw, so that they slightly overlap those of the inferior maxilla both in front and at the sides in the normal condition. In consequence of the greater width of the upper central incisors over those of the lower, the other teeth in the upper jaw are thrown somewhat distally and the two sets do not quite correspond to each other when the mouth is closed: thus the canine tooth of the upper jaw rests partly on the canine of the lower jaw and partly on the first premolar, and in the molar teeth the cusps of the teeth of the upper jaw lie behind the corresponding teeth of the lower jaw. The two series, however, terminate pretty nearly at the same point behind; this is mainly due to the smaller size of the molars in the upper jaw.

### PERMANENT TEETH

The *incisors*, or cutting teeth, are so named from their presenting a sharp cutting edge, adapted for biting the food. They are eight in number, and form the four front teeth in each jaw.

The *crown* is directed vertically, and is chisel-shaped, presenting a sharp horizontal cutting edge, which, before being subject to attrition, presents three small prominent points separated by two slight notches. It is convex, smooth, and highly polished on its labial surface; concave on its lingual surface, where it is frequently marked by slight longitudinal furrows. The one in the centre, being the most prominent, is known as the *basal ridge* or *cingulum*.

The *neck* is constricted.

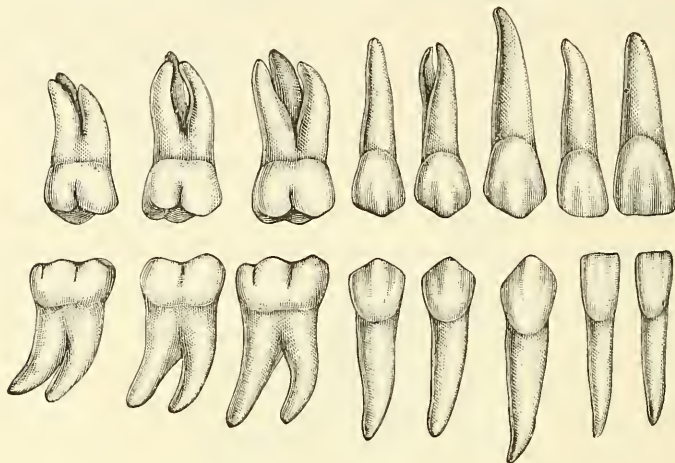
The *fang* is long, single, conical, transversely flattened, thicker before than behind, and slightly grooved on each side in the longitudinal direction.

The *incisors of the upper jaw* are altogether larger and stronger than those of the lower jaw. They are directed obliquely downwards and forwards. The

two central ones are larger than the two lateral, and their free edges are sharp and chisel-like, being bevelled at the expense of their posterior edge: the root is more rounded.

The *incisors of the lower jaw* are smaller than the upper: the two central ones are smaller than the two lateral, and are the smallest of all the incisor

FIG. 554.—Permanent teeth. Right side. (Burchard.)

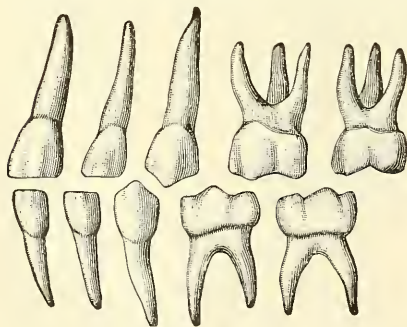


teeth. They are placed vertically in the jaw. These are somewhat bevelled in front, where they have been worn down by contact with the overlapping edge of the upper teeth. The *lingulum* is absent.

The **canine teeth** (*cuspidati*) are four in number: two in the upper, and two in the lower jaw; one being placed distally to each lateral incisor. They are larger and stronger than the incisors, especially the root, which sinks deeply into the jaw, and causes a well-marked prominence upon its surface.

The crown is large and conical, very convex on its labial surface, a little hollowed and uneven on its lingual surface, and tapering to a blunted point or cusp, which rises beyond the level of the other teeth.

FIG. 555.—Deciduous teeth. Left side.



The *root* is single, but longer and thicker than that of the incisors, conical in form, compressed laterally, and marked by a slight groove on each side.

The *upper canine teeth* (vulgarly called *eye-teeth*) are larger and longer than the two lower, and situated a little distally to them.

The *lower canine teeth* are placed mesially to the upper, so that their summits correspond to the interval between the upper canine tooth and the neighbouring incisors on each side.

The **bicuspid teeth** (premolars, small, or false molars) are eight in number: four in each jaw, two being placed distally to each of the canine teeth. They are smaller and shorter than the canine.

The *crown* is compressed proximo-distally, and surmounted by two pyramidal eminences, or cusps, separated by a groove; hence their name, *bicuspidate*. The labial of these cusps is larger and more prominent than the lingual.

The *neck* is oval.

The *root* is generally single, compressed, and presents a deep groove on each



side, which indicates a tendency in the root to become double. The apex is generally bifid.

The *upper bicuspid*s are larger, and present a greater tendency to the division of their roots than the lower; this is especially marked in the second upper bicuspid.

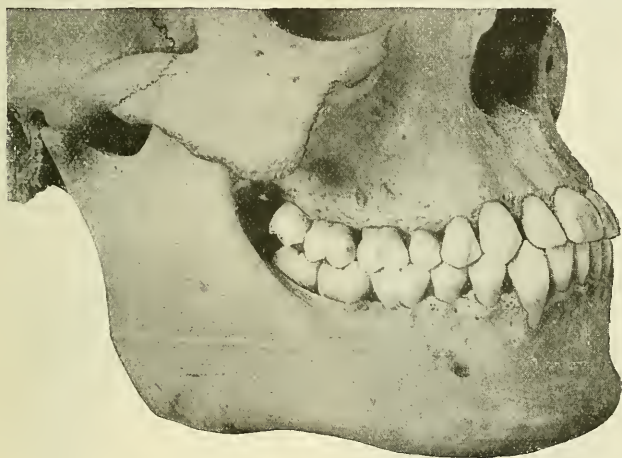The **molar teeth** (*multicuspidati*, true or large molars) are the largest of the permanent set and are adapted from the great breadth of their crowns for grinding and pounding the food. They are twelve in number: six in each jaw, three being placed distally to the second bicuspid.

The *crown* is nearly cubical in form, convex on its labial and lingual surfaces, flattened on its proximal and distal surfaces; the upper surface being surmounted by four or five tubercles, or cusps (four in the upper, five in the lower molars), separated from each other by a crucial depression; hence their name, *multicuspidati*.

The *neck* is distinct, large, and rounded.

The *root* is subdivided into from two to five fangs, each of which presents an aperture at its summit.

FIG. 556.—Front and side views of the teeth and jaws. (Cryer.)



The crown of the *first molar tooth* in the upper jaw has usually four, but occasionally five cusps; the root consists of three fangs, widely separated from one another, two being labial, the other lingual.

The crown of the first molar tooth in the lower jaw is larger than that of the upper; it has five cusps, and its root consists of two fangs, one being placed proximally, the other distally: they are both compressed from before backwards, and grooved on their contiguous faces, indicating a tendency to division.

The *second molar* is a little smaller than the first.

The crown has four cusps in the upper, and five in the lower jaw.

The root has three fangs in the upper jaw, and two in the lower, the characters of which are similar to the preceding tooth.

The *third molar tooth* is called the *wisdom-tooth* (*dens sapientiæ*), from its late appearance through the gum.

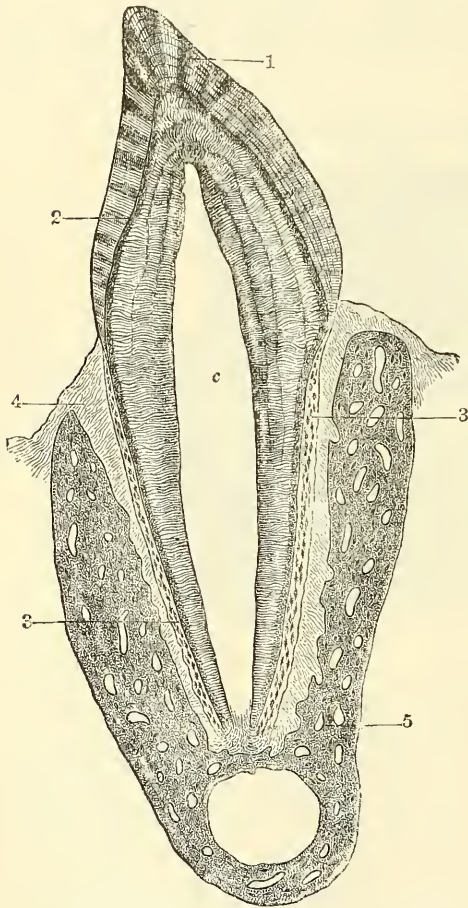
Its crown is usually as large and sometimes larger than the second molar, but smaller than the first. In the upper jaw it is usually furnished with three cusps, the two lingual ones being blended; in the lower jaw there are five cusps as in the other molars.

The root is generally single, short, conical, slightly curved, and grooved so as to present traces of a subdivision into three fangs in the upper, and two in the lower jaw.

## TEMPORARY TEETH

The **temporary or milk teeth** are smaller, but resemble in form those of the permanent set. The hinder of the two temporary molars is the largest of all the milk teeth, and is succeeded by the second permanent bicuspid. The first upper molar has only three cusps—two labial, one lingual; the second upper molar has four cusps. The first lower molar has four cusps; the second lower molar has five. The fangs of the temporary molar teeth are smaller and more diverging than those of the permanent set, but in other respects bear a strong resemblance to them.

FIG. 557.—Vertical section of a tooth *in situ* (15 diameters).

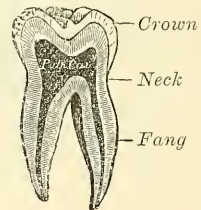


c. is placed in the pulp cavity, opposite the cervix or neck of the tooth; the part above it is the crown, that below is the root (fang). 1. Enamel with radial and concentric markings. 2. Dentine with tubules and incremental lines. 3. Cement or crusta petrosa, with bone corpuscles. 4. Dental periosteum. 5. Bone of lower jaw.

## STRUCTURE OF THE TEETH

On making a vertical section of a tooth (fig. 557), a cavity will be found in the interior. This cavity is situated in the interior of the crown and the centre of each fang, and opens by a minute orifice at the extremity of the latter. The shape of the cavity corresponds somewhat with that of the tooth; it forms what is called the *pulp cavity*, and contains a soft, highly vascular, and sensitive substance,

FIG. 558.—Vertical section of a molar tooth.



the *dental pulp*. The pulp consists of a loose connective tissue and cells; it is richly supplied with vessels and nerves, which enter the cavity through the small aperture at the point of each fang. The cells of the pulp are partly found permeating the pulp matrix, and partly arranged as a layer on the wall of the pulp cavity. These latter cells are named the *odontoblasts of Waldeyer*. These cells, during the development of the

tooth, are columnar in shape, but later on, after the dentine is fully formed, they become flattened and resemble the osteoblasts found in the osteo-genetic layer of the periosteum of bone. They have two fine processes, the outer or distal one passing into a dental tubule, the inner being continuous with the processes of the connective-tissue cells of the pulp matrix.

The solid portion of the tooth consists of three distinct structures, viz. the proper dental substance, which forms the larger portion of the tooth, the *ivory*



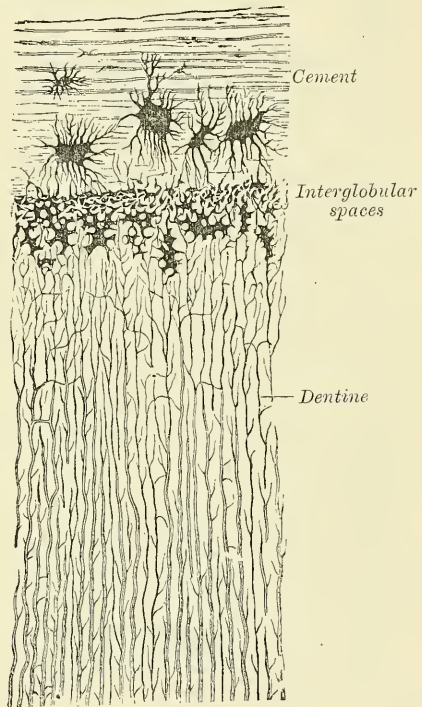
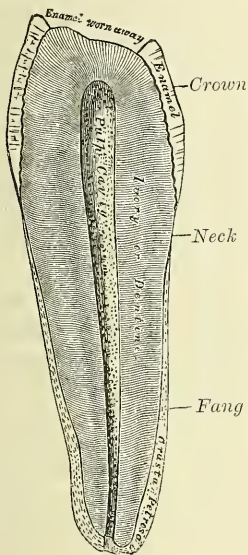
or *dentine*; a layer which covers the exposed part of the crown, the *enamel*; and a thin layer, which is disposed on the surface of the fang, the *cement* or *crusta petrosa*.

The *ivory*, or *dentine* (fig. 559), forms the principal mass of a tooth; in its central part is the cavity enclosing the pulp. It is a modification of osseous tissue, from which it differs, however, in structure. On microscopic examination it is seen to consist of a number of minute wavy and branching tubes, having distinct parietes. They are called the *dentinal tubuli*, and are embedded in a dense homogeneous substance, the *intertubular tissue*.

The *dentinal tubuli* (fig. 560) are placed parallel with one another, and open at their inner ends into the pulp cavity. In their course to the periphery they present two or three curves, and are twisted on themselves in a spiral direction. The direction of these tubes varies: they are vertical in the upper portion of the crown, oblique

FIG. 560.—Canine tooth of man, presenting a transverse section of a portion of the root. (Magnified 300 diameters.)

FIG. 559.—Vertical section of a bicuspid tooth. (Magnified.)



in the neck and upper part of the root, and towards the lower part of the root they are inclined downwards. The tubuli, at their

commencement, are about  $\frac{1}{4300}$  of an inch in diameter; in their course they divide and subdivide dichotomously, so as to give to the cut surface of the dentine a striated appearance. From the sides of the tubes, especially in the fang, ramifications of extreme minuteness are given off, which join together in loops in the intertubular substance, or terminate in small dilatations, from which branches are given off. Near the periphery of the dentine, the finer ramifications of the tubuli terminate imperceptibly by free ends. The dental tubuli have comparatively-thick walls, consisting of an elastic homogeneous membrane, the dentinal sheath of Neumann, which resists the action of acids; they contain slender cylindrical prolongations, first described by Mr. Tomes, and named Tomes's fibres or dentinal fibres. These dentinal fibres are analogous to the soft contents of the canaliculi of bone.

The *intertubular substance* is translucent, and contains the chief part of the earthy matter of the dentine. In it are a number of fine fibrils, which are



continuous with the fibrils of the dental pulp (Mummery). After the earthy matter has been removed by steeping a tooth in weak acid, the animal basis remaining may be torn into laminæ which run parallel with the pulp cavity, across the direction of the tubes. A section of dry-dentine often displays a series of somewhat parallel lines—the *incremental lines of Salter*. These lines are composed of imperfectly calcified dentine arranged in layers. In consequence of the imperfection in the calcifying process, little irregular cavities are left, termed *interglobular spaces*. These spaces are found especially towards the outer surface of the dentine, where they form a layer, which is sometimes known as the *granular layer* (fig. 560). They have received their name from the fact that they are surrounded by minute nodules or globules of dentine. Other curved lines may be seen parallel to the surface. These are the *lines of Schreger*, and are due to the optical effect of simultaneous curvature of the dentinal fibres.

*Chemical Composition.*—According to Berzelius and Bibra, dentine consists of 28 parts of animal and 72 of earthy matter. The animal matter is resolvable by boiling into gelatin. The earthy matter consists of phosphate of lime, carbonate of lime, a trace of fluoride of calcium, phosphate of magnesia, and other salts.

The **enamel** is the hardest and most compact part of a tooth, and forms a thin crust over the exposed part of the crown, as far as the commencement of the fang. It is thickest on the grinding surface of the crown, until worn away by attrition, and becomes thinner towards the neck. It consists of a congeries of minute hexagonal rods or columns. They lie parallel with one another, resting by one extremity upon the dentine, which presents a number of minute depressions for their reception; and forming the free surface of the crown by the other extremity. The columns are directed vertically on the summit of the crown, horizontally at the sides; they are about the  $\frac{1}{5500}$  of an inch in diameter, and pursue a more or less wavy course. Each column is a six-sided prism and presents numerous dark transverse shadings; these shadings are probably due to the manner in which the columns are developed in successive stages, producing shallow constrictions, as will be explained in the sequel. Another series of lines, having a brown appearance, and denominated the *parallel striæ of Retzius*, are seen on a section of the enamel. According to Ebner, they are produced by air in the interprismatic spaces.

Numerous minute interstices intervene between the enamel fibres near their dentinal surface, a provision calculated to allow of the permeation of fluids from the dentinal tubule into the substance of the enamel. It is a disputed point whether the dentinal fibres penetrate a certain distance between the rods of the enamel or not. No nutritive canals exist in the enamel.

*Chemical Composition.*—According to Bibra, enamel consists of 96·5 per cent. of earthy matter, and 3·5 per cent. of animal matter. The earthy matter consists of phosphate of lime, with traces of fluoride of calcium, carbonate of lime, phosphate of magnesia, and other salts.

The **cortical substance**, or **cement** (*crusta petrosa*), is disposed as a thin layer on the roots of the teeth, from the termination of the enamel, as far as the apex of the fang, where it is usually very thick. In structure and chemical composition it resembles bone. It contains, sparingly, the lacunæ and canaliculi which characterise true bone; the lacunæ placed near the surface have the canaliculi radiating from the side of the lacunæ towards the periodontal membrane; and those more deeply placed join with the adjacent dental tubuli. In the thicker portions of the *crusta petrosa*, the lamellæ and Haversian canals peculiar to bone are also found.

As age advances, the cement increases in thickness, and gives rise to those bony growths, or exostoses, so common in the teeth of the aged; the pulp cavity becomes also partially filled up by a hard substance, intermediate in structure between dentine and bone (*osteo-dentine*, Owen; *secondary dentine*, Tomes). It appears to be formed by a slow conversion of the dental pulp, which shrinks, or even disappears.

## DEVELOPMENT OF THE TEETH

In describing the development of the teeth, we have first to consider the mode of formation of the temporary or milk teeth, and then that of the permanent series.

**Development of the temporary teeth.**—The development of these teeth begins at a very early period of fetal life—about the sixth week. It commences as a thickening of the epithelium along the line of the future jaw; the thickening being due to a rapid multiplication of the more deeply situated epithelial cells. As these cells multiply they extend into the subjacent mesoblast, and thus form a semicircular ridge or strand of cells, enclosed by mesoblast. About the seventh week a longitudinal splitting or cleavage of this strand of cells takes place, and it becomes divided into two strands; the separation beginning in front and extending laterally: the process occupying four or five weeks. Of the two strands thus formed, the *outer* or *labial* forms the future labio-dental furrow, and is therefore termed the *labio-dental strand*: whilst the other, the *inner* or *lingual*, is the ridge of cells in connection with which the teeth, both temporary and permanent, are developed. Hence it is known as the *dental lamina* or *common dental germ*. It forms a flat band of cells, which grow into the substance of the embryonic jaw, at first horizontally inwards, and then, as the teeth develop, vertically, i.e. upwards in the upper jaw, and downwards in the lower jaw. Whilst still maintaining a horizontal direction, it has two edges: the one, the *attached edge*, which is continuous with the epithelium lining the mouth; the other, the *free edge*, projecting inwards, and embedded in the mesoblastic tissue of the embryonic jaw. Along its line of attachment to the buccal epithelium is a shallow groove, the *dental furrow*.

About the ninth week this dental lamina begins to develop enlargements along its free border. These are ten in number in each jaw, and each one corresponds to a future milk tooth. They consist of masses of epithelial cells; and the cells of the lower part—that is, the part farthest from the margin of the jaw—increase rapidly and spread out in all directions. Each mass thus comes to assume a flask shape, connected by a narrow neck, embraced by mesoblast, with the general epithelial lining of the mouth. They are now known as *special dental germs*. After a time the lower expanded portion, the body of the flask, inclines outwards, so as to form an angle with the superficial constricted portion, which is sometimes known as the *neck* of the special dental germ. About the tenth week the mesoblastic tissue beneath these special dental germs becomes differentiated into papillæ; these grow upwards, and come in contact with the epithelial cells of the special dental germs, which become folded over them like a hood or cap. We have, then, at this stage a papilla or papillæ, which have already begun to assume somewhat the shape of the crown of the future tooth, and from which the dentine and pulp of the milk teeth are formed, surmounted by a dome or cap of epithelial cells, from which the enamel is derived.

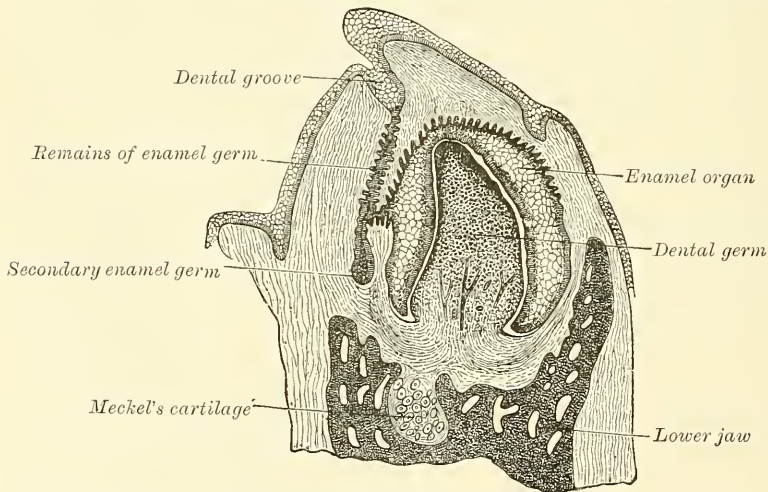
In the meantime, while these changes have been going on, the dental lamina has been extending backwards behind the special dental germ corresponding to the second molar tooth of the temporary set, and at about the seventeenth week it presents an enlargement, the special dental germ for the first permanent molar, soon followed by the formation of a papilla in the mesoblastic tissue for the same tooth. This is followed by a further extension backwards of the dental lamina; the formation of another enlargement and its corresponding papilla about the sixth month after birth for the second molar. And finally the process is repeated for the third molar, its papilla appearing about the fifth year of life.

After the formation of the special dental germs, the dental lamina undergoes atrophic changes and becomes cribriform, except behind and lateral to each of the special germs of the temporary teeth, where it undergoes a local thickening, forming the special dental germ of each of the successional permanent teeth—i.e. the ten anterior ones in each jaw. Here the same process goes on as was



described in connection with those of the milk teeth; that is, they recede into the substance of the gum behind the germs of the temporary teeth. As they recede they become flask-shaped, form an expansion at their distal extremity, and finally meet a papilla, which has been formed in the mesoblast, just in the same manner as was the case in the temporary teeth. The apex of the papilla indentates the dental germ, which encloses it, and forming a cap for it, becomes converted into the enamel, whilst the papilla forms the dentine and pulp of the permanent tooth. The special dental germs consist at first of rounded or polyhedral epithelial cells; after the formation of the papillæ, these cells undergo a differentiation into three classes. Those which are in immediate contact with the papilla become elongated, and form a layer of well-marked and regular columnar epithelium coating the papilla. They are the cells which form the enamel fibres, and are therefore termed *enamel-cells* or *adamantoblasts*. The outer layer of cells of the special dental germ, which are in contact with the inner surface of the dentinal sac, presently to be described, are much shorter, cubical in form, and are named the *external enamel epithelium*. All the intermediate round cells of the dental germ between these two layers undergo a peculiar change. They become stellate in shape and develop processes, which

FIG. 561.—Vertical section of the inferior maxilla of an early human fetus. (Magnified 25 diameters.)



unite to form a network into which fluid is secreted, which has the appearance of a jelly, and to which the name of enamel pulp is given. This transformed special dental germ is now known under the name of *enamel organ*.

While these changes have been going on, a sac is formed around each enamel organ from the mesoblastic tissue around. This is known as the *dentinal sac*, and is a vascular membrane of connective tissue. It grows up from below, and thus encloses the whole tooth germ; as it grows it causes the neck of the enamel organ to atrophy and disappear; so that all communication between the enamel organ and the superficial epithelium is cut off. We have now vascular papillæ surmounted by inverted caps or capsules of epithelial cells, the whole being surrounded by membranous sacs. The cap or capsule consists of an internal layer of cells—the enamel cells or adamantoblasts—in contact with the papilla; of an external layer of cells—the external enamel epithelium—lining the interior of the dentinal sac; and of an intermediate mass of stellate cells, with anastomosing process—the enamel pulp (fig. 562).

*Formation of the enamel.*—The enamel is formed exclusively from the enamel cells or adamantoblasts of the original special dental germ, either by direct calcification of the columnar cell, which becomes elongated into the hexagonal

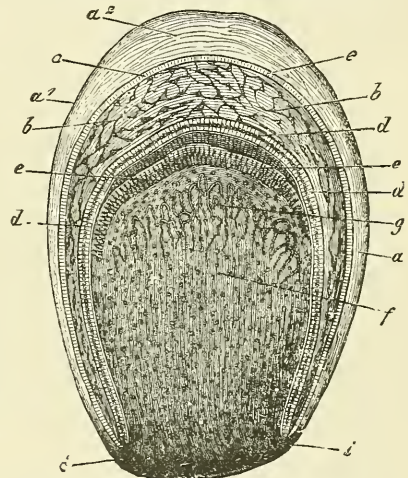


rods of the enamel; or, as is believed by some, as a secretion from the adamantoblasts, within which calcareous matter is subsequently deposited.

The process begins at the apex of each cusp, at the end of the enamel cells, in contact with the dental papilla. Here a fine globular deposit takes place, being apparently shed from the end of the adamantoblasts. It is known by the name of *enamel droplet*, and resembles keratin in its resistance to the action of mineral acids. This droplet then calcifies and forms the first layer of the enamel; a second droplet now appears and calcifies, and so on, successive droplets of keratin-like material are shed from the adamantoblasts and form successive layers of enamel, the adamantoblast gradually receding as each layer is produced, until they have almost disappeared at the termination of the process. The intermediate cells of the enamel pulp atrophy and disappear, so that the newly formed calcified material and the external enamel epithelium come into apposition. This latter layer, however, soon disappears on the emergence of the tooth beyond the gum. After its disappearance the crown of the tooth is still covered by a distinct membrane, which remains persistent for some time. This is known as the *cuticular dentis*, or *Nasmyth's membrane*, and is believed to be the last formed layer of enamel derived from the *adamantoblast*, which has not become calcified. It forms a horny layer, which may be separated from the calcified mass below by the action of strong acids. It is marked by the hexagonal impressions of the enamel prisms, and when stained by nitrate of silver, shows the characteristic appearance of epithelium.

*Formation of the dentine.*—While these changes are taking place in the epithelium to form the enamel, contemporaneous changes are occurring in the differentiated mesoblast of the dental papillæ which result in the formation of the dentine. As before stated, the first germ of the dentine consists in the formation of papillæ, corresponding in number to the teeth, from the soft mesoblastic tissue which bounds the depressions containing the special enamel germ. The papillæ grow upwards into the enamel germ and become covered by it, both being enclosed in a vascular connective tissue, the dental sac, in the manner above described. Each papilla then constitutes the formative pulp from which the dentine and permanent pulp are developed; it consists of rounded cells, and is very vascular, and soon begins to assume the shape of the tooth which is to be developed from it. The next step is the development of the odontoblasts, which have a relation to the development of the teeth similar to that of the osteoblasts in the formation of bone. They are formed first from the cells of the periphery of the papilla—that is to say, from the cells in immediate contact with the adamantoblasts of the special dental germ. These cells become elongated; one end of the elongated cell resting against the epithelium of the special dental germs, the other being tapering and often branched. By the direct transformation of the peripheral end of these cells, or by a secretion from it, a layer of uncalcified matrix is formed which caps the cusp or cusps, if there are more than one, of the papillæ. In this matrix islets of calcification make their appearance, and coalescing form a continuous layer of calcified material, which, capping each cusp, forms the first layer of dentine. The odontoblasts having thus formed the

FIG. 562.—Dental sac of a human embryo at an advanced stage of development. Partly diagrammatic.



a. Wall of the sac, formed of connective tissue, with its outer stratum  $a^1$  and its inner  $a^2$ . b. Enamel organ with its papillary and parietal layer of cells. c, d. The enamel-membrane and enamel-prisms. e. Dentine cells. f. Dental germ and capillaries. g, i. Transition of the wall of the follicle into the tissue of the dental germ.

first layer, retire towards the centre of the papilla, and as they do so form successive layers of dentine from their peripheral extremities—that is to say, they form the dentinal matrix in which calcification subsequently takes place. As they thus retire from the periphery of the papilla, they leave behind them filamentous processes of cell protoplasm, provided with finer side processes; these are surrounded on all sides by calcified material, and thus form the dentinal tubules, and, by their side branches, the anastomosing tubules, whereby the dentinal tubules communicate: the processes of protoplasm contained within them, forming the dentinal fibres (Tomes' fibres) which, as mentioned above, are found within the tubules. In this way the entire thickness of the dentine is formed, each tubule being completed throughout its whole length by a single odontoblast. The central part of the papilla does not undergo calcification; its cells proliferate, nerve fibres are developed in it, and it remains persistent as the pulp of the tooth. In this process of formation of dentine it has been shown that an uncalcified matrix is first formed, and that in this islets of calcification appear, which subsequently blend together to form a cap to each cusp: in like manner a succession of layers become formed, which become ultimately blended with each other. In certain places this blending is not complete, portions of the matrix remaining uncalcified between the successive layers; this gives rise, in the macerated tooth, to little spaces, which are the interglobular spaces alluded to above.

*Formation of the cement.*—The root of the tooth begins to be formed shortly before the crown emerges through the gum, but is not completed until some time afterwards. It is formed by a downward growth of the epithelium of the dental germ, which extends almost as far as the situation of the apex of the future fang, and determines the form of this portion of the tooth. This fold of epithelium is known as the *epithelial sheath*, and on its papillary surface odontoblasts are formed, which in turn form dentine, so that the dentine formation is identical in the crown and root of the tooth. After the dentine of the root has been formed, the vascular tissues of the dental sac begin to break through the epithelial sheath, and spread over the surface of the fang as a layer of bone-forming material. In this osteoblasts form, and the process of ossification goes on identically in the same manner as in the ordinary intra-membranous ossification of bone. In this way the cement is formed, and is simply ordinary bone, containing canaliculi and lacunæ.

*Formation of the alveoli.*—About the fourteenth week of embryonic life the dental lamina becomes enclosed in a trough or groove of mesoblastic tissue, which at first is common to all the dental germs, but subsequently becomes divided, by bony septa, into loculi, each loculus containing the special dental germ of a temporary tooth and its corresponding permanent tooth. After birth each cavity becomes subdivided, so as to form separate loculi (the future alveoli) for the milk tooth and its corresponding permanent tooth. Although at one time the whole of the growing tooth is contained in the cavity of the alveolus, which closely invests it, it never completely encloses it, but there is always an aperture over the top of the crown filled by soft tissue, by which the dental sac is connected with the surface of the gum, and which in the permanent teeth is called the *gubernaculum dentis*.

**Development of the permanent teeth.**—The permanent teeth as regards their development may be divided into two sets: (1) those which replace the temporary teeth, and which, like them, are ten in number; these are the *successional permanent teeth*; and (2) those which have no temporary predecessors, but are superadded at the back of the dental series. These are three in number on either side in each jaw, and are termed *superadded permanent teeth*. They are the three molars of the permanent set, the molars of the temporary set being replaced by the premolars or bicuspidis of the permanent set. The development of the successional permanent teeth—the ten anterior ones in either jaw—will first be considered. As already stated, the original dental lamina, after the



formation of the special dental germs of the temporary teeth, undergoes atrophic changes, except at one spot behind and lateral to each of the special germs of the milk teeth; here a local thickening takes place, and forms the special dental germ of each successional permanent tooth. In this, identically the same changes go on as took place in the special germs of the temporary teeth: they elongate and recede into the gum behind the germs of the milk tooth; a papilla springs up from the mesoblastic tissue to meet them, and the two become enclosed in a dental sac; the formation of the dentine and enamel goes on in the same way as in the temporary teeth. During their development the permanent teeth, enclosed in their sacs, come to be placed behind and at a lower level than the temporary teeth, that is to say, at a further distance from the margin of the future gum, and, as already stated, are separated from it by a bony partition. As the crown of the permanent tooth grows, absorption of this bony partition and of the fang of the temporary tooth takes place, through the agency of osteoblasts; which appear at this time, and finally nothing but the crown of the temporary tooth remains. This is shed or removed, and the permanent tooth takes its place.

The superadded permanent teeth are developed in the manner already described, by extensions backward of the back part of the dental lamina of the immediately preceding tooth. About the seventeenth week, that portion of the common dental germ of the last temporary tooth which lies behind the tooth, and which has remained unaltered, is prolonged backwards, and forms the special dental germ of the first permanent molar, and into this a papilla projects. In a similar manner about the fourth month after birth, a further extension backwards having taken place, a second enlargement occurs, into which a papilla projects about the sixth month, and thus the rudiment of the second molar is formed. Finally a third enlargement takes place, posterior to the other two, for the third molar, and its papilla becomes visible about the fifth year.

*Eruption.*—When the calcification of the different tissues of the tooth is sufficiently advanced to enable it to bear the pressure to which it will be afterwards subjected, its eruption takes place; the tooth making its way through the gum. The gum is absorbed by the pressure of the crown of the tooth against it, which is itself pressed up by the increasing size of the fang. At the same time the septa between the dental sacs, at first fibrous in structure, ossify, and constitute the alveoli; these firmly embrace the necks of the teeth, and afford them a solid basis of support.

The eruption of the temporary teeth commences at the seventh month, and is complete about the end of the second year, those of the lower jaw preceding the upper.

The following, according to C. S. Tomes, is the most usual time of eruption:

Lower central incisors . . . . .	6 to 9 months.
Upper incisors . . . . .	8 to 10 months.
Lower lateral incisors and first molars . . . . .	15 to 21 months.
Canines . . . . .	16 to 20 months.
Second molars . . . . .	20 to 24 months.

Calcification of the permanent teeth proceeds in the following order in the lower jaw; in the upper jaw it takes place a little later:—First molar, soon after birth; the central incisor, lateral incisor, and canine, about six months after birth; the bicuspid, at the second year, or a little later; second molar, end of second year; third molar, about the twelfth year.

The eruption of the permanent teeth takes place at the following periods, the teeth of the lower jaw preceding those of the upper by a short interval:

6 years, first molars.	10th year, second bicuspid.
7th year, two middle incisors.	11th to 12th year, canine.
8th year, two lateral incisors.	12th to 13th year, second molars.
9th year, first bicuspid.	17th to 25th year, wisdom-teeth.



## THE PALATE

The **palate** forms the roof of the mouth: it consists of two portions, the hard palate in front, the soft palate behind.

The **hard palate** is bounded in front and at the sides by the alveolar arches and gums; behind, it is continuous with the soft palate. It is covered by a dense structure formed by the periosteum and mucous membrane of the mouth, which are intimately adherent together. Along the middle line is a linear ridge or raphé, which terminates anteriorly in a small papilla, corresponding with the inferior opening of the anterior palatine fossa. This papilla receives filaments from the naso-palatine and anterior palatine nerves. On either side and in front of the raphé the mucous membrane is thick, pale in colour, and corrugated; behind, it is thin, smooth, and of a deeper colour: it is covered with squamous epithelium, and furnished with numerous glands (palatal glands), which lie between the mucous membrane and the surface of the bone.

The **soft palate** (*velum pendulum palati*) is a movable fold, suspended from the posterior border of the hard palate, and forming an incomplete septum between the mouth and pharynx. It consists of a fold of mucous membrane, enclosing muscular fibres, an aponeurosis, vessels, nerves, adenoid tissue, and mucous glands. When occupying its usual position (i.e. relaxed and pendent), its anterior surface is concave, continuous with the roof of the mouth, and marked by a medium ridge or raphé, which indicates its original separation into two lateral halves. Its posterior surface is convex, and continuous with the mucous membrane covering the floor of the posterior nares. Its upper border is attached to the posterior margin of the hard palate, and its sides are blended with the pharynx. Its lower border is free.

Hanging from the middle of its lower border is a small, conical-shaped, pendulous process, the *uvula*; and arching outwards and downwards from the base of the uvula on each side are two curved folds of mucous membrane, containing muscular fibres, called the *arches* or *pillars of the soft palate*.

The *anterior pillars* run downwards, outwards, and forwards to the sides of the base of the tongue, and are formed by the projection of the Palato-glossi muscles, covered by mucous membrane.

The *posterior pillars* are nearer to each other, and larger than the anterior; they run downwards, outwards, and backwards to the sides of the pharynx, and are formed by the projection of the Palato-pharyngei muscles, covered by mucous membrane. The anterior and posterior pillars are separated below by a triangular interval, in which the tonsil is lodged.

The space left between the arches of the palate on the two sides is called the *isthmus of the fauces*. It is bounded, above, by the free margin of the soft palate; below, by the back of the tongue; and on each side, by the pillars of the soft palate and the tonsil.

The *mucous membrane of the soft palate* is thin, and covered with squamous epithelium on both surfaces, excepting near the orifice of the Eustachian tube, where it is columnar and ciliated.\* Beneath the mucous membrane on the oral surface of the soft palate is a considerable amount of adenoid tissue. The palatine glands form a continuous layer on its posterior surface and round the uvula.

The *aponeurosis of the soft palate* is a thin but firm fibrous layer attached above to the posterior border of the hard palate, and becoming thinner towards the free margin of the velum. Laterally, it is continuous with the pharyngeal aponeurosis. It forms the framework of the soft palate, and is joined by the tendon of the Tensor palati muscle.

\* According to Klein, the mucous membrane on the nasal surface of the soft palate is in the fetus covered throughout by columnar ciliated epithelium, and some anatomists state that it is covered with columnar ciliated epithelium, except at its free margin, throughout life.

The *muscles of the soft palate* are five on each side: the Levator palati, Tensor palati, Azygos uvulæ, Palato-glossus, and Palato-pharyngeus (see page 420). The following is the relative position of these structures in a dissection of the soft palate from the posterior or nasal to the anterior or oral surface. Immediately beneath the nasal mucous membrane is a thin stratum of muscular fibres, the posterior fasciculus of the Palato-pharyngeus muscle, joining with its fellow of the opposite side in the middle line. Beneath this is the Azygos uvulæ, consisting of two rounded fleshy fasciculi, placed side by side in the median line of the soft palate. Next comes the aponeurosis of the Levator palati joining with the muscle of the opposite side in the middle line. Fourthly, the anterior fasciculus of the Palato-pharyngeus, thicker than the posterior, and separating the Levator palati from the next muscle, the Tensor palati. This muscle terminates in a tendon which, after winding round the hamular process, expands into a broad aponeurosis in the soft palate, anterior to the other muscles which have been enumerated. Finally we have a thin muscular stratum, the Palato-glossus muscle, placed in front of the aponeurosis of the Tensor palati, and separated from the oral mucous membrane by adenoid tissue.

The **tonsils** (*amygdalæ*) are two prominent bodies situated one on each side of the fauces, between the anterior and posterior pillars of the soft palate. They are of a rounded form, and vary considerably in size in different individuals. Externally the tonsil is in relation with the inner surface of the Superior constrictor, which separates it from the internal carotid and ascending pharyngeal arteries. It corresponds to the angle of the lower jaw. Its *inner surface* presents from twelve to fifteen orifices, leading into small recesses, from which numerous follicles branch out into the substance of the gland. These follicles are lined by a continuation of the mucous membrane of the pharynx, covered with epithelium; around each follicle is a layer of closed capsules embedded in the submucous tissue. These capsules are analogous to those of Peyer's glands, consisting of adenoid tissue. No openings from the capsules into the follicles can be recognised. They contain a thick greyish secretion. Surrounding each follicle is a close plexus of lymphatic vessels. From these plexuses the lymphatic vessels pass to the deep cervical glands in the upper part of the neck, which frequently become enlarged in affections of these organs.

The *arteries* supplying the tonsil are the dorsalis linguæ from the lingual, the ascending palatine and tonsillar from the facial, the ascending pharyngeal from the external carotid, the descending palatine branch of the internal maxillary, and a twig from the small meningeal.

The *veins* terminate in the tonsillar plexus, on the outer side of the tonsil.

The *nerves* are derived from Meckel's ganglion, and from the glosso-pharyngeal.

#### THE SALIVARY GLANDS (fig. 563)

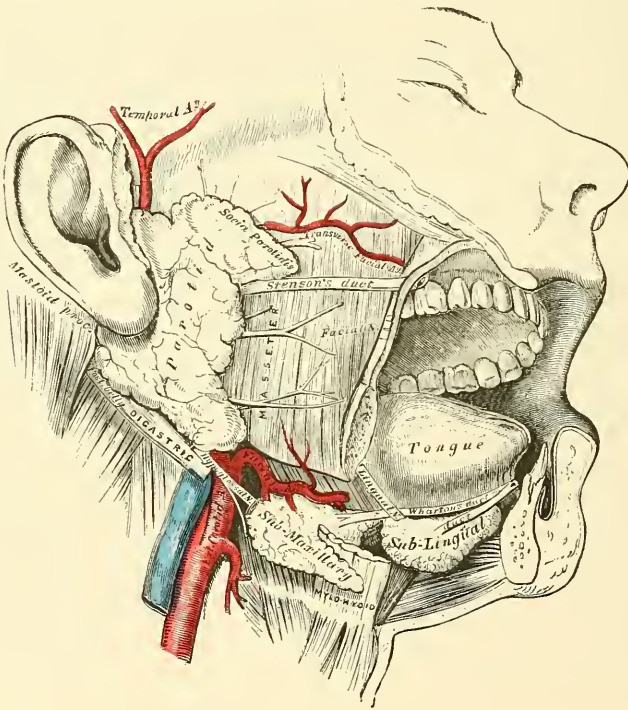
The principal salivary glands communicating with the mouth, and pouring their secretion into its cavity, are the parotid, submaxillary, and sublingual.

The **parotid gland**, so called from being placed near the ear (*παρά*, near; *ὄψ*, *ὄρος*, the ear), is the largest of the three salivary glands, varying in weight from half an ounce to an ounce. It lies upon the side of the face, immediately below and in front of the external ear. It is limited above by the zygoma; below, by the angle of the jaw, and by a line drawn between it and the mastoid process; anteriorly, it extends to a variable extent over the Masseter muscle; posteriorly, it is bounded by the external meatus, the mastoid process, and the Sterno-mastoid and Digastric muscles, slightly overlapping the latter.

Its *anterior surface* is grooved to embrace the posterior margin of the ramus of the lower jaw, and advances forwards beneath the ramus, between the two Pterygoid muscles and in front of the ramus over the Masseter muscle. Its *outer surface*, slightly lobulated, is covered by the integument and parotid fascia,

and has one or two lymphatic glands resting on it. Its *inner surface* extends deeply into the neck, by means of two large processes, one of which dips behind the styloid process, and projects beneath the mastoid process and the Sternomastoid muscle; the other is situated in front of the styloid process, and passes into the back part of the glenoid fossa, behind the articulation of the lower jaw. The structures passing through the parotid gland are, the external carotid artery, giving off its three terminal branches: the posterior auricular artery emerges from the gland behind; the temporal artery above; the transverse facial, a branch of the temporal, in front; and the internal maxillary winds through it as it passes inwards, behind the neck of the jaw. Superficial to the external carotid is the trunk formed by the union of the temporal and internal maxillary veins: a branch, connecting this trunk with the internal jugular, also passes through the gland. It is also traversed by the facial nerve and its branches, which emerge at its anterior border; branches of the great auricular nerve pierce the gland to join

FIG. 563.--The salivary glands.



the facial, and the auriculo-temporal branch of the inferior maxillary nerve emerges from the upper part of the gland. The internal carotid artery and internal jugular vein lie close to its deep surface.

The **duct of the parotid gland** (*Stenson's*) is about two inches and a half in length. It commences by numerous branches from the anterior part of the gland, crosses the Masseter muscle, and at its anterior border dips down into the substance of the Buccinator muscle, which it pierces; it then runs for a short distance obliquely forwards between the Buccinator and mucous membrane of the mouth, and opens upon the inner surface of the cheek by a small orifice, opposite the second molar tooth of the upper jaw. While crossing the Masseter, it receives the duct of a small detached portion of the gland, *socia parotidis*, which occasionally exists as a separate lobe, just beneath the zygomatic arch. In this position it has the transverse facial artery above it and some branches of the facial nerve below it.



**Structure.**—The parotid duct is dense, of considerable thickness, and its canal about the size of a crow-quill ; it consists of an external or fibrous coat, of considerable density, containing contractile fibres, and of an internal or mucous coat lined with short columnar epithelium.

**Surface Form.**—The direction of the duct corresponds to a line drawn across the face about a finger's breadth below the zygoma, that is, from the lower margin of the concha to midway between the free margin of the upper lip and the ala of the nose.

**Vessels and Nerves.**—The *arteries* supplying the parotid gland are derived from the external carotid, and from the branches given off by that vessel in or near its substance. The *veins* empty themselves into the external jugular, through some of its tributaries. The *lymphatics* terminate in the superficial and deep cervical glands, passing in their course through two or three lymphatic glands, placed on the surface and in the substance of the parotid. The *nerves* are derived from the plexus of the sympathetic on the external carotid artery, the facial, the auriculo-temporal, and great auricular nerves.

It is probable that the branch from the auriculo-temporal nerve is derived from the glosso-pharyngeal through the otic ganglion (see page 794). At all events in some of the lower animals this has been proved experimentally to be the case.

The **submaxillary gland** is situated below the jaw, in the anterior part of the submaxillary triangle of the neck. It is irregular in form, and weighs about two drachms. It is covered by the integument, Platysma, deep cervical fascia, and the body of the lower jaw, corresponding to a depression on the inner surface of that bone ; and lies upon the Mylo-hyoid, Hyo-glossus, and Stylo-glossus muscles, a portion of the gland passing beneath the posterior border of the Mylo-hyoid. In front of it is the anterior belly of the Digastric ; behind it is separated from the parotid gland by the stylo-maxillary ligament, and from the sublingual gland in front by the Mylo-hyoid muscle. The facial artery lies embedded in a groove in its posterior and upper border.

The **duct of the submaxillary gland** (*Wharton's*) is about two inches in length, and its walls are much thinner than those of the parotid duct. It commences by numerous branches from the deep portion of the gland which lies on the upper surface of the Mylo-hyoid muscle, and passes forwards and inwards between the Mylo-hyoid and the Hyo-glossus and Genio-hyo-glossus muscles, then between the sublingual gland and the Genio-hyo-glossus, and opens by a narrow orifice on the summit of a small papilla, at the side of the frænum linguæ. On the Hyo-glossus muscle it lies between the lingual and hypoglossal nerves, but at the anterior border of the muscle it crosses under the lingual nerve, and is then placed above it.

**Vessels and Nerves.**—The *arteries* supplying the submaxillary gland are branches of the facial and lingual. Its *veins* follow the course of the arteries. The *nerves* are derived from the submaxillary ganglion, through which it receives filaments from the chorda tympani of the facial and lingual branch of the inferior maxillary, sometimes from the mylo-hyoid branch of the inferior dental, and from the sympathetic.

The **sublingual gland** is the smallest of the salivary glands. It is situated beneath the mucous membrane of the floor of the mouth, at the side of the frænum linguæ, in contact with the inner surface of the lower jaw, close to the symphysis. It is narrow, flattened, in shape somewhat like an almond, and weighs about a drachm. It is in relation, *above*, with the mucous membrane ; *below*, with the Mylo-hyoid muscle ; *in front*, with the depression on the side of the symphysis of the lower jaw, and with its fellow of the opposite side ; *behind*, with the deep part of the submaxillary gland ; and *internally*, with the Genio-hyo-glossus, from which it is separated by the lingual nerve and Wharton's duct. Its excretory ducts (*ducts of Rivini*), from eight to twenty in number, open separately into the mouth, on the elevated crest of mucous membrane, caused by the projection of the gland, on either side of the frænum linguæ. One or more join to

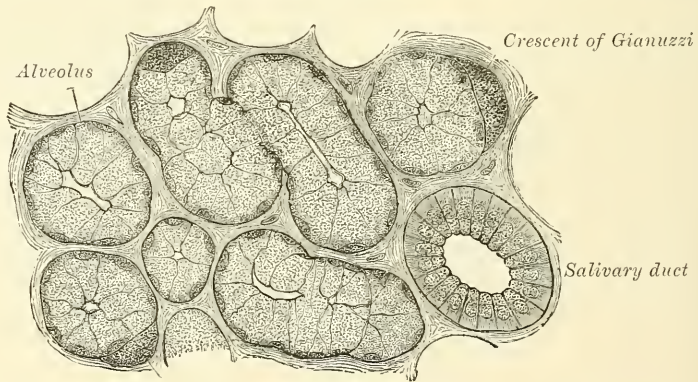
form a tube, which opens into the Whartonian duct; this is called the *duct of Bartholin*.

**Vessels and Nerves.**—The sublingual gland is supplied with blood from the sublingual and submental arteries. Its nerves are derived from the lingual.

**Structure of Salivary Glands.**—The salivary are compound racemose glands, consisting of numerous lobes, which are made up of smaller lobules, connected together by dense areolar tissue, vessels, and ducts. Each lobule consists of the ramifications of a single duct, 'branching frequently in a tree-like manner,' the branches terminating in dilated ends or alveoli on which the capillaries are distributed. These alveoli, however, as Pflüger points out, are not necessarily spherical, though sometimes they assume that form; sometimes they are perfectly cylindrical, and very often they are mutually compressed. The alveoli are enclosed by a basement membrane, which is continuous with the *membrana propria* of the duct. It presents a peculiar reticulated structure, having the appearance of a basket with open meshes, and consisting of a network of branched and flattened nucleated cells.

The alveoli of the salivary glands are of two kinds, which differ both in the appearance of their secreting cells, in their size, and in the nature of their secretion. The one variety secretes a ropy fluid, which contains mucin, and has therefore been named the *mucous*; whilst the other secretes a thinner and

FIG. 564.—A highly magnified section of the submaxillary gland of the dog, stained with carmine. (Kölliker.)



more watery fluid, which contains serum-albumin, and has been named *serous* or *albuminous*. The sublingual gland may be regarded as an example of the former variety: the parotid of the latter. The submaxillary is of the mixed variety, containing both mucous and serous alveoli, the latter, however, preponderating.

Both alveoli are lined by cells, and it is by the character of these cells that the nature of the gland is chiefly to be determined. In addition, however, the alveoli of the serous glands are smaller than those of the mucous ones.

The cells in the mucous alveoli are spheroidal in shape, glassy, transparent, and dimly striated in appearance. The nucleus is usually situated in the part of the cell which is next the basement membrane, against which it is sometimes flattened. The most remarkable peculiarity presented by these cells is, that they give off an extremely fine process, which is curved in a direction parallel to the surface of the alveolus, lies in contact with the *membrana propria*, and overlaps the processes of neighbouring cells. The cells contain a quantity of mucin, to which their clear, transparent appearance is due.

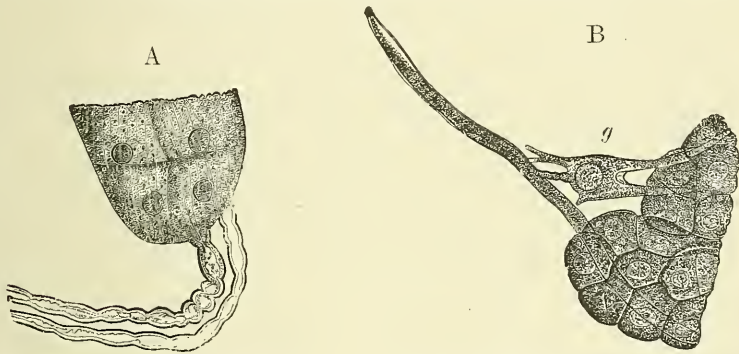
Here and there in the alveoli are seen peculiar half-moon-shaped bodies, lying between the cells and the *membrana propria* of the alveolus. They are termed the *crescents of Gianuzzi*, or the *demilunes of Heidenhain* (fig. 564), and are regarded by Pflüger as due to post-mortem change, but by most other later observers



they are believed to be composed of polyhedral granular cells, which Heidenhain regards as young epithelial cells destined to supply the place of those salivary cells which have undergone disintegration. This view, however, is not accepted by Klein.

**Serous alveoli.**—In the serous alveoli the cells almost completely fill the cavity, so that there is hardly any lumen perceptible. Instead of presenting the clear transparent appearance of the cells of the mucous alveoli, they present a granular appearance, due to distinct granules, of an albuminous nature, embedded in a closely reticulated protoplasm. The ducts which originate out of the alveoli are lined at their commencement by epithelium which differs little from the pavement type. As the ducts enlarge, the epithelial cells change to the columnar type, and they are described by Pflüger as attached to the basement membrane by a brush of fine hair-like processes, which he believes to be continuous with the nerve-fibres. Other anatomists regard these cells as merely striated on their deep surface. The lobules of the salivary glands are richly supplied with blood-vessels which form a dense network in the interalveolar spaces. Fine plexuses of nerves are also found in the interlobular tissue. Pflüger describes the nerves as being directly continuous with the salivary cells of the alveolus, the nerve sometimes passing through a ganglion-cell just before joining the alveolus (fig. 565 A and B). This fact has not, however, been corroborated by other observers.

FIG. 565.—Illustrating Pflüger's views of the termination of the nerves in the alveolar cells. (From Stricker's 'Handbook.')



A. Direct passage of nerve into a salivary cell.

B. By the medium of a multipolar ganglion-cell, *g*.

There is no doubt that ganglia are to be found in some salivary glands in connection with the nerve-plexuses in the interlobular tissue; thus they are to be found in the submaxillary, but not in the parotid; but whether the ultimate fibrils are connected with the salivary cells, as asserted by Pflüger, remains to be proved.

In the submaxillary and sublingual glands the lobes are larger and more loosely united than in the parotid.

**Mucous Glands.**—Besides the salivary glands proper, numerous other glands are found in the mouth. They appear to secrete mucus only, which serves to keep the mouth moist during the intervals of the salivary secretion, and which is mixed with that secretion in swallowing. Many of these glands are found at the posterior part of the dorsum of the tongue, behind the circumvallate papillæ, and also along its margins as far forward as the apex.\* Others lie around and in the tonsil between its crypts, and a large number in the soft palate. These glands are of the ordinary compound racemose type.

\* It has recently been shown by Ebner that many of these glands open into the trenches around the circumvallate papillæ, and that their secretion is more watery than that of ordinary mucous glands. He supposes that they assist in the more rapid distribution of the substance to be tasted over the region where the special apparatus of the sense of taste is situated.



*Surface Form.*—The orifice of the mouth is bounded by the lips: two thick, fleshy folds covered externally by integument and internally by mucous membrane, and consisting of muscles, vessels, nerves, areolar tissue, and numerous small glands. The size of the orifice of the mouth varies considerably in different individuals, but seems to bear a close relation to the size and prominence of the teeth. Its corners correspond pretty accurately to the outer border of the canine teeth. In the Mongolian tribes, where the front teeth are large and inclined forward, the mouth is large; and this, combined with the thick and everted lips, which appear to be associated with prominent teeth, gives to the Negro's face much of the peculiarity by which it is characterised. The smaller teeth, and the slighter prominence of the alveolar arch of the more highly civilised races, render the orifice of the mouth much smaller, and thus a small mouth is an indication of intelligence, and is regarded as an evidence of the higher civilisation of the individual.

Upon looking into the mouth, the first thing we may note is the tongue, the upper surface of which will be seen occupying the floor of the cavity. This surface is convex, and is marked along the middle line by a raphé, which divides it into two symmetrical portions. The anterior two-thirds is rough and studded with papillæ; the posterior third smooth and tuberculated, covered by numerous glands which project from the surface. Upon raising the tongue, the mucous membrane which invests the upper surface may be traced covering the sides of the under surface and then reflected over the floor of the mouth on to the inner surface of the lower jaw, a part of which it covers. As it passes over the borders of the tongue it changes its character, becoming thin and smooth, and losing the papillæ which are to be seen on the upper surface. In the middle line the mucous membrane on the under surface of the tip of the tongue forms a distinct fold, the *frænum lingue*, by which this organ is connected to the symphysis of the jaw. Occasionally it is found that this frænum is rather shorter than natural, and, acting as a bridle, prevents the complete protrusion of the tongue. When this condition exists and an attempt is made to protrude the organ, the tip will be seen to remain buried in the floor of the mouth, and the dorsum of the tongue is rendered very convex, and more or less extruded from the mouth: at the same time a deep furrow will be noticed to appear in the middle line of the anterior part of the dorsum. Sometimes, a little external to the frænum, the maxillary vein may be seen immediately beneath the mucous membrane. The corresponding artery, being more deeply placed, does not come into view, nor can its pulsation be felt with the finger. On either side of the frænum, in the floor of the mouth, is a longitudinal elevation or ridge, produced by the projection of the sublingual gland, which lies immediately beneath the mucous membrane. And close to the attachment of the frænum to the tip of the tongue may be seen on either side the slit-like orifices of Wharton's ducts, into which a fine probe may be passed without much difficulty. By everting the lips the smooth mucous membrane lining them may be examined, and may be traced from them on to the outer surface of the alveolar arch. In the middle line, both of the upper and lower lip, a small fold of mucous membrane passes from the lip to the bone, constituting the *fræna*; these are not so large as the frænum lingue. By pulling outwards the angle of the mouth the mucous membrane lining the cheeks can be seen, and on it may be perceived a little papilla which marks the position of the orifice of Stenson's duct—the duct of the parotid gland. The exact position of the orifice of the duct will be found to be opposite the second molar tooth of the upper jaw. The introduction of a probe into this duct is attended with considerable difficulty. The teeth are the next objects which claim our attention upon looking into the mouth. There are, as stated above, ten in either jaw in the temporary set, and sixteen in the permanent set. The gums, in which they are implanted, are dense, firm, and vascular.

At the back of the mouth is seen the *isthmus of the fauces*, or, as it is popularly called, 'the throat': this is the space between the pillars of the fauces on either side, and is the means by which the mouth communicates with the pharynx. Above, it is bounded by the soft palate, the anterior surface of which is concave and covered with mucous membrane, which is continuous with that lining the roof of the mouth. Projecting from the middle of its lower border is a conical-shaped projection, the *uvula*. On either side of the isthmus of the fauces are the anterior and posterior pillars, formed by the Palato-glossus and Palato-pharyngeus muscles respectively, covered over by mucous membrane. Between the two pillars on either side is situated the tonsil. The extirpation of this body is not unattended with danger of hæmorrhage. Dr. Weir has stated that he believes that when hæmorrhage occurs after their removal, it arises from one of the palatine arteries having been wounded. These vessels are large: they lie in the muscular tissue of the palate, and when wounded are constantly exposed to disturbance from the contraction of the palatine muscles. The vessels of the tonsil, Dr. Weir states, are small, and lie in the soft tissue, and readily contract when wounded.

When the mouth is wide open a prominent tense fold of mucous membrane may be seen and felt extending upwards and backwards from the position of the fang of the last molar tooth to the posterior part of the hard palate. This is caused by the Pterygo-maxillary ligament which is attached by one extremity to the apex of the internal pterygoid plate, and by the other to the posterior extremity of the mylo-hyoid ridge of the lower jaw. It connects the Buccinator with the Superior constrictor of the pharynx. The fang of the last molar tooth indicates the position of the lingual (gustatory) nerve, where it is easily

accessible, and can with readiness be divided in cases of cancer of the tongue (see page 795). On the inner side of the last molar tooth we can feel the hamular process of the internal pterygoid plate of the sphenoid bone, around which the tendon of the Tensor palati plays. The exact position of this process is of importance in performing the operation of staphyloplasty. About one-third of an inch in front of the hamular process and the same distance directly inwards from the last molar tooth is the situation of the opening of the posterior palatine canal, through which emerges the posterior or descending palatine branch of the internal maxillary artery, and one of the descending palatine nerves from Meckel's ganglion. The exact position of the opening on the subject may be ascertained by driving a needle through the tissues of the palate in this situation, when it will be at once felt to enter the canal. The artery emerging from the opening runs forwards in a groove in the bone, just internal to the alveolar border of the hard palate, and may be wounded in the operation for the cure of cleft palate. Under these circumstances the palatine canal may require plugging. By introducing the finger into the mouth the anterior border of the coronoid process of the jaw can be felt, and is especially prominent when the jaw is dislocated. By throwing the head well back a considerable portion of the posterior wall of the pharynx may be seen through the isthmus faucium, and on introducing the finger the anterior surfaces of the bodies of the upper cervical vertebræ may be felt immediately beneath the thin muscular stratum forming the wall of the pharynx. The finger can be hooked round the posterior border of the soft palate, and by turning it forwards, the posterior nares, separated by the septum, can be felt, or the presence of any adenoid or other growths in the naso-pharynx ascertained.

### THE PHARYNX

The **pharynx** is that part of the alimentary canal which is placed behind the nose, mouth, and larynx. It is a musculo-membranous sac, somewhat conical in form, with the base upwards, and the apex downwards, extending from the under surface of the skull to the cricoid cartilage in front, and the intervertebral disc between the fifth and sixth cervical vertebræ behind.

The pharynx is about four inches and a half in length, and broader in the transverse than in the antero-posterior diameter. Its greatest breadth is opposite the cornua of the hyoid bone; its narrowest point at its termination in the œsophagus. It is limited, *above*, by the body of the sphenoid and basilar process of the occipital bone; *below*, it is continuous with the œsophagus; *posteriorly*, it is connected by loose areolar tissue with the cervical portion of the vertebral column, and the Longi colli and Recti capitis antici muscles; *anteriorly*, it is incomplete, and is attached in succession to the internal pterygoid plate, the pterygo-maxillary ligament, the lower jaw, the tongue, hyoid bone, and thyroid and cricoid cartilages; *laterally*, it is connected to the styloid processes and their muscles, and is in contact with the common and internal carotid arteries, the internal jugular veins, and the glosso-pharyngeal, pneumogastric, hypoglossal, and sympathetic nerves, and above with a small part of the Internal pterygoid muscles.

It has seven openings communicating with it: the two posterior nares, the two Eustachian tubes, the mouth, larynx, and œsophagus.

The *posterior nares* are the two oval openings (see page 204) situated at the upper part of the anterior wall of the pharynx.

The *two Eustachian tubes* open one at each side of the upper part of the pharynx, at the back part of the inferior meatus. Below the posterior nares are the posterior surface of the soft palate and uvula, the large aperture of the mouth, the base of the tongue, the epiglottis, and the cordiform opening of the larynx.

The *œsophageal opening* is the lower contracted portion of the pharynx.

**Structure.**—The pharynx is composed of three coats: mucous, fibrous, and muscular.

The *pharyngeal aponeurosis*, or *fibrous coat*, is situated between the mucous and muscular layers. It is thick above where the muscular fibres are wanting, and is firmly connected to the basilar process of the occipital and petrous portion of the temporal bones. As it descends it diminishes in thickness, and is gradually lost. It is strengthened posteriorly by a strong fibrous band, which is attached above to the pharyngeal spine on the under surface of the basilar portion of the



occipital bone, and passes downwards, forming a median raphé, which gives attachment to the Constrictor muscles of the pharynx.

The *mucous coat* is continuous with that lining the Eustachian tubes, the nares, the mouth, and the larynx. It is covered by columnar ciliated epithelium, as low down as on a level with the floor of the nares: below that point the epithelium is of the squamous variety. Beneath the mucous membrane are found racemose mucous glands; they are especially numerous at the upper part of the pharynx around the orifices of the Eustachian tubes. Throughout the pharynx are also numerous crypts or recesses, the walls of which are surrounded by lymphoid tissue, similar to what is found in the tonsils. Across the back part of the pharyngeal cavity, between the two Eustachian tubes, a considerable mass of this tissue exists, and has been named the *pharyngeal tonsil*. Above this in the middle line is an irregular, flask-shaped depression of the mucous membrane, extending up as far as the basilar process of the occipital bone. It is known as the *bursa pharyngea*, and was regarded by Luschka as the remains of the diverticulum of the alimentary canal, which is concerned in the development of the pituitary body (see page 94). Other anatomists believe that it is connected with the formation of the pharyngeal tonsils. In addition to this recess of the mucous membrane there are to be seen two others in the pharynx: one between the Eustachian tube and the posterior wall of the pharynx, the other above the tonsil. These are regarded as the remains of the upper and lower part of the second visceral cleft respectively, the Eustachian tube being formed from the first cleft.

The *muscular coat* has been already described (page 418).

*Surgical Anatomy.*—The internal carotid artery is in close relation with the pharynx, so that its pulsations can be felt through the mouth. It has been occasionally wounded by sharp-pointed instruments, introduced into the mouth and thrust through the wall of the pharynx. In aneurism of this vessel in the neck; the tumour necessarily bulges into the pharynx, as this is the direction in which it meets with the least resistance, nothing lying between the vessel and the mucous membrane except the thin Constrictor muscle, whereas on the outer side there is the dense cervical fascia, the muscles descending from the styloid process and the margin of the Sterno-mastoid.

The mucous membrane of the pharynx is very vascular, and is often the seat of inflammation, frequently of a septic character, and dangerous on account of its tendency to spread to the larynx. On account of the tissue which surrounds the pharyngeal wall being loose and lax, the inflammation is liable to spread through it far and wide, extending downwards into the posterior mediastinum along the œsophagus. Abscess may form in the connective tissue behind the pharynx, between it and the vertebral column, constituting what is known as post-pharyngeal abscess. This is most commonly due to caries of the cervical vertebræ; but may also be caused by suppuration of a lymphatic gland, which is situated in this position opposite the axis, and which receives lymphatics from the nares; by a gumma; or by acute pharyngitis. The abscess may be most easily evacuated by an incision, with a guarded bistoury, through the mouth. It has recently been proposed to open the abscess aseptically by an incision in the neck behind the Sterno-mastoid. The operation, however, is a difficult one, unless the abscess is pointing laterally and does not give such free access to the seat of disease for the removal of necrosed bone, if any exists, and does not appear to present sufficient advantages to warrant its performance.

Foreign bodies not unfrequently become lodged in the pharynx, and most usually at its termination at about the level of the cricoid cartilage, just beyond the reach of the finger, as the distance from the arch of the teeth to the commencement of the œsophagus is about six inches.

The position of the opening of the Eustachian tubes should be carefully studied with a view to catheterism of these tubes, and the student should practise passing a catheter into them. This is to be done by introducing the instrument through the anterior nares, so that its point rests on the floor of the nasal cavity close to the septum; it is then pushed gradually and slowly backwards until the posterior wall of the pharynx is reached. Then, having been slightly withdrawn so as to free the point from the wall of the pharynx, it is rotated outwards and upwards, so that the ring of the instrument is turned towards the external ear, and it can then be made to glide into the Eustachian tube.

## THE ŒSOPHAGUS

The *œsophagus*, or *gullet*, is a muscular canal, about nine inches in length, extending from the pharynx to the stomach. It commences at the upper border



of the cricoid cartilage, opposite the intervertebral disc between the fifth and sixth cervical vertebræ, descends along the front of the spine, through the posterior mediastinum, passes through the Diaphragm, and, entering the abdomen, terminates at the cardiac orifice of the stomach, opposite the tenth dorsal vertebra or the intervertebral disc between the tenth and eleventh dorsal vertebræ. The general direction of the œsophagus is vertical; but it presents two or three slight curves in its course. At its commencement it is placed in the median line; but it inclines to the left side as far as the root of the neck, gradually passes to the middle line again, and finally again deviates to the left as it passes forwards to the œsophageal opening of the Diaphragm. The œsophagus also presents an antero-posterior flexure, corresponding to the curvature of the cervical and thoracic portions of the spine. It is the narrowest part of the alimentary canal, being most contracted at its commencement, and at the point where it passes through the Diaphragm.

**Relations.**—*In the neck*, the œsophagus is in relation, *in front*, with the trachea; and, at the lower part of the neck, where it projects to the left side, with the thyroid gland and thoracic duct; *behind*, it rests upon the vertebral column and Longi colli muscles; *on each side*, it is in relation with the common carotid artery (especially the left, as it inclines to that side), and part of the lateral lobes of the thyroid gland; the recurrent laryngeal nerves ascend between it and the trachea.

*In the thorax*, it is at first situated a little to the left of the median line; it then passes behind the left side of the aortic arch, and descends in the posterior mediastinum, along the right side of the aorta, nearly to the Diaphragm, where it passes in front and a little to the left of the artery, previous to entering the abdomen. It is in relation, *in front*, with the trachea, the arch of the aorta, left carotid, and left subclavian arteries, the left bronchus, and the posterior surface of the pericardium; *behind*, it rests upon the vertebral column, the Longi colli muscles, and the intercostal vessels; and below, near the Diaphragm, upon the front of the aorta; *laterally*, it comes in contact with both pleuræ, especially with the left pleura above and the right pleura below: the vena azygos major lies on the right, and the descending aorta on the left side. The pneumogastric nerves descend in close contact with it, the right nerve passing down behind, and the left nerve in front of it.

**Structure.**—The œsophagus has three coats: an external or muscular; a middle or areolar; and an internal or mucous coat.

The *muscular coat* is composed of two planes of fibres of considerable thickness: an external longitudinal, and an internal circular.

The *longitudinal fibres* are arranged, at the commencement of the tube, in three fasciculi: one in front, which is attached to the vertical ridge on the posterior surface of the cricoid cartilage; and one at each side, which is continuous with the fibres of the inferior constrictor: as they descend they blend together, and form a uniform layer, which covers the outer surface of the tube.

Accessory slips of muscular fibres are described by Dr. Cunningham as passing between the œsophagus and the pleura, where it covers the thoracic aorta (almost always), or the root of the left bronchus (usually), or the back of the pericardium, or corner of the mediastinum (more rarely), as well as other still more rare accessory fibres. In fig. 566, taken from a dissection in the Museum of the Royal College of Surgeons, several of these accessory slips may be seen passing from the œsophagus to the pleura, and two slips to the back of the trachea just above its bifurcation.

The *circular fibres* are continuous above with the Inferior constrictor; their direction is transverse at the upper and lower parts of the tube, but oblique in the central part.

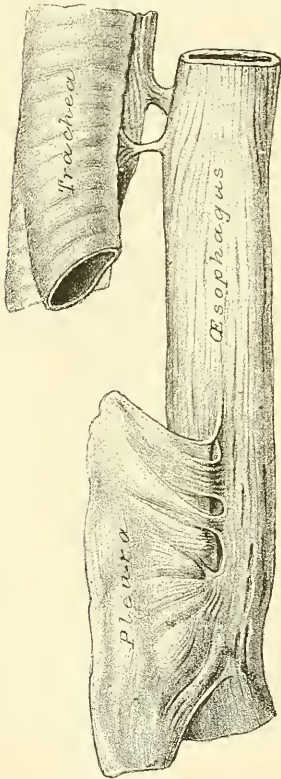
The muscular fibres in the upper part of the œsophagus are of a red colour, and consist chiefly of the striped variety; but below, they consist for the most part of involuntary muscular fibre.

The *areolar coat* connects loosely the mucous and muscular coats.

The *mucous coat* is thick, of a reddish colour above, and pale below. It is disposed in longitudinal folds, which disappear on distension of the tube. Its surface is studded with minute papillæ, and it is covered throughout with a thick layer of stratified pavement epithelium. Beneath the mucous membrane, between it and the areolar coat, is a layer of longitudinally arranged non-stripped muscular fibres. This is the *muscularis mucosæ*. At the commencement it is absent, or only represented by a few scattered bundles; lower down it forms a considerable stratum.

The *œsophageal glands* are numerous small compound racemose glands scattered throughout the tube: they are lodged in the submucous tissue, and open upon the surface by a long excretory duct. They are most numerous at the lower part of the tube, where they form a ring round the cardiac orifice.

FIG. 566.—Accessory muscular fibres between the œsophagus and pleura, and œsophagus and trachea. (From a preparation in the Museum of the Royal College of Surgeons.)



**Vessels of the œsophagus.**—The arteries supplying the œsophagus are derived from the inferior thyroid branch of the thyroid axis of the subclavian; from the descending thoracic aorta, and from the gastric branch of the cœliac axis from the abdominal aorta. They have for the most part a longitudinal direction.

**Nerves of the œsophagus.**—The nerves are derived from the pneumogastric and from the sympathetic; they form a plexus, in which are groups of ganglion-cells, between the two layers of the muscular coats, and also a second plexus in the submucous tissue.

**Surgical Anatomy.**—The relations of the œsophagus are of considerable practical interest to the surgeon, as he is frequently required, in cases of stricture of this tube, to dilate the canal by a bougie, when it is of importance that the direction of the œsophagus, and its relations to surrounding parts, should be remembered. In cases of malignant disease of the œsophagus, where its tissues have become softened from infiltration of the morbid deposit, the greatest care is requisite in directing the bougie through the strictured part, as a false passage may easily be made, and the instrument may pass into the mediastinum, or into one or the other pleural cavity, or even into the pericardium.

The student should also remember that contraction of the œsophagus, and consequent symptoms of stricture, are occasionally produced by an aneurism of some part of the aorta pressing upon this tube. In such a case, the passage of a bougie could only hasten the fatal issue.

In passing a bougie the left forefinger should be introduced into the mouth, and the epiglottis felt for, care being taken not to throw the head too far backwards. The bougie is then to be passed beyond the finger until it touches the posterior wall of the pharynx.

The patient is now asked to swallow, and at the moment of swallowing the bougie is passed gently onwards, all violence being carefully avoided.

It occasionally happens that a foreign body becomes impacted in the œsophagus, which can neither be brought upwards nor moved downwards. When all ordinary means for its removal have failed, excision is the only resource. This, of course, can only be performed when it is not very low down. If the foreign body is allowed to remain, extensive inflammation and ulceration of the œsophagus may ensue. In one case the foreign body ultimately penetrated the intervertebral substance, and destroyed life by inflammation of the membranes and substance of the cord.

The operation of œsophagotomy is thus performed. The patient being placed upon his back, with the head and shoulders slightly elevated, an incision, about four inches in length, should be made on the left side of the trachea, from the thyroid cartilage downwards, dividing the skin and Platysma. The edges of the wound being separated, the Omo-hyoid



muscle should, if necessary, be divided, and the fibres of the Sterno-hyoid and Sterno-thyroid muscles drawn inwards; the sheath of the carotid vessels, being exposed, must be drawn outwards, and retained in that position by retractors: the œsophagus will now be exposed, and should be divided over the foreign body, which can then be removed. Great care is necessary to avoid wounding the thyroid vessels, the thyroid gland, and the laryngeal nerves.

The œsophagus may be obstructed not only by foreign bodies, but also by changes in its coats, producing stricture, or by pressure on it from without of new growths or aneurism, etc.

The different forms of stricture are: (1) the spasmodic, usually occurring in nervous women, and intermittent in character, so that the dysphagia is not constant; (2) fibrous, due to cicatrization after injuries, such as swallowing corrosive fluids or boiling water; and (3) malignant, usually epitheliomatous in its nature. This is situated generally either at the upper end of the tube, opposite the cricoid cartilage, or at its lower end at the cardiac orifice, but is also occasionally found at that part of the tube where it is crossed by the left bronchus.

The operation of œsophagostomy has occasionally been performed in cases where the stricture in the œsophagus is at the upper part, with a view to making a permanent opening below the stricture through which to feed the patient, but the operation has been far from a successful one, and the risk of setting up diffuse inflammation in the loose planes of connective tissue deep in the neck is so great that it would appear to be better, if any operative interference is undertaken, to perform gastrostomy. The operation is performed in the same manner as œsophagotomy, but the edges of the opening in the œsophagus are stitched to the skin incision.

## THE ABDOMEN

The **Abdomen** is the largest cavity in the body. It is of an oval form, the extremities of the oval being directed upwards and downwards: the upper one being formed by the under surface of the Diaphragm, the lower by the upper concave surface of the Levator ani. In order to facilitate description, it is artificially divided into two parts: an upper and larger part, the *abdomen proper*; and a lower and smaller part, the *pelvis*. These two cavities are not separated from each other, but the limit between them is marked by the brim of the true pelvis. The space is wider above than below, and measures more in the vertical than in the transverse diameter.

**Boundaries.**—The **abdomen proper** is bounded *in front*, and *at the sides*, by the lower ribs, the abdominal muscles, and the venter ilii; *behind*, by the vertebral column and the Psoas and Quadratus lumborum muscles; *above*, by the Diaphragm; *below*, by the brim of the pelvis. The muscles forming the boundaries of the cavity are lined upon their inner surface by a layer of fascia, differently named according to the part which it covers.

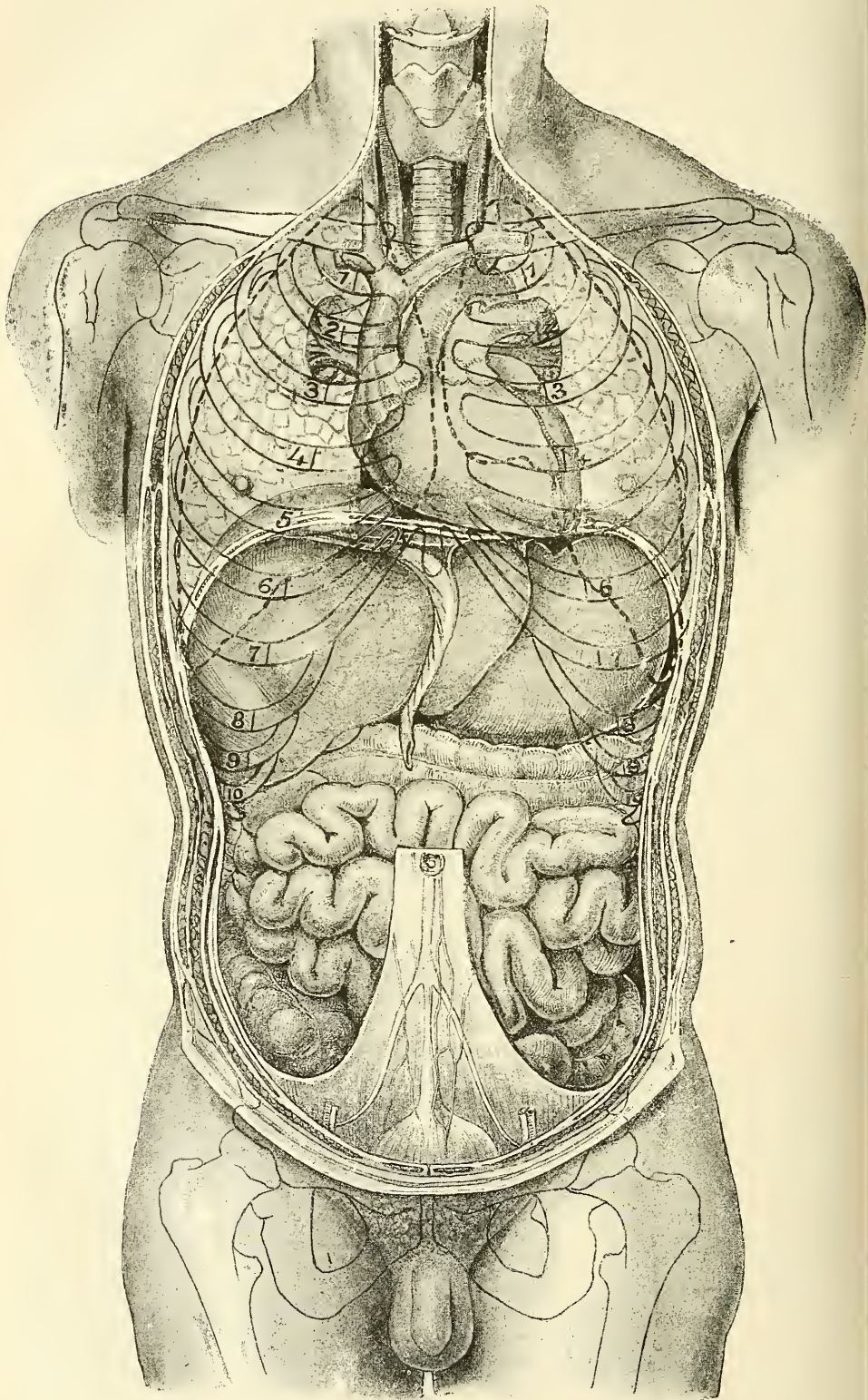
The abdomen contains the greater part of the alimentary canal; some of the accessory organs to digestion, viz. the liver, pancreas, and spleen; and the kidneys and suprarenal capsules. Most of these structures, as well as the wall of the cavity in which they are contained, are covered by an extensive and complicated serous membrane, the *peritoneum*.

The *apertures* found in the walls of the abdomen, for the transmission of structures to or from it, are, the *umbilicus*, for the transmission (in the fœtus) of the umbilical vessels; the *caval opening* in the Diaphragm, for the transmission of the inferior vena cava; the *aortic opening*, for the passage of the aorta, vena azygos, and thoracic duct; and the *œsophageal opening*, for the œsophagus and pneumogastric nerves. *Below*, there are two apertures on each side: one for the passage of the femoral vessels, and the other for the transmission of the spermatic cord in the male, and the round ligament in the female.

**Regions.**—For convenience of description of the viscera, as well as of reference to the morbid condition of the contained parts, the abdomen is artificially divided into nine regions. Thus, if two circular lines are drawn round the body, the one through the extremities of the ninth ribs, where they join their costal cartilages, and the other through the highest point of the crests of the ilia, the abdominal cavity is divided into three zones—an upper, a middle,



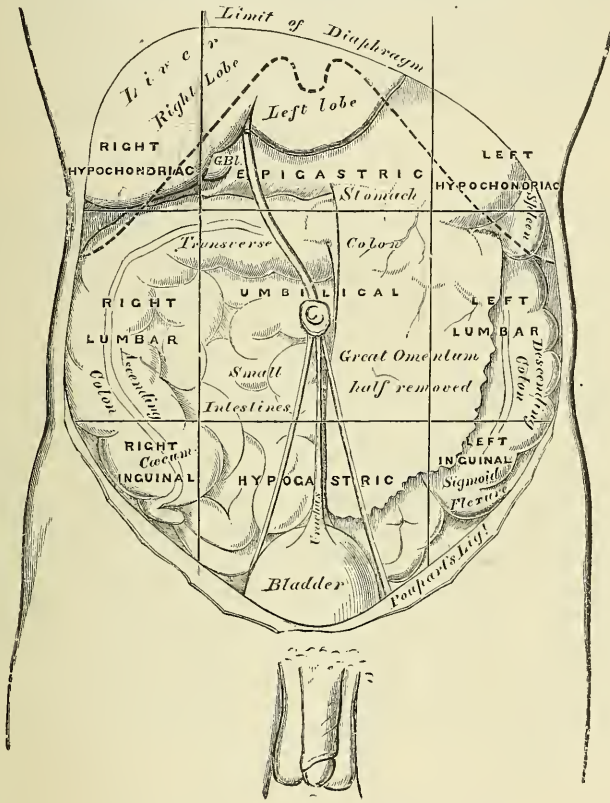
FIG. 567.—Topography of thoracic and abdominal viscera.



and a lower. If two parallel lines are drawn perpendicularly upwards from the centre of Poupart's ligament, each of these zones is subdivided into three parts—a middle and two lateral.

The middle region of the upper zone is called the *epigastric* (ἐπί, over; γαστήρ, the stomach); and the two lateral regions, the *right* and *left hypochondriac* (ὑπό, under; χόνδροι, the cartilages). The central region of the middle zone is the *umbilical*; and the two lateral regions, the *right* and *left lumbar*. The middle region of the lower zone is the *hypogastric* or *pubic region*; and the lateral regions

FIG. 568.—The regions of the abdomen and their contents. (Edge of costal cartilages in dotted outline.)



are the *right* and *left inguinal* or *iliac*. The viscera contained in these different regions are the following (fig. 566) :

*Right Hypochondriac*

The greater part of right lobe of the liver, the hepatic flexure of the colon, and part of the right kidney.

*Epigastric Region*

The greater part of the stomach, including both cardiac and pyloric orifices, the left lobe of the liver and the gall-bladder, the pancreas, the duodenum, parts of the kidneys and the suprarenal capsules.

*Left Hypochondriac*

The splenic end of the stomach, the spleen and extremity of the pancreas, the splenic flexure of the colon, and part of the left kidney.



*Right Lumbar*

Ascending colon, part of the right kidney, and some convolutions of the small intestines.

*Umbilical Region*

The transverse colon, part of the great omentum and mesentery, transverse part of the duodenum, and some convolutions of the jejunum and ileum, and part of both kidneys.

*Left Lumbar*

Descending colon, part of the omentum, part of the left kidney, and some convolutions of the small intestines.

*Right Inguinal (Iliac)*

The cæcum, appendix cæci.

*Hypogastric Region*

Convolutions of the small intestines, the bladder in children, and in adults if distended, and the uterus during pregnancy.

*Left Inguinal (Iliac)*

Sigmoid flexure of the colon.

## THE PERITONEUM

The **peritoneum** (*περιτείνειν*, to extend around) is a serous membrane, and partially invests all the viscera contained in the abdominal and pelvic cavities. In consequence of the viscera and different shapes of these viscera, the reflections of the peritoneum, as it invests them, are exceedingly complex and difficult to understand.

The peritoneum partially invests all the viscera contained in the abdominal and pelvic cavities, forming the visceral layer of the membrane; it is then reflected upon the internal surface of the parietes of those cavities, forming the parietal layer. The *free surface of the peritoneum* is smooth, moist, and covered by a layer of flattened endothelial cells; its *attached surface* is rough, being connected to the viscera and inner surface of the parietes by means of areolar tissue called the *subserous areolar tissue*. The parietal portion is loosely connected with the fascia lining the abdomen and pelvis; but more closely to the under surface of the Diaphragm, and in the middle line of the abdomen.

The description of the peritoneum is difficult, and cannot be made very clear without referring to its more primitive and simpler type in the embryo. The following essential facts in the Development of the Peritoneum, from the pen of Mr. Fred T. Brockway, are here given with a view to rendering the description of this complex structure more intelligible to the student.

## DEVELOPMENT OF THE PERITONEUM

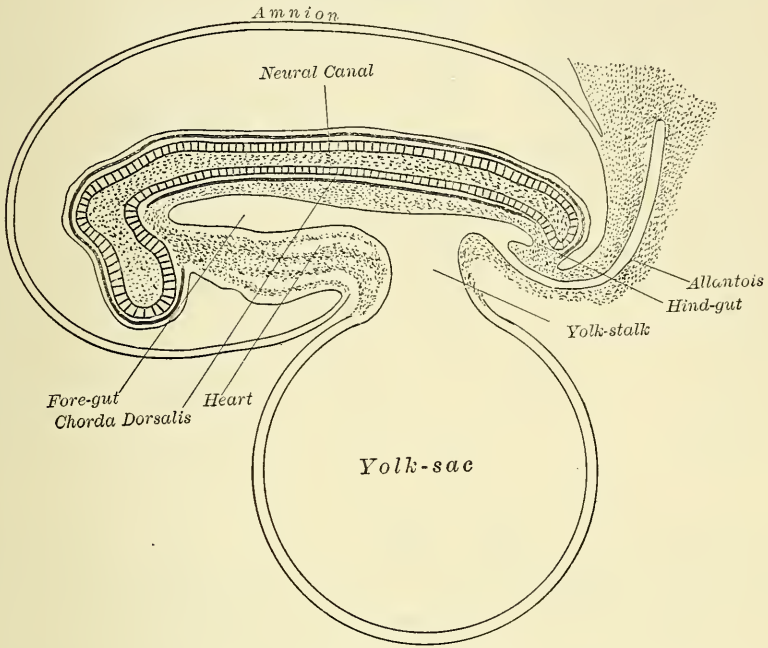
In the early development of the alimentary canal, before the twelfth day in the human embryo, all three germ-layers push forward, are folded over, and produce the head and the anterior part of the *fore-gut*. This is blind at the front end, and the *mouth* is developed later by an invagination from the exterior. The middle part of the future alimentary tract, *mid-gut*, is in free communication for some time with the blastodermic vesicle which is later called the *yolk-sac*. The approximation of the body-walls at the umbilicus gradually pinches the *yolk-stalk* off into the *vitelline duct*, so the sac finally lies wholly outside the body of the embryo, and that part of it enclosed within is the *pleuro-peritoneal cavity* (fig. 569). Finally, at the caudal end a *hind-gut* is formed and an *anus* added by a process of invagination.

Thus the whole alimentary canal was originally a straight tube placed in front of the aorta, or the original two primary aortæ, and that in front of the future vertebral column, the *chorda dorsalis* (fig. 570). Along its middle region, the anterior wall is lacking as it opens here into the yolk-sac.



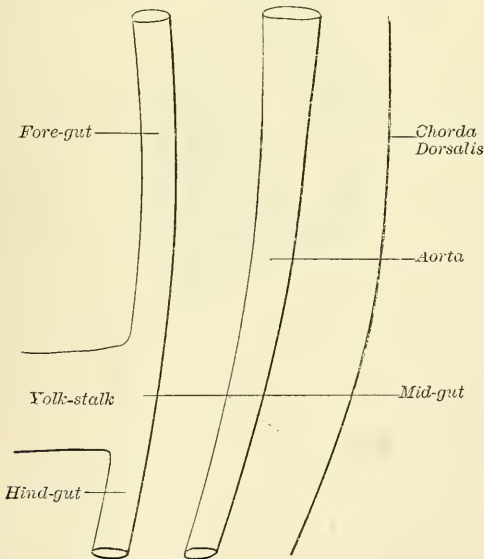
The fore-gut contracts to form the *œsophagus*, which is very short (fig. 571). This gradually widens into a spindle-like dilatation indicating the *stomach*. The

FIG. 569.—Diagram of a longitudinal section of a mammalian embryo. Very early. (After Quain.)



*small intestine* is short and straight with a wide opening into the yolk-sac. Just below the stomach, the liver is budding out from the duodenum. This

FIG. 570.—Schematic median section of a human embryo. (After Dexter.)



stage is attained in the fourth week in the human embryo. There are now five successive districts in the whole canal, *mouth*, *throat*, and *visceral clefts*,

*oesophagus*, spindle-shaped *stomach*, and the remaining *tube* connected with the *yolk-sac*.

By the fifth or sixth week, the *stomach*, at first straight and parallel with the

FIG. 571.—Schematic median section of a human embryo of fourth week.  
(After Dexter.)

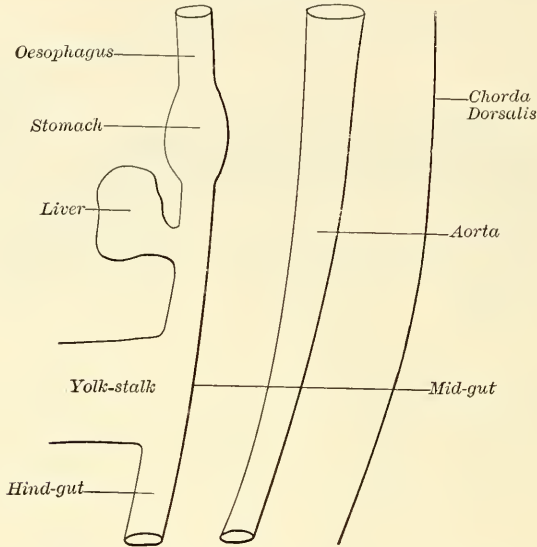
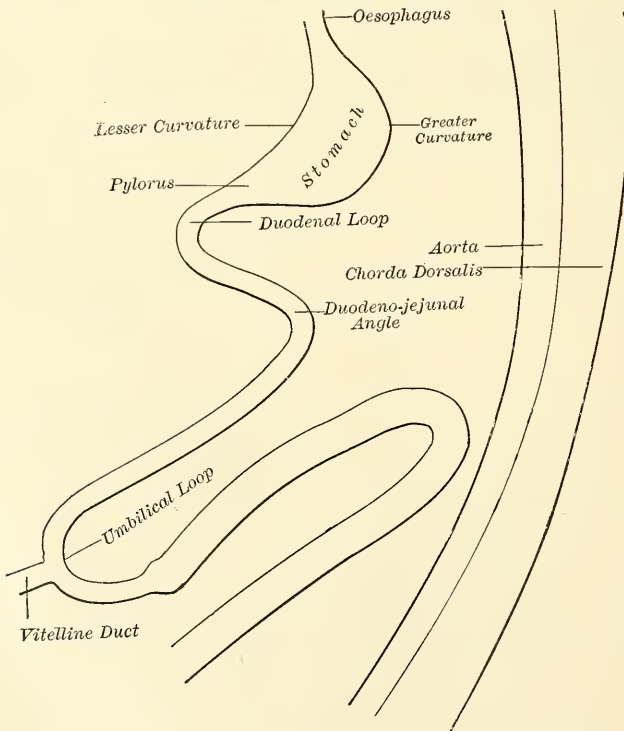


FIG. 572.—Schematic median section of a human embryo of fifth or sixth week. (After Dexter.)



axis of the body, begins to show a convex *greater curvature* toward the vertebral column and a concave *lesser curvature* on the opposite side. This is covered by the voluminous liver. The *pyloric end* is tilted away from the column,

and this forms the *duodenal loop* (fig. 572). As the communication with the yolk-sac becomes constricted and absorbed there is developed a long *umbilical loop* of intestine opposite the *vitelline duct*. The end of this loop passes for a time into the umbilical cord surrounded by a protrusion of the peritoneum. This loop passes downward and forward, and consists of nearly two parallel arms between which is stretched the mesentery. At a little distance from the vitelline duct on the lower arm of the loop is seen a small enlargement; this marks the future *cæcum* and beginning of the *colon* and end of small intestine. Five portions of intestine are now to be distinguished: the short part passing back from the stomach toward the spinal column becomes *duodenum*; at the turning point into the umbilical loop is the *duodeno-jejunal junction*; the anterior descending arm and bend of the loop become *small intestine*; most of the ascending posterior arm becomes *colon*, and the terminal part, *sigmoid flexure* and *rectum*.

At first the alimentary tract is mostly in contact with the chorda dorsalis held by a broad mass of embryonal connective tissue. This tissue contains two primitive aortæ. The right and left portions of the body-cavity approach each other and compress this tissue into a *mesentery*, which is attached to the whole length of the tube beginning with the stomach, connecting it with the chorda. The special part of this membrane attached to the stomach posteriorly is called *mesogastrium*; that to the small intestine is called *mesentery* (*medium intestinum* or *μέσον έντερον*, middle intestine); that to the colon, the *mesocolon*; that to the sigmoid

FIG. 573.—Fig. 570 with mesenteries added. (Dexter.)

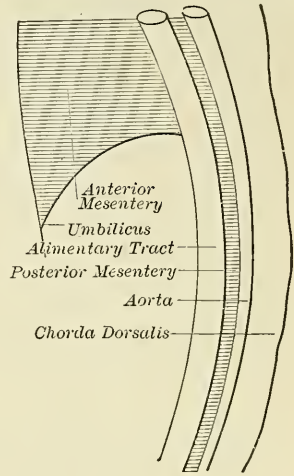
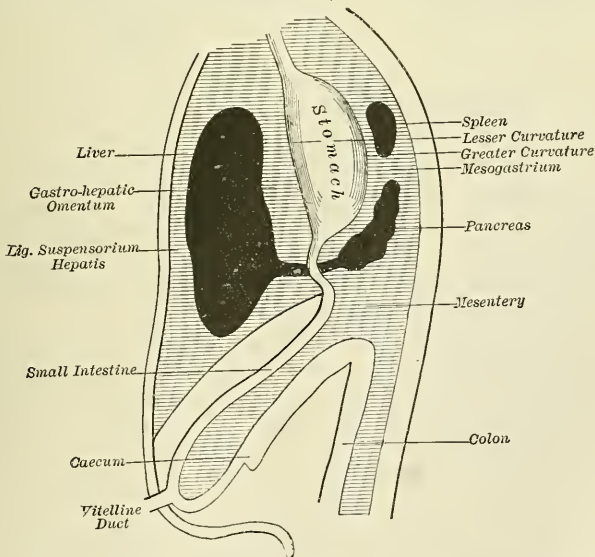


FIG. 574.—Diagram to show the original positions of the liver, stomach, duodenum, pancreas and spleen, and the mesenteries connected. A longitudinal section. (Hertwig.)



flexure, the *mesosigmoidea* or *sigmoid mesocolon*; and that to the rectum the *mesorectum*. This has not been represented in the above figures for the sake of simplicity. There is also a *ventral mesentery*, but not of such extent as the



dorsal. It extends along the front of the alimentary canal from the throat to the lower end of the duodenum and in front as far down as the umbilicus (fig. 573). It almost makes the body-cavity a paired structure. In the upper part of this mesentery is developed the heart, the part enclosing it being called *mesocardium anterius* and *posterius*. The lower part extends from the stomach and duodenum to the anterior wall and has many names—*ventral gastric and duodenal mesentery*, *liver-ridge* and *prohepaticus*; it is never called anterior mesogastrium.

The *liver* is here developed anterior to the stomach, budding from the anterior part of the beginning of the duodenum (fig. 574).

The *pancreas* buds from the posterior part of the duodenum, vertical at first and covered on both sides by the mesentery of the small intestine; it passes into the mesogastrium later and becomes transverse.

The *spleen* is developed in the second month in the mesogastrium and is not connected directly with the alimentary canal.

At this stage, passing from before backward, we find the structures arranged: anteriorly, liver; in the centre, stomach; posteriorly, spleen and pancreas. The anterior mesentery in front of the liver becomes the suspensory or *falciform ligament* of the liver, extending to the umbilicus below and embracing the intra-

FIG. 575.—Cross section in duodenal region to show same structures as in fig. 574. (Hertwig.)

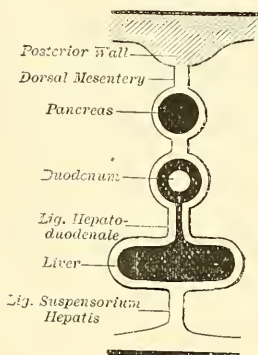
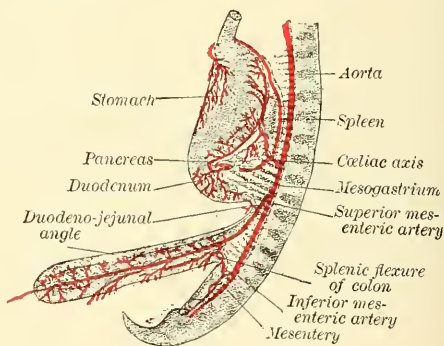


FIG. 576.—Schematic representation of the mesentery in a six weeks' human embryo. (Toldt.)



abdominal part of the umbilical vein. The anterior mesentery between the liver and stomach becomes the *lesser omentum* or *lig. hepato-gastro duodenale*. The mesogastrium between stomach and spleen becomes *gastro-splenic omentum*, and that part between the spleen and vertebral column forms the *great omentum*.

Fig. 575 is a cross-section of the same embryo. Anteriorly are the two sacs of the liver projecting one into each side of the body-cavity. The right sac grows to a larger size than the left; they form respectively the right and left lobes. Behind these is the duodenum and behind that the pancreas. The intervening parts of the mesentery are called ligaments, viz. first, *suspensory ligament* of liver, next *hepato-duodenal ligament*, next *duodeno-pancreatic ligament*, and lastly, the dorsal mesentery. Note that pancreas and duodenum are wholly enclosed.

The *vascular arrangement* of this stage is shown in fig. 576. The *coeliac axis*, the *superior mesenteric* and *inferior mesenteric arteries* have their points of supply definitely marked out even in the sixth week. They pass from the aorta between the two layers of the mesogastrium and mesentery to their destinations, which never change. The *coeliac axis* goes to the stomach, spleen, pancreas, liver and part of duodenum; the *superior mesenteric*, to part of duodenum, the small intestines, and part of colon; the *inferior mesenteric*, to the remainder of the tube.

The length of the intestine continually increases, and it becomes more bent

and tortuous, till from the third month on there occur two important changes: one in regard to a twist of the intestinal loop, and one in regard to a change in position of the stomach. The ascending and descending arms of the umbilical loop have been lying side by side one above the other; now the lower arm, which

Fig. 577.—Torsion of the umbilical loop. Initial position. (Jonnesco.)

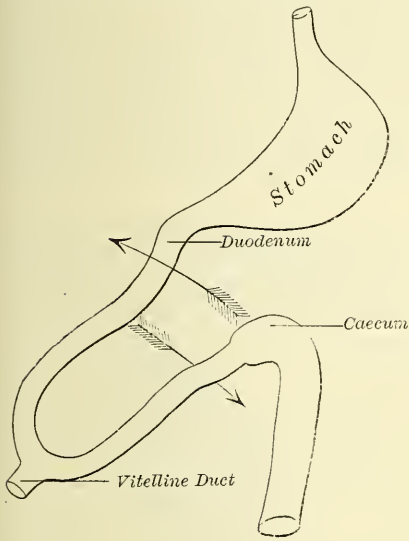
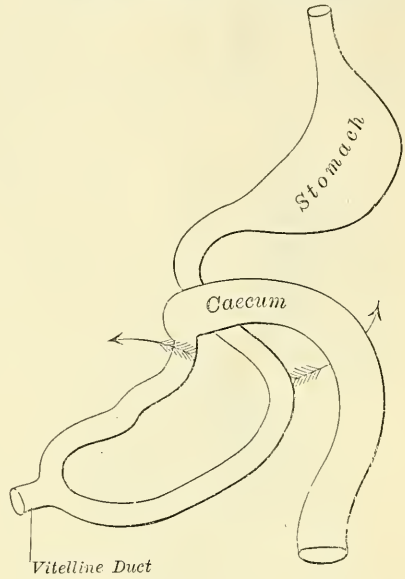


Fig. 578.—Torsion of the umbilical loop. Acquired position. (Jonnesco.)



becomes caecum and colon, begins to pass over the upper arm and crosses the small intestine transversely (fig. 577). The upper arm moves but little or none, as it is already fixed to the vertebral column at its upper duodeno-jejunal end, perhaps by the muscle of Treitz.

The caecum, which has already developed an appendix, is thus landed wholly on the right side of the body up under the liver (figs. 578 and 580). At first

Fig. 579.—Development of human alimentary canal and mesentery. Earlier stage. (Hertwig.)

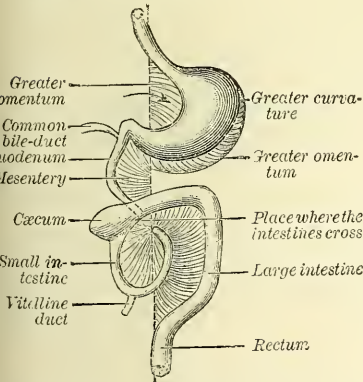
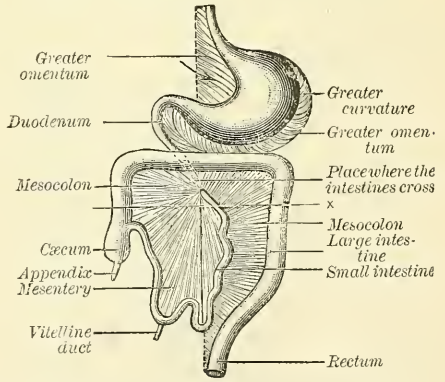


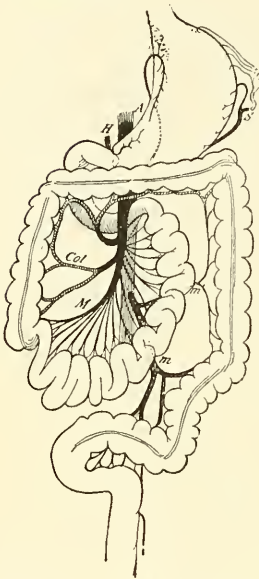
Fig. 580.—Development of human alimentary canal and mesentery. Later stage. (Hertwig.)



there is no ascending colon, the transverse colon running across the duodenum, inferior to the stomach and up to the spleen, making a splenic flexure; it passes through the left lumbar region and is continued into the sigmoid flexure and rectum. The caecum increases in length, and finding least resistance below, finally settles into the right iliac fossa, dragging down a short ascending colon.

The mesentery, seen in the loop of fig. 576, makes a half rotation, as does the loop, and its anterior surface becomes posterior, as may be inferred from figs. 579 and 580.

FIG. 581.—Final disposition of the intestines and their vascular relations. (Jonnesco.)



A. Aorta. H. Hepatic artery. S. Splenic artery. M. Col. Branches of superior mesenteric artery. m, m'. Branches of inferior mesenteric artery.

Fig. 581 shows the arterial supply after the twist of the umbilical loop, with the cœliac axis behind the stomach, the superior mesenteric artery fastening the duodenum between itself and the aorta, and the inferior mesenteric coming off below.

During this period of intestinal torsion, the stomach has suffered a double change. First the stomach twists around an antero-posterior axis, so its cardiac or œsophageal end moves to the left and downward, while its pyloric end moves a little to the right and upward; and its vertical position becomes more transverse.

Secondly, its long axis having been parallel to the vertebral column, it originally presented a right and left surface, supplied respectively by the right and left vagus nerves. It now falls over so that its right side becomes posterior and its left side anterior, and the greater curvature becomes more inferior and the lesser curvature more superior. The vagus nerves still supply the same surfaces, which have changed their positions: the right nerve now goes to the posterior surface and the left one to the anterior surface.

The lower end of the œsophagus also experiences the same torsion.

The *mesogastrium* is modified by this rotation to the right. In the anterior mesentery is the liver (fig. 574), but in the adult we find it shifted to the right side of the body. The spleen was posterior to the stomach; in the adult it is to its left. So these three antero-posterior organs have become laterally placed, and from right to left are hereafter found: liver, stomach, spleen.

FIG. 582.—Wood and cloth to illustrate stomach and mesogastrium of two layers viewed from the side. (G. S. H.)

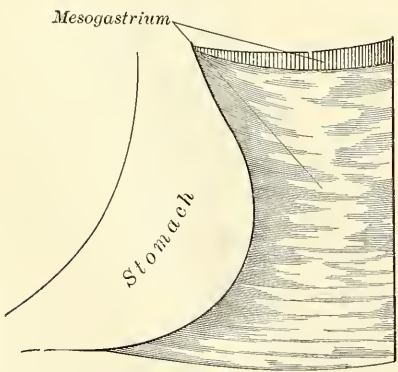
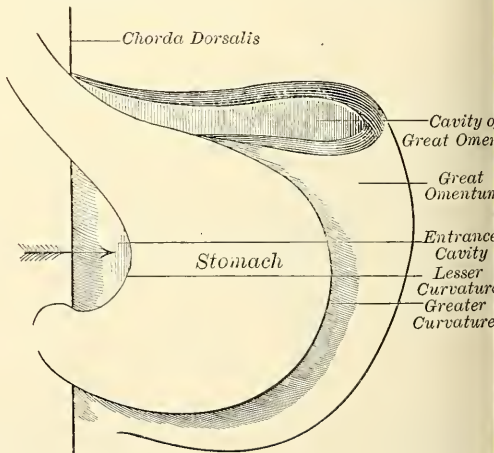


FIG. 583.—Stomach turned to right enclosing a space behind it, representing the great omentum and its cavity view from the front. (G. S. H.)



Again connected with this torsion of the stomach is associated the formation of the *great omentum*. To illustrate this, carve a piece of wood to represent the



stomach; let two layers of cloth attached to the posterior border represent the mesogastrium attached to the vertebral column (fig. 582). This was the original condition (fig. 576). Now turn the stomach to the right, allowing the cloth to fall loosely to the left, and immediately a cavity is formed included between two layers of cloth anteriorly and two layers posteriorly (fig. 583). In the embryo a similar cavity is formed called the *cavity of the great omentum*, the *lesser sac of peritoneum*, *bursa omentalis*; and a similar fold of four layers is formed called the *great omentum*, which in the embryo and infant contains this cavity.

The entrance to this cavity is indicated by the arrow in figs. 579, 580, and 583, and the bulging of the great omentum is seen to the left of and below the greater curvature of the stomach. Compare the above with fig. 584, and the position of the sac will be better understood.

The front wall of the bursa omentalis is formed by the stomach; the posterior wall by the mesogastrium, which at first completely invests the

FIG. 584.—Schematic and enlarged cross section through the body of a human embryo in the region of the mesogastrium. Beginning of third month. (Toldt.)

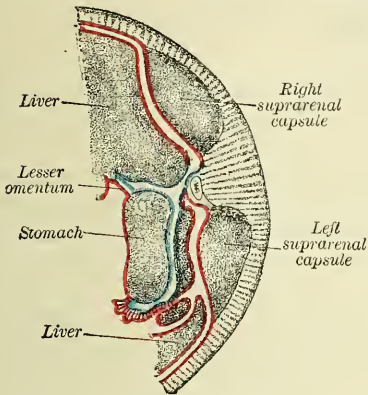
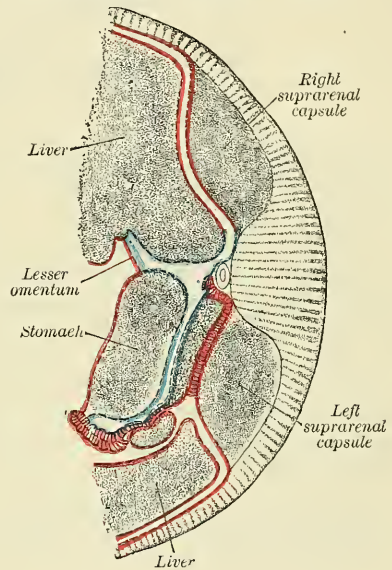


FIG. 585.—Same section as in fig. 584, at end of third month. (Toldt.)



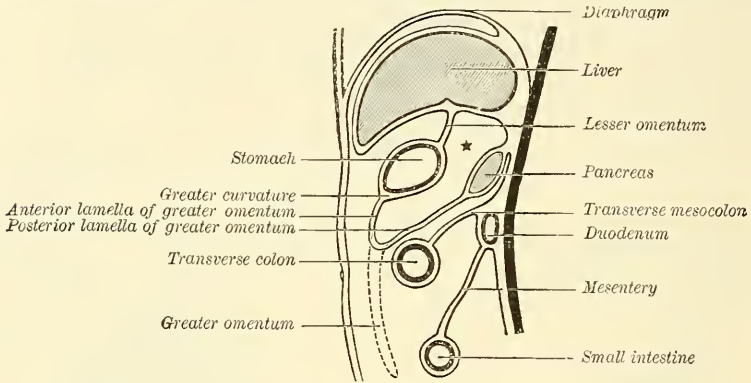
pancreas, touches the spleen, and covers part of the left suprarenal capsule. The opening is turned to the right and covered anteriorly by the lesser omentum. The space between the lesser omentum and right end of pancreas is the *atrium bursæ omentalis* or the *antechamber* or *lesser omental pocket*. It lies below and behind the Spigelian lobe of the liver. The bursa proper, or lesser sac, is that part behind the stomach.

By the end of the third month the pancreas touches the left suprarenal capsule (fig. 585), the layer of mesogastrium separating the two becomes later absorbed, and the pancreas is then an extraperitoneal organ separated from the kidney or capsule by connective tissue. By further development this lesser sac continues to push between the layers of the great omentum downward and to the left, and fuses with neighbouring viscera. The great omentum, formerly a part of the mesogastrium, comes to hang freely down over the transverse colon and then in front of the small intestines, as about to do in figs. 580 and 586.

The lamellæ composing the bursa omentalis or lesser sac are each composed of two layers; they are placed close together and are continuous below (figs. 586 and 587). The more anterior one is attached to the greater curvature of the stomach, and the posterior one lying on the intestines was originally attached to the vertebral column and enclosed most of the pancreas (figs. 584 and 586). In many mammals no further change occurs. In man fusions follow: the posterior lamella covers a large part of the posterior abdominal wall, and its original

line of vertebral attachment gets displaced to the left; it joins the Diaphragm and forms the *lig. phreno-lienale*, suspensory ligament of the spleen. Below it becomes fused to the upper layer of the transverse mesocolon and to the transverse colon (fig. 587). These two contiguous layers, i.e. the posterior layer of the mesogastrium and the upper layer of the transverse mesocolon, may present

FIG. 586.—Diagram to illustrate the development of the bursa omentalis, cavity of the great omentum or lesser sac. Fœtal stage. \* Lesser sac. (Hertwig.)

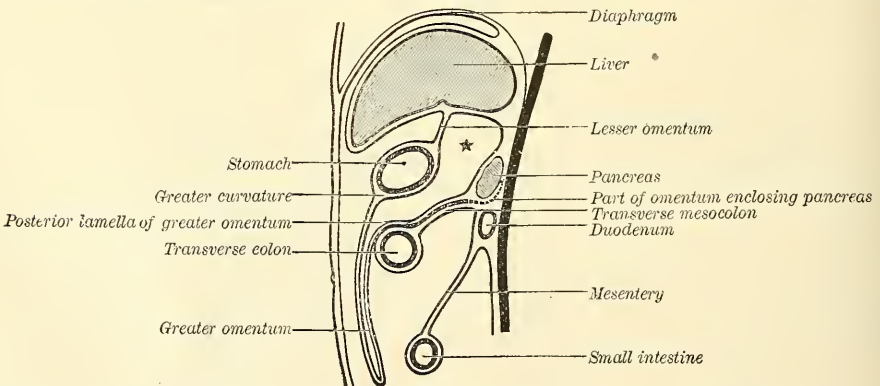


a fissure at birth in many mammals. During early infancy in the human species they form a single lamella with a deposit of fat (fig. 587). In adult life no trace of the extra layer is seen.

There are then three types of relation of the posterior layer of the great omentum to the transverse mesocolon: *fœtal*, where they are separate (fig. 586); *infantile*, where they are fused into one layer (fig. 587); and *adult*, where all trace of this layer has disappeared and the posterior lamella of the great omentum seems to enclose the transverse colon.

The lesser sac of peritoneum (bursa omentalis) is still continuous with the greater sac or general peritoneal cavity, something like the two cavities of an hour-glass, only the upper cavity (lesser sac) is comparatively small and bent down behind the other. In fig. 587 the cavity behind the stomach is connected

FIG. 587.—Development of bursa omentalis. Infantile stage. Great omentum covers the intestines and has fused with the transverse mesocolon. Pancreas is free of peritoneum posteriorly. (Hertwig.)



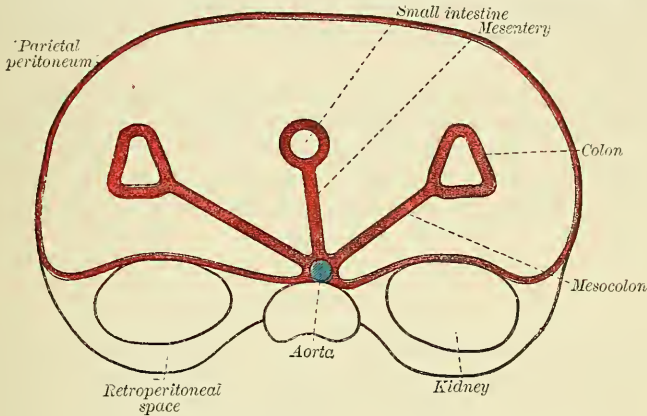
with the larger cavity in front of it by means of a foramen to the right of the lesser omentum. It is the *foramen of Winslow*, and is to be found just under the hilus (the black spot on a bean) of the liver to the right side of the neck of the gall-bladder.

After childhood the cavity of the lesser sac descending into the great omentum is obliterated and the four layers are fused into an *omental plate*.

## MESENTERY OF THE SMALL INTESTINE AND COLON

The mesentery is influenced by the increase in length of the small intestine. It becomes fan-shaped, and its length at its insertion into the intestine is many times that of its origin from the lumbar vertebræ; so it lies in folds and is called a *frill*. In man, after the fourth month, this becomes more complicated by fusions with the posterior body-wall or neighbouring viscera. It affects especially the mesentery of the duodenum and colon.

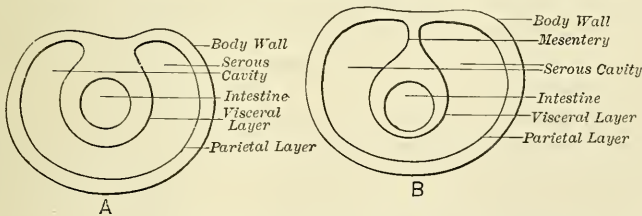
FIG. 588.—Cross section of alimentary canal of fig. 580 to show mesenteries. (Dexter



The duodenum at first is completely invested with peritoneum (fig. 579); later other viscera growing faster are thought to pull it away and appropriate it, and so posteriorly it comes to lie on the posterior wall of the body and becomes an immovable organ (fig. 587).

The large intestine possesses a suspensorium attached to the vertebral column and designated the *mesocolon*. When the twist of the umbilical loop occurred, the transverse colon and its mesocolon were drawn transversely across the duodenum, and a new secondary line of attachment was thus formed. This explains why in the adult we find the body-cavity divided by the transverse colon and transverse mesocolon into chambers, an upper and a lower. In the upper are the stomach, liver, pancreas, spleen and part of duodenum; in the lower, part of duodenum and the small intestines. The duodenum, in order to get from the

FIG. 589.—Schematic drawing of a cross section of a serous cavity. (Gegenbaur.)



upper to the lower space, passes underneath the transverse colon or apparently through the mesocolon (fig. 580).

The cæcum, ascending and descending colon also lie with their posterior walls more or less in contact with the body-wall, but sometimes they have a more or less distinct mesentery, as they did originally. The original disposition can be seen by taking a cross section of the alimentary canal in fig. 580 along the line X. Each colon and the small intestine is fixed to the aorta and vertebral column by its special mesentery, which allows freedom of motion (fig. 588).



The *mesentery* is seen to be formed of two layers of peritoneum which surround an intestine completely, except at a posterior line where there is opportunity for vessels, nerves, and lymphatics to enter or return. Two layers of peritoneal connective tissue, which lodge vessels, nerves, and lymphatics, constitute a mesentery. The intestine looks as though it had pushed its way into the sac of peritoneum as a finger enters a glove. That comparison is incorrect, for intestine and peritoneum are developed simultaneously. The intestine is not first made and then pushed, as would appear (fig. 589).

The intestine and the two layers of peritoneum are formed together. As the intestine recedes, the serous membrane comes from the wall to it in a duplicature. The layer covering the intestine is called *visceral*; that reflected upon the parietes or wall is the *parietal layer*, and the passage from one to the other is the *mesentery*.

In the *adult* the small intestine is unchanged, but the mesentery of the right and left colon has been widely separated posteriorly, and it and some of the parietal peritoneum have been changed to connective tissue, so each colon becomes fixed and partly extraperitoneal, like the duodenum and pancreas (fig. 587). The kidneys were always outside, being developed in the retroperitoneal space.

#### ADULT PERITONEUM

In order to get a first general idea of the peritoneum and its reflections, the student should bear in mind that all the abdominal and pelvic viscera are placed external to it, and that it is a shut sac superimposed upon the viscera.\*

Let the student imagine that all the viscera are in their proper positions in the abdominal cavity, but uninvested by peritoneum. Upon the top of them is placed a large closed sac, the walls of which are of extreme thinness, and wherever there is a cleft between two viscera a process of peritoneum derived from the part of the sac in contact with the viscera is tucked in between them, so as to cover the adjacent surfaces of the two viscera and separate them from each other, and at the same time, by becoming adherent to the viscera, form an investment for them. Thus in fig. 590 such a diverticulum or process may be seen tucked in between the under surface of the liver and the upper surface of the stomach, and extending between the two as far backwards as the portal vein, hepatic artery, and hepatic duct, which it covers on their anterior surfaces, forming the anterior layer of what is termed the lesser omentum.

Another diverticulum or process is tucked in round the hepatic artery, as it passes forwards and upwards to the liver, and afterwards expands into a large sac or bag, which covers the posterior surface of the liver and stomach, and the upper part of the posterior wall of the abdomen, separating these structures from each other. This large *cul-de-sac* of peritoneum is called the *lesser cavity of the peritoneum*, but is only a part of the general cavity differentiated from it by the constriction produced at the situation of the hepatic artery. In this respect the peritoneum may be compared to an hour-glass with two unequal globes: the smaller one constituting the lesser cavity of the peritoneum; the larger one the greater cavity; and the constriction where the two globes communicate corresponding to the constriction in the peritoneum where it hooks round the hepatic artery. This constriction is called the foramen of Winslow.

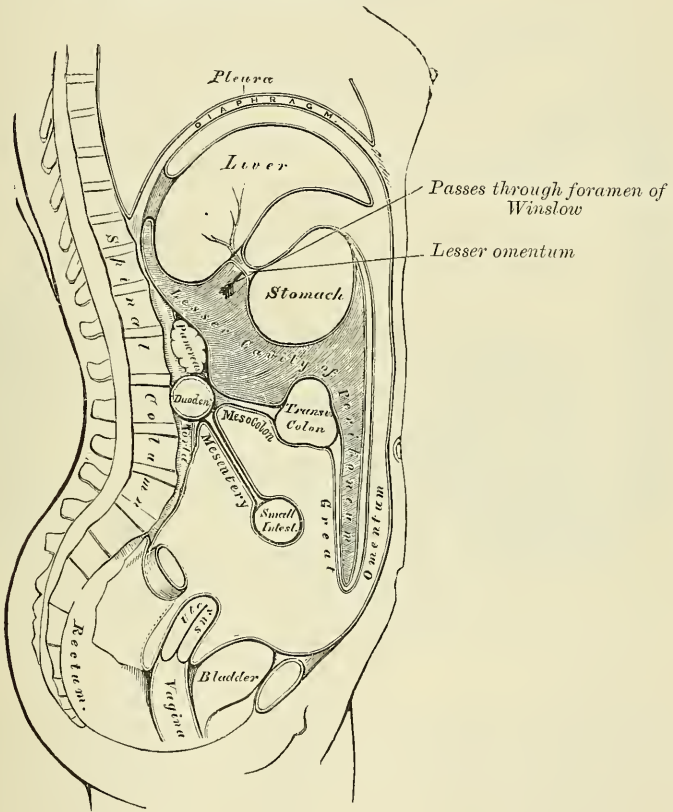
Between the transverse fissure of the liver and the lesser curvature of the stomach there is thus a double layer of peritoneum: the anterior layer being part of the greater bag of the peritoneum, where it is tucked in between the liver and the stomach from the front; while the posterior layer is part of the lesser bag of the peritoneum where it is tucked in round the hepatic artery. These two layers

\* We may disregard, for the present, the fact that the peritoneum in the female is not an absolutely closed sac, since the Fallopian tubes open into it at their free extremities.

constitute the lesser omentum. Between the two layers are situated the hepatic artery, the portal vein, and the hepatic duct.

A process of this lesser bag of the peritoneum is pushed backwards and upwards behind the liver, extending as far as the under surface of the Diaphragm, the posterior part of which it covers. At its extremity this process approaches a diverticulum of the greater bag of the peritoneum, which is pushed in from the front, in the cleft between the upper surface of the liver and the under surface of the Diaphragm. Another process of this lesser bag is pushed downwards between the stomach and the transverse colon and forms the two inner of the four layers of the great omentum. Thus the lesser cavity of the peritoneum is seen to be a complete sac or bag, separating the back and part of the under surface of the liver, the posterior wall of the stomach, and the upper surface of

FIG. 590.—The reflections of the peritoneum, as seen in a vertical section of the abdomen.



the transverse colon from the back part of the under surface of the Diaphragm and the upper part of the posterior wall of the abdomen.

The *greater cavity of the peritoneum* separates the anterior surfaces of the viscera from the front wall of the abdomen; so that in our comparison of the two cavities to an hour-glass it must be borne in mind that they are not in the same straight line as the two globes of the hour-glass, but that, at the point of constriction, the smaller cavity is bent round the hepatic artery, so as to lie behind the greater cavity.

The greater sac of the peritoneum is placed in front of the viscera, one layer being in contact with them, the other lining the inner surface of the anterior wall of the abdomen. The layer which is in relation with the viscera sends backwards diverticula which pass between the various organs, and in certain

places comes in contact with the peritoneum forming the lesser bag, in the manner described above. Thus we have one of these diverticula sent backwards between the liver and Diaphragm, covering the anterior part of the under surface of the Diaphragm and the upper surface of the liver as far backwards as the ligaments. The extremity of this diverticulum approaches a similar diverticulum of the lesser bag, already described, and the two layers form the anterior and posterior layers of the coronary ligament of the liver. Another process, which has already been mentioned, is sent backwards between the under surface of the liver and the stomach, to meet a similar process of the lesser cavity prolonged from behind forwards. Where the two are in apposition the lesser or gastro-hepatic omentum is formed. A third diverticulum is carried backwards to the posterior wall of the abdomen between the transverse colon and the small intestine. This prolongation covers the under surface of the transverse colon and forms the under layer of the transverse mesocolon, and the upper layer of the mesentery; by its extremity it is in contact with the posterior wall of the abdomen, and covers a part of the abdominal aorta. Between the greater curvature of the stomach and the transverse colon there is a fold or reduplication of the peritoneum, which contains between its layers a similar fold from the lesser cavity, and forms the apron or great omentum. Another fold of the greater bag of the peritoneum is pushed backwards to the spine between the small intestines and the pelvic viscera. This fold forms the lower layer of the mesentery, covers a considerable portion of the lower part of the abdominal wall, and passes over the sacro-vertebral angle into the pelvis. Below, where it covers the upper part of the pelvic viscera, it sends diverticula *downwards* between them, separating them from one another; thus one is sent downwards between the back of the rectum and the sacrum, another between the rectum and the bladder. In the female, one is sent down between the rectum and uterus, another between the uterus and bladder. These, then, are the various diverticula sent off from the posterior layer of the greater bag of the peritoneum; the anterior layer simply lines the anterior wall of the abdomen, and is continuous at its extremities with the posterior layer.

The student will perhaps be better able to follow these various folds or reflections of the peritoneum by a reference to the accompanying plan (fig. 591), which should be studied in conjunction with fig. 590. He must not forget, however, that though the lesser and greater cavities of the peritoneum are here represented, for the sake of clearness, as quite distinct from each other, they are not really so, but that they both form part of one great cavity.

The reflections of the peritoneum may be traced in two different ways, either by considering the folds which form each cavity separately, or by describing them together.

According to the first plan (fig. 590), the liver should be raised and supported in that position, and the stomach should be depressed, when a thin membranous layer is seen passing from the transverse fissure of the liver to the upper border of the stomach: this is the *lesser* or *gastro-hepatic omentum*. It consists of two delicate layers of peritoneum, an anterior and a posterior, between which are contained the hepatic vessels and nerves. Of these two layers, the anterior should first be traced, and then the posterior.

The *anterior layer* descends to the lesser curvature of the stomach, and covers its anterior surface as far as the great curvature: it descends for some distance in front of the small intestines, and, returning upon itself to the transverse colon, forms the *external layer of the great omentum*; it then covers the under surface of the transverse colon, and, passing to the back part of the abdominal cavity, forms the *inferior layer of the transverse mesocolon*. It then descends in front of the duodenum, over the superior mesenteric artery, along which it passes to invest the small intestines, and, returning to the vertebral column, forms the *mesentery*; whilst, on either side, it covers the ascending and descending colon, and is thus continuous with the peritoneum lining the walls of the abdomen.

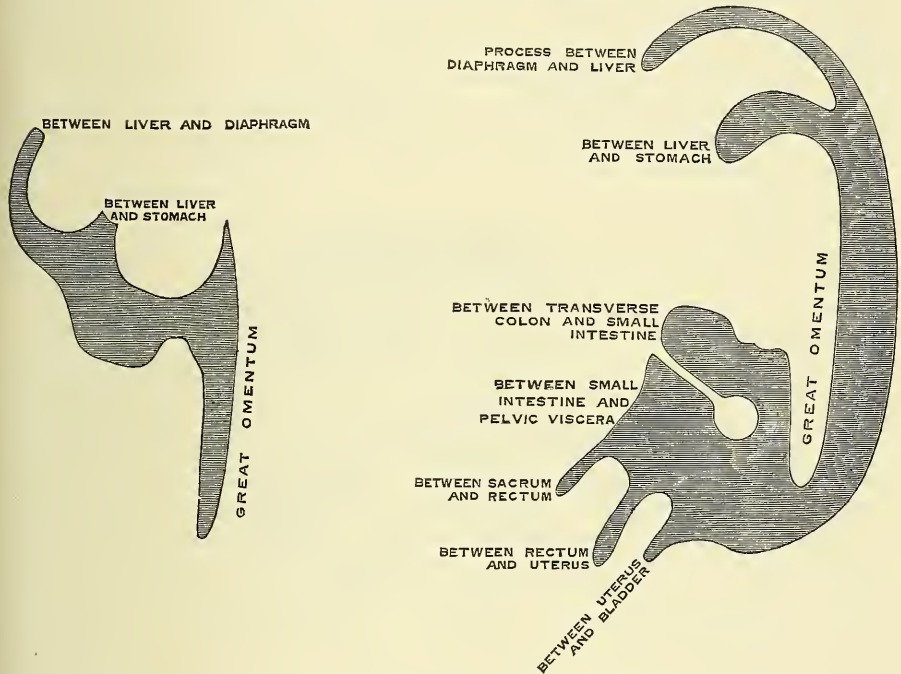


From the root of the mesentery it descends along the front of the spine into the pelvis, and surrounds the upper part of the rectum, which it holds in its position by means of a distinct fold, the *meso-rectum*. Its course in the male and female now differs.

*In the male* it forms a fold between the rectum and bladder, the *recto-vesical fold*, and ascends over the posterior surface of the latter organ as far as its summit.

*In the female* it descends into the pelvis surrounding the rectum, forms a fold between the rectum and vagina, the *recto-vaginal fold* (pouch of Douglas), covers a small part of the posterior wall of the vagina, and passes on to the uterus, the fundus and body of which it covers. From the sides of the uterus it is reflected to the wall of the pelvis, forming the broad ligaments; and from the anterior surface of the uterus it ascends upon the posterior wall of the bladder as far as its summit.

FIG. 591.—Plan of the peritoneum.



From this point it may be traced, as in the male, ascending upon the anterior parietes of the abdomen, to the under surface of the Diaphragm; from which it is reflected upon the liver, forming the anterior layer of the coronary, and the lateral and longitudinal ligaments. It then covers the upper and under surfaces of the liver, and at the transverse fissure becomes continuous with the anterior layer of the lesser omentum, the point whence its reflection was originally traced.

The *posterior layer of the lesser omentum* descends to the lesser curvature of the stomach, and covers its posterior surface as far as the great curvature; it then descends for some distance in front of the small intestines, between the two layers of the great omentum formed by the anterior layer, and, returning upon itself to the transverse colon, forms the internal layer of the great omentum; it covers the upper surface of the transverse colon, and, passing backwards to the spine, forms the upper layer of the transverse meso-colon. Ascending in front of the pancreas and crura of the Diaphragm, it lines the back part of the under surface of that muscle, from which it is reflected on to the posterior border of the liver, forming the posterior layer of the coronary ligament. It then passes to the under surface of the liver, as far as the transverse fissure, where it is

continuous with the posterior layer of the lesser omentum, the point whence its reflection was originally traced.

The space included in the reflections of this layer of the peritoneum is called the *lesser cavity of the peritoneum*, or *cavity of the great omentum*. It is bounded, *in front*, by the lesser omentum, the stomach, and the descending part of the great omentum; *behind*, by the ascending part of the great omentum, the transverse colon, transverse meso-colon, and its ascending layer; *above*, by the liver; and *below*, by the folding of the great omentum. This space communicates with the general peritoneal cavity through the foramen of Winslow, which is situated behind the right, or free border of the lesser omentum.

In order to trace the two layers together, we commence at the top of the abdominal cavity; that is to say, the under surface of the Diaphragm. This muscle is covered throughout the greater part of its extent by peritoneum; one layer extending from its anterior border, backwards; the other from its posterior border, forwards. Where the two layers approach each other they are reflected downwards to the liver, forming the coronary and lateral ligaments of this organ. When these two layers reach the liver, they again separate to enclose the greater part of this viscus, the one passing in front and the other behind, and they meet again on its under surface at the transverse fissure. From this fissure they turn downwards to the lesser curvature of the stomach, forming the gastro-hepatic or lesser omentum, and enclosing the hepatic artery, the portal vein, and the hepatic duct, which are contained between the two folds in this situation. From the lesser curvature of the stomach, the two layers pass over the anterior and posterior surfaces of the viscus, enclosing it and meeting again at the greater curvature. From this point they pass down in front of the small intestines, between this tube and the abdominal wall, and are reflected on themselves, passing upwards to the transverse colon, and forming the apron or great omentum. This reflection, therefore, consists of *four* layers of peritoneum. When the two posterior layers of the great omentum, in their reflection upwards, reach the transverse colon, they separate to enclose this portion of the intestinal tube, the one layer passing above it and the other below. They meet on its posterior surface, and pass backwards to the vertebral column, forming what is called the *transverse meso-colon*. At this point the two layers separate. The one which formed the upper surface of the transverse meso-colon, and which belongs to the lesser cavity, passes upwards in front of the pancreas and crura of the Diaphragm to the back part of the under surface of the Diaphragm, the point from which the description of this layer was commenced. The other, which formed the inferior layer of the transverse meso-colon, turns downwards in front of the duodenum, aorta, and inferior vena cava, and can be traced, as a single layer, in the manner above described, investing the small intestines and forming the mesentery; then passing over the sacro-vertebral angle into the pelvis, the viscera of which it partially invests, and finally over the posterior surface of the front wall of the abdomen to the under surface of the Diaphragm, the point from which the description of this layer was commenced.

In addition to tracing the peritoneum vertically, as has now been done, it is necessary to trace it horizontally. If this is done below the transverse colon, the circle is extremely simple, as it includes only the greater bag of the peritoneum (fig. 590). Above the level of the transverse colon the arrangement is more complicated, on account of the existence of two sacs.

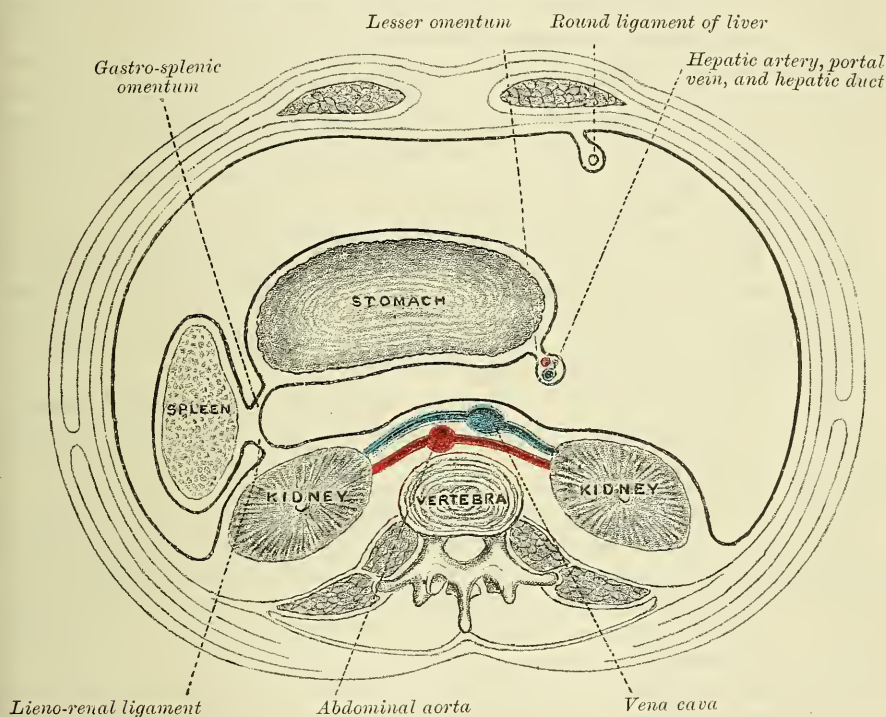
Starting from the *linea alba*, below the level of the transverse colon, and tracing the continuity in a horizontal direction to the right, we find the peritoneum covering the internal surface of the abdominal wall almost as far as the anterior border of the *Quadratus lumborum* muscle; it encloses the *cæcum*, forming the *meso-cæcum*, and is reflected over the sides and anterior surface of the ascending colon, fixing it to the abdominal wall, thus forming the ascending meso-colon, from which it can be traced over the kidney to the front of the bodies of the vertebræ. It then passes along the mesenteric vessels to invest the small



intestines, and back again to the spine, forming the mesentery, between the layers of which are contained the blood-vessels, nerves, lacteals, and glands. Lastly, it passes over the left kidney to the sides and anterior surface of the descending colon, and, reaching the abdominal wall, it passes along it to the middle line of the abdomen.

Above the transverse colon (fig. 592) the peritoneum can be traced, forming the greater and lesser cavities, and their communication through the foramen of Winslow can be demonstrated. Commencing in the middle line of the abdomen, the membrane may be traced lining its anterior wall, and on the right side sending a process backwards to encircle the obliterated umbilical vein (the round ligament of the liver), forming the falciform or longitudinal ligament of the liver. Continuing its course to the right, it is reflected over the front of the upper part of the right kidney, across the vena cava inferior and aorta, and over the left kidney

FIG. 592.—Transverse section of peritoneum.



to the hilum of the spleen, forming the anterior layer of the *lieno-renal ligament*: the posterior layer being formed by the termination of the *cul-de-sac* of the greater cavity between the kidney and spleen (fig. 592). From the hilum of the spleen it is reflected on to the posterior surface of the stomach; at the point where it is reflected it comes in contact with the *cul-de-sac* of the greater cavity between the spleen and stomach, and forms the *gastro-splenic omentum*. It covers the posterior surface of the stomach, and from its right extremity it passes around the vessels to the transverse fissure of the liver, and back again to the stomach, as the lesser omentum, and thus it forms the anterior boundary of the foramen of Winslow. It now covers the front of the stomach, and upon reaching the cardiac extremity it passes to the spleen, which it encloses, forming the gastro-splenic omentum. From the hilum of the spleen it turns backwards to reach the abdominal wall, along which it courses to reach the median line of the abdomen.

The *foramen of Winslow* is bounded, *in front*, by the lesser omentum, enclosing



the vena portæ and the hepatic artery and duct; *behind*, by the inferior vena cava; *above*, by the lobulus Spigelii and lobulus caudatus; *below*, by the hepatic artery curving forwards from the celiac axis.

The reflections of the peritoneum over the transverse colon are somewhat differently described by some authors (Luschka, Holden), and there is no doubt, as was long ago pointed out by Haller, that the arrangement in the fœtus is different from that which has been described above. In the fœtus, and even in the young child, the two ascending layers of the great omentum can be traced passing together *over* the transverse colon, instead of embracing it, as described above, and passing back to the spine as a double fold, which can be separated from the transverse colon and transverse meso-colon. Upon reaching the spine the two layers separate: the upper one (the inner of the two ascending layers of the great omentum) passes upwards in front of the pancreas and crura of the Diaphragm, forming the posterior boundary of the lesser bag of the peritoneum, in a similar manner to the upper layer of the transverse meso-colon in the former description. The other fold (the outer of the ascending layer of the great omentum), after reaching the spine, is turned forwards again on itself as far as the transverse colon, which it covers, and is again reflected back to the spine, to pass down in front of the aorta to form the mesentery, in a similar manner to the lower layer of the transverse meso-colon in the former description. Thus the transverse colon is invested by a distinct fold of peritoneum, prolonged forwards from the spine to surround it, in a very similar manner to the way in which the small intestines are surrounded.

In the adult, however, as a rule, this arrangement disappears. Probably adhesion of the layers of which the fœtal duplication is composed takes place, and then absorption, and thus the arrangement is brought about which has been described above as most frequently seen in the adult subject. It may be that the fœtal duplicature is 'drawn or pushed forwards from its place in the progress of visceral development, and thus effaced.'\*

*Viscera covered by peritoneum.*—The viscera thus shown to be almost entirely invested by peritoneum are, the liver, stomach, spleen, first portion of the duodenum, the jejunum and ileum, the transverse colon, the cæcum, sigmoid flexure, upper half of the rectum, the uterus, and ovaries.

*Viscera partially covered by peritoneum.*—The viscera only partially invested by peritoneum are, the descending and transverse portions of the duodenum, the ascending and descending colon, the middle portion of the rectum, and the upper part of the vagina and posterior wall of the bladder. The kidneys, suprarenal capsules, and pancreas are covered by the membrane without receiving any special investment from it.

*Viscera uncovered by peritoneum.*—The lower end of the rectum, the neck base, and anterior surface of the bladder, the whole of the front, and the lower part of the posterior wall of the vagina, have no peritoneal covering.

Numerous folds are formed by the peritoneum, extending between the various organs. These serve to hold them in position, and, at the same time, enclose the vessels and nerves proceeding to each part. Some of these folds are called *ligaments*, from their serving to support the organs in position. Others, which connect certain parts of the intestine with the abdominal wall, constitute the *mesenteries*; and lastly, those which proceed from the stomach to certain viscera in its neighbourhood are called *omenta*.

The **Ligaments**, formed by folds of the peritoneum, include those of the liver, spleen, bladder, and uterus. They will be found described with their respective organs.

The **Omenta** are, the lesser omentum, the great omentum, and the gastro-splenic omentum.

The *lesser omentum (gastro-hepatic)* is the duplicature which extends between

\* Quain's *Anatomy*, vol. ii. p. 485, 8th ed.

the transverse fissure of the liver and the lesser curvature of the stomach. It is extremely thin, and consists of two layers of peritoneum; that is, the two layers covering the anterior and posterior surfaces of the stomach. When these two layers reach the lesser curvature of the stomach, they join together and ascend as the double fold to the transverse fissure of the liver; to the left of this fissure the double fold is attached to the fissure of the ductus venosus as far as the Diaphragm, on which it extends to the œsophagus. The two layers here separate to embrace the end of the œsophagus. At the right border the lesser omentum is free, and the two layers of which it is composed are continuous. The anterior layer, which belongs to the greater sac, turns round the hepatic vessels to become continuous with the posterior layer belonging to the lesser one. They here form a free, rounded margin, which contains between its layers the hepatic artery, the common bile-duct, the portal vein, lymphatics, and the hepatic plexus of nerves—all these structures being enclosed in loose areolar tissue, called *Glisson's capsule*. Between the layers where they are attached to the stomach lie the gastric artery and the pyloric branch of the hepatic, anastomosing with it.

The *great omentum (gastro-colic)* is the largest peritoneal fold. It consists of four layers of peritoneum, two of which descend from the stomach, one from its anterior, the other from its posterior surface, and, uniting at its lower border, descend in front of the small intestines, as low down as the pelvis; they then turn upon themselves, and ascend again as far as the transverse colon, where they separate and enclose that part of the intestine. These separate layers may be easily demonstrated in the young subject, but in the adult they are more or less inseparably blended. The left border of the great omentum is continuous with the gastro-splenic omentum; its right border extends as far only as the duodenum. The great omentum is usually thin, presents a cribriform appearance, and always contains some adipose tissue, which in fat subjects accumulates in considerable quantity. Its use appears to be to protect the intestines from the cold, and to facilitate their movement upon each other during their vermicular action. Between its two anterior layers is the anastomosis between the right and left gastro-epiploica arteries.

The *gastro-splenic omentum* is the fold which connects the concave surface of the spleen to the *cul-de-sac* of the stomach, being continuous by its lower border with the great omentum. It contains *vasa brevia* vessels.

The **Mesenteries** are, the mesentery proper, the meso-cæcum, the ascending, transverse, and descending meso-colon, the sigmoid meso-colon, and the meso-rectum.

The *mesentery (μέσον, ἔντερον)*, so called from being connected to the middle of the cylinder of the small intestine, is the broad fold of peritoneum which connects the convolutions of the jejunum and ileum with the posterior wall of the abdomen. Its *root*, the part connected with the vertebral column, is narrow, about six inches in length, and directed obliquely from the left side of the second lumbar vertebra to the right sacro-iliac symphysis (fig. 593). Its intestinal border is much longer; and here its two layers separate, so as to enclose the intestine, and form its peritoneal coat. Its breadth, between its vertebral and intestinal border, is about four inches. Its *upper border* is continuous with the under surface of the transverse meso-colon: its *lower border*, with the peritoneum covering the cæcum and ascending colon. It serves to retain the small intestines in their position, and contains between its layers the mesenteric vessels and nerves, the lacteal vessels, and mesenteric glands.

The *meso-cæcum* serves to connect the back part of the cæcum with the posterior wall of the abdomen, being continuous with the ascending meso-colon.

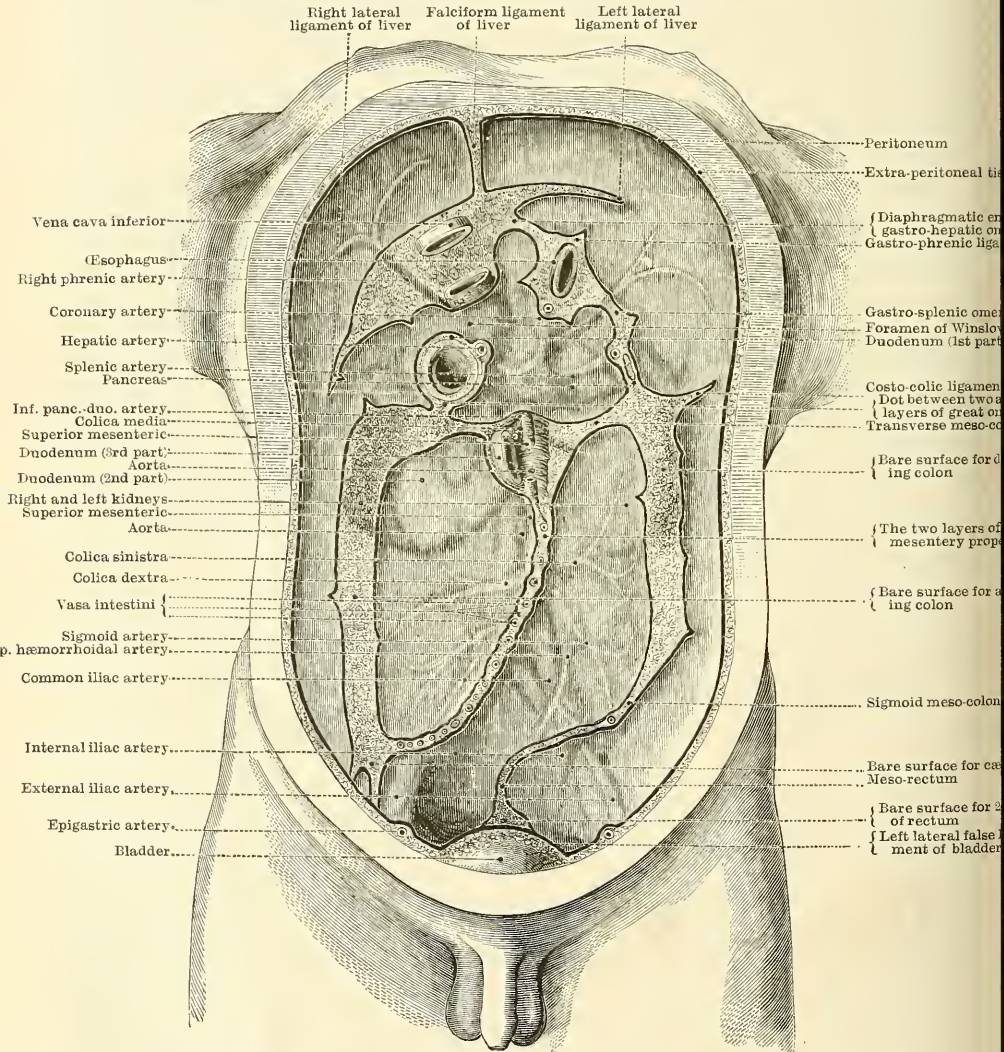
The *ascending meso-colon* is the fold which connects the back part of the ascending colon with the posterior wall of the abdomen; and the *descending meso-colon* retains the descending colon in connection with the posterior abdominal wall; more frequently the peritoneum merely covers the anterior surface and



sides of these two portions of the intestine. At the place where the transverse colon turns downwards to form the descending colon, a fold of peritoneum is continued upwards to the under surface of the Diaphragm opposite the tenth and eleventh ribs. This is the *phreno-colic ligament*; it passes below the spleen, and serves to support this organ and prevent it moving.

The *transverse meso-colon* is a broad fold, which connects the transverse colon to the posterior wall of the abdomen. It is formed by the two ascending layers of the great omentum, which, after separating to surround the transverse colon,

FIG. 593.—Diagram devised by Dr. Delépine to show the lines along which the peritoneum leaves the wall of the abdomen to invest the viscera.



join behind it, and are continued backwards to the spine, where they diverge in front of the duodenum. This fold contains between its layers the vessels which supply the transverse colon.

The *sigmoid meso-colon* is the fold of peritoneum which retains the sigmoid flexure in connection with the left iliac fossa.

The *meso-rectum* is the narrow fold which connects the upper part of the rectum with the front of the sacrum. It contains the superior hæmorrhoidal vessels.

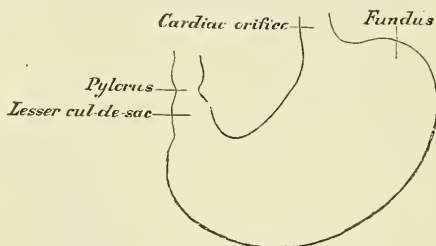


The *appendices epiploicae* are small pouches of the peritoneum filled with fat, and situated along the colon and upper part of the rectum. They are chiefly appended to the transverse colon.

### THE STOMACH

The **Stomach** is the principal organ of digestion. It is the most dilated part of the alimentary canal. Its form is somewhat pyriform, curved upon itself, and presenting a rounded base, turned to the left side. It is placed, in part, immediately behind the anterior wall of the abdomen, and, in part, beneath the liver and Diaphragm and above the transverse colon. It is placed almost vertically in the abdomen, with a slight obliquity from left to right, so that the fundus projects upwards and to the left of the oesophageal opening touches the Diaphragm, while the pyloric or lesser extremity is directed downwards and to the right, so that the opening by which the stomach communicates with the small intestine is situated slightly to the right of the median line of the body (fig. 594): the stomach is situated, therefore, for the most part, in the left hypochondriac region; the pyloric extremity occupying, however, the epigastric region. Its size varies considerably in different subjects, and also according to its state of distension. When moderately full its vertical diameter is about twelve inches, its transverse diameter about four. Its weight, according to Clendenning, is about four ounces and a half. It presents for examination two extremities, two orifices, two borders, and two surfaces.

FIG. 594.—Diagrammatic outline of the stomach.



Its *upper extremity* is called the *greater* or *splenic end*. This is the largest part of the stomach, and extends two or three inches to the left of the point of entrance of the oesophagus. This expanded part is called the *great cul-de-sac* or *fundus*. It lies behind the lower ribs, in contact with the Diaphragm, and is connected posteriorly to the spleen by the gastro-splenic omentum.

The *lesser* or *pyloric end* is much smaller than the fundus, and situated on a plane anterior and inferior to it. It lies in contact with the wall of the abdomen, and the under surface of the liver. Its position on the surface of the body varies with the degree of distension of the organ. Near the pyloric end there is a double bend in the stomach, attended by an appearance of constriction. The distal bend corresponds to the situation of the pyloric valve, and between the two there is a bulging which is named the *lesser cul-de-sac* or *antrum pylori*.

The *oesophageal* or *cardiac orifice* communicates with the oesophagus, and is the most fixed part of the stomach. It is situated on a level with the spine of the ninth dorsal vertebra; in front and to the left of the aorta.

The *pyloric orifice* communicates with the duodenum, the aperture being guarded by a valve, the pylorus. This valve is formed by a thickening of the circular muscular fibres of the stomach in this situation; they form a thick ring, which can be felt from the outside. The mucous membrane is also thickened where it is pushed in by the ring of muscular tissue. The position of the pylorus varies with the movements of the stomach.

The *lesser curvature* extends between the oesophageal and pyloric orifices, along the right border of the organ, and is connected to the under surface of the liver by the lesser omentum.

The *greater curvature* extends between the same two points, along the left border, and gives attachment to the great omentum. The surfaces of the organ are limited by these two curvatures.

The *anterior surface* is directed upwards and forwards, and is in relation

with the Diaphragm, the under surface of the left lobe of the liver, and with the abdominal parietes when distended.

The *posterior surface* is directed downwards and backwards, and is in relation with the Diaphragm, the spleen, the pancreas, the left kidney and suprarenal capsule, and the transverse meso-colon, which separates it from the termination of the duodenum and commencement of the rest of the small intestine.

The stomach is held in position by the lesser omentum, which extends from the transverse fissure of the liver to its lesser curvature, and by a fold of peritoneum, which passes from the Diaphragm on to the œsophageal end of the stomach, the *gastro-phrenic ligament*: this constitutes the most fixed point of the stomach, whilst the pyloric end and greater curvature are the most movable parts. To its greater curvature is attached the great omentum, by which it is connected to the transverse colon.

*Alterations in Position.*—There is no organ in the body the position and connections of which present such frequent alterations as the stomach. *When empty*, it lies at the back part of the abdomen, some distance from the surface. Its pyloric end is situated close to or very slightly to the right of the middle line, covered in front by the left lobe of the liver, and being on a level with the first lumbar vertebra. The direction of the long axis of the stomach, whilst in this condition, is a disputed point, some anatomists asserting that it is vertical, but the majority of authorities are agreed in maintaining that there is always a certain, though varying, obliquity from left to right. When empty, the stomach assumes a more or less cylindrical form, especially noticeable at its pyloric end. *When the stomach is distended*, its surfaces, which are flattened when the organ is empty, become convex. The greater curvature is elevated and carried forwards, so that the anterior surface is turned more or less upwards and the posterior surface downwards, and the stomach brought well against the anterior wall of the abdomen. Its fundus expands and rises considerably above the level of the cardiac orifice, in doing this the Diaphragm is forced upwards, contracting the cavity of the chest; hence the dyspnoea complained of, from inspiration being impeded. The apex of the heart is also tilted upwards; hence the oppression in this region and the palpitation experienced in extreme distension of the stomach. The left lobe of the liver is pushed to the right side. When the stomach becomes distended the change in the position of the pylorus is very considerable; it is shifted to the right, some two or three inches from the median line, and lies under cover of the liver, near the neck of the gall-bladder. In consequence of the distension of the stomach the lesser *cul-de-sac* bulges over the pylorus, concealing it from view, and causing it to undergo a rotation, so that its orifice is directed backwards. *During inspiration* the stomach is displaced downwards by the descent of the Diaphragm, and elevated by the pressure of the abdominal muscles during expiration. *Pressure from without*, as from tight lacing, pushes the stomach down towards the pelvis. In disease, also, the position and connection of the organ may be greatly changed, from the accumulation of fluid in the chest or abdomen, or from alteration in size of any of the surrounding viscera. *Variations according to age.*—In an early period of development the stomach is vertical, and in the new-born child it is more vertical than later on in life, as owing to the large size of the liver it is more pushed over to the left side of the abdomen, and the whole of the anterior surface is covered by the left lobe of this organ.

On looking into the pyloric end of the stomach, the mucous membrane is found projecting inwards in the form of a circular fold, the *pylorus*, leaving a narrow circular aperture, about half an inch in diameter, by which the stomach communicates with the duodenum.

The *pylorus* is formed by a reduplication of the mucous membrane of the stomach, containing numerous muscular fibres, which are aggregated into a thick circular ring; the longitudinal fibres and serous membrane being continued over the fold without assisting in its formation. The aperture is occasionally oval. Sometimes the circular fold is replaced by two crescentic folds, placed one above and the other below the pyloric orifice: and more rarely there is only one crescentic fold.

**Structure.**—The stomach consists of four coats: serous, muscular, areolar, and mucous, together with vessels and nerves.

The *serous coat* is derived from the peritoneum, and covers the entire surface of the organ, excepting along the greater and lesser curvatures, at the points of attachment of the greater and lesser omenta; here the two layers of peritoneum leave a small triangular space, along which the nutrient vessels and nerves



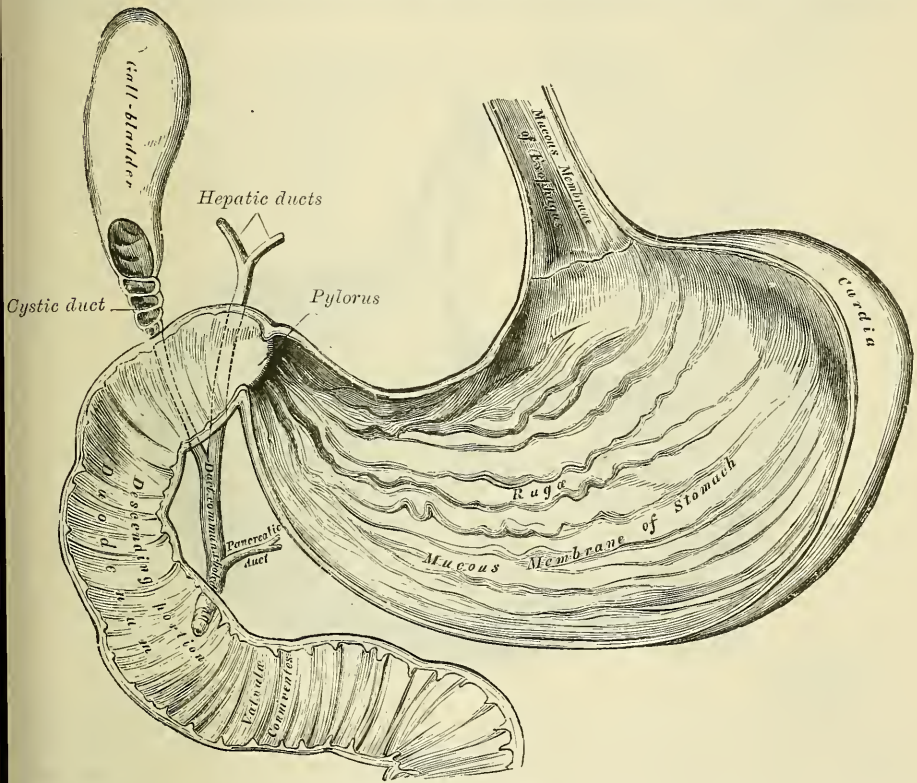
pass. On the posterior surface of the stomach, close to the cardiac orifice there is also a small area uncovered by peritoneum, where the organ is in contact with the under surfaces of the Diaphragm.

The *muscular coat* (fig. 596) is situated immediately beneath the serous covering. It consists of three sets of fibres—longitudinal, circular, and oblique.

The *longitudinal fibres* are most superficial; they are continuous with the longitudinal fibres of the œsophagus, radiating in a stellate manner from the cardiac orifice. They are most distinct along the curvatures, especially the lesser, but are very thinly distributed over the surfaces. At the pyloric end they are more thickly distributed, and continuous with the longitudinal fibres of the small intestine.

The *circular fibres* form a uniform layer over the whole extent of the stomach beneath the longitudinal fibres. At the pylorus they are most

FIG. 595.—The mucous membrane of the stomach and duodenum with the bile ducts.



abundant, and are aggregated into a circular ring, which projects into the cavity, and forms, with the fold of mucous membrane covering its surface, the *pyloric valve*.

The *oblique fibres* are limited chiefly to the cardiac end of the stomach, where they are disposed as a thick uniform layer, covering both surfaces, some passing obliquely from left to right, others from right to left, round the cardiac end. They are continuous with the circular fibres of the œsophagus.

The *areolar* or *submucous coat* consists of a loose, filamentous, areolar tissue, connecting the mucous and muscular layers. It supports the blood-vessels previous to their distribution to the mucous membrane: hence it is sometimes called the *vascular coat*.

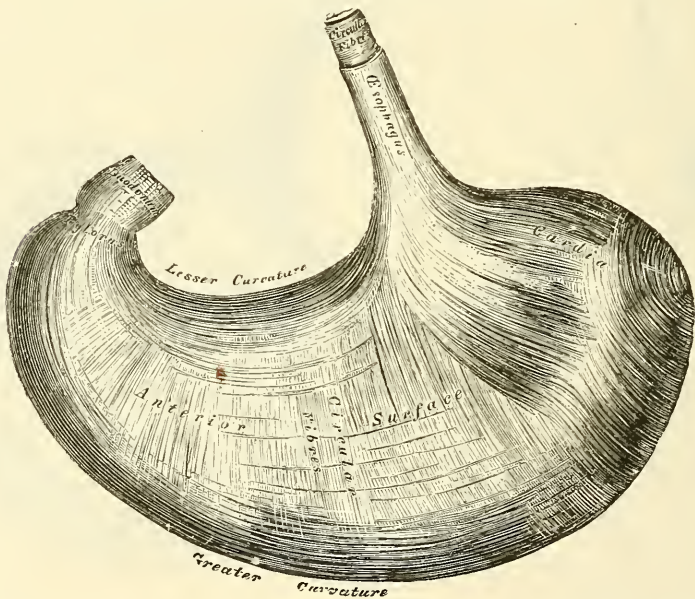
The *mucous membrane* is thick; its surface smooth, soft, and velvety. In the fresh state it is of a pinkish tinge at the pyloric end, and of a red or reddish-



brown colour over the rest of its surface. In infancy it is of a brighter hue, the vascular redness being more marked. It is thin at the cardiac extremity, but thicker towards the pylorus. During the contracted state of the organ it is thrown into numerous plaits or rugæ, which, for the most part, have a longitudinal direction, and are most marked towards the lesser end of the stomach, and along the greater curvature (fig. 595). These folds are entirely obliterated when the organ becomes distended.

*Structure of the Mucous Membrane.*—When examined with a lens, the inner surface of the mucous membrane presents a peculiar honeycomb appearance from being covered with small shallow depressions or alveoli, of a polygonal or hexagonal form, which vary from  $\frac{1}{100}$  to  $\frac{1}{200}$  of an inch in diameter, and are separated by slightly elevated ridges. In the bottom of the alveoli are seen the orifices of minute tubes, the *gastric follicles*, which are situated perpendicularly side by side throughout the entire substance of the mucous membrane. The epithelium which covers the surface of the mucous membrane of the stomach is a single layer of columnar epithelium, it lines the alveoli and also for

FIG. 596.—The muscular coat of the stomach.



a certain distance the mouths of the gastric follicles. This epithelium commences very abruptly at the cardiac orifice, where the cells suddenly change in character from the stratified epithelium of the œsophagus. The cells are elongated and consist of two parts, the inner or attached portions being granular, and the outer or free parts being clear and occupied by a muco-albuminous substance.

The gastric follicles are of two kinds, which differ from each other in structure, and it is believed also in the nature of their secretion. They are named respectively *pyloric* and *cardiac oxyntic glands*. They are both tubular in character, and are formed of a delicate basement membrane, supporting epithelium. The basement membrane consists of flattened transparent endothelial cells, with processes which extend and support the epithelium. The *pyloric glands* (fig. 597) are most numerous at the pyloric end of the stomach, and from this fact have received their name. They were formerly termed mucous glands, and were supposed to secrete mucus; but, as Klein points out, 'the cells are serous, not mucous, and the secretion of the glands cannot therefore be mucus.' They consist of two or three short, closed tubes opening into a common duct, the external orifice of which is situated at the bottom of an alveolus. The cæcal

tubes are wavy, and are of about equal length with the duct. The tubes and duct are lined throughout with epithelium, the duct being lined by columnar cells, continuous with the epithelium lining the surface of the mucous membrane of the stomach, the tubes with shorter and more cubical cells which are finely granular. The *cardiac glands* (fig. 598) are found all over the surface of the stomach, but occur most numerous at the cardiac end. Like the pyloric glands they consist of a duct, into which open two or more caecal tubes. The duct, however, in these glands is shorter than in the other variety, sometimes not amounting to more than one-sixth of the whole length of the gland; it is lined throughout by columnar epithelium. At the point where the terminal tubes open into the duct, and which is termed the neck, the epithelium alters, the cells becoming much shorter, polyhedral and granular, and almost fill the tubercle, so that the lumen becomes suddenly constricted, and is continued down as a very fine channel. They are known as the *chief cells* or *central cells* of the glands.

FIG. 597.—Pyloric gland.

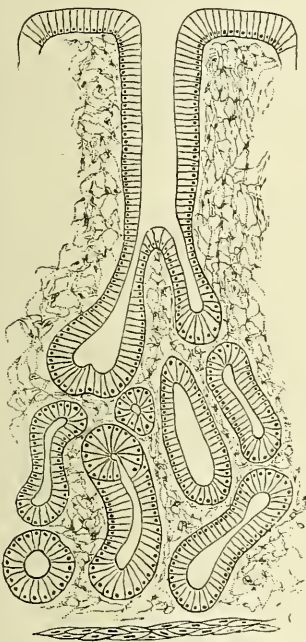
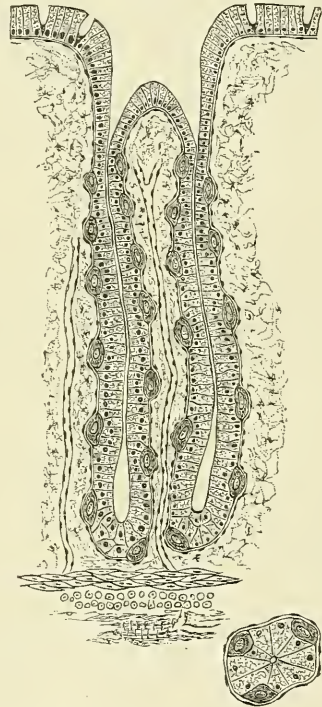


FIG. 598.—Cardiac gland.



Between these cells and the basement membrane are found other darker granular-looking cells, studded throughout the tube at intervals, and giving it a beaded or varicose appearance. These are known as the *parietal* or *oxyntic* cells. Between the glands the mucous membrane consists of a connective-tissue framework, with lymphoid tissue. In places, this latter tissue, especially in early life, is collected into little masses, which to a certain extent resemble the solitary glands of the intestine, and are by some termed the *lenticular* glands of the stomach. They are not, however, so distinctly circumscribed as the solitary glands. Beneath the mucous membrane, and between it and the submucous coat, is a thin stratum of involuntary muscular fibre (*muscularis mucosæ*), which in some parts consists only of a single longitudinal layer; in others of two layers, an inner, circular, and an outer, longitudinal.

**Vessels and Nerves.**—The arteries supplying the stomach are: the gastric, the pyloric and right gastro-epiploic branches of the hepatic, the left gastro-epiploic and vasa brevia from the splenic. They supply the muscular coat, ramify in the



submucous coat, and are finally distributed to the mucous membrane. The arrangement of the vessels in the mucous membrane is somewhat peculiar. The arteries break up at the base of the gastric tubules into a plexus of fine capillaries which run upwards between the tubules, anastomosing with each other, and ending in a plexus of larger capillaries, which surround the mouths of the tubes, and also form hexagonal meshes around the alveoli. From these latter the *veins* arise, and pursue a straight course backwards, between the tubules, to the submucous tissue, and terminate either in the splenic and superior mesenteric veins, or directly in the portal vein. The *lymphatics* are numerous; they consist of a superficial and deep set, which pass through the lymphatic glands found along the two curvatures of the organ. The *nerves* are the terminal branches of the right and left pneumogastric, the former being distributed upon the back, and the latter upon the front part of the organ. A great number of branches from the sympathetic also supply the organ.

*Surface Form.*—The stomach lies for the most part in the left hypochondriac region, but also slightly in the epigastric region, and is partly in contact with the abdominal wall, partly under cover of the lower ribs on the left side, and partly under the left lobe of the liver. Its cardiac orifice is behind the seventh costal cartilage of the left side, about one inch from its junction with the sternum, on a level with the tenth dorsal vertebra. The pyloric orifice is in a vertical line drawn from the right border of the sternum, two and a half or three inches below the level of the sterno-xiphoid articulation. According to Braune, when the stomach is distended, the pylorus moves considerably to the right, as much sometimes as three inches. The lesser curvature of the stomach is represented by a curved line with its convexity downwards from the cardiac to the pyloric extremities; the greater curvature by a similarly curved line between the same points, but with a curve of much greater extent, so that its lowest point reaches a horizontal line drawn between the tips of the tenth costal cartilages. The fundus of the stomach reaches, on the left side, as high as the level of the sixth chondro-sternal articulation, being a little below and behind the apex of the heart. The portion of the stomach which is in contact with the abdominal walls, and is therefore accessible for opening in the operations of gastrotomy and gastrostomy, is represented by a triangular space, the base of which is formed by a line drawn from the tip of the tenth costal cartilage on the left side to the tip of the ninth costal cartilage on the right, and the sides by two lines drawn from the extremity of the eighth costal cartilage on the left side to the ends of the base line.

*Surgical Anatomy.*—Operations on the stomach are frequently performed. By 'gastrotomy' is meant an incision into the stomach for the removal of a foreign body, the opening being immediately afterwards closed—in contradistinction to 'gastrostomy,' the making of a more or less permanent fistulous opening. *Gastrotomy* is probably best performed by an incision in the linea alba, especially if the foreign body is large, by a cut from the ensiform cartilage to the umbilicus; but may be performed by an incision over the body itself, where this can be felt, or by one of the incisions for gastrostomy, to be mentioned immediately. The peritoneal cavity is opened, and the point at which the stomach is to be incised decided upon. This portion is then brought out of the abdominal wound and sponges carefully packed around. The stomach is now opened by a transverse incision and the foreign body extracted. The wound in the stomach is then closed by Lembert's sutures, i.e. by sutures passed through the peritoneal and muscular coats in such a way that the peritoneal surfaces on each side of the wound are brought into apposition, and in this way the wound is closed. *Gastrostomy* is performed in two stages. The first stage consists in opening the peritoneal cavity and stitching the stomach to the abdominal wall. The second stage consists in opening the stomach, after a few days have elapsed, and adhesions formed between the peritoneal surfaces of the stomach and abdominal wall. The operation is usually performed by an oblique incision, about one finger's breadth below and parallel with the margin of the left costal cartilages, commencing an inch and a half from the median line and being about three inches in length. Some surgeons prefer a straight incision, beginning opposite to the end of the eighth intercostal space, and passing down for three inches over the Rectus abdominis muscle. The skin, fasciæ, and muscles are to be severally divided down to the peritoneum. Howse recommends that the sheath of the Rectus should be opened longitudinally and the fibres of this muscle separated, and not cut, in the same direction, so as to secure a sphincter-like action around the opening. After the peritoneum has been opened, the stomach is recognised by its pink red colour and smooth surface. It is to be pulled up into the wound and sutured to the opening. This may be done in several ways, but in whatever way it is done the following points should be carefully attended to. (1) In taking up the stomach, only to pass the needle through the serous and muscular coats, and avoid puncturing the mucous membrane. (2) To take up plenty of the muscular coat. (3) In passing the needle through the parietes of the abdomen, to be careful to include the parietal peritoneum. (4) To enclose a circle of the stomach at least an inch in



diameter. If the symptoms admit of it, the parts are now to be left quiet for four or five days, and a small puncture is then to be made through the exposed portion of the stomach, and a gum elastic catheter passed through it into the viscus, through which fluid can be injected, in small quantities at first. In more urgent cases it may be necessary to make the opening much earlier.

In cases of perforation of gastric ulcer an attempt has been made, in many cases, to close the perforation, and when this has been done before acute peritonitis has actually been established, a very large measure of success has during the last two or three years been obtained. The operation consists in opening the abdomen, and having found the perforation, which is usually on the anterior surface of the stomach, closing it by Lembert's sutures, so that a considerable portion of the peritoneum around the perforation is brought together.

Excision of the pylorus has occasionally been performed, but the results of this operation are by no means favourable, and, in cases of cancer of the pylorus, gastro-enterostomy is generally preferred. The object of this operation is to make a fistulous communication between the stomach, on the cardiac side of the disease, and the small intestine, as high up as is possible.

Digital dilatation of the pylorus for simple stricture was first performed by Loreta. He exposed the stomach and opened it by a transverse incision near the pylorus. He then inserted the forefingers of both hands and passed these through the pylorus and stretched it with some degree of force. The operation has now, however, dropped out of use and been replaced by pyloro-plasty. This operation consists in making a longitudinal incision from the stomach through the pylorus into the duodenum, and converting this longitudinal incision into a transverse one by traction at the centre of the incision, and retaining it permanently in this position by sutures. W. H. Bennett has recently treated dilatation of the stomach by exposing it and making a fold by turning in a portion of the anterior wall and sewing the edges of the fold together.

### THE SMALL INTESTINE

The small intestine is a convoluted tube, about twenty feet in length,\* which gradually diminishes in size from its commencement to its termination. It is contained in the central and lower parts of the abdominal and pelvic cavities, surrounded above and at the sides by the large intestine; it is in relation, in front, with the great omentum and abdominal parietes; and connected to the spine by a fold of peritoneum, the mesentery. The small intestine is divisible into three portions—the duodenum, the jejunum, and ileum.

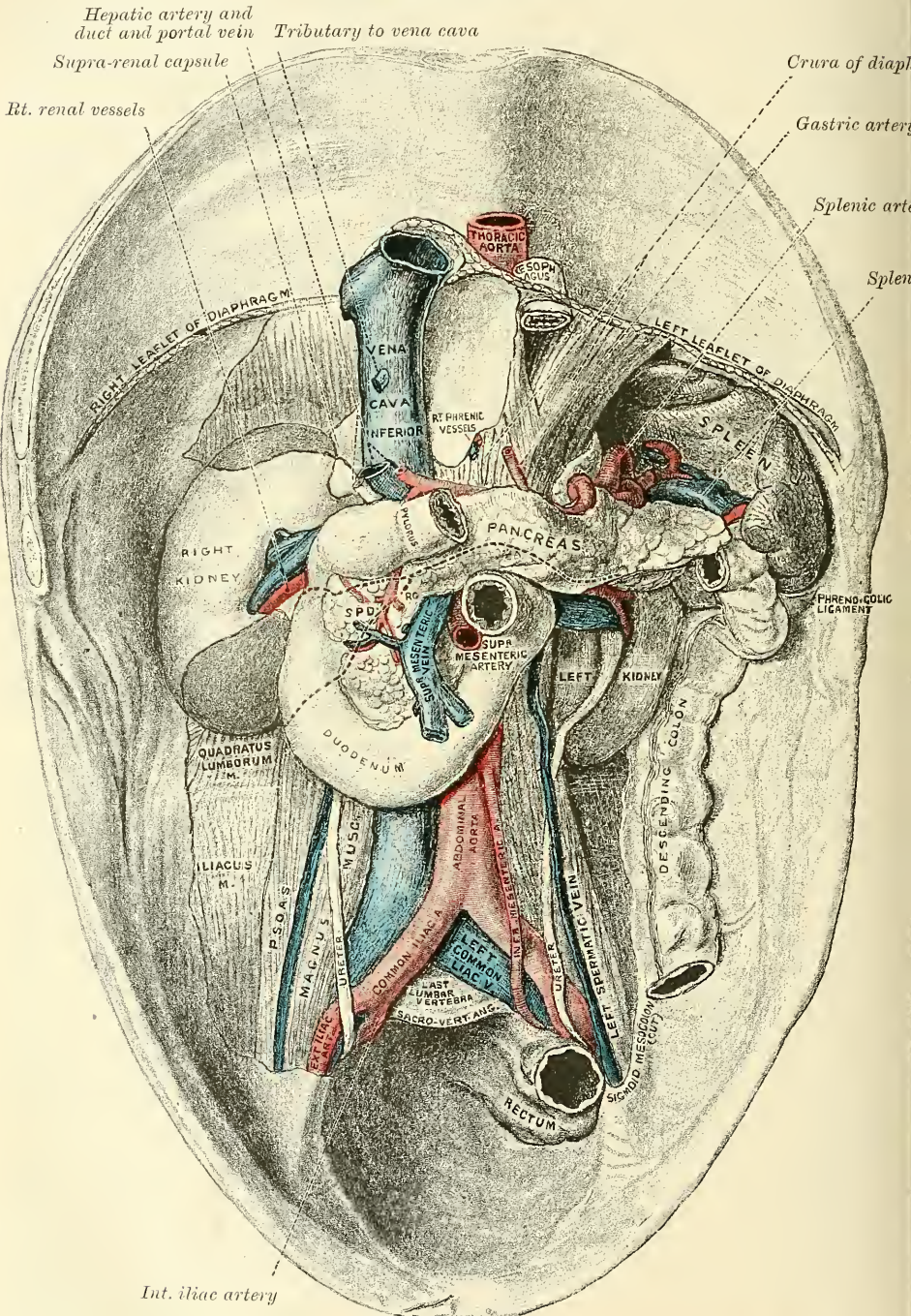
The **duodenum** has received its name from being about equal in length to the breadth of twelve fingers (ten inches). It is the shortest, the widest, and the most fixed part of the small intestine; it has no mesentery, and is only partially covered by the peritoneum. Its course presents a remarkable curve, somewhat like a horseshoe in form, when the stomach is distended, but almost a complete circle when the stomach is empty. The convexity of the curve is directed towards the right and the concavity to the left, embracing the head of the pancreas. Commencing at the pylorus, it passes obliquely upwards and backwards to the right, to the under surface of the liver; it then descends in front of the right kidney to the level of the third lumbar vertebra; it now takes a bend to the left, and passes across the front of the vertebral column from right to left, and finally ascends on the left side of the aorta to the level of the upper border of the second lumbar vertebra, and there terminates in the jejunum. Hence the duodenum may be divided for purposes of anatomical description into four portions—superior, descending, transverse, and ascending.

The first, or *superior portion* (fig. 577), about two inches in length, is free, movable, and completely covered by peritoneum near the pylorus, but only covered in front as it approaches the liver. It varies in direction according to the degree of distension of the stomach. When this organ is empty it commences

\* Treves states that, in one hundred cases, the average length of the small intestine in the adult male was 22 feet 6 inches, and in the adult female 23 feet 4 inches: but that it varies very much, the extremes in the male being 31 feet 10 inches in one case, and 15 feet 6 inches in another, a difference of over 15 feet. He states that he has convinced himself that the length of the bowel is independent, in the adult, of age, height, and weight.

near the middle line of the body and passes obliquely upwards and backwards to the right to the neck of the gall-bladder, where it takes a sudden turn down-

FIG. 599.—Relations of duodenum, pancreas and spleen. From a cast by Professor Birmingham.\*



The dotted line represents the line of attachment of the transverse meso-colon.

wards to become the second portion. When the stomach is distended in consequence of the shifting of the position of the pylorus, the first portion of the

\* In the subject from which the cast was taken the left kidney was lower than normal.



duodenum becomes shortened, and it is directed almost backwards to its termination in the second portion. It is in relation, above and in front, with the quadrate lobe of the liver and the gall-bladder; behind, with the vessels which run between the layers of the lesser omentum, viz. the hepatic artery and duct and vena porta. This portion of the intestine is usually found, after death, stained with bile, especially on its anterior surface.

The second, or *descending portion*, about three inches in length, is firmly fixed by the peritoneum and pancreas. It passes from the neck of the gall-bladder vertically downwards, in front of the right kidney, as far as the third lumbar vertebra. It is covered by peritoneum only on its anterior surface. It is in relation, in front, with the right arch of the colon and the meso-colon; behind, with the front of the right kidney, to which it is connected by loose areolar tissue, and the renal vessels and vena cava inferior; at its inner side is the head of the pancreas, and the ductus communis choledochus. The common bile-duct and the pancreatic duct perforate the inner side of this portion of the intestine obliquely, a little below its middle.

The third, or *transverse portion*, the longest and narrowest part of the duodenum, beginning on the right side of the third lumbar vertebra, passes across the front of the spine, with a slight inclination upward, to the left side, and ends in the fourth portion just to the left of the abdominal aorta. In front it is covered by peritoneum, which in the middle line is separated from the bowel by the superior mesenteric vessels which cross this portion of the duodenum; behind, it rests upon the aorta, the vena cava inferior, and the crura of the Diaphragm; above it is the lower border of the pancreas, the superior mesenteric vessels passing forwards between the two.

The fourth, or *ascending portion*, is from one to two inches long. It ascends on the left side of the vertebral column as far as the level of the upper border of the second lumbar vertebra, where it turns abruptly forwards to become the jejunum. It is covered entirely in front and partly at the sides by peritoneum; on the left side the peritoneum forms a triangular pouch with its base upwards, the *fossa duodeno-jejunalis*. This pouch is of importance in connection with retro-peritoneal hernia. The fourth portion of the duodenum rests on the left Psoas muscle. It is fixed in position by a band which extends upwards from it, obliquely across the aorta to the connective tissue around the celiac axis and the left crus of the Diaphragm, and is termed the *musculus suspensorius duodeni*, from possessing, according to Treitz, plain muscular fibres, mixed with the fibrous tissue of which it is principally made up.

**Vessels and Nerves.**—The *arteries* supplying the duodenum are the pyloric and pancreatico-duodenal branches of the hepatic, and the inferior pancreatico-duodenal branch of the superior mesenteric. The *veins* terminate in the splenic and superior mesenteric. The *nerves* are derived from the solar plexus.

The **jejunum** (*jejunus*, empty), so called from its formerly having been supposed to be empty after death, includes the upper two-fifths of the small intestine below the duodenum. It commences at the duodenum on the left side of the upper border of the second lumbar vertebra, and terminates in the ileum; its convolutions being chiefly confined to the umbilical and left iliac regions. The jejunum is wider, its coats thicker, more vascular, and of a deeper colour than those of the ileum; but there is no characteristic mark to distinguish the termination of the one and the commencement of the other.

The **ileum** ( $\epsilon\lambda\epsilon\upsilon\nu$ , to twist), so called from its numerous coils or convolutions, includes the remaining three-fifths of the small intestine. It occupies chiefly the umbilical, hypogastric, right iliac, and occasionally the pelvic regions, and terminates in the right iliac fossa by opening into the inner side of the commencement of the large intestine. The ileum is narrower, its coats thinner and less vascular than those of the jejunum; a given length of it weighing less than the same length of the jejunum.

**Meckel's diverticulum.**—Occasionally there may be found connected with the



lower part of the ileum, from one to three feet from its termination, a blind diverticulum or tube, varying in length. It is attached to and communicates with the free margin of the bowel by one extremity, and by the other is unattached or may be connected with the abdominal wall or some other portion of the intestine by a fibrous band. This is Meckel's diverticulum, and represents the remains of the vitelline duct, or duct of communication between the umbilical vesicle and the alimentary canal (see page 82).

**Structure.**—The wall of the small intestine is composed of four coats—serous, muscular, areolar, and mucous.

The *serous coat* is derived from the peritoneum. The first or ascending portion of the duodenum is almost completely surrounded by that membrane near its pyloric end, but only in front at the other extremity; the second or descending portion is covered by it only in front; and the third or transverse portion lies behind the peritoneum, which passes over it, without being closely incorporated with the other coats of this part of the intestine, and separated from it in the middle line by the superior mesenteric artery. The remaining portion of the small intestine is surrounded by the peritoneum, excepting along its attached or mesenteric border; here a space is left for the vessels and nerves to pass to the gut.

The *muscular coat* consists of two layers of fibres, an external or longitudinal, and an internal or circular layer. The *longitudinal fibres* are thinly scattered over the surface of the intestine, and are more distinct along its free border. The *circular fibres* form a thick, uniform layer; they surround the cylinder of the intestine in the greater part of its circumference, and are composed of plain muscle cells of considerable length. The muscular coat is thicker at the upper than at the lower part of the small intestine.

The *areolar or submucous coat* connects together the mucous and muscular layers. It consists of loose, filamentous areolar tissue, which forms a nidus for the subdivision of the nutrient vessels, previous to their distribution to the mucous surface.

The *mucous membrane* is thick and highly vascular at the upper part of the small intestine, but somewhat paler and thinner below. It consists of the following structures: next the areolar or submucous coat is a layer of unstriped muscular fibres, the *muscularis mucosæ*; internal to this is a quantity of retiform tissue, enclosing in its meshes lymph-corpuscles, and in which the blood-vessels and nerves ramify. Lastly, a basement membrane, supporting a single layer of epithelial cells, which throughout the intestines are columnar in character. They are granular in appearance, and possess a clear oval nucleus. At their superficial or unattached end they present a distinct layer of highly refracting material, marked by vertical striæ, which were formerly believed to be minute channels, by which the chyle was taken up into the interior of the cell, and by them transferred to the lacteal vessels of the mucous membrane.

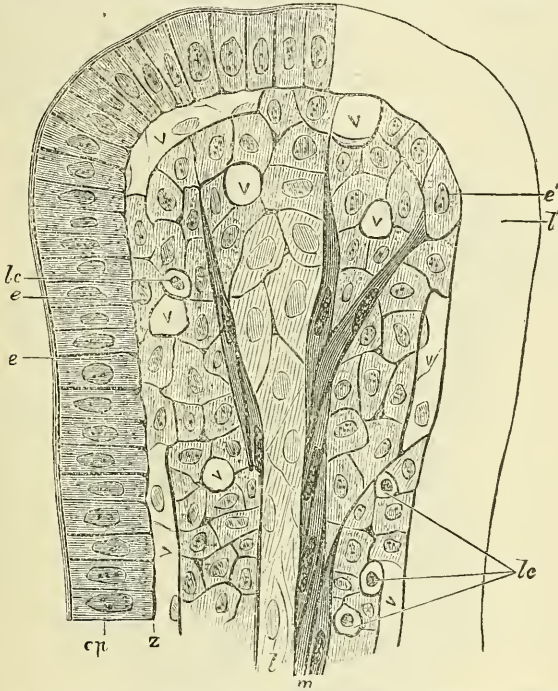
The mucous membrane presents for examination the following structures, contained within it or belonging to it:

Valvulæ conniventes.	Glands	{	Duodenal glands.
Villi.			Solitary glands.
Simple follicles.			Agminate or Peyer's glands.

The **valvulæ conniventes** (valves of Kerkring) are large folds or valvular flaps projecting into the lumen of the bowel. They are composed of reduplications or folds of the mucous membrane, the two layers of the fold being bound together by submucous tissue: they contain no muscular fibres, and therefore, unlike the folds in the stomach, they are permanent, and are not obliterated when the intestine is distended. They extend transversely across the cylinder of the intestine for about one-half or two-thirds of its circumference. The larger folds are about two inches in length, and one-third of an inch in depth at their broadest

part; but the greater number are of smaller size. The larger and smaller folds alternate with each other. They are not found at the commencement of the duodenum, but begin to appear about one or two inches beyond the pylorus. In the lower part of the descending portion, below the point where the common cholemic and pancreatic ducts enter the intestine, they are very large and closely approximated. In the transverse portion of the duodenum and upper half of the jejunum they are large and numerous; and from this point, down to the middle of the ileum, they diminish considerably in size. In the lower part of the ileum they almost entirely disappear; hence the comparative thinness of this portion of the intestine, as compared with the duodenum and jejunum. The valvulae

FIG. 600.—Diagrammatic section of a villus. (Watney.)



*ep.* Epithelium only partially shaded in. *l.* Central chyle-vessel; the cells forming the vessel have been less shaded to distinguish them from the cells of the parenchyma of the villus. *m.* Muscle-fibres running up by the side of the chyle-vessel. It will be noticed that each muscle-fibre is surrounded by the reticulum, and by this reticulum the muscles are attached to the cells forming the membrana propria, as at *e'*, or to the reticulum of the villus. *lc.* Lymph-corpuseles, marked by a spherical nucleus and a clear zone of protoplasm. *v.* Upper limit of the chyle-vessel. *e, e, e'.* Cells forming the membrana propria. It will be seen that there is hardly any difference between the cells of the parenchyma, the endothelium of the upper part of the chyle-vessel, and the cells of the membrana propria. *V.* Blood-vessels. *z.* Dark line at the base of the epithelium formed by the reticulum. It will be seen that the reticulum penetrates between all the other elements of the villus. The reticulum contains thickenings or 'nodal points.' The diagram shows that the cells of the upper part of the villus are larger and contain a larger zone of protoplasm than those of the lower part. The cells of the upper part of the chyle-vessel differ somewhat from those of the lower part, in that they more nearly resemble the cells of the parenchyma.

conniventes retard the passage of the food along the intestines, and afford a more extensive surface for absorption.

The villi are minute, highly vascular processes, projecting from the mucous membrane of the small intestine throughout its whole extent, and giving to its surface a velvety appearance. In shape some are triangular and laminated, others conical or cylindrical, with clubbed or filiform extremities. They are largest and most numerous in the duodenum and jejunum, and become fewer and smaller in the ileum. Krause estimates their number in the upper part of the small intestine at from fifty to ninety in a square line; and in the lower part from forty to seventy; the total number for the whole length of the intestine being about four millions.

**Structure of the villi** (fig. 600).—The structure of the villi has been studied recently by many eminent anatomists. We shall here follow the description of

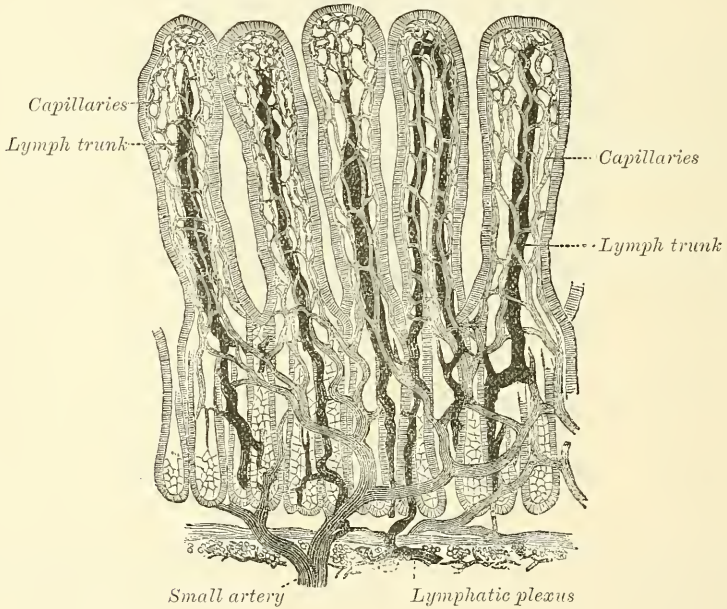


Dr. Watney,\* whose researches have a most important bearing on the physiology of the absorption of fat, which is the peculiar function of this part of the intestine.

The essential parts of a villus are, the lacteal vessel, the blood-vessels, the epithelium, the basement membrane and muscular tissue of the mucosa, these structures being supported and held together by retiform lymphoid tissue.

These structures are arranged in the following manner. Situated in the centre of the villus is the lacteal, terminating near the summit in a blind extremity; running along this vessel are unstriped muscular fibres; surrounding it is a plexus of capillary vessels, the whole being enclosed by a basement membrane, supporting columnar epithelium. Those structures which are contained within the basement membrane—namely, the lacteal, the muscular tissue, and the blood-vessels—are surrounded and enclosed by a delicate reticulum which forms the matrix of the villus, and in the meshes of which are found large flattened cells, with an oval nucleus, and, in smaller numbers, lymph-corpuseles. These latter are to be distinguished from the larger cells of the villus by their behaviour

FIG. 601.—Villi of small intestine. (Cadiat.)



with reagents, by their size, and by the shape of their nucleus, which is spherical. Transitional forms, however, of all kinds are met with between the lymph-corpusele and the proper cells of the villus. Nerve-fibres are contained within the villi: they form ramifications throughout the reticulum.

The *lacteals* are in some cases double, and in some animals multiple. Situated in the axis of the villi, they commence by dilated caecal extremities near to, but not quite at, the summit of the villus. The walls are composed of a single layer of endothelial cells, the interstitial substance between the cells being continuous with the reticulum of the matrix.

The *muscular fibres* are derived from the muscularis mucosæ, and are arranged in longitudinal bundles around the lacteal vessel, extending from the base to the summit of the villus, and giving off, laterally, individual muscle-cells, which are enclosed by the reticulum, and by it are attached to the basement membrane.

The *blood-vessels* form a plexus between the lacteal and the basement membrane, and are enclosed in the reticular tissue. In the interstices of the capillary plexus, which they form, are contained the cells of the villus.

\* *Phil. Trans.* vol. clxvi. pt. ii.



These structures are surrounded by the basement membrane, which is made up of a stratum of endothelial cells, and upon which is placed a layer of columnar epithelium. The reticulum of the matrix is continuous through the basement membrane (that is, through the interstitial substance between the individual endothelial cells) with the interstitial cement-substance of the columnar cells on the surface of the villus. Thus we are enabled to trace a direct continuity between the interior of the lacteal and the surface of the villus by means of the reticular tissue, and it is along this path that, according to Dr. Watney, the chyle passes in the process of absorption by the villi. That is to say, it passes through the interstitial substance between the epithelium cells, through the interstitial substance of the basement membrane, the reticulum of the matrix, and the interstitial substance between the endothelial plates of the lacteal, all which structures have been shown to be continuous with one another, and being probably semi-fluid do not offer any obstacle to the passage of the molecular basis of the chyle.

The **simple follicles**, or *crypts of Lieberkühn* (figs. 602, 603), are found in considerable numbers over every part of the mucous membrane of the small intestine. They consist of minute tubular depressions of the mucous membrane, arranged perpendicularly to the surface, upon which they open by small circular apertures. They may be seen with the aid of a lens, their orifices appearing as minute dots, scattered between the villi. Their walls are thin, consisting of a layer of basement membrane (which is, in fact, an endothelial membrane) lined by columnar epithelium, and covered on their exterior by capillary vessels.

The **duodenal** or **Brunner's glands** are limited to the duodenum and commencement of the jejunum. They are small, flattened, granular bodies, embedded in the submucous areolar tissue, and open upon the surface of the mucous membrane by minute excretory ducts. They are most numerous and largest near the pylorus. They may be compared to the elementary lobules of a salivary gland spread out over a broad surface, instead of being collected in a mass.

FIG. 602.—Transverse section of crypts of Lieberkühn. (Klein and Noble Smith.)

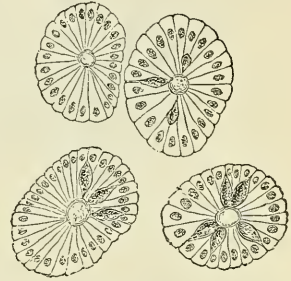
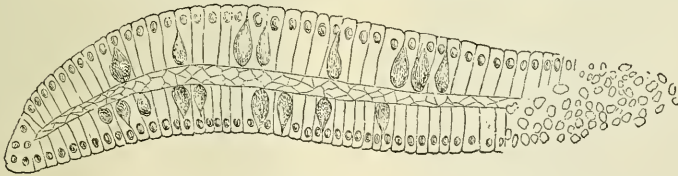


FIG. 603.—Longitudinal section of crypts of Lieberkühn. Goblet-cells seen among the columnar epithelial cells. (Klein and Noble Smith.)

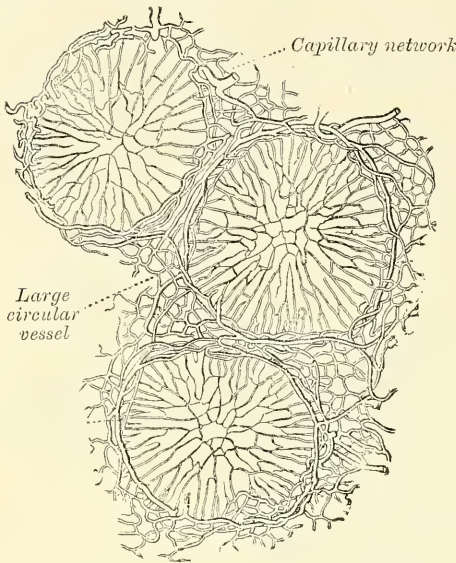


They consist of a number of tubular alveoli, lined by epithelium, and opening by a single duct on the inner surface of the intestine.

The **solitary glands** (*glandulae solitariae*) are found scattered throughout the mucous membrane of the small intestine, but are most numerous in the lower part of the ileum. They are small, round, whitish bodies, from half a line to a line in diameter. Their free surface is covered with villi, and each gland is surrounded by the openings of the follicles of Lieberkühn. They are now recognised as lymph-follicles, and consist of a dense interlacing retiform tissue, closely packed with lymph-corpuscles, and permeated with an abundant capillary network (fig. 604). The interspaces of the retiform tissue are continuous with larger lymph-spaces at the base of the gland through which they communicate

with the lacteal system. They are situated partly in the submucous tissue, partly in the mucous membrane, where they form slight projections of its epithelial layer, after having penetrated the muscularis mucosæ. The villi which

FIG. 604.—Transverse section through the equatorial plane of three of Peyer's follicles from the rabbit.



are situated on them are generally absent from the very summit (or 'cupola,' as Frey calls it) of the gland.

**Peyer's glands** (figs. 604 to 607) may be regarded as aggregations of solitary glands, forming circular or oval patches from twenty to thirty in number, and varying in length from half an inch to four inches. They are largest and most numerous in the ileum. In the lower part of the jejunum they are small, of a circular form, and few in number. They are occasionally seen in the duodenum. They are placed lengthwise in the intestine, covering the portion of the tube most distant from the attachment of the mesentery. Each patch is formed of a group of the above-described solitary glands covered with mucous membrane, and in almost every respect are similar in structure to them. They do not, however, as a

rule, possess villi on their free surface. Each patch is surrounded by a circle of the crypts of Lieberkühn. They are best marked in the young subject, becoming indistinct in middle age, and sometimes altogether disappearing in advanced life. They are largely supplied with blood-vessels, which form an abundant plexus around each follicle, from which fine branches are given off which permeate the lymphoid tissue in the interior of the follicle. The lacteal plexuses which are

FIG. 605.—Patch of Peyer's glands. From the lower part of the ileum.

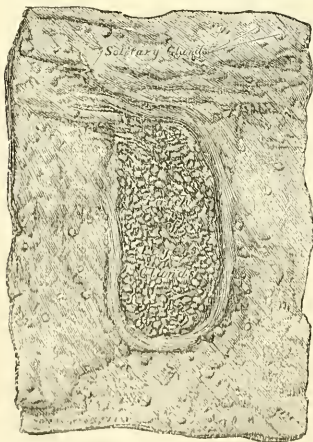
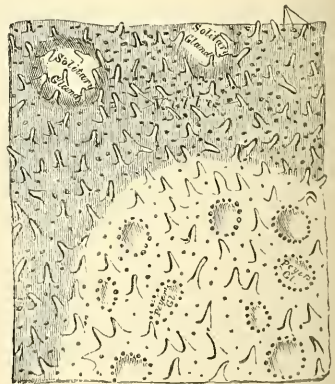


FIG. 606.—A portion of the above magnified.



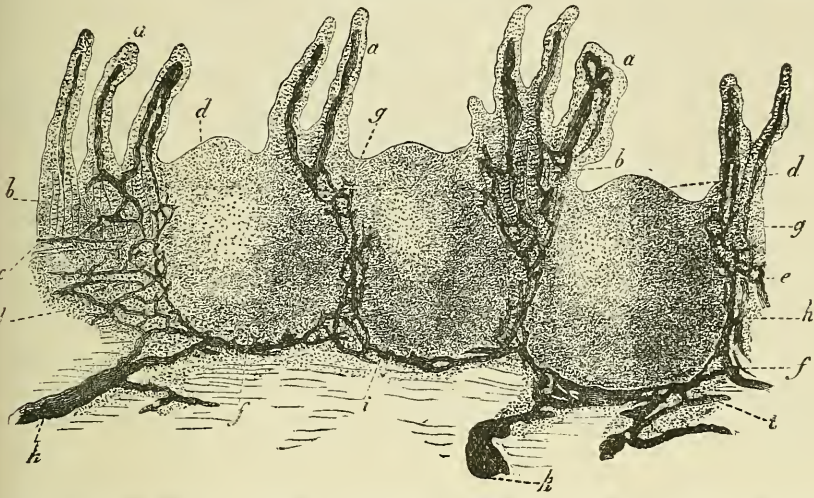
found throughout the small intestine are especially abundant around these patches; here they form rich plexuses with sinuses around the glands (fig. 607).

**Vessels and Nerves.**—The jejunum and ileum are supplied by the superior mesenteric artery, the branches of which, having reached the attached border of the bowel, run between the serous and muscular coats, with frequent inosculation.



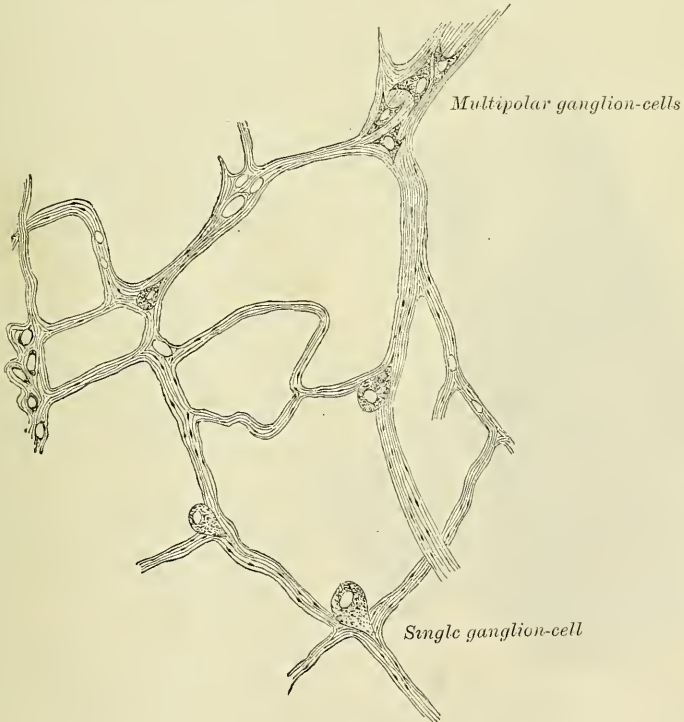
ions to the free border, where they also anastomose with other branches running round the opposite surface of the gut. From these vessels numerous

FIG. 607.—Vertical section of one of Peyer's patches from man, injected through its lymphatic canals.



Villi with their chyle-passages. *b*. Follicles of Lieberkühn. *c*. Muscularis mucosae. *d*. Cupola or apex of solitary glands. *e*. Mesial zone of glands. *f*. Base of glands. *g*. Points of exit of the chyle-passages from the villi, and entrance into the true mucous membrane. *h*. Retiform arrangement of the lymphatics in the mesial zone. *i*. Course of the latter at the base of the glands. *k*. Confluence of the lymphatics opening into the vessels of the submucous tissue. *l*. Follicular tissue of the latter.

FIG. 608.—Meissner's plexus. (Klein and Noble Smith.)



branches are given off, which pierce the muscular coat, supplying it and forming an intricate plexus in the submucous tissue. From this plexus minute vessels pass to the glands and villi of the mucous membrane. The veins have a similar



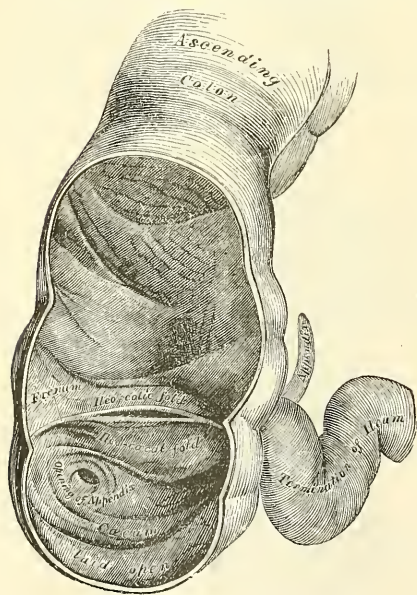
course and arrangement to the arteries. The *lymphatics of the small intestine* (lacteals) are arranged in two sets, those of the villi and those of the muscular coat. The lymphatics of the villi commence in these structures in the manner described above, and form an intricate plexus in the mucous and submucous tissue, being joined by the lymphatics from the lymph-spaces at the bases of the solitary glands, and from this pass to larger vessels at the mesenteric border of the gut. The lymphatics of the muscular coats are situated to a great extent between the two layers of muscular fibres, where they form a close plexus, and throughout their course communicate freely with the lymphatics from the mucous membrane, and empty themselves in the same manner into the commencement of the lacteal vessels at the attached border of the gut.

The *nerves of the small intestines* are derived from the plexuses of sympathetic nerves around the superior mesenteric artery. From this source they run to a plexus of nerves and ganglia situated between the circular and longitudinal muscular fibres (Auerbach's plexus), from which the nervous branches are distributed to the muscular coats of the intestine. From this plexus a secondary plexus is derived (Meissner's plexus), which is formed by branches which have perforated the circular muscular fibres (fig. 608). This plexus lies between the muscular and mucous coats of the intestine. It is also gangliated, and from it the ultimate fibres pass to the muscularis mucosæ and to the villi and mucous membrane.

### THE LARGE INTESTINE

The large intestine extends from the termination of the ileum to the anus. It is about five feet in length, being one-fifth of the whole extent of the intestinal canal. It is largest at its commencement at the cæcum, and gradually diminishes

FIG. 609.—The cæcum and colon laid open to show the ileo-cæcal valve.



as far as the rectum, where there is a dilatation of considerable size just above the anus. It differs from the small intestine in its greater size, its more fixed position, and its sacculated form. The large intestine, in its course, describes an arch, which surrounds the convolutions of the small intestine. It commences in the right inguinal region, in a dilated part, the *cæcum*. It ascends through the right lumbar and hypochondriac regions to the under surface of the liver; passes transversely across the abdomen on the confines of the epigastric and umbilical regions, to the left hypochondriac region; descends through the left lumbar region to the left iliac fossa, where it becomes convoluted, and forms the sigmoid flexure; finally it enters the pelvis, and descends along its posterior wall to the anus. The large intestine is divided into the cæcum, colon, and rectum.

The **cæcum** (*cæcus, blind*) is the large blind pouch, or *cul-de-sac*, in which the large intestine commences (fig. 609). It is the most dilated part of the tube, measuring about two and a half inches, both in its vertical and transverse diameters. Its position varies somewhat; usually it is found lying upon the Psoas muscle, and so placed that its apex or lowest point is just projecting beyond the inner border of that muscle, corresponding to a point a little to the inner side of the middle of Poupart's ligament. Some-

times, however, it is situated external to this, in the right iliac fossa, in relation with the Iliacus muscle; and at other times it lies internal to both Psoas and Iliacus, either resting on the pelvic brim, or altogether contained within the pelvis. It is entirely enveloped on all sides by peritoneum, which, after enclosing it, is reflected on to the posterior wall of the abdomen, being continuous with the ascending meso-colon, when this fold exists. The cæcum, therefore, lies quite free in the abdominal cavity, and enjoys a considerable amount of movement. On its inner side it is joined by the ileum, while attached to its lower and back part is the appendix vermiformis.

The **appendix vermiformis** is a long, narrow, worm-shaped tube, the rudiment of the lengthened cæcum found in nearly all the mammalia. The appendix varies from three to six inches in length, its average diameter being about equal to that of a goose-quill. It is usually directed upwards and inwards behind the cæcum, coiled upon itself, and terminates in a blunt point; being retained in its position by a fold of peritoneum, which sometimes forms a mesentery for it. Its canal is small, and communicates with the cæcum by an orifice, which is placed below and behind that of the ileum. It is sometimes guarded with an incomplete valve formed of a fold of mucous membrane. Its coats are thick, and its mucous lining furnished with a large number of solitary glands.

In the neighbourhood of the cæcum, and especially in the vicinity of the ileo-cæcal valve, are certain pouches of peritoneum or fossæ, which are of surgical importance. Three of these fossæ may be mentioned. The *ileo-colic fossa* (superior ileo-cæcal) is situated at the junction of the ileum and colon, in the angle between the ascending colon which forms the outer boundary of the pouch, and the ileum which forms the lower boundary. Often a fold of peritoneum, arching over a branch of the ileo-colic artery, roofs in this angle and thus forms a pouch, the floor of which is formed by the mesentery. The *ileo-cæcal fossa* (inferior ileo-cæcal) is situated behind the angle of junction of the ileum and cæcum. It is formed by a fold of peritoneum (ileo-cæcal fold), which extends from the border of the ileum, and, passing over the ileo-cæcal junction, joins the mesentery of the appendix. Between this fold and the appendix is the fossa, which is bounded to the right by the ascending meso-colon, and to the left by the mesentery. It may extend a considerable distance upwards, behind and parallel with the colon. The *subcæcal fossa* (retro-cæcal) is situated immediately beneath the cæcum, which has to be raised to bring it into view. It lies close to the ileo-cæcal fossa, from which it is separated by the meso-cæcum and ascending meso-colon. It is not so constant as either the ileo-cæcal or ileo-colic fossæ.

Hernia of the vermiform appendix into one of these pouches frequently takes place, when it is often concealed and might escape the search of the surgeon were he not familiar with their existence. Moreover, a herniated appendix into one of these pouches is very liable to become strangulated. The presence of these pouches also explains the course which pus has been known to take in cases of perforation of the appendix, where it travels upwards behind the ascending colon as far as the Diaphragm.\*

**Ileo-cæcal valve.**—The lower end of the ileum terminates at the inner and back part of the large intestine, opposite the junction of the cæcum with the colon. At this point the mucous membrane forms two valvular folds, which project into the large intestine, and are separated from each other by a narrow elongated aperture. These folds form the ileo-cæcal valve (*valvula Bauhini*). Each fold is semilunar in form. The upper one, nearly horizontal in direction, is attached by its convex border to the point of junction of the ileum with the colon; the lower segment, to the point of junction of the ileum with the cæcum. Their free concave margins project into the intestine, separated from one another by a narrow slit-like aperture, directed transversely. At each end of this

\* On the anatomy of these fossæ, see a paper by Dr. Rolleston and Mr. Lockwood, *Journal of Anatomy and Physiology*, vol. xxvi. p. 130.



aperture the two segments of the valve coalesce, and are continued as a narrow membranous ridge around the canal of the intestine for a short distance, forming the *fræna*, or *retinacula*, of the valve. The left or anterior end of this aperture is rounded; the right or posterior end is narrow and pointed.

Each segment of the valve is formed by a reduplication of the mucous membrane and of the circular muscular fibres of the intestine, the longitudinal fibres and peritoneum being continued uninterruptedly across from one intestine to the other. When these are divided or removed, the ileum may be drawn outwards, and all traces of the valve will be lost, the ileum appearing to open into the large intestine by a funnel-shaped orifice of large size.

The surface of each segment of the valve directed towards the ileum is covered with villi, and presents the characteristic structure of the mucous membrane of the small intestine; whilst that turned towards the large intestine is destitute of villi, and marked with the orifices of the numerous tubular glands peculiar to the membrane in the large intestine. These differences in structure continue as far as the free margin of the valve.

When the cæcum is distended, the margins of the opening are approximated so as to prevent any reflux into the ileum.

The **colon** is divided into four parts—the ascending, transverse, descending, and the sigmoid flexure.

The **ascending colon** is smaller than the cæcum. It passes upwards, from its commencement at the cæcum, opposite the ileo-cæcal valve, to the under surface of the liver, on the right of the gall-bladder, where it bends abruptly inwards to the left, forming the *hepatic flexure*. It is retained in contact with the posterior wall of the abdomen by the peritoneum, which covers its anterior surface and sides, its posterior surface being connected by loose areolar tissue with the *Quadratus lumborum*, right kidney, and descending portion of the duodenum (figs. 610 and 611): sometimes the peritoneum almost completely invests it, and forms a distinct but narrow meso-colon.\* It is in relation, in front, with the convolutions of the ileum and the abdominal parietes; behind it lies on the *Quadratus lumborum* muscle, right kidney and descending portion of the duodenum.

The **transverse colon**, the longest part of the large intestine, passes transversely from right to left across the abdomen, opposite the confines of the epigastric and umbilical zones, into the left hypochondriac region, where it curves downwards beneath the lower end of the spleen, forming the *splenic flexure*. In its course it describes an arch, the concavity of which is directed backwards towards the vertebral column and a little upwards; hence the name *transverse arch* of the colon. This is the most movable part of the colon, being almost completely invested by peritoneum, and connected to the spine behind by a large and wide duplicature of that membrane, the *transverse meso-colon*. It is in relation, by its upper surface, with the liver and gall-bladder, the great curvature of the stomach, and the lower end of the spleen; by its under surface, with the small intestines; by its anterior surface with the anterior layers of the great omentum and the abdominal parietes; by its posterior surface with the transverse meso-colon and third portion of the duodenum.

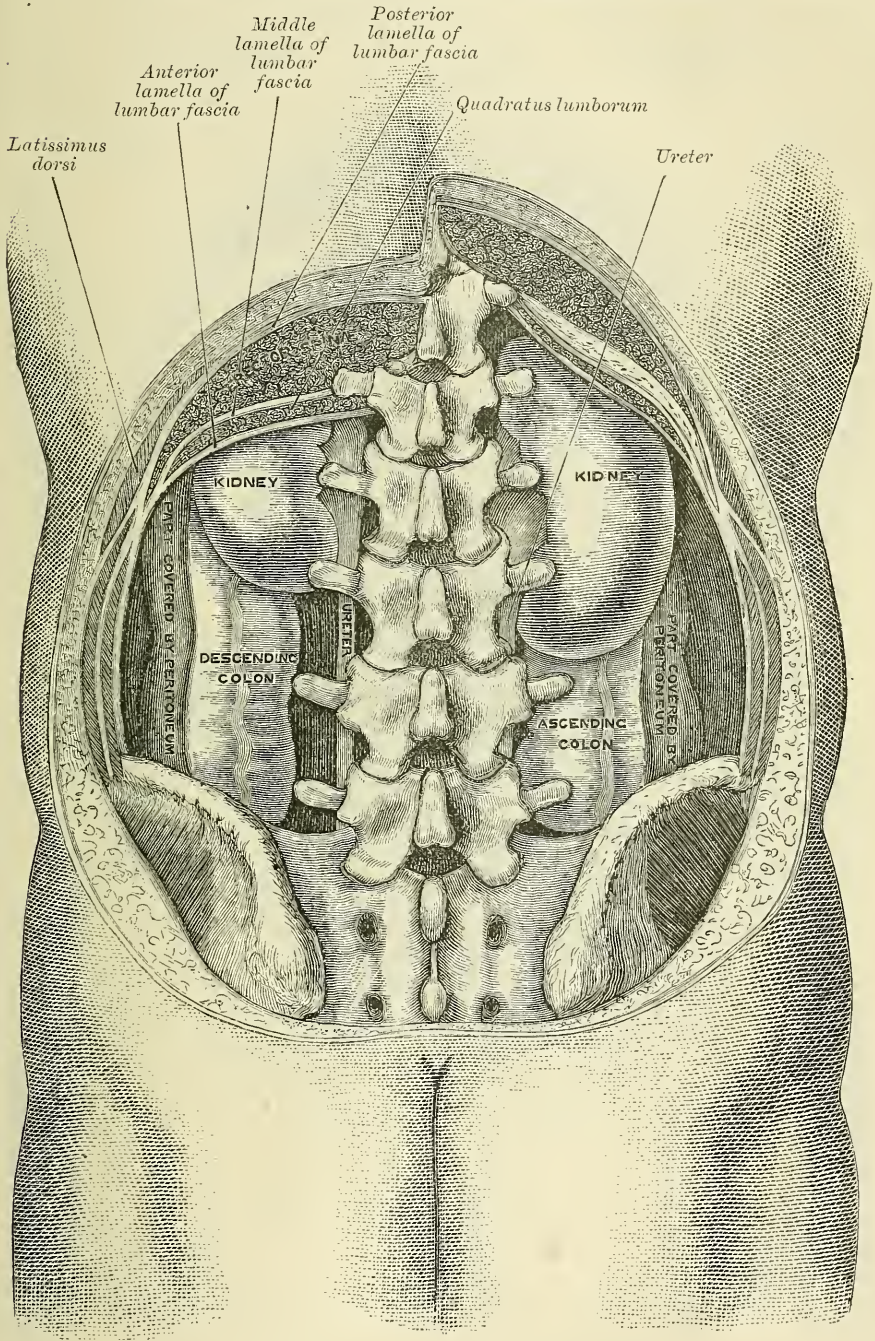
The **descending colon** passes almost vertically downwards through the left hypochondriac and lumbar regions to the upper part of the left iliac fossa, where it terminates in the sigmoid flexure. At its commencement it is connected with

\* Mr. Treves states that, after a careful examination of one hundred subjects, he found that in fifty-two there was neither an ascending nor a descending meso-colon. In twenty-two there was a descending meso-colon, but no trace of a corresponding fold on the other side. In fourteen subjects there was a meso-colon to both the ascending and the descending segments of the bowel; while in the remaining twelve there was an ascending meso-colon, but no corresponding fold on the left side. It follows, therefore, that in performing lumbar colotomy a meso-colon may be expected upon the left side in 36 per cent. of all cases, and on the right 26 per cent.—*The Anatomy of the Intestinal Canal and Peritoneum in Man*, 1885, p. 55.



the Diaphragm by a fold of peritoneum, the *phreno-colic* ligament (see page 966). It is retained in position by the peritoneum, which covers its anterior surface and sides, its posterior surface being connected by areolar tissue with the outer

FIG. 610.—Diagram of the relations of the large intestine and kidney, from behind.

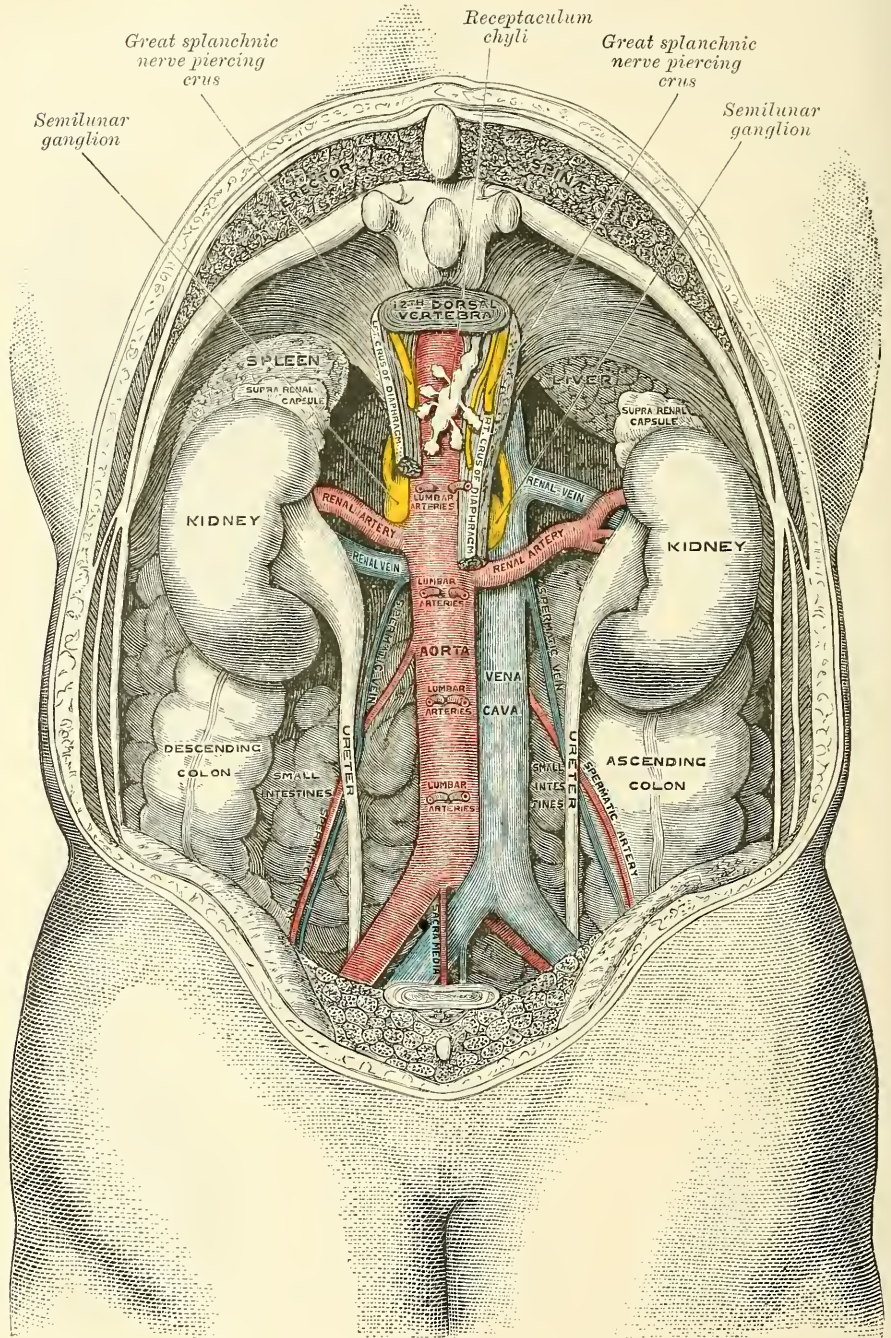


border of the left kidney, and the *Quadratus lumborum* (figs. 610, 611). It is smaller in calibre and more deeply placed than the ascending colon, and is more frequently covered with peritoneum on its posterior surface than the ascending colon (Treves).



The sigmoid flexure is the narrowest part of the colon ; it is situated in the left iliac fossa, commencing from the termination of the descending colon, at the

FIG. 611.—The relations of the viscera and large vessels of the abdomen. (Seen from behind, the last dorsal vertebra being well raised.)



margin of the crest of the ilium, and ending in the rectum, opposite the left sacro-iliac symphysis. It curves in the first place forwards, downwards, and inwards for about two inches and then forms a loop, which varies in length and position

and which terminates in the rectum.\* The first position is in close relation with the iliac fascia, and is covered by peritoneum on its sides and anterior surface only. The loop is entirely surrounded by peritoneum, and is retained in its place by a loose fold of peritoneum, the *sigmoid meso-colon*, which connects it to the Psoas muscle. This loop, which normally hangs downwards, sometimes into the true pelvis, is very movable, and may be displaced upwards in cases of distension of the pelvic viscera. Beneath the sigmoid flexure and its meso-colon is a peritoneal pouch, the *inter-sigmoid fossa*, which extends upwards in the direction of the ureter. The sigmoid flexure is in relation in front with the small intestines and abdominal parietes.

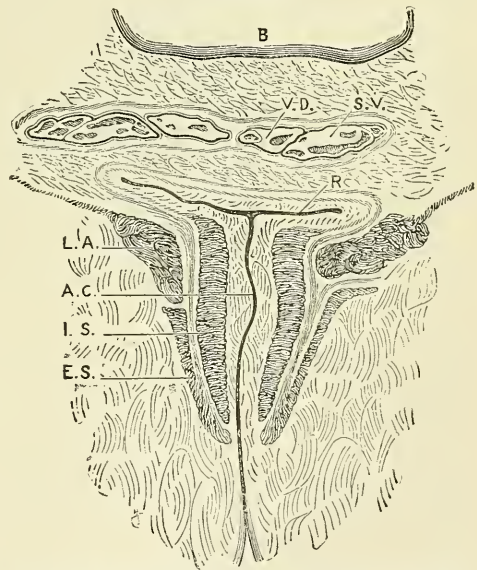
The **rectum** is the terminal part of the large intestine, and extends from the sigmoid flexure to the anus; it varies in length from six to eight inches, and has received its name from being less flexuous than any other part of the intestinal canal. It commences opposite the left sacro-iliac symphysis, passes obliquely downwards from left to right to the middle of the sacrum, forming a gentle curve to the right side; it then descends in front of the lower part of the sacrum and coccyx, presenting a curve with its concavity forwards, and, near the extremity of the latter bone, inclines backwards to terminate at the anus. The rectum is, therefore, not straight, the upper part being directed obliquely from the left side to the median line, the middle portion being curved in the direction of the hollow of the sacrum and coccyx, and the lower portion presenting a short curve in the opposite direction. The rectum is cylindrical, not sacculated like the rest of the large intestine: it is narrower in its upper part than the sigmoid flexure, gradually increases in size as it descends, and immediately above the anus presents a considerable dilatation, capable of acquiring an enormous size. The rectum is divided into three portions—upper, middle, and lower.

The *upper portion*, which includes about half the length of the tube, extends obliquely from the left sacro-iliac symphysis to the middle of the third piece of the sacrum. It is almost completely surrounded by peritoneum, and connected to the sacrum behind by a duplicature of that membrane, the *meso-rectum*. It is in relation, behind, with the Piriformis muscle, the sacral plexus of nerves and the branches of the internal iliac artery of the left side, which separate it from the sacrum and sacro-iliac symphysis; in front, it is separated, in the male, from the posterior surface of the bladder; in the female, from the posterior surface of the uterus and its appendages, by some convolutions of the small intestine.

The *middle portion of the rectum* is about three inches in length, and extends as far as the tip of the coccyx. It is closely connected to the concavity of the sacrum, and covered by peritoneum only on the upper part of its anterior surface.

\* Treves describes the sigmoid flexure somewhat differently. He includes in his description of this portion of the bowel the upper part of the rectum, and makes it terminate opposite the third portion of the sacrum. Instead of forming a sigmoid curve, he describes it as a large loop or bend, more like the Greek letter  $\Omega$  (omega).

FIG. 612.—Coronal section through the anal canal. (Symington.)



B. Cavity of bladder. VD. Vas deferens. SV. Seminal vesicle. R. Second part of rectum. AC. Anal canal. LA. Levator ani. IS. Internal sphincter. ES. External sphincter.



It is in relation, in front, in the male, with the triangular portion of the base of the bladder, the vesiculæ seminales, and vasa deferentia; more anteriorly, with the under surface of the prostate. In the female, with the posterior wall of the vagina, to which it is adherent.

The *lower portion* of the rectum is sometimes termed the *anal canal*. It differs from the second portion in the direction of its curve and in forming an antero-posterior slit, with its lateral walls in apposition, whereas the rest of the lower part of the rectum, when empty, is elongated laterally, so as to appear more like a transverse slit (fig. 612). It is about an inch or an inch and a half in length, and curves backwards at the fore part of the prostate gland to terminate at the anus. This portion of the intestine receives no peritoneal covering. It is invested by the Internal sphincter, supported by the Levatores ani muscles, and surrounded at its termination by the External sphincter. In the male, it is separated from the membranous portion and bulb of the urethra by a triangular space; and in the female a similar space intervenes between it and the vagina in which is contained the perineal body. The base of this space forms the perinæum. The rectum in the female is more capacious and less curved than in the male.

**Structure.**—The large intestine has four coats—serous, muscular, areolar and mucous.

The *serous coat* is derived from the peritoneum, and invests the different portions of the large intestine to a variable extent. The cæcum is completely covered by the serous membrane. The ascending and descending colon are usually covered only in front.\* The transverse colon is almost completely invested, the parts corresponding to the attachment of the great omentum and transverse meso-colon being alone excepted. The first portion of the sigmoid flexure is covered in front and the sides by peritoneum, the remainder is almost completely surrounded, the point corresponding to the attachment of the sigmoid meso-colon being excepted. The upper part of the rectum is almost completely invested by the peritoneum; the middle portion is covered only on its anterior surface; and the lower portion is entirely devoid of any serous covering. In the course of the colon and upper part of the rectum, the peritoneal coat is thrown into a number of small pouches filled with fat, called *appendices epiploicæ*. They are chiefly appended to the transverse colon.

The *muscular coat* consists of an external longitudinal and an internal circular layer of muscular fibres.

The *longitudinal fibres*, although found to a certain extent all round the intestine, do not form a uniform layer over the whole surface of the large intestine. In the cæcum and colon they are especially collected into three flat longitudinal bands, each being about half an inch in width. These bands commence at the attachment of the appendix vermiformis, which is surrounded by a uniform layer of longitudinal muscular fibres, to the cæcum: one, the posterior, is placed along the attached border of the intestine; the anterior band, the largest, corresponds along the arch of the colon to the attachment of the great omentum, but is in front in the ascending and descending colon and sigmoid flexure; the third, or lateral band, is found on the inner side of the ascending and descending colon, and on the under border of the transverse colon. These bands are nearly one-half shorter than the other parts of the intestine, and serve to produce the sacculi which are characteristic of the cæcum and colon; accordingly, when they are dissected off, the tube can be lengthened, and its sacculated character becomes lost. In the sigmoid flexure the longitudinal fibres become more scattered; but upon its lower part, and round the rectum, they spread out and form a layer, which completely encircles this portion of the gut, but is thicker on the anterior and posterior surfaces, where it forms two bands, than on the lateral surfaces.

The *circular fibres* form a thin layer over the cæcum and colon, being especially

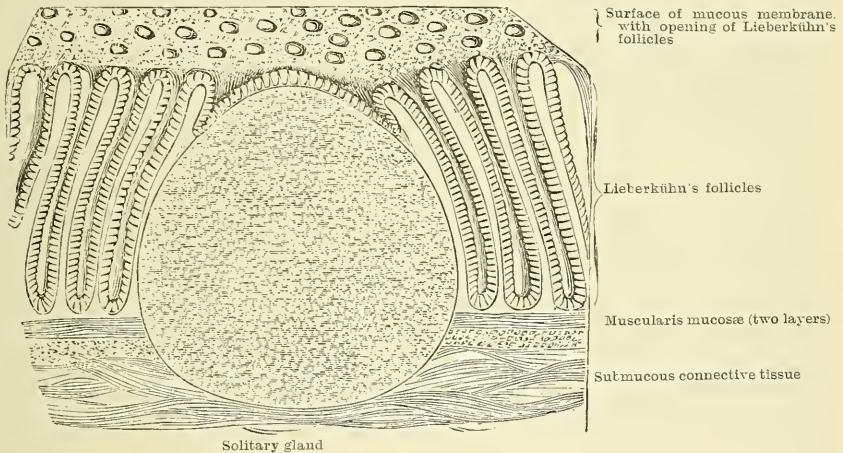
\* See foot-note, p. 984.

accumulated in the intervals between the sacculi; in the rectum they form a thick layer, especially at its lower end, where they become numerous, and form the Internal sphincter.

The *areolar coat* connects the muscular and mucous layers closely together.

The *mucous membrane*, in the cæcum and colon, is pale, and of a greyish or pale yellow colour. It is quite smooth, destitute of villi, and raised into numerous crescentic folds which correspond to the intervals between the sacculi. In the rectum it is thicker, of a darker colour, more vascular, and connected loosely to the muscular coat, as in the œsophagus. When the lower part of the rectum is contracted, its mucous membrane is thrown into a number of folds, some of which, near the anus, are longitudinal in direction, and are effaced by the distension of the gut. Besides these there are certain permanent folds, of a semi-lunar shape, known as Houston's valves.\* They are usually three in number; sometimes a fourth is found, and occasionally only two are present. One is situated near the commencement of the rectum, on the right side; another extends inwards from the left side of the tube, opposite the middle of the sacrum; the largest and most constant one projects backwards from the fore part of the rectum, opposite the base of the bladder. When a fourth is present, it is situated about an inch above the anus on the back of the rectum. These folds are about half an inch in width, and contain some of the circular fibres of the gut. In the

FIG. 613.—Minute structure of large intestine.



empty state of the intestine they overlap each other, as Mr. Houston remarks, so effectually as to require considerable manœuvring to conduct a bougie or the finger along the canal of the intestine. Their use seems to be, 'to support the weight of fæcal matter, and prevent its urging towards the anus, where its presence always excites a sensation demanding its discharge.'

As in the small intestine, the mucous membrane consists of a muscular layer, the muscularis mucosæ; of a quantity of retiform tissue in which the vessels ramify; of a basement membrane and epithelium, which is of the columnar variety, and exactly resembles the epithelium found in the small intestine. The mucous membrane of this portion of the bowel presents for examination simple follicles and solitary glands.

The *simple follicles* are minute tubular prolongations of the mucous membrane arranged perpendicularly, side by side, over its entire surface; they are longer, more numerous, and placed in much closer apposition than those of the small intestine; and they open by minute rounded orifices upon the surface, giving it a cribriform appearance.

The *solitary glands* (fig. 613) in the large intestine are most abundant in the

\* *Dublin Hosp. Reports*, vol. v. p. 163



*cæcum* and *appendix vermiformis*, but are irregularly scattered also over the rest of the intestine. They are similar to those of the small intestine.

**Vessels and Nerves.**—The arteries supplying the large intestine give off large branches, which ramify between the muscular coats, supplying them, and, after dividing into small vessels in the submucous tissue, pass to the mucous membrane. The rectum is supplied mainly by the superior hæmorrhoidal branch of the inferior mesenteric, but also at its lower end by the middle hæmorrhoidal from the internal iliac, and the inferior hæmorrhoidal from the pudic artery. The superior hæmorrhoidal, the continuation of the superior mesenteric, divides into two branches, which run down either side of the rectum to within about five inches of the anus; they here split up into about six branches, which pierce the muscular coat and descend between it and the mucous membrane in a longitudinal direction, parallel with each other as far as the Internal sphincter, where they anastomose with the other hæmorrhoidal arteries and form a series of loops around the anus. The veins of the rectum commence in a plexus of vessels which surrounds the lower extremity of the intestinal canal. In the vessels forming this plexus are small saccular dilatations just within the margin of the anus; from it about six vessels of considerable size are given off. These ascend between the muscular and mucous coats for about five inches, running parallel to each other; they then pierce the muscular coat, and, by their union, form a single trunk, the superior hæmorrhoidal vein. This arrangement is termed the *hæmorrhoidal plexus*; it communicates with the tributaries of the middle and inferior hæmorrhoidal veins at its commencement, and thus a communication is established between the systemic and portal circulations. The nerves are derived from the plexuses of the sympathetic nerve around the branches of the superior and inferior mesenteric arteries that are distributed to the large intestine. They are distributed in a similar way as those in the small intestine.

*Surface Form.*—The coils of the small intestine occupy the front of the abdomen, below the transverse colon, and are covered more or less completely by the great omentum. For the most part the coils of the jejunum occupy the left side of the abdominal cavity, i.e. the left lumbar and inguinal regions and the left half of the umbilical region; whilst the coils of the ileum are situated to the right, in the right lumbar and inguinal regions, in the right half of the umbilical region, and also the hypogastric. The *cæcum* is situated in the right inguinal region. Its position varies slightly, but the mid-point of a line drawn from the anterior superior spinous process of the ilium to the symphysis pubis will about mark the middle of its lower border. It is comparatively superficial. From it the ascending colon passes upwards through the right lumbar and hypochondriac regions, and becomes more deeply situated as it ascends to the hepatic flexure, which is deeply placed, under cover of the liver. The transverse colon crosses the belly transversely on the confines of the umbilical and epigastric regions; its lower border being on a level slightly above the umbilicus, its upper border just below the greater curvature of the stomach. The splenic flexure of the colon is situated behind the stomach in the left hypochondrium, and is on a higher level than the hepatic flexure. The descending colon is deeply seated, passing down through the left hypochondriac and lumbar regions to the sigmoid flexure, which is situated in the left inguinal regions and which can be felt in thin persons, with relaxed abdominal walls, rolling under the fingers when empty, and when distended forming a distinct tumour. The position of the vermiform appendix is indicated by a point midway between the anterior superior spinous process of the right immominate bone and the umbilicus. This is known as McBurney's spot.

*Surgical Anatomy.*—The small intestines are much exposed to injury, but, in consequence of their elasticity and the ease with which one fold glides over another, they are not so frequently ruptured as would otherwise be the case. Any part of the small intestine may be ruptured, but probably the most common situation is the transverse duodenum, on account of its being more fixed than other portions of the bowel, and because it is situated in front of the bodies of the vertebræ, so that if this portion of the abdomen is struck by a sharp blow, as from the kick of a horse, it is unable to glide out of the way, but is compressed against the bone and so lacerated. Wounds of the intestine sometimes occur. If the wound is a small puncture, under, it is said, three lines in length, no extravasation of the contents of the bowel takes place. The mucous membrane becomes everted and plugs the little opening. The bowels, therefore, may be safely punctured with a fine capillary trocar, in cases of excessive distension of the intestine with gas, without fear of extravasation. A longitudinal wound gapes more than a transverse, owing to the greater amount of circular muscular fibres. The small intestine, and most frequently the ileum, may become



strangulated by internal bands, or through apertures, normal or abnormal. The bands may be formed in several different ways: they may be old peritoneal adhesions from previous attacks of peritonitis; or an adherent omentum from the same cause; or the band may be formed by Meckel's diverticulum, which has contracted adhesions at its distal extremity; or the band may be the result of the abnormal attachment of some normal structure, as the adhesion of two appendices epiploicæ, or an adherent vermiform appendix or Fallopian tube. Intussusception or invagination of the small intestine may take place in any part of the jejunum and ileum, but the most frequent situation is at the ileo-cæcal valve, the valve forming the apex of the entering tube. This form may attain great size, and it is not uncommon in these cases to find the valve projecting from the anus. Stricture, the impaction of foreign bodies, and twisting of the gut (*volvulus*) may lead to intestinal obstruction.

The vermiform appendix is very liable to become inflamed, leading to so-called perityphlitis, i.e. a localised inflammation of the peritoneum in the vicinity of the cæcum. This condition may be set up by the appendix becoming twisted, owing to the shortness of its mesentery, in consequence of distension of the cæcum. As the result of this its blood supply, which is mainly through one large artery running in the mesentery, becomes interfered with. Again, in rarer cases, the inflammation is set up by the impaction of a solid mass of fæces or a foreign body in it. The inflammation may result in ulceration and perforation, or if the torsion is very acute in gangrene of the appendix. These conditions may require operative interference, and in cases of recurrent attacks of appendicitis it is generally advisable to remove this diverticulum of the bowel. In external hernia the ileum is the portion of bowel most frequently herniated. When a part of the large intestine is involved it is usually the cæcum, and this may occur even on the left side. In some few cases the vermiform appendix has been the part implicated in cases of strangulated hernia, and has given rise to serious symptoms of obstruction. Occasionally ulceration of the duodenal glands may occur in cases of burns, but is not a very common complication. The ulcer may perforate one of the large duodenal vessels and may cause death from hæmorrhage, or it may perforate the coats of the intestine and produce fatal acute peritonitis. The diameter of the large intestine gradually diminishes from the cæcum, which has the greatest diameter of any part of the bowel, to the point of junction of the sigmoid flexure with the rectum, at or a little below which point stricture most commonly occurs, and diminishes in frequency as one proceeds upwards to the cæcum. When distended by some obstruction low down, the outline of the large intestine can be defined throughout nearly the whole of its course—all, in fact, except the hepatic and splenic flexures, which are more deeply placed; the distension is most obvious in the two flanks and on the front of the abdomen just above the umbilicus. The cæcum, however, is that portion of the bowel which is, of all, most distended. It sometimes assumes enormous dimensions, and has been known to give way from the distension, causing fatal peritonitis. The hepatic flexure and the right extremity of the transverse colon is in close relationship with the liver, and abscess of this viscus sometimes bursts into the gut in this situation. The gall bladder may become adherent to the colon, and gall-stones may find their way through into the gut, where they may become impacted or may be discharged per anum. The mobility of the sigmoid flexure renders it more liable to become the seat of a *volvulus* or twist than any other part of the intestine. It generally occurs in patients who have been the subjects of habitual constipation, and in whom therefore the meso-sigmoid flexure is elongated. The gut at this part being loaded with fæces, from its weight falls over the gut below, and so gives rise to the twist.

The surgical anatomy of the rectum is of considerable importance. There may be congenital malformations due to arrest or imperfect development. Thus, there may be no inflexion of the epiblast (see page 109), and consequently a complete absence of the anus; or the hind-gut may be imperfectly developed, and there may be an absence of the rectum, though the anus is developed; or the inflexion of the epiblast may not communicate with the termination of the hind-gut from want of solution of continuity in the septum which in early fetal life exists between the two. The mucous membrane is thick and but loosely connected to the muscular coat beneath, and thus favours prolapse, especially in children. The vessels of the rectum are arranged, as mentioned above, longitudinally, and are contained in the loose cellular tissue between the mucous and muscular coats, and receive no support from surrounding tissues, and this favours varicosity. Moreover, the veins, after running upwards in a longitudinal direction for about five inches in the sub-mucous tissue, pierce the muscular coats and are liable to become constricted at this spot by the contraction of the muscular wall of the gut. In addition to this there are no valves in the superior hæmorrhoidal veins, and the vessels of the rectum are placed in a dependent position, and are liable to be pressed upon and obstructed by hardened fæces. The anatomical arrangement, therefore, of the hæmorrhoidal vessels explains the great tendency to the occurrence of piles. Again, the presence of the Sphincter ani is of surgical importance, since it is the constant contraction of this muscle which prevents an ischio-rectal abscess from healing, and causes it to become a fistula. Also the reflex contraction of this muscle is the cause of the severe pain complained of in fissure of the anus. The relations of the peritoneum to the rectum are of importance in connection with the operation of removal of the lower end of the rectum for malignant disease. This membrane gradually

leaves the rectum as it descends into the pelvis; first leaving its posterior surface, then the sides, and then the anterior surface, to become reflected, in the male on to the posterior wall of the bladder, forming the recto-vesical pouch, and in the female on to the posterior wall of the vagina, forming Douglas's pouch. The recto-vesical pouch of peritoneum extends to within three and a half or four inches from the anus, so that it is not safe to remove more than three inches of the entire circumference of the bowel for fear of the risk of opening the peritoneum. When, however, the disease is confined to the posterior surface of the rectum, or extends farther in this direction, a greater amount of the posterior wall of the gut may be removed, as the peritoneum does not extend on this surface to a lower level than five inches from the margin of the anus. The recto-vaginal or Douglas's pouch in the female extends somewhat lower than the recto-vesical pouch of the male, and therefore it is necessary to remove a less length of the tube in this sex.\* Of recent years, however, much more extensive operations have been done for the removal of cancer of the rectum, and in these the peritoneal cavity has necessarily been opened. If, in these cases, the opening is plugged with antiseptic wool until the operation is completed and then the edges of the wound in the peritoneum accurately brought together with sutures, no evil result appears to follow. For cases of cancer of the rectum which are too low to be reached by abdominal section, and too high to be removed by the ordinary operation from below, Kraske has devised an operation which goes by his name. The patient is placed on his right side and an incision is made from the second sacral spine to the anus. The soft parts are now separated from the back of the left side of the sacrum as far as its left margin and the greater and lesser sacro-sciatic ligaments are divided. A portion of the lateral mass of the sacrum, commencing on the left border at the level of the third posterior sacral foramen, and running downwards and inwards through the fourth foramen to the cornu, is now cut away with a chisel. The left side of the wound being now forcibly drawn outwards, the whole of the rectum is brought into view and the diseased portion can be removed, leaving the anal portion of the gut, if healthy. The two divided ends of the gut can then be approximated and sutured together in front, the posterior part being left open for drainage.

Upon introducing the finger into the rectum, the membranous portion of the urethra can be felt, if an instrument has been introduced into the bladder, exactly in the middle line; behind this the prostate gland can be recognised by its shape and hardness and any enlargement detected; behind the prostate the fluctuating wall of the bladder when full can be felt, and if thought desirable it can be tapped in this situation; on either side and behind the prostate the vesiculæ seminales can be readily felt, especially if enlarged by tuberculous disease. Behind, the coccyx is to be felt, and on the mucous membrane one or two of Houston's folds. The ischio-rectal fossæ can be explored on either side, with a view to ascertaining the presence of deep-seated collections of pus. Finally, it will be noted that the finger is firmly gripped by the sphincter for about an inch up the bowel. By gradual dilatation of the sphincter, the whole hand can be introduced into the rectum so as to reach the descending colon. This method of exploration is rarely, however, required for diagnostic purposes.

The colon frequently requires opening in cases of intestinal obstruction; the descending colon being usually the portion of bowel selected for this operation. The operation of colotomy may be performed either without opening the peritoneum, by an incision in the loin (lumbar colotomy), or by an opening through the peritoneum (inguinal colotomy). Lumbar colotomy is performed by placing the patient on the side opposite to the one to be operated on, with a firm pillow under the loin. A line is then drawn from the anterior superior to the posterior superior spine of the ilium, and the mid-point of this line (Heath) or half an inch behind the mid-point (Allingham) is taken, and a line drawn vertically upwards from it to the last rib. This line represents, with sufficient correctness, the position of the normal colon. An oblique incision four inches in length is now made midway between the last rib and the crest of the ilium, so that its centre bisects the vertical line, and the following parts successively divided: (1) The skin, superficial fascia, with cutaneous vessels and nerves and deep fascia. (2) The posterior fibres of the External oblique and anterior fibres of the Latissimus dorsi. (3) The Internal oblique. (4) The lumbar fascia and the external border of the Quadratus lumborum. The edges of the wound are now to be held apart with retractors, and the transversalis fascia will be exposed. This is to be opened with care, commencing at the posterior angle of the incision. If the bowel is distended, it will bulge into the wound, and no difficulty will be found in dealing with it. If, however, the gut is empty this bulging will not take place, and the colon will have to be sought for. The guides to it are the lower end of the kidney, which will be plainly felt, and the outer edge of the Quadratus lumborum. The bowel having been found, is to be drawn well up into the wound, and it may be opened at once and the margins of the opening stitched to the skin at the edge of the wound; or, if the case is not an urgent one, it may be retained in this position by two harelip pins passed through the muscular coat, the rest of the wound closed, and the bowel opened in three or four days, when adhesion of the bowel to the edges of the wound has taken place.

\* Allingham says one inch less in the female.



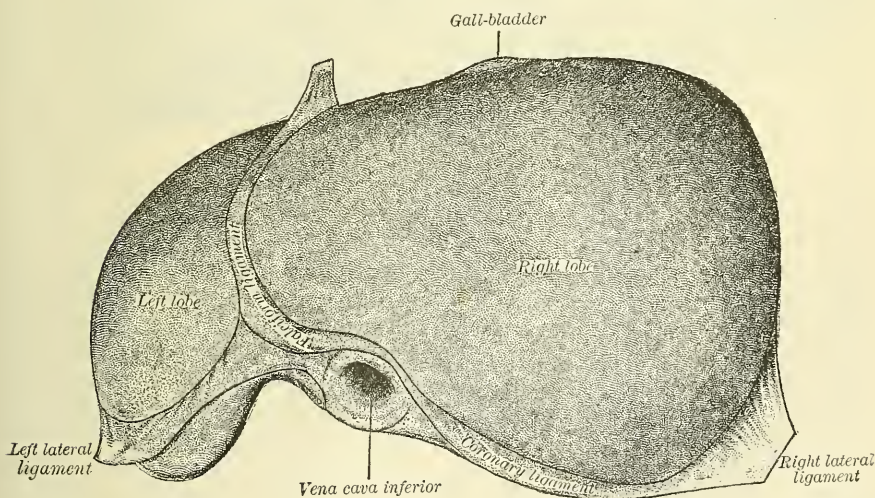
*Inguinal colotomy* is preferred by many surgeons in those cases where there is no urgent obstruction, and where, therefore, there is no necessity to open the bowel at once. The main reason for preferring this operation is that a spur-shaped process of the meso-colon can be formed which prevents any fecal matter finding its way past the artificial anus, and becoming lodged on the diseased structures below. The sigmoid flexure being almost entirely surrounded by peritoneum, a coil can be drawn out of the wound and the greater part of its calibre removed, leaving the remainder attached to the meso-colon, which forms a spur, much the same as in an artificial anus caused by sloughing of the gut after a strangulated hernia, and this prevents any fecal matter finding its way from the gut above the opening into that below. The operation is performed by making an incision two or three inches in length from a point one inch internal to the anterior superior spinous process of the ilium, parallel to Poupart's ligament. The various layers of abdominal muscles are cut through, and the peritoneum opened and sewn to the external skin. The sigmoid flexure is now sought for, and pulled out of the wound and fixed by passing a needle threaded with carbolised silk through the meso-colon close to the gut, and then through the abdominal wall. The intestine is now sewn to the skin all round, the sutures passing only through the serous and muscular coats. The wound is dressed, and on the second to the fourth day, according to the requirements of the case, the protruded coil of intestine is opened and removed with scissors.

## THE LIVER

The **Liver** is a glandular organ of large size, intended mainly for the secretion of the bile, but effecting also important changes in certain constituents of the blood in their passage through the gland. It is situated in the right hypochondriac and epigastric regions, but in the child extends across the epigastrium into the left hypochondrium. It is the largest gland in the body, weighing from three to four pounds (from fifty to sixty ounces avoirdupois). It measures, in its transverse diameter, from ten to twelve inches; from six to seven in its antero-posterior; and is about three inches thick at the back part of the right lobe, which is the thickest part.

Its *upper* or *diaphragmatic surface* (fig. 614) is convex, directed upwards and forwards, smooth, covered by peritoneum except along a narrow line between

FIG. 614.—The liver. Upper surface. (Drawn from His' models.)



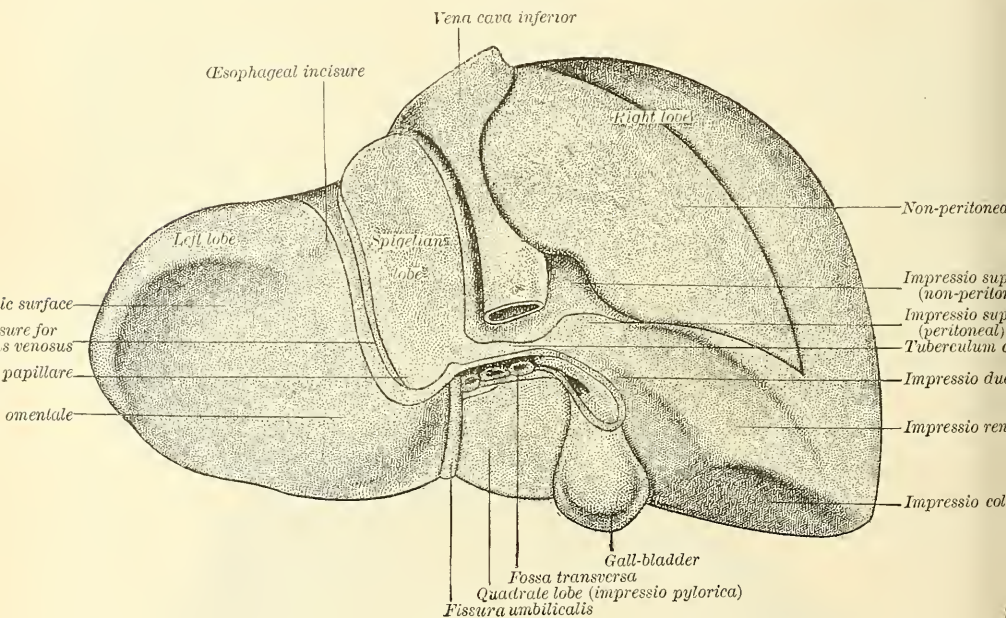
the two layers of the suspensory ligament. It is in relation with the under surface of the Diaphragm; and below, to a small extent, with the abdominal parietes. The surface is divided into two unequal lobes, the right and left; of these the right is much the larger and convex; the left smaller and more flat. The separation between the lobes is indicated by the line of attachment of a fold of peritoneum, the *suspensory* or *broad ligament*, and in front by a notch, the



*umbilical notch*, the termination of the umbilical fissure on the under surface. It is separated from the under surface in front by a sharp margin, in which, to the right of the umbilical notch, is an excavation, which corresponds to the fundus of the gall-bladder. Upon this surface is a shallow depression, corresponding to the heart.

Its *under or visceral surface* (fig. 615) is concave, directed downwards and backwards and to the left, and is in relation with the stomach and duodenum, the hepatic flexure of the colon, and the right kidney and suprarenal capsule. The surface is divided by a longitudinal fissure into a right and left lobe. It is invested by peritoneum over almost its entire surface; the only parts where this covering is absent are where the gall-bladder is attached to the liver and at the transverse fissure, where the two layers of the lesser omentum are separated from each other by the blood-vessels and duct of the viscus. The under surface of the left lobe presents behind and to the left a depression where it is moulded over the cardiac part of the stomach, and to the right and near the centre a

FIG. 615.—The liver. Posterior and inferior surface. (Drawn from His' models.)



rounded eminence, the *tuber omentale*, which fits into the concavity of the lesser curvature resting on the lesser omentum. The under surface of the right lobe is divided into two unequal portions by a fossa, which lodges the gall-bladder, the *fossa vesicalis*; the portion to the left, the smaller of the two, is somewhat oblong in shape, its antero-posterior diameter being greater than its transverse. It is known as the *quadrate lobe*, and is in relation with the pyloric end of the stomach and the first portion of the duodenum. The portion of the under surface of the right lobe to the right of the fossa vesicalis presents in front two shallow concave impressions, the one situated behind the other, and the two being separated by a ridge. The anterior of these two impressions, the *impressio colica*, is produced by the hepatic flexure of the colon; the posterior, the *impressio renalis*, being produced by the upper end of the right kidney. To the inner side of the latter impression is a third and slightly marked impression, lying between it and the neck of the gall-bladder. This is caused by the second portion of the duodenum, and is known as the *impressio duodenalis*. At the back part of the under surface of the right lobe is an impression for the right suprarenal capsule. This

is partly covered by peritoneum, and therefore belongs to the inferior surface of the liver; but in the rest of its extent is uncovered by peritoneum, and belongs to the posterior surface. It lies just to the right of the inferior vena cava. Finally, on this surface is the *caudate lobe*, a narrow strip of liver tissue which connects the right lobe to the Spigelian lobe.

The *posterior surface* is rounded and broad over the right lobe, but narrow on the left. Over the greater part of its extent it is not covered by peritoneum, but a small portion of this surface to the right is covered by this serous membrane. The uncovered portion is about three inches broad, and is in direct contact with the Diaphragm and posterior wall of the abdomen. It is marked off from the upper surface by the line of reflection of peritoneum from the under surface of the Diaphragm to the upper surface of the liver, constituting the anterior layer of the coronary and right lateral ligament of the liver. It is in the same way marked off from the under surface of the liver by the line of reflection of peritoneum from the posterior portion of the Diaphragm on to the liver, which forms the posterior layer of the coronary and right lateral ligaments. In its centre this posterior surface is deeply notched for the vertebral column and aorta, and to the right of this it is indented for the inferior vena cava, which is often partly embedded in its substance. Close to the right of this indentation is the portion of the *impressio suprarenalis* which belongs to the posterior surface (see above). To the left of the inferior vena cava is the Spigelian lobe, which lies between the fissure for the vena cava and the fissure for the ductus venosus. Below and in front it projects and forms part of the posterior boundary of the transverse fissure. Here, to the right, it is connected with the under surface of the right lobe of the liver by the caudate lobe, and to the left it presents a tubercle, the *tuber papillare*. It is opposite the tenth and eleventh dorsal vertebræ, and rests upon the aorta and crura of the Diaphragm. This lobe is nearly vertical in direction, and is directed backwards: it is longer from above downwards than from side to side, and is somewhat concave from side to side. On the posterior surface to the left of the Spigelian lobe is a groove indicating the position of the œsophageal orifice of the stomach.

The *anterior border* is thin and sharp, and marked opposite the attachment of the longitudinal ligament by a deep notch, and opposite the cartilage of the ninth rib by a second notch for the fundus of the gall-bladder. In adult males this border usually corresponds with the margin of the ribs; but in women and children it usually projects below the ribs.

The *right extremity of the liver* is thick and rounded, whilst the *left* is thin and flattened.

**Ligaments.**—The ligaments of the liver (fig. 614) are five in number, four being formed of folds of peritoneum; the fifth, the *ligamentum teres*, is a round fibrous cord, resulting from the obliteration of the umbilical vein. The ligaments are, the longitudinal, two lateral, coronary, and round.

The *longitudinal ligament* (broad, falciform, or suspensory ligament) is a broad and thin antero-posterior peritoneal fold, falciform in shape, its base being directed forwards, its apex backwards. It is attached by one margin to the under surface of the Diaphragm, and the posterior surface of the sheath of the right Rectus muscle as low down as the umbilicus; by its hepatic margin it extends from the notch on the anterior margin of the liver, as far back as its posterior surface. It consists of two layers of peritoneum closely united together. Its anterior free edge contains the round ligament between its layers.

The *lateral ligaments*, two in number, right and left, are triangular in shape. They are formed of two layers of peritoneum united, and extend from the sides of the Diaphragm to the extremities of the posterior surface of the organ. The left is the longer of the two, and lies in front of the œsophageal opening in the Diaphragm.

The *coronary ligament* connects the posterior surface of the liver to the Diaphragm. It is formed by the reflection of the peritoneum from the Diaphragm



on to the upper and lower margins of the posterior surface of the organ. The coronary ligament consists of two layers, which are continuous on each side with the lateral ligaments; and, in front, with the longitudinal ligament. Between the layers, a large oval space is left uncovered by peritoneum, and is connected to the Diaphragm by firm areolar tissue.

The *round ligament* is a fibrous cord resulting from the obliteration of the umbilical vein. It ascends from the umbilicus, in the anterior free margin of the longitudinal ligament, to the notch in the anterior border of the liver, from which it may be traced along the longitudinal fissure on the under surface of the liver as far back as the inferior vena cava.

**Fissures** (fig. 615).—Five fissures are seen upon the under and posterior surfaces of the liver, which serve to divide it into five lobes. They are, the umbilical fissure, the fissure of the ductus venosus, the transverse fissure, the fissure for the gall-bladder, and the fissure for the inferior vena cava. They are arranged in the form of the letter **H**; the left limb of the **H** is known as the longitudinal fissure; the anterior part contains the umbilical vein in the fœtus and its remains in the adult (the *round ligament*); it is known as the *umbilical fissure*; the posterior part, situated on the posterior surface of the liver, contains the ductus venosus, and is known as the *fissure of the ductus venosus*. The right limb of the **H** is formed in front by the *fissure for the gall-bladder* and behind by the *fissure for the inferior vena cava*; these two fissures are separated from each other by the caudate lobe. The connecting bar of the **H** is the *transverse* or *portal fissure*. It separates the quadrate lobe in front from the caudate and Spigelian lobe behind.

The *longitudinal fissure* is a deep groove, which extends from the notch on the anterior margin of the liver to the posterior surface of the organ. It separates the right and left lobes; the transverse fissure joins it, at right angles, about one-third from its posterior extremity, and divides it into two parts. The anterior half is called the *umbilical fissure*; it is deeper than the posterior part, and lodges the umbilical vein in the fœtus, or its remains (the *round ligament*) in the adult. This fissure is often partially bridged over by a prolongation of the hepatic substance, the *pons hepatis*.

The *fissure of the ductus venosus* is the back part of the longitudinal fissure, and is situated partly on the posterior surface of the liver; it is shorter and shallower than the anterior portion. It lies between the left lobe and the lobe of Spigelius. It lodges in the fœtus the ductus venosus, and in the adult a slender fibrous cord, the obliterated remains of that vessel.

The *transverse* or *portal fissure* is a short but deep fissure, about two inches in length, extending transversely across the under surface of the right lobe, nearer to its posterior surface than its anterior border. It joins, nearly at right angles, with the longitudinal fissure. It separates the quadrate lobe in front from the caudate and Spigelian lobe behind. By the older anatomists this fissure was considered the gateway (*porta*) of the liver; hence the large vein which enters at this point was called the *portal vein*. Besides this vein, the fissure transmits the hepatic artery and nerves, and the hepatic duct and lymphatics. At their entrance into the fissure, the hepatic duct lies in front and to the right, the hepatic artery to the left, and the portal vein behind and between the duct and artery.

The *fissure for the gall-bladder* (*fossa cystis felleæ*) is a shallow, oblong fossa, placed on the under surface of the right lobe, parallel with the longitudinal fissure. It extends from the anterior free margin of the liver, which is notched for its reception, to near the right extremity of the transverse fissure.

The *fissure for the inferior vena cava* is a short, deep fissure, occasionally a complete canal, from the substance of the liver uniting around the vena cava. It extends obliquely upwards from the lobus caudatus, which separates it from the transverse fissure on the posterior surface of the liver and separates the Spigelian from the right lobe. On slitting open the inferior vena cava which

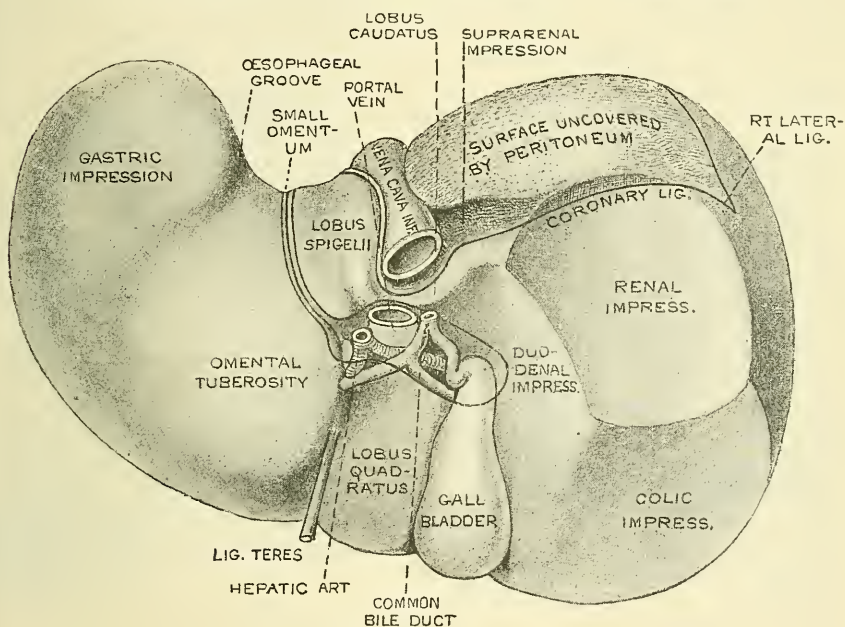


is contained in it, a deep fossa is seen, at the bottom of which the hepatic veins communicate with this vessel.

**Lobes.**—The lobes of the liver, like the ligaments and fissures, are five in number—the right lobe, the left lobe, the lobus quadratus, the lobus Spigelii, and the lobus caudatus.

The *right lobe* is much larger than the left; the proportion between them being as six to one. It occupies the right hypochondrium, and is separated from the left lobe, on its upper surface, by the longitudinal ligament; on its under and posterior surfaces by the longitudinal fissure; and in front by a deep notch. It is of a quadrilateral form, its under surface being marked by three fissures—the transverse fissure, the fissure for the gall-bladder, and the fissure for the inferior vena cava; and by three shallow impressions, one in front (*impressio colica*), for the hepatic flexure of the colon; and one behind (*impressio renalis*), for the right kidney; and one internal, between the last-named and the gall-bladder (*impressio duodenalis*), for the second part of the duodenum.

FIG. 616.—Posterior and under surface of the liver. (From Ellis.)



The *left lobe* is smaller and more flattened than the right. It is situated in the epigastric region. Its upper surface is convex; its under surface is concave, and presents a shallow depression for the stomach (*gastric impression*). This is situated in front of the groove for the œsophagus, and is separated from the longitudinal fissure by a well-marked prominence, the *omental tuberosity*, which lies against the small omentum and lesser curvature of the stomach.

The *lobus quadratus*, or square lobe, is situated on the under surface of the right lobe, bounded in front by the free surface of the liver; behind by the transverse fissure; on the right, by the fissure for the gall-bladder; and on the left, by the umbilical fissure.

The *lobus Spigelii* projects perpendicularly from the posterior surface of the liver. It is bounded, in front, by the transverse fissure; on the right, by the fissure for the vena cava; and, on the left, by the fissure for the ductus venosus. Its left upper angle forms part of the groove for the œsophagus.

The *lobus caudatus*, or tailed lobe, is a small elevation of the hepatic substance, extending obliquely outwards, from the base of the lobus Spigelii to the under

surface of the right lobe. It is situated at the right extremity of the transverse fissure, and separates the fissure for the gall-bladder from the commencement of the fissure for the inferior vena cava.

**Vessels.**—The vessels connected with the liver are also five in number: they are, the hepatic artery, the portal vein, the hepatic vein, the hepatic duct, and the lymphatics.

The *hepatic artery* and *portal vein*, accompanied by numerous lymphatics and nerves, ascend to the transverse fissure, between the layers of the gastro-hepatic omentum. The *hepatic duct*, lying in company with them, descends from the transverse fissure between the layers of the same omentum. The relative position of the three structures is as follows:—The hepatic duct lies to the right, the hepatic artery to the left, and the portal vein behind and between the other two. These are enveloped in a loose areolar tissue, the capsule of Glisson, which accompanies the vessels in their course through the *portal canals*, in the interior of the organ.

The *hepatic veins* convey the blood from the liver. They commence in the substance of the liver, in the capillary terminations of the portal vein and hepatic artery; these tributaries, gradually uniting, usually form three large veins, which converge towards the posterior surface of the liver and open into the inferior vena cava, whilst that vessel is situated in the groove at the back part of this organ. Of these three veins, one from the right and another from the left lobe open obliquely into the vena cava: that from the middle of the organ and lobus Spigelii having a straight course.

The hepatic veins have very little cellular investment; what there is binds their parietes closely to the walls of the canals through which they run; so that, on a section of the organ, these veins remain widely open and solitary, and may be easily distinguished from the branches of the portal vein, which are more or less collapsed, and always accompanied by an artery and duct. The hepatic veins are destitute of valves.

The *lymphatics* are large and numerous, consisting of a deep and superficial set. They have been already described.

**Nerves.**—The nerves of the liver are derived from the hepatic plexus of the sympathetic, from the pneumogastric nerves, especially the left, and from the right phrenic.

**Structure.**—The substance of the liver is composed of lobules, held together by an extremely fine areolar tissue, and of the ramifications of the portal vein, hepatic duct, hepatic artery, hepatic veins, lymphatics, and nerves; the whole being invested by a serous and a fibrous coat.

The *serous coat* is derived from the peritoneum, and invests the greater part of the surface of the organ. It is intimately adherent to the fibrous coat.

The *fibrous coat* lies beneath the serous investment, and covers the entire surface of the organ. It is difficult of demonstration, excepting where the serous coat is deficient. At the transverse fissure it is continuous with the capsule of Glisson, and, on the surface of the organ, with the areolar tissue separating the lobules.

The *lobules* form the chief mass of the hepatic substance; they may be seen either on the surface of the organ, or by making a section through the gland. They are small granular bodies, about the size of a millet seed, measuring from one-twentieth to one-tenth of an inch in diameter. In the human subject their outline is very irregular; but in some of the lower animals (for example, the pig) they are well-defined, and, when divided transversely, have a polygonal outline. If divided longitudinally they are more or less foliated or oblong. The bases of the lobules are clustered round the smallest radicles (*sublobular*) of the hepatic veins, to which each is connected by means of a small branch which issues from the centre of the lobule (*intralobular*). The remaining part of the surface of each lobule is imperfectly isolated from the surrounding lobules by a thin stratum of



areolar tissue, in which is contained a plexus of vessels (the *interlobular plexus*) and ducts. In some animals, as the pig, the lobules are completely isolated one from another by this interlobular areolar tissue.

If one of the sublobular veins be laid open, the bases of the lobules may be seen through the thin wall of the vein on which they rest, arranged in the form of a tessellated pavement, the centre of each polygonal space presenting a minute aperture, the mouth of an intralobular vein (fig. 617).

**Microscopic appearance.**—Each lobule is composed of a mass of cells (*hepatic cells*), surrounded by a dense capillary plexus, composed of vessels which penetrate from the circumference to the centre of the lobule, and terminate in a single straight vein, which runs through its centre, to open at its base into one of the radicles of the hepatic vein. Between the cells are also the minute commencements of the bile-ducts. Therefore, in the lobule we have all the essentials of a secreting gland; that is to say: (1) *cells*, by which the secretion is formed; (2) *blood-vessels*, in close relation with the cells, containing the blood from which the secretion is derived; and (3) *ducts*, by which the secretion, when formed, is carried away. Each of these structures will have to be further considered.

FIG. 617.—Longitudinal section of an hepatic vein. (After Kiernan.)

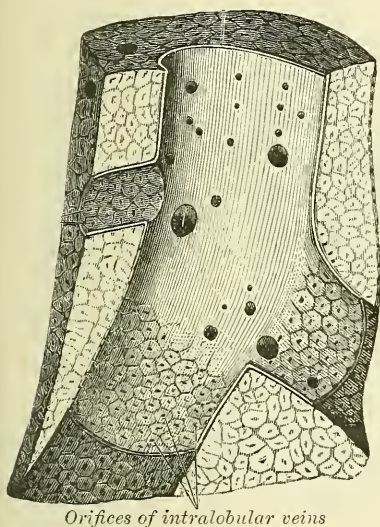
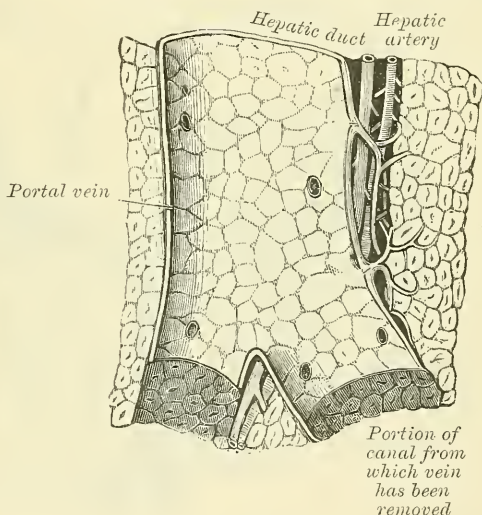


FIG. 618.—Longitudinal section of a small portal vein and canal. (After Kiernan.)



(1) The *hepatic cells* are of more or less spheroidal form; but may be rounded, flattened, or many-sided from mutual compression. They vary in size from the  $\frac{1}{1000}$  to the  $\frac{1}{2000}$  of an inch in diameter. They consist of a honeycomb network (Klein) without any cell-wall, and contain one or sometimes two distinct nuclei. In the nucleus is a highly refracting nucleolus with granules. Embedded in the honeycomb network are numerous yellow particles, the colouring-matter of the bile, and oil-globules. The cells adhere together by their surfaces so as to form rows, which radiate from the centre to the circumference of the lobules.\* As stated above, they are the chief agents in the secretion of the bile.

(2) *The blood-vessels.*—The blood in the capillary plexus, around the liver-cells, is brought to the liver principally by the portal vein, but also to a certain

\* Delépine states that there are evidences of the arrangement of these cells in the form of columns, which form tubes with narrow lumina branching from terminal bile ducts. This branching is evidenced by a divergence of the columns from lines extending between adjacent portal vessels. The columns of cells group round terminal bile ducts and not round the so-called intralobular veins. *Lancet*, vol. i. 1895, p. 1254.

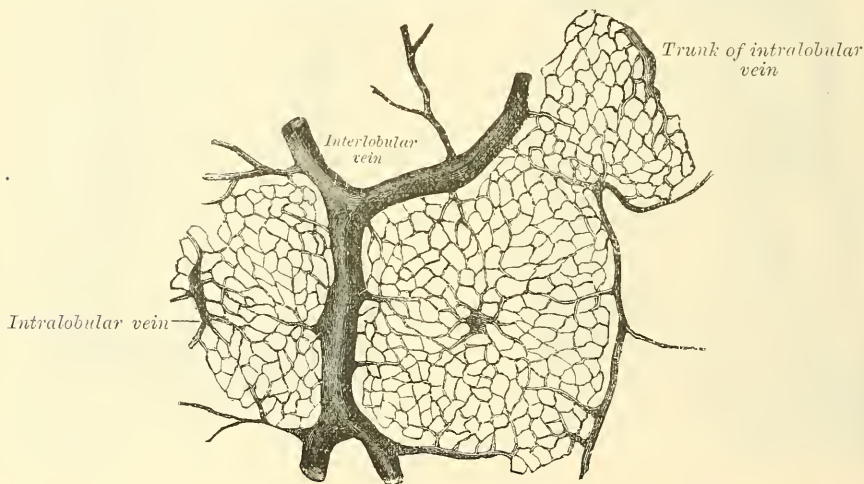


extent by the hepatic artery. For the sake of clearness, the distribution of the blood derived from the hepatic artery may be considered first.

The *hepatic artery*, entering the liver at the transverse fissure with the portal vein and hepatic duct, ramifies with these vessels through the portal canals. It gives off *vaginal branches*, which ramify in the capsule of Glisson, and appear to be destined chiefly for the nutrition of the coats of the large vessels, the ducts, and the investing membranes of the liver. It also gives off *capsular branches* which reach the surface of the organ, terminating in its fibrous coat, in stellate plexuses. Finally it gives off *interlobular branches* which form a plexus on the outer side of each lobule, to supply its wall and the accompanying bile-ducts. From this, lobular branches enter the lobule and end in the capillary network between the cells. Some anatomists, however, doubt whether it transmits any blood directly to the capillary network.

The *portal vein* (fig. 618) also enters at the transverse fissure and runs through the portal canals, enclosed in Glisson's capsule, dividing into branches in its course, which finally break up into a plexus (the *interlobular plexus*) in the interlobular spaces between the lobules. In their course these branches receive the vaginal and capsular veins, corresponding to the vaginal and capsular branches of the hepatic artery (fig. 618). Thus it will be seen that all the blood carried to the liver by the portal vein and hepatic artery, except perhaps that

FIG. 619.—Horizontal section of liver (dog).



derived from the interlobular branches of the hepatic artery, directly or indirectly, finds its way into the interlobular plexus. From this plexus the blood is carried into the lobule by fine branches which pierce its wall, and then converge from the circumference to the centre of the lobule, forming a number of longitudinal vessels, which are connected by transverse or horizontal branches (fig. 619). In the interstices of the network of vessels thus formed are situated, as before said, the liver-cells; and here it is that, the blood being brought into intimate connection with the liver-cells, the bile is secreted. Arrived at the centre of the lobule, all these minute vessels empty themselves into one vein, of considerable size, which runs down the centre of the lobules from apex to base, and is called the *intralobular vein*. At the base of the lobule this vein opens directly into the *sublobular vein*, with which the lobule is connected, and which, as before mentioned, is a radicle of the hepatic vein. The sublobular veins, uniting into larger and larger trunks, end at last in the hepatic veins, which do not receive any intralobular veins. Finally, the hepatic veins, as mentioned at page 693, converge to form three large trunks which open into the inferior vena cava,

while that vessel is situated in the fissure appropriated to it at the back of the liver.

(3) *The ducts.*—Having shown how the blood is brought into intimate relation with the hepatic cells in order that the bile may be secreted, it remains now only to consider the way in which the secretion, having been formed, is carried away. Several views have prevailed as to the mode of origin of the hepatic ducts; it seems, however, to be clear that they commence by little passages which are formed between the cells, and which have been termed *intercellular biliary passages*, or *bile capillaries*. These passages are merely little channels or interspaces left between the contiguous surfaces of two cells, or in the angle where three or more liver-cells meet (fig. 620), and it seems doubtful whether there is any delicate membrane forming the wall of the space. The channels thus formed radiate to the circumference of the lobule, and, piercing its wall, form a plexus (*interlobular*) between the lobules. From this plexus ducts are derived which pass into the portal canals, become enclosed in Glisson's capsule, and, accompanying the portal vein and hepatic artery (fig. 621), join with other ducts to form two main trunks, which leave the liver at the transverse fissure, and by their union form the hepatic duct.

FIG. 620.—Section of liver.

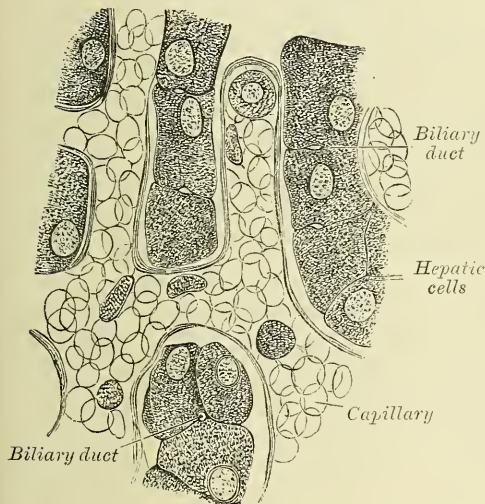
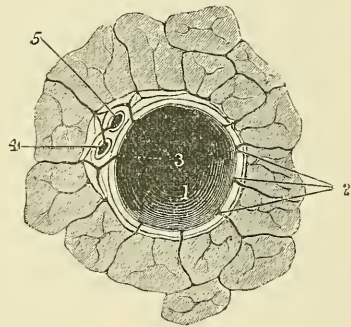


FIG. 621.—A transverse section of a small portal canal and its vessels. (After Kiernan.)



1. Portal vein. 2. Interlobular branches.  
3. Vaginal branches. 4. Hepatic duct.  
5. Hepatic artery.

**Structure.**—The coats of the smallest biliary ducts, which lie in the interlobular spaces, are a connective tissue coat, in which are muscle cells, arranged both circularly and longitudinally, and an epithelial layer, consisting of short columnar cells. In the larger ducts, which lie in the portal canals, there are a number of orifices disposed in two longitudinal rows, which were formerly regarded as the openings of mucous glands, but which are merely the orifices of tubular recesses. They occasionally anastomose, and from the sides of them saccular dilatations are given off.

#### EXCRETORY APPARATUS OF THE LIVER

The excretory apparatus of the liver consists of (1) the *hepatic duct*, which, as we have seen, is formed by the junction of the two main ducts, which pass out of the liver at the transverse fissure, and are formed by the union of the bile capillaries; (2) the *gall-bladder*, which serves as a reservoir for the bile; (3) the *cystic-duct*, which is the duct of the gall-bladder; and (4) the common bile duct, formed by the junction of the hepatic and cystic ducts.

**The hepatic duct.**—Two main trunks of nearly equal size issue from the liver at the transverse fissure, one from the right, the other from the left lobe; these unite to form the hepatic duct, which then passes downwards and to the right for about an inch and a half, between the layers of the lesser omentum, where it joins at an acute angle with the cystic duct, and so forms the ductus communis choledochus. The hepatic duct, as it descends from the transverse fissure of the liver, between the two layers of the lesser omentum, lies in company with the hepatic artery and portal vein.

The **Gall-bladder** is the reservoir for the bile; it is a conical or pear-shaped musculo-membranous sac, lodged in a fossa on the under surface of the right lobe of the liver, and extending from near the right extremity of the transverse fissure to the anterior border of the organ. It is about four inches in length, one inch in breadth at its widest part, and holds from eight to ten drachms. It is divided into a fundus, body, and neck. The *fundus*, or broad extremity, is directed downwards, forwards, and to the right, and occasionally projects beyond the anterior border of the liver; the *body* and *neck* are directed upwards and backwards to the left. The upper surface of the gall-bladder is attached to the liver by connective tissue and vessels. The under surface is covered by peritoneum, which is reflected on to it from the surface of the liver. Occasionally the whole of the organ is invested by the serous membrane, and is then connected to the liver by a kind of mesentery.

**Relations.**—The *body of the gall-bladder* is in relation, by its upper surface, with the liver, to which it is connected by areolar tissue and vessels; by its under surface, with the first portion of the duodenum, occasionally the pyloric end of the stomach, and the hepatic flexure of the colon. The *fundus* is completely invested by peritoneum; it is in relation, in front, with the abdominal parietes, immediately below the ninth costal cartilage; behind, with the transverse arch of the colon. The *neck* is narrow, and curves upon itself like the letter S; at its point of connection with the cystic duct it presents a well-marked constriction.

When the gall-bladder is distended with bile or calculi, the fundus may be felt through the abdominal parietes, especially in an emaciated subject: the relations of this sac will also serve to explain the occasional occurrence of abdominal biliary fistulæ, through which biliary calculi may pass out, and of the passage of calculi from the gall-bladder into the stomach, duodenum, or colon, which occasionally happens.

**Structure.**—The gall-bladder consists of three coats—serous, fibrous and muscular, and mucous.

The *external or serous coat* is derived from the peritoneum; it completely invests the fundus, but covers the body and neck only on their under surface.

The *fibro-muscular coat* is a thin but strong layer, which forms the framework of the sac, consisting of dense fibrous tissue, which interlaces in all directions, and is mixed with plain muscular fibres, which are disposed chiefly in a longitudinal direction, a few running transversely.

The *internal or mucous coat* is loosely connected with the fibrous layer. It is generally tinged with a yellowish-brown colour, and is everywhere elevated into minute rugæ, by the union of which numerous meshes are formed; the depressed intervening spaces having a polygonal outline. The meshes are smaller at the fundus and neck, being most developed about the centre of the sac. Opposite the neck of the gall-bladder the mucous membrane projects inwards in the form of oblique ridges or folds, forming a sort of screw-like valve.

The mucous membrane is covered with columnar epithelium, and secretes an abundance of thick viscid mucus; it is continuous through the hepatic duct with the mucous membrane lining the ducts of the liver, and through the ductus communis choledochus with the mucous membrane of the alimentary canal.

The **cystic duct**, the smallest of the three biliary ducts, is about an inch and a half in length. It passes obliquely downwards and to the left from the neck



of the gall-bladder, and joins the hepatic duct to form the common duct. It lies in the gastro-hepatic omentum in front of the vena portæ, the hepatic artery lying to its left side. The mucous membrane lining its interior is thrown into a series of crescentic folds, from five to twelve in number, similar to those found in the neck of the gall-bladder. They project into the duct in regular succession, and are directed obliquely round the tube, presenting much the appearance of a continuous spiral valve. When the duct has been distended, the spaces between the folds are dilated, so as to give to its exterior a sacculated appearance.

The **ductus communis choledochus**, the largest of the three, is the common excretory duct of the liver and gall-bladder. It is about three inches in length, of the diameter of a goose-quill, and formed by the junction of the cystic and hepatic duct.

It descends along the right border of the lesser omentum behind the first portion of the duodenum, in front of the vena porta, and to the right of the hepatic artery; it then passes between the pancreas and descending portion of the duodenum, and, running for a short distance along the right side of the pancreatic duct, near its termination, passes, with it, obliquely between the mucous and muscular coats. The two ducts open by a common orifice upon the summit of a papilla, situated at the inner side of the descending portion of the duodenum, a little below its middle.

**Structure.**—The coats of the large biliary ducts are, an external or fibrous, and an internal or mucous. The fibrous coat is composed of strong fibro-areolar tissue, with a certain amount of muscular tissue, arranged, for the most part, in a circular manner around the duct. The mucous coat is continuous with the lining membrane of the hepatic ducts and gall-bladder, and also with that of the duodenum; and, like the mucous membrane of these structures, its epithelium is of the columnar variety. It is provided with numerous mucous glands, which are lobulated and open by minute orifices, scattered irregularly in the larger ducts. The coats of the smallest biliary ducts, which lie in the interlobular spaces, are a connective tissue coat, in which, according to Heidenhain, are muscle cells, arranged both circularly and longitudinally, and an epithelial layer, consisting of short columnar cells.

**Surface Form.**—The liver is situated in the right hypochondriac and the epigastric regions, and is moulded to the arch of the Diaphragm. In the greater part of its extent it lies under cover of the lower ribs and their cartilages, but in the epigastric region it comes in contact with the abdominal wall, in the subcostal angle. The *upper limit of the right lobe of the liver* may be defined by a line drawn from the articulation of the fifth right costal cartilage to the sternum horizontally outwards to a little below the nipple, and then inclined downwards to reach the seventh rib at the side of the chest. The *upper limit of the left lobe* may be defined by continuing this line to the left with an inclination downwards as it crosses the gladiolus, to a point about two inches to the left of the sternum on a level with the sixth left costal cartilage. The *lower limit of the liver* may be indicated by a line drawn half an inch below the lower border of the thorax on the right side as far as the ninth right costal cartilage, and thence obliquely upwards across the subcostal angle to the eighth left costal cartilage. A slight curved line with its convexity to the left from this point, i.e. the eighth left costal cartilage, to the termination of the line indicating the upper limit, will denote the left margin of the liver. The fundus of the gall-bladder approaches the surface behind the anterior extremity of the ninth costal cartilage, close to the outer margin of the right Rectus muscle.

It must be remembered that the liver is subject to considerable alterations in position, and the student should make himself acquainted with the different circumstances under which this occurs, as they are of importance in determining the existence of enlargement or other diseases of the organ.

Its position varies according to the posture of the body. In the erect position in the adult male, the edge of the liver projects about half an inch below the lower edge of the right costal cartilages, and its anterior border can be often felt in this situation if the abdominal wall is thin. In the supine position the liver gravitates backwards, and recedes above the lower margin of the ribs, and cannot then be detected by the finger. In the prone position it falls forward, and can then generally be felt in a patient with loose and lax abdominal walls. Its position varies also with the ascent or descent of the Diaphragm. In a deep inspiration the liver descends below the ribs; in expiration it is raised behind them. Again, in emphysema, where the lungs are distended, and the Diaphragm descends

very low, the liver is pushed down; in some other diseases, as phthisis, where the Diaphragm is much arched, the liver rises very high up. Pressure from without, as in tight-lacing, by compressing the lower part of the chest, displaces the liver considerably: its anterior edge often extending as low as the crest of the ilium; and its convex surface is often at the same time deeply indented from the pressure of the ribs. Again, its position varies greatly according to the greater or less distension of the stomach and intestines. When the intestines are empty, the liver descends in the abdomen; but when they are distended, it is pushed upwards. Its relations to surrounding organs may also be changed by the growth of tumours, or by collections of fluid in the thoracic or abdominal cavities.

*Surgical Anatomy.*—On account of its large size, its fixed position, and its friability, the liver is more frequently ruptured than any of the abdominal viscera. The rupture may vary considerably in extent, from a slight scratch to an extensive laceration completely through its substance, dividing it into two parts. Sometimes an internal rupture, without laceration of the peritoneal covering, takes place, and such injuries are most susceptible of repair; but small tears of the surface may also heal; when, however, the laceration is extensive, death usually takes place from hæmorrhage, on account of the fact that the hepatic veins are contained in rigid canals in the liver-substance and are unable to contract, and are moreover unprovided with valves. The liver may also be torn by the end of a broken rib perforating the Diaphragm. The liver may be injured by stabs or other punctured wounds, and when these are inflicted through the chest wall, both pleural and peritoneal cavities may be opened up, and both lung and liver be wounded. In cases of wound of the liver from the front, hernia of a part of this viscus may take place, but can generally easily be replaced. Abscess of the liver is of not unfrequent occurrence, and may open in many different ways on account of the relations of this viscus to other organs. Thus it has been known to burst into the lungs and the pus coughed up, or into the stomach and the pus vomited; it may burst into the colon, or into the duodenum; or, by perforating the Diaphragm, it may empty itself into the pleural cavity. Frequently it makes its way forwards, and points on the anterior abdominal wall, and finally it may burst into the peritoneal or pericardiac cavities. Abscesses of the liver frequently require opening, and this should be done preferably by an incision in the right semilunar line, in two stages: the peritoneal cavity being opened and the liver over the summit of the abscess being stitched to the parietal peritoneum on the first occasion, and three or four days subsequently the abscess being evacuated. Hydatid cysts are more often found in the liver than in any other of the viscera. The reason of this is not far to seek. The embryo of the egg of the tania echinococcus, being liberated in the stomach by the disintegration of its shell, bores its way through the gastric walls and usually enters a blood-vessel, and is carried by the blood-stream to the hepatic capillaries, where its onward course is arrested, and where it undergoes development into the fully formed hydatid.

When the *gall-bladder* is ruptured, or one of its main ducts, which may occur independently of laceration of the liver, the injury is necessarily fatal, from peritonitis caused by the extravasation of bile into the peritoneal cavity.

The gall-bladder may become distended with bile in cases of obstruction of its duct or the common bile duct, or from a collection of gall-stones within its interior, thus forming a large tumour. The swelling is pear-shaped, and projects downwards and forwards to the umbilicus. It moves with respiration, since it is attached to the liver. To relieve this condition, the gall-bladder must be opened and the gall-stones removed. The operation is performed by an incision, two or three inches long in the right semilunar line, commencing an inch below the costal margin. The peritoneal cavity is opened, and the tumour having been found, sponges are packed round it to protect the peritoneal cavity, and it is aspirated. When the contained fluid has been evacuated the flaccid bladder is drawn out of the abdominal wound and its wall incised to the extent of an inch; any gall-stones in the bladder are now removed and the interior of the sac sponged dry. If the case is one of obstruction of the duct, an attempt must be made to dislodge the stone by manipulation through the wall of the duct; or it may be crushed from without by carefully padded forceps; or it may be broken up by a needle introduced into the duct through the gall-bladder. After all obstruction has been removed, four courses are open to the surgeon: 1. The wound in the gall-bladder may be at once sewn up, the organ returned into the abdominal cavity and the external incision closed. 2. The edges of the incision in the gall-bladder may be sutured to the external wound, and a fistulous communication established between the gall-bladder and the exterior; this fistulous opening usually closes in the course of a few weeks. 3. The gall-bladder may be connected with the intestinal canal, preferably the duodenum, by means of a lateral anastomosis; this is known as cholecystenterostomy. 4. The gall-bladder may be completely removed.







The *posterior surface* is separated from the vertebral column by the aorta, the splenic vein, the left kidney and its vessels, the left suprarenal capsule, the pillars of the Diaphragm, and the origin of the superior mesenteric artery.

The *inferior surface* is narrow, and lies upon the duodenum-jejunal flexure and on some coils of the jejunum; its left extremity rests on the splenic flexure of the colon.

The *superior border* of the body is blunt and flat to the right; narrow and sharp to the left, near the tail. It commences to the right in a well marked prominence called the omental tuberosity; to the left of this it is in relation with the celiac axis, from which the hepatic artery courses to the right just above the gland, whilst the splenic branch runs in a groove along this border to the left.

The *anterior border* is the position where the two layers of the transverse meso-colon separate: the one passing upwards in front of the anterior surface; the other passing backwards below the inferior surface.

The *lesser end* or *tail of the pancreas* is narrow; it extends to the left as far as the spleen, and is placed over the left kidney and suprarenal capsule.

Birmingham describes the body of the pancreas as projecting forwards as a prominent ridge into the abdominal cavity and forming a sort of shelf on which the stomach lies. He says: 'The portion of the pancreas to the left of the middle line has a very considerable antero-posterior thickness; as a result the anterior surface is of considerable extent, it looks strongly upwards and forms a large and important part of the shelf. As the pancreas extends to the left towards the spleen, it crosses the upper part of the kidney and is so moulded on to it that the top of the kidney forms an extension inwards and backwards of the upper surface of the pancreas and extends the bed in this direction. On the other hand, the extremity of the pancreas comes in contact with the spleen in such a way that the plane of its upper surface runs with little interruption upwards and backwards into the concave gastric surface of the spleen, which completes the bed behind and to the left, and running upwards, forms a partial cap for the wide end of the stomach' (see fig. 599).\*

The **pancreatic duct**, called the **canal of Wirsung**, from its discoverer, extends transversely from left to right through the substance of the pancreas, nearer to its lower than its upper border, and lying nearer its anterior than its posterior surface. In order to expose it, the superficial portion of the gland must be removed. It commences by the junction of the small ducts of the lobules situated in the tail of the pancreas, and, running from right to left, it constantly receives the ducts of the various lobules composing the gland, and, considerably augmented in size, it leaves the head of the pancreas, and, turning obliquely downwards, backwards and to the right, it gets into relation with the common bile duct, lying to its left side, and passing very obliquely through the mucous and muscular coats of the duodenum, it terminates by an orifice common to it and the ductus communis choledochus upon the summit of an elevated papilla, situated at the inner side of the descending portion of the duodenum, a little below its middle.

Sometimes the pancreatic duct and ductus communis choledochus open separately into the duodenum. Occasionally there is an accessory duct, which is given off from the canal of Wirsung in the neck of the pancreas and passes horizontally to the right to open into the duodenum about an inch above the orifice of the main duct. This is known as the *ductus pancreaticus accessorius* or *ductus Santorini*.

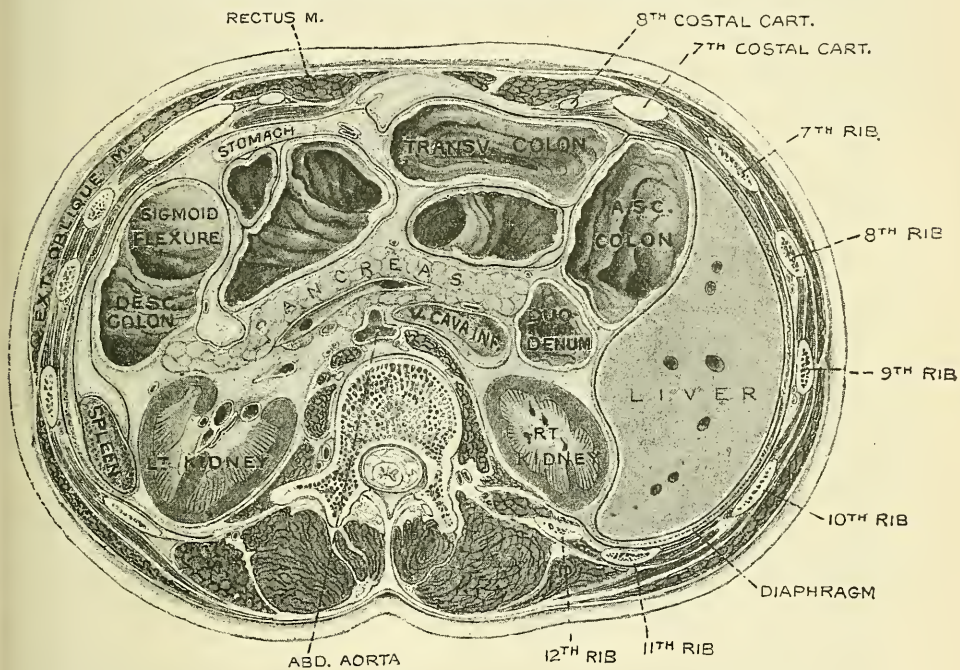
The pancreatic duct, near the duodenum, is about the size of an ordinary quill: its walls are thin, consisting of two coats, an external fibrous and an internal mucous; the latter is thin, smooth, and furnished near its termination with a few scattered follicles.

In **structure**, the pancreas resembles the salivary glands. It differs from them, however, in certain particulars, and is looser and softer in its texture. It is not

\* *Journal of Anatomy and Physiology*, vol. xxxi. pt. 1, p. 102.

enclosed in a distinct capsule, but is surrounded by areolar tissue, which dips down into its interior, and connects together the various lobules of which it is composed. Each lobule, like the lobules of the salivary glands, consists of one of the ultimate ramifications of the main duct, terminating in a number of caecal pouches or alveoli, which are tubular and somewhat convoluted. The minute ducts connected with the alveoli are narrow and lined with flattened cells. The alveoli are almost completely filled with secreting cells, so that scarcely any lumen is visible. In some animals those cells which occupy the centre of the alveolus are spindle-shaped, and are known as the *centro-acinar cells of Langerhans*. The true secreting cells which line the wall of alveolus are very characteristic. They are columnar in shape and present two zones; an outer one clear and finely striated next the basement membrane, and an inner granular one next the lumen. During activity the granular zone occupies the greater part of the cell: before the cells are called into action, whilst in a condition of rest, the outer or

FIG. 623.—Transverse section through the middle of the first lumbar vertebra, showing the relations of the pancreas. (Braune.)



clear zone is the larger. In some secreting cells of the pancreas is a spherical mass, staining more easily than the rest of the cells; this is termed the *paranucleus*, and is believed to be an extension from the nucleus. The connective tissue between the alveoli presents in certain parts collections of cells, which are termed *inter-alveolar cell-islets*.

**Vessels and Nerves.**—The *arteries of the pancreas* are derived from the splenic and the pancreatico-duodenal branches of the hepatic and the superior mesenteric. Its *veins* open into the splenic and superior mesenteric veins. Its *lymphatics* terminate in the lumbar glands. Its *nerves* are filaments from the splenic plexus.

**Surface Form.**—The pancreas lies in front of the first lumbar vertebra, and can sometimes be felt, in emaciated subjects, when the stomach and colon are empty, by making deep pressure in the middle line about three inches above the umbilicus.

**Surgical Anatomy.**—The pancreas presents but little of surgical importance. It is occasionally the seat of cancer, which usually affects the head or duodenal end, and therefore often speedily involves the common bile duct, leading to persistent jaundice.



Cysts are also occasionally found in it, which may present in the epigastric region, above and to the right of the umbilicus, and may require opening and draining. The fluid in them contains some of the elements of the pancreatic secretion, and is very irritating, so that, if allowed to come in contact with the skin of the abdominal wall, it is likely to produce intractable eczema. It has been said that the pancreas is the only abdominal viscus which has never been found in a hernial protrusion; but even this organ has been found, in company with other viscera, in rare cases of diaphragmatic hernia. The pancreas has been known to become invaginated into the intestine, and portions of the organ have sloughed off. In cases of excision of the pylorus great care must be exercised to avoid wounding the pancreas, as the escape of the pancreatic fluid may be attended with serious results. According to Billroth, it is likely, in consequence of its peptonising qualities, to dissolve the cicatrix of the stomach.

### THE SPLEEN

The **Spleen** belongs to that class of bodies which are known as *ductless glands*. It is probably related to the blood-vascular system, but in consequence of its anatomical relationship to the liver it is convenient to describe it in this place. It is situated principally in the left hypochondriac region, its upper and inner extremity extending into the epigastric region; lying between the fundus of the stomach and the Diaphragm. It is the largest of the ductless glands, and is of an oblong, flattened form, soft, of very brittle consistence, highly vascular, of a dark bluish-red colour, and situated in the left hypochondriac region, embracing the cardiac end of the stomach.

**Relations.**—The *external* or *phrenic surface* is convex, smooth, and is directed upwards, backwards and to the left, except at its upper end, where it is directed inwards. It is in relation with the under surface of the Diaphragm, which separates it from the ninth, tenth, and eleventh ribs of the left side and in part from the lower border of the left lung and pleura. The *internal surface* is concave, and divided by a ridge into an anterior or larger, and a posterior or smaller portion.

The *anterior portion* of the internal surface or *gastric surface*, which is directed forwards and inwards, is broad and concave, and is in contact with the posterior wall of the great end of the stomach; and below this with the tail of the pancreas. It presents near its inner border a long fissure, termed the *hilum*. This is pierced by several irregular apertures, for the entrance and exit of vessels and nerves.

The *posterior portion* of the internal surface or *renal surface* is directed inwards and downwards. It is flat, does not reach as high as the gastric surface, and is in relation with the outer surface of the left kidney and occasionally with the left suprarenal capsule.

The *upper end*, thick and rounded, is directed inwards, towards the vertebral column, where it lies on a level with the tenth or eleventh dorsal vertebra. The *lower end*, sometimes termed the *basal surface*, is flat, triangular in shape, and rests upon the splenic flexure of the colon and the phreno-colic ligament, and generally is in contact with the tail of the pancreas. The *anterior* border is free, sharp and thin, and is often notched, especially below. It separates the phrenic from the internal surface. The *posterior* border is more rounded and blunter than the anterior. It separates the renal portion of the internal surface from the phrenic surface. It corresponds to the lower border of the eleventh rib and lies between the Diaphragm and left kidney. The *internal* border is the name sometimes given to the ridge which separates the renal and gastric portions of the internal surface.

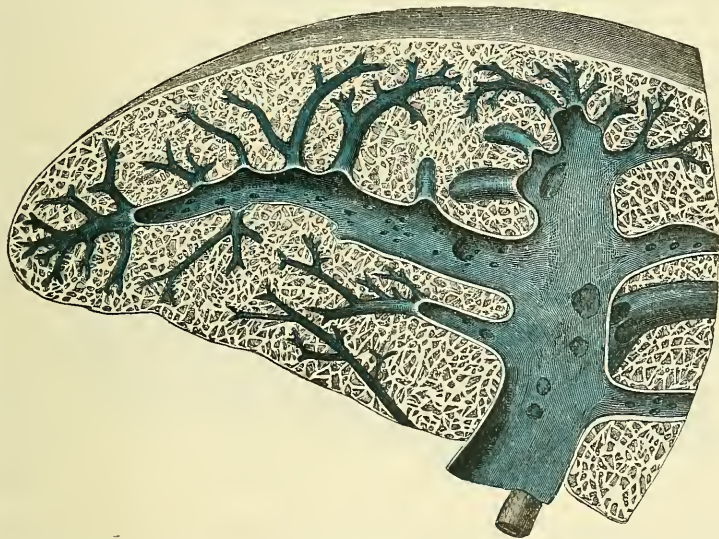The spleen is held in position by folds of peritoneum: one, the *suspensory ligament*, passes from the left crus of the Diaphragm to the so-called inner border of the spleen, from which it is reflected over the gastric and renal surfaces; a second, the *lienorenal ligament*, which is formed by the layers of peritoneum forming the greater and lesser sacs, where they come into contact between the left kidney and the spleen. Between the two layers the splenic vessels pass (fig.



592); and a third, the *gastro-splenic omentum*, also formed of two layers, derived from the greater and lesser sacs respectively, where they meet between the spleen and stomach (fig. 592). Between these two layers run the vasa brevia of the splenic artery and vein. It is also supported by the phreno-colic ligament, upon which its lower end rests (see page 966).

The size and weight of the spleen are liable to very extreme variations at different periods of life, in different individuals, and in the same individual under different conditions. *In the adult*, in whom it attains its greatest size, it is usually about five inches in length, three or four inches in breadth, and an inch or an inch and a half in thickness, and weighs about seven ounces. *At birth*, its weight, in proportion to the entire body, is almost equal to what is observed in the adult, being as 1 to 350: whilst in the adult it varies from 1 to 320 and 400. *In old age*, the organ not only decreases in weight, but decreases considerably in proportion to the entire body, being as 1 to 700. The size of the spleen is increased during and after digestion, and varies considerably according to the state of nutrition of the body, being large in highly-fed, and small in starved animals. In intermittent and other fevers it becomes much enlarged, weighing occasionally from 18 to 20 pounds.

FIG. 624.—Transverse section of the spleen, showing the trabecular tissue and the splenic vein and its branches.



Frequently in the neighbourhood of the spleen, and especially in the gastro-splenic and great omenta, small nodules of splenic tissue may be found, either isolated or connected to the spleen by thin bands of splenic tissue. They are known as *supernumerary* or *accessory spleens*. They vary in size from a pea to a plum.

**Structure.**—The spleen is invested by two coats—an external serous, and an internal fibro-elastic coat.

The *external* or *serous coat* is derived from the peritoneum; it is thin, smooth, and in the human subject intimately adherent to the fibro-elastic coat. It invests the entire organ, except at the places of its reflection on to the stomach and Diaphragm and at the hilum.

The *fibro-elastic coat* forms the framework of the spleen. It invests the exterior of the organ, and at the hilum is reflected inwards upon the vessels in the form of vaginae or sheaths. From these sheaths, as well as from the inner surface of the fibro-elastic coat, numerous small fibrous bands, *trabeculae* (fig. 624), are given off in all directions; these uniting, constitute the areolar framework of the spleen. The framework of the spleen resembles, therefore, a sponge-like

material, consisting of a number of small spaces or *areolæ*, formed by the trabeculæ, which are given off from the inner surface of the capsule, or from the sheaths prolonged inwards on the blood-vessels. And in these spaces or areolæ is contained the *splenic pulp*.

The proper coat, the sheaths of the vessels and the trabeculæ, consist of a dense mesh of white and yellow elastic fibrous tissues, the latter considerably predominating. It is owing to the presence of this tissue that the spleen possesses a considerable amount of elasticity, which allows of the very great variations in size that it presents under certain circumstances. In addition to these constituents of this tunic, there is found in man a small amount of non-striped muscular fibre; and in some mammalia (e.g. dog, pig, and cat) a very considerable amount, so that the trabeculæ appear to consist chiefly of muscular tissue. It is probably owing to this structure that the spleen exhibits, when acted upon by the galvanic current, faint traces of contractility.

The *proper substance of the spleen* or *splenic pulp* is a soft mass of a dark reddish-brown colour, resembling grumous blood. When examined, by means of a thin section, under the microscope, it is found to consist of a number of branching cells, and of an intercellular substance. The cells are connective-tissue corpuscles, and have been named the *sustentacular* or *supporting cells of the pulp*. The processes of these branching cells communicate with each other, thus forming a delicate reticulated tissue in the interior of the areolæ formed by the trabeculæ of the capsule. So that each primary space may be considered to be divided into a number of smaller spaces by the junction of these processes of the branching corpuscles. These secondary spaces contain blood, in which, however, the white corpuscles are found to be in larger proportion than they are in ordinary blood. The sustentacular cells are either small, uni-nucleated, or larger, multi-nucleated cells; they do not become deeply stained with carmalum, like the cells of the Malpighian bodies, presently to be described (W. Müller), but like them they possess amœboid movements (Cohnheim). In many of them may be seen deep red or reddish-yellow granules of various sizes, which present the characters of the hæmatin of the blood. Sometimes, also, unchanged blood-discs are seen included in these cells, but more frequently blood-discs are found which are altered both in form and colour. In fact, blood-corpuscles in all stages of disintegration may be noticed to occur within them. Klein has recently pointed out that sometimes these cells, in the young spleen, contain a proliferating nucleus; that is to say, the nucleus is of large size, and presents a number of knob-like projections, as if small nuclei were budding from it by a process of gemmation. This observation is of importance, as it may explain one possible source of the colourless blood-corpuscles.

The interspaces or areolæ formed by the framework of the spleen are thus filled by a delicate reticulum of branched connective-tissue corpuscles, the interstices of which are occupied by blood, and in which the blood-vessels terminate in the manner now to be described.

*Blood-vessels of the Spleen.*—The splenic artery is remarkable for its large size in proportion to the size of the organ, and also for its tortuous course. It divides into from four to six branches, which enter the hilum of the spleen and ramify throughout its substance (fig. 625), receiving sheaths from an involution of the external fibrous tissue. Similar sheaths also invest the nerves and veins.

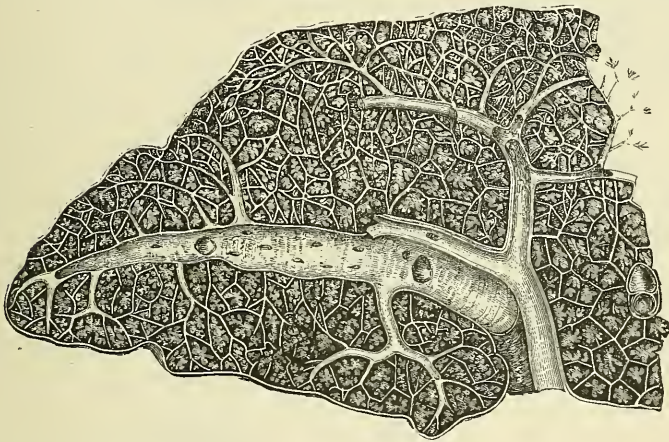
Each branch runs in the transverse axis of the organ, from within outwards, diminishing in size during its transit, and giving off in its passage smaller branches, some of which pass to the anterior, others to the posterior part. These ultimately leave the trabecular sheaths, and terminate in the proper substance of the spleen in small tufts or pencils of minute arterioles, which open into the interstices of the reticulum formed by the branched sustentacular cells. Each of the larger branches of the artery supplies chiefly that region of the organ in which the branch ramifies, having no anastomosis with the majority of the other branches.



The *arterioles*, supported by the minute trabeculæ, traverse the pulp in all directions in bundles or pencilli of straight vessels. Their external coat, on leaving the trabecular sheaths, consists of ordinary connective tissue, but it gradually undergoes a transformation, becomes much thickened, and converted into a lymphoid material.\* This change is effected by the conversion of the connective tissue into a cytogenous tissue; the bundles of connective tissue becoming looser and laxer, their fibrils more delicate, and containing in their interstices an abundance of lymph-corpuscles (W. Müller). This lymphoid material is supplied with blood by minute vessels derived from the artery with which they are in contact, and which terminates by breaking up into a network of capillary vessels.

The altered coat of the arterioles, consisting of lymphoid tissue, presents here and there thickenings of a spheroidal shape, the *Malpighian bodies of the spleen*. These bodies vary in size from about the  $\frac{1}{100}$  of an inch to the  $\frac{1}{25}$  of an inch in diameter. They are merely local expansions or hyperplasiæ of the lymphoid tissue, of which the external coat of the smaller arteries of the spleen is formed. They are most frequently found surrounding the arteriole, which thus seems to tunnel them, but occasionally they grow from one side of the vessel only, and present the appearance of a sessile bud growing from the arterial wall. Klein,

FIG. 625.—Transverse section of the human spleen, showing the distribution of the splenic artery and its branches.



however, denies this, and says it is incorrect to describe the Malpighian bodies as isolated masses of adenoid tissue, but that they are always formed around an artery, though there is generally a greater amount on one side than the other, and that, therefore, in transverse sections, the artery, in the majority of cases, is found in an eccentric position. These bodies are visible to the naked eye on the surface of a fresh section of the organ, appearing as minute dots of a semi-opaque whitish colour in the dark substance of the pulp. In minute structure they resemble the adenoid tissue of lymphatic glands, consisting of a delicate reticulum, in the meshes of which lie ordinary lymphoid cells.

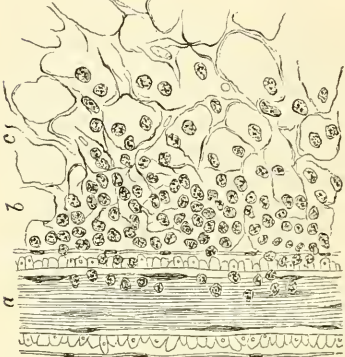
The reticulum of the tissue is made up of extremely delicate fibrils, and is comparatively open in the centre of the corpuscle, becoming closer at the periphery of the body. The cells which it encloses, like the supporting cells of the pulp, are possessed of amœboid movements, but when treated with carmine become deeply stained, and can thus easily be recognised from those of the pulp.

\* According to Klein, it is the sheath of the small vessel which undergoes this transformation, and forms a 'solid mass of adenoid tissue which surrounds the vessel like a cylindrical sheath.'—*Atlas of Histology*, p. 424.



The arterioles terminate in capillaries, which traverse the pulp in all directions; their walls become much attenuated, lose their tubular character, and the cells of the lymphoid tissue of which they are composed become altered, presenting a branched appearance, and acquiring processes which are directly connected with the processes of the sustentacular cells of the pulp (fig. 627). In this manner the capillary vessels terminate, and the blood flowing through them

FIG. 626.—Part of a Malpighian capsule of the spleen of man. (Klein and Noble Smith.)



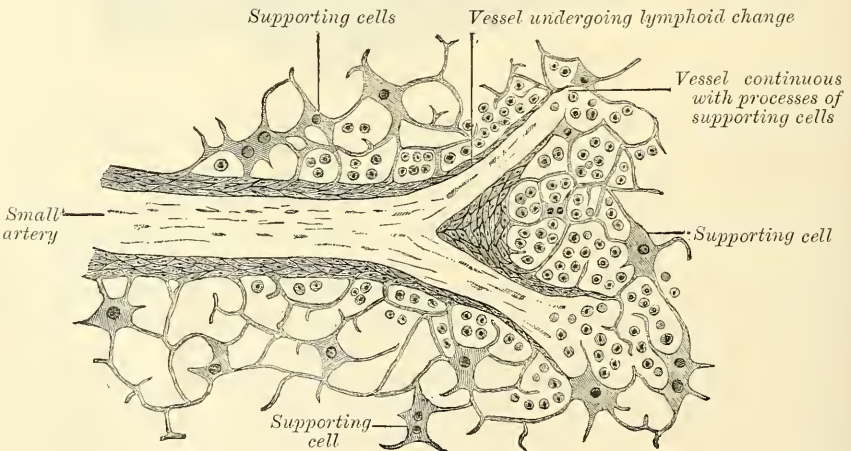
a. Arterial branch in longitudinal section. b. Adenoid tissue, still containing the lymph-corpuscles; only their nuclei are shown. c. Adenoid reticulum, the lymph-corpuscles accidentally removed.

finds its way into the interstices of the reticulated tissue formed by the branched connective-tissue corpuscles of the splenic pulp. Thus the blood passing through the spleen is brought into intimate relation with the elements of the pulp, and no doubt undergoes important changes.

After these changes have taken place the blood is collected from the interstices of the tissue by the rootlets of the veins, which commence much in the same way as the arteries terminate. Where a vein is about to commence the connective-tissue corpuscles of the pulp arrange themselves in rows, in such a way as to form an elongated space or sinus. They become changed in shape, being elongated and spindle-shaped, and overlap each other at their extremities. They thus form a sort of endothelial lining of the path or sinus, which is the radicle of a vein. On the outer surface of these cells are seen delicate trans-

verse lines or markings, which are due to minute elastic fibrillæ arranged in a circular manner around the sinus. Thus the channel obtains a continuous external investment, and gradually becomes converted into a small vein, which after a time presents a coat of ordinary connective tissue, lined by a layer of fusiform epithelial cells, which are continuous with the supporting cells of the pulp. The smaller veins unite to form larger ones, which do not accompany the arteries,

FIG. 627.—Section of spleen, showing the termination of the small blood-vessels.



but soon enter the trabecular sheaths of the capsule, and by their junction form from four to six branches, which emerge from the hilum, and, uniting, form the splenic vein, the largest radicle of the vena porta.

The veins are remarkable for their numerous anastomoses, while the arteries hardly anastomose at all.

The lymphatics originate in two ways, i.e. from the sheaths of the arteries and in the trabeculæ. The former accompany the blood-vessels, the latter pass to the superficial lymphatic plexus which may be seen on the surface of the organ. The two sets communicate in the interior of the organ. They pass through the lymphatic glands at the hilum, and terminate in the thoracic duct.

The *nerves* are derived from branches of the right and left semilunar ganglia, and from the right pneumogastric nerve.

*Surface Form.*—The spleen is situated under cover of the ribs of the left side, being separated from them by the Diaphragm, and above by a small portion of the lower margin of the left lung and pleura. Its position corresponds to the ninth, tenth, and eleventh ribs. It is placed very obliquely. 'It is oblique in two directions, viz. from above downwards and outwards, and also from above downwards and forwards' (Cunningham). 'Its highest and lowest points are on a level respectively with the ninth dorsal and first lumbar spines; its inner end is distant about an inch and a half from the median plane of the body, and its outer end about reaches the mid-axillary line' (Quain).

*Surgical Anatomy.*—Injury of the spleen is less common than that of the liver, on account of its protected situation and connections. It may be ruptured by direct or indirect violence; torn by a broken rib; or injured by a punctured or gunshot wound. When the organ is enlarged, the chance of rupture is increased. The great risk is hæmorrhage, owing to the vascularity of the organ, and the absence of a proper system of capillaries. The injury is not, however, necessarily fatal, and this would appear to be due, in a great measure, to the contractile power of its capsule, which narrows the wound and prevents the escape of blood. In cases where the diagnosis is clear and the symptoms indicate danger to life, laparotomy must be performed, and if the hæmorrhage cannot be stayed by ordinary surgical methods, the spleen must be removed. The spleen may become displaced, producing great pain from stretching of the vessels and nerves, and this may require removal of the organ. The spleen may become enormously enlarged in certain diseased conditions, such as ague, syphilis, valvular disease of the heart, or without any obtainable history of previous disease. It may also become enlarged in lymphadenoma, as a part of a general blood-disease. In these cases the tumour may sometimes fill the abdomen and extend into the pelvis, and may be mistaken for ovarian or uterine disease.

The spleen is sometimes the seat of cystic tumours, especially hydatids, and of abscess. These cases require treatment by incision and drainage; and in abscess great care must be taken, if there are no adhesions between the spleen and abdominal cavity, to prevent the escape of any of the pus into the peritoneal cavity. If possible the operation should be performed in two stages, as in abscess of the liver. Sarcoma and carcinoma are occasionally found in the spleen, but very rarely as a primary disease.

Extirpation of the spleen has been performed for wounds or injuries, in floating spleen, in simple hypertrophy, and in leucæmic enlargement; but in these latter cases the operation is now regarded as unjustifiable, as every case in which it has been performed has terminated fatally. The incision is best made in the left semilunar line; the spleen is isolated from its surroundings, and the pedicle transfixed and ligatured in two portions, before the tumour is turned out of the abdominal cavity, if this is possible, so as to avoid any traction on the pedicle, which may cause tearing of the splenic vein. In applying the ligature care must be taken not to include the tail of the pancreas, and in lifting out the organ to avoid rupturing the capsule.

## THE THORAX

**T**HE Thorax is a cone-shaped cavity, containing and protecting the heart, enclosed in its membranous bag, the *pericardium*; and the lungs, invested by the pleura. Its shape and boundaries have already been described (see page 210).

**The cavity of the thorax.**—The size of the cavity of the thorax does not correspond with its apparent size externally, because (1) the space enclosed by the lower ribs is occupied by some of the abdominal viscera; and (2) the cavity extends above the first rib into the neck. The size of the cavity of the thorax is constantly varying during life with the movements of the ribs and Diaphragm, and with the degree of distension of the abdominal viscera. From the collapsed state of the lungs in the dead body, it would appear as if the viscera only partly filled the cavity of the thorax, but during life there is no vacant space, that which is seen after death being filled up by the expanded lungs.

**The upper opening of the thorax.**—The parts which pass through the upper opening of the thorax are, from before backwards in the middle line, the Sternohyoid and Sternothyroid muscles, the remains of the thymus gland, the trachea, œsophagus, thoracic duct, and the Longus colli muscle of each side; at the sides, the innominate artery, the left common carotid and left subclavian arteries, the internal mammary and superior intercostal arteries, the right and left innominate veins, and the inferior thyroid veins, the pneumogastric, cardiac, phrenic, and sympathetic nerves, the anterior branch of the first dorsal nerve, and the recurrent laryngeal nerve of the left side. The apex of each lung, covered by the pleura, also projects through this aperture, a little above the margin of the first rib.

**The lower opening of the thorax** is wider transversely than from before backwards. It slopes obliquely downwards and backwards, so that the cavity of the thorax is much deeper behind than in front. The Diaphragm (see page 443) closes in the opening, forming the floor of the thorax. The floor is flatter at the centre than at the sides, and is higher on the right side than on the left, corresponding in the dead body to the upper border of the fifth costal cartilage on the former, and to the corresponding part of the sixth costal cartilage on the latter. From the highest point on each side the floor slopes suddenly downwards to the attachment of the Diaphragm to the ribs; this is more marked behind than in front, so that only a narrow space is left between it and the wall of the thorax.

### THE PERICARDIUM

The **Pericardium** (figs. 628, 629) is a conical membranous sac, in which the heart and the commencement of the great vessels are contained. It is placed behind the sternum, and the cartilages of the third, fourth, fifth, sixth, and seventh ribs of the left side, in the interval between the pleuræ.

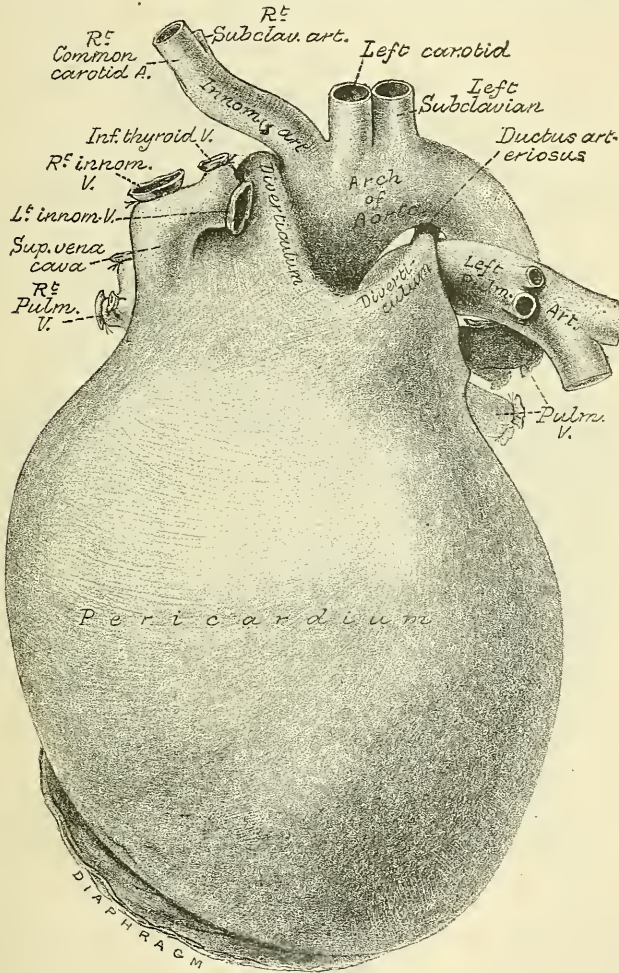
Its *apex* is directed upwards, and surrounds the great vessels about two inches above their origin from the base of the heart. Its *base* is attached to the central tendon and part of the adjoining muscular structure of the Diaphragm, extending a little farther to the left than to the right side. *In front* it is



separated from the sternum by the remains of the thymus gland above, and a little loose areolar tissue below; and is covered by the margins of the lungs, especially the left. *Behind*, it rests upon the bronchi, the œsophagus, and the descending aorta. *Laterally*, it is covered by the pleuræ; the phrenic nerve, with its accompanying vessels, descending between the two membranes on either side.

**Structure of the Pericardium.**—The pericardium is a fibro-serous membrane, and consists, therefore, of two layers, an external fibrous and an internal serous.

FIG. 628.—Pericardium, from in front. The sac has been distended with plaster. (From a preparation in the Museum of the Royal College of Surgeons.)

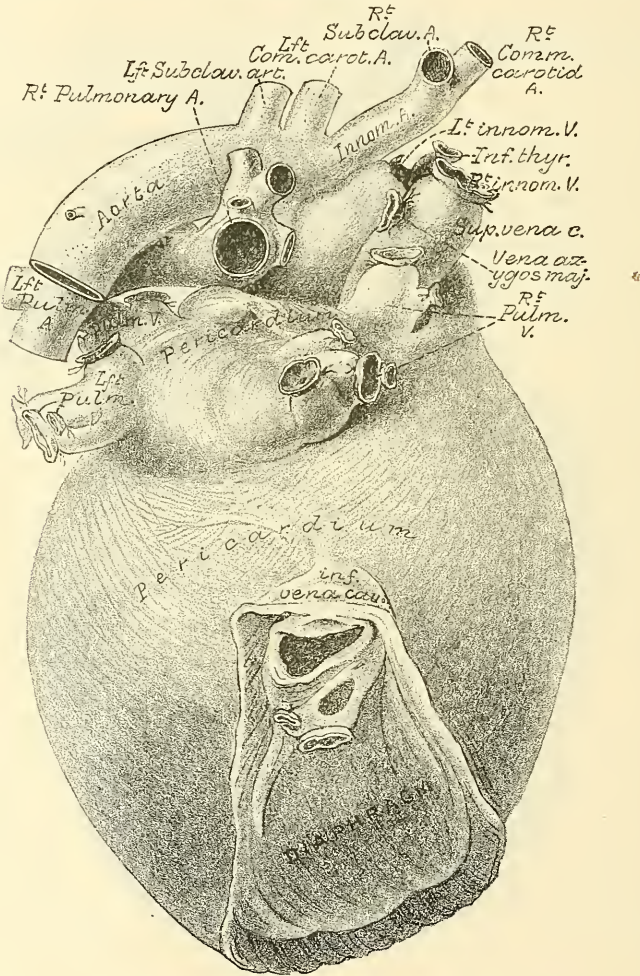


The *fibrous layer* is a strong, dense membrane. Above, it surrounds the great vessels arising from the base of the heart, on which it is continued in the form of tubular prolongations, which are gradually lost upon their external coat; the strongest being that which encloses the aorta. The pericardium may be traced, over these vessels, to become continuous with the deep layer of the cervical fascia. In front the pericardium is connected to the posterior surface of the sternum by two fibrous bands, the *superior* and *inferior sterno-pericardiac ligaments*; the upper passing to the manubrium, and the lower to the ensiform cartilage. On each side of the ascending aorta it sends upwards a diverticulum; the one on the left side, somewhat conical in shape, passes upwards and outwards, between

the arch of the aorta and the pulmonary artery, as far as the ductus arteriosus, where it terminates in a cæcal extremity which is attached by loose connective tissue to the obliterated duct (fig. 628). The one on the right side passes upwards and to the right, between the ascending aorta and vena cava superior, and also terminates in a cæcal extremity. Below, the fibrous layer is attached to the central tendon of the Diaphragm; and, on the left side, to its muscular fibres.

The vessels receiving fibrous prolongations from this membrane are, the aorta, the superior vena cava, the right and left pulmonary arteries, and the four

FIG. 629.—Pericardium, from behind. (From the same preparation as the preceding figure.)



pulmonary veins. As the inferior vena cava enters the pericardium through the central tendon of the Diaphragm, it receives no covering from the fibrous layer.

The *serous layer* invests the heart, and is then reflected on the inner surface of the pericardium. It consists, therefore, of a visceral and parietal portion. The former invests the surface of the heart, and the commencement of the great vessels, to the extent of an inch and a half from their origin; from these it is reflected upon the inner surface of the fibrous layer, lining, below, the upper surface of the central tendon of the Diaphragm. The serous membrane encloses the aorta and pulmonary artery in a single tube; but it only partially covers the



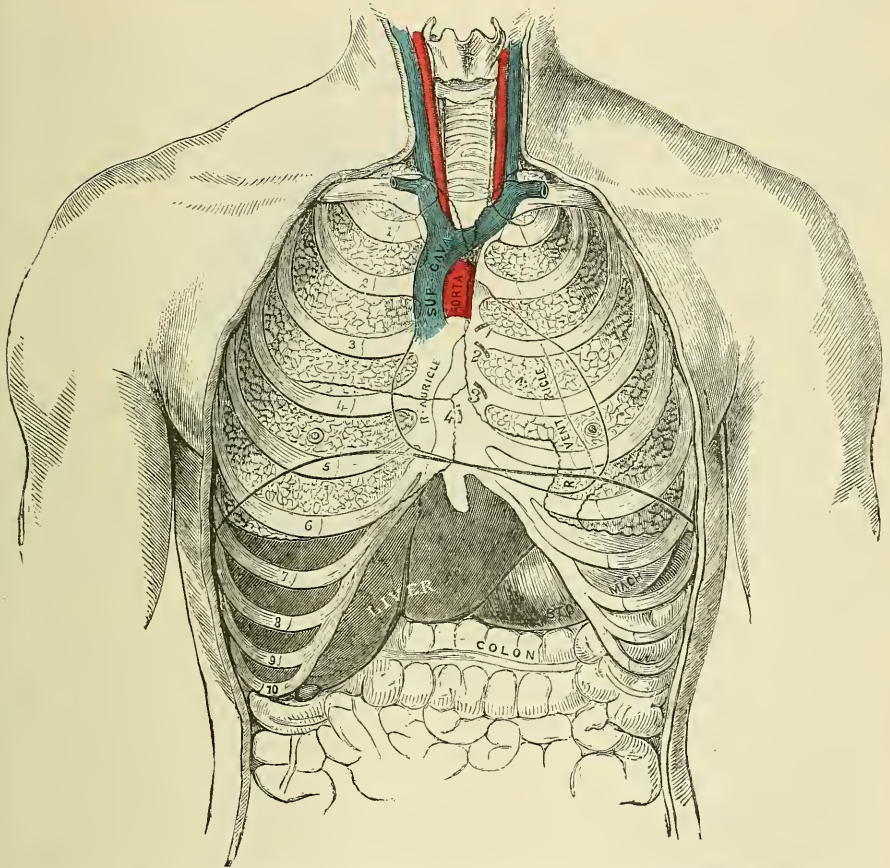
superior and inferior vena cava and the four pulmonary veins. Its inner surface is smooth and glistening, and secretes a thin fluid, which serves to facilitate the movements of the heart.

*Arteries of the pericardium.*—These are derived from the internal mammary, and its musculo-phrenic branch, and from the descending thoracic aorta.

*Nerves of the pericardium.*—These are branches from the vagus, the phrenic, and the sympathetic.

*The vestigial fold of the pericardium.*—Between the left pulmonary artery and the left pulmonary vein is a triangular reduplication of the serous pericardium; it is known as the *vestigial fold of Marshall*. It is formed by the duplicature of

FIG. 630.—Front view of the thorax. The ribs and sternum are represented in relation to the lungs, heart, and other internal organs.



1. Pulmonary orifice. 2. Aortic orifice. 3. Left auriculo-ventricular orifice. 4. Right auriculo-ventricular orifice.

the serous layer over the remnant of the lower part of the left superior cava (duct of Cuvier), which, after birth, became obliterated, and remains as a fibrous band stretching from the left superior intercostal vein to the left auricle. The duplicature also contains some adipose tissue, vessels, and nerves.

*Surgical Anatomy.*—Paracentesis of the pericardium is sometimes required in cases of effusion into its cavity. The operation is best performed in the fifth intercostal space, one inch to the left of the sternum. The operation has been performed, however, in the fourth, sixth, and seventh spaces, and also on the right side of the sternum.

## THE HEART

The **Heart** is a hollow muscular organ of a conical form, placed between the lungs, and enclosed in the cavity of the pericardium.



**Position.**—The heart is placed obliquely in the chest: the broad attached end, or base, is directed upwards, backwards, and to the right, and corresponds to the interval between the fifth and eighth dorsal vertebræ; the apex is directed downwards, forwards, and to the left, and corresponds to the space between the cartilage of the fifth and sixth ribs, three-quarters of an inch to the inner side, and an inch and a half below the left nipple. The heart is placed behind the lower two-thirds of the sternum, and projects farther into the left than into the right cavity of the chest, extending from the median line about three inches in the former direction, and only one and a half in the latter. The anterior surface of the heart is round and convex, directed upwards and forwards, and formed chiefly by the right ventricle and part of the left. Its posterior surface is flattened, and rests upon the Diaphragm, and is formed chiefly by the left ventricle. The right border is long, thin, and sharp; the left border short, but thick and round.

**Size.**—The heart, in the adult, measures five inches in length, three inches and a half in breadth in the broadest part, and two inches and a half in thickness. The prevalent weight, in the male, varies from ten to twelve ounces; in the female, from eight to ten: its proportions to the body being as 1 to 169 in males; 1 to 149 in females. The heart continues increasing in weight, and also in length, breadth, and thickness, up to an advanced period of life: this increase is more marked in men than in women.

**Component Parts.**—The heart is subdivided by a longitudinal muscular septum into two lateral halves, which are named respectively, from their position, right and left; and a transverse constriction subdivides each half of the organ into two cavities, the upper cavity on each side being called the *auricle*, the lower the *ventricle*. The right is the venous side of the heart, receiving into its auricle the dark venous blood from the entire body, by the superior and inferior vena cava, and coronary sinus. From the right auricle the blood passes into the right ventricle, and from the right ventricle, through the pulmonary artery, into the lungs. The blood, arterialised by its passage through the lungs, is returned to the left side of the heart by the pulmonary veins, which open into the left auricle; from the left auricle the blood passes into the left ventricle, and from the left ventricle is distributed, by the aorta and its subdivisions, through the entire body. This constitutes the circulation of the blood in the adult.

The division of the heart into four cavities is indicated by grooves upon its surface. The great transverse groove separating the auricles from the ventricles is called the *auriculo-ventricular groove*. It is deficient, in front, from being crossed by the root of the pulmonary artery. It contains the trunks of the nutrient vessels of the heart. The auricular portion occupies the base of the heart, and is subdivided into two cavities by a median septum. The two ventricles are also separated into a right and left, by two longitudinal furrows, the *interventricular grooves*, which are situated one on the anterior, the other on the posterior surface; these extend from the base of the ventricular portion to the apex of the organ; the former being situated nearer to the left border of the heart, and the latter to the right. It follows, therefore, that the right ventricle forms the greater portion of the anterior surface of the heart, and the left ventricle more of its posterior surface.

Each of these cavities should now be separately examined.

To examine the interior of the right auricle, an incision should be made along its right border, from the entrance of the superior vena cava to that of the inferior. A second cut is to be made from the centre of this first incision to the tip of the auricular appendix, and the flaps raised.

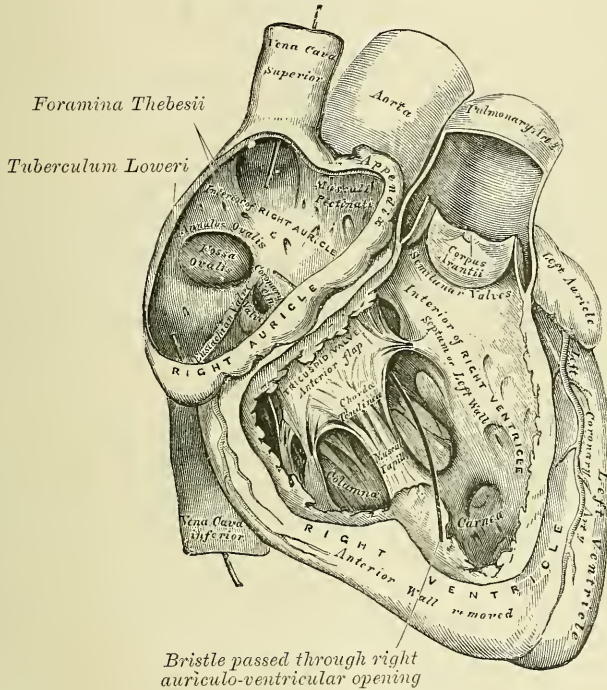
The **Right Auricle** is a little larger than the left, its walls somewhat thinner, measuring about one line; and its cavity is capable of containing about two ounces. It consists of two parts: a principal cavity, or *sinus venosus*, and an *appendix auriculæ*.

The *sinus* is the large quadrangular cavity, placed between the two venæ cavæ; its walls are extremely thin; it is connected below with the right ventricle, and internally with the left auricle, being free in the rest of its extent.

The *appendix auriculæ*, so called from its fancied resemblance to a dog's ear, is a small conical muscular pouch, the margins of which present a dentated edge. It projects from the sinus forwards and to the left side, overlapping the root of the aorta.

The internal surface of the right auricle is smooth, except in the appendix and adjacent part of the anterior wall of the sinus venosus, where it is thrown into parallel ridges.

FIG. 631.—The right auricle and ventricle laid open, the anterior walls of both being removed.



It presents the following parts for examination :

Openings	{	Superior cava.	Valves	{	Eustachian.
		Inferior cava.			Coronary.
		Coronary sinus.			
		Foramina Thebesii.			
		Auriculo-ventricular.			
		Relics of foetal structure	{	Annulus ovalis.	
			{	Fossa ovalis.	
		Musculi pectinati.			
		Tuberculum Loweri.			

The *superior vena cava* returns the blood from the upper half of the body, and opens into the upper and back part of the auricle, the direction of its orifice being downwards and forwards.

The *inferior vena cava*, larger than the superior, returns the blood from the lower half of the body, and opens into the lowest part of the auricle, near the septum, the direction of its orifice being upwards and inwards. The direction of a current of blood through the superior vena cava would consequently be towards the auriculo-ventricular orifice; whilst the direction of the blood through the

inferior cava would be towards the auricular septum. This is the normal direction of the two currents in foetal life.

The *tuberculum Loweri* is a small projection on the right wall of the auricle, between the two venæ cavæ. It is most distinct in the hearts of quadrupeds; in man it is scarcely visible. It was supposed by Lower to direct the blood from the superior cava towards the auriculo-ventricular opening.

The *coronary sinus* opens into the auricle, between the inferior vena cava and the auriculo-ventricular opening. It returns the blood from the substance of the heart, and is protected by a semicircular fold of the lining membrane of the auricle, the *coronary valve*. The sinus, before entering the auricle, is considerably dilated—nearly to the size of the end of the little finger. Its wall is partly muscular, and, at its junction with the great coronary vein, is somewhat constricted, and furnished with a valve, consisting of two unequal segments.

The *foramina Thebesii* are numerous minute apertures, the mouths of small veins (*venæ cordis minimæ*), which open on various parts of the inner surface of the auricle. They return the blood directly from the muscular substance of the heart. Some of these foramina are minute depressions in the walls of the heart, presenting a closed extremity.

The *auriculo-ventricular opening* is the large oval aperture of communication between the auricle and the ventricle, to be presently described.

The *Eustachian valve* is situated between the anterior margin of the inferior vena cava and the auriculo-ventricular orifice. It is semilunar in form, its convex margin being attached to the wall of the vein; its concave margin, which is free, terminating in two cornua, of which the left is attached to the anterior edge of the annulus ovalis; the right being lost on the wall of the auricle. The valve is formed by a duplicature of the lining membrane of the auricle, containing a few muscular fibres.

*In the fœtus* this valve is of large size, and serves to direct the blood from the inferior vena cava, through the foramen ovale, into the left auricle.

*In the adult* it is occasionally persistent, and may assist in preventing the reflux of blood into the inferior vena cava; more commonly it is small, and its free margin presents a cribriform or filamentous appearance; occasionally it is altogether wanting.

The *coronary valve* (valve of Thebesius) is a semicircular fold of the lining membrane of the auricle, protecting the orifice of the coronary sinus. It prevents the regurgitation of blood into the sinus during the contraction of the auricle. This valve is occasionally double.

The *fossa ovalis* is an oval depression, corresponding to the situation of the foramen ovale in the fœtus. It is situated at the lower part of the septum auricularum, above and to the left of the orifice of the inferior vena cava.

The *annulus ovalis* is the prominent oval margin of the foramen ovale. It is most distinct above, and at the sides; below, it is deficient. A small slit-like valvular opening is occasionally found, at the upper margin of the fossa ovalis, which leads upwards, beneath the annulus, into the left auricle, and is the remains of the aperture between the two auricles in the fœtus.

The *musculi pectinati* are small, prominent, muscular columns, which run across the inner surface of the appendix auriculæ and adjoining portion of the wall of the sinus. They have received the name *pectinati* from the fancied resemblance they bear to the teeth of a comb.

The **Right Ventricle** is triangular in form, and extends from the right auricle to near the apex of the heart. Its anterior or upper surface is rounded and convex, and forms the larger part of the front of the heart. Its under surface is flattened, rests upon the Diaphragm, and forms only a small part of the back of the heart. Its posterior wall is formed by the partition between the two ventricles, the *septum ventriculorum*, the surface of which is convex, and bulges into the cavity of the right ventricle. Its upper and inner angle is prolonged into a conical pouch, the *infundibulum*, or *conus arteriosus*, from which the pulmonary



artery rises. The walls of the right ventricle are thinner than those of the left, the proportion between them being as 1 to 3. The wall is thickest at the base, and gradually becomes thinner towards the apex. The cavity, which equals that of the left ventricle, is capable of containing about three fluid ounces.\*

To examine the interior of the right ventricle, an incision should be made a little to the right of the anterior interventricular groove from the pulmonary artery to the apex of the heart, and should be carried up from thence a little to the right of the posterior interventricular groove, as far as the auriculo-ventricular opening.

The following parts present themselves for examination :

Openings	{	Auriculo-ventricular.
	{	Opening of the pulmonary artery.
Valves	{	Tricuspid.
	{	Semilunar.

And a muscular and tendinous apparatus connected with the tricuspid valve :

Columnæ carneæ.

Chordæ tendineæ.

The *auriculo-ventricular orifice* is the large oval aperture of communication between the auricle and ventricle. It is situated at the base of the ventricle, near the right border of the heart. The opening is about an inch in diameter,† oval from side to side, surrounded by a fibrous ring, covered by the lining membrane of the heart, and rather larger than the corresponding aperture on the left side, being sufficiently large to admit the ends of four fingers. It is guarded by the tricuspid valve.

The *opening of the pulmonary artery* is circular in form, and situated at the summit of the conus arteriosus, close to the septum ventriculorum. It is placed on the left side of the auriculo-ventricular opening, upon the anterior aspect of the heart. Its orifice is guarded by the pulmonary semilunar valves.

The *tricuspid valve* consists of three segments of a triangular or trapezoidal shape, formed by a duplicature of the lining membrane of the heart, strengthened by a layer of fibrous tissue, and containing, according to Kürschner and Senac, muscular fibres. These segments are connected by their bases to the auriculo-ventricular orifice, and by their sides with one another, so as to form a continuous annular membrane, which is attached round the margin of the auriculo-ventricular opening, their free margins and ventricular surfaces affording attachment to a number of delicate tendinous cords, the *chordæ tendineæ*. The largest and most movable segment is placed towards the left side of the auriculo-ventricular opening, interposed between that opening and the pulmonary artery. Another segment corresponds to the front of the ventricle; and a third to its posterior wall. The central part of each segment is thick and strong; the lateral margins are thin and indented. The *chordæ tendineæ* are connected with the adjacent margins of the principal segments of the valve, and are further attached to each segment in the following manner: 1. Three or four reach the attached margin of each segment, where they are continuous with the auriculo-ventricular tendinous ring. 2. Others, four to six in number, are attached to the

\* Marrant Baker says that, 'taking the mean of various estimates, it may be inferred that each ventricle is able to contain four to six ounces of blood.'—Kirke's *Physiology*, 10th edition, p. 156.

† In the *Pathological Transactions*, vol. vi. p. 119, Dr. Peacock has given some careful researches upon the weight and dimensions of the heart in health and disease. He states, as the result of his investigations, that, in the healthy adult heart, the right auriculo-ventricular aperture has a mean circumference of 54.4 lines, or  $4\frac{3}{4}$  inches; the left auriculo-ventricular aperture a mean circumference of 44.3 lines, or  $3\frac{3}{4}$  inches; the pulmonic orifice of 40 lines, or  $3\frac{3}{4}$  inches; and the aortic orifice of 35.5 lines, or  $3\frac{1}{4}$  inches; but the dimensions of the orifices varied greatly in different cases, the auriculo-ventricular aperture having a range of from 45 to 60 lines, and the others in the same proportion.

central thickened part of each segment. 3. The most numerous and finest are connected with the marginal portion of each segment.

The *columnæ carneæ* are the rounded muscular columns which project from nearly the whole of the inner surface of the ventricle, excepting near the opening of the pulmonary artery, where the wall becomes smooth. They may be classified, according to their mode of connection with the ventricle, into three sets. The first set merely form prominent ridges on the inner surface of the ventricle, being attached by their entire length on one side, as well as by their extremities. The second set are attached by their two extremities, but are free in the rest of their extent; whilst the third set (*musculi papillares*), three or four in number, are attached by one extremity to the wall of the heart, the opposite extremity giving attachment to the *chordæ tendineæ*.

The *semilunar valves*, three in number,\* guard the orifice of the pulmonary artery. They consist of three semicircular folds, two anterior (right and left) and one posterior, formed by a duplicature of the lining membrane, strengthened by fibrous tissue. They are attached, by their convex margins, to the wall of the artery, at its junction with the ventricle, the straight border being free, and directed upwards in the course of the vessel, against the sides of which the valve-flaps are pressed during the passage of the blood along the artery. The free margin of each is somewhat thicker than the rest of the valve, is strengthened by a bundle of tendinous fibres, and presents, at its middle, a small projecting thickened nodule, called *corpus Arantii*.† From this nodule tendinous fibres radiate through the valve to its attached margin, and these fibres form a constituent part of its substance throughout its whole extent, excepting two narrow lunated portions, the *lunulæ*, placed on each side of the nodule immediately behind the free margin; here the valve is thin, and formed merely by the lining membrane. During the passage of the blood along the pulmonary artery these valves are pressed against the sides of the cylinder, and the course of the blood along the tube is uninterrupted; but during the ventricular diastole, when the current of blood along the pulmonary artery is checked, and partly thrown back by its elastic walls, these valves become immediately expanded, and effectually close the entrance of the tube. When the valves are closed, the lunated portions of each are brought into contact with one another by their opposed surfaces, the three corpora Arantii filling up the small triangular space that would be otherwise left by the approximation of the three semilunar valves.

Between the semilunar valves and the commencement of the pulmonary artery are three pouches or dilatations, one behind each valve. These are the pulmonary sinuses (*sinuses of Valsalva*). Similar sinuses exist between the semilunar valves and the commencement of the aorta; they are larger than the pulmonary sinuses. The blood, in its regurgitation towards the heart, finds its way into these sinuses, and so shuts down the valve-flaps.

In order to examine the interior of the left auricle, make an incision on the posterior surface of the auricle from the pulmonary veins on one side to those on the other, the incision being carried a little way into the vessels. Make another incision from the middle of the horizontal one to the appendix.

The **Left Auricle** is rather smaller than the right; its walls thicker, measuring

\* The pulmonary semilunar valves have been found to be two in number instead of three (Dr. Hand, of St. Paul, Minn., in the *North-Western Med. and Surg. Journ.*, July 1873), and the same variety is more frequently noticed in the aortic semilunar valves.

† In former editions, as well as in other text-books on anatomy, these little nodules have been described as fibro-cartilaginous in structure. At my request, Dr. Le Cronier Lancaster, Demonstrator of Anatomy at St. George's Hospital, has investigated this subject, and reports that the 'corpora Arantii' appear to consist of bundles of interlacing connective-tissue fibres with branched connective-tissue cells, and some few elastic fibres. Occasionally a rounded cell, with indistinct capsule, resembling a cartilage cell, was seen; but there were not many of them. At the free edge of the corpus the structure is denser, there being a larger proportion of fibres to cells than in the central portion. He thinks the structure of the corpus should be put down as fibrous and not fibro-cartilaginous.

about one line and a half; it consists, like the right, of two parts, a principal cavity, or *sinus*, and an *appendix auriculæ*.

The *sinus* is cuboidal in form, and concealed, in front, by the pulmonary artery and aorta; internally, it is separated from the right auricle by the septum auricularum; behind, it receives on each side the pulmonary veins, being free in the rest of its extent.

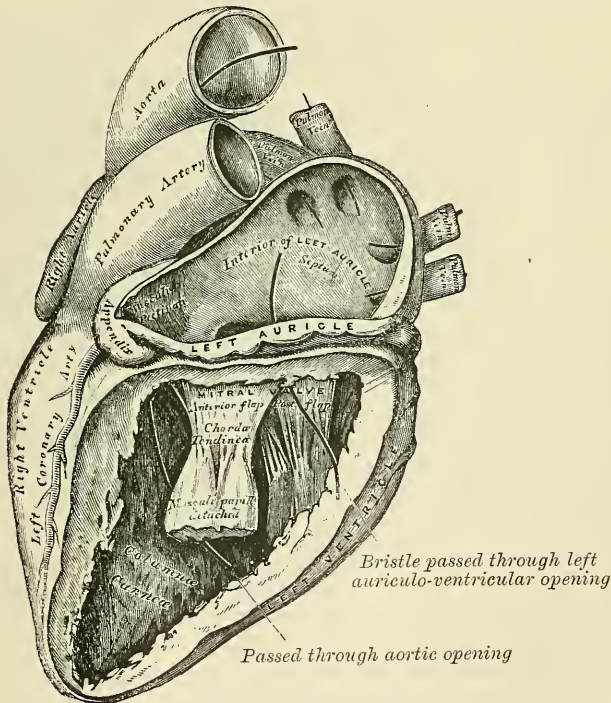
The *appendix auriculæ* is somewhat constricted at its junction with the auricle; it is longer, narrower, and more curved than that of the right side, and its margins more deeply indented, presenting a kind of foliated appearance. Its direction is forwards and towards the right side, overlapping the root of the pulmonary artery.

The following parts present themselves for examination:

- The openings of the four pulmonary veins.
- Auriculo-ventricular opening.
- Musculi pectinati.

The *pulmonary veins*, four in number, open, two into the right, and two into the left side of the auricle. The two left veins frequently terminate by a common opening. They are not provided with valves.

FIG. 632.—The left auricle and ventricle laid open, the posterior walls of both being removed.



The *auriculo-ventricular opening* is the large oval aperture of communication between the auricle and ventricle. It is rather smaller than the corresponding opening on the opposite side (see note, page 1021).

The *musculi pectinati* are fewer in number and smaller than on the right side; they are confined to the inner surface of the appendix.

On the inner surface of the septum auricularum may be seen a lunated impression, bounded below by a crescentic ridge, the concavity of which is turned upwards. The depression is just above the fossa ovalis in the right auricle.



To examine the interior of the left ventricle, make an incision a little to the left of the anterior interventricular groove from the base to the apex of the heart, and carry it up from thence a little to the left of the posterior interventricular groove, nearly as far as the auriculo-ventricular groove.

The **Left Ventricle** is longer and more conical in shape than the right ventricle. It forms a small part of the left side of the anterior surface of the heart, and a considerable part of its posterior surface. It also forms the apex of the heart by its projection beyond the right ventricle. Its walls are much thicker than those of the right side, the proportion being as 3 to 1. They are also thickest in the broadest part of the ventricle, becoming gradually thinner towards the base, and also towards the apex, which is the thinnest part.

The following parts present themselves for examination :

Openings	{	Auriculo-ventricular.	Valves	{	Mitral.
		Aortic.			Semilunar.
		Chordæ tendineæ.			Columnæ carneæ.

The *auriculo-ventricular opening* is placed below and to the left of the aortic orifice. It is a little smaller than the corresponding aperture of the opposite side ; and, like it, is broader in the transverse than in the antero-posterior diameter. It is surrounded by a dense fibrous ring, covered by the lining membrane of the heart, and guarded by the mitral valve.

The *aortic opening* is a circular aperture, in front and to the right side of the auriculo-ventricular, from which it is separated by one of the segments of the mitral valve. Its orifice is guarded by the semilunar valves.

The *mitral valve* is attached to the circumference of the auriculo-ventricular orifice in the same way that the tricuspid valve is on the opposite side. It is formed by a duplicature of the lining membrane, strengthened by fibrous tissue, and contains a few muscular fibres. It is larger in size, thicker, and altogether stronger than the tricuspid, and consists of two segments of unequal size. The larger segment is placed in front, between the auriculo-ventricular and aortic orifices, and is said to prevent the filling of the aorta during the distension of the ventricle. Two smaller segments are usually found at the angles of junction of the larger. The mitral valve-flaps are furnished with chordæ tendineæ, the mode of attachment of which is precisely similar to that of those on the right side ; but they are thicker, stronger, and less numerous.

The *semilunar valves* surround the orifice of the aorta ; two are posterior (right and left) and one anterior : they are similar in structure, and in their mode of attachment, to those of the pulmonary artery. They are, however, larger, thicker, and stronger than those of the right side ; the lunulæ are more distinct, and the corpora Arantii larger and more prominent. Between each valve and the cylinder of the aorta is a deep depression, the *sinus aortici* (sinuses of Valsalva) ; they are larger than those of the root of the pulmonary artery.

The *columnæ carneæ* admit of a subdivision into three sets, like those upon the right side ; but they are smaller, more numerous, and present a dense interlacement, especially at the apex, and upon the posterior wall. Those attached by one extremity only, the *musculi papillares*, are two in number, being connected one to the anterior, the other to the posterior wall ; they are of large size, and terminate by free rounded extremities, from which the chordæ tendineæ arise.

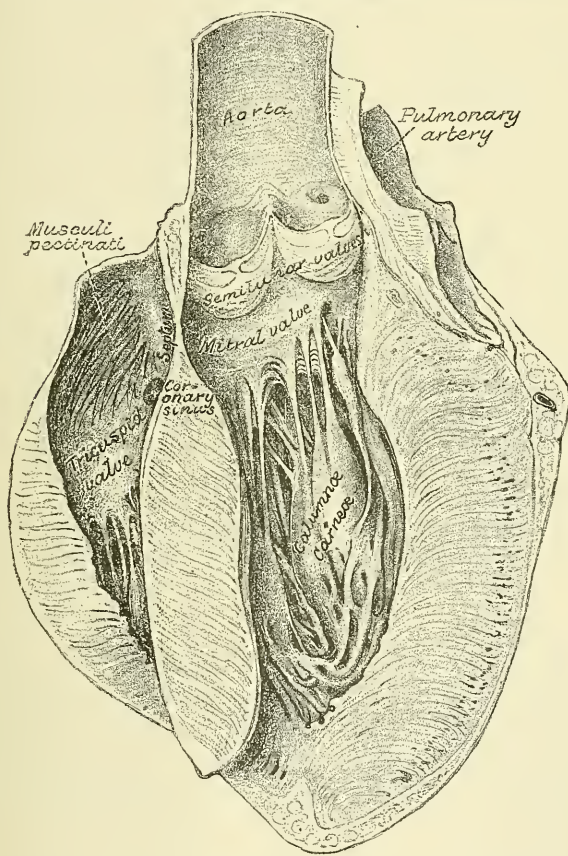
The septum between the two ventricles is thick, especially below (fig. 633). At its upper part it suddenly tapers off and becomes destitute of muscular fibres, consisting only of fibrous tissue, covered by two layers of endocardium ; and on the right side also covered by one of the flaps of the tricuspid valve. It is continued upwards and forms the septum between the aortic vestibule and the right auricle. It is derived from the lower part of the aortic septum of the fœtus, and an abnormal communication may exist at this part owing to defective development of this septum.

The *Endocardium* is a thin membrane which lines the internal surface of the heart; it assists in forming the valves by its reduplications, and is continuous with the lining membrane of the great blood-vessels. It is a smooth, transparent membrane, giving to the inner surface of the heart its glistening appearance. It is more opaque on the left than on the right side of the heart, thicker in the auricles than in the ventricles, and thickest in the left auricle. It is thin on the *musculi pectinati*, and on the *columnæ carneæ*; but thicker on the smooth part of the auricular and ventricular walls, and on the tips of the *musculi papillares*.

**Structure.**—The heart consists of muscular fibres, and of fibrous rings which serve for their attachment.

The *fibrous rings* surround the auriculo-ventricular and arterial orifices: they are stronger upon the left than on the right side of the heart. The auriculo-

FIG. 633.—Section of the heart, showing the interauricular and interventricular septa.



ventricular rings serve for the attachment of the muscular fibres of the auricles and ventricles, and also for the mitral and tricuspid valves; the ring on the left side is closely connected, by its right margin, with the aortic arterial ring. Between these and the right auriculo-ventricular ring is a mass of fibrous tissue; and in some of the larger animals, as the ox and elephant, a nodule of bone.

The fibrous rings surrounding the arterial orifices serve for the attachment of the great vessels and semilunar valves. Each ring receives, by its ventricular margin, the attachment of the muscular fibres of the ventricles; its opposite margin presents three deep semicircular notches, within which the middle coat of the artery (which presents three convex semicircular segments) is firmly fixed; the attachment of the artery to its fibrous ring being strengthened by the



thin cellular coat and serous membrane externally, and by the endocardium within. It is opposite the margins of these semicircular notches, in the arterial rings, that the endocardium, by its reduplication, forms the semilunar valves, the fibrous structure of the ring being continued into each of the segments of the valve at this part. The middle coat of the artery in this situation is thin, and the sides of the vessel are dilated to form the sinuses of Valsalva.

The *muscular structure of the heart* consists of bands of fibres, which present an exceedingly intricate interlacement. They are of a deep red colour, and marked with transverse striæ (page 40).

The muscular fibres of the heart admit of a subdivision into two kinds, those of the auricles and those of the ventricles, which are quite independent of one another.

*Fibres of the Auricles.*—These are disposed in two layers—a superficial layer common to both cavities, and a deep layer proper to each. The *superficial fibres* are more distinct on the anterior surface of the auricles, across the bases of which they run in a transverse direction, forming a thin but incomplete layer. Some of these fibres pass into the septum auricularum. The *internal or deep fibres* proper to each auricle consist of two sets, looped and annular fibres. The *looped fibres* pass upwards over each auricle, being attached by their two extremities to the corresponding auriculo-ventricular rings, in front and behind. The *annular fibres* surround the whole extent of the appendices auricularum, and are continued upon the walls of the venæ cavæ and coronary sinus on the right side, and upon the pulmonary veins on the left side, at their connection with the heart. In the appendices they interlace with the longitudinal fibres.

*Fibres of the Ventricles.*—These are arranged in an exceedingly complex manner, and the accounts given by various anatomists differ considerably. This is probably due, partly, to the fact that the various layers of muscular fibre of which the heart is said to be composed are not independent, but their fibres are interlaced to a considerable extent, and therefore any separation into layers must be to a great extent artificial, and also no doubt partly due to the fact, pointed out by Henle, that there are varieties in the arrangement due to individual differences. If the epicardium (visceral layer of pericardium) and the subjacent fat is removed from a heart which has been subjected to prolonged boiling, so as to dissolve the connective tissues, the superficial fibres of the ventricles will be exposed. They will be seen to commence at the base of the heart, where they are attached to the tendinous rings around the orifices, and to pass obliquely downwards towards the apex, with a direction from right to left. At the apex the fibres turn suddenly inwards, into the interior of the ventricle, forming what is called the *vortex*. On the back of the heart it will be seen that the fibres pass continuously from one ventricle to the other over the interventricular groove; and the same thing will be noticed on the front of the heart at the upper and lower end of the anterior interventricular groove, but in the middle portion of this groove the fibres passing from one ventricle to the other are interrupted by fibres emerging from the septum along the groove; many of the superficial fibres pass in also at this groove to the septum. The vortex is produced, as stated above, by the sudden turning inwards of the superficial fibres in a peculiar spiral manner into the interior of the ventricle. Those fibres which descend on the posterior surface of the heart, enter the left ventricle at the vortex, and, ascending, form the posterior part of the inner layer of muscular fibres lining this cavity and the right (posterior) musculus papillaris; those fibres which descend on the front of the heart, to reach the apex, also pass, at the vortex, into the interior of the ventricle, where they form the remainder of the innermost layer of the ventricle and the left (anterior) musculus papillaris. The fibres forming the inner layer of the wall of the ventricle ascend to be attached to the fibrous rings around the orifices.

By dissection these superficial fibres may be removed as a thin stratum, and it will then be found that the ventricles are made up of oblique fibres, super-



imposed in layers one on the top of another, and assuming gradually a less oblique direction as they pass to the middle of the thickness of the ventricular wall, so that in the centre of the wall the fibres are transverse. Internal to this central transverse layer the fibres become oblique again, but in the opposite direction to the external ones. This division into distinct layers is, however, to a great extent artificial, as the fibres pass across from one layer to another, and have therefore to be divided in the dissection, and the change in the direction of the fibres is very gradual. These oblique fibres commence above at the fibrous rings at the base of the heart, and descending towards the apex they enter the septum near its lower end. In the septum the fibres which form the left ventricle may be traced in three directions. 1. Some pass upwards to be attached to the central mass of fibrous tissue. 2. Others pass through the septum to become continuous with the fibres of the right ventricle. 3. And the remainder pass through the septum to encircle the ventricle as annular fibres. Of the fibres of the right ventricle, some on entering the septum pass upwards to be attached to the central mass of fibrous tissue; some entering the septum from behind pass forwards to become continuous with the fibres on the anterior surface of the left ventricle; and others entering in front pass backwards to join the fibres on the posterior wall of the left ventricle. The septum therefore consists of three varieties of fibres: viz. annular fibres special to the left ventricle; ascending fibres, derived from both ventricles and ascending through the septum to the central fibro-cartilage; and decussating fibres derived from the anterior wall of one ventricle and passing to the posterior wall of the other ventricle, or from the posterior wall of the right ventricle and passing to the anterior wall of the left. In addition to these fibres, there are a considerable number which appear to encircle both ventricles and which pass across the septum without turning into it.

**Vessels and Nerves.**—The *arteries* supplying the heart are the left or anterior and right or posterior coronary (page 549).

The *veins* accompany the arteries, and terminate in the right auricle. They are, the anterior, posterior, left and right cardiac veins, the right or small, and the left or great, coronary sinuses and the *venæ cordis minimæ* (*venæ Thêbesii*) (page 695).

The *lymphatics* terminate in the thoracic and right lymphatic ducts.

The *nerves* are derived from the cardiac plexuses, which are formed partly from the cranial nerves, and partly from the sympathetic. They are freely distributed both on the surface and in the substance of the heart, the separate filaments being furnished with small ganglia.

**Surface Form.**—In order to show the extent of the heart in relation to the front of the chest, draw a line from the lower border of the second left costal cartilage, one inch from the sternum, to the upper border of the third right costal cartilage, half an inch from the sternum. This represents the base line, or upper limit of the organ. Take a point an inch and a half below, and three-quarters of an inch internal to the left nipple, that is, about three and a half inches to the left of the median line of the body. This represents the apex of the heart. Draw a line from this apex point, with a slight convexity downwards, to the junction of the seventh right costal cartilage to the sternum. This represents the lower limit of the heart. Join the right extremity of the first line—that is, the base line—with the right extremity of this line—that is, to the seventh right chondro-sternal joint—with a slight curve outwards, so that it projects about an inch and a half from the middle line of the sternum. Lastly, join the left extremity of the base line and the apex point by a line curved slightly to the left.

The position of the various orifices is as follows: viz. the pulmonary orifice is situated in the upper angle formed by the articulation of the third left costal cartilage with the sternum; the aortic orifice is a little below and internal to this, behind the left border of the sternum, close to the articulation of the third left costal cartilage to this bone. The left auriculo-ventricular opening is behind the sternum, rather to the left of the median line and opposite the fourth costal cartilages. The right auriculo-ventricular opening is a little lower, opposite the fourth interspace and in the middle line of the body (fig. 630).

A portion of the area of the heart thus mapped out is uncovered by lung, and therefore gives a dull note on percussion; the remainder, being overlapped by the lung, gives a more or less resonant note. The former is known as the area of superficial cardiac

dulness; the latter, as the area of deep cardiac dulness. The area of superficial cardiac dulness is included between a line drawn from the centre of the sternum, on a level with the fourth costal cartilages, to the apex of the heart, and a line drawn from the same point down the lower third of the middle line of the sternum. Below, this area merges into the dulness which corresponds to the liver. Dr. Latham lays down the following rule as a sufficient practical guide for the definition of the portion of the heart which is uncovered by lung or pleura: 'Make a circle of two inches in diameter round a point midway between the nipple and the end of the sternum.'

#### PECULIARITIES IN THE VASCULAR SYSTEM OF THE FŒTUS

The chief peculiarities in the heart of the fœtus are the direct communication between the two auricles through the foramen ovale, and the large size of the Eustachian valve. There are also several minor peculiarities. Thus, the position of the heart is vertical until the fourth month, when it commences to assume an oblique direction. Its size is also very considerable as compared with the body, the proportion at the second month being 1 to 50; at birth it is as 1 to 120; whilst in the adult the average is about 1 to 160. At an early period of fœtal life the auricular portion of the heart is larger than the ventricular, the right auricle being more capacious than the left; but towards birth the ventricular portion becomes the larger. The thickness of both ventricles is, at first, about equal, but towards birth the left becomes much the thicker of the two.

The *foramen ovale* is situated at the lower and back part of the septum auricularum, forming a communication between the auricles. It remains as a free oval opening, from the time of the formation of the auricular septum (about the eighth week) until the middle period of fœtal life. About this period a fold grows up from the posterior wall of the auricle, to the left of the foramen ovale, and advances over the opening, so as to form a sort of valve, which allows the blood to pass only from the right to the left auricle, and not in the opposite direction.

The *Eustachian valve* is developed from the anterior border of the inferior vena cava at its entrance into the auricle. It is directed upwards on the left side of the opening of this vein, and serves to direct the blood from the inferior vena cava through the foramen ovale into the left auricle.

The peculiarities in the arterial system of the fœtus are the communication between the pulmonary artery and the descending aorta by means of the *ductus arteriosus*, and the communication between the internal iliac arteries and the placenta by means of the umbilical arteries.

The *ductus arteriosus* is a short tube, about half an inch in length at birth, and of the diameter of a goose-quill. In the early condition it forms the continuation of the pulmonary artery, and opens into the descending aorta, just below the origin of the left subclavian artery; and so conducts the chief part of the blood from the right ventricle into this vessel. When the branches of the pulmonary artery have become larger relatively to the ductus arteriosus, the latter is chiefly connected to the left pulmonary artery; and the fibrous cord, which is all that remains of the ductus arteriosus in later life, will be found to be attached to the root of that vessel.

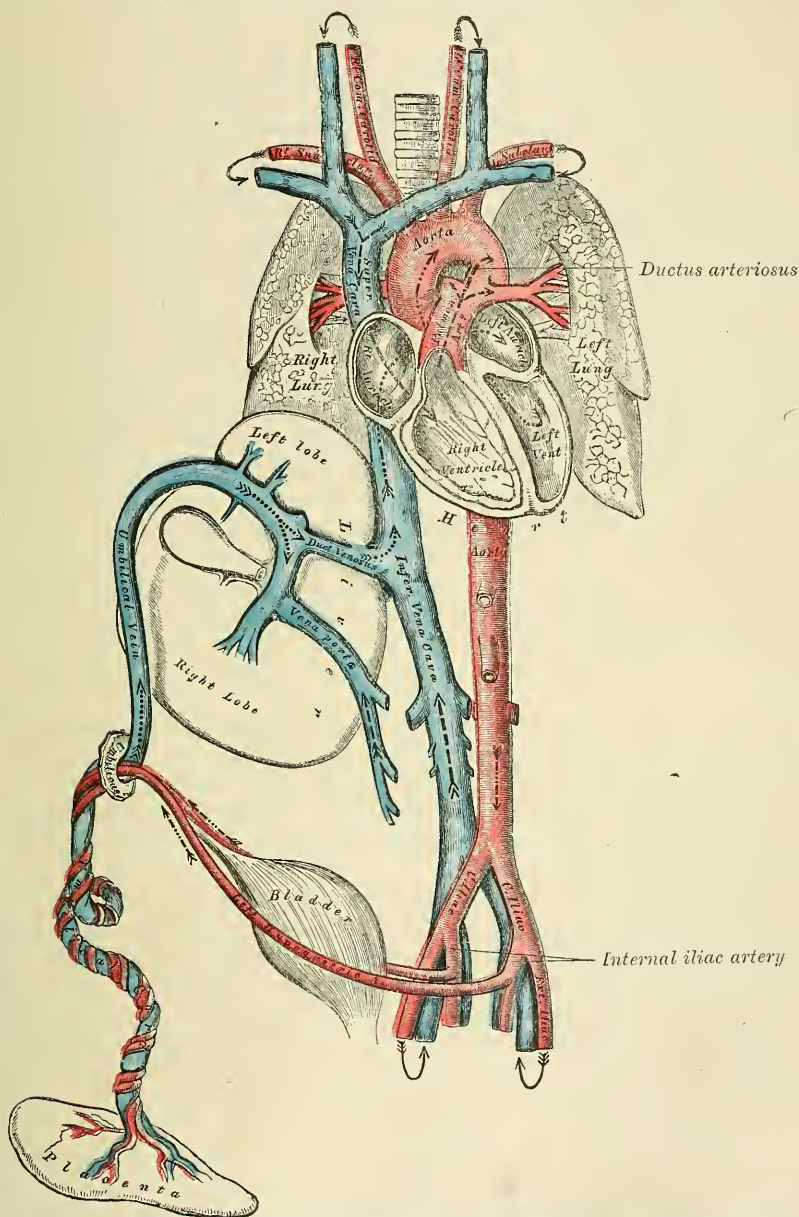
The *umbilical or hypogastric arteries* arise from the internal iliacs, in addition to the branches given off from those vessels in the adult. Ascending along the sides of the bladder to its fundus, they pass out of the abdomen at the umbilicus and are continued along the umbilical cord to the placenta, coiling round the umbilical vein. They return to the placenta the blood which has circulated in the system of the fœtus.

The peculiarity in the venous system of the fœtus is the communication established between the placenta and the liver and portal vein, through the umbilical vein; and the inferior vena cava through the ductus venosus.

FŒTAL CIRCULATION

The blood destined for the nutrition of the fœtus is carried from the placenta to the fœtus, along the umbilical cord, by the umbilical vein. The umbilical vein enters the abdomen at the umbilicus, and passes upwards along the free margin

FIG. 634.—Plan of the fetal circulation.



In this plan the figured arrows represent the kind of blood, as well as the direction which it takes in the vessels. Thus—arterial blood is figured  $\gg\text{---}\text{---}\text{---}\gg$ ; venous blood,  $\gg\text{---}\text{---}\text{---}\gg$ ; mixed (arterial and venous) blood,  $\gg\text{---}\text{---}\text{---}\gg$

of the suspensory ligament of the liver to the under surface of that organ, where it gives off two or three branches to the left lobe, one of which is of large size; and others to the lobus quadratus and lobulus Spigelii. At the transverse fissure it divides into two branches: of these, the larger is joined by the portal vein, and



enters the right lobe ; the smaller branch continues onwards, under the name of the ductus venosus, and joins the left hepatic vein at the point of junction of that vessel with the inferior vena cava. The blood, therefore, which traverses the umbilical vein, reaches the inferior vena cava in three different ways. The greater quantity circulates through the liver with the portal venous blood, before entering the vena cava by the hepatic veins ; some enters the liver directly, and is also returned to the inferior cava by the hepatic veins : the smaller quantity passes directly into the vena cava, by the junction of the ductus venosus with the left hepatic vein.

In the inferior cava, the blood carried by the ductus venosus and hepatic veins becomes mixed with that returning from the lower extremities and viscera of the abdomen. It enters the right auricle, and, guided by the Eustachian valve, passes through the foramen ovale into the left auricle, where it becomes mixed with a small quantity of blood returned from the lungs by the pulmonary veins. From the left auricle it passes into the left ventricle ; and from the left ventricle into the aorta, by means of which it is distributed almost entirely to the head and upper extremities, a small quantity being probably carried into the descending aorta. From the head and upper extremities the blood is returned by the branches of the superior vena cava to the right auricle, where it becomes mixed with a small portion of the blood from the inferior cava. From the right auricle it descends over the Eustachian valve into the right ventricle ; and from the right ventricle, passes into the pulmonary artery. The lungs of the fœtus being solid, and almost impervious, only a small quantity of the blood of the pulmonary artery is distributed to them, by the right and left pulmonary arteries, and is returned by the pulmonary veins to the left auricle : the greater part passes through the ductus arteriosus into the commencement of the descending aorta, where it becomes mixed with a small quantity of blood transmitted by the left ventricle into the aorta. Along this vessel it descends to supply the lower extremities and viscera of the abdomen and pelvis, the chief portion being, however, conveyed by the umbilical arteries to the placenta.

From the preceding account of the circulation of the blood in the fœtus, it will be seen—

1. That the placenta serves the double purpose of a respiratory and nutritive organ, receiving the venous blood from the fœtus, and returning it again re-oxygenated, and charged with additional nutritive material.

2. That nearly the whole of the blood of the umbilical vein traverses the liver before entering the inferior cava ; hence the large size of this organ, especially at an early period of fœtal life.

3. That the right auricle is the point of meeting of a double current, the blood in the inferior cava being guided by the Eustachian valve into the left auricle, whilst that in the superior cava descends into the right ventricle. At an early period of fœtal life it is highly probable that the two streams are quite distinct ; for the inferior cava opens almost directly into the left auricle, and the Eustachian valve would exclude the current along the vein from entering the right ventricle. At a later period, as the separation between the two auricles becomes more distinct, it seems probable that some mixture of the two streams must take place.

4. The blood carried from the placenta to the fœtus by the umbilical vein, mixed with the blood from the inferior cava, passes almost directly to the arch of the aorta, and is distributed by the branches of that vessel to the head and upper extremities : hence the large size and perfect development of those parts at birth.

5. The blood contained in the descending aorta, chiefly derived from that which has already circulated through the head and limbs, together with a small quantity from the left ventricle, is distributed to the lower extremities : hence the small size and imperfect development of these parts at birth.

## CHANGES IN THE VASCULAR SYSTEM AT BIRTH

At birth, when respiration is established, an increased amount of blood from the pulmonary artery passes through the lungs, which now perform their office as respiratory organs, and, at the same time, the placental circulation is cut off. The foramen ovale becomes gradually closed by about the tenth day after birth: the valvular fold above mentioned becomes adherent to the margins of the foramen for the greater part of its circumference, but above a slit-like opening is left between the two auricles which sometimes remains persistent.

The *ductus arteriosus* begins to contract immediately after respiration is established, becomes completely closed from the fourth to the tenth day, and ultimately degenerates into an impervious cord, which serves to connect the left pulmonary artery to the descending aorta.

Of the *umbilical* or *hypogastric arteries*, the portion continued on to the bladder from the trunk of the corresponding internal iliac remains pervious, as the superior vesical artery; and the part between the fundus of the bladder and the umbilicus becomes obliterated between the second and fifth days after birth, and projects into the peritoneal sac, so as to form two of the fossæ of the peritoneum, spoken of in the section on the surgical anatomy of direct inguinal hernia.

The *umbilical vein* and *ductus venosus* become completely obliterated between the second and fifth days after birth, and ultimately dwindle to fibrous cords; the former becoming the round ligament of the liver, the latter the fibrous cord which, in the adult, may be traced along the fissure of the ductus venosus.

# ORGANS OF VOICE AND RESPIRATION

## THE LARYNX

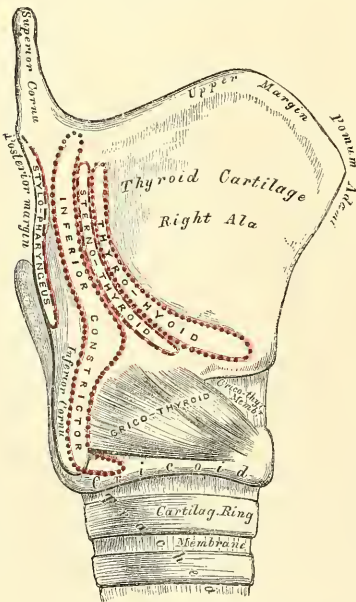
**T**HE Larynx is the organ of voice, placed at the upper part of the air-passage. It is situated between the trachea and base of the tongue, at the upper and fore part of the neck, where it forms a considerable projection in the middle line. On either side of it lie the great vessels of the neck; behind, it forms part of the boundary of the pharynx, and is covered by the mucous membrane lining that cavity.

The larynx is broad above, where it presents the form of a triangular box, flattened behind and at the sides, and bounded in front by a prominent vertical ridge. Below, it is narrow and cylindrical. It is composed of cartilages, which are connected together by ligaments and moved by numerous muscles. It is lined by mucous membrane, which is continuous above with that lining the pharynx and below with that of the trachea.

The **Cartilages of the Larynx** are nine in number, three single, and three pairs:

Thyroid.	Two Arytenoid.
Cricoid.	Two Cornicula Laryngis.
Epiglottis.	Two Cuneiform.

FIG. 635.—Side view of the thyroid and cricoid cartilages.



The **Thyroid** (*θυρεός, a shield*) is the largest cartilage of the larynx. It consists of two lateral lamellæ or alæ, united at an acute angle in front, forming a vertical projection in the middle line which is prominent above, and called the *pomum Adami*. This projection is subcutaneous, more distinct in the male than in the female, and occasionally separated from the integument by a bursa mucosa.

Each lamella is quadrilateral in form. Its *outer surface* presents an oblique ridge, which passes downwards and forwards from a tubercle, situated near the root of the superior cornu, to the anterior part of the lower border. This ridge gives attachment to the Sternothyroid and Thyro-hyoid muscles, and the portion of cartilage included between it and the posterior border to part of the Inferior constrictor muscle.

The *inner surface* of each ala is smooth, slightly concave, and covered by mucous membrane above and behind;

but in front, in the receding angle formed by their junction, are attached the epiglottis, the true and false vocal cords, the Thyro-arytenoid and Thyro-epiglotidean muscles.



The *upper border of the thyroid cartilage* is sinuously curved, being concave at its posterior part, just in front of the superior cornu, then rising into a convex outline, which dips in front to form the sides of a notch, the *thyroid notch*, in the middle line, immediately above the pomum Adami. This border gives attachment throughout its whole extent to the thyro-hyoid membrane.

The *lower border* is nearly straight in front, but behind, close to the cornu, is concave. It is connected to the cricoid cartilage, in the median line, by the crico-thyroid membrane; and, on each side, by the Crico-thyroid muscle.

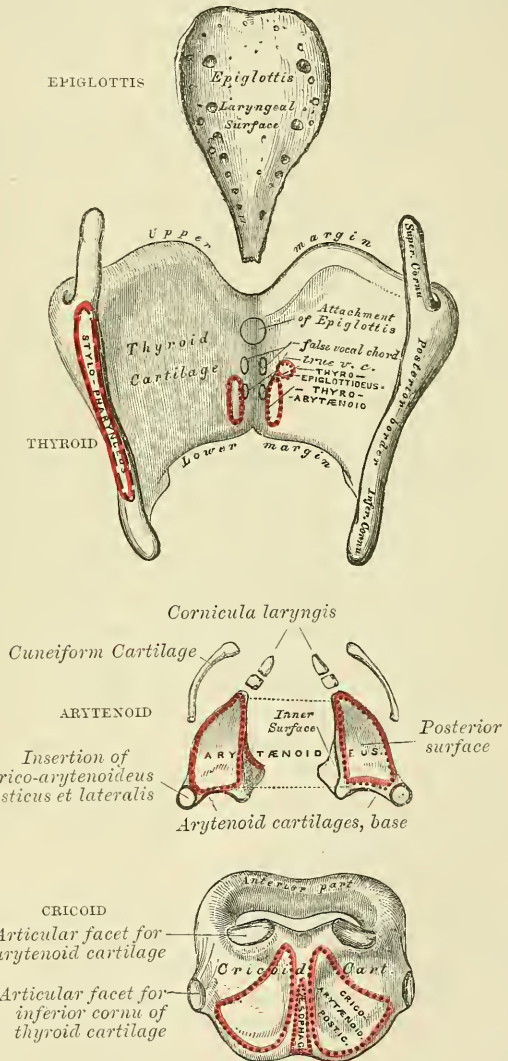
The *posterior borders*, thick and rounded, terminate, above, in the *superior cornua*; and, below, in the *inferior cornua*. The two superior cornua are long and narrow, directed upwards, backwards, and inwards; and terminate in a conical extremity, which gives attachment to the thyro-hyoid ligament. The two inferior cornua are short and thick; they pass downwards, with a slight inclination forwards and inwards, and present, on their inner surfaces, a small oval articular facet for articulation with the side of the cricoid cartilage. The posterior border receives the insertion of the Stylo-pharyngeus and Palato-pharyngeus muscles on each side.

The **Cricoid Cartilage** is so called from its resemblance to a signet ring (*κρίκος, a ring*). It is smaller, but thicker and stronger than the thyroid cartilage, and forms the lower and back part of the cavity of the larynx. It consists of two parts: a quadrate portion, situated behind, and a narrow ring or arch, one-fourth or one-fifth the depth of the posterior part, situated in front. The posterior square portion rapidly narrows at the sides of the cartilage, at the expense of the upper border, into the anterior portion.

Its *posterior portion* is very broad, both from side to side, and from above downwards; it presents, on its posterior surface, in the middle line a vertical ridge for the attachment of the longitudinal fibres of the œsophagus; and on either side a broad depression for the Crico-arytenoideus posticus muscle.

Its *anterior portion* is narrow and convex, affording attachment externally in front and at the sides to the Crico-thyroid muscles, and, behind, to part of the Inferior constrictor.

FIG. 636.—The cartilages of the larynx. Posterior view.



At the point of junction of the posterior quadrangle portion with the rest of the cartilage is a small round elevation, for articulation with the inferior cornu of the thyroid cartilage.

The *lower border of the cricoid cartilage* is horizontal, and connected to the upper ring of the trachea by fibrous membrane.

Its *upper border* is directed obliquely upwards and backwards, owing to the great depth of its posterior surface. It gives attachment, in front, to the cricothyroid membrane; at the sides, to part of the same membrane and to the lateral Crico-arytenoid muscle; behind, the highest point of the upper border is surmounted on each side by a smooth oval surface, for articulation with the arytenoid cartilage. Between the articular surfaces is a slight notch, for the attachment of part of the Arytenoideus muscle.

The *inner surface of the cricoid cartilage* is smooth, and lined by mucous membrane.

The **Arytenoid Cartilages** are so called from the resemblance they bear, when approximated, to the mouth of a pitcher (*ἀπίρανα, a pitcher*). They are two in number, and situated at the upper border of the cricoid cartilage, at the back of the larynx. Each cartilage is pyramidal in form, and presents for examination three surfaces, a base, and an apex.

The *posterior surface* is triangular, smooth, concave, and gives attachment to the Arytenoid muscle.

The *anterior or external surface* is somewhat convex and rough. It presents rather below its centre a transverse ridge, to the inner extremity of which is attached the false vocal cord, and to the outer part, as well as the surfaces above and below, is attached the Thyro-arytenoid muscle.

The *internal surface* is narrow, smooth, and flattened, covered by mucous membrane, and lies almost in apposition with the cartilage of the opposite side.

The *base* of each cartilage is broad, and presents a concave smooth surface, for articulation with the cricoid cartilage. Of its three angles, the *external* is short, rounded, and prominent; it projects backwards and outwards, and is termed the *muscular process*, from receiving the insertion of the Posterior and Lateral crico-arytenoid muscles. The *anterior angle*, also prominent, but more pointed, projects horizontally forwards, and gives attachment to the true vocal cord. This angle is called the *vocal process*.

The *apex* of each cartilage is pointed, curved backwards and inwards, and surmounted by a small conical-shaped, cartilaginous nodule, the *corniculum laryngis*.

The **cornicula laryngis** (*cartilages of Santorini*) are two small conical nodules, consisting of yellow fibro-cartilage, which articulate with the summit of the arytenoid cartilages and serve to prolong them backwards and inwards. To them are attached the aryteno-epiglottidean folds. They are sometimes united to the arytenoid cartilages.

The **cuneiform cartilages** (*cartilages of Wrisberg*) are two small, elongated, cartilaginous bodies, placed one on each side, in the fold of mucous membrane which extends from the apex of the arytenoid cartilage to the side of the epiglottis (*aryteno-epiglottidean fold*); they give rise to small whitish elevations on the inner surface of the mucous membrane, just in front of the arytenoid cartilages.

The **epiglottis** is a thin lamella of fibro-cartilage, of a yellowish colour, shaped like a leaf, and placed behind the tongue in front of the superior opening of the larynx. During respiration its direction is vertically upwards, its free extremity curving forwards towards the base of the tongue; but when the larynx is drawn up beneath the base of the tongue during deglutition, it is carried downwards and backwards, so as to completely close the opening of the larynx. Its free extremity is broad and rounded; its attached end is long and narrow, and connected to the receding angle between the two *alæ* of the thyroid cartilage, just below the median notch, by a long, narrow, ligamentous band, the *thyro-epiglottic ligament*. It is also connected to the posterior surface of the body of the hyoid bone by an elastic ligamentous band, the *hyo-epiglottic ligament*.

Its *anterior* or *lingual surface* is curved forwards towards the tongue, and covered at its upper part by mucous membrane, which is reflected on to the sides and base of the organ, forming a median and two lateral folds, the *glosso-epiglottidean ligaments*.

Its *posterior* or *laryngeal surface* is smooth, concave from side to side, concavo-convex from above downwards, and covered by mucous membrane; when this is removed, the surface of the cartilage is seen to be studded with a number of small mucous glands, which are lodged in little pits upon its surface. To its sides the aryteno-epiglottidean folds are attached.

**Structure.**—The cornicula laryngis, cuneiform cartilages, and epiglottis are composed of yellow fibro-cartilage, which shows little tendency to calcification; but the other cartilages resemble in structure the costal cartilages, becoming more or less calcified in old age.

**Ligaments.**—The ligaments of the larynx are *extrinsic*, i.e. those connecting the thyroid cartilage and epiglottis with the hyoid bone, and the cricoid cartilage with the trachea; and *intrinsic*, those which connect the several cartilages of the larynx to each other.

The ligaments connecting the thyroid cartilage with the hyoid bone are three in number—the thyro-hyoid membrane, and the two lateral thyro-hyoid ligaments.

The *thyro-hyoid membrane* is a broad, fibro-elastic, membranous layer, attached below to the upper border of the thyroid cartilage, and above to the upper border of the posterior surface of the hyoid bone, thus passing behind the posterior surface, and being separated from it by a synovial bursa. It is thicker in the middle line than at either side, in which situation it is pierced by the superior laryngeal vessels and nerve.

The *two lateral thyro-hyoid ligaments* are rounded, elastic cords, which pass between the superior cornua of the thyroid cartilage and the extremities of the greater cornua of the hyoid bone. A small cartilaginous nodule (*cartilago triticea*), sometimes bony, is frequently found in each.

The ligament connecting the epiglottis with the hyoid bone is the *hyo-epiglottic*. In addition to this extrinsic ligament, the epiglottis is connected to the tongue by the three glosso-epiglottidean folds of mucous membrane, which may also be considered as extrinsic ligaments of the epiglottis.

The *hyo-epiglottic ligament* is an elastic fibrous band, which extends from the anterior surface of the epiglottis, near its apex, to the upper border of the body of the hyoid bone.

The ligaments connecting the thyroid cartilage to the cricoid are also three in number—the crico-thyroid membrane, and the capsular ligaments.

The *crico-thyroid membrane* is composed mainly of yellow elastic tissue. It consists of three parts, a central, triangular portion and two lateral portions. The central part is thick and strong, narrow above and broadening out below. It connects together the contiguous margins of the thyroid and cricoid cartilages. It is convex, concealed on each side by the crico-thyroid muscle, but subcutaneous in the middle line; it is crossed horizontally by a small anastomotic arterial arch, formed by the junction of the two crico-thyroid arteries. The lateral portions are thinner and lie close under the mucous membrane of the larynx. They extend from the superior border of the cricoid cartilage to the inferior margin of the true vocal cords, with which it is closely united in front.

The lateral portions are lined internally by mucous membrane, and covered by the lateral Crico-arytenoid and Thyro-arytenoid muscles.

A *capsular ligament* encloses the articulation of the inferior cornu of the thyroid with the cricoid cartilage on each side. The articulation is lined by synovial membrane.

The ligaments connecting the arytenoid cartilages to the cricoid are two



*capsular ligaments*, and two *posterior crico-arytenoid ligaments*. The *capsular crico-arytenoid ligaments* are thin and loose capsules attached to the margin of the articular surfaces; they are lined internally by synovial membrane. The *posterior crico-arytenoid ligaments* extend from the cricoid to the inner and back part of the base of the arytenoid cartilage.

The ligament connecting the epiglottis with the thyroid cartilage is the *thyro-epiglottic*.

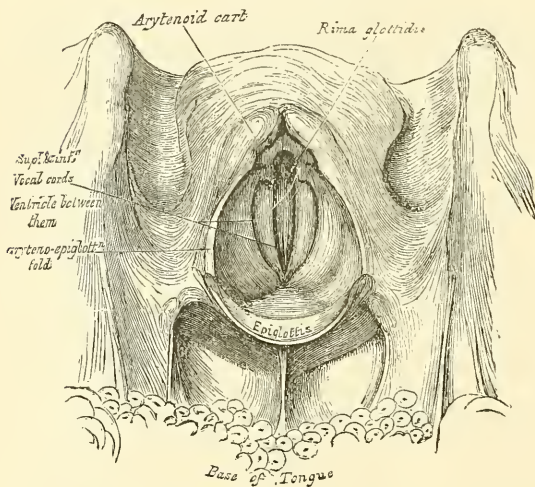
The *thyro-epiglottic ligament* is a long, slender, elastic cord which connects the apex of the epiglottis with the receding angle of the thyroid cartilage, immediately beneath the median notch, above the attachment of the vocal cords.

The *crico-tracheal ligament* connects the cricoid cartilage with the first ring of the trachea. It resembles the fibrous membrane which connects the cartilaginous rings of the trachea to each other.

**Interior of the Larynx.**—The *cavity of the larynx* extends from the superior aperture to the lower border of the cricoid cartilage. It is divided into two parts by the projection inwards of the vocal cords; between the two cords is a long and narrow triangular fissure or chink, the *rima glottidis*. The portion of the cavity

of the larynx above the true vocal cords, sometimes called the *vestibule*, is broad and triangular in shape, and corresponds to the interval between the alæ of the thyroid cartilage; it contains the false vocal cords, and between these and the true vocal cords are the ventricles of the larynx. The portion below the true vocal cords is at first of an elliptical, and lower down of a circular form.

FIG. 637.—The larynx and adjacent parts, seen from above.



of the larynx above the true vocal cords, sometimes called the *vestibule*, is broad and triangular in shape, and corresponds to the interval between the alæ of the thyroid cartilage; it contains the false vocal cords, and between these and the true vocal cords are the ventricles of the larynx. The portion below the true vocal cords is at first of an elliptical, and lower down of a circular form.

It is bounded, in front, by the epiglottis; behind, by the apices of the arytenoid cartilages, and the cornicula laryngis; and laterally, by a fold of mucous membrane, enclosing ligamentous and muscular fibres, stretched between the sides of the epiglottis and the apex of the arytenoid cartilages: these are the *aryteno-epiglottidean folds*, on the margins of which the cuneiform cartilages form more or less distinct whitish prominences.

The *rima glottidis* is the narrow fissure or chink between the inferior or true vocal cords. It is the narrowest part of the cavity of the larynx, and corresponds to the lower level of the arytenoid cartilages. Its length, in the male, measures rather less than an inch; its breadth, when dilated, varying at its widest part from a third to half an inch. In the female these measurements are less by two or three lines. The form of the rima glottidis varies. In its half-closed condition it is a narrow fissure, a little enlarged and rounded behind. In quiet breathing it is widely open, somewhat triangular, the base of the triangle directed backwards, and corresponding to the space between the separated arytenoid cartilages. In forcible expiration it is smaller than during inspiration. When sound is produced it is more narrowed, the margins of the arytenoid cartilages being brought into contact, and the edges of the vocal cords approximated and

made parallel, the degree of approximation and tension corresponding to the height of the note produced.\*

The *superior or false vocal cords*, so called because they are not directly concerned in the production of the voice, are two folds of mucous membrane, enclosing a delicate narrow fibrous band, the *superior thyro-arytenoid ligament*. This ligament consists of a thin band of connective tissue, attached in front to the angle of the thyroid cartilage below the epiglottis, and behind to the anterior surface of the arytenoid cartilage. The lower border of this ligament, enclosed in mucous membrane, forms a free crescentic margin, which constitutes the upper boundary of the ventricle of the larynx.

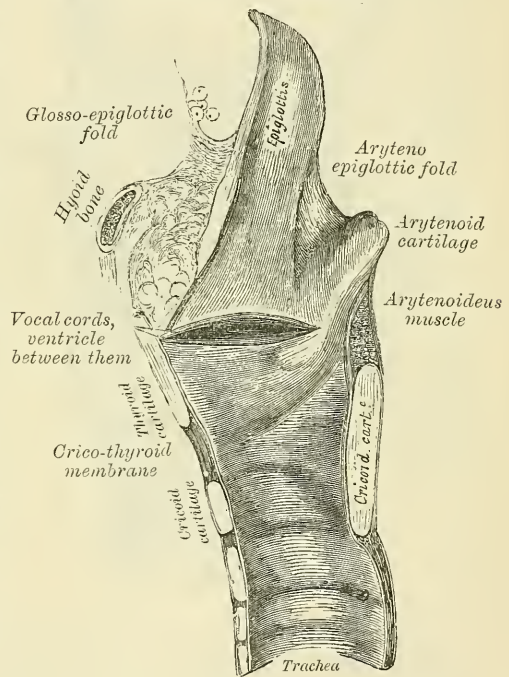
The *inferior or true vocal cords*, so called from their being concerned in the production of sound, are two strong fibrous bands (*inferior thyro-arytenoid ligaments*), covered on their surface by a thin layer of mucous membrane. Each ligament consists of a band of yellow elastic tissue, attached in front to the depression between the two alæ of the thyroid cartilage, and behind to the anterior angle (vocal process) of the base of the arytenoid. Its lower border is continuous with the thin lateral part of the crico-thyroid membrane. Its upper border forms the lower boundary of the ventricle of the larynx. Externally, the Thyro-arytenoideus muscle lies parallel with it. It is covered internally by mucous membrane, which is extremely thin, and closely adherent to its surface.

The *ventricle of the larynx* is an oblong fossa, situated between the superior and inferior vocal cords on each side, and extending nearly their entire length. This fossa is bounded, above, by the free crescentic edge of the superior vocal cord; below, by the straight margin of the true vocal cord; externally, by the corresponding Thyro-arytenoideus muscle. The anterior part of the ventricle leads up by a narrow opening into a cæcal pouch of mucous membrane of variable size, called the *laryngeal pouch*.

The *sacculus laryngis*, or laryngeal pouch, is a membranous sac, placed between the superior vocal cord and the inner surface of the thyroid cartilage, occasionally extending as far as its upper border: it is conical in form, and curved slightly backwards. On the surface of its mucous membrane are the openings of sixty or seventy small follicular glands, which are lodged in the submucous areolar tissue. This sac is enclosed in a fibrous capsule, continuous below with the superior thyro-arytenoid ligament: its laryngeal surface is covered by the Aryteno-epiglottideus inferior muscle (*Compressor sacculi laryngis*, Hilton); whilst its exterior is covered by the Thyro-arytenoideus and Thyro-epiglottideus muscles. These muscles compress the sacculus laryngis, and discharge the secretion it contains upon the chordæ vocales, the surfaces of which it is intended to lubricate.

\* On the shape of the rima glottidis, in the various conditions of breathing and speaking, see Czermak, *On the Laryngoscope*, translated for the *New Sydenham Society*.

FIG. 638.—Vertical section of the larynx and upper part of the trachea.





**Muscles.**—The intrinsic muscles of the larynx are eight in number, five of which are the muscles of the vocal cords and rima glottidis, and three are connected with the epiglottis.

The five muscles of the vocal cords and rima glottidis are—the

Crico-thyroid.

Crico-arytenoideus posticus.

Crico-arytenoideus lateralis.

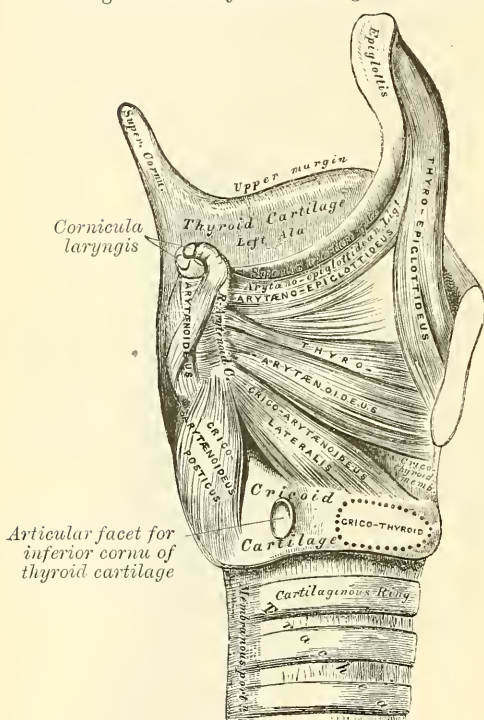
Arytenoideus.

Thyro-arytenoideus.

The *Crico-thyroid* is triangular in form, and situated at the fore part and side of the cricoid cartilage. It arises from the front and lateral part of the cricoid

cartilage; its fibres diverge, passing obliquely upwards and outwards, to be inserted into the lower border of the thyroid cartilage, and into the anterior border of the lower cornua.

FIG. 639.—Muscles of larynx. Side view.  
Right ala of thyroid cartilage removed.



The inner borders of these two muscles are separated in the middle line by a triangular interval, occupied by the crico-thyroid membrane.

The *Crico-arytenoideus posticus* arises from the broad depression occupying each lateral half of the posterior surface of the cricoid cartilage; its fibres pass upwards and outwards, converging to be inserted into the outer angle of the base of the arytenoid cartilage (the muscular process). The upper fibres are nearly horizontal, the middle oblique, and the lower almost vertical.\*

The *Crico-arytenoideus lateralis* is smaller than the preceding, and of an oblong form. It arises from the upper border of the side of the cricoid cartilage, and, passing obliquely upwards and backwards, is inserted into the muscular process of the arytenoid cartilage, in front of the preceding muscle.

The *Arytenoideus* is a single muscle, filling up the posterior concave surface of the arytenoid cartilages. It arises from the posterior surface and outer border of one arytenoid cartilage, and is inserted into the corresponding parts of the opposite cartilage. It consists of three planes of fibres, two oblique and one transverse. The *oblique fibres*, the most superficial, form two fasciculi, which pass from the base of one cartilage to the apex of the opposite one. The *transverse fibres*, the deepest and most numerous, pass transversely across between the two cartilages; hence the *Arytenoideus* was formerly considered as several muscles, under the name of *transversi* and *obliqui*. A few of the oblique fibres are occasionally continued round the outer margin of the cartilage, and blend with the *Thyro-arytenoid* or the *Aryteno-epiglottideus* muscle.

\* Dr. Merkel, of Leipsic, has described a muscular slip which occasionally extends between the outer border of the posterior surface of the cricoid cartilage and the posterior margin of the inferior cornu of the thyroid; this he calls the 'Musculus kerato-ericoideus.' It is not found in every larynx, and when present exists usually only on one side, but is occasionally found on both sides. Sir Wm. Turner (*Edinburgh Medical Journal*, Feb. 1860) states that it is found in about one case in five. Its action is to fix the lower horn of the thyroid cartilage backwards and downwards, opposing in some measure the part of the *Crico-thyroid* muscle which is connected to the anterior margin of the horn.



The *Thyro-arytenoideus* is a broad, flat muscle, which lies parallel with the outer side of the true vocal cord. It arises in front from the lower half of the receding angle of the thyroid cartilage, and from the crico-thyroid membrane. Its fibres pass horizontally backwards and outwards, to be inserted into the base and anterior surface of the arytenoid cartilage. This muscle consists of two fasciculi.\* The *inner* or *inferior portion*, the thicker, is inserted into the vocal process of the arytenoid cartilage, and into the adjacent portion of its anterior surface; it lies parallel with the true vocal cord, to which it is adherent. The *outer* or *superior fasciculus*, the thinner, is inserted into the anterior surface and outer border of the arytenoid cartilage above the preceding fibres; it lies on the outer side of the sacculus laryngis, immediately beneath the mucous membrane.†

The muscles of the epiglottis are, the

Thyro-epiglottideus.

Aryteno-epiglottideus superior.

Aryteno-epiglottideus inferior.

The *Thyro-epiglottideus* is a delicate fasciculus, which arises from the inner surface of the thyroid cartilage, just external to the origin of the Thyro-arytenoid muscle, of which it is sometimes described as a part, and spreads out upon the outer surface of the sacculus laryngis: some of its fibres are lost in the aryteno-epiglottidean fold, whilst others are continued forwards to the margin of the epiglottis (*Depressor epiglottidis*).

The *Aryteno-epiglottideus superior* consists of a few delicate muscular fasciculi, which arise from the apex of the arytenoid cartilages, and become lost in the fold of mucous membrane extending between the arytenoid cartilage and side of the epiglottis (*aryteno-epiglottidean folds*).

The *Aryteno-epiglottideus inferior* (*Compressor sacculi laryngis*, Hilton) arises from the arytenoid cartilage, just above the attachment of the superior vocal cord; passing forwards and upwards, it spreads out upon the anterior surface of the epiglottis. This muscle is separated from the preceding by an indistinct areolar interval.‡

**Actions.**—In considering the action of the muscles of the larynx, they may be conveniently divided into two groups, viz.: 1. Those which open and close the glottis. 2. Those which regulate the degree of tension of the vocal cords.

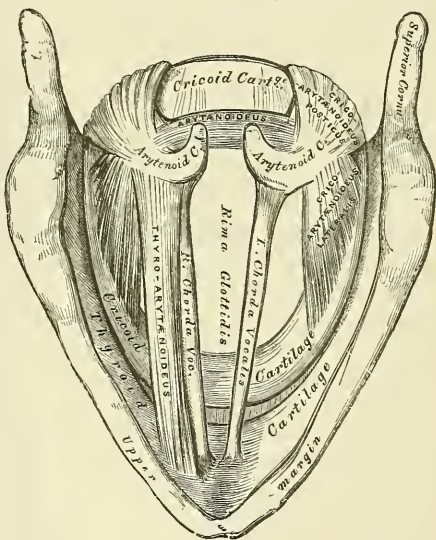
1. The muscles which open the glottis are the *Crico-arytenoidei postici*; and those which close it are the *Arytenoideus* and the *Crico-arytenoidei laterales*.

\* Henle describes these two portions as separate muscles, under the names of *External* and *Internal thyro-arytenoid*.

† Luschka has described a small, but fairly constant muscle, as the *Arytenoideus rectus*. It is attached below to the posterior, concave surface of the arytenoid cartilage, beneath the *Arytenoideus* muscle, and passing upwards, emerges at the upper border of this muscle, and is inserted into the posterior surface of the cartilage of Santorini. (*Anatomy*, by Hyrtl, page 718.)

‡ **MUSCULUS TRITICEO-GLOSSUS.** Bochdalek jun. (*Prager Vierteljahrsschrift*, 2nd part, 1866) describes a muscle hitherto entirely overlooked, except a brief statement in Henle's *Anatomy*, which arises from the nodule of cartilage (*corpus triticeum*) in the posterior thyro-hyoid ligament, and passes forwards and upwards to enter the tongue along with the *Hyo-glossus* muscle. He met with this muscle eight times in twenty-two subjects. It occurred in both sexes, sometimes on both sides, at others on one only.

FIG. 640.—Interior of the larynx, seen from above. (Enlarged.)



2. The muscles which regulate the tension of the vocal cords are the Crico-thyroidei, which tense and elongate them; and the Thyro-arytenoidei, which relax and shorten them. The Thyro-epiglottideus is a depressor of the epiglottis, and the Aryteno-epiglottidei constrict the superior aperture of the larynx, compress the sacculi laryngis, and empty them of their contents.

The *Crico-arytenoidei postici* separate the chordæ vocales, and, consequently, open the glottis, by rotating the arytenoid cartilages outwards around a vertical axis passing through the crico-arytenoid joints; so that their anterior angles and the ligaments attached to them become widely separated, the vocal cords, at the same time, being made tense.

The *Crico-arytenoidei laterales* close the glottis, by rotating the arytenoid cartilages inwards, so as to approximate their anterior angles.

The *Arytenoideus muscles* approximate the arytenoid cartilages, and thus close the opening of the glottis, especially at its back part.

The *Crico-thyroid muscles* produce tension and elongation of the vocal cords. This is effected as follows:—The thyroid cartilage is fixed by the Thyro-hyoid muscles, then the Crico-thyroid muscles, when they act, draw upwards the front of the cricoid cartilage and so depress the posterior portion, which carries with it the arytenoid cartilages, and thus elongate the vocal cords.

The *Thyro-arytenoidei muscles*, consisting of two parts having different attachments and different directions, are rather complicated as regards their action. Their main use is to draw the arytenoid cartilages forwards towards the thyroid, and thus shorten and relax the vocal cords. But, owing to the connection of the inner portion with the vocal cord, this part, if acting separately, is supposed to modify its elasticity and tension, and the outer portion, being inserted into the outer part of the anterior surface of the arytenoid cartilage, may rotate it inwards, and thus narrow the rima glottidis by bringing the two cords together.

The *Thyro-epiglottidei* depress the epiglottis, and assist in compressing the sacculi laryngis. The Aryteno-epiglottideus superior constricts the superior aperture of the larynx, when it is drawn upwards, during deglutition, and the opening closed by the epiglottis. The Aryteno-epiglottideus inferior, together with some fibres of the Thyro-arytenoidei, compress the sacculus laryngis.

The **Mucous Membrane of the Larynx** is continuous above with that lining the mouth and pharynx, and is prolonged through the trachea and bronchi into the lungs. It lines the posterior and upper part of the anterior surface of the epiglottis, to which it is closely adherent, and forms the aryteno-epiglottidean folds which encircle the superior aperture of the larynx. It lines the whole of the cavity of the larynx; forms, by its reduplication, the chief part of the superior, or false, vocal cord; and, from the ventricle, is continued into the sacculus laryngis. It is then reflected over the true vocal cords, where it is thin, and very intimately adherent; covers the inner surface of the crico-thyroid membrane and cricoid cartilage; and is ultimately continuous with the lining membrane of the trachea. It is covered with columnar ciliated epithelium below the superior vocal cord; but above this point the cilia are found only in front, as high as the middle of the epiglottis. In the rest of its extent the epithelium is of the squamous variety.

*Glands.*—The mucous membrane of the larynx is furnished with numerous muciparous glands, the orifices of which are found in nearly every part; they are very numerous upon the epiglottis, being lodged in little pits in its substance; they are also found in large numbers along the posterior margin of the aryteno-epiglottidean fold, in front of the arytenoid cartilages, where they are termed the *arytenoid glands*. They exist also in large numbers upon the inner surface of the sacculus laryngis. None are found on the vocal cords.

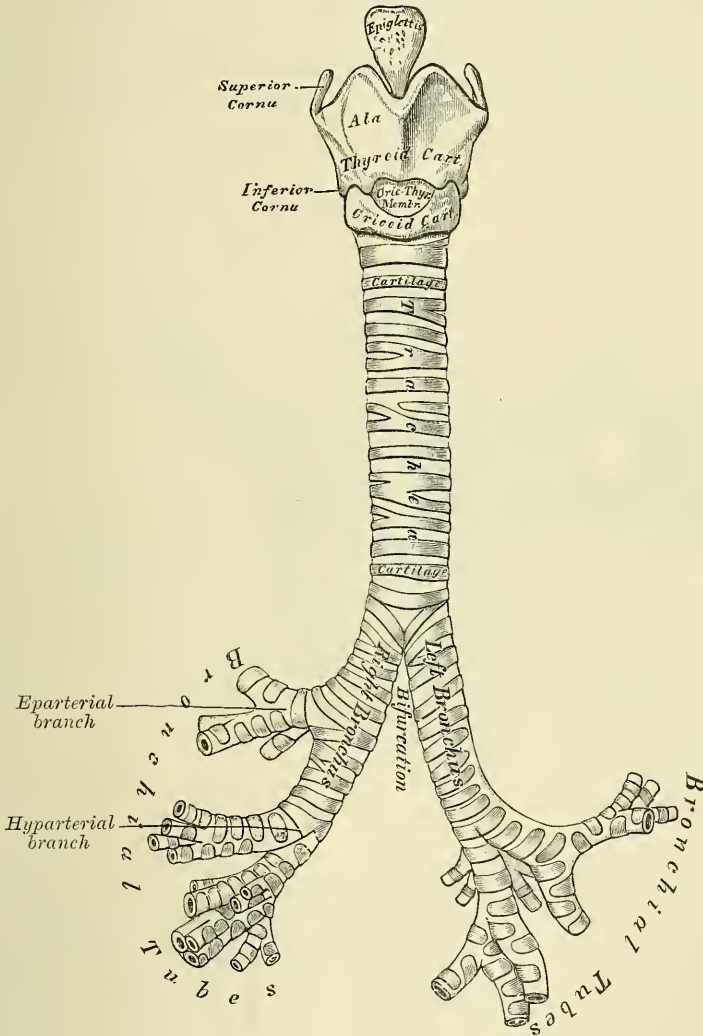
*Vessels and Nerves.*—The *arteries of the larynx* are the laryngeal branches derived from the superior and inferior thyroid. The *veins* accompany the arteries: those accompanying the superior laryngeal artery join the superior thyroid vein, which opens into the internal jugular vein; while those accompanying the inferior laryngeal artery join the inferior thyroid vein which opens into the innominate vein. The *lymphatics* terminate in the deep cervical glands. The *nerves* are the superior laryngeal, and the inferior or recurrent laryngeal branches of the pneumogastric nerves, joined by filaments from the sympathetic.

The superior laryngeal nerves supply the mucous membrane of the larynx and the Crico-thyroid muscles. The inferior laryngeal nerves supply the remaining muscles. The Arytenoid muscle is supplied by both nerves.

THE TRACHEA (fig. 641)

The **trachea**, or **windpipe**, is a cartilaginous and membranous cylindrical tube, flattened posteriorly, which extends from the lower part of the larynx, on a level with the sixth cervical vertebra, to opposite the fourth, or sometimes the fifth,

FIG. 641.—Front view of cartilages of larynx ; the trachea and bronchi.



dorsal, where it divides into the two bronchi, one for each lung. The trachea measures about four inches and a half in length ; its diameter, from side to side, is from three-quarters of an inch to an inch, being always greater in the male than in the female.

**Relations.**—The anterior surface of the trachea is convex, and covered in the neck, from above downwards, by the isthmus of the thyroid gland, the inferior thyroid veins, the arteria thyroidea ima (when that vessel exists), the Sterno-thyroid muscles, the cervical fascia, and, more superficially, by

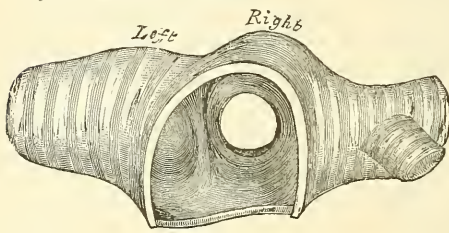


the anastomosing branches between the anterior jugular veins; *in the thorax* it is covered from before backwards by the first piece of the sternum, the remains of the thymus gland, the left innominate vein, the arch of the aorta, the innominate and left carotid arteries, and the deep cardiac plexus. Posteriorly it is in relation with the œsophagus; laterally, *in the neck*, it is in relation with the common carotid arteries, the lateral lobes of the thyroid gland, the inferior thyroid arteries, and recurrent laryngeal nerves; and, *in the thorax*, it lies in the space between the pleuræ, having the pneumogastric nerve on each side of it.

The **Right Bronchus**, wider, shorter, and more horizontal in direction than the left, is about an inch in length, and enters the right lung, opposite the fifth dorsal vertebra. The vena azygos major arches over it, from behind; and the right pulmonary artery lies below, and then in front of it. About three-quarters of an inch from its commencement it gives off a branch to the upper lobe of the right lung. This is termed the *eparterial* branch, because it is given off above the right pulmonary artery. The bronchus now passes below the artery and is known as the *hyarterial* branch. It divides into two branches for the middle and lower lobes.

The **Left Bronchus** is smaller, longer, and more oblique than the right, being nearly two inches in length. It enters the root of the left lung, opposite the sixth dorsal vertebra, about an inch lower than the right bronchus.

FIG. 642.—Transverse section of the trachea, just above its bifurcation, with a bird's-eye view of the interior.



It passes beneath the arch of the aorta, crosses in front of the œsophagus, the thoracic duct and the descending aorta, and has the left pulmonary artery lying at first above, and then in front of it. If a transverse section is made across the trachea, a short distance above its point of bifurcation, and a bird's-eye view taken of its interior (fig. 642), the septum placed at the bottom of the trachea and separating the two

bronchi will be seen to occupy the left of the median line, and the right bronchus appears to be a more direct continuation than the left, so that any solid body dropping into the trachea would naturally be directed towards the right bronchus. This tendency is aided by the larger size of the right tube as compared with its fellow. This fact serves to explain why a foreign body in the trachea more frequently falls into the right bronchus.\*

**Structure.**—The trachea is composed of imperfect cartilaginous rings, fibrous membrane, muscular fibres, longitudinal yellow elastic fibres, mucous membrane, and glands.

The **cartilages** vary from sixteen to twenty in number: each forms an imperfect ring, which surrounds about two-thirds of the cylinder of the trachea, being imperfect behind, where the tube is completed by fibrous membrane. The cartilages are placed horizontally above each other, separated by narrow membranous intervals. They measure about two lines in depth, and half a line in thickness. Their outer surfaces are flattened, but internally they are convex, from being thicker in the middle than at the margins. Two or more of the cartilages often unite, partially or completely, and are sometimes bifurcated at their extremities. They are highly elastic, but sometimes become calcified in advanced life. In the right bronchus the cartilages vary in number from six to eight; in the left, from nine to twelve. They are shorter and narrower than those of the trachea. The peculiar cartilages are the first and the last.

The *first cartilage* is broader than the rest, and sometimes divided at one end;

\* Reigel asserts that the entry of a foreign body into the *left* bronchus is by no means so infrequent as is generally supposed. See also *Med.-Chir. Trans.* vol. lxxi. p. 121.

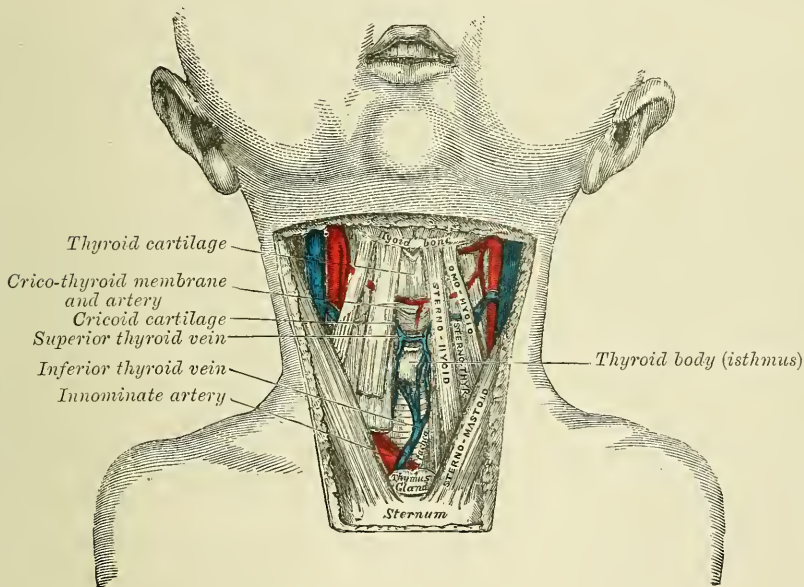
it is connected by fibrous membrane with the lower border of the cricoid cartilage, with which, or with the succeeding cartilage, it is sometimes blended.

The *last cartilage* is thick and broad in the middle, in consequence of its lower border being prolonged into a triangular hook-shaped process, which curves downwards and backwards between the two bronchi. It terminates on each side in an imperfect ring, which encloses the commencement of the bronchi. The cartilage above the last is somewhat broader than the rest at its centre.

**The fibrous membrane.**—The cartilages are enclosed in an elastic fibrous membrane, which forms a double layer; one layer, the thicker of the two, passing over the outer surface of the ring, the other over the inner surface: at the upper and lower margins of the cartilages these two layers blend together to form a single membrane which connects the rings one with another. They are thus, as it were, embedded in the membrane. In the space behind, between the extremities of the rings, the membrane forms a single distinct layer.

The **muscular fibres** are disposed in two layers, longitudinal and transverse. The *longitudinal fibres* are the most external, and consist merely of a few scattered longitudinal bundles of fibres.

FIG. 643.—Surgical anatomy of laryngo-tracheal region.  
In the infant.



The *transverse fibres* (Trachealis muscle, Todd and Bowman), the most internal, form a thin layer, which extends transversely between the ends of the cartilages and the intervals between them at the posterior part of the trachea. The muscular fibres are of the unstriped variety.

The **elastic fibres** are found throughout the trachea, but are most abundant at the posterior part of the tube between the extremities of the rings, where they are collected into distinct longitudinal bundles, and are especially numerous about the bifurcation of the trachea. The fibres are contained in a loose submucous tissue, which contains numerous mucous glands.

The **Mucous membrane** is continuous above with that of the larynx, and below with that of the bronchi. Microscopically, it presents a well-marked basement membrane, supporting a layer of columnar ciliated epithelium, between the deeper ends of which are smaller round or elongated cells. It contains a large amount of lymphoid tissue and some tracheal glands.

The **Tracheal glands** are found in great abundance at the posterior part of the



trachea. They are small, flattened, ovoid bodies, placed upon the outer surface of the fibrous layer; each is furnished with an excretory duct, which pierces the fibrous and muscular layers, and opens on the surface of the mucous membrane. Some glands of smaller size are also found at the sides of the trachea, between the layers of fibrous tissue connecting the rings, and others immediately beneath the mucous coat. The secretion from these glands serves to lubricate the inner surface of the trachea.

**Vessels and Nerves.**—The trachea is supplied with blood by the inferior thyroid arteries. The *veins* terminate in the thyroid venous plexus. The *nerves* are derived from the pneumogastric and its recurrent branches, and from the sympathetic.

**Surface Form.**—In the middle line of the neck, some of the cartilages of the larynx can be readily distinguished. In the receding angle below the chin, the hyoid bone can easily be made out (see page 210), and a finger's breadth below it is the pomum Adami, the prominence between the upper borders of the two alæ of the thyroid cartilage. About an inch below this, in the middle line, is a depression corresponding to the crico-thyroid space, in which the operation of laryngotomy is performed. This depression is bounded below by a prominent arch, the anterior ring of the cricoid cartilage, below which the trachea can be felt, though it is only in the emaciated adult that the separate rings can be distinguished. The lower part of the trachea is not easily made out, for as it descends in the neck it takes a deeper position, and is farther removed from the surface. The level of the vocal cords corresponds to the middle of the anterior margin of the thyroid cartilage.

With the laryngoscope the following structures can be seen: The base of the tongue, and the upper surface of the epiglottis, with the glosso-epiglottic ligaments; the superior aperture of the larynx; bounded on either side by the aryteno-epiglottidean ligaments, in which may be seen two rounded eminences, corresponding to the cornicula and cuneiform cartilages. Beneath these the true and false vocal cords, with the ventricle between them. Still deeper, the cricoid cartilage and some of the anterior parts of the rings of the trachea, and sometimes, in deep inspiration, the bifurcation of the trachea.

**Surgical Anatomy.**—*Foreign bodies* often find their way into the air-passages. These may be either large soft substances, as a piece of meat, which may become lodged in the upper aperture of the larynx, or in the rima glottidis, and cause speedy suffocation unless rapidly got rid of, or unless an opening is made into the air-passages below, so as to enable the patient to breathe. Smaller bodies, frequently of a hard nature, such as cherry or plum stones, small pieces of bone, buttons, etc., may find their way through the rima glottidis into the trachea or bronchus, or may become lodged in the ventricle of the larynx. The dangers then depend not so much upon the mechanical obstruction as upon the spasm of the glottis which they excite from reflex irritation. When lodged in the ventricle of the larynx, they may produce very few symptoms beyond sudden loss of voice or alteration in the voice sounds, immediately following the inhalation of the foreign body. When, however, they are situated in the trachea, they are constantly striking against the vocal cords during expiratory efforts, and produce attacks of dyspnoea from spasm of the glottis. When lodged in the bronchus, they usually become fixed there, and, occluding the lumen of the tube, cause a loss of the respiratory murmur on the affected side, which is, as stated above, more often the right.

Beneath the mucous membrane of the upper part of the air-passages, there is a considerable amount of submucous tissue, which is liable to become much swollen from effusion in inflammatory affections, constituting the disease known as 'œdema of the glottis.' This effusion does not extend below the level of the vocal cords, on account of the fact that the mucous membrane is closely adherent to these structures, without the intervention of any submucous tissue. So that, in cases of this disease, in which it is necessary to open the air-passages to prevent suffocation, the operation of laryngotomy is sufficient.

Chronic laryngitis is an inflammation of the mucous glands of the larynx, which occurs in those who speak much in public, and is known as 'Clergyman's sore throat.' It is due to the dryness induced by the large amount of cold air drawn into the air-passages during prolonged speaking, which excites increased activity of the mucous glands to keep the parts moist, and this eventually terminates in inflammation of these structures.

Ulceration of the larynx may occur from syphilis, either superficial ulceration, or from the softening of a gumma; from tuberculous disease (laryngeal phthisis), or from malignant disease (epithelioma).

The air-passages may be opened in two different situations: through the crico-thyroid membrane (*laryngotomy*), or in some part of the trachea (*tracheotomy*); and to these some surgeons have added a third method, by opening the crico-thyroid membrane and dividing the cricoid cartilage with the upper ring of the trachea (*laryngo-tracheotomy*). The student should carefully consider the relative anatomy of the air-tube in each of these situations (fig. 643).



*Laryngotomy* is anatomically the simple operation; it can readily be performed, and should always be preferred when particular circumstances do not render the operation of tracheotomy absolutely necessary. The crico-thyroid membrane is very superficial, being covered only in the middle line by the skin, superficial fascia, and the deep fascia. On each side of the middle line it is also covered by the Sterno-hyoid and Sterno-thyroid muscles, which diverge slightly from each other at their upper parts, leaving a slight interval between them. On these muscles rests the anterior jugular vein. The only vessel of any importance in connection with this operation is the crico-thyroid artery, which crosses the crico-thyroid membrane, and which may be wounded, but rarely gives rise to any trouble. The operation is performed thus: the head being thrown back and steadied by an assistant, the finger is passed over the front of the neck, and the crico-thyroid depression felt for. A vertical incision is then made through the skin, in the middle line over this spot, and carried down through the fascia until the crico-thyroid membrane is exposed. A cross cut is then made through the membrane, close to the upper border of the cricoid cartilage, so as to avoid, if possible, the crico-thyroid artery, and a tracheotomy tube introduced. It has been recommended, as a more rapid way of performing the operation, to make a transverse instead of a longitudinal cut through the superficial structures, and thus to open at once the air-passages. It will be seen, however, that in operating in this way the anterior jugular veins would be in danger of being wounded.

*Tracheotomy* may be performed either above or below the isthmus of the thyroid body: or this structure may be divided and the trachea opened beneath it.

The isthmus of the thyroid gland usually crosses the second and third rings of the trachea; along its upper border is frequently to be found a large transverse communicating branch between the superior thyroid veins; and the isthmus itself is covered by a venous plexus, formed between the thyroid veins of the opposite sides. Theoretically, therefore, it is advisable to avoid dividing this structure in opening the trachea.

Above the isthmus the trachea is comparatively superficial, being covered by the skin, superficial fascia, deep fascia, Sterno-hyoid and Sterno-thyroid muscles, and a second layer of the deep fascia, which, attached above to the lower border of the hyoid bone, descends beneath the muscles to the thyroid body, where it divides into two layers and encloses the isthmus.

Below the isthmus the trachea lies much more deeply, and is covered by the Sterno-hyoid and the Sterno-thyroid muscles, and a quantity of loose areolar tissue, in which is a plexus of veins, some of them of large size; they converge to two trunks, the inferior thyroid veins, which descend on either side of the median line on the front of the trachea, and open into the innominate vein. In the infant the thymus gland ascends a variable distance along the front of the trachea; and opposite the episternal notch the windpipe is crossed by the left innominate vein. Occasionally also in young subjects the innominate artery crosses the tube obliquely above the level of the sternum. The thyroidea ima artery, when that vessel exists, passes from below upwards, along the front of the trachea.

From these observations it must be evident that the trachea can be more readily opened above, than below, the isthmus of the thyroid body.

Tracheotomy above the isthmus is performed thus: the patient should, if possible, be laid on his back on a table in a good light. A pillow is to be placed under the shoulders and the head thrown back and steadied by an assistant. The surgeon standing on the right side of his patient makes an incision from an inch and a half to two inches in length in the median line of the neck from the top of the cricoid cartilage. The incision must be made exactly in the middle line so as to avoid the anterior jugular veins, and after the superficial structures have been divided, the interval between the Sterno-hyoid muscles must be found, the *raphé* divided, and the muscles drawn apart. The lower border of the cricoid cartilage must now be felt for, and the upper part of the trachea exposed from this point downwards in the middle line. Bosc has recommended that the layer of fascia in front of the trachea should be divided transversely at the level of the lower border of the cricoid cartilage, and, having been seized with a pair of forceps, pressed downwards with the handle of the scalpel. By this means the isthmus of the thyroid gland is depressed and is saved from all danger of being wounded, and the trachea cleanly exposed. The trachea is now transfixed with a sharp hook and drawn forwards in order to steady it, and is then opened by inserting the knife into it and dividing the two or three upper rings from below upwards. If the trachea is to be opened below the isthmus, the incision must be made from a little below the cricoid cartilage to the top of the sternum.

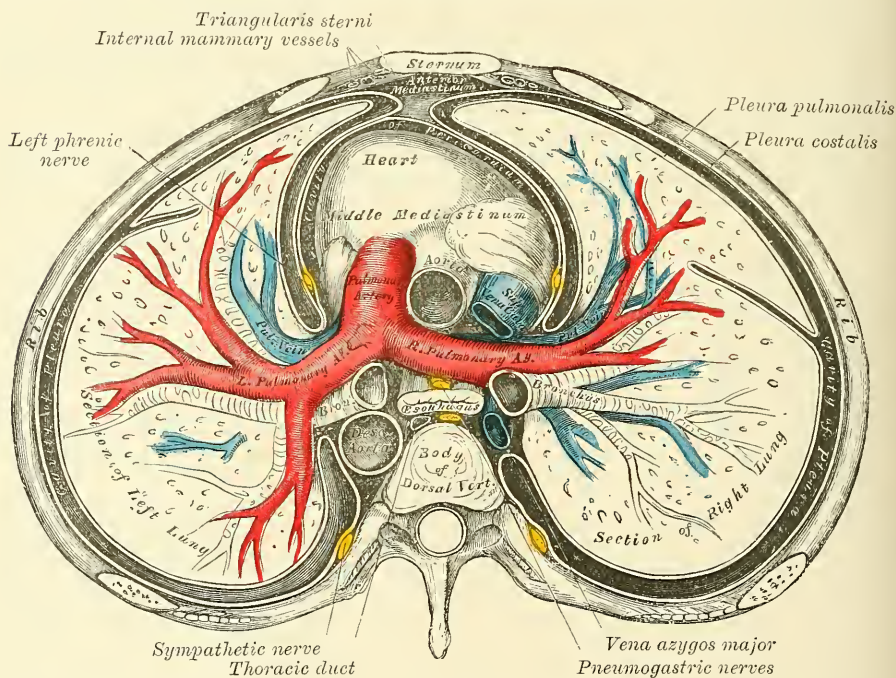
In the child the trachea is smaller, more deeply placed, and more movable than in the adult. In fat or short-necked people, or in those in whom the muscles of the neck are prominently developed, the trachea is more deeply placed than in the opposite conditions.

A portion of the larynx or the whole of it has been removed for malignant disease. The results which have been obtained from the removal of the whole of it have not been very satisfactory, and the cases in which the operation is justifiable are very few. It may be removed by a median incision through the soft parts; freeing the cartilages from the muscles and other structures in front; separating the larynx from the trachea below, and dissecting off the deeper structure from below upwards.

## THE PLEURÆ

Each lung is invested, upon its external surface, by an exceedingly delicate serous membrane, the **pleura**, which encloses the organ as far as its root, and is then reflected upon the inner surface of the thorax. The portion of the serous membrane investing the surface of the lung and dipping into the fissures between its lobes, is called the *pleura pulmonalis* (visceral layer of pleura), while that which lines the inner surface of the chest is called the *pleura costalis* (parietal layer of pleura). The space between these two layers is called the *cavity of the pleura*, but it must be borne in mind that in the healthy condition the two layers are in contact and there is no real cavity, until the lung becomes collapsed and a separation of it from the wall of the chest takes place. Each pleura is therefore a shut sac, one occupying the right, the other the left half of the thorax; and they are perfectly separate, not communicating with each other.

FIG. 644.—A transverse section of the thorax, showing the relative position of the viscera, and the reflections of the pleura.



The two pleuræ do not meet in the middle line of the chest, excepting anteriorly opposite the second piece of the sternum; a space being left between them, which contains all the viscera of the thorax excepting the lungs; this is the *mediastinum*.

**Reflections of the Pleura** (fig. 644).—Commencing at the sternum, the pleura passes outwards, covers the costal cartilages, the inner surface of the ribs and Intercostal muscles, and at the back part of the thorax passes over the thoracic ganglia and their branches, and is reflected upon the sides of the bodies of the vertebræ, where it is separated by a narrow interval, the *posterior mediastinum*, from the opposite pleura. From the vertebral column the pleura passes to the side of the pericardium, which it covers to a slight extent; it then covers the back part of the root of the lung, from the lower border of which a triangular fold descends vertically by the side of the posterior mediastinum to the Diaphragm. This fold is the broad ligament of the lung, the *ligamentum latum pulmonis*, and serves to retain the lower part of that organ in position. From the



*root*, the pleura may be traced over the convex surface of the lung, the summit and base, and also over the sides of the fissures between the lobes on to its anterior surface and the front part of its root; from this it is reflected upon the side of the pericardium to the inner surface of the sternum. *Below*, it covers the upper surface of the Diaphragm and extends, in front, as low as the costal cartilage of the seventh rib; at the side of the chest, as low as the tenth rib on the left side, and the ninth on the right side; and behind, it reaches as low as the twelfth rib, and sometimes even beyond it, as low as the transverse process of the first lumbar vertebra. *Above*, its apex projects, in the form of a *cul-de-sac*, through the superior opening of the thorax into the neck, extending from one to two inches above the margin of the first rib, and receives the summit of the corresponding lung; this sac is strengthened, according to Dr. Sibson, by a dome-like expansion of fascia, attached in front to the posterior border of the first rib, and behind to the anterior border of the transverse process of the seventh cervical vertebra. This is covered and strengthened by a few spreading muscular fibres derived from the Scaleni muscles.

In the front of the chest, where the parietal layer of the pleura is reflected backwards to the pericardium, the two pleural sacs are in contact for a considerable extent. At the upper part of the chest, behind the manubrium, they are not in contact; the point of reflection being represented by a line drawn from the sterno-clavicular articulation to the mid-point of the junction of the manubrium to the body of the sternum. From this point the two pleuræ descend in close contact to the level of the fifth costal cartilage. Here the line of reflection on the right side is continued onwards in nearly a straight line to the lower end of the gladiolus and then turns outwards, whilst on the left side the line of reflection diverges outwards, so that opposite the seventh cartilage it about corresponds to the left border of this structure. It, however, always extends considerably further over the pericardium than the corresponding lung. The lower limit of the pleura is on a considerably lower level than the lower limit of the lung, but does not extend to the attachment of the Diaphragm.

The inner surface of the pleura is smooth, polished, and moistened by a serous fluid; its outer surface is intimately adherent to the surface of the lung, and to the pulmonary vessels as they emerge from the pericardium; it is also adherent to the upper surface of the Diaphragm: throughout the rest of its extent it is somewhat thicker, and may be separated from the adjacent parts with extreme facility.

The right pleural sac is shorter, wider, and reaches higher in the neck than the left.

**Vessels and Nerves.**—The *arteries of the pleura* are derived from the intercostal, the internal mammary, the musculo-phrenic, thymic, pericardiac, and bronchial. The *veins* correspond to the arteries. The *lymphatics* are very numerous. The *nerves* are derived from the phrenic and sympathetic (Luschka). Kölliker states that nerves accompany the ramification of the bronchial arteries in the pleura pulmonalis.

*Surgical Anatomy.*—In operations upon the kidney, it must be borne in mind that the pleura may sometimes extend below the level of the last rib, and may therefore be opened in these operations, especially when the last rib is removed in order to give more room.

#### THE MEDIASTINUM

The **Mediastinum** is the space left in the median line of the chest by the non-approximation of the two pleuræ. It extends from the sternum in front to the spine behind, and contains all the viscera in the thorax excepting the lungs. The mediastinum may be divided for purposes of description into two parts: an upper portion, above the upper level of the pericardium, which is named the *Superior mediastinum* (Struthers); and a lower portion, below the upper level of the pericardium. This lower portion is again subdivided into three: that part





cardiac, phrenic, and left recurrent laryngeal nerves; the trachea, œsophagus, and thoracic duct; the remains of the thymus gland and some lymphatic glands.

The **anterior mediastinum** is bounded in front by the sternum, on each side by the pleura, and behind by the pericardium. It is very narrow, especially above, where the two pleural sacs are almost, if not quite, in contact, but widens out a little below, where the left pleura diverges somewhat from the middle line. It is therefore not parallel with the sternum, but directed from above obliquely downwards and to the left. It contains the origins of the *Triangularis sterni* muscles, and a quantity of loose areolar tissue, in which some lymphatic vessels are found ascending from the convex surface of the liver, and two or three lymphatic glands (anterior mediastinal glands).

The **middle mediastinum** is the broadest part of the interpleural space. It contains the heart, enclosed in the pericardium, the ascending aorta, the lower half of the superior vena cava, with the vena *azygos major* opening into it, the bifurcation of the trachea and the two bronchi, the pulmonary artery dividing into its two branches and the right and left pulmonary veins, the phrenic nerves, and some bronchial lymphatic glands.

The **posterior mediastinum** (fig. 645) is an irregular triangular space running parallel with the vertebral column; it is bounded in front by the pericardium and roots of the lungs, behind by the vertebral column from the lower border of the fourth dorsal vertebra, and on either side by the pleura. It contains the descending thoracic aorta, the greater and lesser *azygos* veins, the pneumogastric and splanchnic nerves, the œsophagus, thoracic duct, and some lymphatic glands.

#### THE LUNGS

The **Lungs** are the essential organs of respiration; they are two in number, placed one on each side of the chest, separated from each other by the heart and other contents of the mediastinum. Each lung is conical in shape, and presents for examination an apex, a base, two borders, and two surfaces (see fig. 647).

The *apex* forms a tapering cone which extends into the root of the neck, about an inch to an inch and a half above the level of the first rib.

The *base* is broad, concave, and rests upon the convex surface of the Diaphragm: its circumference is thin, and fits into the space between the lower ribs and the costal attachment of the Diaphragm, extending lower down externally and behind than in front.

The *external* or *thoracic surface* is smooth, convex, of considerable extent, and corresponds to the form of the cavity of the chest, being deeper behind than in front.

The *inner surface* is concave. It presents, in front, a depression corresponding to the convex surface of the pericardium; and behind, a deep fissure (the *hilum pulmonis*), which gives attachment to the root of the lung.

The *posterior border* is rounded and broad, and is received into the deep concavity on either side of the spinal column. It is much longer than the anterior border, and projects, below, between the ribs and the Diaphragm.

The *anterior border* is thin and sharp, and overlaps the front of the pericardium.

Each lung is divided into two lobes, an upper and lower, by a long and deep fissure, which extends from the upper part of the posterior border of the organ, about three inches from its apex, downwards and forwards to the lower part of its anterior border. This fissure penetrates nearly to the root. In the right lung the upper lobe is partially subdivided by a second and shorter fissure, which extends from the middle of the preceding, forwards and upwards, to the anterior margin of the organ, marking off a small triangular portion, the middle lobe.

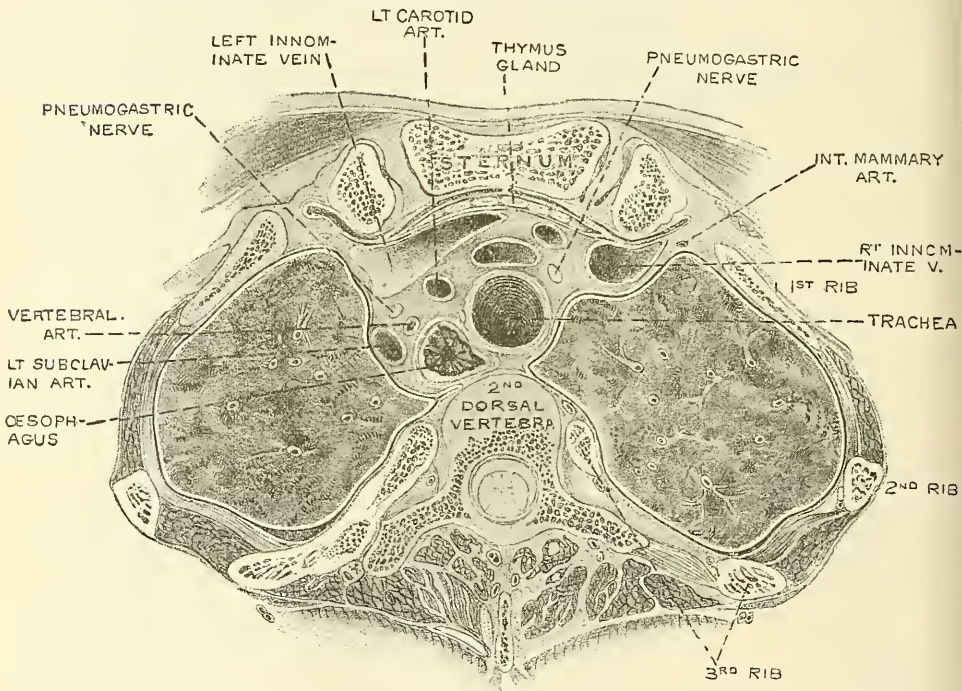
The *right lung* is the larger and heavier; it is broader than the left, owing to the inclination of the heart to the left side; it is also shorter by an inch, in



consequence of the Diaphragm rising higher on the right side to accommodate the liver.

**The roots of the lungs.**—A little above the middle of the inner surface of each lung, and nearer its posterior than its anterior border, is its root, by which the lung is connected to the heart and the trachea. The root is formed by the bronchial tube, the pulmonary artery, the pulmonary veins, the bronchial arteries and veins, the pulmonary plexus of nerves, lymphatics, bronchial glands, and areolar tissue, all of which are enclosed by a reflection of the pleura. The root of the right lung lies behind the superior vena cava and ascending portion of the aorta, and below the vena azygos major. That of the left lung passes beneath the arch of the aorta, and in front of the descending aorta; the phrenic nerve and the anterior pulmonary plexus lie in front of each, and the pneumogastric and posterior pulmonary plexus behind each.

FIG. 646.—Transverse section through the upper margin of the third dorsal vertebra. (Braune.)



The chief structures composing the root of each lung are arranged in a similar manner from before backwards on both sides—viz.: the pulmonary veins most anterior; the pulmonary artery in the middle; and the bronchus, together with the bronchial vessels, behind. From above downwards, on the two sides, their arrangement differs, thus:

On the right side their position is—bronchus, pulmonary artery, pulmonary veins; but on the left side their position is—pulmonary artery, bronchus, pulmonary veins; this is accounted for by the bronchus being placed on a lower level on the left than on the right side, in order that it may pass under the arch of the aorta.

The *weight* of both lungs together is about forty-two ounces, the right lung being two ounces heavier than the left; but much variation is met with according to the amount of blood or serous fluid they may contain. The lungs are heavier in the male than in the female, their proportion to the body being, in the former, as 1 to 37, in the latter as 1 to 43. The specific gravity of the lung-tissue varies from 0.345 to 0.746, water being 1,000.

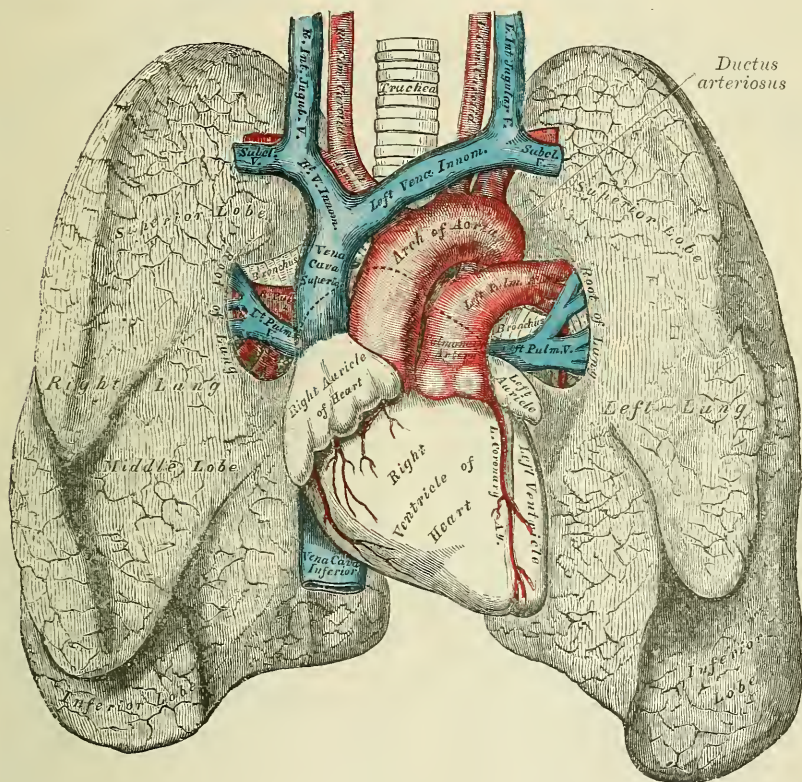


The *colour* of the lungs at birth is a pinkish-white; in adult life, a dark slate-colour, mottled in patches; and as age advances, this mottling assumes a black colour. The colouring matter consists of granules of a carbonaceous substance deposited in the areolar tissue near the surface of the organ. It increases in quantity as age advances, and is more abundant in males than in females. The posterior border of the lung is usually darker than the anterior.

The *surface* of the lung is smooth, shining, and marked out into numerous polyhedral spaces, indicating the lobules of the organ: the area of each of these spaces is crossed by numerous lighter lines.

The *substance* of the lung is of a light, porous, spongy texture; it floats in water, and crepitates when handled, owing to the presence of air in the tissue;

FIG. 647.—Front view of the heart and lungs.



it is also highly elastic; hence the collapsed state of these organs when they are removed from the closed cavity of the thorax.

**Structure.**—The lungs are composed of an external serous coat, a subserous areolar tissue, and the pulmonary substance or parenchyma.

The *serous coat* is derived from the pleura; it is thin, transparent, and invests the entire organ as far as the root.

The *subserous areolar tissue* contains a large proportion of elastic fibres; it invests the entire surface of the lung, and extends inwards between the lobules.

The *parenchyma* is composed of lobules, which, although closely connected together by an interlobular areolar tissue, are quite distinct from one another, and may be teased asunder without much difficulty in the fœtus. The lobules vary in size: those on the surface are large, of pyramidal form, the base turned towards the surface; those in the interior smaller, and of various forms. Each lobule is composed of one of the ramifications of a bronchial tube and its

terminal air-cells, and of the ramifications of the pulmonary and bronchial vessels, lymphatics and nerves; all of these structures being connected together by areolar tissue.

The *bronchus*, upon entering the substance of the lung, divides and subdivides bipinnately throughout the entire organ. Sometimes three branches arise together, and occasionally small lateral branches are given off from the sides of a main trunk. Each of the smaller subdivisions of the bronchi enters a pulmonary lobule, and is termed a *lobular bronchial tube* or *bronchiole*. Its wall now begins to present irregular dilatations, *air-cells* or *alveoli*, at first sparingly and on one side of the tube only, but as it proceeds onwards these dilatations become more numerous and surround the tube on all sides, so that it loses its cylindrical character. The bronchiole now becomes enlarged, and is termed the *atrium* or *alveolar passage*; from it are given off, on all sides, ramifications, called *infundibula*, which are closely beset in all directions by *alveoli* or *air-cells*. Within the lungs the bronchial tubes are circular, not flattened, and present certain peculiarities of structure.

**Changes in the structure of the bronchi in the lungs.**—1. *In the lobes of the lungs.*—In the lobes of the lungs the following changes take place. The *cartilages* are not imperfect rings, but consist of thin laminae, of varied form and size, scattered irregularly along the sides of the tube, being most distinct at the points of division of the bronchi. They may be traced into tubes, the diameter of which is only one-fourth of a line. Beyond this point the tubes are wholly membranous. The fibrous coat and the longitudinal elastic fibres are continued into the smallest ramifications of the bronchi. The muscular coat is disposed in the form of a continuous layer of annular fibres, which may be traced upon the smallest bronchial tubes, and consists of the unstriped variety of muscular tissue. The mucous membrane lines the bronchi and its ramifications throughout, and is covered with columnar ciliated epithelium.

2. *In the lobules of the lung.*—In the lobular bronchial tubes and in the infundibula the following changes take place. The muscular tissue begins to disappear, so that in the infundibula there is scarcely a trace of it. The longitudinal elastic fibres begin to break up, so that in the infundibula they form an interlacement around the mouths of the air-cells which spring from it. The epithelium becomes non-ciliated and flattened. This occurs gradually; thus, in the lobular bronchial tubes, patches of non-ciliated flattened epithelium may be found scattered amongst the columnar ciliated epithelium; then these patches of non-ciliated flattened epithelium become more and more numerous, until in the infundibula and air-cells all the epithelium is of the non-ciliated pavement variety. In addition to these flattened cells, there are small polygonal granular cells in the air-sacs in clusters of two or three, between the others.

The air-cells are small, polyhedral, alveolar recesses composed of a fibrillated connective tissue, and surrounded by a few involuntary muscular and elastic fibres. In their walls are granular, rounded, amœboid cells, often containing carbonaceous particles. The air-cells are well seen on the surface of the lung, and vary from  $\frac{1}{20}$ th to  $\frac{1}{70}$ th of an inch in diameter; being largest on the surface at the thin borders and at the apex, and smallest in the interior.

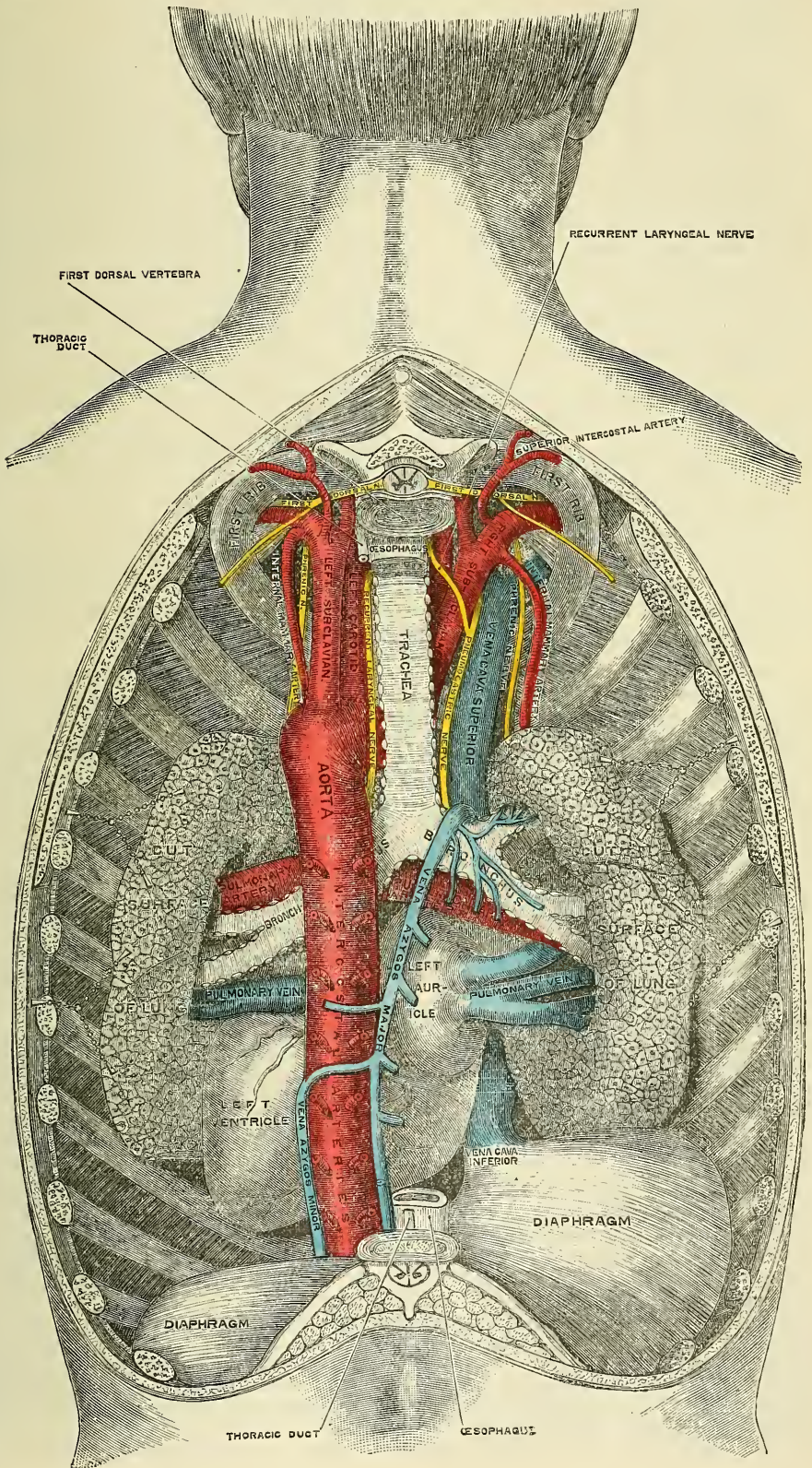
The *pulmonary artery* conveys the venous blood to the lungs; it divides into branches which accompany the bronchial tubes, and terminates in a dense capillary network, upon the walls of the intercellular passages and air-cells. In the lung, the branches of the pulmonary artery are usually above and in front of a bronchial tube, the vein below.

The *pulmonary capillaries* form plexuses which lie immediately beneath the mucous membrane, in the walls and septa of the air-cells, and of the infundibula. In the septa between the air-cells the capillary network forms a single layer. The capillaries form a very minute network, the meshes of which are smaller than the vessels themselves; \* their walls are also exceedingly thin. The arteries

\* The meshes are only 0.002'' to 0.008'' in width, while the vessels are 0.003'' to 0.005''. Kölliker, *Human Microscopic Anatomy*.



FIG. 648.—The roots of the lungs and posterior pulmonary plexus, seen from behind.





of neighbouring lobules are independent of each other, but the veins freely anastomose together.

The *pulmonary veins* commence in the pulmonary capillaries, the radicles coalescing into larger branches, which accompany the arteries and return the oxygenated blood to the left auricle of the heart.

The *bronchial arteries* supply blood for the nutrition of the lung: they are derived from the thoracic aorta, and, accompanying the bronchial tubes, are distributed to the bronchial glands, and upon the walls of the larger bronchial tubes and pulmonary vessels. Those supplying the bronchial tubes form a capillary plexus in the muscular coat, from which branches are given off to form a second plexus in the mucous coat. This plexus communicates with branches of the pulmonary artery, and empties itself into the pulmonary vein. Others are distributed in the interlobular areolar tissue, and terminate partly in the deep, partly in the superficial, bronchial veins. Lastly, some ramify upon the surface of the lung, beneath the pleura, where they form a capillary network.

The *bronchial vein* is formed at the root of the lung, receiving superficial and deep veins corresponding to branches of the bronchial artery. It does not, however, receive all the blood supplied by the artery, as some of it passes into the pulmonary vein. It terminates on the right side in the vena azygos major, and on the left side in the superior intercostal vein.

The *lymphatics* consist of a superficial and deep set: they terminate at the root of the lung, in the bronchial glands.

**Nerves.**—The lungs are supplied from the anterior and posterior pulmonary plexuses, formed chiefly by branches from the sympathetic and pneumogastric. The filaments from these plexuses accompany the bronchial tubes, upon which they are lost. Small ganglia are found upon these nerves.

*Surface Form.*—The apex of the lung is situated in the neck, behind the interval between the two heads of origin of the Sterno-mastoid. The height to which it rises above the clavicle varies very considerably, but is generally about one inch. It may, however, extend as much as an inch and a half or an inch and three-quarters, or, on the other hand, it may scarcely project above the level of this bone. In order to mark out the anterior margin of the lung, a line is to be drawn from the apex point, one inch above the level of the clavicle, and rather nearer the posterior than the anterior border of the Sterno-mastoid muscle, downwards and inwards across the sterno-clavicular articulation and first piece of the sternum until it meets, or almost meets, its fellow of the other side opposite the articulation of the manubrium and gladiolus. From this point the two lines are to be drawn downwards, one on either side of the mesial line and close to it, as far as the level of the articulation of the fourth costal cartilages to the sternum. From here the two lines diverge, the left is to be drawn at first passing outwards with a slight inclination downwards, and then taking a bend downwards with a slight inclination outwards to the apex of the heart, and thence to the sixth costo-chondral articulation. The direction of the anterior border of this part of the left lung is denoted with sufficient accuracy by a curved line, with its convexity directed upwards and outwards from the articulation of the fourth right costal cartilage of the sternum to the fifth intercostal space, an inch and a half below, and three-quarters of an inch internal to the left nipple. The continuation of the anterior border of the right lung is marked by a prolongation of its line from the level of the fourth costal cartilages vertically downwards as far as the sixth, when it slopes off along the line of the sixth costal cartilage to its articulation with the rib.

The lower border of the lung is marked out by a slightly curved line, with its convexity downwards from the articulation of the sixth costal cartilage to its rib to the spinous process of the tenth dorsal vertebra. If vertical lines are drawn downwards from the nipple, the mid-axillary line and the apex of the scapula, while the arms are raised from the sides, they should intersect this convex line, the first at the sixth, the second at the eighth, and the third at the tenth rib. It will thus be seen that the pleura (see page 1047) extends farther down than the lung, so that it may be wounded, and a wound pass through its cavity into the Diaphragm, and even injure the abdominal viscera, without the lung being involved.

The posterior border of the lung is indicated by a line drawn from the level of the spinous process of the seventh cervical vertebra, down either side of the spine, corresponding to the costo-vertebral joints as low as the spinous process of the tenth dorsal vertebra. The trachea bifurcates opposite the spinous process of the fourth dorsal vertebra, and from this point the two bronchi are directed outwards, the right one almost horizontally, the left with a considerable inclination downwards.

The position of the great fissure in the right lung may be indicated by a line drawn

from the fourth dorsal vertebra round the side of the chest to the anterior margin of the lung opposite the seventh rib, and the smaller or secondary fissure by a line drawn from the preceding where it bisects the mid-axillary line to the junction of the fourth costal cartilage to the sternum. The great fissure in the left lung is a little higher, extending from the third dorsal vertebra round the side of the chest to reach the anterior margin of the lung opposite the sixth costal cartilage.

*Surgical Anatomy.*—The lungs may be wounded or torn in three ways. (1) By compression of the chest, without any injury to the ribs. (2) By a fractured rib penetrating the lung. (3) By stabs, gunshot wounds, etc.

The first form, where the lung is ruptured by external compression without any fracture of the ribs, is very rare, and usually occurs in young children, and affects the root of the lung, i.e. the most fixed part, and thus, implicating the great vessels, is frequently fatal. It would seem *a priori* a most unusual injury, and its exact mode of causation is difficult to interpret. The probable explanation is that immediately before the compression is applied a deep inspiration is taken and the lungs are fully inflated; owing then to spasm of the glottis at the moment of compression, the air is unable to escape from the lung, which is not able to recede, and consequently gives way.

In the second variety, when the wound in the lung is produced by the penetration of a broken rib, both the pleura costalis and pulmonalis must necessarily be injured, and consequently the air taken into the wounded air-cells may find its way through these wounds into the cellular tissue of the parietes of the chest. This it may do without collecting in the pleural cavity; the two layers of the pleura are so intimately in contact that the air passes straight through from the wounded lung into the subcutaneous tissue. Emphysema constitutes therefore the most important sign of injury to the lung in cases of fracture of the ribs. Pneumothorax, or air in the pleural cavity, is much more likely to occur in injuries to the lung of the third variety, that is to say, from external wounds, from stabs, gunshot injuries and such like, in which case air passes either from the wound of the lung or from the external wound into the cavity of the pleura during the respiratory movements. In these cases there is generally no emphysema of the subcutaneous tissue unless the external wound is small and valvular, so that the air is drawn into the wound during inspiration, and then forced into the cellular tissue around during expiration because it cannot escape from the external wound. Occasionally in wounds of the parietes of the chest no air finds its way into the cavity of the pleura, because the lung at the time of the accident protrudes through the wound and blocks the opening. This occurs where the wound is large, and constitutes one form of *hernia* of the lung. Another form of hernia of the lung occurs, though very rarely, after wounds of the chest wall, when the wound has healed and the cicatrix subsequently yields from the pressure of the viscus behind. It forms a globular, elastic, crepitating swelling, which enlarges during expiratory efforts, falls in during inspiration, and disappears on holding the breath.

## THE THYROID GLAND

The **thyroid gland** bears much resemblance in structure to other glandular organs, and was formerly classified together with the thymus, suprarenal capsules, and spleen, under the head of *ductless glands*, since when fully developed it has no excretory duct. From its situation in connection with the trachea and larynx, the thyroid body is usually described with those organs, although it takes no part in the function of respiration. It is situated at the upper part of the trachea, and consists of two lateral lobes, placed one on each side of that tube, and connected together by a narrow transverse portion, the *isthmus*.

Its *anterior surface* is convex, and covered by the Sterno-hyoid, Sterno-thyroid, and Omo-hyoid muscles.

Its *lateral surfaces*, also convex, lie in contact with the sheath of the common carotid artery and are overlapped by the Sterno-mastoid muscle.

Its *posterior surface* is concave, and embraces the trachea and larynx. The posterior borders of the gland extend as far back as the lower part of the pharynx, and on the left side to the œsophagus.

The thyroid varies in weight from one to two ounces. It is larger in females than in males, and becomes slightly increased in size during menstruation. Each lobe is somewhat conical in shape, about two inches in length, and three-quarters of an inch to an inch and a quarter in breadth, the right lobe being the larger of the two.

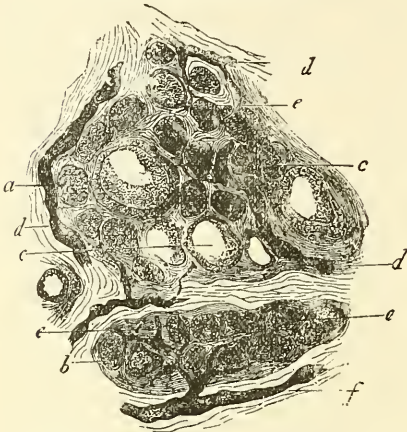
The *isthmus* connects the lower third of the two lateral lobes; it measures about half an inch in breadth, and the same in depth, and usually covers the



second and third rings of the trachea. Its situation presents, however, many variations, a point of importance in the operation of tracheotomy. Sometimes the isthmus is altogether wanting.

A third lobe, of conical shape, called the *pyramid*, occasionally arises from the upper part of the isthmus, or from the adjacent portion of either lobe, but most commonly the left, and ascends as high as the hyoid bone. It is occasionally quite detached, or divided into two parts, or altogether wanting.

FIG. 649.—Two lobules from the thyroid of an infant.



a. Small glandular vesicles with their cells. b. The same with incipient colloid metamorphosis, more strongly marked at c. d. Coarse lymph-canals. c. Fine radicles of the same. f. An efferent vessel of considerable size.

A few muscular bands are occasionally found attached, above, to the body of the hyoid bone, and below to the isthmus of the gland, or its pyramidal process. These form a muscle, which was named by Sömmerring the *Levator glandulae thyroideæ*.

**Structure.**—The thyroid body is invested by a thin capsule of connective tissue, which projects into its substance and imperfectly divides it into masses of irregular form and size. When the organ is cut into, it is of a brownish-red colour, and is seen to be made up of a number of closed vesicles, containing a yellow glairy fluid, and separated from each other by intermediate connective tissue.

According to Dr. Baber, who has recently published some important observations on the minute structure of the thyroid,\* the vesicles of the thyroid of the adult animal are generally closed cavities; but in some young animals (e.g. young dogs) the vesicles are more or less tubular and branched. This appearance he supposes to be due to the mode of growth of the gland, and merely indicating that an increase in the number of vesicles is taking place. Each vesicle is lined by a single layer of epithelium, the cells of which, though differing somewhat in shape in different animals, have always a tendency to assume a columnar form. Between the epithelial cells exists a delicate reticulum. The vesicles are of various sizes and shapes, and contain as a normal product a viscid, homogeneous, semi-fluid, slightly yellowish material, which frequently contains blood; the red corpuscles of which are found in it in various stages of disintegration and decolorisation, the yellow tinge being probably due to the hæmoglobin, which is thus set free from the coloured corpuscles. Baber has also described in the thyroid gland of the dog large round cells ('parenchymatous cells'), each provided with a single oval-shaped nucleus, which migrate into the interior of the gland-vesicles.

The capillary blood-vessels form a dense plexus in the connective tissue around the vesicles, between the epithelium of the vesicles and the endothelium of the lymph-spaces, which latter surround a greater or smaller part of the circumference of the vesicle. These lymph-spaces empty themselves into lymphatic vessels, which run in the interlobular connective tissue, not uncommonly surrounding the arteries which they accompany, and communicate with a network in the capsule of the gland. Baber has found in the lymphatics of the thyroid a viscid material which is morphologically identical with the normal constituent of the vesicle.

**Vessels and Nerves.**—The *arteries* supplying the thyroid are the superior and inferior thyroid, and sometimes an additional branch (thyroidea media, or ima) from the innominate artery, or the arch of the aorta, which ascends upon the

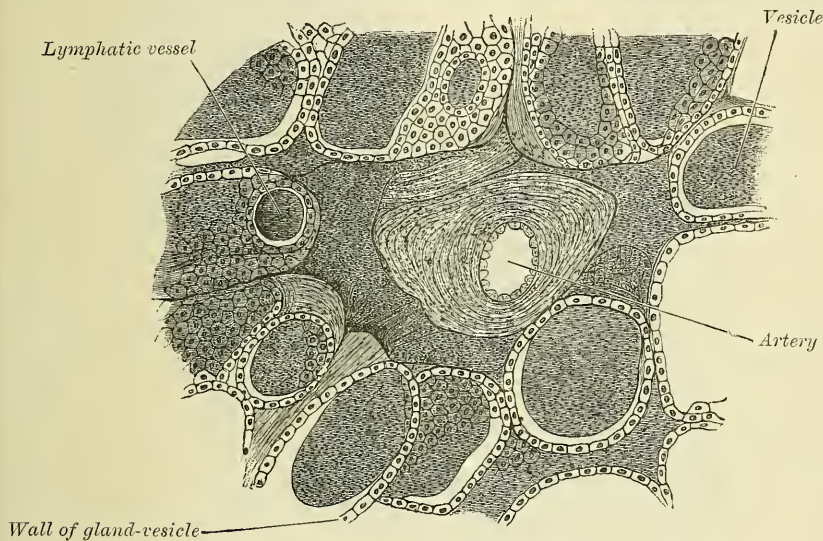
\* 'Researches on the Minute Structure of the Thyroid Gland,' *Phil. Trans.* part iii. 1881.



front of the trachea. The arteries are remarkable for their large size and frequent anastomoses. The *veins* form a plexus on the surface of the gland, and on the front of the trachea, from which arise the superior, middle, and inferior thyroid veins; the two former terminating in the internal jugular, the latter in the innominate vein. The *lymphatics* are numerous, of large size, and terminate in the thoracic and right lymphatic ducts. The *nerves* are derived from the middle and inferior cervical ganglia of the sympathetic.

*Surgical Anatomy.*—The thyroid gland is subject to enlargement, which is called goitre. This may be due to hypertrophy of any of the constituents of the gland. The simplest (parenchymatous goitre) is due to an enlargement of the follicles. The *fibroid* is due to increase of the interstitial connective tissue. The *cystic* is that form in which one or more large cysts are formed from dilatation and possibly coalescence of adjacent follicles. The *pulsating goitre* is where the vascular changes predominate over the

FIG. 650.—Minute structure of thyroid. From a transverse section of the thyroid of a dog. (Semi-diagrammatic.) (Baber.)



parenchymatous, and the vessels of the gland are especially enlarged. Finally, there is *exophthalmic goitre* (Graves's disease), where there is great vascularity and often pulsation accompanied by exophthalmos, palpitation, and rapid pulse.

For the relief of these growths various operations have been resorted to: such as injection of tincture of iodine or perchloride of iron, especially applicable to the cystic form of the disease; ligature of the thyroid arteries; excision of the isthmus; and extirpation of the whole or a part of the gland. This latter operation is one of difficulty, and when the entire gland has been removed the operation has been followed by a condition resembling myxœdema. In removing the organ great care must be taken to avoid tearing the capsule, as if this happens the gland-tissue bleeds profusely. The thyroid arteries should be ligatured before an attempt is made to remove the mass, and in ligaturing the inferior thyroid the position of the recurrent laryngeal nerve must be borne in mind, so as not to include it in the ligature.

### THE THYMUS GLAND

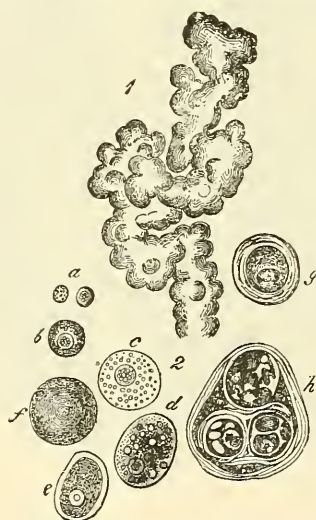
The **thymus gland** presents much resemblance in structure to other glandular organs, and is another of the organs which used formerly to be denominated *ductless glands*.

The thymus gland is a temporary organ, attaining its full size at the end of the second year, when it ceases to grow, and gradually dwindles, until at puberty it has almost disappeared. If examined when its growth is most active, it will be found to consist of two lateral lobes placed in close contact along the middle line, situated partly in the superior mediastinum, partly in the neck, and extending

from the fourth costal cartilage upwards, as high as the lower border of the thyroid gland. It is covered by the sternum, and by the origins of the Sterno-hyoid and Sterno-thyroid muscles: Below, it rests upon the pericardium, being separated from the arch of the aorta and great vessels by a layer of fascia. In the neck it lies on the front and sides of the trachea, behind the Sterno-hyoid and Sterno-thyroid muscles. The two lobes generally differ in size; they are occasionally united, so as to form a single mass; and sometimes separated by an intermediate lobe. The thymus is of a pinkish-grey colour, soft, and lobulated on its surfaces. It is about two inches in length, one and a half in breadth below, and about three or four lines in thickness. At birth it weighs about half an ounce.

**Structure.**—Each lateral lobe is composed of numerous lobules, held together by delicate areolar tissue; the entire gland being enclosed in an investing capsule of a similar but denser structure. The primary lobules vary in size from a pin's head to a small pea, and are made up of a number of small nodules or follicles, which are irregular in shape and are more or less fused together, especially

FIG. 651.—Minute structure of thymus gland.



1. Upper portion of the thymus of a foetal pig of 2'' in length, showing the bud-like lobuli and glandular elements. 2. Cells of the thymus, mostly from a man. *a*. Free nuclei. *b*. Small cells. *c*. Larger. *d*. Larger, with oil-globules, from the ox. *e*, *f*. Cells completely filled with fat, at *f* without a nucleus. *g*, *h*. Concentric bodies. *g*. An encapsulated nucleated cell. *h*. A composite structure of a similar nature.

towards the interior of the gland. According to Watney, each follicle consists of a medullary and cortical portion, which differ in many essential particulars from each other. The *cortical portion* is mainly composed of lymphoid cells, supported by a delicate reticulum. In addition to this reticulum, of which traces only are found in the medullary portion, there is also a network of finely branched cells, which is continuous with a similar network in the medullary portion. This network forms an adventitia to the blood-vessels. In the *medullary portion* there are but few lymphoid cells, but there are, especially towards the centre, granular cells and concentric corpuscles. The granular cells are rounded or flask-shaped masses, attached (often by fibrillated extremities) to blood-vessels and to newly formed connective tissue. The concentric corpuscles are composed of a central mass, consisting of one or more granular cells, and of a capsule which is formed of epithelioid cells, which are continuous with the branched cells forming the network mentioned above.

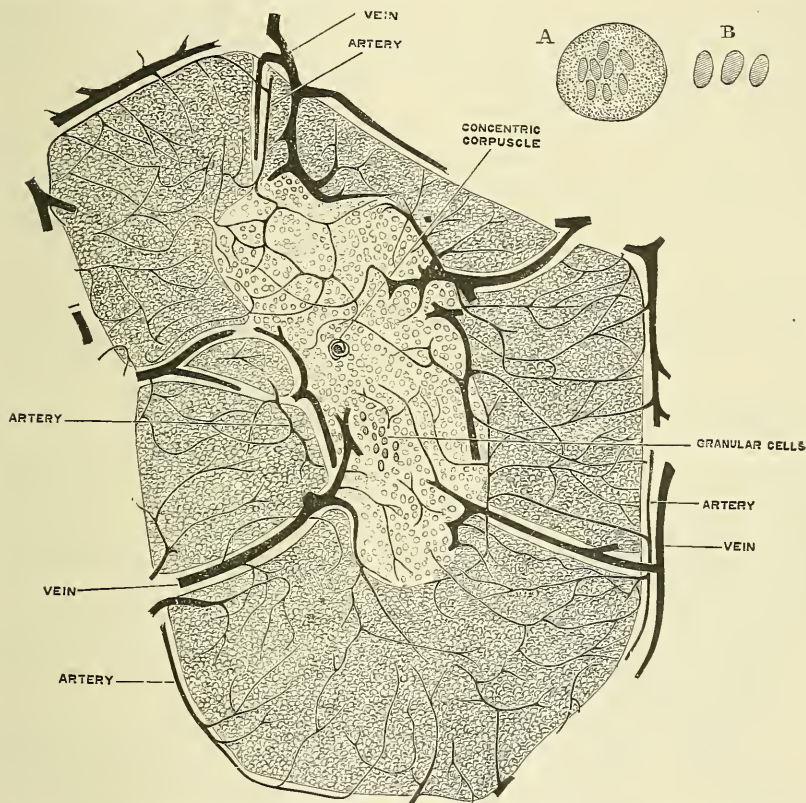
Each follicle is surrounded by a capillary plexus, from which vessels pass into the interior, and radiate from the periphery towards the centre, and form a second



zone just within the margin of the medullary portion. In the centre of the medulla there are very few vessels, and they are of minute size.

Dr. Watney has recently made the important observation that hæmoglobin is found in the thymus, either in cysts or in cells situated near to, or forming part of, the concentric corpuscles. This hæmoglobin varies from granules to masses exactly resembling coloured blood-corpuscles, oval in the bird, reptile, and fish; circular in all mammals, except in the camel. Dr. Watney has also discovered, in the lymph issuing from the thymus, similar cells to those found in the gland, and, like them, containing hæmoglobin, either in the form of granules or masses.

FIG. 652.—Minute structure of thymus gland. Follicle of injected thymus from calf, four days old, slightly diagrammatic, magnified about 50 diameters. The large vessels are disposed in two rings, one of which surrounds the follicle, the other lies just within the margin of the medulla. (Watney.)



A and B. From thymus of camel, examined without addition of any reagent. Magnified about 400 diameters. A. Large colourless cell, containing small oval masses of hæmoglobin. Similar cells are found in the lymph-glands, spleen, and medulla of bone. B. Coloured blood-corpuscles.

From these facts he arrives at the physiological conclusion that the thymus is one source of the coloured blood-corpuscles.

**Vessels and Nerves.**—The *arteries* supplying the thymus are derived from the internal mammary, and from the superior and inferior thyroid. The *veins* terminate in the left innominate vein, and in the thyroid veins. The *lymphatics* are of large size, arise in the substance of the gland, and are said to terminate in the internal jugular vein. The *nerves* are exceedingly minute; they are derived from the pneumogastric and sympathetic. Branches from the descendens hypoglossi and phrenic reach the investing capsule, but do not penetrate into the substance of the gland.



# THE URINARY ORGANS

## THE KIDNEYS

THE Kidneys, two in number, are situated in the back part of the abdomen, and are for the purpose of separating from the blood certain materials which, when dissolved in a quantity of water, also separated from the blood by the kidneys, constitute the urine.

They are placed in the loins, one on each side of the vertebral column, behind the peritoneum, and surrounded by a mass of fat and loose areolar tissue. Their upper extremity is on a level with the upper border of the twelfth dorsal vertebra, their lower extremity on a level with the third lumbar. The right kidney is usually on a slightly lower level than the left, probably on account of the vicinity of the liver.

The kidneys rest on the lower part of the Diaphragm and the fascia covering the *Quadratus lumborum* and the *Psoas magnus* muscles. The right one is covered in front by the right lobe of the liver, the descending portion of the duodenum, and hepatic flexure of the colon; the left one has in front the fundus of the stomach, the tail of the pancreas, and the descending colon.

Each kidney is about four inches in length, two to two and a half in breadth, and rather more than one inch in thickness. The left is somewhat longer, though narrower, than the right. The weight of the kidney in the adult male varies from  $4\frac{1}{2}$  ounces to 6 ounces, in the adult female from 4 to  $5\frac{1}{2}$  ounces. The combined weight of the two kidneys in proportion to the body is about 1 in 240.

The kidney has a characteristic form. It is flattened on its sides, and presents at one part of its circumference a hollow. It is larger at its upper than its lower extremity. It presents for examination two surfaces, two borders, and an upper and lower extremity.

Its *anterior surface* is convex, looks forwards and outwards, and is partially covered by peritoneum. The upper part of this surface on the right side is in contact with the under surface of the right lobe of the liver, on which it produces a slight concave impression, the *impressio renalis* (page 994); below this, the descending portion of the duodenum, and the hepatic flexure of the colon are connected to this surface by a quantity of loose areolar tissue. On the left side, the upper part of the anterior surface of the kidney is in contact with the under surface of the stomach, and below this with the left extremity of the pancreas, whilst the lower part is connected to the descending colon by loose areolar tissue.

The kidneys are partly covered in front by peritoneum and partly uncovered. On the right kidney, the *hepatic area*, that is to say that portion of the kidney which produces the renal impression on the liver, is covered by peritoneum, which therefore separates the kidney from the liver; the *duodenal* and *colic areas* are not peritoneal, and these structures are connected to the kidney by loose connective tissue; at the lower and inner extremity is a small area, the *meso-colic area*, which is covered by a layer of peritoneum of the greater sac and by the colic vessels. On the left kidney, the *gastric area* is covered by the peritoneum of the lesser sac; the *pancreatic* and *colic areas* are non-peritoneal; whilst as on

the right side, at the lower and inner extremity is an area, *meso-colic*, which is covered by the peritoneum of the greater sac and by the colic vessels.

The *posterior surface* is flatter than the anterior, and is embedded in areolar tissue, which separates it from the Diaphragm, and from the anterior lamella of the lumbar fascia covering the Quadratus lumborum muscle, and internally from the fascia covering the Psoas magnus muscle. The last dorsal, the ilio-inguinal and the ilio-hypogastric nerves are also in relation with this surface.

The *external border* is convex, and is directed outwards and backwards, towards the postero-lateral wall of the abdomen. On the left side it is in contact, at its upper part, with the spleen.

The *internal border* is concave, and is directed forwards and a little downwards. It presents a deep longitudinal fissure, bounded by a prominent overhanging anterior and posterior lip. This fissure is named the *hilum*, and allows of the passage of the vessels, nerves, and ureter into and out of the kidney.

The *superior extremity*, directed slightly inwards as well as upwards, is thick and rounded, and is surmounted by the suprarenal capsule, which covers also a small portion of the anterior surface.

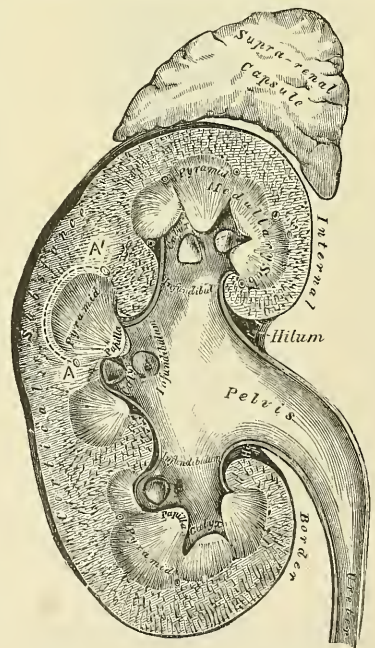
The *inferior extremity*, directed a little outwards, as well as downwards, is smaller and thinner than the superior. It extends to within two inches of the crest of the ilium.

At the hilum of the kidney the relative position of the main structures passing into and out of the kidney is as follows:—the vein is in front, the artery in the middle, and the duct or ureter behind and towards the lower part. By a knowledge of these relations, the student may distinguish between the right and left kidney. The kidney is to be laid on the table, before the student, on its posterior surface, with its lower extremity towards the observer—that is to say, with the ureter *behind* and *below* the other vessels; the hilum will then be directed to the side to which the kidney belongs.

**General Structure of the Kidney.**—The kidney is surrounded by a distinct investment of fibrous tissue, which forms a firm, smooth covering to the organ. It closely invests it, but can be easily stripped off, in doing which, however, numerous fine processes of connective tissue and small blood-vessels are torn through. Beneath this coat, a thin wide-meshed network of unstriped muscular fibre forms an incomplete covering to the organ. When the fibrous coat is stripped off, the surface of the kidney is found to be smooth and even, and of a deep red colour.

In infants, fissures extending for some depth may be seen on the surface of the organ, a remnant of the lobular construction of the gland. The kidney is dense in texture, but is easily lacerable by mechanical force. In order to obtain a knowledge of the structure of the gland, a vertical section must be made from its convex to its concave border, and the loose tissue and fat removed from around the vessels and the excretory duct (fig. 653). It will be then seen that the kidney consists of a central cavity, surrounded at all parts but one by the proper kidney-substance. This central cavity is called the *sinus*, and is lined by a

FIG. 653.—Vertical section of kidney.



prolongation of the fibrous coat of the kidney, which enters through a longitudinal fissure, the *hilum* (before mentioned), which is situated at that part of the cavity which is not surrounded by kidney-structure. Through this fissure the blood-vessels of the kidney and its excretory duct pass, and therefore these structures, upon entering the kidney, are contained within the sinus. The excretory duct, or *ureter*, after entering, dilates into a wide, funnel-shaped sac, named the *pelvis*. This divides into two or three tubular divisions, which subdivide into several short, truncated branches, named *calices* or *infundibula*, all of which are contained in the central cavity of the kidney. The blood-vessels of the kidney, after passing through the hilum, are contained in the sinus or central cavity, lying between its lining membrane and the excretory apparatus before entering the kidney-substance.

This central cavity, as before mentioned, is surrounded on all sides, except at the hilum, by the substance of the kidney, which is at once seen to consist of two parts, viz. of an external, granular, investing part, which is called the *cortical portion*; and of an internal part, the *medullary portion*, made up of a number of dark-coloured pyramidal masses, with their bases resting on the cortical part, and their apices converging towards the centre, where they form prominent papillæ, which project into the interior of the calices.

The cortical substance is of a bright reddish-brown colour, soft, granular, and easily lacerable. It is found everywhere immediately beneath the capsule, and is

seen to extend in an arched form over the base of each medullary pyramid. The part separating the sides of any two pyramids through which the arteries and nerves enter, and the veins and lymphatics emerge from the kidney, is called a *cortical column* or *column of Bertini* (A A', fig. 653); whilst that portion which stretches from one cortical column to the next, and intervenes between the base of the pyramid and the capsule (which is marked by the dotted line, extending from A to A' in fig. 653), is called a *cortical arch*, the depth of which varies from a third to half an inch.

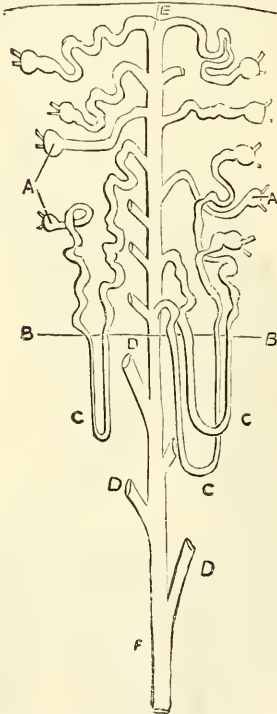
The *medullary substance*, as before said, is seen to consist of pale red-coloured, striated, conical masses, the *pyramids of Malpighi*; the number of which, varying from eight to eighteen, correspond to the number of lobes of which the organ in the foetal state is composed. The base of each pyramid is surrounded by a cortical arch and directed towards the circumference of the kidney; the sides are contiguous with the cortical columns; whilst the apex, known as the *papilla* or *mammilla* of the kidney, projects into one of the calices of the ureter.

These two parts, *cortical* and *medullary*, so dissimilar in appearance, are very similar in structure, being made up of urinary tubes and blood-vessels, united and bound together by a connecting matrix or stroma.

**Minute Anatomy.**—The *tubuli uriniferi*, of

which the kidney is for the most part made up, commence in the cortical portion of the kidney, and, after pursuing a very circuitous course through the cortical and medullary parts of the kidney, finally terminate at the apices of the Malpighian pyramids by open mouths (fig. 654), so that the fluid which they

FIG. 654.



A A. Malpighian bodies. B B. Margin of medullary structure. C C C. Loops of Henle. D D D. Straight tubes cut off. E. Commencing straight tubes. F. Termination of straight tube.



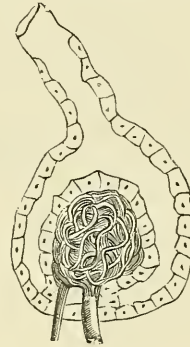
contain is emptied into the dilated extremity of the ureter contained in the sinus of the kidney. If the surface of one of the papillæ is examined with a lens, it will be seen to be studded over with a number of small depressions from sixteen to twenty in number, and in a fresh kidney, upon pressure being made, fluid will be seen to exude from these depressions. They are the orifices of the tubuli uriniferi, which terminate in this situation. They commence in the cortical portion of the kidney as the *Malpighian bodies*, which are small rounded masses, varying in size, but of an average of about  $\frac{1}{120}$  of an inch in diameter. They are of a deep red colour, and are found only in the cortical portion of the kidney. Each of these little bodies is composed of two parts: a central glomerulus of vessels, called a *Malpighian tuft*; and a membranous envelope, the *Malpighian capsule*, or *capsule of Bowman*, which latter is a small pouch-like commencement of a uriniferous tubule.

The *Malpighian tuft*, or vascular glomerulus, is a network of convoluted capillary blood-vessels, held together by scanty connective tissue and grouped into from two to five lobules. This capillary network is derived from a small arterial twig, the *afferent vessel*, which pierces the wall of the capsule, generally at a point opposite that at which the latter is connected with the tube; and the

FIG. 655.—Minute structure of kidney.

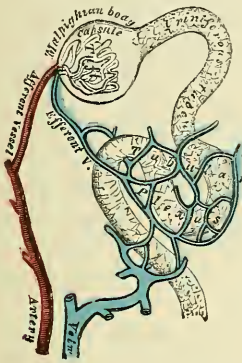

FIG. 656.—Malpighian body.



resulting vein, the *efferent vessel*, emerges from the capsule at the same point. The afferent vessel is usually the larger of the two (fig. 655). The *Malpighian*, or *Bowman's capsule*, which surrounds the glomerulus, is formed of a hyaline membrane, supported by a small amount of connective tissue, which is continuous with the connective tissue of the tube. It is lined on its inner surface by a layer of squamous epithelial cells, which are reflected from the lining membrane on to the glomerulus, at the point of entrance or exit of the afferent and efferent vessels. The whole surface of the glomerulus is covered with a continuous layer of the same cells, on a delicate supporting membrane, which with the cells dips in between the lobules of the glomerulus, closely surrounding them (fig. 656). Thus between the glomerulus and the capsule a space is left, forming a cavity lined by a continuous layer of cells, which varies in size according to the state of secretion and the amount of fluid present in it. The cells, as above stated, are squamous in the adult, but in the fœtus and young subject they are polyhedral or even columnar.

The *tubuli uriniferi*, commencing in the Malpighian bodies, in their course present many changes in shape and direction, and are contained partly in the medullary and partly in the cortical portions of the organ. At their junction with the Malpighian capsule they present a somewhat constricted portion, which is termed the *neck*. Beyond this the tube becomes convoluted, and pursues a considerable course in the cortical structure, constituting the *proximal convoluted tube*. After a time the convolutions disappear, and the tube approaches the medullary portion of the kidney in a more or less spiral manner. This section of

the tube has been called the *spiral tube of Schachowa*. Throughout this portion of their course the tubuli uriniferi have been contained entirely in the cortical structure, and have presented a pretty uniform calibre. They now enter the medullary portion, suddenly become much smaller, quite straight in direction, and dip down for a variable depth into the pyramids, constituting the *descending limb of Henle's loop*. Bending on themselves, they form a kind of loop, the *loop of Henle*, and re-ascending, they become suddenly enlarged and again spiral in direction, forming the *ascending limb of Henle's loop*, and re-enter the cortical structure. This portion of the tube does not present a uniform calibre, but becomes narrower as it ascends, and irregular in outline. As a narrow tube it enters the cortex and ascends for a short distance, when it again becomes dilated, irregular, and angular. This section is termed the *irregular tubule*; it terminates in a convoluted tube, which exactly resembles the proximal convoluted tubule, and is called the *distal convoluted tubule*. This again terminates in a narrow *curved tube*, which enters the straight or collecting tube.

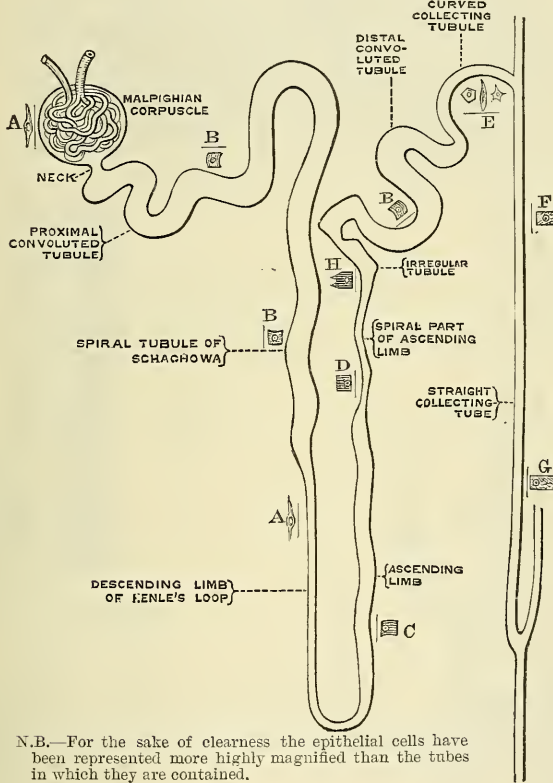
Each *straight*, otherwise called a *collecting* or *receiving tube*, commences by a small orifice on the summit of one of the papillæ, thus opening and discharging its contents into the interior of one of the calices. Traced into the substance of the pyramid, these tubes are found to run from apex to base, dividing dichotomously in their course and slightly diverging from each other. Thus dividing, and subdividing, they reach the base of the pyramid, and enter the cortical structure greatly increased in number. Upon entering the cortical portion they continue a straight course for a variable distance, and are arranged in groups, called *medullary rays*, several of these groups corresponding to a single pyramid. The tubes in the centre of the group are the longest, and reach almost to the surface of the kidney, while the external ones are shorter, and advance only a short distance into the cortex. In consequence of this arrangement the cortical portion presents a number of conical masses, the apices of which reach the periphery of the organ, and the bases are applied to the medullary portion. These are termed the *pyramids of Ferrein*. As they run through the cortical portion, the straight tubes receive on either side the curved extremity of the convoluted tubes, which, as stated above, commence at the Malpighian bodies.

It will be seen from the above description that there is a continuous series of tubes from their commencement in the Malpighian bodies, to their termination at the orifices on the apices of the pyramids of Malpighi; and that the urine, the secretion of which commences in the capsule, finds its way through these tubes into the calices of the kidney, and so into the ureter. Commencing at the capsule, the tube first presents a narrow constricted portion (1) the *neck*. 2. It forms a wide convoluted tube, the *proximal convoluted tube*. 3. It becomes spiral, the *spiral tubule of Schachowa*. 4. It enters the medullary structure as a narrow, straight tube, the *descending limb of Henle's loop*. 5. Forming a loop and becoming dilated, it ascends somewhat spirally and, gradually diminishing in calibre, again enters the cortical structure, the *ascending limb of Henle's loop*. 6. It now becomes irregular and angular in outline, the *irregular tubule*. 7. It then becomes convoluted, the *distal convoluted tubule*. 8. Diminishing in size, it forms a curve, the *curved tubule*. 9. Finally it joins a straight tube, the *straight collecting tube*, which is continued downwards through the medullary substance to open at the apex of a pyramid.

*The Tubuli Uriniferi: their Structure.*—The tubuli uriniferi consist of basement membrane lined with epithelium. The epithelium varies considerably in different sections of the uriniferous tubes. In the neck the epithelium is continuous with that lining the Malpighian capsule, and like it consists of flattened cells with an oval nucleus (fig. 657, A). The cells are, however, very indistinct and difficult to trace, and the tube has here the appearance of a simple basement membrane unlined by epithelium. In the proximal convoluted tubule and the spiral tubule of Schachowa the epithelium is polyhedral in shape, the sides of the cells not being straight, but fitting into each other, and in some animals so fused

together that it is impossible to make out the lines of junction. In the human kidney the cells often present an angular projection of the surface next the basement membrane. These cells are made up of more or less rod-like fibres, which rest by one extremity on the basement membrane, whilst the other projects towards the lumen of the tube. This gives to the cells the appearance of distinct striation (Heidenhain) (fig. 657, B). In the descending limb of Henle's loop the epithelium resembles that found in the Malpighian capsule and the commencement of the tube, consisting of flat transparent epithelial plates with an oval nucleus (figs. 657, A; 658). In the ascending limb, on the other hand, the cells partake more of the character of those described as existing in the proximal convoluted tubule, being polyhedral in shape, and presenting the same appearance of striation. The nucleus, however, is not situated in the centre of the cell, but near the lumen

Fig. 657.—Uriniferous tube.



N.B.—For the sake of clearness the epithelial cells have been represented more highly magnified than the tubes in which they are contained.

(fig. 657, C). After the ascending limb of Henle's loop becomes narrower upon entering the cortical structure, the striation appears to be confined to the outer part of the cell; at all events it is much more distinct in this situation; the nucleus, which appears flattened and angular, being still situated near the lumen (fig. 657, D). In the irregular tubule, the cells undergo a still further change, becoming very angular, and presenting thick bright rods or markings, which render the striation much more distinct than in any other section of the urinary tubules (fig. 657, H). In the distal convoluted tubule the epithelium appears to be somewhat similar to that which has been described as existing in the proximal convoluted tubule, but presents a peculiar refractive appearance (fig. 657, B). In the curved tubule, just before its entrance into the straight collecting tube, the epithelium varies greatly as regards the shape of the cells, some being angular with short processes, others spindle-shaped, others polyhedral (fig. 657, E).



In the straight tubes the epithelium is more or less columnar: in its papillary portion the cells are distinctly columnar and transparent (figs. 659, 660); but as the tube approaches the cortex the cells are less uniform in shape; some are polyhedral, and others angular with short processes (fig. 657, F and G).

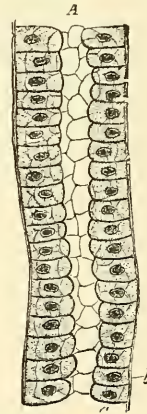
**The Renal Blood-vessels.**—The kidney is plentifully supplied with blood by the renal artery, a large offset of the abdominal aorta. Previously to entering the kidney, each artery divides into four or five branches, which are distributed to its substance. At the hilum these branches lie between the renal vein and ureter, the vein being in front, the ureter behind. Each vessel gives off some small branches to the suprarenal capsules, the ureter, and the surrounding cellular tissue and muscles. Frequently there is a second renal artery, which is given off from the abdominal aorta at a lower level, and supplies the lower portion of the kidney. It is termed the *inferior renal artery*. The branches of the renal artery, whilst in the sinus, give off a few twigs for the nutrition of the surrounding tissues, and terminate in the *arteriæ propriae renales*, which enter the kidney proper in the columns of Bertini. Two of these pass to each pyramid of Malpighi, and run along its sides for its entire length, giving off as they

FIG. 658.\*—Longitudinal section of Henle's descending limb.



a. Membrana propria.  
b. Epithelium.

FIG. 659.—Longitudinal section of straight tube.



a. Cylindrical or cubical epithelium.  
b. Membrana propria.

advance the afferent vessels of the Malpighian bodies in the columns. Having arrived at the bases of the pyramids, they make a bend in their course, so as to lie between the bases of the pyramids and the cortical arches, where they break up into two distinct sets of branches devoted to the supply of the remaining portions of the kidney.

The *first set*, the *interlobular arteries* (figs. 661, 662, B), are given off at right angles from the side of the *arteriæ propriae renales* looking towards the cortical substance, and passing directly outwards between the pyramids of Ferrein they reach the capsule, where they terminate in the capillary network of this part. In their outward course they give off lateral branches; these are the *afferent vessels* for the Malpighian bodies (see page 1063), and, having pierced the capsule, end in the Malpighian tufts. From each tuft the corresponding renal efferent arises, and, having made its egress from the capsule near to the point where the afferent vessel entered, breaks up into a number of branches, which form a dense *venous plexus* around the adjacent urinary tubes (fig. 661).

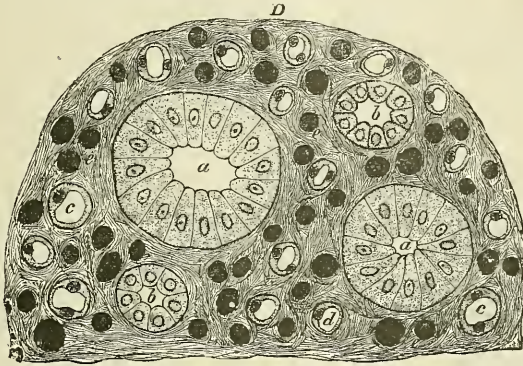
The *second set of branches* from the *arteriæ propriae renales* are for the supply of the medullary pyramids, which they enter at their bases; and, passing straight

\* From the *Handbook for the Physiological Laboratory*.

through their substance to their apices, terminate in the venous plexuses found in that situation. They are called the *arteriola recta* (figs. 661, 662, F).

The *renal veins* arise from *three sources*—the veins beneath the capsule, the plexuses around the tubuli contorti in the cortical arches, and the plexuses

FIG. 660.—Transverse section of pyramidal substance of kidney of pig, the blood-vessels of which are injected.



a. Large collecting tube, cut across, lined with cylindrical epithelium. b. Branch of collecting tube, cut across, lined with epithelium with shorter cylinders. c and d. Henle's loops cut across. e. Blood-vessels cut across. D. Connective-tissue ground-substance.

situated at the apices of the pyramids of Malpighi. The veins beneath the capsule are stellate in arrangement, and are derived from the capillary network of the capsule, into which the terminal branches of the interlobular arteries break up. These join to form the *venæ interlobulares*, which pass inwards

FIG. 661.—Diagrammatical sketch of kidney.

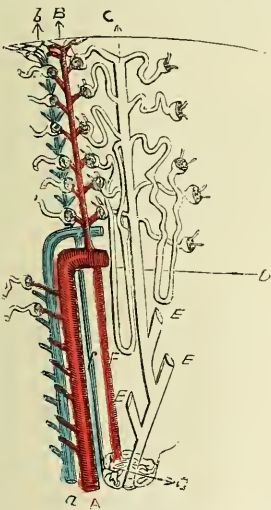
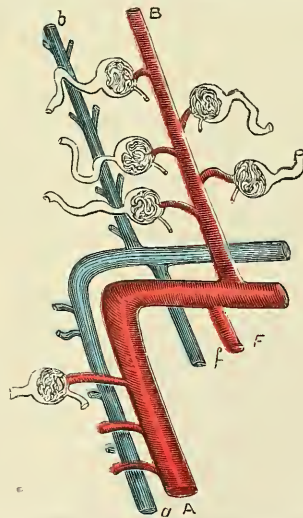


FIG. 662.—A portion of fig. 661 enlarged. (The references are the same.)



A a. Proper renal artery and vein, the former giving off the renal afferents, the latter receiving the renal efferents. B b. Interlobular artery and vein, the latter commencing from the stellate veins, and receiving branches from the plexus around the tubuli contorti, the former giving off renal afferents. c. Straight tube, surrounded by tubuli contorti, with which it communicates, as more fully shown in fig. 654. D. Margin of medullary substance. E E E. Receiving tubes, cut off. F f. Arteriola et venæ rectæ, the latter arising from (G) the plexus at the medullary apex.

between the pyramids of Ferrein, receive branches from the plexuses around the tubuli contorti, and, having arrived at the bases of the Malpighian pyramids, join with the *venæ rectæ*, next to be described (figs. 661, 662, b).

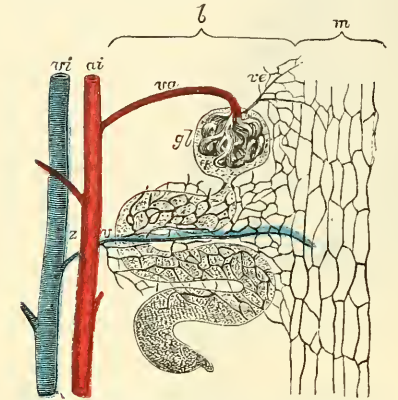
The *venæ rectæ* are branches from the plexuses at the apices of the medullary



pyramids, formed by the terminations of the arteriolæ rectæ. They pass outwards in a straight course between the tubes of the medullary structure, and joining, as above stated, the venæ interlobulares, form the proper renal veins (figs. 661, 662, *f*).

These vessels, *venæ propriae renales*, accompany the arteries of the same name, running along the entire length of the sides of the pyramids; and, having

FIG. 663.—Diagrammatic representation of the blood-vessels in the substance of the cortex of the kidney.



*m.* Region of the medullary ray. *b.* Region of the tortuous portion of the tubules. *ai.* Arteria interlobularis. *vi.* Vena interlobularis. *va.* Vas afferens. *gl.* Glomerulus. *ve.* Vas efferens. *vz.* Venous twig of the interlobularis.—(From Ludwig, in Stricker's 'Handbook'.)

received in their course the efferent vessels from the Malpighian bodies in the cortical structure adjacent, quit the kidney substance to enter the sinus. In this cavity they inosculate with the corresponding veins from the outer pyramids to form the *renal vein*, which emerges from the kidney at the hilum and opens into the inferior vena cava; the left being longer than the right, from having to cross in front of the abdominal aorta.

*Nerves of the Kidney.*—The nerves of the kidney, although small, are about fifteen in number. They have small ganglia developed upon them, and are derived from the renal plexus, which is formed by branches from the solar plexus, the lower and outer part of the semilunar ganglion and aortic plexus, and from the lesser and smallest splanchnic nerves. They communicate with the spermatic plexus, a circumstance which may explain the occurrence of pain in the testicle in affections of

the kidney. So far as they have been traced, they seem to accompany the renal artery and its branches, but their exact mode of termination is not known.

The *lymphatics* consist of a superficial and deep set which terminate in the lumbar glands.

*Connective tissue, or intertubular stroma.*—Although the tubules and vessels are closely packed, a certain small amount of connective tissue, continuous with the capsule, binds them firmly together. This tissue was first described by Goodsir, and subsequently by Bowman. Ludwig and Zawarykin have observed distinct fibres passing around the Malpighian bodies; and Henle has seen them between the straight tubes composing the medullary structure.

*Surface Form.*—The kidneys, being situated at the back part of the abdominal cavity and deeply placed, cannot be felt unless enlarged or misplaced. They are situated on the confines of the epigastric and umbilical regions internally, with the hypochondriac and lumbar regions externally. The left is somewhat higher than the right. According to Morris, the position of the kidney may be thus defined: *Anteriorly.* '1. A horizontal line through the umbilicus is below the lower edge of each kidney. 2. A vertical line carried upwards to the costal arch from the middle of Poupart's ligament has one third of the kidney to its outer side, and two thirds to its inner side, i.e. between this line and the median line of the body.' In adopting these lines it must be borne in mind that the axes of the kidneys are not vertical, but oblique, and if continued upwards would meet about the ninth dorsal vertebra. *Posteriorly.* The upper end of the left kidney would be defined by a line drawn horizontally outwards from the spinous process of the eleventh dorsal vertebra, and its lower end by a point two inches above the iliac crest. The right kidney would be half to three-quarters of an inch lower. Morris lays down the following rules for indicating the position of the kidney on the posterior surface of the body: '1. A line parallel with, and one inch from, the spine between the lower edge of the tip of the spinous process of the eleventh dorsal vertebra, and the lower edge of the spinous process of the third lumbar vertebra. 2. A line from the top of this first line outwards at right angles to it for  $2\frac{3}{4}$  inches. 3. A line from the lower end of the first transversely outwards for  $2\frac{3}{4}$  inches. 4. A line parallel to the first, and connecting the outer extremities of the second and third lines just described.'



The hilum of the kidney lies about two inches from the middle line of the back at the level of the spinous process of the first lumbar vertebra.

*Surgical Anatomy.*—The kidney is embedded in a large quantity of loose fatty tissue, and is only partially covered by peritoneum; hence rupture of this organ is not nearly so serious an accident as rupture of the liver or spleen, since the extravasation of blood and urine which follows is outside the peritoneal cavity. Occasionally the kidney may be bruised by blows in the loin, or by being compressed between the lower ribs and the ilium when the body is violently bent forwards. This is followed by a little transient hæmaturia, which, however, speedily passes off. Occasionally, when rupture involves the pelvis of the kidney or the commencement of the ureter, this duct may become blocked, and hydro-nephrosis follow.

The loose cellular tissue around the kidney may be the seat of suppuration, constituting *perinephritic abscess*. This may be due to injury, to disease of the kidney itself, or to extension of inflammation from neighbouring parts. The abscess may burst into the pleura, constituting empyema; into the colon or bladder; or may point externally in the groin or loin. Tumours of the kidney, of which perhaps sarcoma, in children, is the most common, may be recognised by their position and fixity; by the resonant colon lying in front of it; by their not moving with respiration; and by their rounded outline not presenting a notched anterior margin like the spleen, with which they are most likely to be confounded. The examination of the kidney should be bimanual; that is to say, one hand should be placed in the flank and firm pressure made forwards, while the other hand is buried in the abdominal wall, over the situation of the organ. Manipulation of the kidney frequently produces a peculiar sickening sensation, with sometimes faintness.

The kidney is mainly held in position by the mass of fatty matter in which it is embedded. If this fatty matter is loose or lax or is absorbed, the kidney may become movable and may give rise to great pain. This condition occurs, therefore, in badly nourished people, or in those who have become emaciated from any cause, and is more common in women than in men. It must not be confounded with the *floating kidney*: this is a congenital condition due to the development of a meso-nephron, which permits the organ to move more or less freely. The two conditions cannot, however, be distinguished until the abdomen is opened or the kidney explored from the loin.

The kidney has, of late years, been frequently the seat of surgical interference. It may be exposed for exploration or the evacuation of pus (nephrotomy); it may be incised for the removal of stone (nephro-lithotomy); it may be sutured when movable or floating (nephrorraphy); or it may be removed (nephrectomy).

The kidney may be exposed either by a lumbar or abdominal incision. The lumbar operation is the one which is generally adopted, unless in cases of very large tumours, or of wandering kidneys, with a loose meso-nephron, on account of the advantages which it possesses of not opening the peritoneum, and affording admirable drainage. It may be performed either by an oblique, a vertical, or a transverse incision. Perhaps the preferable, as affording the best means for exploring the whole surface of the kidney, is an incision from the tip of the last rib, backwards to the edge of the Erector spinæ. This incision must not be quite parallel to the rib, but its posterior end must be at least three-quarters of an inch below it, lest the pleura be wounded. This cut is quite sufficient for an exploration of the organ. Should it require removal, a vertical incision can be made downwards to the crest of the ilium, along the outer border of the Quadratus lumborum. The structures divided are, the skin, the superficial fascia with the cutaneous nerves, the deep fascia, the posterior border of the External oblique muscle of the abdomen, and the outer border of the Latissimus dorsi; the Internal oblique and the posterior aponeurosis of the Transversalis muscle; the outer border of the Quadratus lumborum, and the deep layer of the lumbar fascia, and the transversalis fascia. The fatty tissue around the kidney is now exposed to view and must be separated by the fingers, or a director, in order to reach the kidney.

The abdominal operation is best performed by an incision in the linea semilunaris on the side of the kidney to be removed, as recommended by Langenbuch. The incision is made of varying length according to the size of the kidney; its mid-point should be on a level with the umbilicus. The abdominal cavity is opened. The intestines are then held aside, and the outer layer of the meso-colon opened, so that the fingers can be introduced behind the peritoneum and the renal vessels sought for. These are then to be ligatured: if tied separately, care must be taken to ligature the artery first. The kidney must now be enucleated, and the vessels and ureter divided, and the latter tied, or if thought necessary stitched to the edge of the wound.

## THE URETERS

The **Ureters** are the two tubes which conduct the urine from the kidneys into the bladder. They commence within the sinus of the kidney, by a number of short truncated branches, the *calices* or *infundibula*, which unite, either directly or indirectly, to form a dilated pouch, the *pelvis*, from which the ureter, after passing through the hilum of the kidney, descends to the bladder. The *calices*

are cup-like tubes encircling the apices of the Malpighian pyramids; but inasmuch as one calyx may include two or even more papillæ, their number is generally less than the pyramids themselves, the former being from seven to thirteen, whilst the latter vary from eight to eighteen. These calices converge into two or three tubular divisions, which by their junction form the *pelvis*, or dilated portion of the ureter. The portion last mentioned, where the *pelvis* merges into the ureter proper, is found opposite the spinous process of the first lumbar vertebra, in which situation it is accessible behind the peritoneum (see fig. 610, page 985).

The *ureter proper* is a cylindrical, membranous tube, about sixteen inches in length, and of the diameter of a goose-quill, extending from the *pelvis* of the kidney to the bladder. Its course is obliquely downwards and inwards through the lumbar region into the cavity of the *pelvis*, where it passes downwards, forwards, and inwards across that cavity to the base of the bladder, into which it then opens by a constricted orifice, after having passed obliquely for nearly an inch between its muscular and mucous coats.

**Relations.**—In its course it rests upon the Psoas muscle, being covered by the peritoneum, and crossed obliquely, from within outwards, by the spermatic vessels; the right ureter lying close to the outer side of the inferior vena cava. Opposite the first piece of the sacrum it crosses either the common or external iliac artery, lying behind the ileum on the *right* side and the sigmoid flexure of the colon on the *left*. In the *pelvis* it enters the posterior false ligament of the bladder, below the obliterated hypogastric artery, the vas deferens in the male passing between it and the bladder. In the female the ureter passes along the sides and cervix of the uterus and upper part of the vagina. At the base of the bladder it is situated about two inches from its fellow: lying, in the male, about an inch and a half behind the orifice of the urethra, at the posterior angle of the trigone.

**Structure.**—The *ureter* is composed of three coats—a fibrous, muscular, and mucous.

The *fibrous coat* is the same throughout the entire length of the duct, being continuous at one end with the capsule of the kidney at the floor of the sinus; whilst at the other it is lost in the fibrous structure of the bladder.

In the *pelvis* of the kidney the muscular coat consists of two layers, longitudinal and circular; the longitudinal fibres become lost upon the sides of the papillæ at the extremities of the calices; the circular fibres may be traced surrounding the medullary structure in the same situation. In the ureter proper the muscular fibres are very distinct, and are arranged in three layers—an external longitudinal, a middle circular, and an internal layer, less distinct than the other two, but having a general longitudinal direction. According to Kölliker, this internal layer is only found in the neighbourhood of the bladder.

The *mucous coat* is smooth, and presents a few longitudinal folds which become effaced by distension. It is continuous with the mucous membrane of the bladder below, whilst it is prolonged over the papillæ of the kidney above. Its epithelium is of a peculiar character, and resembles that found in the bladder. It is known by the name of 'transitional' epithelium (see fig. 13, page 15). It consists of several layers of cells, of which the innermost—that is to say, the cells in contact with the urine—are quadrilateral in shape, with a concave margin on their outer surface, into which fits the rounded end of the cells of the second layer. These, the intermediate cells, more or less resemble columnar epithelium, and are pear-shaped, with a rounded internal extremity which fits into the concavity of the cells of the first layer, and a narrow external extremity which is wedged in between the cells of the third layer. The external or third layer consists of conical or oval cells varying in number in different parts, and presenting processes which extend down into the basement membrane.

The *arteries* supplying the ureter are branches from the renal, spermatic, internal iliac, and inferior vesical.



The *nerves* are derived from the inferior mesenteric, spermatic, and pelvic plexuses.

## SUPRARENAL CAPSULES

The **Suprarenal Capsules** were formerly classified together with the spleen, thymus, and thyroid, under the head of 'ductless glands,' as they have no excretory duct. They are two small flattened globular bodies, of a yellowish colour, situated at the back part of the abdomen, behind the peritoneum, and immediately in front of the upper part of each kidney; hence their name. The right one is somewhat triangular in shape, bearing a resemblance to a cocked hat; the left is more semilunar, and usually larger and higher than the right. They vary in size in different individuals, being

FIG. 664.—Vertical section of the suprarenal capsule. (From Elberth, in Stricker's 'Manual.')

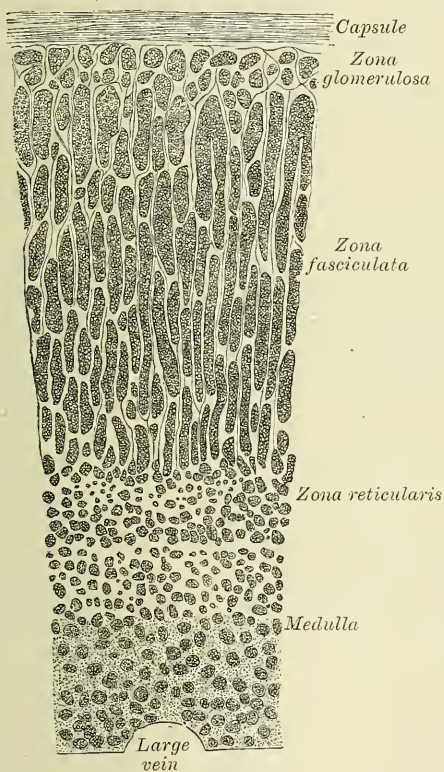


FIG. 665.—Minute structure of suprarenal capsule.

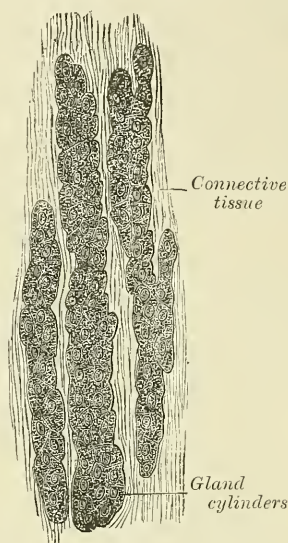
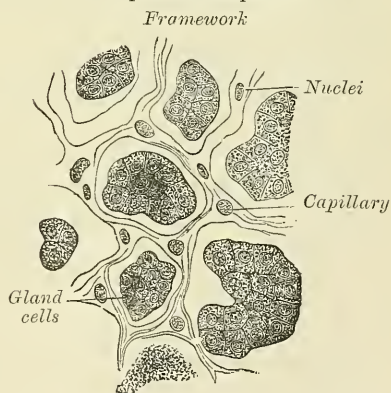


FIG. 666.—Minute structure of suprarenal capsule.



sometimes so small as to be scarcely detected: their usual size is from an inch and a quarter to nearly two inches in length, rather less in width, and from two to three lines in thickness. Their average weight is about a drachm each.

**Relations.**—The relations of the suprarenal capsules differ on the two sides of the body. The *right suprarenal* is roughly triangular in shape, its angles pointing upwards, downwards, and outwards. It presents two surfaces for examination, an anterior and posterior. The *anterior surface* presents two areas, separated by a furrow: one area, occupying about one third of the whole surface, is situated above and internally; it is depressed, uncovered by peritoneum, and is in contact in front with the under surface of the right lobe of the liver, and



along its inner border with the inferior vena cava (Rolleston); the remaining area is elevated, and is divided into a non-peritoneal portion, in contact with the hepatic flexure of the duodenum, and a portion covered by the peritoneum forming the hepato-renal fold. The *posterior surface*, in like manner, is divided into two areas separated by a ridge, which corresponds to the depression on the anterior surface, and which fits into the groove between the kidney and the right crus of the Diaphragm; of these areas, the inner one rests on the right crus of the Diaphragm, and the outer on the upper, inner, and anterior part of the right kidney. The *left suprarenal* is crescentic in shape, and presents an inner border which is convex, and an outer which is concave; its upper border is pointed, and its lower rounded. Its *anterior surface* presents two areas: an upper one, covered by the peritoneum forming the lesser sac, which separates it from the cardiac end of the stomach and to a small extent from the superior extremity of the spleen; and a lower one, which is in contact with the pancreas and splenic artery, and is therefore not in contact with the peritoneum. Its *posterior surface* presents a vertical ridge, which divides it into two areas. The ridge lies in the sulcus between the kidney and crus of the Diaphragm, whilst the area on either side of it lies on these parts respectively; the outer area, which is thin, resting on the kidney, and the inner and smaller area resting on the left crus of the Diaphragm. The surface of the suprarenal gland is surrounded by areolar tissue containing much fat, and closely invested by a thin fibrous coat, which is difficult to remove, on account of the numerous fibrous processes and vessels which enter the organ through the furrows on its anterior surface and base.

Small accessory suprarenals are often to be found in the connective tissue around the suprarenals. The smaller of these, on section, show a uniform surface, but in some of the larger a distinct medulla can be made out.

**Structure.**—On making a perpendicular section, the gland is seen to consist of two substances—external or cortical, and internal or medullary. The former, which constitutes the chief part of the organ, is of a deep yellow colour. The medullary substance is soft, pulpy, and of a dark brown or black colour, whence the name *atriliary capsules* formerly given to these organs. In the centre is often seen a space, not natural, but formed by the breaking down after death of the medullary substance.

The **cortical portion** consists chiefly of narrow columnar masses, placed perpendicularly to the surface. This arrangement is due to the disposition of the capsule, which sends into the interior of the gland processes, passing in vertically and communicating with each other by transverse bands, so as to form spaces which open into each other. These spaces are of slight depth near the surface of the organ, so that there the section somewhat resembles a net; this is termed the *zona glomerulosa*; but they become much deeper or longer further in, so as to resemble pipes or tubes placed endwise, the *zona fasciculata*. Still deeper down, near the medullary part, the spaces become again of small extent; this is named the *zona reticularis*. These processes, or trabeculæ, derived from the capsule and forming the framework of the spaces, are composed of fibrous connective tissue, with longitudinal bundles of unstriped muscular fibres. Within the interior of the spaces are contained groups of polyhedral cells, which are finely granular in appearance, and contain a spherical nucleus, and not unfrequently fat molecules. These groups of cells do not entirely fill the spaces in which they are contained, but between them and the trabeculæ of the framework is a channel, which is believed to be a lymph path or sinus, and which communicates with certain passages between the cells composing the group. The lymph path is supposed to open into a plexus of efferent lymphatic vessels which are contained in the capsule.

In the **medullary portion**, the fibrous stroma seems to be collected together into a much closer arrangement, and forms bundles of connective tissue which are loosely applied to the large plexus of veins of which this part of the organ

mainly consists. In the interstices lie a number of cells compared by Frey to those of columnar epithelium. They are coarsely granular, do not contain any fat molecules, and some of them are branched. Luschka has affirmed that these branches are connected with the nerve-fibres of a very intricate plexus which is found in the medulla: this statement has not been verified by other observers, for the tissue of the medullary substance is less easy to make out than that of the cortical, owing to its rapid decomposition.

The numerous arteries which enter the suprarenal bodies, from the sources mentioned below, penetrate the cortical part of the gland, where they break up into capillaries in the fibrous septa, and these converge to the very numerous veins of the medullary portion, which are collected together into the suprarenal vein, which usually emerges as a single vessel from the centre of the gland.

The *arteries* supplying the suprarenal capsules are numerous and of large size; they are derived from the aorta, the phrenic, and the renal; they subdivide into numerous minute branches previous to entering the substance of the gland.

The *suprarenal vein* returns the blood from the medullary venous plexus, and receives several branches from the cortical substance; it opens on the right side into the inferior vena cava, on the left side into the renal vein.

The *lymphatics* terminate in the lumbar glands.

The *nerves* are exceedingly numerous: they are found chiefly, if not entirely, in the medulla, and are derived from the solar and renal plexuses, and, according to Bergmann, from the phrenic and pneumogastric nerves. They have numerous small ganglia developed upon them, from which circumstance the organ has been conjectured to have some function in connection with the sympathetic nervous system.

## THE PELVIS

The **cavity of the pelvis** is that part of the general abdominal cavity which is below the level of the linea ilio-pectinea and the promontory of the sacrum.

**Boundaries.**—It is bounded, behind, by the sacrum, the coccyx, the Pyri-formis muscle, and the great sacro-sciatic ligaments; in front and at the sides, by the ossa pubis and ischia, covered by the Obturator muscles; above, it communicates with the cavity of the abdomen; and below, the outlet is closed by the triangular ligament, the Levatores ani and Coccygei muscles, and the visceral layer of the pelvic fascia, which is reflected from the wall of the pelvis on to the viscera.

**Contents.**—The viscera contained in this cavity are the urinary bladder, the rectum, some of the generative organs peculiar to each sex, and some convolutions of the small intestines: they are partially covered by the peritoneum, and supplied with blood-vessels, lymphatics and nerves.

## THE BLADDER

The **bladder** is the reservoir for the urine. It is a musculo-membranous sac, situated in the pelvis, behind the pubes, and in front of the rectum in the male; the cervix uteri and vagina intervening between it and that intestine in the female. The shape, position, and relations of the bladder are greatly influenced by age, sex, and the degree of distension of the organ. *During infancy* it is conical in shape, and projects above the upper border of the ossa pubis into the hypogastric region. *In the adult*, when quite empty and contracted, it is cup-shaped and on vertical median section its cavity, with the adjacent portion of the urethra, presents a Y-shaped cleft, the stem of the Y corresponding to the urethra. It is placed deeply in the pelvis, flattened from before backwards, and reaches as high as the upper border of the symphysis pubis. When slightly distended, it has a rounded form, and is still contained within the pelvic cavity; and when greatly distended it is ovoid in shape, rising into the abdominal cavity, and often extending nearly as high as the umbilicus. It is larger in its vertical diameter than

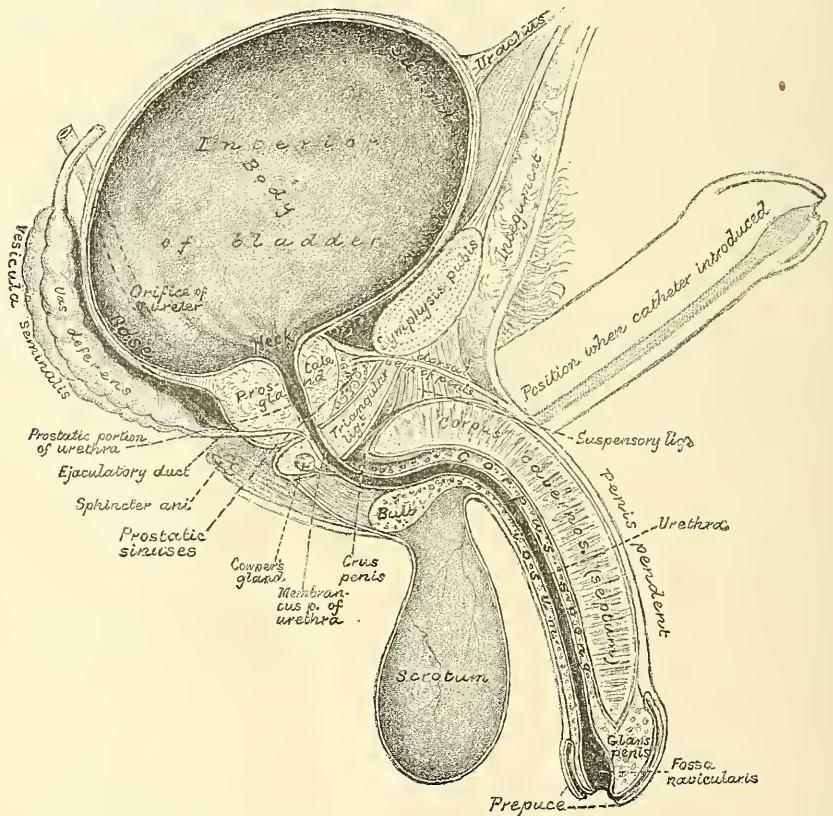


from side to side, and its long axis is directed from above obliquely downwards and backwards, in a line directed from some point between the symphysis pubis and umbilicus (according to its distension) to the end of the coccyx. The bladder, when distended, is slightly curved forwards towards the anterior wall of the abdomen, so as to be more convex behind than in front. In the female it is larger in the transverse than in the vertical diameter, and its capacity is said to be greater than in the male.\* When moderately distended, it measures about five inches in length, and three inches across, and the ordinary amount which it contains is about a pint.

The bladder is divided for purposes of description into a superior, an antero-inferior, a posterior and two lateral surfaces.

The **superior** or **abdominal surface** is entirely free, and is covered throughout by peritoneum. It looks almost directly upwards into the abdominal cavity and

FIG. 667.—Vertical section of bladder, penis, and urethra.



is in relation with the small intestine and sometimes with the sigmoid flexure, and in the female, with the uterus. To its summit is attached the *urachus*.

The *urachus* is the obliterated remains of a tubular canal which exists in the embryo, and connects the cavity of the bladder with a membranous sac placed external to the abdomen, opposite the umbilicus, called the *allantois*. It passes upwards, from the apex of the bladder between the transversalis fascia and peritoneum, to the umbilicus, becoming thinner as it ascends. It is composed of fibrous tissue, mixed with plain muscular fibres. On each side of it is placed a fibrous cord, the obliterated portion of the hypogastric artery, which, passing

\* According to Henle, the bladder is considerably smaller in the female than in the male.



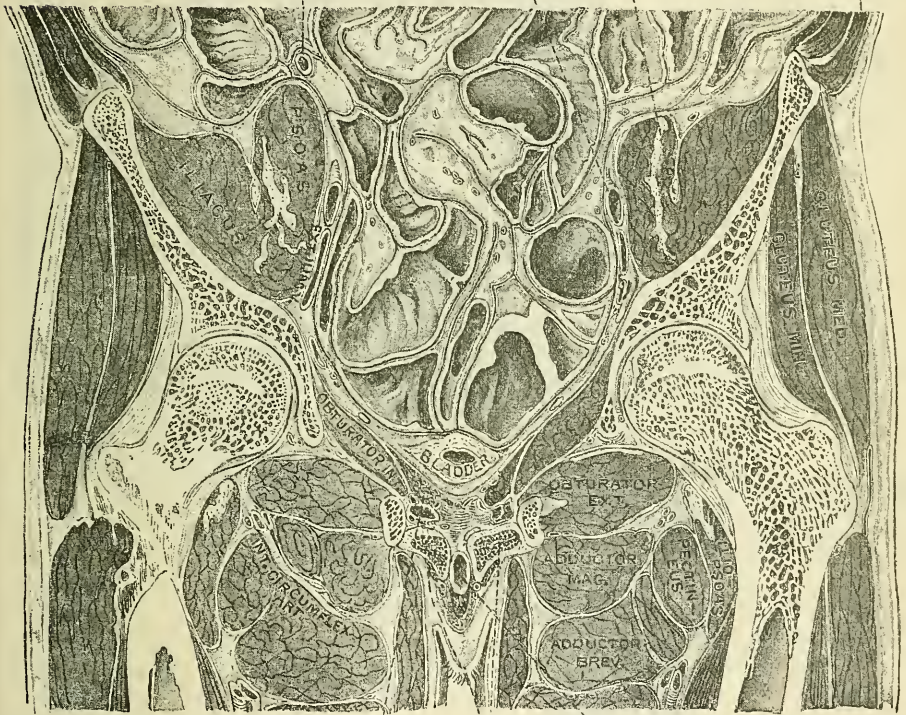
upwards from the side of the bladder, approaches the urachus above its summit. In the infant, at birth, it is occasionally found pervious, so that the urine escapes at the umbilicus, and calculi have been found in its canal.

The **antero-inferior** or **pubic surface** is entirely uncovered by peritoneum, and looks downwards and forwards to the symphysis pubis, to which it is connected by loose cellular tissue. It is also in relation with the anterior part of the Levatores ani and Obturatores interni, and, when distended, with the anterior wall of the abdomen. It is covered by recto-vesical fascia, and at its lower part is attached by two strong bands of this fascia, the *anterior true ligaments*, to the back of the pubic bones.

The **posterior** or **rectal surface** is partly covered by peritoneum and partly uncovered. The upper portion to within about an inch and a half of the prostate

FIG. 668.—Frontal section of the lower part of the abdomen. Viewed from the front. (Braune.)

Vermiform appendix      External iliac artery      Anterior crural nerve      External oblique muscle



Profunda vessels      Levator ani      Corpora cavernosa      Urethra

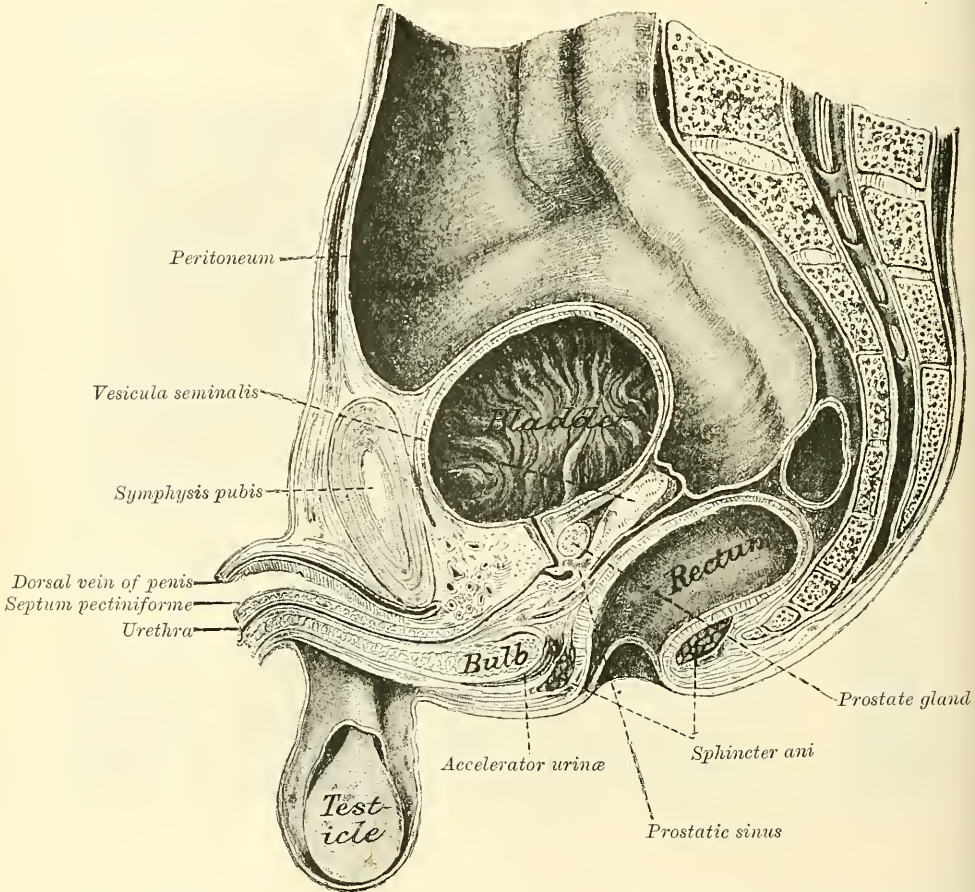
in the male is covered by the recto-vesical pouch of peritoneum; in the female to a similar extent by the utero-vesical pouch. The lower part is in direct contact with the anterior wall of the rectum and the vesiculæ seminales and vasa deferentia in the male.

The portion of the bladder in relation with the rectum corresponds to a triangular space bounded, in front, by the prostate gland; behind, by the recto-vesical fold of the peritoneum; and on each side, by the vesicula seminalis and vas deferens. It is separated from direct contact with the rectum by the recto-vesical fascia. When the bladder is very full, the peritoneal fold is raised with it, and the distance between its reflection and the anus is about four inches; but this distance is much diminished when the bladder is empty and contracted. In

the female, the base of the bladder lies in contact with the lower part of the cervix uteri, is adherent to the anterior wall of the vagina, and separated from the upper part of the anterior surface of the cervix uteri by a fold of the peritoneum.

The **lateral surfaces** are covered behind and above by peritoneum, which extends as low as the level of the obliterated hypogastric artery; below and in front of this, these surfaces are uncovered by peritoneum, and are separated from the Levatores ani muscles and walls of the pelvis by a quantity of loose areolar tissue containing fat. In front this surface is connected to the recto-vesical fascia by a broad expansion on either side, the *lateral true ligaments*. Separating these ligaments and the anterior true ligaments from the peritoneum is a space containing a considerable amount of loose cellular tissue. It is known as the *cavum*

FIG. 669.—Vertical median section of the male pelvis. (Henle.)



*Retzii*. The vas deferens crosses the hinder part of the lateral surface obliquely, and is itself crossed by the ureter, which enters the bladder at the junction of the posterior and lateral surfaces, about two inches above the prostate.

The, so-called, *neck (cervix) of the bladder* is the point of commencement of the urethra; there is, however, no tapering part, which would constitute a true neck, but the bladder suddenly contracts to the opening of the urethra. In the male its direction is oblique in the erect posture, and it is surrounded by the prostate gland. In the female its direction is obliquely downwards and forwards.

**Ligaments.**—The bladder is retained in its place by ligaments, which are divided into true and false. The true ligaments are five in number: two anterior, two



lateral, and the urachus. The false ligaments, also five in number, are formed by folds of the peritoneum.

The *anterior ligaments (pubo-prostatic)* extend from the back of the ossa pubis, one on each side of the symphysis, to the front of the neck of the bladder, over the upper surface of the prostate gland. These ligaments are formed by the recto-vesical fascia, and contain a few muscular fibres prolonged from the bladder.

The *lateral ligaments*, also formed by the recto-vesical fascia, are broader and thinner than the preceding. They are attached to the lateral parts of the prostate, and to the sides of the base of the bladder.

The *urachus* is the fibro-muscular cord already mentioned, extending between the summit of the bladder and the umbilicus. It is broad below, at its attachment to the bladder, and becomes narrower as it ascends.

The *false ligaments of the bladder* are two posterior, two lateral, and one superior.

The *two posterior* pass forwards, in the male, from the sides of the rectum; in the female, from the sides of the uterus, to the posterior and lateral aspect of the bladder: they form the lateral boundaries of the recto-vesical fold of the

FIG. 670.—Superficial layer of the epithelium of the bladder. Composed of polyhedral cells of various sizes, each with one, two, or three nuclei. (Klein and Noble Smith.)

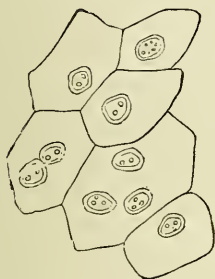
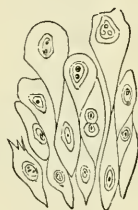

FIG. 671.—Deep layers of epithelium of bladder, showing large club-shaped cells above, and smaller, more spindle-shaped cells below—each with an oval nucleus. (Klein and Noble Smith.)



peritoneum, and contain the obliterated hypogastric arteries, and the ureters, together with vessels and nerves.

The *two lateral ligaments* are reflections of the peritoneum, from the iliac fossæ to the sides of the bladder.

The *superior ligament (ligamentum suspensorium)* is the prominent fold of peritoneum extending from the summit of the bladder to the umbilicus. It covers the urachus and the obliterated hypogastric arteries.

**Structure.**—The bladder is composed of four coats—serous, muscular, sub-mucous, and mucous.

The *serous coat* is partial, and derived from the peritoneum. It invests the superior surface and the upper part of the posterior and lateral surfaces, and is reflected from them on to the abdominal and pelvic walls.

The *muscular coat* consists of three layers of unstriated muscular fibre: an external layer, composed of fibres having for the most part a longitudinal arrangement; a middle layer, in which the fibres are arranged, more or less, in a circular manner; and an internal layer, in which the fibres have a general longitudinal arrangement.

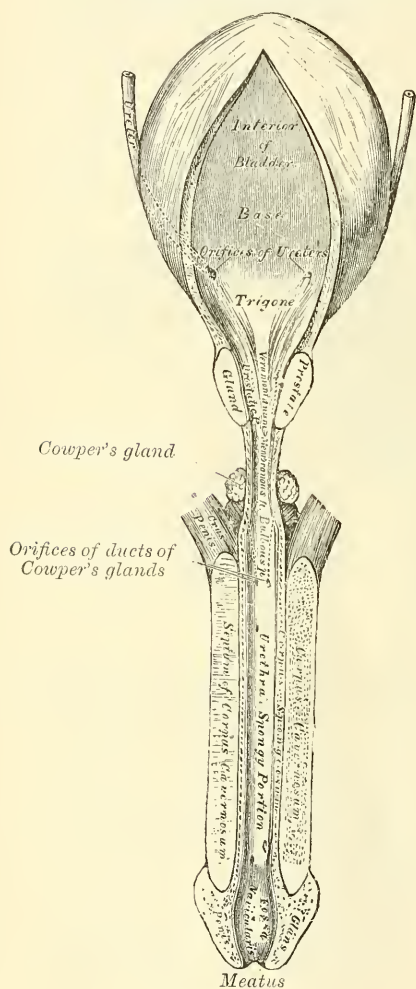
The *fibres of the external longitudinal layer* arise from the posterior surface of the body of the os pubis in both sexes (*musculi pubo-vesicalis*), and in the male from the adjacent part of the prostate gland and its capsule. They pass, in a more or less longitudinal manner, up the anterior surface of the bladder, over its apex, and then descend along its posterior surface to its base, where they become attached to the prostate in the male, and to the front of the vagina in the female.



At the sides of the bladder the fibres are arranged obliquely and intersect one another. This layer has been named the *detrusor urinæ muscle*.

The fibres of the *middle circular layer* are very thin and irregularly scattered on the body of the organ, and though to some extent placed transversely to the long axis of the bladder, are for the most part arranged obliquely. Towards the lower part of the bladder, round the cervix and commencement of the urethra, they are disposed in a thick circular layer, forming the *sphincter vesicæ*, which is continuous with the muscular fibres of the prostate gland.

FIG. 672.—The bladder and urethra laid open. Seen from above.



The *internal longitudinal layer* is thin, and its fasciculi have a reticular arrangement, but with a tendency to assume for the most part a longitudinal direction.

Two bands of oblique fibres, originating behind the orifices of the ureters, converge to the back part of the prostate gland, and are inserted, by means of a fibrous process, into the middle lobe of that organ. They are the *muscles of the ureters*, described by Sir C. Bell, who supposed that during the contraction of the bladder they serve to retain the oblique direction of the ureters, and so prevent the reflux of the urine into them.

The *submucous coat* consists of a layer of areolar tissue, connecting together the muscular and mucous coats, and intimately united to the latter.

The *mucous coat* is thin, smooth, and of a pale rose colour. It is continuous through the ureters with the lining membrane of the uriniferous tubes, and below with that of the urethra. It is connected loosely to the muscular coat by a layer of areolar tissue, excepting at the trigone, where its adhesion is more close. The epithelium covering it is of the transitional variety, consisting of a superficial layer of polyhedral, flattened cells, each with one, two, or three nuclei; beneath these, a stratum of large club-shaped cells, with the narrow extremity directed downwards and wedged in between smaller spindle-shaped cells, containing an oval nucleus (figs. 602, 603).

*Objects seen on the inner surface.*—Upon the inner surface of the bladder are seen the orifices of the ureters, the trigone, and the commencement of the urethra.

*The orifices of the ureters.*—These are situated at the base of the trigone, being distant from each other about two inches; they are about an inch and a half from the base of the prostate and the commencement of the urethra.

The *trigonum vesicæ*, or *trigone vesical*, is a triangular smooth surface with the apex directed forwards, situated at the base of the bladder immediately behind the urethral orifice. It is paler in colour than the rest of the mucous membrane, and never presents any rugæ, even in the collapsed condition of the organ, owing to its intimate adhesion to the subjacent tissue. It is bounded at

each posterior angle by the orifices of the ureters, which are placed nearly two inches from each other, and about an inch and a half behind the orifice of the urethra, which forms the anterior angle of the trigone. Projecting from the lower and anterior part of the bladder, and reaching to the orifice of the urethra, is a slight elevation of mucous membrane, called the *wula vesicæ*. It is formed by a thickening of the submucous tissue.

The *arteries* supplying the bladder are the superior, middle, and inferior vesical in the male, with additional branches from the uterine and vaginal in the female. They are all derived from the anterior trunk of the internal iliac. The obturator and sciatic arteries also supply small visceral branches to the bladder.

The *veins* form a complicated plexus round the neck, sides, and base of the bladder, and terminate in the internal iliac vein.

The *lymphatics* accompany the blood-vessels, passing through the glands surrounding them.

The *nerves* are derived from the pelvic plexus of the sympathetic and from the third and the fourth sacral nerves; the former supplying the upper part of the organ, the latter its base and neck. According to F. Darwin the sympathetic fibres have ganglia connected with them, which send branches to the vessels and muscular coat.

*Surface Form.*—The surface form of the bladder varies with its degree of distension and under other circumstances. In the young child it is represented by a conical figure, the apex of which, even when the viscus is empty, is situated in the hypogastric region, about an inch above the level of the symphysis pubis. In the adult, when the bladder is empty, its apex does not reach above the level of the upper border of the symphysis pubis, and the whole organ is situated in the pelvis; the neck, in the male, corresponding to a line drawn horizontally backwards, through the symphysis a little below its middle. As the bladder becomes distended it gradually rises out of the pelvis into the abdomen and forms a swelling in the hypogastric region, which is perceptible to the hand, as well as to percussion. In extreme distension it reaches into the umbilical region. Under these circumstances it is closely applied to the abdominal wall, without the intervention of peritoneum, so that it can be tapped by an opening in the middle line just above the symphysis pubis, without any fear of wounding the serous membrane. When the rectum is distended, the prostatic portion of the urethra is elongated and the bladder lifted out of the pelvis and the peritoneum pushed upwards. Advantage is taken of this in performing the operation of suprapubic cystotomy. The rectum is distended by an indiarubber bag, which is introduced into this cavity empty, and then filled with ten or twelve ounces of water. If now the bladder is injected with about half a pint of some antiseptic fluid, it will appear above the pubes plainly perceptible to the sight and touch. The peritoneum will be pushed out of the way, and an incision three inches long may be made in the linea alba from the symphysis pubis upwards without any great risk of wounding the peritoneum.

When distended the bladder can be felt in the male, from the rectum, behind the prostate, and fluctuation can be perceived by a bimanual examination, one finger being introduced into the rectum and the distended bladder tapped on the front of the abdomen with the finger of the other hand. This portion of the bladder, that is, the portion felt in the rectum by the finger, is also uncovered by peritoneum, and the bladder may here be punctured from the rectum, in the middle line, without risk of wounding the serous membrane.

*Surgical Anatomy.*—A defect of development, in which the bladder is implicated, is known under the name of *extroversion of the bladder*. In this condition the lower part of the abdominal wall and the anterior wall of the bladder are wanting, so that the posterior surface of the bladder presents on the abdominal surface, and is pushed forwards by the pressure of the viscera within the abdomen, forming a red vascular tumour, on which the openings of the ureters are visible. The penis, except the glans, is rudimentary and is cleft on its dorsal surface, exposing the floor of the urethra, a condition known as *epispadias*. The pelvic bones are also arrested in development (see page 271).

The bladder may be ruptured by violence applied to the abdominal wall, when the viscus is distended, without any injury to the bony pelvis, or it may be torn in cases of fracture of the pelvis. The rupture may be either intraperitoneal or extraperitoneal, that is, may implicate the superior surface of the bladder in the former case, or one of the other surfaces in the latter. Rupture of the antero-inferior surface alone is, however, very rare. Until recently intraperitoneal rupture was uniformly fatal, but now abdominal section and suturing the rent with Lembert's suture is resorted to, with a very considerable amount of success. The sutures are inserted only through the peritoneal and muscular coats in such a way as to bring the serous surfaces at the margins of the wound into apposition, and one is



inserted just beyond each end of the wound. The bladder should be tested as to whether it is water-tight before closing the external wound.

The muscular coat of the bladder undergoes hypertrophy in cases in which there is any obstruction to the flow of urine. Under these circumstances the bundles of which the muscular coat consists become much increased in size, and, interlacing in all directions, give rise to what is known as the *fasciculated bladder*. Between these bundles of muscular fibres the mucous membrane may bulge out, forming sacculi, constituting the *sacculated bladder*, and in these little pouches phosphatic concretions may collect, forming *encysted calculi*. The mucous membrane is very loose and lax, except over the trigone, to allow of the distension of the viscus.

Various forms of tumour have been found springing from the wall of the bladder. The innocent tumours are the papilloma and the mucous polypus arising from the mucous membrane; the fibrous, from the submucous tissue; and the myoma, originating in the muscular tissue; and, very rarely, dermoid tumours, the exact origin of which it is difficult to explain. Of the malignant tumours, epithelioma is the most common, but sarcomata are occasionally found in the bladder of children.

Puncture of the bladder may be performed either above the symphysis pubis or through the rectum, in both cases without wounding the peritoneum. The former plan is generally to be preferred, since in puncture by the rectum a permanent fistula may be left from abscess forming between the rectum and the bladder; or pelvic cellulitis may be set up; moreover, it is exceedingly inconvenient to keep a cannula in the rectum. In some cases, in performing this operation the recto-vesical pouch of peritoneum has been wounded, inducing fatal peritonitis. The operation, therefore, has been almost completely abandoned.

### THE MALE URETHRA

The **urethra in the male** extends from the neck of the bladder to the meatus urinarius. It presents a double curve in the flaccid state of the penis, but in the erect state it forms only a single curve, the concavity of which is directed upwards (fig. 667). Its length varies from eight to nine inches; and it is divided into three portions, the *prostatic*, *membranous*, and *spongy*, the structure and relations of which are essentially different. Except during the passage of the urine or semen, the urethra is a mere transverse cleft or slit, with its upper and under surfaces in contact. At the orifice of the urethra at the end of the penis, the slit is vertical, and in the prostatic portion somewhat arched.

The **Prostatic portion** is the widest and most dilatable part of the canal. It passes through the prostate gland, from its base to the apex, lying nearer its upper than its lower surface. It is about an inch and a quarter in length; the form of the canal is spindle-shaped, being wider in the middle than at either extremity, and narrowest in front, where it joins the membranous portion. A transverse section of the canal as it lies in the prostate is horseshoe in shape, the convexity being directed upwards (fig. 673).

Upon the floor of the canal is a narrow longitudinal ridge, the *verumontanum*, or *caput gallinaginis*, formed by an elevation of the mucous membrane and its subjacent tissue. It is eight or nine lines in length, and a line and a half in height; and contains, according to Kobelt, muscular and erectile tissues. When distended, it may serve to prevent the passage of the semen backwards into the bladder. On each side of the verumontanum is a slightly depressed fossa, the *prostatic sinus*, the floor of which is perforated by numerous apertures, the *orifices of the prostatic ducts*; the ducts of the middle lobe opening behind the verumontanum. At the fore part of the verumontanum, in the middle line, is a depression, the *sinus pocularis (vesicula prostatica)*; and upon or within its margins are the slit-like openings of the ejaculatory ducts. The sinus pocularis forms a *cul-de-sac* about a quarter of an inch in length, which runs upwards and backwards in the substance of the prostate beneath the middle lobe; its prominent upper wall partly forms the verumontanum. Its walls are composed of fibrous tissue, muscular fibres, and mucous membrane; and numerous small glands open on its inner surface. It has been called by Weber, who discovered it, the *uterus masculinus*, from its being developed from the united ends of the rudimentary Müllerian ducts, and therefore homologous with the uterus in the female.



The **Membranous portion of the urethra** extends between the apex of the prostate and the bulb of the corpus spongiosum. It is the narrowest part of the canal (excepting the orifice), and measures three-quarters of an inch along its upper, and half an inch along its lower surface, in consequence of the bulb projecting backwards beneath it. Its anterior concave surface is placed about an inch beneath the pubic arch, from which it is separated by the dorsal vessels and nerves of the penis, and some muscular fibres. Its posterior convex surface is separated from the rectum by a triangular space, which constitutes the perinæum. The membranous portion of the urethra perforates both the inferior and superior layers of the deep perineal fascia, and receives an investment from them. As it pierces the superior layer, the fibres around the opening are prolonged backwards over the posterior part of the membranous portion of the urethra, and as it pierces the inferior layer a similar prolongation takes place in the opposite direction, investing the anterior part of the membranous portion. It is also surrounded by the Compressor urethræ muscle.

The **Spongy portion** is the longest part of the urethra, and is contained in the corpus spongiosum. It is about six inches in length, and extends from the termination of the membranous portion to the meatus urinarius. Commencing just in front of the triangular ligament, it inclines downwards for a short distance; it then ascends for about half its length, and then, in the flaccid condition of the penis, it bends suddenly downwards. It is narrow, and of uniform size in the body of the penis, measuring about a quarter of an inch in diameter; being dilated behind, within the bulb; and again anteriorly within the glans penis, where it forms the *fossa navicularis*.

The *Bulbous portion* is a name given, in some descriptions of the urethra, to the posterior part of the spongy portion contained within the bulb.

The *meatus urinarius* is the most contracted part of the urethra; it is a vertical slit, about three lines in length, bounded on each side by two small labia.

The inner surface of the lining membrane of the urethra, especially on the floor of the spongy portion, presents the orifices of numerous mucous glands and follicles situated in the submucous tissue, and named the *glands of Littré*. They vary in size, and their orifices are directed forwards, so that they may easily intercept the point of a catheter in its passage along the canal. One of these lacunæ, larger than the rest, is situated on the upper surface of the fossa navicularis, about an inch and a half from the orifice; it is called the *lacuna magna*. Into the bulbous portion are found opening the ducts of Cowper's glands.

**Structure.**—The urethra is composed of a continuous mucous membrane, supported by a submucous tissue which connects it with the various structures through which it passes.

The *mucous coat* forms part of the genito-urinary mucous membrane. It is continuous with the mucous membrane of the bladder, ureters, and kidneys; externally, with the integument covering the glans penis; and is prolonged into the ducts of the glands which open into the urethra, viz. Cowper's glands and the prostate gland; and into the vasa deferentia and vesiculæ seminales, through the ejaculatory ducts. In the spongy and membranous portions the mucous membrane is arranged in longitudinal folds when the organ is contracted. Small papillæ are found upon it, near the orifice; and its epithelial lining is of the columnar variety, excepting near the meatus, where it is squamous.

The *submucous tissue* consists of a vascular erectile layer; outside which is a layer of unstripped muscular fibres, arranged in a circular direction, which separates the mucous membrane and submucous tissue from the tissue of the corpus spongiosum.

*Surgical Anatomy.*—The urethra may be ruptured by the patient falling astride of any hard substance and striking his perinæum, so that the urethra is crushed against the pubic arch. Bleeding will at once take place from the urethra, and this, together with the

bruising in the perinæum and the history of the accident, will at once point to the nature of the injury.

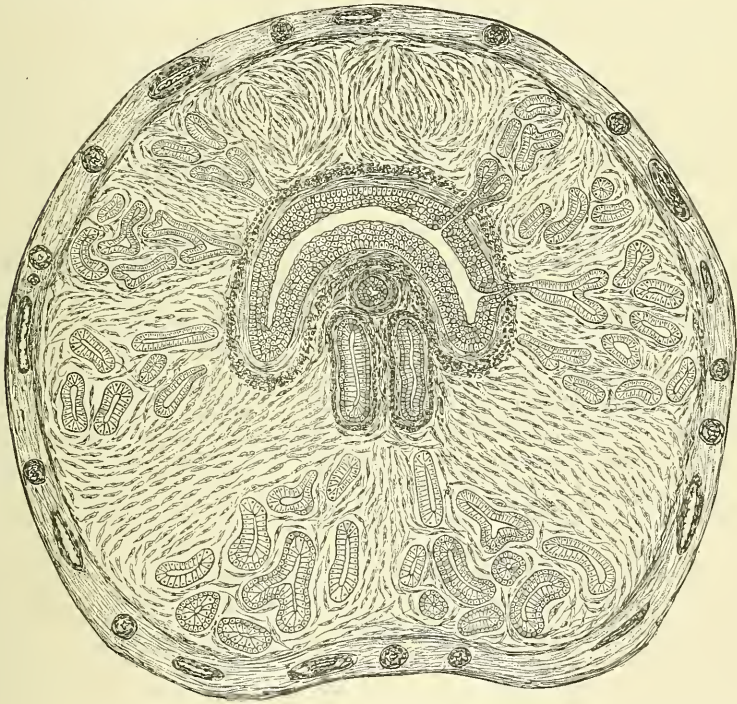The surgical anatomy of the urethra is of considerable importance, in connection with the passage of instruments into the bladder. Otis was the first to point out that the urethra is capable of great dilatability, so that, excepting through the external meatus, an instrument corresponding to 18 English gauge (29 French) can usually be passed without damage. The orifice of the urethra is not so dilatable and therefore frequently requires slitting. A recognition of this dilatability caused Bigelow to very considerably modify the operation of lithotrity and introduce that of litholapaxy. In passing catheters, especially fine ones, the point of the instrument should be kept as far as possible along the upper wall of the canal, as it is otherwise very liable to enter one of the lacunæ. Stricture of the urethra is a disease of very common occurrence, and is generally situated in the spongy portion of the urethra, most commonly in the bulbous portion, just in front of the membranous urethra, but in a very considerable number of cases in the penile or ante-scrotal part of the canal.

# MALE ORGANS OF GENERATION

## THE PROSTATE GLAND

**T**HE Prostate Gland (*πρωϊστρημι*, to stand before) is a pale, firm, glandular body, which is placed immediately in front of the neck of the bladder and around the commencement of the urethra. It is placed in the pelvic cavity, behind and below the symphysis pubis, posterior to the deep perineal fascia, and rests upon

FIG. 673—Transverse section of the prostate gland; showing the urethra, with the eminence of the caput gallinaginis; beneath it the sinus pocularis and ejaculatory ducts.



the rectum, through which it may be distinctly felt, especially when enlarged. In shape and size it resembles a chestnut.

Its *base* is directed upwards and backwards towards the neck of the bladder.

Its *apex* is directed downwards and forwards to the deep perineal fascia, which it touches.

Its *posterior surface* is smooth, marked by a slight longitudinal furrow, and rests on the rectum, to which it is connected by dense areolar tissue.

Its *anterior surface* is convex, and placed about three-quarters of an inch below the pubic symphysis, from which it is separated by a plexus of veins and a quantity of loose fat. It is connected to the pubic bone on either side by the pubo-prostatic ligaments.



The *lateral surfaces* are prominent, and are covered by the Levatores ani muscles.

It measures about an inch and a half in its transverse diameter at the base, an inch in its antero-posterior diameter, and an inch and a quarter in its vertical diameter. Its weight is about four and a half drachms. It is held in its position by the anterior ligaments of the bladder (*pubo-prostatic*); by the posterior layer of the deep perineal fascia, which invests the commencement of the membranous portion of the urethra and prostate gland; and by the anterior portion of the Levator ani muscle (*levator prostatae*), which passes down on each side from the symphysis pubis and anterior ligament of the bladder to the sides of the prostate.

The prostate consists of two lateral lobes and a middle lobe.

The *two lateral lobes* are of equal size, separated by a deep notch behind, and by a slight furrow upon their anterior and posterior surfaces, which indicates the bilobed condition of the organ in some animals.

The third, or *middle lobe*, is a small transverse band, occasionally a rounded or triangular prominence, placed between the two lateral lobes, at the posterior part of the organ. It lies immediately beneath the neck of the bladder, behind the commencement of the urethra, and above and between the ejaculatory ducts. Its existence is not constant; but it is occasionally found at an early period of life, as well as in adults, and in old age.

The prostate gland is perforated by the urethra and the ejaculatory ducts. The urethra usually lies about one-third nearer its anterior than its posterior surface; occasionally, the prostate surrounds only the lower three-fourths of this tube, and more rarely the urethra runs through the lower instead of the upper part of the gland. The ejaculatory ducts pass forwards obliquely through the lower part of the prostate, and open into the prostatic portion of the urethra.

**Structure.**—The prostate is enclosed in a thin but firm fibrous capsule, distinct from that derived from the posterior layer of the deep perineal fascia, and separated from it by a plexus of veins. Its substance is of a pale reddish-grey colour, of great density, and not easily torn. It consists of glandular substance and muscular tissue.

The muscular tissue, according to Kölliker, constitutes the proper stroma of the prostate: the connective tissue being very scanty, and simply forming thin trabeculae between the muscular fibres, in which the vessels and nerves of the gland ramify. The muscular tissue is arranged as follows: immediately beneath the fibrous capsule is a dense layer, which forms an investing sheath for the gland; secondly, around the urethra, as it lies in the prostate, is another dense layer of circular fibres, continuous behind with the internal layer of the muscular coat of the bladder, and in front blending with the fibres surrounding the membranous portion of the urethra. Between these two layers, strong bands of muscular tissue, which decussate freely, form meshes in which the glandular structure of the organ is embedded. In that part of the gland which is situated in front of the urethra the muscular tissue is especially dense, and there is here little or no gland tissue; while in that part which is behind the urethra the muscular tissue presents a wide-meshed structure, which is densest at the base of the gland—that is, near the bladder—becoming looser and more sponge-like towards the apex of the organ.

The *glandular substance* is composed of numerous follicular pouches, opening into elongated canals, which join to form from twelve to twenty small excretory ducts. The follicles are connected together by areolar tissue, supported by prolongations from the fibrous capsule and muscular stroma, and enclosed in a delicate capillary plexus. The epithelium lining of both the canals and the terminal vesicles is of the columnar variety. The prostatic ducts open into the floor of the prostatic portion of the urethra.

**Vessels and Nerves.**—The *arteries* supplying the prostate are derived from the

internal pudic, vesical, and hæmorrhoidal. Its *veins* form a plexus around the sides and base of the gland; they receive in front the dorsal vein of the penis, and terminate in the internal iliac vein. The *nerves* are derived from the pelvic plexus.

*Surgical Anatomy.*—The relation of the prostate to the rectum should be noted: by means of the finger introduced into the gut, the surgeon detects enlargement or other disease of this organ; he can feel the apex of the gland, which is the guide to Cock's operation for stricture; he is enabled also by the same means to direct the point of a catheter, when its introduction is attended with difficulty either from injury or disease of the membranous or prostatic portions of the urethra. When the finger is introduced into the bowel, the surgeon may, in some cases, especially in boys, learn the position, as well as the size and weight, of a calculus in the bladder; and in the operation for its removal, if, as is not unfrequently the case, it should be lodged behind an enlarged prostate, it may be displaced from its position by pressing upwards the base of the bladder from the rectum. The prostate gland is occasionally the seat of suppuration, either due to injury, gonorrhœa, or tuberculous disease. The gland is enveloped in a dense unyielding capsule which determines the course of the abscess, and also explains the great pain which is present in the acute form of the disease. The abscess most frequently bursts into the urethra, the direction in which there is least resistance, but may occasionally burst into the rectum, or more rarely in the perinæum. In advanced life the prostate sometimes becomes considerably enlarged and projects into the bladder so as to impede the passage of the urine. According to Dr. Messer's researches, conducted at Greenwich Hospital, it would seem that such obstruction exists in 20 per cent. of all men over sixty years of age. In some cases the enlargement affects principally the lateral lobes, which may undergo considerable enlargement without causing much inconvenience. In other cases it would seem that the middle lobe enlarges most, and even a small enlargement of this lobe may act injuriously, by forming a sort of valve over the urethral orifice, preventing the passage of the urine, and the more the patient strains, the more completely will it block the opening into the urethra. In consequence of the enlargement of the prostate, a pouch is formed at the base of the bladder behind the projection, in which water collects, and cannot be entirely expelled. It becomes decomposed and ammoniacal, and leads to cystitis. For this condition 'prostatectomy' is sometimes done. The bladder is opened by an incision above the symphysis pubis, the mucous membrane incised, and the enlarged and projecting middle lobe enucleated.

#### COWPER'S GLANDS

**Cowper's Glands** are two small rounded and somewhat lobulated bodies, of a yellow colour, about the size of peas, placed behind the fore part of the membranous portion of the urethra, between the two layers of the deep perineal fascia. They lie close above the bulb, and are enclosed by the transverse fibres of the Compressor urethræ muscle. Their existence is said to be constant: they gradually diminish in size as age advances.

**Structure.**—Each gland consists of several lobules, held together by a fibrous investment. Each lobule consists of a number of acini, lined by columnar epithelial cells, opening into one duct, which, joining with the ducts of other lobules outside the gland, form a single excretory duct. The excretory duct of each gland, nearly an inch in length, passes obliquely forwards beneath the mucous membrane, and opens by a minute orifice on the floor of the bulbous portion of the urethra. Their existence is said to be constant; they gradually diminish in size as age advances.

#### THE PENIS

The **Penis** consists of a root, body, and extremity or *glans penis*.

The *root* is firmly connected to the rami of the os pubis and ischium by two strong tapering fibrous processes, the *crura*; and to the front of the symphysis pubis by the *suspensory ligament*, a strong band of fibrous tissue which passes downwards from the front of the symphysis pubis to the upper surface of the root of the penis, where it blends with the fascial sheath of the organ.

The *extremity*, or *glans penis*, presents the form of an obtuse cone, flattened from above downwards. At its summit is a vertical fissure, the orifice of the urethra (*meatus urinarius*). The base of the glans forms a rounded projecting



border, the *corona glandis*; and behind the corona is a deep constriction, the *cervix*. Upon both of these parts, numerous small sebaceous glands are found the *glandulæ Tysonii odoriferæ*. They secrete a sebaceous matter of very peculiar odour, which probably contains caseine, and becomes easily decomposed.

The *body of the penis* is the part between the root and extremity. In the flaccid condition of the organ it is cylindrical, but when erect has a triangular prismatic form with rounded angles, the broadest side being turned upwards, and called the *dorsum*. The body is covered by integument, and contains in its interior a large portion of the urethra. The integument covering the penis is remarkable for its thinness, its dark colour, its looseness of connection with the deeper parts of the organ, and its containing no adipose tissue. At the root of the penis, the integument is continuous with that upon the pubes and scrotum: and at the neck of the glans it leaves the surface, and becomes folded upon itself to form the *prepuce*.

The internal layer of the prepuce is attached behind to the cervix, and approaches in character to a mucous membrane; from the cervix it is reflected over the glans penis, and at the meatus urinarius is continuous with the mucous lining of the urethra.

The mucous membrane covering the glans penis contains no sebaceous glands; but projecting from its free surface are a number of small, highly sensitive papillæ. At the back part of the meatus urinarius a fold of mucous membrane passes backwards to the bottom of a depressed raphé, where it is continuous with the prepuce; this fold is termed the *frænum præputii*.

**Structure of the Penis.**—The penis is composed of a mass of erectile tissue, enclosed in three cylindrical fibrous compartments. Of these, two, the *corpora cavernosa*, are placed side by side along the upper part of the organ; the third, or *corpus spongiosum*, encloses the urethra, and is placed below.

The **Corpora Cavernosa** form the chief part of the body of the penis. They consist of two fibrous cylindrical tubes, placed side by side, and intimately connected along the median line for their anterior three-fourths, whilst at their back part they separate from each other to form the *crura*, which are two strong tapering fibrous processes firmly connected to the rami of the os pubis and ischium. Each crus commences by a blunt pointed process in front of the tuberosity of the ischium; and, before its junction with its fellow to form the body of the penis, it presents a slight enlargement, named by Kobelt the *bulb of the corpus cavernosum*. Just beyond this point they become constricted, and retain an equal diameter to their anterior extremity, where they form a single rounded end, which is received into a fossa in the base of the glans penis. A median groove on the upper surface lodges the dorsal vein of the penis, and the groove on the under surface receives the corpus spongiosum. The root of the penis is connected to the symphysis pubis by the suspensory ligament.

**Structure.**—The corpora cavernosa are surrounded by a strong fibrous envelope, consisting of two sets of fibres: the one, longitudinal in direction, being common to the two corpora cavernosa, and investing them in a common covering; the other, internal, being circular in direction, and being proper to each corpus cavernosum. The internal circular fibres by their junction at one part form an incomplete partition or septum between the two bodies.

The *septum* between the two corpora cavernosa forms an imperfect partition; it is thick and complete behind, but in front it is incomplete, and consists of a number of vertical bands, which are arranged like the teeth of a comb, whence the name which it has received, *septum pectiniforme*. These bands extend between the dorsal and the urethral surface of the corpora cavernosa. This fibrous investment is extremely dense, of considerable thickness, and consists of bundles of shining white fibres, with an admixture of well-developed elastic fibres, so that it is possessed of great elasticity.

From the internal surface of the fibrous envelope, as well as from the sides of the septum, are given off a number of bands or cords, which cross the interior of



the corpora cavernosa in all directions, subdividing them into a number of separate compartments, and giving the entire structure a spongy appearance. These bands and cords are called *trabeculae*, and consist of white fibrous tissue, elastic fibres, and plain muscular fibres. In them are contained numerous arteries and nerves.

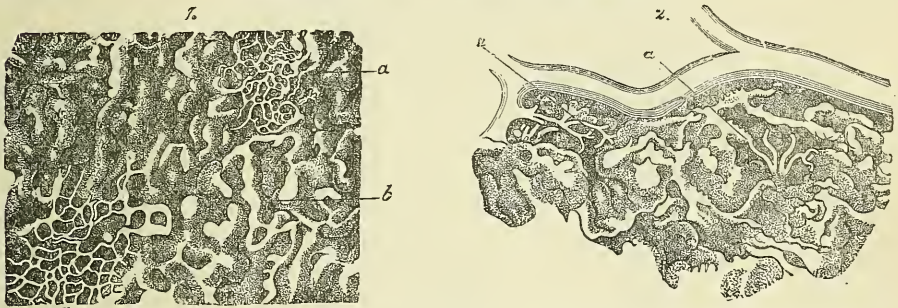
The component fibres of which the trabeculae are composed are larger and stronger round the circumference than at the centre of the corpora cavernosa; they are also thicker behind than in front. The interspaces, on the contrary, are larger at the centre than at the circumference, their long diameter being directed transversely; they are largest anteriorly. They are occupied by venous blood, and are lined by a layer of flattened cells similar to the endothelial lining of veins.

The whole of the structure of the corpora cavernosa, contained within the fibrous sheath, consists therefore of a sponge-like tissue of areolar spaces, freely communicating with each other and filled with venous blood. The spaces may therefore be regarded as large cavernous veins.

The arteries bringing the blood to these spaces are the arteries of the corpora cavernosa and branches from the dorsal artery of the penis, which perforate the fibrous capsule, along the upper surface, especially near the fore part of the organ.

These arteries on entering the cavernous structure divide into branches, which are supported and enclosed by the trabeculae. Some of these terminate in a

FIG. 674.—From the peripheral portion of the corpus cavernosum penis under a low magnifying power. (Copied from Langer.)



1. *a.* Capillary network. *b.* Cavernous spaces. 2. Connection of the arterial twigs (*a*) with the cavernous spaces.

capillary network, the branches of which open directly into the cavernous spaces; others assume a tendril-like appearance, and form convoluted and somewhat dilated vessels, which were named by Müller, *helicine arteries*. They project into the spaces, and from them are given off small capillary branches to supply the trabecular structure. They are bound down in the spaces by fine fibrous processes, and are more abundant in the back part of the corpora cavernosa (fig. 674).

The blood from the cavernous spaces is returned by a series of vessels, some of which emerge in considerable numbers from the base of the glans penis and converge on the dorsum of the organ to form the dorsal vein; others pass out on the upper surface of the corpora cavernosa and join the dorsal vein; some emerge from the under surface of the corpora cavernosa and, receiving branches from the corpus spongiosum, wind round the sides of the penis to terminate in the dorsal vein; but the greater number pass out at the root of the penis, and join the prostatic plexus.

The **Corpus Spongiosum** encloses the urethra, and is situated in the groove on the under surface of the corpora cavernosa. It commences posteriorly in front of the deep perineal fascia, between the diverging crura of the corpora cavernosa, where it forms a rounded enlargement, the *bulb*; and terminates, anteriorly, in

another expansion, the *glans penis*, which overlaps the anterior rounded extremity of the corpora cavernosa. The central portion, or body of the corpus spongiosum, is cylindrical, and tapers slightly from behind forwards.

The *bulb* varies in size in different subjects; it receives a fibrous investment from the anterior layer of the deep perineal fascia, and is surrounded by the Accelerator urinæ muscle. The urethra enters the bulb nearer its upper than its lower surface, being surrounded by a layer of erectile tissue, a thin prolongation of which is continued backwards round the membranous and prostatic portions of the canal to the neck of the bladder, lying between the two layers of muscular tissue. The portion of the bulb below the urethra presents a partial division into two lobes, being marked externally by a linear raphé, whilst internally there projects inwards, for a short distance, a thin fibrous septum, more distinct in early life.

**Structure.**—The corpus spongiosum consists of a strong fibrous envelope, enclosing a trabecular structure, which contains in its meshes erectile tissue. The fibrous envelope is thinner, whiter in colour, and more elastic than that of the corpora cavernosa. The trabeculæ are delicate, uniform in size, and the meshes between them small: their long diameter, for the most part, corresponding with that of the penis. The external envelope or outer coat of the corpus spongiosum is formed partly of unstriped muscular fibre, and a layer of the same tissue immediately surrounds the canal of the urethra.

The *lymphatics of the penis* consist of a superficial and deep set; the former are derived from a dense network on the skin of the glans and prepuce and from the mucous membrane of the urethra, and terminate in the superficial inguinal glands; the latter emerge from the corpora cavernosa and corpus spongiosum, and, passing beneath the pubic arch, join the deep lymphatics of the pelvis.

The *nerves* are derived from the internal pudic nerve and the pelvic plexus. On the glans and bulb some filaments of the cutaneous nerves have Pacinian bodies connected with them, and, according to Krause, many of them terminate in a peculiar form of end-bulb (see p. 48).

*Surgical Anatomy.*—The penis occasionally requires removal for malignant disease. Usually, removal of the ante-scrotal portion is all that is necessary, but sometimes it is requisite to remove the whole organ from its attachment to the rami of the ossa pubes and ischia. The former operation is performed either by cutting off the whole of the anterior part of the penis with one sweep of the knife; or, what is better, cutting through the corpora cavernosa from the dorsum, and then separating the corpus spongiosum from them, dividing it at a level nearer the glans penis. The mucous membrane of the urethra is then slit up, and the edges of the flap attached to the external skin, in order to prevent contraction of the orifice, which would otherwise take place. The vessels which require ligature are the two dorsal arteries of the penis, the arteries of the corpora cavernosa, and the artery of the septum. When the entire organ requires removal, the patient is placed in the lithotomy position, and an incision is made round the root of the penis, and carried down the median line of the scrotum as far as the perinæum. The two halves of the scrotum are then separated from each other, and a catheter having been introduced into the bladder as a guide, the membranous portion of the urethra in front of the triangular ligament is separated from the corpora cavernosa and divided, the catheter having been withdrawn, just behind the bulb. The suspensory ligament is now severed, and the crura separated from the bone with a periosteum scraper, and the whole penis removed. The membranous portion of the urethra, which has not been removed, is now to be attached to the skin at the posterior extremity of the incision in the perinæum. The remainder of the wound is to be brought together, free drainage being provided for.

#### THE TESTES AND THEIR COVERINGS (fig. 675)

The **Testes** are two small glandular organs, which produce the spermatozoa; they are situated in the scrotum, being suspended by the spermatic cords. At an early period of foetal life the testes are contained in the abdominal cavity, behind the peritoneum. Before birth they descend to the inguinal canal, along which they pass with the spermatic cord, and, emerging at the external abdominal ring, they descend into the scrotum, becoming invested in their course by numerous

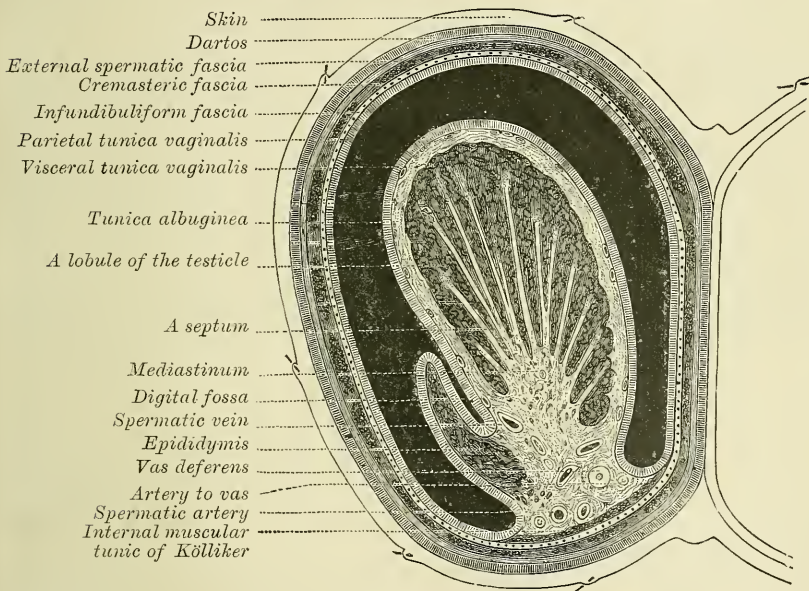


coverings derived from the serous, muscular, and fibrous layers of the abdominal parietes, as well as by the scrotum. The coverings of the testis are—the

- |   |            |
|---|------------|
| Skin  | } Serotum. |
| Dartos  |            |
| Intercolumnar, or External spermatic fascia.                    |            |
| Cremasteric fascia.   |            |
| Infundibuliform, or Fascia propria (Internal spermatic fascia). |            |
| Tunica vaginalis.   |            |

The **scrotum** is a cutaneous pouch which contains the testes and part of the spermatic cords. It is divided into two lateral halves by a median line, or *raphé*, which is continued forwards to the under surface of the penis, and backwards along the middle line of the perinæum to the anus. Of these two lateral portions the left is longer than the right, and corresponds with the greater length of the spermatic cord on the left side. Its external aspect varies under different circumstances :

FIG. 675.—Transverse section through the left side of the scrotum and the left testicle. The sac of the tunica vaginalis represented in a distended condition. (Delépine.)



thus, under the influence of warmth, and in old and debilitated persons, it becomes elongated and flaccid ; but, under the influence of cold, and in the young and robust, it is short, corrugated, and closely applied to the testes.

The scrotum consists of two layers, the integument and the dartos.

The **integument** is very thin, of a brownish colour, and generally thrown into folds or rugæ. It is provided with sebaceous follicles, the secretion of which has a peculiar odour, and is beset with thinly scattered, crisp hairs, the roots of which are seen through the skin.

The **dartos** is a thin layer of loose reddish tissue, endowed with contractility : it forms the proper tunic of the scrotum, is continuous, around the base of the scrotum, with the two layers of the superficial fascia of the groin and perinæum, and sends inwards a distinct septum, *septum scroti*, which divides it into two cavities for the two testes, the septum extending between the raphé and the under surface of the penis, as far as its root.

The dartos is closely united to the skin externally, but connected with the subjacent parts by delicate areolar tissue, upon which it glides with the greatest



facility. The dartos is very vascular, and consists of a loose areolar tissue, containing unstriped muscular fibre, but no fat. Its contractility is slow, and excited by cold and mechanical stimuli, but not by electricity.

The **intercolumnar fascia** is a thin membrane, derived from the margin of the pillars of the external abdominal ring, during the descent of the testis in the fetus, which is prolonged downwards around the surface of the cord and testis. It is separated from the dartos by loose areolar tissue, which allows of considerable movement of the latter upon it, but is intimately connected with the succeeding layers.

The **cremasteric fascia** consists of scattered bundles of muscular fibres (*Cremaster muscle*), connected together into a continuous covering by intermediate areolar tissue. The muscular fibres are derived from the lower border of the Internal oblique muscle, during the descent of the testis.

The **infundibuliform fascia** is a thin membranous layer, which loosely invests the surface of the cord. It is a continuation downwards of the fascia transversalis. Beneath it is a quantity of loose connective tissue which connects this layer of fascia with the spermatic cord and posterior part of the testicle. This connective tissue is continuous above with the sub-serous areolar tissue of the abdomen. These two layers, the infundibuliform fascia and the tissue beneath it, are known collectively as the *fascia propria*.

The **tunica vaginalis** is described with the proper covering of the testis.

**Vessels and nerves.**—The *arteries* supplying the coverings of the testis are : the superficial and deep external pudic, from the femoral; the superficial perineal branch of the internal pudic; and the cremasteric branch from the epigastric. The *veins* follow the course of the corresponding arteries. The *lymphatics* terminate in the inguinal glands. The *nerves* are the ilio-inguinal branch of the lumbar plexus, the two superficial perineal branches of the internal pudic nerve, the inferior pudendal branch of the small sciatic nerve, and the genital branch of the genito-crural nerve.

The **spermatic cord** extends from the internal abdominal ring, where the structures of which it is composed converge, to the back part of the testicle. In the abdominal wall the cord passes obliquely along the inguinal canal, lying at first beneath the Internal oblique, and upon the fascia transversalis; but nearer the pubes, it rests upon Poupart's ligament, having the aponeurosis of the External oblique in front of it, and the conjoined tendon behind it. It then escapes at the external ring, and descends nearly vertically into the scrotum. The left cord is rather longer than the right, consequently the left testis hangs somewhat lower than its fellow.

**Structure of the spermatic cord.**—The spermatic cord is composed of arteries, veins, lymphatics, nerves, and the excretory duct of the testicle. These structures are connected together by areolar tissue, and invested by the fasciæ brought down by the testicle in its descent.

The *arteries of the cord* are : the spermatic, from the aorta; the artery of the vas deferens, from the superior vesical; and the cremasteric, from the deep epigastric.

The *spermatic artery*, a branch of the abdominal aorta, escapes from the abdomen at the internal or deep abdominal ring, and accompanies the other constituents of the spermatic cord along the inguinal canal and through the external abdominal ring into the scrotum. It then descends to the testicle, and, becoming tortuous, divides into several branches, two or three of which accompany the vas deferens and supply the epididymis, anastomosing with the artery of the vas deferens: others pierce the back of the tunica albuginea and supply the substance of the testis.

The *cremasteric artery* is a branch of the deep epigastric artery. It accompanies the spermatic cord and supplies the Cremaster muscle and other coverings of the cord, anastomosing with the spermatic artery.

The *artery of the vas deferens*, a branch of the superior vesical, is a long

slender vessel, which accompanies the vas deferens, ramifying upon the coats of that duct, and anastomosing with the spermatic artery near the testis.

The spermatic veins emerge from the back of the testis, and receive tributaries from the epididymis; they unite and form a convoluted plexus (*plexus pampiniformis*), which forms the chief mass of the cord; the vessels composing this plexus are very numerous, and ascend along the cord in front of the vas deferens; below the external or superficial abdominal ring they unite to form three or four veins, which pass along the spermatic canal, and, entering the abdomen through the internal or deep abdominal ring, coalesce to form two veins. These again unite to form a single vein, which opens on the right side into the inferior vena cava, at an acute angle, and on the left side into the renal vein at a right angle.

The *lymphatic vessels* terminate in the lumbar glands.

The *nerves* are the spermatic plexus from the sympathetic, joined by filaments from the pelvic plexus which accompany the artery of the vas deferens.

*Surgical Anatomy.*—The scrotum forms an admirable covering for the protection of the testicle. This body, lying suspended and loose in the cavity of the scrotum and surrounded by a serous membrane, is capable of great mobility, and can therefore easily slip about within the scrotum, and thus avoid injuries from blows or squeezes. The skin of the scrotum is very elastic and capable of great distension, and on account of the looseness and amount of subcutaneous tissue, the scrotum becomes greatly enlarged in cases of cedema, to which this part is especially liable on account of its dependent position. The scrotum is frequently the seat of epithelioma; this is no doubt due to the rugæ on its surface, which favour the lodgment of dirt, and this, causing irritation, is the exciting cause of the disease, which is especially common in chimney-sweeps from the lodgment of soot. The scrotum is also the part most frequently affected by elephantiasis.

On account of the looseness of the subcutaneous tissue, considerable extravasations of blood may take place from very slight injuries. It is therefore generally recommended never to apply leeches to the scrotum, since they may lead to considerable ecchymosis, but rather to puncture one or more of the superficial veins of the scrotum in cases where local blood-letting from this part is judged to be desirable. The muscular fibre in the dartos causes contraction and considerable diminution in the size of a wound of the scrotum, as after the operation of castration, and is of assistance in keeping the edges together, and covering the exposed parts.

## THE TESTES

The *testes* are suspended in the scrotum by the spermatic cords. As the left spermatic cord is rather longer than the right one, the left testicle hangs somewhat lower than its fellow. Each gland is of an oval form, compressed laterally, and having an oblique position in the scrotum; the upper extremity being directed forwards and a little outwards; the lower, backwards and a little inwards; the anterior convex border looks forwards and downwards; the posterior or straight border, to which the cord is attached, backwards and upwards.

The anterior and lateral surfaces, as well as both extremities of the organ, are convex, free, smooth, and invested by the tunica vaginalis. The posterior border, to which the cord is attached, receives only a partial investment from that membrane. Lying upon the outer edge of this posterior border is a long, narrow, flattened body, named, from its relation to the testis, the epididymis (*διδυμος*, testis). It consists of a central portion, or *body*, an upper enlarged extremity, the *globus major*, or head; and a lower pointed extremity, the tail, or *globus minor*. The globus major is intimately connected with the upper end of the testicle by means of its efferent ducts; and the globus minor is connected with its lower end by cellular tissue, and a reflection of the tunica vaginalis. The outer surface and upper and lower ends of the epididymis are free and covered by serous membrane; the body is also completely invested by it, excepting along its posterior border. The epididymis is connected to the back of the testis by a fold of the serous membrane. Attached to the upper end of the testis, or to the epididymis, are one or more small pedunculated bodies. One of them is pretty constantly found between the globus major of the epididymis and the testicle,

and is believed to be the remains of the upper extremity of the Müllerian duct (page 114). It is termed the *hydatid of Morgagni*. When the testicle is removed from the body, the position of the vas deferens, on the posterior surface of the testicle and inner side of the epididymis, marks the side to which the gland has belonged.

**Size and weight.**—The average dimensions of this gland are from one and a half to two inches in length, an inch in breadth, and an inch and a quarter in the antero-posterior diameter; and the weight varies from six to eight drachms the left testicle being a little the larger.

The testis is invested by three tunics, the tunica vaginalis, tunica albuginea, and tunica vasculosa.

The **tunica vaginalis** is the serous covering of the testis. It is a pouch of serous membrane, derived from the peritoneum during the descent of the testis in the foetus from the abdomen into the scrotum. After its descent, that portion of the pouch which extends from the internal ring to near the upper part of the gland becomes obliterated, the lower portion remaining as a shut sac, which invests the outer surface of the testis, and is reflected on to the internal surface of the scrotum; hence it may be described as consisting of a visceral and parietal portion.

The *visceral portion (tunica vaginalis propria)* covers the outer surface of the testis, as well as the epididymis, connecting the latter to the testis by means of a distinct fold. From the posterior border of the gland it is reflected on to the internal surface of the scrotum.

The *parietal portion of the serous membrane (tunica vaginalis reflexa)* is far more extensive than the visceral portion, extending upwards for some distance

in front, and on the inner side of the cord, and reaching below the testis. The inner surface of the tunica vaginalis is free, smooth, and covered by a layer of endothelial cells. The interval between the visceral and parietal layers of this membrane constitutes the cavity of the tunica vaginalis.

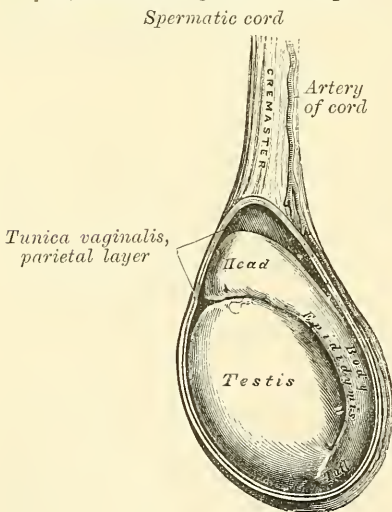
The obliterated portion of the pouch may generally be seen as a fibro-cellular thread lying in the loose areolar tissue around the spermatic cord; sometimes this may be traced as a distinct band from the upper end of the inguinal canal, where it is connected with the peritoneum, down to the tunica vaginalis; sometimes it gradually becomes lost on the spermatic cord. Occasionally no trace of it can be detected. In some cases it happens that the pouch of peritoneum does not become obliterated, but the sac of the peritoneum communicates

with the tunica vaginalis. This may give rise to one of the varieties of oblique inguinal hernia (page 1126). Or in other cases the pouch may contract, but not become entirely obliterated; it then forms a minute canal leading from the peritoneum to the tunica vaginalis.\*

The **tunica albuginea** is the fibrous covering of the testis. It is a dense

\* It is recorded that in the post-mortem examination of Sir Astley Cooper, this minute canal was found on both sides of the body. Sir Astley Cooper states that when a student he suffered from inguinal hernia; probably this was of the congenital variety, and the canal found after death was the remains of the one down which the hernia travelled.—*Lancet*, vol. ii. 1824, p. 116.

FIG. 676.—The testis *in situ*, the tunica vaginalis having been laid open.





fibrous membrane, of a bluish-white colour, composed of bundles of white fibrous tissue, which interlace in every direction. Its outer surface is covered by the tunica vaginalis, except along its posterior border, at the points of attachment of the epididymis; hence the tunica albuginea is usually considered as a fibrous membrane, like the pericardium. This membrane surrounds the glandular structure of the testicle, and, at its posterior border, is reflected into the interior of the gland, forming an incomplete vertical septum, called the *mediastinum testis* (*corpus Highmorianum*).

The *mediastinum testis* extends from the upper, nearly to the lower border of the gland, and is wider above than below. From the front and sides of this septum numerous slender fibrous cords and imperfect septa (*trabeculæ*) are given off, which radiate towards the surface of the organ, and are attached to the inner surface of the tunica albuginea. They therefore divide the interior of the organ into a number of incomplete spaces, which are somewhat cone-shaped, being broad at their bases at the surface of the gland, and becoming narrower as they converge to the mediastinum. The mediastinum supports the vessels and ducts of the testis in their passage to and from the substance of the gland.

The **tunica vasculosa** (*pia mater testis*) is the vascular layer of the testis, consisting of a plexus of blood-vessels, held together by delicate areolar tissue. It covers the inner surface of the tunica albuginea and the different septa in the interior of the gland, and therefore forms an internal investment to all the spaces of which the gland is composed.

**Structure.**—The glandular structure of the testis consists of numerous lobules (*lobuli testis*). Their number, in a single testis, is estimated by Berres at 250, and by Krause at 400. They differ in size according to their position, those in the middle of the gland being larger and longer. The lobules are conical in shape, the base being directed towards the circumference of the organ, the apex towards the mediastinum. Each lobule is contained in one of the intervals between the fibrous cords and vascular processes which extend between the mediastinum testis and the tunica albuginea, and consists of from one to three, or more, minute convoluted tubes, the *tubuli seminiferi*. The tubes may be separately unravelled, by careful dissection under water, and may be seen to commence either by free cæcal ends, or by anastomotic loops. The total number of tubes is considered by Monro to be about 300, and the length of each about sixteen feet; by Lauth, their number is estimated at 840, and their average length two feet and a quarter. Their diameter varies from  $\frac{1}{200}$  to  $\frac{1}{150}$  of an inch. The tubuli are pale in colour in early life, but in old age they acquire a deep yellow tinge, from containing much fatty matter. Each tube consists of a basement layer, formed of epithelioid cells united edge to edge, outside which are other layers of flattened cells arranged in interrupted laminae, which give to the tube an appearance of striation in cross section. The cells of the outer layers gradually pass into the interstitial tissue. Within the basement membrane are epithelial cells arranged in several irregular layers, which are not always clearly separate, but which may be arranged in three different groups. Amongst these cells may be seen the *spermatozoa* in different stages of development. 1. Lining the basement membrane and forming the outer zone is a layer of cubical cells, with small nuclei; these are known as the *lining cells* or *spermatogonia*. The nucleus of some of them may be seen to be in the process of indirect division (*karyokinesis*, page 10), and in consequence of this daughter cells are formed, which constitute the second zone. 2. Within this first layer is to be seen a number of larger cells with clear nuclei, arranged in two or three layers; these are the *intermediate* or *spermatogenic cells*. Embedded between them are clusters of developing spermatozoa, whose tails project into the lumen of the tube. Most of these cells are in a condition of karyokinetic division, and the cells which result from this division are converted into the next layer, or *spermatoblasts*, by further division. 3. The third layer of cells is the *spermatoblast*, from which the spermatozoa originate. They are ill-defined granular masses of

protoplasm, of an elongated form, with a nucleus, which becomes the head of the newly-forming spermatozoa. As development proceeds, the nuclear extremity penetrates between the cells of the intermediate layer and becomes connected with some of the cells of the outermost layer, which become elongated to receive them. When development is almost complete, the spermatozoa begin to travel inwards again towards the lumen of the tube, their connection with the cell of the outer layer becoming stretched and converted into an attenuated thread. Eventually, when they are fully developed, they may be seen forming a zone of contiguous spermatozoa next to the lumen of the tube, with their tails projecting into it; and finally detachment of the head takes place, and they are set free into the interior of the tube.

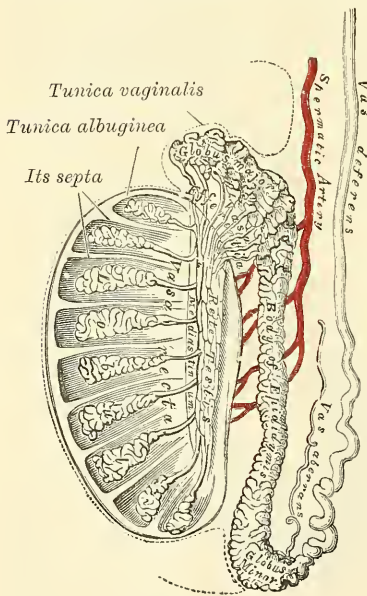
The tubules are enclosed in a delicate plexus of capillary vessels, and are held together by an intertubular connective tissue, which presents large interstitial spaces lined by endothelium, which are believed to be the rootlets of the lymphatic vessels of the testis.

In the apices of the lobules, the tubuli become less convoluted, assume a nearly straight course, and unite together to form from twenty to thirty larger ducts, of about  $\frac{1}{30}$  of an inch in diameter, and these, from their straight course, are called *vasa recta*.

The *vasa recta* enter the fibrous tissue of the mediastinum, and pass upwards and backwards, forming, in their ascent, a close network of anastomosing tubes which are merely channels in the fibrous stroma, lined by flattened epithelium and having no proper walls; this constitutes the *rete testis*. At the upper end

of the mediastinum, the vessels of the rete testis terminate in from twelve to fifteen or twenty ducts, the *vasa efferentia*: they perforate the tunica albuginea, and carry the seminal fluid from the testis to the epididymis. Their course is at first straight, they then become enlarged, and exceedingly convoluted, and form a series of conical masses, the *coni vasculosi*, which, together constitute the globus major of the epididymis. Each cone consists of a single convoluted duct, from six to eight inches in length, the diameter of which gradually decreases from the testis to the epididymis. Opposite the bases of the cones the efferent vessels open at narrow intervals into a single duct, which constitutes, by its complex convolutions, the body and globus minor of the epididymis. When the convolutions of this tube are unravelled, it measures upwards of twenty feet in length, and increases in breadth and thickness as it approaches the vas deferens. The con-

FIG. 677.—Vertical section of the testicle, to show the arrangement of the ducts.



volutions are held together by fine areolar tissue, and by bands of fibrous tissue.

The *vasa recta* are of smaller diameter than the seminal tubes, and have very thin parietes. They, like the channels of the rete testis, are lined by a single layer of flattened epithelium. The *vasa efferentia* and the tube of the epididymis have walls of considerable thickness, on account of the presence in them of muscular tissue, which is principally arranged in a circular manner. These tubes are lined by columnar ciliated epithelium.

The **vas deferens**, the excretory duct of the testis, is the continuation of the epididymis. Commencing at the lower part of the globus minor, it ascends along



the posterior surface of the testis and inner side of the epididymis, and along the back part of the spermatic cord, through the spermatic canal to the internal or deep abdominal ring. From the ring it curves round the outer side of the epigastric artery, crosses the external iliac vessels, and descends into the pelvis at the side of the bladder; it arches backwards and downwards to its base, crossing over the obliterated hypogastric artery, and to the inner side of the ureter. At the base of the bladder it lies between that viscus and the rectum, running along the inner border of the vesicula seminalis. In this situation it becomes enlarged and sacculated, forming the *ampulla*; and then, becoming narrowed at the base of the prostate, unites with the duct of the vesicula seminalis to form the ejaculatory duct. The vas deferens presents a hard and cord-like sensation to the fingers; it is about two feet in length, of cylindrical form, and about a line and a quarter in diameter. Its walls are dense, measuring one-third of a line; and its canal is extremely small, measuring about half a line.

**Structure.**—The vas deferens consists of three coats: 1. An external, or cellular coat. 2. A muscular coat, which in the greater part of the tube consists of two layers of unstriped muscular fibre: an outer, longitudinal in direction, and an inner, circular; but in addition to these, at the commencement of the vas deferens, there is a third layer, consisting of longitudinal fibres, placed internal to the circular stratum, between it and the mucous membrane. 3. An internal, or mucous coat, which is pale, and arranged in longitudinal folds; its epithelial covering is of the columnar variety.

A long narrow tube, the *vas aberrans of Haller*, is occasionally found connected with the lower part of the canal of the epididymis, or with the commencement of the vas deferens. It extends up into the cord for about two or three inches, where it terminates by a blind extremity, which is occasionally bifurcated. Its length varies from an inch and a half to fourteen inches, and sometimes it becomes dilated towards its extremity; more commonly it retains the same diameter throughout. Its structure is similar to that of the vas deferens. Occasionally it is found unconnected with the epididymis.

**Surgical Anatomy.**—The testicle frequently requires removal for malignant disease; in tuberculous disease, to prevent systemic infection; in cystic disease; in cases of large hernia testis, and in some instances of incompletely descended or misplaced testicles. The operation of castration has also been, during the last few years, performed for enlargement of the prostate; for it has been found that removal of the testicles is followed by very rapid and often considerable diminution in the size of the prostate. The operation is, however, one of severity, and is frequently followed by death in these cases, performed, as is necessarily the case, in old men. Reginald Harrison has proposed to substitute for it excision of a portion of the vasa deferentia. The operation of castration is a comparatively simple one. An incision is made from the external ring to the bottom of the scrotum, into the tunica vaginalis. The coverings are shelled off the organ, and the mesorchium, stretching between the back of the testicle and the scrotum, divided. The cord is then isolated, and an aneurism needle, armed with a double ligature, passed under it, as high as is thought necessary, and the cord tied in two places, and divided between the ligatures. Sometimes, in cases of malignant disease, it is desirable to open the inguinal canal and tie the cord as near the internal abdominal ring as possible.

#### VESICULÆ SEMINALES

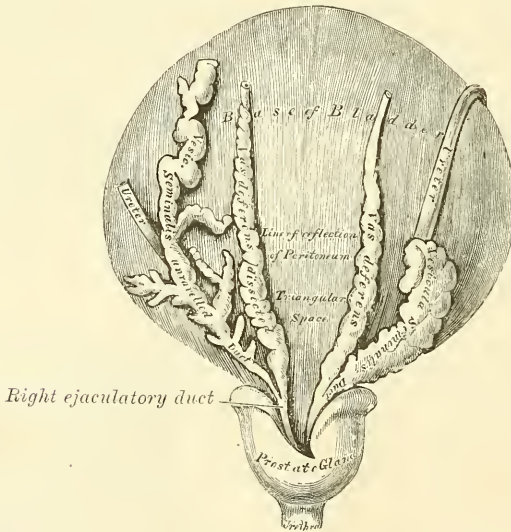
The **seminal vesicles** are two lobulated membranous pouches, placed between the base of the bladder and the rectum, serving as reservoirs for the semen, and secreting a fluid to be added to the secretion of the testicles. Each sac is somewhat pyramidal in form, the broad end being directed backwards, and the narrow end forwards towards the prostate. They measure about two and a half inches in length, about five lines in breadth, and two or three lines in thickness. They vary, however, in size, not only in different individuals, but also in the same individual on the two sides. Their *upper surface* is in contact with the base of the bladder, extending from near the termination of the ureters to the base of the prostate gland. Their *under surface* rests upon the rectum, from which they



are separated by the recto-vesical fascia. Their *posterior extremities* diverge from each other. Their *anterior extremities* are pointed, and converge towards the base of the prostate gland, where each joins with the corresponding vas deferens to form the ejaculatory duct. Along the inner margin of each vesicula runs the enlarged and convoluted vas deferens. The inner border of the vesiculæ, and the corresponding vas deferens form the lateral boundaries of a triangular space, limited behind by the recto-vesical peritoneal fold; the portion of the bladder included in this space rests on the rectum, and corresponds with the trigonum vesicæ in its interior.

Each vesicula consists of a single tube, coiled upon itself, and giving off several irregular cæcal diverticula: the separate coils, as well as the diverticula, being connected together by fibrous tissue. When uncoiled, this tube is about the diameter of a quill, and varies in length from four to six inches; it terminates posteriorly in a *cul-de-sac*; its anterior extremity becomes constricted into a narrow straight duct, which joins on its inner side with the corresponding vas deferens, and forms the ejaculatory duct.

FIG. 678.—Base of the bladder, with the vasa deferentia and vesiculæ seminales.



The **ejaculatory ducts**, two in number, one on each side, are formed by the junction of the ducts of the vesiculæ seminales with the vasa deferentia. Each duct is about three-quarters of an inch in length; it commences at the base of the prostate, and runs forwards and downwards in a canal in its substance, and along the side of the sinus pocularis, to terminate by a separate slit-like orifice close to or just within the margins of the sinus. The ducts diminish in size, and converge towards their termination.

**Structure.**—The vesiculæ seminales are composed of three coats: an *external* or *fibro-cellular*; a *middle* or *muscular coat*, which is thinner than in the vas deferens, arranged in two layers, an outer, longitudinal, and inner, circular; an *internal* or *mucous coat*, which is pale, of a whitish-brown colour, and presents a delicate reticular structure, like that seen in the gall-bladder, but the meshes are finer. The epithelium is columnar.

The coats of the ejaculatory ducts are extremely thin. They are: an *outer fibrous layer*, which is almost entirely lost after their entrance into the prostate; a *layer of muscular fibres*, consisting of an outer thin circular and an inner longitudinal layer, and the *mucous membrane*, forming the only constituents of the tubes.

**Vessels and nerves.**—The *arteries* supplying the vesiculæ seminales are derived

from the middle and inferior vesical and middle hæmorrhoidal. The *veins* and *lymphatics* accompany the arteries. The *nerves* are derived from the pelvic plexus.

*Surgical Anatomy.*—The vesiculæ seminales are often the seat of an extension of the disease in cases of tuberculous disease of the testicle, and should always be examined from the rectum before coming to a decision with regard to castration in this affection.

### DESCENT OF THE TESTES

The testes, at an early period of fœtal life, are placed at the back part of the abdominal cavity, behind the peritoneum; in front, and a little below the kidneys. The anterior surface and sides are invested by peritoneum. At about the third month of intra-uterine life a peculiar structure, the *gubernaculum testis*, makes its appearance. This structure is at first a slender band which extends from the situation of the internal ring, to the epididymis and body of the testicle, and is then continued upwards in front of the kidney towards the Diaphragm. As development advances, the peritoneum covering the testicle encloses it and forms a mesentery, the *mesorchium*, which also encloses the gubernaculum and forms two folds, one above the testicle, and the other below it. The one above the testicle is the *plica vascularis*, and contains ultimately the spermatic vessels; the one below, the *plica gubernatrix*, contains the lower part of the gubernaculum, which has now grown into a thick cord; it terminates below at the internal ring in a tube of peritoneum, the *processus vaginalis*, which protrudes itself down the inguinal canal. The lower part of the gubernaculum by the fifth month has become a thick cord, whilst the upper part has disappeared. The lower part can now be seen to consist of a central core of unstriped muscle-fibre, and outside this of a firm layer of striped elements connected, behind the peritoneum, with the abdominal wall. Later on, about the sixth month, the lower end of the gubernaculum can be traced into the inguinal canal, extending to the pubes, and, at a later period, to the bottom of the scrotum. The fold of peritoneum, constituting the *processus vaginalis*, projects itself downwards into the inguinal canal, forming a gradually elongating depression or *cul-de-sac*, which eventually reaches the bottom of the scrotum, and into this the testicle is drawn by the growth of the body of the fœtus, for the gubernaculum does not grow commensurately with the growth of other parts, and therefore the testicle, being attached by the gubernaculum to the bottom of the scrotum, is prevented from rising as the body grows, and is drawn first into the inguinal canal and eventually into the scrotum. By the eighth month, the testicle has reached the scrotum, preceded by the lengthened pouch of peritoneum, the *processus vaginalis*, which communicates by its upper extremity with the peritoneal cavity. Just before birth the upper part of the pouch usually becomes closed, and this obliteration extends gradually downwards to within a short distance of the testis. The process of peritoneum surrounding the testis, which is now entirely cut off from the general peritoneal cavity, constitutes the *tunica vaginalis*.\*

In the female, a small cord, corresponding to the gubernaculum in the male, descends to the inguinal region, and ultimately forms the round ligament of the uterus. A pouch of peritoneum accompanies it along the inguinal canal, analogous to the *processus vaginalis* in the male: it is called the *canal of Nuck*.

*Surgical Anatomy.*—Abnormalities in the formation and in the descent of the testicle may occur. The testicle may fail to be developed; or the testicle may be fully developed, and the *vas deferens* may be undeveloped in whole or part; or again, both testicle and *vas deferens* may be fully developed, but the duct may not become connected to the gland. The testicle may fail in its descent, or it may descend into some abnormal position. Thus it may be retained in the position where it was primarily developed, below the kidney; or it may descend to the internal abdominal ring, but fail to pass through this opening; it may be retained in the inguinal canal, which is perhaps the

\* The obliteration of the process of peritoneum which accompanies the cord, and is hence called the *funicular process*, is often incomplete. See section on Inguinal Hernia.

most common position; or it may pass through the external abdominal ring and remain just outside it, failing to pass to the bottom of the scrotum. On the other hand, it may get into some abnormal position: it may pass the scrotum and reach the perinæum, or it may fail to enter the inguinal canal, and may find its way through the femoral ring into the crural canal, and present itself on the thigh at the saphenous opening. There is still a third class of cases of abnormality of the testicle, where the organ has descended in due course into the scrotum, but is misplaced. The most common form of this is where the testicle is *inverted*; that is to say, the organ is rotated so that the epididymis is connected to the front of the scrotum, and the body, surrounded by the tunica vaginalis, is directed backwards. In these cases the vas deferens is to be felt in the front of the cord. The condition is of importance in connection with hydrocele and hæmatocele, and the position of the testicle should always be carefully ascertained before performing any operation for these affections. Again, more rarely, the testicle may be *reversed*. This is a condition in which the top of the testicle, indicated by the globus major of the epididymis, is at the bottom of the scrotum, and the vas deferens comes off from the summit of the organ.

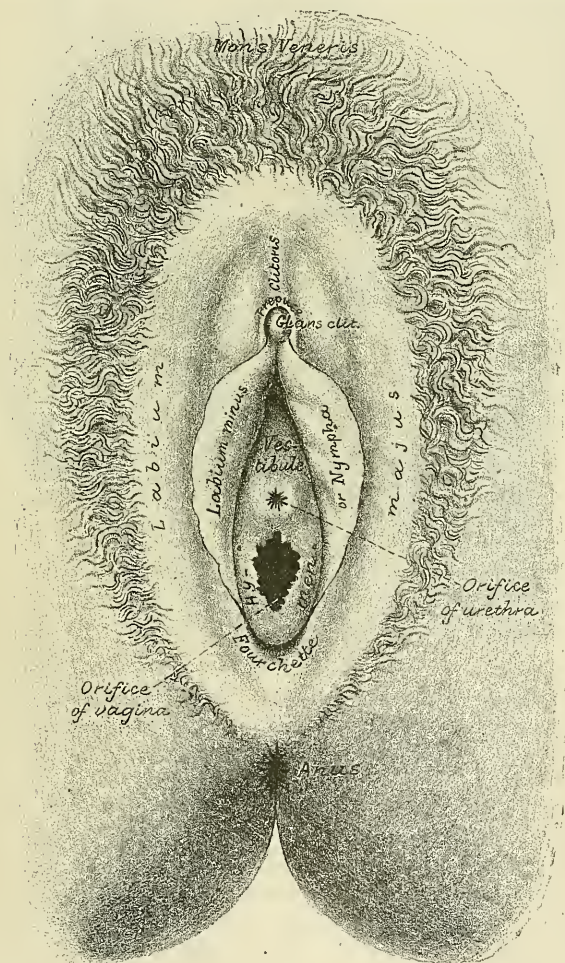


# FEMALE ORGANS OF GENERATION

## EXTERNAL ORGANS

**T**HE external organs of generation in the female are: the mons Veneris; the labia majora and minora, the clitoris, the meatus urinarius, and the orifice of the vagina. The term 'vulva' or 'pudendum,' as generally applied, includes all these parts.

FIG. 679.—The vulva. External female organs of generation

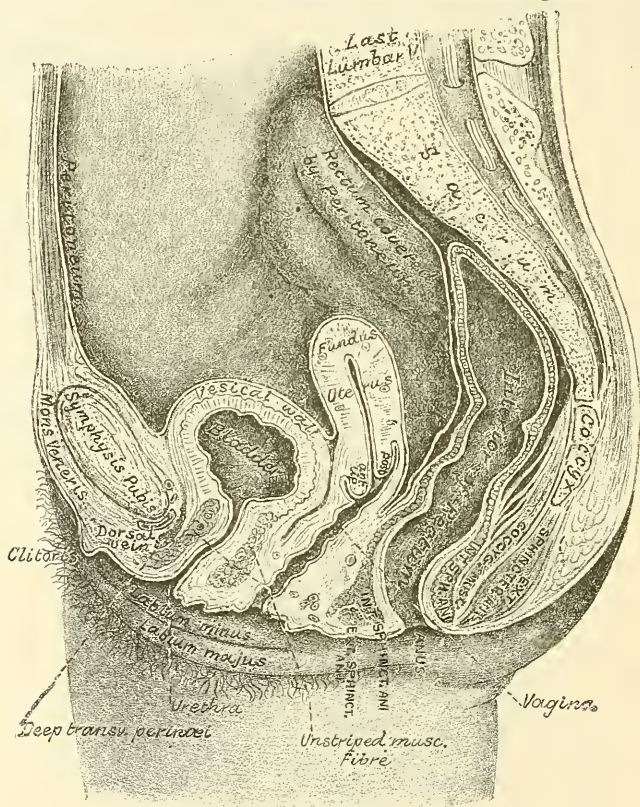


The **mons Veneris** is the rounded eminence in front of the pubic symphysis formed by a collection of fatty tissue beneath the integument. It surmounts the vulva, and becomes covered with hair at the time of puberty.

The **labia majora** are two prominent longitudinal cutaneous folds, extending

downwards from the mons Veneris to the anterior boundary of the perinæum, and enclosing the common urino-sexual opening. Each labium has two surfaces, an outer, which is pigmented and covered with strong, crisp hairs; and an inner, which is smooth and is beset with large sebaceous follicles and is continuous with the genito-urinary mucous tract; and between the two a considerable quantity of areolar tissue, fat, and a tissue resembling the dartos of the scrotum, besides vessels, nerves, and glands. The labia are thicker in front, where they form by their meeting the *anterior commissure*. Posteriorly they are not really joined, but appear to become lost in the neighbouring integument, terminating close to, and nearly parallel with each other. Together with the connecting skin between them, they form the posterior commissure, or posterior boundary of the vulval orifice.

FIG. 680.—Vertical median section of the female pelvis.



The interval between the posterior commissure and the anus, about an inch to an inch and a quarter in length, constitutes the perinæum. The *fourchette* is the anterior edge of the perinæum, and between it and the hymen is a depression, the *fossa navicularis*. The labia correspond to the scrotum in the male.

The *labia minora*, or *nymphæ*, are two small cutaneous folds, situated within the labia majora, and extending from the clitoris obliquely downwards, outwards and backwards for about an inch and a half on each side of the orifice of the vagina, between which and the labia majora they are lost. Anteriorly, the two labia minora meet, and form the *frænum of the clitoris*. The prepuce of the clitoris, passing backwards on each side, is inserted, as it were, into the labia minora, but is not actually a part of them. The nymphæ are really modified skin. Their internal surfaces have numerous sebaceous follicles.

The *clitoris* is an erectile structure, analogous to the corpora cavernosa of the penis. It is situated beneath the anterior commissure, partially hidden between



the anterior extremities of the labia minora. It is connected to the rami of the os pubis and ischium on each side by a crus; the body is short and concealed beneath the labia; the free extremity, or *glans clitoridis*, is a small rounded tubercle, consisting of spongy erectile tissue, and highly sensitive. It is provided, like the penis, with a suspensory ligament, and with two small muscles, the *Erectores clitoridis*, which are inserted into the crura of the clitoris. The clitoris consists of two corpora cavernosa, composed of erectile tissue enclosed in a dense layer of fibrous membrane, united together along their inner surfaces by an incomplete fibrous pectiniform septum.

Between the clitoris and the entrance of the vagina is a triangular smooth surface, bounded on each side by the nymphæ; this is the *vestibule*.

The orifice of the urethra (*meatus urinarius*) is situated at the back part of the vestibule, about an inch below the clitoris, and near the margin of the vagina, surrounded by a prominent elevation of the mucous membrane. Below the meatus urinarius is the orifice of the vagina, more or less closed in the virgin by a membranous fold, the *hymen*.

The *hymen* is a membranous fold which closes to a greater or less extent the opening of the vagina. It varies much in shape. Its commonest form is that of a ring, generally broadest posteriorly: sometimes it is represented by a semilunar fold, with its concave margin turned towards the pubes. A complete septum stretched across the lower part of the vaginal orifice is called 'imperforate hymen.' Occasionally it is cribriform, or its free margin forms a membranous fringe, or it may be entirely absent. It may persist after copulation, so that it cannot be considered as a test of virginity. After parturition, the small rounded elevations known as the *caruncule myrtiformes* are found as the remains of the hymen.

**Glands of Bartholin.**—On each side of the commencement of the vagina, and behind the hymen, is a round or oblong body, of a reddish-yellow colour, and of the size of a horse-bean, analogous to Cowper's gland in the male. It is called the *gland of Bartholin*. Each gland opens by means of a long single duct, on each side, external to the hymen.

**Bulbi vestibuli.**—Extending from the clitoris, along either side of the vestibule, and lying a little behind the nymphæ, are two large oblong masses, about an inch in length, consisting of a plexus of veins, enclosed in a thin layer of fibrous membrane. These bodies are narrow in front, rounded below, and are connected with the crura of the clitoris and rami of the pubes: they are termed by Kobelt the *bulbi vestibuli*; and he considers them analogous to the bulb of the corpus spongiosum in the male. Immediately in front of these bodies is a smaller venous plexus, continuous with the bulbi vestibuli behind and the glans clitoridis in front: it is called by Kobelt the *pars intermedia*, and is considered by him as analogous to that part of the body of the corpus spongiosum which immediately succeeds the bulb.

#### RELATIONS OF THE BLADDER

The **bladder** is situated at the anterior part of the pelvis. It is in relation, *in front*, with the symphysis pubis; *behind*, with the utero-vesical pouch of peritoneum which separates it from the body of the uterus; its *base* lies in contact with the connective tissue in front of the cervix and upper part of the vagina. *Laterally*, is the recto-vesical fascia. The bladder is said by some anatomists to be larger in the female than in the male. At any rate it does not rise above the symphysis pubis till more distended than in the male, but this is perhaps owing to the more capacious pelvis rather than to its being of actually larger size.

#### THE URETHRA

The **urethra** is a narrow membranous canal, about an inch and a half in length, extending from the neck of the bladder to the meatus urinarius. It is



placed beneath the symphysis pubis, embedded in the anterior wall of the vagina ; and its direction is obliquely downwards and forwards, its course being slightly curved, the concavity directed forwards and upwards. Its diameter when undilated is about a quarter of an inch. The urethra perforates the triangular ligament, precisely as in the male.

**Structure.**—The urethra consists of three coats: muscular, erectile, and mucous.

The *muscular coat* is continuous with that of the bladder ; it extends the whole length of the tube, and consists of a circular stratum of muscular fibres. In addition to this, between the two layers of the triangular ligament, the female urethra is surrounded by the Compressor urethræ, as in the male.

A *thin layer of spongy erectile tissue*, containing a plexus of large veins, intermixed with bundles of unstriped muscular fibre, lies immediately beneath the mucous coat.

The *mucous coat* is pale, continuous externally with that of the vulva, and internally with that of the bladder. It is thrown into longitudinal folds, one of which, placed along the floor of the canal, resembles the verumontanum in the male urethra. It is lined by laminated epithelium, which becomes transitional near the bladder. Its external orifice is surrounded by a few mucous follicles.

The urethra, from not being surrounded by dense resisting structures, as in the male, admits of considerable dilatation, which enables the surgeon to remove, with considerable facility, calculi, or other foreign bodies, from the cavity of the bladder.

#### THE RECTUM

The **rectum** is more capacious and less curved in the female than in the male.

The *first portion* extends from the left sacro-iliac symphysis to the middle of the sacrum. Its connections are similar to those in the male.

The *second portion* extends to the tip of the coccyx. It is covered in front by the peritoneum for a short distance, at its upper part: it is in relation with the posterior wall of the vagina.

The *third portion* curves backwards from the vagina to the anus, leaving a space which corresponds on the surface of the body to the perinæum. Its extremity is surrounded by the Sphincter muscles, and its sides are supported by the Levatores ani.

#### INTERNAL ORGANS

The **internal organs of generation** are: the vagina, the uterus and its appendages, the Fallopian tubes, the ovaries and their ligaments, and the round ligaments.

The **vagina** extends from the vulva to the uterus. It is situated in the cavity of the pelvis, behind the bladder, and in front of the rectum. Its direction is curved upwards and backwards, at first in the line of the outlet, and afterwards in that of the axis of the cavity of the pelvis. Its walls are ordinarily in contact, and its usual shape on transverse section is that of an H, the transverse limb being slightly curved forwards or backwards, whilst the lateral limbs are somewhat convex towards the median line. Its length is about two inches along its anterior wall, and two and three-quarter inches along its posterior wall. It is constricted at its commencement, and becomes dilated medially, and narrowed near its uterine extremity ; it surrounds the vaginal portion of the cervix uteri, a short distance from the os, its attachment extending higher up on the posterior than on the anterior wall of the uterus.

**Relations.**—Its *anterior surface* is in relation with the base of the bladder, and with the urethra. Its *posterior surface* is connected for the lower three-fourths of its extent to the anterior wall of the rectum, the upper fourth being separated from that tube by the recto-vaginal fold of peritoneum, which forms a

*cul-de-sac* between the vagina and rectum. Its sides give attachment superiorly to the broad ligaments, and inferiorly to the Levatores ani muscles and recto-vesical fascia.

**Structure.**—The vagina consists of an internal mucous lining, of a muscular coat, and between the two of a layer of erectile tissue.

The *mucous membrane* is continuous above with that lining the uterus. Its inner surface presents, along the anterior and posterior walls, a longitudinal ridge or raphé, called the *columns of the vagina*, and numerous transverse ridges or rugæ, extending outwards from the raphé on either side. These rugæ are divided by furrows of variable depth, giving to the mucous membrane the appearance of being studded over with conical projections or papillæ; they are most numerous near the orifice of the vagina, especially in females before parturition. The epithelium covering the mucous membrane is of the squamous variety. The submucous tissue is very loose, and contains numerous large veins, which by their anastomoses form a plexus, together with smooth muscular fibres derived from the muscular coat; it is regarded by Gussenbauer as an erectile tissue. It contains a number of mucous crypts, but no true glands.

The *muscular coat* consists of two layers: an external longitudinal, which is far the stronger, and an internal circular layer. The longitudinal fibres are continuous with the superficial muscular fibres of the uterus. The strongest fasciculi are those attached to the recto-vesical fascia on each side. The two layers are not distinctly separable from each other, but are connected by oblique decussating fasciculi, which pass from the one layer to the other. In addition to this, the vagina at its lower end is surrounded by a band of striped muscular fibres, the *sphincter vaginae* (see page 465).

External to the muscular coat is a layer of connective tissue, containing a large plexus of blood-vessels.

The *erectile tissue* consists of a layer of loose connective tissue, situated between the mucous membrane and the muscular coat; embedded in it is a plexus of large veins, and numerous bundles of unstriped muscular fibres, derived from the circular muscular layer. The arrangement of the veins is similar to that found in other erectile tissues.

## THE UTERUS

The **uterus** is the organ of gestation, receiving the fecundated ovum in its cavity, retaining and supporting it during the development of the foetus, and becoming the principal agent in its expulsion at the time of parturition.

In the *virgin state* it is pear-shaped, flattened from before backwards, and situated in the cavity of the pelvis, between the bladder and the rectum; it is retained in its position by the round and broad ligaments on each side, and projects into the upper end of the vagina below. Its upper end, or base, is directed upwards and forwards; its lower end, or apex, downwards and backwards, in the line of the axis of the inlet of the pelvis. It therefore forms an angle with the vagina, since the direction of the vagina corresponds to the axis of the cavity and outlet of the pelvis. The uterus measures about three inches in length, two in breadth at its upper part, and nearly an inch in thickness, and it weighs from an ounce to an ounce and a half.

It consists of two parts: (1) the *body*, with its upper broad extremity, the *fundus*; and (2) the *cervix*, or *neck*, which is partly above the vagina, and partly in the vagina. The fundus is placed on a line below the level of the brim of the pelvis, being directed forwards behind the upper portion of the anterior pelvic wall.

The division between the body and cervix is indicated externally by a slight constriction, and by the reflection of the peritoneum from the anterior surface of the uterus on to the bladder, and internally by a narrowing of the canal, called the *internal os*.



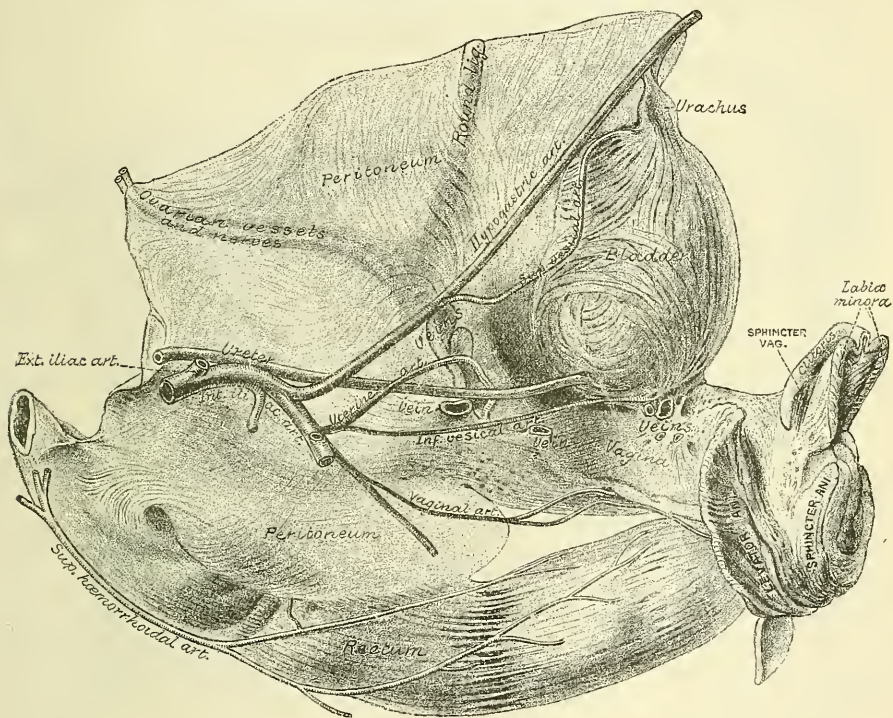




of which are, in front, the posterior wall of the uterus, the supravaginal cervix, and the upper fourth of the vagina; behind, the rectum and sacrum; above, the small intestine; and laterally, the sacro-uterine ligaments.

The *two lateral or broad ligaments* pass from the sides of the uterus to the lateral walls of the pelvis, forming a septum across the pelvis, which divides that cavity into two portions. In the anterior part are contained the bladder, urethra, and vagina; in the posterior part, the rectum. Between the two layers of each broad ligament are contained: (1) the Fallopian tubes superiorly; (2) the round ligament; (3) the ovary and its ligament; (4) the parovarium, or organ of Rosenmüller; (5) connective tissue; and (6) unstriated muscular fibre. The Fallopian tube is contained in a special fold of the broad ligament, which is attached to the part of the ligament near the ovary, and is known by the

FIG. 682.—Side view of the female pelvic organs. (From a preparation in the Museum of the Royal College of Surgeons.)



name of the *meso-salpinx*. Between the fimbriated extremity of the tube and the lower attachment of the broad ligament is a concave rounded margin called the *infundibulo-pelvic ligament* (fig. 684).

The *sacro-uterine ligaments* pass from the second and third bones of the sacrum, downwards and forwards, to be attached one on each side of the uterus at the junction of the supravaginal cervix and the body, this point corresponding internally to the position of the os internum.

The *round ligament* will be described in the sequel.

The *cavity of the uterus* is small in comparison with the size of the organ: that portion of the cavity which corresponds to the body is triangular, flattened from before backwards, so that its walls are closely approximated, and having its base directed upwards towards the fundus. At each superior angle is a funnel-shaped cavity, which constitutes the remains of the division of the body of the uterus into two cornua; and at the bottom of each cavity is the minute orifice of the Fallopian tube. At the inferior angle of the uterine cavity is a small

constricted opening, the internal orifice (*ostium internum*), which leads into the cavity of the cervix.

The **cavity of the cervix** is somewhat fusiform, flattened from before backwards, broader at the middle than at either extremity, and communicates, below, with the vagina. The wall of the canal presents, anteriorly and posteriorly, a longitudinal column, from which proceed a number of small oblique columns, giving the appearance of branches from the stem of a tree; and hence the name *arbor vite uterina* applied to it. These folds usually become very indistinct after the first labour.

**Structure.**—The uterus is composed of three coats: an external serous coat, a middle or muscular, and an internal mucous coat.

The *serous coat* is derived from the peritoneum; it invests the fundus and the whole of the posterior surface of the body of the uterus; but only the upper three-fourths of its anterior surface. In the lower fourth of the posterior surface the peritoneum, though covering the uterus, is not closely connected with it, being separated from it by a layer of loose cellular tissue and some large veins.

The *muscular coat* forms the chief bulk of the substance of the uterus. In the unimpregnated state it is dense, firm, of a greyish colour, and cuts almost like cartilage. It is thick opposite the middle of the body and fundus, and thin at the orifices of the Fallopian tubes. It consists of bundles of unstriped muscular fibres, disposed in layers, intermixed with areolar tissue, blood-vessels, lymphatic vessels, and nerves. In the impregnated state the muscular tissue becomes more prominently developed, and is disposed in three layers—external, middle, and internal.

The external layer is placed beneath the peritoneum, disposed as a thin plane on the anterior and posterior surfaces. It consists of fibres, which pass transversely across the fundus, and, converging at each superior angle of the uterus, are continued on to the Fallopian tube, the round ligament, and the ligament of the ovary: some passing at each side into the broad ligament, and others running backwards from the cervix into the sacro-uterine ligaments.

The middle layer of fibres, which is thickest, presents no regularity in its arrangement, being disposed longitudinally, obliquely, and transversely. It contains most blood-vessels.

The internal or deep layer consists of circular fibres arranged in the form of two hollow cones, the apices of which surround the orifices of the Fallopian tubes, their bases intermingling with one another on the middle of the body of the uterus. At the internal os these circular fibres form a distinct sphincter.

The *mucous membrane* is thin, smooth, and closely adherent to the subjacent tissue. It is continuous, through the fimbriated extremity of the Fallopian tubes, with the peritoneum; and, through the os uteri, with the lining of the vagina.

In the body of the uterus it is smooth, soft, of a pale red colour, lined by columnar ciliated epithelium, and presents, when viewed with a lens, the orifices of numerous tubular follicles arranged perpendicularly to the surface. It is unprovided with any submucosa, but is intimately connected with the innermost layer of the muscular coat, which by some anatomists is regarded as the *muscularis mucosæ*. In structure the corium differs from ordinary mucous membrane, consisting of an embryonic nucleated and highly cellular form of connective tissue in which run numerous large lymphatics. In it are the tube-like *uterine glands*, which are of small size in the unimpregnated uterus, but shortly after impregnation become enlarged, elongated, presenting a contorted or waved appearance towards their closed extremities, which reaches into the muscularis, and may be single or bifid. They consist of a delicate membrane, lined by an epithelium, which becomes ciliated towards the orifices. In the impregnated uterus the epithelium loses its ciliated character, is thicker and tougher, and is provided with a submucous layer of areolar tissue.

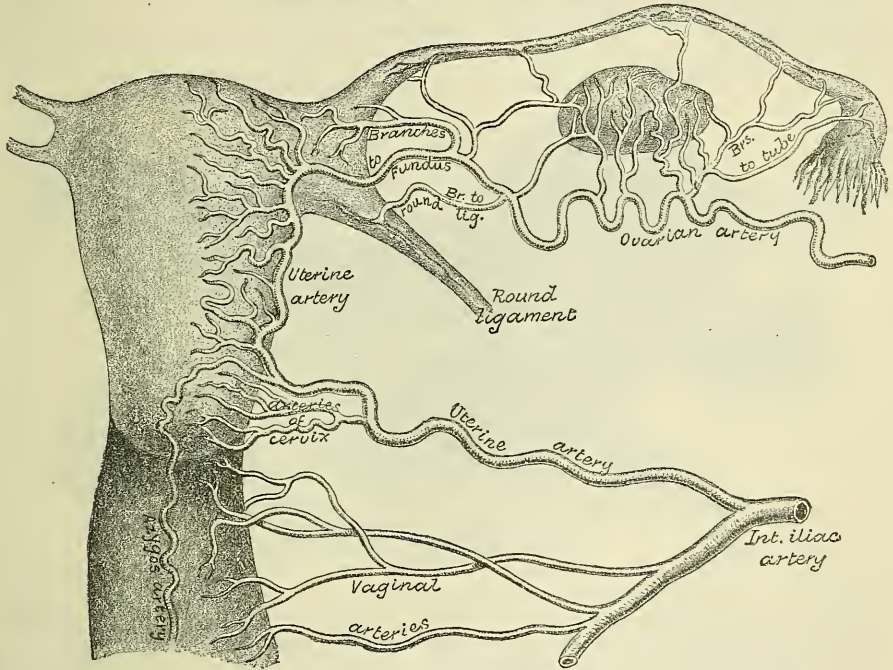
In the cervix the mucous membrane is sharply differentiated from that of the uterine cavity. It is thrown into numerous transverse folds, which are arranged



along an anterior and posterior longitudinal raphé, presenting an appearance which has received the name of *arbor vitæ*. In the upper two-thirds of the canal, the mucous membrane is provided with numerous deep glandular follicles, which secrete a clear viscid alkaline mucus; and in addition, extending through the whole length of the canal, are a variable number of little cysts, presumably follicles, which have become occluded and distended with retained secretion. They are called the *ovula Nabothi*. The mucous membrane covering the lower half of the cervical canal presents numerous papillæ. The epithelium of the upper two-thirds is cylindrical and ciliated, but below this it loses its cilia, and gradually changes to squamous epithelium close to the external os.

**Vessels and nerves.**—The arteries of the uterus are the uterine, from the internal iliac; and the ovarian, from the aorta. They are remarkable for their tortuous course in the substance of the organ, and for their frequent anastomoses. The termination of the ovarian artery meets the termination of the uterine

FIG. 683.—The arteries of the internal organs of generation of the female, seen from behind. (After Hyrtl.)



artery, and forms an anastomotic trunk from which branches are given off to supply the uterus, their disposition being, as shown by Sir John Williams, circular. The veins are of large size, and correspond with the arteries. In the impregnated uterus these vessels are termed the *uterine sinuses*, consisting of the lining membrane of the veins adhering to the walls of canals channelled through the substance of the uterus. They terminate in the uterine plexuses. The lymphatics of the body terminate in the lumbar glands, those of the cervix in the pelvic glands. The nerves are derived from the inferior hypogastric and ovarian plexuses, and from the third and fourth sacral nerves.

The form, size, and situation of the uterus vary at different periods of life and under different circumstances.

*In the fœtus* the uterus is contained in the abdominal cavity, projecting beyond the brim of the pelvis. The cervix is considerably larger than the body.

*At puberty* the uterus is pyriform in shape, and weighs from eight to ten drachms. It has descended into the pelvis, the fundus being just below the level of the brim of this cavity. The *arbor vitæ* is distinct, and extends to the upper part of the cavity of the organ.



*During menstruation* the organ is enlarged, and more vascular, its surfaces rounder; the os externum is rounded, its labia swollen, and the lining membrane of the body thickened, softer, and of a darker colour. According to Sir J. Williams, at each recurrence of menstruation a molecular disintegration of the mucous membrane takes place, which leads to its complete removal, only the bases of the glands embedded in the muscle being left. At the cessation of menstruation, by a proliferation of the remaining structures a fresh mucous membrane is formed.

*During pregnancy* the uterus becomes enormously enlarged, and in the ninth month reaches the epigastric region. The increase in size is partly due to growth of pre-existing muscle, and partly to development of new fibres.

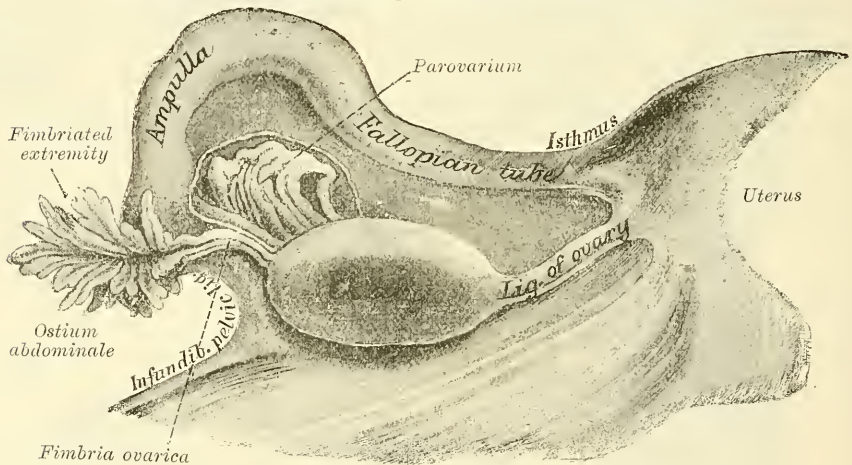
*After parturition* the uterus nearly regains its usual size, weighing about an ounce and a half; but its cavity is larger than in the virgin state; the external orifice is more marked; its edges present a fissured surface; its vessels are tortuous; and its muscular layers are more defined.

*In old age* the uterus becomes atrophied, and paler and denser in texture; a more distinct constriction separates the body and cervix. The ostium internum and, occasionally, the vaginal orifice often become obliterated, and its labia almost entirely disappear.

#### APPENDAGES OF THE UTERUS

The **appendages of the uterus** are the Fallopian tubes, the ovaries and their ligaments, and the round ligaments. They are placed in the following order: in

FIG. 684.—Uterine appendages, seen from behind. (Henle.)



front is the round ligament; the Fallopian tube occupies the upper margin of the broad ligament; the ovary and its ligament are behind and below both.

The **Fallopian tubes**, or **oviducts**, convey the ova from the ovaries to the cavity of the uterus. They are two in number, one on each side, situated in the upper margin of the broad ligament, extending from each superior angle of the uterus to the side of the pelvis. Each tube is about four inches in length; and is described as consisting of three portions: (1) the *isthmus*, or inner constricted half; (2) the *ampulla*, or outer dilated portion, which curves over the ovary; and (3) the *infundibulum* with its *ostium abdominale*, surrounded by fimbriæ, one of which is attached to the ovary, the *fimbria ovarica*. The general direction of the Fallopian tube is outwards, backwards, and downwards. The uterine opening is minute, and will only admit a fine bristle; the abdominal opening is comparatively much larger. In connection with the fimbriæ of the Fallopian tube, or with the broad ligament close to them, there is frequently one or more small vesicles, floating on a long stalk of peritoneum. These are termed the *hydatids of Morgagni*.

**Structure.**—The Fallopian tube consists of three coats: serous, muscular, and mucous.

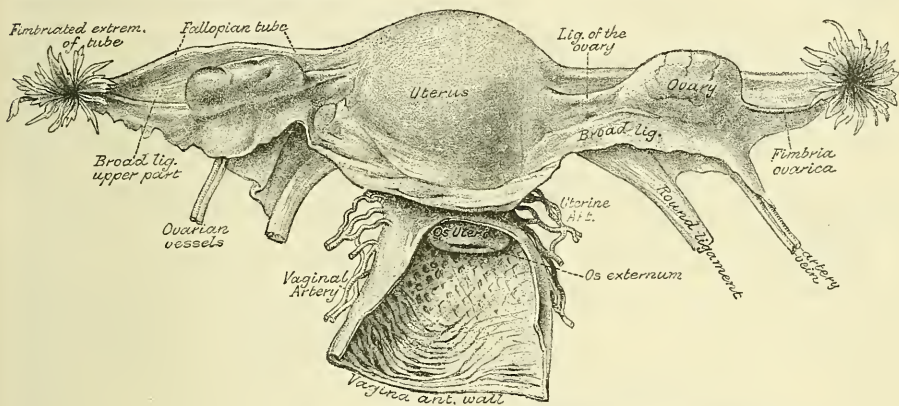
The *external* or *serous coat* is peritoneal.

The *middle* or *muscular coat* consists of an external longitudinal and an internal circular layer of muscular fibres continuous with those of the uterus.

The *internal* or *mucous coat* is continuous with the mucous lining of the uterus, and, at the free extremity of the tube, with the peritoneum. It is thrown into longitudinal folds, which in the outer, larger part of the tube, or ampulla, are much more extensive than in the narrow canal of the isthmus. The lining epithelium is columnar ciliated. This form of epithelium is also found on the inner surface of the fimbriæ; while on the outer or serous surfaces of these processes the epithelium gradually merges into the endothelium of the peritoneum.

The **ovaries** (*testes muliebres*, Galen) are analogous to the testes in the male. They are oval-shaped bodies, of an elongated form, flattened from above downwards, situated one on each side of the uterus, in the posterior part of the broad ligament behind and below the Fallopian tubes. Each ovary is connected, by its anterior straight margin, to the broad ligament; by its lower extremity, to the

FIG. 685.—The uterus and its appendages. Posterior view. The parts have been somewhat displaced from their proper position in the preparation of the specimen; thus the right ovary has been raised above the Fallopian tube, and the fimbriated extremities of the tubes have been turned upwards and outwards. (From a preparation in the Museum of the Royal College of Surgeons.)



uterus by a proper ligament, the *ligament of the ovary*; and by its upper end to the fimbriated extremity of the Fallopian tube by the ovarian fimbria; its mesial and lateral surfaces and posterior convex border are free. The ovaries are of a greyish-pink colour, and present either a smooth or puckered, uneven surface. They are each about an inch and a half in length, three-quarters of an inch in width, and about a third of an inch thick; and weigh from one to two drachms.

The exact position of the ovary has been the subject of considerable difference of opinion, and writers differ much as to what is to be regarded as the normal position. Hasse has described it as being situated with its long axis transverse, or almost transverse, to the pelvic cavity. Schultze, on the other hand, believes that its long axis is antero-posterior. Kölliker asserts that the truth lies between these two views, and that the ovary is placed obliquely in the pelvis, its long axis lying parallel to the external iliac vessels, with its surface directed inwards and outwards, and its convex free border upwards. His has made some important observations on this subject, and his views are largely accepted. He teaches that the uterus rarely lies symmetrically in the middle of the pelvic cavity, but is generally inclined to one or other side, most frequently to the left, in the proportion of three to two. The position of the two ovaries varies according to the inclination of the uterus. When the uterus is inclined to the left, the ovary of this side lies with its long axis vertical and with one side closely applied to the



outer wall of the pelvis; while the ovary of the opposite side, being dragged upon by the inclination of the uterus, lies obliquely, its outer extremity being retained in close apposition to the side of the pelvis by the infundibulo-pelvic ligament (page 1105). When, on the other hand, the uterus is inclined to the right, the position of the two ovaries is exactly reversed, the right being vertical and the left oblique. In whichever position the ovary is placed, the Fallopian tube forms a loop around it, the uterine half ascending obliquely over it, and the outer half, including the dilated extremity, descending and bulging freely behind it. From this extremity the fimbriæ pass upwards on to the ovary and closely embrace it.

**Structure.**—The ovary consists of a number of Graafian vesicles, embedded in the meshes of a stroma or framework, and invested by a serous covering derived from the peritoneum.

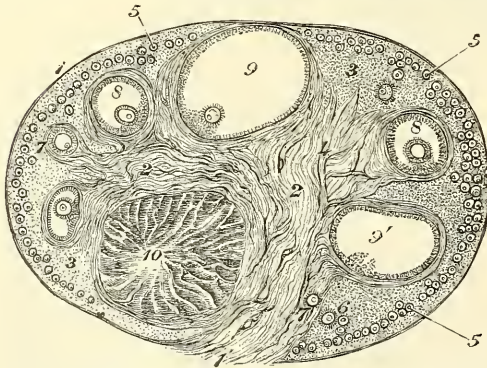
**Serous Covering.**—Though the investing membrane of the ovary is derived from the peritoneum, it differs essentially from that structure, inasmuch as its epithelium consists of a single layer of columnar cells, instead of the flattened endothelial cells on other parts of the membrane; this has been termed the *germinal epithelium of Waldeyer*, and gives to the surface of the ovary a dull grey aspect instead of the shining smoothness of serous membranes generally.

**Stroma.**—The stroma is a peculiar soft tissue, abundantly supplied with blood-vessels, consisting for the most part of spindle-shaped cells, with a small amount of ordinary connective tissue. These cells have been regarded by some anatomists as unstriped muscle cells, which, indeed, they most resemble (His); by others as connective-tissue cells (Waldeyer, Henle, and Kölliker). On the surface of the organ this tissue is much condensed, and forms a layer composed of short connective-tissue fibres, with fusiform cells between them. This was formerly regarded as a distinct fibrous covering, and was termed the *tunica albuginea*, but is nothing more than a condensed layer of the stroma of the ovary.

**Graafian vesicles.**—Upon making a section of an ovary, numerous round transparent vesicles of various sizes are to be seen; they are the *Graafian vesicles*,

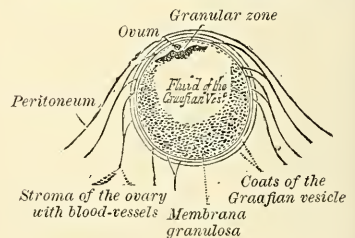
the ovisacs containing the ova. Immediately beneath the superficial covering is a layer of stroma, in which are a large number of minute vesicles, of uniform size, about  $\frac{1}{100}$  of an inch in diameter. These are

FIG. 686.—Section of the ovary. (After Schrön.)



1. Outer covering. 1' Attached border. 2. Central stroma.
3. Peripheral stroma. 4. Blood-vessels. 5. Graafian follicles in their earliest stage. 6, 7, 8. More advanced follicles. 9. An almost mature follicle. 10. Follicle from which the ovum has escaped.

FIG. 687.—Section of the Graafian vesicle. (After Von Baer.)



the Graafian vesicles in their earliest condition, and the layer where they are found has been termed the *cortical layer*. They are especially numerous in the ovary of the young child. After puberty, and during the whole of the child-bearing period, large and mature, or almost mature, Graafian vesicles are also found in the cortical layer in small numbers, and also 'corpora lutea,' the remains of vesicles which have burst and are undergoing atrophy and absorption. Beneath



this superficial stratum, other large and more mature Graafian vesicles are found embedded in the ovarian stroma. These increase in size as they recede from the surface towards a highly vascular stroma in the centre of the organ, termed the *medullary substance* (*zona vasculosa*, Waldeyer). This stroma forms the tissue of the hilum by which the ovary is attached, and through which the blood-vessels enter: it does not contain any Graafian vesicles.

The larger *Graafian vesicles* consist of an external fibro-vascular coat, connected with the surrounding stroma of the ovary by a network of blood-vessels; and an internal coat, named *ovicapsule*, which is lined by a layer of nucleated cells, called the *membrana granulosa*. The fluid contained in the interior of the vesicles is transparent and albuminous, and in it is suspended the ovum. In that part of the mature Graafian vesicle which is nearest the surface of the ovary, the cells of the *membrana granulosa* are collected into a mass which projects into the cavity of the vesicle. This is termed the *discus proligerus*, and in this the ovum is embedded.\*

The ova are formed from the germ-epithelium on the surface of the ovary: the cells become enlarged and involuted, forming little depressions on the surface of the ovary. As they sink deeper into the tissue they become enclosed by the outgrowth of processes from the stroma of the ovary, and, becoming surrounded, their connection with the surface is cut off, and the germ-epithelium forming the involution is contained in a cavity, the future Graafian follicle. The germ-cell or cells now form the ovum; the cell-wall forms the vitelline membrane; the nucleus, the germinal area; and a nucleolus, which soon appears, the germinal spot. A clear homogeneous protoplasm is formed within the cell, constituting the yolk, and thus the primordial ovum is developed. According to Dr. Foulis, the cells of the *membrana granulosa* are formed out of the nuclei of the fibro-cellular stroma of the ovary.†

The development and maturation of the Graafian vesicles and ova continue uninterruptedly from puberty to the end of the fruitful period of woman's life, while their formation commences before birth. Before puberty the ovaries are small, the Graafian vesicles contained in them are disposed in a comparatively thick layer in the cortical substance; here they present the appearance of a large number of minute closed vesicles, constituting the early condition of the Graafian vesicle; many, however, never attain full development, but shrink and disappear, their ova being incapable of impregnation. At puberty the ovaries enlarge, are more vascular, the Graafian vesicles are developed in greater abundance, and their ova are capable of fecundation.

**Discharge of the ovum.**—The Graafian vesicles, after gradually approaching the surface of the ovary, burst: the ovum and fluid contents of the vesicles are liberated, and escape on the exterior of the ovary, passing thence into the Fallopian tube.‡

In the fœtus, the ovaries are situated, like the testes, in the lumbar region, near the kidneys. They may be distinguished from those bodies at an early period by their elongated and flattened form, and by their position, which is at first oblique and then nearly transverse. They gradually descend into the pelvis.

Lying above the ovary in the broad ligament between it and the Fallopian tube is the *organ of Rosenmüller*, called also the *parovarium*. This is the remnant of a fœtal structure, the development of which has been described at a former page (page 114). In the adult it consists of a few closed convoluted tubes, lined with epithelium, which converge towards the ovary at one end and at the other are united by a longitudinal tube, the *epoophoron* or *duct of Gartner*. This duct terminates in a bulbous enlargement (see fig. 111). The parovarium is connected at its uterine extremity with the remains of the Wolffian duct.

\* For a description of the ovum, see page 72.

† *Proceedings of the Royal Society of Edinburgh*, April 1875.

‡ This is effected either by application of the tube to the ovary, or by a curling upwards of the fimbriated extremity, so that the ovum is caught as it falls.

The **ligament of the ovary** is a rounded cord, which extends from each superior angle of the uterus to the inner extremity of the ovary; it consists of fibrous tissue and a few muscular fibres derived from the uterus.

The **round ligaments** are two rounded cords between four and five inches in length, situated between the layers of the broad ligament in front of and below the Fallopian tube. Commencing on each side at the superior angle of the uterus, this ligament passes forwards, upwards, and outwards through the internal abdominal ring, along the inguinal canal to the labia majora, in which it becomes lost. The round ligament consists principally of muscular tissue, prolonged from the uterus; also of some fibrous and areolar tissue, besides blood-vessels and nerves, enclosed in a duplicature of peritoneum, which, in the fœtus, is prolonged in the form of a tubular process for a short distance into the inguinal canal. This process is called the *canal of Nuck*. It is generally obliterated in the adult, but sometimes remains pervious even in advanced life. It is analogous to the peritoneal pouch which accompanies the descent of the testis.

**Vessels and nerves.**—The *arteries of the ovaries and Fallopian tubes* are the ovarian from the aorta. They enter the attached border, or hilum, of the ovary. The *veins* follow the course of the arteries; they form a plexus near the ovary, the *pampiniform plexus*. The *nerves* are derived from the inferior hypogastric or pelvic plexus, and from the ovarian plexus, the Fallopian tube receiving a branch from one of the uterine nerves.

#### MAMMARY GLANDS

The **mammæ**, or breasts, are accessory glands of the generative system, which secrete the milk. They exist in the male as well as in the female; but in the former only in the rudimentary state, unless their growth is excited by peculiar circumstances. In the female they are two large hemispherical eminences situated towards the lateral aspect of the pectoral region, corresponding to the intervals between the third and sixth or seventh ribs, and extending from the side of the sternum to the axilla. Their weight and dimensions differ at different periods of life, and in different individuals. Before puberty they are of small size, but enlarge as the generative organs become more completely developed. They increase during pregnancy, and especially after delivery, and become atrophied in old age. The left mamma is generally a little larger than the right. Their base is nearly circular, flattened, or slightly concave, and has its long diameter directed upwards and outwards towards the axilla; they are separated from the Pectoral muscles by a layer of fascia. The outer surface of the mamma is convex, and presents, just below the centre, a small conical prominence, the nipple (*mammilla*). The surface of the nipple is dark-coloured, and surrounded by an areola having a coloured tint. In the virgin the areola is of a delicate rosy hue; about the second month after impregnation it enlarges and acquires a darker tinge, which increases as pregnancy advances, becoming in some cases of a dark brown, or even black colour. This colour diminishes as soon as lactation is over, but is never entirely lost throughout life. These changes in the colour of the areola are of importance in forming a conclusion in a case of suspected first pregnancy.

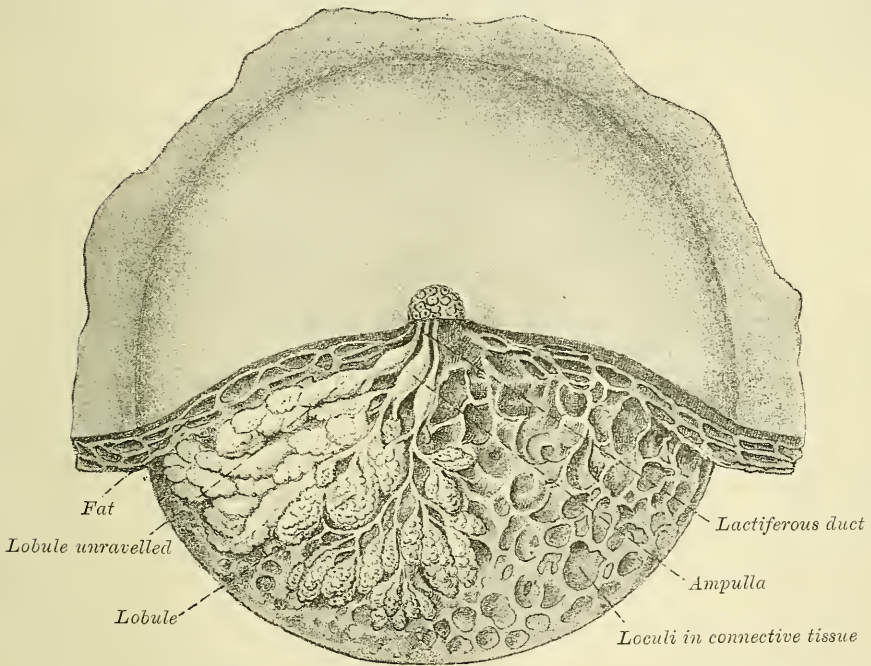
The **nipple** is a cylindrical or conical eminence, capable of undergoing a sort of erection from mechanical excitement, a change mainly due to the contraction of its muscular fibres. It is of a pink or brownish hue, its surface wrinkled and provided with papillæ; and it is perforated by numerous orifices, the apertures of the lactiferous ducts. Near the base of the nipple, and upon the surface of the areola, are numerous sebaceous glands, which become much enlarged during lactation, and present the appearance of small tubercles beneath the skin. These glands secrete a peculiar fatty substance, which serves as a protection to the integument of the nipple during the act of sucking. The nipple consists of numerous vessels, intermixed with plain muscular fibres which are principally



arranged in a circular manner around the base: some few fibres radiating from base to apex.

**Structure.**—The mamma consists of gland-tissue; of fibrous tissue, connecting its lobes; and of fatty tissue in the intervals between the lobes. The gland-tissue, when freed from fibrous tissue and fat, is of a pale reddish colour, firm in texture, circular in form, flattened from before backwards, thicker in the centre than at the circumference, and presenting several inequalities on its surface, especially in front. It consists of numerous lobes, and these are composed of lobules, connected together by areolar tissue, blood-vessels, and ducts. The smallest lobules consist of a cluster of rounded alveoli, which open into the smallest branches of the lactiferous ducts; these ducts uniting form larger ducts, which terminate in a single canal, corresponding with one of the chief subdivisions of the gland. The number of excretory ducts varies from fifteen to twenty; they are termed the *tubuli lactiferi*, or *galactophori*. They converge towards the

FIG. 688.—Dissection of the lower half of the female breast during the period of lactation. (From Luschka.)



areola, beneath which they form dilatations, or *ampullæ*, which serve as reservoirs for the milk, and, at the base of the nipple, become contracted, and pursue a straight course to its summit, perforating it by separate orifices considerably narrower than the ducts themselves. The ducts are composed of areolar tissue, with longitudinal and transverse elastic fibres, and longitudinal muscular fibres: their mucous lining is continuous, at the point of the nipple, with the integument. The epithelium of the mammary gland differs according to the state of activity of the organ. In the gland of a woman who is not pregnant or suckling, the alveoli are very small and solid, being filled with a mass of granular polyhedral cells. During pregnancy the alveoli enlarge, and the cells undergo rapid multiplication. At the commencement of lactation, the cells in the centre of the alveolus undergo fatty degeneration, and are eliminated in the first milk, as *colostrum corpuscles*. The peripheral cells of the alveolus remain, and form a single layer of granular, short columnar cells, with a spherical nucleus, lining the limiting membrana propria. These cells during the state of



activity of the gland, are capable of forming, in their interior, oil-globules, which are then ejected into the lumen of the alveolus, and constitute the milk-globules.

The *fibrous tissue* invests the entire surface of the breast, and sends down septa between its lobes, connecting them together.

The *fatty tissue* surrounds the surface of the gland, and occupies the interval between its lobes. It usually exists in considerable abundance, and determines the form and size of the gland. There is no fat immediately beneath the areola and nipple.

**Vessels and nerves.**—The *arteries* supplying the mammæ are derived from the thoracic branches of the axillary, the intercostals, and internal mammary. The *veins* describe an anastomotic circle round the base of the nipple, called by Haller the *circulus venosus*. From this, large branches transmit the blood to the circumference of the gland, and end in the axillary and internal mammary veins. The *lymphatics*, for the most part, run along the lower border of the Pectoralis major to the axillary glands; some few, from the inner side of the breast, perforate the intercostal spaces and empty themselves into the anterior mediastinal glands. The *nerves* are derived from the anterior and lateral cutaneous nerves of the thorax.

# THE SURGICAL ANATOMY OF INGUINAL HERNIA

*Dissection* (fig. 689).—For dissection of the parts concerned in inguinal hernia, a male subject, free from fat, should always be selected. The body should be placed in the supine position, the abdomen and pelvis raised by means of blocks placed beneath them, and the lower extremities rotated outwards, so as to make the parts as tense as possible. If the abdominal walls are flaccid, the cavity of the abdomen should be inflated by an aperture through the umbilicus. An incision should be made along the middle line, from the umbilicus to the symphysis pubis, and continued along the front of the scrotum; and a second incision, from the anterior superior spine of the ilium to just below the umbilicus. These incisions should divide the integument; and the triangular-shaped flap included between them should be reflected downwards and outwards, when the superficial fascia will be exposed.

**The superficial fascia of the abdomen.**—This, over the greater part of the abdominal wall, consists of a single layer of fascia, which contains a variable amount of fat; but as it approaches the groin it is easily divisible into two layers, between which are found the superficial vessels and nerves and the superficial inguinal lymphatic glands.

The *superficial layer* is thick, areolar in texture, containing adipose tissue in its meshes, the quantity of which varies in different subjects. Below it passes over Poupart's ligament, and is continuous with the outer layer of the superficial fascia of the thigh. In the male, this fascia is continued over the penis and over the outer surface of the cord to the scrotum, where it helps to form the dartos. As it passes to the penis and over the cord to the scrotum it changes its character, becoming thin, destitute of adipose tissue, and of a pale, reddish colour; and in the scrotum it acquires some involuntary muscular fibres. From the scrotum it may be traced backwards, to be continuous with the superficial fascia of the perinæum. In the female this fascia is continued into the labia majora.

The *hypogastric branch of the ilio-hypogastric nerve* perforates the aponeurosis of the External oblique muscle about an inch above and a little to the outer side of the external abdominal ring, and is distributed to the integument of the hypogastric region.

The *ilio-inguinal nerve* escapes at the external abdominal ring, and is distributed to the integument of the upper and inner part of the thigh; to the scrotum in the male and to the labium in the female.

The *superficial epigastric artery* arises from the femoral about half an inch below Poupart's ligament, and, passing through the saphenous opening in the fascia lata, ascends on to the abdomen, in the superficial fascia covering the External oblique muscle, nearly as high as the umbilicus. It distributes branches to the superficial inguinal lymphatic glands, the superficial fascia, and the integument, anastomosing with branches of the deep epigastric and internal mammary arteries.

The *superficial circumflex iliac artery*, the smallest of the cutaneous branches, arises close to the preceding, and, piercing the fascia lata, runs outwards, parallel with Poupart's ligament, as far as the crest of the ilium, dividing into branches which supply the superficial inguinal lymphatic glands, the superficial fascia and

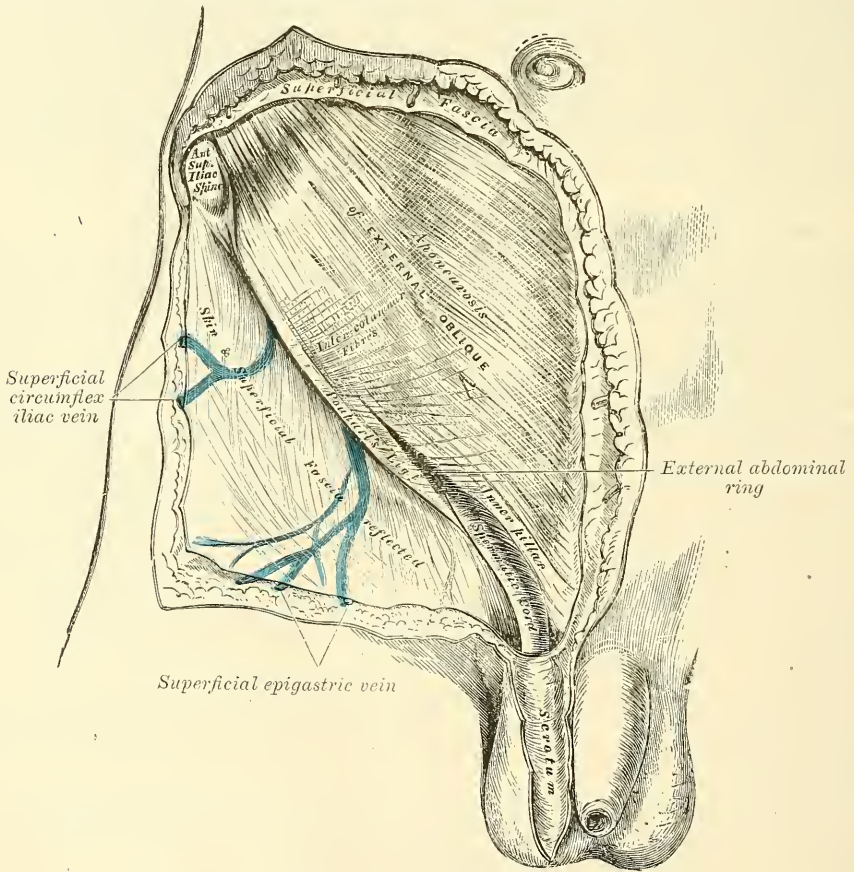
the integument, anastomosing with the deep circumflex iliac and with the gluteal and external circumflex arteries.

The *superficial external pudic (superior) artery* arises from the inner side of the femoral artery, close to the preceding vessels, and, after passing through the saphenous opening, courses inwards, across the spermatic cord, to be distributed to the integument on the lower part of the abdomen, the penis and scrotum in the male, and the labium in the female, anastomosing with branches of the internal pudic.

The *superficial veins*.—The veins accompanying these superficial vessels are usually much larger than the arteries: they terminate in the internal saphenous vein.

The *superficial inguinal lymphatic glands* are placed immediately beneath the integument, are of large size, and vary from eight to ten in number. They are

FIG. 689.—Inguinal hernia. Superficial dissection.



divisible into two groups: an upper, disposed irregularly along Poupart's ligament, which receive the lymphatic vessels from the integument of the scrotum, penis, parietes of the abdomen, perineal and gluteal regions, and the mucous membrane of the urethra; and an inferior group, which surround the saphenous opening in the fascia lata, a few being sometimes continued along the saphenous vein to a variable extent. This latter group receive the superficial lymphatic vessels from the lower extremity.

The *deep layer of the superficial fascia (fascia of Scarpa)* is thinner and more membranous in character than the superficial layer. In the middle line it is intimately adherent to the linea alba; above, it is continuous with the superficial



fascia over the rest of the trunk; below, it blends with the fascia lata of the thigh, a little below Poupart's ligament; below and internally, in the male, it is continued over the penis and over the outer surface of the cord to the scrotum, where it helps to form the dartos. From the scrotum it may be traced backwards to be continuous with the deep layer of the superficial fascia of the perinæum. In the female it is continuous with the labia majora.

The scrotum is a cutaneous pouch, which contains the testes and part of the spermatic cords, and into which an inguinal hernia frequently descends (see page 1089).

**The aponeurosis of the external oblique muscle.**—This is a thin, but strong membranous aponeurosis, the fibres of which are directed obliquely downwards and inwards. That portion of the aponeurosis which extends between the anterior superior spine of the ilium and the spine of the os pubis is a broad band, folded inwards and continuous below with the fascia lata; it is called *Poupart's ligament*. The portion which is reflected from Poupart's ligament at the spine of the os pubis, along the pectineal line, is called *Gimbernat's ligament*. From the point of attachment of the latter to the pectineal line, a few fibres pass upwards and inwards, behind the inner pillar of the ring to the linea alba. They diverge as they ascend, and form a thin, triangular, fibrous band, which is called the *triangular ligament of the abdomen*. In the aponeurosis of the External oblique, immediately above the crest of the os pubis, is a triangular opening, the *external or superficial abdominal ring*, formed by the separation of the fibres of the aponeurosis in this situation.

**The external or superficial abdominal ring.**—Just above and to the outer side of the crest of the os pubis, an interval is seen in the aponeurosis of the External oblique, called the *external abdominal ring*. This aperture is oblique in direction, somewhat triangular in form, and corresponds with the course of the fibres of the aponeurosis. It usually measures from base to apex about an inch, and transversely about half an inch. It is bounded below by the crest of the os pubis; above by a series of curved fibres, the *intercolumnar*, which pass across the upper angle of the ring, so as to increase its strength; and on either side, by the margins of the opening in the aponeurosis, which are called the *columns* or *pillars of the ring*.

The *external pillar*, which, at the same time, is *inferior* from the obliquity of its direction, is the stronger; it is formed by that portion of Poupart's ligament which is inserted into the spine of the os pubis; it is curved, so as to form a kind of groove, upon which the spermatic cord rests.

The *internal or superior pillar* is a broad, thin, flat band, which is attached to the front of the body of the os pubis, interlacing with its fellow of the opposite side, in front of the symphysis pubis, that of the right side being superficial.

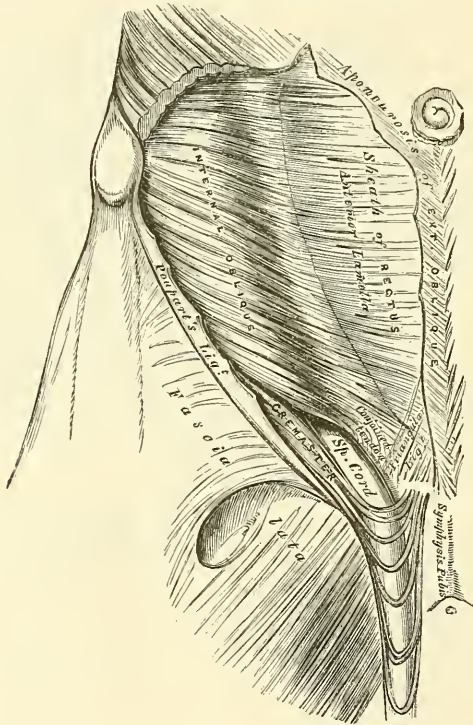
The external abdominal ring gives passage to the spermatic cord in the male, and round ligament in the female; it is much larger in men than in women, on account of the large size of the spermatic cord, and hence the great frequency of inguinal hernia in men.

The *intercolumnar fibres* are a series of curved tendinous fibres, which arch across the lower part of the aponeurosis of the External oblique. They have received their name from stretching across between the two pillars of the external ring; they increase the strength of the lower part of the aponeurosis, and prevent the divergence of the pillars from one another. They are thickest below, where they are connected to the outer third of Poupart's ligament; and are inserted into the linea alba, describing a curve, with the convexity downwards. They are much thicker and stronger at the outer angle of the external ring than internally, and are more strongly developed in the male than in the female. These intercolumnar fibres, as they pass across the external abdominal ring, are themselves connected together by delicate fibrous tissue, thus forming a fascia which, as it is attached to the pillars of the ring, covers it in, and is called the *intercolumnar fascia*. This intercolumnar fascia is continued downwards as a

tubular prolongation around the outer surface of the cord and testis, and encloses them in a distinct sheath; hence it is also called the *external spermatic fascia*. The sac of an inguinal hernia, in passing through the external abdominal ring, receives an investment from the intercolumar fascia.

If the finger is introduced a short distance into the external ring, and then if the limb is extended and rotated outwards, the aponeurosis of the External oblique, together with the iliac portion of the fascia lata, will be felt to become tense, and the external ring much contracted; if the limb is, on the contrary, flexed upon the pelvis and rotated inwards, this aponeurosis will become lax, and the external ring sufficiently enlarged to admit the finger with comparative ease; hence the patient should always be put in the latter position when the taxis is applied for the reduction of an inguinal hernia, in order that the abdominal walls may be relaxed as much as possible.

FIG. 690.—Inguinal hernia, showing the Internal oblique, Cremaster, and spermatic canal.



The aponeurosis of the External oblique should be removed by dividing it across in the same direction as the external incisions, and reflecting it downwards and outwards; great care is requisite in separating it from the aponeurosis of the muscle beneath. The lower part of the Internal oblique and the Cremaster are then exposed, together with the inguinal canal, which contains the spermatic cord (fig. 690). The mode of insertion of Poupart's and Gimbernat's ligaments into the os pubis should also be examined.

**Poupart's ligament**, or the crural arch, is the lower border of the aponeurosis of the External oblique muscle, which extends from the anterior superior spine of the ilium to the spine of the os pubis. From this latter point it is reflected outwards to be attached to the pectineal line for about half an inch, forming Gimbernat's ligament. Its general direction is curved downwards towards the thigh, where it is continuous with the fascia lata. Its outer half is rounded and oblique in direction: its inner half gradually widens at its attachment to the os pubis, is more horizontal in direction, and lies beneath the spermatic cord.

**Gimbernat's ligament** (fig. 698) is that portion of the External oblique muscle



which is reflected downwards and outwards from the spine of the os pubis to be inserted into the pectineal line. It is about half an inch in length, larger in the male than in the female, almost horizontal in direction in the erect posture, and of a triangular form, with the base directed outwards. Its base or outer margin is concave, thin, and sharp, and lies in contact with the crural sheath, forming the inner boundary of the crural ring (see fig. 698). Its apex corresponds to the spine of the os pubis. Its posterior margin is attached to the pectineal line, and is continuous with the pubic portion of the fascia lata. Its anterior margin is continuous with Poupart's ligament.

The **triangular ligament of the abdomen** is a band of tendinous fibres, of a triangular shape, which is attached by its apex to the pectineal line, where it is continuous with Gimbernat's ligament. It passes inwards beneath the spermatic cord, and expands into a somewhat fan-shaped fascia, lying behind the inner pillar of the external abdominal ring, and in front of the conjoined tendon, and interlaces with the ligament of the other side at the linea alba.

The **Internal oblique muscle** has been previously described (page 451). The part which is now exposed is partly muscular and partly tendinous in structure. Those fibres which arise from Poupart's ligament, few in number, and paler in colour than the rest, arch downwards and inwards across the spermatic cord, and, becoming tendinous, are inserted conjointly with those of the Transversalis into the crest of the os pubis and pectineal line, forming what is known as the conjoined tendon of the Internal oblique and Transversalis. This tendon is inserted immediately behind the external abdominal ring, serving to protect what would otherwise be a weak point in the abdominal wall. Sometimes this tendon is insufficient to resist the pressure from within, and is carried forwards in front of the protrusion through the external ring, forming one of the coverings of direct inguinal hernia; or the hernia forces its way through the fibres of the conjoined tendon.

The **Cremaster** is a thin muscular layer, composed of a number of fasciculi which arise from the middle of Poupart's ligament at the inner side of the Internal oblique, being connected with that muscle, and also occasionally with the Transversalis. It passes along the outer side of the spermatic cord, descends with it through the external ring upon the front and sides of the cord, and forms a series of loops, which differ in thickness and length in different subjects. Those at the upper part of the cord are exceedingly short, but they become in succession longer and longer, the longest reaching down as low as the testicle, where a few are inserted into the tunica vaginalis. These loops are united together by areolar tissue, and form a thin covering over the cord and testis, the *fascia cremasterica*. The fibres ascend along the inner side of the cord, and are inserted by a small pointed tendon into the crest of the os pubis, and front of the sheath of the Rectus muscle.

It will be observed that the origin and insertion of the Cremaster is precisely similar to that of the lower fibres of the Internal oblique. This fact affords an easy explanation of the manner in which the testicle and cord are invested by this muscle. At an early period of foetal life the testis is placed at the lower and back part of the abdominal cavity, but during its descent towards the scrotum, which takes place before birth, it passes beneath the arched border of the Internal oblique. In its passage beneath this muscle some fibres are derived from its lower part, which accompany the testicle and cord into the scrotum.

It occasionally happens that the loops of the Cremaster surround the cord, some lying behind as well as in front. It is probable that, under these circumstances, the testis, in its descent, passes through, instead of beneath, the fibres of the Internal oblique.

In the descent of an oblique inguinal hernia, which takes the same course as the spermatic cord, the Cremaster muscle forms one of its coverings. This muscle becomes largely developed in cases of hydrocele and large old scrotal herniæ. No such muscle exists in the female, but an analogous structure is

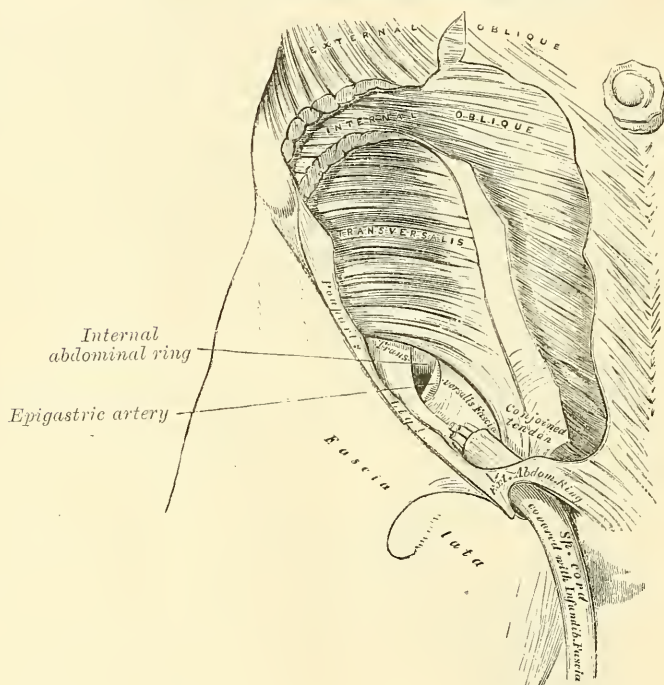


developed in those cases where an oblique inguinal hernia descends beneath the margin of the Internal oblique.

The Internal oblique should be detached from Poupart's ligament, separated from the Transversalis to the same extent as in the previous incisions, and reflected inwards on to the sheath of the Rectus (fig. 691). The circumflex iliac vessels, which lie between these two muscles, form a valuable guide to their separation.

The **Transversalis muscle** has been previously described (page 453). The part which is now exposed is partly muscular and partly tendinous; this portion arises from the outer third of Poupart's ligament, its fibres curve downwards and inwards, and are inserted together with those of the Internal oblique into the lower part of the linea alba, into the crest of the os pubis and pectineal line, forming what is known as the conjoined tendon of the Internal oblique and

FIG. 691.—Inguinal hernia, showing the Transversalis muscle, the transversalis fascia, and the internal abdominal ring.



Transversalis. Between the lower border of this muscle and Poupart's ligament, a space is left in which is seen the fascia transversalis.

The **inguinal or spermatic canal** contains the spermatic cord in the male, and the round ligament in the female. It is an oblique canal, about an inch and a half in length, directed downwards and inwards, and placed parallel with, and a little above, Poupart's ligament. It commences, above, at the internal abdominal ring, which is the point where the cord enters the spermatic canal; and terminates, below, at the external ring. It is bounded, *in front*, by the integument and superficial fascia, by the aponeurosis of the External oblique throughout its whole length, and by the Internal oblique for its outer third; *behind*, by the triangular ligament, the conjoined tendon of the Internal oblique and Transversalis, transversalis fascia, and the subperitoneal fat and peritoneum; *above*, by the arched fibres of the Internal oblique and Transversalis; *below*, by the union of the fascia transversalis with Poupart's ligament. That form of protrusion in which the intestine follows the course of the spermatic cord along the spermatic canal is called *oblique inguinal hernia*.

The **fascia transversalis** is a thin aponeurotic membrane, which lies between the inner surface of the Transversalis muscle and the peritoneum. It forms part of the general layer of fascia which lines the interior of the abdominal and pelvic cavities, and is directly continuous with the iliac and pelvic fasciæ.

In the inguinal region, the transversalis fascia is thick and dense in structure, and joined by fibres from the aponeurosis of the Transversalis muscle; but it becomes thin and cellular as it ascends to the Diaphragm. Below, it has the following attachments: external to the femoral vessels it is connected to the posterior margin of Poupart's ligament, and is there continuous with the iliac fascia. Internal to the vessels it is thin, and attached to the os pubis and pectineal line behind the conjoined tendon, with which it is united; and, corresponding to the points where the femoral vessels pass into the thigh, this fascia descends in front of them, forming the anterior wall of the crural sheath. The spermatic cord in the male, and the round ligament in the female, pass through this fascia; the point where they pass through is called the internal or deep abdominal ring. This opening is not visible externally owing to a prolongation of the transversalis fascia on these structures, forming the infundibuliform fascia.

The **internal or deep abdominal ring** is situated in the transversalis fascia, midway between the anterior superior spine of the ilium and the symphysis pubis, and about half an inch above Poupart's ligament. It is of an oval form, the extremities of the oval directed upwards and downwards; it varies in size in different subjects, and is much larger in the male than in the female. It is bounded, above and externally, by the arched fibres of the Transversalis muscle, below and internally by the deep epigastric vessels. It transmits the spermatic cord in the male, and the round ligament in the female. From its circumference a thin, funnel-shaped membrane, the *infundibuliform fascia*, is continued round the cord and testis, enclosing them in a distinct pouch. When the sac of an oblique inguinal hernia passes through the internal or deep abdominal ring, the infundibuliform process of the transversalis fascia forms one of its coverings.

**The subperitoneal areolar tissue.**—Between the fascia transversalis and the peritoneum is a quantity of loose areolar tissue. In some subjects it is of considerable thickness, and loaded with adipose tissue. Opposite the internal ring it is continued round the surface of the cord, forming a loose sheath for it.

The *deep epigastric artery* arises from the external iliac artery a few lines above Poupart's ligament. It at first descends to reach this ligament, and then ascends obliquely along the inner margin of the internal or deep abdominal ring, lying between the transversalis fascia and the peritoneum, and passing upwards pierces the transversalis fascia and enters the sheath of the Rectus muscle just below the semilunar fold of Douglas. Consequently the deep epigastric artery bears a very important relation to the internal abdominal ring, as it passes obliquely upwards and inwards, from its origin from the external iliac. In this part of its course it lies along the lower and inner margin of the internal ring, and beneath the commencement of the spermatic cord. As it winds round the internal abdominal ring it is crossed by the vas deferens in the male, and by the round ligament in the female.

The **peritoneum**, corresponding to the inner surface of the internal ring, presents a well-marked depression, the depth of which varies in different subjects. A thin fibrous band is continued from it along the front of the cord for a variable distance, and becomes ultimately lost. This is the remains of the pouch of peritoneum which, in the fœtus, accompanies the cord and testis into the scrotum; the obliteration of which commences soon after birth. In some cases the fibrous band can only be traced a short distance; but occasionally it may be followed, as a fine cord, as far as the upper end of the tunica vaginalis. Sometimes the tube of peritoneum is only closed at intervals, and presents a sacculated appearance; or a single pouch may extend along the whole length of the cord,

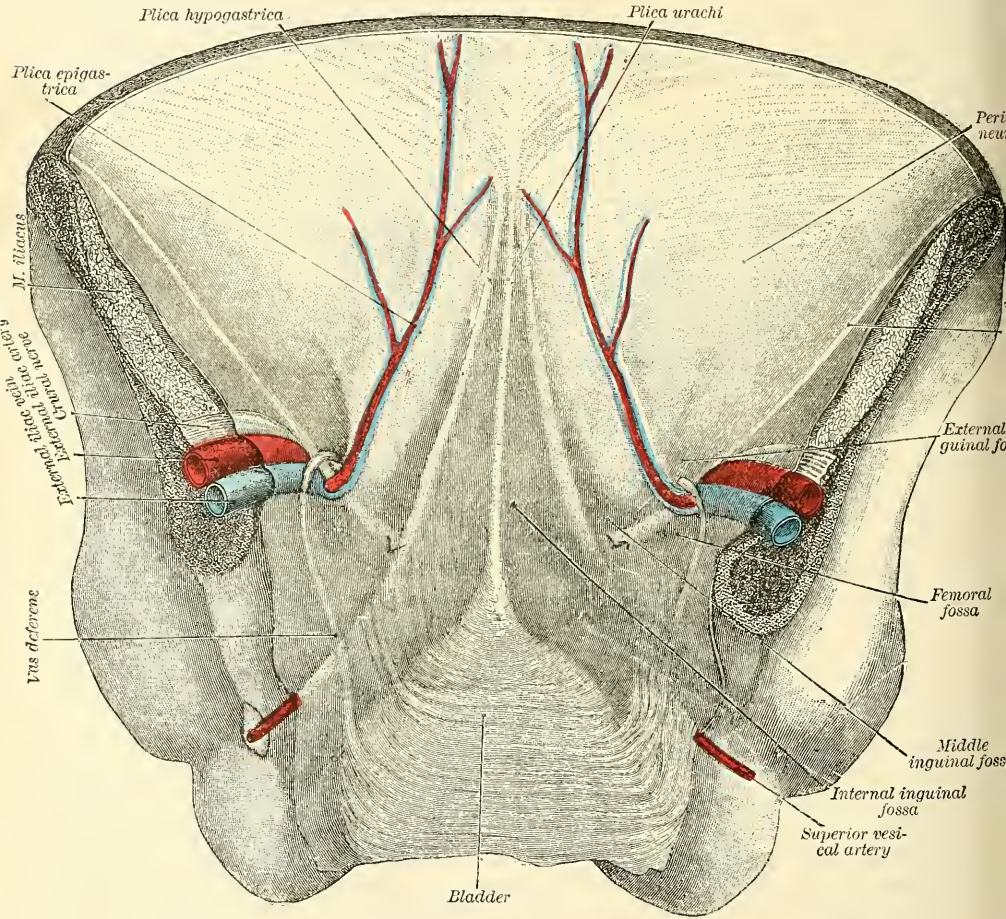


which may be closed above; or the pouch may be directly continuous with the peritoneum by an opening at its upper part.

In the female (in the foetus) the peritoneum is also prolonged in the form of a tubular process for a short distance into the inguinal canal. This process is called the canal of Nuck. It is generally obliterated in the adult, but sometimes it remains pervious even in advanced life. It is analogous to the peritoneal pouch which accompanies the descent of the testis.

In order to understand the relation of the peritoneum to inguinal hernia, it is necessary to view the anterior abdominal wall from its internal aspect, when it will be seen as shown in fig. 692. Between the upper margin of the front

FIG. 692.—Posterior view of the anterior abdominal wall in its lower half. The peritoneum is in place, and the various cords are shining through. (After Joessel.)



of the pelvis and the umbilicus, the peritoneum, when viewed from behind, will be seen to be raised into five vertical folds, with intervening depressions, by more or less prominent bands which converge to the umbilicus. One of these is situated in the median line, and is caused by the urachus, the remnant of the allantois; it extends from the summit of the bladder to the umbilicus. The fold of peritoneum covering it is known as the *plica urachi*. On either side of this is a prominent band, caused by the obliterated hypogastric artery, which extends from the side of the bladder obliquely upwards and inwards to the umbilicus. This is covered by a fold of peritoneum, which is known as the *plica hypogastrica*. To either side of these three cords is the deep epigastric



artery, which ascends obliquely upwards and inwards from a point midway between the symphysis pubis and the anterior superior spine of the ilium to the semilunar fold of Douglas, beneath which it disappears. It is covered by a fold of peritoneum, which is known as the *plica epigastrica*. Between these raised folds are depressions of the peritoneum, constituting so-called fossæ. The most internal, between the plica urachi and the plica hypogastrica, is known as the *internal inguinal fossa* (*fovea supravesicalis*). The middle one is situated between the plica hypogastrica and the plica epigastrica, and is termed the *middle inguinal fossa* (*fovea inguinalis mesialis*). The external one is external to the plica epigastrica, and is known as the *external inguinal fossa* (*fovea inguinalis lateralis*). Occasionally the deep epigastric artery corresponds in position to the obliterated hypogastric artery, and then there is but one fold, and the two external fossæ are merged into one. In the usual condition of the parts the floor of the external inguinal fossa corresponds to the internal abdominal ring, and into this fossa an oblique inguinal hernia descends. To the inner side of the plica epigastrica are the two internal fossæ, and through either of these a direct hernia may descend, as will be explained in the sequel (page 1126). The whole of this space, that is to say, the space between the deep epigastric artery, the margin of the Rectus and Poupart's ligament, is commonly known as *Hesselbach's triangle*. These three depressions or fossæ are situated above the level of Poupart's ligament, and in addition to them is another below the ligament, corresponding to the position of the femoral ring, and into which a femoral hernia descends.

#### INGUINAL HERNIA

**Inguinal hernia** is that form of protrusion which makes its way through the abdomen in the inguinal region.

There are two principal varieties of inguinal hernia—external or oblique, and internal or direct.

*External or oblique inguinal hernia*, the more frequent of the two, takes the same course as the spermatic cord. It is called *external*, from the neck of the sac being on the outer or iliac side of the deep epigastric artery.

*Internal or direct inguinal hernia* does not follow the same course as the cord, but protrudes through the abdominal wall on the inner or pubic side of the deep epigastric artery.

#### OBLIQUE INGUINAL HERNIA

In **oblique inguinal hernia** the intestine escapes from the abdominal cavity at the internal ring, pushing before it a pouch of peritoneum, which forms the hernial sac (fig. 694, A). As it enters the inguinal canal it receives an investment from the subserous areolar tissue, and is enclosed in the infundibuliform process of the transversalis fascia. In passing along the inguinal canal it displaces upwards the arched fibres of the Transversalis and Internal oblique muscles, and is surrounded by the fibres of the Cremaster. It then passes along the front of the cord, and escapes from the inguinal canal at the external ring, receiving an investment from the intercolumnar fascia. Lastly, it descends into the scrotum, receiving coverings from the superficial fascia and the integument.

The coverings of this form of hernia, after it has passed through the external ring, are, from without inwards, the integument, superficial fascia, intercolumnar fascia, Cremaster muscle, infundibuliform fascia, subserous areolar tissue, and peritoneum.

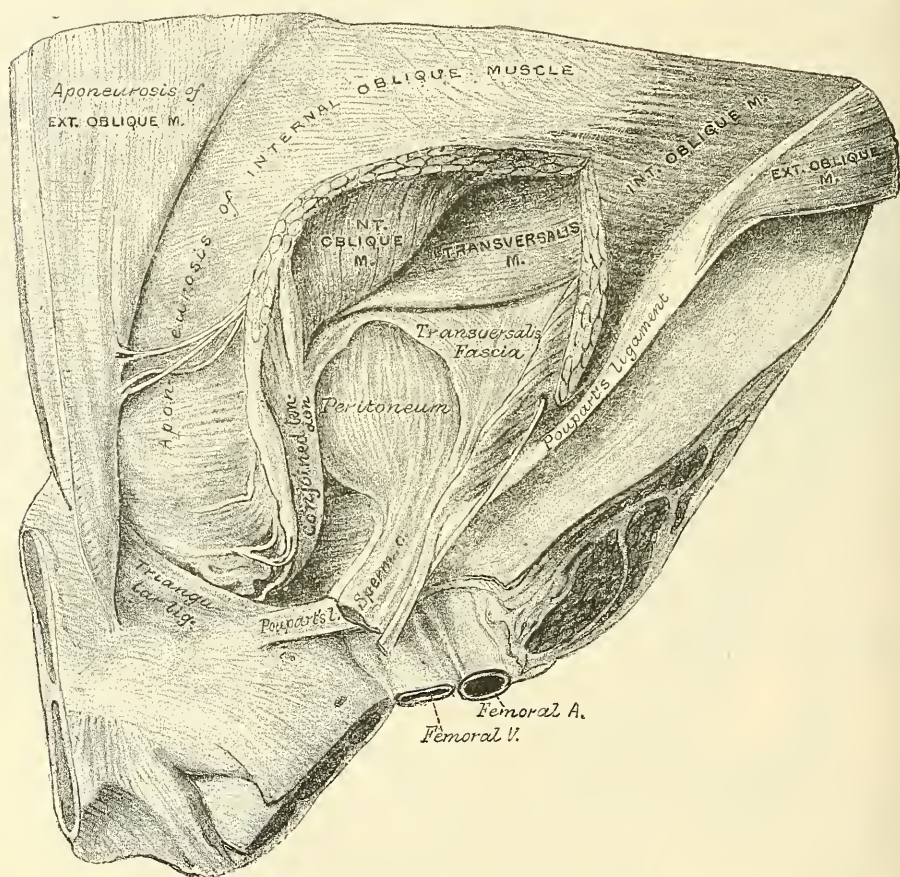
This form of hernia lies in front of the vessels of the spermatic cord, and seldom extends below the testis, on account of the intimate adhesion of the coverings of the cord to the tunica vaginalis.

The *seat of stricture* in oblique inguinal hernia is either at the external ring; in the inguinal canal, caused by the fibres of the Internal oblique or Transversalis;

or at the internal ring; most frequently in the latter situation. If it is situated at the external ring, the division of a few fibres at one point of its circumference is all that is necessary for the replacement of the hernia. If in the inguinal canal, or at the internal ring, it may be necessary to divide the aponeurosis of the External oblique so as to lay open the inguinal canal. In dividing the stricture, the direction of the incision should be upwards.

When the intestine passes along the spermatic canal, and escapes from the external ring into the scrotum, it is called *complete oblique inguinal*, or *scrotal hernia*. If the intestine does not escape from the external ring, but is retained in

FIG. 693.—Oblique inguinal hernia, showing its various coverings. (From a preparation in the Museum of the Royal College of Surgeons.)



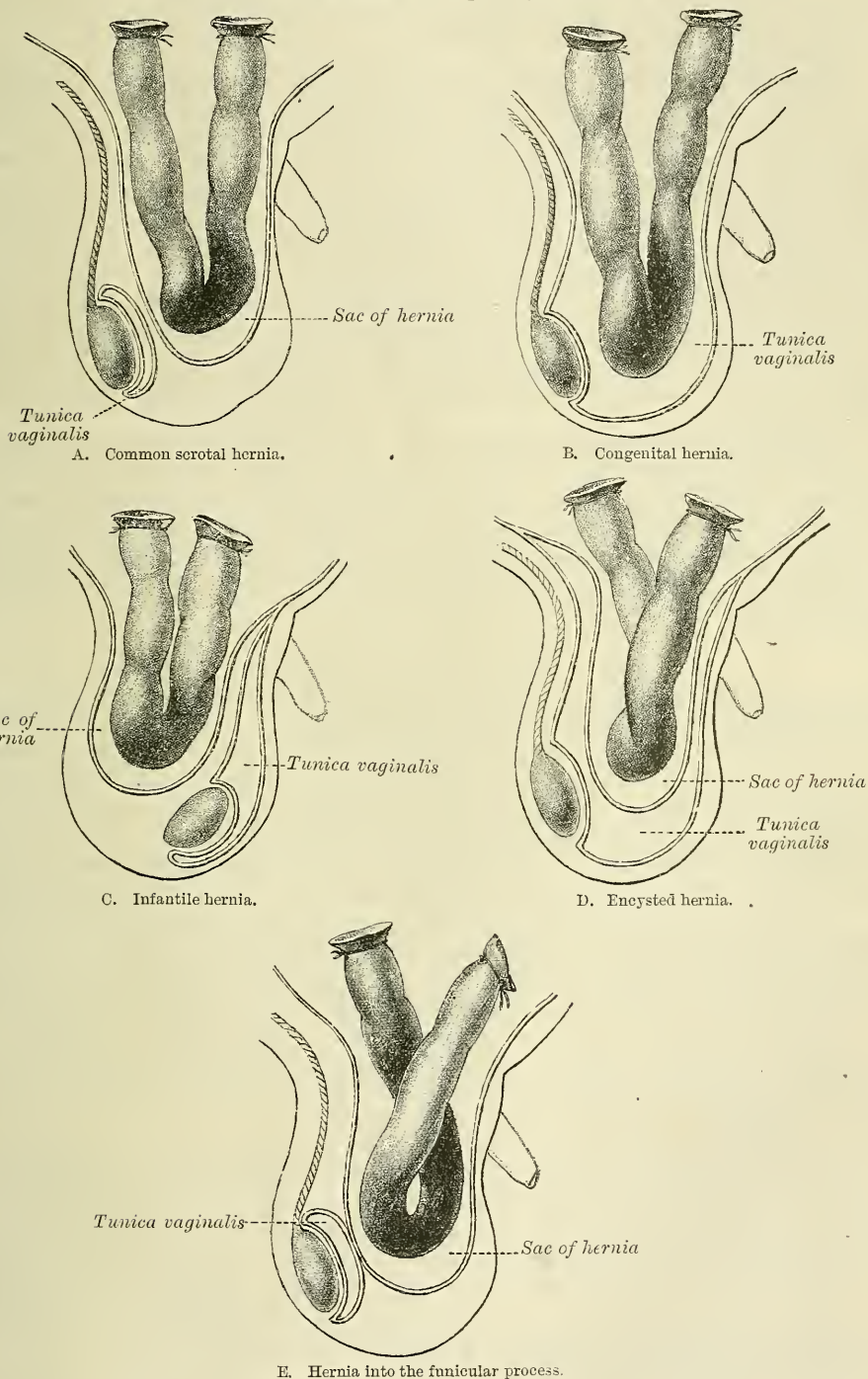
the inguinal canal, it is called *incomplete inguinal hernia*, or *bubonocoele*. In each of these cases, the coverings which invest it will depend upon the extent to which it descends in the inguinal canal.

There are some other varieties of oblique inguinal hernia depending upon congenital defects in the processus vaginalis. The testicle in its descent from the abdomen into the scrotum is accompanied by a pouch of peritoneum, which about the period of birth becomes shut off from the general peritoneal cavity by a closure of that portion of the pouch which extends from the internal abdominal ring to near the upper part of the testicle; the lower portion of the pouch remaining persistent as the tunica vaginalis. It would appear that this closure commences at two points, viz. at the internal abdominal ring, and at the top of the epididymis, and gradually extends until, in the normal condition, the whole of the intervening portion is converted into a fibrous cord. From failure in the



completion of this process, variations in the relation of the hernial protrusion to the testicle and tunica vaginalis are produced, which constitute distinct varieties

FIG. 694.—Varieties of oblique inguinal hernia.



of inguinal hernia, and which have received separate names, and are of surgical importance. These are congenital, infantile, encysted, and hernia of the funicular process.



**Congenital hernia** (fig. 694, B).—Where the pouch of peritoneum which accompanies the cord and testis in its descent remains patent throughout, and is unclosed at any point, the cavity of the tunica vaginalis communicates directly with the peritoneum. The intestine descends along this pouch into the cavity of the tunica vaginalis, which constitutes the sac of the hernia, and the gut lies in contact with the testicle.

**Infantile and encysted hernia.**—Where the pouch of peritoneum is occluded at the internal ring only, and remains patent throughout the rest of its extent, two varieties of oblique inguinal hernia may be produced, which have received the names of infantile and encysted hernia. In the *infantile* form (fig. 694, c) the bowel pressing upon the septum and the peritoneum in its immediate neighbourhood causes it to yield and form a sac, which descends behind the tunica vaginalis; so that, in front of the bowel, there are three layers of peritoneum, the two layers of the tunica vaginalis and its own sac. In the *encysted* form (fig. 694, d) pressure in the same position—namely, at the occluded spot in the pouch—causes the septum to yield and form a sac which projects *into* and not *behind* the tunica vaginalis, as in the infantile form, and thus it constitutes a sac within a sac, so that in front of the bowel there are two layers of peritoneum, one layer of the tunica vaginalis and its own sac.

**Hernia into the funicular process** (fig. 694, E).—Where the pouch of peritoneum is occluded at the lower point only, that is, just above the testicle, the intestine descends into the pouch of peritoneum as far as the testicle, but is prevented from entering the sac of the tunica vaginalis by the septum which has formed between it and the pouch, so that it resembles the congenital form in all respects, except that, instead of enveloping the testicle, that body can be felt below the rupture.

#### DIRECT INGUINAL HERNIA

In **direct inguinal hernia** the protrusion makes its way through some part of the abdominal wall internal to the epigastric artery.

At the lower part of the abdominal wall is a triangular space (*Hesselbach's triangle*), bounded, externally, by the deep epigastric artery; internally, by the margin of the Rectus muscle; below, by Poupart's ligament. The conjoined tendon is stretched across the inner two-thirds of this space, the remaining portion of the space having only the subperitoneal areolar tissue, and the transversalis fascia between the peritoneum and the aponeurosis of the External oblique muscle.

In some cases the hernial protrusion escapes from the abdomen on the outer side of the conjoined tendon, pushing before it the peritoneum, the subserous areolar tissue, and the transversalis fascia. It then enters the inguinal canal, passing along nearly its whole length, and finally emerges from the external ring, receiving an investment from the intercolumnar fascia. The coverings of this form of hernia are precisely similar to those investing the oblique form, with the insignificant difference that the infundibuliform fascia is replaced by a portion derived from the general layer of the fascia transversalis.

In other cases, and this is the more frequent variety, the hernia is either forced through the fibres of the conjoined tendon, or the tendon is gradually distended in front of it, so as to form a complete investment for it. The intestine then enters the lower end of the inguinal canal, escapes at the external ring, lying on the inner side of the cord, and receives additional coverings from the superficial fascia and the integument. This form of hernia has the same coverings as the oblique variety, excepting that the conjoined tendon is substituted for the Cremaster, and the infundibuliform fascia is replaced by a portion derived from the general layer of the fascia transversalis.

The difference between the position of the neck of the sac in these two forms of direct inguinal hernia has been referred, with some probability, to a difference in the relative positions of the obliterated hypogastric artery and the deep epigastric artery. When the course of the obliterated hypogastric artery corre-

sponds pretty nearly with that of the deep epigastric, the projection of these arteries towards the cavity of the abdomen produces two fossæ in the peritoneum. The bottom of the external fossa of the peritoneum corresponds to the position of the internal abdominal ring, and a hernia which distends and pushes out the peritoneum lining this fossa is an oblique hernia. When, on the other hand, the obliterated hypogastric artery lies considerably to the inner side of the deep epigastric artery, corresponding to the outer margin of the conjoined tendon, it divides the triangle of Hesselbach into two parts, so that three depressions will be seen on the inner surface of the lower part of the abdominal wall: viz. an external one, on the outer side of the deep epigastric artery; a middle one, between the deep epigastric and the obliterated hypogastric arteries; and an internal one, on the inner side of the obliterated hypogastric artery (see page 1122). In such a case a hernia may distend and push out the peritoneum forming the bottom of either fossa. When the hernia distends and pushes out the peritoneum forming the bottom of the external fossa, it is an oblique or external inguinal hernia. When the hernia distends and pushes out the peritoneum forming the bottom of either the middle or the internal fossa, it is a direct or internal hernia. The anatomical difference between these two forms of direct or internal inguinal hernia is that, when the hernia protrudes through the middle fossa—that is, the fossa between the deep epigastric and the obliterated hypogastric arteries—it will enter the upper part of the inguinal canal; consequently its coverings will be the same as those of an oblique hernia, with the insignificant difference that the infundibuliform fascia is replaced by a portion derived from the general layer of the fascia transversalis, whereas when the hernia protrudes through the internal fossa it is either forced through the fibres of the conjoined tendon, or the tendon is gradually distended in front of it, so as to form a complete investment for it. The intestine then enters the lower part of the inguinal canal, and escapes from the external abdominal ring lying on the inner side of the cord.

This form of hernia has the same coverings as the oblique variety, excepting that the conjoined tendon is substituted for the Cremaster, and the infundibuliform fascia is replaced by a portion derived from the general layer of the fascia transversalis.

The *seat of stricture* in both varieties of direct hernia is most frequently at the neck of the sac, or at the external ring. In that form of hernia which perforates the conjoined tendon, it not unfrequently occurs at the edges of the fissure through which the gut passes. In dividing the stricture, the incision should in all cases be directed upwards.\*

If the hernial protrusion passes into the inguinal canal, but does not escape from the external abdominal ring, it forms what is called *incomplete direct hernia*. This form of hernia is usually of small size, and in corpulent persons very difficult of detection.

Direct inguinal hernia is of much less frequent occurrence than the oblique, their comparative frequency being, according to Cloquet, as one to five. It occurs far more frequently in men than in women, on account of the larger size of the external ring in the former sex. It differs from the oblique in its smaller size and globular form, dependent most probably on the resistance offered to its progress by the transversalis fascia and conjoined tendon. It differs also in its position, being placed over the os pubis, and not in the course of the inguinal canal. The deep epigastric artery runs on the outer or iliac side of the neck of the sac, and the spermatic cord along its external and posterior side, not directly behind it, as in oblique inguinal hernia.

\* In all cases of inguinal hernia, whether oblique or direct, it is proper to divide the stricture directly upwards; the reason of this is obvious, for by cutting in this direction the incision is made parallel to the deep epigastric artery—either external to it, in the oblique variety; or internal to it, in the direct form of hernia; and thus all chance of wounding the vessel is avoided. If the incision was made outwards, the artery might be divided if the hernia was direct; and if made inwards it would stand an equal chance of injury if the case was one of oblique inguinal hernia.

# SURGICAL ANATOMY OF FEMORAL HERNIA

The dissection of the parts comprised in the anatomy of femoral hernia should be performed, if possible, upon a female subject free from fat. The subject should lie upon its back; a block is first placed under the pelvis, the thigh everted, and the knee slightly bent, and retained in this position. An incision should then be made from the anterior superior spinous process of the ilium along Poupart's ligament to the symphysis pubis; a second incision should be carried transversely across the thigh about six inches beneath the preceding; and these are to be connected together by a vertical one carried along the inner side of the thigh. These several incisions should divide merely the integument; this is to be reflected outwards, when the superficial fascia will be exposed.

The **superficial fascia** forms a continuous layer over the whole of the thigh, consisting of areolar tissue, containing in its meshes much fat, and capable of being separated into two or more layers, between which are found the superficial vessels and nerves. It varies in thickness in different parts of the limb. In the groin it is thick, and the two layers are separated from one another by the superficial inguinal lymphatic glands, the internal saphenous vein, and several smaller vessels. One of these layers, the superficial, is continuous with the superficial fascia of the abdomen.

The superficial layer should be detached by dividing it across in the same direction as the external incisions; its removal will be facilitated by commencing at the lower and inner angle of the space, detaching it at first from the front of the internal saphenous vein, and dissecting it off from the anterior surface of that vessel and its tributaries; it should then be reflected outwards, in the same manner as the integument. The cutaneous vessels and nerves, and superficial inguinal glands, are then exposed, lying upon the deep layer of the superficial fascia. These are the internal saphenous vein, and the superficial epigastric, superficial circumflex iliac, and superficial external pudic vessels, as well as numerous lymphatics ascending with the saphenous vein to the inguinal glands.

The *internal or long saphenous vein* ascends along the inner side of the thigh, and, passing through the saphenous opening in the fascia lata, terminates in the femoral vein about an inch and a half below Poupart's ligament. This vein receives, at the saphenous opening, the superficial epigastric, the superficial circumflex iliac, and the superficial external pudic veins.

The *superficial external pudic artery* (superior) arises from the inner side of the femoral artery, and, after passing through the saphenous opening, courses inwards, across the spermatic cord, to be distributed to the integument on the lower part of the abdomen, the penis and scrotum in the male, and the labium in the female, anastomosing with branches of the internal pudic.

The *superficial epigastric artery* arises from the femoral, about half an inch below Poupart's ligament, and, passing through the saphenous opening in the fascia lata, ascends on to the abdomen, in the superficial fascia covering the External oblique muscle, nearly as high as the umbilicus. It distributes branches to the superficial inguinal lymphatic glands, the superficial fascia, and the integument, anastomosing with branches of the deep epigastric and internal mammary arteries.

The *superficial circumflex iliac artery*, the smallest of the cutaneous branches, arises close to the preceding, and, piercing the fascia lata, runs outwards, parallel with Poupart's ligament, as far as the crest of the ilium, dividing into branches which supply the superficial inguinal lymphatic glands, the superficial fascia and

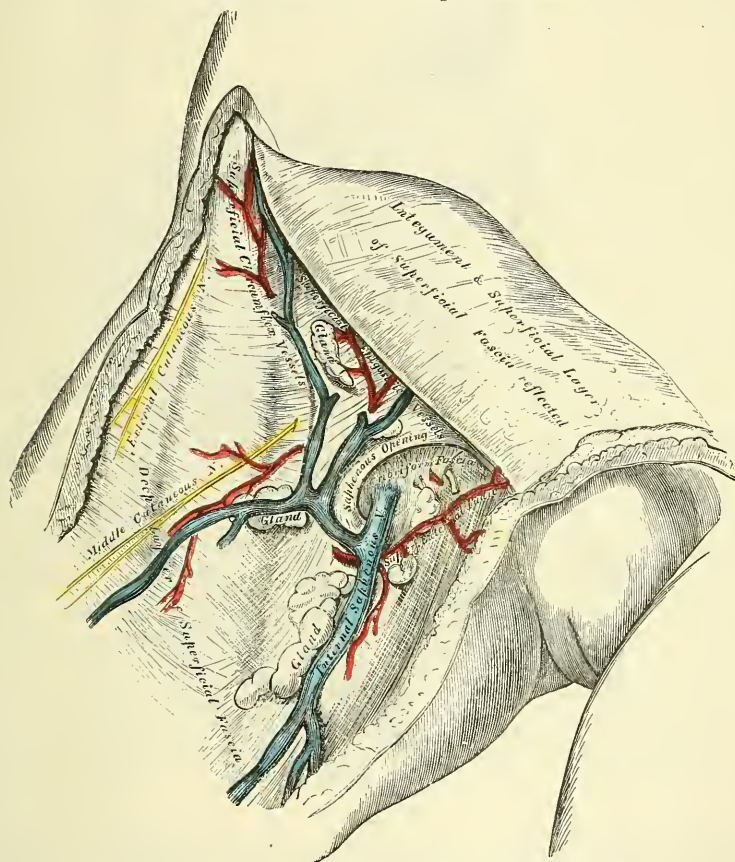


the integument of the groin, anastomosing with the deep circumflex iliac, and with the gluteal and external circumflex arteries.

*The superficial veins.*—The veins accompanying these superficial arteries are usually much larger than the arteries: they terminate in the internal or long saphenous vein at the saphenous opening.

The *superficial inguinal lymphatic glands*, placed immediately beneath the integument, are of large size, and vary from eight to ten in number. They are divisible into two groups: an upper, disposed irregularly along Poupart's ligament, which receive the lymphatic vessels from the integument of the scrotum, penis, parietes of the abdomen, perineal and gluteal regions, and the mucous membrane of the urethra; and an inferior group, which surround the saphenous opening in

FIG. 695.—Femoral hernia. Superficial dissection.



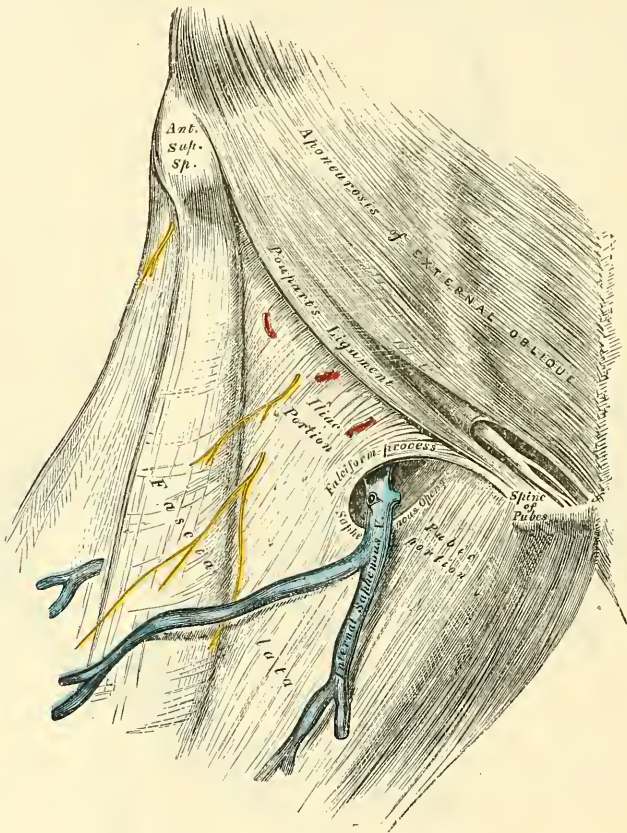
the fascia lata, a few being sometimes continued along the saphenous vein to a variable extent. This latter group receive the superficial lymphatic vessels from the lower extremity.

The *ilio-inguinal nerve* arises from the first lumbar nerve. It escapes at the external abdominal ring, and is distributed to the integument of the upper and inner part of the thigh: to the scrotum in the male, and to the labium in the female. The size of this nerve is in inverse proportion to that of the ilio-hypogastric. Occasionally it is very small, and ends by joining the ilio-hypogastric: in such cases a branch of the ilio-hypogastric takes the place of the ilio-inguinal, or the latter nerve may be altogether absent. The *crural branch of the genito-crural nerve* passes along the inner margin of the Psoas muscle, beneath Poupart's ligament, into the thigh, entering the sheath of the femoral vessels, and lying superficial and a little external to the femoral artery. It pierces the anterior

layer of the sheath of the vessels, and, becoming superficial by passing through the fascia lata, it supplies the skin of the anterior aspect of the thigh as far as midway between the pelvis and knee. On the front of the thigh it communicates with the outer branch of the middle cutaneous nerve, derived from the anterior crural.

The *deep layer of the superficial fascia* is a very thin fibrous layer, best marked on the inner side of the long saphenous vein and below Poupart's ligament. It is placed beneath the subcutaneous vessels and nerves, and upon the surface of the fascia lata, to which it is intimately adherent at the lower margin of Poupart's ligament. It covers the saphenous opening in the fascia lata, is closely united to its circumference, and is connected to the sheath of the femoral vessels corre-

FIG. 696.—Femoral hernia, showing fascia lata and saphenous opening.



sponding to its under surface. The portion of fascia covering this aperture is perforated by the internal saphenous vein, and by numerous blood and lymphatic vessels; hence it has been termed the *cribriform fascia*, the openings for these vessels having been likened to the holes in a sieve. The cribriform fascia adheres closely both to the superficial fascia and to the fascia lata, so that it is described by some anatomists as a part of the fascia lata, but it is usually considered (as in this work) as belonging to the superficial fascia. It is not till the cribriform fascia has been cleared away that the saphenous opening is seen, so that this opening does not in ordinary cases exist naturally, but is the result of dissection. A femoral hernia, in passing through the saphenous opening, receives the cribriform fascia as one of its coverings.

The deep layer of superficial fascia, together with the cribriform fascia, having been removed, the fascia lata is exposed.

The **fascia lata** has been already described with the muscles of the front of the thigh (page 510). At the upper and inner part of the thigh, a little below



Poupart's ligament, a large oval-shaped aperture is observed after the superficial fascia has been cleared away; it transmits the internal saphenous vein and other smaller vessels, and is called the *saphenous opening*. In order the more correctly to consider the mode of formation of this aperture, the fascia lata in this part of the thigh is described as consisting of two portions, an iliac portion and a pubic portion.

The *iliac portion* is all that part of the fascia lata on the outer side of the saphenous opening. It is attached externally to the crest of the ilium and its anterior superior spine; to the whole length of Poupart's ligament as far internally as the spine of the os pubis; and to the pectineal line in conjunction with Gimbernat's ligament. From the spine of the os pubis it is reflected downwards and outwards, forming an arched margin, the outer boundary, or falciform process or superior cornu of the saphenous opening. This margin overlies and is adherent to the anterior layer of the sheath of the femoral vessels; to its edge is attached the cribriform fascia, and, below, it is continuous with the pubic portion of the fascia lata.

The *pubic portion of the fascia lata* is situated at the inner side of the saphenous opening; at the lower margin of this aperture it is continuous with the iliac portion; traced upwards, it covers the surface of the Pectineus, Adductor longus, and Gracilis muscles; and, passing behind the sheath of the femoral vessels, to which it is closely united, is continuous with the sheath of the Psoas and Iliacus muscles, and is attached above to the ilio-pectineal line, where it becomes continuous with the fascia covering the Iliacus muscle. From this description it may be observed that the iliac portion of the fascia lata passes in front of the femoral vessels and the pubic portion behind them, so that an apparent aperture consequently exists between the two, through which the internal saphenous joins the femoral vein.

The **saphenous opening** is an oval-shaped aperture, measuring about an inch and a half in length, and half an inch in width. It is situated at the upper and inner part of the front of the thigh, below Poupart's ligament, and is directed obliquely downwards and outwards.

Its *outer margin* is of a semilunar form, thin, strong, sharply defined, and lies on a plane considerably anterior to the inner margin. If this edge is traced upwards, it will be seen to form a curved elongated process, the *falciform process*, or *superior cornu*, which ascends in front of the femoral vessels, and, curving inwards, is attached to Poupart's ligament and to the spine of the os pubis and pectineal line, where it is continuous with the pubic portion. If traced downwards, it is found continuous with another curved margin, the concavity of which is directed upwards and inwards: this is the inferior cornu of the saphenous opening, and is blended with the pubic portion of the fascia lata covering the Pectineus muscle.

The *inner boundary of the opening* is on a plane posterior to the outer margin and behind the level of the femoral vessels; it is much less prominent and defined than the outer, from being stretched over the subjacent Pectineus muscle. It is through the saphenous opening that a femoral hernia passes after descending along the crural canal.

If the finger is introduced into the saphenous opening while the limb is moved in different directions, the aperture will be found to be greatly constricted on extending the limb or rotating it outwards, and to be relaxed on flexing the limb and inverting it: hence the necessity for placing the limb in the latter position in employing the taxis for the reduction of a femoral hernia.

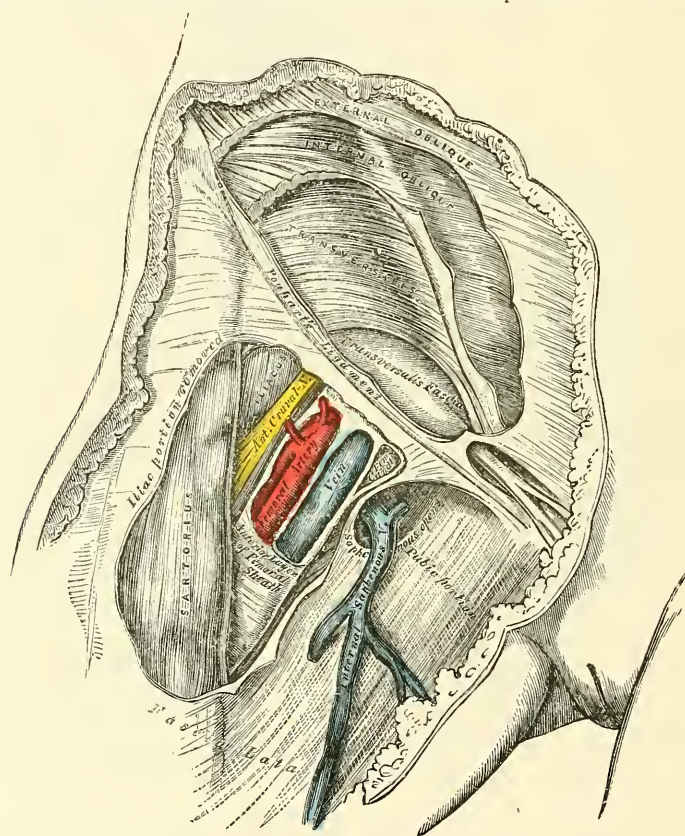
The iliac portion of the fascia lata, but not its falciform process, should now be removed by detaching it from the lower margin of Poupart's ligament, carefully dissecting it from the subjacent structures, and turning it inwards, when the sheath of the femoral vessel is exposed descending beneath Poupart's ligament (fig. 697).

**Poupart's ligament**, or the **crural arch**, is the lower border of the aponeurosis of the External oblique muscle, which extends from the anterior superior spine



of the ilium to the spine of the os pubis. From this latter point it is reflected outwards, to be attached to the pectineal line for about half an inch, forming Gimbernat's ligament. Its general direction is curved downwards towards the thigh, where it is continuous with the fascia lata. Its outer half is rounded and oblique in direction. Its inner half gradually widens at its attachment to the os pubis, is more horizontal in direction, and lies beneath the spermatic cord. Nearly the whole of the space included between the crural arch and innominate bone is filled in by the parts which descend from the abdomen into the thigh (fig. 698). The outer half of the space is occupied by the Iliacus and Psoas muscles, together with the external cutaneous and anterior crural nerves. The pubic half

FIG. 697.—Femoral hernia. Iliac portion of fascia lata removed, and sheath of femoral vessels and femoral canal exposed.

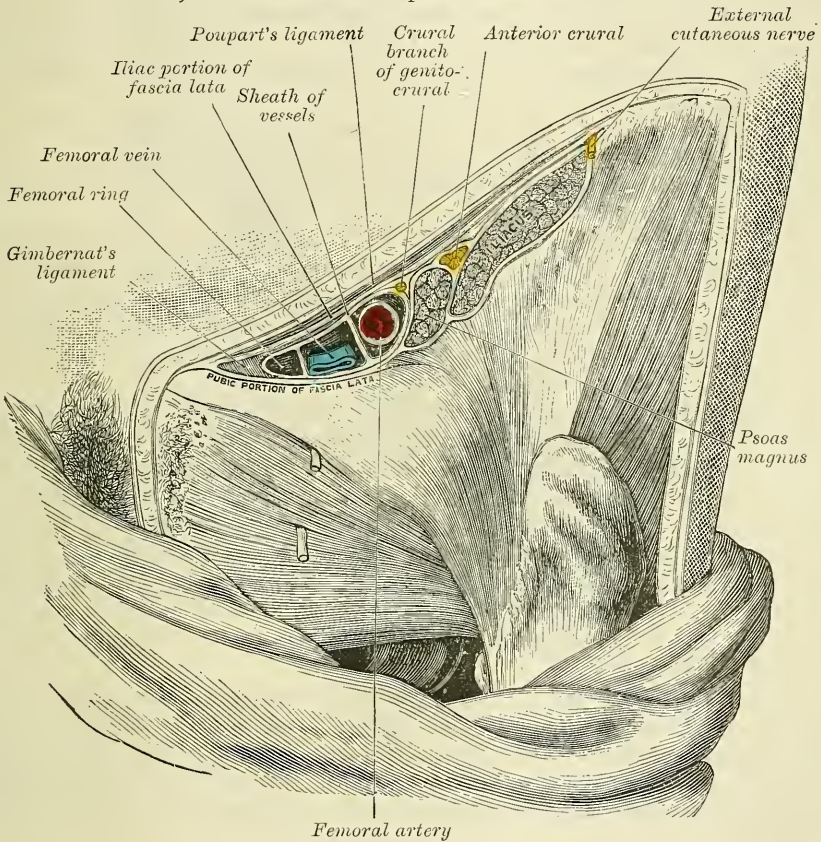


of the space is occupied by the femoral vessels included in their sheath; a small oval-shaped interval existing between the femoral vein and the inner wall of the sheath, which is occupied merely by a little loose areolar tissue, a few lymphatic vessels, and occasionally by a small lymphatic gland: this is the crural ring, through which the gut descends in femoral hernia.

**Gimbernat's ligament** (figs. 698, 699) is that part of the aponeurosis of the External oblique muscle which is reflected downwards and outwards, from the spine of the os pubis, to be inserted into the pectineal line. It is about half an inch in length, larger in the male than in the female, almost horizontal in direction in the erect posture, and of a triangular form, with the base directed outwards. Its *base*, or outer margin, is concave, thin, and sharp, and lies in contact with the crural sheath. Its *apex* corresponds to the spine of the os pubis. Its *posterior margin* is attached to the pectineal line, and is continuous with the pubic portion of the fascia lata. Its *anterior margin* is continuous with Poupart's ligament.

**Crural sheath.**—The femoral or crural sheath is a continuation downwards of the fasciæ that line the abdomen, the transversalis fascia passing down in front of the femoral vessels, and the iliac fascia descending behind them; these fasciæ are directly continuous on the iliac side of the femoral artery, but a small space exists between the femoral vein and the point where they are continuous on the pubic side of that vessel, which constitutes the femoral or crural canal. The femoral sheath is closely adherent to the contained vessels about an inch below the saphenous opening, being blended with the areolar sheath of the vessels, but opposite Poupart's ligament it is much larger than is required to contain them; hence the funnel-shaped form which it presents. The outer

FIG. 698.—Structures which pass beneath the crural arch.



border of the sheath is perforated by the genito-crural nerve. Its inner border is pierced by the internal saphenous vein and numerous lymphatic vessels. In front, it is covered by the iliac portion of the fascia lata; and behind it is the pubic portion of the same fascia.

If the anterior wall of the sheath is removed, the femoral artery and vein are seen lying side by side, a thin septum separating the two vessels, while another septum may be seen lying just internal to the vein, and cutting off a small space between the vein and the inner wall of the sheath. The septa are stretched between the anterior and posterior walls of the sheath, so that each vessel is enclosed in a separate compartment. The interval left between the vein and the inner wall of the sheath is not filled up by any structure, excepting a little loose areolar tissue, a few lymphatic vessels, and occasionally by a small lymphatic gland; this is the femoral or crural canal, through which the intestine descends in femoral hernia.



**Deep crural arch.**—Passing across the front of the crural sheath on the abdominal side of Poupart's ligament, and closely connected with it, is a thickened band of fibres, called the *deep crural arch*. It is apparently a thickening of the fascia transversalis, joining externally to the centre of Poupart's ligament, and arching across the front of the crural sheath, to be inserted by a broad attachment into the pectineal line, behind the conjoined tendon. In some subjects this structure is not very prominently marked, and not unfrequently it is altogether wanting.

The **crural canal** is the narrow interval between the femoral vein and the inner wall of the crural sheath. It exists as a distinct canal only when the sheath has been separated from the vein by dissection, or by the pressure of a hernia or tumour. Its length is from a quarter to half an inch, and it extends from Gimbernat's ligament to the upper part of the saphenous opening.

Its *anterior wall* is very narrow, and formed by a continuation downwards of the fascia transversalis, under Poupart's ligament, covered by the falciform process of the fascia lata.

Its *posterior wall* is formed by a continuation downwards of the iliac fascia covering the pubic portion of the fascia lata.

Its *outer wall* is formed by the fibrous septum separating it from the inner side of the femoral vein.

Its *inner wall* is formed by the junction of the processes of the transversalis and iliac fasciæ, which form the inner side of the femoral sheath, and lies in contact, at its commencement, with the outer edge of Gimbernat's ligament.

This canal has two orifices—an upper one, the *femoral or crural ring*, closed by the septum crurale; and a lower one, the *saphenous opening*, closed by the cribriform fascia.

The **femoral or crural ring** (fig. 699) is the upper opening of the femoral canal, and leads into the cavity of the abdomen. It is bounded, in front, by Poupart's ligament and the deep crural arch; behind, by the os pubis, covered by the Pectineus muscle, and the pubic portion of the fascia lata; internally, by the base of Gimbernat's ligament, the conjoined tendon, the transversalis fascia, and the deep crural arch; externally, by the fibrous septum lying on the inner side of the femoral vein. The femoral ring is of an oval form; its long diameter, directed transversely, measures about half an inch, and is larger in the female than in the male, which is one of the reasons of the greater frequency of femoral hernia in the former sex.

*Position of parts around the ring.*—The spermatic cord in the male, and round ligament in the female, lie immediately above the anterior margin of the femoral ring, and may be divided in an operation for femoral hernia if the incision for the relief of the stricture is not of limited extent. In the female this is of little importance, but in the male the spermatic artery and vas deferens may be divided.

The *femoral vein* lies on the outer side of the ring.

The *deep epigastric artery*, in its passage upwards and inwards from the external iliac artery, passes across the upper and outer angle of the crural ring, and is consequently in danger of being wounded if the stricture is divided in a direction upwards and outwards.

The *communicating branch* between the deep epigastric and obturator lies in front of the ring.

The circumference of the ring is thus seen to be bounded by vessels in every part, excepting internally and behind. It is in the former position that the stricture is divided in cases of strangulated femoral hernia.

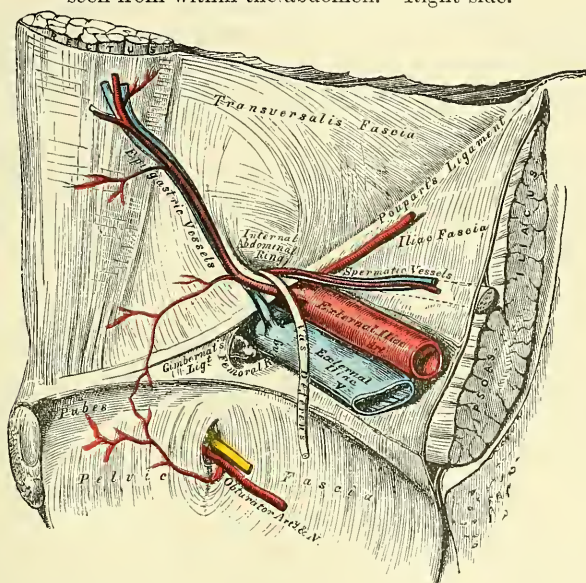
The *obturator artery*, when it arises by a common trunk with the deep epigastric, which occurs once in every three subjects and a half, bears a very important relation to the crural ring. In some cases it descends on the inner side of the external iliac vein to the obturator foramen, and will consequently lie on the outer side of the crural ring, where there is no danger of its being wounded in the operation for dividing the stricture in femoral hernia (see fig. 414, page



636, fig. A). Occasionally, however, the obturator artery curves along the free margin of Gimbernat's ligament in its passage to the obturator foramen; it would, consequently, skirt along the greater part of the circumference of the crural ring, and could hardly avoid being wounded in the operation (see fig. 414, page 636, fig. B).

**Septum crurale.**—The femoral ring is closed by a layer of condensed areolar tissue, called, by J. Cloquet, the *septum crurale*. This serves as a barrier to the protrusion of a hernia through this part. Its upper surface is slightly concave, and supports a small lymphatic gland, by which it is separated from the subserous areolar tissue and peritoneum. Its under surface is turned towards the femoral canal. The septum crurale is perforated by numerous apertures for the passage of lymphatic vessels, connecting the deep inguinal lymphatic glands with those surrounding the external iliac artery.

FIG. 699.—Hernia. The relations of the femoral and internal abdominal rings seen from within the abdomen. Right side.



The size of the femoral canal, the degree of tension of its orifices, and, consequently, the degree of constriction of a hernia, vary according to the position of the limb. If the leg and thigh are extended, abducted, or everted, the femoral canal and its orifices are rendered tense, from the traction on these parts by Poupert's ligament and the fascia lata, as may be ascertained by passing the finger along the canal. If, on the contrary, the thigh is flexed upon the pelvis, and at the same time adducted and rotated inwards, the femoral canal and its orifices become considerably relaxed; for this reason the limb should always be placed in the latter position when the application of the taxis is made in attempting the reduction of a femoral hernia.

The *subperitoneal areolar tissue* is continuous with the subserous areolar tissue of surrounding parts. It is usually thickest and most fibrous where the iliac vessels leave the abdominal cavity. It covers over the small interval (crural ring) on the inner side of the femoral vein. In some subjects it contains a considerable amount of adipose tissue. In such cases, where it is protruded forwards in front of the sac of a femoral hernia, it may be mistaken for a portion of omentum. The peritoneum lining the portion of the abdominal wall between Poupert's ligament and the brim of the pelvis is similar to that lining any other portion of the abdominal wall, being very thin. It has here no natural aperture for the escape of intestine.

**Descent of the hernia.**—From the preceding description it follows that the femoral ring must be a weak point in the abdominal wall: hence it is that, when violent or long-continued pressure is made upon the abdominal viscera, a portion of intestine may be forced into it, constituting a femoral hernia; and the changes in the tissues of the abdomen which are produced by pregnancy, together with the larger size of this aperture in the female, serve to explain the frequency of this form of hernia in women.

When a portion of the intestine is forced through the femoral ring, it carries before it a pouch of peritoneum, which forms what is called the *hernial sac*; it receives an investment from the subserous areolar tissue, and from the septum crurale, and descends vertically along the crural canal in the inner compartment of the sheath of the femoral vessels as far as the saphenous opening; at this point it changes its course, being prevented from extending farther down the sheath, on account of the narrowing of the sheath and its close contact with the vessels, and also from the close attachment of the superficial fascia and crural sheath to the lower part of the circumference of the saphenous opening; the tumour is, consequently, directed forwards, pushing before it the cribriform fascia, and then curves upwards on to the falciform process of the fascia lata and lower part of the tendon of the External oblique, being covered by the superficial fascia and integument. While the hernia is contained in the femoral canal, it is usually of small size, owing to the resisting nature of the surrounding parts; but when it has escaped from the saphenous opening into the loose areolar tissue of the groin, it becomes considerably enlarged. The direction taken by a femoral hernia in its descent is at first downwards, then forwards and upwards; this should be borne in mind, as in the application of the taxis for the reduction of a femoral hernia pressure should be directed in the reverse order.

**Coverings of the hernia.**—The coverings of a femoral hernia, from within outwards, are: peritoneum, subserous areolar tissue, the septum crurale, crural sheath, cribriform fascia, superficial fascia, and integument.\*

**Varieties of femoral hernia.**—If the intestine descends along the femoral canal only as far as the saphenous opening, and does not escape from this aperture, it is called *incomplete femoral hernia*. The small size of the protrusion in this form of hernia, on account of the firm and resisting nature of the canal in which it is contained, renders it an exceedingly dangerous variety of the disease, from the extreme difficulty of detecting the existence of the swelling, especially in corpulent subjects. The coverings of an incomplete femoral hernia would be, from without inwards: integument, superficial fascia, falciform process of fascia lata, crural sheath, septum crurale, subserous areolar tissue, and peritoneum. When, however, the hernial tumour protrudes through the saphenous opening, and directs itself forwards and upwards, it forms a *complete femoral hernia*. Occasionally the hernial sac descends on the iliac side of the femoral vessels, or in front of these vessels, or even sometimes behind them.

The *seat of stricture of a femoral hernia* varies: it may be in the peritoneum at the neck of the hernial sac; in the greater number of cases it would appear to be at the point of junction of the falciform process of the fascia lata with the lunated edge of Gimbernat's ligament; or at the margin of the saphenous opening in the thigh. The stricture should in every case be divided in a direction upwards and inwards; and the extent necessary in the majority of cases is about two or three lines. By these means, all vessels or other structures of importance, in relation with the neck of the hernial sac, will be avoided.

\* Sir Astley Cooper has described an investment for femoral hernia, under the name of 'fascia propria,' lying immediately external to the peritoneal sac, but frequently separated from it by more or less adipose tissue. Surgically, it is important to remember the existence (at any rate, the occasional existence) of this layer, on account of the ease with which an inexperienced operator may mistake the fascia for the peritoneal sac, and the contained fat for omentum. Anatomically, this fascia appears identical with what is called in the text 'subserous areolar tissue,' the areolar tissue being thickened and caused to assume a membranous appearance by the pressure of the hernia.

# SURGICAL ANATOMY OF THE ISCHIO-RECTAL REGION AND PERINÆUM

*Dissection.*—The student should select a well-developed muscular subject, free from fat, and the dissection should be commenced early, in order that the parts may be examined in as recent a state as possible. A staff having been introduced into the bladder, and the subject placed in the position shown in fig. 700, the scrotum should be raised upwards, and retained in that position, and the rectum moderately distended with tow.

The space which is now to be examined corresponds to the inferior aperture or outlet of the pelvis. Its deep boundaries are, in front, the pubic arch and subpubic ligament; behind, the tip of the coccyx; and on each side, the rami of the os pubis and ischium, the tuberosities of the ischium, and great sacro-sciatic ligaments. The space included by these boundaries is somewhat lozenge-shaped, and is limited on the surface of the body by the scrotum in front, by the buttocks behind, and on each side by the inner side of the thighs. A line drawn transversely between the anterior part of the tuberosity of the ischium, on each side, in front of the anus, divides this space into two portions. The anterior portion contains the penis and urethra, and is called the *perinæum*. The posterior portion contains the termination of the rectum, and is called the *ischio-rectal region*.

## ISCHIO-RECTAL REGION

The ischio-rectal region corresponds to the portion of the outlet of the pelvis situated immediately behind the perinæum: it contains the termination of the rectum and a deep fossa, filled with fat, on each side of the intestine, between it and the tuberosity of the ischium: this is called the *ischio-rectal fossa*.

The **ischio-rectal region** presents in the middle line the *aperture of the anus*; around this orifice the integument is thrown into numerous folds, which are obliterated on distension of the intestine. The integument is of a dark colour, continuous with the mucous membrane of the rectum, and provided with numerous follicles, which occasionally inflame and suppurate, and may be mistaken for fistulæ. The veins round the margin of the anus are occasionally much dilated, forming a number of hard pendent masses, of a dark bluish colour, covered partly by mucous membrane and partly by the integument. These tumours constitute the disease called *piles*.

*Dissection* (fig. 700).—Make an incision through the integument, along the median line, from the base of the scrotum to the anterior extremity of the anus: carry it round the margins of this aperture to its posterior extremity, and continue it backwards to about an inch behind the tip of the coccyx. A transverse incision should now be carried across the base of the scrotum, joining the anterior extremity of the preceding; a second, carried in the same direction, should be made in front of the anus; and a third at the posterior extremity of the first incision. These incisions should be sufficiently extensive to enable the dissector to raise the integument from the inner side of the thighs. The flaps of skin corresponding to the ischio-rectal region should now be removed. In dissecting the integument from this region great care is required, otherwise the Corrugator cutis ani and External sphincter will be removed, as they are intimately adherent to the skin.



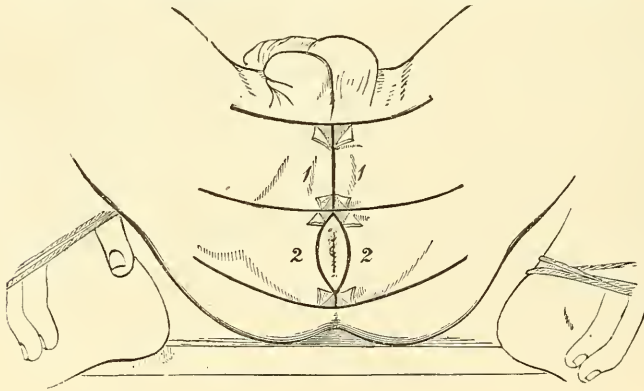
The **superficial fascia** is exposed on the removal of the skin : it is very thick, areolar in texture, and contains much fat in its meshes. In it are found ramifying two or three cutaneous branches of the small sciatic nerve ; these turn round the inferior border of the Gluteus maximus, and are distributed to the integument around the anus.

In this region, and connected with the lower end of the rectum, are four muscles : the Corrugator cutis ani ; the two Sphincters, External and Internal ; and the Levator ani.

These muscles have been already described (see page 459).

The **ischio-rectal fossa** is situated between the end of the rectum and the tuberosity of the ischium on each side. It is triangular in shape ; its base, directed to the surface of the body, is formed by the integument of the ischio-rectal region ; its *apex*, directed upwards, corresponds to the point of division of the obturator fascia, and the thin membrane given off from it, which covers the outer surface of the Levator ani (ischio-rectal or anal fascia). Its dimensions are about an inch in breadth at the base, and about two inches in depth, being deeper behind than in front. It is bounded, *internally*, by the Sphincter ani, Levator ani, and Coccygeus muscles ; *externally*, by the tuberosity of the ischium

FIG. 700.—Dissection of perinæum and ischio-rectal region.



and the obturator fascia, which covers the inner surface of the Obturator internus muscle ; *in front*, it is limited by the line of junction of the superficial and deep perineal fasciæ ; and *behind*, by the margin of the Gluteus maximus, and the great sacro-sciatic ligament. This space is filled with a large mass of adipose tissue, which explains the frequency with which abscesses in the neighbourhood of the rectum burrow to a considerable depth.

If the subject has been injected, on placing the finger on the outer wall of this fossa, the internal pudic artery, with its accompanying veins and nerve, will be felt about an inch and a half above the margin of the ischiatic tuberosity, but approaching nearer the surface as they pass forwards along the inner margin of the pubic arch. These structures are enclosed in a sheath (canal of Alcock) formed by the obturator fascia, the pudic nerve lying below the artery (fig. 415). Crossing the space transversely, about its centre, are the inferior hæmorrhoidal vessels and nerves, branches of the internal pudic ; they are distributed to the integument of the anus, and to the muscles of the lower end of the rectum. These vessels are occasionally of large size, and may give rise to troublesome hæmorrhage when divided in the operation of lithotomy, or of fistula in ano. At the back part of this space may be seen a branch of the fourth sacral nerve ; and at the fore part of the space, the superficial perineal vessels and nerves can be seen for a short distance.

## THE PERINÆUM IN THE MALE

The perineal space is of a triangular form; its deep boundaries are limited, laterally, by the rami of the pubic bones and ischia, meeting, in front, at the pubic arch: behind, by an imaginary transverse line, extending between the tuberosities of the ischia. The lateral boundaries are, in the adult, from three inches to three inches and a half in length; and the base from two to three inches and a half in breadth; the average extent of the space being two inches and three-quarters.

The variations in the diameter of this space are of extreme interest in connection with the operation of lithotomy, and the extraction of a stone from the cavity of the bladder. In those cases where the tuberosities of the ischia are near together it would be necessary to make the incisions in the lateral operation of lithotomy less oblique than if the tuberosities were widely separated, and the perineal space, consequently, wider. The perinæum is subdivided by the median raphé into two equal parts. Of these, the left is the one in which the operation of lithotomy is performed.

In the middle line the perinæum is convex, and corresponds to the bulb of the urethra. The skin covering it is of a dark colour, thin, freely movable upon the subjacent parts, and covered with sharp crisp hairs, which should be removed before the dissection of the part is commenced. In front of the anus a prominent line commences, the *raphé*, continuous in front with the raphé of the scrotum.

Upon removing the skin and superficial structures from this region, in the manner shown in fig. 700, a plane of fascia will be exposed, covering in the triangular space and stretching across from one ischio-pubic ramus to the other. This is the *deep layer of the superficial fascia* or *fascia of Colles*. It has already been described (page 461). It is a layer of considerable strength, and encloses and covers a space in which are contained muscles, vessels, and nerves. It is continuous, in front, with the dartos of the scrotum; on each side, it is firmly attached to the margin of the ischio-pubic ramus and to the tuberosity of the ischium; and posteriorly it curves down behind the *Transversus perinæi* muscles to join the lower margin of the deep perineal fascia.

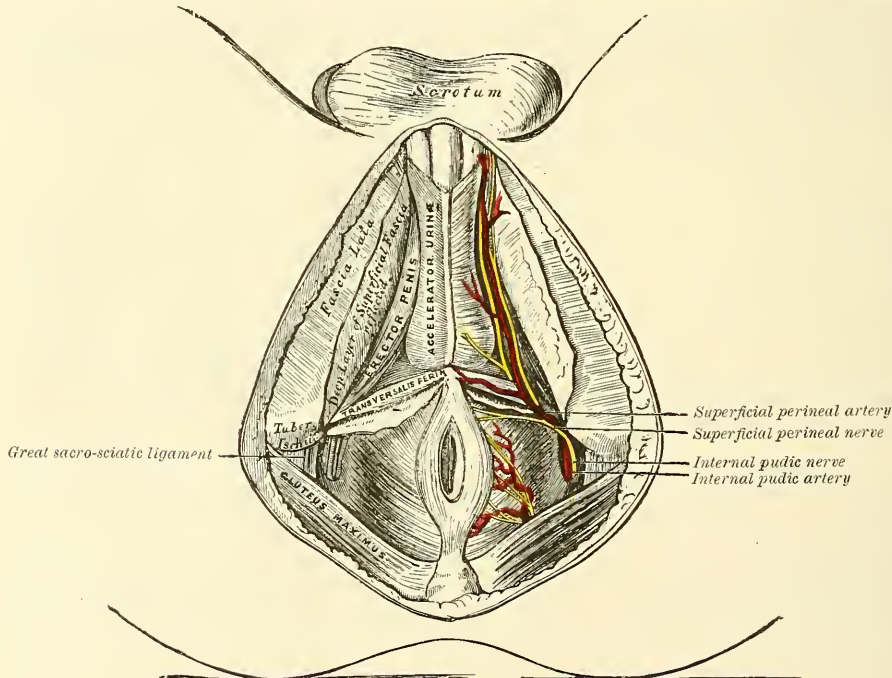
It is between this layer of fascia and the next layer, the superficial layer of the deep perineal fascia, that extravasation of urine most frequently takes place in cases of rupture of the urethra. The superficial layer of the deep perineal fascia (see page 464) is also attached to the ischio-pubic rami, and in front to the subpubic ligament. It is clear, therefore, that when extravasation of fluid takes place between these two layers, it cannot pass backwards, because the two layers are continuous with each other around the *Transversus perinæi* muscles; it cannot extend laterally, on account of the connection of both these layers to the rami of the os pubis and ischium; it cannot find its way into the pelvis, because the opening into this cavity is closed by the deep perineal fascia, and, therefore, so long as these two layers remain intact, the only direction in which the fluid can make its way is forwards into the areolar tissue of the scrotum and penis, and from thence on to the anterior wall of the abdomen.

When the deep layer of the superficial fascia is removed, a space is exposed, between this fascia and the deep perineal fascia, in which are contained most of the branches of the internal pudic artery, with their accompanying veins; the terminal branches of the internal pudic nerve; some of the muscles connected with the penis and urethra; in the middle line, the *Accelerator urinæ*; on each side, the *Erector penis*; and behind, the *Transversus perinæi*;—the *crura* of the *corpora cavernosa*; and the bulb of the *corpus spongiosum*. Here also is seen the *central tendinous point of the perinæum*. This is a fibrous point in the middle line of the perinæum between the urethra and the rectum, being about half an inch in front of the anus. At this point five muscles converge and are attached: viz. the *External sphincter ani*, the *Acceleratores urinæ*, and the two *Transversi perinæi* muscles; so that by the contraction of these muscles, which extend in opposite directions, it serves as a fixed point of support.

The *Accelerator urinæ*, the *Erector penis*, and the *Transversus perinæi* muscles have been already described (page 462). They form a triangular space, bounded, internally, by the *Accelerator urinæ*; externally, by the *Erector penis*;

and behind, by the *Transversus perinæi*. The floor of this space is formed by the triangular ligament of the urethra (deep perineal fascia); and running from behind forwards in it are the superficial perineal vessels and nerves, and the transverse perineal artery coursing along the posterior boundary of the space, on the *Transversus perinæi* muscle. The two terminal branches of the internal pudic artery are also to be seen in this space: the dorsal artery of the penis ascending between the crus and the pubic arch, and the artery to the corpus cavernosum entering the crus immediately after the division of the parent trunk. The perineal nerve and dorsal nerve of the penis, the two terminal branches of the pudic nerve, are also contained in this space: the perineal dividing into muscular and cutaneous branches, and the dorsal nerve accompanying the dorsal artery along the ischio-pubic ramus, and with it piercing the suspensory ligament to be distributed to the penis.

FIG. 701.—The superficial muscles and vessels of the perinæum.



The *Accelerator urinæ* and *Erector penis* should now be removed, when the deep perineal fascia will be exposed, stretching across the front part of the outlet of the pelvis. The urethra is seen perforating its centre, just behind the bulb; and on each side is the crus penis, connecting the corpus cavernosum with the rami of the ischium and os pubis.

The **deep perineal fascia** (*triangular ligament*), which has already been described (see page 464), consists of two layers, the inferior or superficial layer of which, sometimes called the *anterior layer of the triangular ligament*, is now exposed. It is united to the superior or deep layer behind, but is separated in front by a subfascial space in which are contained certain structures.

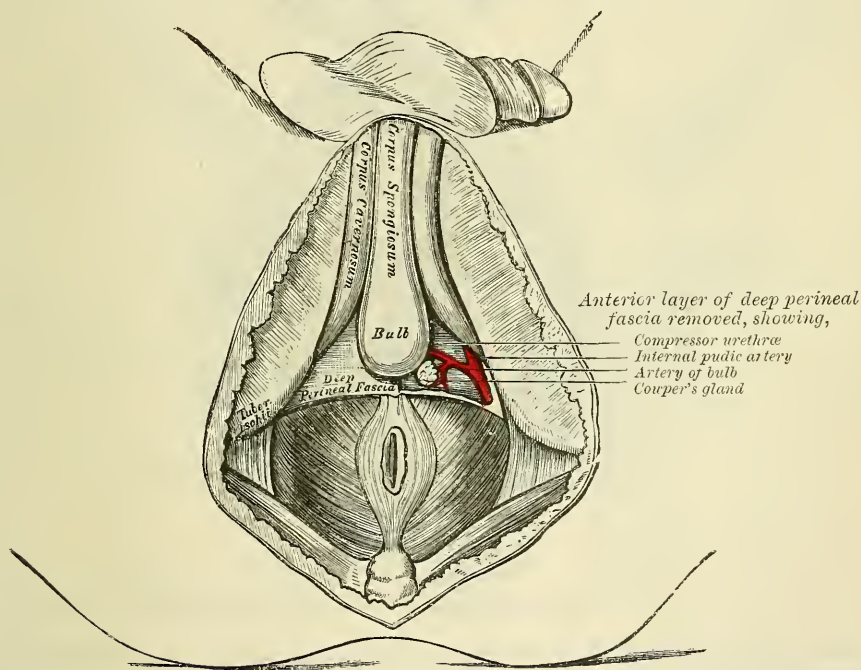
The *superficial layer of the deep perineal fascia* consists of a strong fibrous membrane, the fibres of which are disposed transversely, which stretches across from one ischio-pubic ramus to the other, and completely fills in the pubic arch; it is attached in front to the subpubic ligament, except just in the centre, where a small interspace is left for the dorsal vein of the penis. In the erect position of the body it is almost horizontal. It is perforated by the urethra in the middle line, and on each side by the ducts of Cowper's glands. It is pierced also by three branches of the internal pudic artery: viz. the dorsal artery of the penis near



the apex of the ligament; the artery to the corpus cavernosum more posteriorly, close to the lateral margin of the ligament; and the artery to the bulb in front of the opening for Cowper's duct. The dorsal nerve of the penis also passes through the ligament, in company with the artery of the same name. The *crura penis* are exposed, lying superficial to this ligament. They will be seen to be attached by blunt pointed processes to the rami of the os pubis and ischium, in front of the tuberosities, and passing forwards and inwards joining to form the body of the penis. In the middle line is the bulb and corpus spongiosum exposed by the removal of the Accelerator urinæ muscle.

If the superficial layer of the deep perineal fascia is detached on either side, the deep perineal interspace will be exposed and the following parts will be seen, between it and the deep layer of the fascia: the subpubic ligament in front, close to the symphysis pubis; the dorsal vein of the penis; the membranous portion of the urethra and the Compressor urethræ muscle; Cowper's glands and their ducts; the pudic vessels and the dorsal nerve of the penis; the artery and nerve of the bulb, and a plexus of veins.

FIG. 702.—Deep perineal fascia. On the left side the anterior layer has been removed.



The superior or deep layer of the deep perineal fascia is derived from the obturator fascia, or is continuous with it along the pubic arch. Behind, it joins with the superficial layer of the deep perineal fascia, and is continuous with the anal fascia. Above it is the recto-vesical fascia, separated from it on each side by the anterior fibres of the Levator ani, but in the median line these two layers of fascia are continuous and form a median septum, in consequence of the recto-vesical fascia dipping down to join the deep layer of the deep perineal fascia. Thus on each side of the middle line, beneath this fascia, is a little interspace in which is contained the anterior fibres of the Levator ani (Levator prostatae). It is bounded, below, by the deep layer of the deep perineal fascia; above, by the recto-vesical fascia, and is separated internally from the space on the other side by the median septum. The deep layer of the deep perineal fascia is pierced by the urethra, and is continued backwards around the posterior part of the membranous portion of the urethra and the outer surface of the prostate gland.

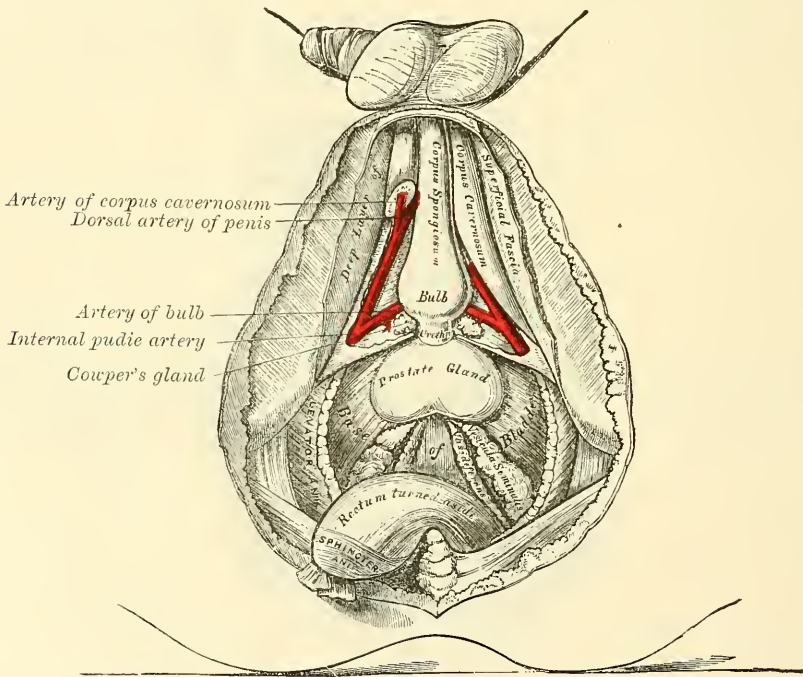
The **Compressor urethræ** has already been described (page 465). In addition to this muscle and immediately beneath it, *circular muscular fibres* surround the membranous portion of the urethra from the bulb in front to the prostate behind, and are continuous with the muscular fibres of the bladder. These fibres are involuntary.

**Cowper's glands** are situated immediately below the membranous portion of the urethra, close behind the bulb and below the artery of the bulb.

The **pubic vessels and dorsal nerve of the penis** are placed along the inner margin of the pubic arch (pages 637 and 847).

The **artery of the bulb** passes transversely inwards, from the internal pudic along the base of the triangular ligament, between the two layers of fascia, accompanied by a branch of the pudic nerve (page 849). If the posterior layer of the deep perineal fascia is removed and the crus penis of one side detached from the bone, the under or perineal surface of the Levator ani is brought fully into

FIG. 703.—A view of the position of the viscera at the outlet of the pelvis.



view. This muscle, with the triangular ligament in front and the Coccygeus and Piriformis behind, closes the outlet of the pelvis.

The Levator ani and Coccygeus muscles have already been described (page 459).

*Position of the Viscera at the Outlet of the Pelvis.*—Divide the central tendinous point of the perinæum, separate the rectum from its connections by dividing the fibres of the Levator ani, which descend upon the sides of the prostate gland, and draw the gut backwards towards the coccyx, when the under surface of the prostate gland, the neck and base of the bladder, the vesiculæ seminales, and the vasa deferentia will be exposed.

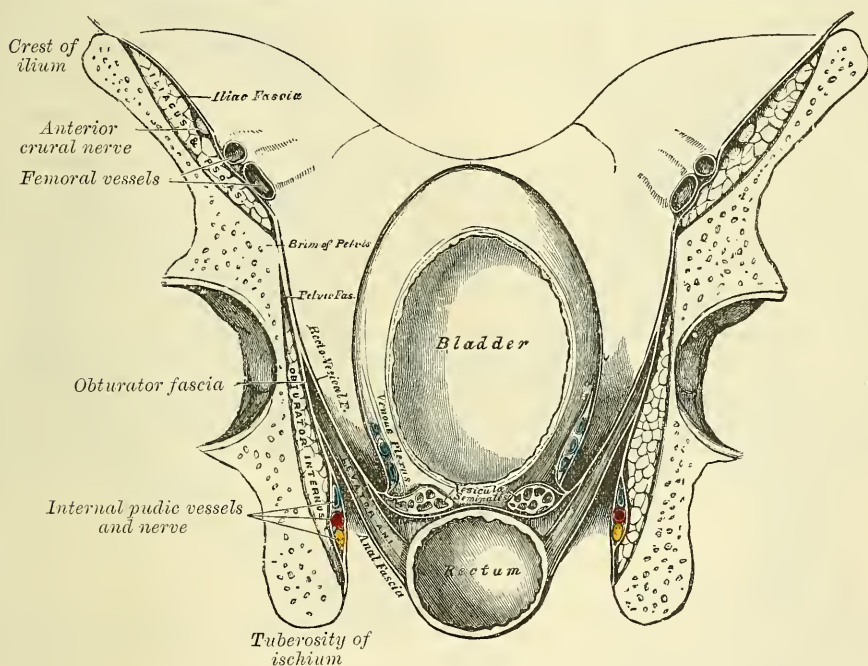
The **prostate gland** is a pale, firm, glandular body which is placed immediately in front of the neck of the bladder, around the commencement of the urethra. It is placed in the pelvic cavity, behind and below the symphysis pubis, posterior to the deep perineal fascia, and rests upon the rectum, through which it may be distinctly felt, especially when enlarged. In shape and size it resembles a chestnut. Its base is directed backwards towards the neck of the bladder. Its apex is directed forwards to the deep perineal fascia, which it touches.



Its under surface is smooth, marked by a slight longitudinal furrow, and rests on the rectum, to which it is connected by areolar tissue. Its upper surface is flattened, marked by a slight longitudinal furrow, and placed about three-quarters of an inch below the pubic symphysis. It measures about an inch and a half in its transverse diameter at the base, an inch in its antero-posterior diameter, and three-quarters of an inch in depth. Hence the greatest extent of incision that can be made in it without dividing its substance completely across, is obliquely backwards and outwards. This is the direction in which the incision is made in the lateral operation of lithotomy.

Behind the prostate is the posterior surface of the neck and base of the bladder : a small triangular portion of the bladder being seen, bounded, in front, by the prostate gland ; behind, by the recto-vesical fold of the peritoneum ; on each side, by the vesicula seminalis and the vas deferens. It is separated from direct contact with the rectum by the recto-vesical fascia. The relation of this portion of the bladder to the rectum is of extreme interest to the surgeon. In cases of retention

FIG. 704.—A transverse section of the pelvis, showing the pelvic fascia from behind.



of urine this portion of the organ is found projecting into the rectum, between three and four inches from the margin of the anus, and may be easily perforated, without injury to any important parts ; this portion of the bladder is, consequently, occasionally selected for the performance of the operation of tapping the bladder.

*Surgical Anatomy.*—The student should consider the position of the various parts in reference to the lateral operation of lithotomy. This operation is performed on the left side of the perinaeum, as it is most convenient for the right hand of the operator. A staff having been introduced into the bladder, the first incision is commenced midway between the anus and the back of the scrotum (i.e. in an ordinary adult perinaeum, about an inch and a half in front of the anus), a little on the left side of the raphé, and carried obliquely backwards and outwards to midway between the anus and tuberosity of the ischium. The incision divides the integument and superficial fascia, the inferior hæmorrhoidal vessels and nerves, and the superficial and transverse perineal vessels. If the forefinger of the left hand is thrust upwards and forwards into the wound, pressing at the same time the rectum inwards and backwards, the staff may be felt in the membranous portion of the urethra. The finger is fixed upon the staff, and the structures covering it are divided with the point of the knife, which must be directed along the groove towards



the bladder, the edge of the knife being turned outwards and backwards, dividing in its course the membranous portion of the urethra, and part of the left lobe of the prostate gland, to the extent of about an inch. The knife is then withdrawn, and the forefinger of the left hand passed along the staff into the bladder. The position of the stone having been ascertained, the staff is to be withdrawn, and the forceps is introduced over the finger into the bladder. If the stone is very large, the opposite side of the prostate may be notched before the forceps is introduced: the finger is now withdrawn, and the blades of the forceps opened and made to grasp the stone, which must be extracted by slow and cautious undulating movements.

*Parts divided in the operation.*—The various structures divided in this operation are as follow:—the integument, superficial fascia, inferior hæmorrhoidal vessels and nerves and probably the superficial perineal vessels and nerves, the posterior fibres of the Accelerator urinæ, the Transversus perinæi muscle and artery, the deep perineal fascia, the anterior fibres of the Levator ani, part of the Compressor urethræ, the membranous and prostatic portions of the urethra, and part of the prostate gland.

*Parts to be avoided in the operation.*—In making the necessary incisions in the perinæum for the extraction of a calculus, the following parts should be avoided. The primary incision should not be made too near the middle line, for fear of wounding the bulb of the corpus spongiosum or the rectum; nor too far externally, otherwise the pudic artery may be implicated as it ascends along the inner border of the pubic arch. If the incisions are carried too far forwards, the artery of the bulb may be divided; if carried too far backwards, the entire breadth of the prostate and neck of the bladder may be cut through, which allows the urine to become infiltrated behind the pelvic fascia into the loose areolar tissue between the bladder and rectum, instead of escaping externally: diffuse inflammation is consequently set up, and peritonitis, from the close proximity of the recto-vesical peritoneal fold, is the result. If, on the contrary, only the anterior part of the prostate is divided, the urine makes its way externally, and there is less danger of infiltration taking place.

During the operation it is of great importance that the finger should be passed into the bladder *before* the staff is removed; if this is neglected, and if the incision made in the prostate and neck of the bladder is too small, great difficulty may be experienced in introducing the finger afterwards; and in the child, where the connections of the bladder to the surrounding parts are very loose, the force made in the attempt is sufficient to displace the bladder upwards into the abdomen, out of the reach of the operator. Such a proceeding has not unfrequently occurred, producing the most embarrassing results, and total failure of the operation.

It is necessary to bear in mind that the arteries in the perinæum occasionally take an abnormal course. Thus the artery of the bulb, when it arises, as sometimes happens, from the pudic opposite the tuber ischii, is liable to be wounded in the operation for lithotomy, in its passage forwards to the bulb. The accessory pudic may be divided near the posterior border of the prostate gland, if this is completely cut across; and the prostatic veins, especially in people advanced in life, are of large size, and give rise, when divided, to troublesome hæmorrhage.

### THE FEMALE PERINÆUM

The **female perinæum** presents certain differences from that of the male, in consequence of the whole of the structures which constitute it being perforated in the middle line by the vulvo-vaginal passage.

The **superficial fascia**, as in the male, consists of two layers: of which the superficial one is continuous with the superficial fascia over the rest of the body; and the deep layer, corresponding to the fascia of Colles in the male, is like it attached to the ischio-pubic ramus, and in front is continued forwards through the labia majora to the inguinal region. It is of less extent than the male, in consequence of being perforated by the aperture of the vulva.

On removing this fascia the muscles of the female perinæum, which have already been described (page 465), are exposed. The Sphincter vaginæ, corresponding to the Accelerator urinæ in the male, consists of an attenuated plane of fibres, forming an orbicular muscle around the orifice of the vagina, instead of being united in a median raphé, as in the male. The Erector clitoridis is proportionately reduced in size, but differs in no other respect; and the Transversus perinæi is similar to the muscle of the same name in the male.

The **deep perineal fascia** is not so strongly marked as in the male. It transmits the urethra, and is wide, separated in the median line by the aperture of the vagina.

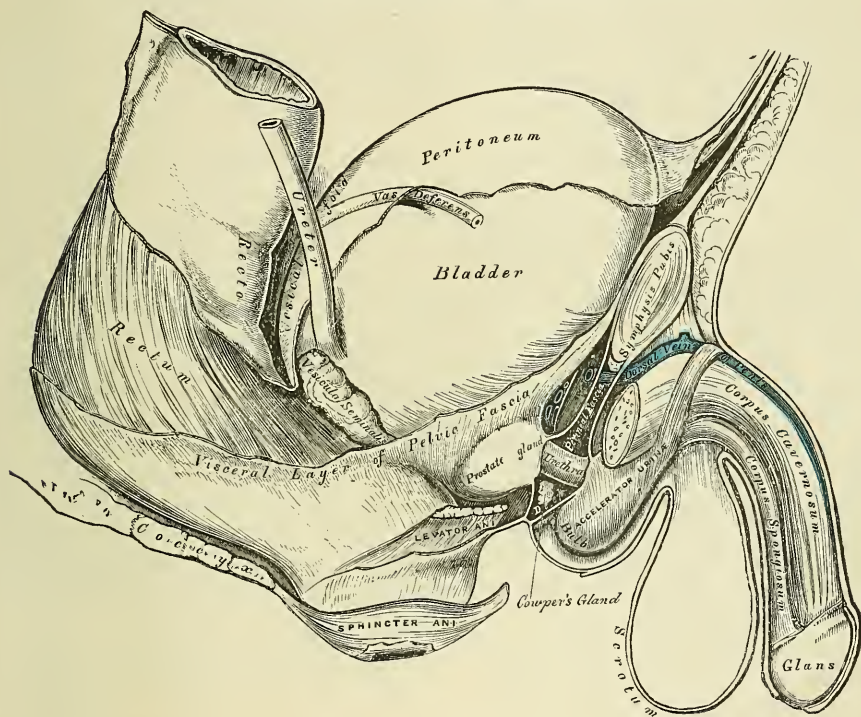
The **Compressor urethræ** (*Transversus perinæi profundus*) is the analogue of the Compressor urethræ in the male. It arises from the ischio-pubic ramus, and, passing inwards, its anterior fibres blend with the muscle of the opposite side in front of the urethra; its middle fibres, the most numerous, are inserted into the side of the vagina, and the posterior fibres join the central point of the perinæum.

The distribution of the internal pudic artery is the same as in the male (see page 639), and the pudic nerve has also a similar arrangement, the dorsal nerve being, however, very small and supplying the clitoris.

The corpus spongiosum is divided into two lateral halves, which are represented by the *bulbi vestibuli* and *partes intermediales* (see page 1101).

The **perineal body** fills up the interval between the lower part of the vagina and the rectum. Its base is covered by the skin lying between the anus and

FIG. 705.—Side view of the pelvic viscera of the male subject, showing the pelvic and perineal fasciæ.



vagina on what is called the ‘perinæum.’ Its anterior surface lies behind the posterior vaginal wall, and its posterior surface lies in front of the anterior rectal wall and the anus. It measures about an inch and a quarter from before backwards, and laterally extends from one tuberosity of the ischium to the other. In it are situated the muscles belonging to the external organs of generation. Through its centre runs the transverse perineal septum, which is of great strength in women, and forms on either side, behind the posterior commissure, a hard, ill-defined body, consisting of connective tissue, with much yellow elastic tissue and interlacing bundles of involuntary muscular fibres, in which the voluntary muscles of the perinæum are inserted.

PELVIC FASCIA

The **pelvic fascia** (fig. 704) is a thin membrane which lines the whole of the cavity of the pelvis, and is continuous with the transversalis and iliac fasciæ. It

is attached to the brim of the pelvis, for a short distance, at the side of the cavity, and to the inner surface of the bone round the attachment of the Obturator internus. At the posterior border of this muscle, it is continued backwards as a very thin membrane in front of the Piriformis muscle and sacral nerves to the front of the sacrum. In front, it follows the attachment of the Obturator internus to the bone, arches beneath the obturator vessels, completing the orifice of the obturator canal, and at the front of the pelvis is attached to the lower part of the symphysis pubis. At the level of a line extending from the lower part of the symphysis pubis to the spine of the ischium, is a thickened whitish band; this marks the attachment of the Levator ani muscle to the pelvic fascia, and corresponds to its point of division into two layers, the *obturator* and *recto-vesical*.

The **obturator fascia** descends and covers the Obturator internus muscle. It is a direct continuation of the pelvic fascia below the white line above mentioned, and is attached to the pubic arch and to the margin of the great sacro-sciatic ligament. From its attachment to the rami of the os pubis and ischium a process is given off which is continuous with a similar process from the opposite side, so as to close the front part of the outlet of the pelvis, forming the posterior layer of the triangular ligament. This fascia forms a canal for the pudic vessels and nerve in their passage forwards to the perinæum, and gives off a thin membrane which covers the perineal aspect of the Levator ani muscle, called the *ischio-rectal (anal) fascia*.

The **recto-vesical fascia** (*visceral layer of the pelvic fascia*) descends into the pelvis upon the upper surface of the Levator ani muscle, and invests the prostate, bladder, and rectum. From the inner surface of the symphysis pubis a short rounded band is continued to the upper surface of the prostate and neck of the bladder, forming the pubo-prostatic or anterior true ligaments of the bladder. At the side, this fascia is connected to the side of the prostate, enclosing this gland and the vesico-prostatic plexus of veins, and is continued upwards on the side of the bladder, forming the lateral true ligaments of the organ. Another prolongation invests the vesiculæ seminales, and passes across between the bladder and rectum, being continuous with the same fascia of the opposite side. Another thin prolongation is reflected round the surface of the lower end of the rectum. The Levator ani muscle arises from the point of division of the pelvic fascia; the visceral layer of the fascia descending upon and being intimately adherent to the upper surface of the muscle, while the under surface of the muscle is covered by a thin layer derived from the obturator fascia, called the *ischio-rectal* or *anal fascia*. In the female, the vagina perforates the recto-vesical fascia, and receives a prolongation from it.



# INDEX

- ABDOMEN, 945; apertures found in, 945; boundaries of, 945; lymphatics of, 706; muscles of, 447; regions of, 945; viscera of, 947
- Abdominal aorta, 621; branches of, 622; surgical anatomy of, 621; surface marking of, 621; muscles, 447; ring external, 449, 1117; internal, 457, 1121; viscera, position of, 947
- Abdomino-thoracic arch, 220
- Abducent nerve, 795; surgical anatomy of, 796
- Abductor hallucis, 537
- Abductor indicis muscle, 500
- Abductor minimi digiti muscle, (hand) 498, (foot) 538
- Abductor pollicis muscle, 495
- Aberrant duct of testis, 1095
- Absorbent glands, 697
- Absorbents, 697
- Accelerator urinæ muscle, 463
- Accessorii orbicularis oris, 398
- Accessorius ad ilio-costalem muscle, 435
- Accessorius pedis, 538
- Accessory ligament of shoulder, 340; obturator nerve, 841; olivary nuclei, 734; descending palatine canals, 179; pudic artery, 638; processes, 129
- Acerivulus cerebri, 762
- Acetabulum, 265
- Acromatin, 10
- Acromial end of clavicle, fracture of, 503
- Acromial region, muscles of, 473; thoracic artery, 603
- Acromio-clavicular joint, 336; surface form of, 338; surgical anatomy of, 338
- Acromion process, 228; fracture of, 503
- Actions of Muscles. *See each Group of Muscles*
- Adamantoblasts, 930
- Adductor brevis muscle, 517; longus muscle, 516; magnus muscle, 517; obliquus pollicis, 496; transversus pollicis, 497; obliquus hallucis, 539; transversus hallucis, 540
- Adductor tubercle, 275
- Adenoid connective tissue, 19
- Adipose tissue, 20
- Afferent nerves, 47
- Afferent vessels of kidney, 1066
- Air-cells, 1052
- Ala cinerea, 733, 776; lobuli centralis, 769; nasi, artery of, 564
- Alæ of vomer, 181; of sacrum, 134
- Alar ligaments, 319; of knee, 367; thoracic artery, 604
- Alcock, canal of, 638, 1138
- Alimentary canal, 921; development of, 108; subdivisions of, 921
- Allantoic vessels, 86; vesicle, 86
- Allantois, 85
- Alveolar artery, 571; process, 172, 184
- Alveoli of lower jaw, 184; of upper jaw, 172; formation of, 932; of stomach, 970
- Amnion, 84; true, 84; false, 85
- Amniotic cavity, 84
- Amphiarthrosis, 307
- Ampullæ of semicircular canals, 912; of tubuli lactiferi, 1113
- Amygdalæ, 935; of cerebellum, 770
- Anal fascia, 460, 1146; canal, 988
- Anastomosis of arteries, 546
- Anastomotica magna of brachial, 608; of femoral, 652
- Anatomical neck of humerus, 231; fracture of, 237
- Anconæus muscle, 489
- Andersch, ganglion of, 802
- Aneurisms of abdominal aorta, 621; of arch of aorta, 551; of thoracic aorta, 618
- Angle of jaw, 185; of os pubis, 264; of rib, 216; sacro-vertebral, 132
- Angular artery, 564; convolution, 740; movement, 310; process, external, 149; internal, 149; vein, 669
- Animal constituent of bone, 29
- Ankle joint, 373; relations of tendons and vessels to, 374; surface form of, 376; surgical anatomy of, 376
- Annectant gyrus, 740, 741, 744
- Annular ligament of radius and ulna, 348; of wrist, anterior, 492; posterior, 493; of ankle, anterior, 534; external, 535; internal, 535; of stapes, 909
- Annulus ovalis, 1020; of cochlæ, 914
- Anterior annular ligament, (wrist) 492; (ankle) 534; chamber of eye, 892; crural nerve, 841; surgical anatomy of, 853; dental canal, 170; ethmoidal cells, 166; fontanelle, 167; fossa of skull, 190; nasal spine, 173; palatine canal, 172; palatine fossa, 172, 193; region of skull, 199; triangle of neck, 572
- Anterior and internal frontal artery, 581
- Antero-lateral ganglionic artery, 582
- Antero-median ganglionic artery, 581
- Antihelix, 902; fossa of, 902
- Antitragicus muscle, 903
- Antitragus, 902
- Antrum of Highmore, 171; mastoid, 154
- Anus, 1137; development of, 109; muscles of, 459
- AORTA, 548; development of, 104; abdominal, 620; branches of, 622; surgical anatomy of arch of, 551; abdominal, 621; thoracic, 618
- Aorta, arch of, 550; branches of, 552; peculiarities of, 551; peculiarities of

- branches of, 552; sinuses of, 549; surgical anatomy of, 551
- Aorta**, abdominal, 620; descending, 617; thoracic, 617; branches of, 618; surgical anatomy of, 618; sinuses of, 549
- Aortic opening of diaphragm**, 445; of heart, 1024; plexus, 865; semilunar valves, 1024; sinuses, 1024
- Apertura scalæ vestibuli cochleæ**, 912
- Apex cornu of eord.** 716
- Aponeurosis**, 385; of deltoid, 473; of external oblique in inguinal region, 449; of occipito-frontalis, 389; supra-hyoid, 411; of soft palate, 934
- Apophysis**, 120
- Apparatus ligamentosus colli**, 318
- Appendages of eye**, 896; surgical anatomy of, 901; of skin, 64; of uterus, 1108
- Appendices epiploicæ**, 988
- Appendix of right auricle**, 1019; of left auricle, 1023; vermiformis, 983
- Aqua labyrinthi**, 918
- Aqueductus cochleæ**, 156, 914; vestibuli, 156, 912; Fallopii, 156, 907; Sylvii, 761
- Aqueous humour**, 892
- Arachnoid of brain**, 725; of cord, 713
- Arantii corpora**, 1022, 1024
- Arantius, ventricle of**, 730
- Arbor vitæ uterina**, 1106, 1107; vitæ of cerebellum, 771
- Arch of aorta**, 550; peculiarities of, 551; branches of, 552; surgical anatomy of, 551; of os pubis, 268; of a vertebra, 120; supra-orbital, 149; crural or femoral, 1134; palmar superficial, 616; deep, 610; plantar, 663; zygomatic, 197
- Arches, pharyngeal**, 91; pre-oral, 92; post-oral, 92; aortic (fœtal), 104
- Arciform or arcuate fibres of medulla oblongata**, 729, 730, 732
- Arcuate fibres of cerebrum**, 464; of cerebellum, 772
- Area, germinal**, 76
- Areas of Cohnheim**, 38
- Areola of breast**, 1112
- Areolæ of bone**, primary, 31; secondary, 32
- Areolar tissue**, 17
- Arm, back of, muscles of**, 480; front of, muscles of, 477; arteries of, 585; bones of, 231; fascia of, 473; lymphatic glands of, 702; lymphatics of, 703; superficial fascia of, 473; nerves of, 823; veins of, 679
- Arnold's nerve**, 806; canal for, 157; ganglion, 793
- Arrectores pili**, 66
- Arteria centralis retinae**, 581
- Arteria magna**, 548
- Arteriæ propriæ renales**, 1066
- Arteriæ receptaculi**, 577
- Arteries, development of**, 104
- ARTERIES, General Anatomy of**, 52; anastomoses of, 546; capillary, 54; development of, 104; distribution of, 546; mode of division, 546; mode of origin of branches, 546; nerves of, 54; sheath of, 53; structure of, 52; subdivision of, 546; systemic, 546; vessels of, 53
- ARTERIES OR ARTERY, accessory pudic**, 638; acromial thoracic, 603; alar thoracic, 604; alveolar, 571; anastomotica magna of brachial, 608; of femoral,

ARTERIES OR ARTERY (*continued*)

- 652; angular, 564; anterior cerebral, 581; anterior choroid, 582; anterior ciliary, 581; anterior communicating, 581; anterior intercostal, 596; anterior and internal frontal, 581; anterior inferior cerebellar, 593; anterior spinal, 592; antero-lateral ganglionic, 582; antero-median ganglionic, 581; aorta, 548; abdominal, 620; arch of, 550; ascending aorta, 549; descending aorta, 617; thoracic, 617; articular, knee, 657; ascending cervical, 594; pharyngeal, 566; auditory, 593, 918; auricular anterior, 567; posterior, 566; axillary, 600; azygos of knee, 657
- basilar**, 593; brachial, 604; bronchial, 619, 1054; buccal, 570; of bulb, 639
- calcanean, external**, 663; internal, 663;
- carotid common**, 554; external, 559; internal, 574; carpal ulnar, 616; carpal radial, 611; of cavernous body, 639; centralis retinae, 581; cerebellar, 593; cerebral, 581, 583, 593; ascending cervical, 594; superficial, 596; princeps, 565; profunda, 598; choroid anterior, 582; posterior, 594; ciliary, 580; circle of Willis, 583, 594; circumflex of arm, 604; of thigh, 651; iliac, deep, 644; superficial, 649; cochlear, 918; coccygeal, 639; colica dextra, 627; media, 627; sinistra, 627; cœliac axis, 622; comes nervi ischiadici, 640; phrenici, 596; common carotid, 554; iliac, 631; communicating, anterior cerebri, 581; posterior cerebri, 593; communicating branch of ulnar, 616; coronary of heart, 549; of lip, 564; cremasteric, 643; crico-thyroid, 561; cystic, 625
- deep branch of ulnar**, 616; cervical, 598; palmar branch, 610; temporal, 570; deferent, 635; dental inferior, 570; anterior, 571; descending aorta, 617; palatine, 571; digital plantar, 664; digital of ulnar, 616; dorsal of penis, 639; of scapula, 604; dorsalis hallucis, 660; indicis, 612; linguæ, 561; pedis, 659; pollicis, 612
- epigastric, deep**, 643; superior, 598; superficial, 649; ethmoidal, 578; external carotid, 559; plantar, 663; iliac, 642
- facial**, 562; femoral, 644; deep, 650; frontal, 580
- gastric**, 623, 625; gastro-duodenalis, 624; gastro-epiploica dextra, 624; gastro-epiploica sinistra, 625; gluteal, 641; inferior, 640
- helicine**, 1087; hæmorrhoidal inferior, 638; middle, 636; superior, 627; hepatic, 623; hyoid branch of lingual, 561; of superior thyroid, 560; hypogastric in fœtus, 634, 1028
- ileo-colic**, 626; iliac common, 631; external, 640; internal, 633; ilio-lumbar, 640; inferior cerebellar, 593; dental, 570; labial, 564; laryngeal, 594; mesenteric, 627; profunda, 608; pyloric, 624; thyroid, 594; infra-orbital, 571; innominate, 553; intercostal, 619; anterior, 596; superior, 598; internal, auditory, 918; carotid, 574; iliac, 633;

ARTERIES OR ARTERY (*continued*)

mammary, 596; maxillary, 568; plantar, 663; interosseous ulnar, 614; of foot, 660; of hand, 613; intestini tenuis, 626

labial inferior, 564; lachrymal, 578; laryngeal superior, 560; inferior, 594; lateral sacral, 641; spinal, 592; lateralis nasi, 564; lingual, 561; long ciliary, 581; thoracic, 604; lumbar, 629

malleolar, 659; mammary internal, 596; masseteric, 570; maxillary internal, 568; median of forearm, 615, of spinal cord, 592; mediastinal, 596; posterior, 619; meningeal anterior, 577, middle, 569, small, 570; from occipital, 565; from pharyngeal, 567, from vertebral, 592; mesenteric inferior, 627; superior, 625; metacarpal, 612; metatarsal, 660; middle cerebral, 581; sacral, 630; musculo-phrenic, 598; mylo-hyoid, 570

nasal, of ophthalmic, 580; of septum inferior, 564, superior, 571; nutrient of humerus, 608; femur, 652; fibula, 663; radius and ulna, 615; tibia, 663

obturator, 636; occipital, 565; œsophageal, 619; ophthalmic, 577; orbital, 571; ovarian, 629

palatine, ascending, 563; descending, 571; of pharyngeal, 566; palmar arch, superficial, 616, deep, 610; palmar interossei, 613; palpebral, 580; pancreatic, 625; pancreatico-duodenalis, 624; inferior, 626; perforating, of hand, 613, of thigh, 652, of foot, 664, of anterior intercostal, 598, plantar, 664; pericardiac, 596, 618; perineal, superficial, 638; transverse, 638; peroneal, 662, anterior, 663; pharyngeal, ascending, 566; phrenic, 629; popliteal, 652; posterior auricular, 566, cerebral, 593; communicating, 582, meningeal, from vertebral, 592; princeps cervicis, 565, pollicis, 612; profunda of arm, inferior, 608, superior, 608, cervicis, 598, femoris, 650; pterygoid, 570, pterygo-palatine, 571; pudic, deep external, 650; superficial external, 649, internal, in male, 637, in female, 641; pulmonary, 547, 1052; pyloric inferior, 624; of hepatic, 624

radial, 609; radialis indicis, 613; ranine, 561; recurrent interosseous, 615, radial, 609; ulnar anterior, 614, posterior, 614; tibial anterior, 659, posterior, 659; renal, 628

sacral lateral, 641; middle, 630; scapular, posterior, 596; sciatic, 639; short ciliary, 580; sigmoid, 627; spermatic, 629, 1090; spheno-palatine, 571; spinal anterior, 592; lateral, 592; posterior, 592; median, 592; splenic, 625; sternomastoid, 560, 565; stylo-mastoid, 566; subclavian, 585; sublingual, 561; submaxillary, 564; submental, 564; subscapular, 604; superficial cervical, 596; circumflex iliac, 649; perineal, 638; palmar arch, 616; superficialis volæ, 611, superior cerebellar, 593, epigastric, 598, hæmorrhoidal, 627, intercostal, 598, laryngeal, 560, mesenteric, 625, profunda, 608, thoracic, 603, thyroid,

ARTERIES OR ARTERY (*continued*)

560; supra-orbital, 578, suprarenal, 628, suprascapular, 595; sural, 655

tarsal, 660; temporal, 567; anterior, 567; deep, 570; middle, 567; posterior, 567; thoracic, acromial, 603, alar, 604, aorta, 617; long, 604; superior, 603; thyroid axis, 594; thyroid inferior, 594; superior, 560; thyroidea ima, 553, 1056; tibial anterior, 657, posterior, 660, recurrent, 659; tonsillar, 563; transverse facial, 567; transversalis colli, 595; tympanic, from internal carotid, 577, from internal maxillary, 569

ulnar, 613; recurrent anterior, 614, posterior, 614; umbilical in fœtus, 634, 1028; uterine, 636

vaginal, 636, vasa aberrantia, of arm, 606; brevia, 625; intestini tenuis, 626; vertebral, 591; vesical inferior, 635; middle, 635; superior, 635; vestibular, 918; Vidian, 571

Arteriola rectæ, 1067

Arthrodia, 308

Articular arteries (knee), from popliteal, 657

Articular cartilage, 22

Articular end bulbs, 48; lamella of bone, 305; processes of vertebra, 121; synovial membranes, 305

ARTICULATIONS in general, 305; different kinds of, 306

acromio-clavicular, 336; ankle, 373; astragalo-calcanean, 376; astragalo-navicular, 378; atlanto-axial, 315

calcaneo-astragaloid, 376; calcaneo-cuboid, 377; calcaneo-navicular, 378; carpo metacarpal, 354; carpal, 352; classification of, 309; coxycgeal, 332; chondro-sternal, 326; costo-transverse, 324; costo-vertebral, 323; of cuboid with external cuneiform, 380; of cuneiform with each other, 379

elbow, 343

femoro-tibial, 363

hip, 357

immovable, 306

knee, 363

metacarpal, 356; metacarpo-phalangeal 356; metatarso-phalangeal, 382; metatarsal, 381; mixed, 307; movable, 307, movements of, 308

naviculo-cuneiform, 379; naviculo-cuboid, 379

occipito-atlantal, 317; occipito-axial, 318

pelvis, 330; pelvis with spine, 329; phalanges, 357; pubic, 333

radio-carpal, 350; radio-ulnar, inferior, 349; middle, 348; superior, 347

sacro-coxycgeal, 332; sacro-iliac, 330; sacro-sciatic, 331; sacro-vertebral, 329; scapulo-clavicular, 336; scapulo-humeral, 339; shoulder, 339; sternoclavicular, 334; of sternum, 328

tarso-metatarsal, 380; tarsal, 376; temporo-maxillary, 320; tibio-fibular, inferior, 372; middle, 372; superior, 371; of tympanic bones, 909

vertebral column, 311

wrist, 350

Aryteno-epiglottideus superior, 1039; inferior, 1039



- Aryteno-epiglottidean folds, 1036  
 Arytenoid cartilages, 1034; glands, 1040  
 Arytenoid muscle, 1038  
 Arytenoideus rectus, 1039 (*foot-note*)  
 Ascending colon, 984; oblique muscle of abdomen, 451  
 Ascending frontal artery, 582  
 Ascending palatine artery, 563; pharyngeal artery, 566; surgical anatomy of, 567  
 Ascending parietal artery, 582  
 Association fibres of hemispheres of brain, 764  
 Astragalus, 291; development of, 300  
 Atlanto-axial articulation, 315  
 Atlas, 122; development of, 130  
 Atlo-odontoid joint, 315  
 Atrabiliary capsules, 1072  
 Atrium bursæ omentalis, 955  
 Attic of tympanum, 154  
 Attollens aurem muscle, 390  
 Attrahens aurem muscle, 390  
 Auditory artery, 918; internal, 593; canal, 904; meatus, external, 155; surface form of, 905; internal, 155; nerve, 801, 918; surgical anatomy of, 802; veins, 918; vesicle, 99  
 Auerbach's plexus, 982  
 Auricle of ear, 902; cartilage of, 902; ligaments of, 903  
 Auricle of heart, left, 1022; appendix of, 1023; sinus of, 1023; right, 1018; openings in, 1019; valves in, 1020; sinus of, 1019; septum of, 1018, 1026  
 Auricular artery, posterior, 566; anterior, 567; fissure, 157, 195; lymphatic glands, 699; nerve of vagus, 806; posterior from facial, 798; veins, anterior, 669; posterior, 670; surface of sacrum, 134  
 Auricularis anterior muscle, 390: posterior, 390; superior, 390  
 Auricularis magnus nerve, 818  
 Auriculo-temporal nerve, 791  
 Auriculo-ventricular groove of heart, 1018; opening, left, 1024; opening, right, 1021  
 Axes of the pelvis, 269  
 Axilla, 598; dissection of, 467; surgical anatomy of, 600  
 Axillary artery, 600; peculiarities, 602; surgical anatomy of, 602; branches of, 603; surface marking of, 602; lymphatic glands, 702; space, 598; vein, 682; surgical anatomy of, 682  
 Axis, or second vertebræ, 124; development of, 130  
 Axis, cerebro-spinal, 712; cœliac, 622; thyroid, 594  
 Axis-cylinder of nerve-tubes, 42  
 Azygos artery, articular, 657; of vagina, 636; veins, 685; uvulæ muscle, 421  
 Bacillary layer of retina, 890  
 BACK, muscles of, first layer, 427; second layer, 430; third layer, 431; fourth layer, 434; fifth layer, 437  
 Ball-and-socket joint. *See* Enarthrodia  
 Bartholin, duct of, 938; glands of, 1101  
 Basal ridge, or cingulum of teeth, 923  
 Base of brain, 747; of skull, 190; external surface, 193; internal surface, 190; of sacrum, 134  
 Basement membranes, 19  
 Basi-hyal of hyoid bone, 209  
 Basilar artery, 593; groove, 144; membrane of cochlea, 916; process, 143; suture, 188  
 Basilic vein, 681; median, 681  
 Basis vertebrarum venæ, 687  
 Bauhin, valve of, 983  
 Beak of corpus callosum, 751  
 BEAUNIS ET BOUCHARD, table of development of fœtus, from, 117  
 Bend of elbow, 605  
 Biceps flexor cruris, 524  
 Biceps flexor cubiti, 478  
 Bicipital fascia, 479, 681; groove, 233; tuberosity, 243; ridges, 233  
 Bicuspis teeth, 924  
 Biliary ducts, 1001, 1003; structure of, 1003  
 Bioplasm, 8  
 Biventer cervicis muscle, 436  
 BLADDER, 1073; development of, 112; ligaments of, 1076; trigone of, 1078; vessels and nerves of, 1079; female, 1101; surface form of, 1079; surgical anatomy of, 1079  
 Blastema, 8  
 Blastodermic membrane, 76  
 BLOOD, *General Composition of*, 1; corpuscles, 2; crystals, 6; gases of, 6; globules, 2; plaques or platelets, 5  
 Blood, circulation of, in adult, 1018; in fœtus, 1029  
 Blood-discs, development of, 102  
 Blood-vascular system, development of, 101  
 Blood-vessels of brain, 583  
 Bochdalek, ganglion of, 788, 790; on musculus triticeo-glossus, 1039 *note*  
 Body of a tooth, 923; of a vertebra, 121  
 BONE, *General Anatomy of*, 25; animal constituent of, 29; apophyses of, 120; articular lamella of, 305; canaliculi of, 29; cancellous tissue of, 25; cells, 29; chemical analysis of, 30; compact tissue of, 25; diploë of, 120; development of, 30; earthy constituent of, 30; eminences and depressions of, 120; epiphyses of, 120; growth of, 34; Haversian canals of, 27; systems of, 27; inorganic constituent of, 30; lacunæ of, 28; lamellæ of, 28; lymphatics of, 27; marrow of, 25; medullary canal of, 25, 119; medullary membrane of, 25; microscopic appearances, 27; nerves of, 27; organic constituent of, 29; ossification of, 30; ossific centres, number of, 35; periosteum of, 25; spongy tissue of, 25; vessels of, 26  
 Bones, forms of, viz. long, short, flat, mixed or irregular, 119; number of, in the body, 119  
 BONES OR BONE, *Descriptive Anatomy of*, 119; astragalus, 291; atlas, 122; axis, 124; calcaneum, 287; carpal, 246; clavicle, 222; coccyx, 136; cranial, 141; cuboid, 293; cuneiform of carpus, 250; of tarsus, 294  
 ear, 908; ethmoid, 163  
 facial, 167; femur, 271; fibula, 285; frontal, 148

BONES OR BONE (*continued*)

- hand, 246; humerus, 231; hyoid, 209  
 ilium, 259; incus, 909; inferior maxillary,  
 183; turbinated, 180; innominate, 259;  
 ischium, 262  
 lachrymal, 174; lesser lachrymal, 175;  
 lingual, 209  
 magnum, 252; malar, 175; malleus,  
 908; maxillary, inferior, 183; superior,  
 169; metacarpal, 253; metatarsal, 297  
 nasal, 167; navicular, 294  
 occipital, 141; orbicular, 909  
 palate, 177; patella, 279; parietal, 145;  
 pelvic, 267; phalanges of foot, 300; of  
 hand, 256; pisiform, 250; pubic, 264  
 radius, 243; ribs, 214  
 sacrum, 132; scaphoid, 246; scapula,  
 225; semilunar, 249; sesamoid, 304;  
 sphenoid, 158; sphenoidal spongy, 159;  
 stapes, 909; sternum, 211; superior  
 maxillary, 169  
 tarsal, 287; temporal, 151; tibia, 280;  
 trapezium, 251; trapezoid, 251; tri-  
 quetral, 167; turbinate, superior, 165;  
 middle, 165; inferior, 180; tympanic,  
 155  
 ulna, 238; unciform, 252  
 vertebra prominens, 125; vertebræ, cer-  
 vical, 121; dorsal, 125; lumbar, 127;  
 vomer, 181  
 Wormian, 167  
 Bone, articular lamella of, 305  
 Bowman, glands of, 877; sarcous elements  
 of, 38  
 Bowman's capsule, 1063  
 Brachia of optic lobes, 762  
 Brachial artery, 604; branches of, 608; pecu-  
 liarities of, 605; surgical anatomy of, 607;  
 surface marking of, 607; lymphatic  
 glands, 702; plexus, 820; surgical ana-  
 tomy of, 831; veins, 682  
 Brachialis anticus muscle, 479  
 Brachio-cephalic artery. *See* Innominate  
 Brachio-radialis muscle. *See* Supinator  
 longus  
 BRAIN, *General anatomy of*, 44; develop-  
 ment of, 93  
 Brain, 723; base of, 747; convolutions of,  
 737; dura mater of, 723; interior of, 751;  
 lobes of, 738; membranes of, dissection of,  
 723; subdivision into parts, 726; upper  
 surface of, 736; weight of, 727  
 Branchial arches, 93  
 Breasts, 1112  
 Bregma, 189  
 Brim of pelvis, 267  
 Broad ligaments of uterus, 1105; formation  
 of, 961  
 Bronchi, right and left, 1042; septum of,  
 1042; in lung, 1052  
 Bronchial arteries, 619, 1054; lymphatic  
 glands, 710; septum, 1042; veins, 686,  
 1054; tubes, *see* Bronchi  
 Brunner's glands, 799  
 Bubonocoele, 1124  
 Buccal arteries, 570; cavity, 921; develop-  
 ment of, 109; glands, 922; lymphatic  
 glands, 699; nerve of facial, 800; of  
 inferior maxillary, 791; veins, 669  
 Buccinator muscle, 399  
 Bulb, artery of, 639; of corpus cavernosum,  
 1086; of corpus spongiosum, 1087; olfac-  
 tory, 748, 766, 777  
 Bulbar portion of spinal accessory nerve,  
 809  
 Bulbi vestibuli, 1111  
 Bulbo-cavernosus muscle, 463  
 Bulbous portion of urethra, 1081  
 Bulbs of the fornix, 749  
 Burdock's column, 720  
 Burns's space, 406  
 Bursæ mucosæ, 306; synoviæ, 306  
 Bursæ of shoulder, 341; of knee, 367  
 Bursal synovial membranes, 306  
 Bursa omentalis, 955; pharyngea, 942  
 Cæcum, 982  
 Calamus scriptorius, 774  
 Calcanean arteries, internal, 663; external,  
 663  
 Calcaneo-astragaloid ligaments, 376  
 Calcaneo-cuboid ligaments, 377  
 Calcaneo-navicular ligaments, 378  
 Calcaneum, 287  
 Calcar femorale, 276; avis, 753  
 Calcarine fissure, 743  
 Calices of kidney, 1069  
 Calloso-marginal fissure, 742  
 Camper's ligament. *See* Triangular liga-  
 ment of Urethra  
 CANALS OR CANAL, accessory palatine, 179;  
 alimentary, 921; anterior dental, 170;  
 palatine, 172; for Arnold's nerve, 157;  
 auditory, 904; carotid, 155, 156; central  
 of modiolum, 913; for chorda tympani,  
 153, 906; of cochlea, 916; crural, 1134;  
 dental posterior, 171; ethmoidal, 150;  
 Haversian, of bone, 27; of Huguier, 153;  
 incisive, 193; inferior dental, 184;  
 infra-orbital, 170; inguinal, 1120; for  
 Jacobson's (tympanic) nerve, 156; lachry-  
 mal, 899; naso-palatine, 181; of Nuck,  
 1097, 1112; of Petit, 894; palatine  
 posterior, 170; anterior, 172; pterygo-pala-  
 tine, 160; sacral, 135; of Schlemm, 882;  
 spermatic, 1120; of spinal cord, 717; spiral  
 of cochlea, 913; of Stilling, 893; of modio-  
 lus, 913; semicircular, 912; for tensor  
 tympani, 157, 907; temporo-malar, 175;  
 vertebral, 139; Vidian, 161; of Wirsung,  
 1006  
 Canaliculi of bone, 29  
 Canalis centralis modioli, 913; membrana-  
 cea, 916; reuniens, 915; spiralis modioli,  
 913  
 Cancellous tissue of bone, 25  
 Canine eminence, 170; fossa, 169; teeth,  
 924  
 Canthi of eyelids, 896  
 Capillaries, 54; structure of, 54  
 Capitellum of humerus, 235  
 Capsular ligament of hip, 357; of knee,  
 365; of shoulder, 339; of thumb, 354;  
 of vertebræ, 313  
 Capsule, external, of brain, 754; internal, of  
 brain, 754; of Glisson, 998; of lens, 893;  
 in fœtus, 99; of kidney, 1061; of Tenon,  
 879  
 Capsules, suprarenal, 1071  
 Caput cornu of cord, 716, 720; gallinaginis,  
 1080

- Cardiac lymphatics, 710; muscular tissue, 40; nerves, 858; from pneumogastric, 808; plexus of nerves, deep, 861; superficial, 862, veins, 695
- Cardinal veins, fetal, 107
- Carotid artery, common, 554; branches of (occasional), 557; peculiarities of, 557; surgical anatomy of, 557; surface marking of, 557; external, 559; branches of, 560; surgical anatomy of, 559; surface marking of, 559; internal, 574; branches of, 577; peculiarities of, 576; surgical anatomy, 577; tubercle, 122
- Carotid branch of Vidian, 788
- Carotid canal, 155, 156; ganglion, 856; groove, 159; plexus, 856; triangle, inferior, 572; triangle, superior, 572
- Carpal arch, anterior, 611; posterior, 612
- Carpal arteries, from radial, 611; from ulnar, 616; ligaments, 352
- Campo-metacarpal articulations, 354
- Carpus, 246; development of, 258; articulations of, 352; surface form of, 257; surgical anatomy of, 258
- CARTILAGE, *General Anatomy of*, 21; cellular, 21; costal, 23; articular, 22; fibrous, 23; hyaline, 21; intercellular substance of, 22; reticular, 24; temporary, 23
- arytenoid, 1034; of auricle, 902
- of bronchi, 1052
- costal, 23, 218; ericoid, 1033; cuneiform, 1034; of ear, 902, 904; ensiform, 213; of epiglottis, 1034
- of Jacobson, 876
- of larynx, 1032
- of the nose, 874
- of the pinna, 902
- of Santorini, 1034; semilunar of knee, 366; of septum of nose, 874
- tarsal, 897; thyroid, 1032; of trachea, 1042; of Wrisberg, 1034
- xiphoid, 213
- Cartilage, articular, 22; cellular, 21; costal, 23; hyaline, 21; permanent, 21; temporary, 23; white fibro-, 23; yellow elastic, 24
- Cartilage cells, 22; lacunæ, 22
- Cartilaginee minores, 874
- Cartilago triticea, 1035
- Caruncula lachrymalis, 899
- Carunculae myrtiformes, 1101
- Cauda equina, 844
- Cava inferior, 691; peculiarities, 692; superior, 684
- Cavernous body, artery of, 639; groove, 159; nerves of penis, 865; plexus, 858; sinus, 676; nerves in, 795; surgical anatomy of, 677
- Cavity, cotyloid, 265; glenoid, 228; of pelvis, 268; sigmoid, greater, 238; lesser, 240; of the great omentum, 962
- Cell, definition of, 7; division of, direct, 11; division of, indirect, 10; nucleus of, 8; reproduction of, 10; structure of, 8
- Cell wall, 11
- Cells of bone, 29; ethmoidal, 164; fat, 20; goblet or chalice, 14; mastoid, 154; prickle, 14
- Cellular tissue, lymphoid, 19; mucoid, 18; retiform, 19
- Cement of teeth, 928; formation of, 932
- Central canal of cord, 717; lobe of cerebrum, 742; ganglionic vessels of brain, 584; tendon of diaphragm, 444
- Central ganglionic system of arteries, 584
- Centres of ossification, 35
- Centrifugal nerve fibres, 47
- Centripetal nerve fibres, 47
- Centrum ovale majus, 751; minus, 751
- Centrum of vertebræ, 121
- Cephalic vein, 681; median, 681
- Cerato-hyal of hyoid bone, 210
- Cerebellar arteries, anterior, inferior, 593; superior, 593; column, 719; veins, 674
- Cerebelli incisura, anterior, 769; posterior, 768
- CEREBELLUM, 768; corpus dentatum of, 771, 774; hemispheres of, 768; laminae of, 772; lobes of, 769; median lobe of, 769; peduncles of, 772; structure of, 771; under surface of, 770; upper surface of, 769; the valley of, 770; ventricle of, 774; weight of, 768
- Cerebral arteries, 583; anterior, 581; middle, 581; posterior, 593; convolutions, 737; lymphatics, 701; topography, 744; veins, 674; ventricles, 752, 757, 759, 774
- CEREBRO-SPINAL AXIS, 712; fluid, 726; nerves, 45
- Cerebro-spinal system, 40
- CEREBRUM, 726, 735; base of, 747; commissures of, 760; commissural fibres of, 764; convolutions of, 737; crura of, 750; fibres of, 763; fissures of, 738; general arrangement of its parts, 750; grey matter of, 44, 765; hemispheres of, 735; interior of, 751; labia of, 751; lobes of, 747; peduncles of, 751; structure of, 763; sulci, 736; under surface, 747; upper surface, 736; ventricles of, 752, 757, 759, 774
- Ceruminous glands, 905
- Cervical artery, ascending, 594; superficial, 596; princeps, 565; profunda, 598
- Cervical fascia, 405
- Cervical ganglion inferior, 859; middle, 859; superior, 856
- Cervical lymphatic glands, deep, 702; superficial, 701; surgical anatomy of, 702
- Cervical nerves, 814; anterior divisions of, 816; posterior divisions of, 814; roots of, 814
- Cervical plexus, 818; deep branches of, 819; posterior, 816; superficial branches of, 818
- Cervical rib, 125
- Cervical veins, deep, 672
- Cervical vertebræ, 121; surgical anatomy of, 319
- Cervicalis ascendens muscle, 435
- Cervico-facial nerve, 800
- Cervix cornu of cord, 720; uteri, 1104
- Chalice cells, 13
- Chambers of the eye, 892
- Chassaignac's tubercle, 122
- Check ligaments, 319
- Cheek, muscles of, 396
- Cheeks, structure of, 922
- Chest, muscles of front of, 468; side, 472;



- surface form of, 219; surgical anatomy of, 220
- Chiasma, or optic commissure, 778
- Cholesterine, 3
- Chondro-glossus muscle, 414; sternal ligaments, 326; xiphoid ligament, 328
- Chorda dorsalis, 80, 88
- Chorda tympani nerve, 798, 911
- Chordæ tendineæ, of right ventricle, 1021; of left, 1024; vocales, 1037; Willisii, 675
- Chorion, 85
- Choroid arteries, anterior, 582; posterior 594; coat of eye, 883; plexus of lateral ventricle, 755; of fourth ventricle, 776; of third ventricle, 759; veins of brain, 674
- Choroidal fissure 98
- Chromatin, 8
- Chromocytes, 2
- Chyle, 7
- Chyli receptaculum, 698
- Cilia, or eyelashes, 897
- Ciliary arteries, 580, 886; ganglion, 784; muscle, 887; nerves, long, 784; short, 786; processes of eye, 884
- Ciliaris muscle, 390; ciliated epithelium, 13; cingulum, 923
- Circle of Willis, 583, 594
- Circular sinus, 677
- Circulation of blood in adult, 1018; in fœtus, 1029
- Circulus tonsillaris, 790
- Circumduction, 310
- Circumferential fibro-cartilage, 24
- Circumflex artery of arm, anterior, 604; posterior, 604; of thigh, external, 651; internal, 651; iliac artery, 644; superficial, 649; iliac vein, 690; superficial, 688; nerve, 823; surgical anatomy of, 831
- Circumflexus palati muscle, 421
- Circumvallate papillæ of tongue, 869
- Cisterna magna, 725; pontis, 725
- Cistern of Pecquet, 698
- Clarke's vesicular column, 721
- Claustral formation of cortex, 766
- Clastrum, 754, 766
- Clava of funiculus gracilis, 730
- Clavicle, 222; development of, 224; fracture of, 503; peculiarities in sexes, 224; surface form of, 224; surgical anatomy of, 224
- Cleft palate, 422
- Clinoid processes, anterior, 161; middle, 158; posterior, 158
- Clitoris, 1100; frænum of, 1100; lymphatics of, 707; muscles of, 466, 1101; prepuce of, 1100
- Clivus, 159; of cerebellum, 770
- Cloaca, 111, 115
- Coccygeal artery, 639; gland, 630; nerve, 844
- Coccygeus muscle, 460
- Coccyx, 136; development of, 137
- Cochlea, 913; aqueduct of, 156; arteries of, 918; central axis of, 913; cupola of, 913; infundibulum of, 913; lamina spiralis of, 914; nerves of, 919; scalæ of, 916; spiral canal of, 913; veins of, 918
- Cochlear artery, 918; nerve, 802, 919
- Cochleariform process, 157, 907
- Celiac axis, 622; plexus, 864
- Cohnheim, areas of, 38
- Colica dextra artery, 627; media, 627; sinistra, 627
- Collateral circulation. *See* Surgical Anatomy of each artery; collateral intercostal artery, 620; fibres of cerebrum, 764; fissure, 743
- Collecting tubes of kidney, 1064
- Colles, fascia of, 461
- Colliculus nervi optici, 887
- Colon, 984
- Colostrum corpuscles, 1113
- Columnella cochleæ, 913
- Columns of abdominal ring, 1117; of spinal cord, 716; of vagina, 1103
- Columnæ carneæ of left ventricle, 1024; of right ventricle, 1022; papillares, 1022, 1024
- Columna nasi, 874
- Columnar epithelium, 13
- Comes nervi ischiadici artery, 640; phrenic artery, 596
- Commissura brevis of cerebellum, 770
- Commissural fibres of brain, 764
- Commissure of Gudden, 778
- Commissure, optic, 778
- Commissures of brain, anterior, 760; middle or soft, 760; posterior, 760; of spinal cord, grey, 717; white, 716
- Common ligaments of vertebræ, 311
- Communicans hypoglossi nerve, 819; peronei, 852; poplitei, 850
- Communicating artery of brain, anterior, 581; posterior, 582; from dorsalis pedis, 660; from ulnar, 616
- Compact tissue of bone, 25, 119
- Complexus muscle, 436
- Compressor narium minor, 396; nasi, 396; sacculi laryngis, 1039; urethræ, 465; in female, 467
- Conarium, 762
- Concentric corpuscles of thymus, 1058
- Conception, where effected, 74
- Concha, 902
- Conducting tracts of cord, 718
- Conductor sonorus, 776
- Condyles of bones. *See* Bones
- Condyloid articulations, 308; foramina, 143; fossæ, 143; process, 185; ridge, external, 235; internal, 235; veins, posterior, 672, 676
- Cone-granules of retina, 890; cones of retina, 890
- Congenital fissures in cranium, 167; hernia, 1126
- Conglobate glands, 58, 697
- Coni vasculosi, 1094
- Conjoined tendon of internal oblique and transversalis, 452, 1119
- Conjunctiva, 898
- Connecting fibro-cartilages, 24
- Connective tissue, 15; development of, 18; vessels of, 18; lymphatics of, 18; nerves of, 18; adenoid, 18; elastic, 16; fibrous, 15; lymphoid, 19; mucoid, or gelatinous, 18; retiform, 19; yellow, 16
- Conoid ligament, 337; tubercle, 222
- Constrictor inferior muscle, 418; medius, 418; superior, 419; isthmi faucium, 421; urethræ, in male, 465; in female, 467
- Contractile fibre cells, 39

- Conus arteriosus, 1020  
 Convolution of corpus callosum, 744  
 Convolutions of cerebrum, structure of, 737; topography of, 744  
 Convolutions, angular, 740; of corpus callosum, 744; cuneate, 744; frontal, 738; marginal, 744; occipital, 741; occipitotemporal, 744; orbital, 738; parietal, 739; precuneus, 744; quadrate, 744; supra-marginal, 740; temporo-sphenoidal, 741; uncinata, 744  
 Coraco-acromial ligament, 338; coraco-brachialis muscle, 478; coraco-clavicular ligament, 335; coraco-humeral ligament, 314  
 Coracoid ligament, 339; process, 229; process, fracture of, 503  
 Cord, spermatie, 1090; spinal, 714; umbilical, 88  
 Cordiform tendon of diaphragm, 444  
 Corium of mucous membrane, 69; of skin, 63; of tongue, 868  
 Cornea, 880  
 Corneal corpuscles, 881; spaces, 881  
 Cornicula laryngis, 1034  
 Cornu Ammonis, 756, 766; formation of, 766  
 Cornua of the coccyx, 136; of hyoid bone, 210; of the sacrum, 133; of thyroid cartilage, 1033  
 Corona glandis, 1086; radiata, 45, 764  
 Coronal suture, 188  
 Coronary artery of stomach, 623  
 Coronary arteries of lip, 564; arteries of heart, 549; peculiarities, 550; ligament of liver, 995; ligaments of knee, 366; plexus, anterior, 862; posterior, 862; sinus, 695; opening of, 1020; valve, 696, 1020  
 Coronoid depression, 235; process of jaw, 185; of ulna, 238  
 Corpora albicantia, 749; Arantii, 1022, 1024; mammillaria, 749; cavernosa penis, 1086; crura of, 1086; cavernosa clitoridis, 1101; geniculata, 759, 763; quadrigemina, 762; striata, 753; veins of, 674  
 Corpus callosum, 751, 764; convolution of, 744; genu of, 751; peduncles of, 751; ventricle of, 751; dentatum of cerebellum, 774; of olivary body, 733; fimbriatum, 758; Highmorianum, 1093; spongiosum, 1087  
 Corpus cavernosum, artery of, 639; dentatum, 771, 774  
 Corpuscles, blood, 2; coloured, 2; white, 3  
 Corpuscles, development of, 102; of Herbst, 49; Malpighian, of kidney, 1063; of Purkinje, 773; of spleen, 1011; tactile, 49; of Vater, 48  
 Corrugator cutis ani, 459; supercillii muscle, 391  
 Cortex of cerebrum, 765; of cerebellum, 772  
 Corti, membrane of, 916; organ of, 916; rods of, 916  
 Cortical arteries of brain, 584  
 Cortical columns, 1062; cortical arches, 1062  
 Cortical substance of brain, 765; of kidney, 1062; of suprarenal capsules, 1072; of teeth, 928  
 Costal cartilages, 23, 218; connection with ribs, 328; process, 122, 129  
 Costo-central articulation, 323  
 Costo-chondral articulation, 328; costo-clavicular ligament, 335; costo-coracoid fascia, 470; costo-coracoid ligament, 470; costo-transverse articulations, 324; costo-vertebral articulations, 323; costo-vertebral ligaments, 323; chondro-xiphoid ligaments, 328  
 Costo-transverse articulation, 323  
 Cotunnus, nerve of, 790  
 Cötylod cavity, 265; ligament, 359; notch, 265  
 Coverings of direct inguinal hernia, 1127; of femoral hernia, 1136; of oblique, 1123; of testis, 1092  
 Cowper's glands, 1085, 1142  
 Cranial bones, 141; articulations of, 186  
 Cranial fossæ, 190  
 CRANIAL NERVES, 776; eighth pair, 801; eleventh, 809; fifth, 782; first, 777; fourth, 781; ninth, 802; second, 778; seventh, 796; sixth, 795; tenth, 803; third, 779; twelfth, 809  
 Cranial nerves, development of, 97  
 Cranial sutures, 186  
 Cranium, 141; development of, 90, 166; congenital fissures in, 167; lymphatics of, 701  
 Cremaster muscle, 452; formation of, 1119  
 Cremasteric artery, 643; fascia, 452  
 Crescents of Gianuzzi, 938  
 Crest, frontal, 149; of ilium, 262; lachrymal, 174; nasal, 168; occipital, 141; internal, 143; turbinated, of palate, 178; of superior maxillary, 172; of os pubis, 264; of spine of scapula, 227; of tibia, 282  
 Cribriform fascia, 510, 1130; plate of ethmoid, 164  
 Crico-arytenoideus lateralis muscle, 1038; posticus muscle, 1038  
 Crico-thyroid artery, 561; membrane, 1035; muscle, 1038  
 Cricoid cartilage, 1033  
 Crista falciformis, 155; galli, 164, 191; pubis, 264; vestibuli, 912  
 Crochet of uncinata gyrus, 744  
 Cross pyramidal tract, 719, 729  
 Crown of a tooth, 923  
 Crucial anastomosis, 640, 651; ligaments of knee, 365  
 Cruciform ligament, 316  
 Crura cerebri, 750; of corpora cavernosa, 1086; of clitoridis, 1101; of diaphragm, 444; of fornix, 757  
 Crural arch, 450, 1131; deep, 457, 1134; canal, 1134; nerve, anterior, 841; surgical anatomy of, 853; ring, 1134; sheath, 1133; septum, 1135  
 Crureus muscle, 514  
 Crus penis, 1085  
 Crusta petrosa of teeth, 928; of crus cerebri, 750, 763  
 Crypts of Lieberkühn, 979  
 Crystalline lens, 893  
 Crystals, blood, 6  
 Cuboid bone, 293  
 Culmen of cerebellum, 770  
 Cuneate lobe, 744; funiculus, 731  
 Cuneiform bone, hand, 250; foot, external, 296; internal, 294; middle, 295; cartilages, 1034

- Cupola of cochlea, 913  
 Curvatures of the spine, 138  
 Cuspidate teeth, 924  
 Cutaneous branches of anterior tibial nerve, 852; of cervical plexus, 818; of circumflex, 823; of dorsal nerve of penis, 849; of dorsal nerves, 832; of external popliteal, 851; internal, 850; of inferior hæmorrhoidal nerve, 847; of ilio-hypogastric, 838; of ilio-inguinal, 839; of intercostal nerves, 834; of lesser sciatic nerve, 847; of lumbar nerves, 836; of median, 827; of musculo-spiral, 830; of ulnar nerve, 828; of arm, musculo-cutaneous, 826; internal, 826; lesser internal, 826; of buttock and thigh, 847; of inguinal region, 1129; of ischio-rectal region, 1138; from obturator, 841; of thigh, external, 839; internal, 842; middle, 842; of patella, 843; of perineal nerve, 849; of plantar nerve, 851; of posterior tibial, 850; of radial, 831; of sacral nerves, 844; of ulnar, 828  
 Cuticle of skin, 61  
 Cuticula dentis, 931  
 Cutis vera, 63  
 Cuvier, ducts of, 106  
 Cylindrical epithelium, 13  
 Cystic artery, 625; duct, 1002; valve of, 1003; plexus of nerves, 864; veins, 695  
  
 Dartos, 1089  
 Decidua, 86; serotina, 87; reflexa, 86; vera, 86  
 Deciduous teeth, 923  
 Decussation of optic nerves, 778; of pyramids, 729  
 Deep crural arch, 457, 1134; palmar arch, 610; perineal fascia, 464, 1140  
 Deferent artery, 635  
 Deglutition, actions of, 422  
 Deltoid aponeurosis, 473; muscle, 473; tubercle, 222  
 Demilunes of Heidenhain, 938  
 Demours, membrane of, 881  
 Dens sapientiæ, 925  
 Dental artery, inferior, 570; posterior, 571; canal, anterior, 170; inferior, 184; posterior, 170; furrow, 929; germ, 929; lamina, 929; nerves, anterior, 788; inferior, 792; middle, 788; posterior, 787; pulp, 932; sacs, 930; tubuli, 927; vein, inferior, 670  
 Dentate fissure, 744  
 Dentinal sac, 930; sheath, 927; tubuli, 927  
 Dentine, 927; formation of, 931  
 Depressions for Pacchionian bodies, 147, 149  
 Depressor alæ nasi, 396; anguli oris, 398; epiglottidis, 1039; labii inferioris, 397  
 Derma, or true skin, 63  
 Dermic coat of hair follicle, 65  
 Descemet, membrane of, 881  
 Descendens hypoglossi nerve, 811  
 Descending aorta, 617; colon, 984; oblique muscle of abdomen, 448  
 Descent of testicle, 1097  
 DEVELOPMENT of atlas, 130; axis, 130; alimentary canal and its appendages, 108; arteries, 104  
 bone, 30  
 DEVELOPMENT (*continued*)  
 carpus, 258; clavicle, 224; coccyx 137; cranium, 90, 166  
 ear, 99; ethmoid, 166; eye, 97  
 face, 90; femur, 277; fibula, 286; foot, 301; frontal bone, 151  
 genital organs, 112  
 hand, 258; heart, 103; humerus, 235; hyoid bone, 210  
 inferior turbinated bone, 181  
 lachrymal bone, 175; lens, 98; lower jaw, 185; lumbar vertebræ, 131  
 malar bone, 176; mammæ, 100; metacarpus, 258; metatarsus, 300; muscles, 101  
 nasal bone, 169; nervous centres, 93; nose, 100  
 occipital bone, 145; os innominatum, 265  
 palate, 92; palate bone, 181; parietal bone, 147; patella, 280; permanent teeth, 932; phalanges of hand, 259; of foot, 300  
 radius, 244; ribs, 218  
 sacrum, 135; scapula, 230; seventh cervical, 131; skin, 100; sphenoid, 162; spine, 88; sternum, 213; superior maxillary bone, 173  
 tarsus, 300; temporary teeth, 929; temporal bone, 157; tibia, 284  
 ulna, 242  
 veins, 105; vertebræ, 129; vomer, 182  
 Wormian, 167  
 Development of organs, chronological table of, 117  
 Diameters of pelvis, 269  
 Diaphragm, 443; development of, 110; lymphatics of, 710  
 Diaphysis, 35  
 Diarthrosis, 307  
 Digestive muscle, 411; fossa, 154; lobe of cerebellum, 770; nerve, from facial, 798  
 Digestion, organs of, 921  
 Digital arteries from ulnar, 616; plantar, 564; cavity of lateral ventricle, 752; fossa, 273; nerves from median, 828; from radial, 831; from ulnar, 829; of foot, 850  
 Dilator naris anterior, 396; posterior, 396  
 Diploë, 120; veins of, 673  
 Direct inguinal hernia, 1126; course of, 1126; coverings of, 1127; pyramidal tract, 718  
 Disc, intermediate, 37; lateral, 37; median of Hensen, 38; transverse, 37  
 Discs, blood, 2; development of, 102  
 Discus proligerus, 73, 1111  
 DISSECTION of abdominal muscles, 447; arm, 473; auricular region, 389; axilla, 467  
 back, 427  
 epicranial region, 387; eye, 882  
 femoral hernia, 1128; face, 390; foot, 535; forearm, 481  
 gluteal region, 518  
 hand, 492; heart, left auricle, 1022; left ventricle, 1024; right auricle, 1018; right ventricle, 1021; hernia, femoral, 1128; inguinal, 1115  
 iliac region, 507  
 inferior maxillary region, 397; infra-hyoid region, 409; inguinal hernia, 1115; ischio-rectal region, 1137



- DISSECTION** of intermaxillary region, 398  
 leg, 526; lingual region, 413  
 neck, 404  
 orbit, 392  
 palatal region, 420; palm of hand, 492;  
 palpebral region, 390; pancreas, 1005;  
 pectoral region, 467; perinæum, 1137;  
 pharynx, 418; pterygoid muscles, 401  
 radial region, 486  
 scalp, 387  
 sole of foot, 537; spinal cord and mem-  
 branes, 712; supra-hyoid region, 411  
 temporal muscle, 400; thigh, front of,  
 510; back of, 524; inner side of, 515  
**Diverticulum**, Meckel's, 976  
**Division** of cells, 10; direct, 11; indirect, 10  
**Dorsal artery** of penis, 639  
**Dorsal nerves**, 832; posterior divisions of,  
 832; anterior divisions of, 834; roots of,  
 832; peculiar, 835  
**Dorsal nerve** of penis, 849  
**Dorsal vein** of penis, 691  
**Dorsal vertebrae**, 125; peculiar, 127  
**Dorsales pollicis arteries**, 612  
**Dorsalis hallucis artery**, 660; indicis, 612;  
 linguae, 561; pedis, 659; branches of, 660;  
 peculiarities of, 660; surgical anatomy of,  
 660; surface marking of, 660; scapulae,  
 604  
**Dorsi-lumbar nerve**, 837  
**Dorsi-spinal veins**, 686  
**Dorsum** of scapula, 225; ephippii or sellae,  
 158  
**Douglas**, pouch of, 961, 1104; semilunar  
 fold of, 455  
**DUCTS** or **DUCT**, of Bartholin, 938; biliary,  
 1001; of Cowper's glands, 1081; of Cuvier,  
 106; cystic, 1002; ejaculatory, 1096; of  
 Gartner, 114; galactophorous, 1113; he-  
 patic, 1001, 1002; of kidney, 1069; lacti-  
 ferous, 1113; of liver, 1001; lymphatic,  
 right, 699; nasal, 900; of pancreas, 1006;  
 parotid, 936; Rivini, 937; seminal, 1094;  
 Stenson's, 936; thoracic, 698; Wharton's,  
 937  
**Ductless glands**: spleen, 1008; suprarenal  
 capsule, 1071; thyroid, 1055; thymus,  
 1057  
**Ductus arteriosus**, 548, 1028; how obliterated  
 in fœtus, 1031; communis chole-  
 dochus, 1003; endo-lymphaticus, 912;  
 pancreaticus accessorius, 1006; Rivini,  
 937; santorini, 1006; venosus, 106, 1030;  
 how obliterated, 1031  
**Duodenal glands**, 979; loop, 951; mesentery,  
 952  
**Duodenum**, 973; vessels and nerves of,  
 975  
**Dura mater** of brain, 723; arteries of, 723;  
 nerves of, 724; processes of, 724; veins  
 of, 723; of cord, 712; peculiarities of,  
 712  
**Dyaster** or daughter star, 10  
 or auricle of, 902; semicircular canals,  
 912; surgical anatomy of, 919; surface  
 form of, 905; tympanum, 905; vestibule,  
 911  
**Ear**, development of, 99  
**Earthy constituents** of bone, 30  
**Ectoderm**, 79  
**Efferent nerves**, 47  
**Egg-tubes**, 113  
**Eighth nerve**, 801; surgical anatomy of,  
 802  
**Ejaculator seminis muscle**, 463  
**Ejaculatory ducts**, 1096  
**Elastic lamina** of cornea, 882; cartilage, 24  
**Elbow**, bend of, 605; joint, 343; anasto-  
 moses around, 608; surface form of, 346;  
 surgical anatomy of, 346; vessels and  
 nerves of, 345  
**Eleventh nerve**, 809; surgical anatomy of,  
 809  
**Embryo**, first rudiments of, 79; develop-  
 ment of, 88  
**Eminence** of aqueductus Fallopii, 907;  
 canine, 170; frontal, 148; ilio-pectineal,  
 262; nasal, 149; parietal, 146  
**Eminences** and depressions of bones, 120  
**Eminentia articularis**, 152; collateralis,  
 756; teres, 776  
**Emissary veins**, 678  
**Enamel cells**, 930; droplet, 931; epithelium,  
 930; of teeth, 928; formation of, 930;  
 organ, 930; rods, 928  
**Enarthrosis**, 308  
**End-bulbs** of Krause, 47  
**End-plates**, motorial, of Kühne, 50  
**Endocardium**, 1025  
**Endolymph**, 914  
**Endomysium**, 36  
**Endoneurium**, 45  
**Endothelium**, 12  
**Ensiform appendix**, 213  
**Entoderm**, 79  
**Eosinophile cells**, 4  
**Eparterial division** of bronchus, 1042  
**Epencephalon**, 94  
**Ependyma**, 752  
**Epiblast**, 76, 79  
**Epicondyles**, 234  
**Epidermic coat** of hair follicle, 65  
**Epidermis**, structure of, 62; development  
 of, 100  
**Epididymis**, 1094; development of, 114  
**Epigastric artery**, deep, 643; peculiarities,  
 644; relation to femoral ring, 1134; with  
 internal ring, 1121; superficial, 649;  
 superior, 598; plexus, 862; region, 947;  
 vein, 690; superficial, 688  
**Epiglottic glands**, 1040  
**Epiglottis**, 1034  
**Epimysium**, 36  
**Epineurium**, 45  
**Epiphysal cartilage**, 30, 34  
**Epiphysis**, 35, 120  
**Epiphysis cerebri**, 761  
**Epithelium**, 12; ciliated, 13; columnar, 13;  
 cylindrical, 13; pavement, 12; spheroidal  
 or glandular, 13; stratified, 14; transi-  
 tional, 15. See Various Organs  
**Epoophoron**, 111, 114  
**Erectile tissue**, its structure, 1087; of penis,  
 1087; of clitoris, 1101

- Erector clitoridis, 466, 1101; penis, 464; spinae, 434
- Eruption of the teeth, 933
- Erythroblasts, 2
- Ethmo-sphenoidal suture, 191
- Ethmoid bone, 163; articulations of, 166; cribriform plate of, 164; development of, 166; lateral masses of, 164; perpendicular plate of, 164; os planum of, 165; unciform process of, 165
- Ethmoidal artery, 578; canal anterior, 150; posterior, 150; cells, 164; notch, 149; process of inferior turbinated, 181; spine, 158
- Ethmo-frontal suture, 191
- Eustachian tube, 157, 908; surgical anatomy of, 920; valve, 1020; in fetal heart, 1028
- Expiration, muscles of, 447
- Extensor coccygis, 438; brevis digitorum muscle, 536; carpi radialis brevior, 487; longior, 487; carpi ulnaris, 489; communis digitorum (hand), 488; indicis, 491; longus digitorum (foot), 527; minimi digiti, 488; ossis metacarpi pollicis, 489; brevis pollicis, 491; proprius hallucis, 527; longus pollicis, 491
- Extensor primi internodii pollicis. *See* Extensor longus pollicis
- Extensor secundi internodii pollicis. *See* Extensor brevis pollicis
- External abdominal ring, 449, 1117; annular ligament, 535; capsule, 754; inguinal hernia, 1123; orbital foramina, 161; pterygoid plate, 162; spermatic fascia, 450, 1118; sphincter ani, 459
- External and inferior frontal artery, 582
- Extrinsic muscles of tongue, 415
- Eye, 879; appendages of, 896; chambers of, 892; ciliary muscle, 887; processes of, 884; humours of, 892; aqueous, 892; crystalline lens, 893; vitreous, 892; membrana pupillaris, 887; choroid, 883; conjunctiva, 898; cornea, 880; hyaloid membrane, 892; iris, 885; Jacob's, 890; retina, 887; sclerotic, 880; pupil of, 885; tunics of, 880; uvea of, 885; vessels of globe of, 894; elastic lamina of cornea, 882; surgical anatomy of, 895
- Eye, development of, 97
- Eyeball, muscles of, 392; nerves of, 895; vessels of, 894
- Eyebrows, 896
- Eyelashes, 897
- Eyelids, 896; cartilages or plates of, 897; development of, 99; Meibomian glands of, 897; muscles of, 390; tarsal ligament of, 897
- Eye-teeth, 924
- Face, arteries of, 562; bones of, 141, 167; development of, 90; muscles of, 386; lymphatics of, 699; nerves of, 796; veins of, 668
- Facial artery, 562; surgical anatomy of, 565; peculiarities of, 564; transverse, 567; bones, 167; nerve, 796; surgical anatomy of, 801; vein, 669; surgical anatomy of, 669
- Falciform process of fascia lata, 512; ligament of liver, 995; ligament of sacro-sciatic articulation, 332
- Fallopian tubes, 1108; development of, 111; fimbriated extremity of, 1108; lymphatics of, 708; nerves of, 1112; structure of, 1108; vessels of, 1112
- False ligaments of bladder, 1077; pelvis, 267; ribs, 215
- Falx cerebelli, 724; cerebri, 724
- Fangs of teeth, 923
- Fasciæ, general description of, 385
- FASCIA, anal, 1146; of arm, 473; of cranial region, 388
- cervical, deep, 405; superficial, 404; of Colles, 461; costo-coracoid, 470; cremasteric, 452; cribriform, 1130
- deep, 386; dentata, 756; dorsal of foot, 536
- fibro-areolar, its structure, 385; plantar, of foot, 535; of forearm, 481
- of hand, 492
- iliac, 507; infundibuliform, 1121; inter-columnar, 450, 1117; intercostal, 441; intermuscular, of arm, 478; of foot, 536; ischio-rectal, 1146
- lata, 510, 1130; falciform process of, 1131; iliac portion, 512, 1131; pubic portion, 512, 1131; of leg, 526; deep transverse, 530; lumborum, 432
- of mamma, 468; masseteric, 400
- of neck, 403
- obturator, 1146
- palmar, 494; parotid, 400, 406; pelvic, 1145; perineal, deep, 1140; superficial, 1139; pharyngeal, 406; plantar, 535; prevertebral, 406; propria of spermatic cord, 1090; of femoral hernia, 1128
- recto-vesical, 1146
- of Scarpa, 448; spermatic, 450, 1118; superficial, 386; of inguinal region, 1115; of ischio-rectal region, 1138; of thigh, 509
- temporal, 400; of thigh, deep, 510; superficial, 510; of thorax, 441, 468; transversalis, 1121; triangular, 451
- visceral layer of pelvic, 1146
- Fasciæ teretes. *See* Eminentia teres
- Fasciculus, of Türek, 718; unciformis, 748
- Fat, 20; fat cells, 20
- Fauces, isthmus of, 934
- Fecundation of ovum, 74
- FEMALE ORGANS OF GENERATION: bulbi vestibuli, 1101; carunculae myrtiformes, 1101; clitoris, 1100; development of, 113, 116; fossa navicularis, 1100; glands of Bartholin, 1101; hymen, 1101; labia majora, 1099; minora, 1100; nymphæ, 1100; uterus, 1103; vagina, 1102; vestibule, 1101
- FEMORAL artery, 644; branches of, 649; common, 646; deep, 650; superficial, 646; peculiarities of, 647; surgical anatomy of, 647; surface marking of, 647; or crural canal, 1134; variation in size of, according to position of limb, 1135; hernia, complete, 1136; coverings of, 1136; descent of, 1136; dissection of, 1128; incomplete, 1136; seat of stricture, 1136; surgical anatomy of, 1128
- region, muscles of anterior, 509; internal,

- FEMORAL (*continued*)  
 515; posterior, 524; ring, 1134; position of surrounding parts, 1134  
 sheath, 1133; spur, 276  
 vein, 689; relation of femoral ring, 1134  
 Femur, 271; articulations of, 277; attachment of muscles to, 278; development of, 277; fracture of, above condyles, 544; below trochanters, 544; head of, 272; neck of, 272; trochanters of, 273; condyles of, 276; structure of, 276; neck, fracture of, 543; surface form of, 278; surgical anatomy of, 278  
 Fenestra ovalis, 907; rotunda, 907, 913  
 Fenestrated membrane of Henle, 17, 52  
 Ferrein, pyramids of, 1064  
 Fertilisation of ovum, 74  
 Fibre-cells, contractile, 39  
 Fibres of muscle, 36; of Müller, 890; of nerves, 39, 50; of Remak, 43  
 Fibrin, 1, 5  
 Fibrinogen, 1, 5  
 Fibrin ferment, 1  
 Fibro-cartilage, 23; interarticular, 23; connecting, circumferential, and stratiform, 24; yellow, 24  
 Fibro-cartilages, acromio-clavicular, 337; intercoccygean, 333; intervertebral, 312; of knée, 366; of lower jaw, 321; pubic, 333; radio-ulnar, 349; sacro-coccygean, 333; sterno-clavicular, 335  
 Fibrous cartilage, 23; connective tissue, 15; nervous matter, 41; rings of heart, 1025; tissue white, 15; yellow, 16  
 Fibro-serous membranes, 68  
 Fibula, 285; articulations of, 286; attachment of muscles to, 287; development of, 286; fracture of, with dislocation of the foot, 545; surface form of, 287  
 Fibular region, muscles of, 533  
 Fifth nerve, 782; surface marking of, 794; surgical anatomy of, 794; ventricle of brain, 757  
 Filiform papillæ of tongue, 869  
 Fillet of the gyrus fornicatus, 764; fillet, inferior or lateral, 762; superior or mesial, 763  
 Filum terminale of cord, 714  
 Fimbriæ of Fallopian tube, 1108  
 First nerve, 777; surgical anatomy of, 778  
 Fissure, auricular, 157; horizontal of cerebellum, 796; of ductus venosus, 996; for gall-bladder, 996; Glaserian, 152, 906; of liver, 996; longitudinal of liver, 996; longitudinal of cerebrum, 735, 748; of lung, 1049; of medulla oblongata, 728; portal, 996; pterygo-maxillary, 198; speno-maxillary, 198; sphenoidal, 161; of spinal cord, 715; Sylvian, 738, 748; transverse, of liver, 996; of cerebrum, 756; umbilical, 996; for vena cava, 996  
 Fissures, congenital, in cranium, 167  
 calcarine, 743; collateral, 743; callosomarginal, 742; dentate, 744  
 intra-parietal, 739  
 parallel, 741; parieto-occipital, 738, 743  
 precentral, 738  
 Rolando, 738  
 Sylvius, 738, 745  
 Flat bones, 119  
 Flexor accessorius muscle, 538; brevis digi-
- torum, 537; brevis minimi digiti, (hand) 499; (foot), 540; brevis pollicis, 496; brevis hallucis, 539; carpi radialis, 482; ulnaris, 482; digitorum sublimis, 483; digitorum profundus, 484; longus digitorum, 532; longus pollicis, 485; longus hallucis, 531; ossis metacarpi pollicis, 495  
 Floating ribs, 215  
 Flocculus, 770  
 Flood's ligaments, 340  
 Fluids of the body, 1  
 Fœtus, circulation in, 1029; Eustachian valve in, 1028; foramen ovale in, 103, 1028; liver of, distribution of its vessels, 1029; ovaries in, 113; vascular system in, peculiarities, 1028  
 Fold of Douglas, 452, 455  
 Folds, aryteno-epiglottidean, 1036; genital, 116; recto-uterine, 1104; recto-vesical, 1077; vesico-uterine, 1104  
 Folium cacuminis, 770  
 Follicle of hair, 65; of intestine, 979  
 Follicles, sebaceous, 66  
 Fontana, spaces of, 882  
 Fontanelles, 144, 166  
 Foot, arteries of, 659, 663; bones of, 287; development of, 300; dorsum, muscles of, 536; fascia of, 536; ligaments of, 376; sole of, muscles of, 536; fascia of, 535; nerves of, 850; surface form of, 302; surgical anatomy, 302; veins of, 689  
 Foramen cæcum of frontal bone, 149, 191; of medulla oblongata, 728; of tongue, 868; carotid, 156; condyloid, 143, 144; dental inferior, 184; ethmoidal, 191; incisive, 193; jugular, 193; infra-orbital, 170; intervertebral, 139; lacerum anterius, 161, 192; medium, 192; posterius, 193; of Majendie, 725, 775; magnum, 142; mastoid, 153; mental, 183; of Monro, 755, 761; obturator, 265; optic, 161, 192; ovale of heart, 103, 1028; of sphenoid, 160, 192; palatine anterior, 172, 193; posterior, 178, 193; parietal, 146; pterygo-palatine, 160; quadratum of diaphragm, 445; rotundum, 160, 192; sacro-sciatic, 263, 332; of Scarpa, 173, 193; of Sömmerring, 887; speno-palatine, 180, 199; spinosum, 160, 192; of Stenson, 173, 193; sternal, 211; stylo-mastoid, 157; supra-orbital, 149; thyroid, 265; Vesalii, 160, 192; of Winslow, 958  
 Foramina, sacral, 132, 133; of diaphragm, 445; external orbital, 161; of Key and Retzius, 726, 775; malar, 175; olfactory, 164; Thebesii, 696, 1020  
 Forearm, arteries of, 609; bones of, 237; fascia of, 481; lymphatics of, 703; muscles of, 481; nerves of, 827; veins of, 680  
 Fore-gut, development of, 108  
 Form of bones, 119  
 Formatio reticularis of medulla, 733  
 Formation of the cornu Ammonis, 766  
 Fornix, 757; bulbs of, 749; conjunctivæ, 898; crura of, 757  
 Fossa acetabuli, 265; of antihelix, 902; canine, 169; condyloid, 143; cochlearis, 912; cystis felleæ, 996; digastric, 154;



- digital, 273; glenoid, 228; of helix, 902; iliac, 262; infra- and supra-spinous, 225; incisive, 169, 183; innominata, 902; ischio-rectal, 1137; jugular, 156; lachrymal, 150; myrtiliform, 169; navicularis of urethra, 1081; of vulva, 1100; occipital, 143; olfactory of fœtus, 100; ovalis, 1020; palatine anterior, 172; pituitary, 158; pterygoid of sphenoid, 162; of lower jaw, 185; scaphoid, 162; scaphoidea, 902; sigmoidea, 154; speno-maxillary, 198; of skull, anterior, 190; middle, 191; posterior, 192; subscapular, 225; sublingual, 184; submaxillary, 184; temporal, 197; triangularis, 902; trochanteric, 273; vesicalis, 994; zygomatic, 197
- Fossa inguinalis lateralis, 1123; mesialis, 1123; supra vesicalis, 1123
- Fossæ, nasal, 201, 875; of skull, 190
- Fourchette, 1100
- Fourth nerve, 781; surgical anatomy of, 781; ventricle, 774
- Fovea inferior of fourth ventricle, 776; centralis retinae, 887; hemispherica, 912; superior of fourth ventricle, 776; semi-elliptica, 912
- FRACTURE of acromion process, 503
- centre of clavicle, 503; acromial end of, 503; coracoid process, 503; coronoid process of ulna, 246
- femur above condyles, 544; below trochanters, 544; fibula, with dislocation of tibia, 545
- humerus, anatomical neck, 237; shaft of, 504; non-union of, 237; surgical neck, 504
- neck of femur, 543
- olecranon process, 505
- patella, 545
- Pott's, 545
- radius, 505; lower end of, 506; neck of, 505; shaft of, 505, and ulna, 506
- tibia, shaft of, 545
- ulna, shaft of, 505
- Fræna of ileo-cæcal valve, 984
- Frænulum of Vieussens' valve, 772
- Frænulum clitoridis, 1100; labii superioris et inferioris, 922; linguæ, 867; præputii, 1086
- Frontal artery, 580; bone, 148; articulations of, 151; attachment of muscles to, 151; development of, 151; structure of, 151; crest, 149; eminence, 148; lobe, 738; nerve, 783; process of malar, 175; sinuses, 149; suture, 148, 151; vein, 668
- Frontalis muscle, 389
- Fronto-nasal process, 92
- Fronto-sphenoidal suture, 188
- Fundus of uterus, 1103
- Fungiform papillæ of tongue, 869
- Funiculi of nerve, 45
- Funiculus cuneatus, 729; gracilis, 730; of Rolando, 729; teres, 776
- Furrow, auriculo-ventricular, 1018; genital, 116; interventricular, 1018
- Furrowed band of cerebellum, 770
- Galactophorous ducts, 1113
- Galen, veins of, 695, 759
- Gall-bladder, 1002; development of, 110; fissure for, 996; structure of, 1002; valve of, 1002; surface form, 1003
- GANGLION OR GANGLIA, *General Anatomy of*, 50; of Andersch, 802; Arnold's, 793; of Bochdalek, 788, 790
- cardiac, 862; carotid, 856; cephalic, 784; cervical, inferior, 859; middle, 859; superior, 856; ciliary, 784; on circumflex nerve, 823
- diaphragmatic, 864
- on facial nerve, 797; of fifth nerve, 784
- Gasserian, 782; of glosso-pharyngeal, 805; geniculate, 797
- impar, 854, 861; inferius, 805; inter-carotid, 859; on posterior interosseous nerve, 831
- jugular, 805
- lenticular, 784; lingual, 859; lumbar, 860
- Meckel's, 788; mesenteric, 865
- ophthalmic, 784; otic, 793
- petrous, 803; pharyngeal, 859; of pneumogastric, 806; of portio dura, 797; of Ribes, 858; of root of vagus, 805
- sacral, 861; semilunar, of abdomen, 862; of fifth nerve, 784; speno-palatine, 788; of spinal nerves, 813; spirale, 919; submaxillary, 794; suprarenal, 864; of sympathetic nerve, 854
- temporal, 859; thoracic, 860; thyroid, 859; of trunk of vagus, 805
- of Valentin, 788
- of Wrisberg, 862
- Ganglion of the cerebellum, 774
- Ganglion corpuscles, 51
- Ganglionic branch of nasal nerve, 784
- Ganglionic nerves, 45
- Gartner, duct of, 114
- Gases of the blood, 6
- Gasserian ganglion, 782: depression for, 155
- Gastric arteries (vasa brevia), 625; artery, 623; follicles, 970; impression of liver, 994; nerves from vagus, 808; plexus, 864; vein, 694
- Gastrocnemius muscle, 528
- Gastro-colic, omentum, 965
- Gastro-duodenal artery, 624; plexus, 864
- Gastro-epiploica dextra artery, 624; sinistra, 625
- Gastro-epiploic plexus, 864; veins, 693
- Gastro-hepatic omentum, 964
- Gastro-phrenic ligament, 968
- Gastro-splenic omentum, 965
- Gelatinous connective tissue, 18
- Gemellus inferior muscle, 522; superior, 522
- GENERATIVE ORGANS, development of, 112; female, 1099; male, 1083
- Genial tubercles, 183
- Geniculate bodies, 759, 763; ganglion, 797
- Genio-hyo-glossus muscle, 413
- Genio-hyoid muscle, 412
- Genital cord, 111; corpuscles, 48; folds, 116; furrow, 116; ridge, 112; tubercle, 116
- Genito-crural nerve, 839
- Genu of corpus callosum, 751
- Gerlach's nerve network, 721
- Germinal area, 76; disc, 76; epithelium, 112; matter, 8; vesicle, 73; spot, 73
- Giant cells, 26
- Gianuzzi, crescents of, 938
- Gimbernat's ligament, 450, 1132

- Gingival branches of dental nerves, 787  
 Ginglymus, 308  
 Giraldès, organ of, 114  
 Girdle, shoulder, 221; pelvic, 221  
 Glabella of frontal bone, 149, 199  
 Gladiolus, 211  
 Glands, development of, 100  
 Glands, simple secreting, 71; tubular, 71; convoluted tubular, 71; racemose or saccular, 71; compound tubular, 71  
 GLANDS, DUCTLESS, 1008; spleen, 1008; suprarrenal, 1071; thymus, 1057; thyroid, 1055  
 GLANDS, LYMPHATIC, 58  
 GLAND OR GLANDS, SECRETING, 70; accessory of parotid, 936; arytenoid, 1040 of Bartholin, 1101; of biliary ducts, 1003; Brunner's, 979; buccal, 922 ceruminous, 905; coecygeal, 630; Cowper's, 1085, 1142 duodenal, 979 epiglottic, 1040 gastric, 970 of Havers, 306 labial, 922; lachrymal, 899; of larynx, 1040; lingual, 870; of Littré, 1081; of Luschka, 630 mammary, 1112; Meibomian, 897; molar, 922; mucilaginous of Havers, 306 odoriferae, 1086 oesophageal, 944 of Pacchioni, 675, 724; palatal, 934, 939; parotid, 935; Peyer's, 980; pharyngeal, 942; pineal, 761; pituitary, 749; prostate, 1083 salivary, 935; sebaceous, 66; solitary, 979; sublingual, 937; submaxillary, 937; sudoriferous, 66; suprarrenal, 1071 thymus, 1057; thyroid, 1055; tracheal, 1043; of Tyson, 1086 uterine, 1106 of vulva, 1101  
 Glandulae odoriferae, 1086; Pacchioni, 675, 723, 724  
 Glandular epithelium, 13  
 Glans penis, 1085; clitoridis, 1101  
 Glasserian fissure, 152, 906  
 Gleno-humeral ligament, 340  
 Glenoid cavity, 228; fossa, 152; ligament of shoulder, 340; of Cruveilhier, 356, 382; of phalanges, 356  
 Gliding movement, 310  
 Glisson's capsule, 965, 998  
 Globules, blood, 2; development of, 102  
 Globus major of epididymis, 1004; minor, 1004  
 Glosso-epiglottic ligaments, 867, 1035  
 Glosso-pharyngeal nerve, 802  
 Glottis, rima of, 1036  
 Gluteal aponeurosis, 519  
 Gluteal artery, 641; inferior, 640; lymphatic glands, 704; nerve, inferior, 847; superior, 846; region, lymphatics of, 706; muscles of, 518; ridge, 274; veins, 690  
 Gluteus maximus muscle, 518; medius, 519; minimus, 520  
 Goblet cells, 13  
 Gogli, organs of, 50  
 Goll's tract, 720  
 Gomphosis, 307  
 Graafian vesicles, 1110; membrana granu-  
 losa of, 1111; ovicapsule of, 1111; structure of, 1110  
 Gracilis muscle, 515  
 Granular formation of cortex, 766; cells, 18; layer of dentine, 928  
 Great omentum, 965; sciatic nerve, 849; surgical anatomy of, 853  
 Greater wings of sphenoid, 160  
 Grey matter of cerebellum, 772; of cerebrum, 765; of medulla oblongata, 733; of spinal cord, 720  
 Grey nervous substance, 41  
 Groin, 1128; cutaneous vessels and nerves of, 1128; superficial fascia of, 1128; surgical anatomy of, 1128  
 Groove, auriculo-ventricular, 1018; bicipital, 233; cavernous, 159; infra-orbital, 170; lachrymal, 172; mylo-hyoid, 184; nasal, 168; occipital, 154; optic, 158; subclavian, 218  
 Grooves in the radius, 244; interventricular, 1018  
 Growth of bone, 34  
 Gubernaculum dentis, 932; testis, 1097  
 Gulf of internal jugular vein, 671  
 Gums, 922  
 Gustatory nerve, 792  
 Gyri, or convolutions of brain, 736  
 Gyri, annectant, 740, 741; operati, 742  
 Gyrus fornicatus, 744  
 Gyrus, or lingual lobule, 744
- Hæmatoidin crystals, 6  
 Hæmin crystals, 6  
 Hæmoglobin, 3; crystals, 6  
 Hæmorrhoidal artery, inferior, 638; middle, 636; superior, 627; nerve, inferior, 847; plexus of nerves, 865; venous plexus, 690; surgical anatomy of, 690  
 Hair cells, of internal ear, 917  
 HAIRS, 64; structure of, 65; root-sheath, 65; follicles, 65; shaft, 66  
 Ham, region of the, 652  
 Hamstring tendons, surgical anatomy of, 525  
 Hamular process of sphenoid, 162; of humerus, 234 *note*; of lachrymal, 175  
 Hand, arteries of, 610; bones of, 246; fascia of, 492; ligaments of, 352; muscles of, 492; nerves of, from median, 827; from radial, 831; from ulnar, 829; surface form of, 257, 502; veins of, 680  
 Hard palate, 934  
 Harmonia, 307  
 Hasner, valve of, 900  
 Havers, glands of, 306  
 Haversian canals of bone, 27; systems of bone, 27  
 Head, lymphatics of, 699; muscles of, 387; veins of, 667; of scapula, 228; of ulna, 242  
 Head, kidney, 111  
 HEART, 1017; development of, 103 annular fibres of auricles, 1026; arteries of, 549, 1027 circular fibres of, 1026; component parts of, 1018 endocardium, 1025 fibres of the auricles, 1026; of the ventricles, 1026; fibrous rings of, 1025; fetal relics in, 1019 infundibulum of, 1020

HEART (*continued*)

- left auricle, 1022; ventricle, 1024; looped fibres of auricles, 1026; lymphatics of, 710, 1027  
 muscular fibres of, 1026; structure of, 40  
 nerves of, 808, 861, 1027  
 position of, 1018  
 right auricle, 1018; ventricle, 1020  
 septum, ventriculorum, 1024; size and weight, 1018; spiral fibres of, 1026; structure of, 1025; subdivision into cavities, 1018; surface marking of, 1027; veins of, 1027; vortex of, 1026
- Heidenhain, demilunes of, 938  
 Helicine arteries, 1087  
 Helicis, major muscle, 903; minor, 903  
 Helicotrema of cochlea, 913  
 Helix, 902; fossa of, 902; muscles of, 903; process of, 902  
 Henle, looped tubes of, 1064  
 Henle's layer of hair follicle, 65  
 Hepatic artery, 623, 1000; cells, 999; duct, 1002; plexus, 864; veins, 693, 998, 1000  
 Herbst, corpuscles of, 49
- HERNIA, congenital, 1126; direct inguinal, 1126; femoral, coverings of, 1136; descent of, 1136; dissection of, 1128; encysted, 1126; of funicular process, 1126; infantile, 1126; inguinal, 1115; dissection of, 1115; oblique inguinal, 1123; scrotal, 1124  
 Hesselbach's triangle, 1123, 1126  
 Hiatus Fallopii, 155  
 Highmore, antrum of, 171  
 Hilton's muscle, 1039  
 Hilum of kidney, 1061; of spleen, 1008  
 Hind-gut, development of, 109; hind-kidney, 111  
 Hinge-joint, 308  
 Hip-joint, 357; muscles of, 518; in relation with, 360; surface form of, 361; surgical anatomy of, 361  
 Hippocampus major, 756; minor, 753  
 Horizontal plate of ethmoid, 164; of palate, 177  
 Horner's muscle, 392  
 Houston's valves of rectum, 989  
 Howship's lacunae, 26  
 Huguier, canal of, 153, 906  
 Humerus, 231; anatomical neck, fracture of, 237; articulations of, 236; attachment of muscles to, 236; development of, 235; head of, 231; neck of, 231; nutrient artery of, 608; shaft, fracture of, 504; surgical neck, fracture of, 504; tuberosities of, greater, 231; lesser, 232; surface form of, 236; surgical anatomy, 237  
 Humours of the eye, 892  
 Hunter's canal, 645  
 Huxley's layer of hair follicle, 65  
 Hyaline cartilage, 21; cell, 4  
 Hyaloid membrane of eye, 892  
 Hydatid of Morgagni, 114  
 Hymen, 1101  
 Hyo-epiglottic ligament, 1034  
 Hyo-glossal membrane, 867, 871  
 Hyo-glossus muscle, 413  
 Hyoid arch (fetal), 93; artery of superior thyroid, 560; bone, 209; attachment of muscles to, 210; cornua of, 210; develop-
- ment of, 210; branch of lingual artery, 561; region, muscles of, infra, 409; supra, 411  
 Hyparterial branch of bronchus, 1042  
 Hypoblast, 76, 79  
 Hypochondriac regions, 947  
 Hypogastric arteries in foetus, 104, 634, 1028; how obliterated, 1031; plexus, 865; inferior, 865; region, 948  
 Hypoglossal nerve, 809; surgical anatomy, of, 812  
 Hypophysis cerebri, 749; of pituitary body, 95
- Ileo-cæcal fossa, 983; valve, 983  
 Ileo-colic artery, 626; fossa, 983  
 Ileum, 975  
 Iliac arteries, common, 631; peculiarities, 631; surgical anatomy of, 632; surface marking of, 632; external, 642; surgical anatomy of, 642; surface marking of, 642; internal, 633; peculiarity in the foetus, 634; at birth, 634; surgical anatomy of, 634; fascia, 507; portion of fascia lata, 512; fossa, 262; furrow, 270; lymphatic glands, 706; region, muscles of, 507; veins, common, 691; peculiarities of, 691; external, 690; internal, 690  
 Iliacus muscle, 508  
 Ilio-costalis muscle, 435  
 Ilio-femoral ligament, 358  
 Ilio-hypogastric nerve, 838  
 Ilio-inguinal nerve, 839  
 Ilio-lumbar artery, 640; ligament, 330; vein, 691  
 Ilio-pectineal eminence, 264  
 Ilio-tibial band, 511, 512  
 Ilio-trochanteric ligament, 358  
 Ilium, 259; crest of, 262; dorsum of, 260; spines of, 262; venter of, 262  
 Impressio colica, 994; duodenalis, 994; renalis, 994  
 Incisive foramina, 193; fossa, 169, 183  
 Incisor teeth, 923  
 Incisura intertragica, 902; cerebelli posterior or marsupialis, 769; anterior or semilunaris, 769; Rivini, 906, 909; Santorini, 904  
 Incremental lines of dentine, 928  
 Incus, 909; development of, 99; ligament of, 909; suspensory, 910  
 Infantile hernia, 1126  
 Inferior dental artery, 570; dental canal, 184; maxillary bone, 183; changes produced by age in, 186; meatus of nose, 204; occipital fossa, 143; profunda artery, 608; turbinated bones, 180; articulations of, 181; development of, 181; ethmoidal process of, 181; lachrymal process of, 181; maxillary process of, 181; vena cava, 691  
 Inferior posterior lobe of cerebellum, 770  
 Infracostal muscles, 442  
 Infraglenoid tubercle, 228  
 Inframaxillary nerves from facial, 800  
 Infra-orbital artery, 571; canal, 170; foramen, 170; groove, 170; plexus of nerves, 786; branches of facial, 799  
 Infraspinus muscle, 476  
 Infraspinous fascia, 475; fossa, 225



- Infra-sternal depression, 219  
 Infratrochlear nerve, 784  
 Infundibula of kidney, 1069  
 Infundibuliform fascia, 457, 1121  
 Infundibulum of brain, 749; of ethmoid, 166; of cochlea, 913; of heart, 1020  
 Ingrassias, processes of, 161  
 Inguinal canal, 1120; glands, deep, 704; superficial, 704, 1116; hernia, 1115; region, 948; dissection of, 1115  
 Inlet of pelvis, 268  
 Innominate artery, 553; peculiarities of, 553; surgical anatomy of, 554; bone, 259; articulations of, 266; attachment of muscles to, 266; development of, 265; veins, 683; peculiarities of, 684  
 Inorganic constituents of bone, 30  
 Insertion of muscles, 385  
 Inspiration, muscles of, 446  
 Interarticular fibro-cartilage, 23; of acromioclavicular joint, 337; of jaw, 321; of knee, 366; of radio-ulnar joint, 349; of sterno-clavicular joint, 335; ligament of ribs, 324  
 Intercarotid ganglion, 859  
 Inter-cellular substance of cartilage, 22; biliary passages, 1001  
 Interchondral ligaments, 328  
 Interclavicular ligament, 335  
 Intercolumnar fascia, 450, 1117; fibres, 450  
 Intercondyloid notch, 275  
 Intercostal arteries, 619; anterior, 596; superior, 598; fasciæ, 441; lymphatics, 710; lymphatic glands, 709; muscles, 441; nerves, 834; spaces, 215; veins, superior, 684  
 Intercosto-humeral nerves, 827, 835  
 Interlobular spaces, 928  
 Interlobular arteries of kidney, 1066  
 Interlobular biliary plexus, 1001  
 Internaxillary suture, 199  
 Intermediate cell mass, 111  
 Intermediate disc of muscular fibre, 37  
 Internembranous ossification, 34  
 Internal abdominal ring, 1121; annular ligament, 535; capsule, 754; carotid artery, 574; cutaneous nerve, 826; inguinal hernia, 1123; mammary artery, 596; maxillary artery, 568; branches of, 569; mammary vein, 684; oblique muscle, 451; occipital crest, 143; pterygoid plate, 162; sphincter, 459  
 Internasal suture, 199  
 Internodia, or phalanges, 256  
 Internodal segment of nerves, 43  
 Interosseus muscles, dorsal of hand, 499; of foot, 541; palmar, 500; plantar, 541  
 Interosseous artery of forearm, 614; recurrent, 615; of foot, 660  
 Interosseous fibro-cartilages, 307  
 Interosseous membrane of forearm, 348; of leg, 372  
 Interosseous nerve, anterior, 827; posterior, 831  
 Interosseous veins of forearm, 682  
 Interpeduncular space of brain, 749  
 Interspinales muscles, 438  
 Interspinous ligaments, 314  
 Intertransversales muscles, 438; laterales, 438; mediales, 438  
 Intertransverse ligaments, 314  
 Intertrochanteric line, anterior, 273; posterior, 274  
 Intertubular stroma of kidney, 1068  
 Intervertebral notches, 121; foramen, 139; substance, 312  
 Intestine, development of, 108; lymphatics of, 709; large, coats of, 988; small, 973; coats of, 976; surface marking, 990; surgical anatomy of, 990  
 Intracartilaginous ossification, 30  
 Intralobular veins, 1000  
 Intramembranous ossification, 34  
 Intraparietal fissure, 739  
 Intrinsic muscles of tongue, 415  
 Intumescentia gangliiformis, 797  
 Investing mass of Rathke, 91  
 Involuntary muscle, 39  
 Iris, 885  
 Irregular bones, 120  
 Ischiatic lymphatic glands, 704  
 Ischio-capsular ligament, 358  
 Ischio-rectal fascia, 1146; fossa, 1137; position of vessels and nerves in, 1137; region, surgical anatomy of, 1137  
 Ischium, 262; body of, 262; ramus of, 263; spine of, 263; tuberosity of, 263  
 Island of Reil, 742  
 Isthmus of the fauces, 934; of thyroid gland, 1055  
 Iter a tertio ad quartum ventriculum, 761; chordæ anterior, 798; posterior, 798  
 Ivory of tooth, 927  
 Jacob's membrane, 890  
 Jacobson's nerve, 803, 911; canal for, 156; organ of, 876; cartilage of, 876  
 Jaw, lower, 183; condyle of, 185; changes produced in, by age, 186; development of, 185; articulations of, 186; ligaments of, 320; attachment of muscles to, 186; oblique line of, 184; pterygoid fossa of, 185; rami of, 184; sigmoid notch of, 185; symphysis of, 183; upper, *see* Maxillary Bone  
 Jejunum, 975  
 Jelly of Wharton, 88  
 Joint. *See* Articulations  
 Jugular foramen, 193; fossa, 156, 195; ganglion, 803; process, 143; vein, anterior, 671; external, 670; surgical anatomy of, 671; posterior external, 671; internal, 671; surgical anatomy of, 672; sinus or gulf of, 671; surface, 157  
 Karyokinesis, 10  
 Karyomitosi, 10  
 Kerkring, valves of, 976  
 Kidney, 1060; calices of, 1062; cortical substance of, 1062; development of, 110; ducts of, 1069; hilum of, 1061; infundibula of, 1062; lymphatics of, 708, 1068; Malpighian bodies of, 1063; mammilla of, 1062; medullary substance, 1062; nerves of, 1068; papillæ of, 1062; pelvis of, 1062; pyramids of Ferrein, 1064; renal artery, 628, 1066; sinus of, 1061; surface marking of, 1068; surgical anatomy of, 1069; tubuli uriniferi, 1063; veins of, 693, 1067; weight and dimensions of, 1060

- Knee-joint, 363; surface form of, 370; surgical anatomy of, 370
- Krause's membrane, 37; end bulbs of, 47
- Kuhne, his views on the terminations of motor nerves, 50
- Küschner, on structure of heart's valves, 1021
- Labia cerebri, 751; pudendi majora, 1099; minora, 1100; lymphatics of, 707
- Labial artery, 564; glands, 922; veins, superior, 669; inferior, 669
- Labio-dental strand, 929
- Labium tympanicum, 916; vestibulare, 916
- Labyrinth, 914; arteries of, 918; fibrous membrane of, 918
- Lachrymal apparatus, 899; artery, 578; bone, 174; articulations of, 175; attachment of muscles to, 175; development of, 175; canals, 899; caruncula, 899; crest, 174; fossa, 150; gland, 899; groove, 172; nerve, 783; notch, 170; papilla, 899; process of inferior turbinated bone, 181; puncta, 899; sac, 900; tubercle, 172
- Lacteals, 697, 709, 978
- Lactiferous ducts, 1113
- Lacuna magna, 1081
- Lacunæ of bone, 28; Howship's, 26
- Lacus lachrymalis, 896, 899
- Lambda, 189
- Lambdoid suture, 188
- Lamella, horizontal, of ethmoid, 164; perpendicular of ethmoid, 164
- of bone, articular, 305
- Lamellæ of bone, 28
- Lamina cinerea, 748; cribrosa, 155; cribrosa of sclerotic, 880; fusca, 880; spiralis ossea of cochlea, 913; suprachoroidea, 883; vitrea, 884
- Lamina of cornea, elastic, 882; of the vertebræ, 121; cerebellum, 768
- Lamina dorsales, 80, 88
- Laminated tubercle of cerebellum, 771
- Lancisi, nerves of, 751
- Lanugo (fetal hairs), 100
- Large intestine, 982; areolar coat, 989; cæcum, 982; colon, 984; ileo-cæcal valve, 983; mucous coat, 989; muscular coat, 988; rectum, 987; serous coat, 988
- Laryngeal artery, inferior, 594; superior, 560; nerve, external, 807; internal, 807; recurrent, 807, superior, 807, from sympathetic, 858; pouch, 1037; veins, 671; nerves, surgical anatomy of, 808
- Laryngo-tracheotomy, 1044
- Laryngotomy, 1045
- Larynx, 1032; actions of muscles of, 1039; arteries of, 1040; cartilages of, 1032; cavity of, 1036; glands of, 1040; interior of, 1036; ligaments of, 1035; lymphatics of, 1040; mucous membrane of, 1040; muscles of, 1038; nerves of, 1040; rima glottidis, 1036; superior aperture of, 1036; surface form of, 1044; surgical anatomy of, 1044; veins of, 1040; ventricle of, 1037; vocal cords of, false, 1037; true, 1037
- Lateral disc of muscular fibre, 37; ligaments of liver, 995; masses of ethmoid, 164; patellar ligaments, 364; recess of fourth ventricle, 774; region of skull, 196; sinus of brain, 676; horn of spinal cord, 721; tract of medulla oblongata, 729, 731
- Lateralis nasi artery, 564
- Latissimus dorsi muscle, 429
- Lecithin, 3
- Leg, arteries of, 652
- bones of, 279
- fascia of, 525; deep transverse, 530
- ligaments of, 371
- lymphatics of, 704
- muscles of, 525; back of, 528; front of, 525
- nerves of, 850
- veins of, 687
- Lens, 893; changes produced in, by age, 894; development of, 98; suspensory ligament of, 894
- Lenticular ganglion, 784; glands of stomach, 971
- Lesser lachrymal bone, 175; omentum, 964; sciatic nerve, 847; wings of sphenoid, 160
- Levator anguli oris, 397; anguli scapulæ, 430; ani, 459; glandulæ thyroideæ, 1056; labii inferioris, 397; labii superioris alæque nasi, 396; labii superioris, 396; menti, 397; palati, 420, palpebræ, 392; prostata, 460
- Leucocytes, 3; development of, 99
- Levatores costarum, 443
- Lieberkühn, crypts of, 979
- Lieno-renal ligament, 1008
- LIGAMENT, structure of, 305; acromio-clavicular, superior, 336; inferior, 336; alar of knee, 367; of ankle, anterior, 373; lateral, 373; annular of radius, 348; of wrist, anterior, 351; posterior, 351; of ankle, 534; external, 535; internal, 535, of stapes, 909; anterior of knee, 363; arcuate, 444; aryteno-epiglottic, 1034; astragalo-navicular, 378; atlanto-axial, anterior, 315; posterior, 316
- of bladder, false, 1077; true, 1076
- broad, of liver, 995
- calcaneo-astragaloid, external, 376; posterior, 377; interosseous, 377; calcaneo-cuboid, internal, 377; long, 377; short, 377; superior, 377; calcaneo-navicular, inferior, 378; superior, 378; capsular (*see* Individual Joints); carpo-metacarpal, dorsal, 355; interosseous, 355; palmar, 355; of carpus, 352; central of spinal cord, 714; check, 319; common vertebral anterior, 311; posterior, 312; conoid, 337; coraco-acromial, 338; coraco-clavicular, 337; coraco-humeral, 340; coracoid, 339; coronary of liver, 995; costo-clavicular, 335; chondro-sternal, anterior, 326; posterior, 327; costo-transverse, 325; costo-vertebral, or stellate, 323; cotyloid, 359; erico-arytenoid, 1036; ericothyroid, 1035; crucial of knee, 365; eruciform, 316
- deltoid, 373; dorsal (*see* Individual Joints) of elbow, 343; anterior, 343; external lateral, 345; internal lateral, 344; posterior, 344
- falciform of liver, 995; of pelvis, 332
- gastro-phrenic, 968; Gimbernat's, 450; 1118, 1132; glenoid, 340; glosso-epiglottidean, 867, 1035

LIGAMENT (*continued*)

of Hesselbach, 455  
 of hip, 357; hyo-epiglottic, 1034  
 ilio-femoral, 358, ilio-lumbar, 330; ilio-trochanteric, 358; of incus, 909; inter-articular of ribs, 324; interclavicular, 335; interchondral, 328; interosseous (*see* Individual Joints); interspinous, 314; intertransverse, 314; intervertebral, 312; ischio-capsular, 358  
 of jaw, 320  
 of knee, 363  
 of larynx, 1035; lateral (*see* Individual Joints); longitudinal of liver, 995; long plantar, 377; lumbo-iliac, 330; lumbo-sacral, 330  
 metacarpal, 356; metacarpo-phalangeal, 356; metatarsal, 381; metatarso-phalangeal, 382; mucosum of knee, 367; of malleus, 909  
 nuchæ, 429  
 oblique, 348; oblique sacro-iliac, 331; obturator, 521; occipito-atlantal, anterior, 317; lateral, 318; posterior, 318; occipito-axial, 318; odontoid, 319; orbicular, 348; of ossicula, 909; of ovary, 1112  
 palpebral or tarsal, 897; of patella, 363; of pelvis, 330; of the phalanges, hand, 357; foot, 383; phreno-colic, 966; of the pinna, 903; plantar, 377; posterior of knee, or posticum Winslowii, 364; Poupart's, 450, 1118, 1131; pterygo-maxillary, 399; pubic, anterior, 333; posterior, 333; superior, 333; subpubic, 333; pubo-femoral, 358; pubo-prostatic, 1077  
 radio-carpal, 350; radio-ulnar joint, inferior, 349; middle, 348; superior, 347; recto-uterine, 1104; rhomboid, 335; round, of uterus, 1112; of liver, 996; of radius and ulna, 347; of hip, 357  
 sacro-coccygeal, anterior, 332; posterior, 332; sacro-iliac, anterior, 331; oblique, 331; posterior, 331; sacro-sciatic, greater, 331; lesser, 332; sacro-uterine, 1105; sacro-vertebral, 329; of scapula, 338; scapulo-clavicular, 336; of shoulder, 339; spring, 378; stellate, 323; sterno-clavicular, anterior, 334; posterior, 335; of sternum, 328; stylo-maxillary, 321; subpubic, 333; suprascapular, 314; suspensory of incus, 910; of lens, 894; of liver, 995; of malleus, 909; of mamma, 468; of penis, 1085; of spleen, 1008; sutural, 307  
 tarsal of eyelids, 391, 897  
 tarso-metatarsal, 380; of tarsus, 376; teres of hip, 359; thyro-arytenoid, inferior, 1037; superior, 1037; of thumb, 354; tibio-tarsal, 373; thyro-epiglottic, 1034; thyro-hyoid, 1035; tibio-fibula, 371; transverse of atlas, 316; of hip, 360; of knee, 366; of scapula, 339; transverse humeral, 340; trapezoid, 337; triangular of urethra, 1140; of tympanic bones, 909  
 of uterus, 1104  
 of vertebræ, 311; vesico-uterine, 1104

LIGAMENT (*continued*)

of Winslow, 364; of wrist, anterior, 351; lateral external, 351; lateral internal, 351; posterior, 351  
 of ZINN, 393  
 Ligamenta alaria, 367; subflava, 313; suspensoria of mamma, 468  
 Ligamentous action of muscles, 310  
 Ligamentum arcuatum externum, 444; internum, 444; denticulatum, 714; latum pulmonis, 1046; mucosum, 367; nuchæ, 429; oculi, 879; patella, 363; pectinatum iridis, 882, 885; posticum Winslowii, 364; spirale, 916; suspensorium, 319; teres, 359  
 Ligature of arteries. *See* each Artery.  
 Ligula, 775  
 Limbs, development of, 100  
 Limbus laminae spiralis, 916; luteus, 887  
 Linea alba, 456; aspera, 274; ilio-pectinea, 264; quadrata, 274; splendens, 714; suprema, 142  
 Lineæ semilunares, 456; transverse of abdomen, 456  
 Lines of Schreger, 928  
 Lingual artery, 561; surgical anatomy of, 562; bone, 209; ganglion, 859; lobule, 744; nerve, 792; strand, 929; veins, 672  
 Lingualis musele, inferior, 417; superior, 416; transverse, 416; vertical, 416  
 Lingula, 770, 772; of inferior maxilla, 184; of sphenoid, 159  
 Lips, 921; arteries of, 564  
 Liquor, amnii, 85; Cotunnii, 918; Scarpæ, 915; sanguinis, 5  
 Lithotomy, parts concerned in operation of, 1143; avoided in operation, 1144; divided, 1144  
 Littré, glands of, 1081  
 LIVER, 993; changes of position in, 1003; development of, 110; distribution of vessels to, in fœtus, 1029; ducts of, 1001; fibrous coat of, 998; fissures of, 996; hepatic artery, 623, 1000; hepatic cells, 999; hepatic duct, 1002; hepatic veins, 693, 1,000; ligaments of, 995; lateral, 995; coronary, 995; round, 996; longitudinal, 995; lobes of, 997; lobules of, 998; lymphatics of, 708; nerves of, 864; portal vein, 695; situation, size, and weight, 993; structure of, 998; its surfaces and borders, 993; surface marking of, 1003; vessels of, 999; surgical anatomy, 1004  
 Liver ridge, 952  
 Lobe, central, 742; cuneate, 744; frontal, 738; marginal, 744; occipital, 741; orbital, 738; parietal, 739; quadrate, 744; temporo-sphenoidal, 741; uncinata, 744  
 Lobes of cerebrum, 737; of cerebellum, 768; of liver, 997; of lung, 1049; of nose, 874; of prostate, 1084; of testis, 1093; of thyroid, 1055; of thymus, 1057; of kidney, 1061  
 Lobule of the ear, 902  
 Lobules of liver, 998; of lung, 1051; of kidney, 1061  
 Lobuli testes, 1093  
 Lobus centralis, 770; Spigelii, 997  
 Lobus caudatus, 997; clivi, 770; culminis, 770; quadratus, 997



Locus cæruleus, 776; niger, 750  
 Long bones, 119  
 Long saphenous nerve, 842  
 Longissimus dorsi muscle, 435  
 Longitudinal fissure, of brain, 735, 748; of liver, 996; ligament of liver, 995; sinus of brain, superior, 675; inferior, 676  
 Longus colli muscle, 424  
 Looped tubes of Henle, 1064  
 Lower extremity, arteries of, 644; bones of, 259; fascia of, 506; lymphatics of, 704; ligaments of, 357; muscles of, 506; nerves of, 837; veins of, 687; surface form of muscles of, 542  
 Lower, tubercle of, 1020  
 Lumbar arteries, 629; fascia, 432; ganglia, 860; glands, 707; nerves, 836; anterior divisions of, 837; posterior divisions of, 836; roots of, 836; plexus of nerves, 837; surgical anatomy of, 852; regions, 948; vein, ascending, 692; veins, 692; vertebrae, 127; development of, 131  
 Lumbo-iliac ligament, 330  
 Lumbo-sacral ligament, 330; nerve, 837;  
 Lumbricales muscles, hand, 499; foot, 539  
 Lungs, 1049; air-cells of, 1052; bronchial, arteries, 1054; veins, 1054; development, 110; capillaries of, 1052; in fœtus, 1031; lobes and fissures of, 1049; lobules of, 1051; lymphatics of, 710, 1054; nerves of, 1054; pulmonary artery, 1052; veins, 1052; root of, 1050; structure of, 1051; surface marking of, 1054; surgical anatomy of, 1055; weight, colour, etc., 1049  
 Lunula of lip, 92  
 Lunulæ of nails, 64  
 Luschka's gland, 630  
 Lymph, 6  
 Lymph path or sinus, 60  
 Lymphatic duct, right, 699  
 LYMPHATIC GLANDS, *General Anatomy of*, 58  
*Descriptive Anatomy*:  
 anterior mediastinal, 710; auricular posterior, 699; axillary, 702  
 brachial, 702; bronchial, 710; buccal, 699  
 cervical, deep, 702; superficial, 701  
 in front of elbow, 702  
 gluteal, 704  
 of head, 699  
 iliac, external, 706; internal, 707; inguinal, deep, 704; superficial, 704; intercostal, 709; internal mammary, 709; ischiatic, 704  
 of large intestine, 709; of lower extremity, 704; lumbar, 707  
 of neck, 701  
 occipital, 699  
 parotid, 699; of pelvis, 706; popliteal, 704  
 radial, 702  
 sacral, 707; of small intestines, 709; of spleen, 709; of stomach, 709; submaxillary, 701  
 of thorax, 709; tibial anterior, 704  
 ulnar, 702; of upper extremity, 702  
 zygomatic, 699  
 LYMPHATICS, *General Anatomy of*, 57; origin of, 58; plexus of, 58; subdivision

LYMPHATICS (*continued*)  
 into deep and superficial, 697; terminations of, 58; valves of, 57  
*Descriptive Anatomy*:  
 abdomen, 707; arm, 703  
 bladder, 708; cone, 27; broad ligaments, 708; cardiac, 710; cerebral, 701; cervical, superficial, and deep, 702; chest, 710; of clitoris, 707; of cranium, 701; diaphragm, 710  
 face, superficial, 700; deep, 700; Fallopian tubes, 708  
 gluteal region, 707  
 head, superficial, 699; heart, 710  
 intercostal, 710; internal mammary, 710; intestines, 709  
 kidneys, 708  
 labia, 707; lacteals, 709; large intestine, 709; leg, 705; liver, 708; lower extremity, 705; lung, 710; lymphatic duct, 699  
 meningeal, 701; mouth, 700  
 neck, 699; nose, 700; nymphæ, 707  
 œsophagus, 711; ovaries, 708  
 pancreas, 709; pelvis, 707; penis, 707; perinæum, 707; pharynx, 702; pia mater, 701; prostate, 708  
 rectum, 708  
 scrotum, 707; small intestine, 709; spleen, 709; stomach, 709  
 testicle, 708; thoracic duct, 698; thorax, 709; thymic, 711; thyroid, 711  
 upper extremity, 702; superficial, 703; deep, 704; uterus, 708  
 vagina, 708  
 Lymphocyte, 4  
 Lymphoid connective tissue, 19; of tongue, 871; of tonsil, 935  
 Lyra of fornix, 758  
 Macula cribrosa, 912; germinativa, 73; lutea, 887  
 Magnum of carpus, 252  
 Majendie. foramen of, 713  
 Malar bone, 175; articulations of, 177; attachment of muscles to, 177; development of, 176; foramina, 175; frontal process of, 175; maxillary process of, 176; orbital process of, 175; zygomatic process of, 176; canals, 175; nerves, from facial, 799; process of superior maxillary, 172  
 Male urethra, 1080  
 Malleolar arteries, external and internal, 659  
 Malleolus, external, 286; internal, 283  
 Malleus, 908; development of, 99; suspensory ligament of, 909  
 Malpighi, pyramids of, 1062  
 Malpighian bodies of kidney, 1063; tufts, 1063; capsules, 1063; bodies of spleen, 1011  
 Mamma, areola of, 1112; lobules of, 1113; nerves of, 1114; nipple or mammilla of, 1112; vessels of, 1114  
 Mammaræ, development of, 100  
 Mammary artery, internal, 596; glands, 1112; lymphatic glands, 710; veins, internal, 684  
 Mammilla of breast, 1112; of kidney, 1062  
 Mammillary processes, 129

- Mandibular arch, 93; nerve, 800  
 Manubrium of sternum, 211; of malleus, 908  
 Marginal lobe, 744  
 Marrow of bone, 25  
 Marshall, vestigial fold of, 684  
 Masseter muscle, 400  
 Masseteric arteries, 570; fascia, 400; nerve, 791; veins, 669  
 Masto-occipital suture, 188  
 Masto-parietal suture, 188  
 Mastoid antrum, 154; opening of, 907; cells, 154; foramen, 153; portion of temporal bone, 153, 197; process, 154; vein, 670  
 Matrix of nail, 64  
 Maxillary arch, fetal, 92; artery, internal, 568; bone, inferior, 183; superior, 169; development of, 173; nerve, inferior, 790; superior, 786; process of inferior turbinated, 181; malar bone, 176; processes (fœtal), 92; sinus, 171; tuberosity, 170; vein, internal, 670  
 Meatus auditorius externus, 155, 904; internus, 155; of nose, inferior, 204, 876; middle, 203, 876; superior, 203, 876; urinarius, male, 1081; female, 1101  
 Meatus of the nose, 203, 876  
 Meckel's cartilage, 93; diverticulum, 976; ganglion, 788  
 Median artery of forearm, 615; of spinal cord, 592; nerve, 827; surgical anatomy of, 831; vein, 681  
 Median disc of Hensen, 38  
 Mediastinal arteries, from internal mammary, 596; posterior, from aorta, 619; lymphatic glands, 710  
 Mediastinum, anterior, 1049; middle, 1049; posterior, 1049; superior, 1048; testis, 1093  
 Medio-tarsal joint, 375, 379  
 MEDULLA OBLONGATA, 728; pyramids of, 728; arcuate fibres of, 730; back of, 730; fissures of, 728; formatio reticularis of, 733; funiculus cuneatus of, 729, 731; funiculus of Rolando of, 729; funiculus gracilis of, 731; grey matter of, 733; lateral column, 729; tract, 731; olivary body of, 729; pyramids of, 728; restiform bodies of, 729; raphé of, 732; structure of, 730  
 Medulla spinalis, 714  
 Medullary artery of bone, 26; canal of bone, 25, 119; membrane of bone, 25; plates, 80; sheath of nerve fibres, 43; spaces of bone, 32; portion of kidney, 1062; of suprarenal capsules, 1072; velum inferior of cerebellum, 771, 775; velum superior, 772, 775  
 Medullary canal of bone, formation of, 34  
 Medullary canal of spine, development of, 80, 93  
 Medullated nerve fibres, 42  
 Medulli-spinal veins, 687  
 Meibomian glands, 897  
 Meissner's plexus, 982  
 Membrana basilaris, 916; granulosa of Graafian vesicle, 1111; limitans of retina, 888, 890; nictitans, 899; pupilaris, 887; sacciformis, 349, 355; tectoria, 916; tympani, 908; tympani secundaria, 907, 913  
 Membrane of aqueous chamber, 882; arachnoid, spinal, 713; cerebral, 725; choroid, 883; of Corti, 916; costo-coracoid, 470; crico-thyroid, 1035; of Descemet, 881; fenestrated, 52; hyaloid, 892; Jacob's, 890; of Kölliker, 917; limiting, 888, 890; pituitary, 875; pupillary, 887; of Reissner, 916; thyro-hyoid, 1035; Schneiderian, 875  
 MEMBRANES OF SPINAL CORD, 712; of brain, 723; of fœtus, 84  
 Membranous labyrinth, 914; portion of urethra, 1081; semicircular canals, 915  
 Meningeal artery, from ascending pharyngeal, 567; anterior, from internal carotid, 577; middle, from internal maxillary, 569; from occipital, 565; posterior, from vertebral, 592; small, from internal maxillary, 570; lymphatics, 701; veins, 670, 723  
 Meninges. *See* Membranes  
 Menisci, 23  
 Mental foramen, 183, 199; process, 183, 199; tubercles, 183  
 Mesencephalon, 94  
 Mesenteric artery, inferior, 627; superior, 625; glands, 708; plexus of nerves, inferior, 865; superior, 864; vein, inferior, 693; superior, 693  
 Mesenteries, 965  
 Mesoblast, 76, 79  
 Mesoblastic somites, 81  
 Meso-cæcum, 965  
 Meso-cardium, anterior, 952; posterior, 952  
 Meso-colon, ascending, 965; descending, 965; transverse, 966  
 Mesoderm, 79  
 Mesogastrium, 951, 954  
 Mesonephros, 111  
 Mesorchium, 113  
 Meso-rectum, 966  
 Meso-sternum, 211  
 Mesovarium, 113  
 Metacarpal artery, 612; articulations, 356  
 Metacarpo-phalangeal articulations, 356  
 Metacarpus, 253; common characters of, 253; development of, 259; peculiar bones of, 254  
 Metanephros, 111  
 Metatarsal artery, 660  
 Metatarsal articulations, 381; bones, 297  
 Metatarso-phalangeal articulations, 382  
 Metatarsus, 297; development of, 300  
 Metasternum, 213  
 Metencephalon, 94  
 Middle and internal frontal artery, 581  
 Middle clinoid processes, 158; ear, or tympanum, 905; fossa of skull, 191; meatus of nasal fosse, 203, 876; odontoid ligament, 319  
 Mid-carpal joint, 353  
 Mid-frontal process (fœtal), 92  
 Mid-gut, development of, 109  
 Mid-kidney, 111  
 Milk teeth, 926  
 Mitral valve, 1024  
 Mixed bones, 120  
 Modiolus of cochlea, 913  
 Mohl, glands of, 897  
 Molar glands, 922; teeth, 925  
 Monaster or mother star, 10



Mons Veneris, 1099  
 Morgagni, hydatid of, 114; sinus of, 419  
 Motor nerves, 49  
 Motor oculi nerve, 779; surgical anatomy of, 781  
 Motorial end plates, 50  
 Mouth, 921; mucous membrane of, 921; muscles of, 398; surface form of, 940  
 Movement admitted in joints, 308  
 Mucilaginous glands, 306  
 Mucoid cellular tissue, 18  
 Mucous glands of tongue, 870; membrane, 69  
 Müller, duct of, 111; fibres of, 890  
 Multicuspidati teeth, 925  
 Multifidus spinæ muscle, 437  
 Munro, foramen of, 761  
**MUSCLE, *General Anatomy of*, 35; of animal life, 35; arrangement of fibres of, 36; bipenniform, 384; blood-vessels of, 39; chemical composition of, 40; derivation of names, 385; development of, 101; fasciculi of, 36; fibrils of, 37; fibres of, 36; form of, 384; fusiform, 384; insertion of, 385; involuntary, 39; lymphatics of, 39; meaning of the terms 'origin' and 'insertion,' 385; mode of connection of, with bone, cartilage, skin, etc., 385; nerves of, 39, 49; of organic life, 39; origin of, 385; penniform, 384; quadrilateral, 384; rhomboidal, 384; sarcoous elements of, 38; sheath of, 36; size of, 385; striped, 36; structure of, 36; tendons of, 385; triangular, 384; unstriped, 39, voluntary, 36**  
 Muscle-plates, 101  
**MUSCLES OR MUSCLE, *Descriptive Anatomy of***  
 of abdomen, 447; abductor minimi digiti, (hand) 498; (foot) 538; indicis, 500; pollicis, 495; hallucis, 537; accelerator urinæ, 463; accessorii orbicularis oris, 398; accessorius pedis, 538; accessorius ad ilio-costalem, 435; adductor brevis, 517, longus, 516, magnus, 517; obliquus pollicis, 496; transversus pollicis, 497; obliquus hallucis, 539; transversus hallucis, 540; anconeus, 489; antitragicus, 903; aryteno-epiglottideus, inferior, 1039; superior, 1039; arytenoideus, 1038; arytenoideus rectus (*foot-note*), 1039; attollens aurem, 390; attrahens aurem, 390; azygos uvulæ, 421  
 biceps (arm), 478; (thigh), 524; biventer cervicis, 436; brachialis anticus, 479; buccinator, 399  
 cervicalis ascendens, 435; chondroglossus, 414; ciliary of eye, 887; circumflexus palati, 421; coccygeus, 460; complexus, 436; compressor narium minor, 396; nasi, 396; sacculi laryngis, 1039; urethræ, 465; in female, 467; constrictor isthmi faucium, 415; pharyngis inferior, 418; medius, 418; superior, 419; coraco-brachialis, 478; corrugator supercilii, 391; cutis ani, 459; of cranial region, 387; cremaster, 452; crico-arytenoideus lateralis, 1038; posticus, 1038; cricothyroid, 1038; crureus, 514  
 deltoid, 473; depressor anguli oris, 398;

**MUSCLES OR MUSCLE (*continued*)**  
 depressor alæ nasi, 396; epiglottidis, 1039; labii inferioris, 397; diaphragm, 443; digastric, 411; dilatator naris, anterior, 396; posterior, 396  
 of external ear, 389; erector clitoridis, 466; penis, 464; spinæ, 434; external sphincter, 459; extensor brevis digitorum, 536; carpi radialis brevis, 487; longior, 487; ulnaris, 489; coccygis, 438; digitorum communis, 488; indicis, 491; longus digitorum, 527; minimi digiti, 488; ossis metacarpi pollicis, 489; brevis pollicis, 491; proprius hallucis, 527; longus pollicis, 491  
 of face, 386; femoral region, anterior, 509; internal, 515; posterior, 524; fibula region, 533; flexor accessorius, 538; brevis minimi digiti, of hand, 499; of foot, 540; hallucis, 539; digitorum, 537; pollicis, 496; carpi radialis, 482; ulnaris, 482; digitorum sublimis, 483; longus digitorum, 532; pollicis, 485; hallucis, 531; ossis metacarpi pollicis, 495; profundus digitorum, 484  
 gastrocnemius, 528; gemellus superior, 522; inferior, 522; genio-hyo-glossus, 413; genio-hyoid, 412; gluteus maximus, 518; medius, 519; minimus, 520; gracilis, 515  
 of hand, 492; of head and face, 386; heliæ, major, 903; minor, 903; Hilton's, 1039; Horner's, 392; hyo-glossus, 413  
 iliac region, 507; iliacus, 508; ilio-costalis, 435; infracostal, 442; infraspinalis, 476; intercostal, 441; internal sphincter, 459; interossei of foot, 540; of hand, 499; interspinales, 438; intertransversales, 438  
 labial, 396; of larynx, 1038; latissimus dorsi, 429; of leg, 525; levator anguli oris, 397; ani, 459; anguli scapulae, 430; glandulæ thyroideæ, 1056; labii inferioris, 397; labii superioris alæque nasi, 396; labii superioris, 396; menti, 397; palati, 420; palpebræ, 392; prostaticæ, 460; levatores costarum, 443; lingualis, 410; longissimus dorsi, 435; longus colli, 424; lumbricales (hand), 499; (foot), 539  
 masseter, 400; multifidus spinæ, 437; musculus accessorius ad ilio-costalem, 435; mylo-hyoid, 412  
 naso-labialis, 398; of neck, 403  
 obliquus auris, 903; abdominis externus, 448; internus, 451; capitis superior, 439; inferior, 439; oculi, inferior, 394; superior, 393; obturator externus, 522; internus, 521; occipito-frontalis, 388; omo-hyoid, 410; opponens minimi digiti, 499; pollicis, 495; orbicularis oris, 398; palpebrarum, 390  
 of palate, 420; palato-glossus, 421; palato-pharyngeus, 421; palmaris brevis, 497; longus, 482; pectineus, 516; pectoralis major, 468; minor, 470; of perinæum, male, 461; female, 465; peroneus brevis, 533; longus, 533; tertius 528; of pharynx, 418; plantaris, 530;



MUSCLES OR MUSCLE (*continued*)

platysma myoides, 404; popliteus, 531;  
 pronator quadratus, 485; radii teres,  
 482; psoas magnus, 508; parvus, 508;  
 pterygoid, internal, 402; external, 401;  
 pyramidalis abdominis, 455; nasi, 395;  
 pyriformis, 520  
 quadratus femoris, 522; lumborum, 458;  
 menti, 397; quadriceps extensor cruris,  
 513  
 rectus abdominis, 453; capitis anticus  
 major, 423; minor, 423; posticus major,  
 438; minor, 438; femoris, 513; oculi,  
 externus, superior, inferior, and in-  
 ternus, 393; lateralis, 424; retrahens  
 aurem, 390; rhomboideus major, 431;  
 minor, 430; risorius, 399; rotatores  
 spinæ, 437  
 sacro-lumbalis, 435; salpingo-pharyngeus,  
 421; sartorius, 512; scalenus anticus,  
 424; medius, 424; posticus, 425; semi-  
 membranosus, 525; serratus posticus,  
 superior, 431; inferior, 432; semi-spina-  
 lis dorsi, 437; colli, 437; semi-tendino-  
 sus, 524; serratus magnus, 472; sole  
 of foot, 536; first layer, 537; second  
 layer, 538; third layer, 539; fourth  
 layer, 540; soleus, 529; sphincter,  
 external, 459; internal, 459; vaginae,  
 465; spinalis dorsi, 436; colli, 436;  
 splenius, 432; capitis, 434; colli, 434;  
 stapedius, 910; sterno-cleido-mastoid,  
 407; sterno-hyoid, 409; sterno-thyroid,  
 409; stylo-glossus, 414; stylo-hyoid,  
 412; stylo-pharyngeus, 419; sub-  
 anconeus, 489; subclavius, 471;  
 suberureus, 515; subscapularis, 474;  
 supinator brevis, 489; longus, 486;  
 supraspinales, 438; supraspinatus, 475  
 temporal, 400; tensor palati, 421; tarsi,  
 392; tympani, 910; vaginae femoris, 512;  
 thyrus major, 477; minor, 476; thyro-  
 arytenoideus, 1039; thyro-epiglottideus,  
 1039; thyro-hyoid, 410; tibialis anticus,  
 527; posticus, 532; of tongue, 413;  
 trachelo-mastoid, 435; tragiæus, 903;  
 transversalis abdominis, 453; colli, 435;  
 transversus auriculæ, 903; perinæi, 462;  
 (female) 465; profundus, 1145; trape-  
 zius, 427; triangularis sterni, 442;  
 triceps extensor cubiti, 480; extensor  
 cruris, 514; femoralis, 514; of tym-  
 panum, 910; of ureters, 1078  
 vastus externus, 514; internus and  
 crureus, 514  
 zygomaticus major, 397, minor, 397  
 Muscles of inspiration and expiration, 446;  
 of expression, 403; of pelvic outlet,  
 459  
 Muscular columns, 38  
 Muscular fibres of heart, 40  
 Muscularis mucosæ, 70  
 Musculi papillares, left ventricle, 1024;  
 right, 1022; pectinati in left auricle,  
 1023, in right, 1020  
 Musculo-cutaneous nerve of arm, 823, from  
 peroneal, 852  
 Musculo-spiral groove, 233; nerve, 830;  
 surgical anatomy of, 832  
 Musculo-phrenic artery, 598  
 Musculus accessorius ad ilio-costalem, 435,

incisivus inferior, 399; superior, 398;  
 suspensorius duodeni, 975

Myelo-plaques, 26

Mylo-hyoid artery, 570; groove, 184;  
 muscle, 412; nerve, 792; ridge, 184

Myrtiform fossa, 169

Nails, 64

Nares, anterior, 204, 875; posterior, 204,  
 875, 941; septum of, 203, 875

Nasal angle, 168; artery, of internal maxil-  
 lary, 571; transverse, 580; of ophthalmic,  
 580; of septum, 564, 571; bones, 167;  
 development of, 169; articulations of,  
 169; cartilages, 874; crest, 168; duct,  
 900; eminence, 149; fossæ, 201, 875;  
 arteries of, 877; mucous membrane of,  
 875; nerves of, 878; surgical anatomy  
 of, 878; veins of, 877; groove, 168; nerve,  
 784; nerves from Meckel's ganglion,  
 790; notch, 149; process, 172; spine,  
 149; anterior, 173, 199; posterior, 178;  
 venous arch, 668

Nasion, 199

Nasi, dorsalis, artery, 580

Nasmyth's membrane, 931

Naso-labialis muscle, 398

Naso-maxillary suture, 199

Naso-palatine nerve, 790

Nates of brain, 762

Navicular bone, 294; articulations of, 294;  
 attachment of muscles to, 294; tuberosity  
 of, 294

Neck, glands of, 701; lymphatics of, 702;  
 muscles of, 403; triangle of, anterior, 572,  
 posterior, 573; veins of, 670

Nélaton's line, 278

Nerve-corpuscles, 41

Nerve-epithelium cells, 49

NERVES, *General Anatomy of*, 45; cerebro-  
 spinal, 45; development of, 96; en-  
 doneurium of, 45; epineurium of, 45;  
 funiculi of, 45; origin of, 47; perineurium  
 of, 45; plexus of, 46; sheath of, 45; ter-  
 mination of, 47; vessels of, 46; spinal  
 roots of, 812; sympathetic, 46

NERVES OR NERVE, *Descriptive Anatomy  
 of*: abducens, 795; accessory obturator,  
 841; anterior crural, 841; auditory,  
 801; auricular, posterior, 798; of vagus,  
 806; auricularis magnus, 818; of auri-  
 culo-temporal, 791; of second cervical,  
 816; of small occipital, 818  
 of brachial plexus, 820; buccal, 791; of  
 facial, 800

cardiac, middle, 859; inferior, 859;  
 superior, 858; plexus, deep, 861; super-  
 ficial, 862; of pneumogastric, 808;  
 cavernous, of penis, 865; cervical an-  
 terior, 816; posterior, 814; superficial,  
 818; cervico-facial, 800; chorda tym-  
 pani, 798, 911; ciliary, long, 784; short,  
 786; circumflex, 823; coccygeal, 844;  
 cochlear, 802; communicans hypo-  
 glossi, 819; peronei, 852; of Cotunnus,  
 790; cranial, 778; crural anterior, 841;  
 cutaneous (*see that heading*)

deep palmar, 829; deep temporal, 791;  
 dental anterior, 792; anterior superior,  
 788; middle superior, 788; posterior

NERVES OR NERVE (*continued*)

superior, 787; inferior, 792; descendens hypoglossi, 811; digastric from facial, 798; digital (foot), 850, 852; dorsal (hand), 831; dorsal of penis, 849; dorsal spinal, 832; peculiar, 835; dorsilumbar, 835; of dura mater, 724  
 eighth pair, 801; eleventh pair, 809; of eyeball, 778  
 facial, 796; fifth, 782; fourth, 781; frontal, 783  
 ganglionic branch of nasal, 784; gastric branches of vagus, 808; genito-crural, 839; glosso-pharyngeal, 802; gluteal, inferior, 847; superior, 846; great petrosal, 788; great splanchnic, 860; gustatory, 792  
 hæmorrhoidal, inferior, 847; of heart (*see* Cardiac); hepatic, 864; hypoglossal, 809  
 ilio-hypogastric, 838; ilio-inguinal, 839; incisive, 793; inferior maxillary, 790; infra-maxillary of facial, 800; infra-orbital of facial, 799; infratrochlear, 784; intercostal, 834; intercosto-humeral, 835; interosseous, anterior, 827, posterior, 831; ischiadic, great, 849; small, 847  
 Jacobson's, 803  
 of labyrinth, 918; labial, 788; lachrymal, 783; of Lancisi, 751; large cavernous, 865; laryngeal, external, 807; internal, 807; recurrent, 807; superior, 807; lesser splanchnic, 860; lingual of fifth, 792; of glosso-pharyngeal, 803; long ciliary, 784; long thoracic, 822; long saphenous, 842; lumbar, 836; lumbosacral, 837  
 malar branch of orbital nerve, 787; of facial, 799; masseteric, 791; maxillary inferior, 790; superior, 786; median, 827; mental, 793; middle cardiac, 859; motor of eye, common, 779; external, 795; musculo-cutaneous of arm, 823; leg, 852; musculo-spiral, 830; mylohyoid, 792  
 nasal, ophthalmic, 784; from Meckel's ganglion, 790; from Vidian, 789; nasopalatine, 790; ninth, 802  
 obturator, 839; œsophageal, 808; occipital, great, 815; small, 818; of third cervical, 816; of facial, 798; olfactory, 777; ophthalmic, 782; optic, 778; orbital nerves, their relation, 795; in cavernous sinus, 795; in orbit, 796; in sphenoidal fissure, 796; orbital of superior maxillary, 786  
 palatine, anterior or large, 789; external, 790; posterior or small, 790; palmar, cutaneous, of median, 827; ulnar, 829; palpebral, 788; par vagum, 803; pathetic, 781; perforans Casserii, 823; perineal, 849; superficial, 849; peroneal, 851; petrosal, superficial, external or large, 788; deep, large, 789; deep, small, 711; small, superficial, 711; pharyngeal of pneumogastric, 807; of glosso-pharyngeal, 803; of sympathetic, 858; of Meckel's ganglion, 790; of external laryngeal, 807; phrenic, 819; plantar, cutaneous, 850; external, 851;

NERVES OR NERVE (*continued*)

internal, 850; pneumogastric, 803; popliteal external, 851; internal, 849; portio dura, 796; portio inter duram et mollem, 797; portio mollis, 801; posterior auricular, 798; pterygoid, 791; pterygo-palatine, 790; pudendal, inferior, 847; pudic, 847; pulmonary, from vagus, 808  
 radial, 830; recurrent laryngeal, 807; recurrent to tentorium, 783; renal splanchnic, 860; respiratory, external, 822; internal, 819  
 sacral, 843; plexus, 845; saphenous long or internal, 842; short or external, 850; sciatic, great, 849; small, 847; short ciliary, 786; sixth, 795; small cavernous, 865; spinal, 812; spinal accessory, 809; splanchnic, great, 860; small, 860; smallest, 860; stylo-hyoid of facial, 798; subclavian, 822; suboccipital, 816; posterior branch of, 814; subscapular, 823; superficialis colli, 818; superior cardiac, 858; maxillary, 786; supra-acromial, 819; supraclavicular, 819; supra-orbital, 784; suprascapular, 822; suprasternal, 819; supratrochlear, 783; supramaxillary of facial, 800; sympathetic, 854  
 temporal, deep, 791; of facial, 799; of auriculo-temporal, 791; temporo-facial, 799; temporo-malar, 786; tenth, 803; third, or motor-oculi, 779; thoracic posterior, 822; anterior, 823; thyrohyoid, 812; tibial, anterior, 852; posterior, 850; of tongue, 872; tonsillar, 803; trifacial or trigeminous, 782; trochlear, 781; twelfth, 809; tympanic, of glosso-pharyngeal, 803, 911; of facial, 798  
 ulnar, 828; uterine, 866  
 vaginal, 865; vagus, 803; vestibular, 802, 918; Vidian, 789  
 of Wrisberg, 826  
 Nervi-nervorum, 46  
 Nervous substance, chemical analysis, 44; grey, 41; white, 41; vesicular, 41; layer, of retina, 888  
 NERVOUS SYSTEM, *General Anatomy of*, 40; fibrous nervous matter, 41; ganglia, 50; grey or cineritious substance, 41; sympathetic, 46; chemical composition of, 44; gelatinous fibres, 41, 43; vesicular nervous matter, 41; white or medullary substance, 41  
 Nervus cardiacus magnus, 859; minor, 859; petrosus profundus, 789; superficialis cordis, 858  
 Neumann, dental sheath of, 927  
 Neural arch, 120; crest, 96; canal, 80  
 Neurilemma, 42; (*footnote*), 42; of cord, 714  
 Neuroblasts, 97  
 Neuroglia, 41; of cord, 718  
 Nidus hirundinis of cerebellum, 771  
 Ninth nerve, 802  
 Nipple, 1112  
 Nodes of Ranvier, 43  
 Nodule of cerebellum, 770  
 Non-medullated nerve-fibres, 43  
 Nose, 873; arteries of, 877; bones of, 167;



- cartilages of, 877; cartilage of septum of, 875; development of, 100; fossæ of, 201, 875; mucous membrane of, 875; muscles of, 395; nerves of, 878; surgical anatomy of, 878; veins of, 877
- Notch, cotyloid, 265; ethmoidal, 149, 164; intercondyloid, 275; nasal, 149; sacro-sciatic, greater, 263; lesser, 263; sigmoid, 185; sphenopalatine, 180; supra-orbital, 149; suprascapular, 228
- Notochord, 80, 88
- Nuck, canal of, 1097, 1112
- Nuclear membrane, 8
- Nucleated sheath of Schwann, 42
- Nuclei pontis, 735
- Nucleus amygdalæ, 755; caudatus, 754; lenticularis, 754
- Nucleus of a cell, 8
- Nucleus emboliformis, 774; fastigii, 774; globosus, 774
- Nutrient artery of bone, 26
- Nymphæ, 1100; lymphatics of, 707
- Obelion, 189
- Oblique inguinal hernia, 1123; coverings of, 1123; ligament, 348; line of the clavicle, 222; of the fibula, 285; of lower jaw, 183; of radius, 243; ridge of ulna, 240
- Obliquus auris muscle, 903; externus abdominis, 448; internus, 451; inferior captis, 439; superior, 439; inferior oculi, 394; superior, 393
- Obturator artery, 636; peculiarities of, 637; relation of, to femoral ring, 1134; externus muscle, 522; internus, 521; fascia, 1146; foramen, 265; ligament, or membrane, 521; nerve, 839; surgical anatomy of, 853; accessory, 841; veins, 690
- Occipital artery, 565; bone, 141; articulations of, 145; attachment of muscles to, 145; development of, 145; crests, 141, 143; protuberances, 141, 143; fossæ, 143; lobe, 741; lymphatic glands, 699; groove, 154; sinus, 676; triangle, 574; vein, 670
- Occipitalis major nerve, 815; minor, 818
- Occipitalis muscle, 389
- Occipito-atlantal articulation, 317; occipito-axial articulation, 318; occipito-frontalis muscle, 388
- Occiput, arteries of, 565
- Ocular cleft, 98; cup, 97; vesicle, primitive, 97; secondary, 98
- Odontoblasts, 926, 931
- Odontoid ligaments, 319; tubercle for, 143; process of axis, 124
- Oesophageal arteries, 619; branches of vagus nerve, 808; glands, 944; opening of in diaphragm, 445; plexus, 808
- Oesophagus, 942; lymphatics of, 711; structure of, 943; surgical anatomy of, 944
- Olecranon process, 238; fossa, 235; fracture of, 505
- Olfactory bulb, 748, 777; cells, 877; foramina, 164; fossæ (fetal), 100; nerve, 777; surgical anatomy of, 778; sulcus, 777
- Olivary bodies of medulla oblongata, 729, 731; nuclei, accessory, 733; nucleus, superior, 735; peduncle, 731; process, 158
- Omenta, 964
- Omental tuberosity of liver, 994
- Omentum, gastro-colic, 965; gastro-hepatic, 964; gastro-splenic, 965; great, 965; lesser, 964
- Omo-hyoid muscle, 410
- Omphalo-mesenteric arteries, fetal, 102; duct, 82; veins, 103; vessels, 82
- Opening of aorta in left ventricle, 1024; aortic in diaphragm, 445; caval in diaphragm, 445; of coronary sinus, 1020; of inferior cava, 1019; left auriculo-ventricular, 1024; œsophageal in diaphragm, 445; of pulmonary artery, 1021; veins, 1023; right auriculo-ventricular, 1021; saphenous, 512, 1131; of superior cava, 1019
- OPERATIONS:—
- amputations of foot, 303; of penis, 1088
- arteries, ligature of, abdominal aorta, 622; axillary, 603; brachial, 607; carotid, common, 557; external, 559; internal, 577; femoral, 647; iliac, common, 632; external, 642; internal, 632; innominate, 554; lingual, 562; popliteal, 655; radial, 611; subclavian, 589; thyroid, inferior, 595; tibial, anterior, 658; posterior, 661; ulnar, 614
- catheterism of Eustachian tube, 942; cholecystotomy, 1004; for cleft palate, 422; colotomy, 993
- division of nerves, facial, 801; infra-orbital, 795; lingual, 795; sciatic, great, 853; spinal accessory, 809; supra-orbital, 794
- excision of, ankle, 376; elbow, 347; hip, 363; knee, 371; of shoulder, 343; extirpation of thyroid, 1057; of spleen, 1013
- gastrostomy, 972; gastro-urethral, 972
- hamstring tendons, division of, 525
- laryngotomy, 1045; lithotomy, 1143
- nephrotomy and nephrectomy, 1069
- œsophagotomy, 944
- paracentesis of pericardium, 1017; pro-statectomy, 1085; puncture of the bladder, 1080
- removal of the clavicle, 225; lower jaw, 209; upper jaw, 208; tongue, 417, 873; scapula, 231; testis, 1095
- for strabismus, 395
- tapping chest, 221; for torticollis, 409; tracheotomy, 1045
- venesection, 681
- Operculum of the insula, 748
- Ophthalmic artery, 577; ganglion, 784; nerve, 782; vein, 677; inferior, 677
- Opponens minimi digiti muscle, in hand, 499; in foot, 540; pollicis muscle, 495
- Optic commissure, 778; foramen, 161, 191; groove, 161, 191; lobes, 762; nerve, 778; inter-retinal fibres of, 778; intercerebral fibres of, 778; surgical anatomy of, 779; recess, 759; thalamus, 759; tract, 778
- Ora serrata, 887
- Oral cavity, 921
- Orbicular bone, 909; ligament, 348



- Orbicularis ciliaris, 390; latus, 390; oris muscle, 398; palpebrarum, 390
- Orbit, 199; arteries of, 577; muscles of, 392; relation of nerves in, 796
- Orbital artery, 571; fascia, 395; foramina, 161; lobe, 738; nerve, 786; process of malar, 175; of palate, 179; sulcus, 738
- Organs of Golgi, 50; of Giralddès, 114; of Jacobson, 876; of Rosenmüller, 114
- Organic constituent of bone, 30
- Orifice, œsophageal of stomach, 967; pyloric of stomach, 967
- Origin of muscles, 385
- Os calcis, 287; development of, 300; hyoides, 209; innominatum, 259; development of, 265; magnum of carpus, 252; orbiculare, 909; planum, 165; unguis, 174
- Os uteri, 1104
- Ossa triquetra, 167
- Ossicula auditus, 908; ligaments of, 909
- Ossification, period of, 35; of bone, 30; of spine, progress in, 131; defects in, 140; intracartilaginous, 30; intramembranous, 34; subperiosteal, 34
- Osteoblasts, 25, 31
- Osteoclasts, 26, 33
- Osteo-dentine, 928
- Osteology, 119
- Ostium abdominale of Fallopiian tube, 1108; internum or uterinum, 1106
- Otic ganglion, 793; vesicle, 99
- Otoliths, 915
- Outlet of pelvis, 268
- Ovarian arteries, 629; plexus of nerves, 864; veins, 692
- Ovary, 1109; development of, 113; Graafian vesicles of, 1110; ligament of, 1112; lymphatics of, 708; nerves of, 1112; ovicapsule of, 1111; shape, position, and dimensions, 1109; stroma of, 1110; tunica albuginea of, 1110; vessels of, 1112
- Ovicapsule of Graafian vesicle, 1111
- Oviducts, 1108
- Ovisacs of ovary, 1110
- Ovula of Naboth, 1107
- Ovum, 7, 72; early changes in, 74; discharge of, 1111; discus proligerus of, 73; fertilisation of, 74; germinal spot of, 73; germinal vesicle of, 73; vitelline membrane of, 73; yolk of, 73; zona pellucida of, 73
- Oxyntic cells, 971
- Oxyntic glands, cardiac, 970; pyloric, 970
- Pacchionian depressions, 147; glands, 675, 723, 724
- Pacinian corpuscles, 48
- Pad of corpus callosum, 751
- Palatal glands, 934
- Palate, arches of, 934; development of, 92; hard, 934; soft, 934; bone, 177; articulations of, 180; attachment of muscles to, 180; development of, 180; turbinated crest of, 178; vertical plate of, 178; horizontal plate of, 177; orbital process of, 179; sphenoidal process of, 179; muscles of, 935; process of superior maxillary, 172
- Palatine aponeurosis, 421; artery, ascending, 563; descending or posterior, 571; canal, anterior, 172; posterior, 170, 178; accessory, 179; fossa, anterior, 172; nerves, 790; process of superior maxillary, 172; veins, inferior, 669
- Palato-glossus muscle, 415, 421; pharyngeus, 421
- Palmar arch, deep, 610; superficial, 616; surface marking of, 617; cutaneous nerve, 827, 828; fascia, 494; interossei arteries, 613; nerve, deep, of ulnar, 929; superficial, 829; veins, 680
- Palmaris brevis muscle, 497; longus muscle, 482
- Palpebræ, 896
- Palpebral arteries, 580; external, 578; cartilages or plates, 897; fissures, 896; fissure, surface form of, 900; folds of conjunctiva, 898; ligaments, 897; muscles, 390; veins, inferior, 669; superior, 669
- Pampiniform plexus of veins, 692, 1091, 1112
- Pancreas, 1005; development of, 110; structure of, 1006; lymphatics of, 709; vessels and nerves of, 1007; surface marking of, 1007; surgical anatomy, 1007
- Pancreatic arteries, 625; duct, 1006; plexus of nerves, 864; veins, 693
- Pancreatica magna artery, 625
- Pancreatico-duodenal artery, 624; inferior, 626; vein, 693; plexus of nerves, 864
- Papilla lachrymalis, 899; spiralis, 916
- Papillæ of tooth, 930; conicæ vel filiformes, 869; fungiformes (mediæ), 869; of kidney, 1062; maximæ (circumvallatæ), 869; of skin, 63; of tongue, 868
- Papillary layer of skin, 63
- Par vagum, 803
- Paraglobulin, 1, 5
- Parallel fissure, 741; striæ of Retzius, 928
- Paramastoid process, 143
- Parietal bones, 145; articulations of, 148; attachment of muscles to, 148; development of, 147; eminence, 146; foramen, 146; cells of gastric glands, 971; lobe, 739; veins, 106
- Parieto-occipital fissure, 738, 743
- Parieto-sphenoid artery, 582
- Parotid duct, 936; fascia, 400, 406; gland, 935; accessory portion of, 936; nerves of, 937; vessels of, 937; lymphatic glands, 699; veins, 669
- Parovarium, 111, 114, 1111
- Patella, 279; articulations of, 280; attachment of muscles to, 280; development of, 280; fracture of, 545; surface form of, 280; surgical anatomy of, 280
- Pecquet, reservoir of, 698
- Pectineus muscle, 516
- Pectiniforme septum, 1086
- Pectoral region, dissection of, 467
- Pectoralis major, 468, minor, 470
- Peculiar dorsal vertebræ, 127
- Pedicles of a vertebra, 121
- Peduncles of cerebellum, 774; of cerebrum, 750; of corpus callosum, 751; of pineal gland, 762
- Peduncular fibres of cerebrum, 763; of cerebellum, 771
- Pelvic fascia, 1145; parietal or obturator layer, 1146; visceral layer, 1146; girdle, 221; plexus, 865

- Pelvis, 267, 1073; arteries of, 633; articulations of, 330; axes of, 269; boundaries of, 267; brim of, 267; cavity of, 268; diameters of, 269; false, 267; inlet of, 268; ligaments of, 330; lymphatics of, 707; male and female, differences of, 270; outlet of, 268; position of, 267; position of viscera at outlet of, 1142; true, 267; of kidney, 1062; surface form of, 270; surgical anatomy of, 271
- Pelvis in fœtus, 270; about puberty, 270; after puberty, 270
- Penis, 1085; arteries of, 1087; body of, 1085; corpora cavernosa, 1086; corpus spongiosum, 1087; development of, 116; dorsal artery of, 639; dorsal vein of, 691; nerve of, 849; suspensory ligament, 1085; lymphatics of, 707, 1088; muscles of, 464; nerves of, 1088; prepuce of, 1086; root of, 1085; surgical anatomy of, 1088
- Penniform muscle, 384
- Perforans Casserii nerve, 823
- Perforated space, anterior, 748; posterior, 749
- Perforating arteries, of hand, 613; from mammary artery, 597; from plantar, 564; from profunda, 652
- Pericardiac arteries, 596, 618
- Pericardium, relations of, 1014; diverticula of, 1015; structure of, 1015; fibrous layer of, 1015; serous layer of, 1016; nerves of, 1017; vessels of, 1017; vestigial fold of, 684, 1017
- Perichondrium, 22, 31
- Perilymph, 914
- Perimysium, external, 36; internal, 36
- Perinæum, in the male, 1139; in the female, 1144; abnormal course of arteries in, 1144; deep boundaries of, 1139; development of, 115; lymphatics of, 707; muscles of, 465; surgical anatomy of, 1137
- Perineal artery, superficial, 638; transverse, 638; fascia, deep, 464, 1140; superficial, 461; nerve, 849; superficial, 849
- Perineurium, 45
- Periosteum, 25; internal, 25; of teeth, 923
- Peripheral termination of nerves, 47
- Peritoneum, lesser cavity of, 958, 962; greater cavity of, 958; ligaments of, 964; mesenteries of, 965; omenta of, 964; reflections traced, 958
- Perivascular lymphatics, 58, 675
- Permanent cartilage, 21; teeth, 923
- Peroneal artery, 662; peculiarities of, 662; anterior, 663; nerve, 851; tubercle, 291; veins, 689
- Peroneus brevis muscle, 533; longus, 533; tertius, 528
- Perpendicular plate of ethmoid, 164; line of ulna, 240
- Pes accessorius, 753; anserinus, 797; hippocampi, 756
- Petit, canal of, 894; triangle of, 449
- Petro-mastoid portion of temporal bone, 157
- Petro-occipital suture, 188
- Petro-sphenoidal suture, 188
- Petrosal nerve, superficial or large, from Vidian, 788; small, superficial, 911; deep, large, 789; deep, small, 911; long, 911; process, 159; sinus inferior, 677; superior, 677
- Petrous ganglion, 803; portion of temporal bone, 155
- Peyer's glands, 980
- Phalanges of cochlea, 918
- Phalanges, hand, 256; articulations of, 357; development of, 259; foot, 300; articulations of, 300, 383; development of, 300
- Pharyngeal aponeurosis, 941; arches, 93; artery, ascending, 566; clefts, 93; fascia, 406; ganglion, 859; glands, 942; nerve, from external laryngeal, 807; from glossopharyngeal, 803; from Meckel's ganglion, 790; from sympathetic, 858; from vagus, 807; plexus of nerves, 807, 858; spine, 143; tonsil, 942; vein, 672
- Pharyngo-glossus muscle, 415
- Pharynx, 941; aponeurosis of, 941; arteries of, 566; development of, 109; mucous membrane of, 942; muscles of, 418; surgical anatomy of, 942
- Phleboliths, 691
- Phrenic arteries, 629; nerve, 819; plexus of nerves, 863; veins, 693
- Phreno-colic ligament, 966
- Pia mater, of brain, 726; of cord, 713; testis, 1093
- Pigment, 21; of iris, 886; of skin, 63
- Pigmentary layer of retina, 890
- Pillars of external abdominal ring, 450, 1117; of diaphragm, 444; of fauces, 934
- Pineal gland, 761; peduncles of, 762; recess, 759
- Pinna of ear, 902; ligaments of, 903; muscles of, 903; nerves of, 904; vessels of, 903
- Pisiform bone, 250
- Piso-metacarpal ligament, 352
- Piso-uncinate ligament, 352
- Pit of the stomach, 219
- Pituitary body, 749; development of, 94; fossa, 158; membrane, 875
- Pivot-joint, 308
- Placenta, 87
- Placental sinus, 88; circulation, 103
- Plantar arch, 663; artery, external, 663; internal, 663; fascia, 535; ligaments, 377; cutaneous nerve, 850; nerve, external, 851; internal, 850; veins, external, 689; internal, 689
- Plantaris muscle, 530
- Plasma, 5
- Plasma cells, 18
- Plates, tarsal, 897
- Platysma myoides, 404
- Pleura, 1046; cavity of, 1046; costalis, 1046; pulmonalis, 1046; reflections of, traced, 1046; vessels and nerves of, 1047; surgical anatomy of, 1047
- Pleuro-peritoneal cavity, 81
- PLEXUS OF NERVES, 46; aortic, 865; brachial, 820; cardiac, deep, 861; superficial, 862; carotid, 856; external, 859; cavernous, 858; cervical, 818; posterior, 816; cœliac, 864; colic, left, 865; middle, 864; right, 864; coronary, anterior, 862; posterior, 862; cystic, 864; diaphrag-

PLEXUS OF NERVES (*continued*)

matic, 863; epigastric or solar, 862; facial, 859; gastric, 864; gastro-duodenal, 864; gastro-epiploic, 864; left, 864; great cardiac, 861; hæmorrhoidal, superior, 865; inferior, 865; hepatic, 864; hypogastric, 865; inferior, 865; ileo-colic, 864; infra-orbital, 786; lumbar, 837; mesenteric, inferior, 865; superior, 864; œsophageal, 808; ovarian, 864; ophthalmic, 858; pancreatic, 864; pancreatico-duodenal, 864; patellæ, 843; pharyngeal, 803, 859; phrenic, 863; prostatic, 865; pulmonary, anterior, 808; posterior, 808; pyloric, 864; renal, 864; sacral, 845; sigmoid, 865; solar, 862; spermatic, 864; splenic, 864; superficial cardiac, 862; suprarenal, 864; tonsillar, 803; tympanic, 910; uterine, 866; vaginal, 865; vertebral, 860; vesical, 865

Plexus of cornea, intra-epithelial, 882; sub-epithelial, 882

Plexus magnus profundus, 861

PLEXUS OF VEINS. *See* Veins

Plica-epigastrica, 1123; hypogastrica, 1123; urachi, 1123

Plica semilunaris, 899

Pneumogastric lobule of cerebellum, 770

Pneumogastric nerve, 803

Polar globules of Robin, 73

Pomum Adami, 1032

Pons hepatis, 996

Pons Varolii, 734; Tarini, 749

Popliteal artery, 652; branches of, 655; peculiarities of, 654; surgical anatomy of, 655; surface marking of, 655; lymphatic glands, 704; nerve, external, 851; surgical anatomy of, 854; internal, 849; notch, 281; space, 652; surface of femur, 275; vein, 689

Popliteus muscle, 531

Pores of the skin, 67

Portal canals, 998; fissure, 996; vein, 695; 998, 1000

Portio dura or seventh nerve, 796; mollis, or auditory nerve, 801; inter duram et mollem, 797

Porus opticus of sclerotic, 880, 887

Posterior (*See under each separate head*)

Posterior and internal frontal artery, 581

Posterior choroid artery, 594

Posterior glenoid process, 152

Posterior vertebral veins of Rathke, 107

Posterior vesicular column, 722

Postero-lateral ganglionic arteries, 594; median ganglionic arteries, 594

Post-central sulcus, 739

Post-glenoid process, 152

Post-oral arches (fœtal), 92

Post-patellar bursa, 515

Pott's fracture, 545

Pouch of Douglas, 1104

Pouches, laryngeal, 1037

Poupart's ligament, 450, 1118, 1131

Præcentral fissure, 738

Precuneus lobe of brain, 744

Pre-oral arches (fœtal), 92

Prepatellar bursa, 515

Prepuce, 1086; of clitoris, 1100

Presternal notch, 211

Presternum, 211

Prevertebral fascia, 406

Prickle cells, 14

Primary areolæ of bone, 31; cerebral vesicles, 90

Primitive jugular veins, 107; trace, 76, 79; aorta, 104; sheath of nerve-fibre, 42; ocular vesicle, 97; otic or auditory vesicle, 99; fibrillæ of Schultze, 43

Princeps cervicis artery, 565; pollicis artery, 612

PROCESSES OR PROCESS, acromion, 228; alveolar, 172; angular, external, 149; internal, 149

basilar, 143

ciliary, 884

clinoid, anterior, 161; middle, 158; posterior, 158; cochleariform, 157, 907; condyloid of lower jaw, 185; coracoid, 229; coronoid of lower jaw, 185; of ulna, 238; costal, 129

ethmoidal of inferior turbinated, 181

frontal of malar, 175

hamular of lachrymal, 175; of sphenoid, 162; of helix, 902

of Ingrassias, 161

jugular, 143

lachrymal of inferior turbinated bone, 181

malar, 172; mastoid, 154; mammillary, 129; maxillary of inferior turbinated,

181; of malar bone, 176; mental, 183

nasal, 172

odontoid of axis, 124; olecranon, 238; olivary, 158; orbital of malar, 175; of palate, 179

palatine of superior maxillary, 172; post-glenoid, 152; pterygoid of palate bone, 178; of sphenoid, 162

sphenoidal of palate, 179; spinous of tibia, 281; of ilium, 262; of sphenoid, 161; styloid of temporal, 157; of ulna, 242; of radius, 244

unciform, 253; of ethmoid, 165

vaginal of sphenoid, 160; of temporal, 157

vermiform of cerebellum, inferior, 770; superior, 769

zygomatic, 176

Processes of Ingrassias, 161

Processus ad medullam, 772; ad pontem, 772; brevis of malleus, 909; cochleariformis, 157, 907; e cerebello ad testes,

771; caudatus, 902; gracilis of malleus, 909

Profunda cervicis artery, 598; femoris artery, 650; vein, 672; inferior artery of arm, 608; superior, 608

Prohepaticus, 952

Promontory of tympanum, 907; of sacrum, 132

Pronator quadratus muscle, 485; radii teres muscle, 482; ridge, 240

Pronephros, 111

Pronucleus, female, 74; male, 74

Prosencephalon, 94

Prostate gland, 1083; lobes of, 1084; levator muscle of, 460, 1084; lymphatics of, 708; surgical anatomy of, 1085; vessels and nerves of, 1084

Prostatic plexus of nerves, 865; of veins, 690; portion of urethra, 1080; sinus, 1080

Protoplasm, 8



- Protovertebræ, 81  
 Protovertebral column, 88; somites, 88  
 Profuberance, occipital, external, 141; internal, 143  
 Pseudostomata of sweat glands, 68  
 Psoas magnus muscle, 508; surgical anatomy of, 509; parvus, 508  
 Pterion ossicle, 167  
 Pterygo-maxillary fissure, 198; ligament, 399  
 Pterygo-palatine artery, 571; canal, 160; nerve, 790  
 Pterygoid arteries, 570; muscles, 401; fossa of sphenoid, 162; of lower jaw, 185; nerve, 791; notch, 162; plexus of veins, 670; process of palate bone, 178; processes of sphenoid, 162; ridge, 160; tubercle, 162  
 Pubic arch, 268; articulations of, 333; portion of fascia lata, 512  
 Pubis, os, 264; angle of, 264; crest of, 264; spine of, 264; symphysis of, 264, 333  
 Pubo-femoral ligament, 358  
 Pubo-prostatic ligaments, 1084  
 Pudendum, 1099  
 Pudic artery in male, 637; peculiarities of, 638; in female, 639; accessory, 638; deep external, 650; superficial external, 649; nerve, 847; vein, external, 688; internal, 690  
 Pulmonary artery, 547, 1052; opening of, in right ventricle, 1021; capillaries, 1052; nerves from vagus, 808; sinuses, 1022; veins, 666, 667, 1054; openings of, in left auricle, 1023  
 Pulp-cavity of tooth, 926; of spleen, 1010; of teeth, development of, 932  
 Pulvinar of optic thalamus, 759  
 Puncta vasculosa, 751; lachrymalia, 899  
 Pupil of eye, 885; membrane of, 887  
 Purkinje, axis-cylinder of, 42; vesicle of, 73; corpuscles of, 773  
 Pyloric artery, 624; inferior, 624; glands, 970; plexus, 864  
 Pylorus, 967  
 Pyramid in vestibule, 912; of cerebellum, 770; of thyroid gland, 1056; of tympanum, 907  
 Pyramidal cell or nerve corpuscle, 766  
 Pyramidalis muscle, 455; nasi, 395  
 Pyramids of medulla, 728, 730; decussation of, 729; of Ferrein, 1064; of Malpighi, 1062; of the spine, 137  
 Pyriformis muscle, 520
- Quadrangle lobe, 74  
 Quadratus femoris muscle, 522; lumborum, 458; menti, 397  
 Quadratus lumborum, fascia covering, 458  
 Quadriceps extensor cruris muscle, 513  
 Quadrigeminal bodies, 762
- Racemose glands, 71  
 Radial artery, 609; branches of, 611; peculiarities of, 610; surgical anatomy of, 611; surface marking of, 611; lymphatic glands, 702; nerve, 830; recurrent artery, 611; region, muscles of, 486; vein, 681  
 Radialis indicis artery, 613
- Radio-carpal articulation, 350; surface form of, 352; surgical anatomy of, 352  
 Radio-ulnar articulations, inferior, 349; middle, 348; superior, 347; region, anterior, muscles of, 481; posterior, muscles of, 488  
 Radius, 243; articulations of, 245; development of, 244; fracture of, 505; grooves in lower end of, 244; muscles attached to, 245; oblique line of, 243; sigmoid cavity of, 244; surface form of, 245; tuberosity of, 243; and ulna, fracture of, 506; surgical anatomy of, 245  
 Rami of the lower jaw, 184  
 Ramus of ischium, 263; of os pubis, 265; ascending of os pubis, 264; descending, 265  
 Ranine artery, 561; vein, 669, 672  
 Ranvier, nodes of, 43  
 Raphé of corpus callosum, 751; of medulla, 732; of palate, 934; of perinæum, 1139; of scrotum, 1089; of tongue, 868  
 Rathke, investing mass of, 91  
 Rathke, posterior vertebral veins of, 107  
 Receiving tubes of kidney, 1064  
 Receptaculi arteriæ, 577  
 Receptaculum chyli, 698  
 Recess, optic, 759; pineal, 759  
 Recessus labyrinthi, 99  
 Reciprocal reception, articulations by, 308  
 Recto-uterine ligaments, 1104  
 Recto-vesical fascia, 1146; fold, peritoneal, 1077  
 Rectum, 987; development of, 109; relations of, male, 987; female, 987, 1102; folds of, 989; lymphatics of, 708; surgical anatomy of, 990  
 Rectus abdominis, 453; capitis anticus major, 423; minor, 423; posticus major, 438; minor, 438; lateralis, 424; femoris muscle, 513; surgical anatomy of, 515; oculi, internus, superior, inferior, and externus, 393  
 Recurrent artery, interosseous, 615; radial, 611; tibial, anterior, 659; posterior, 659; ulnar, anterior, 614; posterior, 614; laryngeal nerve, 807; nerves to tentorium, 781  
 REGION, abdominal, muscles of, 447; acromial, muscles of, 473; auricular, 389  
 back, muscles of, 426  
 cervical superficial, muscles of, 404; cranial, 387  
 epigastric, 947  
 femoral, muscles of, anterior, 509; internal, 515; posterior, 524; fibular, 533; foot, dorsum of, 536; sole of, 536  
 gluteal, muscles of, 518; groin, 1128  
 of hand, muscles of, 492; humeral, anterior, 477; posterior, 480; hypochondriac, 947; hypogastric, 948  
 iliac, muscles of, 507; infra-hyoid, 409  
 inguinal, 1128; intermaxillary, muscles of, 398; ischio-rectal, 1137  
 laryngo-tracheal, surgical anatomy of, 1044; lingual, muscles of, 413; lumbar, 948  
 maxillary, muscles of, inferior, 397; superior, 396  
 nasal, muscles of, 395  
 orbital, muscles of, 392

- palatal, muscles of, 420; palmar, 492; palpebral, 388; perinaeum, 1139; pharyngeal, muscles of, 418; popliteal, 652; pterygo-maxillary, muscles of, 401 radial, muscles of, 495; radio-ulnar, anterior, 481; posterior, 488 scapular, muscles of, anterior, 474; posterior, 475; Scarpa's triangle, 644; suprahyoid, muscles of, 411 temporo-maxillary, muscles of, 400; thoracic, 468; anterior, 468; lateral, 472; tibio-fibular, anterior, 525; posterior, 528 ulnar, 497; umbilical, 948 vertebral, muscles of, anterior, 423; lateral, 424
- REGIONS of abdomen, 947
- Reil, island of, 742
- Remak, fibres of, 43
- Renal afferent vessels, 1063, 1066; artery, 1066; inferior, 628; efferent vessels, 1063, 1067; plexus, 864; veins, 693, 1067
- Reservoir of Pecquet, 698
- RESPIRATION, organs of, 1032; muscles of, 446
- Respiratory nerves of Bell, external, 822; internal, 819; organs, development of, 110
- Restiform bodies of medulla oblongata, 729
- Rete mucosum of skin, 61; Malpighii, 62; testis, 1094
- Reticular cartilage; 24; layer of skin, 63; lamina of Kölliker, 917
- Retiform connective tissue, 19
- Retina, 887; arteria centralis of, 581, 892; fovea centralis of, 891; limbus luteus of, 887; membrana limitans interna, 888; externa, 890; layers of, 888; structure of, 888
- Retinacula of ileo-caecal valve, 984
- Retrahens aurem muscle, 390
- Retro-pharyngeal space, 406
- Rhomboid impression, 223; ligament, 335
- Rhomboidal sinus, 93
- Rhomboideus major, 431; minor, 430
- Ribes, ganglion of, 854
- Ribs, 214; angle of, 216; articulations of, 323; attachment of muscles to, 218; development of, 90, 218; false, 215; floating, 215; head of, 215; ligaments of, 323; neck of, 216; peculiar, 217; true, 215; tuberosity of, 216
- Ridge, internal occipital, 143; mylo-hyoidean, 184; pterygoid, 160; superciliary, 148; temporal, 146, 151, 197
- Rima glottidis, 1036
- Ring, abdominal, external, 449, 1117; internal, 1121; femoral or crural, 1134; fibrous, of heart, 1025
- Ring muscle, 887
- Risorius muscle, 399
- Rivini, ducts of, 937; incisura of, 906, 909
- Robin, polar globules of, 73
- Rods of Corti, 916; of retina, 890
- Rod-granules of retina, 890
- Rolando, tubercle of, 729, 731; fissure of, 738; topography of, 745; funiculus of, 729
- Roof nuclei of Stilling, 774
- Root of lung, 1050
- Root sheath of hair, 65
- Roots of spinal nerves, 812; of teeth, 923; of zygomatic process, 152
- Rosenmüller, organ of, 114, 1111; accessory gland of, 899
- Rostrum of sphenoid bone, 160; of corpus callosum, 751
- Rotation, 310
- Rotatores spinæ muscles, 437
- Round ligaments of uterus, 1112; relations of, to femoral ring, 1134; of liver, 996
- Rugæ of stomach, 970; of vagina, 1103
- Rupture of urethra, course taken by urine in, 1139
- Rust-coloured layer of cerebellar cortex, 773
- Sac, lachrymal, 900
- Saccular secretory glands, 71
- Sacculæ of vestibule, 914
- Sacculus laryngis, 1037
- Sacra-media artery, 630
- Sacral arteries, lateral, 641; canal, 135; cornua, 133; foramina, 133; ganglia, 861; groove, 134; lymphatic glands, 707; nerves, 843; anterior divisions of, 844; posterior divisions, 844; roots of, 843; plexus, 845; vein, lateral, 691; middle, 691; peculiarities of, 691
- Sacro-coxycgeal ligaments, 332
- Sacro-iliac articulation, 330
- Sacro-lumbalis muscle, 435
- Sacro-sciatic foramen, greater, 263, 332; lesser, 263, 332; ligaments, 331; notch, greater, 263; lesser, 263
- Sacro-uterine ligaments, 1105
- Sacro-vertebral angle, 132; ligament, 329
- Sacrum, 132; ala of, 134; articulations of, 136; attachment of muscles to, 136; development of, 135; peculiarities of, 135; structure of, 135
- Sacs, dental, 930
- Saddle joint, 308
- Sagittal suture, 186
- Salivary glands, 935; structure of, 938
- Salpingo-pharyngeus, 421
- Salter, incremental lines of, 928
- Santorini, cartilages of, 1034
- Saphena veins, surgical anatomy of, 689
- Saphenous nerve, long or internal, 842; short, 850; opening, 512, 1131; vein, external or short, 689; internal or long, 688, 1128; surgical anatomy of, 689
- Sarcode, 8
- Sarcolemma, 36
- Sarcoplasm, 37
- Sarcostyles, 37
- Sarcous elements of muscle, 38
- Sartorius muscle, 412
- Scala tympani of cochlea, 914, 916; vestibuli of cochlea, 914, 916; media, 916
- Scala of cochlea, 916
- Scalenus anticus, 424; medius, 424; posterior, 425
- Scalp, skin of, 388
- Scaphoid bone (hand) 246, (foot) 294; fossa of sphenoid, 162
- Scapula, 225; articulations of, 230; attachment of muscles to, 230; development of, 230; dorsum of, 225; glenoid cavity of,

- 228; head of, 228; ligaments of, 338; muscles of, 474; spine of, 226; venter of, 225; surface form of, 230; surgical anatomy of, 231
- Scapular artery, posterior, 596; notch, great, 228; region, muscles of, anterior, 474; posterior, 475
- Scapulo-clavicular articulation, 336
- Scarfskin, 61
- Scarpa, fascia of, 448; foramina of, 173, 193
- Scarpa's triangle, 644
- Schachowa, spiral tubes of, 1064
- Schindylesis, 307
- Schlemm, canal of, 882; ligament of, 340
- Schneiderian membrane, 875
- Schreger, lines of, 928
- Schultze, cells of, 777, 877; primitive fibrillæ of, 43
- Schwann, white substance of, 42
- Sciatic artery, 639; nerve, greater, 849; surgical anatomy of, 853; nerve, lesser, 847; veins, 690
- Sclerotic, 880
- Scrobiculus cordis, 219
- Scrotal hernia, 1124
- Scrotum, 1089; dartos of, 1089; development of, 116; lymphatics of, 707; nerves of, 1090; septum of, 1089; surgical anatomy of, 1091; vessels of, 1090
- Sebaceous glands, 66
- Second nerve, 778; surgical anatomy of, 779
- Secondary areolæ of bone, 32; ocular vesicle, 98
- Secreting glands, 70
- Sella turcica, 158, 191
- Semicircular canals, 912
- Semilunar bone, 249; cartilages of knee, 366; fold of Douglas, 452, 455; fascia, 479; ganglion of fifth nerve, 782; of abdomen, 862; valves, aortic, 1024; pulmonary, 1022
- Semimembranosus muscle, 525
- Seminal cells, 1093; tubes, 1093; vesicles, 1095
- Semispinalis muscle, 437
- Semitendinosus muscle, 524
- Senac, on structure of heart's valves, 1021
- SENSES, organs of the, 867
- Septum auricularum, 1023; crurale, 1135; lucidum, 755; of nose, 203; artery of, 564; cartilage of, 875; pectiniforme, 1086; of Pons Varolii, 735; scroti, 1089; subarachnoid, 713; of tongue, 868; ventriculorum, 1024
- Septum between bronchi, 1042
- Serous glands of tongue, 871
- Serous membranes, 68
- Serratus magnus, 472; posticus inferior, 432; superior, 431
- Serum, 1, 5
- Serum globulin, 1
- Sesamoid bones, 304; cartilages, 874
- Seventh nerve, 796; surgical anatomy of, 801
- Shaft of a bone, its structure, 119
- Sheath of arteries, 53; of muscles, 36; of nerves, 43; femoral or crural, 1133; of rectus muscle, 455
- Shin, 282
- Short bones, 119
- Shoulder, muscles of, 473; girdle, 221; joint, 339; surface form of, 342; surgical anatomy of, 342; vessels and nerves of, 341
- Sigmoid artery, 627; cavity, greater of ulna, 238; lesser, of ulna, 240; of radius, 244; flexure of colon, 986; meso-colon, 966; notch of lower jaw, 185
- Sinuses, cranial, 149, 667, 675; cavernous, 676; circular, 677; lateral, 676; longitudinal, inferior, 676; superior, 675; occipital, 676; petrosal, inferior, 677; superior, 677; straight, 676; transverse, 678
- Sinuses of heart, of right auricle, 1019, of left, 1023; of coronary vein, 695, 1020
- Sinuses of nose, 149; ethmoidal, 166; frontal, 149; maxillary, 171; sphenoidal, 159
- Sinuses of Valsalva, aortic, 549, 1024; pulmonary, 1022
- Sinus circularis iridis, 882
- Sinus of external jugular vein, 671; of internal, 671
- Sinus of kidney, 1061
- Sinus of Morgagni, 419
- Sinus pocularis, 112, 1080
- Sinus prostaticus, 114, 1080
- Sinus venosus, 106
- Sixth nerve, 795; surgical anatomy of, 796
- Skeleton, 119; number of its pieces, 119
- SKIN, *General Anatomy of*, 61; appendages of, 64; arteries of, 63; corium of, 63; cuticle of, 61; derma, or true skin, 63; development of, 100; epidermis of, 61; furrows of, 61; hairs, 64; muscular fibres of, 66; nails, 64; nerves of, 64; papillary layer of, 63; rete mucosum of, 61; sebaceous glands of, 66; sudoriferous or sweat glands of, 66; tactile corpuscles of, 49; vessels of, 63
- SKULL, 141, 189; anterior region, 199; base of, external surface, 193, internal surface, 190; fossa of, anterior, 190, middle, 191, posterior, 192; lateral region of, 196; tables of, 119; surface marking of, 204; vertex of, 189; surgical anatomy of, 206; vitreous table of, 120
- Slender lobe of cerebellum, 770
- Small intestine, areolar coat of, 976; mucous coat of, 976; muscular coat of, 976; serous coat of, 976; simple follicles, 979; valvulæ conniventes, 976; villi of, 977
- Small intestine, 973; duodenum, 973; ileum, 975; jejunum, 975
- Socia parotidis, 936
- Soft palate, 934; aponeurosis of, 934; arches or pillars of, 934; muscles of, 420; structure of, 934
- Solar plexus, 862
- Sole of foot, muscles of, first layer, 537, second layer, 538, third layer, 539, fourth layer, 540
- Soleus muscle, 529
- Solitary glands, 979
- Somatopleure, 81
- Sömmerring, yellow spot of, 887
- Space, anterior perforated, 748; axillary, 598; intercostal, 215; popliteal, 652; posterior perforated, 749
- Spaces of Fontana, 882



- SPERMATIC ARTERY, 629, 1090; canal, 1120; cord, 1090; arteries of, 1090; course of, 1090; lymphatics of, 1091; nerves of, 1091; relation to femoral ring, 1134; relations of, in inguinal canal, 1090, 1121; veins of, 1091; fascia, external, 450, 1118; plexus of nerves, 1091; of veins, 692; veins, 692, 1091; surgical anatomy of, 692
- Spermatoblasts, 1093  
Spermatogenic cells, 1093  
Spermatogonia, 1093  
Spermatozoa, 1093
- Spheno-maxillary fissure, 197; fossa, 198  
Spheno-palatine artery, 571; foramen, 180; ganglion, 788; nerves, 787; notch, 180  
Spheno-parietal suture, 188  
Sphenoid bone, 158; articulations of, 163; attachment of muscles to, 163; body of, 158, development of, 162, greater wings of, 160, lesser wings of, 161, pterygoid processes of, 162, rostrum of, 160; spinous processes of, 161; vaginal processes of, 160
- Sphenoidal epithelium, 13  
Sphenoidal fissure, 161; nerves in, 796; process of palate, 179; sinuses, 159; spongy, or turbinated bones, 162  
Sphincter muscle of bladder, 1078; of rectum, external, 459, internal, 459; of vagina, 465  
Spina bifida, 140  
Spinal accessory nerve, 809; surgical anatomy of, 809  
Spinal arteries, anterior, 592; lateral, 592; posterior, 592; median, 592; canal, 139  
SPINAL CORD, 714; development of, 88; arachnoid of, 713; arrangement of grey and white matter in, 716, central canal of, 717, central ligament of, 714, columns of, 716, dura mater of, 712, fissures of, 715, fetal peculiarity of, 715, grey commissure of, 717, minute structure of, 718, ligamentum denticulatum of, 714, membranes of, 712, neuroglia of, 718, pia mater of, 713, sections of, 716, surgical anatomy of membranes of, 714, white commissure of, 716, white matter of, 716
- Spinal foramen, 121, 139  
Spinal nerves, 812; arrangement into groups, 812; divisions of, anterior, 813, posterior, 813; development of, 96; distribution of, 813; origin of, in cord, 812; ganglia of, 813; origin of roots, anterior, 812, posterior, 812; points of emergence of, 814  
Spinal veins, 686, longitudinal anterior, 686, posterior, 687  
Spinalis colli muscle, 436; dorsi, 436  
Spindle, achromatic, 10; poles of, 10  
SPINE, 120; *General Description of*, 139; articulations of, 311; development of, 88; ossification of, 129; surface form of, 139; surgical anatomy of, 139  
Spines of bones, ethmoidal, 158; of ischium, 263; nasal, 149; anterior, 173; posterior, 178; pharyngeal, 143; of os pubis, 264; scapula, 226  
Spinous process of ilium, 262, of sphenoid, 161, of tibia, 281, of vertebræ, 121  
Spiral canal of cochlea, 913; line of femur, 273  
Spirem or skein, 10  
Splanchnic nerve, greater, 860, lesser, 860, smallest or renal, 860  
Splanchnopleure, 81  
SPLEEN, 1008; capillaries of, 1011; development of, 110; fibro-elastic coat of, 1009; lymphatics of, 709, 1013; Malpighian bodies of, 1011; nerves of, 1013; proper substance of, 1010; relations of, 1008; serous coat of, 1009; size and weight, 1009; artery of, 1010; structure of, 1009; surface marking of, 1013; trabeculæ of, 1010; veins of, 1012; surgical anatomy of, 1013  
Splenial artery, 625; distribution of, 1010; plexus, 864; corpuscles, 1011; pulp, 1010; vein, 693  
Splenium of corpus callosum, 751  
Splenius muscle, 432  
Spongy portion of urethra, 1081; tissue of bone, 119  
Spring ligament, 378  
Squamo-sphenoidal suture, 188; parietal suture, 188; zygomatic portion of temporal bone, 157  
Squamous portion of temporal bone, 151  
Stapedius muscle, 910  
Stapes, 909; annular ligament of, 909; development of, 99  
Stellate ligament, 323; plexus of kidney, 1067  
Stenson, foramina of, 173, 193  
Stenson's duct, 936  
Sternal end of clavicle, fracture of, 503; foramen, 211; furrow, 219; ligaments, 328  
Sterno-clavicular articulation, 334; surface form of, 336; surgical anatomy of, 336  
Sterno-hyoid muscle, 409  
Sterno-mastoid muscle, 407; artery, 560  
Sterno-pericardiac ligaments, 1015  
Sterno-thyroid muscle, 409  
Sternum, 211; articulations of, 214; attachment of muscles to, 214; development of, 90, 213; ligaments of, 328  
Stilling, canal of, 893  
STOMACH, 967; alteration in position of, 968; alveoli of, 970; areolar coat of, 969; cardiac glands of, 971; curvatures of, 967; development of, 108; fundus of, 967; gastric follicles of, 970; ligaments of, 968; lymphatics of, 709; mucous membrane of, 969; muscular coat of, 969; orifices of, 967; pyloric glands of, 970; pyloric end of, 967; pylorus, 968; serous coat of, 968; splenic end of, 967; structure of, 968; surfaces of, 967; surface marking of, 972; surgical anatomy of, 972; vessels and nerves of, 971  
Stomodæum, 93, 94  
Straight sinus, 676  
Straight tubes of kidney, 1064  
Stratified epithelium, 14  
Stratiform fibro-cartilage, 24  
Stratum cinereum, 767; corneum, 62; lucidum, 62; opticum, 767, 778; gelatinosum, 766; glomerulosum, 766  
Striæ longitudinales, 751; laterales, 751  
Striæ medullaris vel acusticæ, 776

- Striped muscle, 36  
 Stroma of ovary, 1110  
 Stylo-glossus muscle, 414  
 Stylo-hyoid ligament, 412; muscle, 412;  
   nerve from facial, 798  
 Stylo-mastoid artery, 566; foramen, 157;  
   vein, 670  
 Stylo-maxillary ligament, 321, 406  
 Stylo-pharyngeus muscle, 419  
 Styloid process of temporal bone, 157; of  
   fibula, 285; of radius, 244; of ulna, 242  
 Subanconeus muscle, 480  
 Subarachnoid space of brain, 725; of cord,  
   713; fluid, 726; septum, 713; tissue,  
   713  
 Subcaecal fossa, 983  
 Subclavian arteries, 585; branches of, 591;  
   first part of, left, 586; right, 585; pecu-  
   liarities of, 588; second portion of, 587;  
   third, 587; surgical anatomy of, 589;  
   surface form of, 589; groove, 223; nerve,  
   822; triangle, 574; vein, 682  
 Subclavius muscle, 471  
 Subcostal angle, 211; artery, 619; muscles,  
   442  
 Suberureus muscle, 515  
 Subcutaneous malæ nerve, 799  
 Subdural space, 713, 725  
 Sublingual artery, 561; fossa, 184; gland,  
   937; vessels and nerves of, 838  
 Sublobular veins, 998  
 Submaxillary artery, 564; fossa, 184; gan-  
   glion, 794; gland, 937; nerves of, 937;  
   vessels of, 937; lymphatic gland, 701;  
   triangle, 573; vein, 669  
 Submental artery, 564; vein, 669  
 Suboccipital nerve, 816; posterior branch  
   of, 814; triangle, 439, 592  
 Subpeduncular lobe of cerebellum, 770  
 Subpleural mediastinal plexus, 596  
 Subpubic ligament, 333  
 Subscapular fascia, 474; angle, 225; artery,  
   604; fossa, 225; nerves, 823  
 Subscapularis muscle, 474  
 Substantia cinerea gelatinosa, 720; ferru-  
   ginea, 776; gelatinosa centralis, 717  
 Sudoriferous glands, 66  
 Sulci of cerebrum, 736  
 Sulcus, frontal, inferior, 738; superior, 738;  
   intraparietal, 739; occipital, inferior,  
   741; middle, 741; superior, 741; for  
   olfactory tract, 738; orbital, 738;  
   parallel, 741; post-central, 739; pre-  
   central, 738; of Reil, anterior, 742;  
   external, 742; posterior, 742; temporo-  
   sphenoidal, middle, 741; superior, 741;  
   tri-radiate, 738; sulcus longitudinalis  
   medians, 776  
 Sulcus spiralis, 916  
 Supercilia, 896  
 Superciliary ridge, 148  
 Superficial palmar arch, 616; cervical  
   artery, 596; circumflex iliac artery, 649;  
   epigastric, 649; external pudic, 649;  
   perineal artery, 638; transverse liga-  
   ment of fingers, 495; temporal artery,  
   567; surgical anatomy of, 567  
 Superficialis colli nerve, 818; volæ artery,  
   611  
 Superior maxillary bone, 169; articulations  
   of, 174; attachment of muscles to, 174;  
   development of, 173; changes in, pro-  
   duced by age, 174; nerve, 786  
 Superior mediastinum, 1048; meatus, 203,  
   876; medullary velum, 772; profunda  
   artery, 608; turbinated crest, 172; of  
   palate, 178; vena cava, 684  
 Superior thyroid artery, 560; surgical ana-  
   tomy of, 561  
 Supinator brevis muscle, 489; longus, 486  
 Supra-acromial nerves, 819; artery, 595  
 Supraclavicular nerves, 819  
 Suprascapular nerves, 819; artery, 595  
 Supraglenoid tubercle, 228  
 Suprahyoid aponeurosis, 209, 411  
 Supramarginal convolution, 740  
 Supramastoid crest, 152  
 Supranaxillary nerves from facial, 800  
 Supra-orbital arch, 149; artery, 578; fora-  
   men, 149, 199; nerve, 784; notch, 149  
 Suprarenal arteries, 628; capsules, 1071;  
   development of, 112; nerves of, 1073;  
   vessels of, 1073; plexus, 864; veins, 693  
 Suprascapular artery, 595; ligament, 339;  
   nerve, 822; notch, 228  
 Supraspinales muscles, 438  
 Supraspinatus muscle, 475  
 Supraspinous ligaments, 314; fascia, 475;  
   fossa, 225  
 Supratrochlear foramen, 234; nerve, 783  
 Sural arteries, 655; veins, 689  
 SURFACE FORM OR MARKING, of abdominal  
   aorta, 621; of acromio-clavicular joint,  
   338; of ankle-joint, 376; of anterior  
   tibial artery, 658; of axillary artery,  
   602  
   of bladder, 1079; of brachial artery, 607;  
   of branches of internal iliac artery,  
   641  
   of carpus, 257; of cerebral convolutions,  
   744; of clavicle, 224  
   of common carotid artery, 557; of com-  
   mon iliac artery, 632; of cranium,  
   204  
   of dorsalis pedis artery, 660  
   of elbow, 346; of external auditory  
   meatus, 905; of external carotid  
   artery, 559  
   of external iliac artery, 642  
   of femoral artery, 647; of femur, 278;  
   of fibula, 287; of fifth cranial nerve,  
   794; of foot, 302  
   of heart, 1027; of hip-joint, 361; of  
   humerus, 236; of hyoid bone, 210  
   of intestines, 990  
   of kidney, 1068; of knee-joint, 370; of  
   knuckles, 357  
   of larynx, 1044; of liver, 1003; of lungs,  
   1054  
   of mouth, 940; of muscles of abdomen,  
   457; of head and face, 403; of back,  
   440; of lower extremity, 542; of neck,  
   426; of upper extremity, 501  
   of palmar arches, 617; of palpebral  
   fissure, 900  
   of pancreas, 1007; of patella, 280; of  
   pelvis, 270  
   of plantar arch, 664; of popliteal artery,  
   655; of posterior tibial artery, 661  
   of radial artery, 611; of radio-ulnar  
   joint, superior, 348; inferior, 350; of  
   radius, 245



SURFACE FORM OR MARKING (*continued*)

- of scapula, 230; of shoulder-joint, 342;
  - of skull, 204; of spleen, 1013; of spine, 139
  - of sterno-clavicular joint, 336; of sterno-mastoid, 409; of stomach, 972
  - of subclavian artery, 589
  - of tarsus and foot, 302
  - of temporo-maxillary joint, 322; of thorax, 219; of tibia, 284
  - of ulnar, 242; of ulnar artery, 614
  - of vertebral column, 139
  - of wrist and hand, 257; of wrist-joint, 352
- SURGICAL ANATOMY, of abdominal aorta, 621; of abducent nerve, 796; of acromio-clavicular joint, 338; of adductor longus muscle, 518; of ankle-joint, 376; of anterior tibial artery, 658; of arch of aorta, 551; of artery of the bulb, 639; of ascending pharyngeal artery, 567; of auditory nerve, 802; of axilla, 600; of axillary artery, 602; of axillary glands, 703; of axillary vein, 682, of azygos veins, 685
- of base of bladder, 1143; of brachial artery, 607; of brachial plexus, 831; of bend of elbow, 605; of bones of face, 208; of branches of internal iliac, 641
  - of cavernous sinus, 677; of cervical glands, 702; of cervical vertebræ, 319; of clavicle, 224; of club-foot, 534; of common carotid, 557; of common iliac, 632
  - of deltoid muscle, 474; of dorsalis pedis artery, 660; of deep epigastric, 644; of descending aorta, 618
  - of extensor muscles of thumb, 492; of external carotid artery, 559; of external iliac artery, 642; of external jugular vein, 671; of eye, 895
  - of external ear, 905; of elbow-joint, 346; of Eustachian tube, 942
  - of facial artery, 565; of facial vein, 669; of facial nerve, 801; of femoral artery, 647; of femoral hernia, 1128; of femur, 278
  - of gluteal artery, 641
  - of hæmorrhoidal veins, 690; of hamstrings, 525; of forearm, bones of, 245; of foot, bones of, 302; of hand, bones of, 258; of hip-joint, 361; of humerus, 224; of hyoid bone, 210; of hypoglossal nerve, 812
  - of iliac fascia, 509; of inferior thyroid artery, 595; of inferior vena cava, 685; of inguinal hernia, 1115; of inguinal glands, 704; of innominate artery, 554; of intercostal nerves, 735; of internal carotid artery, 577; of internal jugular vein, 672; of internal mammary artery, 598; of internal iliac artery, 634; of internal pudic artery, 638; of intestines, 990; of ischio-rectal region, 1137
  - of joints of cervical vertebræ, 319
  - of kidneys, 1069; of knee-joint, 370
  - of lachrymal apparatus, 901; of laryngo-tracheal region, 1044; of larynx, 1044; of laryngeal nerves, 808; of leg, bones of, 287; of lingual artery, 562; of

SURGICAL ANATOMY (*continued*)

- liver, 1004; of lumbar plexus, 852;
  - of lungs, 1055
  - of middle meningeal artery, 569; of motor oculi nerve, 781; of muscles of eye, 395; of muscles of lower extremity, 543; of muscles of soft palate, 422; of muscles of upper extremity, 503; of musculo-spiral nerve, 832
  - of nasal fossæ, 878; of nose, 878
  - of œsophagus, 944; of olfactory nerve, 778; of optic nerve, 779
  - of palmar arch, 617; of palmar fascia, 495; of pancreas, 1007; of patella, 280; of pelvis, bones of, 271; of penis, 1088; of perinæum, 1137; of peroneal or external popliteal nerve, 854; of pharynx, 942; of plantar arch, 664; of plantar ligaments, 378; of pleura, 1047; of popliteal artery, 655; of posterior tibial, 661; of pronator radii teres muscle, 482; of prostate gland, 1085; of psoas magnus, 509
  - of radial artery, 611; of radio-ulnar joint, 348; of rectus femoris muscle, 515; of ribs, 220
  - of saphena veins, 689; of scapula, 231; of Scarpa's triangle, 644; of sciatic artery, 641; of sciatic (great) nerve, 853; of scrotum, 1091; of serratus magnus muscle, 473; of shoulder-joint, 342; of skull, 206; of spermatic veins, 692; of spine, 140; of spinal accessory nerve, 809; of spleen, 1013; of sterno-clavicular joint, 336; of sterno-mastoid muscle, 409; of sternum, 220; of stomach, 972; of subclavian artery, 589; of superior thyroid artery, 561; of synovial sheaths of tendons of wrist, 493
  - of talipes, 534; of tarsal joints, 378, 380; of temporal artery, 567; of temporo-maxillary joint, 322; of testis, 1095; of thoracic aorta, 618; of thorax, 220; of thyroid gland, 1057; of tongue, 417, 872; of triangles of neck, 571; of triceps, 481; of trifacial nerve, 794; of trochlear nerve, 781
  - of ulnar artery, 617; of urethra, 1081
  - of vertebral artery, 593; of vesico-prostatic plexus, 691; of vesiculæ seminales, 1097
  - of wrist-joint, 352
- Suspensory ligament of incus, 910; of lens, 894; of liver, 995; of malleus, 909; of penis, 1085
- Sustentacular cells of spleen, 1010
- Sustentaculum tali, 290
- Sutura, 307; dentata, 307; harmonia, 307; limbosa, 307; notha, 307; serrata, 307; squamosa, 307; vera, 307
- SUTURE, basilar, 188; coronal, 188; cranial, 186; frontal, 186; fronto-parietal, 188; fronto-sphenoidal, 188; intermaxillary, 199; internasal, 199; interparietal, 186; lambdoid, 188; masto-occipital, 188; masto-parietal, 188; occipito-parietal, 188; petro-occipital, 188; petro-sphenoidal, 188; petro-squamous, 188; sagittal, 186; sphenoparietal, 188; squamo-



- parietal, 188; squamo-sphenoidal, 188; temporal, 155; transverse facial, 188
- Swallow's nest of cerebellum, 771
- Sweat-glands, 66
- Sylvius, fissure of, 748; surface marking of, 745; aqueduct of, 761
- SYMPATHETIC NERVE, 46, 854; cervical portion, 856; cranial portion, 858; lumbar portion, 860; pelvic portion, 861; thoracic portion, 861; plexuses, 861; cardiac, 861; epigastric, 862; hypogastric, 865; pelvic, 865; solar, 862
- Symphysis, 307; of jaw, 183; pubis, 264, 333
- Synarthrosis, 306
- Syndesmo-odontoid joint, 315
- Syndesmosis, 307
- Synovia, 306
- Synovial ligaments, 306; sheaths, 306
- SYNOVIAL MEMBRANE, 69, 305; articular, 305; bursal, 306; vaginal, 306. *See also* Individual Joints
- System, Haversian, 27
- Systemic arteries, 546; veins, 666
- Tables of the skull, 119
- Tactile corpuscles, 48; of Grandry, 49
- Tænia hippocampi, 755; semicircularis, 755; of fourth ventricle, 775
- Tænia tectæ, 751
- Tapetum lucidum, 890; nigrum, 890
- Tarsal artery, 660; bones, 287; ligaments, 376; plates of eyelid, 897; ligament of eyelid, 391, 897
- Tarso-metatarsal articulations, 380
- Tarsus, 287; articulations of, 376; surface form of, 302; surgical anatomy of, 302; synovial membranes of, 381; development of, 300
- Taste-goblets, 870
- TEETH, 923; bicuspid, 924; body of, 923; canine, 924; cement of, 928; crown of, 923; crusta petrosa of, 928; cortical substance of, 928; cuspidate, 924; deciduous, 923; dental tubuli of, 927; dentine of, 927; development of, 929; enamel of, 928; eruption of, 933; eye, 924; false molars, 924; fang of, 923; general characters of, 923; incisors, 923; intertubular substance of, 927; ivory of, 928; milk, 923, 926; molar, 925; multi-cuspidate, 925; permanent, 923; pulp-cavity of, 926; root of, 923; structure of, 926; temporary, 923, 926; true or large molars, 925; wisdom, 925
- Tegmen tympani, 155, 906
- Tegmentum of crus cerebri, 750, 764
- Tela choroidea inferior, 775
- Temporal artery, 567; anterior, 567; deep, 570; middle, 567; posterior, 567; surgical anatomy of, 567
- Temporal bone, 151; articulations of, 158; attachment of muscles to, 158; development of, 157; mastoid portion, 153; petrous portion, 155; squamous portion, 151; structure of, 157
- Temporal fascia, 400; fossæ, 197; ganglion, 859; muscle, 400; nerves of auriculo-temporal, 792; deep, 791; of facial, 799; ridge, 146, 149, 197; suture, 155; veins, 669
- Temporary cartilage, 23; teeth, 923, 926
- Temporo-facial nerve, 799; malar, 786; maxillary articulation, 320; surface form of, 322; surgical anatomy of, 322; maxillary vein, 670
- Temporo-sphenoidal lobe, 741
- Tendo Achillis, 529; palpebrarum or oculi, 391
- Tendon, central, or cordiform, of diaphragm, 444; conjoined of internal oblique and transversalis, 452, 1119
- Tendon, structure of, 385
- Tendons of wrist, relation of, 494
- Tenon, capsule of, 879
- Tensor palati muscle, 421; tarsi muscle, 392; tympani muscle, 910; canal for, 157, 907; vaginæ femoris muscle, 512
- Tenth nerve, 803; surgical anatomy of, 808
- Tentorium cerebelli, 724
- Teres major muscle, 477; minor, 476
- Terminal sinus, 103
- Testes, 1091; coni vasculosi of, 1094; coverings of, 1092; development of, 113; tunica albuginea, 1092; vaginalis, 1092; vasculosa, 1093; gubernaculum testis, 1097; lobules of, 1093; lymphatics of, 708; mode of descent, 1097; rete testis, 1094; size and weight of, 1092; structure of, 1093; tubuli, seminiferi of, 1093; surgical anatomy of, 1095; vas deferens of, 1094; vasa efferentia of, 1094; vasa recta of, 1094; vas aberrans of, 1095
- Testes muliebres, 1109
- Thalamencephalon, 94
- Thalami optici, 759
- Thebesii vein, 696; foramina, 696
- Theca vertebralis, 712
- Thigh, muscles of back of, 524; deep fascia, fascia lata, 510; superficial fascia, 510, 1128; muscles of front, 509
- Third nerve, 779; surgical anatomy of, 781; ventricle of the brain, 759
- Thoracic aorta, 617; surgical anatomy of, 618
- Thoracic artery, aëromial, 603; alar, 604; long, 604; superior, 603
- Thoracic duct, 698
- Thoracic ganglia of sympathetic, 860
- Thoracic nerves, anterior, 823; posterior, or long, 822
- Thoracic region, muscles of anterior, 468; lateral, 472
- THORAX, *General Description of*, 1014; base of, 1014; bones of, 210; boundaries of, 210; cavity of, 1014; cutaneous nerves of, anterior, 734; lateral, 734; fasciæ of, 441; lower opening of, 211; lymphatics of, 709; muscles of, 441; parts passing through upper opening of, 1014; lower opening of, 1014; surface form of, 219; upper opening of, 210
- Thumb, articulation of, with carpus, 354; muscles of, 495
- Thymic artery, 553; lymphatic vessels, 711
- Thymus gland, 1057; lobes of, 1058; lymphatics of, 1059
- Thyro-arytenoid ligament, inferior, 1037; superior, 1037
- Thyro-arytenoideus muscle, 1039
- Thyro-epiglottic ligament, 1034
- Thyro-epiglottideus muscle, 1039

- Thyro-hyal of hyoid bone, 210  
 Thyro-hyoid arch (fœtal), 93; ligaments, 1035; membrane, 1035; muscle, 410; nerve, 812  
 Thyroid artery, inferior, 594; superior, 560; surgical anatomy of, 561; axis, 594; branches of sympathetic, 859; cartilage, 1032; foramen, 265; ganglion, 859; gland, 1055; isthmus of, 1055; lymphatics of, 711; veins, inferior, 684; middle, 672; superior, 672  
 Thyroidea ima artery, 553  
 Tibia, 280; articulations of, 284; attachment of muscles to, 284; crest of, 282; development of, 284; fracture of shaft of, 545; nutrient artery of, 663; spinous process of, 281; surface form of, 284; surgical anatomy, 287; tubercle of, 281; tuberosities of, 281  
 Tibial artery, anterior, 657; branches of, 658; peculiarities of, 658; surgical anatomy of, 658; surface marking of, 658; posterior, 660; branches of, 662; peculiarities of, 661; surgical anatomy of, 661; surface marking of, 661; lymphatic glands, 704; nerve, anterior, 852; posterior, 850; recurrent artery, 659; veins, anterior, 689; posterior, 689  
 Tibialis anticus muscle, 527; posticus muscle, 532  
 Tibio-fibular articulations, 371; region, anterior, muscles of, 525; posterior, 528  
 Tibio-tarsal ligament, 373  
 Tongue, 867; arteries of, 872; development of, 109; fibrous septum of, 871; frænnum of, 867; mucous glands, 870; mucous membrane of, 868; muscles of, 413; nerves of, 872; papillæ of, 868; serous glands of, 871; surgical anatomy of, 872  
 Tonsillar artery, 563  
 Tonsillar nerves, 803  
 Tonsils, 935; nerves of, 935; vessels of, 935; of cerebellum, 770  
 Toreular Herophili, 143, 675  
 Trabeculæ of corpus cavernosum, 1087; cranii, 91; of spleen, 1009; of testis, 1093; of fetal skull, 91  
 TRACHEA, 1041; cartilages of, 1042; glands of, 1043; relations of, 1041; structure of, 1042; surgical anatomy of, 1044; vessels and nerves of, 1044  
 Trachealis muscle, 1043  
 Trachelo-mastoid muscle, 435  
 Tracheotomy, 1045  
 Trachoma glands, 898  
 Tracts of cord, antero-lateral, 719; antero-lateral ground bundle, 720; of Burdach, 720; crossed pyramidal, 719; direct cerebellar, 719; direct pyramidal, 718; of Goll, 720; of Gowers, 719; of Lissauer, 720  
 Tractus intermedio-lateralis, 722  
 Tractus opticus, 778  
 Tragicus muscle, 903  
 Tragus, 902  
 Transitional epithelium, 15  
 Transversalis cervicis muscle, 436, *footnote*  
 Transversalis colli artery, 595; muscle, 435  
 Transversalis fascia, 1121; muscle, 453  
 Transversalis humeri artery, 595  
 Transverse arteries of basilar, 593; colon, 984; disc of muscular fibre, 37; facial artery, 567; vein, 669; fissure of brain, 756; of liver, 996; humeral ligament, 340; joint of foot, 375; ligament of atlas, 316; of hip, 360; of knee, 366; metatarsal ligament, 382; of scapula, 339; of shoulder, 340; superficial of fingers, 495; tibio-fibula, 372; mesocolon, 966; process of a vertebra, 121; sinus, 678; suture, 188  
 Transversus auriculæ, 903; perinæi, 462; perinæi (in female), 465  
 Trapezium, bone, 251; of pons, 735  
 Trapezius muscle, 427  
 Trapezoid bone, 251; ligament, 337  
 Treitz, muscle of, 953, 975  
 Triangle, inferior, carotid, 572; of elbow, 605; of Hesselbach, 1123, 1126; of neck, anterior, 572; posterior, 573; occipital, 574; Scarpa's, 644; subclavian, 574; submaxillary, 573; suboccipital, 439; superior carotid, 573  
 Triangular ligament of abdomen, 451, 1119; of urethra, 464, 1140; interarticular fibro-cartilage, 349  
 Triangularis sterni muscle, 442; menti muscle, 397  
 Triceps extensor cruris, 514; extensor cubiti, 480; suræ, *footnote*, 529  
 Tricuspid valves, 1021  
 Trifacial or trigeminus nerves, 782; surface marking of, 794; surgical anatomy of, 794  
 Trigone of bladder, 1078  
 Trigonum, acusticum, 776; habenukæ, 759; hypoglossi, 776; vagi, 776  
 Tri-radiate sulcus, 738  
 Trochanter, greater, 273; lesser, 273  
 Trochanteric fossa, 273  
 Trochlea of humerus, 235; of femur, 275  
 Trochlear fossa, 150; nerve, 781; surgical anatomy of, 781  
 Trochoides, 308  
 Trolard, anastomotic vein of, 674  
 True pelvis, 267; ligaments of bladder, 1076; ribs, 215  
 Trunk, articulations of, 311; muscles of, 426  
 Tube, Eustachian, 908; Fallopian, 1108  
 Tubercle, annular, 734; cinereum, 749; ischii 263; omentale, 994  
 Tubercle, adductor, 275; carotid or Chassaignac's, 122; of the clavicle, 222; conoid, 222; deltoid, 222; of the femur, 275; genital, 116; of hyoid bone, 209; lachrymal, 172; laminated of cerebellum, 771; of Lower, 1020; of navicular, 294; for odontoid ligaments, 143; of the quadratus, 274; of rib, 216; of Rolando, 729, 731; of scaphoid, 249; of the tibia, 281; of ulna, 238; of zygoma, 152  
 Tubercles, genial, 183; mental, 183; of ribs, 216  
 Tubercula quadrigemina, 762  
 Tuberculum acusticum, 776; cuneatum, 729  
 Tuberosities of humerus, greater, 231; lesser, 233; of tibia, 281  
 Tuberosity, cuboid, 293; of ischium, 263; maxillary, 170; of the navicular bone, 294; of palate bone, 179; of radius, 243; of rib, 216

- Tubes, bronchial, 1042; structure of, in lung, 1052
- Tubular membrane of nerves, 43
- Tubular secreting glands, 71
- Tubular substance of kidney, 1062
- Tubuli, dental, 927; of Ferrein, 1064; lactiferi, 1113; seminiferi, 1093; uriniferi, 1062
- Tuft, vascular, in Malpighian bodies of kidney, 1063
- Tunica albuginea, 1092; elastica externa, 53; of eye, 393; of ovary, 1110; Ruyschiana, 884; vaginalis, 1092; vaginalis propria, 1092; reflexa, 1092; vasculosa testis, 1093
- Tunica intima of arteries, 52; media, 52; adventitia, 53
- Tunica vaginalis oculi, 879
- Turbinated bone, superior, 165; inferior, 180; middle, 165; crest, inferior, 178; superior, 178
- Türk, fasciculus of, 718
- Tutamina oculi, 896
- Twelfth nerve, 809; surgical anatomy of, 812
- Tympanic artery, from internal carotid, 577; from internal maxillary, 569; nerve, 803, 911; of facial, 798; plate, 153, 155, 905
- TYMPANUM, 905; arteries of, 910; cavity of, 905; membrane of, 908; mucous membrane of, 910; muscles of, 910; nerves of, 910; ossicula of, 908; veins of, 910
- Tyson's glands, 1086
- Ulna, 238; articulations of, 242; coronoid process of, 238; olecranon process of, 238; development of, 242; fracture of coronoid process of, 246; of olecranon, 505; of shaft, 505; muscles attached to, 242; sigmoid cavities of, 238; styloid process of, 242; surface form of, 242; surgical anatomy of, 245; tubercle of, 238
- Ulnar artery, 613; branches of, 614; peculiarities of, 613; surgical anatomy of, 614; surface marking of, 614; lymphatic glands, 702; nerve, 828; surgical anatomy of, 832; artery recurrent, anterior, 614; posterior, 614; vein, anterior, 680; posterior, 680
- Umbilical arteries in fœtus, 88, 104, 634, 1028; how obliterated, 1031; cord, 88; fissure of liver, 996; region, contents of, 948; vein, 106; vesicle, 81
- Umbilicus, 82, 456
- Unciform bone, 252; process of, 253; process of ethmoid, 165
- Uncinate lobe, 744; fasciculus, 764
- Uncus, 744
- Ungual phalanges, 257
- Unstripped muscle, 39
- Upper extremity, arteries of, 585; bones of, 221; fascia of, 467; ligaments of, 334; lymphatics of, 702; muscles of, 467; nerves of, 820; surgical anatomy of, 503; veins of, 679; surface form of muscles of, 501
- Urachus, 86, 112, 1074
- Ureters, 1069; muscles of, 1078; nerves of, 1071; vessels of, 1070
- URETHRA, development of, 116; male, 1080; bulbous portion of, 1081; caput gallinaginis, 1080; membranous portion, 1081; prostatic portion, 1080; sinus of, 1080; rupture of, course taken by urine, 1139; sinus pularis of, 1080; spongy portion of, 1081; structure of, 1081; surgical anatomy of, 1081; verumontanum, 1080; female, 1101
- Urinary organs, 1060; development of, 110
- Urogenital sinus, 112
- Uterine arteries, 636; plexus, 866; plexus of veins, 691
- UTERUS, 1103; appendages of, 1108; arbor vitæ of, 1106; broad ligaments of, 1105; cavity of, 1105; development of, 111; ganglia of, 866; nerves of, 866; in fœtus, 1107; fundus, body, and cervix of, 1104; ligaments of, 1104; lymphatics of, 708; during menstruation, 1108; in old age, 1108; after parturition, 1108; during pregnancy, 1108; at puberty, 1107; round ligaments of, 1112; shape, positions, dimensions, 1103; structure of, 1106; vessels, 1107; nerves of, 1107
- Uterus masculinus or utriculus hominis, 112, 114, 1080
- Utricle of vestibule, 914
- Uvea, 885
- Uvula of throat, 934; of cerebellum, 770; vesicæ, 1079
- Vagina, 1102; columns of, 1003; lymphatics of, 708; orifice of, 1099
- Vaginal arteries, 636; plexus of nerves, 865; plexus of veins, 691; portal plexus, 1000; process of temporal, 153, 157; processes of sphenoid, 160; synovial membranes, 306
- Vagus nerve, 803; ganglion of root of, 805; of trunk of, 805
- Valentin, ganglion of, 788
- Vallecula Sylvii, 748
- Valley (vallecula) of cerebellum, 768
- Valsalva, sinuses of, 549, 1022, 1024
- Valve of Bauhin, 983; coronary, 1020; of cystic duct, 1003; Eustachian, 1020; of gall-bladder, 1002; of Hasner, 900; ileo-cæcal, 983; of Kerkring, 976; mitral, 1024; of Vieussens, 775
- Valves in right auricle, 1020; semilunar aortic, 1024; pulmonic, 1022; tricuspid, 1021; of lymphatics, 57; of veins, 56
- Valvulæ conniventes, 976
- Vas deferens, 1094; structure of, 1095; aberrans, 1095
- Vasa aberrantia, from brachial artery, 606; afferentia of lymphatic glands, 698; brevia arteries, 625; veins, 693; efferentia of testis, 1094; of lymphatic glands, 698; vasorum of arteries, 53; of veins, 57; intestini tenuis arteries, 626; recta, 1094
- Vascular area of blastodermic membrane, 82, 103
- Vascular system, general anatomy of, 51; changes in, at birth, 1031; peculiarities in fœtus, 1028; capsule of lens, 99
- Vaso-motor nerves, 46



- Vastus externus muscle, 514; internus and crureus, 514
- Vater, corpuscles of, 48 (*footnote*)
- VEINS, *General Anatomy of*, 55; anastomoses of, 666; coats of, 55; development of, 105; muscular tissue of, 56; plexuses of, 666; size, form, &c. 666; structure of, 56; valves of, 56; vessels and nerves of, 57
- VEINS OR VEIN, *Descriptive Anatomy of*, 666; of ale nasi, 669; angular, 669; articular of knee, 689; auditory, 918; auricular anterior, 669; posterior, 670; axillary, 682; azygos, left lower, 685; left upper, 685; right, 685
- basilic, 681; basi-vertebral, 687; of bone, 26; brachial, 682; brachio-cephalic or innominate, 683; bronchial, 686; buccal, 670
- cardiac, 695; anterior, 695; left, 695, right, 695; posterior, 695; cardinal, 107; cava superior, 684; inferior, 691; cephalic, 681; cerebellar, 674; cerebral, 673; cervical, ascending, 672; deep, 672; choroid of brain, 674; circumflex, iliac, 690; superficial, 688; condyloid posterior, 672, 676; of corpora cavernosa, 1087; of corpus spongiosum, 691; of corpus striatum, 674; cystic, 695
- deep, or venæ comites, 667; dental inferior, 670; digital of hand, 680; of diploë, 673; dorsi-spinal, 686; of penis, 691; dorsalis nasi, 669; pedis, 688
- epigastric, deep, 690; superficial, 688; of eyeball, 894; emissary, 678; surgical anatomy of, 679
- facial, 669; femoral, 689; frontal, 668 of Galen, 674; gastric, 694; gastro-epiploic, 693; gluteal, 690
- hemorrhoidal, 690; of head, 667; hepatic, 693
- iliac, common, 691; external, 690; internal, 690; ilio-lumbar, 691; inferior cava, 691; innominate, 683; intercostal, superior, 684; interlobular, of kidney, 1067; of liver, 1000; intralobular of liver, 1000; interosseous of forearm, 682
- jugular anterior, 671; external, 670; external posterior, 671, internal, 671
- of kidney, 1067
- labial inferior, 669; superior, 669; laryngeal, 684; lateral sacral, 691; lingual, 672; of liver, 998; longitudinal inferior, 676; lumbar, 692; ascending, 692
- mammary internal, 684; masseteric, 669; mastoid, 670; maxillary internal, 670; median cutaneous, 681; basilic, 681; cephalic, 681; medullary-spinal, 687; meningeal, 670; meningo-rachidian, 686; mesenteric inferior, 693; superior, 693
- nasal, 668
- oblique cardiac, 696; obturator, 690; occipital, 670; œsophageal, 685; ophthalmic, 677; inferior, 677; ovarian, 692
- palatine, inferior, 669; palmar, deep, 682; palpebral, inferior, 669, superior, 669; pancreatic, 693; pancreatico-duodenal, 693; parotid, 669; peroneal, 689; pharyngeal, 671; phrenic, 693; plantar
- VEINS OR VEIN (*continued*)
- external, 689; internal, 689; popliteal, 689; portal, 666, 695, 1000; profunda femoris, 690; pterygoid plexus, 670; pudic external, 688; internal, 690; pulmonary, 667
- radial, 681; ranine, 669, 672; renal, 693, 1067
- sacral, middle, 691; lateral, 691; salvatella, 680; saphenous external, or short, 689; internal, or long, 688, 1128; sciatic, 690; spermatic, 692; spheno-palatine, 672; spinal, 686; splenic, 693; stylo-mastoid, 670; subclavian, 682; sublobular, 998, 1000; submaxillary, 669; submental, 669; superficial, 666; supra-orbital, 668; supra-renal, 693; supra-scapular, 671; sural, 689; systemic, 667
- temporal, 669; middle, 669; temporo-maxillary, 670; thyroid inferior, 684; middle, 672; superior, 672; tibial anterior, 689; posterior, 689; transverse cervical, 671; facial, 669; Trolard, great anastomotic of, 674
- ulnar anterior, 680; common, 681; deep, 682; posterior, 680; umbilical, 1029
- vaginal of liver, 1000; vasa brevia, 693; vertebral, 672; Vidian, 672
- VEINS, plexuses of, ovarian, 692, 1112; pampiniform, 692, 1091, 1112; pharyngeal, 672; pterygoid, 670; spermatic, 692, 1091; uterine, 691; vaginal, 691; vesico-prostatic, 690
- Velum pendulum palati, 934; interpositum, 758
- Vena cava, superior, 684; inferior, 691; peculiarities of, 692; fetal, 107
- Venæ basic vertebrae, 121; comites, 667; hepaticæ revehentes, 106; advehentes, 106; salvatella, 680; Thebesii, or minima cordis, 696, 1020; vorticosæ, 884; interlobulares of kidney, 1067; rectæ of kidney, 1067
- Venesection, 681
- Venter of ilium, 262; of scapula, 225
- Ventricle of Arantius, 730, 774
- Ventricles of brain, third, 759; fourth, 774; lining membrane of, 776; fifth, 757; lateral, 752; of cerebellum, 774; of corpus callosum, 751; of heart, left, 1024, right, 1020; of larynx, 1037
- Vermicular motion, 40
- Vermiform process of cerebellum, inferior, 770, superior, 769
- Vernix caseosa, 100
- Vertebra prominens, 125; development of, 131
- Vertebrae, 120; cervical, 121; development of, 129; dorsal, 125; general characters, 120; ligaments of, 311; lumbar, 127; sacral, 131; structure of, 129
- Vertebral aponeurosis, 432; artery, 591; column, 137; surface form of, 139; articulation of, 311; ossification of, 129; ligaments, 311; region, muscles of, anterior, 423; lateral, 424; vein, 684
- Vertex of skull, 189
- Vertical plate of palate bone, 178
- Verumontanum, 1080
- Vesicle artery, inferior, 635; middle, 635; superior, 635; plexus of nerves, 865

- Vesicle, auditory, 99; cerebral, 93; germinal, 73; ocular, 97; of Purkinje, 73; umbilical, 81
- Vesicles, Graafian, 1110
- Vesico-prostatic plexus of veins, 690
- Vesico-uterine ligaments, 1104
- Vesicula prostatica, 1080
- Vesiculæ seminales, 1095; vessels and nerves of, 1096; surgical anatomy of, 1097
- Vesicular nervous matter, 41; column of anterior cornu of spine, 722
- Vestibular artery, 918; nerve, 802, 918
- Vestibule of ear, 911; of nose, 877; aqueduct of, 156, 912
- Vestigial fold of pericardium, 684
- Vibrissæ, 874
- Vidian artery, 571; canal, 161; nerve, 789
- Vieussens, valve of, 772
- Villi, 977
- Viscera, position of, in abdominal regions, 947; pelvic, position of, at outlet of pelvis, 1142
- Visceral arches (fœtal), 92
- Vitelline membrane, 73; spheres, 74; circulation, 101
- Vitellus, 73
- Vitreous humour of the eye, 892; table of the skull, 119
- Vocal cords, inferior or true, 1037; superior or false, 1037
- Voice, organs of, 1032
- Voluntary muscles, 36
- Vomer, 181; alæ of, 181; articulations of, 182; development of, 182
- Vortex of heart, 1026
- Vulva, 1099; development of, 116
- Wagner, tactile corpuscles of, 48
- Watney on the structure of villi, 978; of thymus, 1059
- Weight of organs. *See* Individual Organs
- Wharton's duct, 937
- White fibrous tissue, 15
- White substance of cord, 718; nervous, 41; of Schwann, 42
- Willis, circle of, 583, 594
- Winslow, foramen of, 958, 963; ligament of, 364
- Wisdom tooth, 925
- Wolffian body, 111
- Womb. *See* Uterus
- Wormian bones, 167
- Wrisberg, cartilages of, 1034; ganglion of, 862; nerve of, 826
- Wrist-joint, 350; surface form of, 257, 352; surgical anatomy of, 352
- Wry-neck, 409
- Xiphoid appendix, 213
- Y-ligament, 359
- Y-shaped centre of acetabulum, 266
- Yellow elastic fibrous tissue, 16; cartilage, 24
- Yellow spot of retina, 887
- Yolk, 73; cleavage of, 74
- Yolk sac, 81
- Zinn, ligament of, 393
- Zona, arcuata, 916; fasciculata, 1072; glomerulosa, 1072; reticularis, 1072; vasculosa, 1111; pellucida, 73; radiata, 73
- Zygoma, 151; roots of, 152; tubercle of, 152
- Zygomatic arch, 197; fossæ, 197; lymphatic glands, 699; process of malar, 176
- Zygomaticus, major muscle, 397, minor, 397















