

REPRINTED FROM

ANNALS

SURGERY

ALMONTHLY JOURNAL OF MEDICAL SCIENCE AND PRACTICE

EDITED BY

V. S. PILCHER, A.M., M.D.

J. WILLIAM WHITE, M.D.

FREDERICK TREVES, F.R.C.S.

WILLIAM MACEWEN, M.D.

TABLE OF CONTENTS

ORIGINAL MEMOIRS	Notes on the Anatomy of the Prostate Gland, by J. H. Thompson, M.D.
I. A. Pilon's Case of Hemorrhoids, by J. H. Thompson, M.D.	The Treatment of the Hemorrhoids of the Prostate Gland, by J. H. Thompson, M.D.
II. A. Pilon's Case of Hemorrhoids, by J. H. Thompson, M.D.	The Treatment of the Hemorrhoids of the Prostate Gland, by J. H. Thompson, M.D.
III. A. Pilon's Case of Hemorrhoids, by J. H. Thompson, M.D.	The Treatment of the Hemorrhoids of the Prostate Gland, by J. H. Thompson, M.D.
IV. A. Pilon's Case of Hemorrhoids, by J. H. Thompson, M.D.	The Treatment of the Hemorrhoids of the Prostate Gland, by J. H. Thompson, M.D.
V. A. Pilon's Case of Hemorrhoids, by J. H. Thompson, M.D.	The Treatment of the Hemorrhoids of the Prostate Gland, by J. H. Thompson, M.D.
VI. A. Pilon's Case of Hemorrhoids, by J. H. Thompson, M.D.	The Treatment of the Hemorrhoids of the Prostate Gland, by J. H. Thompson, M.D.
VII. A. Pilon's Case of Hemorrhoids, by J. H. Thompson, M.D.	The Treatment of the Hemorrhoids of the Prostate Gland, by J. H. Thompson, M.D.
VIII. A. Pilon's Case of Hemorrhoids, by J. H. Thompson, M.D.	The Treatment of the Hemorrhoids of the Prostate Gland, by J. H. Thompson, M.D.
IX. A. Pilon's Case of Hemorrhoids, by J. H. Thompson, M.D.	The Treatment of the Hemorrhoids of the Prostate Gland, by J. H. Thompson, M.D.
X. A. Pilon's Case of Hemorrhoids, by J. H. Thompson, M.D.	The Treatment of the Hemorrhoids of the Prostate Gland, by J. H. Thompson, M.D.
XI. A. Pilon's Case of Hemorrhoids, by J. H. Thompson, M.D.	The Treatment of the Hemorrhoids of the Prostate Gland, by J. H. Thompson, M.D.
XII. A. Pilon's Case of Hemorrhoids, by J. H. Thompson, M.D.	The Treatment of the Hemorrhoids of the Prostate Gland, by J. H. Thompson, M.D.
XIII. A. Pilon's Case of Hemorrhoids, by J. H. Thompson, M.D.	The Treatment of the Hemorrhoids of the Prostate Gland, by J. H. Thompson, M.D.
XIV. A. Pilon's Case of Hemorrhoids, by J. H. Thompson, M.D.	The Treatment of the Hemorrhoids of the Prostate Gland, by J. H. Thompson, M.D.
XV. A. Pilon's Case of Hemorrhoids, by J. H. Thompson, M.D.	The Treatment of the Hemorrhoids of the Prostate Gland, by J. H. Thompson, M.D.
XVI. A. Pilon's Case of Hemorrhoids, by J. H. Thompson, M.D.	The Treatment of the Hemorrhoids of the Prostate Gland, by J. H. Thompson, M.D.
XVII. A. Pilon's Case of Hemorrhoids, by J. H. Thompson, M.D.	The Treatment of the Hemorrhoids of the Prostate Gland, by J. H. Thompson, M.D.
XVIII. A. Pilon's Case of Hemorrhoids, by J. H. Thompson, M.D.	The Treatment of the Hemorrhoids of the Prostate Gland, by J. H. Thompson, M.D.
XIX. A. Pilon's Case of Hemorrhoids, by J. H. Thompson, M.D.	The Treatment of the Hemorrhoids of the Prostate Gland, by J. H. Thompson, M.D.
XX. A. Pilon's Case of Hemorrhoids, by J. H. Thompson, M.D.	The Treatment of the Hemorrhoids of the Prostate Gland, by J. H. Thompson, M.D.
XXI. A. Pilon's Case of Hemorrhoids, by J. H. Thompson, M.D.	The Treatment of the Hemorrhoids of the Prostate Gland, by J. H. Thompson, M.D.
XXII. A. Pilon's Case of Hemorrhoids, by J. H. Thompson, M.D.	The Treatment of the Hemorrhoids of the Prostate Gland, by J. H. Thompson, M.D.
XXIII. A. Pilon's Case of Hemorrhoids, by J. H. Thompson, M.D.	The Treatment of the Hemorrhoids of the Prostate Gland, by J. H. Thompson, M.D.
XXIV. A. Pilon's Case of Hemorrhoids, by J. H. Thompson, M.D.	The Treatment of the Hemorrhoids of the Prostate Gland, by J. H. Thompson, M.D.
XXV. A. Pilon's Case of Hemorrhoids, by J. H. Thompson, M.D.	The Treatment of the Hemorrhoids of the Prostate Gland, by J. H. Thompson, M.D.
XXVI. A. Pilon's Case of Hemorrhoids, by J. H. Thompson, M.D.	The Treatment of the Hemorrhoids of the Prostate Gland, by J. H. Thompson, M.D.
XXVII. A. Pilon's Case of Hemorrhoids, by J. H. Thompson, M.D.	The Treatment of the Hemorrhoids of the Prostate Gland, by J. H. Thompson, M.D.
XXVIII. A. Pilon's Case of Hemorrhoids, by J. H. Thompson, M.D.	The Treatment of the Hemorrhoids of the Prostate Gland, by J. H. Thompson, M.D.
XXIX. A. Pilon's Case of Hemorrhoids, by J. H. Thompson, M.D.	The Treatment of the Hemorrhoids of the Prostate Gland, by J. H. Thompson, M.D.
XXX. A. Pilon's Case of Hemorrhoids, by J. H. Thompson, M.D.	The Treatment of the Hemorrhoids of the Prostate Gland, by J. H. Thompson, M.D.

KELLY (H.A.)

APRIL, 1898

CYSTOSCOPY AND CATHETERIZATION OF THE URETERS IN THE MALE.

By HOWARD A. KELLY, M.D.,
 OF BALTIMORE, MD.,
 Professor of Gynecology, Johns Hopkins University.

LIBRARY
 SURGEON GENERAL'S OFFICE
 DEC. 30. 1901
 699.

CYSTOSCOPY AND CATHETERIZATION OF THE
URETERS IN THE MALE.

By HOWARD A. KELLY, M.D.,

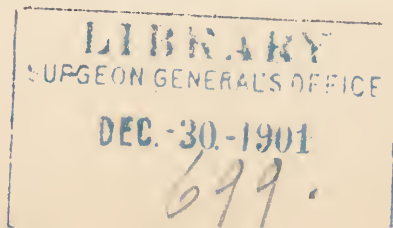
OF BALTIMORE, MD.,

PROFESSOR OF GYNÆCOLOGY, JOHNS HOPKINS UNIVERSITY.

As previously stated in a brief preliminary note, published in the ANNALS OF SURGERY, January, 1898, I have insisted from the very first, when I began my work of inspecting the female bladder and catheterizing the ureters through an open speculum, that there was no reason why the same methods should not be applied, with few changes and slightly increased difficulties, to the male sex. Although I have repeatedly dwelt upon this in conversations with friends and during my cystoscopic demonstrations in women, I have not as yet been able to induce any one to take up the matter and to thoroughly investigate it.

Upon the 18th of November, 1893, I had a speculum made by Messrs. Arnold & Sons, of this city, eight millimetres in diameter, eighteen centimetres long, with a diminutive handle, like those made for my earliest female cystoscopes. I have never had a chance to use this speculum until recently, when opportunities have been afforded me in the genito-urinary clinic in the Johns Hopkins Hospital, under the care of Dr. Hugh H. Young, and at St. Luke's Hospital, New York, through the courtesy of Dr. L. B. Bangs and Robert Abbe. I have been ably assisted throughout in my studies and demonstrations by Dr. Otto G. Ramsay, resident gynæcologist in the Johns Hopkins Hospital.

It was at once demonstrated that the first speculum was longer than necessary, and that its calibre might even be made larger without the risk of injuring the average urethra.



The cystoscope I now use consists of an open cylindrical tube, eight millimetres in diameter, fifteen and a half centimetres long, with a funnel-shaped opening, twenty millimetres long, twenty-seven millimetres in diameter at its outer orifice, blackened on the inside and on the rim to avoid the reflection of the light. A stout handle, eleven centimetres long and twenty-five by twelve millimetres thick, is attached to the funnel, and affords a good grasp to the hand, enabling it to control the speculum perfectly. Other specula, a little larger than this, eight and a half and nine millimetres in diameter, are useful in cases with wider urethræ.

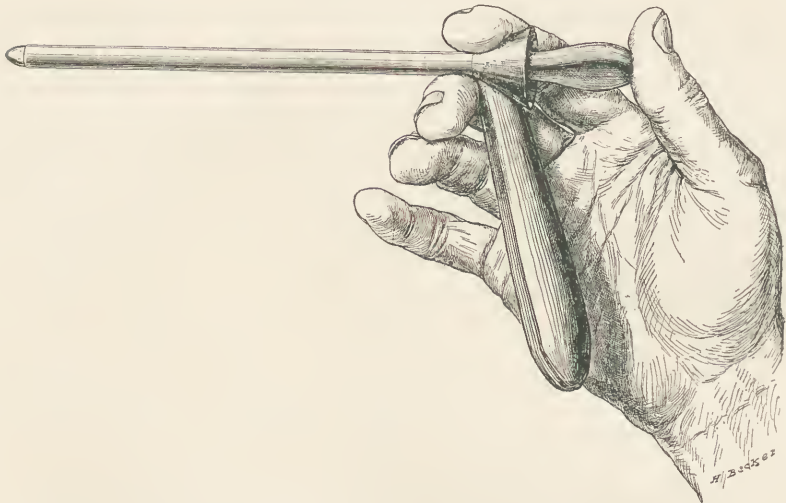


FIG. 1.—Showing male cystoscope reduced to a little less than one-half size; it is held gently poised between index and middle fingers, and during its introduction the thumb keeps the obturator in place.

The end of the cystoscope which enters the bladder is rounded off so that it will not tend to cut the mucous membrane if it happens to be pushed against it; it must be made round enough not to cut, and yet not so round as to present a shoulder on the obturator; the thickness of the edge is about one-fifth or a sixth of a millimetre.

In introducing the cystoscope, it is grasped most conveniently as shown in Fig. 1, with the thumb pressing upon

the obturator to keep the inner end from pushing out of place during the introduction of the instrument into the bladder.

Held in the manner described with the cylinder, at the neck, just back of the handle and the funnel, with the handle directed downward, the cystoscope is poised easily between the last joint of the index-finger and the distal end of the

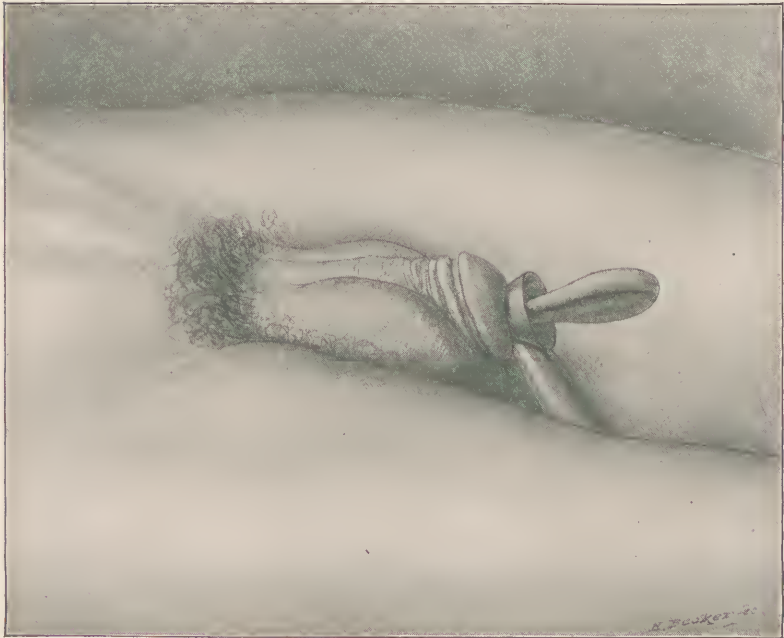

FIG. 2.—The cystoscope introduced with the patient in the dorsal position; note particularly the shortening of the penis and the flattening of the glans, making it possible to use a shorter cystoscope. The obturator is left in place until the patient is in the knee-breast posture and the rectum is inflated with air.

second joint of the middle finger. After cleansing the urethral orifice and injecting a lubricant, the penis is taken in hand, and the end of the speculum introduced into the urethral orifice, and the instrument passed on up towards the triangular ligament, at the same time the organ is drawn up on the cylinder. When the point reaches the triangular liga-

ment the handle is dropped decidedly, as it is pushed on up into the prostatic portion; with a further drop of the handle, making a little decided pressure downward and backward, while pushing the speculum on up, it will often enter the bladder without any resistance. When, however, any resistance is encountered, it is better at once to oil the finger and introduce it into the rectum, and locate the point of the speculum at the neck of the bladder, then lifting up the end a little, while the right hand continues to make pressure, now under intelligent direction, the speculum at once slips in, as recognized by the freedom of the end and the readiness with which it glides on without resistance.

The patient is now aided in rolling over on his side, and then his face, and then in getting up on his hands and knees. This is managed by the assistants, while the surgeon is engaged in retaining the speculum in place.

In taking the knee-breast position it is important to see that he brings his chest close down to the table with the elbows spread out wide apart and the face turned sidewise, at the same time the thighs are vertical or slightly drawn up under the abdomen. If he is allowed to crouch or keeps his back arched, or to take any other of the numerous positions patients try to assume than the one just described, the examination will probably prove unsatisfactory, as the bladder will not distend with air.

I prefer in most cases introducing the speculum with the man in the knee-breast position; he takes the position easily and without the constraint occasioned by the presence of the instrument in his bladder; then the next step is to introduce a small speculum into the rectum to allow it to fill with air; if this is not done, the bladder expands so much that the base of it disappears up in the direction of the sacral hollow out of sight; by distending the rectum with air the base of the bladder drops down into the plane of vision and within easy reach of inspection. If the instrument is introduced with the patient in the knee-breast position, the reversed position of the organs must be borne in mind, the scrotum is lifted up

onto the perineum, while the penis is drawn over the instrument, and the handle is well elevated as it enters the

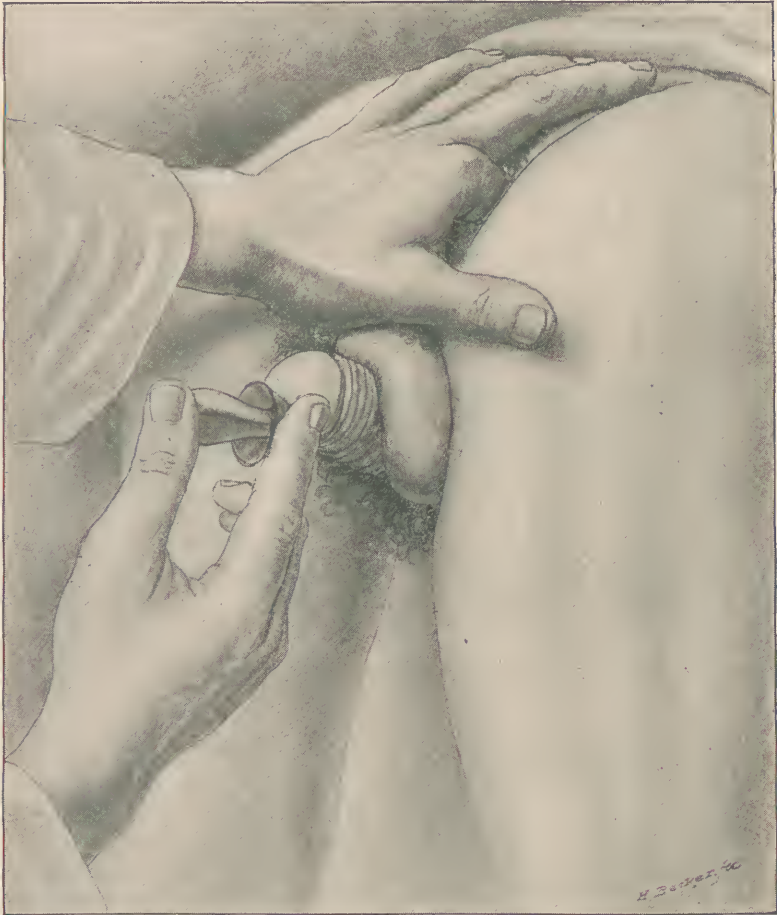

FIG. 3.—When the speculum is inserted with the patient in the knee-chest posture, air is first let into the rectum; then the speculum is introduced as far as the neck of the bladder and guided into the bladder with one finger in the rectum, as shown. The appearance of the penis and scrotum is characteristic.

triangular portion, and still more elevated as it passes through the prostatic portion, and so on into the bladder.

Fig. 3 shows the finger introduced into the rectum with

the patient in the knee-breast position, guiding the end of the speculum into the bladder; Dr. H. H. Young overcomes the resistance at the neck of the bladder by grasping the upper part of the speculum, as shown in Fig. 4, between the thumb and the forefinger, the thumb pressing up in front of the triangular ligament and the forefinger pushing down in the perineum, at the same time the point is pushed onward, the end of the instrument enters the bladder with a little jump, after which its freedom of motion at once tells of the success of the manœuvre.

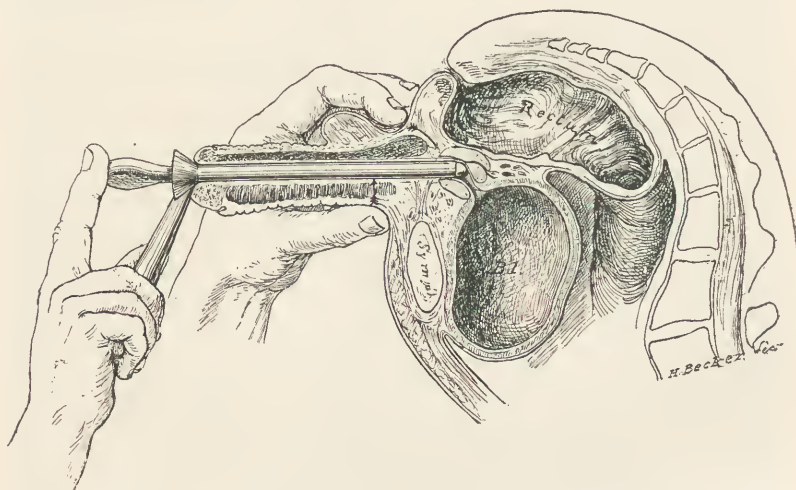


FIG. 4.—Method of conducting the point of the speculum through the prostate and into the bladder suggested by Dr. Young. The rectum is distended with air as it should be, but the bladder is not distended as shown until the speculum is in and the obturator withdrawn.

The obturator is withdrawn as soon as the speculum is in the bladder and the patient in proper position and the rectum inflated; with the withdrawal of the obturator the atmospheric air enters and distends the bladder with an audible suction sound.

The illumination of the interior of the bladder is effected either by direct light, which is the best way, or by a light held close to the sacrum and reflected by a head-mirror of about twenty-five cubic centimetres focal length. If an electric

light, sixteen candle power, it is held close to the sacrum, with a white, enamel-painted, tin reflector back of it, an ordinary head-mirror will direct sufficient light into the interior of the bladder to enable one who is practised in this way of examining patients to see all the details with perfect clearness. One who is not accustomed to this may find it extremely difficult to keep the pencil of the light directed down the tube, as the head-mirror has to be placed at an angle, and the least turning of the head leaves the field in the dark. It is better, therefore, wherever it is available, to use the little mignon electric lamps attached to a steel head-band, with a little bull's-eye in front of the lamp and a ratchet providing for an adjustment of the focus.

The handle of the cystoscope is held either above or below firmly in position, and the light adjusted while the inspection of the bladder is begun. If the bladder has been thoroughly emptied of its urine, the examiner will not be embarrassed by a constant escape of urine out of the speculum with every inspiration.

The position of the examiner is with the head a little below the bladder, looking in a direction slightly upward; if the rectum is not properly distended with air, the bladder will distend so much that he will find it necessary to get his head almost under the patient's pelvis in order to see the base of the bladder.

With satisfactory conditions it will depend upon the amount of elevation of the handle of the cystoscope whether the first part of the bladder, which is brought into view, is the base or the posterior wall. If the posterior wall is seen, it appears as a whitish background, divided up by blood-vessels from a millimetre in diameter down to capillaries spreading out over its surface in the form of a tree, or like rivers dividing up into creeks and rivulets. I have recognized in the male, on the posterior wall, in the right and left hemispheres, two large branching vessels coming from the middle vesical artery, which appear to be quite constant anatomical features in the female. By dropping the handle a

little the base of the bladder comes into view, often considerably foreshortened, so that the area seen at one time is sometimes several centimetres in length, and is never limited to the short area covered by the end of the speculum. By elevating and depressing the handle, and directing it to the right and left in an orderly manner, a continuous impression is made upon the visual sense, so that the examiner is not puzzled by the small area seen at one time, but really sees and retains a comprehensive view of the entire vesical interior.

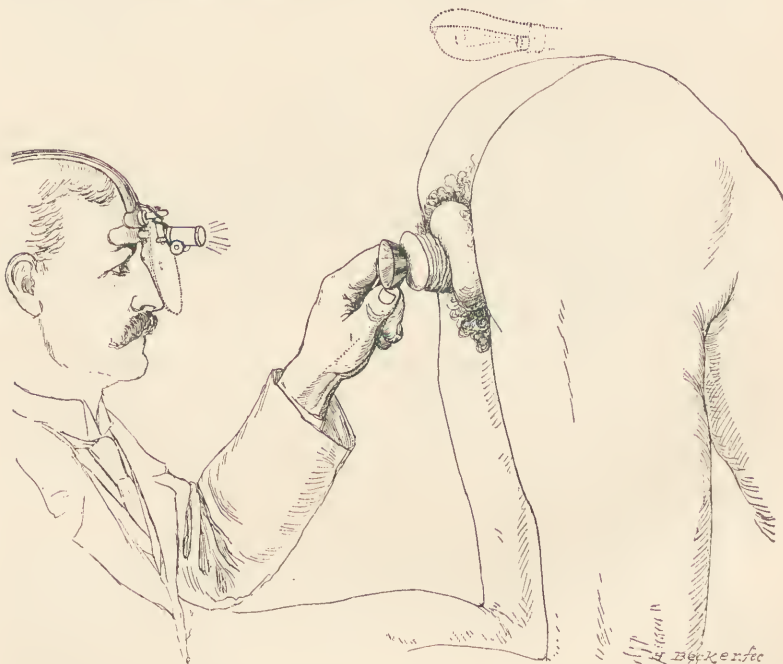

FIG. 5.—The bladder is now inspected through the long open cystoscope, using for illumination either a reflected electric light (shown in dotted outline), or better, a direct electric light with a mignon lamp, a reflector, and a condensing lens.

The trigonum presents a different appearance from the rest of the bladder by its increased injection; it is readily found by withdrawing the speculum until the internal urethral orifice begins to close over the end, and then pushing it in about a half centimetre, and turning the instrument from side to side.

The ureteral orifices will be found at either end of the trigonum by turning the speculum about thirty degrees to the right or left, and looking for the slight eminence on which the orifice is found or for the little slit or mark in the vesical mucosa, surrounded by a little, pale area which signalizes the location of the opening. By pressing with the upper border of the speculum on the mucosa in front of the orifice the orifice itself is brought into a plane at a slight angle with the plane of vision, and therefore more easily seen. A flexible renal catheter, fifty centimetres long, armed with a stylet, is now carried up the cystoscope, and its point engaged in the ureteral opening, then the end of the stylet is firmly grasped by the assistant and the catheter is stripped off from the stylet up the ureter and so on into the pelvis of the kidney. If the catheter is now left in place after a few minutes the urine will begin to flow.

The following are the important requisites for cystoscopy in the male bladder briefly recapitulated:

If the bladder is free from disease and thoroughly emptied beforehand urine may be collected from the opposite side in the bladder while one side is being drained by the renal catheter.

Some degree of persistence is necessary in order to acquire facility in manipulating the instruments and illuminating the field; the difficulties, however, are not so great as those to be overcome in learning to use the Nitze or Casper cystoscopes.

It will be best while acquiring this familiarity with the method of examination to put the first patients examined under anaesthesia.

The rectum should be thoroughly emptied by an enema, and the expansion will be better if the patient has not taken a full meal recently.

The bladder should be emptied and the glans cleansed and a lubricant injected into the urethra.

The patient is then put in the knee-breast position with vertical or slightly flexed thighs and chest close to table.

A speculum is then introduced into the rectum letting in air.

The vesical speculum is then taken up and introduced into the urethra, into the prostatic portion, and then guided back into the bladder with a finger inserted into the rectum.

The obturator is withdrawn and air enters the bladder audibly, expanding it.

The head-light is adjusted so as to reflect its beams into the interior of the bladder in a line closely coinciding with the plane of vision.

The bladder is then inspected in an orderly manner by turning the speculum from side to side and up and down until every accessible portion has been seen.

The ureteral orifices are found by turning the speculum from twenty-five to thirty degrees to the right or to the left, and recognizing their position either by the slight eminence in the vesical mucosa or by the characteristic appearance of the slit and the immediately adjacent area of the vesical mucosa.

I have devised a little mirror on a long flat handle, accommodating itself to the side of the speculum, for the purpose of bringing into view the vertex of the bladder, as this cannot be seen in the male as it can in a female, by an extreme elevation of the speculum. When the abdominal wall is lax a considerably larger portion of the vertex is brought into view by pushing it up with the hand.

Out of several examinations made at the Johns Hopkins Hospital, in the presence of Drs. J. Bloodgood, O. Ramsay, H. W. Cushing, H. H. Young, G. B. Miller, B. M. Bishop, W. M. Dabney, and others, the first one was in the case of an elderly man with a persistent hæmaturia of undetermined origin. We had examined his bladder first with the Casper cystoscope, and saw a little cloud of blood rising from the base, where there was a red villous mass. The urine clouded up quickly, and the affection appeared to be one of vesical papilloma. Upon introducing my speculum, however, in the manner described, it was at once evident that the base

of the bladder was covered with a layer of blood-clots, and on wiping these off, it was seen to be free from disease. The orifice of the left ureter was seen, and a metal catheter introduced a short distance, and a few drops of bloody urine collected, demonstrating the source of a hæmaturia.

The next patient was a young man, a sexual neurasthenic; the cystoscope was readily introduced, and the healthy bladder inspected by a number of those present. The day following the examination he declared himself entirely cured of his ailment, and left the hospital.

The next patient examined had a small oval ulcer in the trigonal portion of the bladder with a whitish base and sharply defined edges. This was demonstrated as clearly as if it had been on the outside of the body; it was also accessible to touch, to applications, and to the curette.

None of these patients were examined under anæsthesia. I owe the first case I was able to examine under an anæsthesia to the courtesy of Dr. L. Bolton Bangs, consulting surgeon at St. Luke's Hospital, New York City; I am also indebted to Dr. Robert Abbe for the kind interest he showed in giving me his clinic hour at St. Luke's Hospital, February 4, 1898.

The patient was a young man, who had been suitably prepared, and was put under anæsthesia in the presence of Drs. Robert F. Weir, Clement Cleveland, Willy Meyer, F. Tilden Brown, Robert A. Murray, Farquhar B. Curtis, Keyes, and others visiting the clinic, in addition to Drs. Bangs and Abbe.

The patient was put in the knee-breast position, the rectum dilated, and the cystoscope introduced as described into the bladder, and the obturator withdrawn. The source of illumination was an electric mignon lamp supplied by the house current reduced by a Vetter controller.

The light was good and the base of the bladder at once came clearly into view; the posterior wall was seen by elevating the handle a little, then, by turning it to the right and to the left, the left and the right lateral walls were clearly seen. I then withdrew the speculum until the internal urethral

orifice began to close over it, and then pushed it in a little, turned it about thirty degrees to the left and dropped the handle, when the right ureteral orifice came clearly into view, as clearly as I have ever seen it in a woman.

Dr. Willy Meyer looked through the cystoscope and agreed it could not have been seen clearer or more unmistakably if it had been on the surface of the body.

Dr. Ramsay then handed me one of my renal catheters, fifty centimetres long and two millimetres in diameter, armed with a stylet, and this was guided, after two attempts, up into the ureteral orifice, and easily stripped of the stylet, into the ureter, ascending up to the pelvis of the kidney. Dr. Abbe now looked through the cystoscope and saw the catheter entering the bladder wall.

The patient was then put to bed with the catheter in position, and before leaving the hospital I had the satisfaction of knowing that half a test-tube full of slightly cloudy urine had been collected.

The use of straight tubes inspecting a limited portion of bladder, with the patient in the dorsal position, dates as far back, as Dr. Weir has pointed out to me, as the work of Desormeaux, published in 1865; in this respect this method of inspection stands in precisely the same relation to the examination of the male bladder as does Simon's work in the inspection of the female bladder, to my own work in that field. The procedure from being one of a very limited utility has been elevated into an important method by the postural atmospheric distention of the bladder, one which bids fair to largely supplant the electro-cystoscopic methods of Nitze, both in the fields of diagnosis and treatment.

The avenue opened up by the straight free calibre of the speculum affords a facility for treatments of all kinds in the way of applications, electro-cauterization, curettages, the snaring of polyps, and bits of tumors, which is unparalleled.

