



B4d

UNIVERSITY COLLEGE, BRISTOL.

Medical Library.


December 23rd 1893

Store 371701

SHELF


D.A.

J. FAWN & SON
QUEEN'S ROAD
BRISTOL.





WILSON'S
ANATOMIST'S VADE MECUM



WILSON'S
ANATOMIST'S VADE MECUM

A SYSTEM OF
HUMAN ANATOMY.

ELEVENTH EDITION

EDITED BY

HENRY EDWARD CLARK

FELLOW OF THE FACULTY OF PHYSICIANS AND SURGEONS OF GLASGOW
MEMBER OF THE ROYAL COLLEGE OF SURGEONS OF ENGLAND
PROFESSOR OF ANATOMY IN ST. MUNGO'S COLLEGE, GLASGOW



LONDON
J. & A. CHURCHILL
11, NEW BURLINGTON STREET

1892

UNIVERSITY
OF BRISTOL
MEDICINE

PREFACE

TO THE

ELEVENTH EDITION.

THE title of VADE MECUM, given to this work by the author, Sir Erasmus Wilson, indicated an intention that it should be a portable manual, containing all that an ordinary student required to know of human anatomy, but not discussing disputed points, or attempting to give everything that could be said on each anatomical detail. The editor of the present edition has endeavoured to act up to this intention, and consequently has neither increased the size of the pages, nor added materially to their number.

He cannot claim for this edition that it contains any novel features, or is distinguished from its predecessors by startling changes; but he has left no part untouched by revision, and has endeavoured to make the work fairly represent the present state of anatomical knowledge.

The description of the central nervous system has undergone more change than any other part of the book; but, while giving the results of the latest investigations, no change has been made for the mere sake of change, and the rage for new names, which seems at present to afflict anatomists, has been kept (it is hoped), within reasonable limits.

Finding it impossible in the space at his disposal to give a complete description of the development of the embryo, the editor has thought it best to omit altogether the paragraphs

which in the last edition gave some particulars of the development of certain organs, as these presupposed a knowledge of the earlier stages of embryonic evolution.

The Vade Mecum in its earliest editions was distinguished by the number and excellence of its illustrations, and was, indeed, a pioneer work in this respect. Now, when woodcuts are so numerous in anatomical works that they not unfrequently outnumber the pages, such a reputation is not easy to maintain. Very numerous additions have, however, been made in this department; they have been drawn from various British and foreign sources, and their origin is in every instance acknowledged in the List of Illustrations at the beginning of the work. It is interesting to notice that, while the woodcuts in the first edition (1840) numbered 150, they have now reached a total of nearly 500.

24 INDIA STREET, GLASGOW,

August 1892.

CONTENTS.

PART I.

HISTOLOGY.

	PAGE		PAGE
Definition of histology	1	Muscle	27
Cells and protoplasm	1	Striated	28
Blood	4	Non-striated	31
Lymph and chyle	6	Heart muscle	31
Epithelium	7	Nerve tissue	32
Connective tissue	11	Nerve fibres	33
Areolar tissue	11	Nerve cells	35
Adipose tissue	13	Ganglia	37
Fibrous tissue	13	Nerve terminations	39
Yellow or elastic tissue	14	Sympathetic nerve	41
Mucous tissue	15	Blood-vessels	42
Reticular tissue	16	Arteries	43
Simple membrane	16	Capillaries	47
Pigment	16	Veins	49
Cartilage	17	Lymphatics	51
Hyaline cartilage	17	Serous membranes	56
Elastic cartilage	18	Synovial membranes	57
Fibro-cartilage	19	Mucous membrane	59
Bone	20	Secreting glands	60
Structure of bone	20	Skin and its appendages	63
Periosteum	21	Derma	63
Minute structure of bone	21	Epidermis	64
Medulla	23	Nails	68
Development of bone	24	Hairs	68
Intramembranous	24	Sebaceous glands	70
Intracartilaginous	25	Sudoriferous glands	71

PART II.

OSTEOLOGY.

Number of bones in the skeleton	73	Lumbar vertebræ	80
General characters of bones	73	General considerations	80
Vertebral column	74	Development	81
Cervical vertebræ	75	Attachment of muscles	83
Dorsal vertebræ	78	Sacrum	84

	PAGE		PAGE
Coccyx	86	Ribs	133
Bones of the cranium	87	Costal cartilages	135
Occipital bone	87	Thorax as a whole	136
Parietal bone	90	Upper extremity	136
Frontal bone	92	Clavicle	136
Temporal bone	94	Scapula	137
Sphenoid bone	100	Humerus	140
Ethmoid bone	105	Ulna	143
Bones of the face	107	Radius	145
Nasal bone	107	Carpus	146
Superior maxillary	107	Metacarpus	151
Lachrymal bone	111	Phalanges	153
Malar bone	112	Pelvis and lower extremity	153
Palate bone	113	Os innominatum	153
Inferior turbinated	115	Ilium	154
Vomer	116	Ischium	155
Inferior maxillary	117	Pubes	156
Sutures	120	Pelvis	158
Regions of the skull	121	Femur	160
Base of the skull	123	Patella	163
Face	127	Tibia	164
Orbits	127	Fibula	166
Spheno-maxillary fossa	128	Tarsus	167
Nasal fossæ	129	Metatarsal bones	172
Os hyoides	131	Phalanges	173
Thorax	131	Sesamoid bones	174
Sternum	131		

PART III.

ARTHROLOGY.

Forms of articulation	175	Articulations of pelvis	193
Structures forming joints	175	UPPER EXTREMITY	197
Bursæ mucosæ	177	Sterno-clavicular	197
Table of articulations	178	Scapulo-clavicular	199
Synarthrosis	178	Shoulder-joint	201
Amphiarthrosis	179	Elbow-joint	202
Diarthrosis	179	Radio-ulnar articulation	204
Movements of joints	180	Wrist-joint	205
LIGAMENTS OF THE TRUNK	181	Carpal articulations	207
Articulation of vertebral column	182	Carpo-metacarpal	208
Atlas with occipital bone	185	Metacarpo-phalangeal	209
Axis with occipital bone	186	Articulation of phalanges	210
Atlas and axis	187	LOWER EXTREMITY	210
Temporo-maxillary articulation	188	Hip-joint	210
Ribs with vertebræ	190	Knee-joint	213
Costal cartilages, with sternum, and each other	192	Tibio-fibular articulation	218
Ribs with costal cartilages	193	Ankle-joint	220
Articulations of sternum	193	Articulation of tarsus	222
Vertebral column with pelvis	193	Tarso-metatarsal joints	225
		Metatarso-phalangeal	225
		Articulation of phalanges	226

PART IV.

MYOLOGY.

	PAGE		PAGE
General arrangement of muscles	227	Muscles of the thorax . . .	281
Nomenclature	227	Muscles of the abdomen . . .	284
Fascia	228	Fasciæ of the abdomen . . .	286
Areolo-fibrous	228	Anatomy of inguinal hernia . .	296
Deep	228	Muscles of posterior wall of	
HEAD AND FACE	229	abdomen, and diaphragm. . .	298
Cranial group	229	Muscles of male perineum . . .	302
Orbital group	231	Perineal fasciæ	303
Auricular group	233	Muscles of female perineum . .	308
Ocular group	234	PELVIC FASCIA	311
Nasal group	238	UPPER EXTREMITY	315
Superior labial group	240	Fasciæ of the upper extremity .	315
Inferior labial group	242	Anterior thoracic region . . .	317
Maxillary group	243	Lateral thoracic region . . .	319
MUSCLES AND FASCIAE OF THE		Anterior scapular region . . .	320
NECK	247	Posterior scapular region . . .	320
Superficial group	247	Acromial region	323
Regional anatomy of neck . . .	251	Anterior humeral region . . .	324
Depressors of os hyoides and		Posterior humeral region . . .	326
larynx	252	Anterior brachial region . . .	327
Elevators of os hyoides	254	Posterior brachial region . . .	332
Muscles of the tongue	256	Muscles of the hand	338
Muscles of the pharynx	259	LOWER EXTREMITY	343
Muscles of the soft palate . . .	263	Fasciæ of the lower extremity .	343
Prævertebral muscles	266	Femoral hernia	346
MUSCLES AND FASCIAE OF THE		Gluteal region	348
TRUNK	268	Anterior femoral region . . .	352
Muscles of the back	269	Internal femoral region . . .	357
First layer	269	Posterior femoral region . . .	361
Second layer	272	Anterior tibial region	363
Third layer	273	Posterior tibial region	365
Fourth layer	274	Fibular region	370
Fifth layer	277	Foot—Dorsal region	371
Sixth layer	278	Plantar region	372

PART V.

ANGIOLOGY.

ARTERIES	377	Posterior auricular artery . .	388
Aorta	377	Ascending pharyngeal artery . .	388
Table of branches	380	Parotidean arteries	389
Coronary arteries	380	Temporal artery	389
Innominate artery	381	Internal maxillary artery . . .	390
Common carotid arteries	381	Internal carotid artery	393
External carotid artery	383	Ophthalmic artery	394
Table of branches	383	Anterior cerebral artery . . .	397
Superior thyroid artery	383	Middle cerebral artery	397
Lingual artery	385	Subclavian artery	397
Facial artery	386	Table of branches	399
Occipital artery	388	Vertebral artery	399

	PAGE		PAGE
Basilar artery	400	Profunda femoris artery	438
Circle of Willis	402	Popliteal space	440
Internal mammary artery	402	Popliteal artery	441
Inferior thyroid artery	403	Anterior tibial artery	442
Supra-scapular artery	404	Dorsalis pedis artery	444
Transversalis colli artery	404	Posterior tibial artery	445
Superior intercostal artery	405	Peroneal artery	446
Axillary artery	405	Plantar arteries	447
Table of branches	407	Pulmonary artery	449
Brachial artery	409	VEINS	449
Bend of the elbow	410	Veins of the head and neck	450
Radial artery	411	Veins of the diploë	452
Ulnar artery	414	Cerebral and cerebellar veins	453
Thoracic aorta; branches	416	Sinuses of the dura mater	454
Abdominal aorta; branches	418	Ophthalmic veins	458
Phrenic arteries	419	Veins of the neck	458
Cœliac axis	419	Veins of the upper extremity	460
Gastric artery	419	Veins of the lower extremity	462
Hepatic artery	419	Veins of the trunk	463
Splenic artery	422	Brachio-cephalic veins	464
Superior mesenteric artery	422	Superior vena cava	464
Spermatic arteries	424	Iliac veins	464
Inferior mesenteric artery	424	Inferior vena cava	466
Renal arteries	425	Azygos veins	468
Common iliac arteries	427	Vertebral and spinal veins	469
Internal iliac artery	427	Cardiac veins	470
Obturator artery	429	Portal vein	471
Ischiatic artery	430	Pulmonary veins	473
Internal pudic artery	430	LYMPHATICS	474
Ilio-lumbar artery	432	Lymphatics of head and neck	474
Lateral sacral arteries	433	Lymphatics of upper extremity	476
Gluteal artery	433	Lymphatics of lower extremity	477
External iliac artery	434	Lymphatics of the trunk	479
Deep epigastric artery	434	Lymphatics of the viscera	480
Triangle of Hesselbach	435	Lacteals	482
Deep circumflex iliac artery	435	Thoracic duct	482
Femoral artery	435	Ductus lymphaticus dexter	484

PART VI.

NEUROLOGY.

Cerebro-spinal axis	485	Transverse section of crura cerebri	523
Spinal cord	485	Lining of ventricles	524
Medulla oblongata	491	White matter of cerebrum	524
Pons Varolii	496	Arteries of the brain	525
Cerebrum	497	Topography of the brain	528
Base of the brain	497	Membranes of the brain	529
Convolutions and sulci	501	Membranes of the spinal cord	534
Inner surface of hemisphere	503	Cranial nerves	536
Structure of the convolutions	505	Olfactory	536
Interior of cerebrum	506	Optic	537
Cerebellum	516	Motores oculorum	538
Fourth ventricle	519	Pathetici	539
Transverse section of cerebrum	521	Trifacial	539

	PAGE		PAGE
Abducentes	547	Lumbar nerves	581
Facial	548	Sacral nerves	588
Auditory	551	Sympathetic nerves	597
Glosso-pharyngeal	553	Cranial ganglia	597
Pneumogastric	555	Cervical ganglia	602
Spinal accessory	559	Thoracic ganglia	607
Hypoglossal	560	Lumbar ganglia	609
Spinal nerves	562	Pelvic plexuses	610
Cervical plexus	565	Sacral ganglia	610
Brachial plexus	568	Coccygeal gland	611
Dorsal nerves	578		

THE ORGANS OF SENSE.

Organ of smell	611	Organ of hearing	633
Nose	611	External ear	633
Nasal fossæ	613	Tympanum	637
Organ of vision	615	Internal ear	643
Appen.lages of the eye	616	Osseous labyrinth	643
Lachrymal apparatus	620	Vestibule	644
Globe of the eye	621	Semicircular canals	644
Sclerotic and cornea	621	Cochlea	645
Choroid coat	624	Membranous labyrinth	646
Iris and ciliary muscle	625	Vessels and nerves of internal	
Retina	627	ear	651
Refracting media	631	Organ of taste	652
Vessels and nerves of eye	633	Taste-buds	655

PART VII.

SPLANCHNOLOGY.

THORAX	657	Formation of the hard	
Pericardium	658	tissues	718
Heart	659	Eruption	719
Structure of the heart	670	Succession	720
Fœtal heart and fœtal circu-		Pharynx	720
lation	672	Oesophagus	722
Organs of respiration and voice	675	Stomach	723
Larynx	675	Small intestines	727
Trachea	684	Large intestine	735
Thyroid body	685	Liver	740
Lungs	686	Gall bladder	750
Pleuræ	693	Pancreas	751
Mediastinum	693	Spleen	753
Thymus body	695	Supra ^a -renal bodies	756
ABDOMEN	696	Kidneys	758
Peritoneum	697	PELVIS	765
Alimentary canal	703	Bladder	765
Cheeks	703	Prostate gland	769
Soft palate	705	Vesiculæ seminales	770
Tonsils	705	MALE ORGANS OF GENERATION.	771
Glands	706	Penis	771
Salivary glands	707	Urethra	774
Teeth	709	Testicles	778
Structure	712	Testicles in the embryo	783
Development	715	Descent of testicle	784

	PAGE		AGE
FEMALE PELVIS	785	Fallopian tubes	791
Bladder	785	Ovaries	792
Urethra	785	External organs of genera-	
Vagina	786	tion	795
Uterus	787	MAMMARY GLANDS	798

GLOSSARY OF ANATOMICAL TERMS	801
INDEX	822

LIST OF ILLUSTRATIONS.



FIGS.	PAGE
1. Different kinds of cells	<i>Frey</i> 2
2. Intercellular and internuclear networks in cells <i>Klein</i> 2
3. Diagram of karyostenosis	<i>M'Kendrick</i> 3
4. Stages of karyokinesis	<i>Gegenbaur</i> 3
5. Red blood corpuscles	<i>Stirling</i> 5
6. White blood corpuscles	<i>Stirling</i> 5
7. Old squamous epithelial cells <i>Frey</i> 8
8. Prickle cells of rete mucosum <i>Frey</i> 8
9. Columnar epithelium from villus	<i>Kölliker</i> 8
10. Columnar epithelium from small intestine <i>Henle</i> 9
11. Columnar epithelium viewed from the surface of the membrane 9
12. Goblet cells from intestinal villus	<i>Frey, after Schultze</i> 9
13. Spheroidal cells of a sebaceous gland <i>Frey</i> 9
14. Cells of ciliated epithelium of nose 10
15. Ciliated cells with branching processes <i>Klein</i> 10
16. Endothelium	<i>Stirling</i> 11
17. Connective tissue <i>Frey</i> 12
18. Areolar and adipose tissue <i>Mandl</i> 13
19. Fat vesicles from omentum <i>Klein</i> 13
20. White fibrous tissue 14
21. Caudal tendon of rat, showing cells <i>Bruce</i> 14
22. Yellow or elastic tissue	<i>Cardiat</i> 15
23. Anastomosing elastic tissue <i>Gerber</i> 15
24. Fenestrated elastic membrane	<i>Kölliker</i> 16
25. Reticular tissue <i>Frey</i> 16
26. Pigment cells from lamina fusca <i>Frey</i> 17
27. Pigmentary layer of retina	<i>Kölliker</i> 17
28. Branchial cartilage of tadpole	<i>Carpenter</i> 18
29. Elastic fibro-cartilage	<i>Cardiat</i> 18
30. White fibro-cartilage	<i>Cardiat</i> 19
31. Section of head of tibia <i>G. Buchanan</i> 20
32. Section of the body of a vertebra <i>G. Buchanan</i> 21
33. Plan of a section of a long bone <i>G. Buchanan</i> 21
34. Vertical section of tibia, with Haversian canals <i>Mandl</i> 22
35. Minute structure of bone 23
36. Lacunæ of bone <i>Mandl</i> 23
37. Intramembranous ossification	<i>Gegenbaur</i> 24
38. Development of bone from cartilage	<i>Kölliker</i> 25
39. Invasion of cartilage by periosteal osteoblasts <i>Stöhr</i> 25
40. Development of bone from cartilage <i>Müller</i> 26
41. Striated muscular fibre, showing sarcolemma <i>Frey</i> 28

FIGS.		PAGE
42.	Striated muscular fibre, showing discs <i>and</i> fibrillæ	<i>Frey</i> 29
43.	Striated muscle, showing secondary striæ	<i>Sharpey</i> 30
44.	Non-striated muscular fibres	<i>Klein</i> 30
45.	Fibres of heart muscle	<i>Frey</i> 31
46.	Nerve fibres of various kinds	<i>Wagner</i> 32
47.	Medullated nerve fibre	<i>Carpenter</i> 33
48.	Gelatinous nerve fibres, from olfactory nerve	<i>Ecker</i> 35
49.	Multipolar nerve cells from spinal cord of dog-fish	<i>Cardiat</i> 35
50.	Multipolar ganglion cells from brain	<i>Frey</i> 36
51.	Sympathetic ganglion	<i>Frey</i> 37
52.	Ganglionic nerve cells	<i>Arnold and Beale</i> 38
53.	Section of a small nerve	<i>Klein</i> 38
54.	Digital nerve with Pacinian corpuscles	<i>Kölliker</i> 40
55.	Pacinian corpuscle from mesentery of cat	<i>Frey</i> 40
56.	End-bulbs of Krause	<i>Frey</i> 41
57.	Structure of a small artery	<i>Frey</i> 44
58.	Muscular fibres from the middle coat of an artery	<i>Kölliker</i> 45
59.	Fenestrated membrane from middle coat	<i>Kölliker</i> 45
60.	Transverse section of the coats of an artery	<i>Schäfer</i> 46
61.	Endothelial cells lining an artery	<i>Schäfer</i> 46
62.	Minute artery and capillary, showing nuclei in the walls	<i>Kölliker</i> 48
63.	Valves of veins	<i>Sharpey</i> 51
64.	Lymphatic capillaries	<i>Klein</i> 52
65.	Epithelium of serous membrane, showing stomata	<i>Klein</i> 54
66.	View of a lymphatic gland	<i>Kölliker</i> 54
67.	Section of a small lymphatic gland	<i>Frey</i> 55
68.	Medullary part of a lymphatic gland, showing lymph path	<i>Klein</i> 55
69.	Plan of a serous membrane	<i>G. Buchanan</i> 56
70.	Endothelium of peritoneum	<i>Klein</i> 57
71.	Goblet cell from the trachea of a cat.	<i>Klein</i> 60
72.	Diagrams of simple glands 61
73.	Diagrams of compound glands 61
74.	Modes of termination of nerves in salivary glands	<i>Pflüger</i> 62
75.	Vertical section of the skin	<i>Ecker</i> 63
76.	Cells of the epidermis	<i>Schäfer after Ranvier</i> 65
77.	Diagram of the development of epidermis 66
78.	Tactile papillæ	<i>Frey</i> 61
79.	Hairs and their connections	<i>Kölliker</i> 67
80.	Section of a hair follicle	<i>Schäfer after Biesiadecki</i> 69
81.	Sebaceous gland	<i>Frey</i> 79
82.	Sudoriferous gland	<i>Frey</i> 70
83.	A middle cervical vertebra 76
84.	Upper surface of atlas 76
85.	Lateral view of axis 77
86.	Lateral view of a dorsal vertebra 78
87.	Peculiar dorsal vertebræ 79
88.	Lateral view of a lumbar vertebra 80
89.	Posterior and lateral view of spinal column	<i>Quain</i> 82
90.	Anterior surface of sacrum 84
91.	Posterior surface of sacrum 85
92.	Anterior view of coccyx 86
93.	External surface of occipital bone 88
94.	Internal surface of occipital bone 89
95.	External surface of parietal bone 90
96.	Internal surface of parietal bone 91
97.	External surface of frontal bone 92
98.	Internal surface of frontal bone 94

FIGS.		PAGE
99.	Articulation of neighbouring bones with nasal spine of frontal <i>A. M. Alister</i>	94
100.	External surface of temporal bone	95
101.	Section through external auditory meatus	96
102.	Basilar surface of temporal bone <i>H. E. Clark</i>	97
103.	Internal surface of temporal bone	98
104.	Tympanic ring	99
105.	Superior surface of sphenoid bone	101
106.	Antero-inferior view of sphenoid bone	102
107.	Ethmoid bone	105
108.	Nasal bone of left side	107
109.	Lateral view of superior maxillary bone	108
110.	Internal view of superior maxillary bone	109
111.	Right lachrymal bone	111
112.	Right malar bone	112
113.	Right palate bone	113
114.	Perpendicular plate of palate bone	114
115.	Right inferior turbinated bone	115
116.	Vomer	117
117.	Inferior maxilla	118
118.	Front view of skull	122
119.	Cerebral surface of base of skull	124
120.	Basilar surface of base of skull	126
121.	Longitudinal section of nasal fossæ	130
122.	Os hyoides	131
123.	Anterior view of thorax	132
124.	Vertebral extremity of seventh rib	134
125.	First rib of left side	135
126.	Clavicle of right side	137
127.	Anterior surface of scapula	138
128.	Posterior view of scapula	139
129.	Front of humerus	141
130.	Back of humerus	141
131.	Radius and ulna, front view	143
132.	Radius and ulna, back view	144
133.	Grooves on back of radius and ulna	146
134.	Dorsal surface of carpus	148
135.	Bones of carpus of right hand	149
136.	Anterior view of hand	150
137.	Os innominatum of right side	154
138.	Female pelvis	158
139.	Diagram to show inclination of pelvis <i>Holden</i>	159
140.	Anterior aspect of femur	161
141.	Diagram of under surface of condyles of femur <i>Wagstaffe</i>	162
142.	Patella of right side	163
143.	Tibia and fibula, front view	164
144.	Tibia and fibula, back view	165
145.	Dorsal surface of left foot	168
146.	Plantar surface of left foot	170
147.	Anterior ligament of vertebræ, and ligaments of ribs	182
148.	Posterior ligament of vertebral bodies	182
149.	Section of an intervertebral disc <i>Frey</i>	183
150.	Lamina of vertebræ and ligamenta subflava	184
151.	Anterior view of ligaments of atlas, axis, and occipital bone	185
152.	Posterior view of ligaments of atlas, axis, and occipital bone	185
153.	Occipito-axial ligament	186
154.	Transverse and odontoid ligaments	187

FIGS.		PAGE
155.	External view of ligaments of lower jaw	188
156.	Internal view of ligaments of lower jaw	189
157.	Section through temporo-maxillary articulation	189
158.	Vertebra and heads of ribs, showing costo-transverse ligaments	191
159.	Ligaments of spines, laminae, and transverse processes of vertebrae	191
160.	Ligaments of pelvis and hip-joint seen from the front	194
161.	Ligaments of pelvis and hip-joint seen from behind	195
162.	Ligaments of pelvis and hip-joint seen from behind	196
	<i>Bonamy and Beau</i>	
163.	Sterno-clavicular articulation	198
164.	Ligaments of scapula and shoulder-joint	199
165.	Sectional view of shoulder-joint	201
	<i>Allen Thomson</i>	
166.	Ligaments of elbow-joint, inner side	203
167.	Ligaments of elbow-joint, outer side	203
168.	Upper part of ulna, and orbicular ligament	205
169.	Lower end of radius and ulna, with articular surfaces	205
170.	Anterior aspect of wrist-joint	206
	<i>Sappey</i>	
171.	Diagram of synovial cavities of wrist-joint	208
	<i>Allen Thomson</i>	
172.	Lateral and anterior ligaments of fingers	210
	<i>Reeves</i>	
173.	Anterior view of the ligaments of the knee-joint	214
	<i>Sappey</i>	
174.	Posterior view of the ligaments of the knee-joint	215
	<i>Sappey</i>	
175.	Internal view of knee-joint	216
176.	Synovial membrane of knee-joint	217
177.	Posterior view of ankle-joint	219
178.	Ligaments of inner side of ankle and foot	220
	<i>Sappey</i>	
179.	Ligaments of outer side of ankle and foot	221
	<i>Sappey</i>	
180.	Ligaments of sole of foot	223
	<i>Sappey</i>	
181.	Synovial membranes of the tarsal joints	224
	<i>Allen Thomson</i>	
182.	Muscles of the head and face	230
183.	Muscles of the eyeball	235
184.	Orbital contents and capsule of Tenon	237
	Modified from <i>Heule</i>	
185.	Muscles of the nose	239
186.	Pterygoid muscles	246
187.	Deep cervical fascia	248
188.	Muscles of front of neck	250
189.	Styloid muscles and muscles of tongue	255
190.	Extrinsic and intrinsic muscles of tongue	257
	<i>Kölliker</i>	
191.	Dissection of constrictor muscles of pharynx	259
	<i>Heath</i>	
192.	Side view of muscles of pharynx	260
	<i>Heath</i>	
193.	Muscles of soft palate	263
	<i>Heath</i>	
194.	Prævertebral muscles	266
195.	Lateral view of prævertebral muscles	267
196.	First, second, and part of third layer of dorsal muscles	270
197.	Fourth, fifth, and part of sixth layer of dorsal muscles	276
198.	Muscles of occipital region	278
	<i>Heath</i>	
199.	Levatores costarum and intercostal muscles	283
	<i>Allen Thomson</i>	
200.	Muscles of front of trunk	285
201.	Section showing fasciæ of groin	286
	<i>G. Buchanan</i>	
202.	Aponeurosis of external oblique and external abdominal ring	287
	<i>Luschka</i>	
203.	Lateral view of abdominal muscles	290
204.	Transverse section of abdominal walls	292
	<i>Cunningham</i>	
205.	Internal view of abdominal wall in inguinal region	293
	<i>Wood</i>	
206.	Dissection of inguinal canal	294
	<i>Wood</i>	
207.	Common scrotal hernia	296
	<i>J. T. Gray</i>	
208.	Congenital hernia	296
	<i>J. T. Gray</i>	
209.	Infantile hernia	296
	<i>J. T. Gray</i>	

FIGS.		PAGE
266.	Gluteal and ischiatic arterics	<i>Henle</i> 433
267.	Femoral artery and its branches	436
268.	Scheme of the profunda femoris artery	<i>A. M'Alister</i> 439
269.	Popliteal space	<i>Heath</i> 440
270.	Anterior tibial and dorsalis pedis arteries	442
271.	Popliteal and posterior tibial arteries	446
272.	Arteries of sole of foot	447
273.	Superficial veins of the head and neck	<i>Quain</i> 450
274.	Veins of the diploë	<i>Wagstaffe</i> 452
275.	Sinuses of the upper and back part of skull	455
276.	Sinuses of the base of the skull	456
277.	Cavernous sinus, and artery and nerves on its wall	<i>Langer</i> 456
278.	Diagram of the nerves passing through cavernous sinus	<i>Heath</i> 457
279.	Veins of the forearm and bend of the elbow	461
280.	Superficial veins of thigh and inner side of leg	462
281.	External saphena vein and its tributaries	463
282.	Veins of the trunk	<i>Cruveilhier</i> 465
283.	Vertebral and spinal veins	<i>Breschet</i> 469
284.	Portal vein	472
285.	Lymphatic vessels and glands of the head and neck	475
286.	Lymphatic vessels and glands of the upper extremity	476
287.	Lymphatic vessels and glands of the lower extremity	478
288.	Thoracic duct	483
289.	Transverse section of half of spinal cord, showing minute structure	<i>Allen Thomson</i> 487
290.	Diagram of the tracts of the spinal cord	<i>Gowers</i> 489
291.	Transverse section of spinal cord, showing roots of nerves	490
292.	Paths taken by nerve fibres on entering spinal cord	<i>E. A. Schäfer</i> 490
293.	Front view of upper part of cranio-spinal axis	<i>Ecker</i> 492
294.	Medulla and pons from behind	<i>G. Dancee Thane</i> 493
295.	Section of medulla at level of decussation of pyramids	<i>Schwalbe</i> 494
296.	Section of medulla through olivary body	<i>Schwalbe</i> 495
297.	Section across pons at middle of fourth ventricle	<i>Stilling und Schwalbe</i> 496
298.	Base of the brain	<i>Hirschfeld and Leveillé</i> 498
299.	Lateral view of brain of Bush-woman	<i>Marshall</i> 500
300.	Upper surface of brain of Bush-woman	<i>Marshall</i> 500
301.	Inner and under surface of the brain	<i>Hirschfeld and Leveillé</i> 504
302.	Structure of cortex of hemispheres	<i>Meynert</i> 506
303.	Centrum ovale majus	507
304.	Lateral ventricles of the brain	509
305.	Section through hippocampus, showing fascia dentata	<i>Sappey</i> 511
306.	Vertical longitudinal section of the brain	<i>Hirschfeld and Leveillé</i> 512
307.	Third ventricle of the brain	<i>Hirschfeld and Leveillé</i> 515
308.	Upper surface of the cerebellum	<i>Hirschfeld and Leveillé</i> 516
309.	Nuclear masses in white centre of cerebellum	<i>Schwalbe</i> 518
310.	Structure of the cerebellar cortex	<i>Meynert</i> 519
311.	Fourth ventricle of the brain	<i>Hirschfeld and Leveillé</i> 519
312.	Diagrammatic view of floor of fourth ventricle	<i>E. A. Schäfer</i> 520
313.	Nerve nuclei in floor of fourth ventricle	<i>Erb</i> 521
314.	Transverse section of cerebrum	<i>H. E. Clark</i> 522
315.	Transverse section through crura cerebri	<i>Wernicke and Gowers</i> 523
316.	Relations of brain to exterior of skull	<i>Poirier</i> 528
317.	Side view of sinuses and membranes of brain	<i>Hirschfeld and Leveillé</i> 531
318.	Spinal cord and its membranes	<i>Hirschfeld and Leveillé</i> 534
319.	Transverse section of spinal cord and its membranes	<i>Hirschfeld and Leveillé</i> 535

FIGS.		PAGE
320.	Olfactory nerve	537
321.	Dissection of the nerves of the orbit	<i>Hirschfeld and Leveillé</i> 540
322.	Diagram of the fifth nerve and its branches	541
323.	Nerves of the orbit	<i>Arnold</i> 542
324.	Inferior maxillary nerve	<i>Hirschfeld and Leveillé</i> 544
325.	Nerves of the face and scalp	<i>Hirschfeld and Leveillé</i> 550
326.	Nerves of head and neck, right side	<i>Hirschfeld and Leveillé</i> 552
327.	Nerves of head and neck, left side	<i>Hirschfeld and Leveillé</i> 554
328.	Diagram of the origin and distribution of the ninth, tenth, and eleventh nerves	557
329.	Diagram of the connections of the ninth, tenth, and eleventh nerves	<i>Hirschfeld and Leveillé</i> 559
330.	Nerves of the tongue	561
331.	Spinal cord, membranes, and spinal nerves	563
332.	Roots of the spinal nerves	563
333.	Nerves forming brachial plexus	<i>Lucas</i> 569
334.	Nerves of the axilla	<i>Hirschfeld and Leveillé</i> 570
335.	Nerves of front of forearm	<i>Hirschfeld and Leveillé</i> 573
336.	Nerves of back of forearm	<i>Hirschfeld and Leveillé</i> 576
337.	Nerves of the abdominal wall	<i>Hirschfeld and Leveillé</i> 580
338.	Lumbar plexus	<i>Hirschfeld and Leveillé</i> 582
339.	Diagram of lumbar and sacral plexuses	584
340.	Nerves of the thigh	<i>Hirschfeld and Leveillé</i> 586
341.	Nerves of the pelvis	<i>Hirschfeld and Leveillé</i> 589
342.	Nerves of the back of the thigh	<i>Hirschfeld and Leveillé</i> 592
343.	Superficial nerves of back of leg	<i>Hirschfeld and Leveillé</i> 594
344.	Dissection of sole of foot	<i>Hirschfeld and Leveillé</i> 595
345.	Cranial ganglia of the sympathetic	598
346.	Dissection showing otic ganglion	<i>Hirschfeld and Leveillé</i> 601
347.	Scheme of formation of cardiac plexuses	<i>Henry E. Clark</i> 605
348.	Diagram of the thoracic sympathetic chain	<i>Henry E. Clark</i> 607
349.	Cartilages of nose	612
350.	Side view of cartilages of nose	<i>Arnold</i> 613
351.	Mucous membrane of olfactory region	<i>Ecker</i> 614
352.	Olfactory cells	<i>Schultze</i> 615
353.	Appendages of the eye	616
354.	Meibomian glands	<i>Arnold</i> 617
355.	Vertical section of upper eyelid	<i>Waldeyer</i> 618
356.	General diagram of the eye	<i>Allen Thomson</i> 622
357.	Vertical section of cornea	<i>Bowman</i> 623
358.	Veins of the choroid	<i>Arnold</i> 624
359.	Iris and ciliary processes	625
360.	Ophthalmoscopic view of fundus of eye	<i>E. Jaeger</i> 626
361.	Section through ciliary processes and iris	<i>Iwanoff</i> 627
362.	Cells of the <i>pars ciliaris retinae</i>	<i>Kölliker</i> 628
363.	Section of the eye at entrance of optic nerve	<i>Ecker</i> 628
364.	Rods and cones seen from outer surface	<i>Kölliker</i> 628
365.	Pigmentary cells of retina	<i>M. Schultze</i> 629
366.	Structure of the retina	<i>M. Schultze</i> 630
367.	Section through yellow spot of retina	<i>Cardiat</i> 631
368.	Crystalline lens	<i>Babuchin</i> 632
369.	External ear	<i>Politzer</i> 634
370.	Pinna and its muscles, front view	<i>Arnold</i> 635
371.	Pinna and its muscles from behind	<i>Arnold</i> 636
372.	View of the middle ear	<i>Politzer</i> 637
373.	Profile view of left tympanic cavity	<i>E. A. Schäfer</i> 639
374.	Small bones of the tympanum	640

FIGS.	PAGE
375. Vertical section of cochlea of a calf	<i>Kölliker</i> 645
376. Membranous labyrinth	<i>Cleland</i> 646
377. Osseous and membranous labyrinth	<i>Breschet</i> 647
378. Section through one of the coils of cochlea	<i>Henle</i> 648
379. Organ of Corti	<i>Cardiat</i> 651
380. Tongue and tonsils	<i>Sappey</i> 653
381. Filiform papillæ	<i>Kölliker</i> 654
382. Taste-buds from rabbit	<i>Engelmann</i> 655
383. Upper opening of thorax	<i>Heath</i> 658
384. Diagram of heart and circulation 661
385. Right side of heart 662
386. Auriculo-ventricular and aortic valves	<i>Allen Thomson</i> 664
387. Left side of heart 666
388. Section of heart at level of valves	<i>Sibson</i> 667
389. Position of heart in relation to chest walls	<i>Luschka</i> 669
390. Endothelium of the endocardium	<i>Kölliker</i> 671
391. Fœtal circulation	<i>Cleland</i> 673
392. Cartilages of larynx	<i>Luschka</i> 676
393. Arytenoid cartilage	<i>Luschka</i> 676
394. Vertical section of larynx 678
395. Posterior view of larynx	<i>Sappey</i> 680
396. Side view of larynx	<i>Sappey</i> 681
397. Vertical section of larynx, showing ligaments	<i>Sappey</i> 682
398. Laryngoscopic view of glottis	<i>Czermak</i> 684
399. Ciliated epithelium of trachea	<i>Kölliker</i> 685
400. Structure of thyroid body	<i>Kölliker</i> 686
401. Heart and lungs 689
402. Transverse section of bronchial tube	<i>Schultze</i> 690
403. Intercellular passages of lung 690
404. Lobules of lung, showing air-cells	<i>Frey</i> 691
405. Capillaries of the lung	<i>Carpenter</i> 691
406. Capillary network of air-cell	<i>Frey</i> 692
407. Transverse section of thorax	<i>Heath</i> 694
408. Viscera of the abdomen 696
409. Reflections of the peritoneum 698
410. Transverse section of abdomen, showing peritoneum	<i>Heath</i> 699
411. Median vertical section of nose, mouth, pharynx, &c.	<i>Quain</i> 704
412. Vertical section of tonsil	<i>H. E. Clark</i> 706
413. Mucous crypt	<i>Kölliker</i> 706
414. Section of submaxillary gland	<i>Heidenhain</i> 708
415. Striated epithelial cell from salivary duct	<i>E. A. Schäfer</i> 709
416. Left upper central incisor tooth	<i>C. S. Tomes</i> 710
417. Lingual, labial, and distal surfaces of upper canine.	<i>C. S. Tomes</i> 710
418. Grinding surface of an upper bicuspid	<i>C. S. Tomes</i> 711
419. Masticating surface of first upper molar	<i>C. S. Tomes</i> 711
420. Masticating surface of first lower molar	<i>C. S. Tomes</i> 711
421. Masticating surface and side view of second lower molar	<i>C. S. Tomes</i> 711
422. Vertical section of molar tooth	<i>Carpenter</i> 712
423. Section of dentine in the direction of the tubules	<i>Kölliker</i> 713
424. Transverse section of dentine, showing tubules	<i>Kölliker</i> 713
425. Longitudinal section of enamel	<i>Kölliker</i> 714
426. Transverse section of enamel	<i>Kölliker</i> 714
427. Three stages of the development of a tooth-germ	<i>Frey</i> 716
428. Dentinal sac of a human fœtus	<i>Frey</i> 717
429. Odontoblasts <i>in situ</i>	<i>Tomes after Waldeyer</i> 718
430. Normal jaws, showing temporary and permanent teeth	<i>C. S. Tomes</i> 719

FIGS.		PAGE
431.	Pharynx laid open from behind	721
432.	Transverse section of œsophagus	<i>V. Horsley</i> 722
433.	Vertical longitudinal section of stomach and duodenum	724
434.	Diagram of muscular fibres of stomach	<i>Henle</i> 725
435.	Mucous membrane of stomach	726
436.	Section of coats of stomach	<i>Kölliker</i> 726
437.	Compound peptic gland	<i>Frey</i> 727
438.	Gastric mucous glands	<i>Frey</i> 727
439.	Relations of pancreas and duodenum	<i>Quain after His</i> 728
440.	Valvulæ conniventes of jejunum	<i>Henle</i> 730
441.	Mucous membrane, showing villi	731
442.	Section of ileum	<i>Kölliker</i> 731
443.	Intestinal villus	<i>Frey after Leydig</i> 732
444.	Brunner's glands from duodenum	<i>Frey</i> 733
445.	Solitary gland from colon	733
446.	Surface view of solitary glands	<i>Ecker</i> 733
447.	Vertical section of a Peyer's patch	<i>Ecker</i> 734
448.	Capillaries of mucous membrane	<i>Kölliker</i> 734
449.	Cæcum and ileo-cæcal valve	<i>Henle</i> 736
450.	Upper surface of the liver	740
451.	Under surface of the liver	743
452.	Lobules of the liver	745
453.	Longitudinal section of two lobules	745
454.	Cells of the liver	<i>Yeo</i> 746
455.	Section of lobule of the liver of a rabbit	<i>Cardiat</i> 747
456.	Arrangement of vascular and biliary capillaries in relation to bile cells	<i>Frey</i> 749
457.	Gall bladder and bile ducts	<i>A. M'Alister</i> 751
458.	Section of the pancreas of a dog	<i>Klein</i> 752
459.	Trabeculæ of spleen	<i>Cardiat</i> 753
460.	Reticulum of splenic pulp	<i>Cardiat</i> 754
461.	Arrangement of splenic corpuscles	<i>Kölliker</i> 754
462.	Section of Malpighian body of spleen	<i>Cardiat</i> 755
463.	Section of fœtal supra-renal body	<i>Allen Thomson</i> 756
464.	Vertical section of supra-renal body	<i>Eberth</i> 757
465.	Section of kidney	759
466.	Section of kidney, showing relation of parts	<i>Henle</i> 759
467.	Arrangement of tubules and vessels of kidney Modified from <i>Klein</i>	760
468.	Epithelium of uriniferous tubules	<i>Klein</i> 762
469.	Plan of renal circulation	<i>Bowman</i> 763
470.	Transverse section through a Malpighian pyramid	<i>Frey</i> 763
471.	Varieties in arrangement of pelvis of kidney	<i>Gegenbaur</i> 764
472.	Side view of male pelvic viscera	768
473.	Transverse section of prostate gland	<i>Allen Thomson</i> 769
474.	Bladder and vesiculæ seminales	770
475.	Transverse section of penis	<i>Heath</i> 772
476.	Structure of corpus cavernosum penis	<i>Langer</i> 774
477.	Anatomy of bladder and urethra	775
478.	Urethra and neck of bladder	776
479.	Transverse section of testicle	780
480.	Diagram of testicle	781
481.	Seminal tubules, with developing spermatozoa	<i>Schäfer</i> 782
482.	Descent of testicle	<i>Curling</i> 784
483.	Descent of testicle, later stage	<i>Curling</i> 784
484.	Female pelvic viscera (diagrammatic)	785
485.	Vertical section of female pelvis in mesial line	<i>Henle</i> 787
486.	Vertical antero-posterior section of uterus	<i>Henle</i> 788

FIGS.	PAGE
487. Uterus and its appendages	789
488. Section of Fallopian tube	<i>A. Milroy</i> 791
489. Ovary, showing Graafian vesicles	<i>Frey</i> 792
490. Minute structure of the ovary and ovum	<i>Waldeyer</i> 793
491. External organs of generation in the female	<i>Henle</i> 796
492. Gland vesicles of mammary gland	<i>Frey</i> 799

LIST OF COLOURED PLATES.

PLATE	FACES	PAGE
1. Occipital bone	88
2. Frontal bone	92
3. Temporal bone	98
4. Sphenoid bone	102
5. Superior maxillary bone	108
6. Inferior maxillary bone	118
7. Clavicle and scapula, dorsal surface	136
8. Clavicle and scapula, ventral surface	138
9. Humerus	142
10. Radius and ulna, anterior surface	144
11. Radius and ulna, posterior surface	146
12. Hand, palmar surface	148
13. Hand, dorsal surface	150
14. Innominate bone	156
15. Femur, anterior surface	160
16. Femur, posterior surface	162
17. Tibia and fibula, anterior surface	164
18. Tibia and fibula, posterior surface	166
19. Foot, dorsal surface	168
20. Foot, plantar surface	172
21. The male perineum	<i>Maclise</i>	306
22. Arteries of the head and neck	<i>Maclise</i>	398
23. Arteries of the hand	<i>Maclise</i>	414
24. Arteries of the male pelvis	<i>Maclise</i>	428
25. Arteries of the foot	<i>Maclise</i>	446
26. Male perineum	<i>Maclise</i>	768

THE
ANATOMIST'S VADE MECUM.

PART I.

HISTOLOGY.

THE human body, complicated though it be, is made up of a small number of elementary tissues; these by their different combinations form the several organs, and a knowledge of them is therefore essential to the proper understanding of those organs and their uses.

The textures of the body which will be described in this section of the work are as follows:—Cells, blood and lymph corpuscles, epithelium, areolar tissue, fibrous tissue, adipose tissue, pigment, cartilage, bone, muscle, nerve, blood-vessels, lymphatic vessels and glands, serous and synovial membranes, mucous membrane, and secreting glands. Some of these are simple in their constitution, and by their combination form the more complex,—such are the cells and fibrous tissues; others are composed of many different constituents, arranged often in a very complex manner, and among these are included the blood-vessels, lymphatics, and secreting glands. The latter are here described because it is necessary to consider them apart from the several organs in which they are found, and because it is convenient to speak of them in connection with the more elementary tissues of which they are constructed.

CELLS AND PROTOPLASM.

Every tissue in the body in its earliest condition consists of an aggregation of minute solid particles which have received the name of cells. Some of the tissues retain throughout life the cellular character, but these are few in number, the majority only having their origin from cells indicated by the presence of minute remains

called *nuclei*. Cells are for the most part spheroidal in shape, unless modified by pressure or other causes, when they may become oval, fusiform, scaly, or hexagonal; in pigment, connective tissue, and the nervous centres they are stellate, having ramifying processes which communicate with each other so as to form a network. Besides those contained in the tissues there are also free cells floating in the fluid of blood, lymph, and chyle, and one form of them has the power of leaving these fluids and travelling through the tissues; these, the "white corpuscles" of the blood, have hence been termed "*wander cells*." Each cell consists of an albuminoid material, transparent, colourless, and of a jelly-like consistence, called *protoplasm*. The cell may have a distinct bounding membrane or *cell-wall*, but this is not invariably the case with the cells of animal tissues; it has usually one or more central spots called *nuclei*, within which again are one or two smaller spots called *nucleoli*; but both nucleus and nucleolus may be absent without interfering with the vitality of the cell.

FIG. 1. — Different kinds of cells with nuclei and protoplasm.




FIG. 2. — Diagram of a cell with two nuclei, showing intercellular and internuclear network.

Protoplasm has commonly a granular appearance, and this is generally due to the existence of a very fine network of fibrils with slight nodes at the points where they intersect (intercellular network). The network is known as the *reticulum* or *spongio-plasm*, while the substance occupying its meshes is called the *hyaloplasm*. Protoplasm is a proteid substance, similar to albumen; it has a strong affinity for staining fluids, especially for carmine and hæmatoxylin, consists very largely of water, but is not miscible with that fluid, and is weakly alkaline or neutral in reaction. It possesses remarkable vital properties, the chief of which are, (a) its power of motion, (b) its active nutrition, and (c) the production of similar masses of protoplasm by division. The power of motion of protoplasm is exhibited in three ways:—(1.) In changing its shape and position, by putting out irregular processes (*pseudopodia*), and then drawing the general mass onwards to the position they occupy; this is known as *amœboïd motion*, and by it the protoplasmic mass is able to travel from place to place. (2.) The second form of motion consists of streaming movements in the substance of the protoplasm (whether it be stationary or exhibit amœboïd movements), and in the pseudopodial processes of

amæboid protoplasm. (3.) The protoplasm is able to wrap itself around a foreign particle of matter with which it is brought in contact, and again to withdraw from it: this is called a *movement of intussusception*. The *nutrition* of protoplasm consists in its taking up material from without and converting it into substance like itself; upon this selective and constructive power depends the development and growth of all organised bodies, whether animal or vegetable.

The *nucleus* consists of a small spherical or oval body embedded in the protoplasm, and generally surrounded by a definite membrane. The nuclear substance is divisible into a *nuclear fluid* and a *nucleoplasm* or *nuclear network*. The fluid does not take on stain readily, and hence has been named *achromatin*, while the network, from its affinity for the stain, has been called *chromatin* or *chromoplasm*. The nuclear network sometimes contains one or more granules or globules, called *nucleoli*, situated at the intersections of the fibres.

The multiplication of protoplasmic masses, or **cell-multiplication**, takes place by *direct* or *indirect division*.

Direct Division, or **Karyostenosis**, consists in the division of the nucleus without any changes taking place in its structure, followed by the division of the protoplasm.

This was formerly supposed to be the common mode of cell-division, but recent investigation shows that neither in animal nor vegetable cells is direct cell-division common.

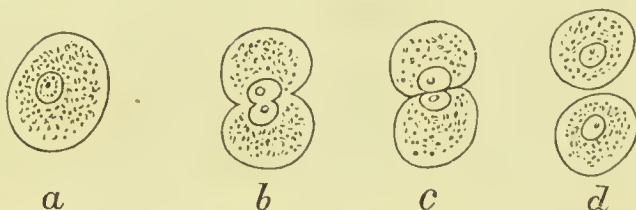


FIG. 3.—Direct cell-division or karyostenosis. *a*. Fully formed cell. *b*. Division of nucleus and cell. *c*. Division of nucleus and cell substance complete. *d*. Formation of two new cells.

Indirect Division, or **Karyokinesis**, or **Mitosis**, is a process wherein the division of the cell is preceded by a series of complex changes in the nuclear network.

These, briefly stated, are as follows:—

(1.) The nucleus becomes enlarged, and the chromoplasm, which in the resting nucleus forms a network, becomes converted into a number of fine filaments, and these become convoluted so as to form a “*skein*” (Fig. 4, *b. c.*).

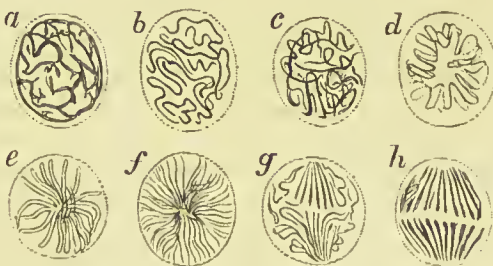


FIG. 4.—Views of various stages of karyokinesis. *a*. Resting nucleus. *b.* and *c.* Varieties of convolution. *d*. Wreath or spirem. *e.* and *f.* Aster stage. *g.* Equatorial division. *h.* Diaster stage.

(2.) A series of fibrils appears in the achromatic part of the nucleus, arranged in the form of a spindle (the *achromatic spindle*); these meet at each pole of the nucleus, and

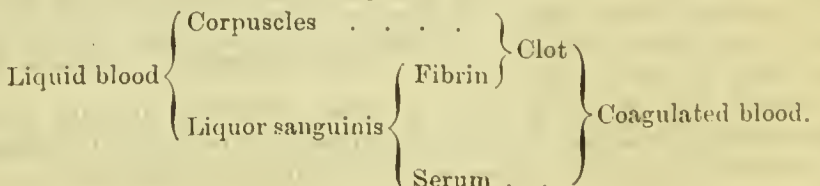
again diverging, radiate into the protoplasm of the cell. The achromatic spindle appears first at the end of the nucleus towards which the filaments of chromoplasm are directed (*polar end*), but from thence it moves and takes up a position in the middle of the nucleus. (3.) The chromatic filaments become shorter and thicker, and are disposed in V-shaped loops radiating from the centre of the achromatic spindle (*aster stage*, Fig. 4, *e. f.*); the filaments next split in their length into two very fine threads. (4.) The threads of the split chromosomes separate, and the two derived from each primary filament pass along the achromatic fibrils in opposite directions towards the poles of the spindle. As they approach the pole they have a radiate appearance (like a rosette) at each end of the nucleus, and this stage has hence been called the *diaster stage* (Fig. 4, *h.*). (5.) As soon as the chromosomes separate in this manner into two groups, one at each pole of the nucleus, the cell protoplasm commences to divide, and thus two cells are formed, which, however, remain for some time intimately connected. (6.) The chromatic filaments in the nucleus of each daughter-cell give off branches; these become convoluted, and form by their inter-communications the *internuclear network* of the resting nucleus.

Protoplasm undergoes a change at its surface, especially in old cells, being converted into a harder layer constituting the cell-wall; such cells lose their power of amœboid movement, and, uniting with other cells, form tissues. Cells are connected with each other either by means of their processes (as above mentioned), by direct union of their walls, or by an intercellular substance.

BLOOD.

Blood is a rather thick fluid, of a bright red or scarlet colour in the arteries, and of dark purple tint in the veins. It has a salt taste, a slight alkaline reaction, a peculiar faint odour, and a specific gravity of 1055.

It consists of a colourless, transparent fluid, the *liquor sanguinis*, and of small solid particles, called *corpuscles*, floating in the fluid. When drawn from the body, it speedily solidifies or *coagulates* into a jelly-like substance, called a *clot*, which as it contracts squeezes out a small quantity of transparent, straw-coloured fluid known as *serum*. In the process of coagulation a substance called *fibrin* is formed, which entangles the corpuscles in its meshes, so that the clot is formed of fibrin and corpuscles, and is of red colour. The relation between the constituents of blood in the liquid and coagulated states is shown in the following scheme:—



The **blood corpuscles** are of two kinds, *red* and *white*, the former greatly exceeding the latter in number. In healthy human blood the proportion of white to red corpuscles varies from 1 to 1000 to 1 to 250. According to Vierordt, a cubic millimeter of healthy human blood contains on an average 5,000,000 red corpuscles and 10,000 white ones.

The **Red Corpuscles** are circular, biconcave discs, having a diameter of about $\frac{1}{2500}$ of an inch, and a thickness of $\frac{1}{12000}$ of an inch; they do not possess a nucleus.

In diseased conditions, and occasionally in health, there are also found smaller red corpuscles, about one-third the size of the ordinary ones, and spheroidal in shape. The corpuscles are elastic, and consequently change their shape when subject to compression. When the blood is drawn from the vessels, they tend to aggregate together and cohere by their broad surfaces, so as to form columns like piles (*rouleaux*) of coins. Their shape also varies according to the specific gravity and chemical composition of the fluid in which they are placed. The

red corpuscles consist of a tough, elastic, transparent *stroma*, supporting a red crystallisable substance called *haemoglobin* ($C_{600}H_{960}N_{154}FeS_3O_{179}$), which has a strong affinity for oxygen, and can be separated from the corpuscles by certain simple processes in the form of rhombic crystals.

The **White Corpuscles** are larger than the red ones, having a diameter of $\frac{1}{2500}$ of an inch; when at rest, they are spherical and have a granular appearance, but they have power of changing their shape, and putting out processes in the manner above described as amæboid motion. They are trans-

parent masses of protoplasm, and

possess one or more nuclei, have no cell-wall, and frequently contain granules, or minute masses of red colouring matter. Sometimes they also contain clear spaces or vacuoles. Having the power of passing through the walls of the blood-vessels and travelling from place to place, they are found in the tissues, and are there described

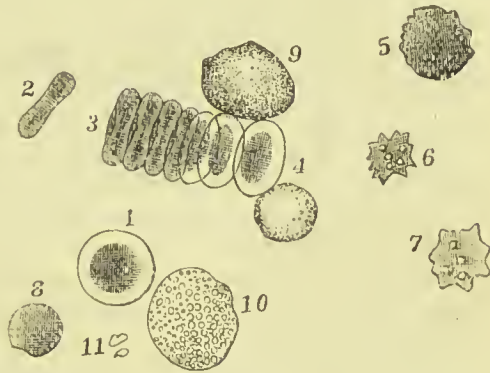


FIG. 5.—Blood corpuscles. 1. Red corpuscle, seen from surface. 2. Red corpuscle, seen from the edge. 3. A group of red corpuscles adherent by their surfaces, and forming a *rouleau*. 4. Three-quarter face. 5. Slightly crenated. 6, 7. Crenated corpuscles. 8. Spherical. 9. Large white corpuscle. 10. Granular leucocyte. 11. Hematoblasts.

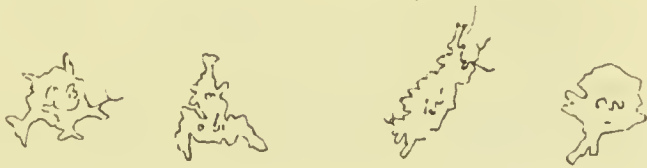

FIG. 6.—White corpuscles of the blood undergoing amæboid changes.

as *migratory* or *wander cells*. The white corpuscles are by some observers regarded as an early stage of the red corpuscles.

In addition to the red and white corpuscles of the blood, other solid particles have been described under the name of *hæmatoblasts* by Hayem, and of *blood-platelets* by Bizzozero. They are found in the midst of the interlacing threads of fibrin in clot, after washing away the corpuscles, as minute, round, colourless, disc-like particles, generally aggregated into masses. They have also been observed in the living blood in the smaller vessels of the rat's mesentery; their exact nature is uncertain.

The **Liquor Sanguinis**, or **Plasma** of the blood, is composed of *serum*, and of two *fibrin-factors* which unite when the blood is drawn from the body to form *fibrin*, and thus determine the coagulation of the blood. The **serum** is the liquor sanguinis deprived of its fibrin; it has a specific gravity of 1.027, is alkaline in reaction, and contains albumen, salts, fatty matter, gases, and sugar.

Fibrin is formed by the union of two fibrin-factors, called *fibrinoplastin* and *fibrinogen*. Fibrinoplastin, or paraglobulin, is in part contained in the white corpuscles, and in part held in solution in the liquor sanguinis; it can be precipitated from the liquor sanguinis, in the form of a white powder, by diluting that fluid with ten times its bulk of ice-cold water, and then passing a stream of CO₂ through it. Fibrinogen is held in solution in the liquor sanguinis, and can be also thrown down as a white powder by a more copious dilution, and a more complete saturation with CO₂ than is requisite to precipitate fibrinoplastin. The combination of these factors is brought about by means of a third substance called the *fibrin-ferment*. Fibrin can be obtained from fresh blood by whipping it with twigs, as fine fibrils of a pale straw-colour, which are insoluble in water, alcohol, or ether.

Gases of the Blood.—The blood contains a very large volume of gases, partly in combination, partly free. These are Carbonic Acid, Nitrogen, and Oxygen. They differ in their proportion in arterial and venous blood, as shown in the following table:—

	Oxygen.	Carbonic Acid.	Nitrogen.
	Vols.	Vols.	Vols.
Arterial blood . . .	16	30	1 to 2
Venous blood . . .	6 to 10	35	1 to 2

The oxygen is for the most part in loose combination with the hæmoglobin of the red corpuscles; the carbonic acid is in combination with the salts of the serum, especially with the salts of sodium; the nitrogen is suspended in the liquor sanguinis.

LYMPH AND CHYLE.

Lymph is a nearly colourless, transparent fluid, contained in a special system of vessels called *lymphatics* or *absorbents*. The lymphatics of the small intestine carry, during digestion, a milky fluid

named *chyle*, which consists of lymph mixed with the products of digestion ; but during fasting, these vessels carry transparent lymph, the same as lymphatic vessels elsewhere.

Lymph consists of a fluid portion, or *lymph-plasma*, and corpuscles, *lymph corpuscles*, floating in it. The plasma resembles liquor sanguinis, and contains about five per cent. of albumen and one per cent. of salts. The corpuscles are indistinguishable from the white corpuscles of the blood, being nucleated masses of protoplasm having the power of amœboid movement ; they are most numerous in the lymph after it has passed through the lymphatic glands.

Chyle consists also of a fluid, containing corpuscles identical with those of lymph ; but it also has what is called a *molecular basis*, consisting of minute particles of fat with some oil vesicles ; it is this which gives the milky appearance. Both lymph and chyle resemble blood in spontaneously coagulating when removed from the body, forming a thin pale clot, from which serum exudes.

EPITHELIUM.

The epithelial tissues are distinguished by their retaining the cellular character throughout the whole of life ; they are used chiefly for the purpose of protection, but epithelial cells constitute also the secreting cells of mucous membrane and of glands. The superficial part of the skin consists of many superimposed layers of epithelial cells, constituting the *epidermis* ; those cells on the surface become flattened and dried, and are cast off as thin scales.

Besides forming the epidermis, epithelial cells are found covering the surface of the mucous membranes of the alimentary canal, lachrymal, nasal, and respiratory passages, the urinary and genital canals, the ventricles of the brain, and central canal of the spinal cord, also, lining the glandular recesses and ducts of secreting glands. Modified epithelial cells form the terminal nervous apparatus of the organs of special sense, such as the eye, ear, and nose.

A single layer of flattened epithelial cells covers the surface of the serous membranes of the abdomen, thorax, and cerebro-spinal cavity, and the synovial membrane of joints ; it also lines the heart, blood-vessels, and lymphatics, and the anterior chamber of the eye. In these situations the epithelial tissue is formed from the mesoblastic layer of the embryo, whereas the epithelium elsewhere is derived from the epiblast or hypoblast ; for this reason it has been the custom of late years to make a separate class for such tissues, under the name of **endothelium**.

True epithelial tissue consists of one or more layers of nucleated cells, united together by an intercellular cement substance, and resting on a basement membrane, and is divisible into *simple non-stratified* and *stratified* epithelium. Its varieties are the following :—

1. Squamous.
2. Columnar.
3. Glandular.
4. Transitional.
5. Ciliated.

1. **Squamous, Scaly, or Tessellated Epithelium** is so called because the cells appear as thin flattened scales; they frequently have in their centre a small nucleus and nucleolus, which are of soft consistence: the rest of the cell is more dense. In the surface cells of the epidermis the nucleus and nucleolus disappear, the cells being converted into thin plates of horny consistence. On the skin, the mucous membrane of the oral cavity, lower half of pharynx, œsophagus, nasal duct, tympanic cavity, vagina, female urethra, bladder, ureter, pelvis of the kidney, and on the conjunctiva of the eye they form the surface layer of a thick mass of cells, the deeper constituents of

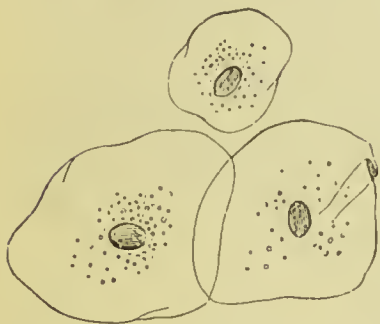

FIG. 7.—Old epithelium cells from the mouth.

which are commonly spheroidal or fusiform in shape. The scales are somewhat larger in the mouth and fauces than elsewhere, and in longest diameter measure $\frac{1}{400}$ to $\frac{1}{300}$ of an inch; in the vagina between $\frac{1}{800}$ and $\frac{1}{500}$; and on the skin $\frac{1}{600}$. The nucleus, which is round or oval in shape and flattened, measures in scales from the mouth $\frac{1}{2000}$ of an inch. In the deep layers of a stratified epithelium, and especially in the *rete mucosum* of the skin, there are found numerous cells with fine fibres or spikes projecting from their edges; they are called **prickle-cells**. The processes of neighbouring cells are joined in such a manner as to leave little canals or intercellular channels between them.




FIG. 8.—Prickle cells from *rete mucosum*.

2. **Columnar or Cylinder Epithelium** consists of cells which have an elongated or pyriform shape, their bases being directed to the free surface, and their

apices to the basement membrane to which they are attached. They are ranged side by side like columns, and are connected together by a small amount of *intercellular or cement substance*. Each column contains near its middle a nucleus, which gives it a swollen appearance, and the nucleus possesses one or more nucleoli; from the transparency of the column the nucleus may be seen through its base. This form of epithelium is found in the alimentary canal from the cardiac end of the stomach to the anus, in the intestinal glands, in the mammary and lachrymal glands, in

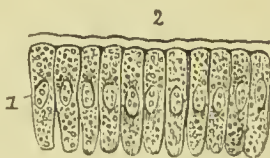


FIG. 9.—Portion of columnar epithelium from one of the villi of the small intestines. 1. Nucleus of the cell. 2. Basement membrane.

the male urethra, vas deferens, seminal vesicles, Cowper's glands, glands of Bartholine, and uterine glands.

Many of the cells have projecting processes on their edges, by which they are connected with similar processes in neighbouring cells, the interstices left between the processes being filled in by lymphoid or other small cells. The protoplasm both of the cell and nucleus appears granular, this appearance being due to the presence of an intercellular and internuclear network. Such cells often have vacuoles in their substance; others contain fatty globules or mucin. The mucin frequently distends the cell so much as to push the nucleus towards the attached end of the cell, and by still further distention bursts the cell, leaving a hollow cavity at the free extremity; such cells are then called **goblet** or **chalice cells**.

Columnar cells, especially those in the mucous membrane of the intestine, have an appearance of fine vertical striation at the free edge; these striæ are probably minute rods or columns, and the part of the cell containing them is sometimes separated off from the rest of the protoplasm by a transverse line or *plate*. In the cells of the smaller salivary ducts, and in some of those lining the uriniferous tubes of the kidney, it is the attached border, and not the free one, which is striated.

3. **Spheroidal or Glandular Epithelium** is composed of cells which are spheroidal in shape, but often become more or less polyhedral from compression.

This form of epithelium occurs in secreting glands such as the liver and pancreas, the salivary, gastric, and intestinal glands, and the glands of the skin. They appear granular owing to the presence of a fine reticulum in the cell and nucleus, and generally contain the materials which the gland secretes.

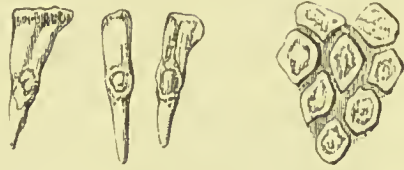

FIG. 10.—Columnar epithelium from the small intestine. Separate cells showing nucleus and nucleolus.

FIG. 11.—Appearance of the surface formed by the apposition of the bases of several cells.

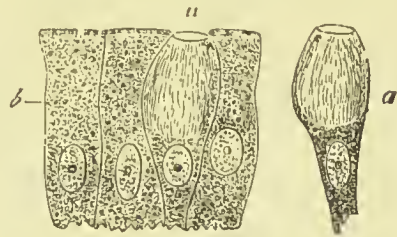


FIG. 12.—Goblet-cells from the epithelium of an intestinal villus from the human subject, treated with Muller's fluid (Schulze). a. Goblet-cells. b. Cylinder-cells.



FIG. 13.—Sacculæ of a sebaceous gland. a. Gland cells clothing the walls. b. Those which have been cast off, filled with oil globules, and occupying the lumen of the sac.

4. **Transitional Epithelium** is the early form of all the varieties

of epithelium, and generally has the character of small granular spheroidal cells. In the pelvis of the kidney, ureter, urinary bladder, and urethra, however, the transitional epithelium is peculiar, consisting of three or four layers of cells. The surface cells are smooth on their upper surface, but hollowed underneath into pits which receive the rounded ends of pear-shaped cells situated beneath them; between the narrow necks of the pear-shaped cells there are smaller cells, rounded or irregular in shape.

5. **Ciliated Epithelium** is characterised by the presence of minute conical vibratile filaments or *cilia* mounted on the broad ends of columnar cells, or upon the free surface of those of the spheroidal kind. The cilia are in constant action, and produce a wave-like

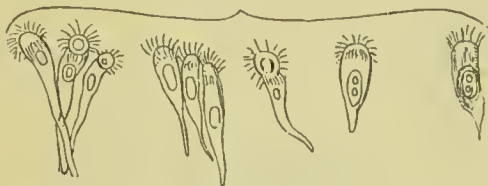

FIG. 14.—Cells of the columnar ciliated epithelium of the nose, magnified 310 times.

membrane of the lower part of the

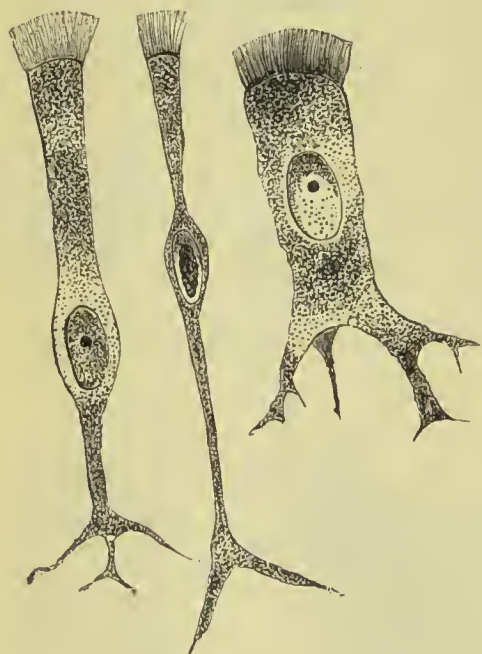

FIG. 15.—Various forms of ciliated epithelial cells, from the trachea of a cat.

motion, which carries the secretions in contact with them towards the outlet of the organ in which they exist. They have an average measurement in the human trachea of $\frac{1}{4000}$ to $\frac{1}{2500}$ of an inch. Ciliated epithelium is found (1) in the mucous membrane of the lower part of the nasal cavities and the adjoining accessory cavities; (2) in the nasal duct and lachrymal sac; (3) the Eustachian tube and cavity of the tympanum; (4) the upper part of the pharynx and upper surface of the soft palate; (5) the larynx (excepting over the true vocal cords), trachea, bronchi, and bronchial tubes to their smallest branches; (6) the uterus and its glands, and the entire length of the Fallopian tubes; (7) the *vasa efferentia* and *coni vasculosi* of the testicle; (8) some part of the ventricles of the brain, and the whole length of the central canal of the spinal cord; (9) the ducts of the lingual and pharyngeal glands; (10) in the embryo, lining the œsophagus, over the whole pharynx and part of the mucous membrane of the stomach.

Ciliated cells possess an intercellular and internuclear network,

and many of them give off forked processes from their deep aspect (fig. 15).

ENDOTHELIUM.—It has been said above that endothelium differs from epithelium in being derived from the mesoblast; another difference is that endothelial cells are never supported by a basement membrane. Endothelium consists of flattened cell plates, held together at their edges by a cement substance which becomes stained brown when the surface is painted with a solution of nitrate of silver. The outlines of the cells thus made apparent are commonly irregular or jagged; more especially where the cells line the lymphatic vessels. Although the majority of the cells are thin and flat, there occur here and there in serous membranes groups of polyhedral or cubical thicker cells, composed of granular protoplasm; these are supposed to be in a condition of reproductive activity, and hence are described as *germinating endothelium*. Such cells generally border the lymphatic pores or *stomata* in the serous membranes. Endothelial cells are found lining the cavities of the peritoneum, pleura, pericardium, and aqueous chamber of the eye; on the surface of the spinal cord and brain; lining the heart, blood-vessels, and lymphatic vessels; lastly, on the free surface of synovial membranes.

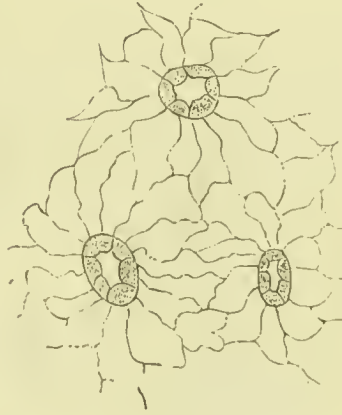

FIG. 16.—Endothelium. Showing stomata bordered by germinating cells.

CONNECTIVE TISSUE.

Connective tissue forms the means of union between the several tissues and organs, forms coverings for the muscles and sheaths for the vessels, and constitutes the supporting framework for the cellular and other elements which make up the individual organs. It consists of fibres and of cells, the former greatly preponderating, and being easily divisible into two sets, elastic and non-elastic. Having many and various duties to perform, connective tissue is necessarily greatly diversified in its arrangement, differing also in different regions in the proportion of cells to fibres, and of the elastic fibres to the non-elastic. We may, however, readily distinguish three chief forms of connective tissue, each of which requires a separate and complete description; these are the **areolar** (including the **adipose**), the **fibrous**, and the **elastic**.

Areolar Tissue.—This consists of delicate fibres and transparent laminae crossing each other in all directions, and leaving between them irregular interspaces or meshes, called *areolae*; these are occupied by a small quantity of clear colourless fluid, sufficient only

to keep the threads and laminae moist. In the midst of the fibres and laminae we can, by the use of reagents, demonstrate the existence

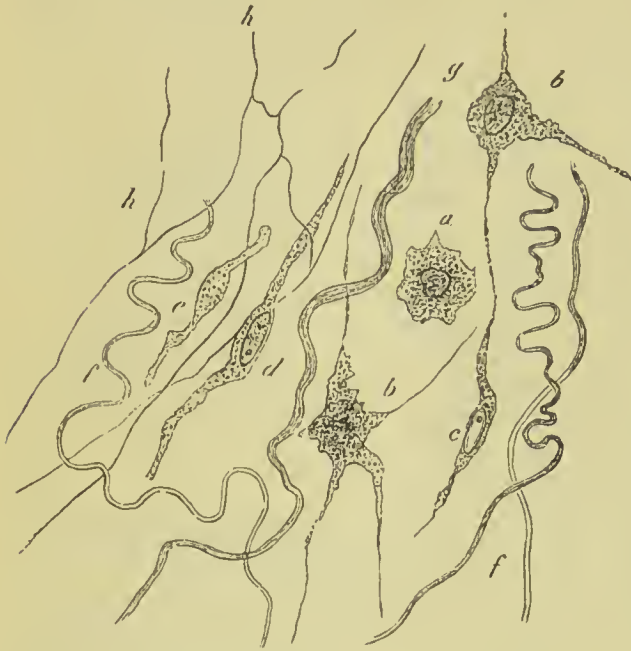

FIG. 17.—A portion of living connective tissue, cut out from between the muscles of the frog's thigh (highly magnified). *a*. A pale contracted cell. *b*. Ramified corpuscles. *c*. A similar corpuscle with vesicular nucleus. *d* and *e*. Motionless, coarsely granular cells. *f*. Fibrille. *g*. Bundles of connective tissue. *h*. Elastic fibrous network.

of numerous branched and anastomosing cells, the *connective tissue corpuscles*; they are composed of protoplasm, which is in some transparent, in others granular, and they have a clear nucleus, and often one or more nucleoli. The cells lie in a gelatinous semifluid substance (called the *ground substance*), which joins the fibres of the tissue together, making them into bundles, occupying in it cavities (called "cell spaces") which correspond accurately to the shape and size of each cell. Besides the branched cells, there are also

found in areolar tissue a number of migratory or wander cells, like the white corpuscles of the blood, composed of protoplasm, and containing one or more nuclei. These cells have the power of moving from place to place, and they become especially numerous when the tissue undergoes inflammation. The fibres are very fine, measuring from $\frac{1}{50000}$ to $\frac{1}{25000}$ of an inch, and are apparently structureless. By means of the ground substance they are united into bundles, which have a wavy course, and, when viewed by reflected light, have a white and shining appearance. Mixed with these we commonly find a number of coarser fibres, having a tendency to curl at their ends, and not gathered into bundles; acetic acid, which causes the bundles of fibres to swell up and become indistinct, has no effect on these single fibres; they will be more fully described in a later page as *yellow* or *elastic fibres*. From the loose arrangement of areolar tissue, it is often subjected during life to infiltration of fluid, this constituting *anasarca*. Areolar tissue is found beneath the skin, forming a continuous layer all over the body; beneath serous and mucous membranes; around muscles, vessels, and nerves, forming sheaths for them, and connecting them with neighbouring parts. It is also found connecting and supporting the lobules

of glands, and in the interior of organs supporting their proper tissues.

Adipose Tissue, or **Fat**, may be described as areolar tissue the meshes of which are occupied by vesicles containing oil. It is chiefly found immediately beneath the skin, forming there a continuous layer over nearly the whole surface of the body, the *panniculus adiposus*; it also exists very plentifully in the mesentery and omenta of the abdomen, round the joints, on the surface of the heart, round the kidneys, and entering into the formation of the marrow of bones. It consists of vesicles which measure from $\frac{1}{500}$ to $\frac{1}{300}$ of an inch, filled with oil; they are aggregated together so as to form little masses or lobules, and are contained in the meshes of areolar tissue. A nucleus generally exists at one side of the vesicle, but is commonly obscured by the oily contents; it is the remains of the protoplasm of the cell from which the vesicle was formed. The vesicles are usually globular in form, unless they have been compressed, when they become hexagonal or polyhedral. After death the contents of the vesicles often crystallise, appearing as groups of fine acicular crystals, which are supposed to consist chiefly of margaric acid.

Each lobule of fatty tissue has entering it a small artery, and leaving it a small vein, these being connected together by a very fine plexus of capillary vessels. No adipose tissue is found, in health, in the subcutaneous tissue of the eyelids or penis, nor in the lungs (except near their roots), nor in the cavity of the cranium.

Fibrous Tissue.—This tissue forms the periosteum of bones, ligaments to bind the bones together, tendons for the attachment of muscles, strong protecting coats for certain organs, and fasciæ to separate the muscles from each other. Thus two forms of it are described—the *fascicular*, where the fibres are gathered up into bundles so as to form a rounded or flattened band, and *membranous*, where they are spread out so as to form a thin sheet. It is composed of fine filaments gathered into bundles, and having all the characters and properties of the white fibres described as forming the greater part of areolar tissue. These are either arranged parallel to each other, as in the formation of tendons and ligaments, or they spread out, cross, and get inter-

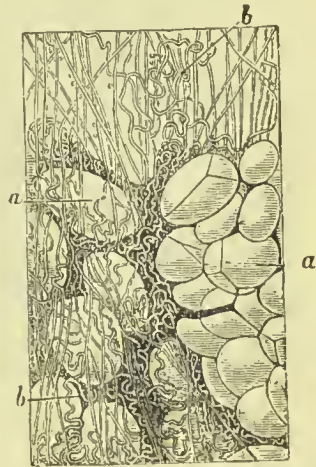


FIG. 18.—Areolar and adipose tissue. *a, a.* Fat vesicles. *b, b.* Fibres of areolar tissue.

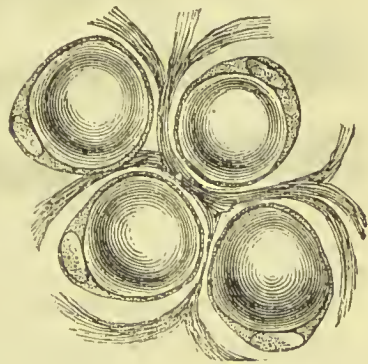


FIG. 19.—Fat vesicles from omentum, showing nuclei at the margins of the vesicles.

woven, so as to form a membranous sheet, as in fasciæ and sheaths of muscles. In the fascicular form white fibres exist almost

exclusively; in the membranous form there is a slight admixture of yellow elastic fibres.



FIG. 20.—White or non-elastic fibrous tissue.

lodge. Although the cells appear cubical in longitudinal view,

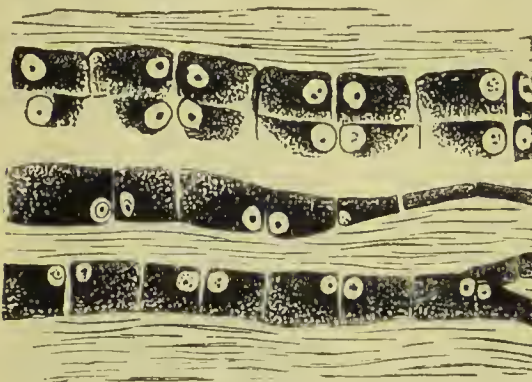


FIG. 21.—Caudal tendon of a young rat, showing the arrangement and form of the tendon cells.

When a tendon is treated with acetic acid, the white fibres of which it is composed swell up and become transparent; there are then brought into view chains of oblong flattened cells lying between the tissue bundles; these are nucleated, the nuclei of pairs of adjoining cells lying side by side. By the use of reagents it can be shown that these cells lie in cell spaces similar to those already described as lodging the cells of areolar tissue; the cell spaces accurately correspond in size and shape to the cells which they

transverse sections of the tendon show them to be stellate, giving off numerous fine processes, which penetrate between contiguous bundles of the tendon.

Fibrous tissue is white and glistening; it is very strong, but is inelastic, unless when intermixed with yellow fibres. It is converted into gelatine by boiling.

Yellow Fibrous Tissue, or Elastic Tissue, enters

very generally into the structure of tissues and organs in which the property of elasticity is an important quality. As an elastic and binding element it is present in the common areolar tissue and superficial fascia, in the fascial sheaths of muscles, in the fibrous capsules of different organs, as of the spleen, in the corium of the skin, in serons and mucous membranes, in the coats of blood-vessels and ducts; and, in certain situations, is the sole tissue present, as in the ligamenta subflava, vocal cords, thyro-epiglottic ligament, crico-thyroid membrane, lateral thyro-hyoid and stylo-hyoid ligaments, the membranous layers connecting the cartilaginous rings of the trachea and bronchial tubes, and ligamentum suspensorium penis. It is most easily obtained from the ligamentum nuchæ of the ox, sheep, or horse.

The fibres of elastic tissue are cylindrical or flattened, brittle, colourless when single, but yellowish in an aggregated form, elastic, admitting of being stretched to double their length and returning to their original size, and variable in dimensions, ranging from $\frac{1}{24000}$ to $\frac{1}{4000}$ of an inch in width. They branch freely, and form communications or *anastomoses* with each other; when cut or broken across, they curl up,—this character serving to distinguish them from the white fibres. They are homogeneous in appearance, and are unaffected by acetic acid. Schwalbe has described numerous flat connective tissue cells as lying in the ground substance between the fibres of elastic tissue.

Isolated elastic fibres of extreme fineness are met with coiled around or entwined among the fasciculi of areolar tissue holding them together.

The elastic network formed by these fibres may be extremely fine and delicate, as in thin membranes; or it may be coarser, as in the various ligamentous bands composed of this tissue; or it may be spread out like a membrane, the interstices forming but a small part of its extent, as in the *fenestrated membrane* of the arteries. Elastic tissue does not, like fibrous tissue, yield gelatine on boiling, but a peculiar substance called *elastin*, which is insoluble in water, acetic acid, ammonia, or alcohol.

Special Varieties of Connective Tissue.—Of these, three kinds deserve special mention, namely, **mucous tissue**, **reticular tissue**, and **simple membrane**.

Mucous Tissue forms the chief part of the umbilical cord (the




FIG. 22.—Coarse (a) and fine (b) yellow elastic fibres after treatment with strong acetic acid.

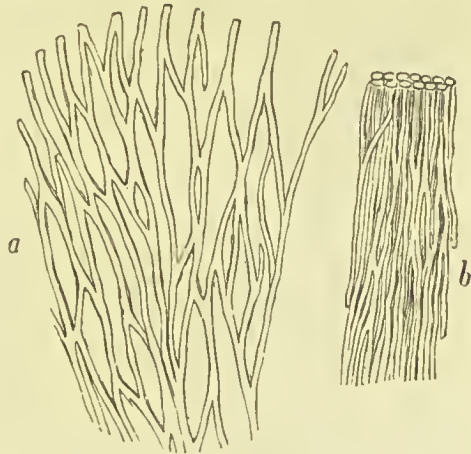


FIG. 23.—Anastomosing form of yellow fibrous tissue. a. The fibres drawn apart to show the reticulate arrangement. b. The fibres *in situ*.

Whartonian gelatine), and also forms the vitreous humour of the eye. In the early embryonic condition all connective tissue consists of a pellucid jelly, in which nucleated corpuscles are embedded, and yields a chemical principle called *mucin*; in the vitreous humour the cells disappear, only the jelly remaining, but in the umbilical cord the corpuscles branch and become connected so as to form trabeculæ, between which the jelly lies.

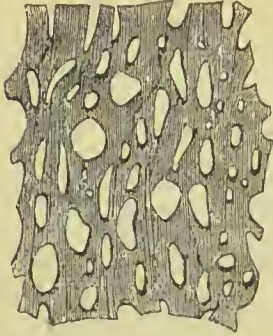


FIG. 24. — Fenestrated membrane from the middle coat of the carotid artery of a horse.

Reticular Tissue is found in all lymphatic glands, in the pharynx and tonsils, the solitary and agminate glands of the intestine, the thymus gland, and in the spleen. It consists of ramified nucleated cells, the branches of which are so connected with each other as to form a network, the meshes being commonly filled with lymph corpuscles. From its presence in lymphatic glands it has been named “adenoid” and “lymphoid” tissue.

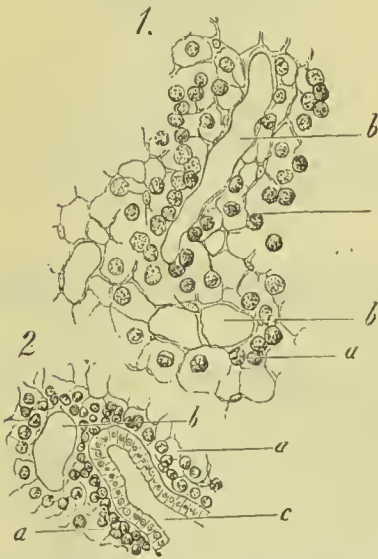

FIG. 25.—Reticular tissue from the vermiform appendix of a rabbit. 1. Deeper portion in horizontal section: *a*. framework; *b*. lymph canals. 2. Superficial portion: *a*. and *b*. as in 1; *c*. follicular gland lined with columnar epithelium.

Simple Membrane was formerly supposed to be structureless, but is now known to be made up of flattened cells united edge to edge. It forms the *membrana propria* or supporting membrane of the epithelial cells in mucous membrane and in secreting glands, and is often spoken of as *basement membrane*.

PIGMENT.

Pigment of a black or dark brown colour is found in the deeper layers of the cells of the epidermis (*rete mucosum*), especially in certain regions, as the perineum, scrotum, and penis, also in the choroid coat of the eye, the olfactory mucous membrane, the pia mater of the spinal cord, and the lungs. It consists of minute granules, composed chiefly of carbon, embedded in the protoplasm of epithelial or other cells, so as often completely to obscure the colourless and transparent nucleus; the granules often exhibit movements in the substance of the containing cell. The cells are sometimes hexagonal in form and arranged side by side, as in the pigmentary layer of the retina of the eye, some-

times they are round, as in the rete mucosum of skin, or are, again, stellate in shape, as in the lamina fusca of the choroid. The stellate pigment cells of the skin of the frog have been observed to change their shape under various forms of irritation,

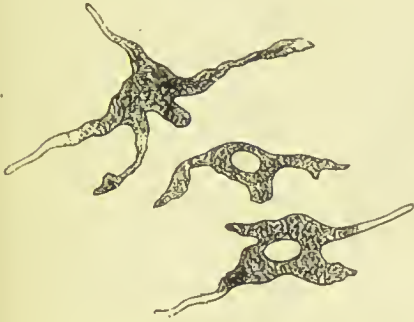

FIG. 26.—Pigmentary connective tissue corpuscles (so-called stellate pigment cells), from the *lamina fusca* of the eye.

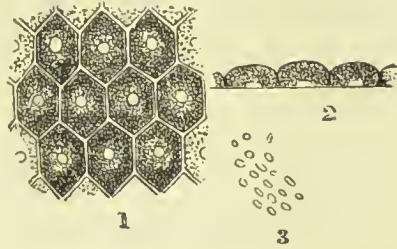


FIG. 27.—Pigmentary layer of the retina. 1. The cells as seen from the surface. 2. The same viewed edgewise. 3. The fine pigment which fills the cells.

chemical, electrical, and mechanical, these processes becoming shorter and less numerous, and at length being retracted into the body of the cell, which thus becomes spheroidal.

CARTILAGE.

Cartilage or gristle is a firm but easily cut, elastic, bluish-white substance, which coats the articular ends of long bones, joins the ribs to the sternum, forms grooves for the passage of tendons, and in the embryo and young child occupies the place of bone, and is the substance from which most of that tissue is formed.

Three forms of cartilage are usually distinguished—**hyaline**, **white fibro-cartilage**, and **yellow** or **elastic fibro-cartilage**.

Hyaline Cartilage is composed of a semi-transparent homogeneous substance called the *matrix*, containing a number of cells dispersed at short intervals through its structure. The cells may be evenly distributed throughout the matrix, as is the case in foetal cartilage, or may be gathered into groups, the members of which by their mutual pressure become changed in shape, and from being round or oval, as the single cells are, become flattened on one or two of their sides where they are in contact with their fellows. The cells have an average measurement of about $\frac{1}{10000}$ of an inch; they lie in the matrix in cell spaces which are bounded by a capsule, but this is often indistinguishable in young cartilages. Some observers state that the matrix is permeated by numerous very fine channels, which also pierce the capsules of the cartilage cells, and thus the cavities in which the cells lie communicate with

each other; these channels are believed to be connected with the lymphatic system. The matrix in some instances can be broken

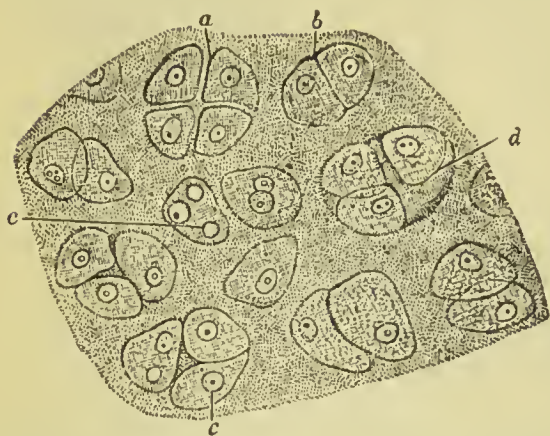


FIG. 28.—Branchial cartilage of a tadpole. *a*. Group of four cells separating from each other. *b*. Pair of cells in apposition. *c*, *c*. Nuclei of cartilage cells. *d*. Cavity containing three cells.

up by prolonged maceration into fine fibrils, having the same chemical characters as the fibres of connective tissue. Hyaline cartilages have been divided into *temporary*, which ultimately become converted into bone, and *permanent*, which remain throughout the whole of life; the majority of the latter are *articular*, that is, they coat the ends of the bones entering into the formation of joints.

In *costal cartilage* the cells are large and are collected into groups; the

matrix is traversed by patches of white fibres, and frequently contains vascular channels of considerable size; it is very prone to calcification in old age.

Articular cartilage forms a thin coating on the articular surface of bones; it has a faintly granular matrix, which has a tendency to split vertically to the surface. It is not covered by perichondrium. The surface cells become branched, and gradually change their character where the synovial membrane joins the cartilage, so as at length to be indistinguishable from the connective tissue corpuscles of that membrane.

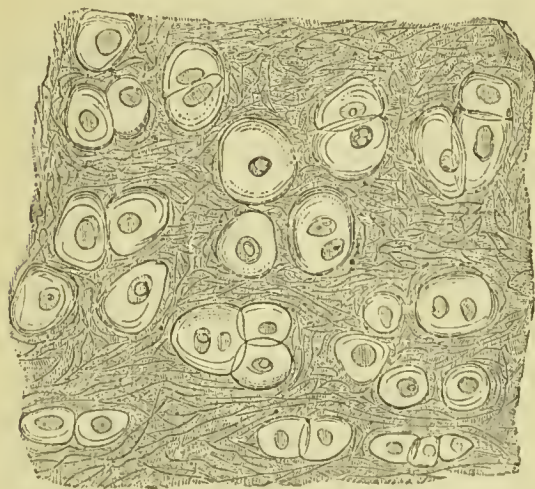


FIG. 29.—Yellow or elastic fibro-cartilage, showing cells in capsules and elastic fibres in matrix.

matrix is traversed by patches of white fibres, and frequently contains vascular channels of considerable size; it is very prone to calcification in old age.

Yellow or Elastic Fibro - Cartilage (*Reticular Cartilage*) is composed of cells ($\frac{1}{1500}$ of an inch in diameter), separated from each other by an opaque, fibrous, intercellular network, the breadth of the cells being considerably greater than that of the intercellular structure. The fibres are

short, imperfect, loose in texture, and yellowish; they are unaffected by acetic acid and do not yield chondrin. Instances of

elastic fibro-cartilage are, the pinna, epiglottis, cornicula laryngis, cuneiform cartilages, and Eustachian tube.

White Fibro-Cartilage is composed of an interlacement of fibres of white fibrous tissue, containing in its meshes scattered groups of cartilage cells which take the place of, and sometimes have a similar arrangement to the tendon-cells described above.

Fibro-cartilages admit of arrangement into four groups: inter-articular, stratiform, connecting, and circumferential. Instances of *interarticular fibro-cartilages* (menisci) are those of the lower jaw, sternal and acromial end of the clavicle, wrist, and knee. The *stratiform fibro-cartilages* are such as form a thin coating to the grooves on bone through which tendons play. The *connecting fibro-cartilages* are the intervertebral substance and cartilage of the symphysis pubis. The *circumferential fibro-cartilages* are the glenoid and cotyloid.

The *invertebral discs* are soft and pulpy in the centre, but firm and dense at their circumference; the cartilage cells are sparsely distributed, but increase in number in the inner layers; the pulp itself, however, usually contains no cartilage cells, but consists of a cell structure, embedded in a soft matrix, and is the remains of the chorda dorsalis of the embryo.

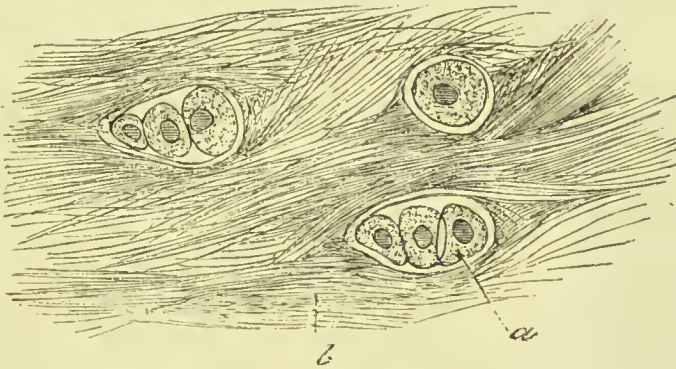


FIG. 30.—White fibro-cartilage, showing cells (*a*) in capsules, and fibrillar matrix (*b*).

Cartilages, excepting those of joints, have their free surfaces covered by a fibrous membrane called the *perichondrium*. Cartilage yields on boiling a substance called *chondrin*, similar to gelatine, but differing from it in not being precipitated by tannic acid.

BONE.

Bone is composed of about one-third of animal substance, which is almost completely reducible to gelatine by boiling, and two-thirds of earthy and alkaline salts. The special constituents of bone are present in the following proportions:—

Organic Matter . . .	Gelatin, fat, and blood-vessels . . .	33.6
Inorganic Matter . . . (66.4)	Phosphate of calcium . . .	51.04
	Carbonate of calcium . . .	12.8
	Fluoride of calcium . . .	1.5
	Phosphate of magnesium . . .	1.00
	Chloride of sodium, &c. . .	0.06
		100.00

Structure of Bone.—On examining the section of a bone, it will be found that there are two varieties of osseous tissue: one forming the exterior—hard, compact, dense; the other occupying the interior—spongy, cellular, cancellated. The best way to obtain a correct idea of the arrangement of bone substance is to study the appearance presented by a long bone, such as the tibia, which has been sawn longitudinally. The shaft is a hollow pillar, the walls of which are formed of dense bone. The hollow interior is the medullary cavity, and in the recent state is filled with marrow. The upper and lower enlarged ends are formed of an exterior thin shell of compact bone which surrounds a beautiful spider-weblike latticework of osseous threads, the meshes of which are also filled with marrow. After complete maceration all the membranous and oily matters are removed, and the dried bony structure alone is visible. On close observation, it will be seen that the walls of the pillar consist of fibres or plates arranged in the direction of the bone, and that the

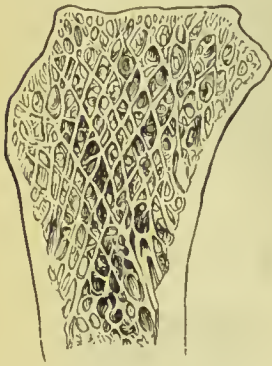

FIG. 31.—Section of head of tibia, to show the cancellated texture.

cancellated texture of the extremities is formed by the separation and divergence of threads of bone which proceed in the same direction as the walls till they reach and support the thin shell which encases the spongy texture of the end. The fibres diverge and decussate like the divisions of a Gothic window, and so enclose diamond-shaped spaces, which are the *cancelli*. This arrangement, which always has reference to the direction in which the bone is to bear pressure, adds greatly to the strength of the loose light part of the bones; and this is further secured by little cross bars, which tie together the long slender fibres just described. The dense and spongy tissues are essentially the same in structure, and the difference is simply in the degree of closeness with which the fibres are packed. A perpendicular section of the body of a vertebra (Fig. 32) shows an example of reticular or cancellated texture where the bars are parallel and straight, in accordance with the direction of the pressure.

In flat bones the osseous substance is arranged as two plates of dense tissue, in some parts closely contiguous to each other, as in the scapula; in others separated by loose tissue, or even by hollow spaces, as in the bones of the skull, where the intervening substance, in which the blood-vessels run, is called the *diploë*.

The simplest arrangement of bone substance is to be found in the

ethmoid and spongy bones of the face, the thin partitions of which are formed of a single plate of bone. This is nourished from the outside, no vessels entering into its substance.

Bone exists in the form of plates or lamellæ, which can be seen by examining a thin slice of bone after it has been softened by steeping in diluted hydrochloric acid. The fibrous character of the lamellæ can be demonstrated by tearing strips from softened bones, by which it will be seen that the direction of the plates is in that of the length of a bone. When thus torn asunder, the lamellæ are found to be connected by fine *perforating fibres*, which pass vertically through several layers, and thus fasten them together; they are believed to be composed of white fibrous tissue.

Periosteum.—This is a fibrous membrane which covers the exterior of all bones, except where they are encrusted with cartilage. It is a tough unyielding tissue, which adds to the strength and elasticity of the bones, and adhering very firmly, forms the means of attachment of the muscles and tendons. Its principal use is to afford a support and bed to the vessels entering the bone, and it may therefore be called the nourishing membrane to the exterior of the bone. It consists of two layers. The outer, composed of fibrous tissue, supports the blood-vessels, and gives off filamentous threads which accompany the branches of the vessels into the Haversian canals; on its inner aspect, this layer contains a considerable admixture of elastic fibres. The inner layer consists of a number of protoplasmic cells (osteoblasts) which in the young bone appear as granular corpuscles, but in the old bone are found only as a flattened epithelial layer, separated from the rest of the periosteum by a narrow cleft or lymph space.

Minute Structure of Bone.—A thin layer of the exterior of a bone derives its nourishment from the periosteum, and a similar layer of the inner surface is nourished by the vessels of the marrow, but in most bones there is a considerable amount of dense tissue, which is too far removed from either to draw its support therefrom.

This intervening portion is supplied by blood-vessels which enter little channels provided for the purpose. These *Haversian canals*, as they are called, are little tubes running for the most part in the direction of the length of a bone, but so obliquely as to form frequent communications with each other, and those near the external and internal surfaces with these

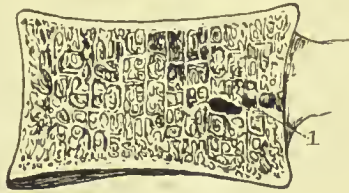


FIG. 32.—Section of the body of a vertebra—perpendicular and transverse bars. 1. Opening for vena basis vertebræ.

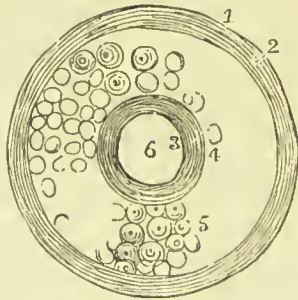


FIG. 33.—Plan of a section of a long bone. 1. Periosteum. 2. Periosteal layer of bone. 3. Inner surface of bone. 4. Peri-medullary layer of bone. 5. Dense tissue beyond the reach of the periosteal and medullary vessels constituting the Haversian system. 6. Medullary cavity.

surfaces respectively. The whole dense substance therefore is permeated by a network of tubules, so that when a thin transverse slice of bone is examined by the microscope, it is seen to be riddled with circular holes. The Haversian canals measure from $\frac{1}{1000}$ to $\frac{1}{250}$ of an inch in diameter. A perpendicular section shows the communications with each other and with the surfaces of the bone. They are largest near to the medullary surface of the bone, and are narrowest next to the periosteal layer; they contain blood-vessels, lymphatics, nerves, osteoblastic cells, and the larger ones contain marrow.

That portion of the dense tissue which derives its nourishment from the Haversian canals is arranged in concentric lamellæ (*Haversian lamellæ*), round these tubes, so that a long bone may be described as a series of hollow rods, the central canals of which are the Haversian canals, bound together by an exterior wrapper consisting of several layers of lamellæ (see Fig. 33).

An Haversian canal and its concentric lamellæ together form an *Haversian system*; as these systems are round or oval, irregular intervals are left where they join; these are filled in by layers irregularly disposed and called *interstitial* or *intercalary lamellæ*.




FIG. 34.—Vertical section of tibia, showing the network of Haversian canals.

A further provision exists for bringing the nutritive fluid into more close relation to the bone substance than can be accomplished by the vascular membranes or Haversian canals. The whole of the dense tissue is permeated by extremely minute channels called **canaliculi**. These pass through the periosteal and perimedullary layers at right angles to their surfaces, and radiate from the Haversian canals. They are smaller in calibre than the smallest capillaries, and serve to conduct the nutritive fluid to the denser tissue. The canaliculi which radiate out from the Haversian canals are interrupted in their passage to the more distant concentric lamellæ by pouring their contents into little oval cavities called the **lacunæ** of bone. They are arranged in circles between the lamellæ, and into their sides next the canals numerous canaliculi enter, while from the further side still more numerous canaliculi diverge towards the circles of lacunæ further out. The lacunæ therefore serve as reservoirs into which fluid from the vessels in the Haversian canals is poured on the one hand, and on the other they pass it on to the outer circles of bone. In this way the nourishment of those parts of bone most distant from the nutrient membranes is provided for by this intricate series of little channels and communicating reservoirs (fig. 35).

In recent bones the lacunæ are occupied by nucleated masses of protoplasm, and the canaliculi by slender threads of the same substance, by means of which the masses in the lacunæ communicate with one another.

The lacunæ and their corresponding canaliculi are to be found in all parts of a bone, and in bones however thin—although Haversian canals are only found in those of some thickness. In the periosteal and perimedullary layers of long bones, and in very thin bones, their arrangement has reference to the surface

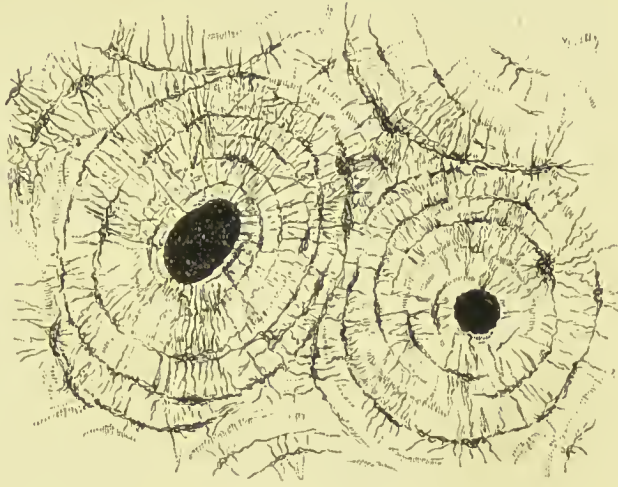

FIG. 35.—Transverse section of a long bone, showing the Haversian systems, Haversian canals, concentric lamellæ, canaliculi, and lacunæ.

of the bone. In cancellous tissue the bone spicules are devoid of Haversian canals, and the canaliculi open into the cancellous spaces; the latter are occupied by marrow, and hence are named *medullary spaces*.

Lymphatic vessels are found in the periosteum, and in the larger Haversian canals; nerves are distributed to the periosteum, and pass into the interior of the bone along with the arteries.

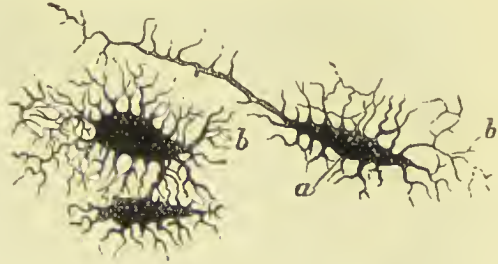

FIG. 36.—Lacunæ magnified 500 diameters. *a*. Central cavity. *b*. Canaliculi.

Medulla or Marrow of Bones.—Marrow occurs in two forms. In the medullary cavities of long bones it is found of a pale yellow colour and consists of fine, branching connective tissue corpuscles supporting fat vesicles; in the cancellated ends of long bones and in short bones, the bodies of the vertebræ, sternum, and ribs, but especially in the cranial *diploë*, it is reddish in colour, contains little fat, and is remarkable for the presence of a large number of round granular cells resembling the white corpuscles of the blood (lymphoid cells), and, like them, being capable of amæboid movement. Amongst these are smaller cells which have a faint red colour; they are nucleated, and resemble the red corpuscles of the blood of the embryo. In both kinds of marrow there are

also found large isolated cells with many nuclei, called *giant cells* or *myeloplaxes*.

Development of Bone.—The majority of the bones are developed from cartilage, which forms a mould of the same shape as the bone to be formed, but the tabular bones of the skull and nearly all the bones of the face are formed between two layers of membrane without the presence of cartilage, and after the bones have been once formed, their further enlargement or growth takes place chiefly by the deposit of osseous matter beneath the periosteum. We have thus three modes of ossification—*intracartilaginous*, *intramembranous*, and *subperiosteal*—but as the two latter are essentially the same, only two forms fall to be described here.

Intramembranous Ossification.—The bones formed without a preceding cartilaginous matrix are, the upper part of the frontal, parietal, upper part of occipital, nasal, lachrymal, palate, vomer, zygoma, upper jaw and greater part of lower jaw, and inner layer of sphenoidal spongy bones (Kölliker). If we examine a parietal bone about the period of commencing ossification, we shall find that the intermediate space between the pericranium on the outside and the dura mater within is occupied by a membranous structure consisting of delicate translucent fibres, among which fusiform and stellate cells are distributed. In the centre of the bone a deposition

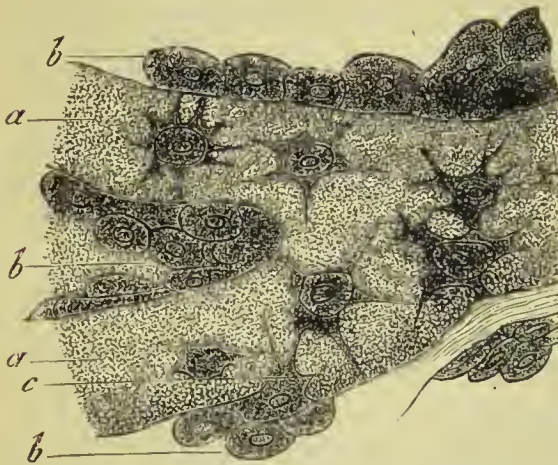

FIG. 37.—Osteoblasts from the parietal bone of a human embryo thirteen weeks old. *a*. Bony septa, with the cells of the lacunæ. *b*. Layers of osteoblasts. *c*. The latter in transition to bone corpuscles.

of calcareous salts takes place in this membrane, and spreads from the centre towards the circumference in radiating lines, connected together by transverse bars irregularly disposed. The osseous spicules are coated over with a soft transparent substance which has been called "osteogen," and upon this groups of cells may be observed. The cells are very closely aggregated so as often completely to cover the spicules; they are granular in character, and of large size, and, as it is believed that they

are the active agents in the production of bone, they have been named "osteoblasts." Many of the cells get embedded in the new bone, and, being compressed by it, become irregular in outline; they give off fine thread-like processes, by means of which they communicate with neighbouring cells. From the presence of these cells and their processes, cavities and canals are necessarily left in the

new bone, and these form the lacunæ and canaliculi. Vessels penetrate from the surface into the growing bone, and becoming enclosed in the calcareous deposit, determine the formation of the Haversian canals, and, in the tabular bones of the skull, of the cranial *diploë*. As the ossification commences in the centres of the tabular bones and spreads to the circumference, their angles are necessarily the last to ossify, so that at the time of birth, and for some months afterwards, spaces are left between the bones, filled by membrane only.

Intracartilaginous Ossification.—Before the commencement of ossification, the cartilage cells are small in size, have a rounded form, and are evenly distributed throughout the matrix. The first indication of approaching ossification is, that these cells become more numerous, increase in size, and become oval in form. Blood-vessels also, which have hitherto been absent, are now observable in the softened and changing cartilage; these grow from the perichondrium in tufts, and are surrounded by a layer of imperfectly formed connective tissue. Another noticeable feature may also be observed in a section of a bone in which ossification has commenced, namely,

that near the ossific centre, the cartilage cells come to be arranged in rows placed vertically to the surface of the new bone. Between these rows calcareous matter gets deposited, forming trabeculæ,

FIG. 38.—Vertical section through cartilage and incipient bone of the shaft of the femur of an infant a fortnight old. *a.* Rows of cartilage cells. *b.* Line of ossification. *c.* Close osseous network, first formed. *d.* Looser structure resulting from reabsorption.

and as development advances, bands are thrown across to join neighbouring trabeculæ; the rows of cartilage cells come thus to be enclosed in spaces (*primary areolæ*), the walls of which are formed by calcareous matter.

At the same time, a deposit of bony matter is taking place beneath the periosteum, through the agency of the osteoblastic cells de-

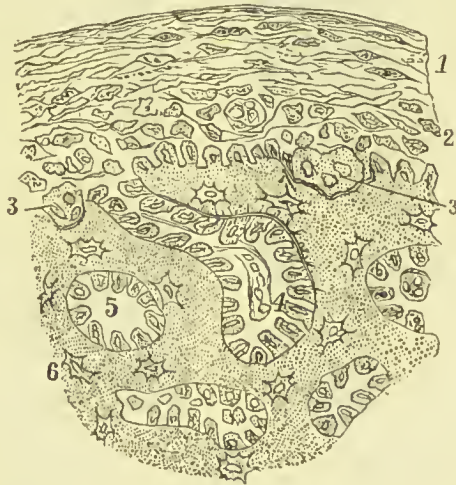

FIG. 39.—Intrusion of periosteal osteoblasts in intracartilaginous ossification. 1. Fibrous layer of periosteum. 2. Osteoblastic layer. 3. Giant cells. 4. Periosteal cells penetrating into calcified cartilage. 5. The same cells completely cut off from their periosteal connection. 6. Cells imbedded in new bone and determining the formation of lacunæ.

scribed above as lining its inner surface. This process is, in its essential particulars, identical with intra-membranous ossification. Very

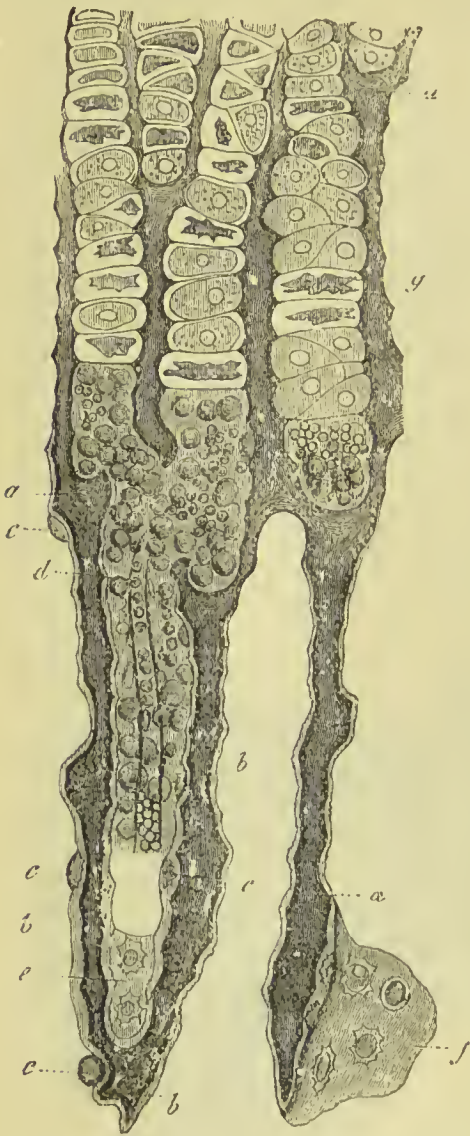


FIG. 40.—Vertical section from the ossifying portion of the shaft of a long bone. *a*. Cartilage. *b*. Bone. *c*. Newly-formed bone cells in profile, more or less embedded in intercellular substance. *d*. Medullary cavity in process of formation with vessels and medullary cells. *e*, *f*. Bone cells on their broad aspect. *g*. Cartilage capsules arranged in rows, and partly with shrunken cell bodies.

soon, however, the vascular and osteoblastic subperiosteal tissue penetrates into the cartilage of the centre, and where it comes in contact with the calcified matter causes its absorption, thus breaking down the walls of the primary areolæ and forming larger spaces, called *secondary areolæ* or *medullary spaces*. Where this has taken place, it is found that in the spaces so formed, the cartilage cells have disappeared, and that the cavity is filled with embryonic marrow, consisting of branched cells, osteoblasts, and blood-vessels. Most of the osteoblasts are derived from the subperiosteal layer, but it is probable that some are formed from the cartilage cells. There are thus two processes going on at the same time, one an endosteal change, taking place in the cartilage, and the other an intrusion of cells of subperiosteal origin.

The walls of the medullary spaces are at first very thin, but they soon become thickened by deposits in the osteoblasts by which they are lined.

Some few of the osteoblastic cells become converted into scattered connective tissue, others retain their original shape, and form the round or lymphoid cells of the medulla, while the larger number are the active agents in the production of bone. They line the medullary sinus, and a deposit of calcareous salts takes place in them; as this deposition advances, layer after layer of the cells takes part in the process,

and the deposition in successive layers around a central blood-vessel results in the formation of concentric laminæ around the Haversian

canal. Many of the cells become embedded in the new deposit, and remain throughout life, the cavities in which they lie constituting the lacunæ, and by their communication with neighbouring cells they establish a series of smaller pores in the bone, which we have spoken of as canaliculi.

The medullary sinuses nearest the centre of a long bone become enlarged by further absorption of their walls, and merge into each other, so as to form a single cavity, which is filled with marrow and remains as the *medullary canal*. Many of the smaller spaces also retain their marrow and are not filled up by bone; they then form the cavities—and their walls form the fine spicules—of cancellous tissue.

The growth of long bones takes place in length by the further ossification of the growing cartilage (*epiphysial cartilage*) between the shaft and extremity, and in thickness by the deposition of new bone between the periosteum and the shaft, this being always accompanied by reabsorption of the interior, so that the medullary canal becomes increased in size. This absorption is brought about by the agency of large cells of varying shape and size, having many clear nuclei, which are numerous in foetal marrow and have been spoken of above as myeloplaxes or giant-cells; here, however, they receive the name of *osteoclasts*. Subperiosteal growth takes place by a process identical in all essential particulars with what we have described above as intramembranous ossification.

Cartilaginification is complete in the human embryo at about the sixth week; and the first point of ossification is observed in the clavicle at about the fifth week. Ossification commences at the centre, and thence proceeds towards the surface; in flat bones the osseous tissue radiates between two membranes from a central point towards the periphery, in short bones from a centre towards the circumference, and in long bones from a central portion, *diaphysis*, towards a secondary centre, *epiphysis*, situated at each extremity. Large processes, as the trochanters, are provided with a distinct centre of development.

MUSCLE.

Muscles are the moving organs of the animal frame; they constitute by their size and number the great bulk of the body, upon which they bestow form and symmetry. In the limbs they are situated around the bones, which they invest and defend, while they form to some of the joints a principal protection. In the trunk they are spread out to enclose cavities and constitute a defensive wall, capable of yielding to internal pressure, and again returning to its original position.

Their colour presents the deep red which is characteristic of flesh, and their form is variously modified, to execute the varied range of movements which they are required to effect.

Muscular fibres are of two kinds, **voluntary** and **involuntary** the former are the most numerous, forming the great muscular masses which move the several parts of the body; the involuntary muscular fibres assist in forming the walls of the hollow viscera, and the middle coat of arteries and veins; they are also found in the iris, ciliary muscle, and the bronchial tubes. Peculiarities in their structure also lead to muscular fibres being distinguished as **striated** and **non-striated**, the striated being voluntary in their action, and the non-striated involuntary, with the exception of the

heart, which, although involuntary in its action, is composed of striated muscular fibre.

Striated or voluntary muscular fibres are collected into bundles, held together by delicate areolar tissue, and enclosed in a sheath or *perimysium*, formed of areolar tissue, with an admixture of elastic tissue, which also sends processes inwards between the fibres (*endomysium*). These bundles are called *fasciculi*, they are prismatic in shape, and of different sizes in different muscles, the apparent coarseness or fineness of a muscle depending chiefly on the size of the fasciculi. The fibres themselves are cylindrical, or oval in shape, and are nearly uniform in size. They average $\frac{1}{750}$ to $\frac{1}{400}$ of an inch in diameter, but in the facial muscles the fibres are much finer, some of them not exceeding $\frac{1}{2400}$ of an inch. Each fibre is enclosed in a sheath of transparent, apparently homogeneous, membrane, the *sarcolemma* or *myolemma*.

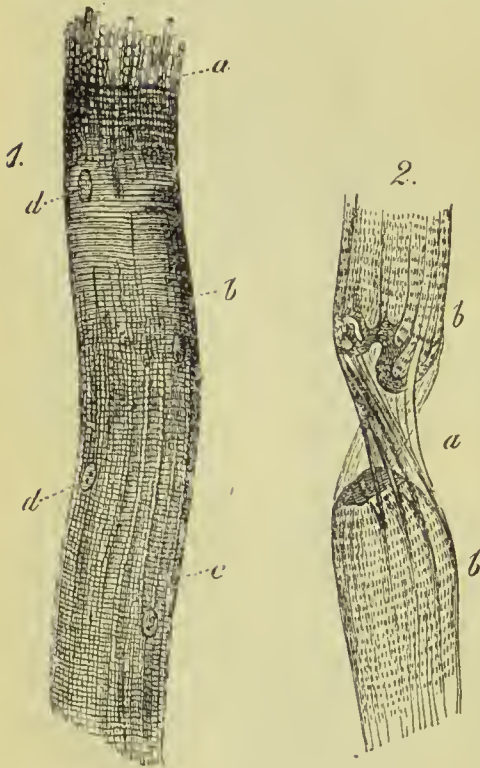


FIG. 41.—1. Striated muscle fibre breaking up into primitive fibrillæ, *a*; more distinct striation at *b*, and longitudinal lines at *c*; *d*, nuclei. 2. A fibre, *b*, torn through at *a*, with the sarcolemma partially empty and visible.

So delicate is this structure that it only becomes visible when the contained fibrils become ruptured, as in fig. 41. It is rather tough, and resembles elastic tissue in its physical and chemical properties. When examined under a high microscopic power the muscular fibres are found to be marked at regular intervals by transverse striae; these are the characteristic markings which distinguish this kind of muscle, not only from the unstriped variety, but also from every other tissue in the body. The stripes are alternately light and dark, each stripe being about $\frac{1}{17000}$ of an

inch in width. The light stripe is crossed by a fine dotted line or secondary dark stripe (*Dobie's line*, or *Krause's membrane*). Some anatomists suppose that the dark portions are occupied by a peculiar semi-fluid material, called "*sarcous matter*" (the individual dark spaces being called "*sarcous elements*"), and the lighter portions of a more fluid and hence less highly refracting matter.

The dark stripe is sometimes crossed by a band of a slightly paler tint; this is described as the *median disc of Hensen*.

The light stripe is divided by *Dobie's line* into two portions, which have been named the *lateral discs of Engelmann*. In many muscular fibres, but especially in those of insects, high microscopic powers show the dark stripe to be made up of minute rods (*muscle-rods*) with light intervals between them; the rods are thicker at their ends and thinner and lighter in their middle.

After the fibres have been hardened in alcohol or solution of osmic acid, they can readily be divided by means of needles into longitudinal filaments or *fibrils*,

but even these may be still further divided, the finest of the filaments so obtained presenting the appearance of a series of minute dots. Under other modes of preparation, and especially by the action of hydrochloric acid, a transverse cleavage may take place, resulting in a series of minute discs (*Bowman's discs*). Whether either of these modes of division corresponds to a normal line of union of elementary parts has never yet been satisfactorily determined, some observers believing the *primitive fibrils* to constitute

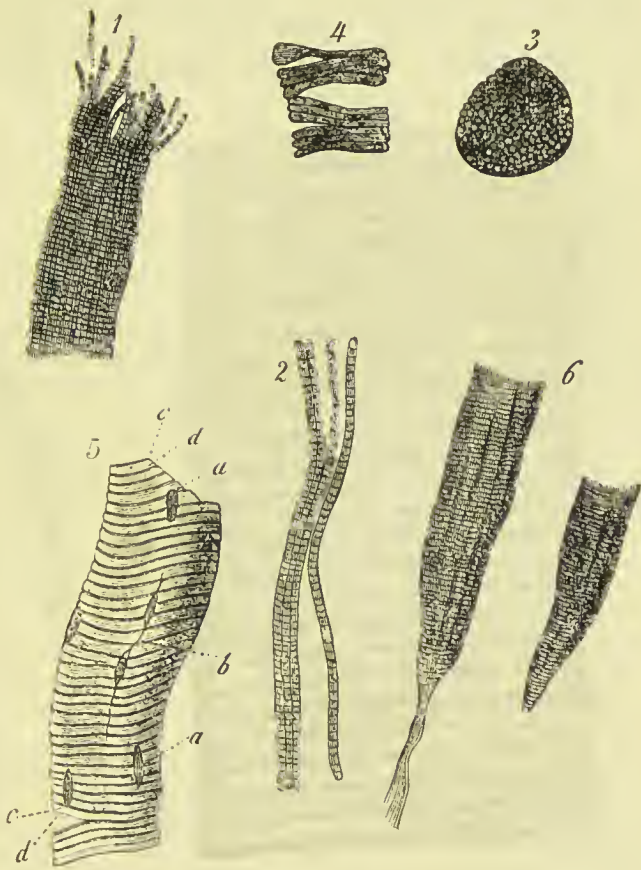


FIG. 42.—1. A muscle fibre with primitive fibrillae and transverse striation strongly marked. 2. Isolated fibrillae. 3. Sarcous elements united, forming a disc. 4. Plates of muscle after treatment with hydrochloric acid. 5. A fibre after prolonged treatment with hydrochloric acid with dark (*c*) and light (*d*) zones and nuclei (*a*, *b*). 6. Two pointed fibres from the human *biceps brachii*.

the true structural unit, and others holding that both fibrils and discs are alike accidental results of different means of preparation.

Under a high microscopic power numerous nuclei may be observed beneath the sarcolemma; they are more distinctly visible in foetal muscle, but can also be traced in that of adult life by the addition of a weak acid. They frequently contain nucleoli, and there is little doubt that they are the nuclei of the cells from which the muscle was developed. A transverse section of a muscular fibre when examined under a high power, appears to be marked out into very




FIG. 43.—Portion of a striated human muscular fibre, showing Dobie's line in the middle of the clear band (*Sharpey*).

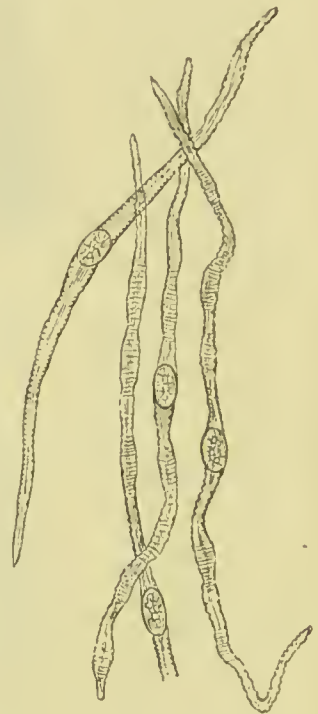


FIG. 44.—Non-striated muscular fibres from mesentery of newt.

minute polygonal portions, bounded by white lines (*polygonal areas of Cohnheim*); they are believed to be due to groupings of the ultimate fibrillæ of the muscle.

Various explanations of the transverse markings in striated muscle have from time to time been propounded, but none has hitherto met with general acceptance.

Striped muscular fibres usually neither divide nor anastomose, but an exception to this rule is found in the muscles of the tongue and of the heart, which do both. The fibres of the facial muscles also, where they are attached to the skin, frequently branch.

Non-striated, plain, or involuntary muscular fibres consist of elongated, fusiform, nucleated cells, commonly pointed at their ends, and from mutual pressure polyhedral in transverse section. They are from $\frac{1}{600}$ to $\frac{1}{120}$ of an inch in length, and from $\frac{1}{8000}$ to $\frac{1}{2500}$ in breadth. The nucleus is oval, and sometimes so elongated as to deserve the name of columnar; it contains an elaborate network of very fine fibrils and often one or more nucleoli. The body of the cell is granular, and presents traces of longitudinal striation; it has a fine sheath, probably elastic, and containing transverse linear thickenings, which here and there give the fibre a varicose appearance. The transverse lines are most distinct when the cell is contracted (Klein). The fusiform cells are united into little bundles or fasciculi by an adhesive interstitial substance, and the fasciculi, which are sometimes round and sometimes flat, are bound together into larger bundles by areolar tissue and fine elastic fibres; the interspaces of the bundles being occupied by vessels and nerves, the former in great abundance.

The fasciculi are connected by their ends with fine tendinous fibres, by means of which they become attached to neighbouring parts.

Unstriped muscle is distributed abundantly in the animal frame, and is met with in the alimentary canal, from the middle of the cesophagus to the internal sphincter ani; in the posterior part of the trachea, and in the bronchial tubes to their finest ramifications; in the excretory ducts of various glands, as Wharton's duct, the common bile duct, the calices and pelvis of the kidneys; in the capsule and trabeculæ of the spleen, the ureters, bladder, and urethra; in the vasa deferentia and vesiculæ seminales, the prostate, Cowper's glands, and in the substance of the corpora cavernosa; in the Fallopian tubes, uterus, and vagina; in the deep layer of the mucous membrane of the alimentary canal (*muscularis mucosæ*); in the middle coat of arteries, veins, and lymphatic vessels; in the iris and ciliary muscle; and in the corium of the skin, particularly in the areola and nipples of the mammary glands, in the dartos of the scrotum, and around the hair follicles, and many of the sudoriferous and sebaceous ducts.

The **muscular structure of the heart** presents certain peculiarities which distinguish it both from the striated and non-striated forms, although the presence of transverse markings leads to its being

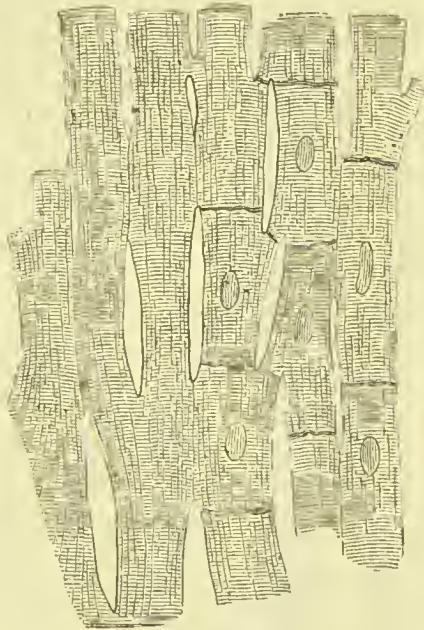


FIG. 45.—Anastomosing muscular fibres of heart. On the right the cells and nuclei are seen.

classed with the former. The striæ are more faintly marked than those of ordinary striped muscle, and the fibres are smaller, and have no sarcolemma; they are remarkable for their numerous branches and frequent anastomoses, and are formed by the union of distinct cells joined end to end. Each cell has a single nucleus near its centre and one or two nucleoli; they frequently contain small fatty granules which are greatly multiplied in fatty degeneration of the heart.

NERVE TISSUE.

The nervous system consists of *nerve centres* and of rounded or flattened cords, called *nerves*, which connect the centres with each other, and bring them into relation with the surface of the body, the muscles, and the different organs. The brain and spinal cord constitute the great nervous centre, or cerebro-spinal axis, and the great majority of the nerves spring from this centre or are connected with it. There also exists a secondary system of nerves called *sympathetic*, the centres of which occur in the form of numerous minute masses named *ganglia*, which are distributed chiefly in the thorax and abdomen, and are intimately connected with the nerves going to the organs contained in those cavities. The sympathetic and cerebro-spinal nerves have frequent communications with each other, which form complicated networks or *plexuses*.

FIG. 46.—Nerve fibres of various kinds. *a.* Showing the axis cylinder and primitive sheath. *b.* Another, with axis cylinder, after treatment with bichromate of potash. *c.* A fibre, treated with collodium, showing the axis cylinder, primitive sheath, and nodes of Ranvier. *d.* A non-medullated fibre, showing the axis cylinder and primitive sheath. *e.* A non-medullated fibre from the olfactory of the calf. *f, g, h.* Fine fibres from the brain with axis cylinders. The fibre *g* unites with the process of a ganglion cell by the branch marked *.

bro-spinal ganglia. The **structural elements** of the nervous system

The **nerve tissues** are readily separable into two forms, the *white* and the *grey*; the former constitutes the greater portion of the interior of the brain, the outer part of the spinal cord, and all the nerves which spring from these; the latter exists in the interior of the spinal cord, on the surface of the brain, in the interior of the brain near its base, and in the sympathetic and cere-

are also of two kinds, *nerve fibres* and *nerve cells*. The fibres form the channels of communication between the centres and the organs, and when gathered together into bundles form nerves; the cells are restricted in their distribution to the nerve centres, ganglia, and certain of the organs of sense.

NERVE FIBRES are of two kinds—*white* or *medullated*, and *grey* or *non-medullated*.

The **white or medullated** nerve fibres form the white matter of the brain, spinal cord, and nerves. When examined immediately after removal from the body they seem to be structureless, and are bounded by a wavy outline. In a short time, however, their appearance changes, and they come to present a double boundary line; the fibre now consists of three parts, an outer delicate, transparent covering, a central thread, firm and solid in consistence, and between these a substance which has a wavy or irregular margin, and often a nodulated aspect. The outer layer is called the *primitive sheath* or *neurolemma*; it is so fine and transparent as to be difficult of demonstration, and, indeed, it is only when a break takes place in the substance of the fibre that it becomes visible; it is elastic and apparently structureless. The primitive sheath disappears when nerves enter the substance of the brain or spinal cord, and is also absent from many nerves in their peripheral distribution.

Beneath the primitive sheath at wide intervals are small nucleated masses of protoplasm; they are the *nerve corpuscles*; they correspond to the nuclei found beneath the sarcolemma of muscle, but are much less numerous.

The pulpy substance which lies between the primitive sheath and the central thread is called the *medullary sheath* (*white matter of Schwann*). It is viscous, clear, transparent, and easily susceptible of coagulation, and is converted in its coagulated state into an opaque, granular, white substance. It is found to consist to a large extent of fatty matter, and, after nerves have been some time removed from the body, becomes irregular in outline, its margins become



FIG. 47.—Medullated nerve fibre. *a*. Axis cylinder. *s*. Medullary sheath. *n*. Nucleus. *p*. Granular protoplasm around nucleus. *r*. Node of Ranvier. *i*, *i*. Dissepiments in medullary sheath.

wrinkled, and portions of it assume the form of round or irregular nodules; these changes are presumably the result of a kind of coagulation.

The centre of the fibre is formed by a firmer and more homogeneous band called the *axis cylinder*. It is elastic, greyish in colour, has a very faint and indistinct boundary line, and is generally flattened or oval in transverse section; it is about one-third the thickness of the nerve fibre. It often presents traces of longitudinal striation, and may occasionally be split up into fine filaments, this taking place especially at the commencement and termination of a nerve; these filaments have been regarded by some observers as the ultimate structural elements of the nerve, and have hence been called *primitive fibrillæ*. Each axis cylinder is continuous with one of the poles of a ganglionic cell. It is distinguished from the other parts of the nerve fibre by its becoming deeply coloured, when a thin section of fresh nervous matter is placed in a solution of carminate of ammonia, while the primitive sheath becomes only faintly tinged, and the medullary sheath is totally unaffected by the reagent. The axis cylinder has also a great affinity for gold salts, becoming stained violet-black when placed in solutions of them; when treated with nitrate of silver and exposed to light it shows transverse striæ, these being most marked near to the nodes of Ranvier; they are known as *Frommann's lines*.

Nodes of Ranvier.—Medullated nerve fibres present breaks in the continuity of their structure at intervals of about $\frac{1}{5}$ of an inch. At these points the axis cylinder is continued uninterruptedly; the primitive sheath also passes over the breaks, but as the fibre is here smaller than elsewhere, the sheath is drawn inwards towards its centre. The medullary sheath is, however, completely interrupted, terminating by a rounded edge. The primitive sheath is separated from the axis cylinder by a small quantity of material of an albuminous character, and corresponding in its behaviour with reagents to the intercellular substance which we have spoken of, as cementing together neighbouring cells. These breaks in the nerve fibre have been named from their discoverer the **Nodes of Ranvier**.

Non-medullated or Gelatinous Nerve Fibres (*fibres of Remak*) are found in the great nerve centres as continuations of the medullated fibres; they also constitute the greater number of the fibres of the sympathetic, and the whole of the olfactory nerves in man. In the brain and spinal cord, they are connected with the processes of the multipolar nerve cells, and serve to connect the medullated fibres with those cells. They are pale in colour, flattened, and bounded by single contour lines; they measure from $\frac{1}{8000}$ to $\frac{1}{5000}$ of an inch in diameter. In structure they are found to consist of a transparent, apparently homogeneous sheath corresponding to the primitive sheath of the medullated fibres, beneath which are numerous oval nuclei. The interior of the fibre consists of a substance corresponding in every particular to the axis cylinder of medullated fibres, and made up of bundles of exceedingly fine

primitive fibrillæ. Non-medullated fibres may thus be regarded as medullated fibres devoid of a medullary sheath.

NERVE CELLS.—These are found in the grey matter of the brain and spinal cord, and in the cerebro-spinal and sympathetic ganglia. They are of various shapes and sizes. Some in the grey matter of the cortex of the brain, in the posterior horn of the grey centre of the spinal cord, and in certain ganglia, are spheroidal, and of very small size. The majority of the nerve cells are, however, distinguished by possessing processes or “poles” by means of which they become connected with each other, and with the nerve fibres passing into the grey centres. A few of the cells possess only one process, and are called *unipolar*, others have two processes, and are called *bipolar*, but the greater number have many processes which branch and form elaborate connections with neighbouring cells and nerve fibres; they are named *multipolar cells*. Many of the nerve cells found in the surface grey matter of the brain are triangular in shape, having their bases directed towards the centre of the brain, and their apices towards the free surface; from their angles they give off

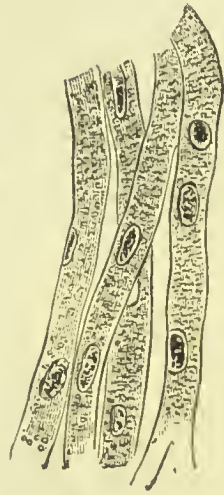

FIG. 48.—Gelatinous nerve fibres from olfactory nerve.

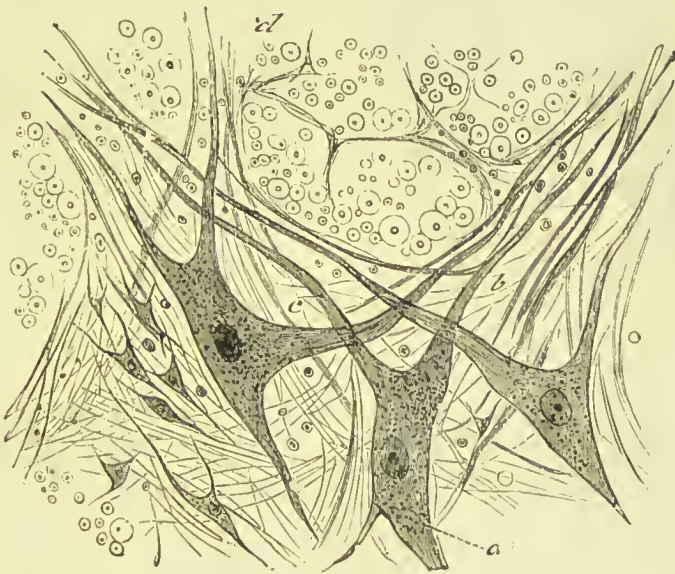

FIG. 49.—Multipolar cells from the anterior grey column of the spinal cord of the dog-fish (*a*) lying in a texture of fibrils; (*b*) prolongation from cells; (*c*) nerve-fibres cut across.

fine processes. Nerve cells vary in size from $\frac{1}{5000}$ to $\frac{1}{200}$ of an inch in width; they have each one or more clear transparent nuclei, in the centre of each of which a nucleolus is visible.

The cell protoplasm is often granular, of a light brown or greyish colour, and presents traces of striation, such as we noticed in the axis cylinder of medullated nerve fibres; not unfrequently it contains deposits of brown pigment. No distinct limiting membrane or cell wall has been ascertained to exist, but each cell is lodged in a kind of capsule composed of fine connective tissue, and lined by a delicate layer of flattened epithelial cells. The cell processes are composed of protoplasm of the same nature as the cell itself; they also present traces of fibrillation, and are likewise destitute



FIG. 50.—Multipolar ganglion cells from the brain. 1. A cell, one of whose processes (*a*) becomes the axis cylinder of a nerve fibre (*b*). 2. A cell (*a*) connected with another (*b*) by means of a commissure (*c*). 3. Diagram of three cells (*a*) connected by means of commissures (*b*), and running into fibres (*c*). 4. A multipolar cell containing black pigment.

of a limiting membrane. One or more processes of each nerve cell may be traced into a nerve fibre, becoming continuous with the axis cylinder of the fibre; other processes become continuous with the "poles" of neighbouring cells. From the fact that nerve cells were first discovered in ganglia, they are often called "ganglion cells;" the true ganglion cell, however, differs from the cells above described, in respect that the primitive sheath of the nerve frequently is continued as a covering over the cell, and in some

instances the medullary sheath also may be traced as a thin coating over its exterior.

Neuroglia.—The proper substance of the nervous centres (nerve fibres and nerve cells) is supported by a peculiar modification of connective tissue, described by Virchow under the name of *neuroglia*. This bears a close resemblance to the *reticular tissue*, described on a previous page, consisting of a reticulum formed by the intercommunication of processes of greatly branched cells. Besides this, there exists a finely granular matrix, in which the nerve cells are embedded.

GANGLIA.—In its widest signification a ganglion is a nervous centre, whether found in the interior of the brain or spinal cord, or existing in an isolated position, remote from those great aggregations of nerve matter; in a more restricted sense it is limited to those small secondary centres found in large numbers throughout the sympathetic system in connection with the roots of the spinal nerves, and on the trunks, or connected with some of the branches of the cerebral nerves. Ganglia have a fibrous covering, continuous with the sheath of the nerves entering and leaving them; from this capsule processes are sent into the interior of the ganglion, dividing it into compartments. The interior of the ganglion is of a greyish colour, and consists of nerve cells and nerve fibres, supported by connective tissue. The nerve cells are round, oval, or multipolar, and are covered by a continuation of the primitive sheath of the nerves, and sometimes also by the medullary sheath. Some of the nerve fibres pass through the ganglion without becoming connected with the cells, others terminate in the branches of the multipolar cells, their axis cylinder becoming continuous with the protoplasm of the cell process. Large pyriform ganglion cells are occasionally found in the sympathetic system; every ganglion cell of this kind is connected with at least two nerve fibres, one of which is straight, and passes directly to the centre of the cell; the other winds spirally round the first, and is traceable for some distance on the outer surface of the cell. According to Arnold the central fibre is connected with the

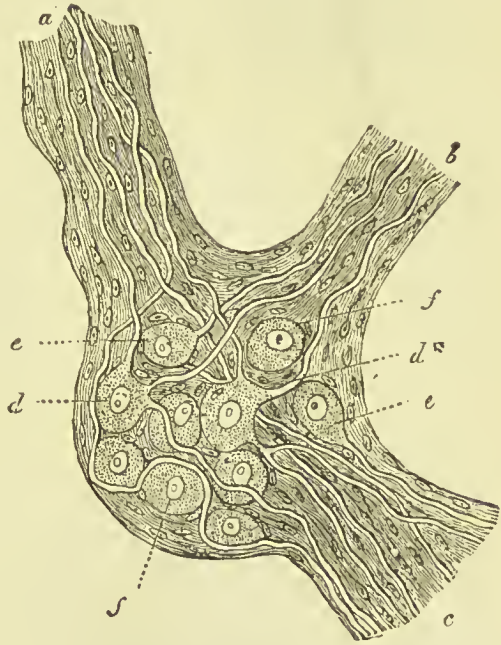


FIG. 51.—Sketch of a sympathetic ganglion. *a, b, c.* Nerve trunks. *d.* Multipolar cells. *d*.* Axis cylinder of nerve joining pole of cell. *e,* unipolar, and *f,* apolar cells.

nucleus of the cell and the spiral fibre with the nucleolus. The two fibres on leaving the cell run in opposite directions in the nerve with which the ganglion is connected.

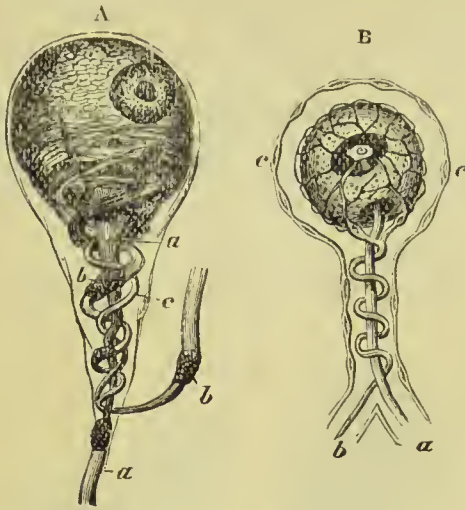


FIG. 52.—Structure of ganglionic nerve cell. A. According to Beale. B. According to Arnold. a. Central fibre. b. Spiral fibre. c. Capsule of ganglion.

A **commissure** is a collection of nerve fibres acting as a link of communication between two nerve centres.

A **nerve** is a rounded or flattened cord of nerve fibres which forms the channel of connection between the nerve centres and all the parts of the body. The nerve cords are surrounded by a strong sheath of fibrous membrane called *epineurium*, which not only preserves their rounded form, but forms septa which pass into the interior of the cord, subdividing it into a number of strands or *funiculi*. Each funiculus is also surrounded by a membrane called *perineurium*, composed of fine connective tissue arranged in concentric lamellæ, with lymph clefts between them; in the surface layers, there is a preponderance of elastic tissue. The lamellæ are lined on both their surfaces by a single layer of flattened epithelial cells. The nerve fibres in each funiculus are held together by very fine connective-tissue fibres, forming the *endoneurium*; these run longitudinally, and serve to support the blood-vessels distributed to the nerve.

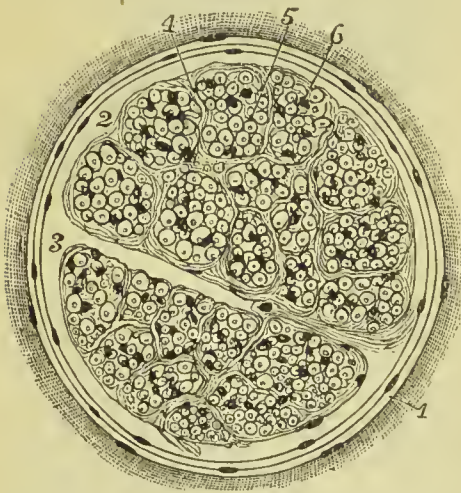


FIG. 53.—Section of a small nerve. 1. Perineurium. 2. Lymph space beneath perineurium. 3. Lymph space penetrating into centre of nerve. 4. Endoneurium. 5. Nerve fibres cut across. 6. Nuclei of endoneurium.

substance so as to become complex in structure, but in such cases the individual nerve fibres do not as a rule communicate with

Branching of Nerves.—A branch of a nerve consists of several funiculi which leave the parent trunk and become invested with an epineurium derived from its sheath.

Inosculation or Communication.—Nerves frequently form junctions of a portion of their

each other, but remain separated by their medullary and primitive sheaths. In the nervous centres, however, in the peripheral distribution of the nerves, and, in rare instances, in their trunks, the fibres themselves branch and form communications, so as to produce a true anastomosis. Nerve tubules by their medullary sheath are insulated throughout their whole course.

Plexus.—A plexus is an intricate intercommunication between the funiculi of adjacent nerves.

Origin.—The *apparent* origin of a nerve is where it becomes connected with the surface of a nerve centre. The *real* origin is where its fibres terminate in the substance of its nerve centre—often far away from where it plunges into the nerve surface. It is very difficult to trace accurately the deeper connections of the extremities of nerve fibres, but as in many instances they have been observed to be directly connected with multipolar cells, the opinion is becoming general that all nerve fibres have a central connection with a nerve cell.

NERVE TERMINATIONS.—Nerve fibres, whether of the medullated or non-medullated variety, when they approach their termination, freely branch, and form numerous communications among themselves, the medullated fibres lose their medullary sheath, and become indistinguishable from the non-medullated kind. The axis cylinder takes part in the branching of the fibres, and becomes split up into very fine threads, consisting of only a few elementary fibrils. The primitive sheath is continued as a covering to the divided fibres, for some distance after they have lost their medullary sheath, but at length becomes also lost; and the fine pale fibrils which form the termination of the nerve may then be traced as faint lines having a wavy course, and marked at short intervals by irregular varicosities.

Sensory or afferent nerves and **motor or efferent** nerves have very different modes of termination, and require therefore a separate description.

Sensory Nerve Endings.—Sensory nerves terminate either in epithelial cells, as in the cornea and skin, or by special terminal organs, some of which fall to be described here, while others will come under consideration in the description of the organs of sense to which they belong. We shall in this place speak only of the *Pacinian corpuscles*, and the *end bulbs* of Krause, leaving the *rods* and *cones* of the retina, the *cells of Corti* and *acoustic filaments* of the internal ear, the *taste buds* of the tongue, the *olfactory cells* of the nose, and the *tactile corpuscles* of the skin to be discussed in the description of the organs in which they are found.

The Pacinian or Vater's Corpuscles are small oval or pyriform masses, varying in size from half a line to three lines in length, situated on the peripheral extremities of the nerve fibres, chiefly in the palm of the hand and sole of the foot, but also found in other parts, as the penis and clitoris, bulb of the urethra, on the intercostal nerves, branches of the sacral plexus, on the cutaneous nerves of the

neck, arm, and leg, and dorsum of the hand and foot, infraorbital nerve, and on the nerves of the periosteum, nipple, and mamma, and those distributed to joints. It has been calculated that in the palm of the hand and palmar surface of the fingers there are six hundred of these bodies, and at the extremities of the fingers they are especially numerous. They are situated for the most part in the subcutaneous areolar tissue, are clear, transparent, and glistening in appearance, and traversed internally with white streaks. In structure a Pacinian body is composed of from twenty to sixty concentric

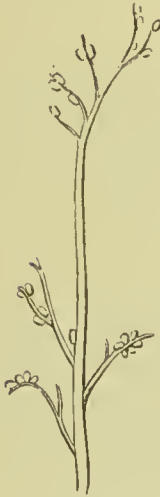

FIG. 54.—Portion of a digital nerve, showing the disposition of the Pacinian corpuscles.

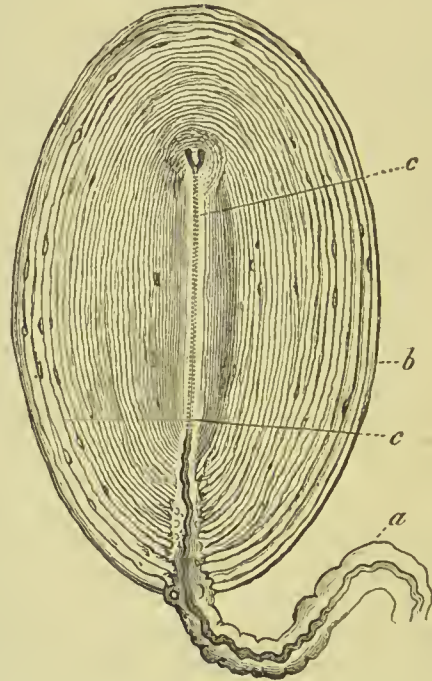


FIG. 55.—Pacinian corpuscle from the mesentery of a cat. *a*. A nerve forming the stalk. *b*. The system of capsules. *c*. Axial canal or internal bulb, within which the axis cylinder ends forked.

layers or capsules of areolar tissue, separated by spaces containing lymph, and having a central cavity also filled with lymph which contains the free extremity of a nerve fibre, divested of its sheath and medulla and reduced to the condition of an axis cylinder. The intercapsular spaces are wider between the external than the internal layers, and each capsule is lined by a single layer of squamous epithelial cells; neighbouring capsules are often branched and connected with each other by fibres. The central stalk of the corpuscle consists of the medullated nerve fibre entering it, and the sheath of the nerve may be traced into the outer layers of the capsule. The axis cylinder included within the central cavity ends

in a small rounded tubercle, and not unfrequently is bifid or even trifid.

The **end bulbs of Krause** have been ascertained to exist in the sclerotic conjunctiva, the mucous membrane of the floor of the mouth, the soft palate and tongue, the lips, and in the skin of the glans penis and glans clitoridis. They are usually spheroidal or oval in shape, and measure about $\frac{1}{600}$ of an inch in diameter. They consist of a capsule of connective tissue containing a soft substance which is transparent and apparently granular, and has embedded in it numerous oval nuclei. A medullated nerve fibre enters its under surface, and as it passes in, generally loses its medullary sheath; the axis cylinder may be traced into the central matrix, where it terminates by dividing into two or more branches. They thus closely resemble the Pacinian corpuscles. The end bulbs which pass to the genital organs differ in some respects from those just described, and have been named *genital nerve corpuscles*; they are characterised by the existence of numerous constrictions which give them a mulberry-like appearance.

Motor Nerve Endings.—Of these there are two varieties; namely, those passing to striated muscle, and those distributed to the non-striated. The former have received the name of *motorial end plates*. The nerves passing to a voluntary muscle retain their medullary sheath, and primitive sheath, till they reach the sarcolemma, when the former ceases, and the latter becomes continuous with the sarcolemma. The axis cylinder pierces the sarcolemma and expands beneath it, so as to produce a prominence (*nerve eminence*), often divided into lobes, and containing many clear oval nuclei. In unstriped or involuntary muscle the nerve fibres are arranged in very fine plexuses over the surface of the muscle cells, and some histologists state that the terminal filaments can be traced into the nucleus or nucleolus of the cell.

SYMPATHETIC NERVE.—The sympathetic or ganglionic nerve, or system of organic nerves, has received its various designations from its numberless communications and anastomoses, from its com-

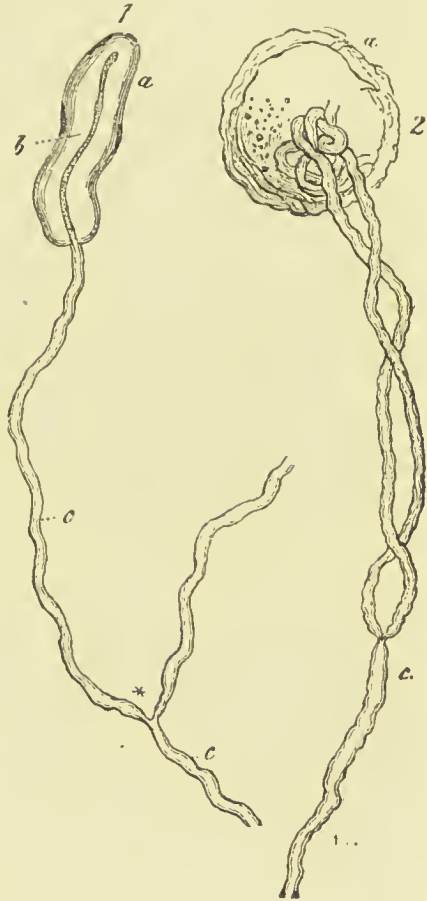


FIG. 56.—End bulbs. 1. From the conjunctiva of a calf. 2. From that of a human being. a. Bulb. b. Nerve fibre ending in an axis cylinder (b). c. Nerve fibre.

position of a series of ganglia, and from its distribution chiefly to the viscera of the body. It consists of a cord of moderate thickness, which extends from the head to the coccyx, lying by the side of the vertebral column; of a series of ganglia, some of which are fusiform and others flattened and multangular; of short branches of communication from the spinal nerves; and of peripheral branches, which for the most part follow the trunks of arteries, and are distributed to the viscera, after uniting with ganglia in their course, or forming smaller ganglia in their distribution. The elementary constituents of the ganglionic nerve are: medullated nerve fibres of every degree of magnitude from coarse to fine, non-medullated or ganglionic nerves, and nerve cells. The medullated nerve fibres are derived from the anterior and posterior roots of the spinal nerves, chiefly from the latter; entering the ganglion, they divide into an ascending and descending fasciculus, which pass upwards and downwards along the main trunk of the nerve, or pass off with the larger branches in company with ganglionic nerves. The non-medullated fibres originate in the multipolar cells of the sympathetic ganglia.

In their peripheral terminations the branches of the sympathetic nerve present numerous minute, almost microscopic ganglia, which are especially remarkable on the carotid arteries, in the pharyngeal plexus, upon the heart, around the root and in the substance of the lungs, upon the supra-renal capsule, on the lymphatic glands, on the posterior wall of the urinary bladder, and in the kidneys. In structure these ganglia are identical with the larger ganglia.

BLOOD-VESSELS.

The blood is distributed throughout the body by means of a series of tubes, which proceed from the heart, ramify through all the organs and tissues, and again return to the heart; thus the blood in its course constantly returns to the centre from whence it was sent forth, and it is this which constitutes the *circulation*. The tubes which carry the blood are called blood-vessels; they are of three kinds—namely, those which convey the blood from the heart to the tissues, **arteries**; those which run through the tissues and organs, **capillaries**; and those by means of which the blood is returned from the tissues to the heart, **veins**.

The artery proceeding from the left ventricle of the heart contains the pure or arterial blood, which is distributed throughout the entire system, and constitutes with its returning veins the *greater* or *systemic circulation*. That which emanates from the right ventricle conveys the impure blood to the lungs; and with its corresponding veins establishes the *lesser* or *pulmonary circulation*.

ARTERIES.

The **arteries** are the cylindrical tubes which convey the blood from the ventricles of the heart to every part of the body. They are dense in structure, and preserve for the most part the cylindrical form when emptied of their blood, which is their condition after death: hence they were considered by the ancients as the vessels for the transmission of the vital spirits, and were therefore named arteries (*ἀήρ τηρεῖν*, to contain air).

The whole of the arteries of the systemic circulation proceed from a single trunk, named the *aorta*, from which they are given off as branches, and divide and subdivide to their ultimate ramifications, constituting the great arterial tree which pervades by its minute subdivisions every part of the animal frame. From the aorta the branches for the most part pass off at right angles, as if for the purpose of checking the impetus with which the blood would otherwise rush along their cylinders from the main trunk; but in the limbs a very different arrangement exists; the branches are given off from the principal artery at an acute angle, so that no impediment may be offered to the free circulation of the blood. The division of arteries is usually dichotomous, as of the aorta into the two common iliaes, common carotid into the external and internal, &c.; but in some few instances a short trunk divides suddenly into several branches which proceed in different directions: this mode of division is termed *axis*, as the thyroid and celiac axis.

In the division of an artery into two branches, it is observed that the combined area of the two branches is somewhat greater than that of the single trunk; and if the combined area of all the branches at the periphery of the body were compared with that of the aorta, it would be seen that the blood, in passing from the aorta into the numerous distributing branches, was flowing through a conical space, of which the apex might be represented by the aorta, and the base by the surface of the body. The advantage of this provision in facilitating the circulation is sufficiently obvious; for the increased channel which is thus provided for the current of the blood, serves to compensate for the retarding influence of friction, resulting from the distance of the heart and the division of the vessels.

The main arteries of the limbs run on the flexor aspect, as they are in that situation less liable to external injury or to over-stretching in the movement of the joints, than if placed on the extensor aspect.

Communications between arteries are free and numerous, and increase in frequency with the diminution in size of the branches; so that, through the medium of the minute ramifications, the entire body may be considered as one uninterrupted circle of *inosculations* or *anastomoses* (*ἀνά*, between, *στόμα*, mouth). This increase in the frequency of anastomosis in the smaller branches is a provision for counteracting the greater liability to impediment existing in them

than in the larger branches. Where freedom of circulation is of vital importance, this communication of the arteries is very remarkable, as in the circle of Willis in the cranium. It is also strikingly seen in situations where obstruction is most likely to occur, as in the distribution to the alimentary canal, around joints, or in the hand and foot. Upon this free communication existing everywhere between arterial branches is founded the principle of cure by the ligature of large arteries; the ramifications of the branches given off from the artery above the ligature inosculate with those which proceed from the trunk of the vessel below the ligature; these anastomosing branches enlarge and constitute a *collateral circulation*, in which several large branches perform the office of the single obliterated trunk.

Arteries pursue a fairly straight course, but in some parts they are tortuous; this is the case in the arteries of the lips and uterus, and in those passing up to the base of the brain. In some instances the tortuous course is to permit of free motion of the parts crossed by the vessel; in others it appears to have the effect of diminishing the force of the propulsion of the blood.

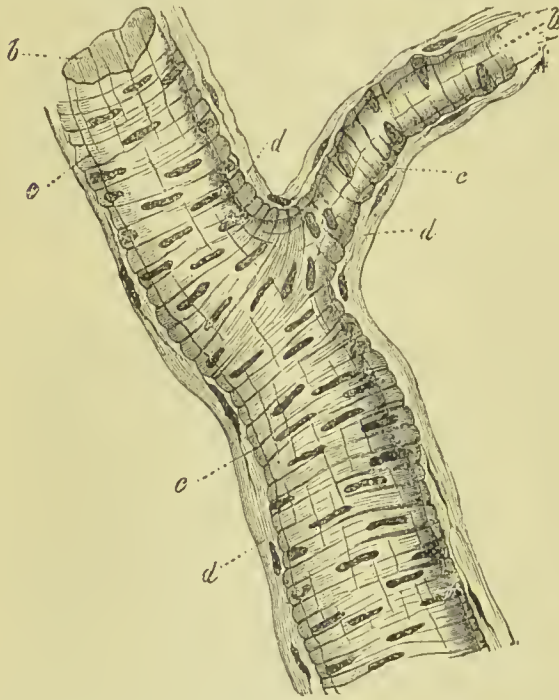


FIG. 57.—A small artery. At *b*, the homogeneous internal layer; *c*, middle tunic formed of unstriped muscular fibre; *d*, the external connective-tissue tunic.

Structure of Arteries.

—Arteries are composed of three coats, *external*, *middle*, and *internal*.

The **external coat** (*tunica adventitia*) is firm and strong; it is thin in the large arteries, but thicker than the middle coat in arteries of small and medium size, and is composed of white fibrous and elastic tissue. The white fibres are arranged in close bundles, which run for the most part diagonally or obliquely across the vessel; they form by their inter-communication a firm felted membrane, with minute interspaces, in which lie numerous branched connective-tissue corpuscles. Among the white fibres a few elastic fibres are found; these are most numerous in the inner layers (that is to say, near the middle coat), and are arranged longitudinally. The interlacement of the fibres is closest in the inner layers, and becomes looser as we approach

the outer surface of the vessel. Longitudinal bands of unstriped muscular fibre have been described as existing in the outer coat of many of the larger arteries, such as the splenic, renal, mesenteric, axillary, popliteal, and femoral.

The **middle coat** (*tunica media*) is in all arteries the thickest and most important. It is composed of many layers of unstriped muscular fibres, with, in the larger arteries, the addition of elastic tissue, and a small quantity of white fibrous tissue; these structures are almost entirely arranged transversely. This coat is very brittle, and hence is easily cut through when a ligature is applied. The *unstriped muscular tissue* is almost the only component structure of the middle coat of small arteries; in which there are two or three laminae, the fibres, about $\frac{1}{3000}$

of an inch in diameter, and $\frac{1}{300}$ to $\frac{1}{200}$ of an inch long, being arranged in rings; in smaller arteries there is but one muscular lamina, the elements of the fibres being shorter, and in proportion as the arteries are more minute, becoming reduced to the earliest developmental form—namely, short elliptic cells with oblong nuclei; ultimately they are completely lost. The *elastic tissue* is absent altogether in the middle coat of small arteries, but makes its appearance in arteries of medium size as fine fibres disposed in a network of wide meshes. In the larger kind of medium-sized arteries, the elastic network is mingled with areolar tissue, and a tendency to the alternation of these tissues begins to be apparent. While thus encroaching as it were on the structure of the middle coat of arteries, the elastic tissue presents a corresponding series of transitional forms; at first it exists as fine fibres disposed singly or in a fine network with open meshes; then the fibres become larger and the meshes closer, and interlaced so as to form a fibrous membrane with narrow meshes; next, by the increase of breadth of their fibres and their intimate union or fusion, a homogeneous membrane is formed, in which the meshes appear as simple perforations (fenestrated membrane). In medium-sized arteries the elastic tissue forms a single layer lying external to the

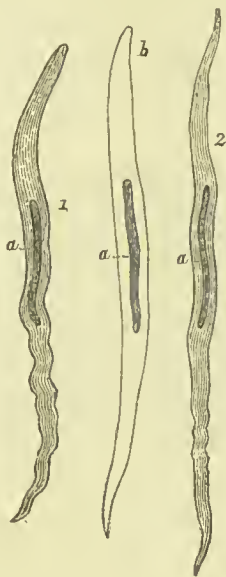


FIG. 58.—Smooth muscular fibre cells from the middle coat of the artery. 1. From the popliteal. 2. From a twig of the anterior tibial, half a line in diameter. *a, a, a*. Elongated or rod-like nucleus. The middle cell (marked *b*) has been rendered transparent by immersion in vinegar.

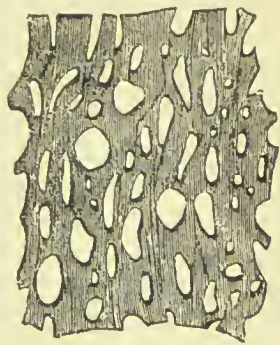


FIG. 59.—Elastic membrane of the fenestrated kind, from the middle coat of the carotid artery of a horse.

muscular fibres; in the largest arteries of this class it is mingled with areolar tissue, and exhibits a tendency to become laminated, the laminae alternating with similar layers of areolar tissue. In the large arteries this is the common character of the middle coat; the elastic tissue is laminated, and between the laminae are strata of areolar and muscular tissue. The presence of elastic tissue as a chief constituent of the middle coat of large arteries gives them

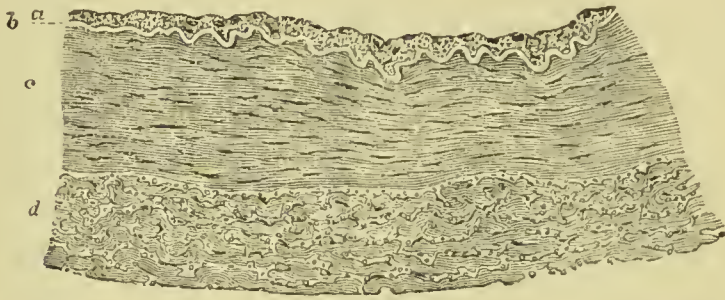


FIG. 60.—Transverse section of wall of posterior tibial artery. *a.* Endothelial lining of tunica intima. *b.* Elastic layer of tunica intima. *c.* Tunica media. *d.* Tunica adventitia. (E. A. Schäfer.)

a yellow colour, while those arteries in which the muscular tissue is abundant have a reddish tint. In the aorta, the laminae of the middle coat are forty or fifty in number.

The **internal coat** (*tunica intima*) is the thinnest of the three, and easily broken in the transverse direction; it is composed of three layers, an internal layer or *endothelium*, a *subendothelial* layer, and an external *elastic membrane*, which is either homogeneous or made up of elastic elements, disposed in a longitudinal direction. The *internal endothelial* layer is formed by a single layer of flattened cells, very thin, polygonal or elliptical in shape, and having transparent oval nuclei; their outlines can be made evident by pencilling the inner surface of the artery with a solution of nitrate of silver. The *subendothelial* layer is absent from the smallest arteries, but is distinguishable in all those of medium and large size in the form of longitudinal bundles of fibrous connective tissue, between which are numerous anastomosing branched connective-tissue cells. The *elastic layer* is a thin, homo-

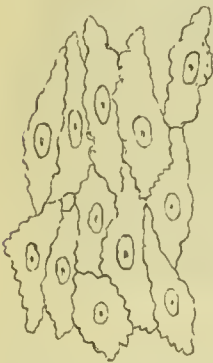

FIG. 61.—Endothelium lining an artery.

geneous membrane of the fenestrated kind, perforated with minute oblong openings having a direction parallel with the axis of the vessel. It is thrown into longitudinal folds when the vessel is empty, and becomes extremely delicate, and is finally lost in the minute vessels. Exteriorly this layer assumes a reticulated character, and is made up of a longitudinal network of elastic fibres.

In taking a summary survey of the constituent tissues of the three coats of arteries in their order of succession from without inwards, it will be seen that the external coat consists of areolar and elastic tissue; the middle coat of smooth muscular fibre, areolar and elastic tissue; and the internal coat of elastic tissue and endothelium.

The arteries in their distribution through the body are included in a loose areolo-fibrous investment which separates them from surrounding tissues, and is called a *sheath*. Around the principal vessels the sheath is an important structure; it is composed of areolar tissue, intermingled with aponeurotic fibres, and is continuous with the fasciæ of the region in which the arteries are situated, as with the thoracic and cervical fascia in the neck, transversalis and iliac fascia, fascia lata in the thigh, &c. The sheath of the arteries contains also their accompanying veins, and sometimes a nerve.

The coats of arteries are supplied with blood like other organs of the body; their vessels proceed from the neighbouring small branches, and are named *vasa vasorum*. The vasa vasorum or vasa nutritia are distributed in the external coat, some few making their way among the external layers of the middle coat. They are met with even on the smallest arteries, and form a rich capillary network with rounded meshes. The small veins which return the blood from the capillaries, open into the companion veins of the artery. The *nerves*, like the vasa vasorum, are found only in the external coat, and are wanting altogether in many arteries, as in those of the cerebral and spinal substance, the choroid membrane of the ovum, the placenta, and also in the arteries of some muscles, glands, and membranes. *Lymphatic vessels* and *lymph spaces* are present in the outer coat.

CAPILLARIES.

The arteries do not terminate directly in veins, but in an intermediate system of vessels which, from their minute size (about $\frac{1}{3000}$ of an inch in diameter), are termed *capillaries* (*capillus*, a hair). The capillaries constitute a microscopic network, which is distributed through nearly every part of the body, so as to render it impossible to introduce the smallest needle-point beneath the skin without wounding several of these fine vessels. It is through the medium of the capillaries that all the phenomena of nutrition and secretion are performed. They are remarkable for their uniformity of diameter, and for the constant divisions and communications which take place between them, without any alteration of size. They communicate on the one hand with the terminal branches of the arteries, and on the other with the minute radicles of the veins. In the maternal part of the placenta and in the erectile organs (as the corpus cavernosum penis), the arteries empty into lacunar spaces, from which the veins gather up the blood, without the intervention of capillaries; and an arrangement somewhat similar is also found in the spleen. Suequet and Hoyer assert that in some parts the small arteries pass

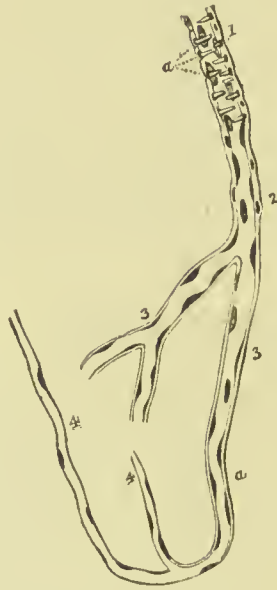directly into small veins, so that the blood does not enter the capillary system.

Structure of Capillaries.—The capillaries are the smallest and simplest of the blood-vessels, their wall being formed by a single layer of flattened endothelial cells, the edges of which can be brought into view by pencilling the surface with nitrate of silver. The cells are irregular in shape, being often pointed at their extremities and sinuous at their edges. They are united together by an albuminous cementing substance, and are connected externally with the processes of the connective-tissue corpuscles of the neighbouring tissues (Klein). During inflammation, the connecting cement of the cells often gives way so as to leave pores or *stomata*, through which the white corpuscles of the blood (and occasionally the red ones) pass. In certain parts the capillaries have, in addition to their endothelial lining, an outer coat, formed by a network of branched connective-tissue cells.

Although capillaries are, as stated above, remarkable for their uniform size in any particular organ, they differ in this respect

in different localities, being smallest in the brain and lung, and largest in the marrow of bones; they are small also in muscle and large in skin and mucous membrane. They differ greatly in the size and arrangement of the meshes which they form, and consequently in the amount of blood which they supply to the tissues, the network being very close in the lungs and choroid coat of the eye, in most mucous membranes and in glands, and very wide

FIG. 62.—Transition of a minute artery into capillary vessels—from the brain. 1. Minute artery. 2. Transitional capillary. 3. Coarse capillary with thick coat, represented by a double contour line. 4. Fine capillary, with single contour. The nuclei are seen widely scattered in 4 and 3; more closely congregated in 2; and still more so in 1. *a*. The transverse elongated nuclei of muscular cells; the muscular coat of the artery.



in ligaments, tendons, and similar structures.

In muscle, nerve, and tendon the meshes of the capillary plexus are long and narrow; in the lungs, adipose tissue, and secreting glands they are rounded or polygonal; while in the skin and mucous membranes the capillaries are drawn out into long loops.

VEINS.

The veins are the vessels which return the blood to the heart, after it has been circulated by the arteries through the various tissues of the body. They are much thinner in structure than the arteries, so that when emptied of their blood they become flattened and collapsed. The veins of the systemic circulation convey the dark-coloured and impure or *venous blood* from the capillary system to the right auricle of the heart, and they are found after death to be more or less distended with that fluid. The veins of the pulmonary circulation contain during life the pure or arterial blood, which they transmit from the capillaries of the lungs to the left auricle.

The veins commence by minute branches which are continuous with the capillaries, and converge to constitute larger and larger branches, till they terminate in the main trunks which convey the venous blood directly to the heart. In diameter they are larger than the arteries, and, like those vessels, their combined area would constitute a hollow cone, whereof the apex is placed at the heart, and the base at the surface of the body. It follows from this arrangement, that the blood in returning to the heart is passing from a larger into a smaller channel, and therefore that it increases in rapidity during its course.

Veins admit of division into superficial and deep.

The *Superficial veins* return the blood from the integument and superficial structures, and take their course between the layers of the superficial fascia; they then pierce the deep fascia in the most convenient and protected situations, and terminate in the deep veins. They are unaccompanied by arteries, and are the vessels usually selected for venesection.

The *Deep veins* are situated among the deeper structures of the body, and generally in relation with the arteries; in the limbs they are enclosed in the same sheath with those vessels, and they return the venous blood from the capillaries of the deep tissues. In company with all the smaller, and also with the secondary arteries, as the brachial, radial, and ulnar in the upper, and the tibial and peroneal in the lower extremity, there are two veins placed one at each side of the artery, and named *venæ comites*. The larger arteries, as the axillary, subclavian, carotid, popliteal, femoral, are accompanied by a single venous trunk; and certain veins, such as those of the cranium, spinal canal, liver, and larger veins of bones, run apart from arteries.

The communications between veins are more frequent than those of arteries, and they take place between the larger as well as the smaller vessels; the *venæ comites* communicate with each other in their course by means of short transverse branches which pass across from one to the other. The office of these inosculation is very apparent, as tending to obviate the obstructions to which veins are

particularly liable from the thinness of their coats, and from their inability to overcome much impediment by the force of their current.

Structure of Veins.—Veins closely resemble arteries in their structure, and like them are formed of three coats—*external* or *tunica adventitia*, *middle* or *tunica media*, and *internal* or *tunica intima*. It will be sufficient if we here indicate the particulars in which these several coats differ from those corresponding to them in arteries.

External Coat.—This is thick in proportion to the other coats, and is composed of longitudinal and oblique bands of fibrous tissue, with some elastic fibres; the interstices between the fibres lodge ramified connective-tissue corpuscles. In certain veins, as the inferior vena cava, renal, azygos, spermatic, and external iliac veins, this coat contains a thin layer of unstriped muscular tissue.

Middle Coat.—The transverse muscular fibres which distinguish this coat in both arteries and veins are in the latter very thin; they never form continuous layers, and are never separated from each other by distinct elastic membranes as in the arteries, the intervening substance in veins being usually white fibrous tissue.

Inner Coat.—This coat is firmer than the inner coat of arteries, and can be stripped off without breaking; it consists of an endothelial layer, a subendothelial layer of branched cells, and an elastic layer, either forming fenestrated membrane, or existing simply as a closely areolated longitudinal network of coarse and fine elastic fibres. Longitudinal muscular fibres are found in the inner coat of some veins.

Variations in the Structure of Veins.—The middle coat is wanting in the thoracic part of the inferior vena cava and in the hepatic veins; it is most developed in the splenic and portal veins, and in those of the gravid uterus. The superior and inferior vena cava and pulmonary veins as they enter the heart receive a covering of striped muscular fibres, continued on to them from that organ. Muscular tissue is absent from the veins of the maternal part of the placenta, the jugular and subclavian veins, the veins of the retina, the sinuses of the dura mater, the veins of bones and muscle, and the spaces in the substance of the corpora cavernosa of the penis. The veins of the gravid uterus have muscular tissue in considerable quantity, and distributed throughout all three of their coats.

The **Valves of Veins** are composed of a thin stratum of fibrous tissue mingled with fine elastic fibres, and coated on the two surfaces with the endothelial lining of the vessel. The segments or flaps of the valves of veins are semilunar in form, and arranged in pairs, one upon each side of the vessel; in some instances there is but a single flap, which has a spiral direction, and occasionally there are three. The free border of the valvular flaps is concave, and directed forwards, so that while the current of blood is permitted to flow freely towards the heart, the valves are distended, and the current intercepted, if the stream become retrograde in its course. On the cardiac side of each valve the vein is expanded into two pouches

(sinuses), corresponding with the flaps of the valves, which give to the distended or injected vein a knotted appearance. The valves are most numerous in the veins of the extremities, particularly in the deeper veins, and they are generally absent in the very small veins, and in the veins of the viscera, as in the portal and cerebral veins, those of the liver, kidney, and uterus; they are also absent in the large trunks, as in the *venæ cavæ*, *venæ azygos*, innominate, pulmonary, and iliac veins. The trunk and branches of the umbilical vein are devoid of valves, as are also the ovarian veins, and the veins of the cancellous tissue of bone.

Sinuses are venous channels, excavated in the structure of an organ, and lined by the internal coat of the veins; of this structure are the sinuses of the dura mater, whose external covering is the fibrous tissue of the membrane. The external investment of the sinuses of the uterus is the tissue of that organ.

Veins, like arteries, are supplied with nutritious vessels, the *vasa vasorum*; their nervous filaments, few in number and of small size, are derived from the sympathetic and spinal system; they have been chiefly found on the larger veins, as, the *venæ cavæ*, iliacs, crural, jugular, vertebral, and sinuses of the dura mater.

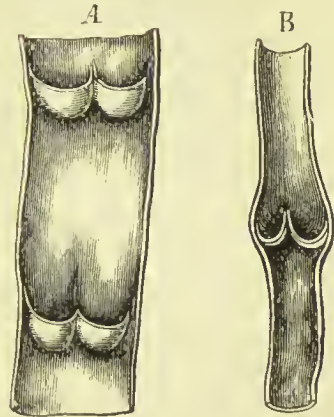


FIG. 63.—A. Part of a vein laid open, with two pairs of valves. B. Longitudinal section of a vein, showing the valves closed.

LYMPHATICS.

Lymphatic vessels form a secondary vascular system and serve two important purposes, namely, to convey into the blood the products of intestinal digestion, and to return to the blood materials which having been once used do not require to be excreted, but may, after undergoing change or elaboration in the lymphatic vessels and glands, be again used for the building up of tissues. The vessels employed for the first of these purposes are called *lacteals*, from the milky fluid they convey; the rest of the vessels are called *lymphatics*, from the fluid contained being clear and transparent (*lymphæ*, water). These two kinds of vessels do not differ structurally from each other.

The lymphatic system consists of three parts, *vessels*, *capillaries*, and *glands*.

Lymphatic vessels are of two kinds—large vessels, as the thoracic duct and its tributaries; and small vessels, such as are found throughout the body generally. Both kinds possess a great number of valves placed at very short distances from each other, so that when a lymphatic vessel is inflated it presents a beaded appearance. The valves are almost identical in structure and arrangement

with those described in connection with veins, consisting of one or two semilunar folds formed by the lining membrane of the vessel.

The **large vessels** correspond in structure to veins, and have three coats of extreme thinness ; the outer formed of delicate fibrous tissue, the middle of unstriped muscular fibres, and the inner of elastic tissue supporting a single layer of nucleated endothelial cells, of elongated form and with sinuous edges.

The **small lymphatics** are very numerous, being found in every part of the body, in every organ, and probably existing in every tissue. They are much more numerous than the veins, but are of microscopic size ; they form, by their communications, complicated plexuses, the meshes of which are often exceedingly close. Their walls are formed by a single layer of flattened endothelial cells with sinuous edges and nuclei which are not in the centre of the cells ; their tubular shape and the existence of valves serve to distinguish them from the lymphatic capillaries.

Lymphatic Capillaries.—These are often larger than the smallest trunks, but are distinguished from them by the extreme irregularity

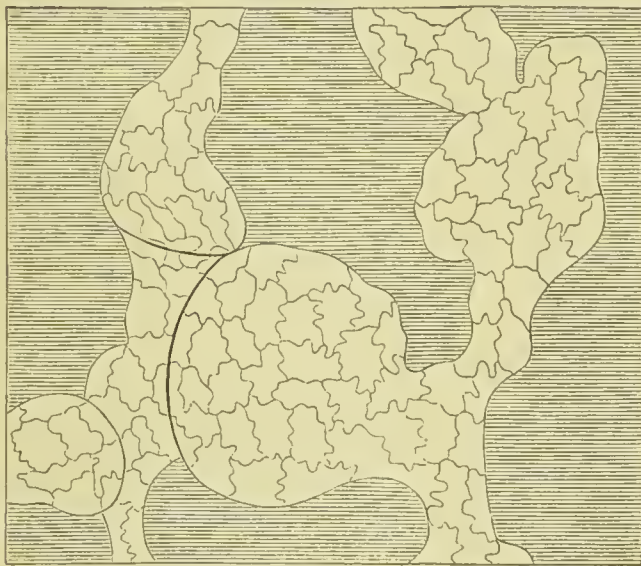

FIG. 64.—Lymphatic capillaries ; showing the great variation in their size and shape.

of their shape and by the absence of valves. They vary greatly in their arrangement in different parts, sometimes ensheathing the blood-vessels, at others forming irregular lacunar cavities, or, yet again, enclosing the bundles of fibrous tissue in a tendon, and forming for them a delicate sheath. In whatever form they exist, they may be identified by pencilling the

tissue with a solution of nitrate of silver, when the endothelial cells are made evident by the colouration of the intercellular cementing substance. The wall is formed by a single layer of cells, which differ from those lining the smallest lymphatic vessels by being shorter, and having more sinuous outlines.

Many lymphatic capillaries open into a system of lacunæ, connected with each other by minute canals (the *lymph-canalicular system* of Recklinghausen), the lacunæ lying in an albuminous ground substance, and lodging ramified cells or connective-tissue corpuscles. The contained cells constitute a sort of lining on one

side of the lacuna, and are continuous with the endothelial cells of the lymphatic capillary with which the lacuna is connected. The lymph-canalicular system is almost the only representative of the lymphatics in the cornea, the grey and white matter of the brain and spinal cord, and in cartilage. In tendon, fasciæ, muscle of both kinds, and nerves, the lymphatics are found as continuous clefts or longitudinal spaces between the connective-tissue bundles or the proper fibres of the tissue. In areolar tissue they form the areolæ or interspaces which we have described on a previous page as characterising that tissue; and in the nervous centres they form spaces or sheaths around the blood-vessels, which have been named *perivascular lymph spaces*. The lymphatics of serous membranes are very numerous, and have a complicated arrangement which cannot here be fully described; the most important features are, first, that there are frequent invaginations of the blood-vessels, either by lymphatic tubes or by an intercommunicating system of lymph sinuses lined with endothelium; and, second, that the lymphatic capillaries communicate with the surface of the serous membrane by means of openings called *stomata*, which are bordered by germinating epithelium differing in character from the cells which form the surface of the membrane. The germinating cells when ripe become detached, and form free lymph cells.

It will be thus seen that there are two chief forms in which the lymphatics originate, namely, by spaces or sinuses lined by a complete endothelium and by irregular lacunæ, lined only on one side by a branched connective-tissue cell.

Lymphatic Glands (absorbent glands) are small, oval or bean-shaped, flattened or rounded bodies, of a reddish-brown colour, placed at short intervals in the course of the small lymphatic vessels. They are found in groups in the axilla, popliteal space, groin, lumbar region of the abdomen, round the root of the lungs, and in the neck, and are joined together by means of the lymphatic vessels which enter or leave them.

Each gland presents externally the appearance of being composed of lobules, and generally has at one side a slight depression or *hilus*, through which the blood-vessels enter the interior. The lymphatic vessels connected with the gland consist of a large one apparently issuing from the very centre of the gland, called *vas efferens*, and numerous smaller ones passing into the interior at different parts of the periphery, each of these being called a *vas afferens*. On section the external part of the gland is found to be of a different colour and consistence to the interior, and hence the two parts are distinguished as *cortical* and *medullary*. The gland is surrounded by a capsule which is continuous with the outer coat of the afferent and efferent vessels; it is formed of white fibrous tissue, the fibres crossing each other in different directions, and enclosing connective-tissue corpuscles in their meshes. At the hilus the fibres of the capsule are continued into the interior of the gland, the fibrous tissue becomes mixed with a small quantity of unstriped

muscle, and the bands so constituted radiate from the centre to the periphery, and become connected with the interior of the capsule; they thus form numerous septa which divide the cavity of the gland into spaces. In the cortical part of the gland the fibrous trabeculae form thin lamellae, and enclose relatively large oval spaces, called *alveoli* ($\frac{1}{60}$ to $\frac{1}{24}$ of an inch wide), which communicate with each other by small openings in the partitions. In the medullary part the trabeculae exist as flattened cords or bands, which form by their communications a network, the meshes of which freely open into each other. The alveoli of the cortical and meshes of the medullary

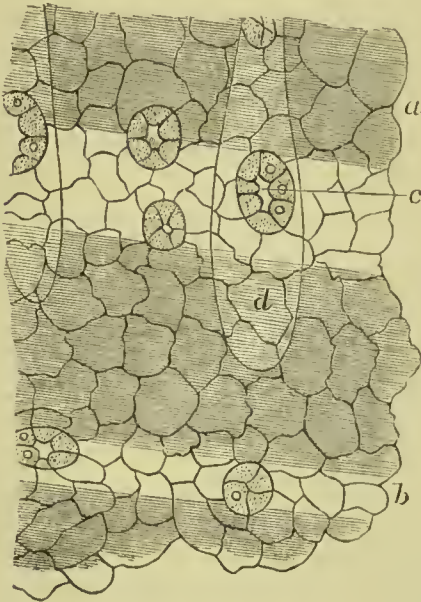


FIG. 65.—Peritoneum covering the central tendon of the diaphragm of a rabbit. *a.* Tendon bundle covered by squamous endothelial cells with wavy margins. *b.* Endothelium covering space between tendon bundles, cells of small size. *c.* One of the stomata, surrounded by germinating endothelium. *d.* Sinus of a lymphatic vessel.

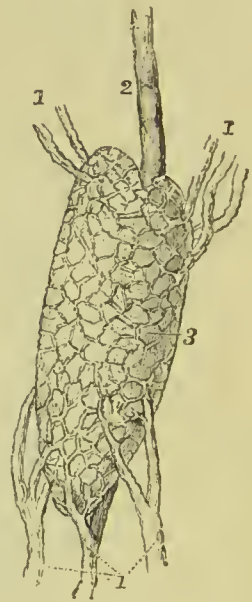


FIG. 66.—View of a lymphatic gland. 1, 1, 1. Vasa afferentia. 2. A vas efferens. 3. Body of the gland.

part are occupied by the proper glandular or adenoid tissue, which in the former takes the shape of oval masses (follicles), and in the latter that of cords or cylinders (medullary cylinders). In both cortex and medulla the gland pulp or substance is separated from the trabeculae forming alveoli and meshes by a space of nearly uniform width throughout; this is the *lymph sinus* or *lymph path*. It is not empty, but is occupied by retiform connective tissue, that is to say, ramified or anastomosing cells; these support large numbers of lymph corpuscles, which are carried onwards by the current of lymph. The lymphoid tissue which forms the great mass of the gland, consists of a reticulum of fine homogeneous fibrils or mem-

branes, arranged so as to form a honeycomb, and covered by numerous flattened endothelial cells. The reticulum is crowded with lymph

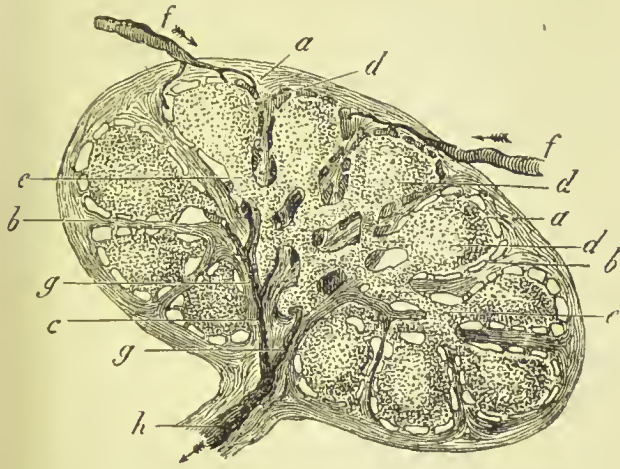


FIG. 67.—Section of a small lymphatic gland, half diagrammatically given, with the course of the lymph. *a*. The capsule. *b*. Septa between the alveoli of the cortical portion. *c*. Septa of the medullary portion, down to the hilus of the organ. *d*. Adenoid tissue. *e*. Lymph vessels of the medullary mass. *f*. Different lymphatic streams which surround the follicles, and flow through the interstices of the medullary portion. *g*. Confluence of these passing through the efferent vessel, *h*, at the hilus of the organ.

corpuscles of small size. The lymphoid tissue contains a dense network of capillary blood-vessels.

Course of the Lymph.

—The afferent vessels, after branching upon and in the tissue of the capsule, open into the lymph sinus in the cortex of the gland; the efferent vessels, on the other hand, commence by small branches connected with the sinus in the medullary meshes. The lymph enters the cortical alveoli by the afferent vessels, traverses the lymph path in the cortex, from thence passes into the medulla, and taking its course through the lymph path in that part of the gland, reaches the efferent vessel, and by it leaves the gland. The lymph cells which it receives in such large numbers in passing through the gland are

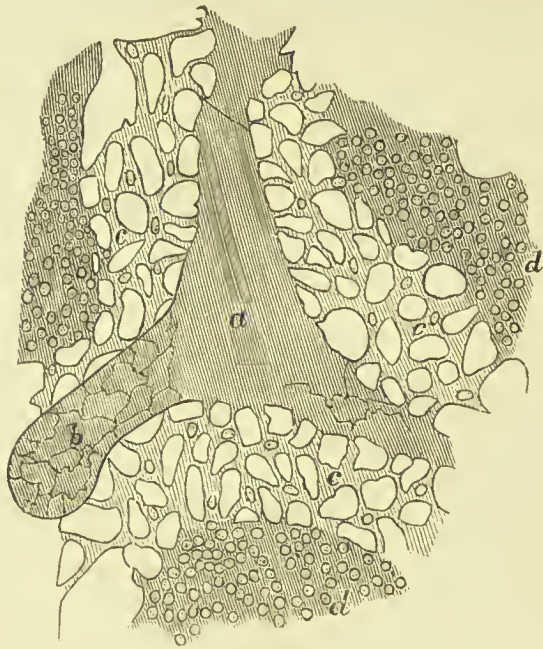


FIG. 68.—Part of medulla of a lymphatic gland. *a*. Trabecula cut longitudinally. *b*. Surface of the trabecula covered by endothelium. *c*. Lymph sinus. *d*. Medullary cylinders composed of lymphoid tissue.

derived from the lymphoid tissue filling up the great part of the

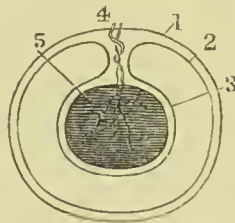
cavities in the cortex and medulla. On entering a gland the lymphatic vessel loses all its coats except the inner endothelial one, which is continued over the trabeculæ, forming a delicate lining for these partitions.

The lymphatic glands above described are sometimes spoken of as *compound lymphatic glands*, to distinguish them from masses of lymphoid tissue found in various parts of the body, and described as *simple lymphatic glands*. Examples of the latter are the tonsils, glands at the root of the tongue, thymus gland, solitary and agminate glands of the intestine, and the Malpighian bodies of the spleen. These will be described in the section on the viscera, in connection with the organs of which the adenoid masses form a part.

SEROUS MEMBRANES.

These occur in the form of a thin transparent web which lines the interior of cavities containing viscera, and is so disposed as to facilitate movement. The chief examples are the pleuræ and pericardium in the chest, peritoneum in the abdomen, arachnoid in the cranium and spinal canal, and the tunica vaginalis in front of the testicle. A serous membrane consists of two parts, one which lines the cavity,

FIG. 69.—Plan of a serous membrane.
1. Wall of cavity.
2. Parietal layer of serous membrane.
3. Visceral layer.
4. Vessel entering at the reflection. 5. The contained organ.



called the *parietal layer*; the other, which is reflected from the wall of the cavity, and is prolonged over the contained organ, the *visceral layer*. These two layers are in contact on their free surfaces; and from this free surface a very small quantity

of limpid fluid is secreted, which serves the purpose of a lubricating medium, and so facilitates the gliding of the enclosed organ in its cavity. The serous membranes are all closed sacs, retaining their fluid contents when from any cause there is an abnormal effusion. The only exception to this is the peritoneum in the female, where at the extremity of the Fallopian tube the serous membrane is continuous with the mucous lining of the tube. In some cases, as the serous membrane of the heart and lungs, its arrangement is very simple; in others, as the peritoneum, it is very complex, owing to the number of organs contained in the cavity; but in all (except the arachnoid) the two layers can easily be made out. At the place where the reflection takes place, the vessels of the contained organ enter it. The viscus, although said to be surrounded by the serous membrane, is in reality outside of it. The accompanying plan of such a sac will give an idea of the manner of arrangement.

Structure.—Serous membranes are lined by a layer of flattened

endothelial cells with sinuous edges and clear oval nuclei, each containing one or more nucleoli. Openings exist in many of the serous membranes, which, as stated above, communicate with the lymphatic capillaries; they are called *stomata*, are commonly oval in shape, and are bordered by cells which are thicker and of a more granular character than those covering the rest of the surface (see Fig. 16, p. 11). As these cells are actively growing, and often produce free corpuscles, they have been described by Klein under the name of *germinating endothelium*. Besides the *stomata*, other interruptions

in the epithelial layer have been noted. These are called *pseudo-stomata*; they are not true openings, but are processes of protoplasm sent up to the surface by the connective-tissue cells of the subserous tissue. The deep layer of serous membranes consists of a connective-tissue ground substance formed of yellow and white fibres, and supporting the capillary vessels and lymphatics; the ground

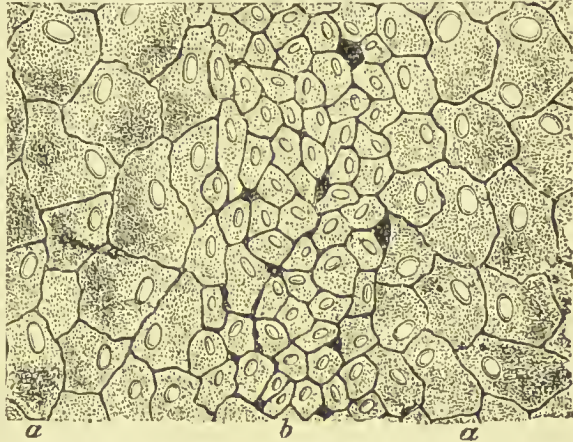


FIG. 70.—Endothelium from abdominal surface of central tendon of diaphragm of a rabbit, stained with nitrate of silver. *a*. Large endothelial cells covering the general surface of the membrane. *b*. Smaller cells over a lymphatic capillary, in which several pseudo-stomata may be seen.

substance also contains branching connective-tissue cells lying in cell spaces, many of the processes of which pass up between the epithelial cells of the surface and form pseudo-stomata. The fluid secreted by serous membranes is almost identical with the fluid part of lymph, and from the fact that the cavities formed by serous membranes freely communicate with the lymphatic system through the medium of the *stomata*, it is now generally held that they are indeed lymph spaces or sacs. As withdrawn from healthy serous cavities the fluid coagulates spontaneously, but when it accumulates under conditions of disease (in dropsy, for instance), it requires for its coagulation the addition of some substance containing globulin.

SYNOVIAL MEMBRANES.

These membranes are nearly identical in structure with the serous membranes, but the secretion is more viscid and something like the white of egg, whence the name. They line the cavities of joints, and are interposed between tendons and bones when much friction or pressure is produced during their movements.

Three classes of synovial membranes have to be described—namely, those lining the cavities of joints, **Articular**; those forming closed sacs, **Bursal**; and those forming lubricating sheaths for tendons, **Vaginal** or **Ensheathing**.

1. Articular Synovial Membranes (*Synovial Capsules*).—These cover the interior of the ligaments enclosing a diarthrodial joint, and secrete a fluid called synovia, which lubricates the articular surfaces and ensures smooth movement. The membrane is not (as was formerly supposed) continued over the whole surface of the articular cartilage, but simply overlaps its margin to a very slight extent; at its termination it becomes firmly adherent to the cartilage. When a tendon passes through a joint, as, for instance, the tendon of the biceps through the shoulder joint, it is invested by this membrane, which is often continued on it for some distance beyond the capsule of the joint. In large joints additional folds of synovial membrane, containing fat, pass between the bones, or are lodged in excavations near the articular surfaces; some of these receive the name of ligaments, others are simply described as synovial fringes.

2. Bursal Synovial Membranes (*Bursæ Mucosæ*).—In these the synovial membrane forms a shut sac, sufficient fluid being secreted to lubricate the opposed surfaces, and the outer surface of the sac being connected with the neighbouring structures. Bursæ are found in all places where it is desirable to prevent friction between surfaces which move on each other; thus they are placed between the tendons of muscles, between tendons and the exterior of certain joints, and sometimes between a muscle and a bone. Many bursæ are subcutaneous, and are then of use to ward off external pressure; such are the bursæ found between the skin and the patella, and between the skin and the olecranon, or those on the styloid processes of the radius and ulna. Bursæ lying in contact with the capsule of a joint often become connected with the cavity of the joint.

3. Vaginal or Ensheathing Synovial Membranes.—These form sheaths for the tendons of many muscles, more especially those on the palmar and dorsal surfaces of the wrist, and the tendons passing to the phalanges of the fingers and toes. They not only serve to lubricate those tendons, but are also the means by which they are connected with the bones, and with each other; small bands called “frenæ” passing from one part of the membrane to another.

Structure of Synovial Membrane.—Synovial membranes are formed entirely of connective tissue, the deep layer being composed of ramified corpuscles embedded in a ground substance. The free surface was formerly described as being covered by a single layer of flattened epithelial cells, but further investigation has established the fact that the only cells found on the surface are of the branched and anastomosing kind, similar to those in the deeper layer of the tissue, and that the surface between the cells is formed by albuminoid ground substance. Here and there, however, the cells become so aggregated together, as to present some resemblance to an

epithelial layer ; but this aggregation only takes place in isolated patches, and not over the whole membrane.

The synovial membrane passes a little beyond the edge of the articular cartilage, and its cells becoming changed in form and losing their processes come to bear a close resemblance to cartilage cells ; it thus becomes quite impossible to determine the exact spot at which the membrane ceases.

Blood-vessels are numerous in the deep layer of synovial membranes ; they extend for only a short distance beyond the edge of the cartilage, where they form a circle of anastomosis, the loops of which are distinguished by dilatations.

MUCOUS MEMBRANE.

Mucous membrane is the tissue which lines all the internal passages communicating with the surface of the body. It secretes a viscid fluid called mucus, which protects and lubricates its surface, so as to allow of the passage of substances which otherwise would injure or irritate it. There are two great tracts of mucous membrane, called the gastro-pulmonary and genito-urinary. The first communicates with the surface of the body at the edge of the eyelids, nostrils, mouth, and anus ; the second at the orifice of the urethra in the male, of the vagina in the female. Every duct which opens into either of these tracts is a tubular prolongation of the mucous membrane ; and the various glands which pour their secretions into the alimentary canal on the one hand, and those connected with the bladder and organs of generation on the other, are but complicated ramifications of that membrane continued to them through their respective ducts.

The **structure of mucous membrane** is analogous to that of serous membrane, but more complex. It consists of two portions—one, the **corium**, a tough fibro-vascular layer ; the other the **epithelium**, composed of one or more layers of cells which rest on the corium.

The corium in most situations is separated from the epithelial layer by a thin, transparent membrane—the **basement membrane** ; it is composed of flattened cells joined by their edges, and is often pierced by numerous openings through which the deeper processes of the epithelial cells pass. Underneath this filmy structure lies the capillary plexus, and on it rest the epithelial cells.

The **corium** consists of a congeries of vessels—capillaries and lymphatics—woven into a compact tissue by interlacing fibres of connective tissue. The pink colour of mucous membrane depends on the capillary plexus seen through the semi-transparent cellular epithelium. In certain situations plain or involuntary muscular fibres occur as a thin but definite layer on the deep aspect of the corium, forming the *muscularis mucosæ* ; this is especially distinct

in the mucous membrane of the alimentary canal, where the fibres may also be traced between the glands, and into the villous projections. Also, in some parts, and especially in the intestinal canal, it contains abundance of lymphoid tissue. The arrangement of the vessels of the capillary plexus differs in each situation, so that a portion of mucous membrane under examination can be recognised by its vessels alone—as, for instance, the villi of the intestines, the air-cells of the lung, &c.

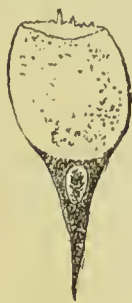

FIG. 71. —
Goblet cell
from tra-
chea of cat.

The epithelium of mucous membrane may be in a single layer or stratified, and the individual cells may be scaly, columnar, or ciliated. A peculiar variety of epithelium is often seen among the ordinary columnar cells in actively secreting mucous membrane, which has been named “goblet epithelium” or “goblet cells.” The mode of its formation from the ordinary columnar cells has been already described (see p. 9).

Submucous Tissue.—The corium is connected to the structures on which it lies by a layer of areolar tissue, which is dense and firm in some situations, where its fibres are continuous with the interlacing fibres of the corium; but in most it is loose, and permits the corium to glide on the surface on which it lies, so that it may be thrown into folds, or *rugæ*. The laxity of this submucous tissue renders it liable to be distended with fluid, as a result of inflammation, as in the case of chemosis of the conjunctiva and œdema of the glottis. The submucous tissue allows of the adaptation of the mucous membrane to the altered size of the organ, according as it is distended or contracted; it lodges the deeper and larger mucous glands, gives space for the subdivision and distribution of the blood-vessels and nerves, and contains lymph spaces and lymphatic plexuses, in free communication with the lymphatic capillaries of the mucous membrane.

The arrangement of the mucous membrane, and the structure of the glands in connection with it, will be described along with the anatomy of the organs of which it constitutes a part.

SECRETING GLANDS.

The simplest example of secreting structure is to be found in the serous membranes, which have on their surface a layer of endothelial cells, performing the work of secretion; beneath this, a subendothelial layer formed of connective-tissue corpuscles embedded in an albuminous ground substance, while in the ground substance and beneath it there is a fine plexus of capillary vessels, furnishing the blood from which the secretion is separated.

However complicated glands may appear, it is easy to recognise in them the same three essential constituents as in serous membranes, namely, secreting cells, supporting tissue, and capillary vessels, but

these three undergo various modifications in the different glands. In most of the glands the cells are of a spheroidal or irregular cubical form, and the supporting tissue is reduced to a *basement membrane*.

Glands may be divided into six forms, three of them being described as simple, and three as compound. The former are the simple follicle, saccule, and tubule; the latter the compound follicle, saccule, and tubule.

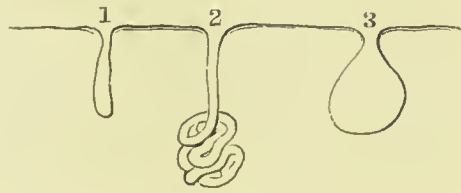


FIG. 72.—1. Simple follicle. 2. Tubular gland. 3. Saccular gland.

The **simple follicle** is merely a depression, resembling in shape the finger of a glove, and lined with cells mostly of the columnar variety, but with some granular spheroidal cells intermixed. The narrow cavity between the cells is called the **lumen** of the gland. The best examples of this form of gland are to be found in the small intestines, where they are called Lieberkuhn's follicles.

The **simple tubule** is an elongated follicle, the deeply seated end becoming convoluted like a ball of twine; the upper part of the tube is lined with squamous, and the lower with cubical epithelium. The sweat glands of the skin are examples of the simple tubular gland.

The **simple saccule** is a pouch-like sac, dilated below, and con-

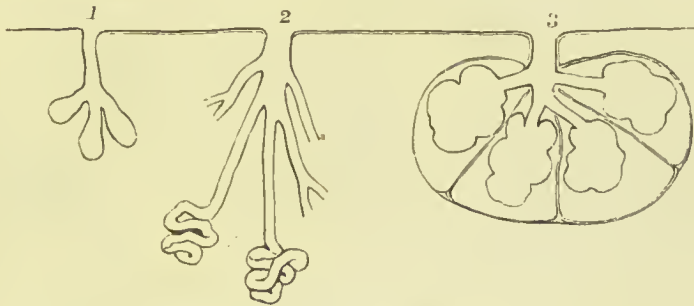


FIG. 73.—1. Compound follicle. 2. Compound tubular gland. 3. Compound saccular or racemose gland.

nected with the surface above by a narrow neck. The saccule is crowded with cells, chiefly of spheroidal form, so that little or no free cavity or lumen is left. The sebaceous glands connected with the hair follicles of the skin are examples of this form of gland.

The **compound follicular gland** is a follicle, the termination of which is cleft into two or three divisions. The gastric follicles near the pyloric end of the stomach have this form.

The **compound tubular gland** consists of branching tubules which become convoluted at their deep extremity. This arrangement may be observed in the tubuli uriniferi of the kidney and seminal tubules of the testicle.

The **compound saccule** is better known under the title of **race-**

mose gland. The salivary glands, pancreas, mammary gland, the lachrymal gland, and Brunner's glands of the duodenum belong to this class. The racemose gland presents to the naked eye the appearance of a number of little lobules, held together by connective tissue, and by the small blood-vessels which enter or leave them. Each lobule is composed of a number of saccules, called **acini**, lined by large protoplasmic cells, with nuclei near their attached margins. The cells are so large as almost to fill the entire saccule, only a small central cavity or lumen being left between them. The cells are supported by a framework of connective tissue, which serves also to connect the saccules, and to support a network of capillary vessels which supplies blood to the gland cells. The acini of a lobule open into a common duct, and the ducts from the lobules unite to form

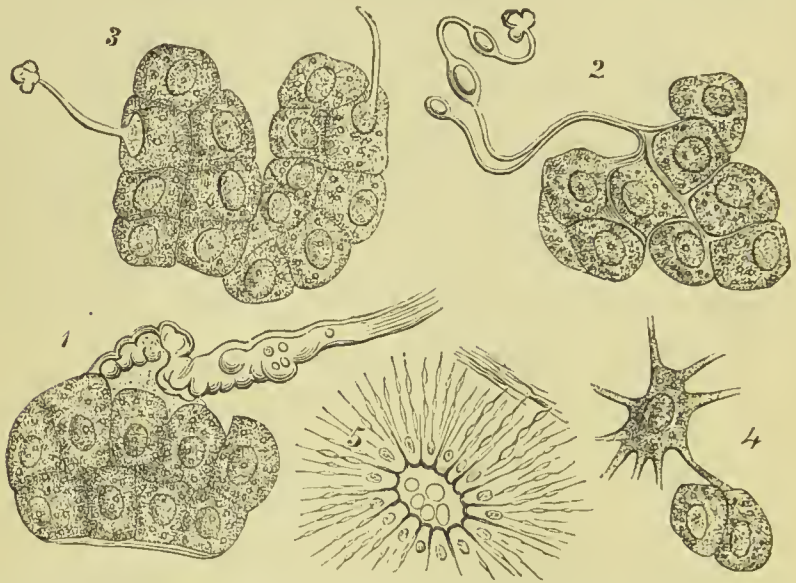


FIG. 74.—Modes of termination of nerves in salivary glands. 1 and 2. Branching of the nerves between the salivary cells. 3. Termination of the nerve in the nucleus. 4. Union of a ganglion cell with a salivary cell. 5. Varicose nerve fibres entering the cylindrical cells of the excretory ducts.

larger ducts, which generally terminate in a single excretory channel for the whole organ; sometimes, however, as in the lachrymal and sublingual glands, the terminal ducts are eight or ten in number. The ducts are lined with cylindrical epithelium.

The blood-vessels distributed to glands are numerous and of large size. They are remarkable for their rapid increase and diminution in size, according to the activity of the gland, or the reverse. The nerves distributed to glands are partly derived from the cerebro-spinal and partly from the sympathetic system; many of the latter are distributed to the blood-vessels, and serve to regulate the supply of blood to the gland. The nerves distributed to the salivary glands form a plexus between the lobules, in the midst of which small ganglia are found. The plexus is composed chiefly of medullated

fibres, and the branches given off from it are also medullated, till they penetrate the basement membrane of the acini, or the wall of the ducts; they then lose their medullary sheath, the axis cylinder splits up into numerous primitive fibrils, which pass into the substance of the epithelial cells of the ducts and the gland cells of the alveoli (Pflüger), often reaching the nuclei of those cells. Ganglion cells are also described as directly connected by their processes with the gland cells of salivary glands.

THE SKIN AND ITS APPENDAGES.

The **skin** is the exterior investment of the body, which it serves to cover and protect. It is continuous at the apertures of the internal cavities with the lining membrane of those cavities, the internal skin or mucous membrane, and is composed essentially of two layers, *derma* and *epidermis*.

The **DERMA**, *cutis vera* or **corium**, is the deep layer of the skin; it is composed of areolar tissue, muscular tissue, and fat, together with numerous blood-vessels, lymphatics, and nerves, which ramify through it. For convenience of description it is divided into a **reticular** and **papillary** layer, but it must be remembered that these are nowhere separable the one from the other.

The **reticular** or deep layer of the derma presents some variety in thickness in different parts of the body. Thus in the more exposed regions, as the back, the outer sides of the limbs, the palms, and the soles, it is remarkable for its thickness; while on protected parts it is comparatively thin, and on the eyelids, penis, and scrotum is peculiarly delicate. It is connected by its under surface with the common superficial fascia of the body. It is composed chiefly of white fibrous tissue collected into bundles, which are small and closely packed in the upper strata, large and coarse in the deeper strata; in the latter they form large areolæ, which contain adipose tissue, and in the midst of the fibrous bundles the hair-

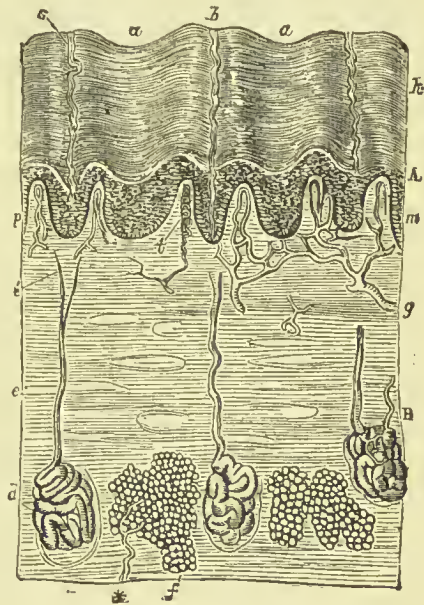


FIG. 75.—Vertical section of skin of finger. A. Epidermis, the surface of which shows hollow depressions, *a*, *a*, between the papillary eminences, *b*, and the openings of the sweat ducts, *s*; at *m* is seen the deeper layer of the epidermis, or rete mucosum, and opposite *A* the clear line of the stratum lucidum. B. Cutis vera, in which are embedded the sweat glands, *d*, with their ducts, *c*, and also aggregations of fat vesicles, *f*; at *g* is seen an arterial twig supplying the vascular papillæ, *p*; and at *l* one of the touch corpuscles with its nerve.

bulbs and the sudoriferous glands are embedded. The superficial strata contain much yellow elastic tissue, the quantity of which varies in different parts of the body, being much increased in the neighbourhood of joints. The deep strata contain unstriped muscular fibres, either gathered into bundles or dispersed among the fibrous tissue. In some parts the muscular tissue is so thick as to form a distinct layer, as in the "tunica dartos" of the scrotum, in the nipple and its areola, the penis and the perineum. There are also distinct bands of muscle connected with the hair follicles; these will be described in speaking of the hairs.

Throughout the whole of the reticular layer *connective-tissue corpuscles* are found; they generally anastomose so as to form a network.

The **papillary** or superficial layer of the derma is raised in the form of conical prominences or papillæ. On the general surface of the body the papillæ are short and exceedingly minute; but in other situations, as the palmar surface of the hands and fingers, and the plantar surface of the feet and toes, they are long and of large size. They also differ in arrangement; for, on the general surface, they are distributed at unequal distances and without order; whereas, on the palms and soles, and on the corresponding surfaces of the fingers and toes, they are collected into little square clumps, containing from ten to twenty papillæ, and these little clumps are disposed in parallel rows. It is this arrangement in rows that gives rise to the characteristic parallel ridges and furrows which are met with on the hands and feet. The papillæ in these little square clumps are for the most part uniform in size and length, but every here and there one papilla may be observed which is longer than the rest. The largest papillæ of the derma are those which produce the nail. In structure the papilla is composed of homogeneous, nucleated, and fibrillated areolar tissue, with a few transverse elastic fibres. The papillæ are separated from the epidermis by an apparently homogeneous **basement membrane** which becomes evident as a transparent line, when the tissue is treated with a solution of chloride of gold. The papillæ are divisible into *vascular* and *nervous*, the former predominating; some of the nervous papillæ are occupied by a peculiar form of nerve termination called the **tactile corpuscle** of Meissner or Wagner.

The **EPIDERMIS** or cuticle (scarfskin) covers the superficial surface of the derma, which it serves to envelop and defend. That surface of the epidermis which is exposed to the influence of the atmosphere and exterior sources of injury, is hard and horny in texture, and consists of many layers of horny cell-plates, which are not affected by acetic acid, and in which no nucleus can be made out; they form the *stratum corneum*. Beneath these cells is a layer in which the outlines of the cells become indistinct, so that they appear to form a homogeneous stratum, wherein nuclei are seen at intervals; this is called the *stratum lucidum*. In the succeeding layers the cells have a granular appearance, and contain a peculiar matter named *eleidin*; they are

oval or flattened, and the granular matter contained in them is remarkable for the readiness with which it absorbs colouring matter, such as carmine or hæmatoxylin. This layer has received the name of *stratum granulosum*. The deepest layer of the epidermis is known as the *rete mucosum* or *Malpighian layer*; it is divisible into a deep and a superficial stratum. The deep stratum is in contact with the basement membrane covering the papillæ, and consists of a layer of

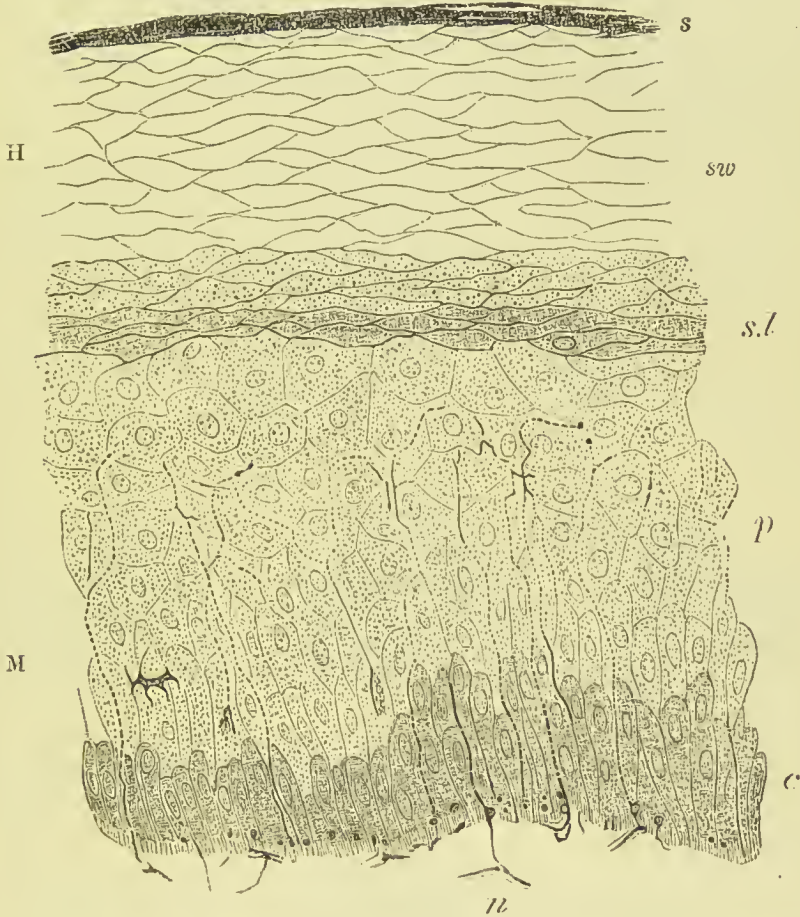


FIG. 76.—Section of epidermis. H. Horny layer, consisting of s, superficial horny scales; sw, swollen-out horny cells; s.l, stratum lucidum. M. Rete mucosum or Malpighian layer, consisting of p, prickle-cells several rows deep; and c, elongated cells next the derma. n. Nerve-plexus branches of which penetrate between the cells. (Schäfer after Ranvier.)

columnar cells; it is believed that they are the active agents in the selection of nourishment from the corium for the epidermis, and in the production of the new cells of the *rete mucosum*. By drawing nourishment from the corium they increase rapidly in size, more especially in length; the upper part then becomes separated from the rest to form a new cell, while the lower part, remaining still attached to the basement membrane, again elongates by the imbibition of new material; again it divides, and so *ad infinitum*. The cells thus

formed become larger by drawing nourishment from the corium, and it is probable that they also divide to form other cells. As this process goes on, the newest-formed cells push the older ones away from the corium, and as the latter ascend towards the surface of the skin they undergo certain changes. In consequence of the pressure which they sustain they become flattened; as they get beyond the range of nutrition they become altered in consistence, and finally they become subject to evaporation. Thus it happens that the cell which is at first spherical becomes elliptical, then becomes still more flattened, and at length desiccates into a thin membranous scale, in which no nucleus is apparent; in this last form it is thrown off.

The superficial cells of the rete mucosum are marked on their surface by irregular ridges and furrows, and sometimes by small spines; the ridges do not fit into the furrows, but the result of their presence is that minute channels are left between the cells which probably serve for the passage of nutrient fluid. Wander-cells are often observed among the cells of the rete mucosum.

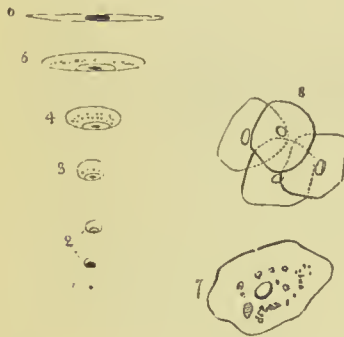

FIG. 77.—Diagram illustrative of the development of the epidermis and of epithelia in general. 1. A new cell. 2. The cell seen to be increased in size. 3. The spheroidal cell. 4. The oval cell. 5. The elliptical cell. 6. The flattened cell; which, by contact of its walls, is speedily converted into a scale. 7. A nucleated scale as seen on its flat surface. 8. A cluster of such scales.

The under surface of the epidermis is accurately modelled on the papillary layer of the derma, each papilla having its appropriate sheath in the newly-formed rete mucosum, and each irregularity of surface of the former having its representative in the soft tissue of the latter. On the external surface, this character is lost; the minute elevations corresponding with the papillæ are, as it were, polished down, and the surface is rendered smooth and uniform. The palmar and plantar surface of the hands and feet are, however, an exception to this rule; for here, in consequence of the large size of the

papillæ and their peculiar arrangement in rows, ridges corresponding with the papillæ are strongly marked on the superficial surface of the epidermis. The epidermis is remarkable for its thickness in situations where the papillæ are large, as in the palms and soles. In other situations, it assumes a character which is also due to the nature of the surface of the derma; namely, that of being marked by a network of linear furrows which trace out the surface into small polygonal and diamond-shaped areas. These lines correspond with the folds of the derma produced by its movements, and are most numerous where those movements are greatest, as in the flexures and on the convexities of joints.

The dark colour of the skin among the natives of the South is due to the presence of pigment granules in the deep cells of the rete

mucosum. As the cells desiccate, the colour of the granules is lost, so that the cells of the superficial layers are very little darker in the skin of the negro than in that of the white man.

The **pores** of the epidermis are the openings of the sweat ducts, hair follicles, and sebaceous glands.

Vessels and Nerves.—The **arteries** of the derma, which enter its structure through the areolæ of the under surface of the corium, divide into innumerable intermediate vessels, which form a rich capillary plexus in the superficial strata of the skin and in its papillary layer. In the papillæ of some parts of the derma, as in the longitudinal plications beneath the nail, the capillary vessels form simple loops, but in other papillæ they are convoluted to a greater or less degree in proportion to the size and importance of the papillæ. Capillary plexuses are also found around the groups of fat vesicles, the sweat glands, and hair follicles. The **lymphatic** vessels form, in the superficial strata of the derma, a plexus, the meshes of which are interwoven with those of the capillary and nervous plexus. In some parts of the palm of the hand and sole of the foot, lymphatics pass into the papillæ, but do not reach their summit.

The **nerves** of the derma, after entering the areolæ of the deeper part of the corium, divide into minute fasciculi, which form a ter-

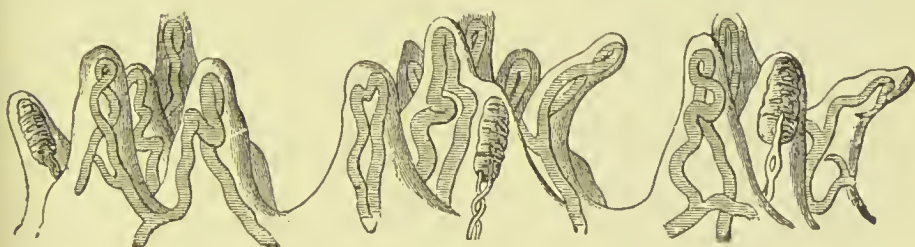

FIG. 78.—Three groups of tactile papillæ from the skin of the index finger, in vertical section. Some are supplied with vascular loops, some with tactile corpuscles.

minal plexus in the upper strata of the corium. From this plexus the primitive fibres pass off to their distribution as loops, in the papillæ. In the less sensitive parts of the skin the loops are simple and more or less acute in their bend, in conformity with the figure of the papillæ. In the sensitive parts, and especially in the tactile papillæ of the pulps of the fingers, the nerves terminate in special sense organs, namely, end bulbs, Pacinian bodies, and tactile corpuscles; the two former have already been described (p. 39). Small varicose nerve fibrils pass into the epidermis, and penetrate between the cells of Malpighian layer, to terminate in minute bulbous ends, without anastomosing.

The **tactile corpuscles** (discovered by Wagner and Meissner) are oval bodies about $\frac{1}{300}$ inch long, having externally a capsule of connective tissue with oval nuclei, some of the fibres being wound round horizontally and in many places penetrating into the central

part or core. The latter appears to be formed of modified connective tissue; the nerve fibres lose their medullary sheath before entering it, they then run a convoluted course (many of them becoming varicose), and terminate in bulbous enlargements.

APPENDAGES OF THE SKIN.

The appendages of the skin are the nails, hairs, sebaceous glands, and sweat glands and ducts.

The **NAILS** are horny appendages of the skin, identical in formation with the epidermis, of which they are a part. A nail is convex on its external surface, concave within, and implanted by means of a thin margin or root in a fold of the derma, which is nearly two lines in depth, and acts the part of a follicle to the nail. At the bottom of the groove of the follicle are a number of filiform papillæ, which produce the margin of the root, and, by a successive formation of new cells, push the nail onwards in its growth. The concave surface of the nail is in contact with the derma, and the latter forms the **matrix** of the nail, and is covered by papillæ, which perform the double office of retaining the nail in its place, and giving it increased thickness by the addition of newly-formed cells to its under surface. It is this constant change occurring in the under surface of the nail, co-operating with the continual formation taking place along the margin of the root, which ensures the growth of the nail in the proper direction. The nail derives a peculiarity of appearance from the disposition and form of the papillæ of the matrix. Thus, beneath the root, and for a short distance onwards towards its middle, the derma is covered by papillæ which are more minute, and consequently less vascular than the papillæ somewhat farther on. This patch of papillæ is bounded by a semilunar line, and that part of the nail covering it being lighter in colour than the rest, has been termed *lunula*. Beyond the lunula the papillæ are raised into longitudinal pleats, which are exceedingly vascular, and give a deeper tint of redness to the nail. These pleat-like papillæ of the derma are well calculated by their form to offer an extensive surface both for the adhesion and formation of the nail. It is the deposit of horny laminae on the surface of these folds that gives rise to the ribbed appearance of the nail. The papillary substance of the derma which produces the nail is continuous around the circumference of the attached part of that organ with the derma of the surrounding skin, and the horny structure of the nail is consequently continuous with that of the epidermis.

HAIRES are horny appendages of the skin, produced by the involution and subsequent evolution of the epidermis; the involution constituting the follicle in which the hair is enclosed, and the evolution the shaft of the hair. Hairs vary much in size and length in different parts of the body; in some they are so short as not to appear beyond the follicle; in others they grow to a great length, as on the

scalp ; while along the margins of the eyelids, and in the whiskers and beard, they are remarkable for their thickness. Hairs are generally more or less flattened in form, and on transverse section present an elliptical or reniform outline. This examination also demonstrates that the centre of the hair is porous and loose in texture, while its periphery is dense ; thus affording ground for its division into a *cortical* and a *medullary* portion. The free extremity of a hair is generally pointed, and sometimes split into two or three filaments. Its attached extremity is implanted deeply in the integument, extending through the derma into the subcutaneous areolar tissue, where it is surrounded by adipose tissue. The central extremity of a hair is larger than its shaft, and is called the *root* or *bulb*. It is rounded or conical in shape.

The outer surface of the hair is covered by a layer of flattened cells, which overlap each other at the edges like the tiles of a house. The bulk of the shaft consists of cells which have become flattened, elongated, and welded together, the union being often so intimate that no indication of the individual elements from which it is formed can be made out, except by the aid of chemical reagents. Very small elongated nuclei may be demonstrated among the fibres, and occasional dark streaks, some of which are due to deposits of pigment, and others to air spaces. The bulb of the hair has projecting into it a small process or papilla from the derma ; it contains blood-vessels and nerves, and furnishes nutriment to the cells of the bulb, by the multiplication of which the hair increases in size.

The hair is contained in a depression passing deeply into the reticular layer of the corium, and

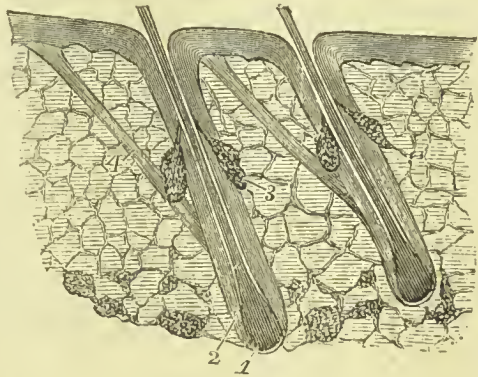


FIG. 79.—The hairs and their connections.
1. Hair bulb. 2. Inner sheath of the follicle. 3. Sebaceous gland. 4. Erector pili muscle.

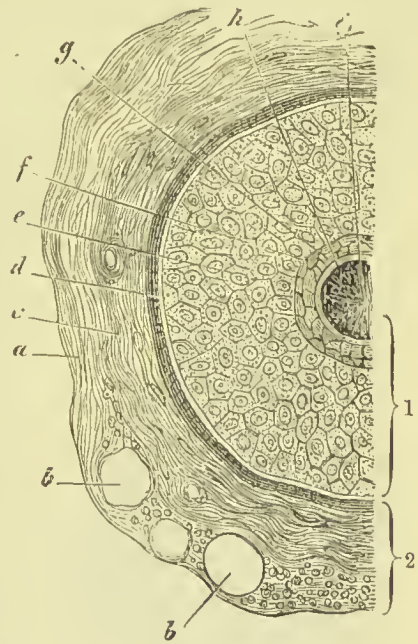


FIG. 80.—Section of a hair follicle.
1. Epidermic coat of follicle or root-sheath. 2. Dermic coat. a. Outer layer of dermic coat with blood-vessels, *b, b*, cut across ; *c*, middle layer ; *d*, inner or hyaline layer ; *e*, outer root-sheath ; *f, g*, inner root-sheath ; *h*, cuticle of root-sheath ; *i*, hair. (Schäfer after Biesiadecki.)

called the **hair follicle**. It is wide in its deepest part where it contains the bulb, gets narrower at the entrance of the ducts of the sebaceous glands, and again widens as it nears the surface. Its wall consists of two distinct layers, called respectively the **external** and **internal sheath of the follicle**, the former being continuous with the corium, and the latter with the epidermis. The *external* or *dermic sheath* is formed in its outer layers of longitudinal bundles of connective tissue, in which corpuscles are found, but no elastic fibres; internally it is distinguishable as a transparent homogeneous membrane, which corresponds to the basement membrane supporting epithelium in other tissues. The *internal* or *epidermic sheath* adheres closely to the root of the hair, and generally comes away with the latter when it is pulled out; hence it is called the **root-sheath**. It is also described as composed of an outer and an inner layer.

The *outer root-sheath* corresponds to the rete mucosum of the epidermis, and is composed of soft polygonal nucleated cells, which in the coloured races are generally pigmented; these cells become continuous at the bottom of the follicle with those forming the hair bulb. The *inner root-sheath* is again divisible into an inner layer (*Huxley's sheath*), formed of flattened, polygonal nucleated cells, two or three deep; and an outer layer (*Henle's sheath*) of oblong, flattened cells, without nuclei. On the inner surface of the inner root-sheath is a thin stratum of imbricated scales, closely applied to the surface of the hair, and forming the *cuticle of the root-sheath*.

Connected with the hair follicles there are some fine bands of unstriped muscular fibre. These arise from the superficial part of the

corium, and are inserted into the outside of the lower part of the follicle, below the sebaceous gland. They are placed on the side towards which the hair slopes, and by their contraction *erect* the hair; hence they have received the name of **erectores pili**.

The colour of the hair is due to pigment deposited in the central cells.

The **SEBACEOUS GLANDS** are embedded in the substance of the derma, and present every degree of complexity, from the simplest follicle to the compound lobulated gland. In some situations their excretory ducts open independently on the surface of the epidermis; but for the most part they terminate in the follicles of the hairs. The sebaceous glands associated

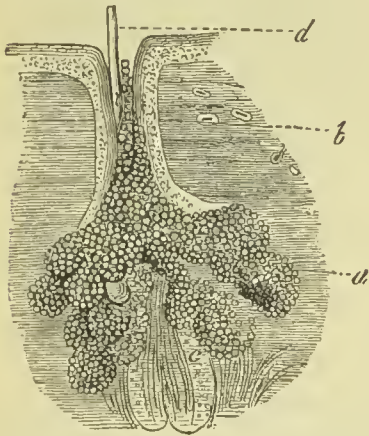


FIG. 81.—A sebaceous gland. *a.* The gland vesicles. *b.* Excretory duct. *c.* The follicle of a downy hair. *d.* Shaft of the latter.

with the hairs are racemose and lobulated, consisting of glandular vesicles lined with polyhedral or spheroidal cells; the central cavity of the gland is occupied by round cells containing fat, mixed

with epithelial and fatty debris, forming the glandular secretion. The ducts of the several acini unite to form a common duct, and the latter, after a short course, terminates in the hair follicle. In the scalp there are two of the glands to each hair follicle. On the nose and face the glands are of large size, and constantly associated with small hair follicles. The ducts are lined by an inversion of the epidermis, which forms a thick and funnel-shaped cone at its commencement, but soon becomes uniform and soft. Sebaceous glands are met with in all parts of the body, but are most abundant in the skin of the face, and in those situations which are naturally exposed to the influence of friction.

The **SUDORIFEROUS** or **SWEAT GLANDS** are situated deeply in the corium and also in the subcutaneous areolar tissue, where they are surrounded by adipose tissue. They are small round or oblong bodies, composed of one or more convoluted tubuli, which open into a common efferent duct. The latter ascends from the gland through the derma and epidermis, and terminates on the surface by a funnel-shaped and oblique aperture or pore. Each gland mass is surrounded by a fine plexus of capillary vessels. The efferent duct presents some variety in its course upwards; within the

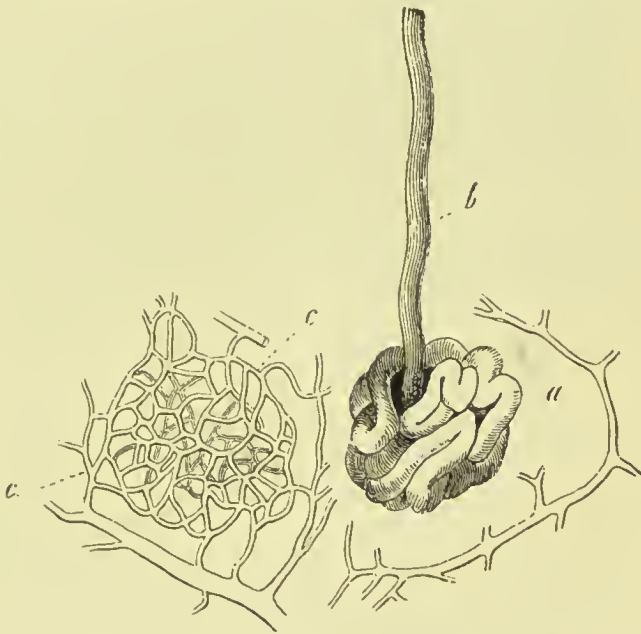

FIG. 82.—Sudoriferous gland and its capillary plexus. *a.* Convoluted portion. *b.* Excretory duct. *c, c.* Basket-like capillary plexus from around a convolution, with arterial twigs.

derma it is straight, or curved and serpentine, and if the epidermis be thin, proceeds more or less directly to the excreting pore. Sometimes it is spirally curved within the derma, and having passed the latter, is regularly and beautifully spiral in its passage through the epidermis, the last forming an oblique and valvular opening on the surface. The spiral course of the duct is especially remarkable in the thick epidermis of the palm of the hand and sole of the foot. On those parts of the skin where the papillæ are irregularly distributed, the efferent ducts of the sudoriferous glands open on the surface also irregularly, while on the palmar and plantar surfaces of the hands and feet, the pores are situated at regular distances along the ridges, at points corresponding with the intervals of the small,

square-shaped clumps of papillæ. Indeed, the apertures of the pores, seen on the surface of the epidermal ridges, give rise to the appearance of small transverse furrows, which intersect the ridges from point to point.

The efferent duct of the sudoriferous gland is lined by epithelium consisting of one or more strata of cells; the convoluted tubule forming the deep part of the gland is lined by a single layer of cubical cells, supported by a basement membrane. The latter are the secreting cells of the gland; they often have a vertical striation, giving them the appearance of being made up of a series of rods, a character they possess in common with the cells of the kidney and other secreting organs. In some of the larger glands a longitudinal layer of unstriped muscular fibre is found in the outer coat, in addition to the connective tissue which forms this coat in the rest of the glands.

The *ceruminous glands* of the external auditory meatus are regarded as modified sweat glands, but their secretion in some respects resembles that of the sebaceous glands.

PART II.

OSTEOLOGY.

THE skeleton is the bony framework which forms the support of the body, and affords points of attachment for the muscles by which the movements are effected. The fundamental part of the skeleton is the spine or vertebral column (from *verto*, I turn), because it is the axis around which all the other parts are disposed and on which they move. It exists in all animals possessing an internal skeleton, which are therefore called vertebrate animals.

The entire osseous framework of the body constitutes the skeleton, which in the adult man is composed of two hundred distinct bones. They may be thus arranged :—

		Cranium	8	} Skull
		Face	14	
Axial skeleton	{	Vertebral column	24	
		Sacrum and coccyx	2	
		Os hyoides	1	
		Sternum and ribs	25	
Appendicular skeleton	{	Upper extremities	64	
		Lower extremities	60	
		Patellæ	2	
			200	

In addition to this number, there are six ossicles of the ear and a variable number of sesamoid bones.

GENERAL CHARACTERS OF BONES.

Bones are divisible into four classes :—**Long, flat, short, and irregular.**

The **long** bones are found principally in the limbs, and consist of a shaft and two extremities. The shaft is cylindrical or prismoid in form, dense and hard in texture, and hollowed in the interior into a medullary canal. The extremities are broad and expanded to articulate with adjoining bones ; and are cancellous in internal

structure. Upon the exterior of the bones are processes and rough surfaces for the attachment of muscles, and foramina for the transmission of vessels and nerves. The character of long bones is, therefore, their general type of structure and their divisibility into a central portion and extremities, and not so much their length; for there are certain long bones, as the second phalanges of the toes, which are less than a quarter of an inch in length, and which, in some instances, exceed in breadth their longitudinal axis. The long bones are, the clavicle, humerus, radius and ulna, femur, tibia and fibula, metacarpal bones, metatarsal, phalanges, and ribs.

Flat bones are composed of two layers of dense bone with intermediate loose structure. They are adapted to enclose cavities; have processes upon their surface for the attachment of muscles; and are perforated by foramina for the passage of nutrient vessels to the cavities in their interior, and for the transmission of vessels and nerves. They articulate with long bones by means of smooth surfaces plated with cartilage, and with each other, either by fibrocartilaginous tissue, as at the symphysis pubis; or by suture, as in the bones of the skull. The two condensed layers of the bones of the skull are named, tables; and the intermediate open structure, diploë. The flat bones are, the occipital, parietal, frontal, nasal, lachrymal, vomer, sternum, scapulæ, and innominate bones.

Short bones have an exterior shell of dense bone filled with spongy or cancellous substance; of this sort are the bones of the carpus and tarsus, and the sesamoid bones, including the patella.

The **irregular** bones include all that remain after the long, short, and flat bones have been excluded. They are essentially irregular in their form, in some parts flat, in others short and thick; and are constructed on the same general principle as other bones. The bones of this class are, the temporal, sphenoid, ethmoid, superior maxillary, inferior maxillary, palate, inferior turbinated, hyoid, vertebræ, sacrum, and coccyx.

The *skeleton* is divisible into: 1. The vertebral column, or central axis. 2. The head and face, or superior development of the central axis. 3. The hyoid arch. 4. The shoulder girdle and upper extremities. 5. The pelvic girdle and lower extremities.

VERTEBRAL COLUMN.

The **vertebral column** is the central axis which supports the head, thorax, and upper extremities. It consists of numerous separate bones called *vertebræ*, which, although possessing a limited degree of motion on each other, yet give to the whole column considerable flexibility.

The vertebræ admit of a division into *true* and *false*. The true vertebræ are twenty-four in number; and are classed, according to the three regions of the trunk which they occupy, into cervical, dorsal, and lumbar. The false or fixed vertebræ consist of nine

pieces united into two bones, the sacrum and coccyx. The arrangement of the vertebræ may be better comprehended by means of the accompanying table :—

True vertebræ	{	7 Cervical,	False vertebræ	{	5 Sacrum,
24		12 Dorsal,	9		4 Coccyx.
		5 Lumbar.			

Characters of a Vertebra.—A vertebra consists of a body or centrum, two laminae, a spinous process, two transverse processes, and four articular processes. The *body* or *centrum* is the solid part of the vertebra; and, by its articulation with adjoining vertebræ, gives strength and support to the trunk. It is flattened above and below, convex in front, and slightly concave behind. Its anterior surface is constricted around the middle, and pierced by numerous small openings, which give passage to nutrient vessels. On its posterior surface is a single irregular opening, or several, for the exit of the *venæ basis vertebræ*.

The *laminae* commence upon the sides of the posterior part of the body of the vertebræ by two *pedicles*; they then expand, and, arching backwards, enclose a *foramen (neural canal)*, which serves for the protection of the spinal cord. The upper and lower borders of the laminae are rough for the attachment of the ligamenta subflava. The concavities above and below the pedicles are the *intervertebral notches*. The *spinous process* stands backwards from the angle of union of the laminae. It is the succession of these projecting processes along the middle line of the back, that has given rise to the common designation of the vertebral column, the *spine*. The use of the spinous process is for the attachment of muscles. The *transverse processes* project one at each side from the laminae of the vertebra; they also are intended for the attachment of muscles. The *articular processes*, four in number, stand upwards and downwards from the laminae, to articulate with the vertebra above and below.

Cervical Vertebræ.—In a cervical vertebra the body is smaller than in the other regions; it is broad from side to side, concave on the upper surface and convex below, so that, when articulated, the vertebræ lock the one into the other. The lateral borders of the upper surface are produced into prominent ridges, and the anterior edge of the lower surface overlaps that of the vertebra below. The *laminae* are narrow and long, and the included *spinal foramen* large and triangular. The *superior intervertebral notches* are slightly deeper than the inferior; the *inferior* being the broadest. The *spinous process* is short and bifid at the extremity, increasing in length from the fourth to the seventh. The *transverse processes* are also short and bifid, and deeply grooved along the upper surface for the cervical nerves. Piercing the base of the transverse process is the vertebral foramen, which gives passage to the vertebral artery and vein, and vertebral plexus of nerves. The artery commonly passes only through the vertebral foramina of

the six upper vertebræ ; the vein more frequently passes through the foramina of all seven. The transverse processes in this region are formed by two small developments, which proceed, the one from the side of the body, the other from the pedicle, and unite near their extremities to enclose the circular area of the vertebral foramen. The anterior of these processes is the rudiment of a cervical rib ; the posterior, the homologue of the transverse processes in the dorsal region. The extremities of these developments are the *anterior* and

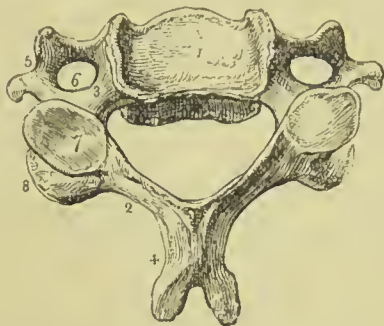


FIG. 83.—A middle cervical vertebra, seen upon its upper surface. 1. The body, concave in the middle, and rising on each side into a sharp ridge. 2. The lamina. 3. The pedicle, rendered concave by the superior intervertebral notch. 4. The bifid spinous process. 5. The bifid transverse process. The number is placed in the concavity between the anterior and posterior tubercle. 6. The vertebral foramen. 7. The superior articular process, looking backwards and upwards. 8. The inferior articular process.

posterior tubercle of the transverse process.* The *articular processes* are oblique ; the superior looking upwards, backwards, and a little inwards ; the inferior downwards, forwards, and a little outwards.

There are three peculiar vertebræ in the cervical region :—The first, or atlas ; the second, or axis ; and the seventh, or vertebra prominens.

The **Atlas** (named from supporting the head) is a simple ring of

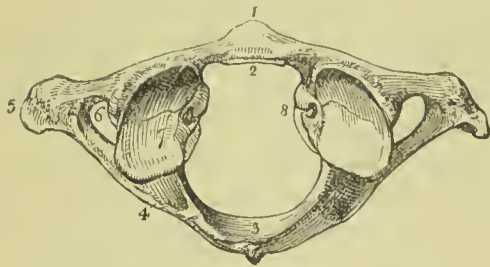


FIG. 84.—The upper surface of the atlas. 1. The anterior tubercle projecting from the anterior arch. 2. The articular surface for the odontoid process on the posterior surface of the anterior arch. 3. The posterior arch, with its rudimentary spinous process. 4. The intervertebral notch. 5. The transverse process. 6. The vertebral foramen. 7. Superior articular surface. 8. Tubercle for the attachment of the transverse ligament.

bone, without body, and composed of arches and processes. The *anterior arch* is the shortest ; it has a tubercle on its anterior surface, for the attachment of the longus colli muscle ; and on its posterior aspect a smooth surface, for articulation with the odontoid process of the axis.

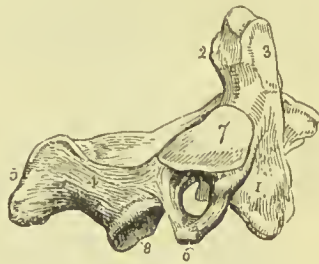
The *posterior arch* is longer and more slender than the anterior, and flattened from above downwards ; at its middle is a rudimentary

* The anterior tubercle of the sixth cervical vertebra is more prominent than the rest ; it has been named the *carotid tubercle*, from its close relation to the common carotid artery, and *Chassaignac's tubercle*, from the author who first pointed out this relation.

spinous process, which gives origin to the *rectus capitis posticus minor* muscle; and upon its upper surface, near the articular processes, a shallow groove at each side (sometimes converted into a foramen), which represents a superior intervertebral notch, and supports the vertebral artery (just before it perforates the *dura mater*) and the first cervical nerve. The intervertebral notches are peculiar, from being situated behind the articular processes, instead of before them as in the other vertebræ. The *transverse processes* are not bifid; they are remarkably large and long, and give attachment to the oblique muscles which rotate the head; they are pierced by the foramina for the vertebral arteries. The *articular processes* are situated on the most bulky and strongest part of the atlas. The superior are oval and concave, and look inwards, so as to form a kind of cup for the condyles of the occipital bone, and are adapted to the nodding movements of the head; the inferior are circular, and nearly horizontal, to permit of the rotatory movements. Upon the inner face of the *lateral mass* which supports the articular processes, is a small tubercle at each side, to which the extremities of the transverse ligament are attached, a ligament which divides the ring of the atlas into two unequal segments: the smaller and anterior, for receiving the odontoid process of the axis; the larger and posterior, to give passage to the spinal cord and its membranes.

The **Axis** (*vertebra dentata*) is so named from having a process shaped like a tooth, forming a pivot upon which the head turns. The

FIG. 85.—A lateral view of the axis. 1. The body; the number is placed on the depression which gives attachment to the *longus colli*. 2. The odontoid process. 3. The smooth facet on the anterior surface of the odontoid process which articulates with the anterior arch of the atlas; the facet for the transverse ligament is beneath No. 2, where the constriction called the neck of the odontoid process is seen. 4. The lamina. 5. The spinous process. 6. The transverse process, pierced obliquely by the vertebral foramen. 7. The superior articular surface. 8. The inferior articular process.



body is of large size, and supports a strong process, the odontoid, which rises perpendicularly from its upper surface. The *odontoid process* presents two articulating surfaces; one on its anterior face, to articulate with the anterior arch of the atlas; the other on its posterior face, for the transverse ligament: the latter surface constricts the base of the process, which has given rise to the term *neck* applied to this part. The tip of the odontoid process is often marked by a spine or ridge which gives attachment to the middle check ligament (*ligamentum suspensorium dentis*). Upon each side of its apex is a rough depression, for the attachment of the lateral odontoid or check ligaments; and running down from its base, on the anterior surface of the body of the vertebra, a vertical ridge, with a depression at each side for the attachment of the *longus colli* muscle. The *laminae* are large and strong, and unite posteriorly to form a bifid

spinous process, which is concave beneath, and by its upper surface gives attachment to the inferior oblique muscle. The *transverse processes* are rudimentary, not bifid, and project only so far as to enclose the vertebral foramen, which is directed obliquely outwards instead of perpendicularly as in the other vertebræ. The *superior articulating processes* are situated on the body of the vertebra, at each side of the odontoid process. They are circular and nearly horizontal, having a slight inclination outwards. The *inferior articulating processes* look downwards and forwards, as do the same processes in the other cervical vertebræ. The *superior intervertebral notch* is remarkably shallow, and lies behind the articular process as in the atlas; the *inferior notch* lies in front of the articular process, as in the rest of the vertebræ. The lower surface of the body is convex, and is received into the concavity upon the upper surface of the third vertebra.

The **Vertebra prominens**, or seventh cervical, approaches in character the upper dorsal vertebræ. It has received its designation from having a very long spinous process, which is single and terminated by a tubercle, and forms a projection on the back part of the neck; to the extremity of this process the ligamentum nuchæ is attached. The transverse processes are but slightly grooved along the upper surface, have each a small foramen for the transmission of the vertebral vein, and present only a rudimentary bifurcation at their extremity. Sometimes the anterior tubercle represents a small but distinct rib.

Dorsal Vertebræ.—The *body* of a dorsal vertebra is as long from before backwards as from side to side, particularly in the middle of

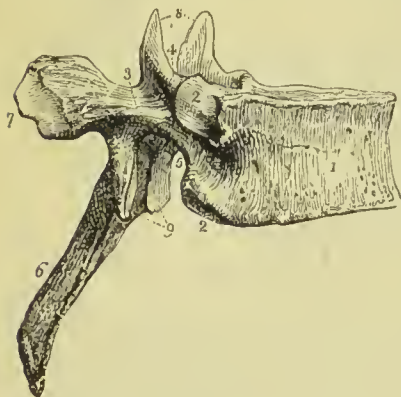


FIG. 86.—Lateral view of a dorsal vertebra. 1. The body. 2, 2. Articular facets for the heads of ribs. 3. The pedicle. 4. The superior intervertebral notch. 5. The inferior intervertebral notch. 6. The spinous process. 7. The extremity of the transverse process, marked by an articular surface for the tubercle of a rib. 8. The two superior articular processes looking backwards. 9. The two inferior articular processes looking forwards.

the dorsal region; it is thicker behind than before, and marked on each side by two half-articulating surfaces for the heads of two ribs. Its upper and lower surfaces are somewhat heart-shaped, and are nearly flat, but have a slightly sunken centre, with distinct margins of dense, smooth bone; in the recent state this is occupied by a plate of cartilage. The *pedicles* are strong, and the *laminae* broad and thick; the spinal *foramen* small and round, and the inferior *intervertebral notch* of large size; the superior can scarcely be said to exist. The *spinous process* is long, prismoid, directed very obliquely downwards,

and terminated by a tubercle. The *transverse processes* are large and strong, and directed obliquely backwards. Upon the anterior and superior aspect of their summits is a small facet for the articulation of the tubercle of a rib. The *articular processes* are nearly vertical, the superior facing backwards, slightly upwards and outwards; the inferior forwards, slightly downwards and inwards.

The **peculiar vertebræ** in the dorsal region are, the first, ninth,

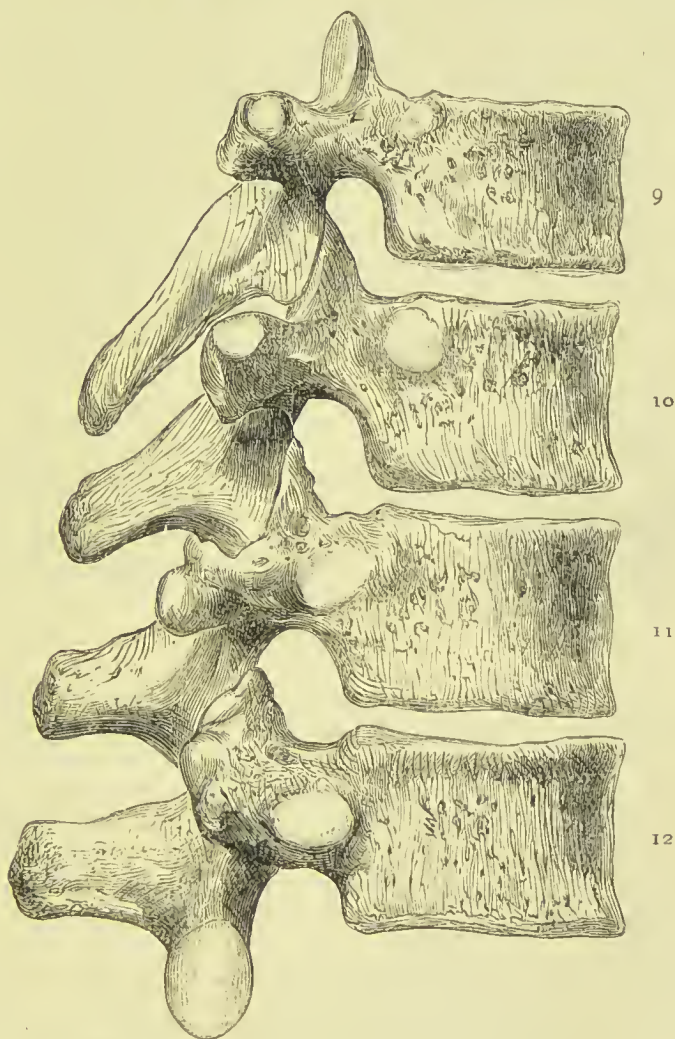


FIG. 87.—The ninth, tenth, eleventh, and twelfth dorsal vertebræ, showing their characteristic peculiarities.

tenth, eleventh, and twelfth. The **first** dorsal vertebra approaches very closely in character the last cervical. The body is broad from side to side, and concave above. It has an entire articular surface for the first rib, and a half surface for the second. The superior articular processes are oblique, and the spinous process horizontal. The **ninth** dorsal vertebra has only one half-articular surface at

each side of the upper part of the body. The **tenth** has a single entire articular surface at each side. The **eleventh** and **twelfth** have each a single entire articular surface at each side; they approach in character the lumbar vertebræ; their transverse processes are very short, and have no articulation with the corresponding ribs. The articular facets are placed partly on the thick and strong laminae, and partly on the bodies. The transverse processes of the twelfth dorsal vertebra are rudimentary, and are marked by three elevations, the *external*, *inferior* and *superior tubercles*, corresponding to the transverse, accessory and mammillary tubercles of lumbar vertebræ; traces of like tubercles are also observed in the tenth and eleventh vertebræ. The inferior articular processes of the last dorsal are convex and look outwards.

Lumbar Vertebræ.—These are the largest pieces of the vertebral column. The *body* is broad and large, its upper and lower surfaces are nearly flat, and present a kidney-shaped outline. The *pedicles* very strong; the *laminae* short, thick, and broad; the *inferior intervertebral notches* very large, and the *spinal foramen* large and oval. The *spinous process* is thick and broad. The *transverse processes*

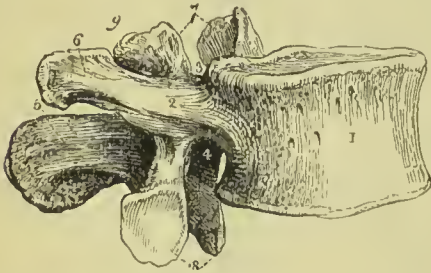


FIG. 88.—Lateral view of a lumbar vertebra. 1. The body. 2. The pedicle. 3. The superior intervertebral notch. 4. The inferior intervertebral notch. 5. The spinous process. 6. The transverse process. 7. The superior articular processes. 8. The inferior articular processes. 9. The mammillary process.

are slender, pointed, and directed very slightly backwards. The superior *articular processes* are concave, and look backwards and inwards; the inferior convex, looks forwards and outwards. The superior are much wider apart than the inferior, and embrace the inferior pair of the vertebra above. Projecting backwards and upwards from the superior articular process is a convex oval tubercle called the *mammillary process* (metapophysis), and in a well-marked vertebra there is at the base of this a smaller tubercle called the *accessory process* (anapophysis).

The **fifth lumbar vertebra** differs from the rest in having the body very much bevelled posteriorly, so as to be thick in front and thin behind; the transverse processes are thick and large, the lower articular processes are wider apart than the upper, and the laminae project into the spinal foramen on each side.

General Considerations.—Viewed as a whole, the vertebral column represents two pyramids applied base to base, the superior being formed by all the vertebræ from the second cervical to the last lumbar; the inferior by the sacrum and coccyx. Examined more attentively, it will be seen to be composed of four irregular pyramids, applied to each other by their smaller extremities and by their bases.

The smaller extremity of the uppermost pyramid is formed by the axis, or second cervical vertebra; and its base, by the first dorsal. The second pyramid is inverted; having its base at the first dorsal, and the smaller end at the fourth. The third pyramid commences at the fourth dorsal, and gradually enlarges to the fifth lumbar. The fourth pyramid is formed by the sacrum and coccyx.

The **bodies** of the vertebræ are broad in the cervical region; narrowed almost to an angle in the middle of the dorsal, and again broad in the lumbar region.

The **arches** are broad and imbricated in the cervical and dorsal regions, the inferior border of each overlapping the superior of the next; in the lumbar region an interval is left between them. A considerable interval exists between the cranium and atlas, and another between the last lumbar vertebra and sacrum.

The **spinous processes** are horizontal in the cervical, and become gradually oblique in the upper part of the dorsal region. In the middle of the dorsal region they are nearly vertical, and imbricated; towards its lower part they assume the direction of the lumbar spines, which are quite horizontal.

The **transverse processes**, although very prominent in the atlas, become almost rudimentary in the axis; they then gradually increase in length to the first dorsal vertebra. In the dorsal region they project obliquely backwards, and diminish suddenly in length in the eleventh and twelfth vertebræ, where they are very small. In the lumbar region they suddenly increase in size, the last lumbar being especially large and strong.

The **intervertebral foramina** formed by the juxtaposition of the intervertebral notches are smallest in the cervical region, and gradually increase to the last lumbar.

On each side of the spinous processes, and extending the whole length of the column, is the *vertebral groove*, which is shallow and broad in the cervical, and deeper and narrower in the dorsal and lumbar regions. It lodges the principal muscles of the back.

Curves of the Vertebral Column.—Viewed from the side, the vertebral column presents several curves, the principal of which is situated in the dorsal region, the concavity looking forwards. In the cervical and lumbar regions the column is convex in front; and in the pelvis an anterior concave curve is formed by the sacrum and coccyx. The dorsal curve is due to the bodies of the vertebræ in that region being thicker behind than in front; the cervical curve depends on the greater thickness of the intervertebral substance in front, and the lumbar curve results in the lower part from the thickness of the body of the last vertebra anteriorly, and in the upper part from the intervertebral substance being thicker in front. Besides the antero-posterior curves, a slight lateral curve sometimes exists in the dorsal region, having its convexity towards the right side. It is probably caused by habitual faulty posture in working at trades, associated with the use of the right hand.

Development.—The vertebræ are developed by three primary and

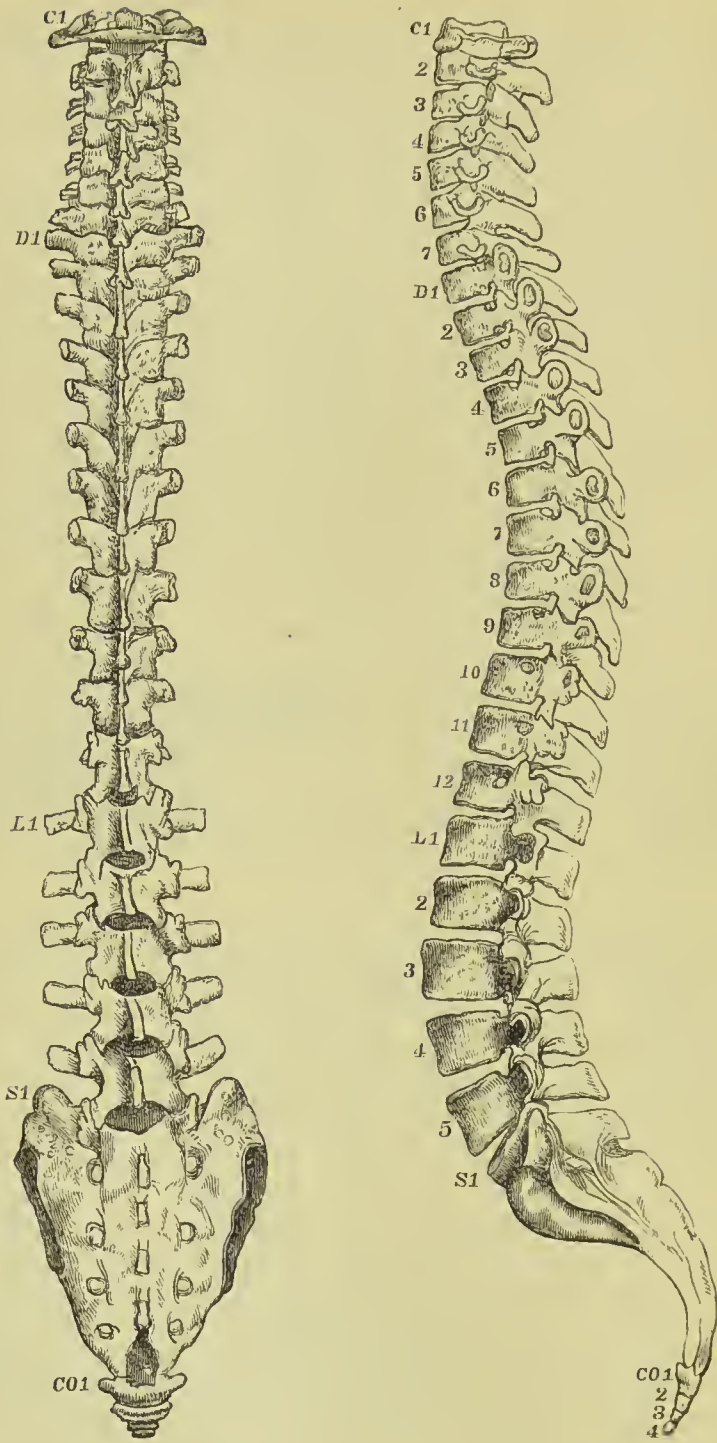


FIG 89.—Posterior and lateral view of spinal column.

five secondary centres or epiphyses. The **primary centres** are, one for each lamina, and one for the body; the **epiphyses**, one for the apex of the spinous process, one for that of each transverse process, one for the upper and one for the under surface of the body. Exceptions to this mode of development are met with in the atlas, axis, vertebra prominens, and lumbar vertebræ. The *atlas* has three centres; one for each lateral mass, and one (sometimes two) for the anterior arch. The *axis* has six; one (sometimes two) for the body; two placed side by side in the base of the odontoid process, and a third at its tip; lastly, one for each lamina. The *vertebra prominens* has two additional centres for the anterior or costal segments of the transverse processes, and the *lumbar vertebræ*, two for the mammillary processes.

The primary centres of the vertebræ make their appearance during the seventh or eighth week of embryonic existence, the laminæ being somewhat in advance of the body. From the laminæ are produced the spinous, transverse, and articular processes, and the sides of the body; they unite, to complete the arch, one year after birth, and with the body during the fifth year. The epiphyses for the extremities of the spinous and transverse processes make their appearance at fifteen or sixteen, and become united to the rest of the bone between twenty and twenty-five. The epiphyses of the body are somewhat later in appearance, and are consolidated between the periods of twenty-five and thirty years of age.

The ossific centres for the lateral masses of the *atlas* appear at the same time as those of the other vertebræ; they unite posteriorly at the end of the second year. The one or two centres of the anterior arch appear during the first year, and become consolidated with the lateral pieces during the fifth or sixth year. The *axis* develops its lateral pieces at the same time as the other vertebræ; they join posteriorly soon after birth, and with the body during the fourth or fifth year. The centres for the body and odontoid process appear during the sixth month, and are consolidated during the third year. The body of the axis is more largely developed at birth than that of the other vertebræ. The costal segments of the *vertebra prominens* appear during the sixth month, and become united to the body at the fifth or sixth year; they sometimes remain permanently separate, and constitute cervical ribs. The lumbar vertebræ have separate centres for the mammillary processes, but the transverse process of the first lumbar is sometimes developed altogether from a separate centre, and may remain permanently separate, in that case forming a lumbar rib.

The ossification of the arches of the vertebræ commences from above, and proceeds gradually downwards; hence arrest of development gives rise to spina bifida, generally in the loins. Ossification of the bodies, on the contrary, commences near the centre, and proceeds towards the extremities of the column; hence imperfection of the bodies occurs either in the upper or lower vertebræ.

Attachment of Muscles.—To the *atlas* are attached nine pairs

of muscles, the longus colli, rectus anticus minor, rectus lateralis, rectus posticus minor, obliquus superior and inferior, splenius colli, levator anguli scapulæ, and first intertransverse.

To the *axis* are attached eleven pairs—viz., longus colli, intertransverse, obliquus inferior, rectus posticus major, interspinal, semispinalis colli, multifidus spinæ, levator anguli scapulæ, splenius colli, transversalis cervicis, and scalenus medius.

To the remaining *vertebræ* collectively, thirty-one pairs and one single muscle—viz., *posteriorly*, trapezius, latissimus dorsi, levator anguli scapulæ, rhomboideus minor and major, serratus posticus superior and inferior, splenius, sacro-lumbalis, longissimus dorsi, spinalis dorsi, cervicalis ascendens, transversalis cervicis, trachelomastoid, complexus, semispinalis dorsi and colli, multifidus spinæ, interspinal, intertransverse, levatores costarum: *anteriorly*, rectus anticus major, longus colli, scalenus anticus, medius, and posticus, psoas magnus, psoas parvus, quadratus lumborum, diaphragm, obliquus internus and transversalis.

The **SACRUM** is a triangular bone, situated at the lower extremity of the vertebral column, and formed by the consolidation of five

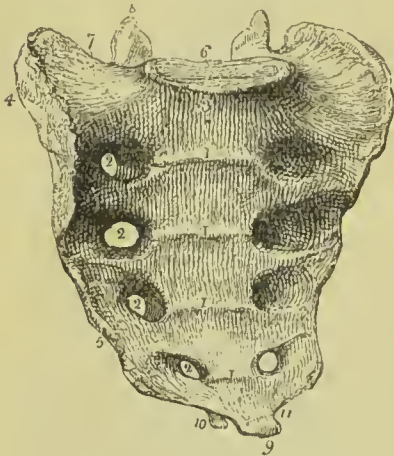


FIG. 90.—The sacrum seen upon its anterior surface. 1, 1. Transverse lines marking the original constitution of the bone of five pieces. 2, 2. Anterior sacral foramina. 3. Promontory of the sacrum. 4. Auricular surface to articulate with the ilium. 5. The sharp edge to which the sacro-ischiatic ligaments are attached. 6. The vertebral articular surface. 7. The broad triangular surface which supports the psoas muscle and lumbo-sacral nerve. 8. Articular process of the right side. 9. Inferior extremity, or apex of the sacrum. 10. One of the sacral cornua. 11. The notch which is converted into a foramen by the coccyx.

false vertebræ. It is divisible into an anterior and posterior surface, two lateral and a superior border, and an inferior extremity.

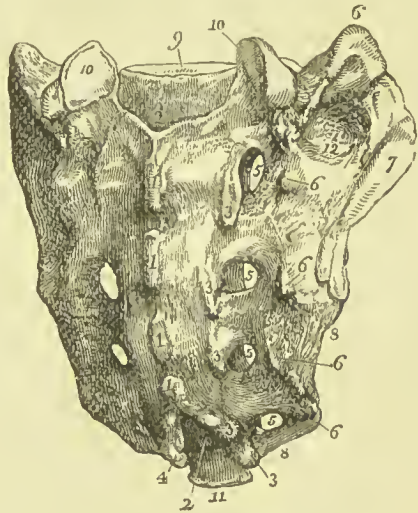
The *anterior surface* is concave, and marked by four transverse lines, which indicate its original constitution of five separate pieces. At the extremities of these lines, on each side, are the four anterior sacral foramina, which diminish in size from above downwards, and transmit the anterior sacral nerves. The ridges between the anterior sacral foramina give attachment to the pyriformis muscle. The projection of the superior piece is the sacro-vertebral angle or *promontory*.

The *posterior surface* is narrower than the anterior, and convex. On a middle line is a rough crest, formed by the rudiments of four spinous processes, the fifth remaining undeveloped, and exposing the lower termination of the sacral canal. Immediately external to and

parallel with the median crest, is a range of five small tubercles which represent the articular processes of the true vertebræ ; beyond these is a shallow groove in which the four posterior sacral foramina open, and farther outwards, a range of five tubercles corresponding with the transverse processes of the lumbar vertebræ. The lowest pair of articular tubercles bound on each side the termination of the sacral canal, and send each a process downwards to articulate with the coccyx. The two descending processes are the *sacral cornua*. The posterior sacral foramina are smaller than the anterior, and transmit the posterior sacral nerves. Of the posterior transverse tubercles the *first* corresponds with the angle of the superior border of the bone ; the *second* is small, and enters into the formation of the sacro-iliac articulation ; the *third* is large, and gives attachment to the oblique sacro-iliac ligament ; the *fourth* and *fifth* are smaller, and serve for the attachment of the sacro-ischiatic ligaments.

The *lateral border* of the sacrum presents superiorly a broad and

FIG. 91.—Posterior view of the sacrum. 1, 1. The four rudimentary spinous processes. 2. The sacral canal. 3, 3. Rudimentary articular processes. The lowest of these processes, with the corresponding process of the opposite side, 4, are the sacral cornua. 5, 5. The four posterior sacral foramina. 6, 6. Posterior transverse tubercles. 7. The auricular surface. 8. Sharp edge for the attachment of the sacro-ischiatic ligaments. 9. Surface for articulation with the body of the last lumbar vertebra. 10, 10. Articulating facets of the articular processes. 11. Apex of the sacrum by which it articulates with the coccyx. 12. Rough surface for the attachment of the posterior sacro-iliac ligaments.



ear-shaped (auricular) surface to articulate with the ilium ; and inferiorly a sharp edge, to which the greater and lesser sacro-ischiatic ligaments are attached. The back part of this border is marked by rough prominences and deep depressions for the posterior sacro-iliac ligaments.

On the *superior border*, in the middle line, is an oval articular surface, corresponding with the under part of the body of the last lumbar vertebra ; and on each side a broad triangular surface, which supports the lumbo-sacral nerve and psoas magnus muscle. Immediately behind the vertebral articular surface is the triangular entrance of the sacral canal ; and, on each side of this opening, an articular process, which looks backwards and inwards, like the superior articular processes of the lumbar vertebræ. In front of each articular process is an intervertebral notch.

The *inferior extremity* of the bone presents a small oval surface which articulates with the coccyx ; and on each side a notch, which,

with a corresponding notch in the upper border of the coccyx, forms the foramen for the transmission of the fifth sacral nerve.

The sacrum presents some variety in respect of curvature, and of the number of pieces which enter into its structure. The curve is often very slight, and situated only near the lower part of the bone; while in other subjects it is considerable, and occurs at the middle of the sacrum. It is sometimes composed of six pieces, more rarely of four, and, occasionally, the first and second pieces remain permanently separate. The female sacrum is wider and shorter than the male, its curvature is less, and is almost confined to the lower part of the bone; it also forms a greater angle with the rest of the vertebral column.

Development.—By *thirty-five* points of ossification; five for each of the first three pieces—viz., one for the body, one for each lateral portion, and one for each lamina; and three for each of the last two—namely, one for the body and one for each lateral portion. In the progress of growth, and after puberty, fourteen epiphyseal centres are added—namely, two for the surfaces of each body, one for each auricular surface, and one for the thin edge of each lateral border. Ossification begins in the bodies of the sacral pieces somewhat later than in those of the true vertebræ; the first three appearing during the eighth and ninth week, and the last two at about the middle of intra-uterine existence. Ossification of the laminae takes place during the interval between the sixth and ninth month. The epiphyses for the upper and under surface of the bodies are developed during the interval between the fifteenth and eighteenth year; and for the auricular and marginal piece, after twenty. The two lower vertebral pieces, although the last to appear, are the first to be completed (between the fourth and fifth year), and unite by their bodies. The union of the bodies takes place from below upwards, and finishes between the twenty-fifth and thirtieth year with the first two pieces.

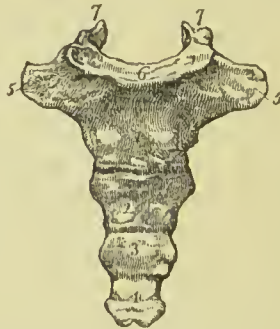
Articulation.—With *four* bones; the last lumbar vertebra, ossa innominata, and coccyx.

Attachment of Muscles.—To *seven* pairs; *in front*, pyriformis; *on the side*, coccygeus; and *behind*, gluteus maximus, latissimus

dorsi, erector spinæ, and multifidus spinæ.

The **COCCYX** (κόκκυξ, cuckoo, resembling a cuckoo's beak) is composed of four small pieces, which form the caudal termination of the vertebral column. The superior piece is broad, and expands laterally into

FIG. 92.—Front view of the coccyx. 1, 2, 3, 4. The four pieces of the bone. 5, 5. The transverse processes of the first piece. 6. Articular surface for the extremity of the sacrum. 7, 7. The cornua which articulate with the sacral cornua.



two transverse processes; it is surmounted by an oval articular surface and two cornua, the former to articulate with the apex of

the sacrum, the latter with the sacral cornua. The lateral wings sometimes become connected with the sacrum, and convert the notches for the fifth pair of sacral nerves into foramina. The remaining three pieces diminish in size from above downwards. The borders of the bone are narrow, and give attachment to the coccygens muscle; the inferior extremity is rounded, and has attached to it the fibres of the external sphincter ani.

Development.—By *four* centres, one for each piece, but, occasionally, one of the upper three pieces has an additional centre. Ossification commences in the first piece soon after birth; in the second, between five and ten years; in the third, between ten and fifteen; and in the fourth, between fifteen and twenty. The pieces unite at an earlier period than the bodies of the sacrum, the first two pieces first, then the third and fourth, and lastly the second and third. Between forty and sixty years, the coccyx becomes consolidated with the sacrum; this event taking place later in the female than in the male.

Articulations.—With the sacrum.

Attachment of Muscles.—To *three* pairs, and one single muscle; on *each side* the coccygens, *behind* the gluteus maximus, *in front* the levator ani, *at the tip* the sphincter ani.

OF THE SKULL.

The skull is divisible into two parts, the cranium and the face; the former being adapted, by its form, structure, and strength, to contain and protect the brain; the latter, the chief organs of sense.

The CRANIUM is composed of eight separate bones—viz., the

Occipital,	Two temporal,
Two parietal,	Sphenoid,
Frontal,	Ethmoid.

OCCIPITAL BONE.

This bone is situated at the posterior part and base of the cranium. It is trapezoid in figure, and divisible into two surfaces, four borders, and four angles.

External Surface.—Is convex from above downwards and from side to side. Crossing the middle of the bone transversely, from one lateral angle to the other, is a prominent ridge, which, as shown in the diagram, commonly consists of an upper and lower line with a smooth surface between them. The upper is called the *highest curved line*, and the lower the *superior curved line*. In the middle of the latter is a projection called the *external occipital protuberance*, for the attachment of the *ligamentum nuchæ*; and descending from it a small vertical ridge, the *external occipital crest*. Above and below the superior curved line the surface is rough, for the attachment of muscles. About three-quarters of an inch below the superior curved

line is another transverse ridge, the *inferior curved line*, and beneath the latter the *foramen magnum*. On each side of the foramen magnum, nearer its anterior than its posterior segment, and encroaching somewhat upon the opening, is an oblong articular surface, the *condyle*, for articulation with the atlas. The condyles approach towards each other anteriorly, their articular surfaces looking downwards and outwards. Directly behind each condyle is an irregular fossa, and, sometimes, a small opening, the *posterior condylar foramen*, for the transmission of a vein to the lateral sinus. In front of the condyle is the *anterior condylar foramen*, transmitting the hypoglossal nerve; on the outer side of each condyle, a projecting ridge, the *transverse* or *jugular process*, excavated in front by a notch (*jugular notch*) which forms part of the jugular foramen; and directly behind the ridge, and forming its posterior boundary, a prominent process, the *jugular tubercle*. In front of the foramen magnum is a thick square mass,

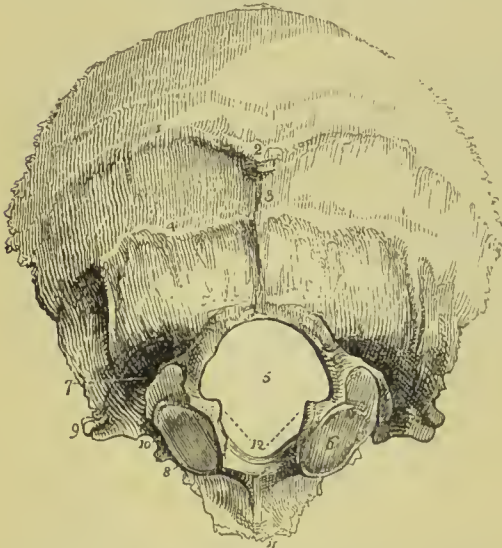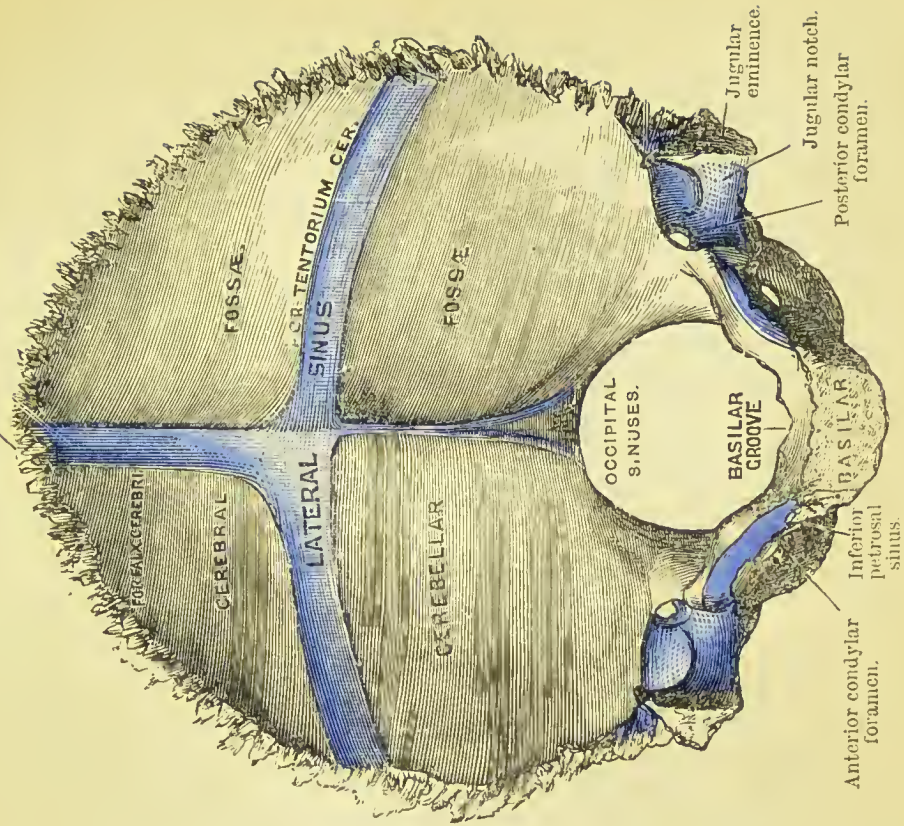
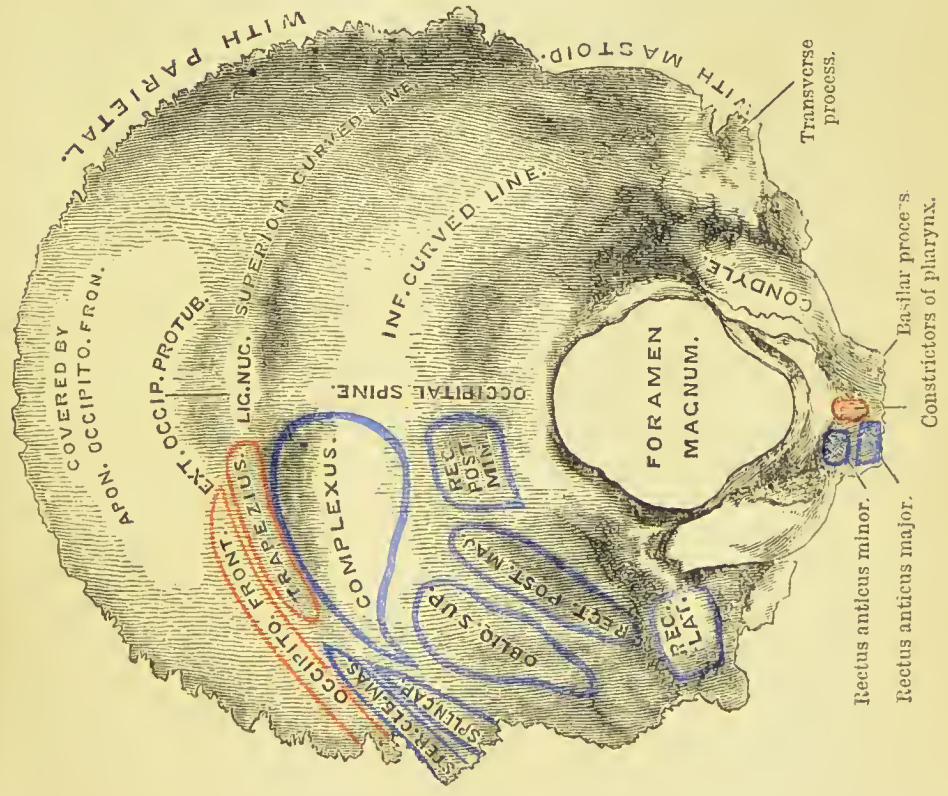


FIG. 93.—External surface of the occipital bone. 1. Superior curved line. 2. External occipital protuberance. 3. External occipital crest. 4. Inferior curved line. 5. Foramen magnum. 6. Condyle of the right side. 7. Posterior condylar fossa, in which the posterior condylar foramen is found. 8. Anterior condylar foramen concealed by the margin of the condyle. 9. Transverse process; this process on the internal surface of the bone forms the jugular eminence. 10. Jugular notch, forming part of the jugular foramen. 11. Basilar process. 12. Rough projections into which the odontoid ligaments are inserted.

the *basilar process*, and in its centre a small tubercle, the *pharyngeal tubercle* or *spine*, for the attachment of the tendinous raphé and superior and middle constrictor muscles of the pharynx.

Internal Surface.—The internal surface is concave from side to side and from above downwards; it is divided by a crucial ridge into four fossæ, the two superior or cerebral fossæ lodging the posterior lobes of the cerebrum, the two inferior or cerebellar, the lateral lobes of the cerebellum. The superior arm of the crucial ridge is grooved for the superior longitudinal sinus, and gives attachment to the falx cerebri; the inferior arm is sharp and prominent for the attachment of the falx cerebelli, and slightly grooved for the two occipital sinuses. The transverse ridge gives attachment to the tentorium cerebelli, and is deeply grooved for the lateral sinuses. At the point of meeting of the four arms is a projection, the *internal occipital protuberance*. The convergence of the four grooves forms a slightly depressed fossa (usually situated to the right of the internal

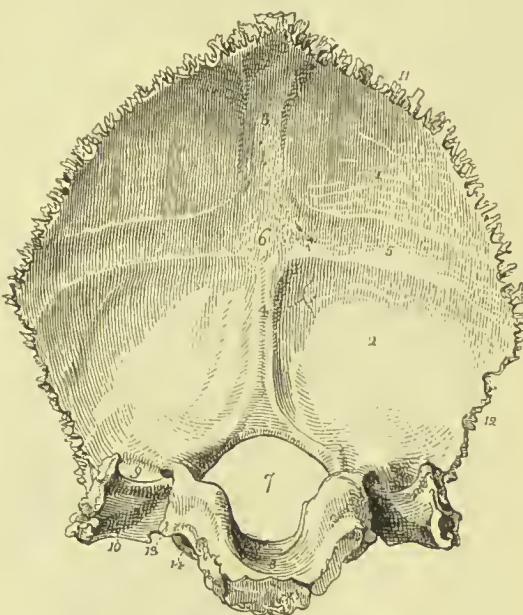
Superior longitudinal sinus.





occipital protuberance), upon which rests the torcular Herophili. In the centre of the basilar portion of the bone is the *foramen magnum*, oblong in form, and larger behind than before, transmitting the spinal cord and its membranes, the spinal accessory nerves, and vertebral and posterior meningeal arteries, and having its anterior constricted portion occupied by the tip of the odontoid process of the axis. Upon the lateral margins of the foramen magnum are two rough eminences, which give attachment to the odontoid ligaments, and immediately above these, the openings of the anterior condylar foramina. In front of the foramen magnum is the basilar process, grooved on its surface for supporting the medulla oblongata, and along each lateral border for the inferior petrossal sinus. On each side of the foramen magnum is a groove, for the termination of the lateral sinus; a smooth surface, which forms part of the jugular

FIG. 94.—Internal surface of the occipital bone. 1. Left cerebral fossa. 2. Left cerebellar fossa. 3. Groove for the posterior part of the superior longitudinal sinus. 4. Spine for the falx cerebelli, and groove for the occipital sinuses. 5. Groove for the left lateral sinus. 6. Internal occipital protuberance. 7. Foramen magnum. 8. Basilar process, grooved for the medulla oblongata. 9. Termination of the groove for the lateral sinus, bounded externally by the jugular eminence. 10. Jugular fossa; this fossa is completed by the petrous portion of the temporal bone. 11. Superior border. 12. Inferior border. 13. Border which articulates with the petrous portion of the temporal bone, grooved by the inferior petrosal sinus. 14. Anterior condylar foramen.



fossa; and a projecting process, which divides the two, and is called the *jugular eminence*. Into the jugular fossa will be seen opening the posterior condylar foramen.

The *superior borders* are strongly serrated, and assist in forming the lambdoidal suture; the *inferior* are rough, not serrated, and articulate with the mastoid portion of the temporal bones. The jugular eminence and side of the basilar process articulate with the petrous portion of the temporal bone, and the intervening space, which is irregularly notched, forms the posterior boundary of the jugular foramen, or foramen lacerum posterius.

The *angles* of the occipital bone are, the superior, inferior, and two lateral. The *superior angle* is received into the interval formed by the union of the posterior and superior angles of the parietal bones, and corresponds with that portion of the fetal head which is

called the *posterior fontanelle*. The *inferior angle* is the extremity of the basilar process, which in the adult is united with the sphenoid. The *lateral angles*, at each side, project into the interval formed by the articulation of the posterior and inferior angle of the parietal with the mastoid portion of the temporal bone.

Development.—By *seven* centres; four for the four parts of the expanded portion divided by the crucial ridge, one for each condylar part and one for the basilar portion. Ossification commences in the expanded portion of the bone during the eighth week. At birth the bone consists of four distinct pieces, called respectively *supra-occipital*, two *ex-occipitals*, and *basi-occipital*, the division between the basi-occipital and each ex-occipital passing through the anterior third of the condyles. The three first unite during the third or fourth year, the last joins them about the fourth to the sixth year. After twenty-five the basilar process unites with the body of the sphenoid. The part above the occipital protuberances is developed from membrane, the rest from cartilage.

Articulations.—With *six* bones; two parietal, two temporal, sphenoid, and atlas.

Attachment of Muscles.—To *twelve* pairs; to the *superior curved line*, the occipito-frontalis, trapezius and sterno-mastoid; to the *rough space between the curved lines*, complexus, and splenius capitis; to the *space between the inferior curved line and foramen magnum*, the rectus posticus major and minor, and obliquus superior; to the *transverse process*, the rectus lateralis; and to the *basilar process*, the rectus anticus major and minor, and superior and middle constrictors of the pharynx.

PARIETAL BONE.

The parietal bone (*paries*, a wall) is situated at the side and vertex of the skull; it is quadrilateral in form, and divisible into an



FIG. 95.—External surface of the left parietal bone. 1. Superior or saggital border. 2. Inferior or squamous border. 3. Anterior or coronal border. 4. Posterior or lambdoidal border. 5. Upper temporal crest; the figure is situated immediately in front of the parietal eminence. 6. The parietal foramen, unusually large in the bone from which this figure was drawn. 7. Anterior inferior angle. 8. Posterior inferior angle.

external and internal surface, four borders, and four angles. The superior border is straight, to articulate with its fellow of the

opposite side. The inferior border is arched and thin, to articulate with the temporal bone. The anterior border is concave, and the posterior somewhat convex.

External Surface.—Crossing the bone in a longitudinal direction from the anterior to the posterior border, is an arched line, the *temporal crest*, to which the temporal fascia is attached. Beneath this in well-marked specimens, and separated from it by a very narrow interval, is a second line limiting the attachment of the temporal muscle. In the middle of these lines, and nearly in the centre of the bone, is the projection called the *parietal eminence*, which marks the centre of ossification. Above the temporal crest the surface is rough, and covered by the aponeurosis of the occipito-frontalis; below the crest the bone is smooth, for the attachment of the fleshy fibres of the temporal muscle. Near the superior border of the bone, and at about one-third from its posterior extremity, is the *parietal foramen*, which transmits a vein to the superior longitudinal sinus. This foramen is often absent.

Internal Surface.—The internal table is smooth; it is marked by numerous furrows, which lodge the ramifications of the middle

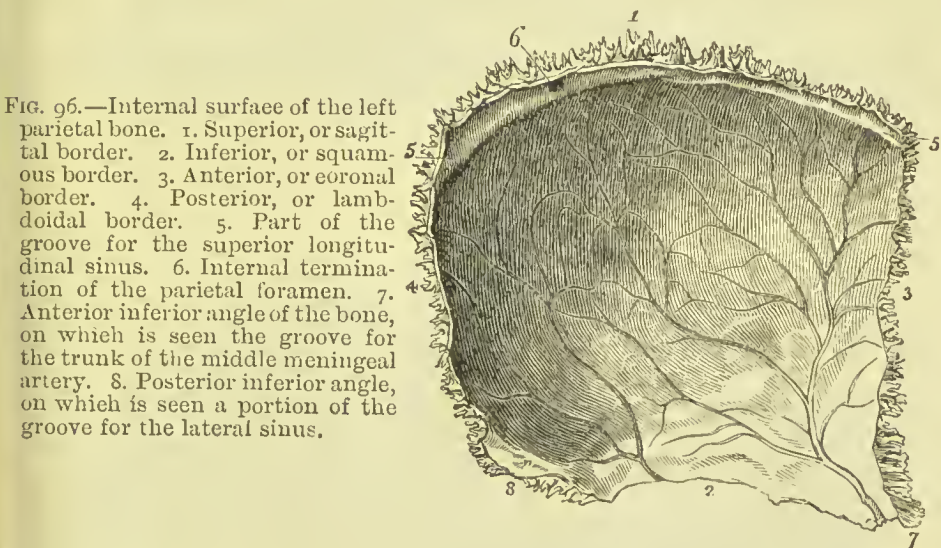


FIG. 96.—Internal surface of the left parietal bone. 1. Superior, or sagittal border. 2. Inferior, or squamous border. 3. Anterior, or coronal border. 4. Posterior, or lambdoidal border. 5. Part of the groove for the superior longitudinal sinus. 6. Internal termination of the parietal foramen. 7. Anterior inferior angle of the bone, on which is seen the groove for the trunk of the middle meningeal artery. 8. Posterior inferior angle, on which is seen a portion of the groove for the lateral sinus.

meningeal artery, and by irregular depressions called digital fossæ, which correspond with the convolutions of the brain. Along the upper border is part of a shallow groove, completed by the opposite parietal bone, which serves to contain the superior longitudinal sinus. Near this groove, some slight pits, which lodge the Pacchionian bodies, are also observable.

The *anterior inferior angle* is thin and lengthened, and articulates with the tip of the great wing of the sphenoid bone. Its inner surface is deeply grooved for the middle meningeal artery; the groove being frequently converted into a closed canal. The *posterior inferior angle* is thick, and presents a broad and shallow groove for the lateral sinus.

Development.—Ossified in membrane from a single centre which appears in the parietal eminence in the seventh week. At the time of birth the superior angles are unossified, and intervals are thus left between the parietal and frontal in front, and the parietal and occipital behind; these are called the *anterior* and *posterior fontanelles*.

Articulations.—With *five* bones; with the opposite parietal, occipital, frontal, temporal, and sphenoid.

Attachment of Muscles.—To *one* only, the temporal. The aponeurosis of the occipito-frontalis glides over its upper surface.

FRONTAL BONE.

The frontal bone bears some resemblance in form to the under valve of a scallop-shell. It is situated at the anterior part of the cranium, forming the forehead, and assisting in the construction of the roof of the orbits and nose. Hence it is divisible into a superior or frontal portion, and an inferior or orbito-nasal portion. Each of these portions presents for examination an external and internal surface, borders, and processes.

External Surface.—At about the middle of each lateral half of the frontal portion is a projection, the *frontal eminence*. Below these

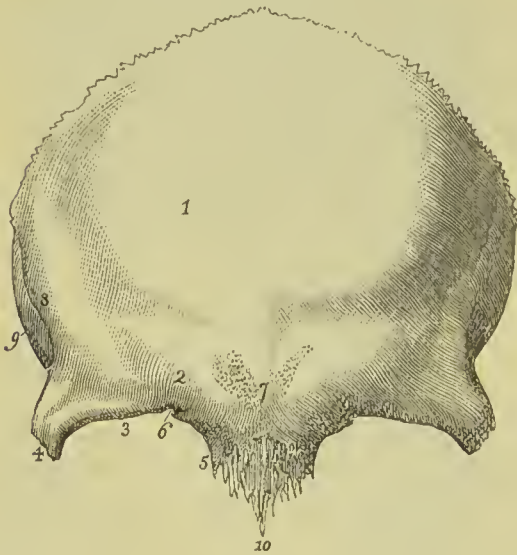
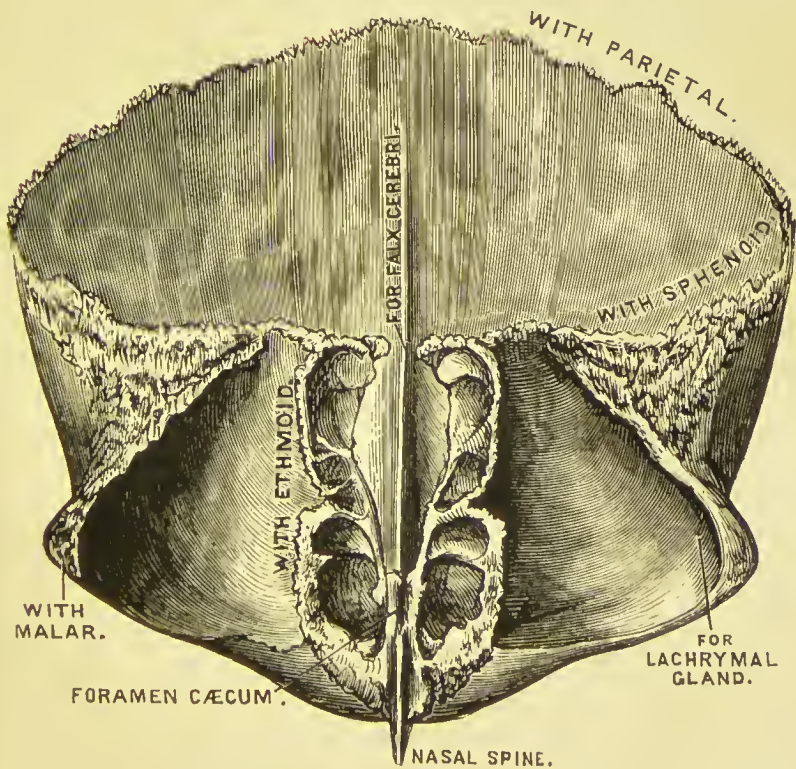
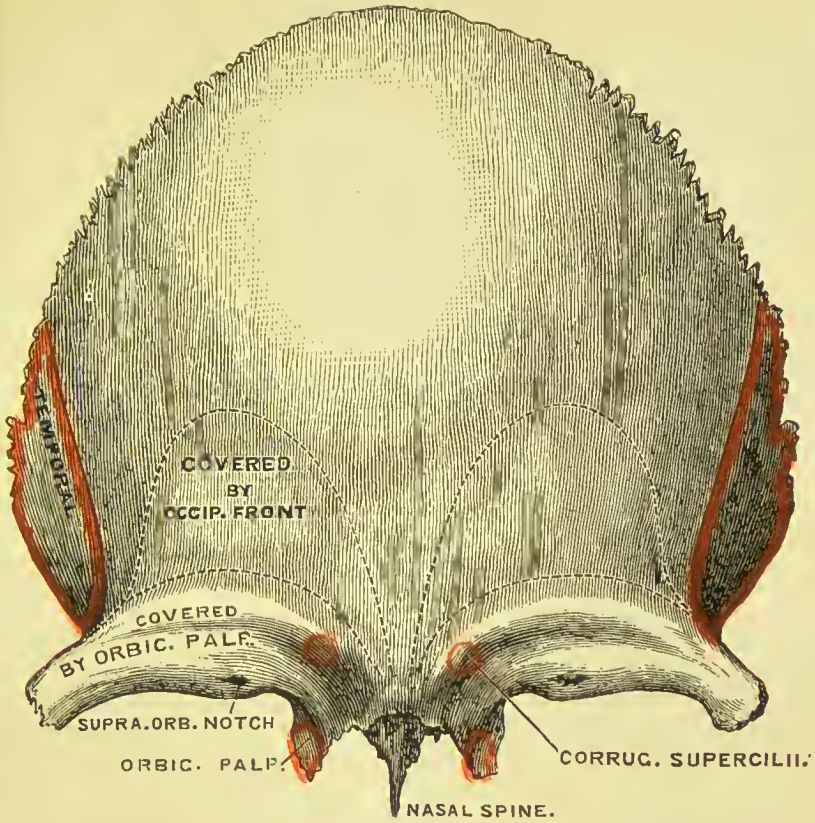


FIG. 97.—External surface of the frontal bone. 1. Situation of the frontal eminence of the right side. 2. Superciliary ridge. 3. Supraorbital ridge. 4. External angular process. 5. Internal angular process. 6. Supraorbital notch, for the transmission of the supra-orbital nerve and artery. 7. Glabella. 8. Temporal crest, commencing from the external angular process (4). 9. Part of the temporal fossa. 10. Nasal spine.

points are the *superciliary ridges*, large towards their inner termination, where they become continuous with the nasal tuberosity, and becoming gradually smaller as they arch outwards: they support the eyebrows. Beneath the superciliary ridges are the sharp and prominent arches which form the upper margin of the orbits, the *supraorbital ridges*. Externally the supraorbital ridge terminates in the *external angular process*, internally in the *internal angular process*;

PLATE 2.





at the inner third of this ridge is a notch, sometimes converted into a foramen—the *supraorbital notch*, which gives passage to the supra-orbital artery, veins, and nerve. Between the two superciliary ridges is a projection, the *glabella*; this portion of the bone denotes by its prominence the situation of the frontal sinuses. Extending upwards and backwards from the external angular process is a sharp ridge, the commencement of the *temporal crest*, and beneath the ridge a depressed surface, forming part of the *temporal fossa*, and giving attachment to the *temporal muscle*.

The *orbito-nasal portion* of the bone consists of two thin processes, the *orbital plates*, which form the roof of the orbits, and an intervening notch which lodges the ethmoid bone, and is called the *ethmoidal fissure*. The edges of the ethmoidal fissure are hollowed into cavities, which, by their union with the ethmoid bone, complete the ethmoidal cells. Crossing these edges transversely are two small grooves, which are converted into canals by articulation with the ethmoid: these are the *anterior* and *posterior internal orbital* (or *ethmoidal*) *canals*; they open on the inner wall of the orbit,—the anterior transmitting the anterior ethmoidal vessels and nasal nerve, the posterior giving passage to the posterior ethmoidal vessels. At the anterior termination of these edges are the irregular openings which lead into the frontal sinuses; and between the two internal angular processes is a rough excavation which receives the nasal bones, and a projecting process, the *nasal spine*. On each orbital plate, immediately beneath the external angular process, is a shallow depression which lodges the lachrymal gland; and beneath the internal angular process a small pit (*trochlear fossa*), sometimes a tubercle, to which the cartilaginous pulley of the superior oblique muscle of the eye is attached.

Internal Surface.—Along the middle line of this surface is a *grooved ridge*, the edges of the ridge giving attachment to the falx cerebri, the groove lodging the superior longitudinal sinus. At the commencement of the ridge is an opening, sometimes completed by the ethmoid bone, the *foramen cæcum*. This opening lodges a process of the dura mater, and occasionally gives passage to a small vein which communicates with the nasal veins. On each side of the vertical ridge are some slight depressions which lodge the Pacchionian bodies, and branching grooves for meningeal vessels. There are also numerous shallow depressions called *digital fossæ*, which correspond with the convolutions of the anterior lobes of the cerebrum; these are especially distinct on the orbital plates.

The *superior border* is thick and strongly serrated, bevelled at the expense of the internal table in the middle, where it rests on the junction of the two parietal, and at the expense of the external table on each side where it receives the lateral pressure of those bones. The *inferior border* is thin, irregular, and squamous, and articulates with the sphenoid bone.

Development.—By *two* centres, one for each lateral half, which appear in the orbital arches about the seventh week. The two

pieces are separate at birth, and unite by suture during the first year, the suture sometimes remaining permanent through life, *frontal suture*. The frontal sinuses make their appearance during

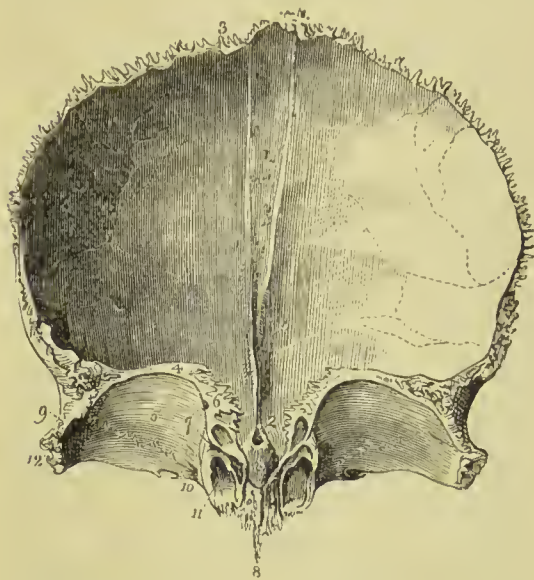


FIG. 98.—Internal surface of the frontal bone; the bone is raised to show the orbito-nasal portion. 1. Grooved ridge for the lodgment of the superior longitudinal sinus and attachment of the falx. 2. Foramen caecum. 3. Superior or coronal border of the bone; the figure is situated near that part which is bevelled at the expense of the internal table. 4. Inferior border of the bone. 5. Orbital plate of the left side. 6. Cellular border of the ethmoidal fissure. The foramen caecum (2) is seen through the ethmoidal fissure. 7. Anterior and posterior internal orbital foramen. 8. Nasal spine. 9. The depression for the lacrimal gland. 10. Depression for the pulley of the superior oblique muscle of the eye; immediately to the left of this number is the supraorbital notch, and to its right the internal angular pro-

cess. 11. Opening leading into the frontal sinuses; the leading line crosses the internal angular process. 12. External angular process. The corresponding parts are seen on the other side of the figure.

the seventh year, and increase in size until old age. This bone is entirely developed in membrane.

Articulations.—With *twelve* bones: two parietal, sphenoid, eth-

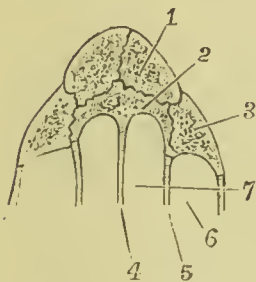


FIG. 99.—Shows articulation of nasal spine of frontal with neighbouring bones. 1. Nasal. 2. Nasal spine of frontal. 3. Nasal process of superior maxillary. 4. Central lamella of ethmoid. 5. Lateral mass of ethmoid. 6. Anterior ethmoidal cell. 7. Superior meatus.

moid, two nasal, two superior maxillary, two lachrymal, and two malar.

Attachment of Muscles.—To *three* pairs: corrugator supercili, to the inner end of the superciliary ridge; temporal to the temporal fossa; and orbicularis palpebrarum, to the internal angular process.

TEMPORAL BONE.

The temporal bone is situated at the side and base of the skull, and contains in its interior the organ of hearing. It is divisible into a squamous, mastoid, and petrous portion.

The **Squamous portion** (*squama*, a scale), forming the anterior part of the bone, is thin, translucent, and contains no diploë. On its *external surface* it is smooth, gives attachment to the fleshy fibres of the temporal muscle, and is marked by a small groove running almost vertically upwards, for the posterior deep temporal artery. It has projecting from it an arched and lengthened process, the *zygoma* (from ζυγός, a yoke, because it joins the temporal and malar bones together), which, as it passes forwards, becomes twisted in itself. Near the commencement of the zygoma, upon its lower border, is a projection called the *tubercle*, to which is attached the external lateral ligament of the lower jaw, and continued horizontally inwards from the tubercle, a rounded eminence, the *eminentia articularis*. The process of bone which is continued from the tubercle of the zygoma into the eminentia articularis is the *inferior root* of the zygoma. The *superior root* is continued upwards from the upper

FIG. 100.—External surface of the

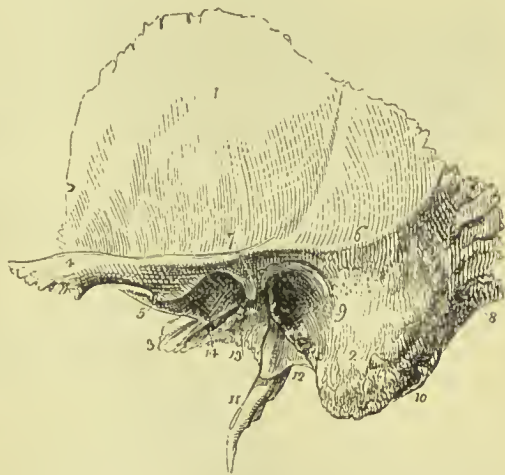

FIG. 100.—External surface of the temporal bone of the left side. 1. Squamous portion. 2. Mastoid portion. 3. Extremity of the petrous portion. 4. The zygoma. 5. Indicates the tubercle of the zygoma, and at the same time its anterior root turning inwards to form the eminentia articularis. 6. Superior root of the zygoma, forming the posterior part of the temporal crest. 7. Middle root of the zygoma, terminating abruptly at the glenoid fossa. 8. Mastoid foramen. 9. External auditory meatus, surrounded by the auditory process. 10. The digastric fossa, situated immediately to the inner side of (2) the mastoid process. 11. Styloid process. 12. Vaginal process. 13. Fissure of Glaser; the leading line from this number crosses the rough posterior portion of the glenoid fossa. 14. The

opening and part of the groove for the Eustachian tube. border of the zygoma, and forms the posterior part of the temporal crest (*supra-mastoid crest*), serving by its projection to mark the division of the squamous from the mastoid portion of the bone; and the *middle root*, called also *post-glenoid process*, passes inwards and backwards, and terminates abruptly at a narrow fissure, the fissure of Glaser. The upper border of the zygoma is thin and sharp, and has attached to it the fibres of the temporal fascia; the lower border is thick, and gives origin to some fibres of the masseter muscle. The *internal surface* of the squamous portion is marked by several shallow fossæ, which correspond with the convolutions of the cerebrum, and by a furrow for the posterior branch of the middle meningeal artery. The *superior* or *squamous border* is very thin, and bevelled at the expense of the inner surface, so as to overlap the lower and arched border of the parietal bone. The *inferior border* is thick, and dentated to articulate with the spinous process of the sphenoid bone.

The **Mastoid portion** (*μαστὸς εἶδος*, nipple-like) forms the posterior part of the bone; it is thick and hollowed between its tables into numerous cavities. Those situated near the apex and back part of the bone are small and generally filled with marrow; the upper and anterior cavities, much larger in size, contain air, and are in communication with the tympanic cavity. One of the latter, larger and more constant than the rest, is named the *mastoid antrum*. On its *external surface* the mastoid portion is rough for the attachment of muscles, and near the posterior border of the bone is an irregular opening, sometimes large, and sometimes so small as to be almost indistinguishable, called the *mastoid foramen*, which transmits a vein to the lateral sinus, and a small artery to the dura mater. The inferior part of the mastoid portion is round and expanded, the *mastoid process*. Directly to the inner side of, and partly concealed by it, is a deep groove, the *digastric fossa*, for the digastric muscle, and a little more internally the *occipital groove*, which lodges the occipital artery, a branch of the external carotid. On its *internal surface* the mastoid portion presents a broad and shallow groove (*fossa sigmoidea*) for the lateral sinus, and terminating in this groove the internal opening of the mastoid foramen. The *superior border* of the mastoid

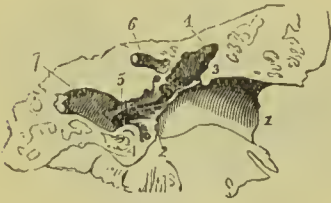

FIG. 101.—Section of the temporal bone, right side, showing the curved direction of the external auditory meatus. 1. Edge of the auditory process. 2. Groove into which the membrana tympani is inserted. The obliquity of the line from 2 to 3 indicates the oblique termination of the meatus, and the consequent oblique direction of the membrana tympani. 4, 4. Cavity of the tympanum. 5. Opening of the Eustachian tube. 6. Part of the aqueductus Fallopii. 7. Part of carotid canal.

portion is dentated, and articulates with the posterior inferior angle of the parietal bone; its posterior border is thick, and less serrated, and articulates with the inferior border of the occipital bone.

The *external auditory meatus* is a slightly curved canal, about half an inch in length, and rather longer on its floor than on its roof; it is narrower in the middle than at either end, and is broadest in its horizontal diameter, and terminates at the outer wall of the tympanum by an abrupt oval border. Within the margin of this border is a groove for the insertion of the membrana tympani.

The **Petrous portion** of the temporal bone is named from its extreme hardness and density (*πέτρος*, a rock). It is a three-sided pyramid, projecting horizontally forwards into the base of the skull, the base being partly applied against the internal surface of the squamous and mastoid portions, and partly exposed as the opening of the ear; its apex is received into the triangular interval between the spinous process of the sphenoid and the basilar process of the occipital bone. For convenience of description it is divisible into base, apex, three surfaces, anterior, posterior, and basilar; and three borders, superior, anterior, and posterior. The *base* is pierced by the external auditory meatus, surrounded by a rough process

of bone, the *auditory process*, which, when traced backwards, is seen to be continuous with the bone ensheathing the styloid process.

The *apex* of the petrous bone is pierced by the inner opening of the carotid canal, and forms the posterior and external boundary of the middle lacerated foramen.

The *anterior surface*, forming the back part of the middle fossa of the base of the skull, presents from base to apex, firstly, a slight depression, which corresponds to the position of the roof of the tympanic cavity; next, an *eminence* caused by the projection of the superior semicircular canal; thirdly, a groove leading to an irregular oblique opening, the *hiatus Fallopii*, for the transmission of the petrosal branch of the Vidian nerve; another and smaller oblique foramen, immediately beneath the preceding, for the passage of the lesser petrosal nerve; and lastly, near the apex of the bone, a depression for the Gasserian ganglion.

The *posterior surface* forms the front of the posterior fossa of the skull; near its middle is the oblique entrance of the *meatus auditorius internus*, which gives passage to the seventh and eighth nerves and the auditory artery. Above the meatus auditorius internus is a small oblique fissure, and a minute foramen; the former lodges a process of the dura mater, and the foramen gives passage to a small vein. Further outwards, towards the mastoid portion of the bone, is a small slit, almost hidden by a thin plate of bone; this is the *aquæductus vestibuli*, and transmits a small artery and vein of the vestibule and a process of dura mater. Below the meatus, and partly concealed by the margin of the posterior border of the bone, is a triangular opening, the termination of the *aquæductus cochleæ*, through which passes a vein from the cochlea to the inferior petrosal sinus, and a process of dura mater.

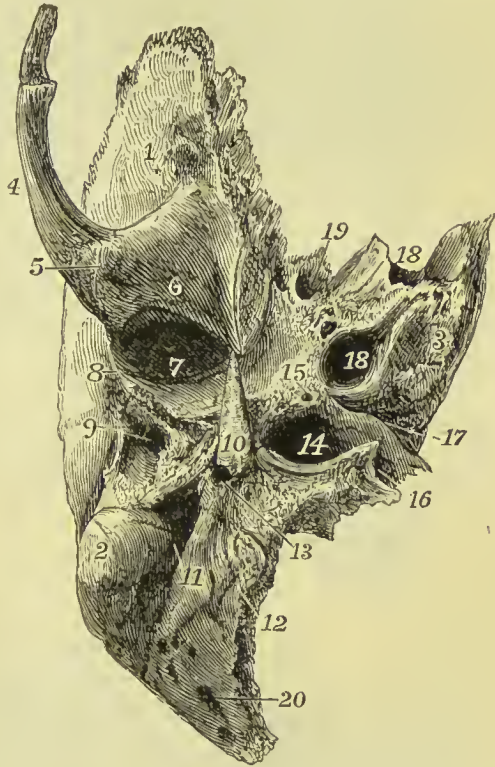

FIG. 102.—Right temporal bone, seen from below. 1. Squamous portion. 2. Mastoid portion. 3. Petrous portion. 4. Zygoma. 5. Tubercle of the zygoma. 6. Articular eminence. 7. Glenoid fossa. 8. Glaserian fissure. 9. External auditory meatus. 10. Styloid process. 11. Digastric fossa. 12. Occipital groove. 13. Stylo-mastoid foramen. 14. Jugular fossa. 15. Foramen for Jacobson's nerve. 16. Jugular notch. 17. Aquæductus cochleæ. 18, 18. Carotid canal. 19. Canals for the tensor tympani muscle and Eustachian tube. 20. Mastoid foramen.

The *basilar surface* of the petrous portion is rough, irregular, and enters into the formation of the under surface of the base of the skull. Projecting downwards, near its middle, is a long sharp spine, the *styloid process*, occasionally connected with the bone only by cartilage, and lost during maceration, particularly in the young subject. At the base of this process is a rough sheath-like ridge, into which the styloid process appears implanted, the *vaginal process* or tympanic lamina; it is continuous externally with the auditory process. In front of the vaginal process is a broad triangular depression, the *glenoid fossa*, bounded in front by the eminentia articularis, behind by the vaginal process, and externally by the rough lip of the auditory process.

The *glenoid fossa* (γλήνη, a socket) is divided transversely by the

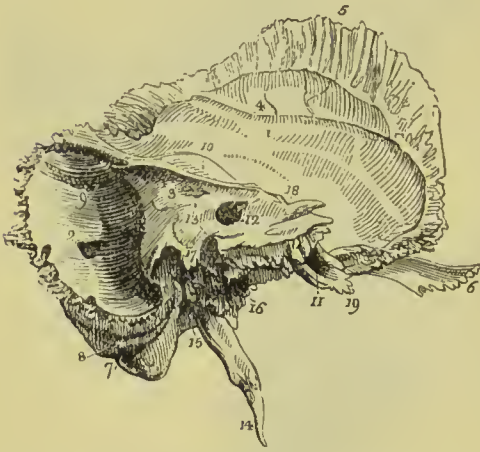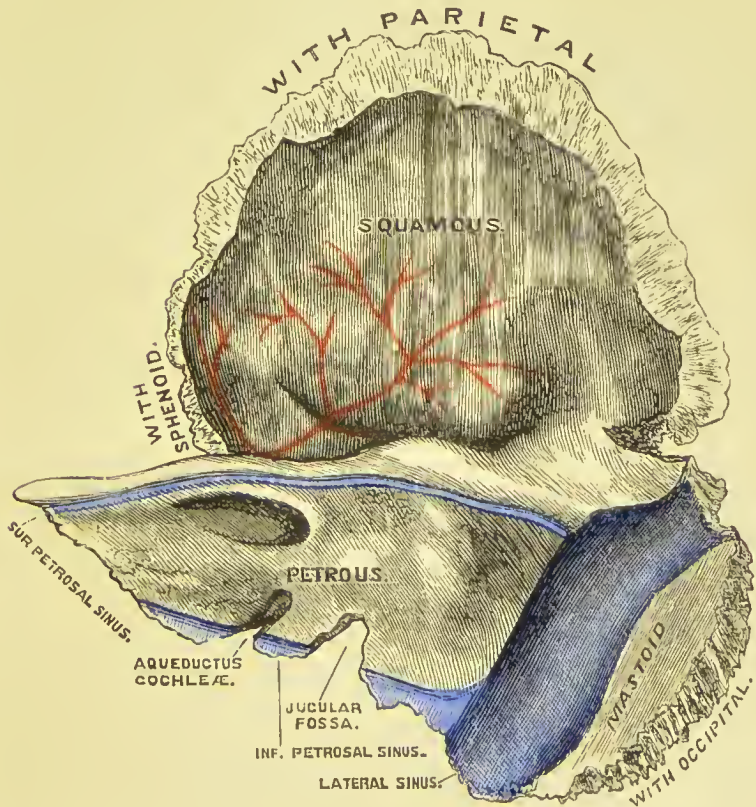
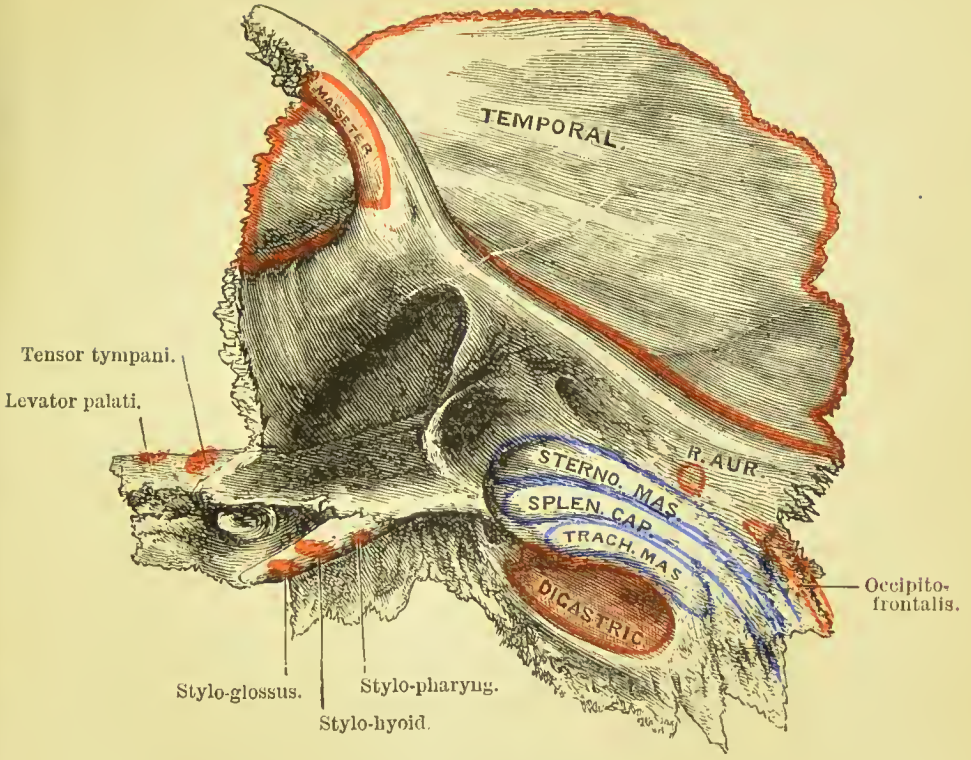


FIG. 103.—Left temporal bone, seen from within. 1. Squamous portion. 2. Mastoid portion. The figure is placed immediately above the inner opening of the mastoid foramen. 3. Petrous portion. 4. Groove for the posterior branch of the middle meningeal artery. 5. Bevelled edge of the squamous border of the bone. 6. Zygoma. 7. Digastric fossa, immediately internal to the mastoid process. 8. Occipital groove. 9. Groove for the lateral sinus. 10. Elevation on the anterior surface of the petrous bone, marking the situation of the perpendicular semi-circular canal. 11. Opening of termination of the carotid canal. 12. Meatus auditorius internus. 13. A dotted line leads upwards from this figure to the narrow fissure which lodges a process of the dura

mater. Another line leads downwards to the sharp edge which conceals the opening of the aquæductus cochleæ, while the cipher itself is situated on the bony lamina which overlies the opening of the aquæductus vestibuli. 14. Styloid process. 15. Stylo-mastoid foramen. 16. Carotid foramen. 17. Jugular process. The deep excavation to the left of this forms part of the jugular fossa; that to the right is the groove for the ninth, tenth, and eleventh pairs of nerves. 18. Notch for the fifth nerve on the upper border of the petrous bone, near its apex. 19. Extremity of the petrous bone, giving origin to the levator palati and tensor tympani muscle.

fissure of Glaser, which is the line of union between the tympanic and squamous portions of the temporal bone; it receives the extremity of the processus gracilis of the malleus, and transmits the laxator tympani muscle, and anterior tympanic artery. At the inner extremity of the fissure a minute canal terminates, *canal of Huyvier*; it transmits the chorda tympani nerve. The surface of the fossa in front of the fissure is smooth, to articulate with the condyle of the lower jaw; and that behind the fissure rough, for the reception of part of the parotid gland. At the extremity of the inner angle of the glenoid fossa is the opening of the *Eustachian tube*; above this, and separated from it by a thin lamella of bone, called *processus cochleariformis*, is a small canal for the transmission of the tensor tympani muscle.

PLATE 3.





Directly behind, and at the root of the styloid process, is the *stylo-mastoid foramen*, the opening of exit of the facial nerve, and entrance of the stylo-mastoid artery; and a little in front of this, between the mastoid and vaginal processes, is a small slit, the *auricular fissure*, for the exit of the auricular branch of the pneumogastric (Arnold's nerve). Midway between the styloid process and apex of the bone is a large oval opening, the foramen of entrance of the internal carotid artery and carotid plexus of nerves into the carotid canal. Between the stylo-mastoid and carotid foramen, in the posterior border, is an irregular excavation forming part of the jugular fossa for the commencement of the internal jugular vein, on the inner wall of which will be found a minute foramen, for the entrance of Arnold's nerve. The share of the jugular fossa formed by the petrous portion of the temporal bone is different in different bones; but in all the fossa presents a vertical ridge on its inner side, which cuts off a small portion from the rest. The upper part of this ridge forms a spinous projection, the *jugular process*; the groove to the inner side of the ridge lodges the ninth, tenth, and eleventh nerves, and the lower part of the ridge is the septum of division between the jugular fossa and carotid foramen. Upon the latter portion of the ridge, near the posterior margin of the carotid foramen, is a small opening leading into a canal which transmits the tympanic branch of the glosso-pharyngeal nerve (Jacobson's nerve).

The *superior border* of the petrous portion is sharp, and gives attachment to the tentorium cerebelli. It is grooved for the superior petrosal sinus, and near its extremity is marked by a smooth notch, upon which reclines the fifth nerve. The *anterior border* is grooved for the Eustachian tube, and forms the posterior boundary of the foramen lacerum basis cranii; by its sharp extremity it gives attachment to the tensor tympani, and levator palati muscle. The *posterior border* is grooved for the inferior petrosal sinus, and excavated for the jugular fossa: it forms the anterior boundary of the jugular foramen.

Development.—The temporal bone is developed in four portions, the *squamo-zygomatic*, *tympanic*, *petro-mastoid* (or *periotic*), and *styloid*. Ossification commences in the squamo-zygomatic portion about the seventh week. In the third month ossific deposits appear in the floor of the outer wall of the tympanum, and extending upwards form a circle, the *tympanic ring*, which is defective above; it joins the squamo-zygomatic portion in the ninth month. In the petro-mastoid portion ossification begins in the fifth month, taking place by four distinct osseous deposits; one for the promontory (*opisthotic*), one for the greater part of the petrous bone seen in the base of the skull (*prootic*), a third in connection with the posterior semicircular canal and lower part of the mastoid (*epiotic*), and a fourth forming the roof of the tympanum and covering of the external semicircular canal (*pteroitic*); these centres all fuse by the end of the sixth month.

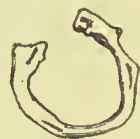

FIG. 104.—The tympanic ring of the fetal skull, right side.

The styloid process is commonly formed by two osseous deposits, one (the *tympano-hyal*) at the base, before birth; the other (*stylo-hyal*) at the tip, after birth; the latter often remains separate during the whole of life. The squamo-zygomatic portion is developed from membrane, the other portions from cartilage. At the time of birth the temporal bone consists of three pieces; the mastoid antrum is present, but the mastoid cells do not commence to be formed till the ninth year. From the above description it will be seen that the total number of centres of ossification is *eight*.

Articulations.—With *five* bones: occipital, parietal, sphenoid, inferior maxillary, and malar.

Attachment of Muscles.—To *fourteen*: by the *squamous portion*, to the temporal; by the *zygoma*, to the masseter; by the *mastoid portion*, to the occipito-frontalis, splenius capitis, sterno-mastoid, trachelo-mastoid, digastricus, and retrahens auriculam; by the *styloid process*, to the stylo-pharyngeus, stylo-hyoid, stylo-glossus, and two ligaments, stylo-hyoid and stylo-maxillary; and by the *petrous portion*, to the levator palati, tensor tympani, and stapedius.

SPHENOID BONE.

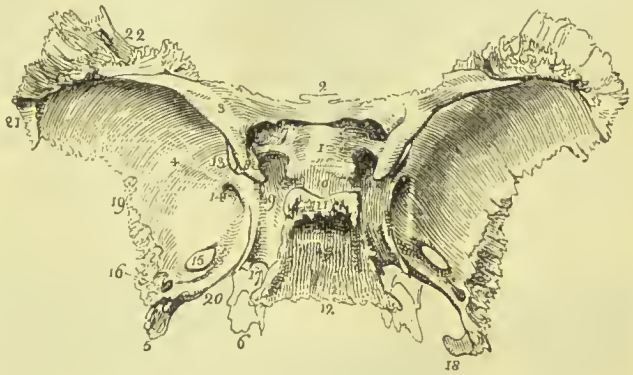
The sphenoid ($\sigma\phi\eta\nu$, a wedge) is an irregular bone, situated at the base of the skull, wedged between the other bones of the cranium, and entering into the formation of the cranium, orbits, and nasal fossæ. It bears some resemblance, in form, to a bat with its wings extended, and is divisible into body, wings, and processes.

The **body** forms the central mass of the bone, from which the wings and processes are projected. From the upper and anterior part of the body extend, one to each side, two small triangular plates, the *lesser wings*; from each side, and expanding laterally, are the *greater wings*; proceeding backwards from the base of the greater wings, the *spinous processes*, and downwards, the *pterygoid processes*. The body presents for examination a superior or cerebral surface, an antero-inferior surface, and a posterior surface.

Superior Surface.—At the anterior extremity of this surface is a small projecting plate, the *ethmoidal spine*, which articulates with the cribriform plate of the ethmoid; and spreading out on each side the *lesser wings*. Behind the ethmoidal spine in the middle line is a shallow transverse groove which lodges the optic commissure; behind this is a rounded elevation, the *olivary process*; and on each side of the posterior margin of that process a tubercle, the *middle clinoid process* ($\kappa\lambda\acute{\iota}\nu\eta$, a bed). Passing outwards and forwards from the groove just mentioned are the *optic foramina*, which transmit the optic nerves and ophthalmic arteries. Behind the optic foramina are two sharp tubercles, the *anterior clinoid processes*, which are the inner terminations of the lesser wings. Beneath these processes, on the sides of the olivary process, are two depressions for the last turn of the internal carotid arteries; they are often converted into foramina

(*carotico-clinoid*) by a spicule of bone uniting the anterior and middle clinoid processes. Behind the olivary process is the *sella turcica*, the deep fossa which lodges the pituitary gland and circular sinus; behind and somewhat overhanging the *sella turcica*, is a broad rough plate, *dorsum sellæ*, bounded at each angle by a tubercle, the *posterior clinoid processes*; and behind this plate an inclined surface (*clivus Blumenbachii*), which is continuous with the basilar process of the occipital bone, and supports the Pons Varolii. On each side of the *sella turcica* is a broad groove (*carotid or cavernous groove*); it is bounded externally at its back part by a well-marked ridge called the *lingula sphenoidalis*. The carotid groove lodges the internal carotid artery, cavernous sinus, orbital nerves, and cavernous plexus of the sympathetic. Opposite the middle of the *sella turcica* the

FIG. 105.—Superior or cerebral surface of the sphenoid bone. 1. Olivary process. 2. Ethmoidal spine. 3. Lesser wing of the left side. 4. Cerebral surface of the greater wing of the same side. 5. Spinous process. 6. Extremity of the pterygoid process, projecting downwards from the under surface of the body of the bone. 7. Optic foramen. 8. Anterior clinoid process. 9. Carotid or cavernous groove. 10. *Sella turcica*; the two tubercles in front of the figure are the middle clinoid processes. 11. *Dorsum sellæ*; its projecting angles are the posterior clinoid processes. 12. Basilar portion of the bone. 13. Part of the sphenoidal fissure. 14. Foramen rotundum. 15. Foramen ovale. 16. Foramen spinosum. 17. The angular interval which receives the apex of the petrous portion of the temporal bone. The posterior extremity of the Vidian canal terminates at this angle. 18. Spine of the spinous process. 19. The border of the greater wing which articulates with the squamous portion of the temporal bone. 20. The internal border of the spinous process, which assists in the formation of the foramen lacerum basis cranii. 21. That portion of the greater wing which articulates with the anterior inferior angle of the parietal bone. 22. The portion of the greater wing which articulates with the orbital process of the frontal bone.



groove is single, but as it passes backwards it divides into two portions, which are separated by a projecting ridge, springing from the lower part of the *dorsum sellæ* (*superior petrosal process*). The upper groove lodges the cavernous sinus and orbital nerves, and the lower the carotid artery and carotid plexus of nerves.

Upon the **antero-inferior surface** of the body of the sphenoid is a long flattened spine or crest, the superior part of which *sphenoidal crest* articulates with the central lamella of the ethmoid, while the inferior part, longer and sharper, the *rostrum*, is inserted into the sheath formed by the upper border of the vomer. On each side of the sphenoidal crest is an irregular opening leading into the sphenoidal cells. The sphenoidal cells, absent in the young subject, are divided by a median septum which is continuous with the crest,

and are partially closed by two thin plates of bone (frequently broken away), the *sphenoidal spongy bones* (bones of Bertin). On each side of the sphenoidal cells are the outlets of the optic foramina, and other openings to be presently described; the lesser and greater wings; and, below, the pterygoid processes. At the under surface of the body are two thin plates of bone (*vaginal processes*), proceeding from the base of the pterygoid process at each side, articulating with the alæ of the vomer. On each of these plates, close to the root of the pterygoid process, is a groove converted into a canal by the palate bone, the *pterygo-palatine canal* for the pterygo-palatine nerve and pharyngeal artery; and traversing the root of the pterygoid process at its union with the body of the bone, is the *pterygoid or Vidian canal*, which gives passage to the Vidian nerve and artery.

The **posterior surface** of the body is flat and rough, and articulates with the basilar process of the occipital bone; after the twenty-fifth year this union is usually completed by bone. The posterior surface is continuous at each side with the spinous process, and in the angle of union is the termination of the Vidian canal.

The **lesser wings** (*orbito-sphenoids*) are thin and triangular, the base being attached to the upper and anterior part of the body of the sphenoid; and the apex, prolonged outwards, terminating in an

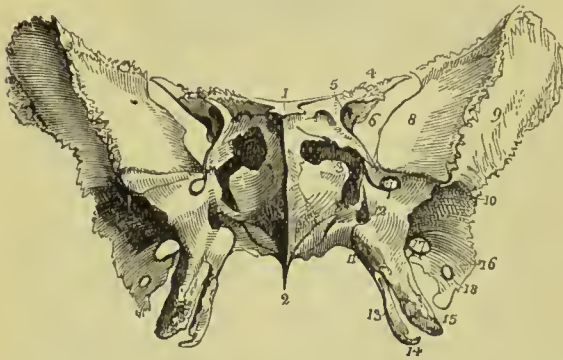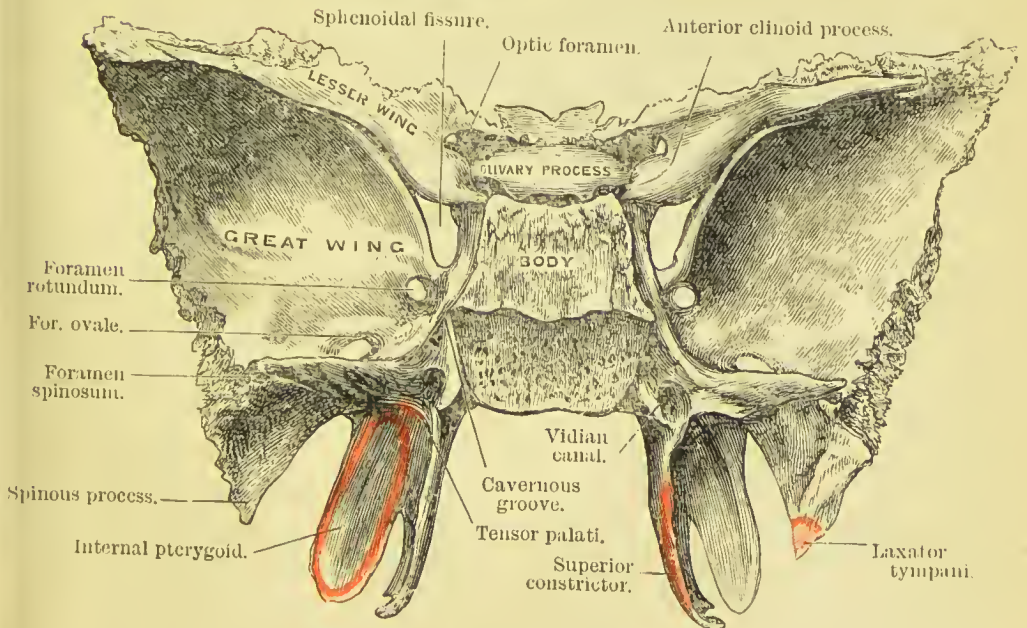
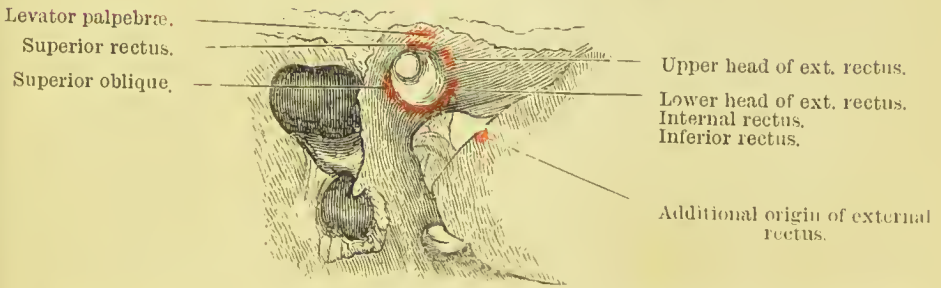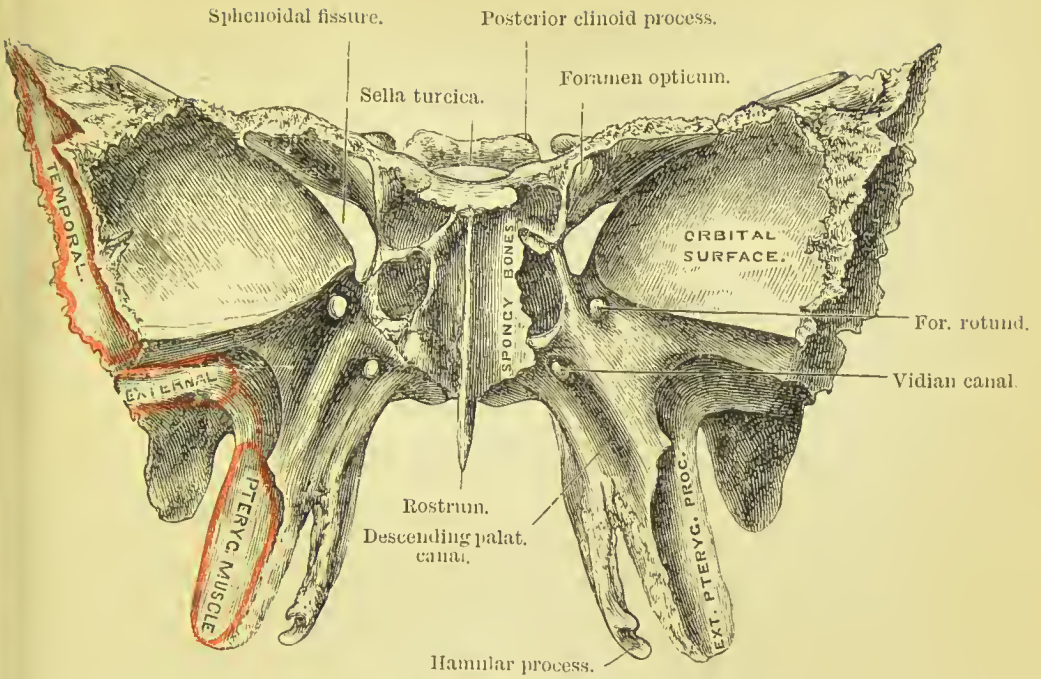


FIG. 106.—Antero-inferior view of the sphenoid bone. 1. Ethmoidal spine. 2. The rostrum. 3. Sphenoidal spongy bone partly closing the left opening of the sphenoidal cells. 4. Lesser wing. 5. Optic foramen, piercing the base of the lesser wing. 6. Sphenoidal fissure. 7. Foramen rotundum. 8. Orbital surface of the greater wing. 9. Its temporal surface. 10. The pterygoid ridge. 11. Pterygo-palatine canal. 12. Foramen of entrance of the Vidian canal. 13. Internal

pterygoid plate. 14. Hamular process. 15. External pterygoid plate. 16. Foramen spinosum. 17. Foramen ovale. 18. Extremity of the spinous process of the sphenoid.

acute point. The anterior border, irregularly serrated, articulates with the orbital plate of the frontal; the posterior, free and rounded, is received into the fissure of Sylvius of the cerebrum. The inner extremity of this border is the anterior clinoid process; it is supported by a short pillar of bone, which forms the inferior boundary of the optic foramen, and gives attachment by its anterior surface to part of the common tendon of the muscles of the orbit. The lesser wing forms the posterior part of the roof of the orbit. Between the lesser and greater wings is a triangular slit, broad internally, but narrowing almost to a point at its outer extremity—this is the *sphenoidal fissure* (*foramen lacerum anterius*); it transmits the third, fourth, three branches of the ophthalmic division of the fifth, the

PLATE 4.





sixth nerves, and some branches from the cavernous plexus of the sympathetic, with the ophthalmic vein.

The **greater wings** (*ala-sphenoids*) present three surfaces; a superior or cerebral, which forms part of the middle fossa of the base of the skull; an anterior surface, which assists in forming the outer wall of the orbit; and an external surface, divided into two parts by the *pterygoid ridge*. The *superior surface* is concave, and receives the anterior part of the temporo-sphenoidal lobe of the cerebrum; at its internal border, where the greater wing joins the body, and immediately behind the sphenoidal fissure, is a circular opening, *foramen rotundum*, through which passes the superior maxillary branch of the fifth nerve. Behind and external to this, is a large foramen called *foramen ovale*; it transmits the inferior maxillary division of the fifth nerve, the small meningeal artery, and lesser petrosal nerve. At the inner side of the foramen ovale a small opening is sometimes found; it is the *foramen Vesalii*, and transmits a small vein. The *anterior or orbital surface* looks into the orbit; it is quadrilateral in shape, and its posterior border, which bounds the sphenoidal fissure inferiorly, is usually marked by a slight prominence, for the attachment of part of the external rectus muscle; its inferior edge forms the outer boundary of the sphenomaxillary fissure; its outer edge is rough for articulation with the malar bone. The superior part of the *external surface* enters into the formation of the temporal fossa, the inferior portion forms part of the zygomatic fossa. The *pterygoid ridge*, dividing the two, gives attachment to the upper origin of the pterygoideus externus muscle.

The **spinous processes** are the posterior terminations of the greater wings; they project backwards, and are received into the angular interval between the squamous and petrous portions of the temporal bones. Near its apex each process is pierced by a small opening, *foramen spinosum*, for the middle meningeal vessels, and extending downwards from the apex is a short spine, which gives attachment to the long internal lateral ligament of the lower jaw, and to the laxator tympani muscle. The external border of the spinous process is rough, to articulate with the lower border of the squamous portion of the temporal bone; the internal border forms the anterior boundary of the foramen lacerum basis cranii, and is somewhat grooved for the reception of the Eustachian tube.

The **pterygoid processes** descend perpendicularly from the base of the greater wings, and form in the articulated skull the lateral boundaries of the posterior nares. Each process consists of an external and internal plate, partly united in front, but divergent behind, so as to enclose a space called the *pterygoid fossa*, and separated below by an interval, the *pterygoid notch*, which receives the tuberosity of the palate bone. The *external plate* is broad and thin, giving attachment, by its external surface, to the external pterygoid muscle, and by its internal surface to the internal pterygoid. The *internal pterygoid plate* is long and narrow, terminating at its extremity by a curved hook, the *hamular process*, around which plays the

tendon of the tensor palati muscle, and to the tip of which the pterygo-maxillary ligament is attached ; while from the lower third of its posterior border some fibres of the superior constrictor muscle of the pharynx have their origin. At the base of the internal pterygoid plate is a small oblong depression, the *scaphoid* or *navicular fossa*, from which arises the circumflexus or tensor palati muscle. The *anterior surface* of the pterygoid process is broad near its base ; it forms the posterior wall of the spheno-maxillary fossa, and supports Meckel's ganglion. At its lower part this surface is slightly grooved, to form part of the descending palatine canal. The base of the pterygoid process is pierced by the Vidian canal.

Development.—Up to the seventh or eighth month of intra-uterine existence, the anterior and posterior parts of the body of the sphenoid are distinct from each other ;—the anterior part, extending from the posterior border of the olivary process to the ethmoidal spine, being called *pre-sphenoid*, and the posterior portion, from the border of the olivary process to the spheno-occipital synchondrosis, the *post-sphenoid*.

The sphenoid is developed by *fourteen* centres of ossification, four for the pre-sphenoid, six for the post-sphenoid, two for the internal pterygoid plates, and two for the sphenoidal spongy bones. The first pre-sphenoidal centres appear at the outer side of the optic foramina, about the eighth or ninth week. These are soon followed by another pair of centres, placed to the inner side of the optic foramina. From these four centres the anterior part of the body of the sphenoid and the lesser wings are developed. About the eighth week ossific nuclei appear in the greater wings (*ali-sphenoids*) between the foramen ovale and rotundum. From this point ossification extends into the whole of the great wing and the external pterygoid plate. In the eighth week also, or a little later, two centres appear in the post-sphenoidal portion of the body (*basi-sphenoids*), placed side by side in the bottom of the sella turcica. These unite about the fourth month, and after their union two new centres spring up at the other side of the carotid groove, and form the lingula (*sphenotics*). The centres for the internal pterygoid processes appear about the fourth month, and they unite with the external pterygoid about the sixth month. The sphenoidal spongy bones do not become ossified till after birth ; they join the rest of the bone at the time of puberty.

At the time of birth the sphenoid consists of three pieces—the body in the centre, and on each side the great wings with the external pterygoid plates. They unite during the first year. The sphenoidal cells first begin to appear at about seven years of age. The sphenoid joins the occipital from the eighteenth to the twenty-fifth year.

Articulations.—With *twelve* bones : that is, with all the bones of the cranium, and five of the face—viz., two malar, two palate, and vomer.

Attachment of Muscles.—To *twelve* pairs : temporal, external

pterygoid, internal pterygoid, superior constrictor, tensor palati, laxator tympani, levator palpebræ, obliquus superior, superior rectus, internal rectus, inferior rectus, and external rectus.

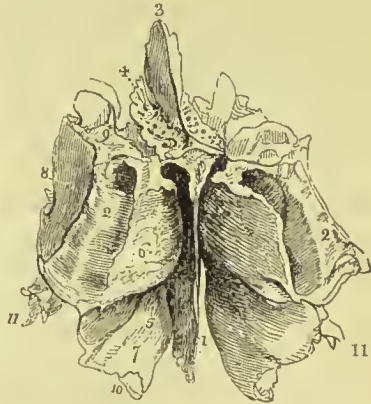
ETHMOID BONE.

The ethmoid ($\eta\theta\mu\delta\varsigma$, a sieve) is a square-shaped cellular bone, situated between the two orbits, at the root of the nose, and perforated on its upper surface by a number of small openings, from which peculiarity it has received its name. It consists of a horizontal plate, a perpendicular lamella, and two lateral masses.

The **horizontal** or **cribriform plate** connects the lateral masses with the perpendicular lamella, and is situated on the upper aspect of the bone. It is hollowed into two shallow grooves (*olfactory grooves*) which support the olfactory bulbs, and is pierced by numerous foramina, for the filaments of the olfactory nerve. In the middle of each groove the foramina pierce the bone completely, but at the sides the openings communicate with minute canals which run in the sides of the central lamella, the lateral masses and turbinated bones. At the anterior extremity of the cribriform plate are two narrow slits, for the nasal branch of the fifth nerve; its posterior border articulates with the ethmoidal spine of the sphenoid.

The **perpendicular lamella** is a thin central plate, which articulates by its anterior border with the frontal spine and crest of the

FIG. 107.—Ethmoid bone seen from above and behind. 1. Perpendicular lamella. 2, 2. Lateral masses; the figures are placed on the posterior border of the lateral mass at each side. 3. Crista galli. 4. Cribriform plate of the left side, pierced by its foramina. 5. The hollowspace immediately above and to the left of this number is the superior meatus. 6. Superior turbinated bone. 7. Middle turbinated bone; the numbers, 5, 6, 7, are situated on the internal surface of the left lateral mass, near its posterior parts. 8. External surface of the lateral mass, or os planum. 9. Superior or frontal border of the lateral mass, grooved by the anterior and posterior internal orbital canals. 10. Refers to the concavity of the middle turbinated bone, which is the upper boundary of the middle meatus. 11. Unciform process.



nasal bones, and by its posterior border with the crest of the sphenoid and upper edge of the vomer. Its inferior border is broad and bilaminar; it articulates with the septal cartilage of the nose. It is surmounted superiorly by a thick and strong process, the *crista galli*, which projects into the cavity of the skull, and gives attachment to the falx cerebri. From the base of the anterior border of this process there project forward two small plates, *alar processes*, which are received into corresponding depressions in the frontal bone, and often complete posteriorly the foramen cæcum. That portion of the perpendicular plate which lies below the level of the cribriform plate assists in forming the septum of the nose.

The **lateral masses** or **labyrinths** are divisible into an internal and external surface, and four borders, superior, inferior, anterior, and posterior.

The *internal surface* is rough, slightly convex, and forms the external boundary of the upper part of the nasal fossæ. Towards the posterior border of this surface is a narrow horizontal fissure, the *superior meatus* of the nose; the upper margin of this fissure is thin, and somewhat curled inwards; hence it is named the *superior turbinated bone*. Below the meatus is the convex surface of another thin plate, which is curled outwards, and forms the lower border of the mass, the *middle turbinated bone*. The *external surface* is quadrilateral and smooth; hence it is named *os planum*; it enters into the formation of the inner wall of the orbit.

The *superior border* is uneven and cellular, the cells being completed by the edges of the ethmoidal fissure of the frontal bone. This border is crossed by two grooves, sometimes complete canals, opening into the orbit by the anterior and posterior internal orbital foramina. The *inferior border* is formed internally by the lower border of the middle turbinated bone, and externally by a concave irregular fossa, the upper boundary of the middle meatus. The *anterior border* presents a number of incomplete cells, which are closed by the superior maxillary and lachrymal bones; the *posterior border* is irregularly cellular, to articulate with the sphenoid and palate bone. From the anterior part of each lateral mass an irregular plate of bone descends backwards, terminating in a hook-like extremity: this is called the *unciform process*. It assists in closing the orifice of the antrum, and articulates with the ethmoidal process of the inferior turbinated bone.

The lateral masses are composed of cells, divided by a thin partition into anterior and posterior ethmoidal cells. The anterior, the most numerous, communicate with the frontal sinuses, and open by means of an irregular and incomplete tubular canal, the *infundibulum*, into the middle meatus. The posterior cells, fewer in number, open into the superior meatus.

Development.—By *three* centres: one for each lateral mass, and one for the perpendicular lamella. Ossification commences in the lateral masses at about the beginning of the fifth month, appearing first in the *os planum*, and then in the turbinated bones. At birth the bone merely consists of two ill-developed lateral masses. During the latter half of the first year after birth, the central lamella and cribriform plate begin to ossify, and are united to the lateral masses by the beginning of the second year. The cells of the ethmoid are developed in the course of the fourth and fifth year.

Articulations.—With *thirteen* bones: two of the cranium, frontal and sphenoid; and eleven of the face, viz., two nasal, two superior maxillary, two lachrymal, two palate, two inferior turbinated, and vomer.

No muscles are attached to this bone.

BONES OF THE FACE.

The face is composed of fourteen bones—namely,

Two nasal,	Two palate,
Two superior maxillary,	Two inferior turbinated,
Two lachrymal,	Vomer,
Two malar,	Inferior maxillary.

NASAL BONES.

The nasal are two small quadrangular bones, forming by their union the bridge and base of the nose. They are convex on their outer surface, and pierced by a foramen for a small vein; on the inner surface they are somewhat concave, and marked by a groove which lodges the nasal branch of the ophthalmic nerve. The superior border is narrow and thick; the inferior broad, thin, and irregular. The anterior border, thick above and thin below, articulates with the bone of the opposite side. The external border is thin and irregular; it is bevelled at the expense of the inner surface above, and of the outer surface below, and articulates with the nasal process of the superior maxillary.

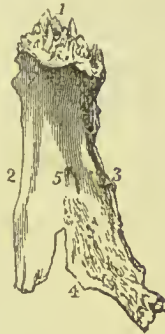

FIG. 108.—Nasal bone of the left side; its external or convex surface. 1. Superior border. 2. Internal or mesial border. 3. External border. 4. Inferior or free border. 5. Foramen for a small vein.

Development.—By a *single* centre for each bone, ossification commencing in the seventh week.

Articulations.—With *four* bones: frontal, ethmoid, nasal, and superior maxillary.

Attachment of Muscles.—It has in relation with it the pyramidalis nasi and compressor nasi; but neither is inserted into it.

SUPERIOR MAXILLARY BONES.

The superior maxillary are the largest bones of the face, with the exception of the lower jaw; they form, by their union, the whole of the upper jaw, and assist in the construction of the nose, orbit, cheek, and palate. Each bone is divisible into a body and four processes.

The **body** is triangular in form, and hollowed in its interior into a large cavity, the *antrum maxillare* (antrum of Highmore). It presents for examination four surfaces, external or facial, internal or nasal, posterior or zygomatic, and superior or orbital.

The **external** or **facial surface** forms the anterior part of the

bone; it presents a deep depression towards its centre, the *canine fossa*, which gives attachment to the *levator anguli oris* muscle. Immediately above this fossa is the *infraorbital foramen*, the termination of the infraorbital canal, transmitting the infraorbital nerve and artery; and above the infraorbital foramen is the lower margin of the orbit, continuous externally with the rough articular surface of the malar process, and internally with a thick ascending plate, the nasal process. Between the infraorbital foramen and the margin of the orbit, the *levator labii superioris proprius* muscle has its origin. Towards the middle line of the face the external surface is bounded by the concave border of the opening of the nose; this border is projected forwards at its inferior termination into a sharp process, forming, with a similar process of the opposite bone, the *nasal spine*. Beneath the nasal spine, and above the two superior incisor teeth, is a slight depression, the *incisive* or *myrtiform fossa*, which gives origin to the *depressor labii superioris atque nasi* muscle. Above and a

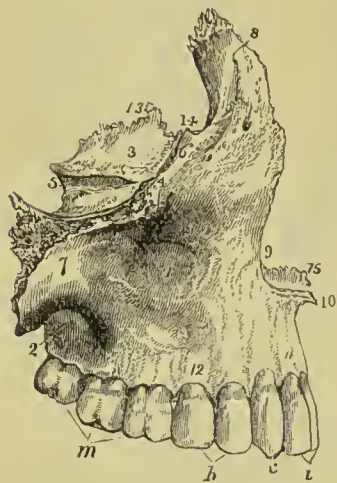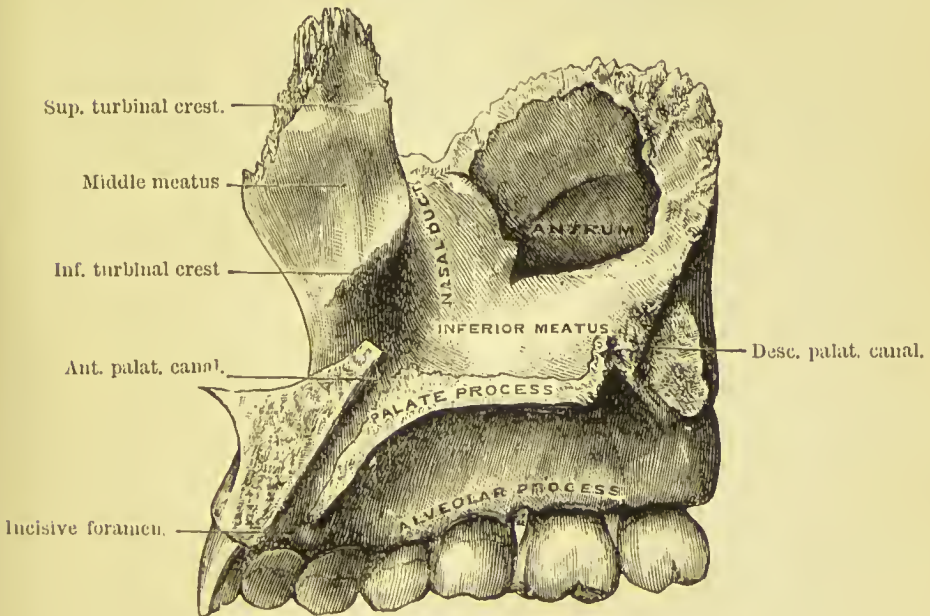
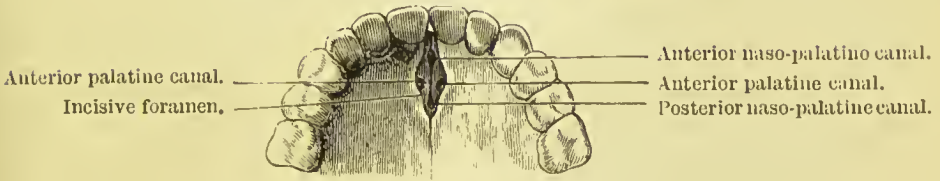
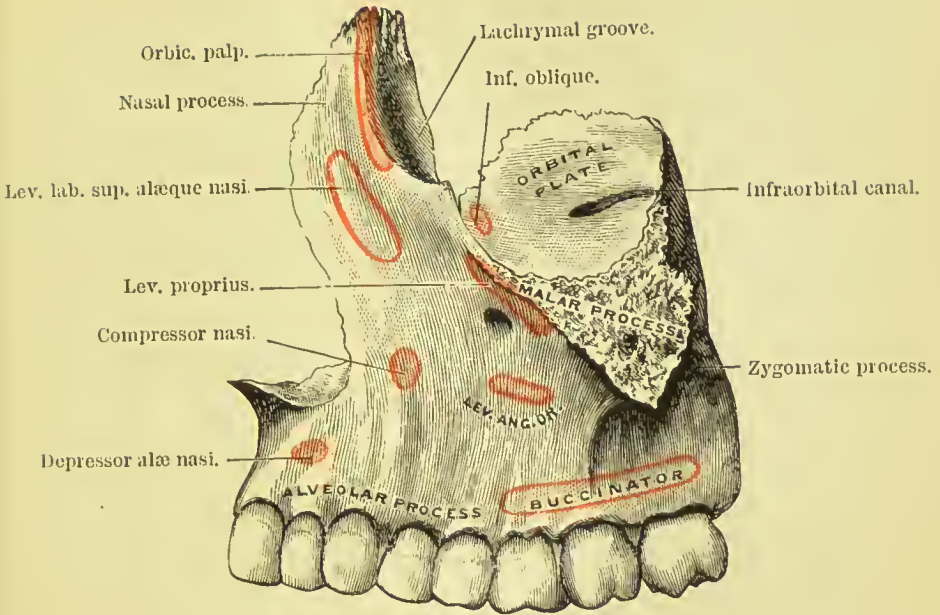



FIG. 109.—Superior maxillary bone of the right side, as seen on its lateral aspect. 1. External or facial surface; the depression in which the cipher is placed is the canine fossa. 2. Posterior, or zygomatic surface. 3. Superior or orbital surface. 4. Infraorbital foramen, situated immediately below the cipher. 5. Infraorbital canal, leading to the infraorbital foramen. 6. Inferior border of the orbit. 7. Malar process. 8. Nasal process. 9. Lateral boundary of the anterior nares. 10. Nasal spine. 11. Incisive or myrtiform fossa. 12. Alveolar process. 13. The internal border of the orbital surface, which articulates with the ethmoid and palate bone. 14. Concavity which articulates with the lachrymal bone, and forms the commencement of the nasal duct. 15. Nasal crest of the palate process. *i*. Two incisor teeth. *c*. Canine. *b*. Two bicuspid teeth. *m*. Three molars.

little to the outer side of the fossa the compressor nasi has its origin. The myrtiform fossa is divided from the canine fossa by a perpendicular ridge (*canine ridge*) corresponding with the root of the canine tooth. The inferior boundary of the facial surface is the alveolar process which contains the teeth of the upper jaw; and the facial is separated from the zygomatic surface by a strong projecting eminence, the *malar process*.

The **internal** or **nasal surface** presents a large irregular opening, leading into the antrum; this opening is nearly closed in the articulated skull by the ethmoid, palate, lachrymal, and inferior turbinated bone. In front of the opening of the antrum is the strong ascending plate of the nasal process, marked inferiorly by a rough horizontal ridge, *inferior turbinal crest*, which gives attachment to the inferior turbinated bone. The concave depression immediately above this ridge corresponds with the middle meatus of the nose, that below the ridge with the inferior meatus. Between the nasal process and the opening of the antrum is a deep vertical groove,

PLATE 5.

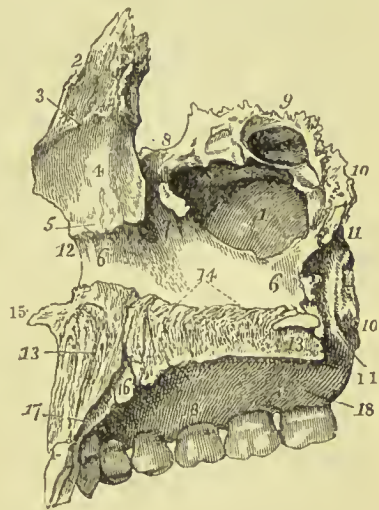




converted into a canal by the lachrymal and inferior turbinated bone, and constituting the *nasal duct*. The *superior border* of the nasal surface is irregularly cellular, and articulates with the lachrymal and ethmoid bones; the *posterior border* is rough, and articulates with the palate bone; it is marked by a narrow groove, nearly vertical in direction, which forms part of the *descending palatine canal*; the *anterior border* is sharp, and forms the free margin of the opening of the nose, and, from the *inferior border*, projects inwards a strong horizontal plate, the *palate process*.

The **Antrum of Highmore** or *maxillary sinus* is an irregular four-sided cavity with thin walls; the outer wall being formed by the facial portion of the bone, the posterior by the zygomatic process, the roof by the orbital process, and the inner wall by the nasal surface of the bone, the unciform process of the ethmoid, the palate, lachrymal and inferior turbinated. Its floor is rendered

FIG. 110.—Right superior maxillary bone; internal surface. 1. Antrum. 2. Nasal process. 3. Superior turbinal crest. 4. Depression corresponding with the middle meatus. 5. Inferior turbinal crest. 6, 6. Inferior meatus. 7. Nasal duct. 8. Notch for articulation with the lachrymal bone. 9. Superior border of the bone, in which are seen three ethmoidal cells. 10, 10. Posterior border; the lower 10 marks the articulating surface for the palate bone. 11, 11. Groove of the descending palatine canal. 12. Anterior border of the bone. 13, 13. Palate process. 14. Nasal crest. 15. Nasal spine. 16. Anterior palatine canal. 17. Situation of the incisive foramen. 18, 18. Alveolar process.



irregular by the pushing upwards of the bone by the fangs of the molar teeth. In the articulated skull the opening of the antrum is in the middle meatus of the nose, and is close to the roof of the cavity.

The **posterior** or **zygomatic surface** is bounded externally by the malar process, and internally by a rough and rounded border, the *tuberosity*, which is pierced by a number of small foramina, giving passage to the posterior dental nerves and branches of the superior dental artery. The *superior border* is smooth and rounded, forming the lower boundary of the spheno-maxillary fissure, and marked by a notch, the commencement of the infraorbital canal. The *inferior* boundary is the alveolar process, containing the last two molar teeth.

The **orbital surface** is triangular and thin, and forms the floor of the orbit. It is bounded internally by an irregular edge, which articulates with the palate, ethmoid, and lachrymal bone; posteriorly, by the smooth border which enters into the formation of the spheno-

maxillary fissure ; and, anteriorly, by a convex margin, partly smooth and partly rough, the smooth portion forming part of the lower border of the orbit, the rough portion articulating with the malar bone. The middle of this surface is channelled by a deep groove and canal, the infraorbital, which terminates at the infraorbital foramen ; and near the root of the nasal process is a slight depression, marking the origin of the inferior oblique muscle of the eyeball.

The *four processes* of the superior maxillary bone are, the nasal, malar, alveolar, and palate.

The **nasal process** ascends by the side of the nose, to which it forms the lateral boundary, and articulates with the frontal and nasal bones. By its *external surface* it gives attachment to the *levator labii superioris alaeque nasi*, and to the *orbicularis palpebrarum* muscle. Its *internal surface* contributes to form the outer wall of the nares, and is marked transversely by a horizontal ridge, *superior turbinal crest*, which divides it into two portions, one above the ridge irregular and uneven, for giving attachment to and completing the cells of the lateral mass of the ethmoid ; the other below, smooth and concave, corresponding with the middle meatus. The *posterior border* is thick, and grooved for the nasal duct ; while the prominent margin in front of that groove is continuous with the lower border of the orbit ; this margin is marked by a small *tubercle (lachrymal tubercle)*, which serves as a guide to the introduction of the knife in opening into the lachrymal sac.

The **malar process**, large and irregular, is situated at the angle of separation between the facial and zygomatic surface, and presents a triangular surface for articulation with the malar bone.

The **alveolar process** forms the lower margin of the bone ; it is spongy and cellular in texture, and excavated into deep holes for the reception of eight teeth. By its outer surface, as far forwards as the first molar tooth, it gives origin to the *buccinator* muscle. The anterior portion containing the sockets of the incisor teeth, together with a small portion of the palate process, has a separate centre of ossification, and in the lower animals remains separate throughout life as the *intermaxillary* or *premaxillary* bone. In young human skulls, a fissure running backwards from the outer edge of the second incisor nearly to the incisive foramen, indicates the line of junction of the premaxillary bone with the rest of the maxilla ; and in cases of cleft palate (there being an arrest of development) this portion is present as a distinct bone.

The **palate process** is thick and strong, and projects horizontally inwards from the inner surface of the body of the bone. *Superiorly*, it is concave and smooth, and forms the floor of the nares ; *inferiorly*, it is also concave, but uneven, and assists in the formation of the roof of the palate. The latter surface is marked by a deep groove, which lodges the anterior palatine nerve and artery. Its internal edge is raised into a ridge (*nasal or palate crest*), which, with a corresponding ridge in the opposite bone, forms a groove for the reception of the

vomer. The prolongation of this ridge forwards beyond the level of the facial surface of the bone is the *nasal spine*. Near the anterior extremity of the internal border is seen a deep groove, which, expanding inferiorly, forms with its fellow of the opposite side the *incisive foramen*. When the hard palate (completed by the junction of the two bones) is viewed from below, this foramen is seen to contain four smaller foramina, two of which are placed in the middle line, one before the other (foramina of Scarpa), the anterior transmitting the left naso-palatine nerve and the posterior the right; the other two (foramina of Stenson), being placed laterally, form the entrance to the anterior palatine canals and give passage to the anterior palatine arteries. These all open above into the inferior meatus of the nose.

Development.—By *four* centres: one for the anterior part of the palate and incisive portion of the alveolar process (intermaxillary); one for that portion of the bone lying internally to the infraorbital canal and foramen; one for that portion lying externally to the infraorbital groove and canal; and one for the palate process. The antrum first begins to be formed about the fourth month of foetal life. The superior maxillary bone is one of the earliest to show signs of ossification, this action beginning in the alveolar process, and being associated with the early development of teeth.

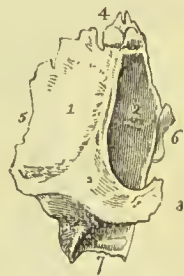
Articulations.—With *nine* bones; viz., two of the cranium, and all the bones of the face, excepting the inferior maxillary. These are, frontal and ethmoid; nasal, lachrymal, malar, inferior turbinated, palate, vomer, and its fellow of the opposite side.

Attachment of Muscles.—To *twelve*: orbicularis palpebrarum, obliquus inferior oculi, levator labii superioris alæque nasi, levator labii superioris proprius, levator anguli oris, compressor nasi, dilatator naris, depressor alæ nasi, buccinator, masseter, orbicularis oris and internal pterygoid.

LACHRYMAL BONES.

The lachrymal (called *os unguis* from an imagined resemblance to a finger-nail) is a thin oval-shaped plate of bone, situated in front

FIG. 111.—Lachrymal bone of the right side viewed on its external or orbital surface. 1. Orbital portion of the bone. 2. Lachrymal portion; the prominent ridge between these two portions is the crest. 3. Lower termination of the crest, the hamulus lachrymalis. 4. Superior border, which articulates with the frontal bone. 5. Posterior border, which articulates with the ethmoid bone. 6. Anterior border, which articulates with the superior maxillary bone. 7. The border which articulates with the inferior turbinated bone.



and at the inner angle of the orbit. It may be divided into an external and internal surface and four borders. The *external surface* is smooth, and marked by a vertical ridge, the *lachrymal crest*, into

two portions, one of which is flat and enters into the formation of the orbit, hence may be called the orbital portion; the other is concave, and lodges the lachrymal sac, hence the lachrymal portion. The crest is expanded inferiorly into a hook-shaped process (hamulus lachrymalis), which forms part of the outer boundary of the lachrymal groove. The *internal surface* is uneven, and completes the anterior ethmoidal cells; it assists also in forming the wall of the nasal fossæ. The *upper border* articulates with the frontal bone, the *anterior border* with the nasal process of the superior maxillary, and the *posterior border* with the os planum of the ethmoid. The *lower border* is divided into two portions by the vertical crest; the posterior part articulates with the orbital plate of the superior maxillary; the anterior part is prolonged downwards (*descending process*) and joins the lachrymal process of the inferior turbinated.

Development.—By a single centre, appearing in the early part of the third month.

Articulations.—With *four* bones; two of the cranium, frontal and ethmoid; and two of the face, superior maxillary and inferior turbinated bone.

Attachment of Muscles.—To *one* muscle, the tensor tarsi, and to an expansion of the tendo oculi.

MALAR BONES.

The malar (*os jugale*) is the strong quadrangular bone which forms the prominence of the cheek. It is divisible into an external

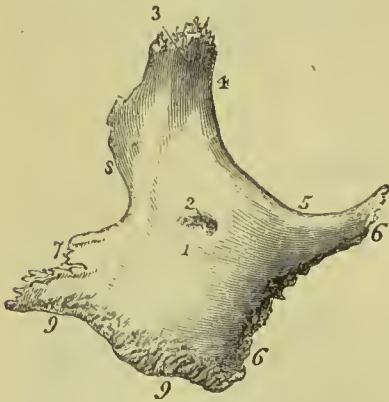


FIG. 112.—Malar bone of the right side. 1. External surface. 2. Opening for an artery and nerve. 3. Frontal process. 4. Outer border of the orbit. 5. Inferior border of the orbit. 6, 6. Maxillary process. 7. Zygomatic process. 8. Postero-superior border, to which the temporal fascia is attached. 9, 9. Postero-inferior border, from which the masseter muscle arises.

and internal surface, and four processes, frontal, orbital, maxillary, and zygomatic. The *external surface* is smooth and convex (*malar tuberosity*); it gives origin to the zygomaticus major and minor muscles, and is pierced by several small openings, which give passage to filaments of the temporo-malar nerve and minute arteries. The *internal surface* is concave, partly smooth and partly rough; smooth where it forms part of the temporal fossa, and rough where it articulates with the superior maxillary bone. In well-marked bones a

foramen is found opening from the orbital surface into the temporal fossa ; it transmits the temporal branch of the orbital nerve and the orbital branch of the temporal artery.

The *frontal process* ascends perpendicularly to form the outer border of the orbit, and articulates with the external angular process of the frontal bone. The *orbital process* is a thick plate, which projects inwards from the frontal process, and unites with the great wing of the sphenoid to constitute the outer wall of the orbit. The *maxillary process* is broad, and articulates with the superior maxillary bone. The *zygomatic process*, narrower than the rest, projects backwards to unite with the zygoma of the temporal bone. The *postero-inferior border* of the bone is strong and rough, and gives attachment by its internal aspect to the masseter muscle ; the *postero-superior border* is thin and sharp, for the attachment of the temporal fascia.

Development.—By a single centre : in rare instances by two or three. In many animals the malar bone is permanently divided into two portions, orbital and malar. Ossification commences in the malar bone soon after the vertebræ.

Articulations.—With *four* bones : three of the cranium, frontal, temporal, and sphenoid ; and one of the face, superior maxillary.

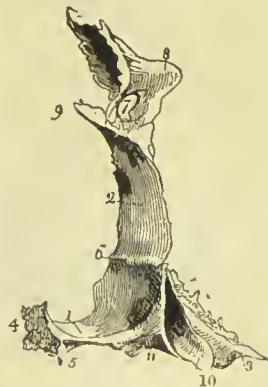Attachment of Muscles.—To *five* : levator labii superioris propius, zygomaticus minor and major, masseter, and temporal.

PALATE BONES.

The palate bones are situated at the posterior part of the nares, where they enter into the formation of the palate, side of the nose, and posterior part of the floor of the orbit. Each bone resembles in general form the letter L, and is divisible into a horizontal plate, a perpendicular plate, and a pterygoid process or tuberosity.

The **horizontal plate** is quadrilateral ; and presents two surfaces,

FIG. 113.—Posterior view of the right palate bone in its natural position ; it is slightly turned on one side, to obtain a sight of the internal surface of the perpendicular plate (2). 1. Horizontal plate of the bone ; its upper or nasal surface. 2. Perpendicular plate ; its internal or nasal surface. 3, 10, 11. Pterygoid process or tuberosity. 4. Internal border of the horizontal plate, which, articulating with the similar border of the opposite bone, forms the nasal crest for the reception of the vomer. 5. The pointed process, which, with a similar process of the opposite bone, forms the palate spine. 6. Inferior turbinal crest. 7. Spheno-palatine notch. 8. Orbital portion. 9. Superior turbinal crest. 10. The smooth surface of the tuberosity, which enters into the formation of the pterygoid fossa. The facets 11 and 3 articulate with the two pterygoid plates, 11 with the internal, 3 with the external.



one superior, which enters into the formation of the floor of the nares, the other inferior, forming the posterior part of the hard palate. The *superior surface* is concave, and rises towards its inner

edge, where it unites with its fellow of the opposite side and forms part of a crest (*nasal or palate crest*), which articulates with the vomer. The *inferior surface* is uneven, and marked by a slight transverse ridge, to which is attached the tendinous expansion of the tensor palati muscle. Near its external border are two openings, one large and one small, the *posterior palatine foramina*; they are the terminations of two minute canals, and transmit the descending palatine artery and nerves. The posterior border is concave, and presents at its inner extremity a sharp point, which, with a corresponding point in the opposite bone, constitutes the *palate spine* for the attachment of the azygos uvulæ muscle.

The **perpendicular plate** is also quadrilateral; and presents two surfaces, one internal or nasal, forming part of the wall of the nares; the other external, bounding the sphenomaxillary fossa and antrum. The *internal surface* is marked near its middle by a horizontal ridge (*inferior turbinal crest*), to which is united the inferior turbinate bone; and about half an inch above this, by another ridge (*superior turbinal crest*), for the attachment of the middle turbinate bone.

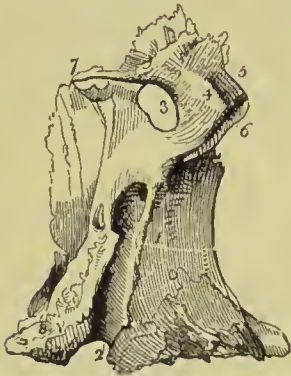

FIG. 114.—Perpendicular plate of the right palate bone, seen on its external or sphenomaxillary surface. 1. The rough surface of this plate, which articulates with the superior maxillary bone and bounds the antrum. 2. Posterior palatine canal; completed by the tuberosity of the superior maxillary bone and pterygoid process of sphenoid. The rough surface to the left of the canal (2) articulates with the internal pterygoid plate. 3. Spheno-palatine notch. 4, 5, 6. Orbital portion of the perpendicular plate. 4. Spheno-maxillary surface of this portion. 5. Orbital surface. 6. Maxillary surface, to articulate with the superior maxillary bone. 7. Sphenoidal portion of the perpendicular plate. 8. Pterygoid process or tuberosity of the bone.

The concave surface below the inferior ridge is the lateral boundary of the inferior meatus of the nose; that between the two ridges corresponds with the middle meatus, and the surface above the superior ridge with the superior meatus. The *external surface* is rough on each side for articulation with neighbouring bones, and smooth in the middle to constitute the inner boundary of the sphenomaxillary fossa. This smooth surface terminates inferiorly in a deep groove, which, being completed by the tuberosity of the superior maxillary bone and pterygoid process of the sphenoid, forms the *descending palatine canal*.

Near the upper part of the perpendicular plate is a large oval notch completed by the sphenoid, the *spheno-palatine foramen*, which transmits the superior nasal and naso-palatine nerves and spheno-palatine artery, and serves to divide the upper extremity of the bone into two portions, an anterior or orbital, and a posterior or sphenoidal portion. The **orbital portion** is hollow within, and presents five surfaces externally, three articular and two free; the three articular are, anterior, which looks forward and articulates with the

superior maxillary bone, internal with the ethmoid, and posterior with the sphenoid. The free surfaces are, superior or orbital, which forms the posterior part of the floor of the orbit; and external, which looks into the speno-maxillary fossa. The internal aspect generally shows a hollow cavity which forms part of the posterior ethmoidal cell. The **sphenoidal portion**, much smaller than the orbital, has three surfaces, two lateral and one superior. The external lateral surface enters into the formation of the speno-maxillary fossa; the internal lateral forms part of the lateral boundary of the nares; the superior surface articulates with the under part of the body of the sphenoid bone, and assists the sphenoidal spongy bones in closing the sphenoidal sinuses. This portion takes part in the formation of the pterygo-palatine canal.

The **pterygoid process** or **tuberosity** of the palate bone is the thick and rough process which stands backwards from the angle of union of the horizontal with the perpendicular portion of the bone. It is received into the angular fissure, which exists between the two plates of the pterygoid process at their inferior extremity, and presents three surfaces: one concave and smooth, which forms part of the pterygoid fossa, and gives origin to some fibres of the internal pterygoid muscle; and one at each side to articulate with the pterygoid plates. The anterior face of this process is rough, and articulates with the superior maxillary bone.

Development.—By a single centre, which appears in the angle of union between the horizontal and perpendicular portion, in the seventh or eighth week.

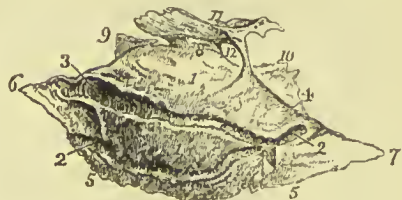
Articulations.—With *six* bones: two of the cranium, sphenoid and ethmoid; and four of the face, superior maxillary, inferior turbinated, vomer, and the palate bone of the opposite side.

Attachment of Muscles.—To *four*: tensor palati, azygos uvulæ, internal and external pterygoid.

INFERIOR TURBINATED BONES.

The inferior turbinated or spongy bone, is a thin layer of light and porous bone, attached to the inferior turbinal crest of the inner

FIG. 115.—Inferior turbinated bone of the right side. 1, 1. Its internal or convex surface. 2, 2, 3. Canal for a branch of the sphenopalatine artery. The figure 3 also denotes the anterior border of the bone. 4. Posterior border. 5, 5. Inferior border. 6. Anterior angle. 7. Posterior angle. 8. Superior angle. 9. Lachrymal process. 10. Ethmoidal process. 11. A large irregular process, appertaining to the ethmoidal process, and articulating with the ethmoid bone. 12. An opening into the antrum.



wall of the nares, and projecting inwards towards the septum. It is somewhat triangular in form, one angle being directed upwards and the curved base downwards; and slightly curled upon itself, so

as to bear some resemblance to one valve of a bivalve shell ; hence its designation, *concha inferior*. The *internal* or *convex surface* looks inwards and upwards, and forms the inferior boundary of the middle meatus of the nose ; it is marked by one or two longitudinal grooves or canals for branches of the nasal nerves and sphenopalatine artery. The *external* or *concave surface* looks downwards and outwards, and constitutes the roof of the inferior meatus. The *anterior border* looks upwards and forwards, is thin and somewhat concave, and articulates with the inferior turbinal crest of the superior maxillary and with the lachrymal bone. The *inferior border* is convex, rounded, and free, and thicker than the rest of the bone. The *anterior angle*, attached to the superior maxillary bone, advances forward nearly to the anterior margin of the nares. The *posterior angle*, sharp and pointed, is prolonged backwards on the internal pterygoid plate. The *superior angle* gives origin to three thin and laminated processes. The most anterior of these, *lachrymal process*, derived from the upper part of the anterior border, articulates with the lachrymal bone ; it is grooved on the external aspect and assists in completing the nasal duct. The posterior process, *ethmoidal process*, derived directly from the superior angle, articulates with the unciform process of the ethmoid bone ; the middle process, *maxillary process*, proceeding also from the superior border, is reflected downwards, and assists in completing the inner wall of the antrum, articulating with the superior maxillary and palate bones.

Recognition.—If the bone be held with its convex lower edge directed downwards, and the end nearest to the groove for the nasal duct looking forwards, the maxillary process will point to the side to which the bone belongs.

Development.—By a single centre, which appears at about the fifth month of fetal life.

It affords no attachment to muscles.

Articulations.—With *four* bones : ethmoid, superior maxillary, lachrymal, and palate.

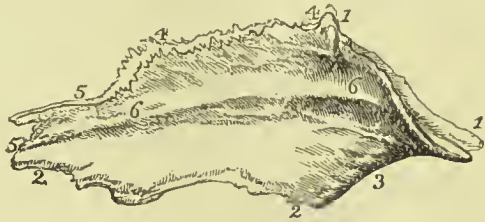VOMER.

The vomer (*vomer*, a ploughshare) is a thin, quadrilateral plate of bone, forming the posterior and inferior part of the septum of the nares.

The *superior border* is broad and expanded, to articulate, in the middle, with the under surface of the body of the sphenoid ; it has projecting on each side a horizontal process or *ala*, by means of which it articulates with the vaginal processes of the sphenoid. The anterior part of this border is hollowed into a sheath for the reception of the rostrum of the sphenoid. The *inferior border* is thin and uneven, and is received into the grooved summit of the palate crest of the superior maxillary and palate bones. The *posterior border* is sharp and free, and forms the posterior division of

the two nares. The *anterior border* is more or less deeply grooved for the reception of the central lamella of the ethmoid and the cartilage of the septum. The lateral surfaces are smooth and marked by small furrows for vessels; each has a groove which runs downwards and forwards, giving passage to the naso-palatine nerve, and terminates inferiorly at the upper opening of the canal of Scarpa. The

FIG. 116.—The vomer viewed on its left aspect. 1, 1. Its superior border, with the two alæ. 2, 2. Inferior border. 3. Posterior border. 4, 4. That portion of the anterior border which articulates with the central lamella of the ethmoid. 5, 5. Inferior portion of the anterior border, which unites with the cartilage of the septum. 6, 6. An elevation on the bone marking its point of separation into two layers; the two layers are seen along the whole length of the anterior border from 4 to the lower 5.



vomer not unfrequently presents a convexity to one or the other side; generally, it is said, to the left.

Development.—By a single centre, which makes its appearance at the same time with those of the vertebræ. Ossification begins from below and proceeds upwards. At birth, the vomer presents the form of a trough, in the concavity of which the cartilage of the septum nasi is placed; it is this disposition which subsequently enables the bone to embrace the rostrum of the sphenoid.

The vomer has no muscles attached to it.

Articulations.—With *six* bones: sphenoid, ethmoid, two superior maxillary, two palate; and with the cartilage of the septum.

INFERIOR MAXILLARY BONE.

The lower jaw or mandible is the arch of bone which contains the inferior teeth; it is divisible into a horizontal portion or body, and a perpendicular portion, the ramus, at each side.

The **body** is divisible into two portions. That above the mental foramen (*alveolar*) is of spongy texture, and contains the sockets for the teeth—that below this foramen (*basilar*) is thick and rounded; it is dense in structure, and is marked by ridges for the attachment of muscles. The relative proportion of these two parts varies with the age of the individual: in childhood, in consequence of containing the two sets of teeth, the alveolar portion is large, and the mental foramen is near the lower border of the bone; in old age, on the contrary, from the loss of teeth and consequent absorption of the alveolar process, the basilar portion alone remains, and the mental foramen is situated near its upper border. In adult age the alveolar and basilar portions are of equal depth, the mental foramen being situated midway between the upper and lower border.

Upon the **external surface** of the *body*, at the middle line, and

extending from between the two first incisor teeth to the chin, is a slight ridge, *crista mentalis*, which indicates the point of conjunction of the lateral halves of the bone in the young subject, the *symphysis*. The ridge expands below into a triangular eminence, the *mental protuberance* (or *mentum*), and this at the lower edge of the bone is marked by a slight depression, the *mental dimple*. Immediately external to this ridge is a depression which gives origin to the depressor labii inferioris muscle; and, corresponding with the root of the lateral incisor tooth, another depression, the *incisive fossa*, for the levator labii inferioris. A few fibres of the orbicularis oris (accessory fibres) are attached to the base of the alveolar process, immediately above the incisive fossa. Farther outwards is an oblique opening, the *mental foramen*, for the exit of the mental nerve and inferior dental artery; and below this foramen, the commencement of a ridge, the *external oblique ridge*, which gives attachment to the depressor anguli oris. Near the posterior part of this surface is a rough impression made by the masseter muscle; and, immediately in front of this impression, a groove for the facial artery. The external surface of the lower border of the bone gives attachment to some fibres of the platysma myoides muscle. The buccinator muscle arises from the base of the alveolar process as far forwards as the first molar tooth. The projecting tuberosity at the posterior extremity of the lower jaw, at the point where the body and ramus meet, is the *angle*.

Upon the **internal surface** of the *body* of the bone, at the *symphysis*, are two small pointed tubercles (*mental tubercles*); imme-

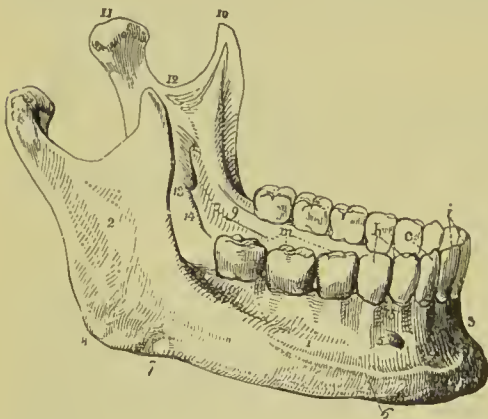
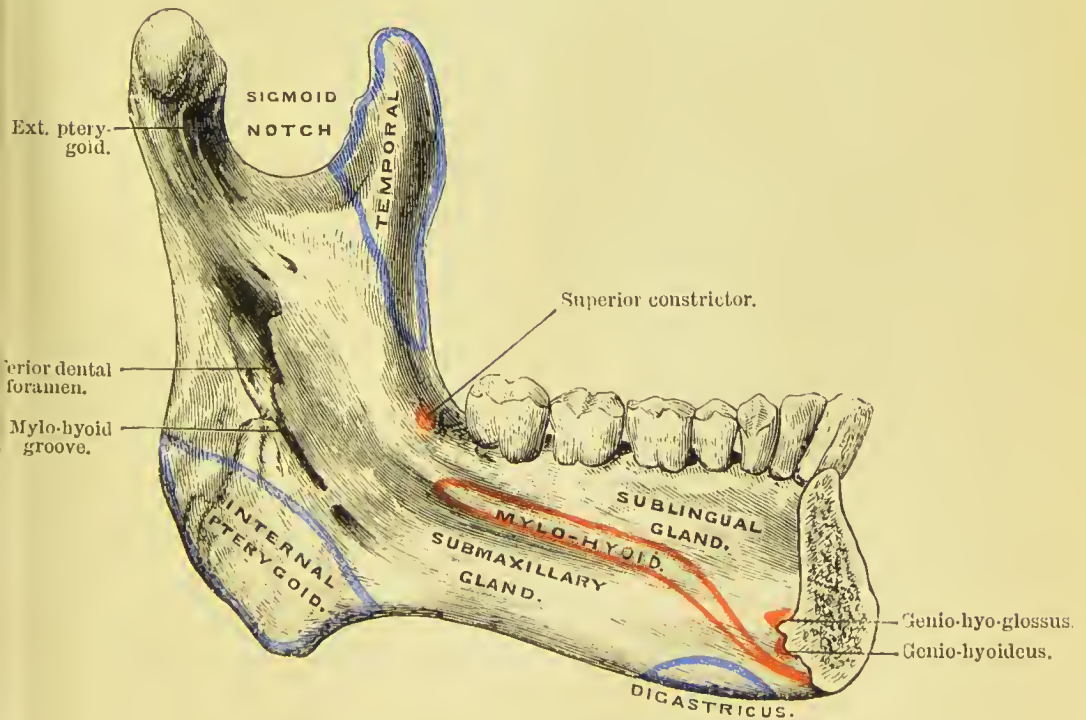
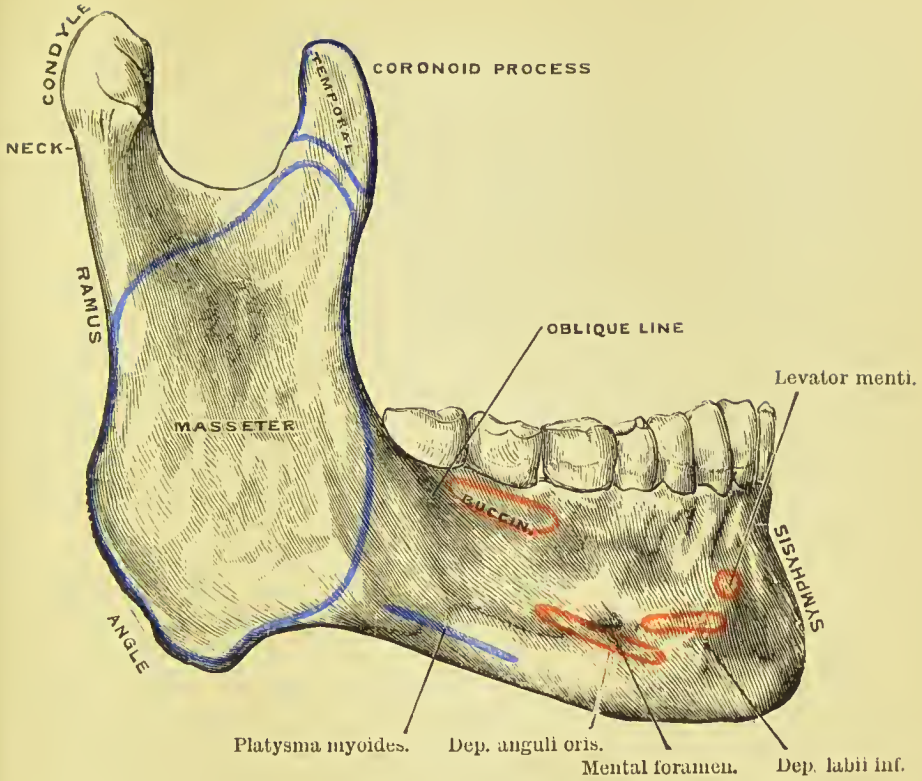



FIG. 117.—The lower jaw. 1. Body. 2. Ramus. 3. Symphysis. 4. Fossa for the depressor labii inferioris muscle. 5. Mental foramen. 6. External oblique ridge. 7. Groove for the facial artery; the situation of the groove is marked by a notch in the bone a little in front of the figure. 8. The angle. 9. Extremity of the mylo-hyoidean ridge. 10. Coronoid process. 11. Condyle. 12. Sigmoid notch. 13. Inferior dental foramen. 14. Mylo-hyoidean groove. 15. Alveolar process. *i*. Middle and lateral incisor tooth of one side. *c*. Canine tooth. *b*. Two bicuspids. *m*. Three molars.

diately beneath these, two other tubercles less marked; beneath them, a ridge, and beneath the ridge two depressions of some size. These four points give attachment, from above downwards, to the genio-hyo-glossi, genio-hyoidei, part of the mylo-hyoidei, and digastric muscles. Running outwards into the body of the bone from the above ridge is a prominent line, the *mylo-hyoidean ridge*, which gives attachment to the mylo-hyoid muscle; above its posterior termination, and near the margin of the alveolar process, the

PLATE 6.





superior constrictor muscle and pterygo-maxillary ligament have their attachment. Immediately above the ridge, and by the side of the symphysis, is a smooth concave surface, which corresponds with the sublingual gland; and below the ridge, and more externally, a deeper fossa for the submaxillary gland.

The **superior border** of the body of the bone is the alveolar process, furnished in the adult with alveoli for sixteen teeth. The inferior border or base is rounded and smooth; thick and everted in front to form the chin, and thinner behind where it merges into the angle of the bone.

The **ramus** is a strong square-shaped process, differing in direction at various periods of life; thus, in the fœtus and infant, it is almost parallel with the body; in youth it is oblique, and gradually approaches the vertical direction until manhood; in old age, after the loss of the teeth, it again declines, and assumes the oblique direction. On its external surface it is rough, for the attachment of the masseter muscle; and at the junction of its posterior border with the body of the bone it has a rough tuberosity, the *angle* of the lower jaw, which gives attachment by its inner margin to the stylo-maxillary ligament.

The upper extremity of the ramus presents two processes, separated by a concave sweep, the *sigmoid notch*. The anterior is the *coronoid process*; it is sharp and pointed, and gives attachment to the temporal muscle. The posterior process is the *condyle*, which is flattened from before backwards, oblique in direction, and smooth on its upper surface, to articulate with the glenoid cavity of the temporal bone. The constriction around the base of the condyle is its *neck*, into the external aspect of which is attached the external lateral ligament. A fossa on the anterior part of the neck of the condyle gives attachment to the external pterygoid muscle. The sigmoid notch is crossed by the masseteric artery and nerve.

The *internal surface* of the ramus is marked near its centre by a large oblique foramen, the *inferior dental*, for the entrance of the inferior dental artery and nerve into the dental canal. Bounding this opening is a sharp margin (*lingula mandibularis*), to which is attached the long internal lateral ligament, and passing downwards from the opening a narrow groove which lodges the mylo-hyoid vessels and nerve. To the uneven surface above and in front of the inferior dental foramen is attached the temporal muscle, and to the rough internal surface of the angle, the internal pterygoid.

Development.—In its earliest condition the inferior maxilla consists of fibrous tissue investing a cartilaginous rod called the *Cartilage of Meckel*, formed in the *first post-oral* or *mandibular arch*. Ossific deposit takes place (probably by several centres which fuse early), mainly in fibrous tissue, but the portion at the symphysis is formed by direct ossification of the Cartilage of Meckel, and the condyle and back part of the ramus, including the angle, are formed from plates of cartilage unconnected with Meckel's cartilage. The lower jaw is the earliest of the bones of the skeleton to exhibit

ossification, with the exception of the clavicle. At the time of birth it consists of two lateral halves united by fibrous tissue; ossific union of the symphysis takes place during the first year.

Articulations.—With the glenoid fossæ of the two temporal bones, through the medium of a fibro-cartilage.

Attachment of Muscles.—To *fifteen* pairs: by the *external surface*, commencing at the symphysis and proceeding outwards, levator labii inferioris, depressor labii inferioris, depressor anguli oris, platysma myoides, a few fibres of the orbicularis oris, buccinator, and masseter; by the *internal surface*, also commencing at the symphysis, the genio-hyo-glossus, genio-hyoid, mylo-hyoid, digastric, superior constrictor, temporal, external pterygoid, and internal pterygoid.

SUTURES.

The bones of the cranium and face are connected with each other by means of sutures (*sutura*, a seam). That is, the edges of the bone are roughened or uneven, are accurately adapted to each other, and united by a small quantity of fibrous tissue.

When the process of union of the bones of the skull is retarded by over-distension of the head, as in hydrocephalus, and sometimes without any such apparent cause, distinct ossific centres are developed in the interval between the edges; and, being surrounded by the suture, form independent pieces which are called *ossa triquetra*, or *ossa Wormiana*. These are most frequently found in the lambdoidal suture; but one sometimes occurs at the junction of the anterior inferior angle of the parietal bone with the tip of the great wing of the sphenoid; it is called the *pterion ossicle*.

The sutures may be divided into (1) those at the vertex, (2) those at the side of the skull, and (3) those at the base.

Those at the vertex are the *coronal*, *sagittal*, and *lambdoidal*.

The **coronal suture** (Fig. 118) extends transversely across the vertex of the skull, and connects the frontal with the parietal bones. In the formation of this suture the edges of the articulating bones are bevelled, so that the parietal rest on the frontal at each side, and in the middle the frontal rests on the parietal bones.

The **sagittal suture** extends longitudinally backwards along the vertex of the skull, from the middle of the coronal to the apex of the lambdoidal suture. It is much serrated, and serves to unite the two parietal bones. In the young subject, and sometimes in the adult, this suture is continued through the middle of the frontal bone to the root of the nose, under the name of *frontal suture*. *Ossa triquetra* are sometimes found in the sagittal suture.

The **lambdoidal suture** is named from some resemblance to the Greek letter lambda (Λ), consisting of two branches, which diverge at an acute angle from the extremity of the sagittal suture. This suture connects the occipital with the parietal bones.

The sutures at the side of the skull are the *squamo-parietal*, the *spheno-parietal*, and the *masto-parietal*.

The **squamo-parietal suture** (Fig. 118) unites the squamous portion of the temporal bone with the parietal, overlapping the lower border of the latter.

The **spheno-parietal suture** is formed by the union of the tip of the great wing of the sphenoid with the anterior inferior angle of the parietal bone.

The **masto-parietal suture** is the continuation backwards of the squamo-parietal; it unites the upper edge of the mastoid portion of the temporal with the back part of the lower border of the parietal.

The sutures at the base of the skull are the *basilar*, *petro-occipital*, *masto-occipital*, *petro-sphenoidal*, and *squamo-sphenoidal*.

The **basilar suture** is formed by the union of the basilar portions of the occipital and sphenoid bones; it is obliterated by the fusion of the bones in early adult life.

The **masto-occipital** and **petro-occipital sutures** are continuous; the former runs between the posterior edge of mastoid, and the lower part of the lateral edge of the occipital; the latter is placed between the petrous portion of the temporal and the basi- and ex-occipital, and has in it the large opening called jugular foramen.

The **petro-sphenoidal suture** is the short, irregular, union of the anterior edge of the petrous bone and the posterior border of the great wing of the sphenoid, and has in it the middle lacerated foramen.

The **squamo-sphenoidal suture** is the continuation downwards of the squamo-parietal suture.

Across the upper part of the face is an irregular suture, the **transverse**, which connects the frontal bone with the nasal, superior maxillary, lachrymal, ethmoid, sphenoid, and malar bones.

REGIONS OF THE SKULL.

The skull, considered as a whole, is divisible into five regions: a superior region or vertex; two lateral regions; an inferior region or base; and an anterior region, the face.

The **superior region**, or vertex of the skull, is bounded anteriorly by the frontal eminences; on each side by the temporal crest and parietal eminence; and behind by the superior curved line of the occipital bone and occipital protuberance. It is crossed transversely by the coronal suture, and marked from before backwards by the sagittal, which terminates posteriorly in the lambdoidal suture. Near the posterior extremity of the region, and on each side of the sagittal suture, is the parietal foramen.

The junction of the sagittal and coronal sutures is called the *bregma*, and lies vertically above the external auditory meatus; the junction of the sagittal and lambdoidal sutures is named the *lambda*, and is usually situated about $2\frac{1}{2}$ in. above the external occipital protuberance (60 mm., Clark). The part of the vertex in the neighbourhood of

the parietal foramen is generally a little flattened ; it has received the name of *obelion*.

On the *inner* or *cerebral surface* of this region is a shallow groove extending along the middle line from before backwards, for the superior longitudinal sinus ; at each side of this groove are several small fossæ for the Pacchionian bodies, and farther outwards, digital fossæ corresponding with the convexities of the convolutions, and numerous ramified grooves for lodging the branches of the meningeal arteries.

Each **lateral region** of the skull is divisible into three portions ; temporal, mastoid, and zygomatic.

The *temporal portion* or *temporal fossa* is bounded above and behind by the temporal crest, in front by the external angular process of the frontal and by the malar bone, and below by the zygoma. It

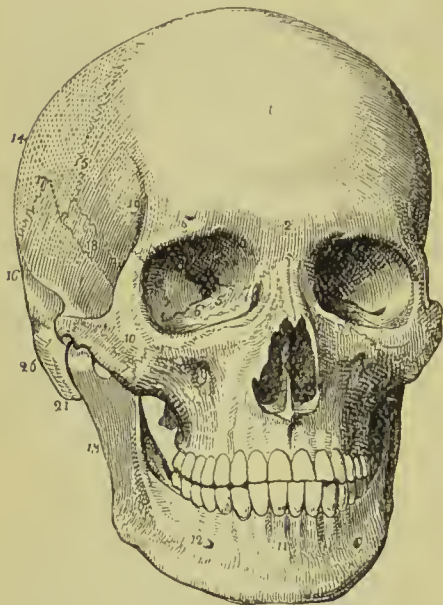


FIG. 118.—Front view of the skull. 1. Frontal portion of the frontal bone. The 2 immediately over the root of the nose refers to the glabella ; the 3 over the orbit to the supraorbital ridge. 4. Optic foramen. 5. Sphenoidal fissure. 6. Spheno-maxillary fissure. 7. The commencement of the nasal duct. The figures 4, 5, 6, 7, are within the orbit. 8. Opening of the anterior nares, divided into two parts by the vomer ; the figure is placed upon the latter. 9. Infraorbital foramen. 10. Malar bone. 11. Symphysis of the lower jaw. 12. Mental foramen. 13. Ramus of the lower jaw. 14. Parietal bone. 15. Coronal suture. 16. Temporal bone. 17. Squamo-parietal suture. 18. Upper part of the great wing of the sphenoid bone. 19. Commencement of the temporal crest. 20. Zygoma. 21. Mastoid process.

is formed by part of the frontal, great wing of the sphenoid, parietal, squamous portion of the temporal, malar bone, and zygoma, and is crossed by six sutures, the transverse of the face, coronal, squamo-parietal, sphe-no-parietal, sphe-no-malar, and squamo-sphenoidal ; it lodges the temporal muscle with the deep temporal arteries and nerves.

The *mastoid portion* is rough, for the attachment of muscles. On its posterior part is the mastoid foramen ; and below, the mastoid process. In front of the mastoid process is the external auditory meatus, surrounded by the external auditory process ; and in front of the meatus the glenoid cavity, bounded above by the middle root of the zygoma, and in front by the eminentia articularis.

The *zygomatic portion*, or *fossa*, is the irregular cavity below the zygoma, bounded in front by the superior maxillary bone, internally

by the external pterygoid plate, above by the part of the great wing of the sphenoid external to the pterygoid ridge, and lower part of the squamous portion of the temporal bone ; and externally by the zygomatic arch and ramus of the lower jaw. It contains the external pterygoid, part of the temporal, and internal pterygoid muscles ; and the internal maxillary artery and inferior maxillary nerve, with their branches. At the inner side and upper part of the zygomatic fossa are two fissures, spheno-maxillary and pterygo-maxillary. The *spheno-maxillary fissure*, horizontal in direction, opens into the orbit, and is situated between the great wing of the sphenoid and the superior maxillary bone. It is completed externally by the malar bone. The *pterygo-maxillary fissure* is vertical, and descends at a right angle from the extremity of the preceding. It is situated between the pterygoid process and the tuberosity of the superior maxillary bone, and transmits the internal maxillary artery. At the angle of junction of these two fissures is a small space, the *spheno-maxillary fossa*, bounded by the sphenoid, palate, and superior maxillary bones.

The **base of the skull** presents an internal or cerebral, and an external or basilar surface.

The *cerebral surface* is divisible into three parts, which are named anterior, middle, and posterior fossa of the base of the cranium. The *anterior fossa* is somewhat convex at each side, where it corresponds with the roof of the orbits ; and concave in the middle, in the situation of the ethmoid bone and interior part of the body of the sphenoid. The latter and the free edges of the lesser wings constitute its posterior boundary. It supports the anterior lobes of the cerebrum. In the middle line of this fossa, at its anterior part, is the *crista galli* ; immediately in front of that process, the *foramen cæcum*, which gives passage to a small vein from the nose to the superior longitudinal sinus ; and on each side, the *cribriform plate* with its *foramina*, for the transmission of the filaments of the olfactory nerve, and a slit for the nasal branch of the ophthalmic nerve. On the outer edges of the cribriform plate are seen the openings of the *anterior* and *posterior internal orbital foramina*. Farther back in the middle line is the olivary process, and, at the sides of this process, the *optic foramina*, *anterior* and *middle clinoid processes*, and vertical *grooves* for the internal carotid arteries.

The *middle fossa* of the base, deeper than the preceding, is bounded in front by the lesser wing of the sphenoid ; behind, by the upper border of the petrous portion of the temporal bone ; and is divided into two lateral parts by the sella turcica. It is formed by the posterior part of the body, great wing, and spinous process of the sphenoid, and by the petrous and squamous portion of the temporal bones. In the centre of this fossa is the *sella turcica*, which lodges the pituitary gland and circular sinus, bounded in front by the *anterior* and *middle*, and behind by the *dorsum sellæ* and *posterior clinoid processes*. On each side of the sella turcica is the *carotid groove* for the internal carotid artery, cavernous plexus of nerves,

cavernous sinus, and orbital nerves; and farther outwards the following foramina, from before backwards: *sphenoidal fissure* (foramen lacerum anterius) for the transmission of the third, fourth, three branches of the ophthalmic division of the fifth, and the sixth nerve, and ophthalmic vein; *foramen rotundum*, for the superior maxillary nerve; *foramen ovale*, for the inferior maxillary nerve, lesser meningeal artery, and lesser petrosal nerve; *foramen Vesalii* for a small vein; *foramen spinosum*, for the middle meningeal artery; *foramen lacerum basis cranii* (foramen lacerum medium), which is, in the recent state, closed in by fibrous tissue below, and is crossed by the internal carotid artery, carotid plexus, and petrosal branch of the Vidian nerve. On the anterior surface of the petrous portion of the temporal bone is a groove, leading to a fissured open-

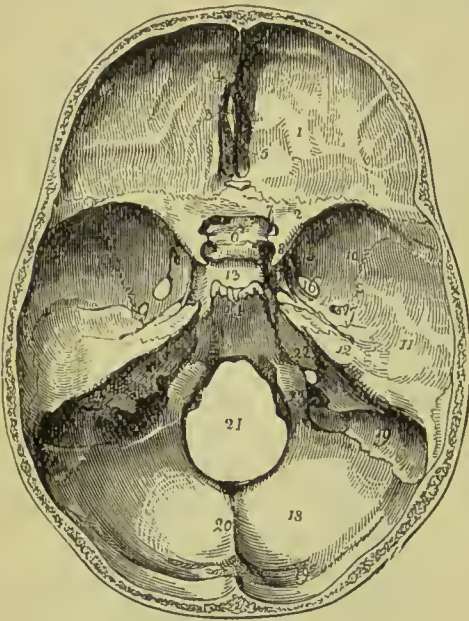


FIG. 119.—Cerebral surface of the base of the skull. 1. One side of the anterior fossa; the figure is placed on the roof of the orbit, formed by the orbital plate of the frontal bone. 2. Lesser wing of the sphenoid. 3. Crista galli. 4. Foramen cæcum. 5. Cribriform plate of the ethmoid. 6. Olfactory process. 7. Optic foramen. 8. Anterior clinoid process. 9. Carotid groove for the internal carotid artery and cavernous sinus. 10, 11, 12. Middle fossa. 10 marks the great wing of the sphenoid. 11. Squamous portion of the temporal bone. 12. Petrous portion. 13. Sella turcica. 14. Basilar portion of the sphenoid and occipital bone. The uneven ridge between Nos. 13, 14, is the dorsum sellæ, and the prominent angles of this ridge the posterior clinoid processes. 15. Foramen rotundum. 16. Foramen ovale. 17. Foramen spinosum; the small irregular opening between 17 and 12 is the hiatus Fallopii. 18. Posterior fossa. 19, 20. Groove for the lateral sinus. 20. Ridge which gives attachment to the falx cerebelli. 21. Foramen magnum. 22. Meatus auditorius internus. 23. Jugular foramen.

ment to the falx cerebelli. 21. Foramen magnum. 23. Jugular foramen.

ing, the *hiatus Fallopii*, for the petrosal branch of the Vidian nerve; and immediately beneath this a smaller foramen, for the lesser petrosal nerve. Towards the apex of the petrous portion is the notch for the fifth nerve, and below it a slight depression for the Gasserian ganglion. Farther outwards is the eminence which marks the position of the perpendicular semi-circular canal. Proceeding from the foramen spinosum are two grooves, which indicate the course of the trunks of the middle meningeal artery. The whole fossa lodges the temporo-sphenoidal lobes of the cerebrum.

The *posterior fossa*, larger than the other two, is formed by the occipital bone, petrous and mastoid portion of the temporals, and by a small part of the sphenoid and parietals. It is bounded in front by the upper border of the petrous portion and dorsum sellæ, and

along its posterior circumference by the groove for the lateral sinuses ; it gives support to the pons Varolii, medulla oblongata, and cerebellum. In the centre of this fossa is the *foramen magnum*, bounded at each side by a rough tubercle, which gives attachment to the odontoid ligament, and by the anterior condylar foramen. In front of the foramen magnum is the concave surface which supports the medulla oblongata and pons Varolii, and on each side the following foramina, from before backwards. The *internal auditory meatus* for the auditory and facial nerves and auditory artery ; behind, and externally to this, is a small foramen leading into the *aquæductus vestibuli* ; and below it, partly concealed by the edge of the petrous bone, the *aquæductus cochleæ* ; next, a long fissure, the *foramen lacernum posterius* or *jugular foramen*, partially divided into two by the jugular spine, the outer portion giving passage to the termination of the inferior petrosal and lateral sinuses, and the inner to the ninth, tenth, and eleventh pairs of nerves. Converging towards this foramen from behind is the deep groove of the lateral sinus, and from the front the groove for the inferior petrosal sinus.

Behind the foramen magnum is the *internal occipital crest*, which gives attachment to the falx cerebelli, and divides the two inferior fossæ of the occipital bone ; and above the ridge is the internal occipital protuberance, the transverse groove lodging the lateral sinus, and the transverse ridge giving attachment to the tentorium cerebelli.

The *external surface* of the base of the skull is extremely uneven. From before backwards it is formed by the palate processes of the superior maxillary and palate bones ; the vomer ; pterygoid, spinous processes, and part of the body of the sphenoid ; under surface of the squamous, petrous, and mastoid portion of the temporals ; and by the occipital bone. The palate processes of the superior maxillary and palate bones constitute the hard palate, which is raised above the level of the rest of the base (when the skull is turned over for the purpose of examination), and is surrounded by the alveolar processes containing the teeth of the upper jaw. At the anterior extremity of the hard palate, and directly behind the front incisor teeth, is the *anterior palatine* or *incisive foramen*, which transmits the naso-palatine nerves and anterior palatine arteries. At the posterior angles of the palate are the *posterior palatine foramina*, for the palatine nerves and arteries. Passing inwards from these foramina is the *transverse ridge*, to which are attached the aponeurotic expansions of the tensor palati muscles ; and at the middle line of the posterior border, the *palate spine*, which gives origin to the azygos uvulæ. The hard palate is marked by a crucial suture, which distinguishes the four processes of which it is composed. Behind, and above the hard palate, are the *posterior nares*, separated by the vomer, and bounded at each side by the internal pterygoid plates. At the base of the pterygoid plates are the *pterygo-palatine canals*. The internal pterygoid plate is long and narrow, terminated at its apex by the hamular process, and at

its base by the scaphoid fossa. The external plate is broad; the space between the two is the pterygoid fossa; it contains part of the internal pterygoid muscle, and the tensor palati. Externally to the external pterygoid plate is the zygomatic fossa. Behind the nasal fossæ, in the middle line, is the under surface of the body of the sphenoid, and the basilar process of the occipital bone, and still farther back, the foramen magnum. At the base of the external pterygoid plate on each side, is the *foramen ovale*, and behind this the *foramen spinosum* with the prominent spine which gives attachment to the long internal lateral ligament of the lower jaw and laxator tympani muscle. Running outwards from the apex of the spinous process of the sphenoid bone is the fissure of Glaser, which crosses

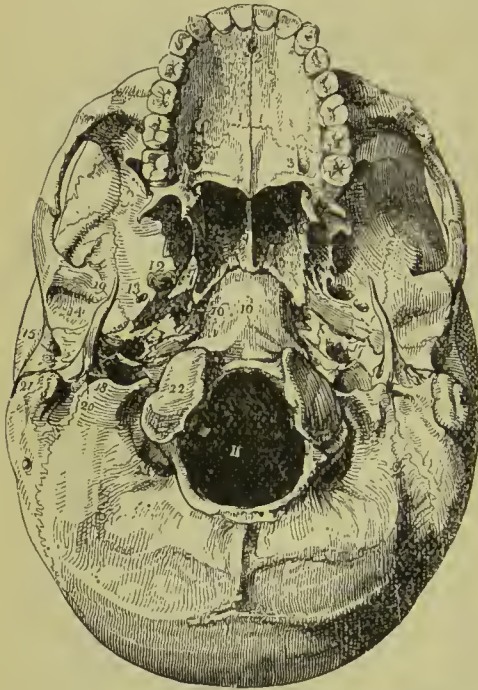


FIG. 120.—External or basilar surface of the base of the skull. 1, 1. The hard palate. The figures are placed on the palate processes of the superior maxillary bones. 2. Incisive foramen. 3. Palate process of the palate bone. The large opening near the figure is the posterior palatine foramen. 4. Palate spine; the curved line upon which the number rests is the transverse ridge. 5. Vomer, dividing the openings of the posterior nares. 6. Internal pterygoid plate. 7. Scaphoid fossa. 8. External pterygoid plate. The interval between 6 and 8 (right side of the figure) is the pterygoid fossa. 9. Zygomatic fossa. 10. Basilar process of the occipital bone. 11. Foramen magnum. 12. Foramen ovale. 13. Foramen spinosum. 14. Glenoid fossa. 15. Meatus auditorius externus. 16. Foramen lacerum medium. 17. The carotid foramen of the left side. 18. Jugular foramen. 19. Styloid process. 20. Stylo-mastoid foramen. The elevation just to the right of the number is the jugular tubercle; and the groove to its left

the digastric fossa. 21. Mastoid process. 22. One of the condyles of the occipital bone. 23. Posterior condylar fossa.

the glenoid fossa transversely, and divides it into an anterior smooth surface, bounded by the eminentia articularis, for the condyle of the lower jaw, and a posterior rough surface for a part of the parotid gland. Behind the foramen ovale and spinosum is the irregular fissure between the spinous process of the sphenoid bone and the petrous portion of the temporal, the foramen lacerum basis cranii (called also foramen lacerum medium), which lodges the internal carotid artery, and in which the carotid branch of the Vidian nerve joins the carotid plexus. Following the direction of this fissure outwards, we see the foramen for the Eustachian tube, and that for the tensor tympani muscle, separated from each other by the processus cochleariformis. Behind the fissure is the pointed process

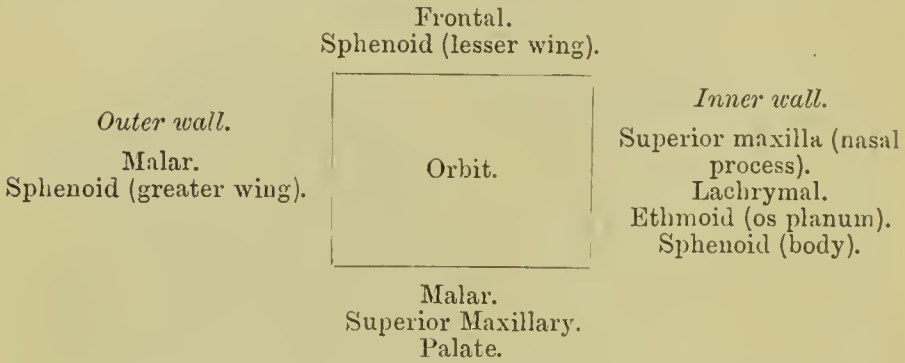
of the petrous bone which gives origin to the levator palati and tensor tympani muscles, and, externally to this process, the carotid foramen for the transmission of the internal carotid artery and ascending branches of the superior cervical ganglion of the sympathetic; and behind the carotid foramen, the jugular foramen and jugular fossa. Externally, and somewhat in front of the latter, is the styloid process, and at its base the vaginal process. Behind and at the foot of the styloid process is the stylo-mastoid foramen, for the facial nerve and stylo-mastoid artery, and farther outwards the mastoid process. At the inner side of the root of the mastoid process is the digastric fossa; and a little farther inwards, the occipital groove. On the sides of the foramen magnum, and near its anterior circumference, are the condyles of the occipital bone. In front of each condyle, and piercing its base, is the anterior condylar foramen for the hypoglossal nerve, and directly behind the condyle the irregular fossa in which the posterior condylar foramen is situated. Behind the foramen magnum are the two curved lines of the occipital bone, the spine, and the protuberance, with the rough surfaces for the attachment of muscles.

The **Face** is somewhat oval in contour, uneven in surface, and excavated for the reception of two principal organs of sense, the eye and the nose. It is formed by part of the frontal bone, and by the bones of the face. Superiorly it is bounded by the frontal eminences; beneath these are the superciliary ridges, converging towards the glabella; beneath the superciliary ridges are the supraorbital ridges, terminating externally in the external border of the orbit, and internally in the internal border, and presenting towards their inner third the supraorbital notch, for the supraorbital nerve and artery. Beneath the supraorbital ridges are the cavities of the orbits. Beneath the orbits is the bridge of the nose, overarched the anterior nares; and on each side of the nares the canine fossa of the superior maxillary bone, the infraorbital foramen, and still farther outwards the prominence of the malar bone; at the lower margin of the nares is the nasal spine, and beneath it the superior alveolar arch, containing the teeth of the upper jaw. Forming the lower boundary of the face is the lower jaw, containing in its alveolar process the lower teeth, and projecting inferiorly to constitute the chin; on each side of the chin is the mental foramen. If a perpendicular line be drawn from the inner third of the supraorbital ridge to the inner third of the body of the lower jaw, it will be found to intersect three openings: the supraorbital, infraorbital, and mental, each giving passage to a facial branch of the fifth nerve.

ORBITS.

The *orbits* are two quadrilateral hollow cones, situated in the upper part of the face, and intended for the reception of the eyeballs, with their muscles, vessels, and nerves, and the lachrymal

glands. The central axis of each orbit is directed outwards, so that the axes of the two, continued into the skull through the optic foramina, would intersect over the middle of the sella turcica. The *superior boundary* of the orbit is formed by the orbital plate of the frontal bone, and part of the lesser wing of the sphenoid; the *inferior* by part of the malar bone, superior maxillary, and orbital plate of the palate bone; the *internal*, by the nasal process of the superior maxillary, lachrymal, os planum of the ethmoid, and part of the body of the sphenoid; the *external*, by the orbital process of the malar bone and great wing of the sphenoid. These may be expressed more clearly in a tabular form:—



There are *nine* openings communicating with the orbit: the *optic*, for the admission of the optic nerve and ophthalmic artery; the *sphenoidal fissure*, for the transmission of the third, fourth, the three branches of the ophthalmic division of the fifth nerve, the sixth nerve, and the ophthalmic vein; the *spheno-maxillary fissure*, for the passage of the superior maxillary nerve and infraorbital artery to the opening of entrance of the *infraorbital canal*; *temporo-malar foramina*, two or three small openings in the orbital process of the malar bone, for the passage of filaments of the orbital branch of the superior maxillary nerve; *anterior* and *posterior internal orbital foramina* in the suture between the os planum and frontal bone, the former transmitting the nasal nerve and anterior ethmoidal vessels, the latter the posterior ethmoidal vessels; the opening of the *nasal duct*; and the *supraorbital notch* or foramen, for the supraorbital nerve and artery.

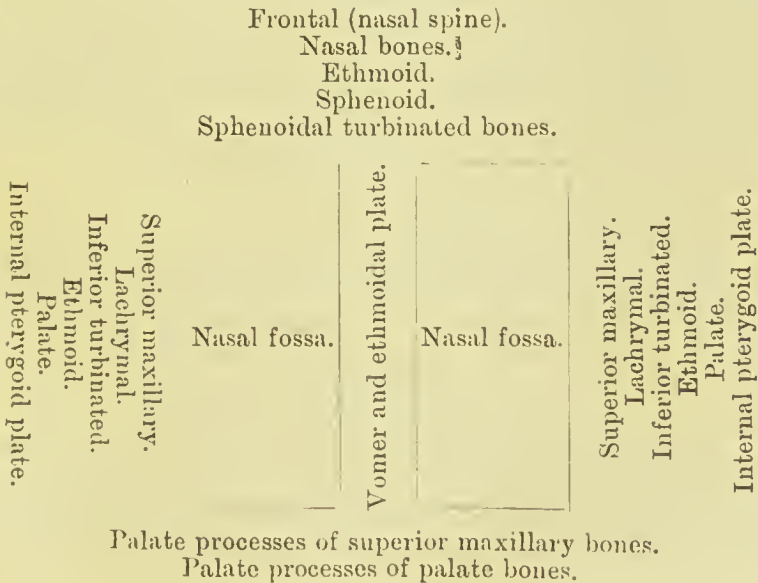
SPHENO-MAXILLARY FOSSA.

This is a small space situated between the bones of the head and those of the face; it corresponds in position to the junction of the spheno-maxillary and pterygo-maxillary fissures. It is triangular in form, and is bounded above by the body of the sphenoid and orbital process of the palate, in front by the superior maxillary, behind by the base of the pterygoid plate and lower part of the anterior surface

of the great wing of the sphenoid, internally by the vertical plate of the palate ; it is wide above, near the base of the skull, but narrow below, where it is continued into the upper part of the descending palatine canal. The fossa has opening into it three fissures and five foramina : the former are the sphenoidal, speno-maxillary, and pterygo-maxillary ; the latter are the foramen rotundum, Vidian, descending palatine, pterygo-palatine, and speno-palatine. The foramen rotundum, Vidian, and pterygo-palatine foramina are on the posterior wall, being placed in the order of their enumeration from above downwards ; the speno-palatine is on the inner wall, and the descending palatine below. The fossa lodges Meckel's ganglion, the superior maxillary nerve, and the third part of the internal maxillary artery ; and the foramina which open into it (with the exception of the foramen rotundum) give passage to nerve-twigs derived from the ganglion and small branches of the artery.

NASAL FOSSÆ.

The nasal fossæ are two irregular cavities, situated in the middle of the face, and extending from before backwards. They are bounded *above* by the nasal spine of the frontal, nasal, ethmoid, sphenoid, and sphenoidal turbinated bones ; *below* by the palate processes of the superior maxillary and palate bones ; *externally* by the superior maxillary, lachrymal, inferior turbinated, superior and middle turbinated bones of the ethmoid, palate, and internal pterygoid plate of the sphenoid ; and the two fossæ are separated by the vomer and perpendicular lamella of the ethmoid. The inner wall presents a large triangular notch anteriorly, which in the recent state is filled in by the cartilage of the septum. These may be more clearly expressed in a tabular form :—



Each nasal fossa is divided into three irregular longitudinal passages, or *meatuses*, by three processes of bone, which project from its outer wall—the superior, middle, and inferior turbinated bone; the superior and middle turbinated bone being processes of the ethmoid; the inferior, a distinct bone of the face. The **superior meatus** occupies the superior and posterior part of each fossa; it is situated between the superior and middle turbinated bone, and has opening into it two foramina—viz., foramen of the posterior ethmoidal cells, and spheno-palatine foramen. The sphenoidal sinuses usually open into the upper part of the nasal fossæ, immediately behind the superior turbinated bone. The **middle meatus** is the space between

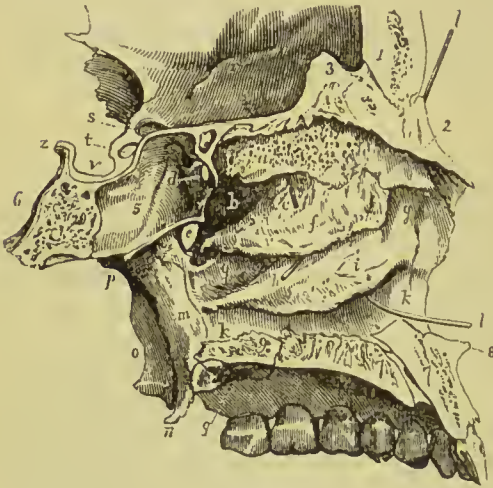


FIG. 121.—Longitudinal section of the nasal fossæ made immediately to the right of the middle line, the bony septum removed in order to show the external wall of the left fossa. 1. Frontal bone. 2. Nasal bone. 3. Crista galli. The groove between 1 and 3 is the lateral boundary of the foramen cæcum. 4. Cribriform plate of the ethmoid. 5. Sphenoidal cells. Bones 2, 4, and 5 form the superior boundary of the nasal fossa. 6. Basilar portion of the sphenoid bone. 7, 7. Palate process of superior maxillary bone. The groove between 7, 7, is the lateral half of the incisive canal, and the dark aperture in the groove the inferior termination of the left naso-palatine canal. 8. Nasal spine. 9. Palate process of palate bone. a. Superior turbinated bone. b. Su-

perior meatus. c. A probe passed into the posterior ethmoidal cells. d. Opening of the sphenoidal cells into the superior meatus. e. Spheno-palatine foramen. f. Middle turbinated bone. g, g. Middle meatus. h. A probe passed into the infundibulum leading from the frontal sinuses and anterior ethmoidal cells; the triangular aperture immediately above the letter is the opening of the antrum. i. Inferior turbinated bone. k, k. Inferior meatus. l, l. A probe passed up the nasal duct, showing the direction of that canal. m. Internal pterygoid plate. n. Its lamular process. o. External pterygoid plate. p. Root of pterygoid processes. q. Posterior palatine foramina. r. Roof of the left orbit. s. Optic foramen. t. Groove for the last turn of the internal carotid artery converted into a carotico-ethmoid foramen. v. Sella turecia. z. Posterior clinoid process.

the middle and inferior turbinated bone; it also presents two foramina, the opening of the *infundibulum* (the common opening of the anterior ethmoidal cells and frontal sinus), and of the antrum. The largest of the three passages is the **inferior meatus**, which is the space between the inferior turbinated bone and the floor of the nasal fossa; in it there are two foramina, the termination of the nasal duct, and the opening of the anterior palatine canal. In the recent state the Eustachian tube looks forward into the nares, and opens into the pharynx just behind the inferior meatus. The nasal fossæ commence upon the face by a large irregular opening, the anterior nares, and terminate posteriorly in the two posterior nares.

OS HYOIDES.

The os hyoides (*lingual bone*) gives support to the tongue, and attachment to numerous muscles in the neck. It is named from its resemblance to the Greek letter ν , and consists of a central portion or body, of two larger cornua, which project backwards from the body; and two lesser cornua, which ascend from the angle of union between the body and the greater cornua.

The body (*basihyal*) is somewhat quadrilateral, rough and convex on its antero-superior surface, by which it gives attachment to muscles; concave and smooth on the postero-inferior surface, by which it lies in contact with the thyro-hyoid membrane. The greater cornua (*thyro-hyals*) are flattened from above downwards, and terminated posteriorly by a tubercle; and the lesser cornua (*cerato-hyals*), conical in form, give attachment to the stylo-hyoid ligaments. In early age and in the adult the cornua are connected with the body by distinct diarthrodial joints; in old age they become united by bone.

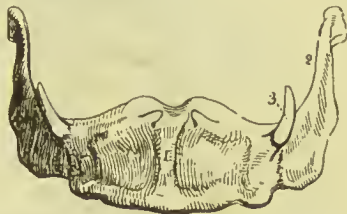

FIG. 122.—The os hyoides seen from before. 1. Antero-superior, or convex side of the body. 2. Great cornu of the left side. 3. Lesser cornu of the same side.

Development.—By *five* centres, one for the body, and one for each cornu. Ossification commences in the greater cornua and body during the last month of fetal life, and in the lesser cornua soon after birth. The cornua do not unite with the body till after middle life.

Attachment of Muscles.—To *eleven* pairs: sterno-hyoid, thyro-hyoid, omo-hyoid, pulley of the digastricus, stylo-hyoid, mylo-hyoid, genio-hyoid, genio-hyo-glossus, hyo-glossus, lingualis, and middle constrictor of the pharynx. It also gives attachment to the stylo-hyoid, thyro-hyoid, and hyo-epiglottic ligaments, and to the thyro-hyoid membrane.

THE THORAX.

The skeleton of the thorax consists of the dorsal vertebræ, already described, the sternum, ribs, and costal cartilages.

STERNUM.

The sternum (Fig. 123) is situated in the middle line of the front of the chest, and is oblique in direction, the superior end lying within a few inches of the vertebral column, the inferior being projected forwards so as to be placed at a considerable distance from the spine. The bone is flat in front, and marked by five transverse lines

which indicate its original subdivision into six pieces. It is slightly concave behind, broad and thick above, narrowest at the junction of the first and second pieces, and flattened and pointed below; it is divisible in the adult into three pieces, superior, middle, and inferior, or presternum, mesosternum, and metasternum.

The **manubrium** (*presternum*) is somewhat triangular in shape; it is broad and thick above, where it presents a concave border, *suprasternal* or *interclavicular* notch; and narrow at its junction with the middle piece. At each superior angle is a deep articular depression for the clavicle; and on either side two notches for articulation with the cartilage of the first rib, and one-half that of the second. The junction of the manubrium and body is marked by a transverse ridge, the *sternal angle*, which serves as a guide to the anterior extremity of the second rib.

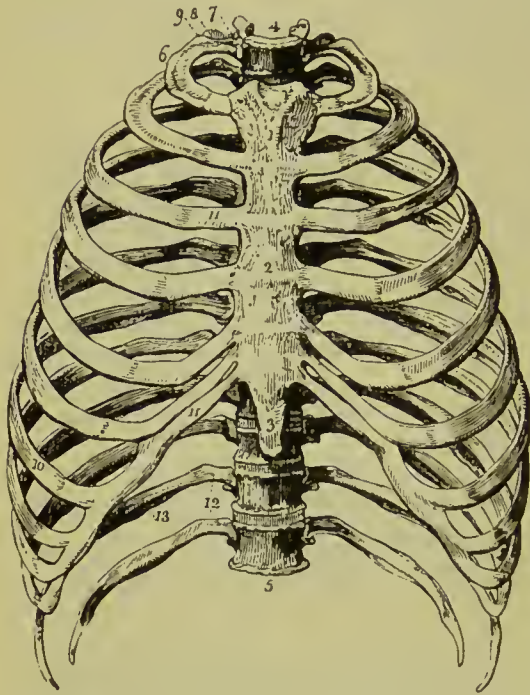


FIG. 123.—Anterior view of the thorax. 1. Manubrium. 2. Body or gladiolus. 3. Ensiform cartilage. 4. First dorsal vertebra. 5. Last dorsal vertebra. 6. First rib. 7. Its head. 8. Its neck, resting against the transverse process of the first dorsal vertebra. 9. Its tubercle. 10. Seventh or last true rib. 11. Costal cartilages of the true ribs. 12. The last two false ribs or floating ribs. 13. The groove along the lower border of the rib.

piece is sometimes perforated by an opening of variable size, resulting from arrest of development.

The **ensiform** or **xiphoid process** (*metasternum*) is the smallest of the three, often merely cartilaginous, and very variable in appearance, being sometimes pointed, at other times broad and thin, and at other times, again, perforated by a round hole, or bifid. It presents a notch at each side for articulation with the lower half of the cartilage of the seventh rib.

Development.—The sternum is usually developed from six centres, one for each of the segments of which the bone primarily

The body or **gladiolus** (*mesosternum*), considerably longer than the superior, is broad in the middle, and somewhat narrower at each extremity. It presents at each side six articular notches for the lower half of the second rib, the four next ribs, and the upper half of the seventh. The articular notches are placed opposite to the lines which indicate the original subdivision of the bone. This

consists. Ossification commences in the manubrium towards the end of the sixth month of fetal life, in the second segment about the seventh or eighth month, in the third and fourth about the time of birth, and in the fifth segment during the first year. The osseous centre for the ensiform cartilage is very variable in its advent, being first apparent at any period from the sixth to the fifteenth year, or even later. Frequently, additional nuclei appear in several of the segments, this being more especially the case with the manubrium, in which as many as six centres have occasionally been observed; in the third, fourth, and fifth segments there are frequently two centres which are placed laterally, and it is the irregular union of these pairs that gives rise to the foramina occasionally seen in the sternum towards its lower part. Union of the pieces of the sternum commences from below and proceeds upwards; the fifth piece unites with the fourth at about puberty, the fourth and third between twenty and twenty-five, the third and second between twenty-five and thirty. The ensiform appendix becomes joined to the body of the sternum at forty or fifty years; and the manubrium to the body only in very old age. Two small pisiform pieces have been described by Béclard and Breschet, as being situated upon and somewhat behind each extremity of the supra-sternal notch of the upper border of the manubrium.

Articulations.—With the clavicles and seven costal cartilages on each side.

Attachment of Muscles.—To *nine* pairs and one single muscle—viz., by its *anterior surface* to the pectoralis major, by its *upper border* to the sterno-mastoid, by the *upper and posterior part of the manubrium* to the sterno-hyoid and sterno-thyroid, by the *posterior surface of the body* to the triangularis sterni, and by the *ensiform cartilage* to the external oblique, internal oblique, transversalis, rectus, and diaphragm.

RIBS.

The ribs are twelve in number at each side; the first seven are connected with the sternum by the costal cartilage, and are thence named *sternal* or *true* ribs; the remaining five are the *asternal* or *false* ribs; and the last two, shorter than the rest, and free at their extremities, are the *floating* ribs. The ribs increase in length from the first to the eighth, whence they diminish to the twelfth; in breadth they diminish gradually from the first to the last, and, with the exception of the last two, are broader at the anterior than at the posterior end. The first rib is horizontal in direction; all the rest are oblique, the anterior extremity falling considerably below the posterior. Each rib presents an external and internal surface, a superior and inferior border, and two extremities; it is curved to correspond with the arch of the thorax, and twisted, so that, when laid on a horizontal surface, one end is tilted up.

The **external surface** is convex, and marked by the attachment

of muscles; the *internal* is flat, and corresponds with the pleura; the *superior border* is rounded. The *inferior border* is sharp and grooved on its inner edge, the lower edge of the groove giving attachment to the external, and the upper edge to the internal intercostal muscle. Near its vertebral extremity, the rib is somewhat bent; and opposite the bend, on the external surface, is a rough oblique ridge, which gives attachment to a tendon of the sacro-lumbalis muscle, and is called the *angle*. The distance between the vertebral extremity and the angle increases gradually from the second to the eleventh rib. Beyond the angle is a rough elevation, the *tubercle*, to which the posterior costo-transverse ligament is attached; and immediately at the base and under side of the tubercle a smooth surface for articulation with the extremity of the transverse process of the corresponding vertebra. The vertebral end of the rib is somewhat expanded, and termed the *head*, and that portion between the head and tubercle, the *neck*. On the extremity of the head is an oval smooth surface divided by a transverse ridge into two facets for articulation with two contiguous vertebræ; the ridge being joined to the intervertebral substance by means of an inter-

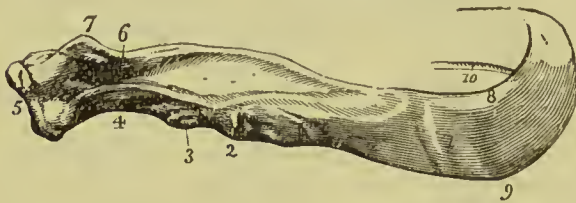


FIG. 124.—Vertebral extremity of the seventh rib of the right side. 1. The angle. 2. The tubercle; rough surface for the posterior costo-transverse ligament. 3. Articular surface. 4. Neck of rib. 5. Head, presenting two articular facets. 6. Rough surface

for the attachment of the middle costo-transverse ligament. 7. Crest for the anterior costo-transverse ligament. 8. Upper rounded border. 9. Lower sharp border. 10. Groove on the inner edge of the lower border.

articular ligament. The posterior surface of the neck is rough, for the attachment of the middle costo-transverse ligament; and upon its upper border is a crest, which gives attachment to the anterior costo-transverse ligament. The sternal extremity is flattened, and presents an oval depression for the reception of the costal cartilage.

The ribs that demand especial consideration are the first, tenth, eleventh, and twelfth.

The **first** is the shortest rib; it is broad and flat, and placed horizontally at the upper part of the thorax, the surfaces looking upwards and downwards, in place of forwards and backwards as in the other ribs. At about the anterior third of the upper surface of the bone, and near its internal border, is a tubercle (*scalene tubercle*), which gives attachment to the scalenus anticus muscle, and immediately before and behind that tubercle, a shallow oblique groove, the former for the subclavian vein, the latter for the subclavian artery. Near the posterior extremity of the bone is a thick and prominent *tubercle*, with a smooth articular surface for the transverse process of the first dorsal vertebra; and between the tubercle and the groove for the subclavian artery is a depression for the attach-

ment of the scalenus medius muscle. There is no angle, and no groove on the under side. Beyond the tubercle is a narrow constricted neck; and at the extremity, a head, presenting a single articular surface.

The **second** rib, in some of its characters, resembles the first, being flattened from above downwards, and only slightly twisted; it presents near the middle a rough surface for the attachment of the second and third digitations of the serratus magnus.

The **tenth** rib has a single articular surface on its head.

The **eleventh** and **twelfth** have each a single articular surface on the head, no neck or tubercle, and are pointed at the free extremity. The eleventh has a slight ridge, representing the angle, and a shallow groove on the lower border; the twelfth has neither.

Development.—The ribs are developed by *three* centres; one for the central part, one for the head, and one for the tubercle. The last two have no centre for the tubercle. Ossification commences in the body somewhat before its appearance in the vertebræ; the epiphyseal centres for the head and tubercle appear between sixteen and twenty, and are consolidated with the rest of the bone at twenty-five.

Articulations.—Each rib articulates with two vertebræ and one costal cartilage, with the exception of the first, tenth, eleventh, and twelfth, which articulate each with a single vertebra only.

Attachment of Muscles.—Intercostal muscles, scalenus anticus, medius, and posticus, pectoralis minor, serratus magnus, obliquus externus, latissimus dorsi, quadratus lumborum, serratus posticus superior, serratus posticus inferior, sacro-lumbalis, longissimus dorsi cervicalis ascendens, levatores costarum, transversalis, and diaphragm.

COSTAL CARTILAGES.—The costal cartilages serve to prolong the ribs forward to the anterior part of the chest, and contribute mainly to the elasticity of the thorax. They are broad at their attachment with the ribs, and taper slightly towards the sternal end; they diminish gradually in breadth from the first to the last; in length they increase from the first to the seventh, and then decrease to the last. The cartilages of the first two ribs are horizontal in direction; the rest incline more and more upwards. In advanced age

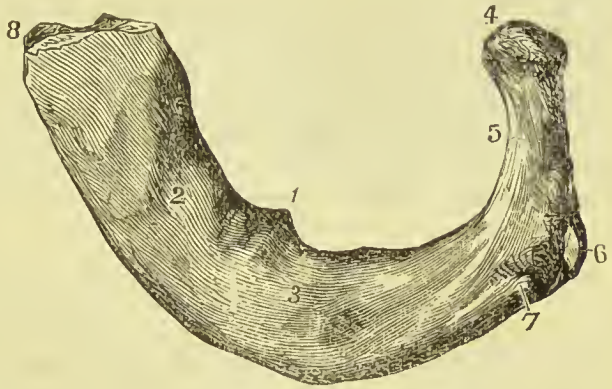


FIG. 125.—First rib of left side. 1. Scalene tubercle. 2. Groove for subclavian vein. 3. Groove for subclavian artery. 4. Head. 5. Neck. 6. Articular portion of tubercle. 7. Rough portion of tubercle. 8. Anterior end.

the costal cartilages are converted more or less completely into bone, the change taking place earlier in the male than in the female.

The first seven cartilages articulate with the sternum ; the three next, with the lower border of the cartilage immediately preceding ; the last two lie free between the abdominal muscles. All the cartilages of the false ribs terminate by pointed extremities.

Attachment of Muscles.—Subclavius, sterno-thyroid, pectoralis major, internal oblique, rectus, transversalis, diaphragm, triangularis sterni, internal intercostals.

THE THORAX AS A WHOLE.

The thorax is conical in shape, flattened antero-posteriorly, and wider from side to side than from before backwards. It is formed posteriorly by the dorsal vertebræ, and ribs, the bodies of the former projecting into the cavity, and the latter forming a backward convexity on each side, the furrow between the back of the ribs and the spinous processes of the vertebræ being occupied in the recent state by the dorsal muscles. The anterior wall, formed by the sternum and costal cartilages, inclines forwards as it descends, and at its lower end is a depression corresponding to the xiphoid cartilage. The upper edge of the sternum corresponds to the level of the lower part of the body of the second dorsal vertebra in the male, and in the female to the lower part of the body of the third. The female thorax is relatively shorter and rounder than the male, and is also relatively wider in its upper part. The lower part of the thoracic wall encloses the upper part of the abdominal cavity.

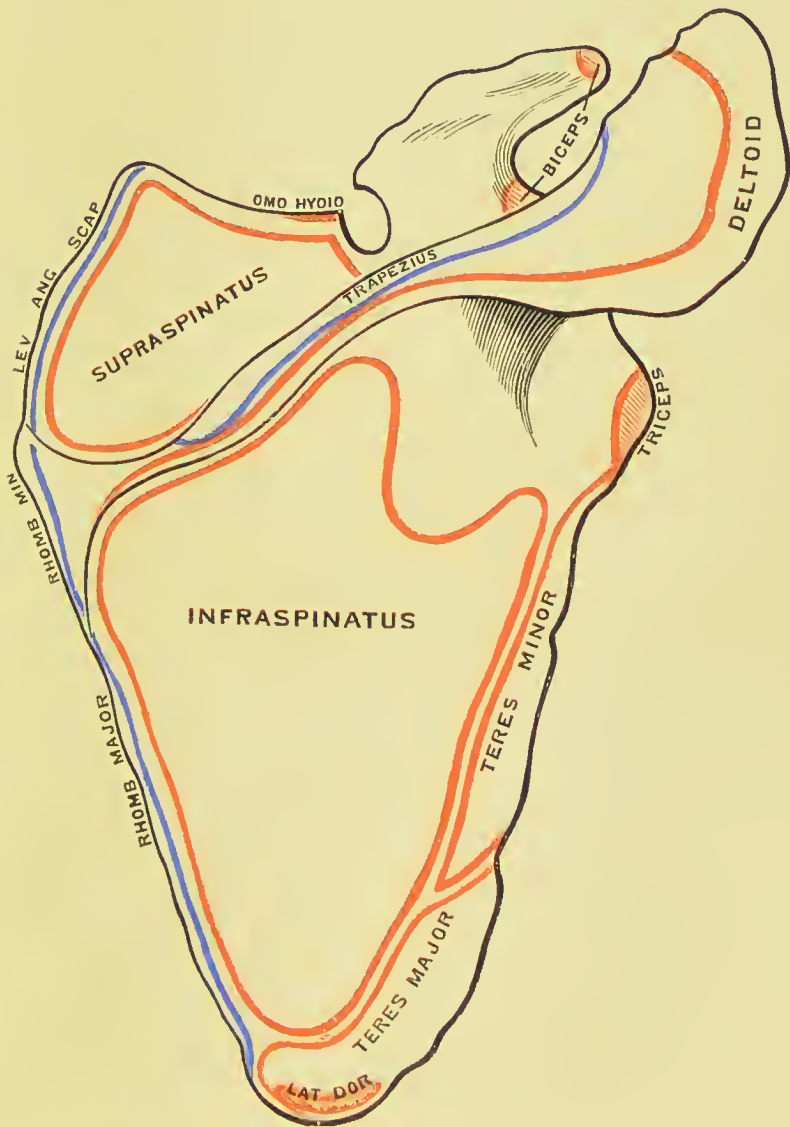

THE UPPER EXTREMITY.

The upper extremity is formed by the clavicle, scapula, humerus, radius, ulna, carpus, metacarpus and phalanges. The clavicle and scapula form the *shoulder-girdle*.

CLAVICLE.

The clavicle (*clavis*, a key), or collar-bone, is a long bone, shaped like the italic letter *f*, and extended across the upper part of the side of the chest from the upper piece of the sternum to the point of the shoulder, where it articulates with the scapula. The curves are so disposed that at the sternal end the convexity, and at the scapular the concavity, is directed forwards. The sternal half of the bone is rounded, and terminates in a broad facet for articulation with the sternum ; this facet is continued for a short distance on to the under surface, where it articulates with the cartilage of the first rib. The

PLATE 7.



scapular half is flattened from above downwards, and broad at its extremity, the articular surface for the acromion occupying only part of its extent. The upper surface is smooth, convex, and partly subcutaneous; the under surface rough at its outer part, and excavated into a smooth groove in the middle, where it lodges the subclavius muscle. At the sternal extremity of the under surface is a very rough prominence, which gives attachment to the rhomboid ligament; and at the other extremity a rough tubercle near the posterior border, for the conoid ligament, and a ridge, running

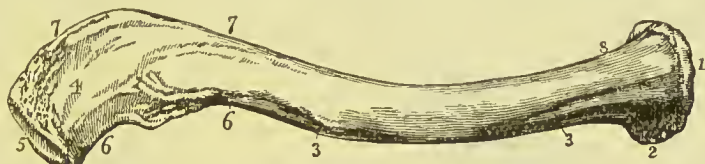

FIG. 126.—Clavicle of the right side; its upper and anterior face. 1. The sternal end. 2. The portion which articulates with the first rib. 3, 3. Ridge of attachment of the pectoralis major. 4. Acromial end. 5. Surface of articulation with the acromion. 6, 6. Ridge for the attachment of the deltoid. 7, 7. Line of insertion of the trapezius. 8. Line of origin of the sterno-mastoid.

forwards and outwards from this, for the trapezoid ligament, both parts of the coraco-clavicular ligament. The opening for the nutrient vessels is seen at the under surface of the bone.

Development.—By *two* centres; one for the shaft and one for the sternal extremity; the former appearing (in membrane) before any other bone of the skeleton, the latter between eighteen and twenty. The epiphysis joins the shaft about the twenty-fifth year.

Articulations.—With the sternum, scapula, and cartilage of the first rib.

Attachment of Muscles.—To *seven*; sterno-cleido-mastoid, trapezius, pectoralis major, deltoid, subclavius, sterno-hyoid and platysma myoides.

SCAPULA.

The scapula (*σκαπάνη*, a *spade*) is a flat triangular bone, situated on the posterior aspect and side of the thorax, and occupying the space from the second to the seventh rib. It is divisible into an anterior and posterior surface; superior, inferior, and posterior border; anterior, superior, and inferior angle; and processes.

The **anterior surface**, or *venter*, is concave and uneven, forming the *subscapular fossa*, and is marked by several oblique ridges which have a direction upwards and outwards. It is occupied by the subscapularis muscle, with the exception of the posterior border, a triangular surface near the superior angle, and similar area near the inferior angle, these parts giving attachment to the serratus magnus. The **posterior surface**, or *dorsum*, is convex, and unequally divided into two portions by the spine: that portion above the spine is the supra-spinous fossa; and that below, the infra-spinous fossa.

The **superior border** is the shortest of the three; it is thin and concave, terminated at one extremity by the superior angle, and at the other by the coracoid process. At the base of the coracoid process is the *supra-scapular* or *coraco-scapular* notch (converted into a foramen by a ligament), for the transmission of the supra-scapular nerve.

The **inferior or axillary border** is thick, and marked by several grooves and depressions; it terminates superiorly at the glenoid cavity, and inferiorly at the inferior angle. Immediately below the glenoid cavity is a rough ridge, which gives origin to the long head of the triceps muscle. In the middle of this border is a depression

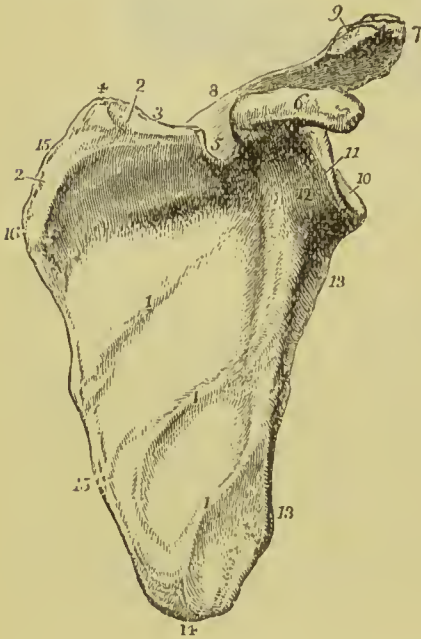


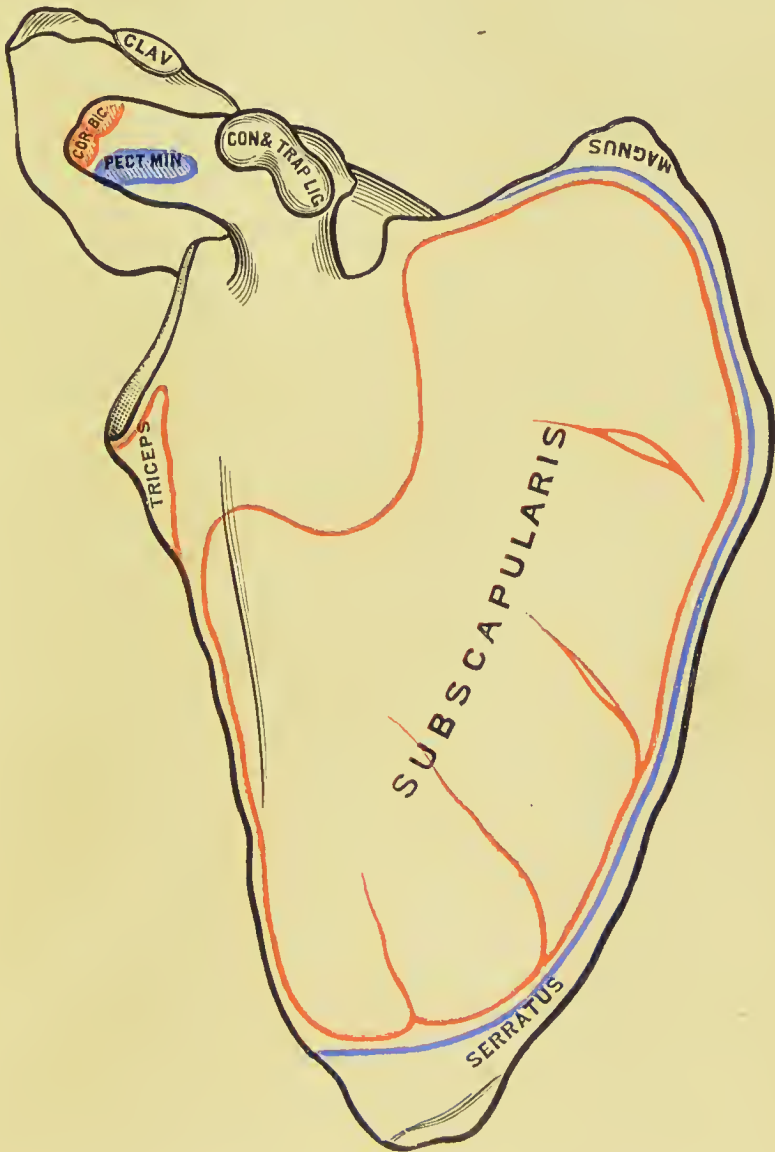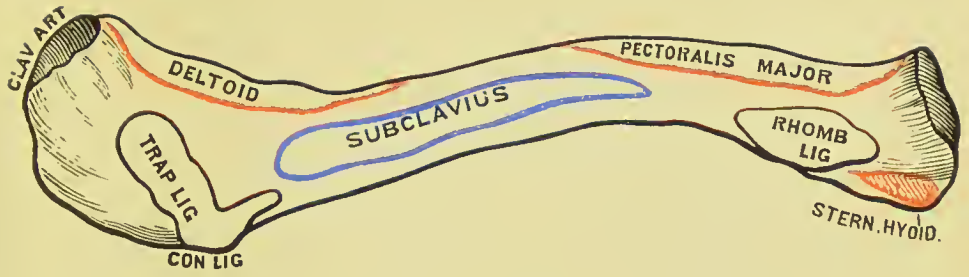
FIG. 127.—Anterior surface or venter of the scapula. 1, 1, 1. Oblique ridges crossing the subscapular fossa. 2, 2. Upper part of the surface occupied by the serratus magnus muscle. 3. Superior border. 4. Superior angle. 5. Supra-scapular notch. 6. Coracoid process. 7. Acromion process. 8. Spine of the scapula; the figure 5, while indicating the supra-scapular notch, is placed on the spine. 9. Articular surface of the acromio-clavicular joint. 10. Glenoid cavity. 11. Head of the scapula. 12. Its neck. 13, 13. Axillary border; the upper 13 is placed against the ridge for the triceps. 14. Inferior angle. 15, 15. Posterior border. 16. Prominence corresponding with the origin of the spine of the scapula.

for the *teres minor*, and beneath this a deeper groove for the *teres major*; near the inferior angle is a projecting lip, which increases the surface of origin of the latter muscle.

The **posterior border or base**, the longest of the three, is turned towards the vertebral column. It is intermediate in thickness between the superior and inferior, and convex. Attached to it are three muscles, the *levator anguli scapulae* extending from the upper edge of the triangular area at the root of the spine to the superior angle, the *rhomboideus minor* corresponding in its attachment to the triangular area, and the *rhomboideus major* attached to the rest of the border.

The **anterior angle** is the thickest part of the bone, and forms the *head* of the scapula; it is immediately surrounded by a constricted portion, the *neck*. The head presents a shallow pyriform articular surface, the *glenoid cavity*, having the pointed extremity upwards; and at its apex is a rough depression, which gives attach-

PLATE 8.



ment to the long tendon of the biceps. At the anterior and upper part of the glenoid cavity a rudimentary notch is observed in its margin; this is interesting as corresponding to the notch at the inner side of the acetabulum. The **superior angle** is thin and pointed. The **inferior angle** is thick, and smooth upon the posterior surface for the origin of the *teres major*, and for a large bursa over which the upper border of the *latissimus dorsi* muscle plays; it also occasionally gives origin to a few fibres of the latter muscle.

The **spine** of the scapula, triangular in form, crosses the upper part of the dorsum of the bone; it commences at the posterior border by a smooth triangular surface over which the fan-shaped tendon of the *trapezius* glides, and terminates at the point of the shoulder in the *acromion* process. At a short distance from its origin, where the triangular surface rises to the level of the spine, is a prominent tubercle, which marks the termination of the line of attachment of the tendon of the *trapezius*. The anterior border of the spine is smooth and concave, it arises near the neck of the scapula, and is continued into the under surface of the *acromion*; it encloses a notch, the *great scapular notch*, between it and the glenoid cavity. The free border of the spine is rough and subcutaneous, and gives attachment, by two projecting lips, to the *trapezius* above and *deltoid* below; the surfaces of the spine enter into the formation of the *supra-* and *infra-spinous fossa*. The nutrient foramina of the scapula are situated in the base of the spine.

The **acromion**, somewhat triangular in form, is flattened from above downwards; it overhangs the glenoid cavity, the upper surface being rough and subcutaneous, the lower smooth. Near its extremity, on the anterior border, is an oval articular surface, for the end of the *clavicle*.

The **coracoid process** is a thick, round, and curved process of bone, arising from the upper part of the neck of the scapula, and

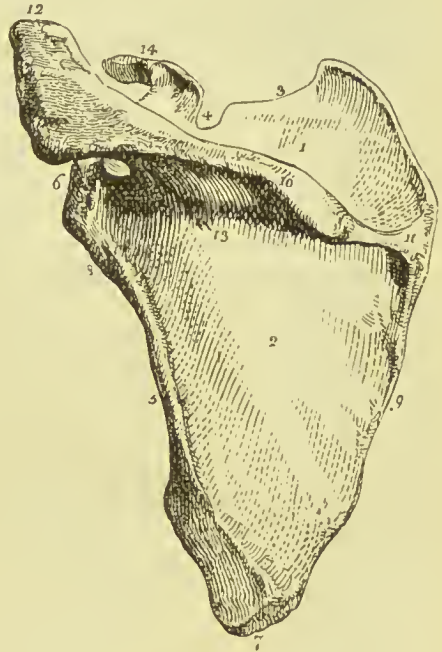


FIG. 128.—Posterior view of the scapula. 1. Supra-spinous fossa. 2. Infra-spinous fossa. 3. Superior border. 4. Supra-scapular notch. 5. Axillary border. 6. Head of the scapula and glenoid cavity. 7. Inferior angle. 8. Neck of the scapula; the ridge opposite the figure gives origin to the long head of the *triceps*. 9. Posterior border or base of the scapula. 10. The spine. 11. Triangular smooth surface, over which the tendon of the *trapezius* glides. 12. *Acromion* process. 13. One of the nutrient foramina. 14. *Coracoid* process.

overarching the glenoid cavity. It is about two inches in length, very strong, and gives attachment by its tip to the biceps and coraco-brachialis muscles, by its anterior border to the pectoralis minor, and by its posterior border to the coraco-acromial ligament. Near its base is a rough impression for the conoid ligament, and running forwards from this an oblique ridge for the trapezoid ligament.

Development.—By *seven* centres; one for the body (including the spine), two for the coracoid process, two for the acromion, one for the inferior angle, and one for the posterior border. The ossific centre for the body appears near the head about the seventh or eighth week, one for the coracoid process during the first year, and a second at the base of the same process in the tenth year; the acromion process at puberty; the inferior angle in the fifteenth year; and the posterior border at seventeen or eighteen. Union between the coracoid process and body takes place during the fifteenth year; the bone is not complete till after the twenty-second year.

Articulations.—With the clavicle and humerus.

Attachment of Muscles.—To *sixteen*; by its *anterior surface* to the subscapularis and serratus magnus; *posterior surface*, supra-spinatus and infra-spinatus; *superior border*, omo-hyoid; *posterior border*, levator anguli scapulæ, rhomboideus minor, rhomboideus major; *axillary border*, long head of the triceps, teres minor, teres major; *upper angle of the glenoid cavity*, long tendon of the biceps; *spine and acromion*, trapezius and deltoid; *coracoid process*, pectoralis minor, short head of the biceps, and coraco-brachialis. The ligaments attached to the coracoid process are, coraco-acromial, coraco-clavicular, coraco-humeral, and the costo-coracoid membrane.

HUMERUS.

The humerus is divisible into a shaft and two extremities.

The **upper extremity** presents a rounded *head*; a constriction immediately around the base of the head, the *anatomical neck*; a *greater* and a *lesser tuberosity*. The greater tuberosity is situated most externally, and is marked by three facets for the insertion of the supra-spinatus, infra-spinatus, and teres minor muscles. The lesser tuberosity, placed internally, gives attachment to the tendon of the subscapularis. The tuberosities are separated by a vertical furrow, the *bicipital groove*, which lodges the long tendon of the biceps, and a branch of the anterior circumflex artery. The edges of this groove below the head of the bone are prominent and rough, and called the *external* and *internal bicipital ridges*; the former serves for the insertion of the pectoralis major muscle, the latter for the tendon of the teres major; at the bottom of the groove the tendon of the latissimus dorsi is inserted.

The constriction of the bone below the tuberosities is the *surgical*

neck, and is so named, in contradistinction to the anatomical neck, from being the seat of the accident called by surgical writers *fracture of the neck of the humerus*.

The **shaft** of the bone is somewhat cylindrical at its upper part, and flattened from before backwards below. On the outer side, at about its middle, is a rough triangular eminence (*deltoid tuberosity*),

FIG. 129.



FIG. 129.—Humerus of the right arm; its anterior surface. 1. Shaft of the bone. 2. Head. 3. Anatomical neck. 4. Greater tuberosity. 5. Lesser tuberosity. 6. Bicipital groove. 7. External bicipital ridge. 8. Internal bicipital ridge. 9. Rough surface into which the deltoid is inserted. 10. Nutrient foramen. 11. Eminentia capitata. 12. Trochlea. 13. External epicondyle. 14. Internal epicondyle. 15. External supracondylar ridge. 16. Internal supracondylar ridge. 17. Fossa for the coronoid process of the ulna.

FIG. 130.



FIG. 130.—Humerus of the right arm; its posterior aspect. 1. Shaft. 2. Head. 3, 3. Anatomical neck. 4, 4. Surgical neck. 5. Great tuberosity. 6. Facets of insertion of the infra-spinatus and teres minor. 7. Groove for the musculo-spiral nerve. 8. Back of trochlear surface. 9. Internal epicondyle. 10. External epicondyle. 11. External supracondylar ridge. 12. Fossa for the reception of the olecranon.

which gives insertion to the deltoid ; and immediately on each side of this eminence is a smooth depression, corresponding with the origin of the brachialis anticus. On the inner side of the middle of the shaft is a smooth surface for the attachment of the coracobrachialis muscle ; and behind, an oblique and shallow groove (*musculo-spiral groove*), which lodges the musculo-spiral nerve and superior profunda artery. The foramen for the medullary vessels is situated on the inner surface of the shaft of the bone a little below the coraco-brachial impression ; it is directed downwards.

The **lower extremity** is flattened behind and convex in front ; it is terminated inferiorly by a long articular surface, divided into two parts by an elevated ridge. The external portion of the articular

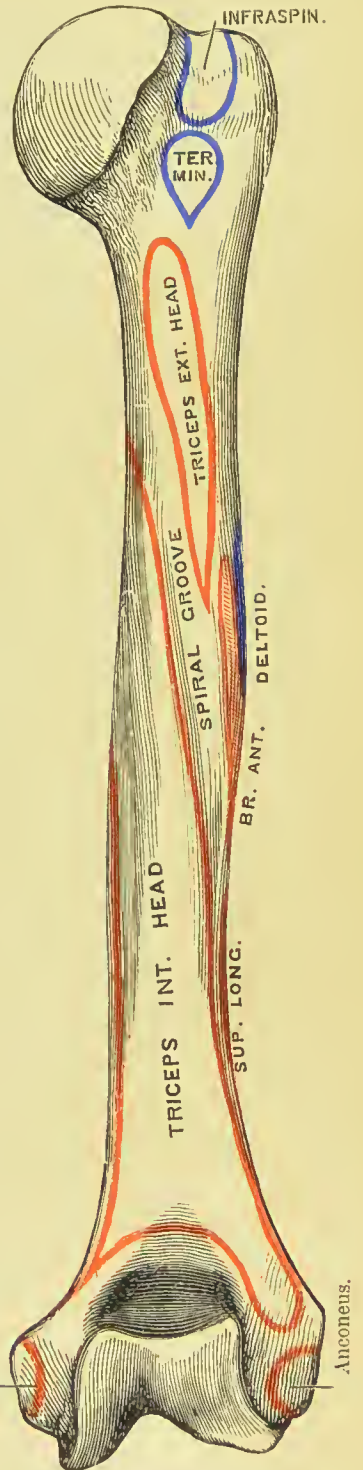
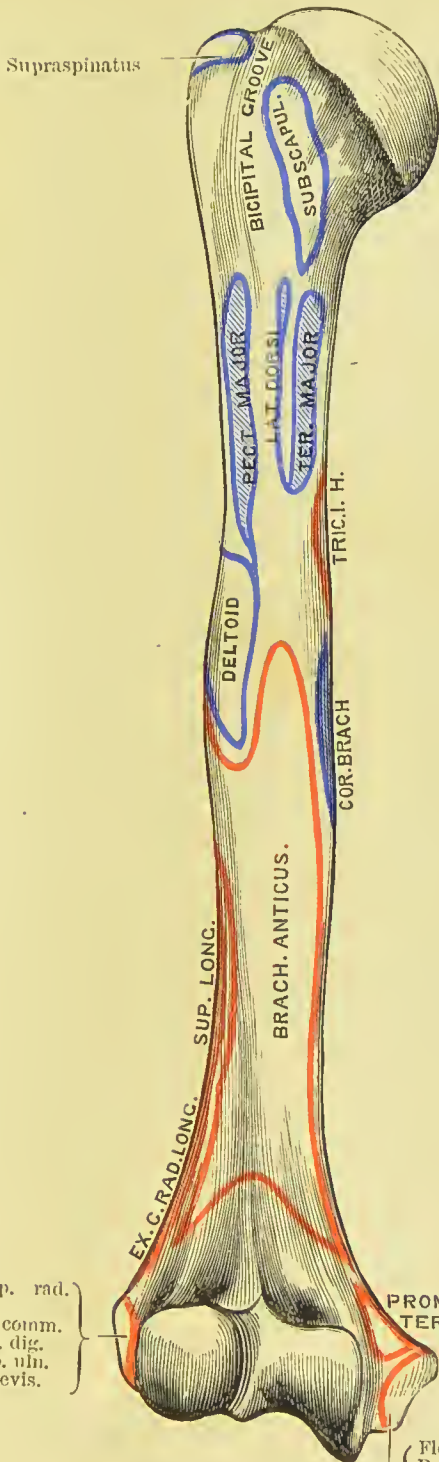
surface is a rounded protuberance, *capitellum* or *eminentia capitata*, which articulates with the cup-shaped depression on the head of the radius; the internal portion is a concave and pulley-like surface, *trochlea*, for articulation with the ulna. It will be noticed that the capitellum is limited to the anterior and lower aspect of the bone, and is not seen from behind, while the trochlear surface is even more marked behind than in front; the latter is bounded on its inner side by a salient ridge. Projecting beyond the articular surface at each side are the *external* and *internal epicondyle*, the latter being considerably the longer; and running upwards from the epicondyles along the borders of the bone are the supracondylar ridges, of which the external is the most prominent. Immediately in front of the trochlea is a small depression for receiving the coronoid process of the ulna during flexion of the fore-arm (*coronoid fossa*); and immediately behind it a large and deep fossa, for containing the olecranon process during extension (*olecranon fossa*); above the trochlea is a small pit (*radial fossa*), which receives the anterior part of the head of the radius in complete flexion. The average length of the humerus is, in the male thirteen inches, and in the female twelve inches.

Development.—By *seven* centres; one for the shaft, one for the head, one for the tuberosities, one for the eminentia capitata, one for the trochlea, and one for each epicondyle, the internal preceding the external. Ossification commences in the shaft of the humerus in the eighth week; in the head during the first year, and in the tuberosities during the third year; in the eminentia capitata and trochlea during the third and eleventh year; and in the epicondyles during the fifth and fifteenth. At the time of birth the shaft is ossified, but the extremities are cartilaginous; the centre for the head and that for the tuberosities unite during the fifth year. The entire bone is consolidated at twenty.

Articulations.—With the glenoid cavity of the scapula, the ulna, and radius.

Attachment of Muscles.—To *twenty-four*: by the *greater tuberosity*, supra-spinatus, infra-spinatus, and teres minor; *lesser tuberosity*, subscapularis; *external bicipital ridge*, pectoralis major; *internal bicipital ridge and groove*, teres major and latissimus dorsi; *shaft*, external and internal head of the triceps, deltoid, coraco-brachialis, and brachialis anticus; *external supracondylar ridge and epicondyle* extensors and supinators of the fore-arm, viz., supinator longus, extensor carpi radialis longior, extensor carpi radialis brevior, extensor communis digitorum, extensor minimi digiti, extensor carpi ulnaris, anconens, and supinator brevis; *internal epicondyle* flexors and one pronator, viz., pronator radii teres, flexor carpi radialis, palmaris longus, flexor sublimis digitorum, and flexor carpi ulnaris.

PLATE 9.





ULNA.

The ulna is divisible into a shaft and two extremities. The upper extremity is large, and forms principally the articulation of the elbow; the lower extremity is small, and is excluded from the wrist-joint by an interarticular fibrocartilage.

The **upper extremity** presents a semilunar concavity of large size, the *greater sigmoid notch*, for articulation with the humerus; and on the outer side a *lesser sigmoid notch*, for the head of the radius. Bounding the greater sigmoid notch posteriorly is the *olecranon process*, and overhanging it in front, a pointed eminence with a rough triangular base, the *coronoid process*. The *olecranon process* (*ὀλένη*, elbow; *κράνον*, head) terminates in front by a sharp beak, which in full extension passes into the olecranon fossa on the humerus; behind this is a rough and prominent surface or tuberosity for the attachment of the triceps muscle; and on the posterior aspect of the process a smooth triangular area which is subcutaneous. The *coronoid process* has also a sharp beak in front, and below this a triangular, rough surface (*tuberosity of the ulna*) for the brachialis anticus, immediately to the inner side of which one head of the pronator radii teres is attached. Below the lesser sigmoid notch is a rough pit, which gives attachment to some fibres of the supinator brevis.

The **shaft** is prismoid in form, and presents three surfaces, anterior, posterior, and internal; and three borders. The *anterior surface* is occupied by the flexor profundus digitorum for the upper three-fourths of its extent; and below, by a depression for the pronator quadratus muscle. A little above its middle is the nutrient foramen, directed upwards. On the *posterior surface*, at the upper part of the bone, is the triangular uneven depression for the anconeus muscle, bounded inferiorly by an oblique ridge which runs downwards from the posterior extremity of the lesser sigmoid notch. Below the ridge, the surface is marked into several grooves for the attachment of the extensor ossis metacarpi pollicis, extensor secundi internodii pollicis, and extensor indicis muscles. The

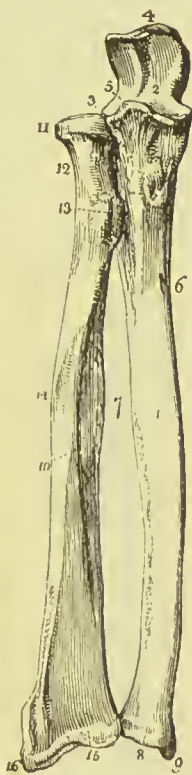

FIG. 131.—The two bones of the fore-arm seen from the front. 1. Shaft of the ulna. 2. Greater sigmoid notch. 3. Lesser sigmoid notch, with which the head of the radius is articulated. 4. Olecranon process. 5. Coronoid process. 6. Nutrient foramen. 7. The sharp ridges upon the two bones to which the interosseous membrane is attached. 8. Capitulum ulnæ. 9. Styloid process. 10. Shaft of the radius. 11. Its head surrounded by the smooth border for articulation with the orbicular ligament. 12. Neck of the radius. 13. Its tubercle. 14. The oblique line. 15. Lower extremity of the bone. 16. Styloid process.

internal surface is covered in for the greater part of its extent by the flexor profundus digitorum. The *anterior border* is rounded, and gives origin by its lower fourth to the pronator quadratus. The *posterior* is prominent, and affords attachment to the tendinous expansion common to the flexor carpi ulnaris, extensor carpi ulnaris, and flexor profundus digitorum; expanding at the upper extremity into the triangular subcutaneous surface of the olecranon. The *external or radial border* is sharp and prominent, for the attachment of the interosseous membrane.

The **lower extremity** terminates in a small rounded head, *capitulum ulnæ*, from the side of which projects the *styloid process*. The latter presents a deep notch at its base for the attachment of the apex of the triangular interarticular cartilage, and by its point gives attachment to the internal lateral ligament. On the posterior surface of the head is a groove, for the tendon of the extensor carpi ulnaris; and on the side opposite the styloid process a smooth surface, for articulation with the side of the radius.

Development.—By *three* centres; one for the shaft, one for the inferior extremity, and one for the tip of the olecranon. Ossification commences in the ulna during the eighth week; the ends of the

bone are cartilaginous at birth. The centre for the lower end appears at about the fifth, that for the tip of the olecranon about the tenth, year. The upper epiphysis joins the shaft about the sixteenth year, and the lower epiphysis joins about the twentieth.

Articulations.—With *two* bones; humerus and radius; it is separated from the cuneiform bone of the carpus by the triangular interarticular cartilage.

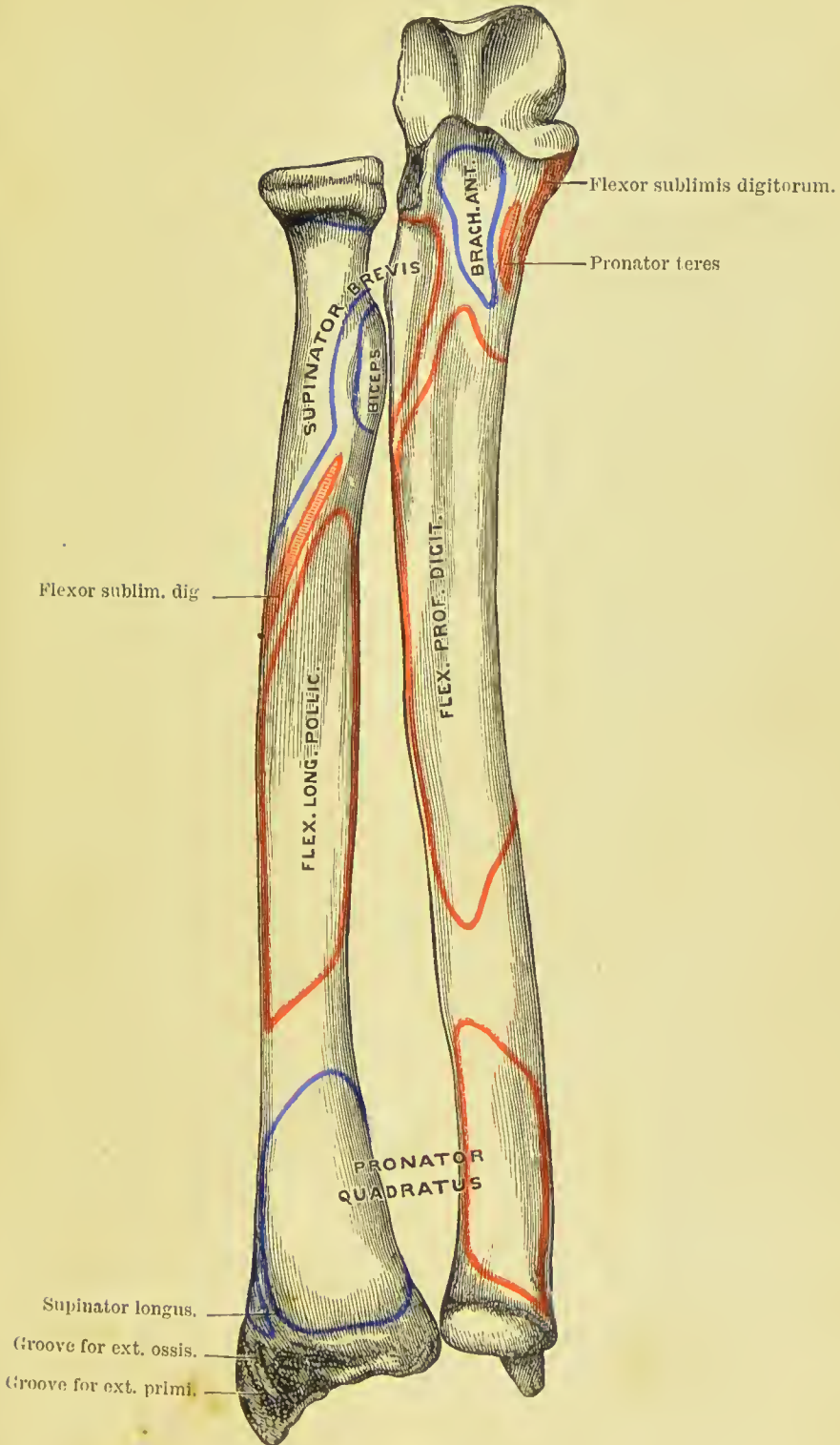
Attachment of Muscles.—To *thirteen*: by the *olecranon* to the triceps, one head of the flexor carpi ulnaris, and anconeus; by the *coronoid process*, brachialis anticus, pronator radii teres, flexor sublimis digitorum, and flexor profundus digitorum; by the *shaft*, flexor profundus digi-

FIG. 132.—Bones of the fore-arm, seen on their posterior aspect. 1. Shaft of the ulna. 2. Olecranon process. 3. Border of the great sigmoid notch. 4. Ridge on radius and ulna for the interosseous membrane. 5. Capitulum ulnæ. 6. Styloid process. 7. Shaft of the radius. 8. Its head. 9. Neck. 10. Tuberosity. 11. Lower extremity of the bone. 12. Ridge separating the tendons of the extensors in their passage to the dorsum of the hand. 13. Styloid process.



torum, flexor carpi ulnaris, pronator quadratus, supinator brevis, anconeus, extensor carpi ulnaris, extensor ossis metacarpi pollicis, extensor secundi internodii pollicis, and extensor indicis.

PLATE 10.



RADIUS.

The radius is the rotatory bone of the fore-arm ; it is divisible into a shaft and two extremities : unlike the ulna, its upper extremity is small, and merely accessory to the formation of the elbow-joint ; while the lower extremity is large, and forms almost solely the joint of the wrist.

The **upper extremity** presents a rounded *head*, depressed on its upper surface into a shallow cup for articulation with the capitellum of the humerus. Around the margin of the head is a smooth articular surface which is broad on the inner side, where it articulates with the lesser sigmoid notch of the ulna, and narrow in the rest of its circumference, to play in the orbicular ligament. Beneath the head is a constricted circular *neck* ; and beneath the neck, on its internal aspect, a prominent process, the *tuberosity*. The surface of the tuberosity is partly smooth and partly rough : rough behind, where it receives the attachment of the tendon of the biceps ; and smooth in front, where a bursa is interposed between the tendon and the bone.

The **shaft** of the bone is prismoid, and presents three surfaces. The *anterior surface* is somewhat concave superiorly, where it lodges the flexor longus pollicis ; and flat below, where it supports the pronator quadratus. At about the upper third of this surface is the nutrient foramen, which is directed upwards. The *posterior surface* is round above, where it supports the supinator brevis muscle, and marked below by several shallow oblique grooves, which afford attachment to the extensor muscles of the thumb. The *external surface* is round and convex, and marked in its middle by a rough impression for the insertion of the pronator radii teres ; it is separated from the anterior surface below by a rounded border, and above by a distinct ridge which runs forwards on to the anterior surface of the bone, and terminates in the lower part of the tuberosity ; this is called the *oblique ridge*, and gives attachment to the flexor sublimis digitorum. On the *inner margin* is a sharp and prominent crest, which gives attachment to the interosseous membrane.

The **lower extremity** of the radius is broad and triangular, and provided with two articular surfaces ; one at the side of the bone, which is concave to receive the rounded head of the ulna ; the other at the extremity, and marked by a slight ridge into two facets, one external and triangular, corresponding with the scaphoid ; the other square, with the semilunar bone. At the outer side of the extremity is a strong conical projection, the *styloid process*, which gives attachment by its base to the tendon of the supinator longus, and by its apex to the external lateral ligament of the wrist-joint. The inner edge of the terminal articular surface affords attachment to the base of the triangular interarticular fibro-cartilage of the wrist-joint.

Immediately in front of the styloid process is a groove, which lodges the tendons of the extensor ossis metacarpi pollicis and ex-

tensor primi internodii ; and, behind the process, a broader groove, frequently divided by a slight ridge, for the tendons of the extensor carpi radialis longior and brevior ; behind this is a prominent ridge,

and a deep narrow groove, for the tendon of the extensor secundi internodii pollicis ; and internal to this, another broad groove for the tendons of the extensor communis digitorum, and extensor indicis : the extensor minimi digiti running in a groove at the point of articulation of the radius and ulna.

Development.—By *three* centres ; one for the shaft, and one for each extremity. Ossification commences in the shaft soon after the humerus, and before the ulna. The inferior centre appears during the second year, the superior about the fifth. The upper epiphysis unites about puberty, the lower about the age of twenty.

Articulations.—With *four* bones : humerus, ulna, scaphoid, and semilunar.

Attachment of Muscles.—To *nine* : by the *tuberosity* to the biceps ; by the *oblique ridge*, supinator brevis, flexor sublimis digitorum ; by the *anterior surface*, flexor longus pollicis and pronator quadratus ; by the *external surface*, pronator radii teres ; by the *posterior surface*, extensor ossis metacarpi pollicis and extensor primi internodii ; and by the *styloid process*, supinator longus.



FIG. 133.—Grooves at the back of the radius and ulna. 1. Radius. 2. Ulna. 3. Groove for extensor ossis metacarpi and extensor primi internodii pollicis. 4. Groove for extensor carpi radialis longior. 5. For extensor carpi radialis brevior. 6. For extensor secundi internodii pollicis. 7. For extensor communis digitorum and extensor indicis. 8. For extensor minimi digiti. 9. For extensor carpi ulnaris.

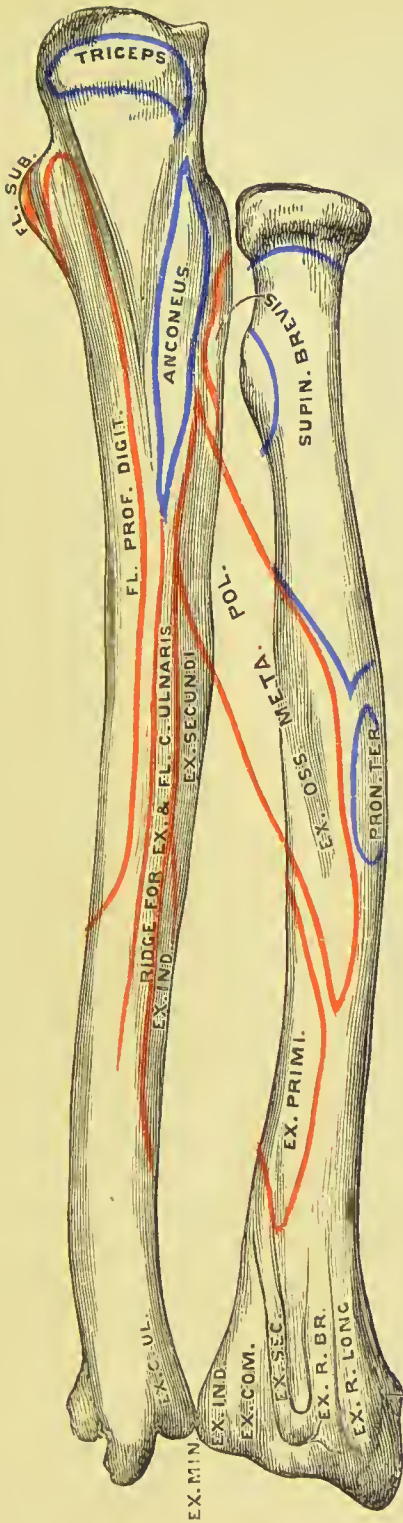
by the *external surface*, pronator radii teres ; by the *posterior surface*, extensor ossis metacarpi pollicis and extensor primi internodii ; and by the *styloid process*, supinator longus.

CARPUS.

The bones of the carpus are eight in number, arranged in two rows, consisting of four bones each : those of the proximal row, enumerating from the radial side, are the scaphoid, semilunar, cuneiform, and pisiform ; those of the distal row, in the same order, are the trapezium, trapezoid, os magnum, and unciform.

With the exception of the semilunar, they all have the dorsal surface broad and convex, and the palmar contracted ; the semilunar differs from the rest, in that its dorsal surface is narrow and flattened

PLATE 11.



Groove for ext. ossis, meta-
 poll., and ext. prim. inter-
 nod. poll.



and its palmar surface broad and convex. The proximal articulating surface is usually convex, and the distal concave.

SCAPHOID.—This bone is named from bearing some slight resemblance to the shape of a boat, being broad at one end, and narrowed like a prow at the opposite; concave on one side, and convex on the other. If carefully examined, it will be found to present *proximally* a large convex articular surface, which fits into the outer part of the cupped extremity of the radius; *distally* it is bluntly pointed, and has two smooth surfaces, divided by a slight ridge, for articulation, the outer with the trapezium, and the inner with the trapezoid. Its *internal* (ulnar) surface is concave, and presents two articular facets, one shallow and crescentic for the semilunar, the other circular and deeply excavated for receiving the head of the os magnum. The proximal portion of the *palmar* surface is depressed and concave; the distal portion is raised above the level of the rest of the bone, forming a marked prominence called the *tubercle*, to which the anterior annular ligament is attached. The *dorsal* surface is convex from side to side, contracted from above downwards, and grooved for the attachment of ligaments. The *external* surface is narrow, non-articular, and rough for the attachment of fibres of the external lateral ligament.

Recognition.*—To ascertain the hand to which the bone belongs:—hold it with the tubercle upwards, and the smooth, convex, proximal surface directed backwards; the narrow, non-articular, external surface will point to the hand to which the bone belongs.

Articulations.—With *five* bones: radius, semilunar, trapezium, trapezoid, and os magnum.

Attachment of Muscles.—No muscles are attached directly to this bone.

SEMILUNAR.—This bone may be known by its crescentic figure. The *dorsal* surface is narrow and flat, the *palmar* broad and rounded. The other surfaces are all articular; they are as follows:—

The *proximal*, large and convex, occupies the second depression on the inferior articulating surface of the radius; the *distal*, concave, articulates with the head of the os magnum; the *external*, crescentic, corresponds with a like surface on the scaphoid; and the *internal*, nearly circular, articulates with the cuneiform, and by a small bevelled edge with the unciform. Sometimes it articulates also with the unciform, in which case the last-named articulating surface is divided into two parts by a slight ridge.

Recognition.—If the bone be held with the broad palmar surface upwards, and the convex proximal articulating surface directed backwards, the crescentic articular facet will point to the appropriate hand.

* In referring each bone to its appropriate hand the same system is to be followed throughout the series; it consists in placing the bone in the position it occupies in the hand, namely, with the narrow palmar surface upwards, and the proximal surface (usually convex) looking backwards; the outer surface then points to the side to which the bone belongs.

Articulations.—With *five* bones: radius, scaphoid, os magnum, cuneiform, and unciform.

Attachment of Muscles.—No muscles are attached to this bone.

CUNEIFORM OR PYRAMIDAL.—This bone may be best distinguished by an oval isolated facet, which articulates with the pisiform bone. Its *palmar* surface is narrow and rough externally for the attachment of ligaments; internally it presents the characteristic facet for the pisiform just referred to. The *dorsal* surface is broad and rough for ligamentous attachment.

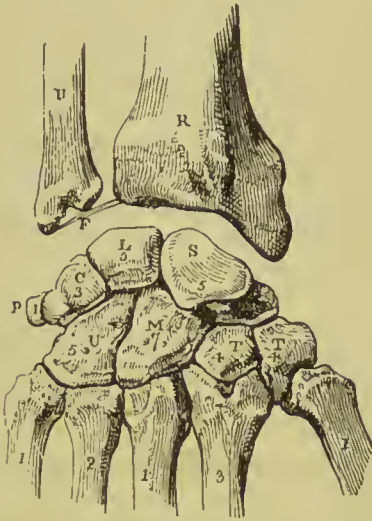


FIG. 134.—Diagram showing the dorsal surface of the bones of the carpus, with their articulations. The right hand:—R. Lower end of radius. U. Lower end of ulna. F. Interarticular fibrocartilage, attached to the styloid process of the ulna, and to the margin of the articular surface of the radius. S. Scaphoid bone. L. Semilunar. P. Pisiform. T. Trapezium. T. Trapezoid. M. Os magnum. U. Unciform. The figures both on the carpal and metacarpal bones refer to the number of bones with which they articulate.

The *distal* end of the cuneiform bone has a broad smooth surface for articulation with the unciform; the *proximal* surface is partly rough for the attachment of ligaments, and partly smooth for articulation with the triangular fibrocartilage. The *outer* side is marked by a circular facet corresponding to the one on the inner side of the semilunar; the *inner* surface is rough, and gives attachment to the internal lateral ligament of the wrist.

Recognition.—Hold the bone with the pisiform articular facet upwards, and the broad articular surface directed forwards; the

circular articular facet for the semilunar will point to the hand to which the bone belongs.

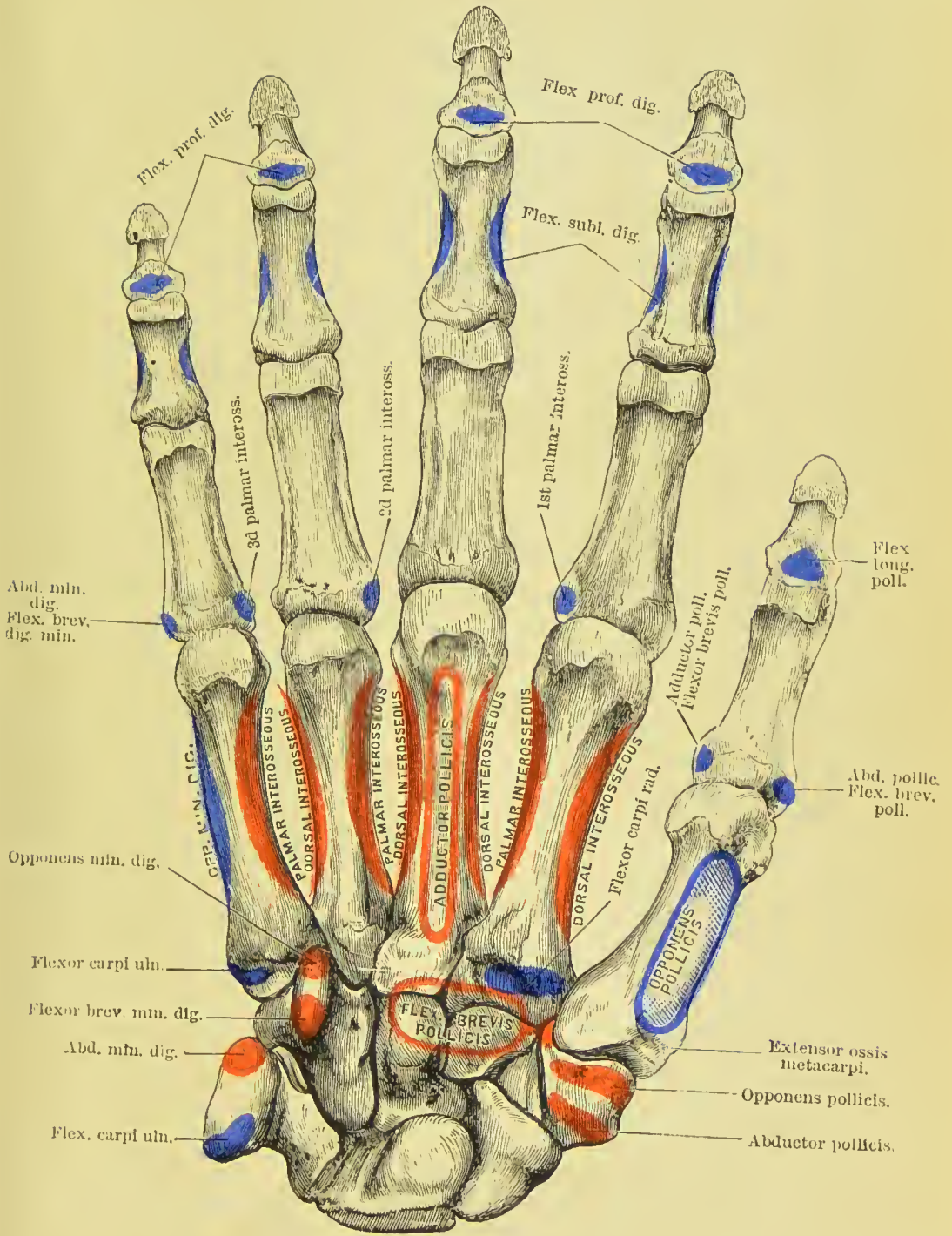
Articulations.—With three bones: semilunar, pisiform, and unciform; and with the triangular fibrocartilage of the wrist-joint.

Attachment of Muscles.—To none.

PISIFORM.—This bone may be recognised by its small size, and by the possession of only one articular facet. Examined carefully, it will be observed to present four sides and two extremities; one side is articular, the smooth facet approaching nearer to the proximal than to the distal extremity. The side opposite to this is rounded; the remaining sides are, one slightly concave, the other slightly convex.

Recognition.—If the bone be held with the articular surface directed downwards, and the overhanging portion pointing forwards,

PLATE 12.





the concave border will point to the hand to which the bone belongs.

Articulations.—With the cuneiform bone only.

Attachment of Muscles.—To two : flexor carpi ulnaris, and abductor minimi digiti ; and to the anterior annular ligament.

TRAPEZIUM.—This bone may be distinguished by a deep groove for the tendon of the flexor carpi radialis muscle, and by the saddle-shaped distal articular facet. Its *palmar* surface is marked by this groove, and by a prominent tubercle which overhangs it, which gives attachment to the abductor, flexor brevis, and flexor ossis metacarpi pollicis muscles, and to the anterior annular ligament. The *proximal* extremity of the trapezium has a facet for articulation with the scaphoid, and its *distal* extremity one of large size, concave from side to side, convex from above downwards, for articulation with the metacarpal bone of the thumb. *Internally* it presents two articular facets—the upper, large and concave, for the trapezoid ; the lower, small and flat, for the extremity of the second metacarpal bone.

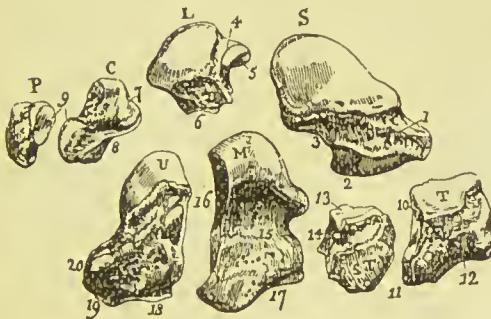


FIG. 135.—Bones of the carpus of the right hand, separated so as to show the form of the individual bones. s. Scaphoid: the letter is placed over the surface which articulates with the radius. 1. Its dorsal surface. 2. Surface to articulate with the trapezium and trapezoid, the two facets divided by a ridge. 3. Concave articulating surface for the head of the os magnum. L. Semilunar: the letter is placed over the surface which articulates with the radius. 4. Surface to articulate with the scaphoid. 5. Surface to art-

iculate with the head of the os magnum. 6. Border of the surface which articulates with the unciform. c. Cuneiform. 7. Surface to articulate with the semilunar. 8. Surface to articulate with the unciform. P. Pisiform. 9. Articular facet. T. Trapezium: the letter is placed on the surface which articulates with the scaphoid. 10. Surface to articulate with the trapezoid. 11. Articulating surface for the metacarpal bone of the thumb. 12. Articulating surface for the metacarpal bone of the thumb. 13. Articulating surface for the scaphoid. 14. Articulating surface for the os magnum. M. Os magnum: the letter is placed on the head of the bone. 15. Rough surface of the dorsum of the bone. 16. Articulating surface for the unciform. 17. Articulating surface for the metacarpal bone of the middle finger. U. Unciform: the letter is placed on the surface which articulates with the semilunar and cuneiform. 18. Articulating surface for the ring finger. 19. Articulating surface for the little finger. 20. Rough point forming part of the free border of the carpus.

Its *dorsal* and *external* surfaces are rough for ligamentous attachments.

Recognition.—If the bone be held with the grooved surface upwards, and the surface with two facets forwards, the saddle-shaped surface will point to the hand to which the bone belongs.

Articulations.—With *four* bones : scaphoid, trapezoid, and two first metacarpals.

Attachment of Muscles.—To three : abductor pollicis, flexor brevis pollicis, and flexor ossis metacarpi pollicis.

TRAPEZOID.—This bone is small, oblong, quadrilateral, and bent near its middle. Its *dorsal* surface is wide and convex, its *palmar* very narrow and flattened. It has four articular surfaces separated by slight ridges; the proximal of these is quadrilateral, and articulates with the scaphoid; the *distal* one is saddle-shaped for the second metacarpal bone; the *internal* surface is smooth and concave for the os magnum, and the *external* is convex for the trapezium.

Recognition.—Hold the bone with the narrow free surface upwards, and the saddle-shaped surface looking forwards; the convex articular surface will point to the appropriate hand.

Articulations.—With *four* bones: trapezium, os magnum, scaphoid, and second metacarpal.

Attachment of Muscles.—Part of the flexor brevis pollicis.

OS MAGNUM.—This is the largest bone of the carpus; it is

divisible into a head or *proximal*, and a body or *distal* extremity. The rounded head articulates by its proximal and external surfaces with the semilunar and scaphoid bones. Its *palmar* and *dorsal* surfaces are both rough; the latter being square and flat, the former rounded and prominent. Its *distal* extremity is divided into three small facets for articulation with the second, third, and fourth metacarpal bones; its *internal* surface is rough distally for an interosseous ligament, smooth proximally for articulation with the unciform. By its *external* surface it articulates by means of a small facet with the trapezoid, and proximal to this facet is a rough space for another interosseous ligament. The proximal articular surface enroaches on the external surface but not on the internal, so that the former is easily identified by this peculiarity.

Recognition.—If the bone be held with the flat and rough dorsal surface downwards, and the head directed backwards, the side of the head on to which the proximal articular facet is continued will point to the appropriate hand.

Articulations.—With *seven* bones: scaphoid, semilunar, trapezoid, unciform, and the second, third, and fourth metacarpal bones.

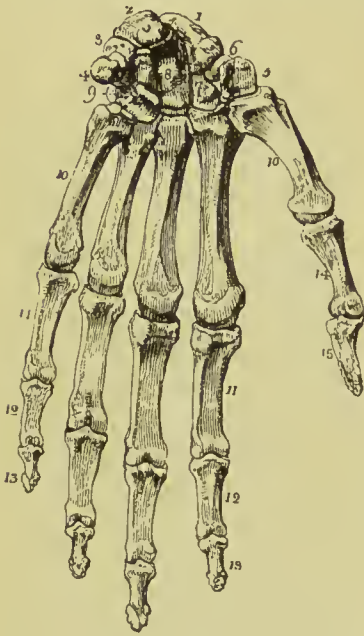
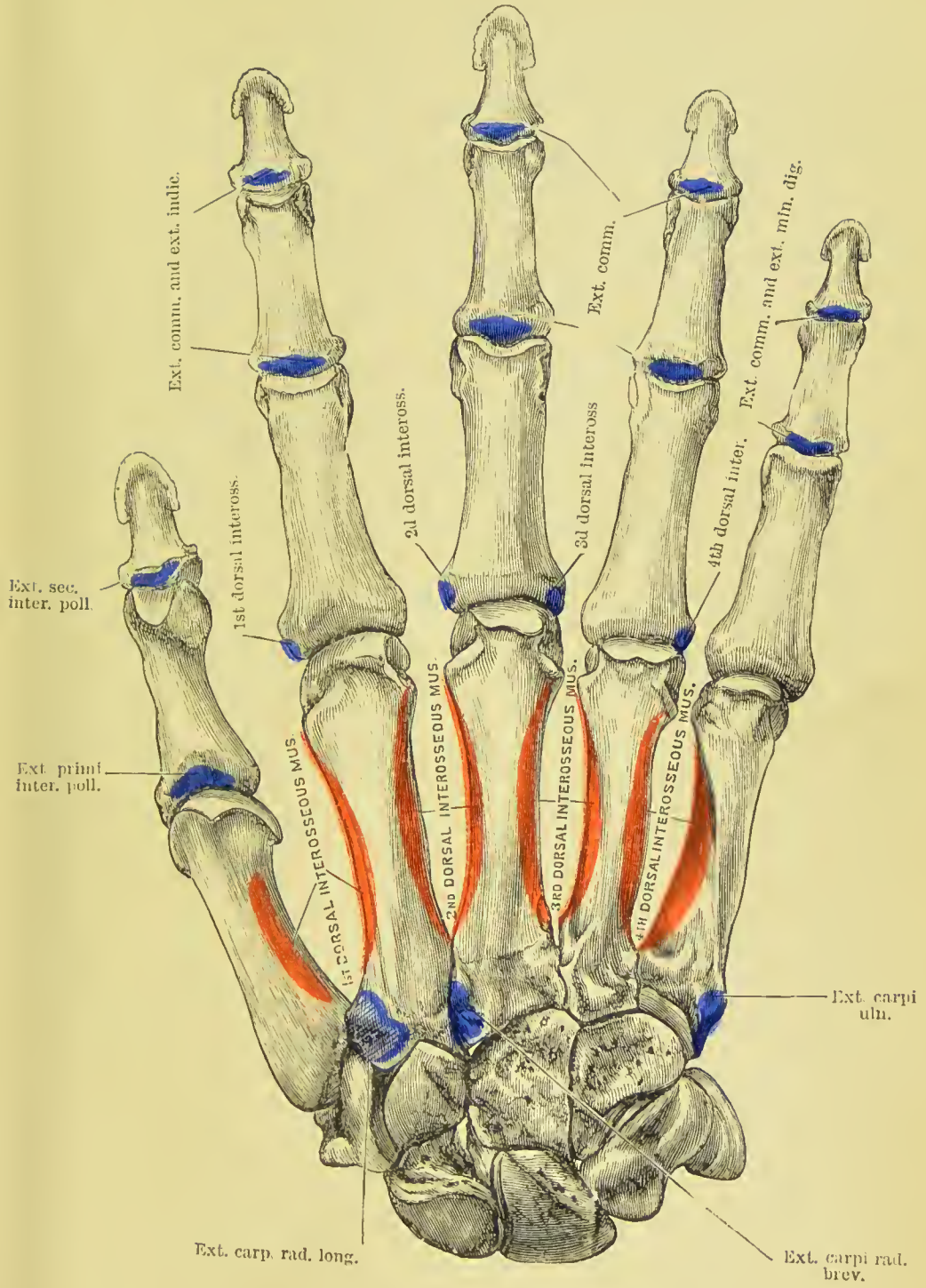


FIG. 136.—Left hand viewed on its anterior or palmar aspect. 1. Scaphoid bone. 2. Semilunar. 3. Cuneiform. 4. Pisiform. 5. Trapezium. 6. Groove in the trapezium which lodges the tendon of the flexor carpi radialis. 7. Trapezoid. 8. Os magnum. 9. Unciform. 10, 10. The five metacarpal bones. 11, 11. First row of phalanges. 12, 12. Second row. 13, 13. Third row, or unequal phalanges. 14. First phalanx of the thumb. 15. Second and last phalanx of the thumb.

form, and the second, third, and fourth metacarpal bones.

PLATE 13.





Attachment of Muscles.—Part of the flexor brevis pollicis.

UNCIFORM.—This is a triangular-shaped bone, remarkable for a long and curved process, which projects from its palmar aspect. The *palmar* surface is free, and is distinguished by the hooked process just mentioned; the *dorsal* surface is broad and rough. Its *distal extremity* presents a double articular surface for the fourth and fifth metacarpal bones; its *proximal* extremity is convex for articulation with the semilunar; *externally* it has two facets, with an intervening rough space, these being for articulation with the os magnum; and *internally* it has an oblong smooth facet for the cuneiform, and below this a rough edge for attachment of ligaments.

Recognition.—If the bone be held with the uncinatè process upwards, and the double facet forwards, the two small articular surfaces, with the intervening rough portion, will point to the appropriate hand.

Articulation.—With *five* bones: semilunar, os magnum, cuneiform, and fourth and fifth metacarpals.

Attachment of Muscles.—To *two*: flexor ossis metacarpi minimi digiti and flexor brevis minimi digiti; and to the anterior annular ligament.

Development of the Carpus.—The bones of the carpus are each developed by a single centre; they are cartilaginous at birth. Ossification commences towards the end of the first year in the os magnum and unciform; at the end of the third year, in the cuneiform; during the fifth year, in the trapezium and semilunar; during the sixth, in the scaphoid; eighth, in the trapezoid; and twelfth, in the pisiform. The latter bone is the last in the skeleton to ossify; it is, in reality, a sesamoid bone of the tendon of the flexor carpi ulnaris.

The number of articulations which each bone of the carpus maintains with surrounding bones may be expressed in figures, which will facilitate the student's recollection; the cipher for the first row is 5531, and for the second 4475.

METACARPUS.

The bones of the metacarpus are five in number. They are long bones, divisible into a head, shaft, and base.

The *head* is rounded at the distal extremity, forming an articular surface which extends farther on the front than on the back of the bone; each lateral aspect presents a small tubercle with a pit below it for the attachment of the lateral ligaments of the metacarpo-phalangeal joint. The *shaft* is prismoid; its posterior surface, upon which the extensor tendon lies, is flat; its anterior surface presents a ridge dividing two sloping surfaces for the attachment of the interossei muscles. The *base* is irregularly quadrilateral, and rough for the insertion of tendons and ligaments; it presents three articular surfaces: one at each side for adjoining metacarpal bones, and one at the extremity for the carpus.

The *metacarpal bone of the thumb* is one-third shorter than the rest, flattened and broad on its dorsal aspect, and convex on its palmar side ; the articular surface of the head is not so round as that of the other metacarpal bones ; and the base has a single proximal saddle-shaped surface, to articulate with the corresponding surface of the trapezium. It has no lateral facets.

The metacarpal bones of the different fingers may be distinguished by certain special characters. The base of the *metacarpal bone of the index finger* is the largest of the four, and presents three articular facets at its proximal extremity for the trapezium, trapezoid, and os magnum, and one on its ulnar side for the third metacarpal. It may most readily be identified by its proximal articular surface being divided into two, so as to present a notched appearance. That of the *middle finger* may be distinguished by a rounded projecting process at the radial side of its base (*styloid process*) for the attachment of the tendon of the extensor carpi radialis brevis, and two small circular facets on its ulnar lateral surface. The base of the *metacarpal bone of the ring finger* is small and square, and has two small circular facets on the radial side to correspond with those of the middle metacarpal, and one on the ulnar side for the metacarpal of the little finger. The *metacarpal bone of the little finger* has only one lateral articular surface, namely, on the radial side.

Development.—By *two* centres ; one for the shaft, and one for the digital extremity, with the exception of the metacarpal bone of the thumb, the epiphysis of which, like that of the phalanges, occupies the carpal end of the bone. Ossification of the metacarpal bones commences in the embryo during the eighth or ninth week, that is, soon after the bones of the fore-arm. The epiphyses make their appearance at the end of the second or early in the third year, and the bones are completed at twenty.

Articulations.—The *first* with the trapezium ; *second*, trapezium, trapezoid, os magnum, and middle metacarpal ; *third* or middle, os magnum, and adjoining metacarpal bones ; *fourth*, os magnum, unciform, and adjoining metacarpal bones ; *fifth*, unciform, and metacarpal bone of the ring finger. Each bone also articulates with its appropriate proximal phalanx.

Attachment of Muscles.—To the metacarpal bone of the thumb, *three*, flexor ossis metacarpi, extensor ossis metacarpi, and first dorsal interosseous ; index finger, *six*, extensor carpi radialis longior, flexor brevis pollicis, flexor carpi radialis, first and second dorsal and first palmar interosseous ; middle finger, *six*, extensor carpi radialis brevis, flexor brevis pollicis, flexor carpi radialis, adductor pollicis, second and third dorsal interosseous ; ring finger, *three*, third and fourth dorsal interosseous, and second palmar ; little finger, *four*, extensor carpi ulnaris, flexor ossis metacarpi minimi digiti, fourth dorsal and third palmar interosseous.

PHALANGES.

The phalanges (*internodia*) are the bones of the fingers ; they are named from their arrangement in rows, and are fourteen in number, three to each finger, and two to the thumb. In each finger the proximal phalanx is the longest, and the distal phalanx the shortest. In conformation they are long bones, divisible into a shaft and two extremities.

The *shaft* is compressed from before backwards, convex on its posterior surface, and flat with raised edges in front. The metacarpal extremity or *base* in the first row is a simple concave articular surface ; that in the other two rows a double concavity, separated by a slight ridge. The *digital extremities* of the first and second row present a pulley-like surface, concave in the middle, and convex at each side. The unguis extremity of the last phalanx is broad, rough, and expanded into a semilunar crest.

Development.—By *two* centres ; one for the shaft, and one for the base. Ossification commences (during the eighth week) in the third or unguis phalanges, then in the first, and lastly in the second. The epiphyses of the first row appear during the third or fourth year, those of the second row during the fourth or fifth, and of the last during the sixth or seventh. The phalanges are perfected by the twentieth year.

Articulations.—The first row, with the metacarpal bones and second row of phalanges ; the second row, with the first and third ; the third, with the second row.

Attachment of Muscles.—To the base of the *first phalanx* of the thumb *four* muscles, abductor pollicis, flexor brevis pollicis, adductor pollicis, and extensor primi internodii ; to the *second phalanx*, *two*, flexor longus pollicis, and extensor secundi internodii. To the *first phalanx* of the second, third, and fourth fingers, one dorsal and one palmar interosseous ; to that of the little finger, abductor minimi digiti, flexor brevis minimi digiti, and one palmar interosseous. To the *second phalanges*, flexor sublimis and extensor communis digitorum ; to the *last phalanges*, flexor profundus and extensor communis digitorum.

PELVIS AND LOWER EXTREMITY.

The bones of the pelvis are the two ossa innominata, the sacrum, and the coccyx, forming the *pelvic girdle* ; and those of the lower extremity, the femur, patella, tibia and fibula, tarsus, metatarsus, and phalanges.

OS INNOMINATUM.

The os innominatum (*os coxæ*) is an irregular, flat bone, consisting in the young subject of three parts, which meet at the acetabulum. Hence it is described in the adult as divisible into three portions,

ilium, ischium, and pubes. The *ilium* is the superior, broad, and expanded portion which forms the prominence of the hip, and articulates with the sacrum. The *ischium* is the inferior and strong part of the bone on which the body rests in sitting. The *pubes* is that portion which forms the front of the pelvis, and gives support to the external organs of generation.

The **ILIUM** may be described as divisible into an internal and external surface, a crest, and an anterior and posterior border.

The **internal surface** is bounded above by the crest, below by a prominent line, the *pectineal line*, and before and behind by the anterior and posterior border. It is concave and smooth for the anterior two-thirds of its extent, and lodges the iliacus muscle. The posterior third is rough, for articulation with the sacrum, and divided by a deep groove into two parts; an anterior or *auricular*

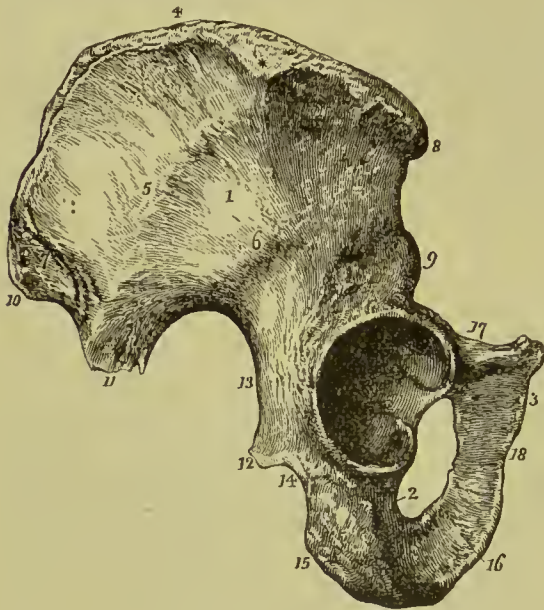


FIG. 137.—Os innominatum of the right side. 1. Ilium; its external surface. 2. Ischium. 3. Pubes. 4. Crest of the ilium. The * is situated upon the widest portion of the crest of the ilium. 5. Middle curved line. 6. Inferior curved line. 7. Surface for the gluteus maximus, and superior curved line. 8. Anterior superior spinous process. 9. Anterior inferior spinous process. 10. Posterior superior spinous process. 11. Posterior inferior spinous process. 12. Spine of the ischium. 13. Great sacro-ischiatic notch. 14. Lesser sacro-ischiatic notch. 15. Tuberosity of the ischium, showing its three facets. 16. Ramus of the ischium. 17. Superior ramus of the pubes. 18. Inferior ramus of the pubes.

portion, shaped like the pinna of the ear, and coated by cartilage in the fresh bone; and a posterior portion, very rough and uneven, for the attachment of the posterior sacro-iliac ligaments.

The **external surface** (*dorsum of the ilium*) is uneven, partly convex, and partly concave: it is bounded above by the crest; below by a prominent arch, which forms the upper margin of the acetabulum; and, before and behind, by the anterior and posterior border. At the posterior part, a rough line marks off a triangular area which gives attachment to the gluteus maximus; the line is continued anteriorly into the outer lip of the crest, and is called the *superior* or *posterior curved line*. Near the middle of this surface is a second ridge which is called the *middle curved line*; it commences at about an inch and a half from the anterior extremity of the crest, and terminates in the upper part of the greater sacro-ischiatic notch.

Below this is a third ridge called the *inferior curved line*, commencing just above the anterior inferior spine, and terminating at the lower part of the greater sacro-ischiatic notch. The surface included between the superior and middle curved lines gives origin to the gluteus medius muscle; that between the middle and inferior curved lines, to the gluteus minimus; and the rough interval between the inferior curved line and the arch of the acetabulum, to one head of the rectus femoris.

The **crest** of the ilium is arched, and curved in direction like the italic letter *f*, being bent inwards at its anterior termination, and outwards at the posterior. It is broad for the attachment of three planes of muscle, which are connected with its external and internal border or lip, and with the intermediate space. On its outer lip, at about midway between the anterior superior spinous process and the summit of the crest, is a prominent tubercle, from which a strong ridge runs down to the acetabulum. This is the broadest part of the crest, and the descending ridge serves as a buttress in giving strength to the bone.

The **anterior border** is marked by two prominences, the *anterior superior spinous process*, which is the anterior termination of the crest, and the *anterior inferior spinous process*; the first of these and the space beneath it give attachment to Poupart's ligament and the sartorius muscle, the second to one head of the rectus. This border terminates inferiorly in the lip of the acetabulum. The **posterior border** also presents two prominences, the *posterior superior* and *posterior inferior spinous process*, separated by a notch; the former gives attachment to the oblique sacro-iliac ligament, the latter to the greater sacro-ischiatic ligament. Inferiorly this border is broad and arched, and forms the upper part of the great sacro-ischiatic notch.

The ISCHIUM is divisible into a thick and solid portion, the **body**, and a thin and ascending part, the **ramus**; it may be considered also, for convenience of description, as presenting an external and internal surface, and three borders, posterior, inferior, and superior.

The **external surface** is rough and uneven for the attachment of muscles; and broad and smooth above, where it enters into the formation of the acetabulum. Below the inferior lip of the acetabulum is a notch which lodges the obturator externus muscle in its passage outwards to the trochanteric fossa of the femur. The **internal surface** is smooth, and somewhat encroached upon at its posterior border by the spine; it is separated by the pectineal line from the concave inner surface of the ilium, and is chiefly occupied by the origin of the obturator internus.

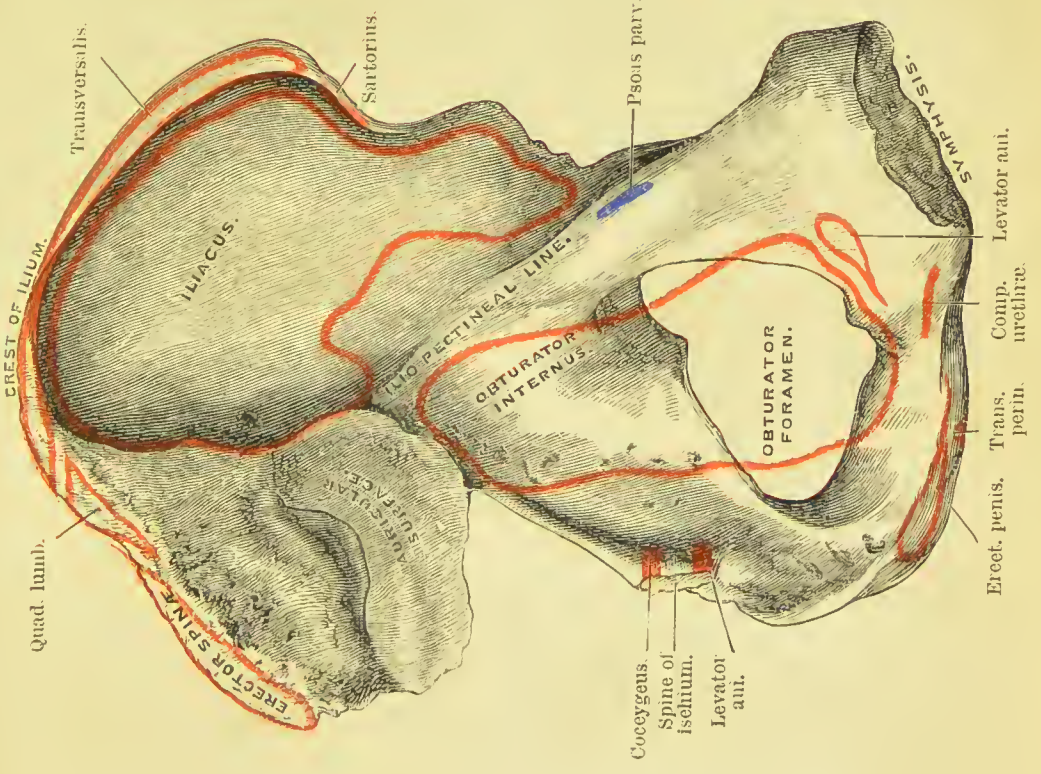
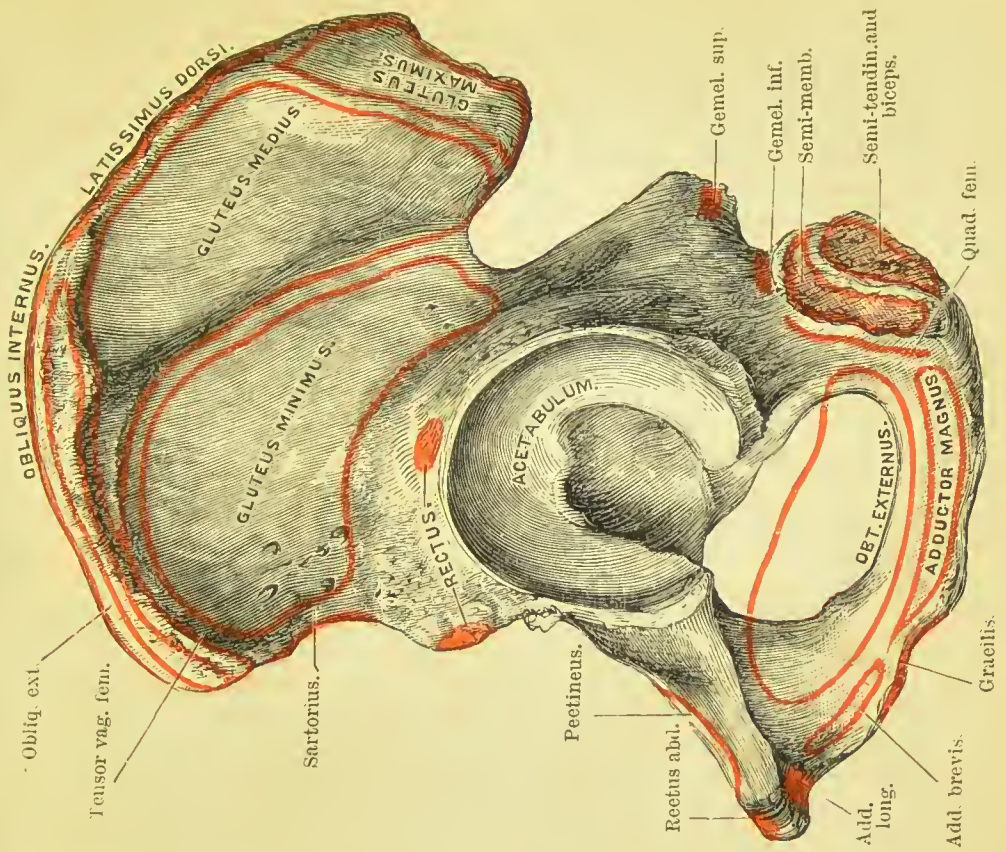
The **posterior border** of the ischium presents towards its middle a remarkable projection, the *spine*, which is directed backwards and inwards, and gives origin by its inner surface to two muscles, the coccygeus and levator ani. Immediately above the spine is a notch of large size, the *great sacro-ischiatic*, and below the spine, the *lesser sacro-ischiatic notch*; the former, being converted into a foramen by

the lesser sacro-ischiatic ligament, gives passage to the gluteal vessels and nerve, pyriformis muscle, pudic vessels and nerve, and ischiatic vessels and nerves; the lesser, completed by the great sacro-ischiatic ligament, to the obturator internus muscle, the nerve which is distributed to it, and internal pudic vessels and nerve. The **inferior border** is thick and broad, and called the *tuberosity*. The surface of the tuberosity is divided into two facets; the upper and outer, for the origin of the semi-membranosus; and the lower and inner, for the semi-tendinosus and biceps muscles. The inner margin of the tuberosity is bounded by a sharp ridge, which gives attachment to a prolongation of the great sacro-ischiatic ligament; and the outer margin by a prominent ridge, from which the quadratus femoris muscle arises. The **superior border** of the ischium is thin, and forms the lower circumference of the obturator foramen. The **ramus** of the ischium is continuous with the ramus of the pubes, and is slightly everted.

The PUBES is divided into a central part or **body**, a **horizontal ramus**, and a **descending ramus**.

The *external surface* of the **body** is rough for the attachment of muscles; the *internal surface* is smooth, and enters into the formation of the cavity of the pelvis. The *superior border* is marked by a rough ridge, the *crest*; the inner termination of the crest is the *angle*; the outer end, the *spine*; the latter gives attachment to the inner end of Poupart's ligament. The inner extremity of the body is the *symphysis*; it is oval and rough for the attachment of the articular cartilage. Running outwards from the spine is a sharp ridge, the *pectineal line*, which marks the brim of the true pelvis. The *inferior border* is broad, deeply grooved for the passage of the obturator vessels and nerve, and forms part of the boundary of the obturator foramen. The *outer border* of the body is sharp and thin, forming part of the margin of the obturator foramen, and giving attachment to the obturator membrane. The **horizontal ramus** extends from the body of the pubes to the junction of pubes and ilium; their point of union is marked by a rounded projection, the *ilio-pubic eminence*, which serves to separate the surface for the femoral vessels from another depression which overhangs the acetabulum and lodges the psoas and iliacus muscles. Behind this eminence runs the *ilio-pectineal line*, and on its inner side is a triangular area for the attachment of the pectineus muscle. The **descending ramus** of the pubes passes obliquely outwards, and is continuous with the ramus of the ischium. The inner border forms with the corresponding bone the *arch of the pubes*, and at its inferior part is everted, to give attachment to the crus penis. The ramus of the ischium and pubes together give attachment by their external surface to the adductor longus, brevis, and magnus muscles, the gracilis and obturator externus, and by their internal surface to the compressor urethræ, erector penis, transversus perinei, obturator internus, and levator ani.

The **acetabulum** (cotyloid cavity) is a deep cup-shaped cavity,



Erect. penin.
 Trans. urethre.
 Levator aut.
 Comp. urethre.



situated at the point of union between the ilium, ischium, and pubes; a little less than two-fifths being formed by the ilium, a little more than two-fifths by the ischium, the remaining fifth by the pubes. It is bounded by a deep rim or lip, broad and strong above, where most resistance is required, and marked in front by a deep notch, which is arched over in the fresh subject by a strong ligament, and transmits the nutrient vessels of the joint. At the bottom of the cup, and communicating with the notch, is a deep circular pit, which lodges a mass of fat, and gives attachment by its edges to the broad extremity of the ligamentum teres.

The **obturator** or **thyroid foramen** (also called *foramen ovale*) is a large oval interval between the ischium and pubes, bounded by a narrow rough margin, to which a ligamentous membrane is attached. The upper part of the foramen is increased in depth by the groove in the under surface of the os pubis, which lodges the obturator vessels and nerve.

Development.—By *eight* centres: three principal, one for the ilium, one for the ischium, and one for the pubes; and five secondary, one, the Y-shaped piece, for the interval between the primitive pieces in the bottom of the acetabulum, one for the crest of the ilium, one (not constant) for the anterior and inferior spinous process of the ilium, one for the tuberosity of the ischium, and one (not constant) for the angle of the pubes. Ossification commences in the primitive pieces, immediately after that in the vertebræ, firstly in the ilium during the eighth week, then in the ischium in the third month, and lastly in the pubes in the fourth or fifth month; the first ossific deposits being situated near the future acetabulum. At birth, the acetabulum, crest of the ilium, and ramus of the pubes and ischium, are cartilaginous. The rami of the ischium and pubes unite during the eighth year. The epiphyses appear about the time of puberty, that for the Y-shaped cartilage ossifying first; the three parts of the bone unite in the acetabulum at about the seventeenth or eighteenth year, and the bone is completed from the twenty-third to the twenty-fifth year.

Articulations.—With *three* bones; sacrum, opposite innominate, and femur.

Attachment of Muscles and Ligaments.—To *thirty-four* muscles: to the ilium *thirteen*; by the *outer lip of the crest*, obliquus externus for two-thirds its length, latissimus dorsi one-third, and tensor vaginæ femoris its anterior fourth; by the *middle of the crest*, internal oblique three-fourths its length, erector spinæ the remaining fourth; by the *internal lip*, transversalis three-fourths, and quadratus lumborum the posterior part of its middle third. By the *external surface*, gluteus medius, minimus, maximus, and one head of the rectus; by the *internal surface*, iliacus; by the *anterior border*, sartorius, and the other head of the rectus; by the *edge of the great sacro-sciatic foramen*, pyriformis. To the ischium *fourteen*; by its *external surface*, adductor magnus and obturator externus; by the *internal surface*, obturator internus and levator ani; by the *spine*,

gemellus superior, levator ani, coccygeus, and lesser sacro-ischiatic ligament; by the *tuberosity*, biceps, semi-tendinosus, semi-membranosus, gemellus inferior, quadratus femoris, erector penis, and great sacro-ischiatic ligament; by the *ramus*, gracilis, and transversus perinei. To the os pubis *sixteen*; by its *upper border*, obliquus externus, obliquus internus, transversalis, rectus, pyramidalis, pectineus, and psoas parvus; by its *external surface*, adductor longus, adductor brevis, gracilis, and obturator externus; by its *internal surface*, levator ani and obturator internus; and by the *ramus*, adductor magnus, ischio-cavernosus, and compressor urethræ.

PELVIS.

The pelvis is formed by the union of four bones, namely, the two innominate bones, sacrum, and coccyx. It is divisible into a **false**

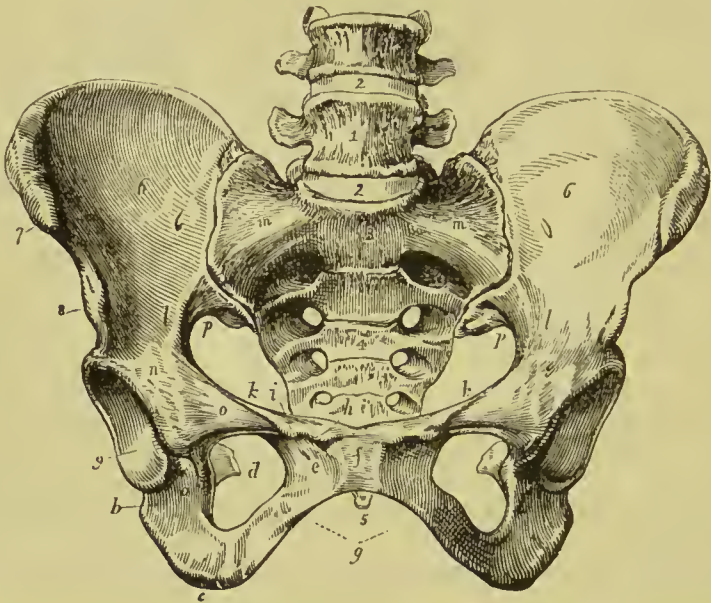


FIG. 138.—Female pelvis. 1. Last lumbar vertebra. 2, 2. Intervertebral substance connecting the last lumbar vertebra with the fourth and sacrum. 3. Promontory of the sacrum. 4. Anterior surface of the sacrum, on which its transverse lines and foramina are seen. 5. Tip of the coccyx. 6, 6. Iliac fossæ, forming the lateral boundaries of the false pelvis. 7. Anterior superior spinous process of the ilium; right side. 8. Anterior inferior spinous process. 9. Acetabulum. *a*. Notch of the acetabulum. *b*. Body of the ischium. *c*. Its tuberosity. *d*. Spine of the ischium seen through the obturator foramen. *e*. Pubes. *f*. Symphysis pubis. *g*. Arch of the pubes. *h*. Angle of the pubes. *i*. Spine of the pubes; the prominent ridge between *h* and *i* is the crest of the pubes. *k*, *k*. Pectineal line of the pubes. *l*, *l*. Pectineal line. *m*, *m*. The prolongation of this line to the promontory of the sacrum. The line represented by *h*, *i*, *k*, *k*, *l*, *l*, and *m*, *m*, is the brim of the true pelvis. *n*. Ilio-pubic eminence. *o*. The smooth surface which supports the femoral vessels. *p*, *p*. Great sacro-ischiatic notch.

and **true** pelvis; the former is the expanded portion, bounded on each side by the ilium, and separated from the true pelvis by the

pectineal line. The true pelvis is all that portion which is situated below this line, which thus forms the margin or **brim** of the true pelvis, while the included area is called the **inlet**. The form of the inlet is heart-shaped, obtusely pointed in front at the symphysis pubis, expanded on each side, and encroached upon behind by a projection of the upper part of the sacrum, which is named the promontory. The **cavity** is somewhat encroached upon at each side by a smooth quadrangular plane of bone, corresponding with the internal surface of the acetabulum, and prolonged posteriorly into the spine of the ischium. In front are two fossæ around the obturator foramina, for lodging the obturator internus muscle at each side. The inferior termination of the pelvis is very irregular, and is termed the **outlet**. It is bounded, in front, by the convergence of the rami of the ischium and pubes, which constitute the arch of the pubes; on each side by the tuberosity of the ischium, and two irregular fissures formed by the greater and lesser sacro-ischiatic notches; and behind by the lateral borders of the sacrum, and the coccyx.

The pelvis is placed obliquely with regard to the trunk of the body, the inner surface of the pubes being directed upwards, and serving to support the weight of the abdominal viscera. The base of the sacrum rises nearly four inches above the level of the upper border of the symphysis pubis, and the apex of the coccyx somewhat more than half an inch above its lower border. If a line were carried through the central axis of the inlet, it would impinge by one extremity against the umbilicus, and by the other against the middle of the coccyx. The **axis of the inlet** is, therefore, directed *upwards and forwards*, while that of the **outlet** points *downwards and forwards*, and corresponds with a line drawn from the upper part of the sacrum, through the centre of the outlet. The axis of the cavity represents a curve, corresponding very nearly with the curve of the sacrum, the extremities being indicated by the central points of the inlet and outlet. A knowledge of the direction of these axes is important to the surgeon, as indicating the line in which instruments should be used in operations upon the viscera of the pelvis, and the direction of force in the

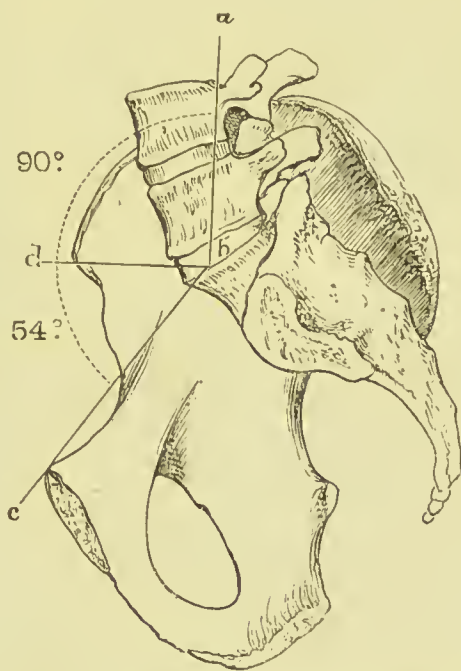


FIG. 139.—Angle of inclination of the brim of the pelvis 144° to the perpendicular, or 54° to the horizontal line.

removal of calculi from the bladder; and to the accoucheur, as explaining the course taken by the fetus during parturition.

There are certain characteristic differences between the male and female pelvis. In the male the bones are thicker, stronger, and more solid, the cavity being deeper and narrower. In the female the bones are lighter and more delicate, the iliac fossæ large, and the ilia expanded; the inlet, outlet, and cavity are large, and the acetabula farther removed from each other; the cavity is shallow, the tuberosities widely separated, the obturator foramina triangular, the sacrum broader and its curvature chiefly limited to the lower end, the coccyx more movable, and the span of the pubic arch greater. The precise diameter of the inlet and outlet, and the depth of the cavity of the female pelvis, are important considerations to the accoucheur.

Three diameters are usually described in each part of the true pelvis; they are: (1) Antero-posterior or conjugate; (2) Transverse; and (3) Oblique. The following table shows the comparative measurements in the male and female pelvis in inches:—

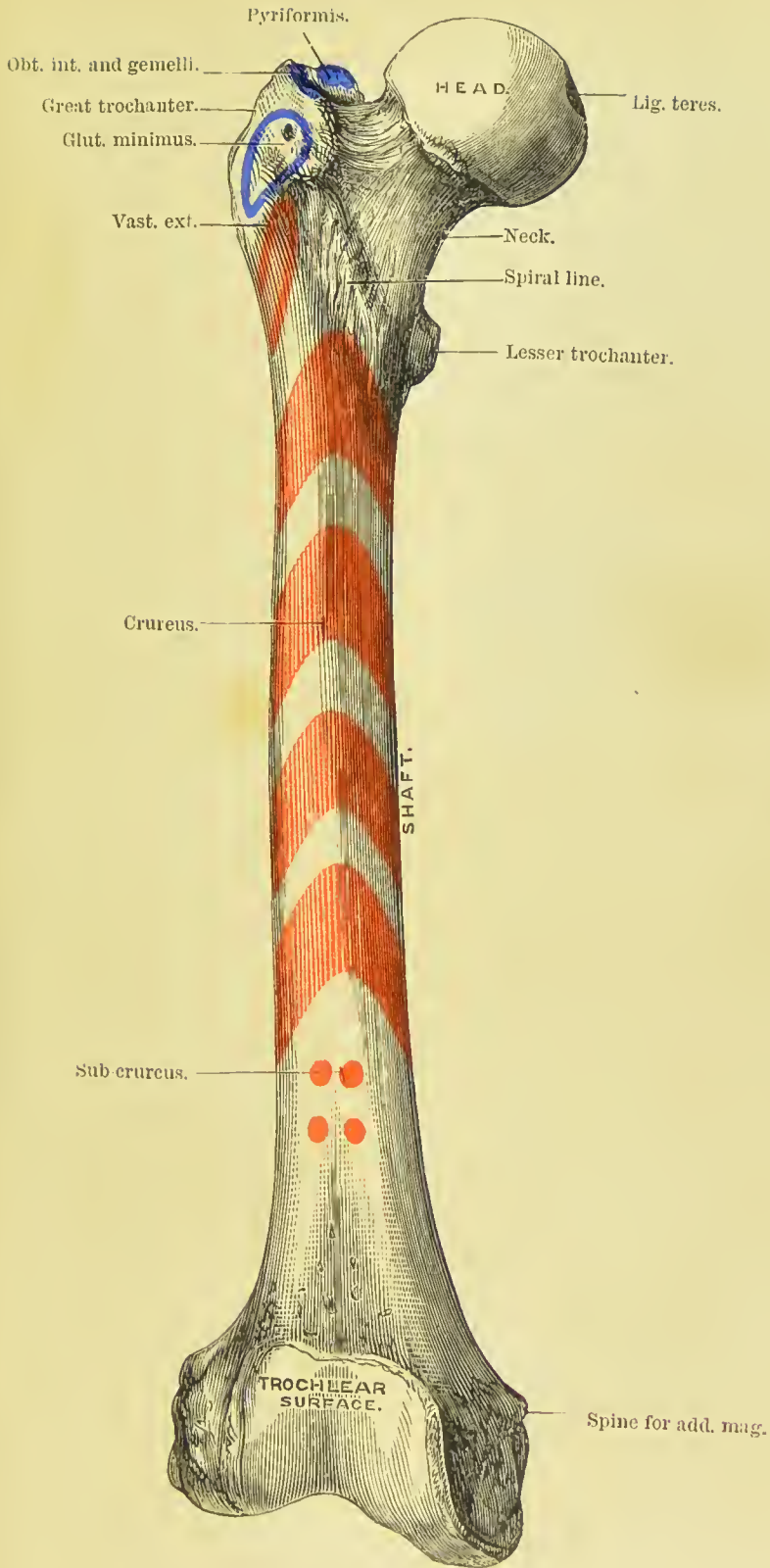
	MALE.			FEMALE.		
	Brim.	Cavity.	Outlet.	Brim.	Cavity.	Outlet.
Antero-posterior diameter.	4	4 $\frac{1}{4}$	3 $\frac{1}{4}$	4 $\frac{1}{2}$	5	5
Transverse diameter . . .	5	4 $\frac{3}{4}$	3 $\frac{1}{2}$	5 $\frac{1}{4}$	5	4 $\frac{3}{4}$
Oblique diameter . . .	4 $\frac{3}{4}$	4 $\frac{1}{2}$	4	5	5 $\frac{1}{4}$	4 $\frac{1}{2}$


FEMUR.

The femur, the longest bone of the skeleton, is situated obliquely in the upper part of the lower limb, articulating by means of its head with the acetabulum, and inclining inwards as it descends, until it almost meets its fellow of the opposite side at the knee. In the female this obliquity is greater than in the male, in consequence of the great breadth of the pelvis. The femur is divisible into a shaft, a superior, and an inferior extremity.

At the **upper extremity** is a rounded *head* directed upwards and inwards, and marked just below its centre by an oval depression for the ligamentum teres. The head is supported by a *neck*, which varies in length and obliquity with sex and period of life, being long and oblique in the adult male, shorter and more horizontal in the female and in old age. Externally to the neck is a large process, the *trochanter major*, which presents on its anterior surface an oval facet, for the attachment of the tendon of the gluteus minimus muscle; and on its outer surface, an oblique line for the insertion of the gluteus medius. On its posterior side is a vertical ridge (*quadrate line*) for the attachment of the quadratus femoris muscle. At the inner side of the trochanter major is a deep pit, *trochanteric* or *digital fossa*, at the bottom of which the obturator externus muscle is

PLATE 15.





inserted. The upper border of the great trochanter gives attachment near its anterior extremity to the gemellus superior, obturator internus, and gemellus inferior muscles, and a little behind this to the pyriformis muscle. Passing downwards from the trochanter major in front of the bone is an oblique ridge, which forms the inferior boundary of the neck, the *spiral line*, which if traced downwards will be found to lead into the upper part of the *linea aspera*; in well-marked specimens, two small tubercles will be found on it, one near the great trochanter, and the other lower down; they are called the *external* and *internal cervical tubercles*. Behind there is another oblique ridge, the *intertrochanteric line*, which terminates in a rounded tubercle on the posterior and inner side of the bone, the *trochanter minor*, for the insertion of the psoas and iliacus.

The **shaft** of the femur is convex in front, and covered with muscles; and somewhat concave and raised into a rough and prominent ridge behind, the *linea aspera*. The *linea aspera* near the upper extremity of the bone divides into three branches. The anterior branch is continued forwards in front of the lesser trochanter, and is continuous with the spiral line; the middle is continued directly upwards into the lesser trochanter; and the posterior, broad and strongly marked, ascends to the base of the trochanter major. Towards the lower extremity of the bone the *linea aspera* divides into two ridges, which descend to the two condyles, and enclose a triangular space upon which rests the popliteal artery. The internal supracondylar ridge is less marked than the external, and presents a broad and shallow groove for the passage of the femoral artery. The nutrient foramen is situated in or near the *linea aspera*, at about one-third from its upper extremity, and is directed obliquely from below upwards. The outer side of the shaft immediately above the condyles is very much thicker than the inner side, a point to be borne in mind in division of the femur for the cure of knock-knee.



FIG. 140. — The right femur, seen on its anterior aspect. 1. The shaft. 2. The head. 3. The neck. 4. Great trochanter. 5. Spiral line. 6. Lesser trochanter. 7. External condyle. 8. Internal condyle. 9. Tuberosity for the attachment of the external lateral ligament. 10. Fossa for the tendon of origin of the popliteus muscle. 11. Tuberosity for the attachment of the internal lateral ligament. 12. Adductor spine.

The **lower extremity** of the femur is broad and porous, and divided by a smooth depression in front, and by a large fossa (intercondylar fossa) behind, into two condyles.

The **external condyle** is the broadest and most prominent, the internal the narrowest and longest; the difference in length depending on the obliquity of the femur, in consequence of the separation of the two bones at their upper extremity by the breadth of the pelvis. The difference in the length of the condyles has been ascertained to amount to about eight millimetres, this being the average of a hundred observations (H. E. Clark). The external condyle is marked on its outer side by a prominent tuberosity, which gives

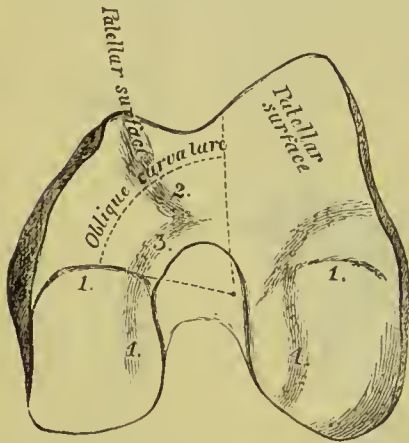


FIG. 141.—Diagram of under surface of condyles of femur.

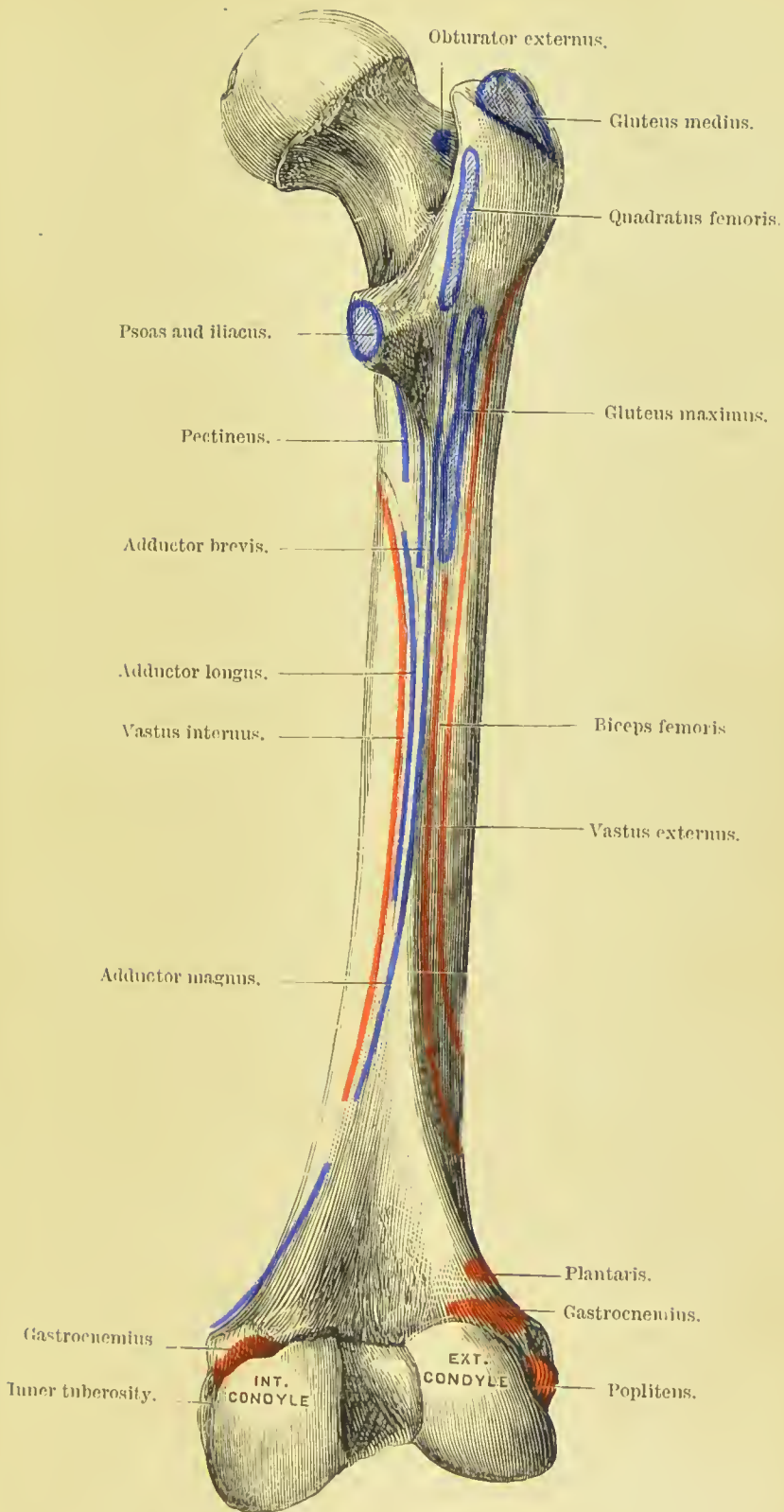
attachment to the external lateral ligament; and immediately beneath this is a fossa which lodges the tendon of origin of the popliteus. By the internal surface it gives attachment to the anterior crucial ligament of the knee-joint; and by its upper and posterior part, to the external head of the gastrocnemius and plantaris. The **internal condyle** projects on its inner side into a tuberosity, to which is attached the internal lateral ligament; above this tuberosity, at the extremity of the internal supra-condylar ridge, is a tubercle for the insertion of the tendon of the adductor magnus;

and above the posterior surface of the condyle, a depression from which the internal head of the gastrocnemius arises. The outer side of the internal condyle is rough and concave, for the attachment of the posterior crucial ligament.

The lower articular surface of the femur is divisible into three parts, the two *condylar* surfaces, and the *patellar* surface: the latter is marked off from the two former by shallow depressions running from the free margins of the articulation into the upper part of the intercondylar notch. In addition to the true condylar surface, the internal condyle has on its anterior face a small *oblique* surface, interposed between the condylar and patellar surfaces. The patellar or trochlear surface is the anterior part of the articular surface; its outer side extends higher up than its inner, and terminates by a more salient edge.

Development.—By *five* centres; one for the shaft, one for each extremity, and one for each trochanter. The femur is the first of the long bones to show signs of ossification; ossific matter is found immediately after the maxillæ and before the termination of the second month of embryonic life. The secondary deposits take place in the following order: in the condylar extremity during the last month of foetal life; in the head towards the end of the first year; in the greater trochanter between the third and fourth year; in the

PLATE 16.





lesser trochanter between the thirteenth and fourteenth. The lesser trochanter joins the shaft about the seventeenth year, the great trochanter in the eighteenth year, the head during the nineteenth year, and the lower extremity soon after twenty.

Articulations.—With *three* bones: os innominatum, tibia, and patella.

Attachment of Muscles.—To *twenty-three*: by the *greater trochanter*, to the gluteus medius and minimus, pyriformis, gemellus superior, obturator internus, gemellus inferior, obturator externus, and quadratus femoris; by the *lesser trochanter*, to the common tendon of the psoas and iliacus. By the *linea aspera*, its outer lip, to the vastus externus, gluteus maximus, and short head of the biceps; by its inner lip, vastus internus, pectineus, adductor brevis, and adductor longus; by its middle lip, adductor magnus; by the *anterior part* of the bone, cruræus and subcruræus; by its *condyles*, gastrocnemius, plantaris, and popliteus.

PATELLA.

The patella is a sesamoid bone, developed in the tendon of the quadriceps extensor muscle, and usually described as a bone of the lower extremity. It is heart-shaped in figure, the broad end being directed upwards, the apex downwards; the external surface is convex, and the internal divided by a ridge into two smooth surfaces, to articulate with the condyles of the femur. The external articular surface, corresponding with the external condyle, is the larger of the two, and serves to indicate the leg to which the bone belongs. Each surface presents a faint transverse line near its lower end, another near its upper border, so as to divide them into three facets; the internal surface has also a vertical line near its inner edge. To the upper border of the bone are attached the rectus femoris and crureus muscles, and to the upper part of the lateral margins the expanded tendons of the vastus externus and internus, and by the inferior pointed process it is attached, through means of a strong band called the *ligamentum patellæ*, to the tubercle of the tibia.

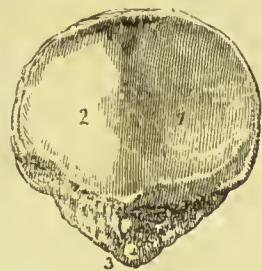

FIG. 142.—Patella of the right side. 1. Surface of articulation with the external condyle of the femur. 2. Surface of articulation with the internal condyle. 3. Apex of the bone.

Development.—By a single centre, at about the middle of the third year.

Articulations.—With the two condyles of the femur.

Attachment of Muscles.—To *four*: rectus, cruræus, vastus internus, vastus externus; and to the ligamentum patellæ.

TIBIA.

The tibia is the inner and larger bone of the leg; it is prismoid in form, and divisible into a shaft, an upper and lower extremity.

The **upper extremity**, or head, is large, and expanded laterally into two *tuberosities*. On the upper surface the tuberosities are smooth to articulate with the condyles of the femur; the internal articular surface being oval to correspond with the internal condyle; the external, broad and nearly circular. Between the two articular surfaces is a *spinous process*; and in front of and behind the spinous

process a rough depression, giving attachment to the anterior and posterior crucial ligament and the two semilunar cartilages. Between the two tuberosities on the front aspect of the bone is a prominent elevation, the *tubercle* for the insertion of the ligamentum patellæ, and immediately above the tubercle a smooth facet, corresponding with the bursa of the ligamentum patellæ. Posteriorly the tuberosities are separated by a depression called the popliteal notch, which gives attachment to part of the posterior crucial ligament, and part of the posterior ligament of Winslow. Upon the posterior and under part of the external tuberosity is an articular surface for the head of the fibula; and upon the posterior part of the internal tuberosity a depression for the insertion of the tendon of the semi-membranosus muscle.

The **shaft** of the tibia presents three surfaces. The *internal* is convex, and is subcutaneous throughout its lower three-fourths; at the

upper part, on a line with the tubercle of the tibia, it gives attachment to the tendons of the sartorius, gracilis, and semi-tendinosus muscles. The *external* is concave, and is occupied by the tibialis anticus muscle; at its lower third it curves forwards towards the front of the bone, and supports the tendons of the tibialis anticus, extensor proprius hallucis, and extensor communis digitorum. The *posterior* is grooved for the attachment of muscles. Near the upper extremity of the posterior surface is an oblique ridge, the *oblique line* (or *soleal ridge*), for the attachment of the soleus muscle and fascia of the popliteus muscle; and immediately

FIG. 143. — Tibia and fibula of the right leg, articulated and seen from the front. 1. Shaft of the tibia. 2. Inner tuberosity. 3. Outer tuberosity. 4. Spinous process. 5. Tubercle. 6. Internal or subcutaneous surface of the shaft. 7. Lower extremity of the tibia. 8. Internal malleolus. 9. Shaft of the fibula. 10. Its upper extremity. 11. Its lower extremity, the external malleolus. The sharp border between 1 and 6 is the crest of the tibia.


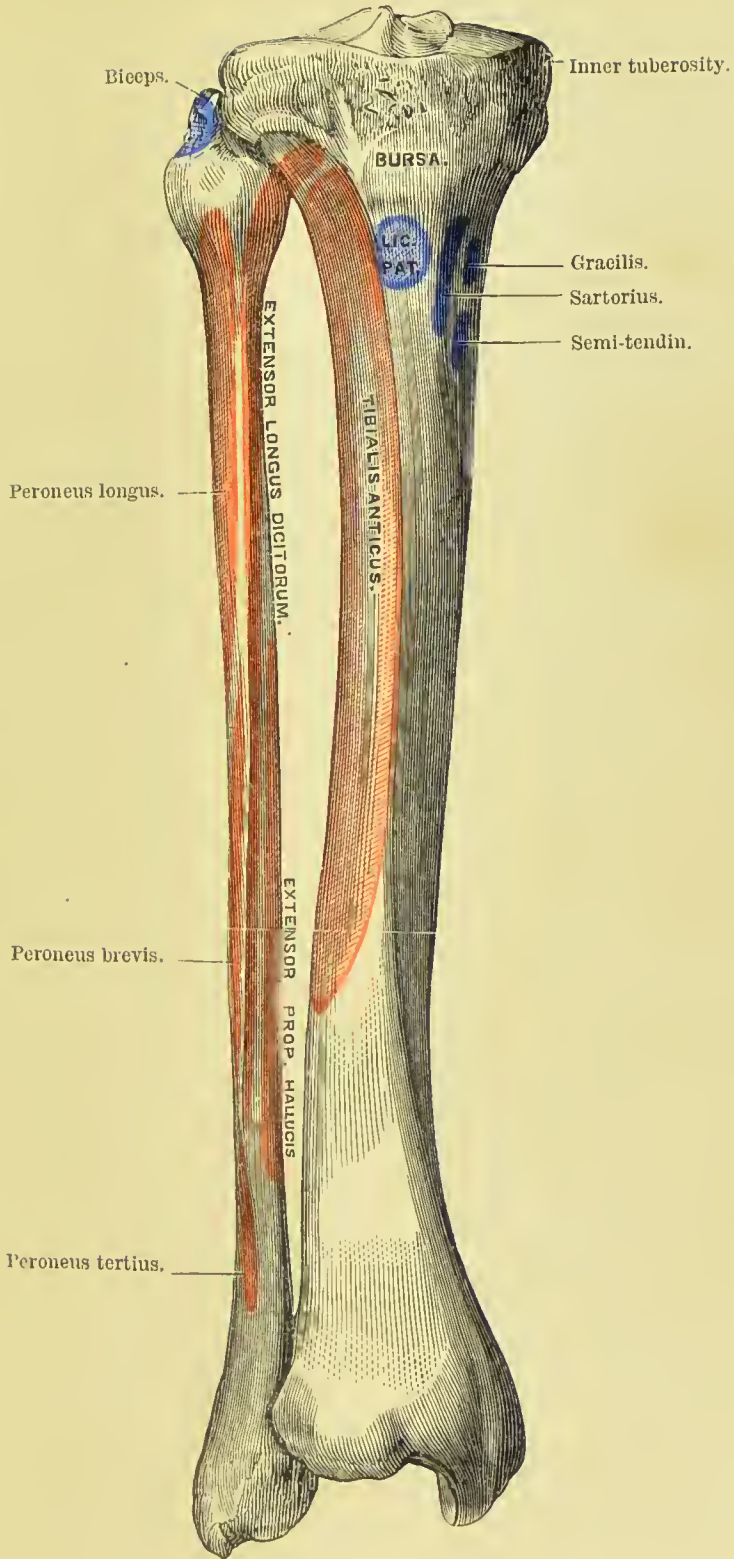


PLATE 17.





below the oblique line, the nutrient canal, which is directed downwards. The triangular space above the oblique line is occupied by the popliteus muscle.

The borders of the tibia are anterior, internal, and external. The *anterior border* is sharp and curved outwards in its upper two-thirds, and rounded and curved inwards below. It is known as the *crest of the tibia*, and, popularly, as the *shin*. The *internal border* is most prominent in the middle, and is rounded above and below; it gives attachment to the internal lateral ligament of the knee-joint, and to the soleus and flexor longus digitorum muscles. The *external border* gives attachment throughout its whole length to the interosseous membrane, and divides below to enclose a triangular rough space, for the interosseous ligament between the lower end of tibia and fibula.

The **inferior extremity** of the bone is somewhat quadrilateral, and prolonged on its inner side into a large process, the *internal malleolus*. The inner surface of the malleolus is smooth for articulation with the astragalus; at its tip is a small depression for the internal lateral ligament of the ankle-

joint. Behind the internal malleolus is a broad and shallow groove for lodging the tendons of the tibialis posticus and flexor longus digitorum; and farther outwards another groove for the tendon of the flexor longus hallucis. At the outer side the surface is concave and triangular, rough above for the attachment of the interosseous ligament; and smooth below, to articulate with the fibula. On the extremity of the bone is a triangular smooth surface for articulation with the astragalus.

Development.—By *three centres*; one for the shaft, one for the upper extremity, including the tubercle, and one for the lower extremity. Ossification commences in the tibia immediately after the

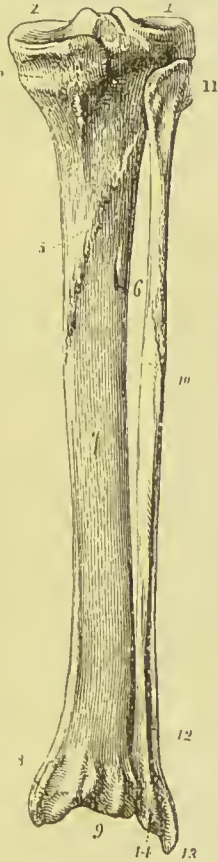

FIG. 141.—Tibia and fibula of the right leg articulated and seen from behind. 1. Articular depression for the external condyle of the femur. 2. Articular depression for the internal condyle; the prominence between the two is the spinous process. 3. Fossa and groove for the insertion of the tendon of the semi-membranosus. 4. Popliteal plane, for the origin of the popliteus. 5. Oblique line. 6. Nutrient foramen. 7. Surface of the shaft on which the flexor longus digitorum rests. 8. Broad groove on the back part of the inner malleolus, for the tendons of the flexor longus digitorum and tibialis posticus. 9. Groove for the tendon of the flexor longus hallucis. 10. Shaft of the fibula. The flexor longus hallucis lies on this surface of the bone; its superior limit being marked by the oblique line immediately above the figure. 11. Styloid processes on the head of the fibula for the attachment of the tendon of the biceps. 12. Subcutaneous surface of the lower part of the shaft of the fibula. 13. External malleolus formed by the lower extremity of the fibula. 14. Groove on the posterior part of the external malleolus for the tendons of the peronei muscles.

femur; the centre for the head of the bone appears either in the ninth month or soon after birth, and that for the lower extremity during the second year; the latter is the first to join the diaphysis. The lower epiphysis joins the shaft about the twentieth year, and the bone is completed by the union of the upper epiphysis about the twenty-fifth year. Two additional centres are sometimes found in the tibia, one for the tubercle, the other for the internal malleolus.

Articulations.—With *three* bones: femur, fibula, and astragalus.

Attachment of Muscles.—To *ten*: by the *internal tuberosity* to the semi-membranosus; by the *external tuberosity*, tibialis anticus and extensor longus digitorum; by the *tubercle*, ligamentum patellæ; by the *external surface* of the shaft, tibialis anticus; by the *posterior surface*, popliteus, soleus, flexor longus digitorum, and tibialis posticus; and by the *internal surface* to the sartorius, gracilis, and semitendinosus.

FIBULA.

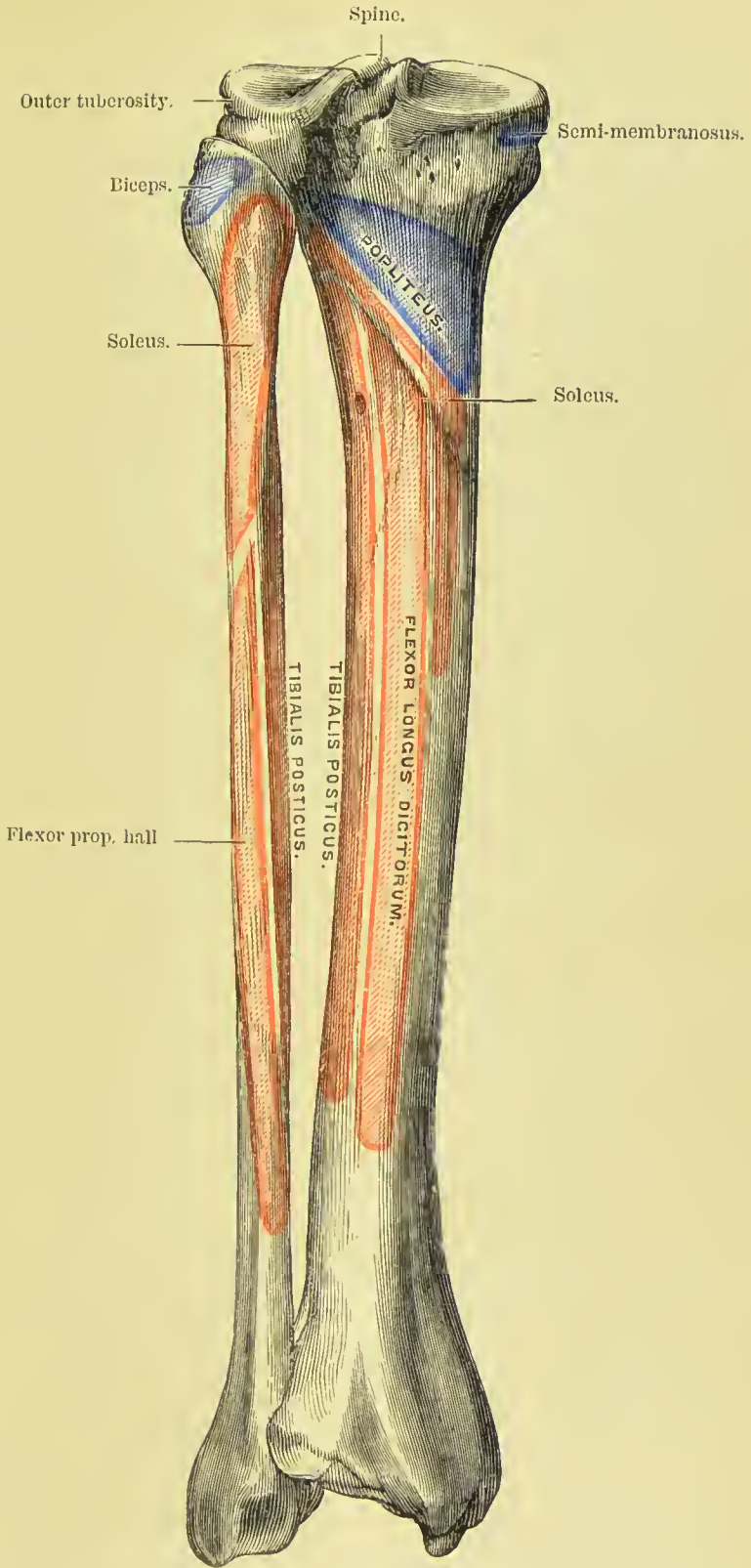
The fibula (*περόνη*, a brooch, from its resemblance, in conjunction with the tibia, to the pin of an ancient brooch) is the outer and smaller bone of the leg; it is long and slender in figure, prismoid in shape, and, like other long bones, divisible into a shaft and two extremities.

The **upper extremity** or head is thick and large, and depressed at the upper part by a concave surface, which articulates with the external tuberosity of the tibia. Externally to this surface is a thick and rough prominence, terminated behind by a *styloid process* for the attachment of the long external lateral ligament of the knee-joint, and for the insertion of the tendon of the biceps.

The **lower extremity** is flattened from without inwards, and prolonged downwards beyond the articular surface of the tibia, forming the *external malleolus*. Its external side presents a rough and triangular surface, which is subcutaneous. On the internal surface is a smooth triangular facet to articulate with the astragalus, and a rough depression for the insertion of the interosseous ligament. Behind the articular surface and between it and the tip of the malleolus is a deep fossa which lodges the posterior slip of the external lateral ligament. The *anterior border* is thin and sharp, the *posterior* broad and grooved for the tendons of the peronei muscles.

The **shaft** of the fibula is prismoid, and presents three surfaces; external, internal, and posterior; and three borders. The *external surface* is the broadest of the three; it commences on the anterior part of the bone above, and curves around it so as to terminate on its posterior side below. This surface is completely occupied by the two peronei muscles. The *internal surface* commences on the side of the superior articular surface, and terminates below by narrowing to a ridge which is continuous with the anterior border of the malleolus. It is marked along its middle by the *interosseous ridge*, which

PLATE 18.





is lost above and below in the inner border of the bone, and which gives attachment to the interosseous membrane. The *posterior surface* is twisted like the external ; it commences above on the posterior side of the bone, and terminates below on its internal side ; at about the middle of this surface is the *nutrient foramen*, which is directed downwards.

The *internal border* commences superiorly in common with the interosseous ridge, and bifurcates inferiorly into two lines, which bound the triangular subcutaneous surface of the external malleolus. The *external border* begins at the base of the styloid process of the head, and winds around the bone, following the direction of the corresponding surface. The *posterior border*, sharp and prominent, is lost inferiorly in the interosseous ridge.

Recognition.—In order to recognise whether the bone belongs to the right or left side, it should be held with the head (known by the styloid process and terminal articular facet) upwards, and the pit at the back of the external malleolus directed towards the observer ; the triangular subcutaneous area will then point to the side to which the bone belongs.

Development.—By *three* centres ; one for the shaft, and one for each extremity. Ossification commences in the shaft soon after its appearance in the tibia ; at birth the extremities are cartilaginous, an osseous deposit taking place in the inferior epiphysis during the second year, and in the superior during the fourth or fifth. The inferior epiphysis is the first to become united with the diaphysis, but the bone is not completed until nearly the twenty-fifth year. The epiphyses of all the long bones except the fibula unite with the diaphysis in the reverse order of their appearance ; but in the fibula, the lower epiphysis, which is the first to appear, is also the first to join the shaft.

Articulations.—With the tibia and astragalus.

Attachment of Muscles.—To *nine* : by the *head*, to the tendon of the biceps and soleus ; by the *shaft*, its *external* surface, peroneus longus and brevis ; *internal* surface, extensor longus digitorum, extensor proprius hallucis, peroneus tertius, and tibialis posticus ; by the *posterior* surface, flexor longus hallucis.

TARSUS.

The bones of the tarsus are *seven* in number, viz., astragalus, os calcis, scaphoid, internal, middle, and external cuneiform, and cuboid.

ASTRAGALUS.—The astragalus (*os tali*) may be recognised by its rounded head, a broad articular facet on its convex surface, and two articular facets, separated by a deep groove, on its concave surface.

The bone is divisible into a superior and inferior surface, an external and internal border, and an anterior and posterior extremity.

The *superior surface* is convex, and presents a large quadrilateral and smooth facet, somewhat broader in front than behind, to articulate with the tibia. The *inferior surface* is concave, and divided by a deep and rough groove (*sulcus tali*), which lodges a strong interosseous ligament, into two facets—the posterior large and quadrangular, the anterior smaller and elliptical—which articulate with the os calcis. The *internal border*, flat and uneven, is marked by a pyriform articular surface, limited to the upper half of this border, for the inner malleolus. The *external* presents a large triangular articular facet, extending the whole depth of the border, for the external malleolus, and is rough and concave in front. The *anterior extremity* presents a rounded *head*, encircled by a constriction somewhat resembling a neck; the *posterior extremity* is narrow, and marked by a deep groove for the tendon of the flexor longus hallucis.

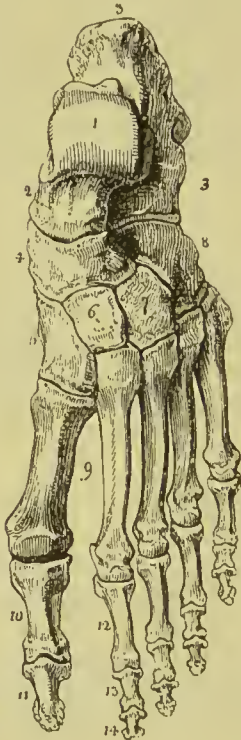Recognition.—Hold the astragalus with the broad convex articular surface upwards, and rounded head forwards; the large triangular lateral articular surface will point to the side to which the bone belongs.

Articulations.—With *four* bones: tibia, fibula, os calcis, and scaphoid.

OS CALCIS.—This bone may be known by its large size and oblong figure, by the massive portion which forms the heel, and by two articular surfaces, separated by a broad groove, upon its upper side.

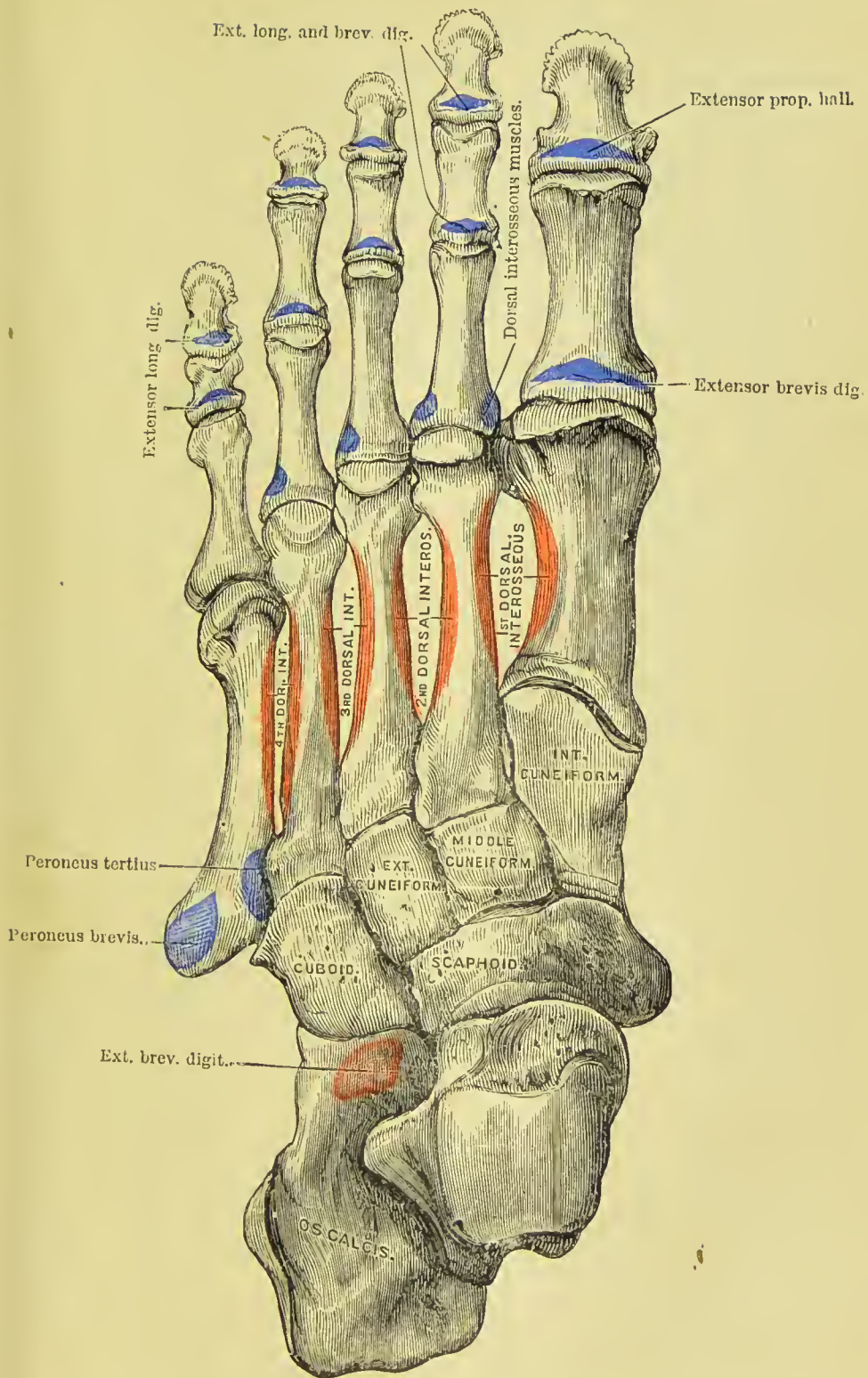
The os calcis is divisible into four surfaces, superior, inferior, external, and internal; and two extremities, anterior and posterior. The *superior surface* is convex behind and irregularly concave in front, where it presents two and sometimes three articular facets, divided by a broad and shallow groove (*sulcus calcanei*), for the interosseous ligament. The *inferior surface* is convex and rough, and bounded posteriorly by the two inferior tuberosities, of which the internal is broad and large, the external smaller and prominent. The *external surface* is convex and subcutaneous, and is often marked towards its anterior third by two grooves, separated by a

FIG. 145. — Dorsal surface of the left foot. 1. Astragalus; its superior quadrilateral articular surface. 2. Head of the astragalus which articulates with (4) the scaphoid bone. 3. Os calcis. 4. Scaphoid bone. 5. Internal cuneiform bone. 6. Middle cuneiform bone. 7. External cuneiform bone. 8. Cuboid bone. 9. Metatarsal bones of the first and second toes. 10. First phalanx of the great toe. 11. Second phalanx of the great toe. 12. First phalanx of the second toe. 13. Second phalanx. 14. Third phalanx.



tubercle, for the tendons of the peroneus longus and brevis. The *internal surface* is concave and grooved for the tendons and vessels

PLATE 19.





which pass into the sole of the foot. At the anterior extremity of this surface is a projecting process (*sustentaculum tali*), which supports the anterior articulating surface of the astragalus, and serves as a pulley for the tendon of the flexor longus hallucis.

At the *anterior extremity* of the bone is a flat articular surface, surmounted by a rough prominence, which affords one of the guides to the surgeon in the performance of Chopart's operation. The *posterior extremity* is prominent and convex, and constitutes the *posterior tuberosity*; it is smooth for the upper half of its extent, where it corresponds with a bursa; and rough below, for the insertion of the tendo Achillis; the lower part of this surface is bounded by the two inferior tuberosities.

Articulations.—With *two* bones: astragalus and cuboid. In their articulated state a large oblique canal is situated between the astragalus and calcaneum, being formed by the apposition of the two grooves, sulcus tali and sulcus calcanei. This canal is called the *sinus tarsi*, and serves to lodge a strong interosseous ligament which ties the two bones together.

Attachment of Muscles.—To *eight*: by the *posterior tuberosity*, to the tendo Achillis and plantaris; by the *inferior tuberosities* and under surface, abductor hallucis, abductor minimi digiti, flexor brevis digitorum, flexor accessorius, and plantar fascia; by the *external surface*, extensor brevis digitorum; and by the *sustentaculum tali*, a few fibres of the tibialis posticus.

SCAPHOID.—This bone may be distinguished by its boat-like figure, being concave on one side, and convex with three facets on the other. It presents for examination six surfaces; three articular and three non-articular. The *anterior surface* is convex, and divided into three facets to articulate with the three cuneiform bones; the *posterior* is concave to articulate with the rounded head of the astragalus. The *superior surface* is convex and rough, and the *inferior* somewhat concave and uneven. The *external extremity* is broad and rough; the *internal* pointed and prominent, forming a tuberosity (*tubercle of the scaphoid*) which gives attachment to part of the tendon of the tibialis posticus. The external extremity sometimes presents a facet of articulation with the cuboid.

Recognition.—If the bone be held so that the convex articular surface with three facets look forwards, and the convex non-articular surface upwards, the broad extremity will point to the side corresponding with the foot to which the bone belongs.

Articulations.—With *four* bones: astragalus and three cuneiform, sometimes also with the cuboid.

Attachment of Muscles.—To the tendon of the tibialis posticus.

INTERNAL CUNEIFORM.—The internal cuneiform may be known by its irregular wedge shape, and by being larger than the two other bones which bear the same name. It presents for examination a convex and a concave surface, a long and a short articular border, and a small and a large extremity.

The *convex surface* is internal and free, and assists in forming the

inner border of the foot; it presents near its anterior extremity a smooth facet, into which part of the tendon of the tibialis anticus is inserted. The *concave* is external, and is marked by an inverted L-shaped articular surface, limited to its superior and posterior borders, for articulation with the middle cuneiform and second metatarsal bone. The *long border* is kidney-shaped, and articulates with the metatarsal bone of the great toe; the *short border* is posterior, and articulates with the scaphoid bone. The small extremity (edge) is sharp, and is directed upwards; the larger extremity (base) looks towards the sole of the foot, and is rounded into a broad tuberosity.

Recognition.—Place the bone so that the small extremity may look upwards and the kidney-shaped articular border forwards; the depression in the middle of the latter will point to the side corresponding with the foot to which it belongs.

Articulations.—With *four* bones: scaphoid, middle cuneiform, and first two metatarsal bones.

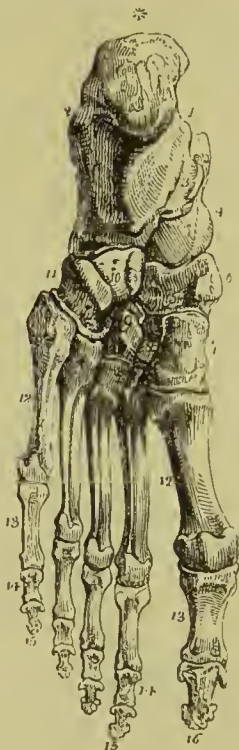Attachment of Muscles.—To the tibialis anticus and posticus and peroneus longus.

MIDDLE CUNEIFORM.—The middle cuneiform is the smallest of the three; it is wedge-shaped, the broad extremity being placed upwards,

the sharp end downwards in the foot. It presents for examination four articular surfaces and two free borders. The *anterior* and *posterior surfaces* have nothing worthy of remark, excepting that the former extends the whole depth of the bone, while the latter is limited to its upper two-thirds. The *internal lateral surface* has an L-shaped articular facet, extending along its upper and posterior margins for the internal cuneiform; the *external* has an articular facet limited to the posterior border for the external cuneiform bone.

Recognition.—If the bone be held so that the

FIG. 146.—Sole of the left foot. 1. Inner tuberosity of the os calcis. 2. Outer tuberosity. * Posterior tuberosity. 3. Groove for the tendon of the flexor longus hallucis; this figure indicates also the sustentaculum tali, upon which it is placed. 4. Rounded head of the astragalus. 5. Scaphoid bone. 6. Its tubercle. 7. Internal cuneiform bone; its broad extremity. 8. Middle cuneiform bone. 9. External cuneiform bone. 10, 11. Cuboid bone. 11. Groove for the tendon of the peroneus longus; the prominence between this groove and figure 10 is the tuberosity of the bone. 12, 12. Metatarsal bones. 13, 13. First phalanges. 14, 14. Second phalanges of the four lesser toes. 15, 15. Third or unguis phalanges of the four lesser toes. 16. Last phalanx of the great toe.



flat dorsal surface look upwards, its broadest edge being towards the holder, the articular surface, limited to the posterior border, will point to the side to which the bone belongs.

Articulations.—With *four* bones : scaphoid, internal and external cuneiform, and second metatarsal bone.

EXTERNAL CUNEIFORM.—The external cuneiform is intermediate in size between the two preceding, and placed, like the middle, with the broad end upwards, and sharp extremity downwards. It may be identified by a triangular articular facet on its outer side. It presents for examination four surfaces, and a superior and inferior extremity. The *anterior surface* is wedge-shaped and articular throughout its entire depth, for articulation with the third metatarsal. The *posterior surface*, also wedge-shaped, is articular only in its upper two-thirds, the lower part being rough for the attachment of ligaments. The *external surface* presents posteriorly a large smooth oval articular surface for the cuboid bone, and anteriorly at its upper angle a small facet for the base of the fourth metatarsal. The *internal surface* also has two facets separated by a rough depression, one along the posterior margin for the middle cuneiform, and the other at the upper and anterior angle of the bone for the base of the second metatarsal. The *upper extremity* is flat, of an oblong square form, and bevelled posteriorly, at the expense of the outer surface, into a sharp edge ; the *lower extremity* forms a rounded ridge which serves for the attachment of the tibialis posticus and part of the flexor brevis hallucis.

Recognition.—Hold the bone with the flat dorsal surface upwards and the narrower wedge-shaped articular surface directed backwards ; the large oval articular facet for the cuboid will then point to the side to which the bone belongs.

Articulations.—With *six* bones : scaphoid, middle cuneiform, cuboid, and second, third, and fourth metatarsal bones.

Attachment of Muscles.—To the flexor brevis hallucis and tibialis posticus.

CUBOID.—The cuboid bone is irregularly cuboid in shape, and marked on its under surface by a deep groove for the tendon of the peroneus longus muscle. It presents for examination six surfaces, three articular and three non-articular. The *non-articular* surfaces are—*superior*, which is slightly convex, and assists in forming the dorsum of the foot ; *inferior*, marked by a prominent ridge, the *tuberosity*, and a deep groove for the tendon of the peroneus longus ; and *external*, the smallest of the whole, and deeply notched by the commencement of the peroneal groove. The *articular surfaces* are—*posterior*, of large size, and concavo-convex, to articulate with the os calcis ; *anterior*, of smaller size, divided by a slight ridge into two facets, for the fourth and fifth metatarsal bones ; and *internal*, a small oval articular facet, upon a large and quadrangular surface, for the external cuneiform bone.

Recognition.—If the bone be held so that the plantar surface, with the peroneal groove, look downwards, and the largest articular surface backwards, the small non-articular surface, marked by the deep notch, will point to the side to which the bone belongs.

Articulations.—With *four* bones : os calcis, external cuneiform, fourth and fifth metatarsal bone, and sometimes the scaphoid.

Attachment of Muscles.—To *two* : flexor brevis hallucis, and adductor hallucis.

Upon a consideration of the articulations of the tarsus it will be observed that each bone articulates with four adjoining bones, with the exception of the calcaneum, which articulates with two, and the external cuneiform with six.

Development.—By a single centre for each bone, with the exception of the os calcis, which has an epiphysis for its posterior tuberosity. The centres appear in the following order : calcanean, sixth month ; astragalan, seventh month ; cuboid, ninth month ; external cuneiform, end of the first year ; internal cuneiform, during the third year ; middle cuneiform and scaphoid, during the fourth year. The epiphysis of the calcaneum appears at the tenth year, and is united with the diaphysis at about the fifteenth.

METATARSAL BONES.

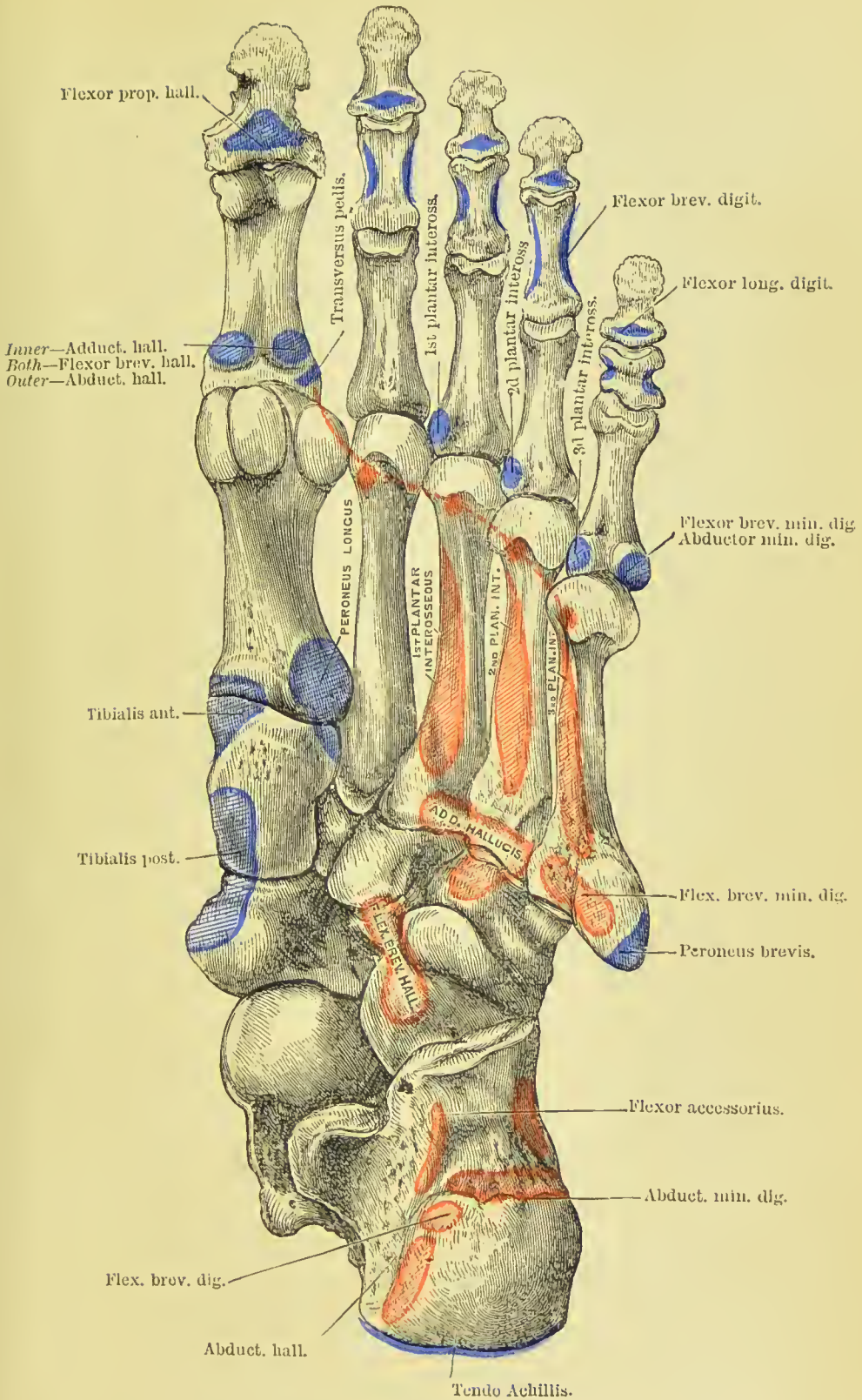
These bones, *five* in number, are long bones, and divisible therefore into a shaft and two extremities. The shaft is prismoid, and compressed from side to side ; the posterior extremity, or base, is wedge-shaped, to articulate with the tarsal bones, and with each other ; the anterior extremity presents a rounded head, circumscribed by a neck, to articulate with the first row of the phalanges.

Peculiar Metatarsal Bones.—The *first* is shorter and larger than the rest, and forms part of the inner border of the foot ; its posterior extremity has no lateral facet, but presents a large kidney-shaped surface at its base, and an oval rough prominence beneath for the insertion of the tendon of the peroneus longus. The head of the bone has, on its plantar surface, two grooved facets, for sesamoid bones. To find the side to which the bone belongs, hold it with the base towards you and the convex surface upwards ; the concavity of the kidney-shaped surface will then point to the appropriate side.

The *second* is the longest and largest of the remaining metatarsal bones ; it presents at its base an articular facet for the middle cuneiform bone, and has on its outer lateral surface four facets, two for the outer cuneiform and two for the third metatarsal. On its inner surface it has only one facet, for the internal cuneiform. If the bone be held with its head directed forwards and the convex surface of the shaft upwards, the four lateral facets will point to the side to which it belongs.

The *third* may be known by two facets on the inner side of its base, corresponding with the second, and one on the outer side for the fourth metatarsal. It may be distinguished also by its smaller size. When held in the usual position, the side with the single lateral facet will indicate the foot to which the bone belongs.

PLATE 20.





The *fourth* may be distinguished by its smaller size, and by having a single articular surface on each side of the base, the facet on the outer side being bounded distally by a very deep pit for an interosseous ligament. When held with the base backwards and dorsal surface upwards, the most prominent angle at the base will point to the foot to which the bone belongs.

The *fifth* is recognised by its broad base, and by the large tuberosity at its outer side.

Development.—Each bone by *two* centres ; one for the body and one for the digital extremity in the four outer metatarsal bones ; and one for the body, the other for the base, in the metatarsal bone of the great toe. In the latter toe there is frequently a second or distal epiphysis. Ossification appears in the shafts of these bones at about the eighth or ninth week ; the epiphyses appear in the heads of the metatarsals of the four outer toes about the third year, and in the base of that of the great toe in the fifth year, consolidation being effected at eighteen.

Articulations.—With the tarsal bones by one extremity, and first row of phalanges by the other. The number of tarsal bones with which each metatarsal articulates from within outwards, is the same as between the bones of the metacarpus and carpus, one for the first, three for the second, one for the third, two for the fourth, and one for the fifth.

Attachment of Muscles.—To *fourteen* : to the first, peroneus longus and first dorsal interosseous ; to the second, two dorsal interossei and transversus pedis ; to the third, two dorsal and one plantar interosseous, adductor hallucis and transversus pedis ; to the fourth, two dorsal and one plantar interosseous, adductor hallucis and transversus pedis ; to the fifth, one dorsal and one plantar interosseous, peroneus brevis, peroneus tertius, abductor minimi digiti, flexor brevis minimi digiti, and transversus pedis.

PHALANGES.

There are two phalanges in the great toe and three in the other toes, as in the hand. They are long bones, divisible into a central portion and extremities.

The phalanges of the first row are convex above, concave on the under surface, and compressed from side to side. The proximal extremity has a single concave articular surface, for the head of the metatarsal bone ; the distal extremity, a pulley-like surface, for the second phalanx.

The *second phalanges* are short and diminutive, but somewhat broader than those of the first row.

The *third* or *ungual phalanges*, including the second phalanx of the great toe, are flattened from above downwards, spread out laterally at the base to articulate with the second row, and at the opposite extremity to support the nail and the rounded extremity of the toe.

Development.—By *two* centres ; one for the body and one for the metatarsal extremity. Ossification commences in these bones after the metatarsus, appearing firstly in the last phalanges, then in the first, and lastly in the middle row. The centres for the epiphyses appear during the fourth year for the first row, and the sixth year for the other two rows. The bones are completed at eighteen.

Articulations.—The first row with the metatarsal bones and second phalanges ; the second, of the great toe, with the first phalanx ; of the other toes, with the first and third phalanges ; the third, with the second row.

Attachment of Muscles.—To *twenty-three*: to the *first phalanges* ; *great toe*, innermost tendon of the extensor brevis digitorum, abductor hallucis, adductor hallucis, flexor brevis hallucis, and transversus pedis ; *second toe*, first and second dorsal interosseous and lumbricalis ; *third toe*, third dorsal and first plantar interosseous and lumbricalis ; *fourth toe*, fourth dorsal and second plantar interosseous and lumbricalis ; *fifth toe*, third plantar interosseous, abductor minimi digiti, flexor brevis minimi digiti and lumbricalis. *Second phalanges* : *great toe*, extensor longus hallucis, and flexor longus hallucis ; *other toes*, one slip of the common tendon of the extensor longus and extensor brevis digitorum, and flexor brevis digitorum. *Third phalanges* : two slips of the common tendon of the extensor longus and extensor brevis digitorum, and the flexor longus digitorum.

SESAMOID BONES.

These are small masses, cartilaginous in early life, osseous in the adult, developed in those tendons which exert a certain degree of force upon the surface over which they glide, or where, by continued pressure and friction, the tendon would become a source of irritation to neighbouring parts, as to joints. The best example of a sesamoid bone is the patella, developed in the common tendon of the quadriceps extensor, and resting against the front of the knee-joint. Besides the patella, there are four pairs of sesamoid bones constantly found, two on the metacarpo-phalangeal articulation of each thumb, and existing in the tendons of insertion of the flexor brevis pollicis, and two on the corresponding joint in the foot, in the tendons of the muscles inserted into the base of the first phalanx. In addition to these there is often a sesamoid bone on the metacarpo-phalangeal joint of the little finger ; and on the corresponding joint in the foot, in the tendons inserted into the base of the first phalanx ; there is one also in the tendon of the peroneus longus muscle, where it glides through the groove in the cuboid bone ; sometimes in the tendons, as they wind around the inner and outer malleolus ; in the psoas and iliacus, where they glide over the os pubis ; and in the external head of the gastrocnemius.

The **bones of the tympanum**, as they belong to the apparatus of hearing, will be described with the anatomy of the ear.

PART III.

ARTHROLOGY.

ARTICULATIONS or joints are the means by which the bones of the skeleton are united together, the same terms being also applied to the union between cartilages when these are adapted for movement on each other, as, for instance, in the larynx. The connections between the bones may take place simply by the intervention of a small quantity of connective tissue, and the union be so close as to render movement impossible, forming an immovable joint, or **Synarthrosis**; or the bones may be widely separated, and the substance lying between them and connecting them together may be so yielding as to admit of a limited degree of movement in several directions, forming a yielding joint, or **Amphi-artrosis**. In all the articulations of the limbs, however, we find a more elaborate and perfect arrangement admitting of much freer motion, constituting a movable joint, or **Diarthrosis**. In the latter the expanded ends of the bones are coated by a thin layer of cartilage, are connected together by bands of fibrous tissue called *ligaments*, and are lubricated by the fluid secreted by a synovial membrane which lines the inner surface of the ligaments; in many joints, also, a disc of fibro-cartilage is interposed between the articular surfaces, and the cavity divided into two, the advantages of a double joint being thus secured.

The structures entering into the composition of a joint are bone, cartilage, areolar and adipose tissue, elastic tissue, fibrous tissue, and synovial membrane; the microscopic anatomy of these has been fully described in Part I. of this work, but it remains to point out their peculiar arrangement in the construction of joints.

The *articular ends of long bones* are expanded and rendered either concave or convex, so as to fit each other; they are formed of cancellous tissue with an outer thin coating of dense bone. This layer of compact bone is called the *articular lamella*; it is distinguished from ordinary bone by the absence of Haversian canals, the large size of the lacunæ, and by the canaliculi being few in number, and so short as not to communicate with those derived from neighbouring lacunæ. The vessels of the cancellous tissue do not penetrate the articular lamella, but turn back in loops before reaching it. In some places the bones are produced into projecting processes which

overhang the joint, affording protection against external injury, as well as giving greater leverage to the muscles; this arrangement may be noticed in the elbow, ankle, and wrist joints.

The *cartilage* found in joints is of two kinds, hyaline and fibro-cartilage. The former is known as true articular cartilage, or cartilage of incrustation; it coats the articular surfaces of the bones, and is generally so arranged as to increase the depth of articular cavities and the prominence of articular convexities, being in the one case thickest at its edges, and in the other in the middle. Fibro-cartilage is in amphiarthrodial joints the connecting medium binding the bones together; in diarthrodial joints it forms encircling bands which deepen the articular cavities, or it occurs as concave discs (interarticular fibro-cartilages) which divide the joint into two parts, each part having its own synovial membrane.

Areolar and *adipose tissue* are used for filling up the interstices in and around joints, so as to ensure the perfect adaptation of the articular surfaces to each other; in joints (such as the knee) which received little protection from the surrounding muscles, the amount of fat found among the ligaments and beneath the superficial fascia is relatively very large.

The *ligaments* which connect the bones together are for the most part formed of strong bands of white fibrous tissue, but in some few a slight admixture of yellow fibres may be observed, and those connecting the laminae of the vertebrae (ligamenta subflava) are entirely formed of yellow or elastic tissue. In the joints possessing the freest movement the ligaments form a fibrous envelope which entirely surrounds and encloses the articular surfaces—these are called *capsular ligaments*; in those enjoying the next degree of mobility the ligaments exist as flattened bands arranged in front, behind, and at the sides of the articulation. Some few joints have ligamentous bands in their interior; examples of these are the ligamentum teres of the hip and crucial ligaments of the knee; they are enclosed in a tube formed of synovial membrane.

The *synovial membrane* lines the whole of the interior of the joint, except where the articular cartilage is interposed; it is smooth and glistening on the inner surface, rough externally where it becomes attached to the bones and ligaments; it often forms folds, which project into the interior of the joint and contain masses of fat with loops of capillary vessels.

Besides the structures which form the joints, others also contribute to keep the articular ends of the bones in place, and to ensure due and smooth movement; of these the most important are the *muscles* and *bursae*. The muscles not only act as the agents of motion, but are of essential service in maintaining the structures of the joint in their proper relative position, supporting the ligaments by their tonic contraction, and in some instances acting directly on the synovial membrane so as to prevent its becoming squeezed between the ends of the bones. In the shoulder-joint the tendon of a muscle passes through the synovial cavity, and in both that joint and the knee the

tendons of certain muscles take the place of ligaments and are coated on their interior by synovial membrane.

Bursæ mucosæ are closed synovial sacs, the structure of which has been described on a previous page. Some of them lie between the tendons of muscles and the ligaments of joints, and in this position often communicate with the cavities of those joints; this being especially apt to occur with the bursa which lies between the capsule of the hip-joint and the united tendons of the psoas and iliacus. Bursæ occur (1) between tendons and bones, (2) between tendons and ligaments, (3) between superficial bony prominences and the fasciæ beneath the skin, (4) between contiguous tendons, and (5) between neighbouring bones. They are very numerous, about 140 being found in the human body. *Superficial bursæ* are constantly found in the following positions:—In the head and neck they occur on each angle of the lower jaw, beneath the symphysis of the jaw, and on the salient angle of the thyroid cartilage. In the upper extremity, over the acromion process, on the external and internal condyles of the humerus, on the back of the olecranon, the styloid processes of the radius and ulna, and the dorsal and palmar surfaces of the metacarpo-phalangeal joints. In the lower extremity they are found on the anterior superior spine of the ilium, over the great trochanter, on the tuberosity of the ischium, the lower half and the upper and outer angle of the patella, on the outer and inner condyles of the femur, the outer and inner tuberosities of the tibia, the head of the fibula, the outer and inner malleoli, the posterior and inner face of the os calcis, and the dorsal surface of the articulations of the toes. The *deep bursæ* lie between the tendons of muscles, or between the tendons and joints; these are even more numerous than the superficial ones, so that only a few of the more important will be mentioned here. These are the bursa beneath the deltoid, that between the tendon of the psoas and capsule of the hip-joint, one beneath the tendon of insertion of the triceps, one beneath the ligamentum patellæ, one between the gluteus maximus and vastus externus, one beneath the tendon of insertion of the biceps of the arm, and one between the tendon of insertion of the semi-membranosus and the inner head of the gastrocnemius. Besides these normal bursæ, other accidental or pathological ones are formed wherever there is great pressure, as, for instance, on the parts of the foot which come in contact with the ground in club-foot, and on the ends of stumps after amputation.

Blood-vessels.—The arteries distributed to a joint pass to all the structures excepting the cartilages, which are *non-vascular*; they frequently form fine circles round the edges of the cartilage, and are more especially abundant in the synovial membrane.

Nerves.—Hilton formulated a law regarding the distribution of nerves to joints, which is as follows:—“The same trunks of nerves, whose branches supply the groups of muscles moving a joint, furnish also a distribution of nerves to the skin over the insertion of the same muscle, and the interior of the joint receives its nerves from the same source.”

TABLE OF ARTICULATIONS.

I. SYNARTHROSIS.

	<i>Example.</i>
1. Suture	Tabular bones of skull.
2. Harmonia	Union of bones of face.
3. Schindylesis	Vomer with rostrum of sphenoid.
4. Gomphosis	Teeth with alveolar processes.

II. AMPHI-ARTHROSIS.

1. Complete union by fibro- cartilage	} Intervertebral substance.
2. Partial synovial cavity	
	} Symphysis pubis, and sacro-iliac joint.

III. DIARTHROSIS.

1. Arthrodia	} Sterno- and acromio-clavicular articulations.
2. Ginglymus	
3. Trochoides	} Odontoid process with atlas, and upper radio-ulnar joint.
4. Condylarthrosis	
5. Enarthrosis	} Metacarpo- and metatarso-phalangeal, wrist-joint.
	} Hip, shoulder.

SYNARTHROSIS (*σύν, ἄρθρωσις*, articulation) includes all those articulations in which there is no appreciable movement, the bones being united only by a small quantity of connective tissue, sometimes described under the name of the *sutural ligament*. This class of joints includes all the articulations of the bones of the skull and face, excepting those of the lower jaw. There are three kinds of synarthrosis; namely, Suture, Schindylesis, and Gomphosis.

Suture (*sutura*, a seam) is the name given to a joint in which the edges of the bone are projected into fine irregular processes, which fit into the intervals between corresponding processes in the bone with which it joins, somewhat like the dove-tail joint in cabinet-work. Between the bones so articulating there is a small quantity of connective tissue, which in the young skull is continuous with the pericranium on the outside, and with the dura mater on the inside. Three varieties of suture are distinguished,—the *Serrated*, *Harmonia*, and *Squamous*. The *serrated suture* is formed by the union of two borders possessing serrated edges, as in the coronal, sagittal, and lambdoidal sutures. In these sutures the serrations are formed almost wholly by the external table, the edges of the internal table lying merely in apposition. The serrated suture is formed by the interlocking of the radiating fibres along the edges of the flat

bones of the cranium during growth. A variation in the formation of the serrated suture is seen in the coronal suture, where the edge of the bone is bevelled at the expense of the inner table of the one bone, and of the outer table of the other at one part; and in another part these conditions are reversed. This condition is sometimes described under the name of *sutura limbosa*. The *harmonia suture* (*ἄρῆιν*, to adapt) is the simple apposition of contiguous surfaces, the surfaces being more or less rough. This suture is seen in the connection between the superior maxillary bones, or of the palate processes of the palate bone with each other. The *squamous suture* is formed by the overlapping of the lower border of the parietal bone, by the thin scale-like edge of the squamous portion of the temporal.

Schindylesis (*σχωδύλησις*, a fissure) is the reception of one bone into a sheath or fissure of another, as occurs in the articulation of the rostrum of the sphenoid with the vomer, or of the latter with the perpendicular plate of the ethmoid, and with the nasal crest of the superior maxillary and palate bones.

Gomphosis (*γόμφος*, a nail) is expressive of a union similar to that of a peg driven into a socket, and is used to describe the articulation of the teeth with the alveoli of the upper and lower jaws. The term is, however, misleading, as the teeth are not held in place simply by their impact, but by the fibrous tissue forming the alveolo-dental membrane.

AMPHI-ARTHROSIS (*ἀμφί*, both, *ἄρθρωσις*) is a joint intermediate in aptitude for motion between the immovable synarthrosis and the movable diarthrosis. Two forms of it are described, namely, those where the union takes place entirely by means of fibro-cartilage, without any joint cavity, and those where some part of the joint is formed by surfaces coated with articular cartilage, between which there is a small synovial cavity. Examples of the first are seen in the union between the bodies of the vertebræ, the sacrum with the coccyx, and the pieces of the sternum; and of the second, the sacro-iliac and pubic symphyses (*σὺν φνείν*, to grow together).

DIARTHROSIS (*διὰ*, through, *ἄρθρωσις*) is the movable articulation which constitutes by far the greater number of the joints of the body. The degree of motion in this class has given rise to a subdivision into five genera: Arthrodia, Ginglymus, Trochoides, Condylarthrosis, and Enarthrosis.

Arthrodia is the movable joint in which the extent of motion is slight and limited, as in the articulations of the clavicle, ribs, articular processes of the vertebræ, axis with the atlas, radius with the ulna, fibula with the tibia, carpal and metacarpal, tarsal and metatarsal bones. It is formed by the apposition of two nearly plane articular surfaces. The movement is very limited, but by bringing together a number of small bones articulated in this way, great pliability is obtained, as may be observed in the carpus.

Ginglymus (*γίγγλυμος*, a hinge), or hinge-joint, is the movement of bones upon each other in two directions only, viz., forwards and backwards; but the degree of motion may be very considerable.

Instances of this form of joint are numerous; they comprehend the elbow and phalangeal joints in the upper extremity; the knee, ankle, and phalangeal joints in the lower extremity. The articulation of the lower jaw exhibits an example of the combination of this form of joint with the preceding, the joint between the interarticular cartilage and eminentia articularis being arthro-dial, and that between the cartilage and the condyle ginglymous.

The form of the ginglymoid joint is somewhat quadrilateral, each of its four sides being provided with a ligament, which is named from its position, *anterior*, *posterior*, *internal lateral*, or *external lateral*. The *lateral ligaments* are thick and strong, and the chief bond of union between the bones. The *anterior* and *posterior* are thin and loose in order to permit the required extent of movement.

Trochoides or **lateral ginglymus** (*pivot-joint*) is a form of joint of which there exist only two examples in the human body, namely, the articulation of the anterior arch of the atlas and transverse ligament with the odontoid process of the axis, and the superior radio-ulnar joint. In the first of these a ring composed partly of bone and partly of ligament rotates round a pivot, in the second the rounded bone moves within a ring formed of ligamentous fibres; in both the movement is purely rotatory.

Condylarthrosis (*condyloid articulation*) is a variety of joint in which an ovoid condyle is received into an elliptical cavity, so as to permit of flexion, extension, abduction, adduction, and circumduction, but no axial rotation. Examples of this form are seen in the wrist-joint, and metacarpo-phalangeal and metatarso-phalangeal articulations.

Enarthrosis (*ἐν*, in, *ἄρθρωσις*) is the most extensive in its range of motion of all the movable joints. From the manner of connection and form of the bones in this articulation, it is called the ball-and-socket joint. There are two instances in the body, namely, the hip and the shoulder.

The ball-and-socket joint has a circular form; and, in place of the four distinct ligaments of the ginglymus, is enclosed in a bag of ligamentous membrane, called *capsular ligament*.

We may add to the preceding the carpo-metacarpal articulation of the thumb, although not strictly a ball-and-socket joint, from the great extent of motion which it enjoys, and from the nature of the ligament connecting the bones. Some authors make a special genus for this joint, under the title of *articulation by reciprocal surfaces*.

MOVEMENTS OF JOINTS.

The motions of joints may be referred to four heads, viz., Gliding, Angular movement, Circumduction, and Rotation.

1. **Gliding** is the simple movement of one articular surface on another, and exists to a greater or less extent in all the joints. In the least movable joints, as in the carpus and tarsus, this is the only motion which is permitted. Gliding is, in certain joints,

accompanied by what is known as *coaptation*, that is, the successive application of different parts of an articular surface to its fellow, in the manner of a wheel rolling on the ground. This is well seen in the motion of the patella on the condyles of the femur.

2. **Angular movement** may be performed in four different directions, either forwards and backwards, as in flexion and extension; or inwards and outwards, constituting adduction and abduction. Flexion and extension are illustrated in the ginglymoid joint, and exist in a large proportion of the joints of the body. Adduction and abduction, conjoined with flexion and extension, are met with complete only in the most movable joints, as the shoulder, hip, and thumb. In the wrist and ankle, adduction and abduction are only partial.

3. **Circumduction** is most strikingly exhibited in the shoulder and hip joints; it consists in the slight degree of motion which takes place between the head of a bone and its articular cavity, while the extremity of the limb is made to describe a large circle on a plane surface. It is also seen, but in a less degree, in the carpo-metacarpal articulation of the thumb, and the metacarpo-phalangeal articulation of the fingers and toes.

4. **Rotation** is the movement of a bone on its own axis, and is illustrated in the hip and shoulder, or better, in the rotation of the cup of the radius against the eminentia capitata of the humerus. Rotation is also observed in the movements of the atlas upon the axis, where the odontoid process serves as a pivot around which the atlas turns.

ARTICULATIONS.

The joints may be arranged, according to a natural division, into those of the trunk, those of the upper extremity, and those of the lower extremity.

LIGAMENTS OF THE TRUNK.

The articulations of the trunk are divisible into eleven groups, namely:—

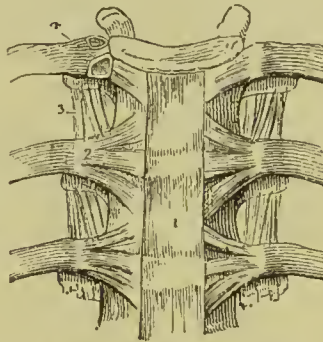
1. Of the vertebral column.
2. Of the atlas, with the occipital bone.
3. Of the axis, with the occipital bone.
4. Of the atlas, with the axis.
5. Of the lower jaw.
6. Of the ribs, with the vertebræ.
7. Of the costal cartilages, with the sternum, and with each other.
8. Of the ribs, with the costal cartilages.
9. Of the sternum.
10. Of the vertebral column, with the pelvis.
11. Of the pelvis.

1. **ARTICULATIONS OF THE VERTEBRAL COLUMN.**—The ligaments connecting together the different pieces of the vertebral column, admit of the same arrangement as the vertebræ themselves. Thus the ligaments

Of the bodies , are the	Anterior common ligament, Posterior common ligament, Intervertebral substance.
Of the arches ,	Ligamenta subflava.
Of the articular processes ,	Capsular ligaments, Synovial membranes.
Of the spinous processes ,	Inter-spinous, Supra-spinous.
Of the transverse processes ,	Inter-transverse.

BODIES.—The **anterior common ligament** is a broad and ribbon-like band of ligamentous fibres, extending along the front sur-

FIG. 147.—Anterior ligament of the vertebræ, and ligaments of the ribs. 1. Anterior common ligament. 2. Anterior costo-vertebral or stellate ligament. 3. Anterior costo-transverse ligament. 4. Interarticular ligament connecting the head of the rib to the intervertebral substance, and separating the two synovial membranes of this articulation.

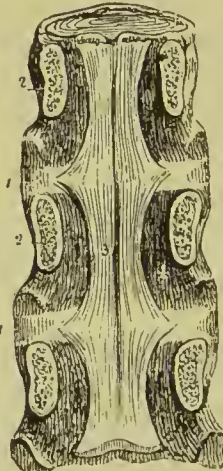


face of the vertebral column, from the axis to the sacrum, and becoming broader as it descends. It is intimately connected with the intervertebral substance, and less closely with the bodies of

the vertebræ. In the dorsal region it is thicker than in the cervical and lumbar, and consists of a median and two lateral portions separated from each other by a series of openings for the passage of vessels. The ligament is composed of fibres of various lengths

closely interwoven with each other; the *deeper* and shorter crossing the intervertebral substance from one vertebra to the next; the *superficial* and longer fibres crossing three or four vertebrae.

FIG. 148.—A posterior view of the bodies of three dorsal vertebræ, connected by their intervertebral substance, 1, 1. The laminae (2) have been sawn through near the bodies of the vertebræ, and the arches and processes removed, in order to show (3) the posterior common ligament. Part of one of the openings in the posterior surface of the vertebra, for the transmission of the vena basis vertebræ, is seen at 4, by the side of the narrow and unattached portion of the ligament.



The **posterior common ligament** is situated in the spinal canal; it lies on the posterior surface of the bodies of the vertebræ, and extends from the axis to the sacrum. It is broad

opposite the intervertebral substance, to which it is closely adherent; narrow and thick over the bodies of the vertebræ, from which it is

separated by the veins of the body of each vertebra ; it thus comes to present a festooned or dentate margin. It is composed, like the anterior ligament, of shorter and longer fibres, arranged in a similar manner. It is broader above than below, the reverse of the anterior common ligament, and is thicker in the dorsal than in the cervical or lumbar region. At its upper end it is continuous with the posterior occipito-axial ligament.

The **intervertebral substance** is a lenticular disc of fibro-cartilage, interposed between the bodies of the vertebræ from the axis to the sacrum, and retaining them firmly in connection with each other. The discs vary in thickness in different parts of the column and at different points of the same disc, being thickest in the lumbar region, deeper in front than behind in the cervical and lumbar regions, and contribute to the formation of the natural curves of the vertebral column. The aggregate thickness of the intervertebral substance has been estimated at one-fourth that of the entire vertebral column, exclusive of the sacrum and coccyx.

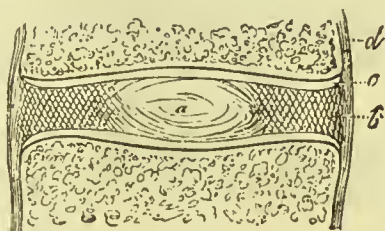


FIG. 149.—Diagram of an intervertebral disc divided vertically. At *a*, the pulpy centre ; at *b*, the fibrous ring ; at *c*, the cartilaginous covering of the body of the vertebra ; *d*, the periosteum.

When the intervertebral substance is bisected either horizontally or vertically, it is seen to be composed of a series of layers of fibro-cartilage mixed with fibrous tissue. The central part of each intervertebral disc is much softer than the rest ; it has the appearance of pulp, and is so elastic as to rise above the level of the section as soon as its division is completed. Examined from the exterior, the layers are found to consist of fibres passing obliquely between the two vertebræ, in one layer passing from left to right, in the next from right to left, alternating in each successive layer. Examined microscopically, the central pulp is found to be composed of fine fibrous tissue supporting cells some of which resemble those of cartilage ; it is generally regarded as a persistent part of the chorda dorsalis.

The central pulp and several layers of fibres surrounding it, are separated from the bone of the vertebral bodies by a thin layer of cartilage.

ARCHES.—The **ligamenta subflava** are two thin planes of yellow fibrous tissue, situated between the arches of the vertebræ, from the axis to the sacrum. From the imbricated position of the laminae, they are attached to the posterior surface of the vertebra below, and the anterior surface of the arch of the vertebra above, being separated from each other in the cervical region at the middle line by a slight interspace filled with areolar tissue. In the dorsal and lumbar regions they are continued for a little way on to the roots of the spinous processes, where they unite with the interspinous ligaments and with each other. They counteract, by their elasticity, the efforts

of the flexor muscles of the trunk ; and, preserving the upright position of the spine, limit the expenditure of muscular force. They are longest in the cervical and thickest in the lumbar region.

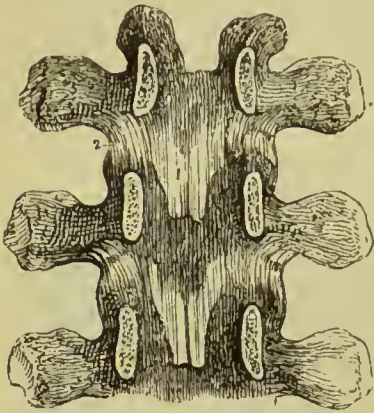


FIG. 150.—Internal view of the arches of three vertebrae. To obtain this view the laminae have been divided through their pedicles. 1. One of the ligamenta subflava. 2. The capsular ligament of one side.

The ligamenta subflava are continued in the cervical region on to the inner side, and in the dorsal and lumbar regions on to both anterior and inner sides of the articular processes, so as to form part of the capsules of the joints.

ARTICULAR PROCESSES.—The ligaments of the articular processes of the vertebrae are thin **capsules** of white and yellow fibres which surround and enclose the synovial membrane ; the latter being looser in the cervical than in the other regions of the spine.

SPINOUS PROCESSES.—The **interspinous ligaments**, thin and membranous, are extended between the spinous processes in the dorsal and lumbar region ; being thickest in the

latter. They are in *relation* with the interspinous muscles at each side.

The **supraspinous ligament** (Fig. 159) is a strong, fibrous cord, extending from the apex of the spinous process of the last cervical vertebra to the coccyx, and attached to each spinous process in its course. Like the anterior and posterior common ligaments, it is composed of fibres of unequal length, the deeper fibres passing from one vertebra to the next, the superficial fibres extending over several spinous processes. It is thickest in the lumbar region. The continuation of this ligament upwards to the tuberosity of the occipital bone, constitutes the rudimentary ligamentum nuchæ of man. The latter is strengthened, as in animals, by a thin slip from the spinous process of each cervical vertebra. At its lower termination the supraspinous ligament spreads out to cover the end of the spinal canal, exposed by the deficiency of the laminae of the lower sacral and coccygeal vertebrae.

TRANSVERSE PROCESSES.—The **intertransverse ligaments** are represented in the cervical region only by a few scattered fibres, in the dorsal region they are rounded cords, and in the lumbar region they are thin and membranous.

Movements of the Spine.—Flexion and extension take place freely in the cervical and lumbar regions, but especially in the latter ; in the dorsal region these movements are very slight in consequence of the imbrication of the laminae and the small amount of intervertebral substance. Rotation is free in the neck, but in consequence of the direction of the articular processes takes place round an oblique axis, the articular process of one side moving

upwards and forwards, while the other travels downwards and backwards. In the dorsal region rotation is free (especially in the upper part), the movement taking place round an axial line running through the centre of the vertebral bodies. The articular processes of the lumbar region are so disposed as to prevent anything like free rotation, but as the capsules are lax and the facets do not fit closely to each other, a slight degree of rotatory motion does take place. Lateral flexion may take place in any part of the spine, but is most free in the cervical and lumbar regions.

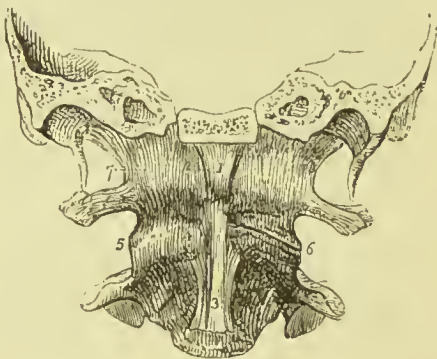
2. ARTICULATION OF THE ATLAS WITH THE OCCIPITAL BONE.

—The ligaments of this articulation are *seven* in number :—

Two anterior occipito-atlantal,	Two lateral occipito-atlantal,
Posterior occipito-atlantal,	Two capsular.

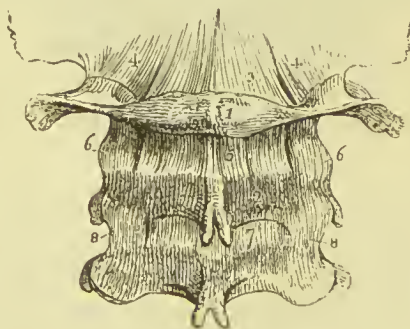
Of the two **anterior ligaments**, one is a *rounded cord*, situated in the middle line, and attached above to the basilar process of the

FIG. 151.—Anterior view of the ligaments connecting the atlas, axis, and occipital bone. A transverse section has been carried through the base of the skull, dividing the basilar process of the occipital bone and the petrous portion of the temporal bones. 1. Anterior round occipito-atlantal ligament. 2. Anterior broad occipito-atlantal ligament. 3. Commencement of the anterior common ligament. 4. Anterior atlanto-axial ligament, continuous inferiorly with the commencement of the anterior common ligament. 5. One of the atlanto-axial capsular ligaments; that on the opposite side has been removed to show the approximated surfaces of the articular processes (6). 7. One of the occipito-atlantal capsular ligaments. The most external of these fibres constitute the lateral occipito-atlantal ligament.



occipital bone; below, to the anterior tubercle of the atlas. The deeper ligament is a *broad* membranous layer, attached above to the margin of the occipital foramen, between the two condyles; and

FIG. 152.—Posterior ligaments of the occipito-atlantal and atlanto-axial articulations. 1. Atlas. 2. Axis. 3. Posterior ligament of the occipito-atlantal articulation. 4, 4. Capsular and lateral ligaments of this articulation. 5. Posterior ligament of the atlanto-axial articulation. 6, 6. Its capsular ligaments. 7. The first pair of ligamenta subflava; passing between the axis and third cervical vertebra. 8, 8. Capsular ligaments of those vertebrae.



below, to the whole length of the anterior arch of the atlas; it is continuous laterally with the capsular ligaments.

The **posterior ligament** is thin and membranous; attached above to the margin of the occipital foramen, between the two condyles;

and below, to the posterior arch of the atlas. It is closely adherent to the dura mater, by its inner surface; and forms a ligamentous arch at each side for the passage of the vertebral artery and first cervical nerve. It corresponds in its position to the ligamenta subflava of the other vertebræ, but it has no elastic fibres, being composed entirely of white fibrous tissue.

The two **lateral ligaments** are strong fasciculi of ligamentous fibres, attached below to the base of the transverse process of the atlas at each side; and above, to the transverse process of the occipital bone.

The **capsular ligaments** are thin and loose ligamentous capsules which surround the synovial membranes of the articulations between the condyles of the occipital bone and the superior articular processes of the atlas. The ligamentous fibres are most numerous on the anterior and external part of the articulation.

The **movements** taking place between the cranium and atlas are those of flexion and extension, giving rise to the forward nodding of the head; there is also a slight lateral movement to either side. When either of these actions is increased to any extent, the whole of the cervical region concurs in its production.

3. ARTICULATION OF THE AXIS WITH THE OCCIPITAL BONE.

—The ligaments of this articulation are *four* in number:—

Occipito-axial,

Three odontoid.

The **occipito-axial ligament** (*apparatus ligamentosus colli*) is a broad and strong band, which covers in the odontoid process and its ligaments. It is attached below to the body of the axis, where it

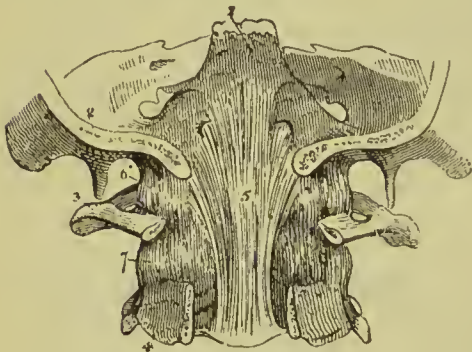


FIG. 153.—Upper part of the vertebral canal, opened from behind in order to show the occipito-axial ligament. 1. Basilar portion of the sphenoid bone. 2. Section of the occipital bone. 3. Atlas, its posterior arch removed. 4. Axis, posterior arch removed. 5. Occipito-axial ligament, rendered prominent at its middle by the projection of the odontoid process. 6. Lateral and capsular ligament of the occipito-atlantal articulation. 7. Capsular ligament of the articular process of the atlas and axis.

is continuous with the posterior common ligament; superiorly it is inserted by a broad expansion into the basilar groove of the occipital bone, where it is blended with the dura mater.

The **odontoid ligaments** (*alar* or *check ligaments*) are two short and thick fasciculi, which pass outwards from the apex of the odontoid process to the sides of the occipital foramen and condyles. A third and smaller fasciculus (*ligamentum dentis suspensorium*) proceeds from the apex of the odontoid process to the anterior margin of the foramen magnum.

These ligaments serve to limit the extent of rotation of the head ; hence they are termed *check* ligaments.

4. **ARTICULATION OF THE ATLAS WITH THE AXIS.**—The ligaments of this articulation are *five* in number :—

Anterior atlanto-axial,	Two capsular,
Posterior atlanto-axial,	Transverse.

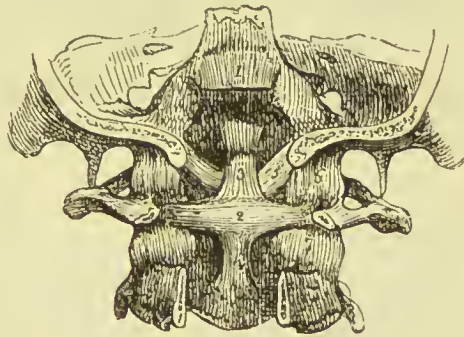
The **anterior ligament** consists of ligamentous fibres which pass from the anterior tubercle and arch of the atlas to the base of the odontoid process and body of the axis, where they are continuous with the commencement of the anterior common ligament. The fibres in the middle form a thick band which is tense in all positions of the joints ; the lateral portions are thin, and assist in limiting the rotation of the atlas on the axis.

The **posterior ligament** is a thin, membranous layer, passing between the posterior arch of the atlas and the laminae of the axis ; it represents the ligamenta subflava in a rudimentary state, and has on its deep or anterior surface a layer of dense elastic fibres, like those of the latter.

The **capsular ligaments** surround the articular process of the atlas and axis ; they are loose, to permit of the free movement which exists between these vertebrae. The ligamentous fibres are most numerous on the outer and anterior part of the articulation ; and the *synovial membrane* of each joint often communicates with the synovial cavity between the transverse ligament and odontoid process.

The **transverse ligament** is a strong ligamentous band, which arches across the area of the ring of the atlas from a rough tubercle

FIG. 154.—Posterior view of the ligaments connecting the atlas, axis, and occipital bone. The posterior part of the occipital bone has been sawn away, and the arches of the atlas and axis removed. 1. Superior part of the occipito-axial ligament, which has been cut away in order to show the ligaments beneath. 2. Transverse ligament of the atlas. 3, 4. Ascending and descending slips of the transverse ligament, which have obtained for it the title of cruciform ligament. 5. One of the lateral odontoid ligaments ; the fellow-ligament is seen on the opposite side. 6. One of the occipito-atlantal capsular ligaments. 7. One of the atlanto-axial capsular ligaments.



on the inner surface of one articular process to a corresponding tubercle on the other ; and serves to retain the odontoid process of the axis in connection with the anterior arch of the atlas. As it crosses the neck of the odontoid process, some fibres are sent downwards to be attached to the body of the axis, and others pass upwards to be inserted into the basilar process of the occipital bone ; hence the ligament has a cross-like appearance, and is termed *cruciform*. A *synovial membrane* is situated between the transverse ligament

and odontoid process; and another between that process and the anterior arch of the atlas.

Actions.—It is the peculiar disposition of the transverse ligament in relation to the odontoid process that enables the atlas, and with it the entire cranium, to rotate upon the axis; the perfect freedom of movement between these bones being ensured by the two synovial membranes. The lower part of the ring, formed by the transverse ligament with the atlas, is smaller than the upper, while the summit of the odontoid process is larger than its base; hence the process is retained in its place by the transverse ligament when the other ligaments are cut through. The extent to which rotation of the head upon the axis can be carried, is determined by the odontoid or check ligaments. The odontoid process with its ligaments is covered in by the occipito-axial ligament.

5. **TEMPORO-MAXILLARY ARTICULATION.**—The ligaments of this joint are the following:—

External lateral,
Two internal lateral,
Capsular,

Interarticular fibro-cartilage,
Stylo-maxillary ligament,
Two synovial membranes.

The **external lateral ligament** is a short and thick band of fibres, passing obliquely backwards from the tubercle of the zygoma, to the neck of the lower jaw. It is incorporated with the capsular ligament, and is, in relation, externally, with the integument of the face; internally, with the two synovial membranes of the articulation and the interarticular cartilage.

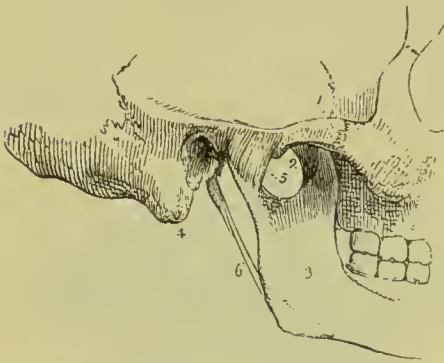


FIG. 155.—External view of the articulation of the lower jaw. 1. Zygomatic arch. 2. Tubercle of the zygoma. 3. Ramus of the lower jaw. 4. Mastoid portion of the temporal bone. 5. External lateral ligament. 6. Stylo-maxillary ligament.

The **short internal lateral ligament** has a broad attachment above to the outer part of the spine of the sphenoid, and is inserted below into the ridge on the inner side of the neck of the condyle. It is intimately connected with the capsule, and is separated from the long internal lateral ligament by fat and areolar tissue.

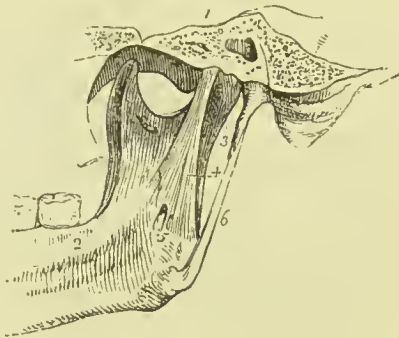The **long internal lateral ligament** (spheno-maxillary) is a thin aponeurotic expansion extending from the extremity of the spinous process of the sphenoid bone to the margin of the dental foramen; it is pierced at its insertion by the mylo-hyoidean nerve.

Between the internal lateral ligament and neck of the jaw is a triangular space, in which are situated the internal maxillary artery, auriculo-temporal nerve, inferior dental artery and nerve, and part

of the external pterygoid muscle; internally the ligament is in relation with the internal pterygoid muscle.

The middle meningeal artery in its upward course to the foramen

FIG. 156.—Internal view of the articulation of the lower jaw. 1. Section through the petrous portion of the temporal bone and spinous process of the sphenoid. 2. Internal surface of the ramus and body of the lower jaw. 3. Capsular ligament. 4. Long internal lateral ligament. 5. A small interval at its insertion through which the mylo-hyoidean nerve passes. 6. Stylo-maxillary ligament, a process of the deep cervical fascia.



spinosum, and the inferior dental nerve as it passes downwards to the dental canal, run along the outer side of this ligament.

The **capsular ligament** consists of numerous irregular ligamentous fibres, which pass from the edge of the glenoid cavity to the neck of the lower jaw, and surround the articulation. The capsule is thickest where it receives the accessory fibres called external and short internal lateral ligaments; it has inserted into it anteriorly a few fibres of the external pterygoid muscle.

The **interarticular fibro-cartilage** is a thin oval plate, thicker at the edges than in the centre, placed horizontally between the head of the condyle of the lower jaw and the glenoid cavity. Its upper surface is, from before backwards, concave anteriorly and slightly convex posteriorly, the former portion fitting the eminentia articularis, and the latter the glenoid cavity; its under surface is concave to receive the convex condyle. It is connected by its outer border with the external lateral ligament, and receives in front some fibres of insertion of the external pterygoid muscle. It divides the joint into two cavities, one being above, the other below, the cartilage; but it is occasionally incomplete in the centre.

The **synovial membranes** are situated, one above, the other below the fibro-cartilage, the former being the larger of the two. When the fibro-cartilage is perforated, the synovial membranes communicate.

Besides the lower jaw, there are several other joints provided

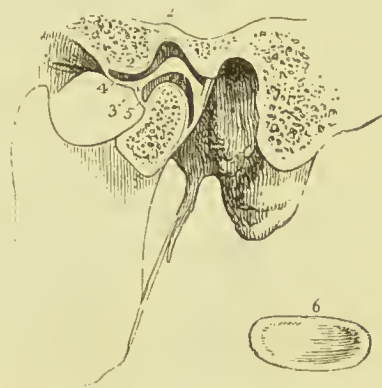

FIG. 157.—In this sketch a section has been made through the joint to show the position of the interarticular fibro-cartilage, and the manner of its adaptation to the articulating surfaces. 1. Glenoid fossa. 2. Eminentia articularis. 3. Interarticular fibro-cartilage. 4. Superior synovial cavity. 5. Inferior synovial cavity. 6. An interarticular fibro-cartilage, removed from the joint, in order to show its oval and concave form; it is seen from below.

with a complete interarticular cartilage, and, consequently, with two synovial membranes; they are—the *sterno-clavicular*, *acromio-clavicular*, and *the articulation of the ulna with the cuneiform bone*. The interarticular fibro-cartilages of the *knee-joint* are partial, and there is but one synovial membrane. The articulations of the heads of the ribs with the vertebræ have two synovial membranes separated by an interarticular ligament without fibro-cartilage.

Connected with the lower jaw, though not with the joint, is the **stylo-maxillary ligament**, a process of the deep cervical fascia extended between the point of the styloid process and the angle of the jaw. It is attached to the jaw between the insertions of the masseter and internal pterygoid muscle; it separates the parotid from the submaxillary gland, and gives attachment to some fibres of the stylo-glossus muscle.

Actions.—The movements of the lower jaw are—*depression*, by which the mouth is opened; *elevation*, by which it is closed; a *forward* and *backward* movement; and a movement from *side to side*.

In the movement of *depression* the interarticular cartilage glides forward on the eminentia articularis, carrying with it the condyle. In *elevation* the fibro-cartilage and condyle are returned to their original position. The *forward* and *backward* movement is a gliding of the fibro-cartilage on the eminentia articularis in the antero-posterior direction; and the movement from *side to side*, in the lateral direction. The articulation between the condyle and fibro-cartilage forms a true ginglymus or hinge-joint, that between the fibro-cartilage and eminentia articularis an arthro-dial or gliding joint.

The **arteries** of the temporo-maxillary joint are derived from the posterior auricular, anterior tympanic or internal maxillary, inferior or ascending palatine of facial, temporal, and middle meningeal.

The **nerves** are chiefly derived from the auriculo-temporal, but some filaments also come from the masseteric branch of inferior maxillary.

6. ARTICULATION OF THE RIBS WITH THE VERTEBRÆ.—

The ligaments of these articulations are remarkable for their strength, being in fact so strong as to render dislocation impossible; the neck of the rib must break before displacement could occur: they are divisible into two groups:—(1) Those connecting the *head of the rib* with the bodies of the *vertebræ*; and (2) Those connecting the *neck and tubercle of the rib* with the *transverse processes*.

1st Group.

Anterior costo-vertebral or stellate,
Capsular,
Interarticular ligament,
Two synovial membranes.

2nd Group.

Anterior costo-transverse,
Middle costo-transverse,
Posterior costo-transverse.

The **anterior costo-vertebral or stellate ligament** (costo-central, Fig. 147) consists of three short bands of ligamentous fibres which radiate from the anterior part of the head of the rib. The *superior band* passes upwards to be attached to the vertebra above;

the *middle fasciculus* is attached to the intervertebral substance ; the *inferior* to the vertebra below.

In the **first** rib the ligament is not divided, but its fibres pass to the body of the last cervical as well as the first dorsal. In like manner the ligaments connected with the **tenth, eleventh, and twelfth** ribs pass to the body of the vertebra above, as well as to that with which the head of the rib articulates.

The **capsular ligament** is a thin layer of ligamentous fibres surrounding the joint in the interval left by the anterior ligament ; it is thickest above and below the articulation, and protects the synovial membranes.

The **interarticular ligament** is a short band of fibres which passes between the sharp crest on the head of the rib and the intervertebral substance. It divides the joint into two cavities, each being furnished with a separate *synovial membrane*. The **first, tenth, eleventh, and twelfth** ribs have no interarticular ligament, and consequently but one synovial membrane.

The **anterior (or superior) costo-transverse ligament** is a broad band composed of two fasciculi, which ascend from the crest-like ridge on the neck of the rib, to the transverse process immediately above. The ligament separates the anterior from the dorsal branch of the intercostal nerve ; it is absent from the first rib.

The **middle costo-transverse ligament** is a strong interosseous ligament passing directly between the posterior surface of the neck of the rib, and the anterior surface of the transverse process against which it rests. It is rudimentary in the two inferior ribs.

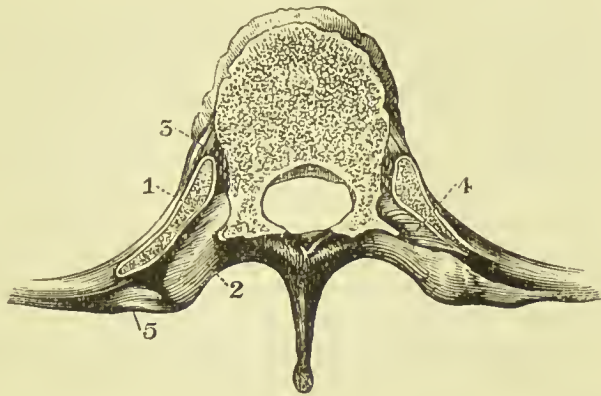


FIG. 158.—Transverse section of dorsal vertebra and heads of ribs. 1. Head of rib. 2. Transverse process of vertebra. 3. Anterior costo-vertebral or stellate ligament. 4. Interosseous costo-transverse ligament. 5. Posterior costo-transverse ligament.

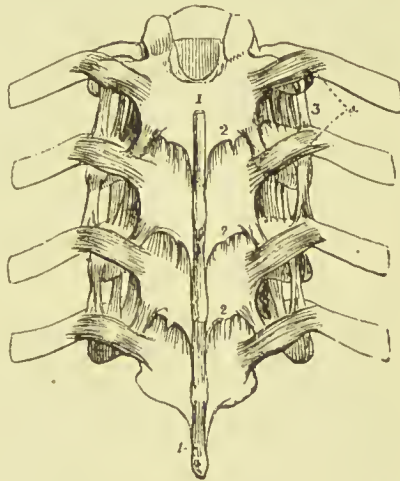


FIG. 159.—Posterior view of part of the dorsal portion of the vertebral column, showing the ligaments connecting the vertebrae with each other and the ribs with the vertebrae. 1, 1. Supraspinous ligament. 2, 2, 2. Ligamenta subflava, connecting the laminae. 3. Anterior costo-transverse ligament. 4. Posterior costo-transverse ligaments.

The **posterior costo-transverse ligament** is a small but strong fasciculus, passing obliquely from the tubercle of the rib to the apex of the transverse process. The articulation between the tubercle of the rib and the transverse process is provided with a small synovial membrane. This ligament is absent in the two last ribs.

Several accessory bands are found passing between the transverse processes and the ribs; a broad band of this kind connects the last rib with the transverse process of the first or second lumbar vertebra.

Actions.—The movements permitted by the articulations of the ribs are *upwards, downwards, and slightly forwards and backwards*; the movement increasing in extent from the head to the extremity of the rib. The forward and backward movement is trifling in the seventh superior, but greater in the inferior ribs; the eleventh and twelfth are very movable.

7. ARTICULATION OF THE COSTAL CARTILAGES WITH THE STERNUM, AND WITH EACH OTHER.—The ligaments of the chondro-sternal articulations are :—

Anterior chondro-sternal,	Superior chondro-sternal,
Posterior chondro-sternal.	Inferior chondro-sternal,
Synovial membranes.	

The **anterior chondro-sternal ligament** (anterior stellate ligament) is a thin band of ligamentous fibres, passing in a radiated direction from the extremity of the costal cartilage to the anterior surface of the sternum, and intermingling its fibres with those of the ligament of the opposite side, and with the tendinous fibres of origin of the pectoralis major muscle.

The **posterior chondro-sternal ligament**, much smaller than the anterior, consists of a thin fasciculus of fibres, situated on the posterior surface of the articulation.

The **superior and inferior chondro-sternal ligaments** are narrow fasciculi corresponding with the breadth of the cartilage, and connecting its superior and inferior border with the side of the sternum.

The **synovial membrane** is absent in the articulation of the first rib, its cartilage being usually adherent to the sternum; that of the second rib has an interarticular ligament, with two synovial membranes; the synovial membranes of the other costal cartilages are single.

The **sixth and seventh** ribs have several fasciculi of strong ligamentous fibres, passing from the extremity of their cartilages to the anterior surface of the ensiform cartilage, which latter they are intended to support. They are named the **chondro-xyphoid ligaments**.

The **sixth, seventh, and eighth**, and sometimes the **fifth** and the **ninth** costal cartilages, have articulations with each other, and a synovial membrane for each articulation. They are connected by ligamentous fibres (*ligamenta corruscantia*), which pass from one cartilage to the other.

The **ninth** and **tenth** are connected at their extremity by ligamentous fibres, but have no synovial membrane.

Actions.—The movements of the chondro-sternal articulations are very trifling, being limited to a slight degree of gliding motion. The first rib is the least, the second the most movable.

8. ARTICULATIONS OF THE RIBS WITH THE COSTAL CARTILAGES.—The anterior extremity of each rib is excavated, so as to receive the convex outer end of the costal cartilage; there is no true ligament, but the periosteum is prolonged on the cartilage, and takes the place of one. No motion takes place at this articulation.

9. ARTICULATIONS OF THE STERNUM.—The pieces of the sternum are connected by means of a thin plate of interosseous cartilage placed between each, and by an anterior and posterior ligament. The fibres of the **anterior sternal ligament** are longitudinal in direction, but so blended with the anterior chondro-sternal ligaments and tendinous fibres of origin of the pectoral muscles, as scarcely to be distinguished as a distinct ligament. The **posterior sternal ligament** is a broad smooth plane of longitudinal fibres, placed on the posterior surface of the bone, and extending from the manubrium to the ensiform cartilage. These ligaments contribute very materially to the strength of the sternum and elasticity of the front of the chest; their continuation downwards on the ensiform cartilage constitutes the **sterno-xyphoid ligaments**.

10. ARTICULATION OF THE VERTEBRAL COLUMN WITH THE PELVIS.—The last lumbar vertebra is connected with the sacrum by the same ligaments as those with which the various vertebræ are connected to each other: viz., anterior and posterior common ligament, intervertebral substance, ligamenta subflava, capsular ligament, interspinous and supraspinous ligament.

There are, however, *two* proper ligaments connecting the vertebral column with the pelvis; these are the

Sacro-lumbar,

Ilio-lumbar.

The **sacro-lumbar** or **sacro-vertebral ligament** is a thick triangular fasciculus of ligamentous fibres, connected above with the lower and front part of the transverse process of the last lumbar vertebra, and below with the upper border of the sacrum, becoming blended with the anterior sacro-iliac ligament.

The **ilio lumbar ligament** passes from the apex of the transverse process of the last lumbar vertebra to that part of the crest of the ilium which surmounts the sacro-iliac articulation. It is triangular in form, and gives origin to the quadratus lumborum and a few fibres of the iliacus muscle.

11. ARTICULATIONS OF THE PELVIS.—The ligaments of the articulations of the pelvis are divisible into four groups:—(1) Those connecting the *sacrum* and *ilium*; (2) those passing between the *sacrum* and *ischium*; (3) between the *sacrum* and *coccyx*; and (4) between the *two pubic bones*.

1st, *Between the sacrum and ilium.*

Anterior sacro-iliac,
Posterior sacro-iliac.

2nd, *Between the sacrum and ischium.*

Lesser sacro-ischiatic,
Greater sacro-ischiatic.

3rd, *Between the sacrum and coccyx.*

Anterior sacro-coccygean,
Posterior sacro-coccygean.

4th, *Between the pubic bones.*

Anterior pubic, Superior pubic,
Posterior pubic, Sub-pubic,
Interosseous fibro-cartilage.

1. BETWEEN THE SACRUM AND ILIUM.—This joint is commonly known as the *sacro-iliac synchondrosis*, but is sometimes called the *sacro-iliac symphysis*; it belongs to the class amphiarthrosis.

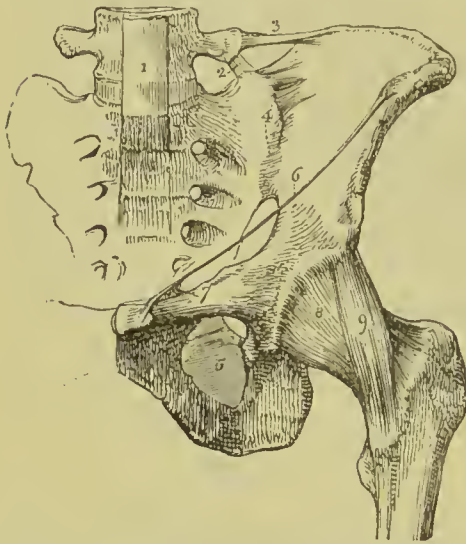


FIG. 160.—Ligaments of the pelvis and hip-joint. 1. Lower part of the anterior common ligament of the vertebræ, extending downwards over the front of the sacrum. 2. Sacro-lumbar ligament. 3. Ilio-lumbar ligament. 4. Anterior sacro-iliac ligament. 5. Obturator membrane. 6. Poupart's ligament. 7. Gimbernat's ligament. 8. Capsular ligament of the hip-joint. 9. Ilio-femoral or accessory ligament.

The **anterior sacro-iliac ligament** consists of numerous short ligamentous bands and fibres, which pass from bone to bone on the anterior surface of the joint.

The **posterior sacro-iliac or interosseous ligament** is composed of numerous strong fasciculi of ligamentous fibres, which pass horizontally between the rough surfaces of the *posterior half* of the sacro-iliac articulation, and constitute the principal bond of connection between the sacrum and ilium.

They are lodged in the hollow between the posterior surface of the sacrum and the backward projection of the ilium. One fasciculus of this ligament, longer and larger than the rest, is distinguished, from its direction, by the name of **oblique**

sacro-iliac ligament. It is attached, by one extremity, to the posterior superior spine of the ilium; and, by the other, to the third transverse tubercle on the posterior surface of the sacrum.

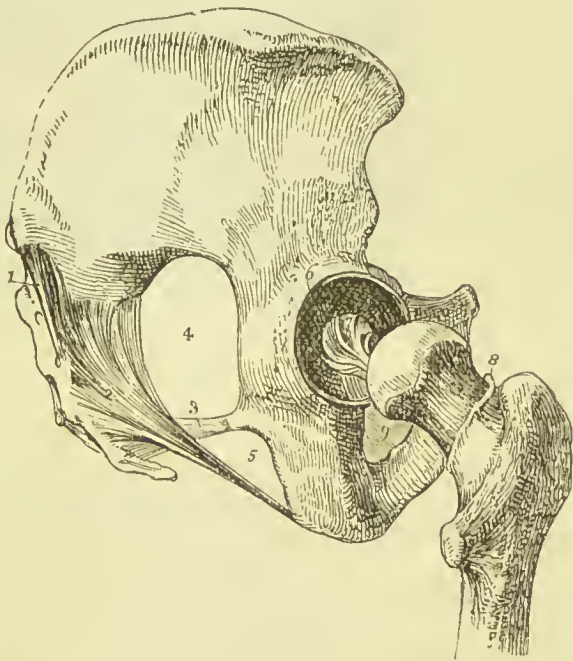
The surfaces of the two bones forming the sacro-iliac articulation are partly connected by cartilage, and partly rough and connected by the interosseous ligament. The **anterior or auricular half** is

coated by a layer of cartilage which binds the corresponding surfaces of the ilium and sacrum together; when the two bones are forcibly separated this cartilage sometimes adheres to the ilium, sometimes to the sacrum, and occasionally splits equally or unequally. In some instances there are two plates of cartilage with a small cavity between them, and this arrangement is more common in the female than in the male.

2. BETWEEN THE SACRUM AND ISCHIUM. — The **anterior or lesser sacro-ischiatic ligament** is thin and triangular in form; it is attached by its apex to the spine of the ischium, and by its broad extremity to the side of the sacrum and coccyx, interlacing its fibres with the greater sacro-ischiatic ligament. By its upper border it forms part of the lower boundary of the great sacro-ischiatic foramen, and by the lower, part of the lesser sacro-ischiatic foramen.

The **posterior or greater sacro-ischiatic ligament**, larger, thicker, and posterior to the preceding, is narrower in the middle

FIG. 161.—Ligaments of the pelvis and hip-joint, lateral view. 1. Oblique sacro-iliac ligament. The other fasciculi of the posterior sacro-iliac ligament are not seen in this view of the pelvis. 2. Greater sacro-ischiatic ligament. 3. Lesser sacro-ischiatic ligament. 4. Great sacro-ischiatic foramen. 5. Lesser sacro-ischiatic foramen. 6. Cotyloid ligament of the acetabulum. 7. Ligamentum teres. 8. Cut edge of the capsular ligament, showing its extent posteriorly, as compared with its anterior attachment. 9. Obturator mem-
branc, only partly scen.



than at each extremity. It is attached, by its smaller end, to the inner margin of the tuberosity and ramus of the ischium, where it forms a falciform process, which protects the internal pudic artery, and is continuous with the obturator fascia. By its larger extremity it is inserted into the side of the coccyx, sacrum, posterior inferior spine, and extremity of the crest of the ilium.

The greater sacro-ischiatic ligament is *in relation*, in front, with the lesser ligament; behind, with the gluteus maximus, to some fibres of which it gives origin. By its superior border it forms part of the boundary of the lesser ischiatic foramen, and, by its lower border, part of the boundary of the perinæum. It is pierced by the

coccygeal branch of the ischiatic artery. The two ligaments convert the sacro-ischiatic notches into foramina.

3. BETWEEN THE SACRUM AND COCCYX.—The **anterior sacro-coccygean ligament** is a thin fasciculus passing from the anterior surface of the sacrum to the front of the coccyx, and is continuous with the anterior common ligament.

The **posterior sacro-coccygean ligament** is a thick ligamentous layer, which completes the lower part of the sacral canal, and connects the sacrum with the coccyx posteriorly, extending as far as the apex of the latter bone. It is a direct continuation of the posterior common ligament, and becomes connected with the termination of

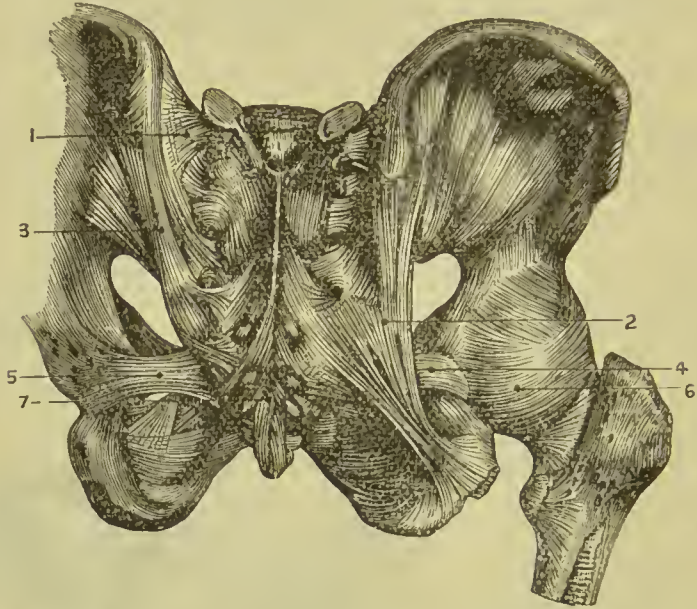


FIG. 162.—Ligaments of pelvis and hip-joint. 1. Posterior sacro-iliac ligament. 2. Great sacro-sciatic ligament. 3. Oblique sacro-iliac ligament. 4. Lesser sacro-sciatic ligament. 5. The same, exposed by the removal of the greater. 6. Back part of capsule of hip-joint. 7. Posterior sacro-coccygeal ligament.

the supraspinous ligament, and the filum terminale of the spinal cord.

Between the two bones is a thin intervertebral disc of fibro-cartilage; and in females not unfrequently a synovial membrane. The articulation admits of a certain degree of movement backwards during parturition.

The ligaments connecting the different pieces of the coccyx consist of a few scattered *anterior* and *posterior* fibres, and a thin disc of interosseous cartilage; the latter exists only in the young subject, as, in the adult, the pieces become ossified.

4. BETWEEN THE PUBIC BONES.—This articulation receives the name of *symphysis pubis*; it is an example of an amphiarthrodial joint.

The **anterior pubic ligament** is composed of ligamentous fibres,

which pass obliquely across the union of the two bones from side to side, and form an interlacement in front of the symphysis.

The **posterior pubic ligament** consists of a few irregular bands of fibres uniting the pubic bones posteriorly.

The **superior pubic ligament** is a thick band of fibres connecting the angles of the pubes superiorly, and filling the inequalities of the surface of the bones.

The **sub-pubic ligament** is a thick arch of fibres connecting the two bones inferiorly, and forming the upper boundary of the pubic arch.

The **interosseous fibro-cartilage** unites the two surfaces of the pubic bones in the same manner as the intervertebral substance connects the bodies of the vertebræ. It resembles the intervertebral substance also in being composed of oblique fibres disposed in concentric layers, which are more dense towards the surface than near the centre. It is thick in front, and thin behind; and a synovial membrane is found in the upper and posterior part of the articulation.

This articulation becomes movable towards the latter term of pregnancy, and admits of a slight degree of separation of its surfaces.

The **obturator membrane** is not a ligament of articulation, but simply a ligamentous membrane stretched across the obturator foramen. It gives attachment by its surfaces to the two obturator muscles, and leaves a space in the upper part of the foramen for the passage of the obturator vessels and nerve.

LIGAMENTS OF THE UPPER EXTREMITY.

The **ligaments of the upper extremity** may be arranged in the order of the articulations of the different bones; they are:—

- | | |
|-------------------------------------|---|
| 1. Sterno-clavicular articulation. | 8. Articulation between the carpal bones. |
| 2. Scapulo-clavicular articulation. | 9. Carpo-metacarpal articulations. |
| 3. Ligaments of the scapula. | 10. Metacarpo-phalangeal articulations. |
| 4. Shoulder-joint. | 11. Articulations of the phalanges. |
| 5. Elbow-joint. | |
| 6. Radio-ulnar articulations. | |
| 7. Wrist-joint. | |

1. **STERNO-CLAVICULAR ARTICULATION.**—The sterno-clavicular is an arthrodial articulation; its ligaments are:—

Anterior sterno-clavicular,	Inter-clavicular,
Posterior sterno-clavicular,	Costo-clavicular (<i>rhomboid</i>),
	Interarticular fibro-cartilage,
	Two synovial membranes.

The **anterior sterno-clavicular ligament** is a broad ligamen-

tous layer extending obliquely downwards and inwards, and covering the anterior aspect of the articulation. This ligament is *in relation* by its anterior surface with the integument and sternal origin of the sterno-mastoid muscle; and behind with the inter-articular fibro-cartilage and synovial membranes.

The **posterior sterno-clavicular ligament** is a broad band covering the posterior surface of the articulation. It is *in relation*

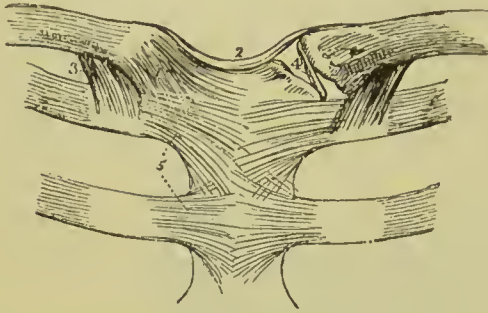


FIG. 163.—Ligaments of the sternoclavicular and chondrosternal articulations. 1. Anterior sternoclavicular ligament. 2. Interclavicular ligament. 3. Costoclavicular or rhomboid ligament, seen on both sides. 4. Interarticular fibro-cartilage, brought into view by the removal of the anterior and posterior ligaments. 5. Anterior chondro-sternal ligaments of the first and second ribs.

by its anterior surface with the interarticular fibro-cartilage and synovial membranes; and behind, with the sterno-hyoid and sterno-thyroid muscle.

The anterior and posterior sternoclavicular ligaments, together with a few short fibres connecting the bones above, are sometimes described as forming one ligament, which is then called *capsular*.

The **inter-clavicular ligament** is a cord-like band which crosses from the extremity of one clavicle to that of the other, and is closely adherent to the upper border of the sternum.

The **costo-clavicular** or **rhomboid ligament** is a thick fasciculus of fibres, connecting the sternal extremity of the clavicle with the cartilage of the first rib. It is placed obliquely between the rib and under surface of the clavicle; and is *in relation*, in front, with the tendon of origin of the subclavius muscle, and behind with the subclavian vein.

The **interarticular fibro-cartilage** is nearly circular in form, and thicker at the edges than in the centre. It is attached above, to the clavicle; below, to the cartilage of the first rib; and throughout the rest of its circumference, to the anterior and posterior sternoclavicular ligaments. It divides the joint into two cavities, which are lined by separate *synovial membranes*; is sometimes pierced through its centre, and not unfrequently deficient, to a greater or less extent, at its lower part.

One of the **synovial cavities** lies between the end of the clavicle and interarticular cartilage, the other between the sternum and the cartilage; the former is more loose than the latter.

Actions.—The movements of the sternoclavicular articulation are—a *gliding movement* of the clavicle on the fibro-cartilage, or of the latter on the sternum, in the directions forward, backward, upward, and downward; and *circumduction*. The upward and downward movements take place between the clavicle and inter-

articular cartilage, the forward and backward movements between the cartilage and the sternum ; in circumduction the two portions of the articulation alternately take part in the movement. The upward movement is limited by the rhomboid ligament, the downward movement by the inter-clavicular ligament. This articulation is the centre of the movements of the shoulder.

2. **SCAPULO-CLAVICULAR ARTICULATION.**—The ligaments of the scapular end of the clavicle are :—

Superior acromio-clavicular,
 Inferior acromio-clavicular,
 Coraco-clavicular (*trapezoid* and *conoid*),
 Interarticular fibro-cartilage,
 Two synovial membranes.

The **superior acromio-clavicular ligament** is a moderately thick plane of fibres passing between the extremity of the clavicle and the acromion, on the upper surface of the joint. It is strengthened by the tendinous fibres of the trapezius and deltoid, and on its deep surface is connected with the inter-articular cartilage.

The **inferior acromio-clavicular ligament** is a thin plane situated on the under surface. These two ligaments are continuous with each other in front and behind, and form a *capsule* around the articulation.

The **interarticular fibro-cartilage** is often indistinct, from having partial connections with the cartilaginous surfaces of the two bones between which it is placed, and is frequently absent. When partial, it occupies the upper part of the articulation. The *synovial membranes* are thin ; and when the fibro-cartilage is incomplete, there is but one.

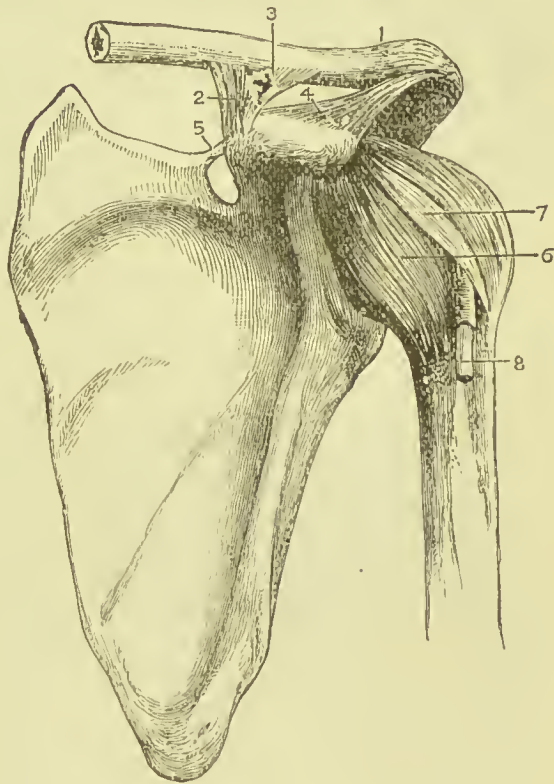


FIG. 164.—Ligaments of the scapula and shoulder-joint. 1. Superior acromio-clavicular ligament. 2. Coraco-clavicular ligament ; this aspect of the ligament is named trapezoid. 3. Trapezoid portion of the same ligament. 4. Coraco-acromial ligament. 5. Transverse ligament. 6. Capsular ligament. 7. Coraco-humeral ligament. 8. The long tendon of the biceps issuing from the capsular ligament, and entering the bicipital groove.

The **coraco-clavicular ligament** is a thick fasciculus of ligamen-

tous fibres, passing obliquely between the base of the coracoid process and the under surface of the clavicle, and holding the end of the clavicle in firm connection with the scapula. It is divisible into two parts, an anterior and external called **trapezoid**, and a posterior and internal called **conoid**. The trapezoid portion is seen best from the front; it is attached below to the upper surface of the coracoid process and above to the oblique line on the under surface of the clavicle; its anterior border is free, its posterior joins with the conoid portion. The conoid ligament has its base directed upwards and attached to the conoid tubercle on the under surface of the clavicle; its apex is inserted into a rough process at the base of the coracoid process of the scapula.

Actions.—The acromio-clavicular articulation admits of two movements, *gliding* of the surfaces on each other, and *rotation* of the scapula on the extremity of the clavicle, the extent of this rotation being limited by the two parts of the coraco-clavicular ligament.

Bursæ.—There are commonly *three* bursæ in connection with this articulation; one in the recess between the trapezoid and conoid ligaments, one between the base of the coracoid process and apex of the conoid ligament, and the third between the coraco-acromial ligament and the capsule of the shoulder-joint.

3. The **PROPER LIGAMENTS OF THE SCAPULA** are:—

Coraco-acromial,

Transverse.

The **coraco-acromial ligament** is a broad and thick triangular band, which forms a protecting arch over the shoulder-joint. It is attached by its apex to the point of the acromion process, and by its base to the external border of the coracoid process its whole length. This ligament is *in relation* above with the clavicle and under surface of the deltoid muscle; and below with the tendon of the supra-spinatus muscle, a bursa mucosa being usually interposed.

The **transverse** or **coracoid ligament** (supra-scapular) is a narrow but strong fasciculus which crosses the notch in the upper border of the scapula, from the base of the coracoid process, and converts it into a foramen. The supra-scapular nerve passes through this foramen, the artery and veins over it. The omo-hyoid muscle takes origin from this ligament.

Movements of the Scapula.—The mobility of the scapula is very great; it takes place in upward, downward, forward, and backward directions, and by a combination of all these as a modified circumduction. In the forward and backward movements the scapula glides over the chest wall, carrying the clavicle with it, and being kept in apposition with the chest by the latissimus dorsi muscle. In raising the arm at the shoulder, the deltoid and supra-spinatus can only raise it to a right angle with the trunk; elevation above that is effected by the rotation of the scapula on the chest wall by the trapezius, the glenoid cavity being directed upwards and forwards. The rotation movement commences at the very beginning

of lifting the arm, and not (as was formerly supposed) when the arm has reached the level of the shoulder.

4. **SHOULDER-JOINT.**—The scapulo-humeral articulation is an enarthrosis, or ball-and-socket joint; its ligaments are :—

Capsular,	Coraco-humeral,	Glenoid,
	Gleno-humeral.	

The **capsular ligament** encloses the articulating head of the scapula and head of the humerus, and is attached above to the neck of the scapula externally to the glenoid ligament, and to the root of the coracoid process; on the humerus it is attached to the upper half of the anatomical neck, but below it passes farther from the articular surface, some of its deeper fibres being, however, reflected upwards to terminate at the articular margin, much in the same way as fibres are reflected on the neck of the femur in the hip. It is thick above, where resistance is most required, and strengthened by the tendons of the supra-spinatus, infra-spinatus, teres minor, and subscapularis muscles: below it is thin and loose. The tendons of all the muscles in contact with the capsule except the subscapularis can be readily separated from it by careful dissection, but the latter either has beneath it a bursa which communicates with the cavity of the joint, or is itself united with the capsule and lined by the synovial membrane of the articulation.

The **coraco-humeral ligament** is a broad band which descends obliquely outwards from the border of the coracoid process to the greater tuberosity of the humerus, and serves to strengthen the superior and anterior part of the capsular ligament; it assists the latter in bridging over the bicipital groove.

The **gleno-humeral ligament** (*ligament of Flood*) is an accessory slip of fibres which projects into the joint along the inner edge of the biceps tendon, and is inserted into the upper part of the bicipital groove. It is supposed to be the homologue of the ligamentum teres in the hip-joint.

The **glenoid ligament** is the prismoid band of fibro-cartilage, which is attached around the margin of the glenoid surface for the purpose of protecting its edge and deepening its cavity. It divides superiorly into two slips which are continuous with the long tendon of the biceps;

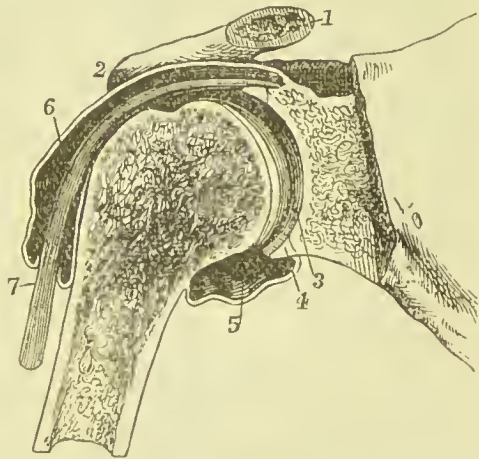


FIG. 165.—Section through the shoulder-joint. 1. The cut end of the clavicle. 2. Acromial end of the clavicle. 3. Articular surface of the glenoid cavity covered with cartilage. 4. Cross section of the glenoid ligament. 5. Lower part of capsule and synovial sac. 6. Synovial membrane prolonged on biceps tendon. 7. Tendon of biceps muscle.

hence the ligament is sometimes described as being formed by the splitting of that tendon. The cavity of the articulation is traversed by the long tendon of the biceps, which is enclosed in a sheath of synovial membrane in its passage through the joint.

The **synovial membrane** of the shoulder-joint is extensive ; it communicates anteriorly through an opening in the capsular ligament with a large bursal sac, which lines the under surface of the tendon of the subscapularis muscle. Superiorly it frequently communicates through another opening in the capsular ligament with a bursal sac belonging to the infra-spinatus muscle ; and it moreover forms a sheath around that portion of the tendon of the biceps which is included within the joint.

Capsular Muscles.—The muscles immediately surrounding the shoulder-joint are—the subscapularis, supra-spinatus, infra-spinatus, teres minor, long head of the triceps, and deltoid ; the long tendon of the biceps is within the capsular ligament.

Actions.—The shoulder-joint is capable of every variety of motion—viz., of movement forwards and backwards, of abduction and adduction, of circumduction and rotation. The great freedom of movement which this joint enjoys depends on the laxity of the capsule and the large size of the head of the humerus in comparison with the depth of the glenoid cavity. The capsule is so loose that if an opening be made in it the humerus will fall about an inch from the scapula, showing that the articular surfaces are not kept in contact by the fibres of the capsule, but by atmospheric pressure.

Bursæ.—The bursæ in connection with this joint are *four* in number : one between the subscapularis tendon and the capsule and neck of the scapula ; a second one between the capsule and the tendon nearer to the insertion of the latter ; a third between the tip of the coracoid process and the capsule ; and a fourth between the combined origins of the biceps and coraco-brachialis and the capsule.

Nerve-supply.—Branches of the circumflex and supra-scapular nerves.

5. **ELBOW-JOINT.**—The elbow is a ginglymus or hinge-joint ; and its ligaments *four* in number, namely :—

Anterior,	Internal lateral,
Posterior,	External lateral.

The **anterior ligament** is a broad and thin membranous layer, descending from the anterior surface of the humerus immediately above the coronoid and radial fossæ to the coronoid process of the ulna and orbicular ligament. It is connected on each side with the lateral ligaments, and is composed of fibres which pass in three different directions, vertical, transverse, and oblique, the latter being extended downwards and outwards to the orbicular ligament, into which they are inserted inferiorly. This ligament is covered in by the brachialis anticus muscle.

The **posterior ligament** is a broad and loose layer passing transversely across the olecranon fossa, and from the sides of the fossa to the base of the olecranon ; it is connected at each side with the lateral ligaments. It is covered in by the tendon of the triceps.

The **internal lateral ligament** is a thick triangular layer, attached above, by its apex, to the internal condyle of the humerus ; and below, by its expanded border, to the margin of the greater sigmoid cavity of the ulna, extending from the coronoid process to the olecranon. At its insertion it is intermingled with some transverse fibres ; and posteriorly is in relation with the ulnar nerve.

The **external lateral ligament** is a strong and narrow band which descends from the external condyle of the humerus, to be inserted into the orbicular ligament and the ridge on the ulna with which the posterior part of the latter ligament is connected. The ligament is closely united with the tendon of origin of the supinator brevis muscle.

The four preceding ligaments are sometimes described as one under the name of *capsular ligament*.

The **synovial membrane** is extensive, and is reflected from the margins of the cartilaginous surfaces of the bones upon the inner surface of the

ligaments. It forms an articulating sac between the head of the radius and the lesser sigmoid notch of the ulna.

The muscles immediately surrounding and in contact with the elbow-joint are—*in front*, brachialis anticus ; *inner side*, pronator radii teres, flexor sublimis digitorum, and flexor carpi ulnaris ; *externally*, extensor carpi radialis brevis, extensor communis digitorum, ex-

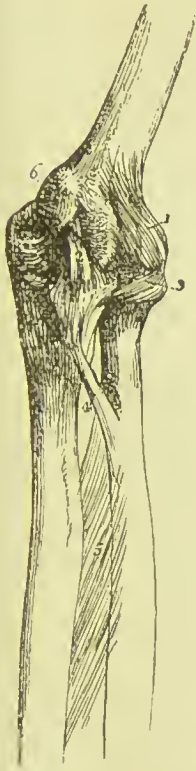

FIG. 166.—Ligaments of the elbow-joint, inner side. 1. Anterior ligament. 2. Internal lateral ligament. 3. Orbicular ligament. 4. Oblique ligament. 5. Interosseous membrane. 6. Internal epicondyle of the humerus, which conceals the posterior ligament.



FIG. 167.—External view of the elbow-joint. 1. Humerus. 2. Ulna. 3. Radius. 4. External lateral ligament inserted inferiorly into (5) the orbicular ligament. 6. Posterior extremity of the orbicular ligament, spreading out at its insertion into the ulna. 7. Anterior ligament, scarcely apparent in this view of the articulation. 8. Posterior ligament, thrown into folds by the extension of the joint.

tensor carpi ulnaris, anconeus, and supinator brevis ; *behind*, triceps and anconeus.

Nerves.—The chief supply of the joint is derived from the ulnar nerve, but it also receives twigs from the muscular-cutaneous and median.

Actions.—The movements of the elbow-joint are *flexion* and *extension*. These movements are oblique, so that the forearm is inclined inwards in flexion and outwards in extension. Flexion is limited by the meeting of the soft parts of the arm and forearm, and extension by the muscles and ligaments on the front of the joint becoming tense ; these effects being produced before the coronoid and olecranon processes reach the bottom of their respective fossæ.

Bursæ.—The bursæ in connection with this joint are only *three* in number : the first of these lies between the tendons of the extensor carpi radialis brevis and extensor communis digitorum, and the external lateral ligament ; the second between the olecranon and posterior ligament ; and the third between the olecranon and the superficial structures.

6. **RADIO-ULNAR ARTICULATION.**—The radius and ulna are firmly held together by ligaments, connected with both extremities of the bones, and with the shaft ; they are :—

Orbicular,	Anterior inferior radio-ulnar.
Oblique,	Posterior inferior radio-ulnar.
Interosseous,	Interarticular fibro-cartilage.

The **orbicular ligament** (**annular, coronary**) is a firm band, several lines in breadth, which surrounds the head of the radius, and is attached by each end to an extremity of the lesser sigmoid cavity. Some of the lower fibres are continued round beneath the sigmoid cavity so as to form a complete circle. It is strongest behind where it receives the external lateral ligament, and is lined on its inner surface by a reflection of the synovial membrane of the elbow-joint ; it gives attachment to fibres of the supinator brevis muscle.

The **oblique ligament** is a narrow slip of ligamentous fibres, descending obliquely from the base of the coronoid process of the ulna to the inner side of the radius, a little below its tuberosity. Its fibres run in the opposite direction to those of the interosseous membrane.

The **interosseous membrane** is a broad and thin plane of aponeurotic fibres passing obliquely downwards from the sharp ridge on the radius to that on the ulna. It is deficient superiorly, broader in the middle than at each extremity, and perforated at its lower part for the passage of the anterior interosseous artery. The posterior interosseous artery passes backwards between the oblique ligament and upper border of the interosseous membrane.

The interosseous membrane affords an extensive surface for the attachment of muscles ; and is *in relation, in front*, with the flexor profundus digitorum, flexor longus pollicis, pronator quadratus, and

anterior interosseous artery and nerve; *behind*, with the supinator brevis, extensor ossis metacarpi pollicis, extensor primi internodii pollicis, extensor secundi internodii pollicis, extensor indicis, and near the wrist with the anterior interosseous artery and posterior interosseous nerve.

The **anterior inferior radio-ulnar ligament** is a thin band of fibres, passing transversely between the *anterior surface* of the lower end of the radius and ulna.

The **posterior inferior radio-ulnar ligament**, also thin and loose, has the same disposition on the posterior surface of the articulation.

The **triangular interarticular fibro-cartilage** acts the part of a ligament between the lower extremity of the radius and ulna. It is inserted by its apex into a depression on the inner surface of the styloid process of the ulna, and attached by its base to the edge of the radius. This fibro-cartilage is lined on the upper surface by a synovial membrane, which forms a remarkably loose capsule between the radius and ulna, and is called the *membrana sacciformis*. By its lower surface it enters into the articulation of the wrist-joint.

Actions.—The movements taking place between the radius and ulna are—rotation of the former upon the latter, rotation forwards being termed *pronation*, and rotation backwards *supination*; in the former the palm of the hand comes to be directed downwards, in the latter it looks upwards. In these movements the head of the radius turns upon its axis, within its orbicular ligament and lesser sigmoid notch of the ulna; while inferiorly, the radius presents a concavity which moves on the rounded head of the ulna. The ulna also moves, although in much less degree, in a direction opposite to that of the radius; this movement depends chiefly on rotation at the shoulder-joint, and to some extent on a laxity of the elbow-joint. The movements of the radius are chiefly limited by the anterior and posterior inferior ligaments; hence these are not unfrequently ruptured in great muscular efforts.

7. **WRIST-JOINT.**—The wrist is a condyloid articulation; the articular surfaces entering into its formation being the radius and

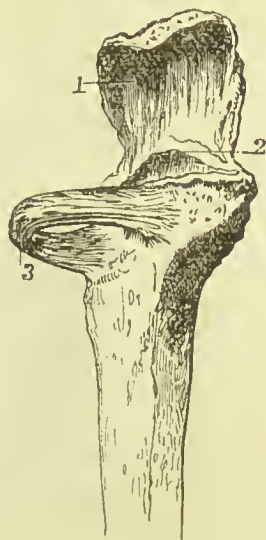


FIG. 168.—Upper part of ulna and orbicular ligament. 1. Olecranon. 2. Tip of coronoid process. 3. Orbicular ligament.

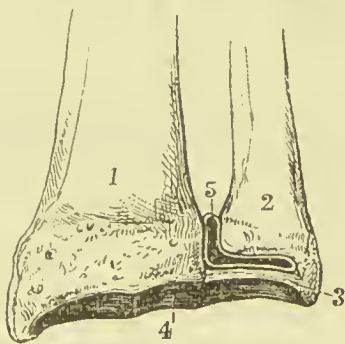


FIG. 169.—Lower end of radius and ulna, with articular surfaces. 1. Radius. 2. Ulna. 3. Interarticular fibro-cartilage. 4. Articular end of radius. 5. Membrana sacciformis.

triangular fibro-cartilage above, and the rounded surface of the scaphoid, semilunar, and cuneiform bones below; its ligaments are *four* in number:—

Anterior,
Posterior,

Internal lateral,
External lateral.

The **anterior ligament** is a broad and membranous layer consisting of three fasciculi, which pass downwards and inwards between the anterior margin of the lower end of the radius and the scaphoid, semilunar, and cuneiform bones.

It is pierced by numerous small openings for vessels, and has lying in front of it the tendons of the flexor profundus digitorum and flexor longus pollicis.

The **posterior ligament**, also thin and loose, passes downwards and inwards between the posterior surface of the radius and the posterior surface of the scaphoid, semilunar, and cuneiform bones.

The **internal lateral ligament** extends from the styloid process of the ulna to the cuneiform and pisiform bones.

The **external lateral ligament** is attached by one extremity to the styloid process of the radius, and by the other to the side of the scaphoid bone, some of its fibres being prolonged to the trapezium and anterior annular ligament. The radial artery rests on this ligament as it passes backwards to the first metacarpal space.

Actions.—The movements of the wrist-joint are *flexion*, *extension*, *adduction*, *abduction*, and *circumduction*: no rotation takes place at this joint.

Nerve-supply.—The ulnar and posterior interosseous.

Bursæ.—The bursæ in connection with this joint chiefly take the form of synovial sheaths for the tendons; those more immediately in relation with the ligaments are as follows:—One between the tendon of the flexor longus pollicis and the anterior ligament, one between the flexor profundus tendons and the same ligament, a third of rounded form between the tendon of the flexor carpi ulnaris

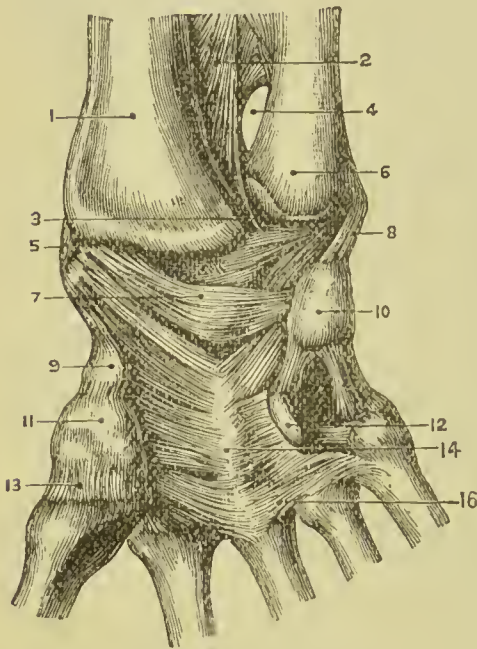


FIG. 170.—1. Radius. 2. Interosseous membrane. 3. Articulation between lower end of ulna and interarticular fibro-cartilage opened. 4. Space for anterior interosseous artery. 5. External lateral ligament of wrist. 6. Lower end of ulna. 7. Anterior ligament of wrist. 8. Internal lateral ligament of wrist. 9. Tubercle of scaphoid. 10. Pisiform bone. 11. Trapezium. 12. Hook of unciform bone. 13. Articulation between trapezium and first metacarpal. 14. Anterior ligament of carpus. 15. Intermetacarpal and carpo-metacarpal ligaments.

and the internal lateral ligament, a fourth separating the radial extensors from the posterior ligaments, a fifth beneath the tendons of the common extensor, and a sixth beneath the tendon of the extensor carpi ulnaris.

8. ARTICULATIONS BETWEEN THE CARPAL BONES.—These are arthrodial joints, with the exception of the conjoined head of the os magnum and unciform, which is received into a cup formed by the scaphoid, semilunar, and cuneiform bone, and constitutes an enarthrosis. The ligaments are :—

Dorsal,	Interosseous fibro-cartilages,
Palmar,	Annular.

The **dorsal ligaments** are ligamentous bands that pass transversely and longitudinally from bone to bone on the dorsal surface of the carpus.

The **palmar ligaments** are fasciculi of the same kind, but stronger than the dorsal, having the like disposition on the palmar surface.

The **interosseous ligaments** are fibro-cartilaginous lamellæ situated between the adjoining bones in each range : in the upper range they close the upper part of the space between the scaphoid, semilunar, and cuneiform bones ; in the lower range they are stronger than in the upper, and connect the os magnum on the one side to the unciform, on the other to the trapezoid, leaving intervals through which the synovial membrane is continued to the bases of the metacarpal bones.

The **anterior annular ligament** is a firm ligamentous band, which connects the bones of the two sides of the carpus. It is attached by one extremity to the trapezium and scaphoid, by the other to the unciform process of the unciform and base of the pisiform bones, and forms an arch over the anterior surface of the carpus, beneath which the tendons of the long flexors and the median nerve pass into the palm of the hand.

The **posterior annular ligament** is a flattened band of fibrous tissue about half an inch in breadth, passing across from the lower end and styloid process of the radius to the cuneiform, pisiform, and base of the fifth metacarpal. It assists the posterior ligament of the wrist-joint in binding the hand to the forearm, and in carrying the hand with the radius in pronation. A more complete description of this ligament and the preceding will be found in the section on the muscles and fasciæ.

The **articulation of the pisiform bone** with the cuneiform is provided with a separate synovial membrane, protected by fasciculi of ligamentous fibres, which form a kind of capsule around the joint, and are inserted into the cuneiform bone. This bone is also connected with the unciform and base of the metacarpal of the little finger by two strong fibrous bands.

Synovial Cavities.—There are *five* synovial cavities between the articulations of the carpus :—

The *first* is situated between the lower end of the ulna and the

interarticular fibro-cartilage; it has been described above, and is called *sacciform*, on account of forming a sacculus between the ulna and radius.

The *second* is situated between the lower surface of the radius and interarticular fibro-cartilage *above*, and the first range of bones of the carpus *below*.

The *third*, the most extensive of the synovial cavities of the wrist, is situated between the two rows of carpal bones, and passes between the bones of the first and between those of the second range, also between the carpal extremities of the four metacarpal bones of the fingers.

The *fourth* is the synovial cavity of the articulation of the metacarpal bone of the thumb with the trapezium.

The *fifth* is situated between the pisiform and cuneiform bones.

Actions.—Very little movement exists between the bones in each range, but more is permitted between the two ranges. The most important movements are flexion and extension, but there is also a slight amount of lateral motion and of rotation in the medio-carpal articulation. The rotation takes place by the head of the os magnum and upper outer angle of the unciform moving in the socket formed by the three outer bones of the first row, together with some gliding backwards and forwards of the trapezium and trapezoid on the scaphoid.

9. **CARPO-METACARPAL ARTICULATIONS.**—The second row of bones of the carpus articulates with the metacarpal bones of the

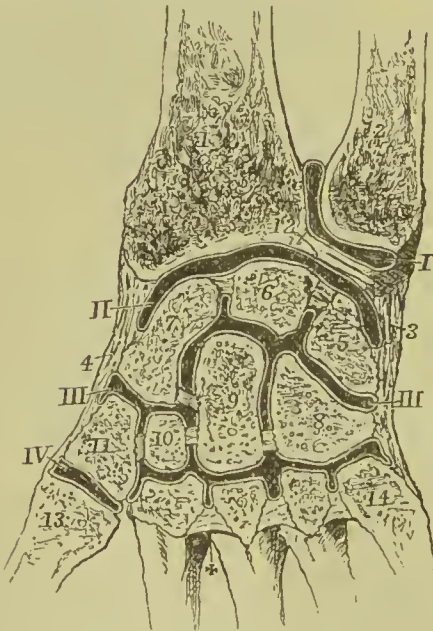


FIG. 171.—Diagram showing the disposition of the chief synovial membranes (of the wrist-joint). 1. Sacciform membrane. II. Second synovial cavity. III. Third or large synovial cavity. IV. Synovial cavity between the trapezium and metacarpal bone of thumb. That of the pisiform bone is here omitted. 1. Radius. 2. Ulna. 3. Internal lateral ligament. 4. External lateral ligament. 5. Cuneiform bone. 6. Semilunar. 7. Scaphoid. 8. Unciform. 9. Os magnum. 10. Trapezium. 11. Trapezoid. 12. Interarticular fibro-cartilage. 13. Metacarpal bone of thumb. 14. Metacarpal of little finger. † Interosseous metacarpal ligaments. Interosseous ligaments are also seen connecting the bones of each row of the carpus.

four fingers by *dorsal* and *palmar* ligaments; and the metacarpal bone of the thumb with the trapezium by a *capsular ligament*. There is also in the carpo-metacarpal articulation a thin *interosseous* band, which passes from the ulnar edge of the os magnum to the

base of the third and fourth metacarpal bones at their point of connection.

The **dorsal ligaments** are strong fasciculi which pass from the second range of carpal to the metacarpal bones; with the exception of the little finger there are two fasciculi to each bone, namely, to the index finger, one each from the trapezium and trapezoid; to the middle finger, one each from the trapezoid and os magnum; to the ring finger, one each from the os magnum and unciform; and to the little finger, one from the unciform.

The **palmar ligaments** are thin fasciculi arranged according to the same plan on the palmar surface, but the third metacarpal has three slips, one from the ridge on the trapezium, one from the os magnum, and one from the unciform.

The **synovial cavity** is a continuation of the great synovial cavity of the two rows of carpal bones.

The **capsular ligament** of the thumb is one of the three true capsular ligaments of the skeleton; the other two being the shoulder and hip. The articulation has a special **synovial membrane**.

The **metacarpal bones** of the four fingers are firmly connected at their bases by means of dorsal and palmar ligaments, which extend transversely from one bone to the other, and by interosseous ligaments which pass between their contiguous surfaces. Their lateral articular facets are lined by a reflection of the great synovial membrane of the two rows of carpal bones.

Actions.—The movements of the metacarpal on the carpal bones are restricted to a slight degree of gliding motion, with the exception of the articulation of the metacarpal bone of the thumb with the trapezium. In the latter, the movements are *flexion, extension, adduction, abduction, and circumduction*.

10. **METACARPO-PHALANGEAL ARTICULATIONS.**—The metacarpophalangeal articulation is a condyloid joint; and its ligaments four in number:—

Anterior,

Two lateral,

Transverse.

The **anterior ligaments** (glenoid), thick and fibro-cartilaginous, form part of the articulating surface of the joints. They are grooved on their palmar surface for the lodgment of the flexor tendons, and by their deep aspect form part of the articular surface for the head of the metacarpal bone. At each side they are continuous with the lateral ligaments.

The **lateral ligaments** are strong narrow fasciculi, holding the bones together at each side.

The **transverse ligament** is a strong ligamentous band passing across the heads of the metacarpal bones of the four fingers, and connected with the anterior ligaments.

The expansion of the extensor tendon over the back of the fingers takes the place and performs the office of a posterior ligament.

Actions.—The chief motions which this articulation admits of

are *flexion* and *extension*. When the finger is extended the lateral ligaments are in a condition of relaxation, and adduction, abduction, and circumduction take place; when, however, the finger is flexed,

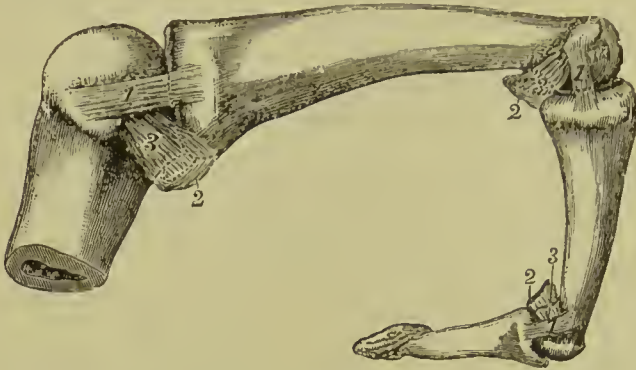


FIG. 172. — Lateral and anterior ligaments of metacarpophalangeal and interphalangeal joints; showing their condition during flexion. 1, 1, 1. Posterior part of lateral ligaments tense. 2, 2, 2. Anterior ligaments. 3, 3, 3. Anterior part of lateral ligaments relaxed.

these ligaments become tense and all lateral movement is prevented.

II. ARTICULATIONS OF THE PHALANGES.—These articulations are ginglymus joints; and furnished with three ligaments:—

Anterior,

Two lateral.

The **anterior ligament**, firm and fibro-cartilaginous, forms part of the articular surface for the head of the phalanges; while externally it is grooved for the reception of the flexor tendons.

The **lateral ligaments** are very strong, and the principal bond of connection between the bones.

The extensor tendon takes the place and performs the office of a posterior ligament.

Actions.—The movements of the phalangeal joints are *flexion* and *extension*, these movements being more free between the first and second than between the second and third.

LIGAMENTS OF THE LOWER EXTREMITY.

The **ligaments of the lower extremity**, like those of the upper, may be arranged in the order of the joints to which they belong; these are:—

1. Hip-joint.
2. Knee-joint.
3. Articulations between the tibia and fibula.
4. Ankle-joint.
5. Articulations of the tarsal bones.
6. Tarso-metatarsal articulations.
7. Metatarso-phalangeal articulations.
8. Articulations of the phalanges.

1. **HIP-JOINT.**—The articulation of the head of the femur with the acetabulum constitutes an enarthrosis, or ball-and-socket joint.

The articular surfaces are—the cup-shaped cavity of the acetabulum and the rounded head of the femur; the ligaments are *five* in number, viz. :—

Capsular,	Teres,
Ilio-femoral,	Cotyloid,
Transverse.	

The **capsular ligament** (Fig. 160, 8) is a strong ligamentous capsule embracing the acetabulum superiorly, the neck of the femur below, and connecting the two bones firmly together. The pelvic origin of the fibres extends superiorly as high as the base of the anterior inferior iliac spine, posteriorly it is connected with the ilium and ischium only a few lines from the margin of the acetabulum, inferiorly it is attached to the outer lip of the groove between the ischial tuberosity and acetabulum, while in front it springs from the transverse ligament, the pubes near the notch, and the pectineal eminence. On the femur the capsule gets attached in front to the spiral line, above to the base of the great trochanter, behind to the junction of the middle and outer thirds of the neck, and reaches below to within three-quarters of an inch of the lesser trochanter. The capsule is composed of longitudinal and circular fibres; the former are chiefly found on the front, and the latter are most numerous on the back. The longitudinal fibres at the back of the capsule are almost entirely confined to the surface next the synovial membrane; after running outwards for some distance they are reflected along the neck of the femur to the articular margin; from their close connection with the bone they often prevent the separation of the fragments in intracapsular fracture of the neck, and have received the name of *retinacula*. The capsule receives strengthening bands from the tendons of the rectus, ilio-psoas, gluteus minimus, and obturator externus.

The **ilio-femoral ligament** is the chief accessory band of the capsule. It is placed anteriorly, and is connected above with the ilium immediately below and behind the anterior inferior spine; it is attached below to the front of the great trochanter and spiral line as far as the inner border of the shaft of the femur. The fibres at the inner and outer borders of this ligament are thicker than the middle ones, and as they diverge from each other they present the appearance of an inverted Y; hence this ligament has been described by Bigelow under the name of the Y-shaped ligament: it must, however, be borne in mind that the interspace between the two limbs is filled in by radiating fibres, so that strictly no true Y-shaped ligament exists. Other accessory bands of fibres exist on the superior, inferior, and anterior aspects of the capsule; these have been named respectively, *ilio-trochanteric*, *ischio-capsular*, and *pubo-femoral* ligaments.

The **ligamentum teres** (Fig. 161, 7), triangular in shape, is attached by a round apex to the depression just below the middle of the head of the femur, and by its base, which separates into two fasciculi, into

the borders of the notch of the acetabulum, where it is connected with the transverse ligament. It is formed by a fasciculus of fibres of variable size, surrounded by synovial membrane; sometimes the synovial membrane is present without the fibres, or the ligament is wholly absent. The round ligament limits adduction in the flexed position, and thus resists dislocation of the head of the femur on to the dorsum of the ilium; it also limits external rotation when the limb is partly flexed.

The **cotyloid ligament** (Fig. 161, 6) is a prismoid cord of fibro-cartilage, attached around the margin of the acetabulum, and serving to deepen that cavity and protect its edges. It is thicker at the upper and posterior border of the acetabulum than in front, is inclined inwards towards the acetabulum, and consists of fibres which arise from the whole circumference of the brim, and interlace with each other at acute angles.

The **transverse ligament** is a strong fasciculus of ligamentous fibres, continuous with the cotyloid ligament, and stretching across the notch of the acetabulum. It converts the notch into a foramen, through which the articular branches of the internal circumflex and obturator artery enter the joint.

The fossa at the bottom of the acetabulum is filled with a mass of fat, covered by synovial membrane, which serves as an elastic cushion for the head of the bone during its movements. This was described by Havers as the *synovial gland*.

The **synovial membrane** is extensive; it commences at the margin of the head of the femur, and is continued around the ligamentum teres to the acetabulum, whence it is reflected on the inner surface of the capsular ligament back to the head of the bone.

Capsular Muscles.—The muscles immediately surrounding and in contact with the hip-joint are—*in front*, psoas and iliacus, separated from the capsular ligament by a large synovial bursa; *above*, short head of the rectus and gluteus minimus; *behind*, pyriformis, gemellus superior, obturator internus, gemellus inferior, and quadratus femoris; and at the *inner side*, obturator externus and pectineus.

Actions.—The movements of the hip-joint are very extensive: they are *flexion, extension, adduction, abduction, circumduction, and rotation*. When the knee is flexed, flexion of the hip-joint is limited only by the contact of the thigh with the abdominal wall, but when the knee is extended the ham-string muscles check the movement in most persons when the leg forms an angle of 75° with the body. Extension is checked by the ilio-femoral ligament; rotation outwards by the outer part of the ilio-femoral ligament and ligamentum teres; rotation inwards by the back part of the capsule, the ischio-capsular ligament, and the muscles at the back of the joint. Adduction is limited by the ilio-femoral ligament and upper part of capsule; abduction by the pubo-femoral band and lower part of capsule.

Nerve-supply.—Obturator, accessory obturator, and anterior

crural from the lumbar plexus; branches of the great sciatic, and of the nerve to the quadratus femoris, from the sacral plexus.

Bursæ.—Nine bursæ are found in the neighbourhood of the hip-joint, five in front and four behind. Those on the front are as follows:—One of large size between the ilio-psoas tendon and the capsule, which often communicates with the cavity of the joint; another between the tendon of the gluteus medius and the great trochanter; a third between the gluteus minimus and the great trochanter; a fourth between the gluteus maximus and vastus externus; and a fifth of large size and often multilocular between the gluteus maximus and great trochanter. The bursæ situated at the back of the joint are:—One beneath the tendon of the obturator externus, another between the quadratus femoris and great trochanter, a third between the capsule and common tendon of the obturator internus and gemelli, and a fourth between the quadratus femoris, obturator externus, and the back part of the capsule.

2. **KNEE-JOINT.**—The knee is a ginglymus articulation of large size, and provided with numerous ligaments; the latter may be divided into an external and an internal set.

External ligaments.	{	Anterior or ligamentum patellæ, Posterior or ligamentum posticum Winslowii, Internal lateral, Two external lateral, Capsular ligament,
Internal ligaments.	{	Anterior or external crucial, Posterior or internal crucial, Transverse, Coronary, Ligamentum mucosum, } <i>false ligaments.</i> Two ligamenta alaria, } Two semilunar fibro-cartilages, Synovial membrane.

The **anterior ligament**, or **ligamentum patellæ**, is the prolongation of the tendon of the extensor muscles of the thigh downwards to the tubercle of the tibia. Between the upper part of this ligament and the knee-joint a pad of fat is placed, and between its lower part and the tibia there is a synovial bursa.

The **posterior ligament**, or **ligamentum posticum Winslowii**, is a broad expansion of ligamentous fibres, which covers the whole of the posterior aspect of the joint. It is divisible into two lateral portions, which invest the condyles of the femur, and a central portion which is depressed, and formed by the interlacement of fasciculi passing in different directions. The strongest of these fasciculi is derived from the tendon of the semi-membranosus, and passes obliquely upwards and outwards from the posterior part of the inner tuberosity of the tibia to the external condyle of the femur. Other accessory fasciculi are given off by the tendon of the popliteus

and heads of the gastrocnemius. The middle portion of the ligament supports the popliteal artery and vein, and is perforated by several openings for the passage of branches of the azygos articular artery and the nerves of the joint.

The **internal lateral ligament** is a broad and trapezoid layer of ligamentous fibres attached above to the tubercle on the internal condyle of the femur, and below to the inner tuberosity and upper part of the shaft of the tibia. It is intimately connected with the edge of the internal semilunar cartilage and with the coronary ligament, and by its posterior edge becomes blended with the ligament of Winslow. It is crossed at its lower part by the tendons of the sartorius, gracilis, and semi-tendinosus, from which it is separated by a synovial bursa, and has passing beneath it the anterior slip of the semi-membranosus tendon and the inferior internal articular artery.

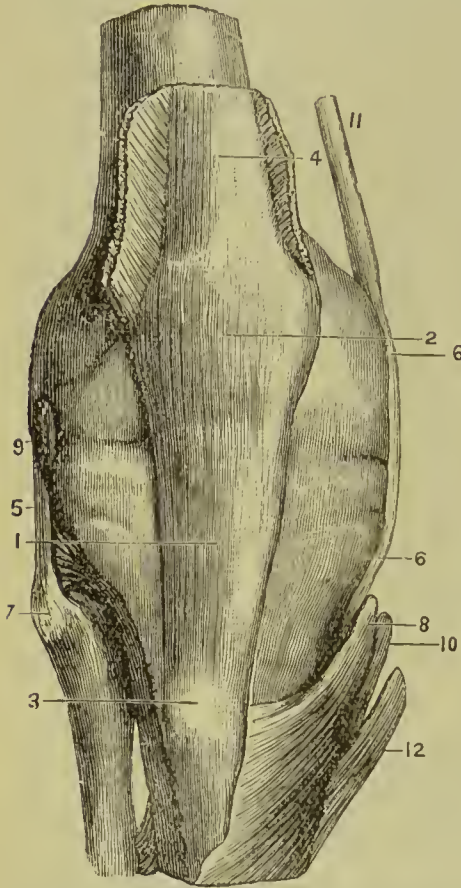


FIG. 173.—Anterior view of the ligaments of the knee-joint. 1. Ligamentum patellæ. 2. Patella covered by ligamentous fibres. 3. Tubercle of tibia. 4. Tendon of rectus. 5. Long external lateral ligament. 6, 6. Internal lateral ligament. 7. Head of fibula. 8. Insertion of sartorius. 9. Tendon of popliteus. 10. Insertion of gracilis. 11. Tendon of adductor magnus prolonged into internal lateral ligament. 12. Insertion of semi-tendinosus.

External Lateral Ligaments.

—The **long** external lateral ligament is a strong and round cord, which descends from the posterior part of the tubercle on the external condyle of the femur to the outer part of the head of the fibula. It is covered in by the tendon of the biceps, and has passing beneath it the tendon of origin of the popliteus muscle, and the inferior external articular artery.

The **short** external lateral ligament is an irregular fasciculus situated behind the preceding, arising from the external condyle near the origin of the head of the gastrocnemius muscle, and inserted into the middle of

the outer surface of the head of the fibula. It is firmly connected with the external semilunar fibro-cartilage, and appears principally intended to connect that cartilage with the fibula: sometimes it is lost superiorly in the capsular ligament without reaching the femur.

The **capsular ligament** consists of thin fibres which fill up the interval left between the patella in the centre and the lateral liga-

ments on each side ; the fibres are attached above to the margin of the articular surface of the femur, and to the upper edge and lateral margins of the patella, while they are inserted below into the inner and outer tuberosities of the tibia. They are intimately connected with the lateral expansions of the tendons of the vastus externus, vastus internus, and crureus, and receive additional fibres from the tendons of the biceps, semi-tendinosus, and sartorius.

The true ligaments *within the joint* are the crucial, transverse, and coronary.

The **anterior** or **external crucial ligament** arises from the depression on the head of the tibia in front of the spinous process, and passes upwards and backwards to be inserted into the inner surface of the outer condyle of the femur, as far back as its posterior border. It is smaller than the posterior.

The **posterior** or **internal crucial ligament** arises from the depression on the head of the tibia behind the spinous process, and passes upwards and forwards to be inserted into the intercondylar hollow, and outer surface of the inner condyle of the femur. This ligament is less oblique and larger than the anterior. The anterior crucial ligament limits extension, and the posterior limits flexion ; they also limit rotation when the leg is flexed.

The **transverse ligament** is a small slip of fibres which extends transversely from the external semilunar fibro-cartilage, near its anterior extremity, to the anterior convexity of the internal cartilage.

The **coronary ligaments** are the short fibres by which the convex borders of the semilunar cartilages are connected to the head of the tibia and ligaments surrounding the joint.

The **semilunar fibro-cartilages** are two falciform plates of fibro-

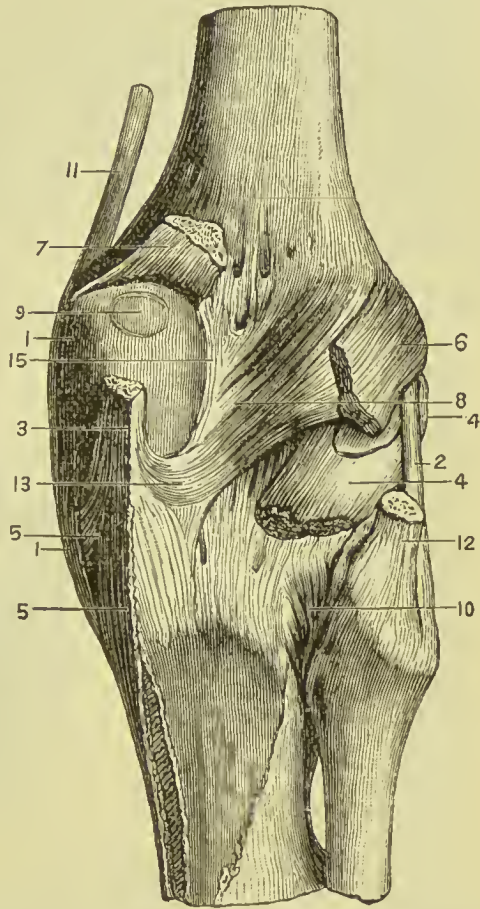
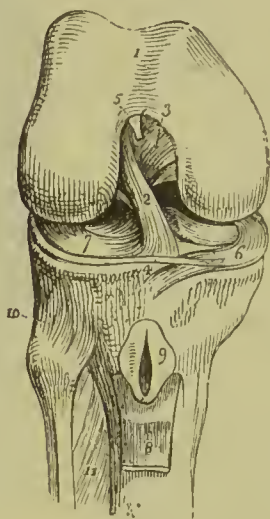


FIG. 174.—Posterior view of the ligaments of the knee-joint. 1, 1. Internal lateral ligament. 2. Long external lateral ligament. 3. Tendon of semi-membranosus. 4, 4. Popliteus. 5, 5. Prolongations of tendon of semi-membranosus. 6. Outer head of gastrocnemius. 7. Inner head of gastrocnemius. 8, 15. Posterior ligament (of Winslow). 9. Opening in capsule. 10. Posterior superior tibio-fibular ligament. 11. Tendon of adductor magnus. 12. Tendon of biceps. 13. Prolongation from tendon of semi-membranosus to posterior ligament.

cartilage, situated on the head of the tibia around its margin, and serving to deepen the surface of articulation for the condyles of the femur. They are thick along their convex border; thin and sharp along their concave edge. Each cartilage covers about two-thirds of the corresponding articular surface of the tibia, leaving the inner third uncovered; both surfaces are covered by synovial membrane.

The **internal semilunar fibro-cartilage** forms an oval cup for the reception of the internal condyle of the femur: it is connected by its convex border with the head of the tibia and internal and posterior ligaments, by means of its coronary ligament; and by its two extremities is firmly implanted into the depression before and behind the spinous process. The **external semilunar fibro-cartilage** bounds a circular fossa for the external condyle; it is connected

FIG. 175.—The right knee-joint laid open from the front in order to show the internal ligaments. 1. Cartilaginous surface of the lower extremity of the femur; the figure 5 rests on the external, the figure 3 on the internal, condyle. 2. Anterior cruceal ligament. 3. Posterior cruceal ligament. 4. Transverse ligament. 5. Attachment of the ligamentum mucosum; the rest has been removed. 6. Internal semilunar fibro-cartilage. 7. External fibro-cartilage. 8. Part of the ligamentum patellæ turned down. 9. Bursa situated between the ligamentum patellæ and the head of the tibia, laid open. 10. Antero-superior tibio-fibular ligament. 11. Interosseous membrane.



by its convex border with the head of the tibia, and to the external and posterior ligaments by its coronary ligament; by its two extremities it is inserted into the depression between the two projections which constitute the spinous process of the tibia; being placed between the attached ends of the internal cartilage. The

two extremities of the external cartilage, being inserted into the same fossa, form an almost complete circle, and the cartilage, being somewhat broader than the internal, covers more of the articular surface of the tibia.

The external semilunar fibro-cartilage, besides giving off a fasciculus from its anterior border to constitute the transverse ligament, is continuous by some of its fibres with the extremity of the anterior crucial ligament: posteriorly it divides into three slips; one, a strong cord, ascends obliquely forwards to be inserted into the anterior part of the inner condyle of the femur in front of the posterior crucial ligament; another is the fasciculus of insertion into the fossa of the spinous process; while the third, of small size, is continuous with the posterior part of the anterior crucial ligament.

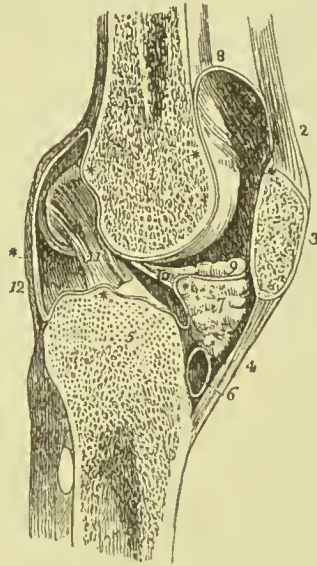
The **ligamentum mucosum** is a slender conical process of synovial membrane enclosing a few ligamentous fibres which proceed from the transverse ligament. It is connected, by its apex, with the

anterior part of the condylar notch, and, by its base, is lost in the mass of fat which projects into the joint beneath the patella.

The **alar ligaments** are two fringed folds of synovial membrane, extending from the ligamentum mucosum, along the edges of the mass of fat, to the sides of the patella.

The **synovial membrane** of the knee-joint is by far the most extensive in the body. It commences near the margins of the cartilaginous surfaces of the condyles of the femur, it covers both surfaces of the semilunar fibro-cartilages, and is reflected upon the crucial ligaments, and inner surface of the ligaments which form the circumference of the joint. On each side of the patella it lines the capsular

FIG. 176.—Longitudinal section of the left knee-joint, showing the reflections of its synovial membrane. 1. Cancellous structure of the lower part of the femur. 2. Tendon of the extensor muscles of the leg. 3. Patella. 4. Ligamentum patellæ. 5. Cancellous structure of the head of the tibia. 6. A bursa situated between the ligamentum patellæ and head of the tibia. 7. Mass of fat projecting into the cavity of the joint below the patella. ** The synovial membrane. 8. The pouch of synovial membrane which ascends between the tendon of the extensor muscles of the leg and front of the lower extremity of the femur. 9. One of the alar ligaments; the other has been removed with the opposite section. 10. Ligamentum mucosum left entire; the section being made to its inner side. 11. Anterior or external crucial ligament. 12. Posterior ligament.



ligament, and forms a pouch of considerable size between the extensor tendon and front of the femur; it passes upwards for fully two inches above the patella, and is supported and raised during the movements of the limb by a small muscle, the *subcrureus*, which is inserted into it. It also forms the folds in the interior of the joint, called “ligamentum mucosum” and “ligamenta alaria.”

Between the ligamentum patellæ and synovial membrane is a considerable mass of fat, which presses the membrane towards the interior of the joint, and occupies the fossa between the condyles.

Actions.—The knee-joint is one of the strongest of the articulations of the body, while, at the same time, it admits of the most perfect degree of movement in the direction of *flexion* and *extension*. During *flexion* the articular surface of the tibia glides forward on the condyles of the femur; the lateral ligaments, the posterior ligament, and the anterior crucial ligament are relaxed; while the ligamentum patellæ being on the stretch, serves to press the adipose mass behind it into the vacuity formed in the front of the joint. In complete *flexion* the posterior crucial ligament is rendered tense,

but flexion is also limited during life by the contact of the leg with the thigh. In complete *extension* all the ligaments are put on the stretch, with the exception of the ligamentum patellæ and the posterior crucial ligament. In the movements of flexion and extension the patella in turn presents to the femoral surface each of the three facets into which the condylar surfaces of that bone are divided, this *coaptation* being associated with *gliding*. At the termination of the act of flexion the patella rests with its inner vertical facet (seventh facet) against the outer part of the internal condyle, and its upper and outer facet against the front of the external condyle. At the end of extension the external condyle reaches its resting position before the internal, so that the latter continues to move backwards, thus rotating the femur inwards upon the tibia. When the knee is semi-flexed, a partial degree of *rotation* is permitted.

Bursæ.—The bursæ in the neighbourhood of the knee-joint are numerous and important; three large ones are placed in front, and numerous small ones at the back of the joint. Those in front are—first, one, large and superficial, placed between the patella and subcutaneous tissue, it is this which becomes enlarged in the disease known as “housemaid’s knee;” second, one between the common extensor tendon and the lower part of the shaft of the femur, it frequently communicates with the synovial pouch of the joint; the third is placed between the ligamentum patellæ and the head of the tibia; it also, sometimes, communicates with the cavity of the joint. The bursæ at the back of the joint are chiefly connected with the tendons of muscles; the most important are the following:—One placed between the tendons of the semi-membranosus and inner head of the gastrocnemius and the internal condyle; this is the largest bursa in the popliteal region, and extends from the posterior inferior part of the internal condyle to the back of the inner tuberosity of the tibia as low down as the upper border of the popliteus muscle. A second bursa lies between the anterior surface of the semi-membranosus tendon and the inner tuberosity of the tibia. Other bursæ exist, between the tendon of the popliteus and the external lateral ligament, between the same tendon and the outer tuberosity of the tibia, between the tendon of the biceps and the external lateral ligament, and beneath the outer head of the gastrocnemius.

Nerve-supply.—Branches of the obturator, anterior crural, external and internal popliteal.

3. **ARTICULATIONS BETWEEN THE TIBIA AND FIBULA.**—The tibia and fibula are held firmly connected by means of *seven* ligaments, namely:—

Anterior,	} above.	Anterior,	} below.
Posterior,		Posterior,	
Interosseous membrane,		Transverse.	
Interosseous inferior,			

The **anterior superior tibio-fibular ligament** is a strong fasciculus of parallel fibres passing obliquely downwards and outwards from the outer tuberosity of the tibia to the anterior surface of the head of the fibula.

The **posterior superior tibio-fibular ligament**, thicker and stronger than the anterior, is disposed in a similar manner on the posterior surface of the joint. It is covered by the tendon of the popliteus.

Within the articulation there is a **synovial membrane** which is sometimes continuous with that of the knee-joint.

The **interosseous membrane** is a broad layer of aponeurotic fibres which pass obliquely downwards and outwards, from the sharp ridge on the tibia to the inner edge of the fibula, and are crossed by a few fibres taking the opposite direction. The ligament is deficient *above*, leaving a considerable interval between the bones, through which the anterior tibial artery takes its course forward to the anterior aspect of the leg; and perforated *below*, near its lower third, for the anterior peroneal artery and vein.

The interosseous membrane is *in relation, in front*, with the tibialis anticus, extensor longus digitorum, extensor proprius hallucis, anterior tibial vessels and nerve, and anterior peroneal artery; *behind*, with the tibialis posticus, flexor longus hallucis, flexor longus digitorum, and posterior peroneal artery.

The **inferior interosseous ligament** consists of short and strong fibres, which hold the bones firmly together inferiorly, where they are nearly in contact; it is continuous above with the interosseous membrane. This articulation is so firm, that the fibula is broken when an attempt is made to rupture the ligament.

The **anterior inferior tibio-fibular ligament** is a broad band, consisting of two fasciculi of parallel fibres which pass obliquely across the anterior aspect of the articulation of the two bones at their inferior extremity, from tibia to fibula.

The **posterior inferior tibio-fibular ligament** is a similar band on the posterior surface of the articulation. Both ligaments project somewhat below the margin of the bones, and serve to deepen the cavity of articulation with the astragalus.

The **transverse ligament** is a narrow band of ligamentous fibres, continuous with the preceding, and passing transversely across the back of the ankle-joint between the two malleoli.

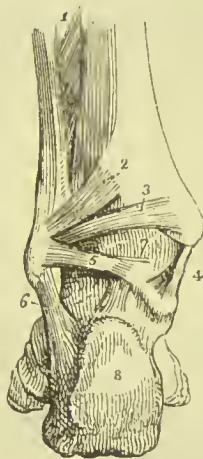


FIG. 177.—Posterior view of the ankle-joint. 1. Lower part of the interosseous membrane. 2. Postero-inferior tibio-fibular ligament. 3. Transverse ligament. 4. Internal lateral ligament. 5. Posterior fasciculus of the external lateral ligament. 6. Middle fasciculus of the external lateral ligament. 7. Synovial membrane of the ankle-joint. 8. Posterior tuberosity of the os calcis.

The **synovial membrane** of the inferior tibio-fibular articulation is a fold of the synovial membrane of the ankle-joint, reflected upwards for a short distance between the two bones.

Actions.—Between the tibia and fibula there exists a slight degree of movement, which is calculated to enable the latter to resist injury by yielding for a trifling extent to forcible pressure.

4. **ANKLE-JOINT.**—The ankle is a ginglymus articulation; the surfaces entering into its formation are the under surface of the tibia with its malleolus and the malleolus of the fibula, above; and the surface of the astragalus with its two lateral facets, below. The ligaments are four in number:—

Anterior,
Internal lateral,

External lateral,
Posterior.

The **anterior ligament** is a thin membranous layer, passing from the margin of the tibia to the astragalus in front of its articular sur-

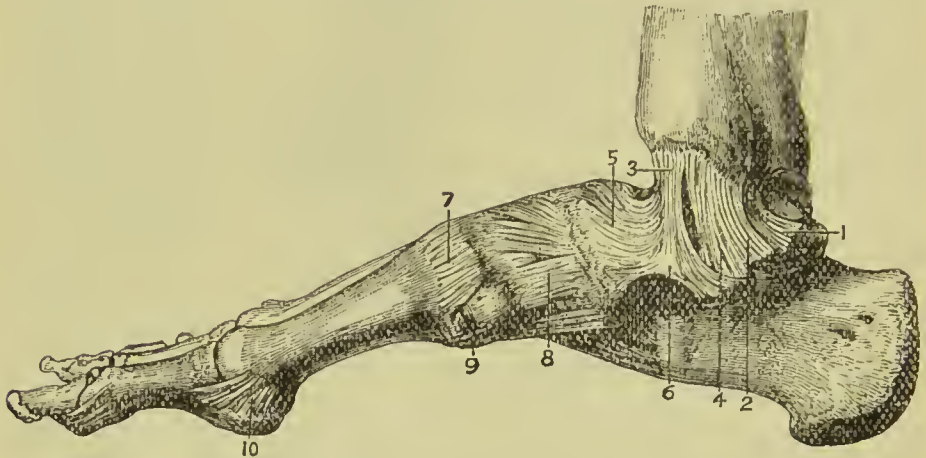


FIG. 178.—Ligaments of inner side of ankle and foot. 1, 2, 3, 4. Different parts of internal lateral ligament of ankle. 5, 6. Inferior calcaneo-scaphoid ligament. 7. Internal ligament between internal cuneiform and first metatarsal. 8. Ligament between the scaphoid and internal cuneiform. 9. Inferior ligament between internal cuneiform and first metatarsal. 10. Inferior ligament of first metatarsophalangeal joint.

face. It is *in relation, in front*, with the tendons of the extensors of the great and lesser toes, tibialis anticus, peroneus tertius, and anterior tibial vessels and nerves. *Posteriorly* it lies in contact with a stratum of extra-synovial adipose tissue and the synovial membrane.

The **internal lateral or deltoid ligament** is a triangular layer of fibres, attached superiorly, by its apex, to the internal malleolus: inferiorly, by an expanded base, to the astragalus, os calcis, and scaphoid bones. Beneath the superficial layer of this ligament is a stronger and thicker fasciculus, which connects the apex of the internal malleolus with the side of the astragalus.

The internal lateral ligament is covered in and partly concealed by the tendon of the tibialis posticus, and, at its posterior part, is in

relation with the tendon of the flexor longus digitorum and flexor longus hallucis.

The **external lateral ligament** consists of three strong fasciculi, which proceed from the inner side of the external malleolus, and radiate in three different directions. The *anterior fasciculus* passes forward, to be attached to the astragalus; the *posterior*, backward, to be connected with the astragalus posteriorly; and the *middle*, longer than the other two, descends to be inserted into the outer side of the os calcis.

The **posterior ligament** consists of a few scattered and thin fibres which are attached above to the external malleolus, the back part of the lower end of the tibia, and to the posterior inferior tibio-fibular ligament, and below to the posterior surface of the astragalus, from the external to the internal lateral ligaments.

The **synovial membrane** is reflected upon the anterior and lateral

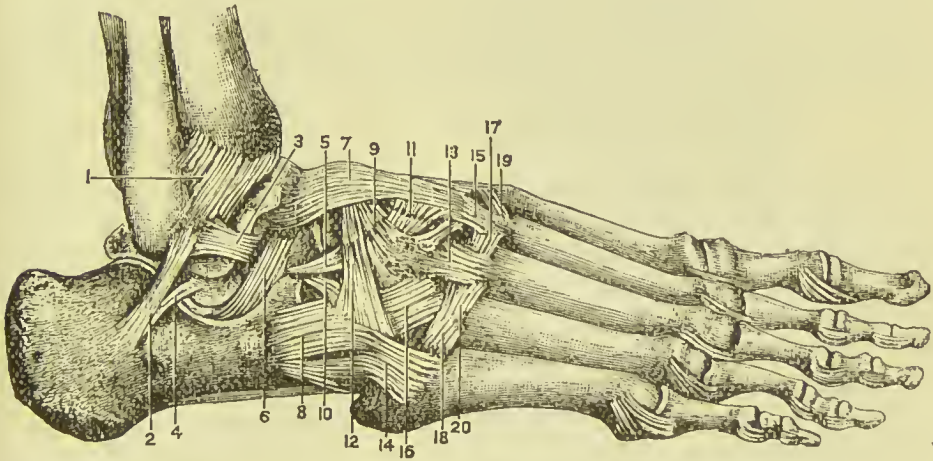


FIG. 179.—Ligaments of outer side of ankle and foot. 1. Anterior-inferior tibio-fibular ligament. 2. Middle fasciculus of external lateral ligament of ankle. 3. Anterior fasciculus. 4. External calcaneo-astragaloid ligament. 5. External calcaneo-scaphoid ligament. 6. Interosseous calcaneo-astragaloid ligament. 7. Superior astragalo-scaphoid ligament. 8. External calcaneo-cuboid ligament. 9. Superior scapho-cuneiform ligament. 10. Internal calcaneo-cuboid ligament. 11. Dorsal ligament between external and middle cuneiform. 12. Dorsal ligament between scaphoid and cuboid. 13. Dorsal ligament between external cuneiform and third metatarsal. 14. Dorsal ligament between cuboid and fifth metatarsal. 15. Dorsal ligament between middle cuneiform and second metatarsal. 16. Dorsal ligament between cuboid and third and fourth metatarsals. 17, 18, 19, 20. Dorsal ligaments between bases of metatarsal bones.

ligaments, and on the transverse and posterior ligaments behind; it also sends a fold upwards between the tibia and fibula.

Actions.—The movements are mainly those of *flexion* and *extension*, the latter being accompanied by a slight inward movement of the toes, in consequence of the outer border of the articular surface of the astragalus being longer than the inner. Both the cupped lower end of the tibia and the corresponding surface of the astragalus are wider in front than behind; hence, in complete extension the narrow part of the latter comes to occupy the wide part of the former,

and a limited degree of lateral motion is thus allowed ; in flexion, on the other hand, they fit accurately to each other, thus securing that fixation so necessary to the erect posture.

Bursæ.—The bursæ in connection with the ankle-joint are chiefly of the ensheathing or vaginal variety, and are continued for some distance along the tendons on the front and back of the joint. The annular ligament binding down the tendons in front of the joint is divided into three compartments, each of which has its special synovial sheath. The first gives passage to the tibialis anticus, the second to the extensor longus hallucis, and the third is common to the extensor longus digitorum and peroneus tertius. Behind the ankle there is a bursa common to the two peronei muscles, one in the course of the flexor longus digitorum, and one in that of the tibialis posticus.

Nerve-supply.—Branches of the anterior and posterior tibial nerves.

5. **ARTICULATION OF THE TARSAL BONES.**—The ligaments which connect the seven bones of the tarsus to each other are of three kinds :—

Dorsal, Plantar, Interosseous.

The **dorsal ligaments** are small fasciculi of parallel fibres, which pass from each bone to all the neighbouring bones with which it articulates. The only dorsal ligaments deserving of particular mention are the **external** and **posterior astragalo-calcaneal**, which, with the interosseous ligament, complete the articulation of the astragalus with the os calcis ; the **superior** and **internal calcaneo-cuboid** ligaments ; and the **superior astragalo-scaphoid** ligament. The internal calcaneo-cuboid, and superior calcaneo-scaphoid ligament, which are closely united posteriorly in the deep groove which intervenes between the astragalus and os calcis, separate anteriorly to reach their respective bones ; they form the principal bond of connection between the first and second range of bones of the foot. It is the division of this portion of these ligaments that demands the careful attention of the surgeon in performing Chopart's operation.

The **plantar ligaments** have the same disposition on the plantar surface of the foot ; three of them, however, are of large size, and have especial names, viz., the

Calcaneo-scaphoid,
Long calcaneo-cuboid,
Short calcaneo-cuboid.

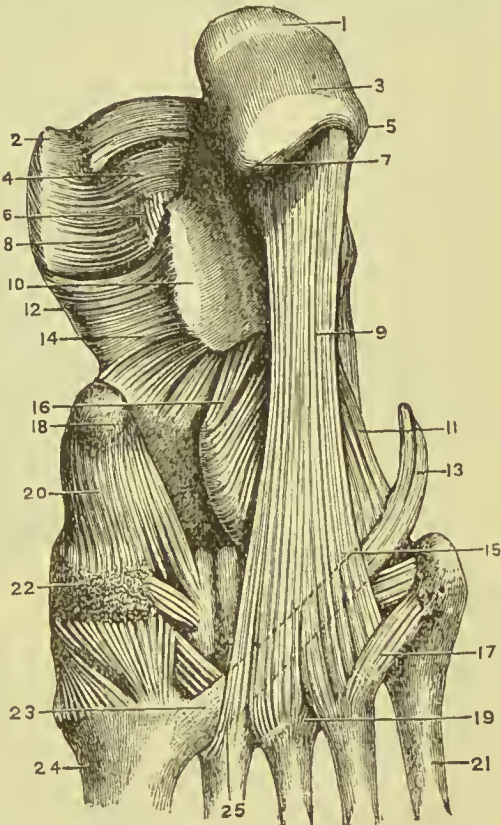
The **inferior calcaneo-scaphoid ligament** is a broad and fibro-cartilaginous band of ligament which passes forward from the anterior and inner border of the os calcis to the edge of the scaphoid bone. Besides connecting the os calcis and scaphoid, it supports the astragalus, and forms part of the cavity in which the rounded head of the latter bone is received. It is lined on its upper surface by the synovial membrane of the astragalo-scaphoid articulation.

This ligament is the main support of the arch of the foot, and is sometimes called the "*spring*" ligament; it is braced up by the tendon of the tibialis posticus, which runs beneath it.

The firm connection of the os calcis with the scaphoid bone, and the feebleness of the astragalo-scaphoid articulation, are conditions favourable to the occasional dislocation of the head of the astragalus.

The **long calcaneo-cuboid ligament** or **ligamentum longum plantæ** is a long band of ligamentous fibres, which proceeds from the under surface of the os calcis to the rough surface on the under part

FIG. 180.—Ligaments of the sole of the foot. 1. Point of attachment of tendon Achilles. 2. Internal malleolus. 3. Posterior tuberosity of os calcis. 4. Posterior part of astragalus. 5. External tubercle on under surface of os calcis. 6. Posterior calcaneo-astragaloid ligament. 7. Internal tubercle of os calcis. 8 and 12. Internal lateral ligament. 9. Long plantar ligament. 10. Groove on sustentaculum tali for flexor proprius hallucis. 11 and 16. Short plantar ligament. 13 and 23. Tendon of peroneus longus. 14. Inferior calcaneo-scaphoid ligament. 15 and 25. Sheath of peroneus longus. 17. Plantar ligament between fourth and fifth metatarsals. 18. Tubercle of scaphoid. 19. Plantar ligament between third and fourth metatarsals. 20. Plantar ligament between scaphoid and internal cuneiform. 21. Fifth metatarsal. 22. Internal cuneiform. 24. First metatarsal.



of the cuboid bone, its fibres being continued onwards to the base of the second, third, and fourth metatarsal bones.

This ligament forms the inferior boundary of the canal in the cuboid bone, through which the tendon of the peroneus longus passes to its insertion into the base of the metatarsal bone of the great toe.

The **short calcaneo-cuboid** or **ligamentum breve plantæ** is situated closer to the bones than the long plantar ligament, from which it is separated by adipose tissue; it is broad and extensive, and ties the under part of the os calcis and cuboid bone firmly together.

The **interosseous ligaments** are five in number; they are short and strong ligamentous fibres situated between adjoining bones, and firmly attached to their rough surfaces. One of these, **astragala-**

calcaneal, is lodged in the groove between the upper surface of the os calcis and the lower of the astragalus. It is large and very strong, consists of vertical and oblique fibres, and serves to unite the os calcis and astragalus solidly together. The second interosseous ligament, also very strong, is situated between the sides of the scaphoid and cuboid bone; the three remaining interosseous ligaments connect strongly together the three cuneiform bones and the cuboid.

The **synovial membranes** of the tarsus are four in number: *one*, for the posterior astragalo-calcaneal articulation; a *second*, for the anterior astragalo-calcaneal and astragalo-scaphoid articulation; occasionally an additional small synovial membrane is found in the

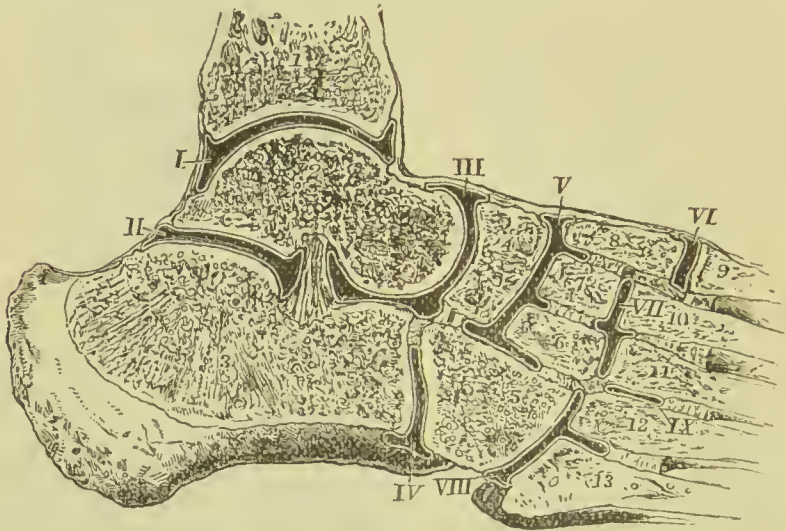


FIG. 181.—Diagram showing the arrangement of the synovial membranes of the tarsal joints. I. Synovial membrane of the ankle-joint. II. That between the back of the astragalus and os calcis. III. That between the astragalus and scaphoid, and between the front of the astragalus and os calcis. IV. Between the os calcis and cuboid. V. Between the cuneiform bones and scaphoid. VI. Between the internal cuneiform and metatarsal of big toe. VII. Between the middle metatarsal and two outer cuneiform bones. VIII. Between the cuboid and outer metatarsals. IX. Between the third and fourth metatarsals. 1. Tibia. 2. Astragalus. 3. Os calcis. 4. Scaphoid. 5. Cuboid. 6. External cuneiform. 7. Middle, and 8, Internal cuneiform. 9, 10, 11, 12, 13. Metatarsal bones. Interosseous ligaments are shown connecting the several bones of the tarsus and metatarsus.

anterior astragalo-calcaneal joint; a *third*, for the calcaneo-cuboid articulation; and a *fourth*, the large tarsal synovial membrane for the articulations between the scaphoid and three cuneiform bones, the cuneiform bones with each other, the external cuneiform bone with the cuboid, and the two outer cuneiform bones with the bases of the second and third metatarsal bones. The prolongation which reaches the metatarsal bones passes forward between the internal and middle cuneiform bone. The synovial membrane between the two outer cuneiform and second and third metatarsal bones is often distinct from the large one; it is so represented in Fig. 181, VII. A small synovial membrane is sometimes met with between the contiguous surfaces of the scaphoid and cuboid bone.

Actions.—The movements permitted by the articulation between the astragalus and os calcis, are a slight degree of gliding, in the direction *forwards* and *backwards*, and *laterally* from side to side. The movements of the second range of tarsal bones are very trifling, being greater between the scaphoid and three cuneiform bones than in the other articulations. The movements occurring between the first and second range are the most considerable; they are *adduction* and *abduction*; and, in a minor degree, *flexion*, which increases the arch of the foot, and *extension*, which flattens the arch.

6. **TARSO-METATARSAL ARTICULATION.**—The ligaments of this articulation are :—

Dorsal, Plantar, Interosseous.

The **dorsal ligaments** connect the metatarsal to the tarsal bones, and the metatarsal bones with each other. The base of the second metatarsal bone, articulating with the three cuneiform bones, receives a ligamentous slip from each, while the rest articulating with a single tarsal bone receive only a single tarsal slip.

The **plantar ligaments** have a similar disposition on the plantar surface.

The **interosseous ligaments** are situated between the bases of the metatarsal bones of the four lesser toes; also between the base of the second and third metatarsal bones and the internal and external cuneiform bones.

The metatarsal bone of the second toe being implanted by its base between the internal and external cuneiform bones, is the most strongly articulated of all the metatarsal bones. This disposition must be recollected in amputation at the tarso-metatarsal articulation.

The **synovial membranes** of the tarso-metatarsal articulation are three in number: one for the metatarsal bone of the great toe; one for the second and third metatarsal bones, which is continuous with the great tarsal synovial membrane; and one for the fourth and fifth metatarsal bones.

Actions.—The movements of the metatarsal on the tarsal bones and on each other are very slight; they are such only as contribute to the strength of the foot, by permitting a certain degree of yielding to opposing forces.

7. **METATARSO-PHALANGEAL ARTICULATION.**—The ligaments of this articulation, like those between the first phalanges and metacarpal bones of the hand, are :—

Inferior or plantar, Two lateral, Transverse.

The **inferior or plantar ligaments**, thick and fibro-cartilaginous, form part of the articulating surface of the joint.

The **lateral ligaments**, short and very strong, are situated one on each side of the joint.

The **transverse ligament** is a strong band, which passes transversely between the plantar ligaments.

The expansion of the extensor tendon supplies the place of a dorsal ligament.

Actions.—The movements of the first phalanges on the rounded heads of the metatarsal bones are, *flexion, extension, adduction, and abduction.*

8. **ARTICULATION OF THE PHALANGES.**—The ligaments of the phalanges are the same as those of the fingers, and have the same disposition ; their actions are also similar. They are :—

Inferior or plantar, and, Two lateral.

PART IV.

MYOLOGY.

In this section will be described the arrangement, attachments, and actions of the voluntary muscles, and the disposition of the fascia supporting or connected with them.

MUSCLES present various modifications in the arrangement of their fibres in relation to their tendinous structure. Sometimes they are longitudinal, and terminate at each extremity in tendon, the entire muscle being *fusiform* in shape ; in other situations they are disposed like the rays of a fan, converging to a tendinous point, as the temporal, pectoral, glutei, &c., and constitute a *radiate* muscle. Again, they are *penniform*, converging like the barbs of a feather to one side of a tendon, which runs the whole length of the muscle, as in the peronei ; or *bipenniform*, converging to both sides of the tendon. In other muscles the fibres pass obliquely from the surface of a tendinous expansion spread out on one side, to that of another extended on the opposite side, as in the semi-membranosus ; or, they are composed of penniform or bipenniform fasciculi, as in the deltoid, and constitute a *compound* muscle. In the broad muscle the tendon is spread out so as to form an expansion, called *aponeurosis*.

The muscles are all symmetrical, and, with the exception of the splinters and diaphragm, are arranged in pairs. It is calculated that they number about 240 pairs, and that the weight of the total mass of muscle is about 63 lbs. in a man whose total body-weight is 150 lbs.

The nomenclature of muscles is generally derived from some prominent character which the muscle presents ; thus, some are named from their situation, as the tibialis, peroneus, brachialis, temporal ; others from their use, as the flexors, extensors, abductors, levators, tensors, splinters, &c. Some again from their form, as the trapezius, triangularis, deltoid, rhomboid, scalene, orbicularis, &c. ; and others from their direction, as the rectus, obliquus, transversalis, &c. Certain muscles have received names expressive of their attachments, as the sterno-mastoid, sterno-hyoid, &c. ; and others, of their divisions, as the biceps, triceps, digastricus, complexus, &c.

In the description of a muscle we express its attachment by the words "origin" and "insertion:" the term *origin* is generally applied to the more fixed attachment, or to the point towards which the motion is directed, while *insertion* is assigned to the more movable point. Where both ends are equally movable the term *origin* is given to the attachment nearest to the middle line of the body, and that farthest from the middle line is called the *insertion*.

FASCIA (*fascia*, a bandage) is the name assigned to fibrous laminae of various extent and thickness, which are distributed through the different regions of the body, for the purpose of investing or protecting the softer and more delicate organs. From a consideration of their structure, these fasciæ may be arranged into two groups: areolo-fibrous fasciæ, and aponeurotic fasciæ.

The **areolo-fibrous** or **superficial fascia** is the common subcutaneous investment of the entire body; it is situated immediately beneath the integument over every part of the frame, and is the medium of connection between that layer and the deeper parts. It is composed of areolar and elastic tissue, and contains in its areolæ an abundance of adipose tissue, constituting the *panniculus adiposus*. Fat is, however, absent from the subcutaneous tissue of the penis, scrotum, and eyelids. By dissection, the superficial fascia may be separated into *two layers*, between which are found the superficial or cutaneous vessels and nerves; as the superficial epigastric artery, saphena veins, radial and ulnar veins, superficial lymphatic vessels, and the cutaneous muscles, such as the platysma myoides. The deep layer of this fascia usually forms a more distinct sheet than the superficial, and is almost devoid of fat vesicles.

The **aponeurotic** or **deep fascia** is the strongest kind of investing membrane; it is composed of tendinous fibres, running parallel with each other, and connected by other fibres of the same kind passing in different directions, together with areolar tissue and fine elastic fibres. When freshly exposed, it is white, glistening, and iridescent, and is firm, unyielding, and but little elastic. It encloses and forms distinct sheaths to all the muscles and tendons. It is thick on the outer and least protected side of the limb, and thinner at its inner side. It is firmly connected to the bones, and to the prominent points of each region, as to the pelvis, knee, and ankle, in the lower; and to the clavicle, scapula, elbow, and wrist, in the upper extremity. It assists the muscles in their action, by keeping up a tonic pressure on their surface; aids materially in the circulation of the fluids; and in the palm of the hand and sole of the foot is a powerful protection to the structures which enter into the composition of those regions. In some situations its tension is regulated by muscular action, as by the tensor vaginæ femoris and gluteus maximus in the thigh, by the biceps in the leg, and by the biceps and palmaris longus in the arm; in other situations it affords an extensive surface for the origin of the fibres of muscles.

The MUSCLES and FASCIÆ may be arranged in conformity with the general division of the body into—1. Those of the head and neck, 2. Those of the trunk. 3. Those of the upper extremity. 4. Those of the lower extremity.

MUSCLES AND FASCIÆ OF THE HEAD AND NECK.

These admit of subdivision into those of the head and face, and those of the neck.

Muscles of the Head and Face.—These muscles may be divided into groups corresponding with the natural regions of the head and face; the groups are eight in number, namely:—

- | | |
|---------------------|---------------------------|
| 1. Cranial group. | 5. Nasal group. |
| 2. Orbital group. | 6. Superior labial group. |
| 3. Auricular group. | 7. Inferior labial group. |
| 4. Ocular group. | 8. Maxillary group. |

1. Cranial Group.—Occipito-frontalis.

Dissection.—The *occipito-frontalis* is to be dissected by making a longitudinal incision along the vertex of the head, from the root of the nose to the external occipital protuberance, and a second incision along the forehead and around the side of the head, to join the two extremities of the preceding. Dissect the integument and superficial fascia carefully outwards, beginning at the anterior angle of the flap, where the muscular fibres are thickest, and remove it altogether. This dissection requires care; for the muscle is very thin, and without attention would be raised with the integument.

FASCIA.—The **superficial fascia** forms a firm, dense layer, which is closely connected with the integument and the surface of the aponeurosis of the occipito-frontalis; behind it becomes continuous with the superficial fascia of the neck, and laterally it passes over the temporal aponeurosis, and may be traced nearly as far as the zygoma. It contains between its layers the muscles of the auricle, and the superficial vessels and nerves. There is no deep fascia on the face or head, nor is it required; for here the muscles are closely applied against the bones, upon which they depend for support, whilst in the extremities the support is derived from the dense layer of fascia by which they are invested, and which forms for each muscle a distinct sheath.

The **OCCIPITO-FRONTALIS** is a broad musculo-aponeurotic layer, which covers the whole side of the vertex of the skull, from the occiput to the eyebrow. It consists of two fleshy bellies and an intervening tendinous aponeurosis. The *occipital* portion arises from the outer two-thirds of the superior curved line of the occipital bone, and from the mastoid portion of the temporal; its fibres pass upwards to be inserted into the posterior margin of the aponeurosis. The *frontal* portion is thinner and paler than the occipital, but covers a larger extent of surface; its fibres are continuous

with those of the *pyramidalis nasi*, *corrugator supercilii*, and *orbicularis palpebrarum*; immediately above the root of the nose the fibres of the right and left muscles are united, but as they pass upwards a small angular interval is left between them; they are inserted into the anterior extremity of the aponeurosis. Most of the frontal fibres have no bony attachment, but a few are connected with the internal angular process of the frontal bone. The *epicranial aponeurosis* of the two sides covers the whole of the vertex of the skull, and terminates in front and behind in narrow processes interposed between the fleshy bellies; it is attached posteriorly to the occipital protuberance and superior curved line, and receives

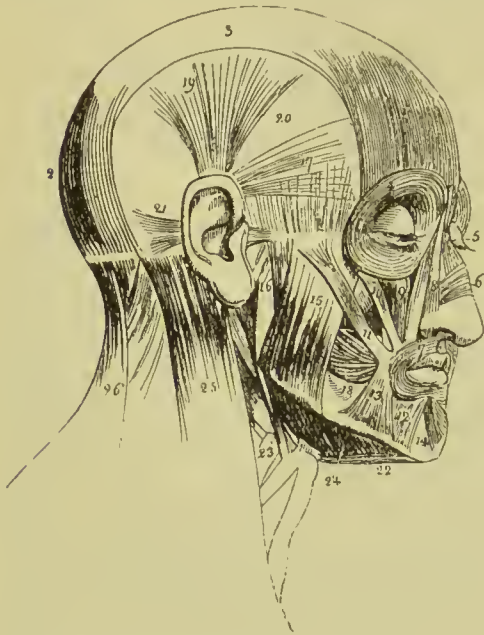


FIG. 182.—Muscles of the head and face. 1. Frontal portion of the occipito-frontalis. 2. Its occipital portion. 3. Epicranial aponeurosis. 4. Orbicularis palpebrarum, which conceals the corrugator supercilii and tensor tarsi. 5. Pyramidalis nasi. 6. Compressor nasi. 7. Orbicularis oris. 8. Levator labii superioris alæque nasi; the adjoining fasciculus between figures 8 and 9 is the labial portion of the muscle. 9. Levator labii superioris proprius; the lower part of the levator anguli oris is seen between the muscles 10 and 11. 10. Zygomaticus minor. 11. Zygomaticus major. 12. Depressor anguli oris. 13. Depressor labii inferioris. 14. Levator labii inferioris. 15. Superficial portion of the masseter. 16. Part of its deep portion. 17. Attrahens auriculam. 18. Buccinator. 19. Attollens auriculam. 20. Temporal fascia covering the temporal muscle. 21. Retrahens auriculam. 22. Anterior belly of the digastric; the tendon is seen passing through its

aponeurotic pulley. 23. Stylo-hyoid muscle pierced by the superior belly of the digastric. 24. Mylo-hyoid. 25. Upper part of the sterno-mastoid. 26. Upper part of the trapezius. The muscle between 25 and 26 is the splenius.

in front the attachment of the anterior bellies, ending about the middle of the forehead. By its lateral margins it gives origin to the attollens and attrahens auriculam muscles, and is continued down to the zygoma as a thin layer of fascia.

Relations.—This muscle is in relation by its *external surface* with the frontal and supraorbital vessels, supraorbital and facial nerves, temporal vessels and auriculo-temporal nerve, occipital vessels and nerves, and integument, to which last it is closely adherent. Its *under surface* is attached to the pericranium by a loose areolar tissue, which permits considerable movement.

Nerve-supply.—Posterior or occipital portion by the posterior auricular; frontal portion by the temporal—both branches of the facial.

Actions.—The occipital portion acting alone draws the scalp backwards. The frontal portion, if it has its fixed point above, draws the eyebrows upwards and produces transverse wrinkles in the forehead, as in expressing surprise, wonder, attention, or terror; if its fixed point be below it draws forward the scalp. By the alternate action of the two portions the scalp is drawn to and fro on the underlying pericranium.

2. **Orbital Group.**—

Orbicularis palpebrarum, Corrugator supercilii,
Tensor tarsi.

Dissection.—Great care is requisite in the dissection of the first of these muscles, from the total absence of subcutaneous fat over the eyelids, and the extreme delicacy of the muscular fibres which cover them. A hook should be introduced into the palpebral fissure at the outer canthus, and one of the other hooks of the set fastened to the table, so as to put the eyelids slightly on the stretch; an incision should be made along the margin of each lid, and the cut already made from the scalp to the root of the nose should be carried onwards to the tip of that organ. The skin is now to be raised from the margin of the lids as a delicate layer not thicker than ordinary tissue-paper. In order completely to expose the orbicularis it will be necessary to make an additional incision, after the skin has been raised from the lids, from the outer canthus of the eye on to the lateral aspect of the head.

The **ORBICULARIS PALPEBRARUM** is a sphincter muscle, surrounding the orbit and eyelids, and consists of two portions, external and internal. The *external* or *orbital portion* arises from a short tendon, *tendo oculi*, situated at the inner angle of the eye, and from the internal angular process of the frontal bone; it encircles the orbit, and is *inserted* into the nasal process of the superior maxillary and lower border of the *tendo oculi*, some of its fibres being continuous with the upper segment. This portion of the muscle becomes intimately blended with the occipito-frontalis and corrugator supercilii; it also sends off slips which communicate with the muscles of the upper lip. The *internal* or *palpebral portion* forms a curved plane of fibres on the eyelids, thinner and paler than the orbital portion; externally these fibres are attached to the external palpebral ligament and border of the orbit, some being continuous with the orbital portion; internally they are attached to the borders of the lacus lachrymalis and *tendo oculi*. The fibres of the palpebral portion nearest the edges of the lids are thicker than the rest, and are termed *ciliary*. A few fibres placed within the line of the eyelashes and separated by them from the rest of the orbicularis, have been described as a distinct muscle under the name of *ciliary muscle of Riolan*.

The **tendo oculi** (*internal tarsal ligament*), about two lines in length and one in breadth, is attached by one end to the nasal process of the superior maxillary bone, close to the edge of the

orbit; the other end bifurcates to be inserted into the inner extremities of the tarsal plates; from its posterior aspect is given off a process which spreads over the lachrymal sac, and is attached to the crest of the lachrymal bone; this is the reflected aponeurosis of the tendo oculi, and serves to protect the lachrymal sac.

The **external tarsal ligament** is a thin band of fibres, connecting the outer extremity of the eyelids with the malar bone.

Relations.—By its *superficial surface* the muscle is closely adherent to the integument, from which it is separated on the eyelids by a loose areolar tissue. By its *deep surface* it lies in contact, *above*, with the upper border of the orbit, corrugator supercillii muscle, frontal and supraorbital vessels, and supraorbital nerve; *below*, with the lachrymal sac, levator labii superioris alæque nasi, levator labii superioris proprius, zygomaticus major and minor muscles, and malar bone; *externally*, with the temporal fascia. On the eyelids it is in relation with the broad tarsal ligament and tarsal plates, and by its upper border is connected with the occipito-frontalis.

Nerve-supply.—Temporal and malar branches of the facial.

The **CORRUGATOR SUPERCILII** is a small, narrow, and pointed muscle, situated immediately above the orbit, and beneath the upper segment of the orbicularis palpebrarum. It *arises* from the inner extremity of the superciliary ridge, and passes upwards and outwards to be *inserted* into the under surface of the orbicularis palpebrarum. Some of the fibres pass through the orbicularis and are inserted into the skin.

Relations.—By its *superficial surface* with the occipito-frontalis and orbicularis palpebrarum; by its *deep surface* with the frontal bone and supra-trochlear nerve.

Nerve-supply.—The facial nerve.

The **TENSOR TARSI** (Horner's muscle) is a thin plane of muscular fibres, about three lines in breadth and six in length. It is best dissected (after the dissection of the orbit has been completed) by separating the eyelids from the eye, and turning them over the nose without disturbing the tendo oculi; then dissect away the small fold of mucous membrane called plica semilunaris, and some loose areolar tissue under which the muscle is concealed. It *arises* from the orbital surface of the lachrymal bone, and passing across the lachrymal sac, divides into two slips, which pass behind the lachrymal canals and become continuous with the margin of the orbicularis along the edges of the lids; some few of its fibres being attached to the lachrymal canals as far as the puncta.

Nerve-supply.—Infraorbital branch of facial.

Actions.—The palpebral portion of the orbicularis acts involuntarily in closing the lids, and from the greater curve of the upper lid, upon that principally. The entire muscle constitutes a sphincter, drawing at the same time, by means of its osseous attachment, the integument and lids inwards towards the nose. The corrugatores superciliarum draw the eyebrows downwards and inwards, and

produce the vertical wrinkles of the forehead. The *tensor tarsi* is an auxiliary to the orbicularis, and draws the extremities of the lachrymal canals inwards, so as to place the puncta in the best position for receiving the tears. It compresses the lachrymal sac, and serves also to keep the lids in relation with the surface of the eye.

3. Auricular Group.—

Attollens auriculam, Attrahens auriculam,
Retrahens auriculam.

Dissection.—If the pinna of the ear be drawn down by means of a hook, a ridge of skin will rise up, extending from the ear to the cut edge of the scalp; along this ridge an incision is to be made and the skin reflected downwards; by this means the upper of the three muscles will be exposed. In like manner the pinna must be drawn backwards to expose the attrahens, and forwards to expose the retrahens, the skin being removed by an incision close around the base of the ear, supplemented by others running in the course of the muscles. The muscles are best dissected by commencing with their tendons, and thence proceeding in the course of their radiating fibres.

The **ATTOLLENS AURICULAM**, the largest of the three, is a thin fan-shaped plane of muscular fibres, *arising* from the lateral portion of the epicranial aponeurosis at about the middle of the temporal ridge, and *inserted* into the upper part of the concha and inner and upper part of the pinna.

It is **in relation** by its external surface with the integument, and by the internal with the temporal fascia.

Nerve-supply.—Temporal branches of facial.

The **ATTRAHENS AURICULAM** *arises* from the lateral portion of the epicranial aponeurosis above the zygoma, and is *inserted* into the spine of the helix. It is often blended with the anterior edge of the former muscle.

It is **in relation** by its external surface with the integument, and by the internal with the temporal fascia and temporal artery and veins.

Nerve-supply.—Temporal branches of facial.

The **RETRAHENS AURICULAM** *arises* by two (sometimes three) muscular slips from the root of the mastoid process. They are *inserted* into the posterior surface of the concha.

It is **in relation** by its external surface with the integument, and by its internal surface with the mastoid portion of the temporal bone.

Nerve-supply.—Posterior auricular branch of facial, and small occipital nerves.

Actions.—The *actions* of the auricular muscles are expressed in their names; they have but little power in man, but are important muscles in brutes.

4. Ocular Group.—

Levator palpebræ,	Rectus internus,
Rectus superior,	Rectus externus,
Rectus inferior,	Obliquus superior,
	Obliquus inferior.

Dissection.—To open the orbit (the calvarium and brain having been removed) the frontal bone must be sawn through at the inner extremity of the orbital ridge, the saw being directed to the supra-orbital notch; and, externally, at its outer extremity. The roof of the orbit may then be comminuted with the hammer—a process easily accomplished, on account of the thinness of the orbital plate of the frontal bone and lesser wing of the sphenoid. The superciliary portion of the orbit may next be driven forwards by a smart blow, and the external angular process and external wall of the orbit outwards in the same manner; the broken fragments of the roof of the orbit should then be removed. Remove the periosteum from the whole of the upper surface of the exposed orbit, and examine the parts beneath.

The **LEVATOR PALPEBRÆ SUPERIORIS** is a long, thin, and triangular muscle situated at the upper part of the orbit in the middle line; it *arises* from the under surface of the lesser wing of the sphenoid, above and in front of the optic foramen, and is *inserted* into the upper border of the superior tarsal plate by a broad but thin tendon.

Relations.—By its *upper surface* with the fourth nerve, supra-orbital nerve and artery, periosteum of the orbit, and, in front, inner face of the broad tarsal ligament. By its *under surface* it rests on the superior rectus, globe of the eye, and conjunctiva; it receives its nerve and artery by this aspect.

Nerve-supply.—Superior division of the third nerve.

The **RECTUS SUPERIOR** *arises* from the upper margin of the optic foramen, and from the fibrous sheath of the optic nerve; and is *inserted* into the upper surface of the globe of the eye at a point somewhat more than three lines from the margin of the cornea.

Relations.—By its *upper surface* with the levator palpebræ muscle; by the *under surface* with the optic nerve, ophthalmic artery and nasal nerve, and, in front, with the globe of the eye, the tendon of the superior oblique muscle being interposed.

Nerve-supply.—Superior division of the third nerve.

The **RECTUS INFERIOR** *arises* from the inferior margin of the optic foramen by a tendon (ligament of Zinn) which is common to it and the internal and external rectus, and from the fibrous sheath of the optic nerve; it is *inserted* into the inferior surface of the globe of the eye, a little more than two lines from the margin of the cornea.

Relations.—By its *upper surface* with the optic nerve, inferior branch of the third nerve, adipose tissue of the orbit, and under

surface of the globe of the eye. By its *under surface* with the periosteum of the floor of the orbit, and inferior oblique muscle.

Nerve-supply.—Inferior division of the third nerve.

The **RECTUS INTERNUS**, the thickest and shortest of the straight muscles, *arises* from the common tendon, and from the fibrous sheath of the optic nerve; and is *inserted* into the inner surface of the globe of the eye at two lines from the margin of the cornea.

Relations.—By its *internal surface* with the optic nerve, adipose tissue of the orbit and eyeball. By its *outer surface* with the periosteum of the orbit; by its *upper border* with the anterior and posterior ethmoidal vessels, nasal and infra-trochlear nerves.

Nerve-supply.—Inferior division of the third nerve.

The **RECTUS EXTERNUS**, the longest of the straight muscles, *arises* by two heads, one with the origin of the superior rectus, from the margin of the optic foramen; the other partly from the common tendon, and partly from the lower margin of the sphenoidal fissure; the nasal, third, and sixth nerves and ophthalmic vein passing between them. It is *inserted* into the outer surface of the globe of the eye, a little more than two lines from the margin of the cornea.

Relations.—By its *internal surface* with the third, nasal, sixth, and optic nerves, ciliary ganglion and nerves, ophthalmic artery and vein, adipose tissue of the orbit, inferior oblique muscle, and eyeball. By its *external surface* with the periosteum of the orbit and lachrymal gland; by the *upper border* with the lachrymal vessels and nerve.

Nerve-supply.—The sixth nerve.

The recti muscles present several characters in common; thus, they are thin, have each the form of an isosceles triangle, bear the same relation to the globe of the eye, and are inserted in a similar manner into the sclerotic, at about two lines from the circumference of the cornea. The points of difference relate to thickness and length; the internal rectus is the thickest and shortest, the external the longest, and the superior the most thin. The insertion of the four recti into the globe of the eye forms a tendinous expansion, which is continued as far as the margin of the cornea, and is termed *tunica albuginea*.

The **OBLIQUUS SUPERIOR** (trochlearis) is a fusiform muscle *arising* from the margin of the optic foramen, and from the fibrous

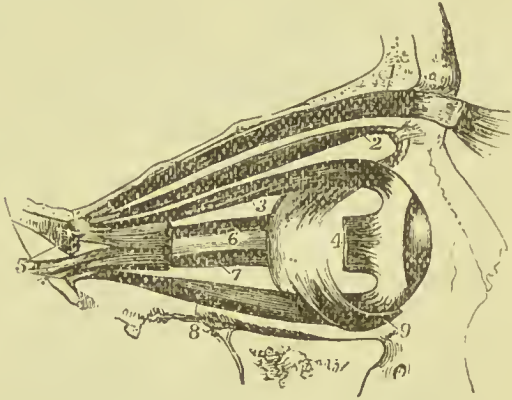


FIG. 183.—Muscles of the eyeball; the view is taken from the outer side of the right orbit. 1. Levator palpebrae. 2. Superior oblique. 3. Superior rectus. 4. Cut outer end of the external rectus. 5. The two heads of origin of the external rectus. 6. Optic nerve. 7. Internal rectus. 8. Inferior rectus. 9. Inferior oblique.

sheath of the optic nerve; it passes forward to the pulley at the internal angular process of the frontal bone; its tendon is then reflected outwards beneath the superior rectus to the outer part of the globe of the eye, where it is *inserted* into the sclerotic coat, at about midway between the margin of the cornea and the optic nerve. The *trochlea* or *pulley* of the superior oblique muscle is a cartilaginous ring attached to the depression beneath the internal angular process of the frontal bone by bands of white fibrous tissue. The ring is flat, about a line in width, and provided with a synovial membrane, which is continued, together with a fibrous sheath, for a short distance, upon the tendon. Sometimes the ring is supported, or in part formed, by a process of bone.

Relations.—By its *superior surface* with the fourth nerve, supra-trochlear nerve, superior rectus, and periosteum of the orbit. By the *inferior surface* with the adipose tissue of the orbit, globe of the eye, upper border of the internal rectus, and the vessels and nerves crossing that border.

Nerve-supply.—The fourth nerve.

The **OBLIQUUS INFERIOR**, a thin and narrow muscle, *arises* from the inner margin of the superior maxillary bone, immediately external to the lachrymal groove, and passes beneath the inferior rectus, to be *inserted* into the outer and posterior part of the eyeball, at about two lines from the entrance of the optic nerve.

Relations.—By its *superior surface* with the inferior rectus muscle and eyeball; by the *inferior surface* with the periosteum of the floor of the orbit, and external rectus.

Nerve-supply.—Inferior division of the third nerve.

CAPSULE OF TENON.—The muscles of the orbit are separated from the globe of the eyeball and structures immediately surrounding the optic nerve, by a fascia, which is continuous with the broad tarsal ligament and tarsal cartilages. This fascia is termed *tunica vaginalis oculi*, or **capsule of Tenon**. It surrounds the eyeball except at the anterior part where it is reflected on the inside of the conjunctiva and eyelids, and is pierced anteriorly, for the passage of the six orbital muscles, by six openings, through which the tendons of the muscles play as through pulleys. Tubular prolongations are continued on to the muscles as they pierce the capsule, but soon become lost in their sheaths. From this fascia processes pass off into the fat of the orbit, and divide the cavity into a number of loculi filled with fat. The most important of these bands passes across the lower part of the orbit, and is attached to the malar and lachrymal bones; it slings up the orbital contents, and hence has been called the *suspensory ligament* by Lockwood. Other bands pass from the malar and lachrymal bones to the sheaths around the external and internal recti muscles; they serve to check the external and internal rotation of the eyeball, and have been named the *external* and *internal check ligaments*. The capsule of Tenon is a serous membrane and is lined with endothelium; it consists of a parietal and visceral layer, and the

space between these forms a lymph-space which is continuous with the space between the inner and outer sheath of the optic nerve.

Actions.—The levator palpebræ raises the upper eyelid. The four recti, acting singly, pull the eyeball in the four directions—upwards, downwards, inwards, and outwards. Acting by pairs, they carry the eyeball in the diagonal of these directions, viz., upwards and inwards, upwards and outwards, downwards and inwards, downwards and outwards. Acting all together, they directly retract the globe within the orbit. The superior oblique muscle, acting alone, rolls the globe inwards and forwards, and carries the

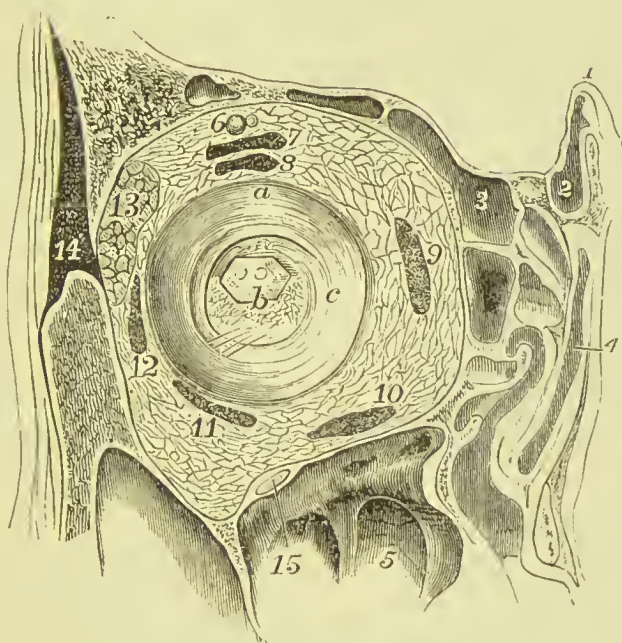


FIG. 184.—Section of right orbit seen from the front, and showing orbital contents and capsule of Tenon. 1. Crista galli. 2. Infundibulum. 3. Frontal sinus. 4. Superior meatus of nose. 5. Antrum of Highmore. 6. Supra-orbital vessels and nerve. 7. Levator palpebræ. 8. Superior rectus. 9. Internal rectus. 10. Inferior rectus. 11. Inferior oblique. 12. External rectus. 13. Lachrymal gland. 14. Temporal muscle. 15. Infra-orbital nerve. a. Cut edge of capsule of Tenon. b. Optic nerve with small portion of sclerotic coat attached. c. Cavity for the eyeball, formed by the capsule of Tenon.

pupil outwards and downwards to the lower and outer angle of the orbit. The inferior oblique, acting alone, rolls the globe outwards and backwards, and carries the pupil outwards and upwards to the upper and outer angle of the eye. The superior rectus when acting alone tends not only to raise the eyeball, but also to carry it inwards, and rotate it slightly on its own axis; this tendency to inversion and rotation is corrected by the combination of that muscle with the inferior oblique, the latter tending to direct the pupil outwards and to rotate the ball in the opposite direction to the rectus. In like manner the inferior rectus and superior oblique are combined in

their action, the oblique muscle correcting the tendency of the rectus to carry the eyeball inwards, and to rotate the ball on its own axis. In all oblique movements of direction there is a combination of two recti with one oblique muscle; the actions performed by the several muscles, and the way in which they are associated, are well shown in the subjoined table taken from Beaunis' work:—

Number of Muscles in Activity.	Direction of Line of Regard.	Muscles Acting.
ONE	{ Inwards Outwards	Internal rectus.
		External rectus.
TWO	{ Upwards Downwards	Superior rectus.
		Inferior oblique.
	{ Inwards and Up- wards Inwards and Down- wards	Inferior rectus.
		Superior oblique.
THREE	{ Inwards and Up- wards Inwards and Down- wards	Internal rectus.
		Superior rectus.
	{ Outwards and Up- wards Outwards and Down- wards	Inferior oblique.
		Internal rectus.
	{ Inwards and Up- wards Inwards and Down- wards	External rectus.
		Superior rectus.
{ Outwards and Up- wards Outwards and Down- wards	Inferior oblique.	
	External rectus.	

5. Nasal Group.—

Pyramidalis nasi,
Compressor nasi,

Dilatator naris.
Depressor alæ nasi.

Dissection.—The incision already made down the centre of the nose is to be continued round the margin of the ala to the lower edge of the septum, from thence down the middle of the upper lip to its free margin; from this point it should be carried round the mouth to the middle of the lower lip, and from thence vertically downwards to the chin. The whole of the flap must now be carefully dissected back, care being taken to keep the knife very close to the inner surface of the skin.

The **PYRAMIDALIS NASI** is a small pyramidal slip of muscular fibres sent downwards on the bridge of the nose by the occipito-frontalis. It becomes tendinous and is *inserted* into the tendinous expansion of the compressor nasi.

Relations.—By its *upper surface* with the integument; by its *under surface* with the periosteum of the frontal and nasal bone. Its *outer border* corresponds with the edge of the orbicularis palpebrarum: its *inner border* with its fellow, from which it is separated by a narrow areolar interval.

Nerve-supply.—Infraorbital branch of facial

The **COMPRESSOR NASI** is a thin and triangular muscle; it *arises* by its apex from the canine ridge of the superior maxillary bone, and spreads out upon the side of the nose into a thin tendinous expansion, which is continuous across the ridge with the muscle of the opposite side, and above with the tendon of the pyramidalis nasi. It is connected at its origin with a muscular fasciculus which is attached to the nasal process of the superior maxillary bone immediately below the origin of the levator labii superioris alæque nasi. This muscular slip was termed by Albinus, *musculus anomalus*, from its attachment to bone by both ends.

Relations.—By its *superficial surface* with the levator labii superioris proprius, levator labii superioris alæque nasi, and integument; by its *deep surface* with the superior maxillary and nasal bones, and with the alar and lateral cartilages of the nose.

Nerve - supply.—Infraorbital branch of facial.

The **DILATATOR NARIS** is a thin and indistinct muscular apparatus expanded on the ala of the nostril, and consisting of an anterior and posterior slip. The anterior slip (**levator proprius alæ nasi anterior**) *arises* from the upper border and surface of the alar cartilage, and is *inserted* into the integument of the border of the nostril. The posterior slip (**levator proprius alæ nasi posterior**) *arises* from the nasal process of the superior maxillary bone and sesamoid cartilages, and is *inserted* into the posterior half of the integument of the border of the nostril. These muscles are difficult of dissection, from the close adhesion of the integument to the nasal cartilages.

Nerve-supply.—Infraorbital branch of facial.

The **DEPRESSOR ALÆ NASI** (depressor labii superioris alæque nasi) is brought into view by drawing upwards the upper lip and raising the mucous membrane. It *arises* from the incisive fossa of the superior maxillary bone, and passes upwards and inwards to be *inserted* into the posterior part of the columna and ala nasi. It is closely connected with the deep surface of the orbicularis.

Relations.—By its *superficial surface* with the mucous membrane

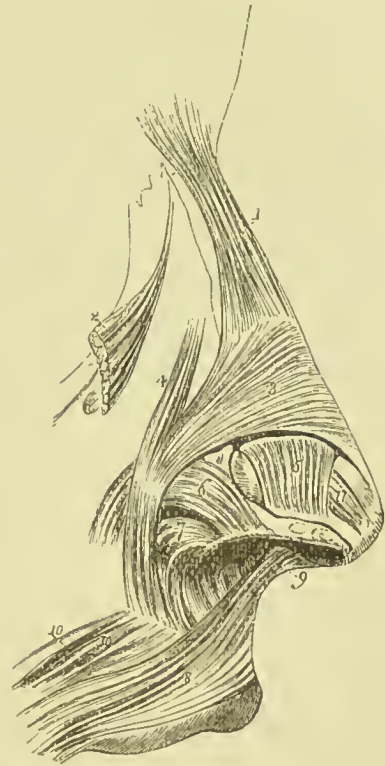


FIG. 185.—Muscles of the nose. 1. Pyramidalis nasi. 2. Upper part of the levator labii superioris alæque nasi turned aside. 3. Compressor nasi. 4. Musculus anomalus. 5. Levator proprius alæ nasi anterior. 6. Levator proprius alæ nasi posterior. 7. Part of the depressor alæ nasi. 8. Upper segment of the orbicularis oris. 9. Naso-labialis. 10. Accessory slips of the orbicularis.

of the mouth, orbicularis oris, and levator labii superioris alæque nasi; by its *deep surface* with the superior maxillary bone.

Nerve-supply.—Infraorbital branch of facial.

Actions.—The pyramidalis nasi, as a point of attachment of the occipito-frontalis, assists that muscle in its action: it also draws down the inner angle of the eyebrow and produces short horizontal wrinkles across the root of the nose. By its insertion it fixes the aponeurosis of the compressores nasi, and tends to elevate the nose. The compressores nasi appear to act in expanding rather than compressing the nares. The dilatator naris is a dilator of the nostril, and the depressor alæ nasi draws downwards both the ala and columnna of the nose, the depression of the latter being assisted by the naso-labialis.

6. Superior Labial Group.—

Orbicularis oris,	Levator anguli oris,
Levator labii superioris alæque nasi,	Zygomaticus major,
Levator labii superioris proprius,	Zygomaticus minor.

Dissection.—The skin has been already removed in order to display the preceding group, but it is necessary now to put a hook in the angle of the mouth and carry it downwards, so as to keep the muscles of the upper lip on the stretch during the removal of the muscular fascia.

The **ORBICULARIS ORIS** is a sphincter muscle, completely surrounding the mouth, and possessing consequently neither origin nor insertion. The upper part is attached by means of a small muscular fasciculus (*naso-labialis*) to the columnna of the nose. It is divisible into two portions, *internal* or *marginal*, in immediate contact with the lips, and thick; and *external*, broad and thin; the separation between the two being indicated by the coronary arteries. The internal fibres are continued uninterruptedly from one lip to the other round the angle of the mouth, the external fibres decussate with those of the buccinator, the upper fibres of the orbicularis being continued into the lower ones of the latter muscle, and *vice versâ*. Accessory fibres spring from the incisive fossa of the upper and lower jaw, and pass to the deep aspect of the muscle. In addition to the buccinator its fibres intermingle with those of the levator labii superioris proprius, levator labii superioris alæque nasi, depressor labii superioris alæque nasi, levator anguli oris, zygomaticus major, risorius Santorini, depressor anguli oris, depressor labii inferioris, and levator labii inferioris.

Relations.—By its *superficial surface* with the integument of the lips, with which it is closely connected. By its *deep surface* with the mucous membrane of the mouth, the labial glands and coronary arteries being interposed. By its *circumference* with the numerous muscles which move the lips, and by the *inner border* with the mucous membrane of the margin of the month.

Nerve-supply.—Infraorbital and buccal branches of the facial.

The **LEVATOR LABII SUPERIORIS ALÆQUE NASI** is a thin triangular muscle; it *arises* from the upper part of the nasal process of the superior maxillary bone, and, becoming broader as it descends, is *inserted* by two portions, one into the ala of the nose, the other into the orbicularis oris and upper lip.

Relations.—By its *superficial surface* with the orbicularis palpebrarum, facial artery, and integument. By its *deep surface* with the superior maxillary bone, musculus anomalus, compressor nasi, dilatator naris, and alar cartilage.

Nerve-supply.—Infraorbital branch of facial.

The **LEVATOR LABII SUPERIORIS PROPRIUS** is a thin quadrilateral muscle; it *arises* from the lower border of the orbit, immediately above the infraorbital foramen, and passing obliquely downwards and inwards, is *inserted* into the integument of the upper lip, its deep fibres being blended with those of the orbicularis.

Relations.—By its *superficial surface* with the lower segment of the orbicularis palpebrarum, facial artery, and integument. By its *deep surface* with the compressor nasi, levator anguli oris, orbicularis oris, and infraorbital artery and nerve.

Nerve-supply.—Infraorbital branch of facial.

The **LEVATOR ANGULI ORIS** *arises* from the canine fossa of the superior maxillary bone, and passes obliquely downwards and outwards to be *inserted* into the angle of the mouth; its fibres being continued into the orbicularis and depressor anguli oris.

Relations.—By its *superficial surface* with the levator labii superioris proprius, branches of the infraorbital artery and nerve, and inferiorly with the integument. By its *deep surface* with the superior maxillary bone and buccinator muscle.

Nerve-supply.—Infraorbital branch of facial.

The **ZYGOMATIC** muscles are two slender fasciculi of fibres which *arise* from the malar bone, and are *inserted* into the upper lip. The zygomaticus major descends to the angle of the mouth, and is continuous with the inferior segment of the orbicularis, depressor anguli oris, and risorius Santorini. The zygomaticus minor, lying in front of the major, becomes connected with the outer border of the levator labii superioris proprius, and is attached to the integument of the upper lip. This muscle is in reality only a detached slip of the orbicularis palpebrarum.

Relations.—The *zygomaticus major* is in relation by its *superficial surface* with the lower segment of the orbicularis palpebrarum above, and with the fat of the cheek and integument for the rest of its extent. By its *deep surface* with the malar bone, masseter, buccinator, and facial vessels.

Nerve-supply.—Infraorbital branch of facial.

Actions.—The orbicularis oris produces the direct closure of the lips by means of its continuity, at the angles of the mouth, with the fibres of the buccinator. When acting singly in the forcible closure of the mouth, the integument is thrown into wrinkles, in consequence of its firm connection with the surface of the muscle; its naso-labial

fasciculus draws downwards the *columna nasi*. The levator labii superioris *alæque nasi* lifts the upper lip with the ala of the nose, and expands the opening of the nares. The levator labii superioris proprius is the proper elevator of the upper lip: acting singly, it draws the lip a little to one side. The levator proprius, and still more the levator *alæ nasi*, is brought into play in the expression of contempt or derision. The levator anguli oris lifts the angle of the mouth and draws it inwards, while the *zygomatici* pull it upwards and outwards, as in laughing, and produce the dimple in the cheek. In the movement of laughter the *zygomatici* are assisted by the risorius Santorini.

7. Inferior Labial Group.—

Depressor labii inferioris,
Depressor anguli oris,

Risorius Santorini,
Levator labii inferioris.

Dissection.—To dissect the inferior labial region, continue the incision already made along the margin of the lower jaw to its angle. Dissect off the integument and superficial fascia from this surface, and the muscles of the inferior labial region will be exposed.

The **DEPRESSOR LABII INFERIORIS** (*quadratus menti*) arises from the oblique line by the side of the symphysis of the lower jaw, and passing upwards and inwards, is inserted into the orbicularis muscle and integument of the lower lip. Its inner fibres interlace with those of the opposite muscle; the outer fibres reach nearly to the angle of the mouth. This muscle is very thin, and pale in colour, and its fibres are mixed with a considerable quantity of fat, so that it is very difficult to make a good dissection of it.

Relations.—By its *superficial surface* with the platysma myoides, part of the depressor anguli oris, and the integument of the chin with which it is closely connected. By the *deep surface* with the levator labii inferioris, labial glands, mucous membrane of the lower lip, and mental nerve and artery.

Nerve-supply.—Supra-maxillary of facial.

The **DEPRESSOR ANGULI ORIS** (*triangularis oris*) is a triangular plane of muscle arising by a broad base from the external oblique ridge of the lower jaw just below the mental foramen, and inserted by its apex into the angle of the mouth, where it is continuous with the levator anguli oris, zygomaticus major, and upper segment of the orbicularis. Near its insertion it is joined by the following muscle.

Relations.—By its *superficial surface* with the integument; by its *deep surface* with the depressor labii inferioris, buccinator, and branches of the mental nerve and artery.

Nerve-supply.—Supra-maxillary of facial.

The **RISORIUS SANTORINI** is a triangular muscle, partly formed by the continuation above the jaw of fibres of the platysma myoides, and partly of scattered and thin fibres arising from the fascia over the masseter and buccinator. It converges to the angle of the mouth

where it becomes connected with the outer border of the depressor anguli oris and zygomaticus major.

Nerve-supply.—Supra-maxillary of facial.

The **LEVATOR LABII INFERIORIS** (*levator menti*) is to be dissected by everting the lower lip and raising the mucous membrane. It is a short but strong muscle arising from the incisive fossa of the lower jaw, and inserted into the integument of the chin. It is in relation with the mucous membrane of the mouth, with its fellow, and with the depressor labii inferioris.

Nerve-supply.—Supra-maxillary of facial.

The whole of the muscles of the face have attachments to the integuments, as well as to each other and to the bones, and it is chiefly in consequence of the integumentary attachments that they act as muscles of expression, for it is by this means that the ridges and furrows which give such characteristic expressions to the face are produced.

Actions.—The depressor labii inferioris draws the lower lip downwards, and a little outwards. The depressor anguli oris, from the radiated direction of its fibres, will pull the angle of the month either downwards and forwards, or downwards and backwards, and be expressive of grief; or acting with the levator anguli oris, zygomaticus major, and risorius Santorini, will draw the angle of the month upwards and backwards, or directly backwards. The levator labii inferioris raises and protrudes the integument of the chin.

8. Maxillary Group.—

Masseter,
Temporal,

Buccinator,
Pterygoidens externus,
Pterygoidens internus.

Dissection.—The flap already obtained must be carried as far back as the posterior margin of the ramus of the jaw, and the structures which cover the masseter must be cut away.

FASCIA.—The masseter muscle is covered by a strong layer of fascia continued on to it from the surface of the parotid gland (*parotideo-masseteric fascia*); below, it may be traced into the neck, where it is found to be continuous with the anterior layer of the deep cervical fascia. It is intimately connected with the tendinous fibres of the muscle, and is attached above to the lower border of the zygomatic arch.

The **MASSETER** (*μασσάομαι*, to chew) is a short, thick, and somewhat quadrilateral muscle, composed of two planes of fibres, superficial and deep. The *superficial* layer arises by a strong aponeurosis from the malar process of the superior maxillary bone and lower border of the malar bone, and passes downwards and backwards to be inserted into the ramus and angle of the inferior maxilla. The *deep* layer arises from the lower border of the malar bone and zygomatic process of the temporal, and passes downwards and forwards to be inserted into the upper half of the ramus.

Relations.—By its *external surface* with the zygomaticus major, risorius Santorini and platysma myoides, parotid gland and Stenson's

duct, transverse facial artery, pes anserinus, and integument. By its *internal surface* with the temporal muscle, buccinator, from which it is separated by a mass of fat, and ramus of the lower jaw. By its *posterior border* with the parotid gland; by the *anterior border* with the facial artery and vein.

Nerve-supply.—Masseteric branch of the inferior maxillary of the fifth cerebral nerve.

FASCIA.—The strong aponeurotic layer which covers the temporal muscle is called the **temporal fascia** or **aponeurosis**; it is attached above to the posterior border of the malar bone and the upper temporal crest on the frontal, parietal, and temporal bones. Below it separates into two layers, between which there is a small quantity of fat, a small nerve derived from the orbital branch of the superior maxillary nerve, and the orbital branch of the temporal artery. Of these two layers one is attached to the outer, and the other to the inner surface of the zygoma.

Dissection.—Make an incision along the upper border of the zygoma, for the purpose of separating the temporal fascia from its attachment. Then saw through the zygomatic process of the malar bone, and through the root of the zygoma near the meatus auditorius. Draw down the zygoma, and with it the origin of the masseter, and dissect the latter muscle away from the ramus and angle of the inferior maxilla. Now remove the temporal fascia from the rest of its attachment, and the whole of the temporal muscle will be brought into view.

The **TEMPORAL** is a broad and radiating muscle, occupying a considerable extent of the side of the head, and filling the temporal fossa. It *arises* by tendinous fibres from the whole length of the inferior temporal crest, and by muscular fibres from the temporal fascia and entire surface of the temporal fossa, excepting the anterior or malar wall. Its fibres converge to a strong and narrow tendon, which is *inserted* into the apex, internal surface, and anterior border of the coronoid process of the lower jaw, as far down as the junction of the body and ramus.

Relations.—By its *external surface* with the temporal fascia (which separates it from the attollens and attrahens auriculam muscles, and temporal vessels and nerves) and with the zygoma and masseter. By its *internal surface* with the bones forming the temporal fossa, the external pterygoid muscle, part of the buccinator, and the internal maxillary artery with its deep temporal branches.

Nerve-supply.—Temporal branches of the inferior maxillary of the fifth cerebral nerve.

Dissection.—Saw through the ramus of the lower jaw a little above the level of the crowns of the lower molar teeth, then divide the neck of the condyle with saw and bone-forceps. Now turn up the coronoid process and portion of ramus thus detached, together with the temporal muscle (which may be dissected from the fossa), and a view of the entire extent of the buccinator and external pterygoid muscles will be obtained.

The **BUCCINATOR** (*buccina*, a trumpet), the trumpeter's muscle, *arises* from the base of the alveolar processes of the superior and inferior maxillary bones, corresponding to the three molar teeth, and the **pterygo-maxillary ligament**. This ligament is the raphé of union between the buccinator and superior constrictor muscles, and is attached by one extremity to the hamular process of the internal pterygoid plate, and by the other to the extremity of the molar ridge of the lower jaw. The fibres of the muscle converge towards the angle of the mouth, where some are continuous with the levator and depressor anguli oris, and the greater number cross each other, the superior being continuous with the inferior segment of the orbicularis oris, the inferior with the superior segment. The fibres along the upper border of the muscle pass directly into the upper fibres of the orbicularis and do not decussate, and those along the lower border in like manner pass directly into the lower fibres of that muscle. The muscle is invested externally by a thin fascia (buccal) which extends backwards to the pharynx.

Relations.—By its *external surface*, posteriorly, with a large and rounded mass of fat, which separates the muscle from the ramus of the lower jaw, temporal, and masseter: *anteriorly* with the risorius Santorini, zygomatici, levator anguli oris, and depressor anguli oris. It is also in relation with a part of Stenson's duct (which pierces it opposite the second molar tooth of the upper jaw), with the transverse facial artery, branches of the facial and buccal nerves, and facial and buccal arteries and veins. By its *internal surface* with the buccal glands and mucous membrane of the mouth.

Nerve-supply.—Buccal branch of facial, which supplies it on its superficial surface.

The **PTERYGOIDEUS EXTERNUS** is a short and thick muscle, broader at its origin than at its insertion. It *arises* by two heads, *one* from the pterygoid ridge on the under surface of the great wing of the sphenoid; the *other* from the outer surface of the external pterygoid plate, tuberosity of the palate bone and tuberosity of the superior maxillary. The fibres pass backwards to be *inserted* into a depression on the anterior aspect of the neck of the lower jaw, and into the interarticular fibro-cartilage. The internal maxillary artery passes between the two heads of this muscle, and the lower head is commonly pierced by the buccal branch of the fifth nerve.

Relations.—By its *external surface* with the ramus of the lower jaw, temporal muscle, and internal maxillary artery; by its *internal surface* with the internal pterygoid muscle, internal lateral ligament of the jaw, middle meningeal artery, and inferior maxillary nerve; by its *upper border* with the muscular branches of the inferior maxillary nerve.

Nerve-supply.—Buccal branch of inferior maxillary.

Dissection.—The condyle of the jaw must now be removed from its socket, and, together with the external pterygoid, be turned over towards the nose, so as to expose the internal pterygoid.

The **PTERYGOIDEUS INTERNUS** is a thick quadrangular muscle

It *arises* from the pterygoid fossa, being attached to the inner surface of the external pterygoid plate, and that part of the tuberosity of the palate bone which is interposed between the pterygoid plates ;

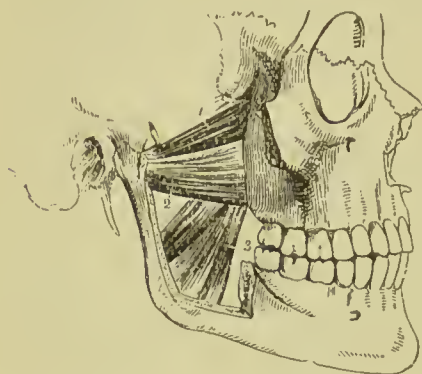


FIG. 186.—The two pterygoid muscles. The zygomatic arch and the greater part of the ramus of the lower jaw have been removed in order to bring these muscles into view. 1. The sphenoid head of the external pterygoid. 2. Its pterygoid head. 3. The internal pterygoid.

it also gets an additional origin from the angle between the outer surface of the external pterygoid plate and the tuberosity of the superior maxillary bone. It descends obliquely backwards, to be *inserted* into the inner surface of the angle of the lower jaw. It resembles the masseter in appearance and direction, and was named by Winslow *internal masseter*.

Relations.—By its *external surface* with the external pterygoid, inferior maxillary nerve and branches, internal maxillary artery and branches, internal lateral ligament, and ramus of the lower jaw. By its *internal surface* with the tensor palati, superior constrictor and fascia of the pharynx ; by its posterior border with the parotid gland.

Nerve-supply.—Pterygoid branch of inferior maxillary.

Actions.—The maxillary muscles are the active agents in mastication, and form an apparatus admirably fitted for that office. The buccinator circumscribes the cavity of the mouth, and with the aid of the tongue keeps the food under the immediate pressure of the teeth. By means of its connection with the superior constrictor, it shortens the cavity of the pharynx from before backwards, and becomes an auxiliary in deglutition. The temporal, the masseter, and the internal pterygoid are the bruising muscles, drawing the lower jaw against the upper with great force. The two latter, from the obliquity of their direction, assist the external pterygoid in grinding the food, by carrying the lower jaw forward upon the upper ; the jaw being brought back again by the deep portion of the masseter and posterior fibres of the temporal. The external pterygoid muscles, when both act together, draw the jaw forwards, but more frequently they act alternately, each drawing the jaw forwards and towards the opposite side, so as to produce by their alternate action the grinding movements of the molar teeth. The internal pterygoid assists the external muscle of the same side in protracting the jaw, and throwing the teeth towards the opposite side. The temporal is the only muscle of mastication which *retracts* the jaw ; all the rest *protract* it. The whole of these muscles, acting in succession, produce a rotatory movement of the teeth upon each other, which, with the direct action of the lower jaw against the upper, effects the mastication of the food.

MUSCLES AND FASCIÆ OF THE NECK.

The muscles of the neck may be arranged into eight groups, corresponding with the natural divisions of the region ; they are :—

1. Superficial group.
2. Depressors of the os hyoides and larynx.
3. Elevators of the os hyoides and larynx.
4. Lingual group.
5. Pharyngeal group.
6. Palatine group.
7. Prævertebral group.
8. Laryngeal group.

Superficial Group.—

Platysma myoides.
Sterno-cleido mastoid.

Dissection.—The dissection of the neck should be commenced by making an incision along the middle line of its fore-part from the chin to the sternum, and bounding it superiorly and inferiorly by two transverse incisions ; the superior being carried along the margin of the lower jaw, and across the mastoid process to the protuberance on the occipital bone, the inferior along the clavicle to the acromion process. The square flap of integument thus included should be turned back from the entire side of the neck, which brings into view the superficial fascia, and on the removal of a thin layer of this the platysma myoides will be exposed.

The **superficial cervical fascia** is a part of the common superficial fascia of the entire body, and is only interesting from containing between its layers the platysma myoides muscle.

The **PLATYSMA MYOIDES** (*πλατύς μὲς εἶδος*, broad muscle-like lamella) is a thin plane of muscular fibres, situated beneath the integument on the side of the neck. It *arises* from the fascia over the pectoralis major and deltoid muscle, and from the clavicle and acromion ; it passes obliquely upwards and inwards to be *inserted* into the side of the chin, oblique line of the lower jaw, angle of the mouth, and integument of the face. The anterior fibres mingle beneath the chin with those of the muscle of the opposite side ; the next interlace with the depressor anguli oris and depressor labii inferioris ; the posterior fibres are disposed in a transverse direction across the lower part of the face, arising from the fascia over the parotid gland and masseter muscle, and inserted into the angle of the mouth, where they form part of the risorius Santorini muscle. The entire muscle is analogous to the cutaneous muscle of brutes, the *panniculus carnosus*.

Relations.—By its *external surface* with the integument, with which it is closely adherent below, but loosely above. By its

internal surface, below the clavicle, with the pectoralis major and deltoid; in the neck with the trapezius, sterno-mastoid, external jugular vein and deep cervical fascia; on the face, with the parotid gland, masseter, facial artery and vein, buccinator, depressor anguli oris, and depressor labii inferioris.

Nerve-supply.—Its upper part by the facial, its lower by the superficial cervical.

Dissection.—The platysma is now to be removed, commencing in front and turning it backwards towards the spine; great care must be taken not to cut the branches of the superficial cervical plexus, or the external jugular vein which lies beneath it. The deep cervical fascia will now be exposed, and must be carefully studied.

The **deep cervical fascia** is a strong areolo-fibrous membrane, which invests the muscles of the neck, and retains and supports the vessels and nerves. It commences posteriorly at the ligamentum nuchæ, and passes forwards at each side beneath the trapezius

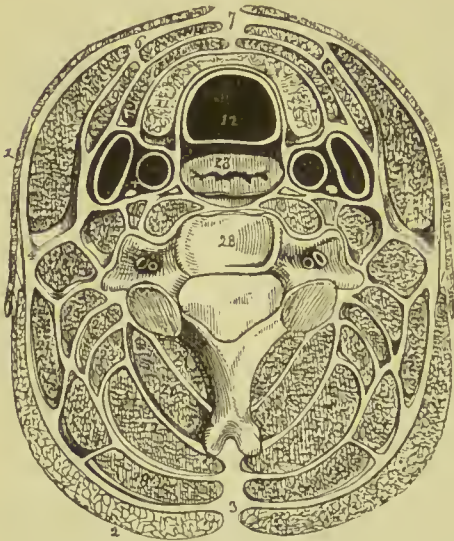


FIG. 187.—Transverse section of the neck, showing the deep cervical fascia and its prolongations forming sheaths for the muscles. 1. Platysma myoides. 2. Trapezius. 3. Ligamentum nuchæ. 4. The point at which the fascia divides to form the sheath for the sterno-mastoid (5). 6. The point of reunion of the two layers. 7. The point of union of the fascia of opposite sides of the neck. 8. Sterno-hyoid. 9. Omo-hyoid. 10. Sterno-thyroid. 11. Lateral lobe of the thyroid gland. 12. Trachea. 13. Esophagus. 14. Carotid sheath. 15. Longus colli. The nerve in front of the sheath of this muscle is the sympathetic. 16. Rectus anticus major. 17. Scalenus anticus. 18. Scalenus medius. 19. Splenius capitis. 20. Splenius colli. 21. Levator anguli scapulae. 22. Complexus. 23. Trachelo-mastoid. 24. Transversalis cervicis. 25. Cervicalis ascendens. 26. Semi-spinalis colli. 27. Multifidus spinæ. 28. Cervical vertebra.

muscle to the posterior border of the sterno-mastoid; here it divides into two layers, which embrace that muscle and unite upon its anterior border to be prolonged onwards to the middle line of the neck, where it is continuous with the fascia of the opposite side. Besides constituting a sheath for the sterno-mastoid, it also forms sheaths for the other muscles of the neck over which it passes. If the superficial layer (anterior layer) of the sheath of the sterno-mastoid be traced upwards, it will be found to pass over the parotid gland and masseter muscle (fascia parotideo-masseterica), to be inserted into the zygomatic arch; traced downwards, it will be seen to pass to the front of the clavicle, to which it becomes attached. If the deep layer (posterior layer) of the sheath be examined supe-

riorly, it will be found attached to the styloid process, from which it is reflected to the angle of the lower jaw, forming the *stylo-maxillary ligament*; followed downwards, a process of it will be found connected with the tendon of the omo-hyoid muscle, binding it down to the clavicle, while still lower it becomes continuous with the costo-coracoid membrane. It is pierced in the posterior triangle of the neck by the external jugular vein. In the middle line the deep cervical fascia is thin above where it becomes attached to the hyoid bone, but as it descends it becomes thicker and splits into two layers, a superficial and a deep, between which there is a little fat and areolar tissue, as well as a lymphatic gland. The superficial of these layers is attached to the anterior edge of the sterno-mastoid, and below to the sternum and inter-clavicular ligament; the deep layer is intimately connected with the sterno-hyoid and sterno-thyroid, ensheathing them, and becoming attached to the posterior surface of the sternum. Still deeper in the anterior triangle, a thin sheet of fascia passes behind the depressor muscles of the hyoid to invest the thyroid body, and being continued on to the trachea may be traced to the fibrous layer of the pericardium, with which it blends. The deep cervical fascia also forms a sheath for the common carotid artery, internal jugular vein, and pneumogastric nerve, a fibrous septum intervening between the artery and vein. That portion of the fascia which covers the muscles lying on the front of the vertebral column, and intervenes between them and the pharynx and œsophagus, is called the *pre-vertebral fascia*.

Dissection.—Remove the deep cervical fascia and expose the sterno-mastoid muscle.

The **STERNO-CLEIDO MASTOID** is the large oblique muscle of the neck, and is situated between two layers of the deep cervical fascia. It *arises*, as implied by its name, from the sternum and clavicle (*κλειδιον*), and passes obliquely upwards and backwards, to be *inserted* into the mastoid process of the temporal, and superior curved line of the occipital bone. The sternal portion arises by a rounded tendon, increases in breadth as it ascends, and spreads out to a considerable extent at its insertion. The clavicular portion is broad and fleshy, separate from the sternal portion below, but blended with the posterior surface of the latter as it ascends.

The two portions of this muscle are sometimes described as separate muscles under the names of *sterno-mastoid* and *cleido-mastoid*, these being again occasionally subdivided, the first into *sterno-mastoid* and *sterno-occipital*, and the second into *cleido-mastoid* and *cleido-occipital*. The cleido-mastoid is the most deeply seated slip of the muscle, and has a separate attachment to the mastoid process; it is generally perforated by the spinal accessory nerve.

Relations.—By its *superficial surface* with the integument, *platysma myoides*, external jugular vein, superficial branches of the cervical plexus of nerves, and anterior layer of the deep cervical fascia. By its *deep surface* with the deep layer of the cervical fascia, sterno-clavicular articulation, sterno-hyoid, sterno-thyroid, omo-

hyoid, scilicet, levator anguli scapulae, splenii, and posterior belly of the digastricus muscle; phrenic nerve, transversalis colli, and supra-scapular artery; deep lymphatic glands, sheath of the common carotid and internal jugular vein, descendens cervicis nerve, external carotid artery with its posterior branches, and commencement of the internal carotid artery; cervical plexus of nerves, pneumogastric spinal accessory, hypoglossal, sympathetic, and facial nerves, and parotid gland. It is pierced on this aspect by the spinal accessory nerve.

Nerve-supply.—Spinal accessory nerve, and branches of the second and third cervical nerves.

Actions.—The platysma produces a muscular traction on the integument of the neck, which prevents it from falling so flaccid in

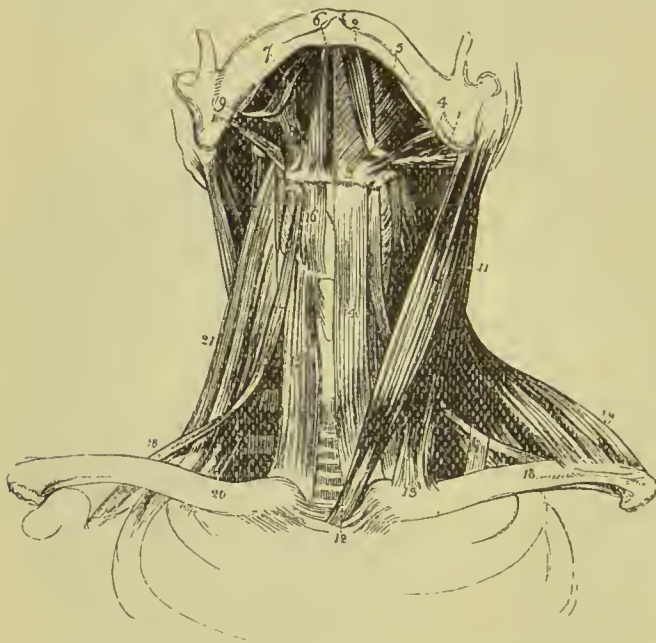

FIG. 188.—Muscles of the anterior aspect of the neck; on the right side of the figure the superficial muscles are seen, on the left the deep. 1. Posterior belly of digastricus. 2. Its anterior belly. Aponeurotic pulley, through which its tendon is seen passing, attached to the body of the os hyoides. 3. 4. Stylo-hyoid muscle transfixed by the posterior belly of the digastricus. 5. Mylo-hyoid. 6. Genio-hyoid. 7. The tongue. 8. Hyo-glossus. 9. Stylo-glossus. 10. Stylo-pharyngeus. 11. Sterno-mastoid. 12. Its sternal origin. 13. Its clavicular origin. 14. Sterno-hyoid. 15. Sterno-thyroid of the right side. 16. Thyro-hyoid. 17. Hyoid por-

tion of the omo-hyoid. 18, 18. Its scapular portion; on the left side, the tendon of the muscle is seen to be bound down by a portion of the deep cervical fascia. 19. Clavicular portion of the trapezius. 20. Scalenus anticus, of the right side. 21. Scalenus posticus; the scalenus medius is seen between the two.

old persons as it would if the extension of the skin were the mere result of elasticity. It draws also on the angle of the mouth, and is one of the depressors of the lower jaw. It assists in the expression of the emotion of fright or extreme fear. The sternomastoid muscles (*nutatores capitis*) are the great anterior muscles of connection between the thorax and the head. Both muscles acting together, when the spine is fixed, raise the head and carry it backwards. The clavicular portions, acting more forcibly than the sternal, give stability and steadiness to the head in supporting weights. Either muscle acting singly would draw the head towards

the shoulder of the same side, and carry the face towards the opposite side. If the head be fixed, they can raise the sternum in forced inspiration.

Regional Anatomy of the Neck.

The region of the neck is divided into two great triangles by the sterno-mastoid muscle. The **posterior triangle** is bounded by the posterior border of the muscle, by the clavicle, and by the anterior edge of the trapezius. The **anterior triangle** is bounded by the anterior border of the sterno-mastoid, by the lower border of the inferior maxilla, and a line drawn from the angle of this bone to the mastoid process, and by the mesial line.

The posterior triangle is subdivided into two by the scapular belly of the omo-hyoid muscle. The **posterior superior triangle** (occipital triangle) is bounded by the posterior border of the sterno-mastoid, the anterior edge of the trapezius, and the posterior belly of the omo-hyoid. Its floor is formed from above downwards by the splenius capitis, levator anguli scapulæ, scalenus posticus, scalenus medius, and upper digitation of the serratus magnus muscles. It contains the superficial descending branches of the cervical plexus, the spinal accessory nerve, the transversalis colli artery and vein, the superficialis colli artery, and the cervical lymphatics and glands.

The **posterior inferior** or **subclavian triangle** is bounded by the clavicle, the posterior belly of the omo-hyoid, and the posterior border of the sterno-mastoid. This triangle contains the third part of the brachial plexus; above and behind which are the trunks of the brachial plexus; below, and in front of it, almost overlapped by the clavicle, the subclavian vein, in close proximity to which, behind the clavicle, is the suprascapular artery, both of which vessels, although not strictly *in* the triangle, are apt to invade it as soon as the fascia is divided in the operation for ligature of the subclavian. The external jugular vein terminates in the subclavian vein about the middle of this space; near its termination it receives the transversalis colli and suprascapular veins. This triangle also contains a small nerve to the subclavius muscle and a lymphatic gland.

The **anterior triangle** has been divided into three—the inferior carotid, the superior carotid, and the submaxillary.

The **inferior carotid triangle** is bounded by the mesial line, the anterior border of the sterno-mastoid, and the anterior belly of the omo-hyoid. Its floor is formed by the longus colli muscle and vertebral column, and its roof by the integument, superficial fascia, platysma myoides, and deep cervical fascia. It contains the sterno-hyoid and sterno-thyroid muscles, common carotid artery, internal jugular vein, inferior thyroid artery, superior thyroid artery, thyroid body, lower part of larynx, trachea, lower part of pharynx, œsophagus, recurrent laryngeal nerve, descendens and communicans cervicis nerves, sympathetic nerves, inferior thyroid veins, and one or two lymphatic glands.

The **superior carotid triangle** (the place of selection for ligature of the carotid artery) is bounded by the anterior border of the sterno-mastoid, the anterior belly of the omo-hyoid, and the posterior belly of the digastricus. Its floor is formed by parts of the thyro-hyoid, hyo-glossus, and middle and inferior constrictor muscles, and its roof by the integument, superficial fascia, platysma, and deep fascia. It contains the common, external and internal carotid arteries, the superior thyroid, lingual, facial, occipital, and ascending pharyngeal arteries; the superior thyroid, lingual, facial, ascending pharyngeal and internal jugular veins; the hypoglossal, vagus, spinal accessory, descendens cervicis, superior laryngeal and sympathetic nerves; the upper part of larynx and lower part of pharynx; some lymphatic vessels and glands.

The **submaxillary triangle** is bounded above by the lower border of the body of the lower jaw, the parotid gland and mastoid process, below by the posterior belly of the digastricus and the stylo-hyoid, in front by the mesial line. Its floor is formed by the anterior belly of the digastricus, the mylo-hyoid and hyo-glossus muscles. The space contains the submaxillary gland, facial artery and vein, submental artery, mylo-hyoid artery and nerve, external carotid artery, part of the parotid gland, internal carotid artery, commencement of external and interior jugular veins, pneumogastric and glosso-pharyngeal nerves, and submaxillary lymphatic vessels and glands.

Second Group.—Depressors of the Os Hyoides and Larynx.

Sterno-hyoid,
Sterno-thyroid,

Thyro-hyoid,
Omo-hyoid.

Dissection.—These muscles are brought into view by removing the deep fascia from the front of the neck between the two sterno-mastoid muscles. The omo-hyoid to be seen in its whole extent requires that the sterno-mastoid muscle be divided from its origin and turned aside.

The **STERNO-HYOID** is a narrow ribbon-like muscle, *arising* from the posterior surface of the first bone of the sternum and from the inner extremity of the clavicle. It is *inserted* into the lower border of the body of the hyoid bone.

Relations.—By its *superficial surface* with the sternum, sternal end of clavicle, deep cervical fascia, platysma myoides and sterno-mastoid muscle; by its *deep surface* with the sterno-thyroid, crico-thyroid, and thyro-hyoid muscles, superior thyroid artery, thyroid gland, crico-thyroid and thyro-hyoid membranes.

Nerve-supply.—Descendens cervicis.

The **STERNO-THYROID**, broader than the preceding, beneath which it lies, *arises* from the posterior surface of the upper bone of the sternum, and from the cartilage of the first rib; it is *inserted* into the oblique line on the great ala of the thyroid cartilage. The inner

borders lie in contact along the middle line, and the muscles are sometimes marked by a tendinous intersection at their lower part. Some of the fibres of this muscle are continued directly into the thyro-hyoid without intervening attachment; others are continuous with the inferior constrictor.

Relations.—By its *external surface* with the sterno-hyoid, omo-hyoid, and sterno-mastoid muscle; by its *internal surface*, with the trachea, inferior-thyroid veins, thyroid gland, lower part of the larynx, sheath of the common carotid artery and internal jugular vein, subclavian vein, vena innominata, and on the right side, arteria innominata. The middle thyroid vein lies along its inner border.

Nerve-supply.—Descendens cervicis.

The **THYRO-HYOID** is the continuation upwards of the sterno-thyroid muscle. It *arises* from the oblique line on the thyroid cartilage, and is *inserted* into the lower border of the body, and great cornu of the os hyoides for one-half its length.

Relations.—By its *external surface* with the sterno-hyoid and omo-hyoid muscle; by its *internal surface* with the great ala of the thyroid cartilage, thyro-hyoid membrane, and superior laryngeal artery and nerve.

Nerve-supply.—A special branch of the hypoglossal.

The **OMO-HYOID** (*ὤμος*, shoulder) is a double-bellied muscle passing obliquely across the neck from the scapula to the os hyoides; it forms an obtuse angle behind the sterno-mastoid, and is retained in that position by a process of the deep cervical fascia which forms a sheath for its tendon and holds it in connection with the sternum and first rib. It *arises* from the upper border of the scapula and transverse ligament of the suprascapular notch, and is *inserted* into the hyoid bone at the junction of the body and great cornu.

Relations.—By its *superficial surface* with the trapezius, subclavius, clavicle, deep cervical fascia, platysma myoides, sterno-mastoid, and integument. By its *deep surface* with the brachial plexus, scaleni muscles, phrenic nerve, sheath of the common carotid artery and jugular vein, descendens cervicis nerve, sterno-thyroid and thyro-hyoid muscle, and the sterno-hyoid at its insertion.

Nerve-supply.—Descendens cervicis.

Actions.—The four muscles of this group are depressors of the hyoid bone and larynx, the three former drawing these parts downwards in the middle line, and the two omo-hyoid muscles regulating their traction to the one or other side of the neck, according to the position of the head. The omo-hyoid muscles, by means of their connection with the deep cervical fascia, are rendered tensors of that portion of the deep fascia which covers the lower part of the neck, between the two sterno-mastoid muscles. The thyro-hyoid muscles, by approximating the hyoid bone to the thyroid cartilage, relax the hyo-epiglottic ligament, and permit the epiglottis to fall down over the aperture of the larynx during deglutition (G. Buchanan).

Third Group.—Elevators of the Os Hyoides.

Digastricus,
Stylo-hyoid,
Mylo-hyoid,

Genio-hyoid,
Genio-hyo-glossus.

Dissection.—These are best dissected by placing a high block beneath the neck, and throwing the head backwards. The integument has been already dissected away, and the removal of some areolar tissue and fat brings them clearly into view.

The **DIGASTRICUS** (*dis*, twice ; *γαστήρ*, belly ; biventer) is a small muscle situated immediately beneath the side of the body of the lower jaw ; fleshy at each extremity, and tendinous in the middle. It *arises* from the digastric fossa and anterior border of the mastoid process of the temporal bone ; pierces by its posterior belly the stylo-hyoid muscle, and is *inserted* into a depression on the inner side of the lower jaw, close to the symphysis. The middle tendon is held in connection with the body of the os hyoides by an aponeurotic loop, through which it plays as through a pulley ; the loop being lubricated by a synovial membrane. A thin layer of aponeurosis is given off from the tendon of the digastricus at each side, which is connected with the body of the os hyoides, and forms a strong plane of fascia between the anterior portions of the two muscles. This fascia, the *supra-hyoidean*, is continuous with the deep cervical fascia.

Relations.—By its *superficial surface* with the platysma myoides, sterno-mastoid, trachelo-mastoid, anterior fasciculus of the stylo-hyoid muscle, parotid gland, and submaxillary gland. By its *deep surface* with the styloid muscles, hyo-glossus, mylo-hyoid, external carotid artery, lingual and facial arteries, internal carotid artery, jugular vein, and hypoglossal nerve.

Nerve-supply.—The anterior belly of the digastric muscle is supplied by the mylo-hyoid nerve, a branch of the inferior maxillary ; the posterior belly by a branch of the facial.

The **STYLO-HYOID** is a small and slender muscle situated in immediate relation with the posterior belly of the digastricus, by which it is pierced. It *arises* from the middle of the styloid process, its outer side, and is *inserted* in the body of the os hyoides near the union of the lesser cornu with the body.

Relations.—By its *superficial surface* with the posterior belly of the digastricus, parotid gland and submaxillary gland ; its deep relations are similar to those of the posterior belly of the digastricus.

Nerve-supply.—A branch of the facial.

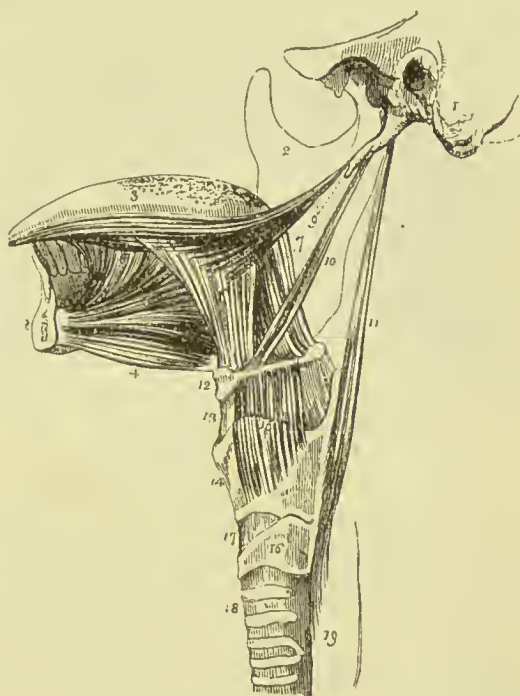
Dissection.—The digastricus and stylo-hyoid must be removed from their connection with the lower jaw and os hyoides, and turned aside, in order to see the next muscle.

The **MYLO-HYOID** (*μύλη*, mola, *i.e.*, attached to the molar ridge of the lower jaw) is a broad and triangular plane of muscular fibres, forming, with its fellow of the opposite side, the floor of the mouth.

It arises from the whole length of the molar ridge of the lower jaw, from the symphysis to the last molar tooth, and proceeds inwards and backwards to the middle line, where its fibres are continuous with those of the opposite side, the posterior fibres being *inserted* into the body of the os hyoides. At the middle line the union is tendinous on the upper surface in front, on the lower behind, the rest being fleshy.

Relations.—By its *superficial* or inferior surface, with the platysma myoides, digastricus, supra-hyoidean fascia, submaxillary gland, submental artery and mylo-hyoidean nerve and artery. By its *deep* or superior surface with the genio-hyoid, genio-hyo-glossus, hyo-glossus, stylo-glossus, gustatory nerve, hypoglossal nerve, Whar-

FIG. 189.—Styloid muscles and muscles of the tongue. 1. Temporal bone of the left side. 2, 2. The right side of the lower jaw, divided at its symphysis, the left side having been removed. 3. Tongue. 4. Genio-hyoid. 5. Genio-hyo-glossus. 6. Hyo-glossus; its basio-glossus portion. 7. Its cerato-glossus portion. 8. Anterior fibres of the inferior lingualis issuing from between the hyo-glossus and genio-hyo-glossus. 9. Stylo-glossus with part of the stylo-maxillary ligament. 10. Stylo-hyoid. 11. Stylo-pharyngeus. 12. Os hyoides. 13. Thyro-hyoid membrane. 14. Thyroid cartilage. 15. Thyro-hyoid muscle arising from the oblique line of the thyroid cartilage. 16. Cricoid cartilage. 17. Crico-thyroid membrane, through which the operation of laryngotomy is performed. 18. Trachea. 19. Commencement of the œsophagus.



ton's duct, sublingual gland, and mucous membrane of the floor of the mouth.

Nerve-supply.—The mylo-hyoid nerve, a branch of the inferior dental, which supplies it on its lower or superficial surface.

Dissection.—After the mylo-hyoid has been examined, it should be cut away from its origin and insertion, and completely removed. The view of the next muscles would also be improved by dividing the lower jaw a little to the side of the symphysis, and drawing it outwards; or removing it altogether if the ramus have been already cut across in dissecting the internal pterygoid muscle. The tongue may then be drawn out of the mouth by means of a hook.

The **GENIO-HYOID** ($\gamma\acute{\epsilon}\nu\epsilon\iota\omicron\nu$, the chin) arises from a small tubercle on the inner side of the symphysis of the lower jaw, and is *inserted* into the body of the os hyoides. It is a short and slender muscle,

closely connected with its fellow and with the border of the following.

Relations.—By its *superficial* or inferior *surface* with the mylo-hyoid; by the *deep* or superior *surface* with the lower border of the genio-hyo-glossus.

Nerve-supply.—The hypoglossal nerve.

The **GENIO-HYO-GLOSSUS** (γλωσσα, the tongue) is a triangular muscle, narrow and pointed at its origin from the lower jaw, broad and fan-shaped at its attachment to the tongue. It *arises* from a tubercle above that of the genio-hyoid, and spreads out to be *inserted* into the whole length of the tongue, from base to apex, and into the body of the os hyoides.

Relations.—By its *inner surface* with its fellow of the opposite side. By its *outer surface* with the mylo-hyoid, hyo-glossus, stylo-glossus, lingualis, sublingual gland, lingual artery, gustatory nerve, and hypoglossal nerve. By its *upper border* with mucous membrane of the floor of the mouth, in the situation of the frænum linguæ; by its *lower border* with the genio-hyoid.

Nerve-supply.—The hypoglossal nerve.

Actions.—All the members of this group of muscles act on the os hyoides when the lower jaw is fixed, and on the lower jaw when the os hyoides is drawn downwards and fixed by its depressor muscles. They act, therefore, as depressors of the jaw or as elevators of the hyoid bone. The genio-hyo-glossus is, moreover, a muscle of the tongue; its action upon that organ will be considered with the next group.

Fourth Group.—Muscles of the Tongue.

Genio-hyo-glossus,	Lingualis,
Hyo-glossus,	Stylo-glossus,
Palato-glossus.	

Dissection.—These are already exposed by the preparation we have just made; there remains, therefore, only to dissect and examine them.

The substance of the tongue is chiefly composed of muscular fibres; these are divisible into two sets, the *extrinsic* and *intrinsic*. The extrinsic muscles are the genio-hyo-glossus, hyo-glossus, stylo-glossus and palato-glossus. The intrinsic muscles of the tongue form the great bulk of that organ, and are known collectively under the general title of **lingualis**.

The **genio-hyo-glossus**, the first of these muscles, has been described with the last group.

The **HYO-GLOSSUS** is a square-shaped plane of muscle, *arising* from the whole length of the great cornu, the lesser cornu, and side of the body of the os hyoides; and *inserted* between the stylo-glossus and lingualis into the side of the tongue. The direction of the fibres which arise from the body is obliquely backwards; those from the great cornu pass obliquely forwards; hence they are described by

Albinus as two muscles, under the names of *basio-glossus* and *cerato-glossus*, to which he added a third fasciculus, arising from the lesser cornu, and spreading along the side of the tongue, the *chondro-glossus*. The *basio-glossus* slightly overlaps the upper part of the *cerato-glossus*, and is separated from it by the transverse portion of the *stylo-glossus*.

Relations.—By its *external surface* with the digastric, stylo-hyoid, stylo-glossus, mylo-hyoid, gustatory nerve, hypoglossal nerve, Wharton's duct, and sublingual gland. By its *internal surface* with the middle constrictor of the pharynx, lingualis, genio-hyo-glossus, lingual artery, and glosso-pharyngeal nerve.

Nerve-supply.—The hypoglossal nerve.

THE LINGUALIS.—Muscular fibres may be seen towards the apex of the tongue, issuing from the interval between the *hyo-glossus* and *genio-hyo-glossus*; these constitute the **lingualis longitudinalis inferior**. It consists of a small fasciculus of fibres running longitudinally from the base, where it is attached to the *os hyoides*, to the apex of the tongue.

The other muscles entering into the structure of the tongue, are the *lingualis longitudinalis superior* vel *superficialis*, the *lingualis transversus*, and the *lingualis verticalis*. The **lingua-**

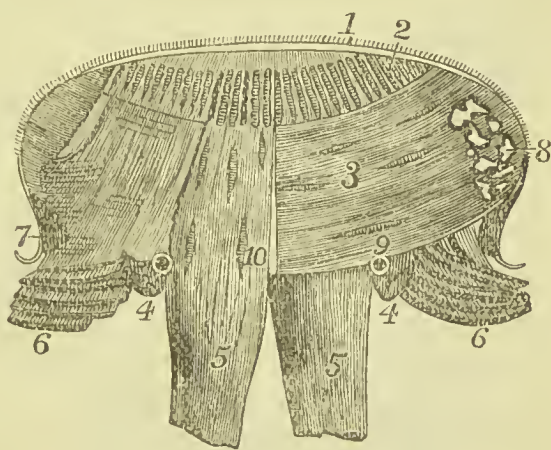


FIG. 190.—Extrinsic and intrinsic muscles of the tongue. 1. Mucous membrane. 2. Superficial longitudinal lingualis. 3. Transverse lingualis. 4, 4. Inferior longitudinal lingualis. 5, 5. Genio-hyo-glossus. 6, 6. Hyo-glossus. 7. Stylo-glossus. 8. Glands.

lis superior forms a thin plane on the upper surface of the organ, lying immediately beneath the mucous membrane, and is intermixed with fine areolar and adipose tissue. This layer is thicker in front than behind, and is covered posteriorly by a thin stratum of transverse fibres derived from the *hyo-glossus*. The **lingualis transversus** constitutes the chief bulk of the tongue; it lies between the *lingualis superior* and *inferior*, its fibres being attached at the middle line to the fibrous septum of the tongue, and laterally to the mucous membrane; some of its fibres are continuous with those of the *stylo-glossus*, *hyo-glossus*, and *palato-glossus*. The **lingualis verticalis** forms a series of curves in each half of the tongue, intersecting the transverse *lingualis*, and extending from the dorsum to the under surface, where many of the fibres become continuous with those of the *genio-hyo-glossus*. The fibres of the muscular structure of the tongue are separated from each other by a large quantity of very fine fat and some glandular tissue. The lateral halves of

the tongue are divided by a fibrous septum, which involves only the inner or medullary portion of the muscular mass, but is sufficiently complete to prevent anastomosis of the arteries of one side with those of the other.

Nerve-supply.—The several layers of muscular fibre which constitute the lingualis muscle are chiefly supplied by the hypoglossal nerve, but some filaments of the facial also reach them.

The **STYLO-GLOSSUS** arises from the apex of the styloid process and from the stylo-maxillary ligament; it divides on the side of the tongue into two parts, one transverse, which passes inwards between the two portions of the hyo-glossus, and is lost among the transverse fibres of the substance of the tongue; the other longitudinal, which spreads out upon the side of the tongue, and is prolonged forwards with the inferior lingualis as far as its tip.

Relations.—By its *external surface* with the internal pterygoid muscle, gustatory nerve, parotid gland, sublingual gland, and mucous membrane of the floor of the mouth. By its *internal surface* with the tonsil, superior constrictor of the pharynx, and hyo-glossus.

Nerve-supply.—The hypoglossal and facial nerves.

The **PALATO-GLOSSUS** passes between the soft palate and the side of the base of the tongue, forming a prominence of the mucous membrane, which is called the anterior pillar of the fauces. Its fibres are spread out superiorly among the muscular fibres of the palato-pharyngeus, and inferiorly among the fibres of the stylo-glossus upon the side of the tongue.

Nerve-supply.—This muscle is supplied by branches from Meckel's ganglion and the pharyngeal plexus; the motor filaments being ultimately traceable to the facial.

Actions.—The genio-hyo-glossus muscle effects several movements of the tongue. When the tongue is steadied and pointed by the other muscles, the posterior fibres of the genio-hyo-glossus would dart it from the mouth, while its anterior fibres would restore it to its former position. The whole length of the muscle acting on the tongue, would render it concave along the middle line, and form a channel for the current of fluid towards the pharynx, as in sucking. The apex of the tongue is directed to the roof of the mouth, and rendered convex from before backwards by the linguales. The hyo-glossi, by drawing down the sides of the tongue, render it convex along the middle line. It is drawn upwards at its base by the palato-glossi, and backwards or to either side by the stylo-glossi. The palato-glossi muscles, assisted by the uvula, have the power of closing the fauces completely, an action which takes place in deglutition. The lingualis fibres are mainly brought into play in the production of articulate speech.

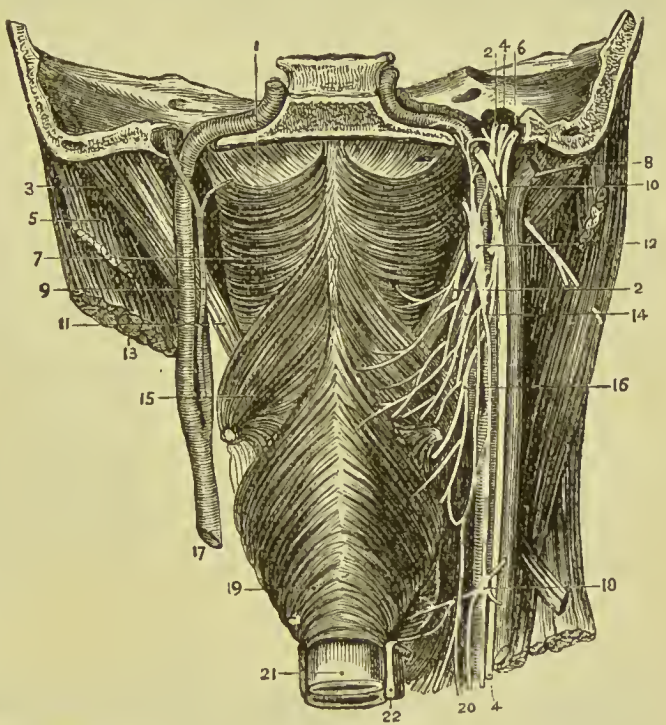
Fifth Group.—Muscles of the Pharynx.

Inferior constrictor,
Middle constrictor,
Superior constrictor,

Stylo-pharyngeus,
Palato-pharyngeus.

Dissection.—To dissect the pharynx, the trachea and œsophagus are to be cut through at the lower part of the neck, and drawn upwards by dividing the loose areolar tissue which connects the back of the pharynx with the vertebral column. The saw is then to be applied behind the styloid processes, and the base of the skull sawn through. The vessels and loose structures should be removed

FIG. 191.—Dissection of the constrictor muscles of the pharynx with the vessels and nerves in relation with them. 1. Pharyngeal aponeurosis. 2, 2. Glosso-pharyngeal nerve. 3. Posterior belly of digastric. 4, 4. Vagus nerve. 5. Splenius capitis. 6. Spinal-accessory nerve. 7. Superior constrictor muscle. 8. Internal jugular vein. 9. Ascending pharyngeal artery. 10. Hypoglossal nerve. 11. Stylo-pharyngeus. 12. Superior ganglion of sympathetic. 13. Sterno-mastoid. 14. Pharyngeal branch of pneumogastric. 15. Middle constrictor. 16. Superior laryngeal nerve. 17. Common carotid artery. 18. Middle ganglion of sympathetic. 19. Inferior constrictor. 20. Cardiac nerves. 21. Œsophagus. 22. Recurrent laryngeal nerve.



from the preparation, and the pharynx stuffed with tow or wool for the purpose of distending it, and rendering the muscles more easy of dissection.

FASCIA.—The **pharyngeal fascia** or **aponeurosis** is a strong sheet situated between the muscles and mucous membrane; it is especially strong at its upper part, where it fills in the interval left above the festooned upper margin of the superior constrictor, and is attached to the basilar process of the occipital bone and petrous portion of the temporal. It is strengthened in the middle line by a strong band, which is attached to the pharyngeal tubercle on the basilar process of the occipital bone; this has been named by Cleland the **cranio-**

pharyngeal ligament. As it passes down, the fascia gradually becomes thinner, and at the lower part of the pharynx is distinguishable only as a layer of connective tissue uniting the mucous and muscular coats.

The **constrictors of the pharynx** are web-like sheets of muscle with fibres differently disposed, which form a muscular bag attached to the base of the skull. This bag communicates in front with the mouth. Each of the constrictors may be described as having one posterior attachment and several lateral.

The **INFERIOR CONSTRICTOR**, the thickest of the three constrictor muscles, *arises* from the cricoid cartilage, and the inferior cornu and oblique line of the thyroid. Some fibres are continuous with those of the sterno-thyroid, thyro-hyoid, and crico-thyroid muscles; inferiorly it is blended with the transverse fibres of the

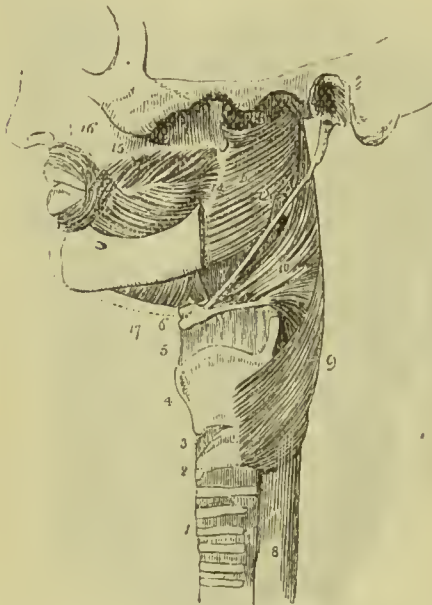


FIG. 192.—Side view of the muscles of the pharynx. 1. Trachea. 2. Cricoid cartilage. 3. Crico-thyroid membrane. 4. Thyroid cartilage. 5. Thyro-hyoid membrane. 6. Os hyoides. 7. Stylo-hyoid ligament. 8. Œsophagus. 9. Inferior constrictor. 10. Middle constrictor. 11. Superior constrictor. 12. Stylo-pharyngeus, passing down between the superior and middle constrictor. 13. Upper concave border of superior constrictor; at this point the muscular fibres of the pharynx are deficient. 14. Pterygo-maxillary ligament. 15. Buccinator. 16. Orbicularis oris. 17. Mylo-hyoid.

œsophagus. Its fibres spread out, and are *inserted* into the middle line of the pharynx, the inferior fibres being almost horizontal, the superior oblique and overlapping the middle constrictor.

Relations.—By its *external surface* with the vertebral column, longus colli, sheath of the common carotid artery, sterno-thyroid muscle, thyroid gland, and some lymphatic glands. By its *internal surface* with the middle constrictor, stylo-pharyngeus, palato-pharyngeus, and mucous membrane of the pharynx. By its *lower border*, near the cricoid cartilage, it is in relation with the recurrent laryngeal nerve; and by the *upper border* with the superior laryngeal nerve.

The muscle must be removed before the next can be fully seen.

The **MIDDLE CONSTRICTOR** *arises* from the great cornu of the os hyoides, from the lesser cornu, and from the stylo-hyoid liga-

ment. It radiates from its origin, and spreads out upon the side of the pharynx, the lower fibres descending and being overlapped by the inferior constrictor; the upper fibres ascending, so as to cover in the superior constrictor. It is *inserted* into the raphé of the pharynx, and by a fibrous aponeurosis into the basilar process of the occipital bone.

Relations.—By its *external surface* with the vertebral column, longus colli, rectus anticus major, carotid vessels, inferior constrictor, hyo-glossus, lingual artery, pharyngeal plexus of nerves, and some lymphatic glands. By its *internal surface* with the superior constrictor, stylo-pharyngeus, palato-pharyngeus, and mucous membrane of the pharynx.

The upper portion of this muscle must be turned down, to bring the whole of the superior constrictor into view; in so doing, the stylo-pharyngeus muscle will be seen passing behind its upper border.

The **SUPERIOR CONSTRICTOR** is a thin and quadrilateral plane of muscular fibres *arising* from the side of the tongue, the mucous membrane of the floor of the mouth, the extremity of the molar ridge of the lower jaw, the pterygo-maxillary ligament, and lower third of the posterior margin of the internal pterygoid plate; and *inserted* into the raphé of the pharynx and basilar process of the occipital bone. Its superior fibres are arched, leaving a concave interspace between its upper border and the basilar process; some of its lower fibres are continuous with those of the genio-hyo-glossus on the side of the tongue, and it is overlapped inferiorly by the middle constrictor.

Relations.—By its *external surface* with the vertebral column and muscles of the latter, behind; with the vessels and nerves contained in the *maxillo-pharyngeal space* laterally, and with the middle constrictor, stylo-pharyngeus, and tensor palati. By its *internal surface* with the levator palati, palato-pharyngeus, tonsil, and mucous membrane of the pharynx.

Nerve-supply.—The constrictor muscles of the pharynx are supplied by a plexus of nerves derived from the superior laryngeal and pharyngeal branches of the pneumogastric, the glosso-pharyngeal, and cervical plexus, mixed with some fibres from the sympathetic.

Muscular Interspaces.—The three constrictor muscles of the pharynx, having festooned upper edges, necessarily leave between them muscular interspaces; these being occupied by important structures, require to be recognised and remembered. The first is placed between the upper edge of the superior constrictor and the base of the skull, and has received the name of **Sinus of Morgagni**; it gives passage to the Eustachian tube, levator palati muscle, and a branch of the ascending pharyngeal artery, and is closed in by the pharyngeal aponeurosis and mucous membrane. The second space is between the superior and middle constrictors; it contains the stylo-pharyngeus muscle and glosso-pharyngeal nerve.

The third space forms the interval between the middle and inferior constrictors ; it corresponds to the lateral part of the thyroid-hyoid membrane, and transmits the superior laryngeal nerve and artery.

Maxillo-Pharyngeal Space.—Between the side of the pharynx and ramus of the lower jaw is a triangular interval, the *maxillo-pharyngeal space*, which is bounded at the *inner* side by the superior constrictor muscle ; at the *outer* side by the internal pterygoid muscle ; and *behind* by the rectus anticus major and vertebral column. In this space are situated the internal carotid artery, ascending pharyngeal artery, internal jugular vein, glosso-pharyngeal, pneumogastric, spinal accessory, sympathetic, and hypoglossal nerves.

The **STYLO-PHARYNGEUS** is a long and slender muscle *arising* from the inner side of the base of the styloid process ; it descends between the superior and middle constrictor muscles, and spreads out beneath the mucous membrane of the pharynx ; it is *inserted* partly into the posterior border of the thyroid cartilage and partly into the internal face of the inferior constrictor.

Relations.—By its *external surface* with the stylo-glossus muscle, external carotid artery, parotid gland, and middle constrictor. By its *internal surface* with the internal carotid artery, internal jugular vein, superior constrictor, palato-pharyngeus, and mucous membrane. Along its lower border is seen the glosso-pharyngeal nerve, which crosses it opposite the root of the tongue, to pass between the superior and middle constrictor and behind the hyo-glossus.

Nerve-supply.—Glosso-pharyngeal nerve.

Associated in function with the preceding is a small muscle, not always present, the **salpingo-pharyngeus** (σάλπιγξ, a tube), which *arises* from the lower border of the Eustachian tube near its aperture, and passes down upon the inner surface of the side of the pharynx, where it becomes united with the palato-pharyngeus.

The **palato-pharyngeus** is described with the muscles of the soft palate.

Actions.—The three constrictor muscles are important agents in deglutition ; they contract upon the morsel of food as soon as it is received by the pharynx, and convey it downwards into the œsophagus. Constriction of the pharynx takes place by the anterior wall of the cavity being drawn backwards, and at the same time there is a slight upward movement of the hyoid bone and larynx in consequence of the oblique direction of most of the fibres of the middle and inferior constrictors. The stylo-pharyngei draw the pharynx upwards, and widen it laterally. The palato-pharyngei also draw it upwards, and with the aid of the uvula close the opening of the fauces. The salpingo-pharyngei are elevators of the upper part of the pharynx. A more complete description of the mechanism of deglutition will be given after the palate muscles have been described.

Sixth Group.—Muscles of the Soft Palate.

Levator palati,
Tensor palati,
Azygos uvulæ,

Palato-glossus,
Palato-pharyngeus.

Dissection.—To examine these muscles, the pharynx must be opened from behind by a vertical incision, and the mucous membrane carefully removed from the posterior surface of the soft palate.

The **LEVATOR PALATI**, a moderately thick muscle, *arises* from the extremity of the petrous bone in front of the opening of the carotid canal, and from the posterior and inferior aspect of the cartilage of the Eustachian tube, and passing down by the side of the posterior nares spreads out between the fasciculi of origin of the palato-pharyngeus; it is *inserted* into the middle line, where it is continuous with the muscle of the opposite side, and is overlaid by the azygos uvulæ. In order to reach the palate it passes through the opening above the superior constrictor muscle.

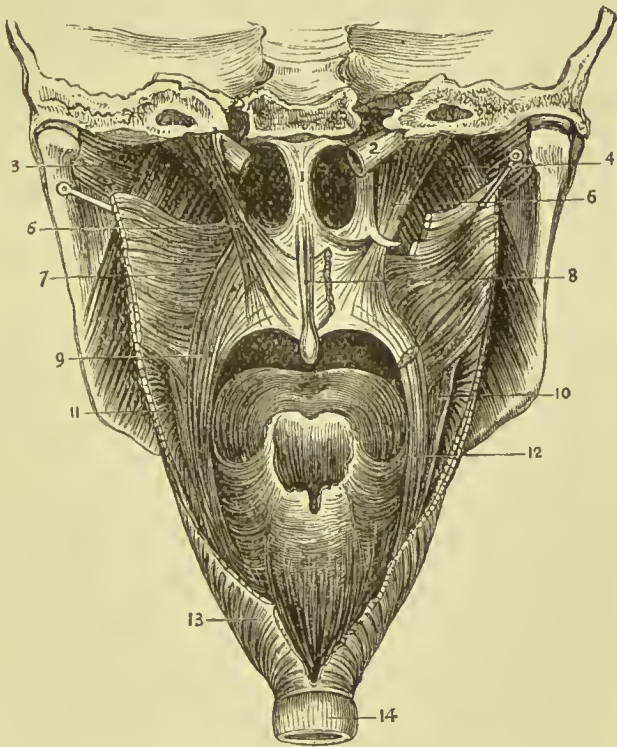


FIG. 193.—Muscles of the palate. 1. Septum narium. 2. Eustachian tube. 3. Pterygoideus externus. 4. Pterygoideus internus. 5. Levator palati. 6. Tensor palati. 7. Superior constrictor of pharynx. 8. Azygos uvulæ. 9. Palato-pharyngeus. 10. Stylo-pharyngeus. 11. Middle constrictor of pharynx. 12. Palato-pharyngeus (cut). 13. Inferior constrictor of pharynx. 14. Œsophagus.

Relations.—*Externally* with the tensor palati and superior constrictor muscle; *internally* and *posteriorly* with the mucous membrane of the pharynx and soft palate; *inferiorly* it passes between the two fasciculi of origin of the palato-pharyngeus to reach its insertion.

Nerve-supply.—Branches from Meckel's ganglion, the motor root of which is the facial nerve.

Dissection.—This muscle must be turned down from its origin on

one side, and removed, and the superior constrictor dissected away from its pterygoid origin, to bring the next muscle into view.

The **TENSOR PALATI** (*circumflexus*) is a slender and flattened muscle; it *arises* from the scaphoid fossa at the base of the internal pterygoid plate, from the spinous process of the sphenoid bone, the edge of the tympanic plate of the temporal bone, and from the anterior aspect of the Eustachian tube. It lies between the internal pterygoid muscle and internal pterygoid plate; the tendon winds around the hamular process of the latter, and expands into an aponeurosis, which is *inserted* into the transverse ridge on the horizontal portion of the palate bone, by means of the *palatine aponeurosis*. The tendon as it passes round the hamular process is contained in a synovial sheath.

Relations.—By its *external surface* with the internal pterygoid muscle; by its *internal surface* with the levator palati, internal pterygoid plate, and superior constrictor. In the soft palate, its tendinous expansion is placed in front of the other muscles, and in contact with the mucous membrane.

Nerve-supply.—From the otic ganglion, the motor root of which is the facial nerve.

Palatine Aponeurosis.—A firm but not well-defined elastic membrane extends from the posterior border of the palate plate into the velum of the palate; it thins as it descends, and at the sides becomes continuous with the pharyngeal aponeurosis. It gives attachment to portions of all the palatine muscles.

The **AZYGOS UVULÆ** (*motor uvulæ*) is a pair of small muscles situated along the mid-line of the soft palate. They *arise* from the spine of the palate bone and aponeurosis of the soft palate, and are *inserted* into the uvula. By their anterior surface they are in relation with the levatores palati, palato-glossi, and anterior fasciculus of the palato-pharyngei; posteriorly they have the thin posterior fasciculus of the palato-pharyngei and the mucous membrane.

Nerve-supply.—Probably from Meckel's ganglion, the nerve fibres being, however, ultimately traceable to the facial nerve.

Dissection.—The two next muscles are brought into view by raising the mucous membrane from the pillars of the soft palate at each side.

The **PALATO-GLOSSUS** (*constrictor isthmi faucium*) is a small fasciculus of fibres, which *arises* in the soft palate as a radiated expansion continuous with its fellow of the opposite side; and descends to be *inserted* into the side of the tongue, where its fibres mingle with those of the transverse lingualis. It is the prominence of this small muscle, covered by mucous membrane, that constitutes the anterior pillar of the soft palate. It has been named constrictor isthmi faucium, from a function it performs in common with the palato-pharyngeus—viz., constricting the opening of the fauces.

The **PALATO-PHARYNGEUS** (*constrictor isthmi faucium posterior*) forms the posterior pillar of the fauces; it *arises* by two fasciculi from the raphé of the soft palate, where its fibres are continuous

with those of the muscle of the opposite side ; and is *inserted* with the stylo-pharyngeus into the inner surface of the pharynx and posterior border of the thyroid cartilage. This muscle is broad above where it forms the whole thickness of the lower half of the soft palate, narrow in the posterior pillar, and again broad and thin in the pharynx where it spreads out previously to its insertion. The levator palati passes to its insertion between the two fasciculi of origin of this muscle.

Relations.—In the soft palate it is in relation with the mucous membrane both by its *anterior* and *posterior* surface ; *above*, with the levator palati, and *below*, with the mucous glands situated along the margin of the arch of the palate. In the posterior pillar, it is surrounded for two-thirds of its extent by mucous membrane. In the pharynx, it is in relation by its *outer surface* with the superior and middle constrictor muscle, by its *inner surface* with the mucous membrane.

Nerve-supply.—The palato-glossus is supplied by the facial nerve, and the palato-pharyngeus from Meckel's ganglion and the pharyngeal plexus.

Actions.—The azygos uvulæ shortens the uvula. In speaking and singing, the uvula is by its muscles placed in contact with the posterior wall of the pharynx, and in that position serves to steady the palate and prevent the vibration of its edge. The levator palati raises the soft palate, while the tensor spreads it out laterally so as to form a septum between the pharynx and posterior nares. The palato-glossus and palato-pharyngeus constrict the opening of the fauces, and drawing down the soft palate, serve to press the mass of food from the dorsum of the tongue into the pharynx. The action of the pharyngeal muscles on the Eustachian tube has been much debated ; the generally received view is, that while the lower opening is always in some measure patent, it is distinctly enlarged by these muscles in the act of swallowing.

Mechanism of Deglutition.—Deglutition is performed by means of the tongue and the muscles of the soft palate, fauces, and pharynx. The food bolus is pushed towards the fauces by the application of the tongue to the hard palate, the base of the tongue being also carried upwards and backwards by the action of the stylo-glossus muscles ; in this way the bolus is caused to pass between the anterior pillars of the fauces, the muscles of which (the palato-glossi) contract upon it. The palato-pharyngeus muscles forming the posterior pillars of the fauces also contract and narrow the faucial opening, the interval between them being filled up by the uvula ; the tensor palati muscles make tense, and the levator palati draw upwards and backwards the soft palate till it nearly touches the posterior wall of the pharynx, thus preventing the food from passing upwards to the nasal cavity. At the same time the larynx is drawn upwards beneath the lower jaw by the elevator muscles of the os hyoides, and the thyroid cartilage is carried beneath the hyoid bone by the thyro-hyoid muscles so as to allow the epiglottis to fall over the

upper opening of the larynx, this being facilitated by the tongue being carried backwards and the glosso-epiglottic folds rendered lax. The food, being thus prevented from passing into the nose or larynx, is thrown into the grasp of the constrictors of the pharynx, which successively contract upon it from above downwards, so as to pass it into the upper part of the œsophagus.

Seventh Group.—Prævertebral Muscles.

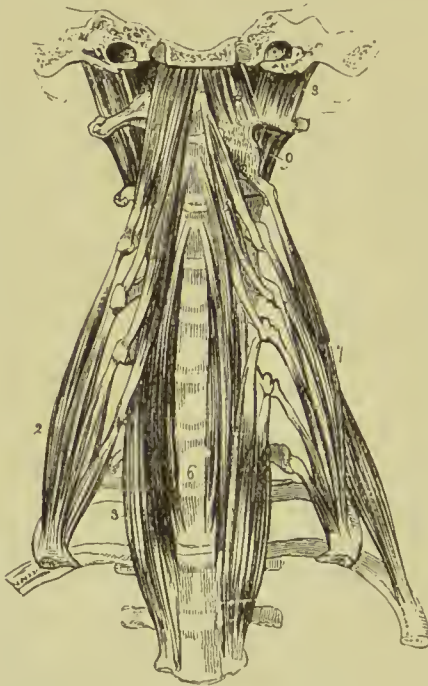Rectus anticus major,
Rectus anticus minor,
Scalenus anticus,

Scalenus medius,
Scalenus posticus,
Longus colli.

Dissection.—These muscles have already been exposed by the removal of the pharynx from the anterior aspect of the vertebral

column; all that is further needed is the removal of the fascia by which they are invested.

FIG. 194.—Prævertebral group of muscles of the neck. 1. Rectus anticus major. 2. Scalenus anticus. 3. Lower oblique part of the longus colli of the right side; it is concealed superiorly by the rectus anticus major. 4. Rectus anticus minor. 5. Upper oblique portion of the longus colli. 6. Its vertical portion; the figure rests on the seventh cervical vertebra. 7. Scalenus medius; behind which is seen the scalenus posticus. 8. Rectus lateralis, left side. 9. One of the intertransversals.



column; all that is further needed is the removal of the fascia by which they are invested.

The **RECTUS ANTICUS MAJOR**, broad and thick above, narrow and pointed below, arises from the anterior tubercles of the transverse processes of the third, fourth, fifth, and sixth cervical vertebræ; and is inserted into the basilar process of the occipital bone.

Relations.—By its *anterior surface* with the pharynx, internal carotid artery,

internal jugular vein, superior cervical ganglion and trunk of the sympathetic nerve, pneumogastric, and spinal accessory nerve. By its *posterior surface* with the rectus anticus minor, and superior cervical vertebræ; *internally* with the longus colli, and *externally* with the scaleni.

Nerve-supply.—Anterior division of the first cervical nerve.

The **RECTUS ANTICUS MINOR** arises from the anterior border of the lateral mass of the atlas, and is inserted into the basilar process of the occipital bone; its fibres being directed obliquely upwards and inwards.

Relations.—By its *anterior surface* with the rectus anticus major, and superior cervical ganglion of the sympathetic. By its *posterior surface* with the articulation of the condyle of the occipital bone with the atlas, and anterior occipito-atlantal ligament.

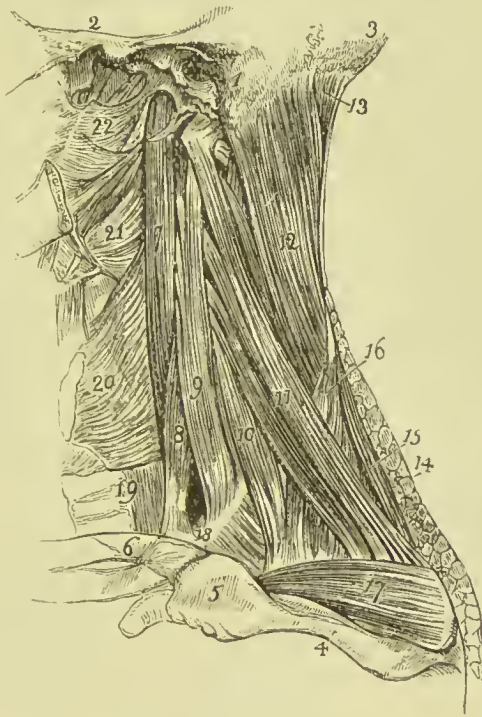Nerve-supply.—Anterior division of the first cervical.

The **SCALENUS ANTICUS** is a triangular muscle, as its name implies, situated at the root of the neck, and appearing like a continuation of the rectus anticus major; it *arises*, by a flat and narrow tendon, from a tubercle on the upper and inner border of the first rib; and is *inserted* into the anterior tubercles of the transverse processes of the third, fourth, fifth, and sixth cervical vertebræ.

Relations.—By its *anterior surface* with the sterno-mastoid, subclavius, omo-hyoid, supra-scapular, ascending and superficial cer-

FIG. 195.—Lateral view of the muscles of the prævertebral region and side of the neck.

1. The mastoid process of the temporal bone.
2. The zygoma.
3. The occipital bone.
4. The spine of the scapula.
5. The acromion process.
6. The clavicle.
7. The longus colli muscle.
8. Scalenus anticus.
9. Scalenus medius.
10. Scalenus posticus.
11. Levator anguli scapulæ.
12. Splenius.
13. Complexus.
14. Cut edge of the trapezius.
15. Rhomboideus minor.
16. Serratus posticus superior.
17. Supra-spinatus.
18. Opening between the scalenus anticus and medius for the subclavian artery; the number is placed on the first rib; and the fibres below it are those of the first intercostal muscle.
19. Oesophagus and trachea.
20. Inferior constrictor of pharynx.
21. Middle constrictor.
22. Superior constrictor.



vical arteries, phrenic nerve, and subclavian vein, by which latter it is separated from the subclavius muscle and clavicle. By its *posterior surface* with the pleura, the nerves which form the brachial plexus, and below, the subclavian artery. By its *inner side* with the longus colli, being separated by the vertebral artery; by its *outer side* with the scalenus medius. Its relations with the subclavian artery and vein are important, the vein being before, the artery behind the muscle.

Nerve-supply.—Branches of the lower cervical nerves.

The **SCALENUS MEDIUS**, the largest of the three, *arises* from the first rib between the groove for the subclavian artery and the tubercle, and is *inserted* by separate tendons into the posterior

tubercles of the transverse processes of all the cervical vertebræ excepting the first.

Nerve-supply.—Branches of the lower cervical nerves.

The **SCALENUS POSTICUS**, of small size, *arises* by a thin tendon from the second rib between its tubercle and angle, and divides superiorly into two or three tendons, which are *inserted* into the posterior tubercles of the transverse processes of the two or three lower cervical vertebræ.

Nerve-supply.—Branches from the brachial and cervical plexus.

The **LONGUS COLLI** is a long and flat muscle, consisting of three portions, two oblique and one vertical. The *superior oblique* portion *arises* from the anterior tubercle of the atlas, and is *inserted* into the anterior tubercles of the transverse processes of the third, fourth, and fifth cervical vertebræ. The *inferior oblique* portion *arises* from the transverse processes of the fifth and sixth cervical vertebræ, and passes down the neck to be *inserted* into the bodies of the two or three upper dorsal vertebræ. The *vertical* portion *arises* from the bodies of the second, third, and fourth cervical vertebræ, and is *inserted* into the bodies of the three lower cervical and three upper dorsal vertebræ.

In general terms, the muscle is attached to the bodies and transverse processes of the six superior cervical vertebræ above, and to the bodies of the last three cervical and first three dorsal below.

Relations.—By its *anterior surface* with the pharynx, œsophagus ; sheath of the common carotid, internal jugular vein and pneumogastric nerve ; sympathetic nerve, inferior laryngeal nerve, and inferior thyroid artery. By its *posterior surface* it rests on the cervical and upper dorsal vertebræ.

Nerve-supply.—Brachial plexus.

Actions.—The rectus anticus major and minor preserve the equilibrium of the head upon the atlas ; and acting with the longus colli, flex and rotate the head and the cervical portion of the vertebral column. The scaleni muscles are flexors of the vertebral column ; and, acting from above, fix the first and second ribs for the inspiratory muscles, and themselves act as muscles of forced inspiration.

Eighth Group.—Muscles of the Larynx.

These muscles are described with the anatomy of the larynx, in Part VII.

MUSCLES AND FASCLE OF THE TRUNK.

The muscles of the trunk may be subdivided into four natural groups, viz. :—

1. Muscles of the back.
2. Muscles of the thorax.
3. Muscles of the abdomen.
4. Muscles of the perinæum.

1. **Muscles of the Back.**—The *region of the back*, in consequence of its extent, is common to the neck, upper extremities, and abdomen; and its muscles, which are numerous, may be arranged into six layers.

First Layer.

Trapezius,
Latissimus dorsi.

Dissection.—The muscles of this layer are to be dissected by making an incision along the middle line of the back, from the tubercle on the occipital bone to the coccyx. From the upper end of this incision carry a second transversely outwards to the back of the ear; inferiorly an incision must be made from the extremity of the sacrum, along the crest of the ilium, to about its middle. For convenience of dissection, a fourth may be carried from the spine of the seventh cervical vertebra to the acromion process. The integument and superficial fascia, together, are to be dissected off the muscles in the course of their fibres, over the whole of this region.

Fasciæ.—The *superficial fascia* of this region is continuous with that of the rest of the body; it is of considerable thickness and strength, and contains much pinkish fat. The *deep fascia* forms a dense fibrous layer which is attached to the superior curved line of the occipital bone, the spines of the vertebræ, spine of the scapula, crest of the ilium, and sacrum; it is closely connected with the muscles, for which it forms sheaths, and is continuous with the deep cervical fascia and with the deep fascia of the abdominal and thoracic walls.

The **TRAPEZIUS** muscle (*trapezium*, a quadrangle with unequal sides) *arises* from the inner third of the superior curved line of the occipital bone, from the ligamentum nuchæ, and from the supraspinous ligament and spinous processes of the last cervical and all the dorsal vertebræ. The fibres converge from these various points, the upper and lower being oblique, and the middle nearly horizontal, and are *inserted* into the scapular third of the clavicle, acromion process, and upper border of the spine of the scapula, as far back as its tubercle. Over the two lower cervical and two upper dorsal spines the origin is markedly aponeurotic, so as to present the appearance of a tendinous ellipse. The lower fibres of the muscles terminate in a flattened tendon which plays over the smooth triangular area at the root of the spine of the scapula. When the trapezius is dissected on both sides, the two muscles resemble a trapezium, or diamond-shaped quadrangle, on the posterior part of the shoulders; hence the muscle was formerly named *cucullaris* (*cucullus*, a monk's cowl).

Relations.—By its *superficial surface* with the integument and superficial fascia, to which it is closely adherent by its cervical portion, loosely by its dorsal portion. By its *deep surface*, from above downwards, with the complexus, splenius, levator anguli

scapulæ, supra-spinatus, rhomboideus minor, rhomboideus major and small portions of the infra-spinatus, serratus posticus superior, latissimus dorsi and vertebral aponeurosis, the latter separating

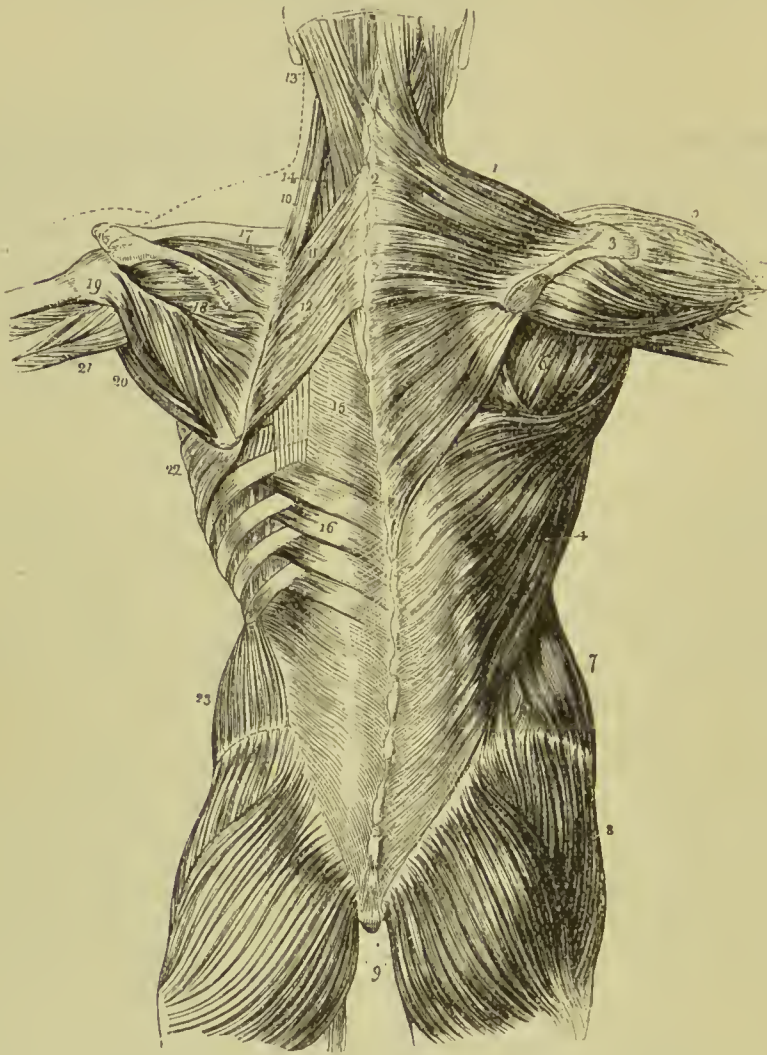


FIG. 196.—First, second, and part of the third layer of muscles of the back; the first layer occupies the right, the second, the left side. 1. Trapezius. 2. Tendinous portion, forming, with a corresponding part of the opposite muscle, the tendinous ellipse on the back of the neck. 3. Acromion process and spine of the scapula. 4. Latissimus dorsi. 5. Deltoid. 6. Muscles of the dorsum of the scapula; infra-spinatus, teres minor, and teres major. 7. Obliquus externus. 8. Gluteus medius. 9. Glutei maximi. 10. Levator anguli scapulæ. 11. Rhomboideus minor. 12. Rhomboideus major. 13. Splenius capitis; the muscle immediately above, and overlaid by the splenius, is the complex. 14. Splenius colli, partially seen; the common origin of the splenius is seen attached to the spinous processes below the origin of the rhomboideus major. 15. Lumbar aponeurosis. 16. Serratus posticus inferior. 17. Supra-spinatus. 18. Infra-spinatus. 19. Teres minor. 20. Teres major. 21. Long head of triceps, passing between teres minor and major to the arm. 22. Serratus magnus. 23. Obliquus internus.

it from the erector spinæ. The *anterior border* of the cervical portion forms the posterior boundary of the posterior triangle of the neck. Its clavicular insertion sometimes advances to the middle of the clavicle, or as far as the outer border of the sterno-mastoid, and occasionally it has been seen to overlap the latter. This is a point to be borne in mind in the operation for ligature of the sub-clavian artery. The spinal accessory nerve passes beneath the anterior border, near the clavicle, previously to its distribution to the under surface of the muscle.

Nerve-supply.—Spinal accessory, and third and fourth cervical.

The **ligamentum nuchæ** is a band composed of white fibrous tissue extended from the tubercle and spine of the occipital bone to the spinous process of the seventh cervical vertebra, where it is continuous with the supraspinous ligament. It is connected with the spinous processes of all the cervical vertebræ, excepting the atlas, by means of a series of small fibrous slips; and is the homologue of an important elastic ligament in animals.

The **LATISSIMUS DORSI** muscle covers the whole of the lower part of the back and loins. It *arises* from the spinous processes of the six inferior dorsal, and all the lumbar vertebræ, from the supraspinous ligament, spinous tubercles of the sacrum, posterior third of the outer lip of the crest of the ilium, and four lower ribs; the latter origin taking place by muscular slips, which indigitate with the external oblique muscle of the abdomen. The fibres from this extensive origin converge as they ascend, and cross the inferior angle of the scapula; they then curve around the lower border of the teres major muscle, and terminate in a short quadrilateral tendon, which gets in front of the tendon of the teres, and is *inserted* into the bicipital groove of the humerus. The tendinous origin of the muscle is united by its under surface with the posterior lamella of the fascia lumborum. A synovial bursa is interposed between its upper border and the lower angle of the scapula, and another between the upper half of its tendon and that of the teres major; the two tendons being united inferiorly. The muscle frequently receives a small fasciculus from the scapula as it crosses its inferior angle; its tendon also gives off fibres to the deep fascia of the upper arm.

In many instances, a muscular slip arises from the edge of the latissimus where it forms the posterior fold of the axilla, and crossing the axillary artery terminates by joining the under surface of the pectoralis major, or the coraco-brachialis. This is called the *musculus axillaris (dorsi-axillaris of Macalister)*.

At the upper border of the latissimus is a small triangular interval (*triangle of Clark*), bounded above by the lower border of the rhomboidens major, within by the trapezius, and below by the latissimus dorsi; in this space the ribs and intercostal muscles are seen to be uncovered by the muscles of the back.

Relations.—By its *superficial surface* with the integument and superficial fascia, and with the trapezius. By its *deep surface*, from

below upwards, with the erector spinæ, serratus posticus inferior, posterior aponeurosis of the obliquus internus, obliquus externus, serratus magnus, intercostal muscles and ribs, rhomboideus major, inferior angle of the scapula, and teres major. The latissimus dorsi, with the teres major, forms the posterior border of the axilla.

Nerve-supply.—By the long subscapular branch of the posterior cord of the brachial plexus, and by the posterior branches of the dorsal and lumbar nerves.

Second Layer.

Levator anguli scapulæ,
Rhomboideus minor,
Rhomboideus major.

Dissection.—This layer is brought into view by dividing the two preceding muscles near their origin, and turning them aside.

The **LEVATOR ANGULI SCAPULÆ** arises, by tendinous slips, from the posterior tubercles of the transverse processes of the four upper cervical vertebræ; and is inserted into the upper angle and posterior border of the scapula, as far as the triangular smooth surface at the root of its spine. Being the principal elevator of the shoulder, it has been termed *musculus patientiæ*.

Relations.—By its *superficial surface* with the trapezius, sternomastoid, and integument. By its *deep surface* with the splenius colli, transversalis cervicis, cervicalis ascendens, scalenus posticus and serratus posticus superior, and with the superficialis colli and posterior scapular arteries. The tendons of origin are interposed between the attachments of the scalenus medius in front and the splenius colli and transversalis cervicis behind.

Nerve-supply.—By the rhomboid branch of the brachial plexus, and branches from the second, third, and fourth cervical.

The **RHOMBOIDEUS MINOR** (*rhombus*, a parallelogram with four equal sides) is a narrow slip of muscle, detached from the rhomboideus major by a slight areolar interspace. It arises from the spinous processes of the last cervical and first dorsal vertebræ and ligamentum nuchæ; and is inserted into the edge of the triangular surface on the posterior border of the scapula.

The **RHOMBOIDEUS MAJOR** arises from the spinous processes and supra-spinous ligaments of the four upper dorsal vertebræ, and is inserted into the posterior border of the scapula as far as its inferior angle. The insertion is effected by means of a tendinous band, which is attached above to the triangular surface at the root of the spine, below to the inferior angle, and between these points to the posterior border of the scapula by means of a thin membrane.

Relations.—By their *superficial surface* the rhomboid muscles are in relation with the trapezius, and the rhomboideus major with the latissimus dorsi and integument; by their *deep surface* with the serratus posticus superior, erector spinæ, posterior scapular artery, intercostal muscles and ribs.

Nerve-supply.—The rhomboid muscles are supplied by a branch of the brachial plexus called rhomboid ; it is derived from the fifth cervical.

Third Layer.

Serratus posticus superior,
Serratus posticus inferior,
Splenius.

Dissection.—The *third layer* consists of muscles which arise from the spinous processes of the vertebral column, and pass outwards. It is brought into view by dividing the levator anguli scapulæ near its insertion, and reflecting the two rhomboid muscles upwards from their insertion into the scapula. The latter muscles should now be removed.

The **SERRATUS POSTICUS SUPERIOR** is situated at the upper part of the thorax ; it *arises* from the ligamentum nuchæ and spinous processes of the last cervical and two upper dorsal vertebræ. The muscle passes obliquely downwards and outwards, and is *inserted* by four serrations into the upper border of the second, third, fourth, and fifth ribs, a little beyond their angle.

Relations.—By its *superficial surface* with the trapezius, rhomboideus major and minor, and serratus magnus. By its *deep surface* with the splenius, erector spinæ, intercostal muscles and ribs.

The **SERRATUS POSTICUS INFERIOR** *arises* from the spinous processes and interspinous ligaments of the two lower dorsal and two or three upper lumbar vertebræ, and passing obliquely upwards, is *inserted* by four serrations into the lower border of the four inferior ribs. Both muscles consist of a thin aponeurosis for about half their extent.

Relations.—By its *superficial surface* with the latissimus dorsi, its tendinous origin being inseparably connected with the aponeurosis of that muscle. By its *deep surface* with the erector spinæ, intercostal muscles, and lower ribs. The *upper border* is continuous with a thin tendinous layer, the vertebral aponeurosis.

Nerve-supply.—The serrati muscles are supplied by the external branches of the posterior divisions of the dorsal nerves.

The **vertebral aponeurosis** is a thin membranous expansion, composed of transverse and longitudinal fibres, extending from the upper border of the serratus posticus inferior upwards beneath the serratus posticus superior to the neck, where it is lost in the cervical fascia. It is attached along the middle line to the spinous processes of the dorsal vertebræ, externally to the angles of the ribs, and becomes continuous below with the strong aponeurosis, called lumbar fascia, which contains the erector spinæ and deep muscles of the back.

Dissection.—The serratus posticus superior must be removed from its origin and turned outwards, to bring into view the whole extent of the splenius muscle.

The **SPLENIUS** muscle is single at its origin, but divides soon after into two portions, which are destined to distinct insertions. It *arises* from the lower half of the ligamentum nuchæ, the spinous process of the last cervical, and spinous processes and interspinous ligaments of the six upper dorsal vertebræ; it divides as it ascends the neck into the splenius capitis and splenius colli.

The **splenius capitis** is *inserted* into the rough surface of the occipital bone beneath the superior curved line, and posterior border of the mastoid process of the temporal bone.

The **splenius colli** is *inserted* into the posterior tubercles of the transverse processes of the three upper cervical vertebræ.

The splenius is separated from its fellow of the opposite side by a triangular interval in which is seen the complexus.

Relations.—By its *superficial surface* with the trapezius, sternomastoid, levator anguli scapulæ, rhomboideus minor and major, and serratus posticus superior. By its *deep surface* with the spinalis dorsi, longissimus dorsi, semi-spinalis colli, complexus, trachelo-mastoid, and transversalis cervicis.

Nerve-supply.—The great occipital, and the external branches of the posterior divisions of the cervical and five upper dorsal nerves.

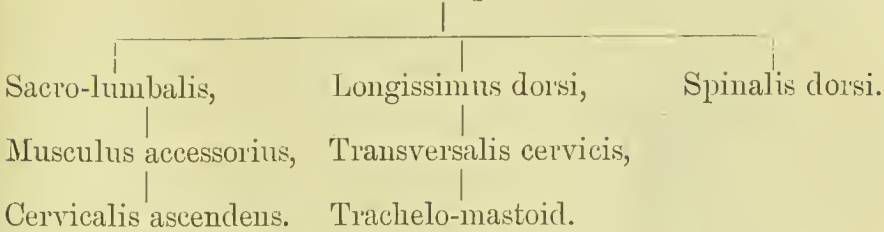
Fourth Layer.

Erector spinæ.
Cervicalis ascendens.
Transversalis cervicis.
Trachelo-mastoid.
Complexus.

Dissection.—The two serrati and two splenii muscles must be removed by cutting them away from their origin and insertion, and the vertebral aponeurosis laid open, to bring the fourth layer into view.

The muscles of the fourth layer form the greater part of the muscular mass which fills up the great vertebral groove on each side of the spine; they are often described collectively under the name of **erector spinæ**; but this title should correctly be limited to the fleshy and tendinous mass which springs from the back of the pelvis and the lumbar vertebræ. When the erector spinæ reaches the level of the last rib, the greater part of it divides to form two muscular columns, the outer receiving the name of sacro-lumbalis, the inner of longissimus dorsi; these are continued as they ascend into the muscles of the upper part of the back and neck, their relation to each other being indicated in the subjoined statement. To these two columns a third is added, forming the spinalis dorsi; it is placed the most internally of the three, and is limited to the dorsal and upper lumbar region.

Erector Spinæ.



The **ERECTOR SPINÆ** arises from the posterior third of the crest of the ilium, the oblique sacro-iliac ligament, articular and spinous tubercles of the sacrum, spinous processes and transverse processes of the lumbar vertebræ; the external portion being fleshy, the internal tendinous. The tendinous portion is broad and flat, and gives origin by its deep surface to a considerable part of the muscular fibres. In the lumbar region, the muscle proceeding from this extensive origin is a broad and thick musculo-tendinous mass, on the surface of which, opposite the last rib, a line of separation is apparent, the outer portion, about one-third, being the sacro-lumbalis, the inner two-thirds the longissimus dorsi.

The **sacro-lumbalis** (ilio-costalis) ascends upon the chest internally to the angles of the ribs, and is *inserted* by separate slips, the four upper tendinous, the two lower fleshy, into the angles of the six lower ribs.

If this muscle be turned a little outwards, a number of tendinous slips will be seen which take their origin from the upper border of the ribs near their angles, and terminate in muscular fasciculi, which prolong the sacro-lumbalis to the upper part of the chest. This is the **musculus accessorius ad sacro-lumbalem**; it arises from the six lower ribs, and is *inserted* by separate tendons into the angles of the six upper ribs and transverse process of the seventh cervical vertebra.

The **longissimus dorsi** is *inserted* by two series of tendons, internal and external; the *internal* being implanted into the accessory and transverse processes of all the lumbar, and transverse processes of all the dorsal vertebræ; the *external* into the transverse processes of the lumbar vertebræ, and all the ribs, excepting the first, between their tubercles and angles.

The **spinalis dorsi** is situated at the inner side of the longissimus dorsi, and arises from the spinous processes of the two upper lumbar and two lower dorsal vertebræ; it is *inserted* into the spinous processes of the upper dorsal vertebræ from the second to the sixth or eighth. It also receives several fasciculi from the longissimus dorsi and semi-spinalis dorsi. The two muscles form an ellipse, which embraces the spinous processes of the dorsal vertebræ.

The lumbar fascia, with the spinal column, aponeurosis of the latissimus dorsi, and ribs, forms a complete osseo-aponeurotic sheath for the erector spinæ.

The **CERVICALIS ASCENDENS** vel descendens is the continua-

tion of the sacro-lumbalis upwards into the neck. It *arises* from the angle of the third, fourth, fifth, and sixth ribs, and is *inserted* by slender tendons into the posterior tubercles of the transverse processes of the third, fourth, fifth, and sixth cervical vertebræ. The term *descendens*, applied to this muscle, can only be correct when it is described as arising in the neck and passing downwards to the ribs.

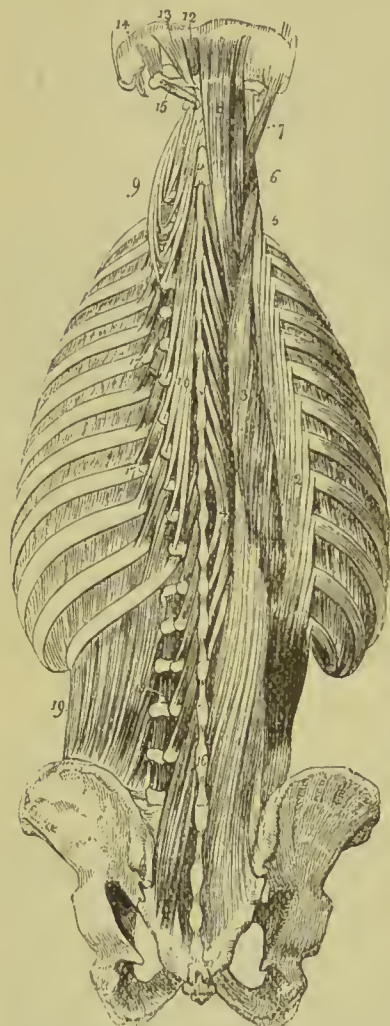


FIG. 167.—Fourth, fifth, and part of the sixth layer of the muscles of the back. 1. Origin of the erector spinæ. 2. Sacro-lumbalis. 3. Longissimus dorsi. 4. Spinalis dorsi. 5. Cervicalis ascendens. 6. Transversalis cervicis. 7. Trachelo-mastoid. 8. Complexus. 9. Transversalis cervicis, showing its origin. 10. Semi-spinalis dorsi. 11. Semi-spinalis colli. 12. Rectus posticus minor. 13. Rectus posticus major. 14. Obliquus superior. 15. Obliquus inferior. 16. Multifidus spinæ. 17, 17. Levatores costarum. 18. Inter-transversales. 19. Quadratus lumborum.

arising from the transverse processes of the three upper dorsal and last cervical, and from the articular processes of the fourth, fifth,

The **TRANSVERSALIS CERVICIS** appears to be the continuation upwards into the neck of the longissimus dorsi; it *arises* from the transverse processes of the five or six upper dorsal vertebræ, and is *inserted* into the posterior tubercles of the transverse processes of the cervical vertebræ, from the second to the sixth. It receives a fasciculus from the longissimus dorsi and several small slips from the trachelo-mastoid.

The **TRACHELO-MASTOID** is likewise a continuation upwards from the longissimus dorsi. It is a slender and delicate muscle, *arising* from the transverse processes of the three upper dorsal and last cervical, and from the articular processes of the three next cervical vertebræ, its origin being similar to that of the complexus, with which and the origin of the transversalis cervicis it is closely connected. It receives a fasciculus from the longissimus dorsi, and is *inserted* into the posterior border and summit of the mastoid process.

Nerve-supply.—This and the preceding muscles are supplied by the external branches of the posterior divisions of the dorsal and cervical nerves.

The **COMPLEXUS** is a large muscle, forming with the splenius the great bulk of the back of the neck. It crosses the direction of the splenius,

and sixth cervical vertebræ; and is *inserted* into the rough surface of the occipital bone between the two curved lines, as far as the occipital spine. The complexus is marked in the upper part of the neck by a transverse tendinous intersection.

A large fasciculus of the complexus lying superficially to the rest of the muscle, and remarkable for consisting of two fleshy bellies with an intermediate tendon, is usually described under the name of *biventer cervicis*. Considered as a separate muscle, it *arises* by three or four slips from the transverse processes of the dorsal vertebræ, from the fourth to the seventh; and is *inserted* into the inner portion of the superior curved line of the occipital bone.

Nerve-supply.—The great occipital, and internal branches of posterior divisions of the six lower cervical and five upper dorsal nerves.

Fifth Layer.

Semi-spinales,
 Rectus posticus major,
 Rectus posticus minor,
 Rectus lateralis,
 Obliquus inferior,
 Obliquus superior.

Dissection.—The muscles of the preceding layer are to be removed by dividing them transversely through the middle, and turning one extremity upwards, the other downwards. In this way the whole of the muscles of the fourth layer may be dissected off, and the remaining muscles of the spine brought into a state to be examined.

The **SEMI-SPINALES** muscles are connected with the transverse and spinous processes of the vertebræ, spanning one-half the vertebral column; hence their name, semi-spinales.

The **semi-spinalis dorsi** *arises* from the transverse processes of the dorsal vertebræ from the sixth to the tenth; and is *inserted* into the spinous processes of the four upper dorsal and two lower cervical vertebræ. It is united below with the spinalis dorsi, and above with the semi-spinalis colli; it also sends several small slips to the longissimus dorsi.

The **semi-spinalis colli**, larger than the preceding, *arises* from the transverse processes of the five or six upper dorsal vertebræ; and is *inserted* into the spinous processes of the cervical vertebræ from the second to the fifth.

Nerve-supply.—The semi-spinales are supplied by the internal branches of the posterior divisions of the dorsal and cervical nerves.

Occipital Group.—This group of small muscles is intended for the movements of the cranium on the atlas, and atlas on the axis.

The **RECTUS CAPITIS POSTICUS MAJOR** *arises* from the spinous process of the axis, and is *inserted* into the inferior curved line of the occipital bone.

The **RECTUS CAPITIS POSTICUS MINOR** arises from the spinous tubercle of the atlas, and is inserted into the rough surface of the occipital bone, beneath the inferior curved line.

The **RECTUS CAPITIS LATERALIS** arises from the transverse process of the atlas, and is inserted into the rough surface of the occipital bone, externally to the condyle.

The **OBLIQUUS INFERIOR CAPITIS** (major) arises from the spinous process of the axis, and passes obliquely outwards to be inserted into the extremity of the transverse process of the atlas.

The **OBLIQUUS SUPERIOR CAPITIS** (minor) arises from the extremity of the transverse process of the atlas, and passes obliquely

inwards to be inserted into the rough surface of the occipital bone, between the curved lines, and directly behind the mastoid process.

Relations.—By their superficial surface the recti and obliqui are in relation with a strong aponeurosis which separates them from the complexus. By their deep surface with the atlas and axis. The rectus posticus major partly covers in the rectus minor. The rectus lateralis is in relation by its anterior surface with the internal jugular vein, and by its posterior surface with the vertebral artery.

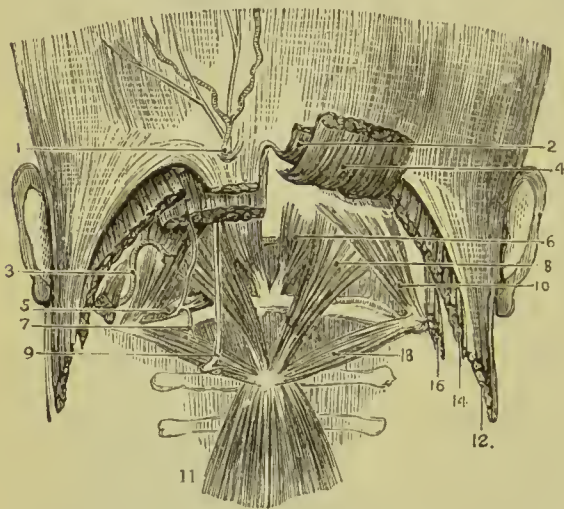


FIG. 198.—Suboccipital region. 1. Occipital artery and nerve piercing the trapezius. 2. Trapezius. 3. Occipital artery. 4. Complexus. 5. Vertebral artery. 6. Rectus capitis posticus minor. 7. Suboccipital nerve. 8. Rectus capitis posticus major. 9. Great occipital nerve. 10. Obliquus superior. 11. Semi-spinalis colli. 12. Sterno-mastoid. 14. Splenius capitis. 16. Trachelo-mastoid. 18. Obliquus inferior.

Nerve-supply.—The recti and obliqui are supplied by the posterior divisions of the first and second cervical nerves.

Sixth Layer.

Multifidus spinæ,
Rotatores spinæ,
Interspinales,
Inter-transversales.

Dissection.—The semi-spinæles muscles must be removed to obtain a good view of the multifidus spinæ, which lies beneath them, and fills up the concavity between the spinous and transverse processes, the whole length of the vertebral column.

The **MULTIFIDUS SPINÆ**, consisting of about twenty-two small muscular fasciculi, extends along the vertebral groove from the sacrum to the axis. The muscle commences by tendinous fibres on the dorsum of the sacrum, proceeding from the lateral tubercles of the sacrum and even from the lateral cornu of the coccyx, and passing obliquely upwards and inwards to the spinous tubercles. The fasciculi *arise* inferiorly from the sacrum, ilium, and tendon of the erector spinæ; in the lumbar region from the articular and mammillary processes of the vertebræ; in the dorsal region from the transverse processes; and in the cervical region from the articular processes of the four inferior vertebræ. They are *inserted* into the spinous processes and laminae of all the vertebræ from the sacrum to the axis. Of the twenty-two fasciculi, six are lumbar, twelve dorsal, and four cervical. Each fasciculus, separate below, spreads out as it ascends, and passing over the next vertebra, is inserted into the four or five immediately above it. The muscle is thick inferiorly; and the uppermost fasciculus larger than those immediately below it.

The **ROTATORES SPINÆ** are situated in the dorsal region beneath the multifidus spinæ; they are eleven in number, and *arise* from the upper and back part of the transverse processes, and are *inserted* into the laminae and roots of the spinous processes.

The **INTERSPINALES** are small muscular slips arranged in pairs and situated between the spinous processes of the vertebræ. In the *cervical region* there are six pairs of these muscles, the first being placed between the axis and third vertebra, the sixth between the last cervical and first dorsal; they are attached to the apices of the spinous processes, and are separated by the interspinous ligaments. In the *dorsal region*, rudiments of these muscles are occasionally met with between the upper and lower vertebræ, but are absent in the rest. In the *lumbar region* there are six pairs of interspinales, the first pair occupying the interspinous space between the last dorsal and first lumbar vertebræ, the last, the space between the fifth lumbar and sacrum. They are thin, broad, and imperfectly developed. Rudimentary interspinales are occasionally met with between the sacrum and coccyx; these are the analogues of the caudal muscles of brutes; in man they are named collectively the *extensor coccygis* (sacro-coccygeus posticus).

The **INTER-TRANSVERSALES** are small quadrilateral muscles situated between the transverse processes of the vertebræ. In the *cervical region* they are arranged in pairs corresponding with the double conformation of the transverse processes, the vertebral artery and anterior division of a cervical nerve lying between them. The rectus anticus minor and rectus lateralis represent the inter-transversales between the atlas and cranium. In the *dorsal region* the anterior inter-transversales are represented by the intercostal muscles, while the posterior are mere tendinous bands, muscular only between the first and last vertebræ. In the *lumbar region*, the anterior inter-transversales are thin, and occupy only part of the

space between the transverse processes. Homologues of posterior inter-transversales exist in the form of small muscular fasciculi extended between the mammillary process of the lumbar vertebrae.

Nerve-supply.—The multifidus spinæ, interspinales, and inter-transversales, are supplied by branches from the posterior divisions of the spinal nerves, from the atlas to the sacrum.

With regard to the origin and insertion of the muscles of the back, the student should be informed that no exact regularity attends their attachments. At the best, a knowledge of their precise connections, even were it possible to retain it, would be but a barren information, if not absolutely injurious, as tending to exclude more valuable learning.

Actions.—The upper fibres of the *trapezius* draw the shoulder upwards and backwards; the middle fibres, directly backwards; the lower, downwards and backwards. The lower fibres also produce rotation of the scapula on the chest, tilting the lower angle of that bone forwards and upwards, and carrying the upper angle slightly downwards and inwards; in this way the glenoid cavity is directed obliquely upwards and outwards, and the trapezius thus performs an important part in the elevation of the arm above the shoulder. If the shoulder be fixed, the upper fibres will flex the spine towards the corresponding side. The *latissimus dorsi* is a muscle of the arm, drawing it backwards and downwards, and at the same time rotating it inwards; if the arm be fixed, the latissimus dorsi will draw the spine to that side, and, raising the lower ribs, be an inspiratory muscle; and if both arms be fixed, the two muscles will draw the whole trunk forwards, as in climbing or walking on crutches. By passing over the inferior angle of the scapula it binds that bone to the thoracic wall, and by being folded round the axillary border it limits the outward projection of the same angle when the arm is raised. The *levator anguli scapulae* lifts the upper angle of the scapula, and with it the entire shoulder; the *rhomboidei* carry the scapula and shoulder upwards and backwards, and approximate the inferior angle of the scapula to the spine.

The *serrati* are respiratory muscles acting in opposition to each other, the *serratus posticus superior* drawing the ribs upwards, and thereby expanding the chest; the *inferior* drawing the lower ribs downwards, and diminishing the cavity of the chest. The former is an inspiratory, the latter an expiratory muscle. The *splenii* muscles of one side draw the vertebral column backwards and to one side, and rotate the head towards the corresponding shoulder. The muscles of opposite sides acting together, draw the head directly backwards. They are direct antagonists of the sternomastoid muscles.

The *sacro-lumbalis* with its *accessory muscle*, the *longissimus dorsi* and *spinalis dorsi*, are known by the general term of *erector spinæ*, which sufficiently expresses their action. They keep the spine supported in the vertical position by their broad origin from below,

and by their insertion, by distinct tendons, into the ribs and spinous processes. Being made up of a number of distinct fasciculi, which act alternately, the spine is kept erect without fatigue, even when the muscles have to counterbalance a corpulent abdomen. The continuations upwards of these muscles into the neck preserve the steadiness and uprightness of that region. When the muscles of one side act alone, the neck is rotated on its axis. The *complexus*, being attached to the occipital bone, draws the head backwards, and counteracts the muscles of the anterior part of the neck. It assists also in the rotation of the head.

The *semi-spinalis* and *multifidus spinæ* muscles act directly on the vertebræ, and contribute to the general action of supporting the vertebral column erect.

The four little muscles situated between the occiput and the first two vertebræ, effect the various movements between these bones; the *recti* producing the antero-posterior actions, the *obliqui* the rotatory motions of the atlas on the axis.

The actions of the remaining muscles of the spine, the *rotatores spinæ*, *interspinales* and *inter-transversales*, are expressed in their names. They approximate their attachments, and assist the more powerful muscles in preserving the erect position of the body.

MUSCLES AND FASCIÆ OF THE THORAX.

The principal muscles situated on the front and sides of the thorax belong in their actions to the upper extremity, with which they will be described. They are the pectoralis major and minor, subclavius and serratus magnus. The true thoracic muscles, which appertain exclusively to the actions of the ribs, are the—

External intercostals,	Subcostals,
Internal intercostals,	Triangularis sterni.
Levatores costarum.	

The intercostal muscles are two planes of muscular and tendinous fibres directed obliquely between adjacent ribs and closing the intercostal spaces. They are seen partially on the reflection of the pectoral muscles, or on the inner surface of the chest. The triangularis sterni is within the chest, and requires the removal of the anterior part of the thorax to bring it into view.

FASCIÆ.—A thin layer of fascia covers the external surface of the external intercostal, and the inner surface of the internal muscle and a still finer layer is interposed between them. The surface layers become thicker in front, where the external intercostal is deficient, and behind, where the internal intercostal is wanting.

The **EXTERNAL INTERCOSTALS**, eleven on each side, commence posteriorly at the tubercles of the ribs, and advance forwards to the costal cartilages, where they terminate in a thin aponeurosis (*anterior*

intercostal membrane) which is continued onwards to the sternum. Their fibres are directed obliquely downwards and forwards, pursuing the same line with those of the external oblique muscle of the abdomen. They are thicker than the internal intercostals, and more tendinous in structure.

The **INTERNAL INTERCOSTALS**, also eleven on each side, commence anteriorly at the sternum, and extend backwards as far as the angle of the ribs, whence they are prolonged to the vertebral column by a thin aponeurosis (*posterior intercostal membrane*). Their fibres are directed obliquely downwards and backwards, corresponding with those of the internal oblique muscle of the abdomen, and crossing those of the external intercostals.

In structure the intercostal muscles consist of an admixture of muscular and tendinous fibres. They *arise* from the two lips of the lower border of the rib, the external from the outer lip, the internal from the inner; and are *inserted* into the upper border of the rib below, encroaching somewhat on its surfaces.

Nerve-supply.—The intercostal nerves.

The **SUBCOSTALS** are nine or ten small muscles situated within the thorax at its posterior part, and lying upon the ribs. They increase in size from above downwards, and the direction of their fibres corresponds with that of the internal intercostals. Each muscle *arises* from the front of a rib, and is *inserted* into the front of the rib but one below. They are most constant on the lower ribs.

Relations.—The external intercostals, by their *external surface* with the muscles which immediately invest the chest, viz., pectoralis major and minor, serratus magnus, serratus posticus superior and inferior, scalenus posticus, sacro-lumbalis and longissimus dorsi with their continuations, cervicalis ascendens and transversalis cervicis, levatores costarum, and obliquus externus abdominis. By their *internal surface* with the internal intercostals, intercostal vessels and nerves, and posteriorly with the pleura, a thin layer of fascia being interposed. The internal intercostals, by their *external surface* with the external intercostals, and intercostal vessels and nerves; by their *internal surface* with the costal pleura, triangularis sterni, subcostals, and diaphragm.

The **TRIANGULARIS STERNI**, situated upon the inner wall of the front of the chest, *arises* by a thin aponeurosis from the side of the sternum, ensiform cartilage, and sternal extremities of the costal cartilages from the third to the sixth or seventh; it is *inserted* by fleshy digitations into the second, third, fourth, and fifth costal cartilages and corresponding ribs.

Relations.—By its *external surface* with the sternum, ensiform cartilage, costal cartilages, internal intercostal muscles, and internal mammary vessels. By its *internal surface* with the costal pleura, areolar tissue of the anterior mediastinum, and diaphragm. The lower fibres of the triangularis sterni are continuous with those of the transversalis abdominis.

Nerve-supply.—The intercostal nerves.

The **LEVATORES COSTARUM** are divided into long and short. The *short*, twelve in number at each side, *arise* from the apex and lower border of the transverse process of the last cervical and eleven upper dorsal vertebræ; and pass downwards and outwards, radiating in their descent, to be *inserted* into the upper border of all the ribs, between the tubercle and angle. The uppermost muscle is the smallest, and their breadth increases from above downwards.

The *long muscles*, four in number at each side, *arise* from the transverse processes of the dorsal vertebræ, the seventh to the tenth, and are *inserted* into the four lower ribs; each muscle passing over a rib in its descent, and being attached to the rib below as far as its angle. The long muscles lie superficially to the short ones and increase in size from above downwards.

Relations.—By their *superficial surface* with the sacro-lumbalis, longissimus dorsi, and transversalis cervicis. By their *deep surface* with the ribs and intercostal spaces; the short muscles close the intercostal spaces, and are united by their external border with the external intercostals.

Nerve-supply.—The posterior divisions of the dorsal nerves.

Actions of the Respiratory Muscles.—Respiration

is produced by the alternate enlargement and diminution of the capacity of the thorax; the former resulting in the influx of air, or *inspiration*, and the latter

in an expulsion of air, or *expiration*. The enlargement of the thoracic cavity takes in its three diameters, the vertical, transverse, and antero-posterior; the vertical measurement being increased by the descent of the diaphragm which forms the floor of the cavity, and by the elevation of the first rib; the transverse diameter by the elevation and rotation of the ribs; and the antero-posterior by the raising of the ribs and forward projection of the sternum. *Ordinary tranquil inspiration* is performed by the descent of the diaphragm and the elevation of the ribs and sternum by means of the intercostal muscles; when the act is more forcibly performed these are aided by the levatores costarum, scalene muscles, and serratus posticus superior. In *full inspiration* the scapula is fixed by means of the muscles which connect it with the vertebral column; the powerful muscles which pass from the shoulder to the

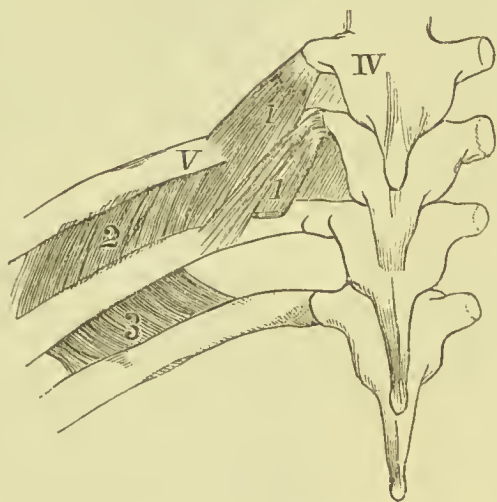


FIG. 199.—Intercostal muscles and levatores costarum. IV. Fourth dorsal vertebra. V. Fifth rib. 1, 1. Levatores costarum muscles, long and short. 2. External intercostal. 3. Internal intercostal.

ribs are then brought into play, and by their action elevate the ribs; these are the pectoralis major and minor, serratus magnus, and latis-simus dorsi. Much difference of opinion prevails as to the action of the external and internal intercostals, many anatomists adhering to the theory taught by Hamberger that the external are inspiratory, and the internal expiratory muscles; while others accept the view so forcibly expounded by Hutchinson that the whole of the external and the part of the internal lying between the costal cartilages act in inspiration, and the rest of the internal intercostals in expiration. Duchenne, as the result of direct experiment on the muscles, supported the theory that both muscles act in common as muscles of inspiration, by raising the ribs, and so increasing the capacity of the thorax; and the same view has been adopted by Henle and Luschka. *Ordinary tranquil expiration* is not a muscular act, but an elastic and mechanical recoil, due to the elasticity of the lung-substance and the recoil of the chest wall after the muscles of inspiration have ceased to act. In *forced expiration* all the muscles which depress the ribs are brought into action, more especially those forming the abdominal wall (obliqui, transversales, and recti), and the triangularis sterni and sacro-lumbalis. Lastly, it should be noted that certain muscles usually classed with those of expiration, from their being attached to the lower ribs, may in consequence of that attachment assist in inspiration, by giving a point of fixation and support for the action of the diaphragm; such are the serratus posticus inferior and quadratus lumborum. The *levator costarum* are generally regarded as muscles of inspiration, but Von Ebner considers them to be chiefly brought into play in lateral flexion of the dorsal spine.

MUSCLES AND FASCLE OF THE ABDOMEN.

The muscles of the abdominal region are the—

Obliquus externus (descendens),	Rectus,
Obliquus internus (ascendens),	Pyramidalis,
Cremaster,	Quadratus lumborum,
Transversalis,	Psoas parvus.
Diaphragm.	

Dissection.—The dissection of the abdominal muscles is to be commenced by making three incisions:—The first, *vertical*, in the middle line, from over the lower part of the sternum to the pubes; the second, *transverse*, from the top of the first incision across the chest, as far back as the knife can be carried; the third, *oblique*, from the umbilicus, downwards and outwards, to the anterior superior spine of the ilium. The three flaps included by these incisions should then be dissected back in the direction of the fibres of the external oblique muscle, beginning at the angle of each. The integument and superficial fascia should be dissected off separately, so as to enable the student to examine the relation of the vessels to the parts connected with hernia.

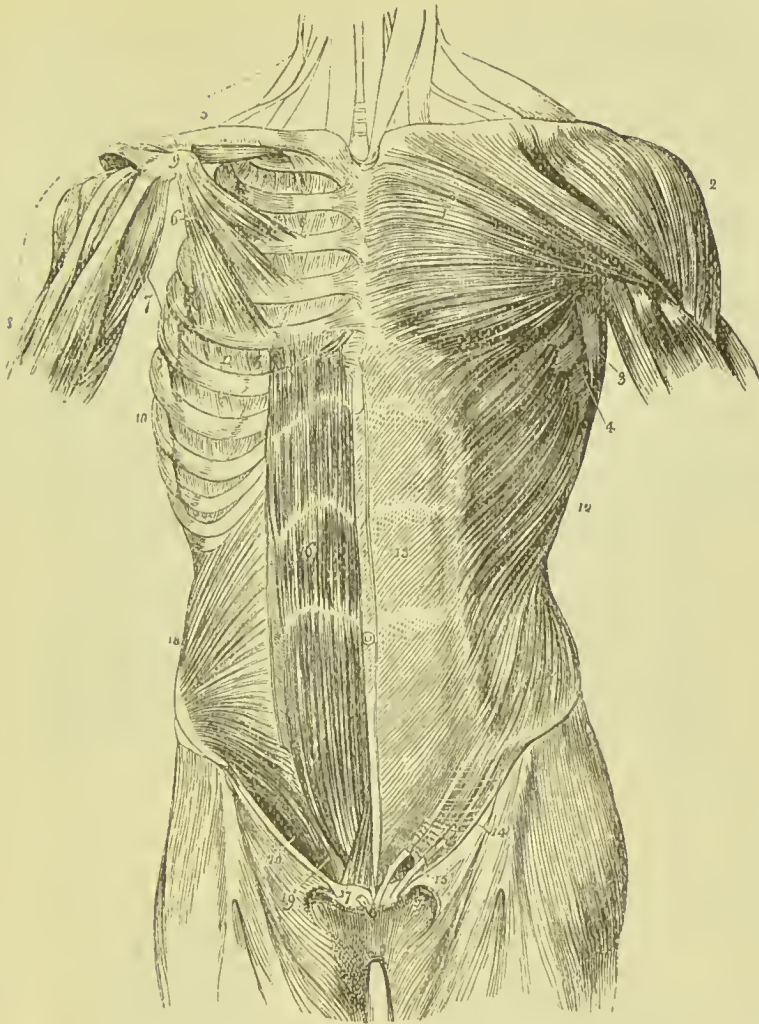
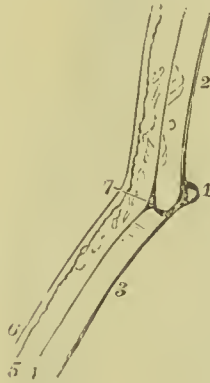

FIG. 200. — Muscles of the anterior aspect of the trunk; on the left side the superficial layer is seen, on the right the deeper layer. 1. Pectoralis major. 2. Deltoid; the interval between these muscles lodges the cephalic vein. 3. Anterior border of the latissimus dorsi. 4. Serratus magnus. 5. Subclavius, right side. 6. Pectoralis minor. 7. Coraco-brachialis. 8. Upper part of the biceps, showing its two heads. 9. Coracoid process of the scapula. 10. Serratus magnus, right side. 11. External intercostal muscle of the fifth intercostal space. 12. External oblique. 13. Its aponeurosis; the median line to the right of this number is the linea alba; the curved line to its left, the linea semilunaris; the transverse lines above and below the figure, the lineae transversae. 14. Poupart's ligament. 15. External abdominal ring; the margin above the ring is the superior or internal pillar; the margin below the ring, the inferior or external pillar; the curved intercolumnar fibres are seen proceeding upwards from Poupart's ligament to strengthen the ring. The numbers 14 and 15 are placed on the fascia lata of the thigh; the opening to the inner side of 15 is the saphenous opening. 16. Rectus muscle of the right side brought into view by the removal of the anterior segment of its sheath; * posterior segment of its sheath with the divided edge of the anterior segment. 17. Pyramidalis muscle. 18. Internal oblique. 19. Conjoined tendon of the internal oblique and transversalis descending behind Poupart's ligament to the pectineal line. 20. The arch formed between the lower curved border of the internal oblique muscle and Poupart's ligament; it is beneath this arch that the spermatic cord and oblique

The **superficial fascia** at the upper part of the abdomen is continuous with the superficial fascia of the thorax ; it is loose, areolar, and contains but little fat. As it descends it becomes thicker, more elastic, and very fatty, and is continued into the superficial fascia of the thigh. Over the pubes the fascia contains much coarse-grained fat, but as it passes on to the penis this ceases, and is replaced by elastic tissue ; and on its continuation into the scrotum, a layer of unstriped muscular tissue takes the place of the fat, forming the *tunica dartos*. Along the *linea alba* and in the groin, fine fibrous bands connect the superficial fascia with the deep layer and with the aponeurosis of the external oblique. Branches of the superficial epigastric, superficial external pudic, and superficial circumflex iliac arteries and their companion veins ramify in the substance of the fascia, and the superficial lymphatic vessels are distributed throughout it ; in the groin it lodges the inguinal lymphatic glands.

The **deep fascia** (*Scarpa's fascia*) lies on the abdominal aponeurosis, a thin layer of connective tissue being interposed. It is continued

FIG. 201. — Section showing the fasciæ at the groin. 1. Section of Poupert's ligament. 2. Aponeurosis of external oblique. 3. Fascia lata. 4. Membranous layer of the superficial fasciæ of the thigh. 5. Superficial layer. 6. Skin. 7. Scarpa's fasciæ.



upwards over the abdomen, being closely adherent to the *linea alba*. From the lower part of this attachment a triangular piece is prolonged to the dorsum of the penis, and is called the suspensory ligament of the penis, the superficial part of which is formed of elastic tissue and the deep part of white fibrous tissue. At the groin the deep fascia is attached to the *fascia lata* of the thigh by a piece which passes down from its under surface along the line of Poupert's

ligament, but about half an inch farther down the thigh. The deep fascia is continued down into the scrotum, where it forms a sheath for the testicle, the processes from the two sides combining in the middle line to form the septum scroti. In the perineum it becomes inseparable from the deep layer of the superficial fascia of that region (fascia of Colles), and is attached to the ramus of the pubes on each side. From this description it follows that if air or fluid be forced under the deep fascia, it will travel through the connective tissue all over the abdomen, and could reach the scrotum and perineum, but could not pass down the thigh, being prevented by the connection of the fascia with the rami of the pubes, and the attachment of the fascia lata in the groin ; it would, moreover, be prevented from infiltrating the back part of the perineum by the deep layer of the superficial fascia being united to the deep perineal fascia along the posterior edge of the transverse perineal muscle.

Linea Alba, &c.—When the external oblique muscle is dissected on both sides, a white tendinous line will be seen along the middle of the abdomen, extending from the ensiform cartilage to the pubes ;

this is the *linea alba*. A little external to it, on each side, two curved lines will be observed extending from the eighth rib to the spine of the pubes, and bounding the recti muscles; these are the *lineæ semilunares*. Some transverse lines, *lineæ transversæ*, three in number, connect the *lineæ semilunares* with the *linea alba*; the lowest is situated opposite the umbilicus, the middle one on a level

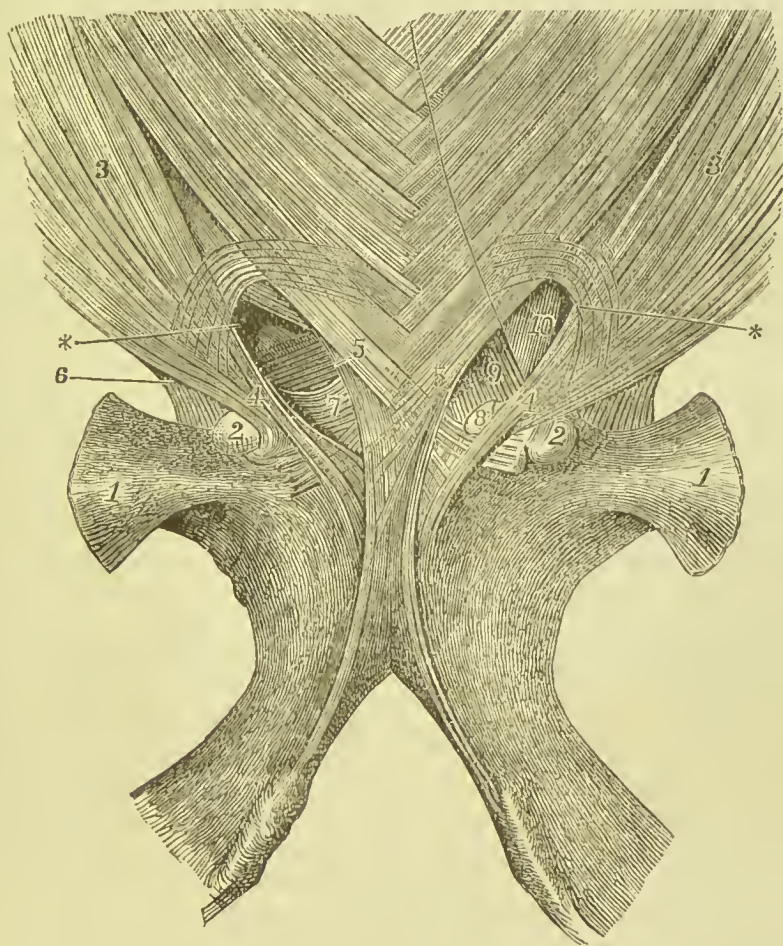


FIG. 202.—Lower part of aponeurosis of external oblique muscle, and external abdominal ring. 1. Horizontal ramus of pubes. 2. Spine of pubes. 3. Aponeurosis of external oblique. 4. External pillar of abdominal ring. 5. Internal pillar. 6. Gimbernat's ligament. 7. Triangular fascia. 8. The cut end of the same fascia. 9. The conjoined tendon. 10. Transversalis fascia. * External abdominal ring.

with the cartilage of the tenth rib, and the highest opposite the cartilage of the seventh rib.

The **EXTERNAL OBLIQUE MUSCLE** (*obliquus externus abdominis, descendens*) is the external flat muscle of the abdomen. Its name is derived from the obliquity of its direction, and the descending course of its fibres. It *arises* by fleshy digitations from the external surface of the eight inferior ribs; the five upper digitations being

received between corresponding processes of the serratus magnus, the three lower, of the latissimus dorsi. The fleshy fasciculi proceeding from this extensive origin terminate on the front of the abdomen in a broad aponeurosis, and posteriorly are *inserted* into the outer lip of the crest of the ilium for the anterior two-thirds its length, and into the anterior superior spinous process. The aponeurosis is united, in front, by its under surface, with that of the obliquus internus, forming the anterior wall of the sheath of the rectus, and is *inserted* into the linea alba, front of the pubes, spine of the pubes, and pectineal line.

The lower border of the aponeurosis, which is stretched between the anterior superior spinous process of the ilium and the spine of the pubes, is round from being folded inwards, and forms **Poupart's ligament**; the insertion into the pectineal line is **Gimbernat's ligament**.

Just above the crest of the pubes is the **external abdominal ring**, a triangular opening formed by the separation of the fibres of the aponeurosis of the external oblique. It is oblique in direction, and corresponds with the course of the fibres of the aponeurosis. It is bounded below by the crest of the pubes; on either side by the borders of the aponeurosis, which are termed *pillars*; and above by some curved fibres (*intercolumnar*) which originate from Poupart's ligament, and cross the upper angle of the ring, to give it strength. The *external pillar*, which is at the same time *inferior* from the obliquity of the opening, is inserted into the spine of the pubes; the *internal* or *superior pillar* forms an interlacement with its fellow of the opposite side over the front of the symphysis pubis. The inner fibres of the outer pillar pass behind the spermatic cord and internal pillar of the ring, and expanding into a thin triangular sheet interlace with the corresponding fibres of the opposite side on the back part of the crest and symphysis pubis; they receive the name of *triangular fascia*. The external abdominal ring gives passage to the spermatic cord in the male, and the round ligament in the female: they are both invested in their passage through it by a prolongation of the intercolumnar fibres of the external oblique muscle, the *intercolumnar fascia*, or *spermatic fascia*.

Relations.—By its *external surface* with the superficial fascia, integument, cutaneous vessels and nerves, particularly the superficial epigastric and superficial circumflex iliac vessels, and latissimus dorsi, by which it is overlapped posteriorly. By its *internal surface* with the internal oblique, lower part of the eight inferior ribs and intercostal muscles, cremaster, spermatic cord in the male, and round ligament in the female. The upper border of the external oblique is continuous with the pectoralis major.

Nerve-supply.—Anterior branches of the lower intercostals.

Dissection.—The external oblique is now to be removed by making an incision from the anterior superior spine of the ilium towards the umbilicus as far as the aponeurosis can be separated from the subjacent muscle. From this latter point an incision is to

be made to the crest of the pubis, and the aponeurosis included in these incisions to be turned down to Poupart's ligament. The remainder of the muscle may be removed by carrying a perpendicular incision from the end of the first up to the chest, and dissecting off the aponeurosis and muscle.

The **INTERNAL OBLIQUE MUSCLE** (*obliquus internus abdominis, ascendens*) is the middle flat muscle of the abdomen. It arises from the outer half of Poupart's ligament, from the middle of the crest of the ilium for the anterior two-thirds its length, and from the fascia lumborum. Its fibres diverge from their origin, those from Poupart's ligament curving downwards, those from the anterior part of the crest of the ilium passing transversely, and the rest ascending obliquely. The muscle is inserted into the pectineal line and crest of the pubes, linea alba, and lower border of the four inferior ribs.

Along the upper three-fourths of the linea semilunaris, the aponeurosis of the internal oblique separates into two lamellæ, which pass one in front, the other behind the rectus muscle to the linea alba, where they are inserted; the former of these unites with the aponeurosis of the external oblique, and the latter with that of the transversalis. Along the lower fourth of the linea semilunaris, the aponeurosis does not divide, but passes in front of the rectus.

The lowest fibres of the internal oblique are inserted into the crest and pectineal line of the pubes in common with those of the transversalis muscle. Hence the tendon of this insertion is called the *conjoined tendon of the internal oblique and transversalis*. This tendon is situated directly behind the external abdominal ring, and serves to strengthen what would otherwise be a weak point in the abdomen. Sometimes the tendon is insufficient to resist the internal pressure, and is forced through the external ring; it then forms the distinctive covering of *direct inguinal hernia*.

Nerve-supply.—Ilio-inguinal and ilio-hypogastric of first lumbar, and anterior branches of lower intercostal nerves.

The spermatic cord passes beneath the arched border of the internal oblique muscle, between it and Poupart's ligament. The interval between this lower border and Poupart's ligament is therefore called the **spermatic or inguinal canal**. During its passage some fibres are given off from the lower border of the muscle, which accompany the cord downwards to the testicle, and form loops around it; this is the *cremaster muscle*.

The **CREMASTER**, considered as a distinct muscle, arises from the middle of Poupart's ligament, and forms a series of loops upon the spermatic cord. A few of its fibres are inserted into the tunica vaginalis; the rest ascends along the inner side of the cord, to be inserted, with the conjoined tendon, into the crest of the pubes in front of the sheath of the rectus. Where the muscle spreads out over the tunica vaginalis and spermatic cord it receives the name of *cremasteric fascia*.

Relations.—The internal oblique is in relation by its *external surface* with the external oblique, latissimus dorsi, spermatic cord,

and external abdominal ring. By its *internal surface* with the transversalis muscle, fascia transversalis, internal abdominal ring, and spermatic cord. By its *lower and arched border* with the spermatic cord; forming the upper boundary of the inguinal canal.

Nerve-supply.—The genital branch of the genito-crural nerve.

Dissection.—The internal oblique muscle is to be removed by making an incision from the anterior superior spine of the ilium horizontally inwards to the edge of the rectus, and another at right

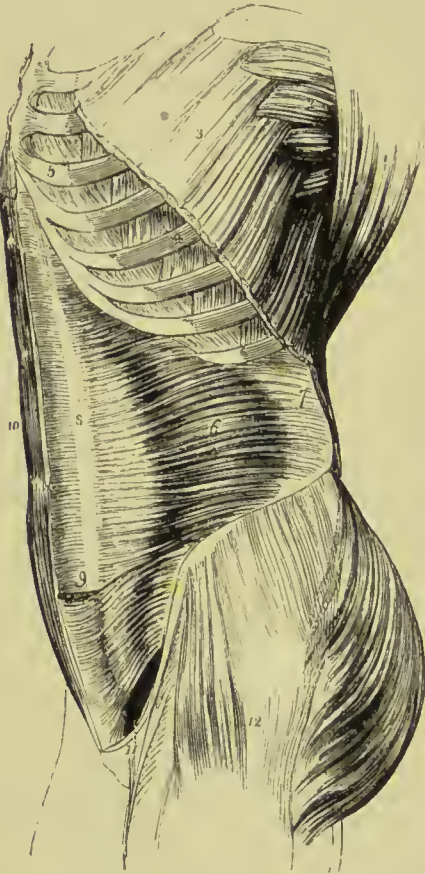


FIG. 203.—Lateral view of the trunk, showing its muscles, particularly the transversalis abdominis. 1. Costal origin of the latissimus dorsi. 2. Serratus magnus. 3. Upper part of the external oblique, divided in the direction best calculated to show the muscles beneath without interfering with its indigitations with the serratus magnus. 4. Two of the external intercostal muscles. 5. Two of the internal intercostals. 6. Transversalis. 7. Its posterior aponeurosis. 8. Its anterior aponeurosis, forming the posterior layer of the sheath of the rectus. 9. Lower part of the left rectus with the aponeurosis of the transversalis passing in front. 10. Right rectus muscle. 11. Arched opening left between the lower border of the transversalis muscle and Poupart's ligament through which the spermatic cord and oblique inguinal hernia pass. 12. Tensor vaginae femoris, gluteus medius and maximus invested by fascia lata.

angles to this, near the margin of the latter muscle, to the ribs; the muscle is then to be separated from its anterior connections and turned backwards. Some degree of care will be required in performing this dissection, from the difficulty of distinguishing between this muscle and the one beneath. A thin layer of connective tissue is all that separates them for the greater part of their extent. Near the crest of the ilium the deep circumflex iliac artery ascends between the two muscles, and forms a guide to their separation; but just above Poupart's ligament they are so closely united that separation is impossible.

The **TRANSVERSALIS** is the internal flat muscle of the abdomen, and is transverse in the direction of its fibres, as implied in its name. It *arises* from the outer third of Poupart's ligament, from the anterior two-thirds of the internal lip of the crest of the ilium; from the spinous and transverse processes of the lumbar vertebræ through the medium of the aponeurosis, and from the inner surface of the six inferior costal cartilages, interdigitating with the fibres of the diaphragm. The superior fibres, proceeding from the cartilage of the seventh rib, are *inserted* into the ensiform cartilage; the inferior fibres, proceeding from Poupart's ligament, curve downwards to be *inserted* by means of a tendinous expansion common to it, and the internal oblique, the *conjoined tendon*, into the crest of the pubes and pectineal line; while the fibres intermediate between these points terminate near the outer border of the rectus in an aponeurosis, which is continued onwards to the linea alba. The upper portion of the aponeurosis, closely united with the posterior lamella of the aponeurosis of the internal oblique, assists in forming the posterior wall of the sheath of the rectus, while the inferior portion, commencing at a point midway between the umbilicus and pubes, is continued with the undivided aponeurosis of the internal oblique in front of the rectus.

Relations.—By its *external surface* with the internal oblique, the internal surface of the six lower ribs, and internal intercostal muscles. By its *internal surface* with the transversalis fascia, which separates it from the peritoneum, with the psoas magnus, the lower part of the rectus, and pyramidalis. The spermatic cord and oblique inguinal hernia pass beneath the *lower border*, but have no direct relation with it. The *upper border* is continuous with the diaphragm and triangularis sterni.

Nerve-supply.—Anterior branches of lower intercostals.

Lumbar Fascia.—The *posterior aponeurosis* of the transversalis divides into three lamellæ, anterior, middle, and posterior, which constitute the *fascia lumborum*. The *anterior* lamella, thin and membranous, is attached to the base of the transverse processes of the lumbar vertebræ; the *middle* lamella, of considerable thickness, to their apices; the *posterior* layer receives the posterior aponeurosis of the internal oblique, and is attached to the spines of the lumbar vertebræ; near the border of the erector spinæ, it becomes united with the aponeurosis of the latissimus dorsi and serratus posticus inferior. Between the anterior and middle lamella is lodged the quadratus lumborum; and between the middle and posterior layer, the erector spinæ and multifidus spinæ, which are thus furnished with aponeurotic sheaths. The anterior layer is attached above to the lower margin of the last rib and forms the *ligamentum arcuatum externum*.

Dissection.—To dissect the *rectus* muscle, its sheath should be opened by a vertical incision extending from over the cartilages of the lower ribs to the front of the os pubis. The sheath may then be dissected off and turned aside; this is easily done excepting at

the lineæ transversæ, where a close adhesion exists between the muscle and the external wall of the sheath.

The **RECTUS ABDOMINIS** arises by a double tendon from the front and crest of the os pubis, and is inserted by three broad digitations into the outer surfaces of the cartilages of the fifth, sixth, and seventh ribs. It is traversed by several tendinous intersections, called lineæ transversæ (inscriptiones tendineæ). One of these is situated at the umbilicus, one over the ensiform cartilage,

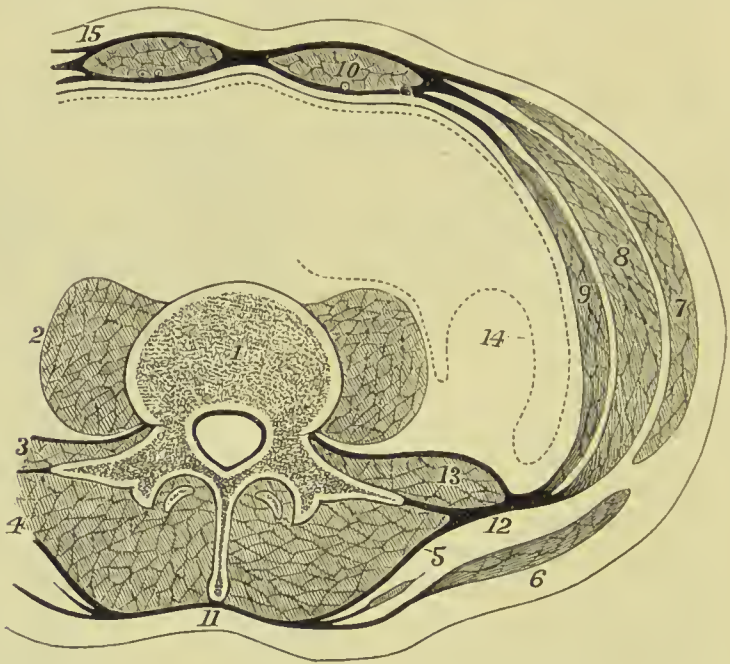


FIG. 204.—Transverse section through the abdominal walls, showing the arrangement of muscles and tendons. 1. A lumbar vertebra. 2. Psoas magnus muscle. 3. Quadratus lumborum. 4. Erector spine. 5. Lumbar aponeurosis. 6. Latissimus dorsi. Between 5 and 6 the serratus posticus inferior is seen. 7. External oblique. 8. Internal oblique. 9. Transversalis. 10. Rectus abdominis. 11. Insertion of the lumbar aponeurosis into the spine of the lumbar vertebra. 12. Lumbar aponeurosis dividing into three layers. 13. The figure is placed on the quadratus lumborum, and has above it the anterior layer of the lumbar aponeurosis, and below it the middle layer. 14. Peritonium where it covers the kidney. 15. Shows the mode of union of the tendons in the formation of the sheath of the rectus.

and one midway between these points; when a fourth exists, it occurs below the umbilicus. They frequently do not involve the whole thickness of the muscle.

Nerve-supply.—The ilio-hypogastric and anterior branches of intercostal nerves.

The **PYRAMIDALIS** arises from the crest of the os pubis in front of the rectus, and is inserted into the linea alba at about midway between the umbilicus and pubes. It is enclosed in the sheath with the rectus, and rests against the lower part of that muscle: it is sometimes absent.

Nerve-supply.—The ilio-hypogastric nerve.

The rectus may now be divided across the middle, and the two ends drawn aside for the purpose of examining the mode of construction of its sheath.

Sheath of the Rectus.—This is formed, *in front*, for the upper three-fourths of its extent, by the aponeurosis of the external oblique

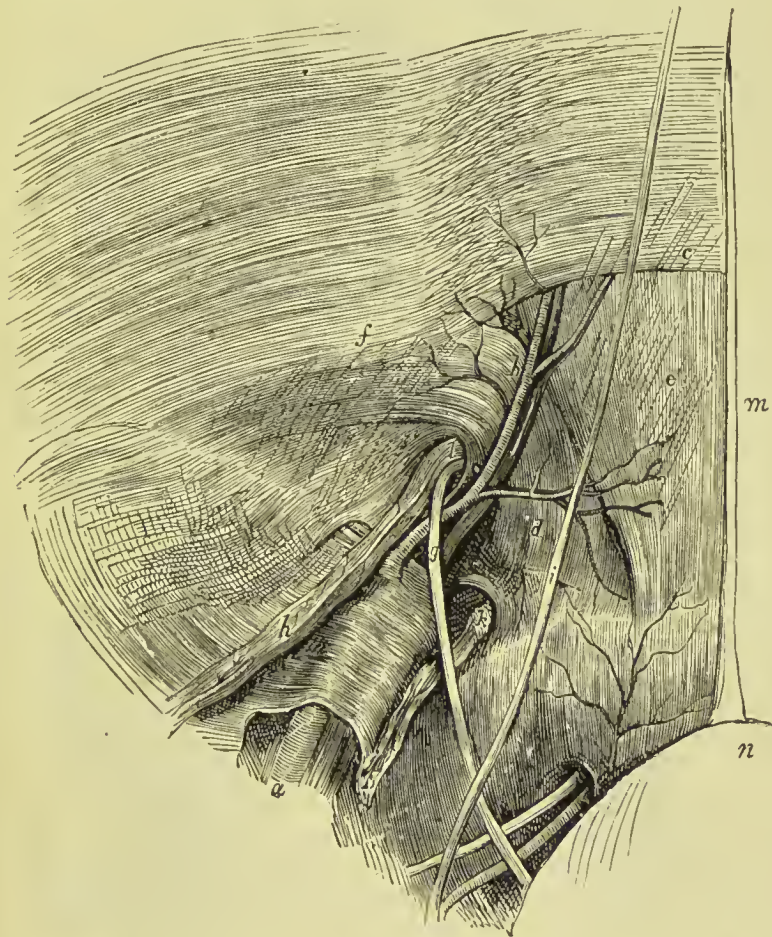


FIG. 205.—Dissection of the lower part of the abdominal wall from within, the peritoneum having been removed. *a.* External iliac artery. *b.* Deep epigastric artery. *c.* Lower edge of the posterior part of sheath of rectus (fold of Douglas). *d.* Conjoint tendon in the triangle of Hesselbach. *e.* Posterior surface of rectus. *f.* Fascia transversalis. *g.* Vas deferens. *h.* Spermatic vessels. *i.* Obliterated hypogastric artery. *k.* Lymphatics of crural ring. *l.* Internal abdominal ring. *m.* Urachus. *n.* Bladder.

and anterior lamella of the internal oblique; *behind* by the posterior lamella of the internal oblique and aponeurosis of the transversalis. Midway between the umbilicus and the pubes, the posterior wall of the sheath terminates in a thin curved margin (*semilunar fold of Douglas*), the aponeurosis of the three muscles passing, below this point, altogether in front of the rectus.

Contents of the Sheath. These are the rectus and pyramidalis

the abdominal intercostal vessels; anterior cutaneous branches of the intercostal nerves, and lymphatic vessels.

Fascia Transversalis (*abdominal fascia*).—This is a thin fibrous membrane which lines the inner surface of the transversalis muscle and the other structures which form the abdominal wall where that

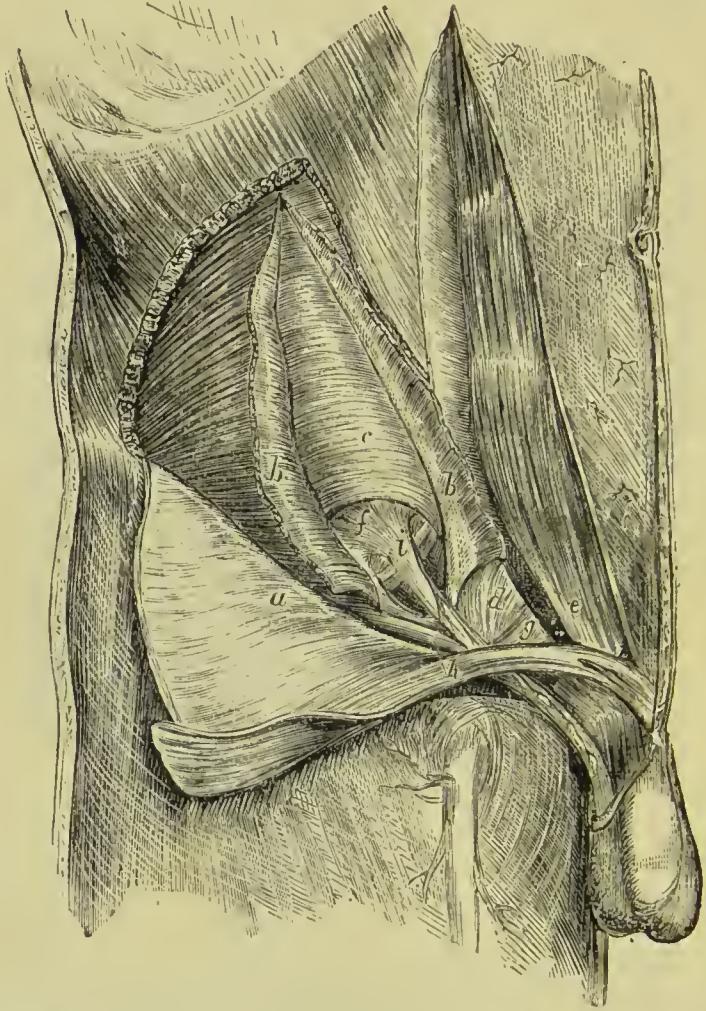


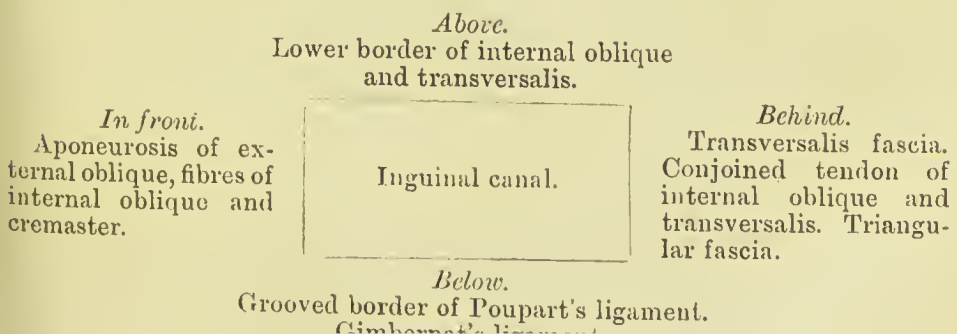
FIG. 206.—Dissection of the inguinal canal. *a*. External oblique (turned down). *b, b*. Internal oblique. *c*. Transversalis. *d*. Conjoined tendon. *e*. Rectus, with sheath opened. *f*. Fascia transversalis. *g*. Triangular fascia. *h*. Cremaster. *i*. Infundibular fascia.

muscle is absent. It is continuous behind with the iliac, and below with the pelvic fascia. It is strong and tough at the lower part of the abdomen, especially where the sheath of the rectus is deficient; but at the upper, where it is continued on to the diaphragm, it is little more than loose areolar tissue. In the centre it lines the back part of the sheath of the rectus, and where that is absent lines the rectus muscle and is attached to the crest of the pubis. At the sides it is attached to the inner lip of the crest of the ilium and along the whole

length of Poupart's ligament, where it is connected to the fascia lata, and for the outer half of the ligament to the iliac fascia which joins it behind. The union of these three fasciæ takes place rather under than in Poupart's ligament, which could therefore be cut away, leaving them connected together as a firm fibrous cord, to which is given the name of **deep crural arch**. At the inner half of Poupart's ligament it is prolonged into the thigh, forming the anterior part of the sheath of the femoral vessels, as the posterior part is formed of a similar prolongation of the iliac fascia.

The **internal abdominal ring** is an opening in this fascia situated about half-way between the anterior superior spine of the ilium and the symphysis of the pubis, and half an inch above Poupart's ligament. It is oval in form, the lower edge being strong, the upper thin and weak. Through this opening the spermatic cord in the male passes to the testicle, and the round ligament of the uterus in the female to its insertion over the pubis. From the edges of the ring a funnel-shaped tube of transversalis fascia is given off which surrounds the structures forming the spermatic cord. This is the **infundibuliform fascia**, sometimes called the **fascia propria** of the cord. The internal abdominal ring, therefore, is simply the funnel-shaped mouth of this tube, and it is situated immediately external to the deep epigastric artery round which the spermatic cord turns in its passage from the abdomen to the scrotum.

Inguinal Canal.—The spermatic or inguinal canal, which in the normal condition of the abdominal parietes serves for the passage of the spermatic cord in the male, and the round ligament with its vessels in the female, is about one inch and a half in length. It is bounded, *in front*, by the aponeurosis of the external oblique muscle and a few fibres of the internal oblique and cremaster; *behind*, by the transversalis fascia, the conjoined tendon of the internal oblique and transversalis, and triangular fascia; *above*, by the arched border of the internal oblique and transversalis; *below*, by the grooved border of Poupart's ligament and the upper surface of Gimbernat's ligament; and at each extremity by one of the abdominal rings, the internal ring at the inner, the external ring at the outer extremity. These relations may be more distinctly illustrated by the following plan:—



SURGICAL ANATOMY OF INGUINAL HERNIA.

Inguinal hernia is of two kinds, oblique and direct.

In **OBLIQUE INGUINAL HERNIA** the intestine follows the same course as is pursued by the testicle in its descent, and obtains the same coverings as that organ. It escapes from the cavity of the abdomen into the *spermatic or inguinal canal*, through the *internal abdominal ring*, pressing before it a pouch of peritoneum which constitutes the *hernial sac*, and distending the infundibuliform process of the transversalis fascia. After emerging through the internal abdominal ring it passes *firstly* beneath the lower and arched border of the internal oblique muscle; and *then* through the *external abdo-*

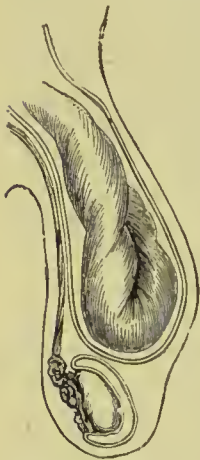

FIG. 207.—Diagram of a common scrotal hernia, showing the relation of the sac to the tunica vaginalis testis.

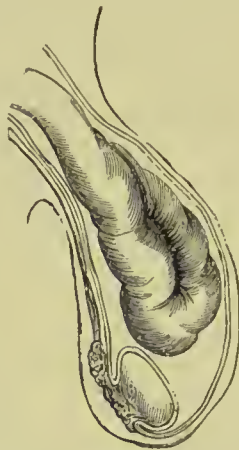

FIG. 208.—Diagram of a congenital hernia, the sac being continuous with the tunica vaginalis testis.

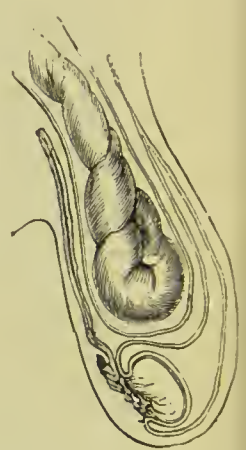


FIG. 209.—Diagram of an infantile hernia, showing the tunica vaginalis prolonged in front of the sac.

minal ring, in the aponeurosis of the external oblique. While passing beneath the lower border of the internal oblique it obtains the cremaster muscle; and on escaping at the external abdominal ring, receives the intercolumnar or spermatic fascia. So that the coverings of an oblique inguinal hernia, after it has emerged through the external abdominal ring, are, from the surface to the intestine, the—

Integument,
 Superficial fascia,
 Intercolumnar fascia,
 Cremaster muscle,
 Transversalis, or infundibuliform fascia,
 Retro-peritoneal fat,
 Peritoneal sac.

There are three varieties of oblique inguinal hernia: common, congenital, and infantile.

Common oblique hernia is that which has been described above.

Congenital hernia results from the non-closure of the pouch of peritoneum carried downwards into the scrotum by the testicle, during its descent in the fœtus. In consequence of this defect, the intestine at some period of life is forced into the peritoneal canal, and descends through it into the tunica vaginalis, where it lies in contact with the testicle; so that congenital hernia has *no proper sac*, but is contained within the tunica vaginalis. The other coverings are the same as those of common inguinal hernia. In the female, congenital hernia descends into the canal of Nuck.

Infantile hernia is that form of protrusion in which the pouch of peritoneum forming the tunica vaginalis is only partially closed. The connection with the abdomen is completely closed at the inguinal canal, but the rest of the tube remains in its original state, and when a hernia makes its way into the scrotum it lies behind the enclosed tunica vaginalis. So that the surgeon, in operating upon this variety, requires to divide three layers of serous membrane; the first and second layer being those of the tunica vaginalis, the third the true sac of the hernia.

A variety of this form is called **encysted hernia**; in it, the hernial sac is invaginated into the incompletely closed tunica, as shown in Fig. 210. The surgeon has, therefore, to divide two layers of peritoneum before he reaches the bowel.

DIRECT INGUINAL HERNIA has received its name from passing *directly* through the external abdominal ring, and forcing before it the opposing parietes. This portion of the wall of the abdomen is strengthened by the conjoined tendon of the internal oblique and transversalis, which is pressed before the hernia, and forms one of its investments. Its coverings, therefore, are the—

Integument,
Superficial fascia,
Intercolumnar fascia,
Conjoined tendon,
Transversalis fascia,
Retro-peritoneal fat,
Peritoneal sac.

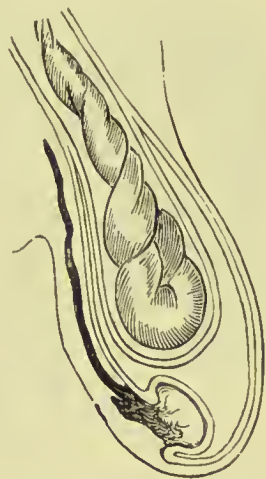


FIG. 210.—Encysted hernia.

Direct inguinal hernia differs from oblique, firstly, in never attaining the same bulk, in consequence of the resisting nature of the conjoined tendon and transversalis fascia; secondly, in its having a tendency to protrude *from the middle line* rather than from the side.

Thirdly, in making for itself a new passage through the abdominal parietes, instead of following a natural channel; and fourthly, in the relation of the neck of its sac to the epigastric artery; that vessel lying to the outer side of the opening of the sac of direct hernia, and to the inner side of that of oblique hernia.

The direct hernia passes through a triangular space, bounded on the outer side by the deep epigastric artery, on the inner by the edge of the rectus muscle, and below by Poupart's ligament; this space is called the **triangle of Hesselbach**.

All the forms of inguinal hernia are designated *scrotal*, when they have descended into the scrotum; the oblique inguinal is most frequently found in this situation, from its following the course of the spermatic cord.

MUSCLES OF THE POSTERIOR WALL OF THE ABDOMEN, AND DIAPHRAGM.

Dissection.—The next two muscles can be examined only when the viscera of the abdomen are removed. To see the quadratus lumborum, it is also necessary to divide and draw aside the psoas muscle and the anterior lamella of the posterior aponeurosis of the transversalis.

The **QUADRATUS LUMBORUM** will be seen to consist of two portions:—one, the *external*, arising from the ilio-lumbar ligament and adjoining part of the crest of the ilium for two inches in extent, and *inserted* into the apices of the transverse processes of the four upper lumbar vertebræ (sometimes also last dorsal) and last rib; the other, the *internal* and anterior portion, arises by tendinous slips from the transverse processes of the three or four lower lumbar vertebræ, and passes upwards to be *inserted* into the lower border of the last rib. If the muscle be cut across or removed, the middle lamella of the aponeurosis of the transversalis will be seen, attached to the apices of the transverse processes; the quadratus being enclosed between the two lamellæ as in a sheath.

Relations.—Enclosed in the sheath formed by the aponeurosis of the transversalis muscle, it is in relation, *in front*, with the kidney, colon, psoas magnus, and diaphragm. *Behind*, but also separated by its sheath, with the erector spinæ.

Nerve-supply.—Anterior branches of the lumbar nerves.

The **PSOAS PARVUS** is a small and infrequent muscle which arises from the last dorsal and first lumbar vertebra and from the intervertebral substance between them, and terminates in a long slender tendon which expands inferiorly and is *inserted* into the pectineal line and eminence. The tendon is continuous by its outer border with the iliac fascia.

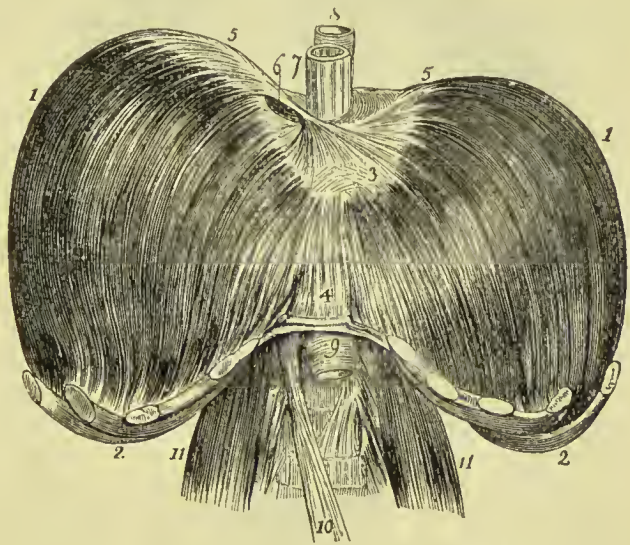
Relations.—It rests on the psoas magnus, and is covered in by the peritonæum; superiorly it passes beneath the ligamentum arcuatum internum of the diaphragm.

Nerve-supply.—Branches of the lumbar plexus.

DIAPHRAGM.—To obtain a good view of this important inspiratory muscle, the peritonemum should be dissected from its under surface. It is a transverse muscular septum between the thorax and abdomen, and is composed of two portions, thoracic and lumbar. The **thoracic portion** *arises* from the ensiform cartilage by a distinct slip and from the internal surface of the six inferior ribs, interdigitating with the transversalis. The fibres converge to be *inserted* into the central tendon.

A triangular interval exists between the sternal and costal portion of the muscle at each side, closed by a few irregular muscular fibres, some connective tissue, and by the serous membranes of the cavity of the chest and abdomen. A protrusion of any portion of the contents

FIG. 211. The diaphragm viewed from the front, showing its upper or thoracic surface. 1, 1. The lateral segments of the thoracic portion; arising from 2, 2. The cartilages of the ribs; and inserted into 3, The central tendon. The right segment is seen to be higher than the left. 4. The fasciculus which arises from the ensiform cartilage. 5, 5. Lateral leaflets of the central tendon. 6. Opening for the inferior vena cava. 7. The œsophagus. 8. The thoracic aorta. 9. The abdominal aorta. 10. The tendon of the right crus of the diaphragm: that of the left is seen immediately above on the lumbar vertebræ. 11, 11. The psoas muscles.



of the abdomen through this opening constitutes *phrenic* or *diaphragmatic hernia*.

The **lumbar portion** consists of a right and left lateral half (*crura*); each of which is composed of *three* smaller pillars, *internal, middle, and external*.

The **crura** *arise* from the front and lateral aspect of the bodies of the first, second, and third lumbar vertebræ, from the intervertebral substance between the first, second, third, and fourth, from the transverse process of the first, ligamentum arcuatum internum and externum, and last rib. The *left crus* is shorter than the right by the breadth of a vertebra, and does not advance so far forward on the front of the vertebral column. The crura are *inserted* into the whole length of the posterior border of the central tendon.

The origin of the crura takes place by a strong tendon, from which and from the other points of attachment muscular fibres proceed. The *internal pillar* of the crus is its anterior fasciculus, which pro-

ceeds from the third lumbar vertebra; the *middle pillar*, smaller than the others, proceeds from the second vertebra; the *external pillar*, the largest of the three, from the first lumbar vertebra, ligamenta arcuata, and last rib. The internal pillars approach each other as they ascend, the arched interval between them being the aortic opening; their internal fibres, consisting of several fasciculi, cross each other in front of the aortic opening and form the lateral boundaries of another opening of elliptical shape (œsophageal), and are then lost in the central tendon. In the decussation between the

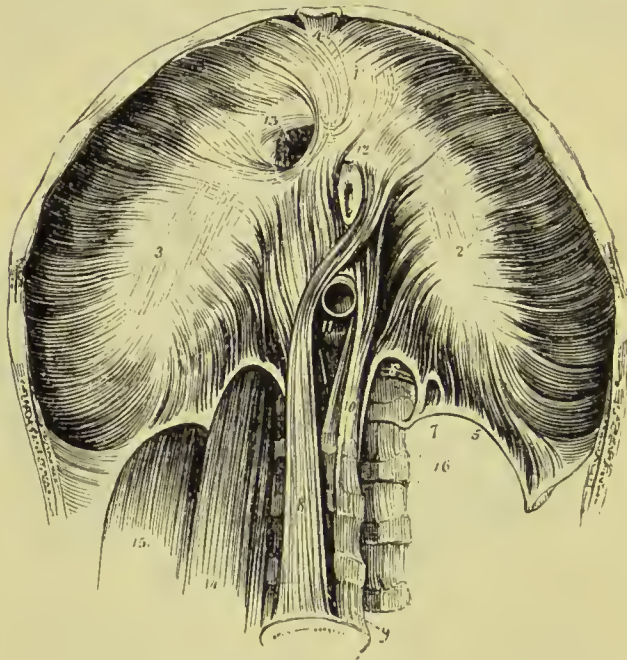


FIG. 212.—Abdominal side of the diaphragm. 1, 2, 3. The thoracic portion; figure 1 rests on the central leaflet of the tendinous centre; figure 2 on the left or smallest leaflet; figure 3 on the right leaflet. 4. Fasciculus from the ensiform cartilage; a small triangular space is left on either side of the fasciculus. 5. Ligamentum arcuatum externum of the left side. 6. Ligamentum arcuatum internum. 7. A small arched opening occasionally found, through which the lesser splanchnic nerve passes. 8. Tendon of the right crus. 9. Fourth lumbar vertebra. 10. Ten-

dendon of the left crus. 11. Aortic opening occupied by the aorta. 12. Portion of the œsophagus issuing through the œsophageal opening. 13. Opening for the inferior vena cava, in the tendinous centre of the diaphragm. 14. Psoas magnus passing beneath the ligamentum arcuatum internum; it has been removed on the opposite side to show the arch more distinctly. 15. Quadratus lumborum passing beneath the ligamentum arcuatum externum; this muscle has also been removed on the left side. 16. Transverse processes of lumbar vertebrae, and intertransverse muscles.

aortic and œsophageal opening the fibres of the right internal pillar are generally the most superficial. Muscular fibres are commonly found passing from the upper surface of the diaphragm on to the left side of the pericardial sac (Forbes). Between the lumbar and costal portion of the diaphragm at each side there is often a triangular interval like that between the costal and sternal portion, closed only by areolar tissue and the serous membranes of the two cavities.

The **ligamentum arcuatum internum** is a tendinous arch thrown across the upper part of the psoas muscle from the side of the body of the first lumbar vertebra to the apex of its transverse

process, extending sometimes also to that of the second. Beneath this arch a psoas abscess emerges from the chest.

The **ligamentum arcuatum externum** is a tendinous band extended from the apex of the transverse process of the first lumbar vertebra to the lower border of the last rib. It forms an arch across the quadratus lumborum, and is a thickened part of the sheath of that muscle derived from the posterior aponeurosis of the transversalis abdominis.

The **tendinous centre** of the diaphragm is shaped like a trefoil leaf, of which the central leaflet points to the ensiform cartilage, and is the largest; the lateral leaflets, right and left, occupy the corresponding portions of the muscle; the right being the larger and rounded, the left smaller and lengthened in its form.

The **openings in the diaphragm** are three: one, *quadrilateral*, in the tendinous centre, at the union of the right and middle leaflets, for the passage of the *inferior vena cava* and a branch of the *phrenic nerve*; a muscular opening of an elliptical shape formed by the internal pillars of the crura, the *oesophageal*, for the transmission of the *oesophagus* and *pneumogastric nerves*; a third, the *aortic*, formed by a tendinous arch thrown from the tendon of one crus to that of the other. The latter opening is the largest, lowest, and most posterior of the three; it is bounded behind by the vertebral column, and gives passage to the *aorta*, *vena azygos major*, and *thoracic duct*. The great splanchnic nerve passes through the diaphragm between the internal and middle pillar of the crus; the lesser splanchnic nerve escapes between those fibres of the external pillar which proceed from the ligamentum arcuatum internum. The sympathetic chain passes into the abdomen beneath the ligamentum arcuatum internum, and the *vena azygos minor* passes from the abdomen to the thorax through the left crus of the diaphragm.

The diaphragm forms a dome, the convexity of which is directed towards the thorax and the concavity towards the abdomen; the right half rises to a higher level than the left, in consequence of being pushed upwards by the liver, and the central leaflet of the tendon is lower than the top of either half of the dome. During life, the level of the diaphragm varies with respiration and with the condition of the organs; after death the top of the right half of the dome reaches to about a level with the lower border of the fourth rib, the left half to the upper edge of the fifth rib, and the central leaflet corresponds to the junction of the xiphoid cartilage with the sternum.

Relations.—By its *superior surface* with the pleuræ, pericardium, heart, and lungs. By its *inferior surface* with the peritoneum; on the left with the stomach and spleen; on the right with the convexity of the liver; behind with the kidneys, supra-renal capsules, duodenum, and solar plexus. By its *circumference* with the ensiform cartilage, ribs, intercostal muscles, and vertebral column.

Nerve-supply.—The phrenic nerve, derived from the third, fourth, and fifth cervical

Actions of the Muscles of the Abdominal Wall and the Diaphragm.—The external oblique muscle, acting singly, draws the thorax towards the pelvis, and twists the body to the opposite side. Both muscles, acting together, flex the thorax directly on the pelvis. The internal oblique of one side draws the chest downwards and outwards; both together bend it directly forwards. Either transversalis muscle, acting singly, will diminish the size of the abdomen on its own side, and both together will constrict the entire cylinder of the cavity. The recti muscles flex the thorax towards the pelvis, and, through the arrangement of their sheaths, combine with the oblique and transverse muscles in exercising pressure on the abdominal viscera. The absence of the posterior layer of the sheath of the rectus muscles below allows of direct pressure being brought to bear upon the bladder when full, and upon the uterus in parturition. The pyramidales are tensors of the linea alba. The abdominal are expiratory muscles, and chief agents in expulsion; by their action, the fœtus is expelled from the uterus, the urine from the bladder, fæces from the rectum, bile from the gall-bladder, ingesta from the stomach and bowels in vomiting, and mucus and irritating substances from the bronchial tubes, trachea, and nasal passages during coughing and sneezing. To produce these effects, they all act together. The quadratus lumborum draws the last rib downwards, and is an expiratory muscle; it also serves to bend the vertebral column to one or the other side. The psoas parvus is a tensor of the iliac fascia, and, taking its fixed origin from below, may assist in flexing the vertebral column forwards. The diaphragm is an inspiratory muscle, and the sole agent in tranquil inspiration. When in action, the muscle is drawn downwards, its plane being rendered oblique from the level of the ensiform cartilage to that of the upper lumbar vertebra. During relaxation it is convex, and encroaches considerably on the cavity of the chest, particularly at the sides, where it corresponds with the lungs. It assists the abdominal muscles powerfully in expulsion, every act of that kind being preceded or accompanied by inspiration. Spasmodic action of the diaphragm produces hiccough and sobbing, and its rapid alternation of contraction and relaxation, combined with laryngeal and facial movements, laughing and crying.

MUSCLES AND FASCLE OF THE PERINEUM.

The muscles of the perineum are situated in the outlet of the pelvis, and consist of two groups, one of which belongs especially to the organs of generation and urethra, the other to the termination of the alimentary canal. To these may be added the muscles of the coccyx. The muscles of the perineal region in the male are the—

Bulbo-cavernosus,	Sphincter ani,
Ischio-cavernosus,	Levator ani,
Transversus perinei,	Coccygeus.
Compressor urethræ,	

Dissection.—To dissect the perineum, the subject should be fixed in the position for lithotomy, that is, the hands should be bound to the soles of the feet, and the knees kept apart. Both of these means of preparation have for their object the full exposure of the perineum. And as this is a dissection which demands some degree of delicacy and nice manipulation, a strong light should be thrown upon the part. A large sound is to be introduced into the bladder, and a string, tied round the testicles, to be fixed to its handle. This will retain the sound in the bladder and put the perineum on the stretch. An incision is to be made from the point where the scrotum joins the perineum along the middle of the latter to the anterior edge of the anus, round each side of this, and from the posterior edge of it to the tip of the coccyx. This incision is to be supplemented by lateral ones carried from the anterior end of the first outwards on to the thigh and then backwards to a little beyond the level of the posterior margin of the anus, so as to include in its area the tuberosity and ramus of the ischium. The flaps are to be dissected back with great care, the integument alone being removed so as to expose the subcutaneous sphincter and the superficial fascia. After the fascia has been carefully dissected off and the perineal vessels and nerves turned aside, the muscles are brought into view.

PERINEAL FASCIÆ.—The fasciæ of the perineum are the superficial and the deep.

The **superficial fascia** consists, as in other situations, of two layers, one lying next the skin and containing an abundance of fat, the other more condensed lying in contact with the muscles.

The **superficial layer**, or fatty layer, in the perineum is continuous with the dartos of the scrotum, or areolar tissue of the labia majora, in front, with the superficial fascia of the thighs at each side, and with the superficial fascia covering the glutei maximi and with the coccyx behind. It differs in character and composition in different parts of the perineum; thus at the back part it consists of fine granular fat which fills up the large space between the ischium and anus called the *ischio-rectal fossa*; over the tuberosity of the ischium it becomes tough and stringy, and is formed by interwoven strands of fibrous tissue between which numerous small synovial bursæ are found; in the anterior part of the perineum, again, it is thin and membranous, the fat being replaced by unstriped muscular tissue, and is continued into the tunica dartos.

The **deep or membranous layer** of the superficial fascia, or **fascia of Colles**, lies in close contact with the muscles and superficial vessels of the perineum, packing them into their places. On each side it is attached to the ramus of the ischium and pubes, and this attachment is continued forwards and outwards on to the fascia lata of the thigh, where it becomes continuous with the deep fascia of the groin. It is prolonged backwards as far as the transversalis perinei muscle, round the posterior border of which it turns to be united to the deep perineal fascia on which the muscle rests. At this point these two fasciæ are blended together and united to the

tinued backwards on the outer surface of the levator ani, to join the anal fascia. It is continued forwards to blend with the deep fascia of the penis. In the middle line it has on its deep aspect a septal prolongation, complete behind but incomplete in front, so that air or fluid injected beneath the fascia would fill up one side of the pouch which it forms, then passing forwards to where the septum is incomplete, would infiltrate the other side. The attachment of the membranous layer to the deep perineal fascia explains why an extravasation of fluid under that membrane could not pass back into

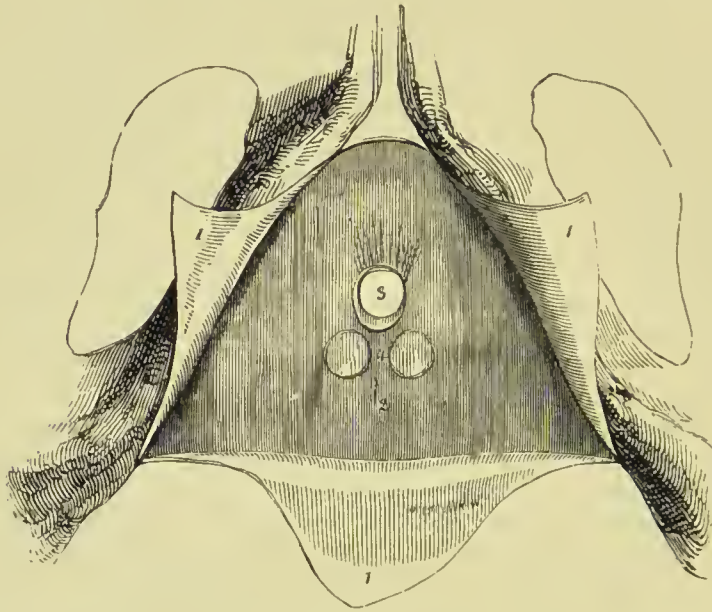


FIG. 213.—The pubic arch and perineal fasciæ. The corpora cavernosi and corpus spongiosum with the muscles which lie upon them, as well as the vessels and nerves, have been removed. 1, 1, 1. The deep layer of the superficial perineal fascia divided by a Λ -shaped incision into three flaps; the lateral flaps are turned over the ramus of the pubes and ischium at each side, to which they are firmly attached; the posterior flap is continuous with the deep perineal fascia or triangular ligament. 2. The triangular ligament of the urethra. 3. Opening for the passage of the membranous portion of the urethra, previously to the entrance of the latter into the bulb. 4. Two projections of the triangular ligament corresponding with the position of Cowper's glands.

the posterior half of the perineum, but could find its way, as it often does, into the scrotum and up over the abdomen.

Muscular Triangle.—The space between Colles' fascia and the triangular ligament is occupied by the bulb of the urethra, corpus spongiosum, crura penis, bulbo-cavernosi, ischio-cavernosi and transversus perinei muscles, anterior and posterior superficial perineal nerves, superficial perineal and transverse perineal vessels, and a few lymphatic vessels.

The **deep perineal fascia or triangular ligament** of the urethra is a strong aponeurotic sheet which is stretched across the inter-pubic arch. It is attached firmly to the sub-pubic ligament, and to the

ramus of the pubes and ischium. At the posterior border of the transversalis perinei muscle, it has attached to it the deep layer of the superficial fascia, and with it is prolonged back on the levator ani muscle, as the *anal* fascia. At an inch and a half from the symphysis pubis, in the middle line, it is connected to the central tendinous point of the perineum. About an inch below the symphysis pubis it is pierced for the passage of the membranous portion of the urethra, which is contained between it and the parietal layer of the pelvic fascia behind. Immediately below the sub-pubic ligament the dorsal vein of the penis passes back through it to join the prostatic plexus, and on each side, a little in front of this, the pudic arteries pass through it to enter the corpora cavernosa penis. Between this ligament and the pelvic fascia are situated the compressor urethræ muscle, the internal pudic arteries, the arteries of the corpus cavernosum, dorsum of the penis and bulb, Cowper's glands, the membranous part of the urethra, the dorsal vein of the penis, the dorsal nerve, lymphatic vessels, and a plexus of veins. Sometimes the triangular ligament is described as consisting of two layers, anterior and posterior, the former being the deep perineal fascia, and the latter the layer of pelvic fascia passing across the pelvic arch. When the ligament is thus described, the structures above enumerated are said to be placed between the two layers of the triangular ligament.

The **BULBO-CAVERNOSI** (*acceleratores urinæ*) arise from a tendinous point in the centre of the perineum, and from the fibrous raphé of the two muscles. From this origin the fibres diverge like the barbs of a pen; the posterior to be *inserted* into the triangular ligament; the middle, to encircle the corpus spongiosum and meet on its upper side; the anterior, to spread out on the corpus cavernosum at each side, and be inserted partly into its fibrous structure, and partly into the fascia on the dorsum of the penis. The posterior and middle insertions of these muscles are best seen by carefully raising one muscle from the corpus spongiosum and tracing its fibres.

The **ISCHIO-CAVERNOSUS** (*erector penis*) arises from the tuberosity of the ischium and from the ramus of the pubes behind the extremity of the crus, and curves around the root of the penis; to be *inserted* into the upper surface of the corpus cavernosum, where it is continuous with a strong fascia which covers the dorsum of the organ, the *fascia penis*.

Nerve-supply.—The perineal branch of the pudic nerve supplies the acceleratores urinæ and the erector penis.

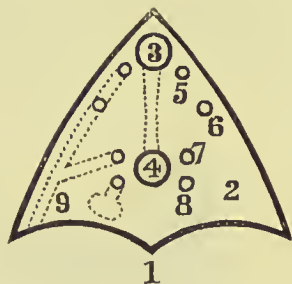


FIG. 214.—Diagrammatic view of the anterior layer of the triangular ligament and the structures passing through it. 1. Process passing down to central tendinous point. 2. Triangular ligament. 3. Dorsal vein of penis. 4. Urethra. 5. Dorsal artery. 6. Artery of corpus cavernosum. 7. Artery of bulb. 8. Duct of Cowper's gland. 9. Internal pudic artery.

The **TRANSVERSUS PERINEI** arises from the ramus of the ischium at each side, and is inserted into the central tendinous point of the perineum, where it is connected with the bulbo-cavernosus and sphincter ani. Occasionally the transversus perinei is of large size, and spreads out as it approaches the middle line so as to become fan-shaped. The posterior fibres are continuous with those of the

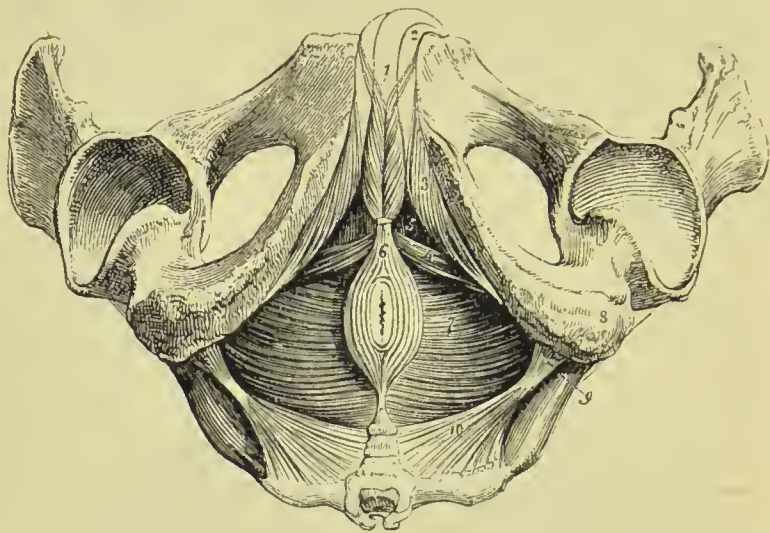


FIG. 215.—Muscles of the perineum. 1. Bulbo-cavernosi; the figure rests on the corpus spongiosum penis. 2. Corpus cavernosum of one side. 3. Ischio-cavernosus of one side. 4. Transversus perinei of one side. 5. Muscular triangle, through which the triangular ligament is seen. 6. Sphincter ani; its anterior extremity cut off. 7. Levator ani of the left side; the deep space between the tuberosity of the ischium (8) and the anus, is the ischio-rectal fossa; the same fossa is seen on the opposite side. 9. Spine of the ischium. 10. Left coccygeus muscle. The boundaries of the perineum are well exhibited in this engraving.

muscle of the opposite side; but the anterior are prolonged forwards upon the bulb and corpus spongiosum of the urethra.

Nerve-supply.—The perineal branch of the pudic nerve.

Dissection.—To dissect the *compressor urethræ*, the three preceding muscles should be removed, so as to render the glistening surface of the triangular ligament apparent. This ligament should then be carefully dissected away, and the corpus spongiosum penis divided through its middle, separated from the corpus cavernosum, and drawn forwards in order to put on the stretch the membranous portion of the urethra, with which the compressor muscles are connected. The compressor urethræ is, however, better seen in a dissection made from within the pelvis, after having turned down the bladder from its attachment to the os pubis, and removed a plexus of veins together with the pelvic fascia.

The **COMPRESSOR URETHRÆ** (constrictor urethræ membranacea), directed transversely across the perineum above the triangular ligament, arises from the ramus of the pubes and ischium, their point of union, and from the anterior ligament of the bladder

PLATE 21.

THE MALE PERINEUM.

FIG. 1.—SUPERFICIAL DISSECTION SHOWING THE VESSELS AND NERVES.

FIG. 2.—DISSECTION SHOWING THE MUSCLES.

- A. Urethra.
- B. Bulbo-cavernosus.
- C. Central point of perineum.
- D. Ischio-cavernosus.
- E. Transversus perinei.
- F. Anus.
- G. Tuber_ischii.

- H. Coccyx.
- I. Gluteus maximus.
- K. Levator ani.
- L. Triangular ligament.
- 1. Superficial perineal vessels and nerves.
- 2. Inferior hæmorrhoidal vessels and nerves.

PLATE 21.

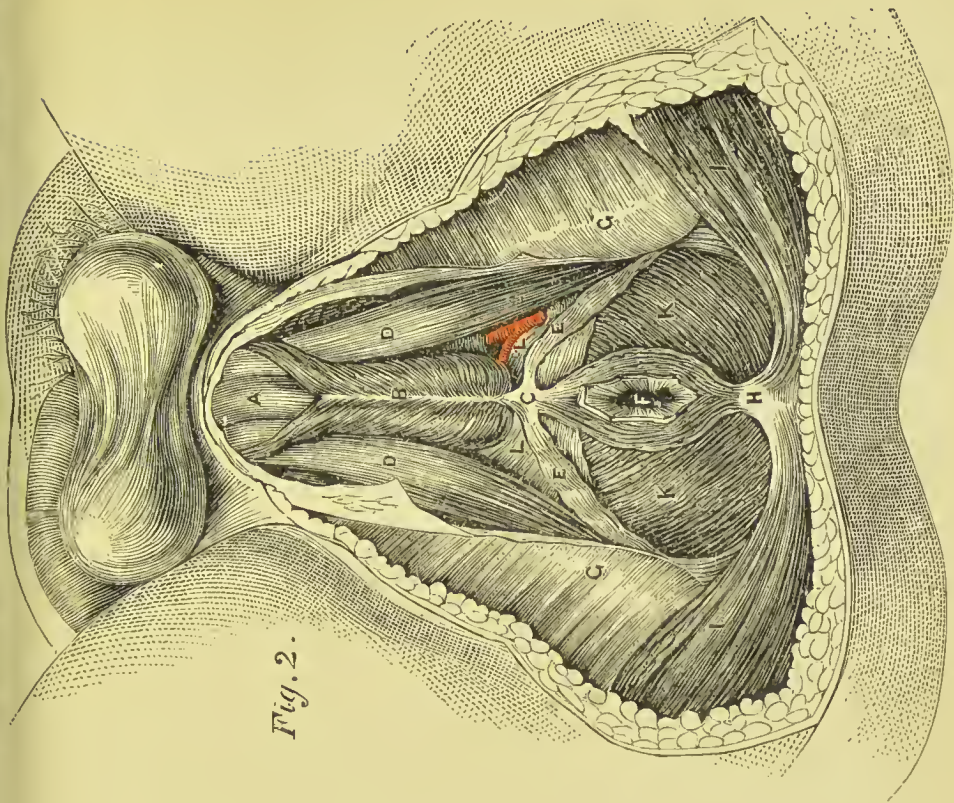


Fig. 2.

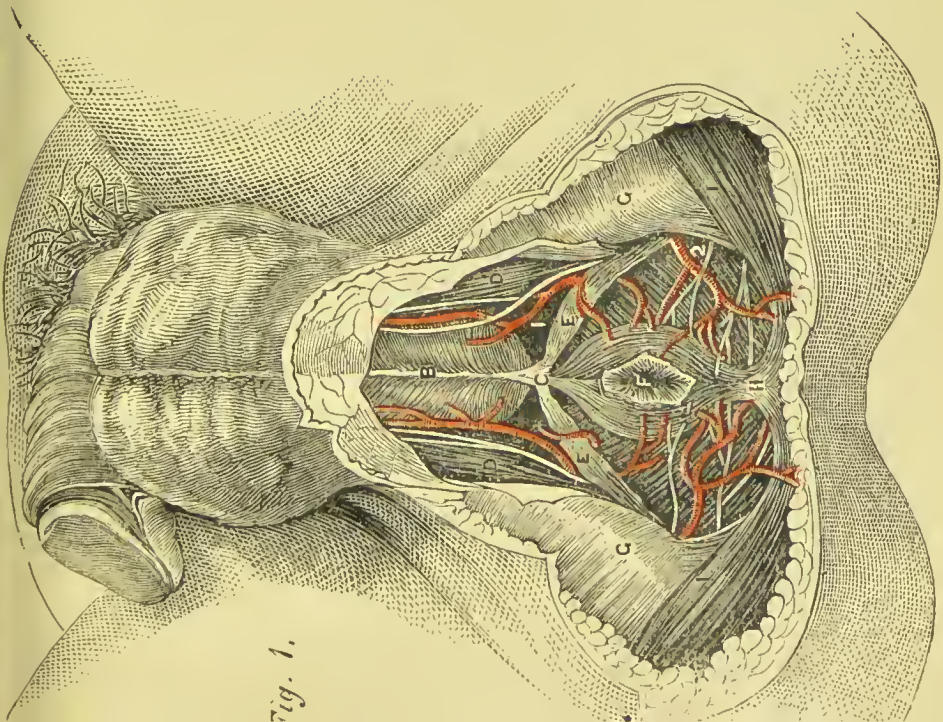


Fig. 1.



and prostate gland. Proceeding inwards it divides into two fan-shaped fasciculi, superior and inferior, which embrace the membranous portion of the urethra, and are continuous with the muscle of the opposite side. The *superior fasciculus* is continued forwards to the junction of the crura penis, and backwards to the prostate gland; on the upper surface of which it is spread out. The *inferior fasciculus* is attached to the bulb of the urethra in front, and extends to the prostate gland behind. The lowest fibres of this fasciculus are sometimes described as a separate muscle under the name of *deep transversus perinei muscle*. A third fasciculus, closely united with the two preceding, consists of *circular* fibres, which enclose and form a muscular sheath for the membranous part of the urethra, and are continuous posteriorly with the circular muscular fibres of the prostate gland.

Under the name of *Wilson's muscle*, a fourth fasciculus has been described as descending vertically from the body of the pubes, near the symphysis, to unite with the superior fasciculus of the compressor urethrae.

Nerve-supply.—The perineal branch of the pudic.

The **SPHINCTER ANI** is a thin and elliptical plane of muscle closely adherent to the integument, and surrounding the opening of the anus. It *arises* posteriorly in the superficial fascia around the coccyx, and by a fibrous raphé (called the *ano-coccygeal ligament*) from the apex of that bone; it passes round the margin of the anus, and is *inserted* anteriorly into the tendinous centre of the perineum, and into the raphé of the integument, nearly as far forward as the commencement of the scrotum. The anterior fibres mingle with those of the bulbo-cavernosus, the outer ones pass into the levator ani, while some of the innermost fibres cross the median line and decussate with those of the opposite side.

The **SPHINCTER ANI INTERNUS** is a muscular band embracing the extremity of the intestine, and formed by an aggregation of the circular muscular fibres of the rectum; it is composed of *m-striped* muscle.

Nerve-supply.—The sphincters are supplied by the anterior branch of the fourth sacral, and inferior hæmorrhoidal branch of

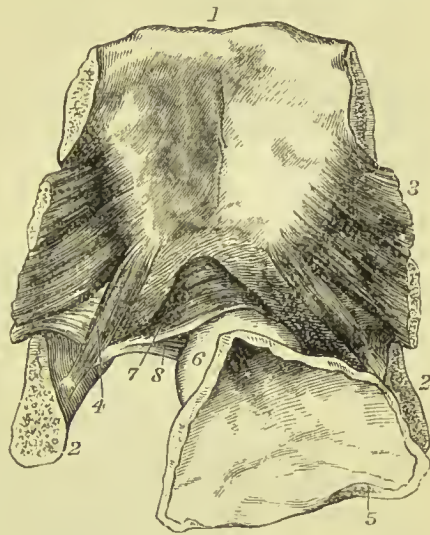


FIG. 216.—Posterior view of the pubes, with part of bladder and urethra attached. 1. Body of pubes. 2. Ramus. 3. Obturator internus muscle. 4. Portion of the fundus and neck of the bladder laid open. 5. Prostate gland. 6. Transverse fibres of the compressor urethrae, passing above the urethra. 7. Similar fibres passing beneath that canal.

The **central tendinous point of the perineum** is situated in the middle line of the perineum, midway between the anns and bulb of the urethra. It forms the meeting-point of a number of the perineal muscles; these are the bulbo-cavernosus, transversus perinei, external sphincter ani, and levator ani muscles of the two sides.

Dissection.—Part of the levator ani may be seen during the dissection of the anal portion of the perineum by removing the fat from the ischio-rectal fossa. But to study the entire muscle, a lateral section of the pelvis must be made by sawing through the pubes a little to one side of the symphysis, separating the bones behind at the sacro-iliac symphysis, and turning down the bladder and rectum. The spine of the ischium should be cut off with the bone forceps or saw, so as to leave it in connection with the levator ani and pelvic fascia. The pelvic fascia is then to be carefully raised, beginning at the base of the bladder, and proceeding upwards, until the whole extent of the muscle is exposed.

The **LEVATOR ANI** is a thin plane of muscular fibres, situated at each side of the pelvis. The muscle *arises* from the inner surface of the os pubis near the pubic arch, from the base and upper border of the spine of the ischium, and between those points, from a tendinous arch which occupies the line of division of the pelvic fascia into parietal and visceral layers, and is called the **white line**. Its fibres descend to be *inserted* into its fellow of the opposite side beneath the prostate gland, into the rectum, and behind the rectum into its fellow of the opposite side and the side of the extremity of the coccyx. Its anterior fibres are sometimes described separately, under the name of *levator prostatici*.

In the female this muscle has an additional insertion into the vagina.

Relations.—By its *external* or *perineal surface*, with the *anal fascia*, by which it is separated from the ischio-rectal fossa; with the fat in the ischio-rectal fossa, triangular ligament, sphincter ani, and posteriorly, glutens maximus. By its *internal* or *pelvic surface* with the pelvic fascia, which separates it from the viscera of the pelvis and peritoneum. Its posterior border is continuous with the coccygeus muscle.

Nerve-supply.—The anterior branch of the fourth sacral.

The **COCCYGEUS** muscle, thin and triangular, *arises* from the pelvic surface of the spine of the ischium and lesser sacro-ischiatic ligament, and spreads out to be *inserted* into the side of the coccyx and lower part of the sacrum.

Relations.—By its *internal* or *pelvic surface* with the cavity of the pelvis and rectum; by its *external surface* with the lesser sacro-ischiatic ligament; and by its *borders* with the pyriformis behind, and levator ani in front.

Nerve-supply.—The fourth and fifth sacral and coccygeal nerves.

FEMALE PERINEUM.—The muscles of the perineum in the female are the same as in the male, and have received analogous names. They are smaller in size, and are modified to suit the difference of form of the organs; they are—

Sphincter vaginae,
Ischio-cavernosus,
Transversus perinei,
Compressor urethrae,

Sphincter ani,
Levator ani,
Coccygeus.

The **SPHINCTER VAGINÆ** corresponds to the bulbo-cavernosus of the male; it *arises* from the tendinous centre of the perineum, where it is continuous with the sphincter ani and transversus

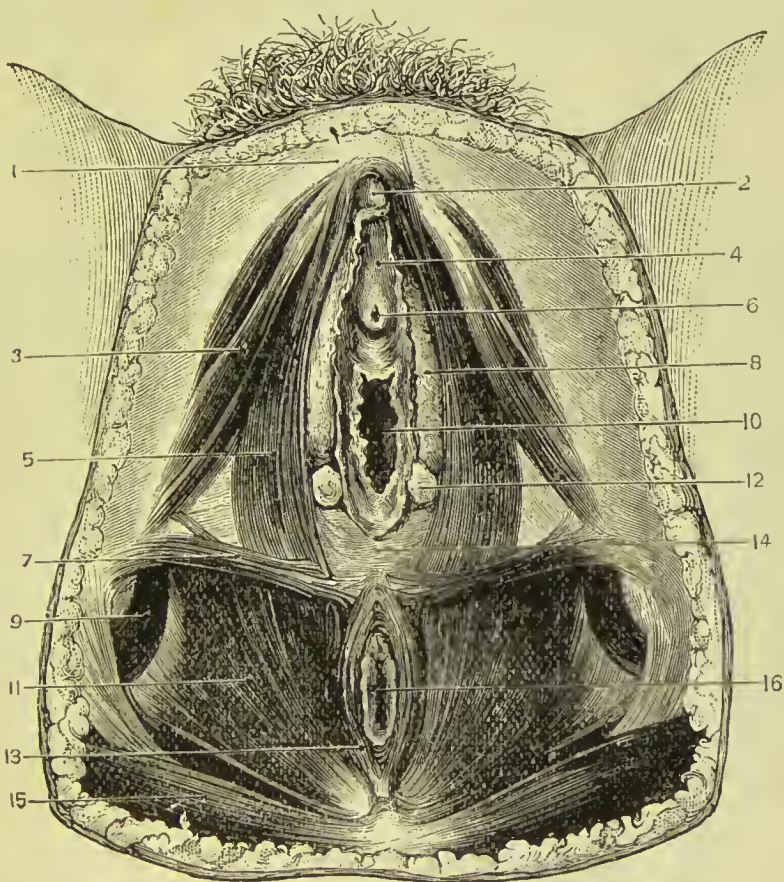


FIG. 217.—Superficial muscles of female perineum. 1. Pubes. 2. Clitoris. 3. Ischio-cavernosus. 4. Vestibulc. 5. Sphincter vaginae. 6. Urethra. 7. Transverse perineal muscle. 8. Bulb of vagina. 9. Obturator externus muscle. 10. Vagina. 11. Levator ani. 12. Gland of Bartholine. 13. Sphincter ani externus. 14. The perineal body. 15. Gluteus maximus. 16. Anus.

perinei; and passes forwards on each side of the entrance of the vagina, to be *inserted* into the corpus cavernosum clitoridis, a fasciculus crossing over this structure so as to compress the dorsal vein of the clitoris.

The **ISCHIO-CAVERNOSUS** (*erector clitoridis*) *arises* from the ramus of the ischium, and is *inserted* on each side into the crus clitoridis. It is in relation by its inner border with the sphincter vaginae.

side from the ramus of the ischium, and *inserted* into the central point of the perineum.

The **COMPRESSOR URETHRÆ** has the same origin and insertion, and exercises the same functions in the female as in the male.

The **SPHINCTER ANI** and **SPHINCTER ANI INTERNUS** surround the lower extremity of the rectum, as in the male.

The **LEVATOR ANI** is *inserted* into the side of the vagina and rectum.

The **COCCYGEUS** is identical with the same muscle in the male.

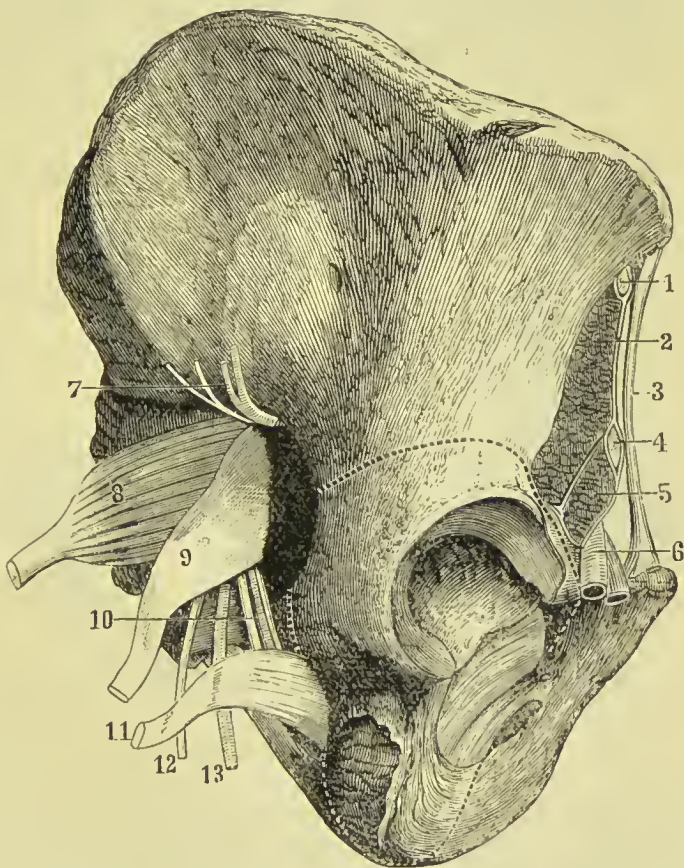
Nerve-supply.—These muscles are supplied by the same nerves as the corresponding muscles of the male perineum.

Actions.—The *bulbo-cavernosi* being continuous at the middle line, and attached at each side to the triangular ligament by means of their posterior fibres, support the bulbous portion of the urethra, and acting forcibly, propel the semen, or the last drops of urine from the canal. The posterior and middle fibres contribute to the erection of the corpus spongiosum, by compressing the veins leaving the bulb; and the anterior fibres assist in the erection of the entire organ by compressing the vena dorsalis, by means of their insertion into the fascia penis. The *ischio-cavernosus* spreads out on the dorsum of the organ into a membranous expansion (*fascia penis*), which compresses the dorsal vein during the action of the muscle, and especially after the erection of the organ has commenced. Erection of the penis results from the retention of the blood in the venous spaces of the corpora cavernosa and corpus spongiosum, that retention being brought about by the compression of the veins of those bodies by the bulbo-cavernosus and ischio-cavernosus muscles. The *transverse* muscles serve to steady the tendinous centre, that the muscles attached to it may obtain a firm point of support. The *compressor urethræ*, taking its fixed point from the ramus of the ischium at each side, can compress the urethra so as to close it completely, after the manner of a sphincter. The *external sphincter*, being a cutaneous muscle, contracts the integument around the anus, and by its attachment to the tendinous centre of the perineum and point of the coccyx, assists the levator ani in giving support to the opening during expulsive efforts. The contraction of this muscle is usually involuntary, but may be made more forcible at will. The *internal sphincter* contracts the extremity of the cylinder of the intestine. The use of the *levator ani* is expressed in its name; it is the antagonist of the diaphragm and abdominal expulsive muscles, and serves to support the rectum and vagina during their expulsive efforts. Yielding to the propulsive action of the abdominal muscles, it enables the outlet of the pelvis to bear a greater force than a resisting structure, and, on the remission of such action, restores the perineum to its original form. Along with the coccygeus it inverts the anal border of the rectum after its protrusion in defæcation. The coccygei muscles restore the coccyx to its natural position, after it has been pressed backwards during defæcation or parturition.

PELVIC FASCIA.

Dissection.—The pelvic fascia may be dissected in three different ways, and viewed from three different aspects; thus, (1) it may be seen from above, by stripping the peritoneum from the wall of the pelvis and the surface of the bladder, and carefully removing the extra-peritoneal fat. Again, (2) it may be seen from below, by removing the fat and the hæmorrhoidal vessels and nerves from the ischio-rectal fossa. After the layer covering the levator ani

FIG. 218.—Side view of pelvis, showing the line of section through the bone to display the pelvic fascia. 1. External cutaneous nerve. 2. Iliacus muscle. 3. Poupart's ligament. 4. Anterior crural nerve. 5. Psoas. 6. Femoral vessels. 7. Gluteal vessels and nerve. 8. Pyri-formis. 9. Great ischiatic nerve. 10. Pudic vessels and nerve, and nerve to the obturator internus. 11. Obturator internus. 12. Lesser ischiatic nerve. 13. Ischiatic artery.



(*anal fascia*) and that lining the wall of the pelvis (*obturator fascia*) have been studied in this way, the levator may be separated from the rectum and turned down, when the fascia which lines its inner surface (*rectal fascia*) will be seen, and there will also be brought into view the ischio-rectal layer passing between the bladder and rectum. (3) To obtain a lateral view of the pelvic fascia a more elaborate dissection is required. The muscles attached to one side of the pubic arch and margin of the obturator foramen are to be completely removed, and also the obturator membrane. The spine

the bone is to be sawn through above and below the acetabulum, by two cuts, the upper running from the upper margin of the obturator foramen to the upper part of the great sciatic notch, and the lower from the lower margin of the obturator foramen through the tuberosity of the ischium into the lesser sciatic notch; the line of section is shown in Fig. 218. The obturator internus may now be detached from adjacent structures, by grasping its tendon and gently drawing it upwards and forwards.

The **pelvic fascia** is a strong fibrous layer situated beneath the peritoneum, forming a covering to the walls of the pelvis, and reflected from its walls on to the viscera. It corresponds in position in the pelvis to the fascia lining the abdominal wall (transversalis fascia), and with that covering the iliacus muscle in the iliac fossa (iliac

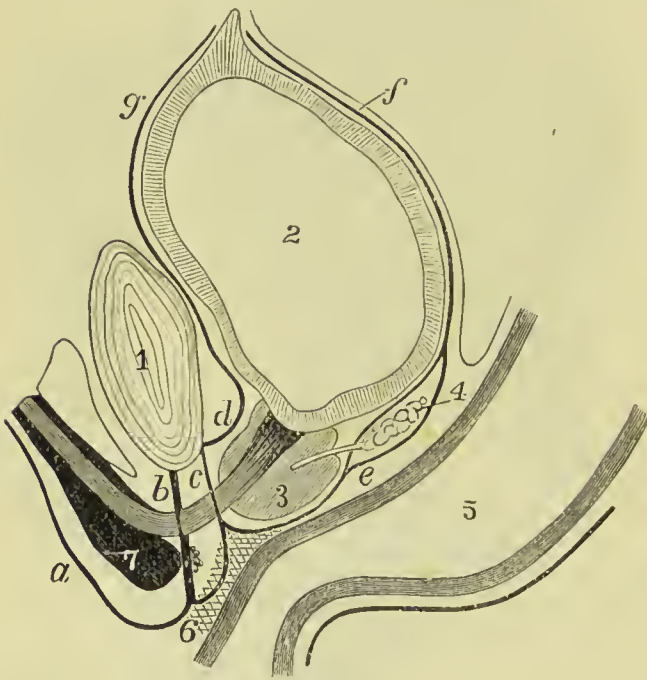


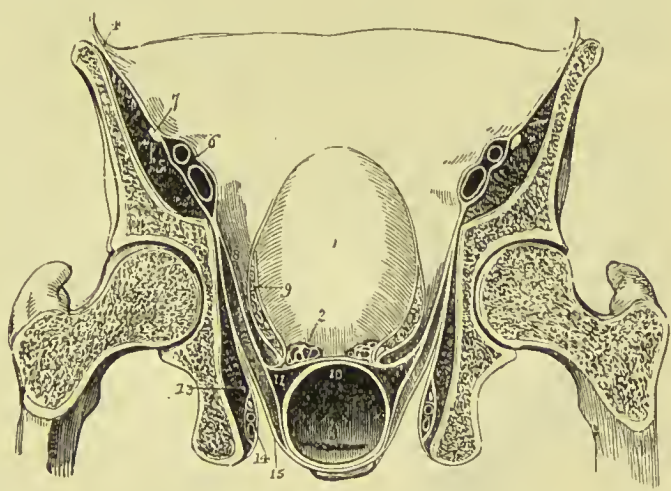
FIG. 219.—Arrangement of pelvic fascia. 1. Symphysis pubis. 2. Bladder. 3. Prostate gland. 4. Vesicula seminalis. 5. Rectum. 6. Perineal body. 7. Bulb of urethra. a. Colles' fascia. b. Anterior layer of triangular ligament. c. Posterior layer of triangular ligament. d. Pubo-prostatic ligament. e. Rectovesical fascia, forming a sheath for the vesicula seminalis. f. Posterior true ligament of bladder. g. Anterior true ligament of bladder.

fascia), but is not at any part directly continuous with the former fascia, and is connected with the latter only for about an inch of the back part of the pectineal line. The pelvic fascia is, for convenience of description, divided into a **parietal** and a **visceral layer**.

The **parietal layer of pelvic fascia** is connected with the back part of the pectineal line, being there continuous with the iliac fascia; it then passes obliquely downwards and forwards, along the upper edge of the obturator internus muscle to the upper margin of the obturator foramen; it here leaves the bone, and passing over the upper edge of the obturator muscle joins the obturator membrane, thus converting the groove on the under surface of the pubic bone into a canal for the obturator vessels and nerve. Again reaching the bone, it descends still lower, being found at the middle line of the

body at the level of the lower border of the pubic symphysis. From this line of attachment, the parietal pelvic fascia passes down over the inner surface of the obturator internus to the ramus of the ischium and pubes and the greater and lesser sciatic ligaments, to all of which structures it is very firmly attached; it is here known as the **obturator fascia**. Where the internal pudic vessels and nerve pass inside the tuberosity of ischium, this fascia forms a canal for them in conjunction with the falciform edge of the great sciatic ligament; this is called **Alcock's canal**. Across the pubic arch the parietal layer is continued to form the so-called **posterior layer of the triangular ligament**; this portion is attached above to the sub-pubic ligament, on each side to the ramus of the pubes, and below is continuous with the triangular ligament (anterior layer). Traced backwards the parietal layer is found to clothe the pyri-

FIG. 220.—Transverse section of the pelvis, seen from behind, showing the arrangement of the pelvic fascia. 1. Bladder. 2. Vesicula seminalis of one side divided. 3. Rectum. 4. Iliac fascia, covering in the iliacus and psoas (5); and forming a sheath for the external iliac vessels (6). 7. Anterior crural nerve excluded from the sheath. 8. Pelvic fascia. 9. Its ascending layer, forming the lateral ligament of the bladder of one side, and a sheath to the vesical plexus of veins. 10. Recto-vesical fascia. 11. Rectal fascia. 12. Levator ani. 13. Obturator internus, covered in by the obturator fascia, which also forms a sheath for the internal pudic vessels and nerve (14). 15. Anal fascia investing the under surface of the levator ani. Figures 14, 15 are placed in the ischio-rectal fossa.

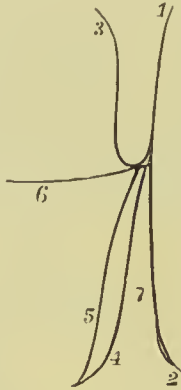


formis muscle (**fascia of the pyriformis**) and sacral plexus, being pierced by the branches of the internal pudic artery; it is here very thin and ill-defined, and, becoming more so as it passes backwards, is lost in the loose connective tissue and fat filling in the interval between the rectum and front of the sacrum.

The **visceral layer of the pelvic fascia** is derived from the inner surface of the parietal layer along a line drawn from the inner surface of the body of the pubes to the spine of the ischium. Along this line the fascia is thickened and shining, hence it is known as the **white line**; it gives attachment to the origin of the levator ani muscle. The visceral layer is reflected backwards from the symphysis pubis on the upper surface of the prostate gland and neck of the bladder. This curved, reflected fascia is called the **an-**

terior true ligament of the bladder, or pubo-prostatic ligament, and as there is a pouch-like depression in the centre, dividing the fascia of one side from that on the other, each side rises up in a little curved ridge, so that there are two anterior ligaments. The space between the two contains, external to the fascia, the dorsal vein of the penis before it enters the prostatic plexus. At the sides

FIG. 221.—Diagram of the layers of pelvic fascia. 1. Pelvic fascia. 2. Obturator. 3. Lateral ligament. 4. Anal. 5. Rectal. 6. Recto-vesical. 7. Ischio-rectal fossa.



of the pelvis the anterior ligaments are continued back into another part of the pelvic fascia, which is reflected inwards towards the bladder from the line of origin of the visceral layer. This begins as a strong white band, and is called the **lateral ligament of the bladder**; it not only reaches the side of the bladder, but is continued over it, although it becomes very thin and is almost lost in the areolar tissue over the apex.

If the lateral ligament be divided near its attachment to the bladder, there will be found beneath it another layer of fascia passing across the pelvis between bladder and rectum; this is the **recto-vesical fascia**. As it crosses the pelvis it gives capsules to the prostate gland and vesiculæ seminales, and forms a sheath which encloses the lower three inches of the rectum; posteriorly, it only extends back as far as the posterior limit of the trigone of the

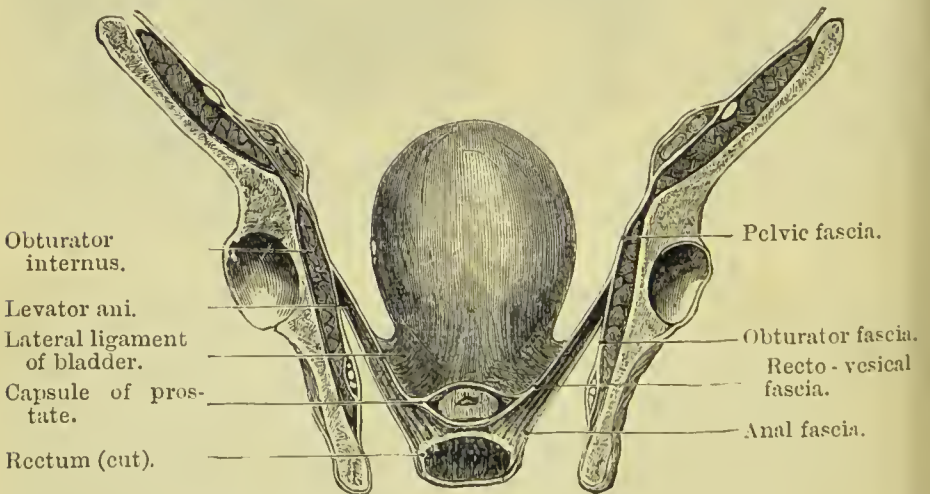


FIG. 222.—Section of pelvis to show the pelvic fascia from the front.

bladder, where it is attached to the anterior extremity of the recto-vesical pouch of peritoneum. Beneath this layer, a thin and ill-defined fascia passes on the inner surface of the levator ani and between that muscle and the side of the rectum; this is named the

rectal fascia ; it is absent at the anterior border of the levator, where that muscle passes beneath the prostate gland. Still another layer of the visceral pelvic fascia is found, clothing the external surface of the levator ani ; it is called the **anal fascia** ; it is continuous at its anterior extremity with the perineal fascia, and by its upper edge with the obturator fascia, and forms the inner boundary of the ischio-rectal fossa.

The veins of the bladder form a large and important plexus (vesical plexus) at the side of the base of that organ, between the lateral ligaments and recto-vesical fascia ; this plexus is continuous with a similar plexus on the prostate (*prostatic plexus*), placed between the pubo-prostatic ligaments and the capsule of the gland.

MUSCLES AND FASCIÆ OF THE UPPER EXTREMITY.

The **superficial fascia** of the upper extremity contains between its layers the superficial veins and lymphatics, and superficial nerves.

The **deep fascia** is thin over the deltoid and pectoralis major muscle, but thick on the dorsum of the scapula, where it binds down the infra-spinatus muscle. It is attached to the clavicle, coracoid process, acromion process, and spine of the scapula, and forms separate sheaths for all the muscles of the scapula and shoulder. In the *upper arm* it is somewhat stronger, receives fibres from the lower border of the tendons of the pectoralis major and latissimus dorsi, as also from the costo-coracoid membrane and deltoid, and forms an anterior and posterior sheath for the muscles lying in front of and behind the humerus. It is attached to the condylar ridges, by means of the **internal** and **external intermuscular septum**, and is inserted inferiorly into the two condyles, the olecranon, and posterior border of the ulna, being continuous between these points with the fascia of the forearm. Besides forming separate sheaths for the muscles, the anterior portion of the brachial fascia gives a sheath likewise to the brachial vessels and median nerve.

The **intermuscular septa** serve to separate the muscles on the back from those on the front of the upper arm, and also give an increased area for the attachment of those muscles. The **external septum** is pierced from behind forwards by the musculo-spiral nerve and superior profunda artery ; the **internal** is pierced from before backwards by the ulnar nerve and inferior profunda and anastomotica arteries.

Axillary Fascia.—A strong layer of deep fascia stretches across the base of the axillary space. It is continuous in front with the fascia which encloses the pectoralis muscle, and slopes downwards and backwards to join the fascia covering the latissimus dorsi ; on its upper surface it is joined by a layer descending from the pectoralis minor and by this means is drawn upwards so as to produce

the hollow of the arm-pit. Near the chest wall it is pierced by numerous lymphatic vessels, and on the outer side it is continuous with the sheath of the axillary vessels and with the deep fascia of the arm.

The deep fascia of the forearm is strong, and at the bend of the elbow is augmented in thickness by a broad band, which is given off from the inner side of the tendon of the biceps (*bicipital fascia*). It is firmly attached to the olecranon process, to the ulna, and to the prominent points about the wrist, forms sheaths for the muscles and vessels, gives origin to some of the fibres of the muscles, and is pierced a little above the wrist by the tendon of the palmaris longus. At the wrist the transverse fibres form the anterior and posterior annular ligament.

The **anterior annular ligament** is a narrow band of fibres attached externally to the scaphoid, and internally to the pisiform bone and tendon of the flexor carpi ulnaris; it is continuous above with the deep fascia of the forearm, and below with the palmar fascia. It is connected with the tendons of the palmaris longus and flexor carpi ulnaris, and gives origin to certain of the muscles of the thumb and little finger. The ulnar vessels and nerve, and the cutaneous branches of the median nerve, lie superficially to it. The ligament is pierced by the tendon of the flexor carpi radialis, and forms with the carpal bones a canal which is lined by synovial membrane, and gives passage to the tendons going to the fingers. The synovial sheath is divided into a large and a small compartment, the former transmitting the flexor sublimis and profundus tendons and the median nerve, the latter enclosing the tendon of the flexor longus pollicis.

The **posterior annular ligament** is an oblique band about half an inch in breadth, extending from the lower end and styloid process of the radius to the cuneiform and pisiform bone at the border of the carpus. It is continuous above with the fascia of the forearm, below with the thin fascia of the dorsum of the hand, and sends processes inwards to be attached to the bones and form sheaths for the extensor tendons. There are six of these sheaths, the first on the radial side giving passage to the extensor ossis metacarpi and extensor primi internodii pollicis; the second, to the extensor carpi radialis longior and brevior; the third, to the extensor secundi internodii; the fourth, to the extensor indicis and extensor communis digitorum; the fifth, which is placed between the two bones, to the extensor minimi digiti; and the sixth, situated on the ulna, to the extensor carpi ulnaris. The tendons in passing through these sheaths are each provided with a synovial bursa.

On the back of the hand there are two fasciæ, superficial and deep. The *superficial dorsal fascia* is thin and covers in the extensor tendons; it is attached laterally to the metacarpal bones of the index and little finger, and is continuous above with the posterior annular ligament. The *deep dorsal fascia* is stretched across the metacarpal spaces and covers in the interossei muscles.

The **palmar fascia** is divided into three portions. A central portion, which occupies the middle of the palm, and two lateral portions, which are thin and enclose the muscles of the borders of the hand, being continuous with the dorsal fascia. The central portion is strong and tendinous: it is narrow at the wrist, where it is attached to the annular ligament and receives the insertion of the tendon of the palmaris longus, and broad over the heads of the metacarpal bones, where it divides into four processes, each of which subdivides to embrace the root of the corresponding finger. These processes are attached at the middle line to the sheath of the tendons, and at the side of each finger to the lateral and transverse ligament. The fascia is strengthened at this point of division by strong fasciculi of transverse fibres; the arched interval caused by the bifurcation of each slip gives passage to the tendons of the flexor muscles, while the greater arches between the fingers transmit the digital vessels and nerves, and lumbricalis muscles. The palmar fascia is intimately adherent to the skin of the palm by numerous fine fibrous bands, and gives attachment by its inner margin to the palmaris brevis muscle.

Beneath the skin of the fingers some tendinous bands are found, which are probably the representatives of the deep fascia. They have been described by Cleland under the name of **phalangeo-cutaneous ligaments**, and pass from the sides of the base of the first phalanx of each finger to the skin on the back of the second, and from the sides of the base of the second phalanx to the deep surface of the skin forming the pulp of the finger.

Anterior Thoracic Region.

Dissection.—Make an incision along the line of the clavicle, from the upper part of the sternum to the acromion process, and thence down the arm as far as the level of the lower border of the latissimus dorsi; a second carried transversely outwards from the base of the ensiform cartilage to the posterior border of the axilla; and connect the two by a third, carried longitudinally along the middle of the sternum. The integument and superficial fascia are to be dissected separately from off the fibres of the muscle, and always in the direction of their course. For this purpose the dissector, if he have the right arm, will commence with the lower angle of the flap; if the left, with the upper angle. He will thus expose the pectoralis major muscle in its whole extent.

Pectoralis major, Pectoralis minor, Subclavius.

The **PECTORALIS MAJOR** arises from the sternal half of the clavicle, from half the sternum its whole length, from the cartilages of all the true ribs, excepting the first and last, and from the aponeurosis of the external oblique muscle of the abdomen. From this extensive origin the fibres converge to be *inserted* by a broad and folded tendon into the external bicipital ridge of the humerus.

The pectoralis major admits of division into three portions, *clavicular*, *sternal*, and *costal*; the two former are separated from each other by a well-marked areolar interspace; the latter is distinguished not only by its origin, but also by forming a fold beneath the sternal portion, and lying behind it at its insertion. At the latter point the three portions are superimposed, the clavicular being in front, the sternal next, the costal behind; the clavicular portion being prolonged at its insertion to the lower extremity of the bicipital ridge, the costal portion to its upper end. The clavicular portion, which arises highest up, is inserted lowest down, and the costal portion which arises lowest is inserted highest on the humerus.

Relations.—By its *external surface* with the fibres of origin of the platysma myoides, mammary gland, superficial fascia, and integument. By its *internal surface*, on the thorax, with the clavicle, sternum, costal cartilages, intercostal muscles, subclavius, pectoralis minor, and serratus magnus; in the axilla, with the axillary vessels and glands. By its *external border* with the deltoid, from which it is separated above by an areolar interspace lodging the cephalic vein and descending branch of the thoracico-acromialis artery. Its *lower border* forms the anterior boundary of the axillary space.

Nerve-supply.—External and internal anterior thoracic branches of the brachial plexus.

Dissection.—The pectoralis major is to be removed by dividing its fibres along the lower border of the clavicle, and then carrying the incision perpendicularly downwards, parallel to the sternum, and at about three inches from its border. Divide some loose areolar tissue, and several small branches of the thoracic arteries, and reflect the muscle outwards. We thus bring into view a region of considerable interest, in the middle of which is situated the pectoralis minor.

The **PECTORALIS MINOR** arises by three digitations from the front, upper border and outer surface of the third, fourth, and fifth ribs near their cartilages, and from the intercostal fascia; and is inserted by a broad tendon into the anterior border and upper surface of the coracoid process of the scapula. It is closely united at its insertion with the coraco-brachialis.

Relations.—By its *anterior surface* with the pectoralis major and superior thoracic vessels and nerves. By its *posterior surface* with the ribs, intercostal muscles, serratus magnus, axillary space, and axillary vessels and nerves. Its *upper border* forms the lower boundary of a triangular space, bounded above by the costo-coracoid membrane, and internally by the ribs; in this space are found the axillary vessels and nerves.

Nerve-supply.—Internal anterior thoracic from the inner cord of the brachial plexus.

Costo-coracoid Membrane.—In order to see the next muscle it is necessary to remove a strong sheet of fascia which covers it in: this is called the costo-coracoid membrane. It is a process of deep cervical fascia which, passing beneath the clavicle, encloses the sub-

clavius, and is stretched across from the cartilage of the first rib to the coracoid process. It becomes thinner as it passes downwards, and may be traced to the upper edge of the pectoralis minor; it encloses that muscle, and from its lower border is continued downwards to join the axillary fascia and the fascia covering the short head of the biceps. Between the subclavius and pectoralis minor it covers in the first part of the axillary artery, and is pierced by the cephalic vein, acromial thoracic artery and vein, superior thoracic artery and anterior thoracic nerves.

The **SUBCLAVIUS** arises by a round tendon from the cartilage and adjacent osseous part of the first rib; it is inserted into the under surface of the clavicle near the coraco-clavicular ligament. It lies in a groove on the inferior aspect of the clavicle.

Relations.—By its *upper surface* with the clavicle. By the *lower* with the subclavian artery and vein and brachial plexus, which separate it from the first rib. In *front* with the pectoralis major, the costo-coracoid membrane being interposed.

Nerve-supply.—A branch from the fifth and sixth cervical.

Actions.—The pectoralis major draws the arm across the thorax, while its upper fibres assist the upper part of the trapezius in raising the shoulder, as in supporting weights. The lower fibres depress the shoulder with the aid of the latissimus dorsi. Taking its fixed point from the shoulder, the pectoralis major assists the pectoralis minor, subclavius, and serratus magnus in drawing up and expanding the chest. The pectoralis minor, in addition to this action, draws the coracoid process downwards and forwards, and rotates the scapula on the chest wall in such a manner as to direct the glenoid cavity downwards. The subclavius draws the clavicle downwards and forwards, and thereby assists in steadying the shoulder. All the muscles of this group are agents in forced inspiration, but are incapable of acting in that capacity until the shoulders are fixed.

Lateral Thoracic Region.

Serratus Magnus.

The **SERRATUS MAGNUS** (*serratus*, indented like the edge of a saw), broad, thin, and trapezoid in shape, arises by nine fleshy serrations from the eight upper ribs (two of the serrations being attached to the second rib), and extends backwards upon the side of the chest, to be inserted into the whole length of the base of the scapula, its anterior aspect. In structure, the muscle is composed of three portions: *superior*, formed by the first and second serrations and inserted into the inner surface of the superior angle of the scapula; *middle*, composed of the third and fourth serrations and inserted into the greater part of the posterior border; *inferior*, consisting of the last five serrations: these latter interdigitate with the obliquus externus and form a thick muscular fasciculus, which is inserted into the

Relations.—By its *superficial surface* with the pectoralis major and minor, subscapularis, latissimus dorsi, and axillary vessels and nerves. By its *deep surface* with the ribs and intercostal muscles, to which it is connected by loose areolar tissue.

Nerve-supply.—Posterior thoracic nerve, from the fifth and sixth cervical.

Actions.—The serratus magnus is the great muscle of forced inspiration, raising the ribs when the shoulders are fixed, and thereby increasing the cavity of the chest. By drawing the scapula forwards it allows of the further outstretching of the arm after it has been raised, as in the action called extension in fencing. Along with the trapezius it rotates the scapula so as to project its inferior angle, and thus assists in raising the arm above the level of the shoulder. It is also of service in all movements of pushing.

Anterior Scapular Region.

Subscapularis.

The **SUBSCAPULARIS** arises from the whole of the ventral surface of the scapula excepting the superior and inferior angle and posterior border, and terminates by a broad and thick tendon, which is *inserted* into the lesser tuberosity of the humerus, and by muscular fibres into the surface of bone immediately below that process. In structure the subscapularis is composed of eight or ten fasciculi, four or five of which arise from one side of as many aponeurotic processes attached to the ridges of the venter of the scapula; and four or five proceed from the other side of the aponeurotic processes and from the surface of bone intervening between them. Its tendon forms part of the capsule of the shoulder-joint, glides over a large bursa which separates it from the base of the coracoid process, and is lined by a prolongation of the synovial membrane of the articulation.

Relations.—By its *anterior surface* with the serratus magnus, coraco-brachialis, and axillary vessels and nerves. By its *posterior surface* with the scapula and shoulder-joint.

Nerve-supply.—The short and middle subscapular nerves, branches from the posterior cord of the brachial plexus.

Action.—It rotates the head of the humerus inwards, and is a powerful defence to the joint. When the arm is raised, it draws the humerus downwards.

Posterior Scapular Region.

Supra-spinatus,
Infra-spinatus,

Teres minor,
Teres major.

The **SUPRA-SPINATUS** muscle (*supra*, above; *spina*, the spine) arises from the supra-spinous fossa, spine of the scapula, and proper investing fascia; and is *inserted* into the uppermost depression on

the greater tuberosity of the humerus, the tendon being united near its attachment with that of the infra-spinatus. The tendon cannot be seen until the acromion process is removed.

Relations.—By its *upper surface* with the trapezius, clavicle, acromion, and coraco-acromial ligament. From the trapezius it is separated by a strong fascia. By its *lower surface* with the supra-spinous fossa, supra-scapular vessels and nerve, origin of the omohyoid muscle, and upper part of the shoulder-joint.

Nerve-supply.—The supra-scapular nerve, a branch from the fifth and sixth cervical.

The **INFRA-SPINATUS** (*infra*, beneath; *spina*, the spine) is covered in by a layer of tendinous fascia, which must be removed before the fibres of the muscle can be seen, the deltoid muscle having been previously turned down from its scapular origin. It *arises* from the whole of the infra-spinous fossa, excepting the inferior angle, axillary border, and a small portion near the neck of the bone: from the spine of the scapula, and from the investing fascia; it is *inserted* into the middle depression of the greater tuberosity of the humerus, its tendon being blended with that of the supra-spinatus above and the teres minor below.

Relations.—By its *posterior surface* with the deltoid, latissimus dorsi, trapezius, and integument. By its *anterior surface* with the infra-spinous fossa, supra-scapular and dorsal scapular vessels, and shoulder-joint. By its *upper border* it is in relation with the spine of the scapula, and by the *lower* with the teres major and minor, being closely united with the latter.

Nerve-supply.—The supra-scapular nerve.

The **TERES MINOR** (*teres*, round) *arises* from the posterior surface of the axillary border of the scapula for about the middle third of its extent; it is connected with the lower border of the preceding muscle, and is *inserted* into the inferior depression of the greater tuberosity of the humerus. The tendons of the three preceding muscles are in immediate contact with the shoulder-joint.

Relations.—By its *posterior surface* with the deltoid and integument. By its *anterior surface* with the inferior border and part of the dorsum of the scapula, dorsalis scapulæ vessels, scapular head of the triceps, and shoulder-joint. By its *upper border* with the infra-spinatus; by the *lower* with the teres major, and long head of the triceps.

Nerve-supply.—A branch of the circumflex nerve. This branch is distinguished by a ganglionic enlargement, just before it enters the muscle.

The **TERES MAJOR** muscle *arises* from the dorsal surface of the inferior angle of the scapula, and from its axillary border; it is *inserted* into the internal bicipital ridge of the humerus, immediately behind the tendon of the latissimus dorsi. At its origin this muscle is covered by the latissimus dorsi, but the latter shortly afterwards curves around its lower border and becomes placed in front; the two tendons at their insertion, one lying behind the other, are separated by a bursa.

Relations.—By its *posterior surface* with the latissimus dorsi, scapular head of the triceps, and integument. By its *anterior surface* with the subscapularis, latissimus dorsi, coraco-brachialis, short head of the biceps, axillary vessels, and nerves of the brachial plexus. By its *upper border* it is in relation with the teres minor, from which it is separated by the scapular head of the triceps; and, by the *lower forms*, with the latissimus dorsi, the lower and posterior border of the axilla.

Nerve-supply.—Middle and long subscapular branches derived from the posterior cord of the brachial plexus.

Triangular and Quadrangular Spaces.—A large triangular space exists between the two teres muscles, which is divided into two minor spaces by the long head of the triceps. The smaller of the two spaces is placed posteriorly; it is triangular in form, being bounded above by the teres minor, below by the teres major, and

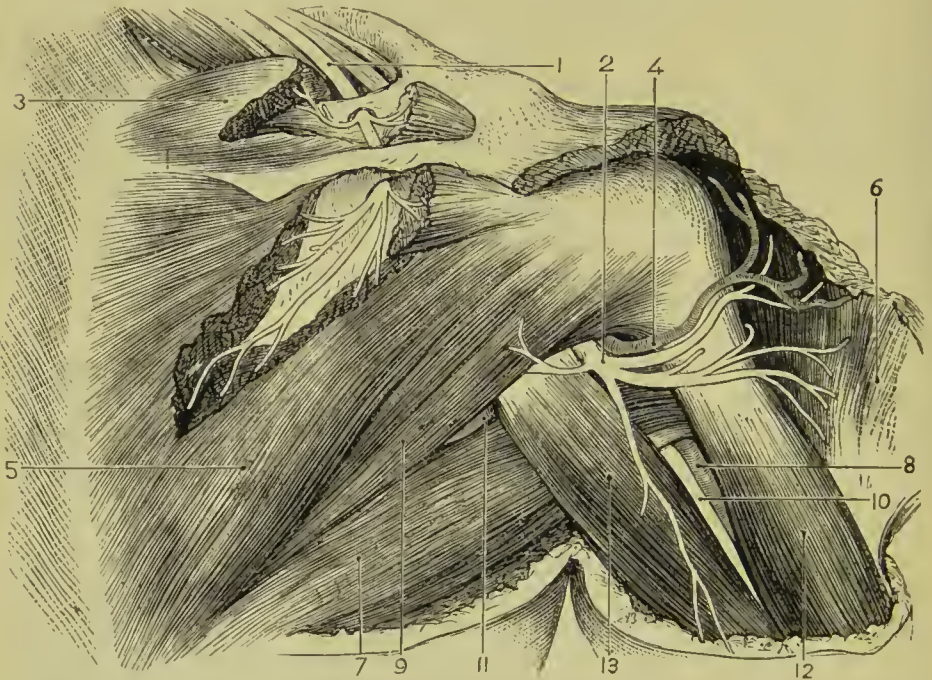


FIG. 223.—Scapular muscles, vessels, and nerves. 1. Supra-scapular nerve. 2. Circumflex nerve. 3. Supra-spinatus. 4. Posterior circumflex artery. 5. Infra-spinatus. 6. Deltoid (reflected). 7. Teres major and latissimus. 8. Brachial artery. 9. Teres minor. 10. Muscular spiral nerve. 11. Dorsalis scapulae artery. 12. Triceps (outer head). 13. Triceps (long head).

in front by the long head of the triceps. It gives passage to the dorsalis scapulae vessels. The anterior space is quadrangular, and is bounded above by the teres minor, below by the teres major, in front by the humerus, and behind by the long head of the triceps; it transmits the posterior circumflex vessels and circumflex nerve.

Actions.—The supra-spinatus raises the arm from the side; but feebly, from the disadvantageous direction of its force. The infra-

pinatus and teres minor are rotators of the head of the humerus outwards. The most important use of these three muscles is the protection of the joint, and defence against displacement of the head of the humerus, in which action they co-operate with the subscapularis. The teres major combines with the latissimus dorsi in rotating the arm inwards, and at the same time carrying it towards the side, and somewhat backwards.

Acromial Region.

Deltoid.

The **DELTOID** (Δ , delta ; εἶδος, like) is the large triangular muscle which forms the convexity of the shoulder ; it *arises* from the outer third of the clavicle, from the acromion process, and from the whole length of the lower border of the spine of the scapula. The fibres from this broad origin converge to the middle of the outer side of the humerus, where they are *inserted* into a rough triangular elevation. In structure the deltoid is composed of seven fasciculi, four of which are fleshy above and tendinous below ; and three tendinous above and fleshy below. To bring the muscles beneath it into view, the deltoid must be cut away from its origin, and turned down ; in so doing, a large bursa will be seen between its under surface and the head of the humerus.

Relations.—By its *superficial surface* with the deep fascia, a few fibres of the platysma myoides, the superficial fascia, and integument. By its *deep surface* with the shoulder-joint (from which it is separated by a thin tendinous fascia and a synovial bursa), the coraco-acromial ligament, coracoid process, pectoralis minor, coracobrachialis, both heads of the biceps, tendon of the pectoralis major, tendon of the supra-spinatus, infra-spinatus, teres minor, teres major, scapular and external heads of the triceps, anterior and posterior circumflex vessels, and humerus. By its *anterior border* with the external border of the pectoralis major, from which it is separated by an interspace, lodging the cephalic vein and descending branch of the thoracico-acromialis artery. Its *posterior border* is thin and tendinous above, where it is connected with the aponeurotic covering of the infra-spinatus muscle, and thick below.

Nerve-supply.—The circumflex nerve, from the posterior cord of the brachial plexus.

Actions.—The deltoid is the elevator muscle of the arm in a direct line, and, by means of its extensive origin, it can carry the arm forwards or backwards so as to range with the hand a considerable segment of a large circle. The arm, raised by the deltoid, is an illustration of a lever of the *third* power, so common in the animal machine, by which velocity is gained at the expense of power. In this lever, the weight (hand) is at one extremity, the fulcrum (glenoid cavity) at the opposite end, the power (insertion of the muscle) between the two, but nearer to the fulcrum than to the weight. When the scapula is fixed the deltoid can only raise

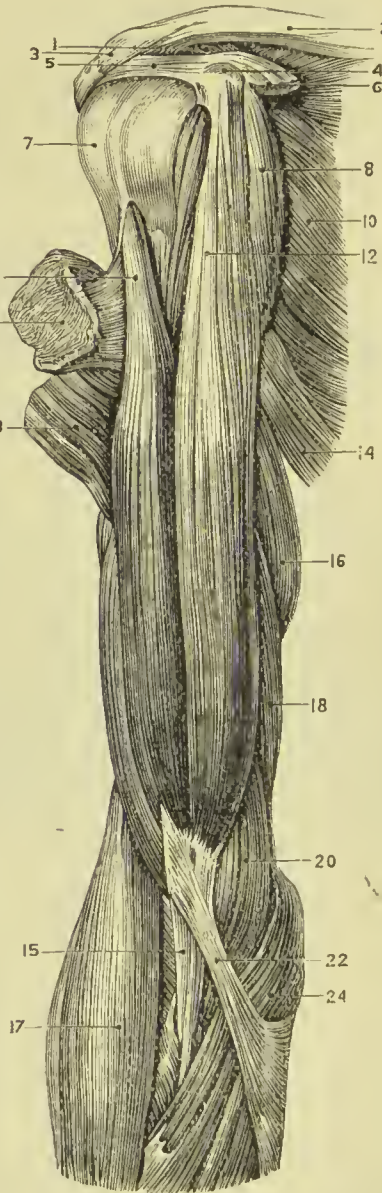
the arm to a level with the shoulder, all elevation above that level depending upon its rotation, the glenoid cavity being in this way directed upwards and outwards (see page 200).

Anterior Humeral Region.

Coraco-brachialis, Biceps brachii, Brachialis anticus.

Dissection.—These muscles are exposed on the removal of the integument and fascia from the anterior half of the upper arm, and the clearing away of the areolar tissue.

FIG. 224.—Muscles of the front of the upper arm.
 1. Coraco-clavicular ligament.
 2. Clavicle. 3. Acromio-clavicular ligament.
 4. Coracoid process. 5. Coraco-acromial ligament. 6. Pectoralis minor.
 7. Head of humerus enclosed in capsule of shoulder-joint.
 8. Coraco-brachialis. 9. Long head of triceps.
 10. Subscapularis. 11. Pectoralis major (cut). 12. Short head of biceps.
 13. Deltoid (cut). 14. Latissimus dorsi and teres major combined. 15. Tendon of biceps.
 16. Long head of triceps. 17. Supinator longus. 18. Inner head of triceps.
 20. Brachialis anticus. 22. Bicipital fascia. 24. Pronator radii teres.



The **CORACO-BRACHIALIS**, a name suggestive of its points of origin and insertion, *arises* from the apex of the coracoid process in common with the short head of the biceps; and is *inserted* into a smooth impression on the inner side of the middle of the humerus.

Relations.—By its *anterior surface* with the deltoid and pectoralis major. By its *posterior surface* with the shoulder-joint, humerus, subscapularis, teres major, latissimus dorsi, short head of the triceps, and anterior circumflex vessels. By its *internal border* with the axillary and brachial vessels and nerves, particularly with the median and musculo-cutaneous nerve, by the latter

of which it is pierced. By the *external border* with the short head of the biceps and brachialis anticus.

Nerve-supply.—The external cutaneous nerve which pierces it about its middle.

The **BICEPS BRACHII** (*bis*—*caput*, two heads; flexor cubiti) *arises* by two tendons; one, the *short head*, from the coracoid process in common with the coraco-brachialis; the other, the *long head*, from the upper part of the glenoid cavity, where it is continuous with the glenoid ligament. The muscle is *inserted* by a flattened tendon into the back part of the tubercle of the radius. The long head, a long slender tendon, passes through the capsular ligament of the shoulder-joint enclosed in a sheath of the synovial membrane; after leaving the cavity of the joint, it is lodged in the deep groove that separates the two tuberosities of the humerus, the bicipital groove. A small synovial bursa is interposed between the tendon of insertion and the tubercle of the radius. At the *bend* of the elbow, the tendon of the biceps gives off from its inner side a tendinous band, which spreads out to form a sheet of fascia called the *semilunar* or *bicipital fascia*; it protects the brachial artery, and is continuous with the fascia of the forearm.

The biceps occasionally has a third head, connected with the humerus; this most frequently arises from the shaft of that bone in connection with the insertion of the coraco-brachialis and origin of the brachialis anticus, and is inserted into the back part of the bicipital fascia and inferior tendon of the muscle.

Relations.—By its *anterior surface* with the deltoid, pectoralis major, superficial and deep fascia, and integument. By its *posterior surface* the short head rests on the subscapularis, from which it is separated by a bursa. In the rest of its extent the muscle is in relation with the humerus, teres major, latissimus dorsi, and brachialis anticus; from the latter it is separated by the musculocutaneous nerve. By its *inner border* with the coraco-brachialis, brachial artery and veins, and median nerve; the brachial vessels crossing its tendon at the bend of the elbow. By its *outer border* with the deltoid and supinator longus.

Nerve-supply.—The external or muscular cutaneous nerve.

The **BRACHIALIS ANTICUS** is a broad muscle covering the whole of the anterior surface of the lower part of the humerus; it *arises* by two fleshy serrations, which embrace the insertion of the deltoid, from the anterior surface of the humerus, and from the inner intermuscular septum. Its fibres converge to be *inserted* into the base of the coronoid process of the ulna, between two processes of the flexor profundus digitorum.

Relations.—By its *anterior surface* with the biceps, musculocutaneous nerve, brachial artery and veins, and median nerve. By its *posterior surface* with the humerus, anterior ligament of the elbow-joint, and intermuscular septum. The latter separates it from the triceps. By its *external border* with the supinator longus, extensor carpi radialis longior, musculo-spiral nerve, and recurrent radial artery. By its *internal border* with the intermuscular septum (which separates it from the triceps and ulnar nerve), and with the pronator radii teres.

Nerve-supply.—The musculo-cutaneous and musculo-spiral nerves.

Actions.—The coraco-brachialis draws the humerus inwards, and assists in flexing it upon the scapula. The biceps is one of the chief flexors of the elbow-joint; it is also an important supinator, this action resulting from the attachment of the tendon to the *back* part of the tubercle of the radius. It makes tense the fascia of the forearm, and so assists the muscles connected with the fascia. Its long tendon passing through the shoulder-joint acts as a ligament, keeping the head of the humerus in its place, and the same tendon, where it lies in the bicipital groove, limits the outward rotation of the humerus in supination, by pressing against the lesser tuberosity. Lastly, the biceps acts as an extensor of the arm at the shoulder, assisting the deltoid. The brachialis anticus is a powerful flexor of the elbow, and in some measure supplies the place of an anterior ligament to that joint.



FIG. 225.—Posterior view of the upper arm, and triceps muscle.
1. External head. 2. Long or scapular head. 3. Internal or short head. 4. Olecranon process of ulna. 5. Radius. 6. Capsular ligament of the shoulder-joint.

part of the groove. The *internal* head is attached to the inner margin of the humerus below the insertion of the teres major, to the whole of the posterior surface of the bone below the musculo-spiral groove to the back of the internal condyle and posterior aspect of both external and internal intermuscular septum. The *middle* or *long* head arises by a tendon from the ridge below the glenoid cavity of the scapula and the adjoining rough portion

Posterior Humeral Region.

Triceps brachii.

Dissection.—Remove the integument and fascia from the posterior aspect of the upper arm.

The **TRICEPS BRACHII** (having three heads; triceps extensor cubiti) arises by three heads: external, middle, and internal.

The *external* head arises from the outer part of the posterior surface of the humerus in a line extending from the insertion of the teres minor to the musculo-spiral groove, and from a tendinous arch derived from the upper part of the external intermuscular septum and bridging over the upper

of that bone. The three heads, passing downwards in different directions, unite to form a broad muscle, which is *inserted* into the olecranon process of the ulna, and sends an expansion to the deep fascia of the forearm. A small bursa is situated between the tendon of the muscle and the upper part of the olecranon.

Beneath the lower part of the triceps are two small fasciculi *arising* from the humerus, and descending one on either side of the fossa of the olecranon to be *inserted* into the capsule of the elbow-joint. These have been named **sub-anconeus**; they are analogous to the sub-crureus.

Relations.—By its *posterior surface* with the deep and superficial fascia and integument. By its *anterior surface* with the superior profunda artery, musculo-spiral nerve, humerus, intermuscular septa which separate it from the brachialis anticus, and elbow-joint. The *scapular head* is in relation posteriorly with the deltoid and teres minor; anteriorly with the subscapularis, teres major, and latissimus dorsi; and externally with the posterior circumflex vessels and nerve.

Nerve-supply.—The musculo-spiral nerve.

Actions.—The triceps brachii is an extensor of the forearm. When the arm has been raised at the shoulder, the long head assists the teres major and latissimus dorsi, in drawing it down again to the side of the chest.

Anterior Brachial Region.

Superficial Layer.

Pronator radii teres,
Flexor carpi radialis,
Palmaris longus,
Flexor sublimis digitorum,
Flexor carpi ulnaris.

Dissection.—These muscles are brought into view by making an incision through the integument along the middle line of the forearm, crossing each extremity by a transverse incision, and turning aside the flaps. The superficial and deep fascia are then to be removed.

The **PRONATOR RADII TERES** *arises* by two heads: one from the anterior aspect of the inner condyle of the humerus, fascia of the forearm, and intermuscular septum; the other from the inner side of the coronoid process of the ulna; the median nerve passing between them. Its tendon is flat, and is *inserted* into the middle of the outer side of the shaft of the radius. The two heads of this muscle are best examined by cutting through that which rises from the inner condyle, and turning it aside. The second head will then be seen with the median nerve lying across it.

Relations.—By its *anterior surface* with the deep fascia of the

radial artery and veins, and radial nerve. By its *posterior surface* with the brachialis anticus, flexor sublimis digitorum, ulnar artery and veins, and the median nerve after it has passed between the two heads of the muscle. By its *upper border* it forms the inner boundary of the triangular space, in which the termination of the

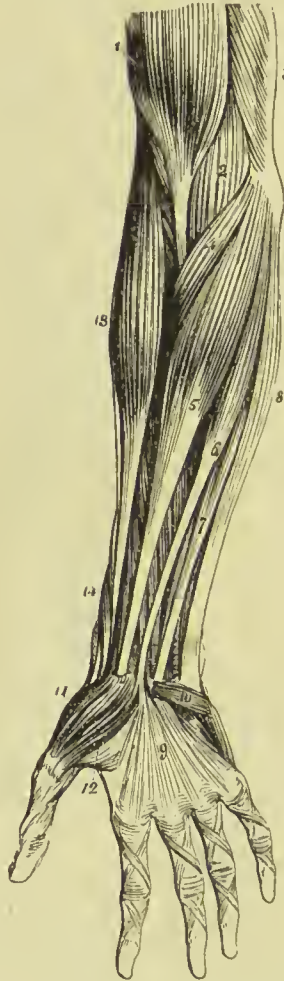brachial artery is situated. By its *lower border* it is in relation with the flexor carpi radialis.

Nerve-supply.—Median nerve.

The **FLEXOR CARPI RADIALIS** arises from the inner condyle, deep fascia, and intermuscular septa. Its tendon perforates the anterior annular ligament, and passes through a groove in the trapezium bone, to be *inserted* into the base of the metacarpal bones of the index and middle fingers. The groove is converted into a canal by a fibrous band, and is lined by a synovial membrane.

Relations.—By its *anterior surface* with the deep fascia of the forearm, and at the wrist with the tendinous canal through which its tendon passes. By its *posterior surface* with the flexor sublimis digitorum, flexor longus pollicis, wrist-joint, and groove in the trapezium bone. By its

FIG. 226. — Superficial layer of muscles of the forearm. 1. Biceps, with its tendon. 2. Brachialis anticus, seen beneath biceps. 3. Part of triceps. 4. Pronator radii teres. 5. Flexor carpi radialis. 6. Palmaris longus. 7. One of the fasciculi of the flexor sublimis digitorum; the rest of the muscle is seen beneath the tendons of the palmaris longus and flexor carpi radialis. 8. Flexor carpi ulnaris. 9. Palmar fascia. 10. Palmaris brevis. 11. Abductor pollicis. 12. Flexor brevis pollicis; the leading line crosses part of the adductor pollicis. 13. Supinator longus. 14. Extensor ossis metacarpi and extensor primi internodii pollicis, curving around the lower border of the forearm.



outer border with the pronator radii teres, radial artery and veins. By its *inner border* with the palmaris longus.

Nerve-supply.—Median nerve.

The **PALMARIS LONGUS** is a small muscle which arises from the inner condyle, deep fascia, and intermuscular septa. Its tendon pierces the deep fascia and crosses the annular ligament to be *inserted* into the palmar fascia. This muscle is often absent.

Relations.—By its *anterior surface* with the deep fascia of the forearm. By the *posterior surface* with the flexor sublimis digitorum; to the *external side* with the flexor carpi radialis; and to the *internal side* with the flexor carpi ulnaris.

Nerve-supply.—Median nerve.

Dissection.—Cut the flexor carpi radialis and palmaris longus from their origin, in order to obtain a good view of the whole extent of origin of the flexor sublimis digitorum.

The **FLEXOR SUBLIMIS DIGITORUM** (*perforatus*) arises from the inner condyle, intermuscular septa, internal lateral ligament, coronoid process of the ulna, and oblique line of the radius. The median nerve and ulnar artery pass between its heads. It divides into four tendons, which pass beneath the annular ligament, and are inserted into the sides of the second phalanges of the fingers about their middle, splitting at their termination to give passage to the tendons of the deep flexor; hence its designation, *perforatus*. The tendons pass beneath the annular ligament arranged in pairs, those for the middle and ring fingers being placed superficially, and those for the index and little fingers beneath them. At the bases of the first phalanges the flexor tendons enter small canals which are in part formed by the grooved surfaces of the bones, and in part by fibrous arches thrown across the tendons; these are called *thecæ* (*θήκα*, a case). In

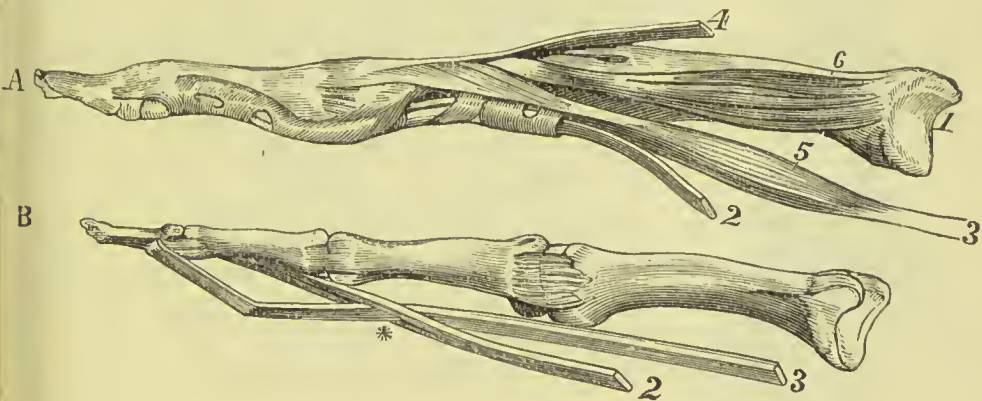


FIG. 227.—Bones of two fingers with the insertion of the tendons. In A the tendons of the flexor muscles are bound to the bone by the fibrous sheath. In B the sheath has been removed, as well as the vincula accessoria. 1. Metacarpal bone. 2. Tendon of the flexor sublimis. 3. Tendon of the flexor profundus. * Perforation of the sublimis by the profundus tendon. 4. Tendon of the extensor communis digitorum. 5. Lumbricalis muscle. 6. One of the interossei muscles.

the thecæ of the fingers several small tendinous fasciculi are found, which pass from the phalanges to the edges of the tendons; these have been termed the *vincula accessoria*. One of these connects the deep tendon with the bone before it pierces the superficial tendon; another connects the superficial and deep tendon after the latter has passed through the former; and a third connects the deep tendon with the head of the second phalanx. This last consists largely of elastic tissue, and may assist in reinstating the tendon after flexion of the finger.

Relations.—In the forearm: by its *anterior surface* with the pronator radii teres, flexor carpi radialis, palmaris longus, flexor carpi ulnaris, and the deep fascia. By its *posterior surface* with the flexor profundus digitorum.

and nerve, and median nerve. This muscle frequently sends a fasciculus to the flexor longus pollicis or flexor profundus. In the hand: its tendons, after passing beneath the annular ligament, are in relation *superficially* with the superficial palmar arch, and palmar fascia; and *deeply* with the tendons of the deep flexor and lumbricales.

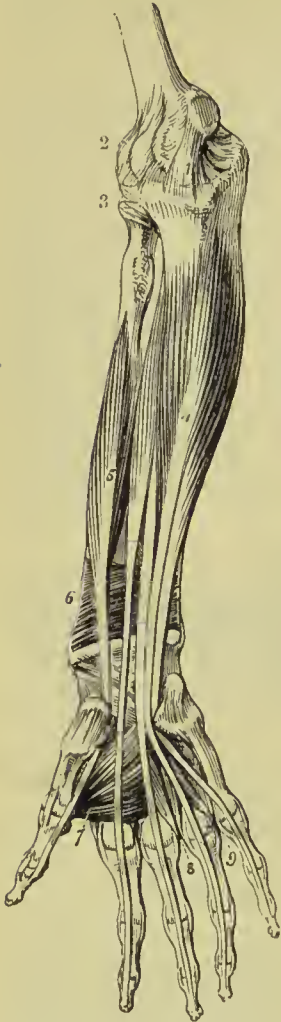

FIG. 228.—Deep layer of muscles of the forearm.
 1. Internal lateral ligament of the elbow-joint.
 2. Anterior ligament. 3. Orbicular ligament of the head of the radius.
 4. Flexor profundus digitorum. 5. Flexor longus pollicis. 6. Pronator quadratus. 7. Adductor pollicis. 8. Dorsal interosseous of the middle, and palmar interosseous of the ring finger.
 9. Dorsal interosseous muscle of the ring finger, and palmar interosseous of the little finger.

the forearm it divides into four tendons which pass beneath the

Nerve-supply.—Median nerve.

The **FLEXOR CARPI ULNARIS** arises by two heads, one from the inner condyle and intermuscular septa, the other from the olecranon and by means of a strong aponeurosis from two-thirds of the posterior border of the ulna. Its tendon is inserted into the pisiform bone, anterior annular ligament, and base of the metacarpal bone of the little finger.

Relations.—By its *anterior surface* with the deep fascia of the forearm, with which it is closely united superiorly. By its *posterior surface* with the flexor sublimis digitorum, flexor profundus, pronator quadratus, ulnar artery, veins, and nerve. By its *radial border* with the palmaris longus, and in the lower third of the forearm, the ulnar vessels and nerve. The ulnar nerve, and the posterior ulnar recurrent artery, pass between its two heads of origin.

Nerve-supply.—Ulnar nerve.

Deep Layer.

Flexor profundus digitorum,
 Flexor longus pollicis,
 Pronator quadratus.

Dissection.—This group is brought into view by removing the flexor sublimis, and drawing aside the pronator radii teres.

The **FLEXOR PROFUNDUS DIGITORUM** (perforans) arises from the upper two-thirds of the ulna, its anterior and inner surface and posterior border, from the inner side of the olecranon, where it is connected with the aponeurotic expansion of the flexor carpi ulnaris, and from the ulnar half of the interosseous membrane. At the middle of

annular ligament, and along the fingers, between the two slips of the tendons of the flexor sublimis, to be *inserted* into the base of the last phalanges. In the groove of the carpus the tendons are enclosed in a synovial membrane, and the three outer tendons communicate with each other by means of small slips, the tendon of the index-finger remaining distinct. In the hand, the tendons give origin to the lumbricales muscles, and on the second phalanges are retained in position by two little tendinous slips, the vincula accessoria.

Relations.—In the forearm: by its *anterior surface* with the flexor sublimis digitorum, flexor carpi ulnaris, median nerve, and ulnar artery, veins, and nerve. By its *posterior surface* with the ulna, interosseous membrane, pronator quadratus, and wrist-joint. By its *radial border* with the flexor longus pollicis, the anterior interosseous artery and nerve being interposed. By its *ulnar border* with the flexor carpi ulnaris. In the hand: its tendons are in relation *superficially* with the tendons of the superficial flexor; and *deeply* with the interossei, adductor pollicis, and deep palmar arch.

Nerve-supply.—Median and ulnar nerves.

The **FLEXOR LONGUS POLLICIS** arises from the anterior surface of the shaft of the radius for two-thirds of its extent, and from

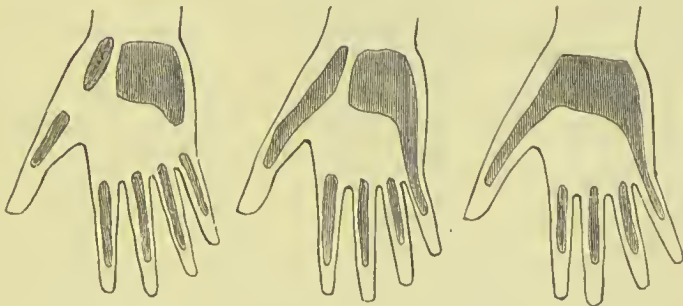


FIG. 229.—Varieties in the arrangement of the synovial sheaths of the wrist and fingers. The middle one is the most frequent.

one-half the interosseous membrane. Its tendon passes beneath the annular ligament to be *inserted* into the base of the last phalanx of the thumb.

Relations.—By its *anterior surface* with the flexor sublimis digitorum, flexor carpi radialis, supinator longus, and radial artery and veins. By its *posterior surface* with the radius, interosseous membrane, pronator quadratus, and wrist-joint. By its *ulnar border*, it is separated from the flexor profundus digitorum by the anterior interosseous artery and nerve. In the hand: after passing beneath the annular ligament, it is lodged in the interspace between the two portions of the flexor brevis pollicis, and afterwards in the tendinous theca of the phalanx.

Synovial Sheaths.—Beneath the anterior annular ligament two synovial sheaths are found; the larger of these surrounds the tendons of flexor sublimis and flexor profundus digitorum, and

extends from a little above the annular ligament to about the middle of the palm. The smaller sheath surrounds the flexor longus pollicis, and extends from above the annular ligament to the base of the second phalanx of the thumb. Between the two sheaths the median nerve lies, or it may occupy the larger sheath along with the flexor tendons. Each of the fingers has a digital synovial sheath commencing above the metacarpo-phalangeal joint and terminating at the base of the last phalanx; the digital sheath of the little finger generally communicates with the common sheath beneath the annular ligament. The commonest variations in the synovial sheaths are shown in Fig. 229.

Nerve-supply.—Anterior interosseous, a branch of the median.

Dissection.—If the tendons of the last two muscles be drawn aside or divided, the third muscle of this group will be brought into view, lying across the lower part of the two bones.

The **PRONATOR QUADRATUS** arises from the anterior and inner side of the ulna, and is inserted into the front of the radius. This muscle occupies about the lower fourth of the two bones, is broad at its origin, and narrower at its insertion.

Relations.—By its *anterior surface* with the tendons of the supinator longus, flexor carpi radialis, flexor longus pollicis, flexor profundus digitorum, and flexor carpi ulnaris, radial artery and veins, and ulnar artery, veins, and nerve. By its *posterior surface* with the radius, ulna, and interosseous membrane.

Nerve-supply.—Anterior interosseous, a branch of the median.

Actions.—The pronator radii teres and pronator quadratus rotate the radius upon the ulna, and render the hand prone. The remaining muscles are flexors: two flexors of the wrist, flexor carpi radialis and ulnaris; two of the fingers, flexor sublimis and profundus, the former flexing the second phalanges, the latter the last; one flexor of the last phalanx of the thumb, flexor longus pollicis. The palmaris longus is primarily a tensor of the palmar fascia, and secondly a flexor of the wrist and forearm. The muscles which arise from the internal condyle of the humerus act as flexors of the elbow-joint, those which pass to the radial side of the hand and arm being more effective in this respect than the muscles on the ulnar side. The flexor carpi ulnaris is an effective pronator in the early part of its action, and when the hand is placed in the position of supination. The superficial and deep flexors of the fingers assist in producing flexion of the wrist, after the flexion of the fingers is completed, or when the fingers are fixed by being pressed against an opposing surface.

Posterior Brachial Region.

Superficial Layer.

Supinator longus,
Extensor carpi radialis longior,
Extensor carpi radialis brevior,
Extensor communis digitorum,

Extensor minimi digiti,
Extensor carpi ulnaris,
Anconeus.

Dissection.—The integument is to be divided and turned aside, and the fascia removed in the same manner as for the anterior brachial region.

The **SUPINATOR LONGUS** is placed along the radial border of the forearm. It *arises* from the upper two-thirds of the external supracondylar ridge of the humerus, reaching as high as the musculo-spiral groove, and from the external intermuscular septum, passes forward to the anterior aspect of the elbow-joint, and ends in a long flat tendon, which descends the forearm to be *inserted* into the outer side of the base of the styloid process of the radius.

Relations.—By its *superficial surface* with the extensor ossis metacarpi pollicis, extensor primi internodii pollicis, and deep fascia of the forearm. By its *deep surface* with the brachialis anticus, extensor carpi radialis longior, tendon of the biceps, supinator brevis, pronator radii teres, flexor carpi radialis, flexor sublimis digitorum, flexor longus pollicis, pronator quadratus, radius, musculo-spiral nerve, radial and posterior interosseous nerve, and radial artery and veins.

Nerve-supply.—A special branch of the musculo-spiral.

Dissection.—This muscle must be divided through the middle, and the two ends turned aside to expose the next muscle.

The **EXTENSOR CARPI RADIALIS LONGIOR** *arises* from the lower third of the external supracondylar ridge, immediately below the preceding, and from the intermuscular septum. Its tendon passes through a groove in the radius behind the styloid process, to be *inserted* into the base of the metacarpal bone of the index-finger.

Relations.—By its *superficial surface* with the supinator longus,

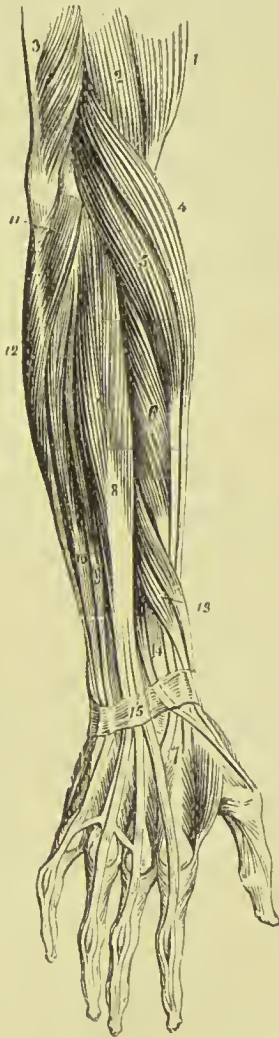

FIG. 230. — Superficial layer of muscles of the posterior aspect of the forearm. 1. Biceps. 2. Brachialis anticus. 3. Lower part of the triceps, inserted into the olecranon. 4. Supinator longus. 5. Extensor carpi radialis longior. 6. Extensor carpi radialis brevior. 7. Tendons of insertion of these two muscles. 8. Extensor communis digitorum. 9. Extensor minimi digiti. 10. Extensor carpi ulnaris. 11. Anconeus. 12. Flexor carpi ulnaris. 13. Extensor ossis metacarpi and extensor primi internodii lying together. 14. Extensor secundi internodii; its tendon is seen crossing the tendons of the extensor carpi radialis longior and brevior. 15. Posterior annular ligament. The tendons of the common extensor are seen on the back of the hand, and their mode of distribution on the dorsum of the fingers.

extensor secundi internodii pollicis, radial nerve, fascia of the forearm, and posterior annular ligament. By its *deep surface* with the brachialis anticus, extensor carpi radialis brevior, radius, and wrist-joint.

Nerve-supply.—A special branch of the musculo-spiral.

The **EXTENSOR CARPI RADIALIS BREVIOR** is seen by drawing aside the former muscle. It *arises* from the external condyle of the humerus, external lateral ligament and intermuscular septa, by a tendon common to it and the next three muscles, and is *inserted* into the styloid process on the base of the metacarpal bone of the middle finger. Its tendon is lodged in the same groove on the radius with that of the extensor carpi radialis longior.

Relations.—By its *superficial surface* with the extensor carpi radialis longior, extensor ossis metacarpi pollicis, extensor primi internodii pollicis, extensor secundi internodii pollicis, fascia of the forearm, and posterior annular ligament. By its *deep surface* with the supinator brevis, tendon of the pronator radii teres, radius, and wrist-joint. By its *ulnar border* with the extensor communis digitorum.

Nerve-supply.—Posterior interosseous, a branch of the musculo-spiral.

The **EXTENSOR COMMUNIS DIGITORUM** *arises* from the external condyle by the common tendon, from the intermuscular septa, and deep fascia; and divides into four tendons, which are *inserted* into the second and third phalanges of the fingers. At the metacarpo-phalangeal articulation each tendon becomes narrow and thick, and sends a thin fasciculus upon each side of the joint. It then spreads out, and receiving the tendon of the lumbricalis and some tendinous fasciculi from the interossei, forms a broad aponeurosis, which covers the whole posterior aspect of the finger. At the first phalangeal joint the aponeurosis divides into three slips. The middle slip is inserted into the base of the second phalanx, and the two lateral portions are continued onwards at each side of the joint, to be inserted into the last. Little oblique tendinous slips connect the tendon of the ring with those of the middle and little finger as they cross the back of the hand.

Relations.—By its *superficial surface* with the deep fascia of the forearm and hand, and posterior annular ligament. By its *deep surface* with the supinator brevis, extensor ossis metacarpi pollicis, extensor primi internodii, extensor secundi internodii, extensor indicis, posterior interosseous artery and nerve, wrist-joint, metacarpal bones, interossei muscles, and phalanges. By its *radial border* with the extensor carpi radialis longior and brevior. By the *ulnar border* with the extensor minimi digiti, and extensor carpi ulnaris.

Nerve-supply.—Posterior interosseous.

The **EXTENSOR MINIMI DIGITI** (auricularis) is an offset from the extensor communis, with which it is connected by means of a tendinous slip. Passing down to the inferior extremity of the ulna, it traverses a distinct fibrous sheath, and at the metacarpo-

phalangeal articulation unites with the tendon derived from the common extensor. The common tendon then spreads out into a broad expansion which divides into three slips to be *inserted* as in the other fingers into the last two phalanges. It is to this muscle that the little finger owes its power of separate extension ; and, being called into action when the point of the finger is introduced into the meatus of the ear, for the purpose of removing unpleasant sensations or producing titillation, the muscle was called by the old writers "auricularis."

Nerve-supply.—Posterior interosseous.

The **EXTENSOR CARPI ULNARIS** *arises* from the external condyle by the common tendon, from the posterior border of the ulna by an aponeurosis common to the flexor carpi ulnaris, flexor profundus digitorum, and this muscle, and from the deep fascia. Its tendon passes through the posterior groove in the lower extremity of the ulna, to be *inserted* into the ulnar side of the base of the metacarpal bone of the little finger.

Relations.—By its *superficial surface* with the deep fascia of the forearm, and posterior annular ligament. By its *deep surface* with the supinator brevis, extensor ossis metacarpi pollicis, extensor secundi internodii, extensor indicis, ulna, and wrist-joint. By its *radial border* it is in relation with the extensor communis digitorum and extensor minimi digiti, and by the *ulnar border* with the anconeus.

Nerve-supply.—Posterior interosseous.

The **ANCONEUS** is a small triangular muscle, having the appearance of being a continuation of the triceps ; it *arises* from the outer condyle and is *inserted* into the olecranon and triangular surface on the outer and back part of the upper extremity of the ulna.

Relations.—By its *superficial surface* with a strong tendinous aponeurosis derived from the triceps. By its *deep surface* with the elbow-joint, orbicular ligament, and slightly with the supinator brevis.

Nerve-supply.—Musculo-spiral.

Deep Layer.

Supinator brevis,
Extensor ossis metacarpi pollicis,
Extensor primi internodii pollicis,
Extensor secundi internodii pollicis,
Extensor indicis.

Dissection.—The muscles of the superficial layer should be removed in order to bring the deep group completely into view.

The **SUPINATOR BREVIS** cannot be seen in its entire extent until the radial extensors of the carpus are divided from their origin. It *arises* from the external condyle, from the external lateral and orbicular ligament, and from a rough depression below the lesser sigmoid notch of the ulna, and winds around the upper part of the

radius, to be *inserted* into the neck of that bone and the upper third of the shaft, excepting its

internal border, as low down as the insertion of the pronator teres. The posterior interosseous nerve perforates the lower border of this muscle.

Relations.—By its *superficial surface* with the pronator radii teres, supinator longus, extensor carpi radialis longior and brevior, extensor communis digitorum, extensor carpi ulnaris, anconeus, radial artery and veins, musculo-spiral nerve, radial and posterior interosseous nerve. By its *deep surface* with the elbow-joint and ligaments, interosseous membrane, and radius.

Nerve - supply.—Posterior interosseous.

The **EXTENSOR OSSIS METACARPI POLLICIS** is placed immediately below the supinator brevis. It *arises* from the ulna, interosseous membrane, and radius, and is *inserted* into the base of the metacarpal bone of the thumb. Its tendon passes through the groove immediately in front of the styloid process of the radius.

Relations.—By its *superficial surface* with the extensor carpi ulnaris, extensor minimi digiti, extensor communis digitorum, fascia of the forearm, and annular ligament. By its *deep surface* with the ulna, interosseous membrane, radius, tendons of the extensor carpi radialis longior and brevior, and supinator longus, and at the wrist with the radial artery. By its *upper border* with the edge of the supinator brevis; by its *lower border* with the extensor secundi and primi internodii. It is crossed by branches of the posterior interosseous artery and nerve.

Nerve - supply.—Posterior interosseous.

The **EXTENSOR PRIMI INTERNODII POLLICIS**, the smallest of the muscles in this layer, *arises* from the posterior surface of the interosseous membrane and radius, and passes through the groove with the to be *inserted* into the base of the first

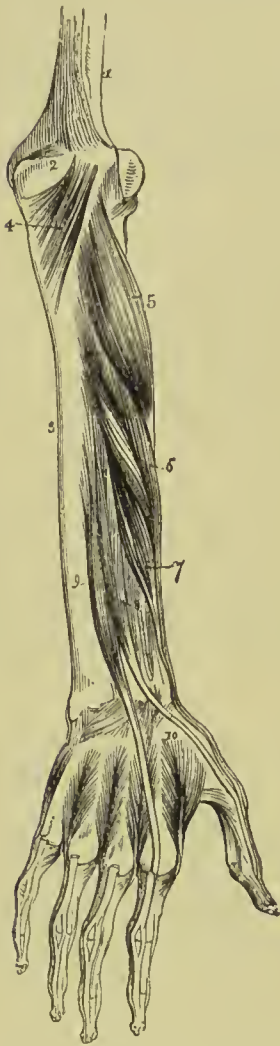

FIG. 231.—Deep layer of muscles of the posterior aspect of the forearm. 1. Humerus. 2. Olecranon. 3. Ulna. 4. Anconeus. 5. Supinator brevis. 6. Extensor ossis metacarpi pollicis. 7. Extensor primi internodii pollicis. 8. Extensor secundi internodii pollicis. 9. Extensor indicis. 10. First dorsal interosseous muscle. The other three dorsal interossei are seen between the metacarpal bones of their respective fingers.

extensor ossis metacarpi, phalanx of the thumb.

Relations.—The same as the preceding muscle, with the exception of the extensor carpi ulnaris. The muscle accompanies the extensor ossis metacarpi.

Immediately before entering the groove on the radius this muscle and the preceding one arch over the tendons of the extensor carpi radialis longior and brevior.

Nerve-supply.—Posterior interosseous.

The **EXTENSOR SECUNDI INTERNODII POLLICIS** arises from the posterior surface of the ulna and interosseous membrane. Its tendon passes through the narrow, oblique groove on the back of the radius, and is inserted into the base of the last phalanx of the thumb.

Relations.—By its *external surface*, the same as the extensor ossis metacarpi. By its *deep surface* with the ulna, interosseous membrane, radius, wrist-joint, radial artery, and metacarpal bone of the thumb. The muscle is placed between the extensor primi internodii and extensor indicis.

Nerve-supply.—Posterior interosseous.

The **EXTENSOR INDICIS** (indicator) arises from the ulna, below the origin of the extensor secundi internodii, and from the interosseous membrane. Its tendon passes beneath the posterior annular ligament in the same groove on the back of the radius as the extensor communis digitorum, to be *inserted* into the aponeurosis of the common extensor tendon of the index finger.

Relations.—The same as the preceding muscle, with the exception of the hand, where the tendon rests on the metacarpal bone of the forefinger and second interosseous muscle, and has no relation with the radial artery.

Nerve-supply.—Posterior interosseous.

The tendons of the extensors, as of the flexor muscles of the forearm, are provided with synovial bursæ as they pass beneath the annular ligament; those of the back of the wrist have separate sheaths, formed by the posterior annular ligament.

Actions.—The anconeus is associated in its action with the triceps extensor cubiti; it assists in extending the forearm on the arm. The supinator longus is a weak supinator, being effective only in the early part of that action; it is a powerful flexor, but acts only after the flexion has been begun by other muscles. The supinator brevis is the chief supinator, and the direct antagonist of the two pronators. The extensor carpi radialis longior and brevior and extensor carpi ulnaris extend the wrist in opposition to the two flexors of the carpus; they also abduct the hand. The extensor communis digitorum restores the fingers to the straight position after they have been flexed by the two flexors, sublimis and profundus. The extensor ossis metacarpi, primi internodii, and secundi internodii pollicis are the special extensors of the thumb, and serve to balance the actions of the flexor ossis metacarpi, flexor brevis, and flexor longus pollicis. The extensor indicis produces extension of the index finger, and is therefore named "indicator," and the ex-

tensor minimi digiti supplies that finger with the power of exerting a distinct extension.

MUSCLES OF THE HAND.

Radial or Thenar Region.

Abductor pollicis, Flexor brevis pollicis,
Flexor ossis metacarpi (opponens), Adductor pollicis.

Dissection.—The hand is best dissected by making an incision along the middle of the palm, from the wrist to the base of the middle finger, and crossing it at each extremity by a transverse incision, then turning aside the flaps of integument. For exposing the muscles of the radial region, the removal of the integument and fascia on the radial side will be sufficient.

The **ABDUCTOR POLLICIS** is a thin flat muscle, which *arises* from the trapezium bone and annular ligament. It is *inserted* into the radial side of the base of the first phalanx of the thumb.

Nerve-supply.—Median nerve.

Relations.—By its *superficial surface* with the external portion of the palmar fascia; by its *deep surface* with the flexor ossis metacarpi. At its *inner side* it is separated by a narrow areolar interspace from the flexor brevis pollicis. This muscle must be divided from its origin and turned aside, in order to see the next.

The **FLEXOR OSSIS METACARPI** or **OPPONENS POLLICIS** *arises* from the trapezium and annular ligament, and is *inserted* into the whole length of the shaft of the metacarpal bone of the thumb on its radial border.

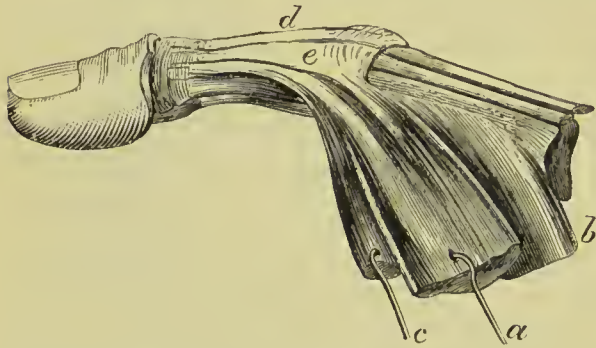


FIG. 232.—Insertion of the muscles of the thumb. *a.* Abductor pollicis. *b.* Opponens pollicis. *c.* Outer head of flexor brevis. *d.* Tendon of extensor secundus internodii. *e.* Tendinous expansion of flexor brevis, joining tendon of extensor.

Nerve - supply.—Median nerve.

Relations.—By its *superficial surface* with the abductor pollicis. By its *deep surface* with the trapezo-metacarpal articulation and metacarpal bone. *Internally* with the flexor

brevis pollicis. The flexor ossis metacarpi may now be divided from its origin and turned aside, in order to show the next muscle.

The **FLEXOR BREVIS POLLICIS** consists of two portions, between which lies the tendon of the flexor longus pollicis. The external portion *arises* from the trapezium and annular ligament; the internal portion from the trapezoid, os magnum, and base of the second and third metacarpal bones. They are *inserted* into the two sides of the base of the first phalanx of the thumb, having a sesamoid

bone in each of their tendons to protect the joint, and send tendinous slips to join the tendon of the extensor secundi internodii at the back of the first phalanx. The outer head is joined by a considerable bundle of fibres from the inner, which passes obliquely behind the long flexor tendon in order to reach it.

Relations.—By its *superficial surface* with the external portion of the palmar fascia. By its *deep surface* with the adductor pollicis, tendon of the flexor carpi radialis, and trapezo-metacarpal articulation. By its *external surface* with the flexor ossis metacarpi and metacarpal bone. By its *inner surface* with the tendons of the long flexor muscles and first lumbricalis.

Nerve-supply.—Outer head by the median nerve, inner by the ulnar.

The **ADDUCTOR POLLICIS** is a triangular muscle; it *arises* by a broad origin from the middle two-thirds of the palmar surface of the metacarpal bone of the middle finger; the fibres converge to its *insertion* into the base of the first phalanx of the thumb and internal sesamoid bone, where it is united with the inner head of the flexor brevis.

Relations.—By its *anterior surface* with the flexor brevis pollicis, tendons of the deep flexor of the fingers, lumbricales, and deep palmar arch. By its *posterior surface* with the metacarpal bones of the index and middle finger, the interossei of the second interosseous space, and the first dorsal interosseous. Its inferior border is subcutaneous.

Nerve-supply.—Ulnar nerve.

Ulnar or Hypothenar Region.

Palmaris brevis,	Flexor brevis minimi digiti,
Abductor minimi digiti,	Flexor ossis metacarpi.

Dissection.—Turn aside the ulnar flap of integument from the palm of the hand; in doing this, a small subcutaneous muscle, the palmaris brevis, will be exposed. After examining this muscle, remove it with the deep fascia, in order to bring into view the muscles of the little finger.

The **PALMARIS BREVIS** is a thin plane of muscular fibres about an inch in width, which *arises* from the annular ligament and palmar fascia, and passes transversely inwards to be *inserted* into the integument of the inner border of the hand.

Relations.—By its *superficial surface* with the fat and integument of the inner portion of the palm. By its *deep surface* with the ulnar portion of the palmar fascia, which separates it from the ulnar artery, veins, and nerve, and from the muscles of the inner border of the hand.

Nerve-supply.—Ulnar nerve.

The **ABDUCTOR MINIMI DIGITI** is a small tapering muscle which *arises* from the pisiform bone, where it is continuous with the tendon

of the flexor carpi ulnaris, and is *inserted* into the base of the first phalanx of the little finger, and into the expansion of the extensor tendon.

Relations.—By its *superficial surface* with the internal portion of the deep fascia and palmaris brevis; by its *deep surface* with the flexor ossis metacarpi and metacarpal bone. By its *inner border* with the flexor brevis minimi digiti.

Nerve-supply.—Ulnar nerve.

The **FLEXOR BREVIS MINIMI DIGITI** is a small muscle *arising* from the unciform bone and annular ligament, and *inserted* into the base of the first phalanx of the little finger in connection with the preceding muscle. It is sometimes wanting.

Relations.—By its *superficial surface* with the internal portion of

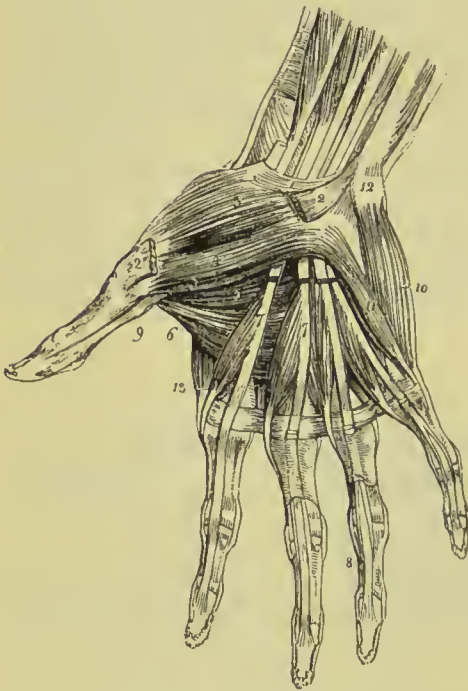


FIG. 233.—Muscles of the hand. 1. Annular ligament. 2, 2. Origin and insertion of the abductor pollicis muscle; the middle portion has been removed. 3. Flexor ossis metacarpi, or opponens pollicis. 4. Superficial portion of the flexor brevis pollicis. 5. Deep portion of the flexor brevis pollicis. 6. Adductor pollicis. 7, 7. The lumbricales muscles, arising from the deep flexor tendons, upon which the figures are placed. The tendons of the flexor sublimis have been removed. 8. One of the tendons of the deep flexor, passing between the two terminal slips of the tendon of the flexor sublimis to reach the last phalanx. 9. The tendon of the flexor longus pollicis, passing between the two portions of the flexor brevis to the last phalanx. 10. Abductor minimi digiti. 11. Flexor brevis or opponens minimi digiti. The edge of the flexor ossis metacarpi is seen projecting beyond the inner border of the flexor brevis. 12. Pisiform bone. 13. First dorsal interosseous muscle, the abductor indicis.

the palmar fascia, and palmaris brevis. By its *deep surface* with the flexor ossis metacarpi and metacarpal bone. *Externally* with the abductor minimi digiti, from which it is separated near its origin by the deep palmar branch of the ulnar nerve and communicating artery. *Internally* with the tendons of the flexor sublimis and profundus.

Nerve-supply.—Ulnar nerve.

The **FLEXOR OSSIS METACARPI** or **OPPONENS MINIMI DIGITI** *arises* from the unciform bone and annular ligament, and is *inserted* into the whole length of the metacarpal bone of the little finger on its ulnar border.

Relations.—By its *superficial surface* with the flexor brevis and

abductor minimi digiti. By its *deep surface* with the interossei muscles of the last metacarpal space, metacarpal bone, and flexor tendons of the little finger.

Nerve-supply.—Ulnar nerve.

Palmar Region.

Lumbricales, Palmar interossei, Dorsal interossei.

The **LUMBRICALES**, four in number, are accessories to the deep flexor muscle. They *arise* from the tendons of the deep flexor; the first and second from the radial side of one tendon; the third and fourth from the contiguous sides of two tendons. They pass to the radial side of each finger and are *inserted* into the aponeurotic expansion of the extensor tendons on the dorsal aspect of the first phalanx. The third, or that of the tendon of the ring finger, sometimes bifurcates; at other times it is inserted wholly into the extensor tendon of the middle finger.

Relations.—In the palm of the hand with the flexor tendons; at their insertion, with the tendons of the interossei and the metacarpophalangeal articulations.

Nerve-supply.—The two outer by the median, the two inner by the ulnar nerve.

The **PALMAR INTEROSSEI**, three in number, are visible only on the palmar aspect of the hand; they are placed upon the metacarpal bones, rather than between them. They *arise* from the base of the metacarpal bone of one finger, and are *inserted* into the base of the first phalanx and aponeurotic expansion of the extensor tendon of the same finger. The

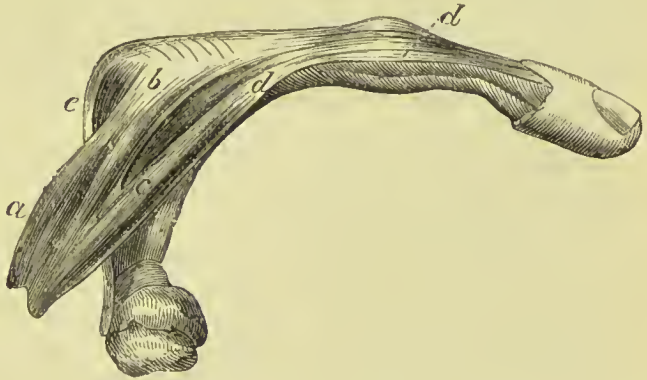


FIG. 234.—Attachment of an interosseous muscle. *a*. Interosseous muscle. *b*. Attachment to the base of first phalanx. *c*. Slip passing forward to *d*, Side of extensor tendon. *e*. Central portion of extensor tendon.

first belongs to the index finger; the second, to the ring finger; the third, to the little finger; the middle finger being omitted.

Relations.—By their *palmar surface* with the flexor tendons and deep muscles in the palm of the hand. By their *dorsal surface* with the dorsal interossei. On one side with the metacarpal bone, on the other with the corresponding dorsal interosseous muscle.

DORSAL INTEROSSEI.—Turning to the dorsum of the hand, the four *dorsal interossei* are seen in the four spaces between the metacarpal bones. They are bipenniform muscles, and *arise* by two

heads from adjoining sides of the bases of the metacarpal bones. They are *inserted* into the base of the first phalanges, and into the aponeurosis of the extensor tendons.

The first is inserted into the index finger, and from its use is called *abductor indicis*; the second and third are inserted into the middle finger, compensating its exclusion from the palmar group; the fourth is attached to the ring finger; so that each finger is provided with two interossei, with the exception of the little finger, as may be shown by means of a table, thus:—

<i>Index finger,</i>	{	one dorsal (<i>abductor indicis</i>),
		one palmar.
<i>Middle finger,</i>	{	two dorsal.
		one dorsal,
<i>Ring finger,</i>	{	one palmar.
<i>Little finger,</i>		remaining palmar (<i>adductor minimi digiti</i>).

Relations.—By their *dorsal surface* with a thin aponeurosis, which separates them from the tendons on the dorsum of the hand. By their *palmar surface* with the muscles and tendons in the palm of the hand. By one side with the metacarpal bone; by the other with the corresponding palmar interosseous. The *abductor indicis* is in relation by its palmar surface with the *adductor pollicis* and *flexor brevis pollicis*. The radial artery passes into the palm of the hand between the two heads of the first dorsal interosseous muscle (*abductor indicis*); and the perforating branches of the deep palmar arch, between the heads of the other dorsal interossei.

Nerve-supply.—All the interosseous muscles are supplied by the ulnar nerve.

Actions.—The actions of the muscles of the hand are expressed in their names. Those of the radial region belong to the thumb, and provide for three of its movements, *abduction*, *adduction*, and *flexion*. The ulnar group, in like manner, are subservient to the same motions of the little finger. The *lumbricales* are accessory in their actions to the deep flexors; they were called by the earlier anatomists *fidicini*—*i.e.*, fiddlers' muscles, from an idea that they might effect the rapid movements by which the performer is enabled to produce the various notes on that instrument. The seven interossei and the four *lumbricales* have a double action on the fingers in consequence of being inserted partly into the bases of the first phalanges and partly into the expansion of the extensor tendon. They thus become flexors of the fingers at the metacarpo-phalangeal joint, and extensors of the two last phalanges; the former action being due to their osseous and the latter to their tendinous insertion. The interossei are, however, chiefly concerned in flexion of the first phalanx, since the greater part of their insertion is into that bone; the *lumbricales*, again, almost entirely pass to the extensor tendon, and they thus combine the action of the flexors with that of the extensors, so as to give fineness and firmness of digital action (Clark).

In relation to the axis of the hand, the four *dorsal* interossei are *abductors*, the three palmar *adductors*. It will therefore be seen that each finger is provided with its proper adductor and abductor, two flexors, and (with the exception of the middle and ring finger) two extensors. The thumb has, moreover, a flexor (opponens) and extensor of the metacarpal bone ; and the little finger a flexor of the metacarpal bone (opponens) without an extensor.

The palmaris brevis draws together the skin on the ulnar margin of the hand, and so increases the hypothenar eminence and deepens the hollow of the hand.

MUSCLES AND FASCIÆ OF THE LOWER EXTREMITY.

FASCIÆ OF THE LOWER EXTREMITY.

The **superficial fascia** of the thigh consists of two layers, the superficial or fatty, and the deep or membranous. The first is continuous with that of the abdomen, and contains more or less fat, according to the subject. Between the two layers are contained the superficial epigastric, superficial circumflex iliac, and superficial external pudic branches of the femoral artery and vein ; also the femoral and inguinal lymphatic glands and the vessels connected with them, the crural branch of the genito-crural nerve, and the internal, middle, and external cutaneous nerves. The deep or membranous layer is thin but strong, and is attached to the fascia lata a short distance below Poupart's ligament. It is also closely connected to the fascia lata around the margin of the saphenous opening, which it closes, and here it is more dense than elsewhere, and being pierced by openings for the superficial vessels before alluded to, it is called the *cribriform fascia*, which forms one of the coverings of femoral hernia. It becomes incorporated with the fascia lata as it descends, and at about six inches below the groin becomes inseparably united with it.

The **deep fascia** of the thigh is named, from its great extent, the **fascia lata** ; it is thick and strong upon the outer side of the limb, and thinner on its inner and posterior aspect. That portion of the deep fascia which invests the gluteus maximus is very thin, but that which covers in the gluteus medius is excessively thick, and gives origin, by its inner surface, to the superficial fibres of that muscle. The fascia lata is attached superiorly to Poupart's ligament, the crest of the ilium, sacrum, coccyx, tuberosity of the ischium, ramus of the ischium and pubes, body of the pubes, and pectineal line ; it has also a deep attachment (ligamentum iliaceum) to the anterior border of the ilium, tendon of origin of the rectus muscle, and border of the acetabulum. It forms sheaths for the muscles of the thigh and femoral vessels, and is connected with the linea aspera by means of two **intermuscular septa**, **external** and **internal** ; the former extending from the insertion of the gluteus maximus to the external

condyle, and separating the vastus externus from the biceps muscle; the internal being attached to the inner branch of the linea aspera for a short distance above the internal condyle, and separating the vastus internus from the adductor magnus. The fascia lata receives the attachment of two muscles, tensor vaginæ femoris and gluteus maximus, and glides over the trochanter major on a bursa. At the lower part of the thigh, the fascia forms a very distinct band of about an inch and a half in width, **ilio-tibial band**, which receives tendinous fibres from the extensor and flexor muscles of the thigh, and is inserted into the outer tuberosity of the tibia and head of the fibula. At the back of the knee the fascia bridges over the popliteal space, the longitudinal fibres being strengthened by numerous transverse fasciculi.

In addition to the smaller openings in the fascia lata which transmit the small cutaneous vessels and nerves, there exists at the upper and inner extremity of the thigh an oval opening, which gives passage to the superficial lymphatic vessels and the large subcutaneous vein of the lower extremity, the internal saphenous vein, and is thence named the **saphenous opening**. The existence of this opening has given rise to the division of the upper part of the fascia lata into two portions, an iliac portion and a pubic portion.

The **iliac portion** is situated upon the iliac side of the opening. It is attached to the crest of the ilium, and along Poupert's ligament to the spine of the pubes, whence it is reflected downwards and outwards in an arched direction, and forms a *falciform border* (*falciform process of Burns*), which constitutes the outer boundary of the saphenous opening. The edge of this border immediately overlies, and is adherent to, the sheath

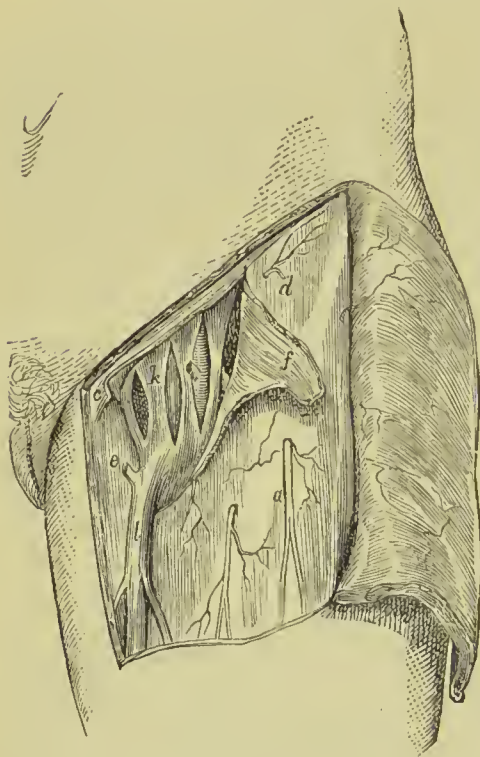


FIG. 235.—Crural sheath laid open. *a*. Middle cutaneous nerve. *c*. Placed to the inner side of Gimbernat's ligament. *d*. Iliac portion of fascia lata. *e*. Pubic portion of fascia lata. *f*. Margin of saphenous opening (turned back). *k*. Femoral sheath opened by three incisions. *l*. Saphena vein.

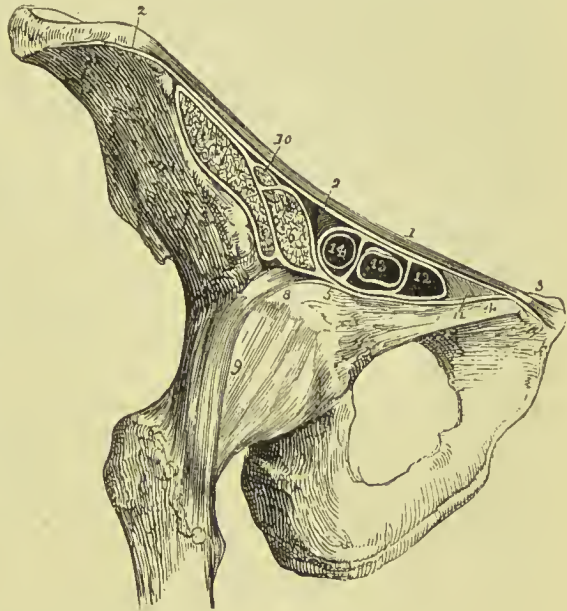
of the femoral vessels, and the lower extremity of the curve is continuous with the pubic portion.

The **pubic portion**, occupying the pubic side of the saphenous opening, is attached to the spine of the pubes and pectineal line;

and passing outwards behind the sheath of the femoral vessels, divides into two layers; the anterior layer is continuous with that portion of the iliac fascia which forms the sheath of the iliacus and psoas muscle, the posterior layer is lost upon the capsule of the hip-joint.

The interval between the falciform border of the iliac portion and the opposite surface of the pubic portion is closed by an areolo-fibrous layer, derived from the deep layer of the superficial fascia, and pierced by numerous openings for the passage of arteries, veins, and lymphatic vessels, the **cribriform fascia**. The cribriform fascia lies superficial to the sheath of the femoral vessels, and forms one of the coverings of femoral hernia. When the iliac portion of the fascia lata is removed from its attachment to Poupart's ligament

FIG. 236.—Section of the structures which pass beneath the crural arch. 1. Poupart's ligament. 2, 2. Iliac portion of the fascia lata, attached along the margin of the crest of the ilium, and along Poupart's ligament, as far as the spine of the pubes (3). 4. Pubic portion of the fascia lata, continuous at 3 with the iliac portion, and passing outwards behind the sheath of the femoral vessels to its outer border at 5, where it divides into two layers; one is continuous with the sheath of the psoas (6), and iliacus (7); the other (8) is lost upon the capsule of the hip-joint (9). 10. The anterior crural nerve. 11. Gimbernat's ligament. 12. The crural ring. 13. Femoral vein. 14. Femoral artery; the two vessels and the ring are surrounded by the femoral sheath, and thin septa are sent between the anterior and posterior wall of the sheath, dividing the artery from the vein, and the vein from the crural canal.



and turned aside, the sheath of the femoral vessels (the **femoral** or **crural canal**) is brought into view; and if Poupart's ligament be carefully divided, the sheath may be isolated, and its continuation with the transversalis and iliac fascia demonstrated. In this view, the sheath of the femoral vessels is an infundibuliform continuation of the abdominal fasciæ, closely adherent to the vessels a little way down the thigh, but much larger than the vessels it contains at Poupart's ligament. If the sheath be opened, the artery and vein will be found lying side by side, and occupying the outer two-thirds of the sheath, leaving an infundibuliform interval between the vein and inner wall of the sheath; this portion of the sheath is distinguished under a different title and called **crural sheath**. The superior opening of the space is named the **femoral** or **crural ring**; it is bounded in front by Poupart's ligament, behind by

the os pubis, internally by Gimbernat's ligament, and externally by the femoral vein. The interval itself serves for the passage of the superficial lymphatic vessels from the saphenous opening to a lymphatic gland, which generally occupies the femoral ring, and from thence they proceed into the current of the deep lymphatics. The crural ring is closed merely by a thin layer of sub-serous areolar tissue, which retains the lymphatic gland in its position, and is named **septum crurale**, and by the peritoneum. It follows from this description that the femoral ring must be a weak point in the parietes of the abdomen, particularly in the female, in whom the **femoral arch**, or space included between Poupart's ligament and the border of the pelvis, is larger than in the male, while the structures which pass through it are smaller. It happens, consequently, that if violent or continued pressure be made upon the abdominal viscera, a portion of intestine may be forced through the femoral ring into the infundibuliform space in the sheath of the femoral vessels, carrying before it the peritoneum and septum crurale,—this constitutes **femoral hernia**. If the causes which gave rise to the formation of the hernia continue, the intestine, unable to extend further down the sheath, from the close connection of the latter with the vessels, will, in the next place, be forced forwards through the saphenous opening in the fascia lata, carrying before it two additional coverings, the sheath of the vessels or fascia propria, and the cribriform fascia; and then, curving upwards over Poupart's ligament, the hernia will become placed beneath the superficial fascia and integument.

The direction which femoral hernia takes in its descent is at first *downwards*, then *forwards*, and then *upwards*; and in endeavouring to reduce it, the application of the taxis must have reference to this course, and be directed in precisely the reverse order. The coverings of femoral hernia are the—

Integument,
Superficial fascia,
Cribriform fascia,
Femoral sheath,
Septum crurale,
Peritoneal sac.

The **deep fascia of the leg** is attached to the inner and outer tuberosity of the tibia and head of the fibula, and receives an accession of fibres from the tendons of the sartorius, gracilis, and biceps. Between its points of attachment, and especially behind, it is continuous with the fascia of the thigh. In the front of the leg it encloses the tibialis anticus and extensor muscles, and affords origin to some of their fibres. On the outer side it forms a sheath for the peronei muscles; and behind, two sheaths, superficial and deep; the former for the gastrocnemius and soleus with the tendo-Achillis, the latter for the deep flexor muscles. At the ankle these four sheaths are

differently arranged; the posterior superficial sheath terminates on the os calcis with the tendo-Achillis; the posterior deep sheath is attached at one side to the border of the internal malleolus, at the other to the os calcis and inner side of the foot, being blended with the origin of the abductor pollicis. This portion of the deep fascia is the **internal annular ligament**; it sends processes inwards to separate the tendons of the flexors and forms sheaths for their passage into the foot. The sheath of the peronei muscles at the outer ankle is attached to the external malleolus on one side, and the border of the os calcis on the other, and forms the **external annular ligament**. The anterior portion of the fascia forms at the ankle the **anterior annular ligament**; it is divisible into two parts, the upper being transversely disposed, the lower arranged in the form of the letter \succ placed on its side. The latter is often described as a separate ligament under the name of *cruciform ligament*; it is composed of two bands about half-an-inch in width, blended with each other at their point of union on the front of the joint. The internal band is attached above to the internal malleolus and below to the os calcis at the outer side of the foot; the external band to the external malleolus above, and the scaphoid and internal cuneiform bone at the inner border of the foot. The internal band at its origin consists of two layers, between which passes the tendon of the tibialis anticus. The tendons of the extensor longus digitorum and peroneus tertius have also a separate loop connected with the cruciform ligament, the *sling ligament* of Retzius; this is a narrow band which embraces the tendons in a sling-shaped loop, and passes outwards and backwards to be attached to the sulcus tali and neighbouring part of the calcaneum. The tendons passing through the loops and sheaths around the ankle are each furnished with a synovial bursa. That portion of the deep fascia of the leg which forms a septum between the superficial and deep muscles of the back of the leg is sometimes called the *intermuscular fascia*; and in operations on the arteries of that region the *deep layer* of the deep fascia. There is besides another deep portion of fascia above the preceding, the **popliteal fascia**, derived from the tendon of the semi-membranosus muscle and binding down the popliteus muscle. By its inferior border this fascia is inserted into the soleal ridge of the tibia.

The **fasciæ dorsales pedis** are three in number, superficial, middle, and deep.

The *superficial layer* of deep fascia of the foot is thin and covers the dorsum of the foot, being continuous at the ankle with the cruciform ligament, and attached at either side to the borders of the foot, where it becomes united with the plantar fascia. A second or *middle layer* of fascia covers in the anterior part of the extensor brevis digitorum with its tendons; and a third or *deep layer* is found beneath the latter, and covering in the interossei muscles. On the interossei muscles the three layers are united, and the extensor tendons are consequently separated from each other in their course to the toes.

The **Plantar Fascia** consists of three portions, middle and two lateral.

The *middle portion* is thick and dense, and composed of strong aponeurotic fibres, closely interwoven with each other. It is attached posteriorly to the inferior surface of the tuberosities of the os calcis, and terminates under the heads of the metatarsal bones in five fasciculi. Each of these fasciculi bifurcates to embrace the base of the corresponding toe, and is attached in the middle to the sheath of the flexor tendons, and at either side to the head of the metatarsal bone. The point of division of the fascia into fasciculi is strengthened by transverse bands, which preserve the solidity of the fascia at its broadest part. The intervals between the toes give passage to the digital arteries and nerves and lumbricales muscles.

The *lateral portions* are thin, and cover the sides of the sole of the foot; they are continuous behind with the internal and external annular ligament; and on the mesial side with the central portion. The *inner* portion is continuous along the border of the foot with the fascia of the dorsum; the *outer* portion is attached to the os calcis and base of the metatarsal bone of the little toe, forming between these points a thick band, which gives origin to part of the abductor minimi digiti muscle.

Besides constituting a strong layer of investment and defence to the soft parts situated in the sole of the foot, these three portions of fascia send processes inwards, which form sheaths for the different muscles. A strong septum (*intermuscular septum*) is given off from each side of the middle portion of the plantar fascia, which is attached to the tarsal bones, and divides the muscles into three groups, middle and two lateral; and transverse septa are stretched between these to separate the layers. The superficial layer of muscles derive part of their origin from the plantar fascia.

Gluteal Region.

Gluteus maximus,	Gemellus superior,
Gluteus medius,	Obturator internus,
Gluteus minimus,	Gemellus inferior,
Pyramiformis.	Obturator externus,

Quadratus femoris.

Dissection.—The subject being turned on its face, and a block placed beneath the pubes to support the pelvis, the student commences the dissection of this region by carrying an incision from the apex of the coccyx along the crest of the ilium to its anterior superior spinous process; or *vice versa*, if he be on the left side. He then reflects the integument, superficial fascia, and deep fascia, which latter is very thin over this muscle, from the gluteus maximus, following rigidly the course of its fibres; and having exposed the muscle in its entire extent, he dissects the integument and superficial fascia from off the deep fascia which binds down the gluteus medius, the other portion of the region.

The **GLUTEUS MAXIMUS** (*γλουτὸς*, nates) is the thick, fleshy mass of muscle, of a trapezoid shape, which forms the convexity of the nates. In structure it is coarse, being made up of fibres collected into large fasciculi, and these again into distinct muscular masses, separated by deep furrows. It *arises* from the posterior fourth of the crest of the ilium, from the rough triangular surface between the crest and superior curved line, the posterior surface of the sacrum and coccyx, and from the great sacro-ischiatic ligament. It passes obliquely outwards and downwards, to be *inserted* into the rough line leading from the trochanter major to the linea aspera, and is continuous by means of its tendon with the fascia lata covering the outer side of the thigh, and with the ilio-tibial band. Several bursæ are situated between this muscle and subjacent parts: one upon the tuberosity of the ischium, one between its tendon and the trochanter major, and one between it and the tendon of the vastus externus.

Relations.—By its *superficial surface* with a thin aponeurotic fascia, which separates it from the superficial fascia and integument, and near its insertion, with the vastus externus. By its *deep surface* with the gluteus medius, pyriformis, gemelli, obturator internus, quadratus femoris, sacro-ischiatic foramina, great sacro-ischiatic ligament, tuberosity of the ischium, semi-membranosus, semi-tendinosus, biceps, and adductor magnus; gluteal vessels and nerve, ischiatic vessels and nerves, and internal pudic vessels and nerve. By its *upper border* it overlaps the gluteus medius; and by the *lower border* forms the lower margin of the nates. The gluteus maximus must be turned down from its origin, in order to bring the next muscles into view.

Nerve-supply.
—Inferior gluteal branch of the lesser ischiatic nerve.

The **GLUTEUS MEDIUS** is placed in front of, rather than beneath, the gluteus maximus; and is covered in by a process of the deep fascia, which is very thick and dense. It *arises* from the outer surface of the ilium between the superior and middle curved lines,

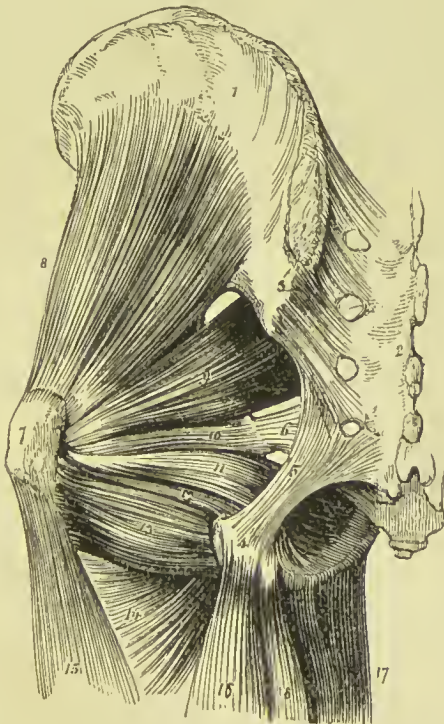

FIG. 237.—Deep muscles of the gluteal region. 1. Ilium. 2. Sacrum. 3. Posterior sacro-iliac ligaments. 4. Tuberosity of the ischium. 5. Great sacro-ischiatic ligament. 6. Lesser sacro-ischiatic ligament. 7. Trochanter major. 8. Gluteus minimus. 9. Pyriformis. 10. Gemellus superior. 11. Obturator internus, passing out of the lesser sacro-ischiatic foramen. 12. Gemellus inferior. 13. Quadratus femoris. 14. Adductor magnus. 15. Vastus externus. 16. Biceps. 17. Gracilis. 18. Semi-tendinosus.

and from the thick fascia above mentioned. Its fibres converge to a triangular rough surface on the outer part of the trochanter major, into which its tendon is *inserted*.

Relations.—By its *superficial surface* with the tensor vaginae femoris, gluteus maximus, and its own proper fascia. By its *deep surface* with the gluteus minimus and gluteal vessels and nerve. By its *lower border* with the pyriformis muscle. A bursa is interposed between its tendon and the upper part of the trochanter major.

Nerve-supply.—Superior gluteal nerve, from the sacral plexus.

This muscle should now be removed from its origin and turned down, to expose the next, which is situated beneath it.

The **GLUTEUS MINIMUS** is a radiate muscle *arising* from the surface of the dorsum ilii, between the middle and inferior curved lines; its fibres converge to the anterior border of the trochanter major, into which it is *inserted* by means of a rounded tendon.

Relations.—By its *superficial surface* with the gluteus medius and gluteal vessels. By its *deep surface* with the ilium, long tendon of the rectus femoris, and capsule of the hip-joint. A bursa is interposed between its tendon and the trochanter.

Nerve-supply.—Superior gluteal nerve.

The **PYRIFORMIS** (*pyrum*, a pear), *i.e.*, pear-shaped, *arises* from the anterior surface of the sacrum, by three little slips interposed between the anterior sacral foramina, from the first to the fourth, from the adjoining surface of the ilium, and from the greater sacro-ischiatic ligament. It passes out of the pelvis through the great sacro-ischiatic foramen, and is *inserted* by a rounded tendon into the upper border of the trochanter major, behind the tendon of the obturator internus, with which it is often blended.

Relations.—By its *superficial or external surface* with the sacrum and gluteus maximus. By its *deep or pelvic surface* with the rectum, sacral plexus of nerves, branches of the internal iliac artery, great sacro-ischiatic notch, and capsule of the hip-joint. By its *upper border* with the gluteus medius and gluteal vessels and nerve. By its *lower border* with the gemellus superior, ischiatic vessels and nerves, and internal pudic vessels and nerve.

Nerve-supply.—A branch from the sacral plexus.

The **GEMELLUS SUPERIOR** (*gemellus*, double, twin) is a small slip of muscle situated immediately below the pyriformis; it *arises* from the spine of the ischium, and is *inserted* into the upper border of the tendon of the obturator internus, and into the upper border of the trochanter major. The gemellus superior is not unfrequently wanting.

Relations.—By its *superficial surface* with the gluteus maximus, ischiatic vessels and nerves, and internal pudic vessels and nerve. By its *deep surface* with the pelvis and capsule of the hip-joint.

Nerve-supply.—A branch from the sacral plexus.

The **OBTURATOR INTERNUS** *arises* from the inner surface of the anterior wall of the pelvis, being attached to the margin of

bone around the obturator foramen and to the obturator membrane. It passes out of the pelvis through the lesser sacro-ischiatic foramen, and is *inserted* by a flattened tendon into the inner aspect of the upper border of the trochanter major. The lesser sacro-ischiatic notch, over which this muscle plays as through a pulley, is faced with cartilage, and provided with a synovial bursa to facilitate its movements. The tendon is most marked on the side applied to the surface of the notch, and is divided into four or five narrow portions, which have a silky sheen; it is bordered above and below by the gemelli muscles (hence their names), which are inserted into the sides of its tendon, and appear to be auxiliaries or superadded portions—external origins, in fact, of the obturator internus.

Relations.—By its *superficial* or *posterior surface* with the internal pudic vessels and nerve, the obturator fascia, which separates it from the levator ani and viscera of the pelvis, the sacro-ischiatic ligaments, gluteus maximus, and ischiatic vessels and nerves. By its *deep* or *anterior surface* with the obturator membrane and the margin of bone surrounding it, the cartilaginous pulley of the lesser ischiatic foramen, external surface of the pelvis, and capsular ligament of the hip-joint. By its *upper border* within the pelvis, with the obturator vessels and nerve; externally to the pelvis, with the gemellus superior. By its *lower border* with the gemellus inferior.

Nerve-supply.—A special branch of the sacral plexus.

The **GEMELLUS INFERIOR** arises from the posterior border of the tuberosity of the ischium, and is *inserted* into the lower border of the tendon of the obturator internus, and into the upper border of the trochanter major.

Relations.—By its *superficial surface* with the gluteus maximus, and ischiatic vessels and nerves. By its *deep surface* with the external surface of the pelvis and capsule of the hip-joint. By its *upper border* with the tendon of the obturator internus. By its *lower border* with the tendon of the obturator externus and quadratus femoris.

Nerve-supply.—A branch from the sacral plexus.

In this region only the tendon of the obturator externus can be seen, by pulling apart the gemellus inferior and quadratus femoris; it is situated deeply between the gemellus inferior and upper border of the quadratus femoris. To expose the muscle fully, it is necessary to dissect it on the anterior part of the thigh, after the removal of the pectineus, adductor longus, and adductor brevis.

The **OBTURATOR EXTERNUS** muscle (*obturare*, to stop up) arises from the obturator membrane and from the surface of the bone immediately surrounding it anteriorly—viz., from the ramus of the pubes and ischium; its tendon passes outwards behind the neck of the femur, to be *inserted* into the digital fossa of the trochanter major. When the femur is rotated outwards the tendon of this muscle lies in the groove between the acetabulum and tuberosity of the ischium.

Relations.—By its *superficial* or *anterior surface* with the tendon of the psoas and iliacus, pectineus, adductor brevis and magnus,

obturator vessels and nerve. By its *deep* or *posterior surface* with the obturator membrane and margin of bone which surrounds it, the lower part of the capsule of the hip-joint and quadratus femoris.

Nerve-supply.—The obturator nerve.

The **QUADRATUS FEMORIS** (square-shaped) *arises* from the external border of the tuberosity of the ischium; and is *inserted* into a rough line on the posterior border of the trochanter major, which is thence named *linea quadrati*.

Relations.—By its *posterior surface* with the gluteus maximus, and ischiatic vessels and nerves. By its *anterior surface* with the tendon of the obturator externus and trochanter minor, a synovial bursa often separating it from the latter. By its *upper border* with the gemellus inferior; and by the *lower border* with the adductor magnus.

Nerve-supply.—A branch from the sacral plexus.

Actions.—The gluteal muscles are abductors of the thigh, when they take their fixed point from the pelvis. Taking their fixed point from the thigh, they act as extensors of the pelvis on the femur, and thus are the chief muscles by which the erect posture is maintained: they assist also in carrying the leg forward in progression. The anterior fibres of the gluteus medius and minimus assisted in rotating the limb inwards. The gluteus maximus, from its fibres passing backwards to the posterior aspect of the bone, rotates the limb outwards; it is, moreover, a tensor of the fascia of the thigh, and through the agency of the ilio-tibial band acts as an extensor of the leg on the thigh. The other muscles rotate the limb outwards, everting the knee and foot; hence they are named external rotators.

The obturator externus, besides being an external rotator, is also a flexor and adductor of the thigh.

Anterior Femoral Region.

Tensor vaginæ femoris,	Vastus internus,
Sartorius,	Vastus externus,
Rectus femoris,	Crureus.

Dissection.—Make an incision along the line of Poupart's ligament, from the anterior superior spinous process of the ilium to the spine of the pubes; and a second, from the inner end of the preceding, down the inner side of the thigh, and across the inner condyle of the femur to about two inches below the head of the tibia, where it may be bounded by a transverse incision. Turn back the integument from the whole of this region, and examine the superficial fascia; which is next to be removed in the same manner. After the deep fascia has been well considered, it is likewise to be removed, by dissecting it off in the course of the fibres of the muscles. As it might not be convenient to the junior student to expose so large a surface at once as ordered in this dissection, the vertical incision

may be crossed by one or two transverse incisions, as may be deemed most proper.

The **TENSOR VAGINÆ FEMORIS** (stretcher of the sheath of the thigh) is a short flat muscle, situated on the outer side of the hip. It *arises* from the crest of the ilium, near its anterior superior spinous process, and from the notch between the two anterior spinous processes, and is *inserted* between two layers of the fascia lata at about one-fourth down the thigh.

Relations.—By its *superficial surface* with the fascia lata and integument. By its *deep surface* with an internal layer of the fascia lata, gluteus medius, rectus, and vastus externus. By its *inner border* near its origin with the sartorius.

Nerve-supply.—Superior gluteal nerve.

The **SARTORIUS** (tailor's muscle) is a long ribbon-like muscle, *arising* from the anterior superior spinous process of the ilium, and from the notch immediately below that process; it crosses obliquely the upper third of the thigh, descends behind the inner condyle of the femur, and is *inserted* by an aponeurotic expansion into the upper part of the inner side of the tibia, nearly as far forward as the crest. This expansion covers in the insertion of the tendons of the gracilis and semi-tendinosus muscles. The inner border of the sartorius muscle is the guide to the operation for tying the femoral artery in the middle of its course, and the outer boundary of Scarpa's triangular space. This muscle is pierced by two nerves, the middle cutaneous and the patellar branch of the long saphenous.

Nerve-supply.—Anterior crural nerve.

Relations.—By its *superficial surface* with the fascia lata and cutaneous nerves. By its *deep surface* with the psoas and iliacus, rectus, sheath of the femoral vessels, vastus internus, adductor longus, adductor magnus, gracilis, long saphenous nerve, internal lateral ligament of the knee-joint. By its *expanded insertion* with the tendons of the gracilis and semi-

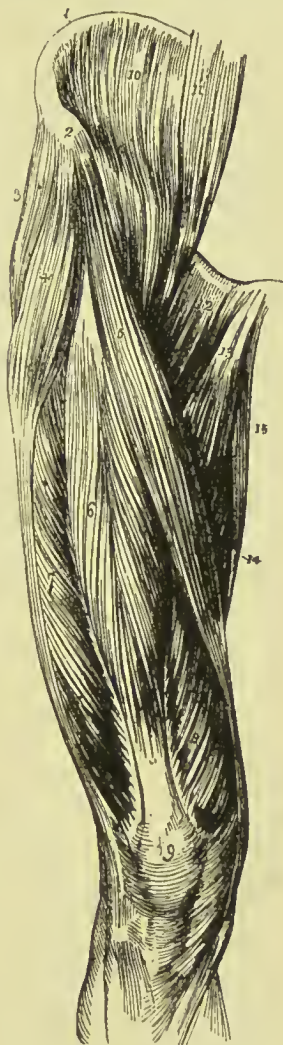


FIG. 238.—Muscles of the anterior femoral region. 1. Crest of the ilium. 2. Its anterior superior spinous process. 3. Gluteus medius. 4. Tensor vaginæ femoris; its insertion into the fascia lata is shown inferiorly. 5. Sartorius. 6. Rectus. 7. Vastus externus. 8. Vastus internus. 9. Patella. 10. Iliacus internus. 11. Psoas magnus. 12. Pectineus. 13. Adductor longus. 14. Part of the adductor magnus. 15. Gracilis.

tendinosus, a synovial bursa being interposed. At the knee-joint its *posterior border* is in relation with the internal saphena vein.

SCARPA'S SPACE.—This is a triangular space of some surgical importance situated at the upper part of the thigh; in its upper part femoral hernia takes place, and in its lower part ligature of the femoral artery is usually performed. Its base is formed by Poupart's ligament, its inner border by the adductor longus, its outer border by the sartorius muscle, and its apex is at the point where the latter muscle crosses the artery. Its floor is formed by the iliacus, psoas, pectineus, adductor longus, and a small part of the adductor brevis. It contains the common femoral, superficial femoral, profunda femoris, and circumflex arteries, the superficial and profunda femoris veins, anterior crural nerve and its branches, external cutaneous nerve and deep lymphatic vessels. A perpendicular line, drawn from the middle of the base to the apex of this triangle, immediately overlies the femoral artery with its sheath.

The **RECTUS FEMORIS** is a fusiform muscle placed in the middle of the anterior aspect of the thigh. It *arises* by a flattened tendon from the space between the inferior curved line of the dorsum of the ilium and the upper margin of the acetabulum, its fibres being intimately blended with the circular fibres of the capsular ligament of the hip, and with the cotyloid ligament; this is usually described as the *reflected* head. The muscle is also connected by means of a rounded accessory band of condensed areolar tissue with the anterior inferior spine of the ilium, and by a falciform process to about an inch of the anterior border of the ilium above the inferior spine; this connection is generally regarded as the direct continuation of the muscle, and is described as the *straight* head. These heads are connected by a deep process of the ilio-tibial band and by areolar and adipose tissue situated between the two layers of that process of fascia. The body of the muscle is spindle-shaped, and is composed of fleshy and tendinous fibres disposed in the following manner: the superior tendon as it descends spreads out into an aponeurosis which covers the anterior surface of the upper third of the muscle, and sends a tendinous band between the fleshy fibres as far as the lower third of the thigh; the inferior tendon, in like manner, spreads out on the back part of the muscle, so as to form an aponeurosis which covers the lower two-thirds of that aspect. Between these two the fleshy fibres pass, being arranged in a penniform manner, those in the middle of the thigh being connected anteriorly with the tendinous band above described as originating from the upper aponeurosis. The lower tendon becomes narrowed a few inches above the patella into a flat band which receives on its borders the attachment of some fibres of the vastus externus and internus, and is *inserted* into the anterior edge of the upper surface of the patella.

Relations.—By its *superficial surface* with the gluteus medius, psoas and iliacus, sartorius; and for the lower three-fourths of its extent with the fascia lata. By its *deep surface* with the capsule

of the hip-joint, external circumflex vessels, crureus, vastus internus and externus.

Nerve-supply.—Anterior crural nerve.

The rectus must now be divided through its middle, and the two ends turned aside to bring clearly into view the next muscles.

The **VASTUS EXTERNUS** arises from the upper end of the spiral line of the femur as far inwards as the external cervical tubercle, from the inferior border of the great trochanter (where that process joins the shaft of the bone), from the line leading from the great trochanter to the linea aspera, from the outer lip of the latter as far down as its bifurcation, and from the external intermuscular septum. At the point of its attachment where it lies against the insertion of the gluteus maximus, it becomes blended with the tendon of that muscle, and where the two muscles glide over each other a bursa is interposed. The greater part of the superficial surface is aponeurotic, this being usually the case with the upper three-fourths, excepting the anterior border; the fleshy fibres run downwards and slightly forwards, passing from the superficial aponeurosis to one situated on the deep aspect of the muscle and derived from the tendon of insertion. The lower fleshy fibres are more oblique than the upper; they are inserted into a narrow thick tendon which is intimately connected with the crureus and rectus; from this tendon fibrous expansions are given off to blend with similar processes derived from the other extensor muscles, and form a fibrous capsule, which passes over the lateral aspect of the front of the knee-joint and is inserted into the head of the tibia. The tendon of insertion gives off an aponeurosis which lines the deep surface of the muscle for the lower half of its extent; traced downwards the tendon is found to be *inserted* into the upper half of the outer border of the patella.

It is often difficult to define the anterior edge of this muscle, and to distinguish its fibres from those of the crureus, but the line of separation is almost invariably indicated by the course of the external circumflex vessels, and the nerve passing to the muscle itself.

Relations.—By its *superficial surface* with the fascia lata, rectus, biceps, semi-membranosus, and gluteus maximus. By its *deep surface* with the crureus and femur.

Nerve-supply.—Anterior crural nerve.

The **VASTUS INTERNUS** arises from the spiral line of the femur, from the internal cervical tubercle to the point where that line joins the linea aspera, and from the inner border of the latter as far as the groove for the femoral artery. As was observed with the vastus externus, the superficial portion of the muscle is chiefly aponeurotic, excepting at the lower third of the thigh, where it becomes fleshy. The fleshy fibres below the groove for the artery spring from the rounded tendon of insertion of the adductor magnus and the fibrous membrane which unites that tendon with the internal supracondylar line. The fibres of the vastus internus are connected at their origin with those of the adductor muscles; they lie upon and clothe the

inner surface of the femur, but are not attached to it. The muscle is *inserted* by a tendon common to it, the crureus, vastus externus and rectus, into the front of the inner half of the base of the patella, but the lower fibres pass directly to the inner border of that bone without joining the tendon, and from this latter portion of the muscle an aponeurosis is prolonged to be inserted immediately below the inner tuberosity of the tibia, some of its fibres joining the internal lateral ligament of the knee. In its upper part the muscle is often blended with the crureus, but their line of separation may be made out by following the course of a small nerve which is derived from the upper branch to the vastus internus, and passes down between the vastus internus and crureus to be distributed to the subcrureus and upper part of the synovial pouch of the knee.

Relations.—By its *superficial surface* with the psoas and iliacus, rectus, sartorius, femoral artery and vein, and saphenous nerve, pectineus, adductor longus, brevis, and magnus, and fascia lata. By its *deep surface* with the crureus and femur.

Nerve-supply.—Anterior crural nerve.

The **CRUREUS** (*crus*, the leg) consists of four laminae, placed one over the other; separated above, at their origin, by intervals of bare bone, but fused below. The first of these is placed superficially to the rest, and *arises* from the spiral line to the outer side of the internal cervical tubercle; its attachment passes from thence down the outer surface of the bone to the gluteal ridge, and is continued downwards along the outer lip of the linea aspera and external intermuscular septum. Below the point where the linea aspera divides, the fibres cease to arise from bone, but continue to spring from the external intermuscular septum close to its attachment to the supracondylar line. The second layer lies beneath the first, and is attached lower down on the shaft of the femur, and the third and fourth in like manner lie beneath and below the second. Each layer arises entirely by fleshy fibres in the form of an arched process, which extends from the inner border of the shaft transversely across its front, and then obliquely down its outer surface for a short distance to the linea aspera, where it blends with the adjacent layers of the crureus, the vastus externus and external intermuscular septum. The lower two-thirds of the anterior surface of the crureus is aponeurotic, the aponeurosis being narrow below, where it lies in the middle of the limb, and spread out above, where it covers the whole of the anterior and part of the outer surface. The crureus is *inserted* by means of the common tendon into the upper border of the patella.*

Relations.—By its *superficial surface* with the external circumflex vessels, rectus, vastus internus and externus. By its *deep surface* with the femur, sub-crureus, and synovial membrane of the knee-joint.

* The above description of the extensor muscles is condensed from an exhaustive account given by Mr. W. Roger Williams, M.R.C.S., in the *Journal of Anatomy and Physiology*, vol. xiii. p. 204.

Nerve-supply.—Anterior crural nerve.

The four muscles above described are often grouped under one common title as the **quadriceps extensor cruris**; or, the three muscles most intimately connected, the two vasti and the crureus, receive the name of **triceps femoralis**.

SUB-CRUREUS.—When the crureus is divided from its insertion, a small muscle is seen upon the lower part of the femur; it generally consists of two fasciculi, external and internal, which are inserted into the pouch of synovial membrane that extends upwards from the knee-joint, behind the patella; and is named, from its situation, *sub-crureus*. It draws up the synovial membrane in the act of extension of the knee-joint.

Actions.—The tensor vaginæ femōris renders the fascia lata tense, and rotates the limb inwards. The sartorius flexes the leg upon the thigh, and, continuing to act, the thigh upon the pelvis, at the same time rotating it outwards and carrying the leg across that of the opposite side, into the position in which tailors sit; hence its name. Taking its fixed point from below, it assists the extensor muscles in steadying the leg, for the support of the trunk. The other four muscles have been collectively named *quadriceps extensor*, from their similarity of action. They extend the leg upon the thigh, and obtain a great increase of power by their attachment to the patella, which acts as a fulcrum. Taking their fixed point from the tibia, they steady the femur upon the leg, and the rectus, being attached to the pelvis, serves to balance the trunk upon the lower extremity.

Internal Femoral Region.

Iliacus internus,
Psoas magnus,
Pectineus,

Adductor longus,
Adductor brevis,
Adductor magnus,
Gracilis.

Dissection.—These muscles are exposed by the removal of the inner flap of integument recommended in the dissection of the anterior femoral region. The iliacus and psoas arising from within the abdomen can only be seen in their entire extent after the removal of the viscera from that cavity.

The **ILIACUS INTERNUS** is a flat radiated muscle. It *arises* from the fossa of the ilium, ilio-lumbar ligament, base of the sacrum, internal lip of the crest, and anterior border of the bone; and after escaping beneath the crural arch and joining the tendon of the psoas, is *inserted* into the trochanter minor of the femur. A few fibres of this muscle are derived from the base of the sacrum, and others from the capsular ligament of the hip-joint.

The iliacus internus and psoas magnus are so intimately blended at their insertion that they are sometimes described as a single muscle arising by two heads under the name of **ilio-psoas**.

Relations.—By its *anterior surface*, within the pelvis, with the

external cutaneous nerve and iliac fascia, which latter separates it from the peritoneum, on the right from the cæcum, and on the left from the sigmoid flexure of the colon; *externally* to the pelvis, with the fascia lata, rectus, and sartorius. By its *posterior surface* with the iliac fossa, margin of the pelvis, and capsule of the hip-joint, a synovial bursa of large size being interposed. This bursa sometimes communicates with the synovial membrane of the ilio-femoral articulation. By its *inner border*, with the psoas magnus and anterior crural nerve.

Nerve-supply.—Anterior crural nerve.

The **iliac fascia** is the aponeurotic investment of the psoas and iliacus muscle; and, like the transversalis fascia, is thick below, and becomes gradually thinner as it ascends. It is attached superiorly, along the edge of the psoas, to the anterior lamella of the aponeurosis of the transversalis muscle, to the ligamentum arcuatum internum, and to the bodies of the lumbar vertebræ, leaving arches corresponding with the constricted part of the vertebræ for the transit of the lumbar vessels. Lower down it passes beneath the external iliac vessels, and is attached along the margin of the true pelvis; *externally* it is connected to the crest of the ilium; and, *inferiorly*, to the outer two-thirds of Poupart's ligament, where it is continuous with the transversalis fascia. Passing beneath Poupart's ligament, it surrounds the psoas and iliacus muscle to its termination, and beneath the inner part of the femoral arch forms the posterior segment of the crural canal and sheath of the femoral vessels.

The **PSOAS MAGNUS** ($\psi\acute{o}\alpha$, lumbus, a loin), situated by the side of the vertebral column in the loins, is a long fusiform muscle. It *arises* from the bodies and bases of transverse processes of the last dorsal and all the lumbar vertebræ. It also takes its origin from the intervertebral substance, and from a series of tendinous arches attached to the vertebræ, and intended for the protection of the lumbar vessels and branches of the sympathetic nerve in their passage between the muscle and the bone. From this extensive origin the muscle passes along the margin of the brim of the pelvis, and beneath Poupart's ligament, to its insertion. The tendon of the psoas magnus is joined by the iliacus, and *inserted* into the posterior part of the trochanter minor, a bursa being interposed.

Relations.—By its *anterior surface* with the ligamentum arcuatum internum of the diaphragm, kidney, psoas parvus, genito-crural nerve, sympathetic nerve, psoas fascia, peritoneum, colon, and along its pelvic border, the common and external iliac artery and vein. By its *posterior surface* with the lumbar vertebræ, lumbar arteries, quadratus lumborum (from which latter it is separated by the anterior layer of the aponeurosis of the transversalis), and crural nerve, which, near Poupart's ligament, reaches its outer side. The lumbar plexus of nerves is situated in the substance of the posterior part of the muscle. In the thigh the muscle is in relation with the fascia lata *in front*; the border of the pelvis and hip-joint, from which it is separated by the synovial membrane, common to it and the preced-

ing muscle, *behind*; the crural nerve and iliacus muscle to the *outer* side; and the femoral artery, by which it is slightly overlaid, to the *inner* side.

Nerve-supply.—Branches from the lumbar plexus.

The **PECTINEUS** is a flat and quadrangular muscle; it *arises* from the pectineal line (*pecten*, a crest) of the os pubis, and from the surface of bone in front of that line. It is *inserted* into the ridge leading from the lesser trochanter to the linea aspera of the femur.

Relations.—By its *anterior surface* with the pubic portion of the fascia lata, which separates it from the femoral artery and vein and internal saphenous vein, and lower down with the profunda artery. By its *posterior surface* with the capsule of the hip-joint, obturator externus, and adductor brevis, the obturator vessels being interposed. By its *external border* with the psoas, the femoral artery resting on the line of interval. By its *internal border* with the outer edge of the adductor longus. Obturator hernia is situated directly behind this muscle, which forms one of its coverings.

Nerve-supply.—This muscle receives one branch from the anterior crural, and another from the obturator.

The **ADDUCTOR LONGUS** (*adducere*, to draw to), the most superficial of the three adductors, *arises* by a round and thick tendon from the front surface of the os pubis, immediately below the angle of that bone; and, assuming a flattened and expanded form as it descends, is *inserted* into the middle third of the inner lip of the linea aspera.

Relations.—By its *anterior surface* with the pubic portion of the fascia lata, and near its insertion, with the femoral artery and vein. By its *posterior surface* with the adductor brevis and magnus, anterior branches of the obturator vessels and nerve, and, near its insertion, profunda artery and vein. By its *outer border* with the pectineus; by the *inner border* with the gracilis.

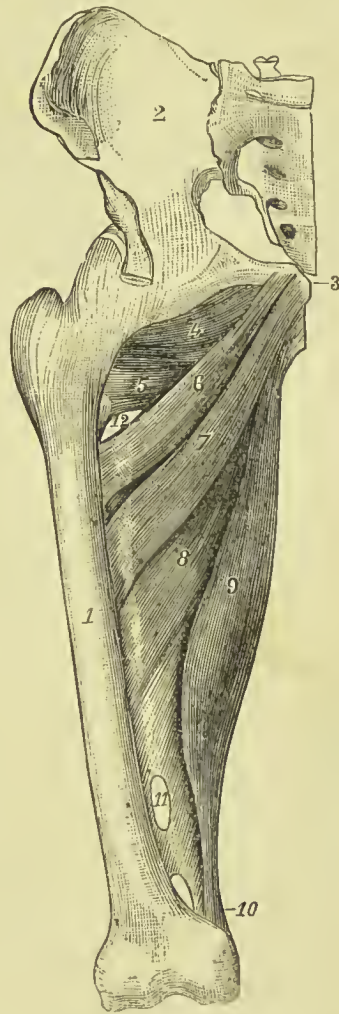


FIG. 239.—1. Femur. 2. Ilium. 3. Pubes. 4. Obturator externus. 5. Upper portion of adductor magnus. 6. Upper portion of adductor brevis. 7. Lower part of the same muscle. 8. Middle portion of adductor magnus, partly covered by adductor brevis. 9. Lower part of adductor magnus, terminating in a round tendon. 10. Opening for femoral artery. 11. Opening for the passage of the internal circumflex vessels.

The pectineus must be divided near its origin and turned outwards, and the adductor longus through its middle, turning its ends to either side, to bring into view the adductor brevis.

Nerve-supply.—Obturator nerve.

The **ADDUCTOR BREVIS**, placed behind the pectineus and adductor longus, is fleshy, and thicker than the adductor longus; it *arises* from the body of the os pubis, and is *inserted* into the line leading from the lesser trochanter to the linea aspera, immediately behind the insertion of the pectineus.

Nerve-supply.—Obturator nerve.

Relations.—By its *anterior surface* with the pectineus, adductor longus, and anterior branch of the obturator nerve and artery. By its *posterior surface* with the adductor magnus. By its *outer border* with the obturator externus, and tendon of the psoas and iliacus. By its *inner border* with the gracilis and adductor magnus. It is pierced near its insertion by the middle perforating artery.

The adductor brevis may now be divided from its origin and turned outwards, or its inner two-thirds may be cut away entirely, when the adductor magnus muscle will be exposed in its entire extent.

The **ADDUCTOR MAGNUS** is a broad triangular muscle, forming a septum of division between the muscles situated on the anterior and those on the posterior aspect of the thigh. It *arises* by fleshy fibres from the ramus of the pubes and ischium and from the anterior border of the tuber ischii; and radiating in its passage outwards, is *inserted* into the line leading from the great trochanter to the linea aspera, to the whole length of the middle lip of the linea aspera, and by a rounded tendon into a small spine on the inner condyle of the femur. The adductor magnus is pierced by five openings; the three superior, for the three perforating arteries; the fourth, for the termination of the profunda. The fifth is the large oval opening, in the tendinous portion of the muscle, that gives passage to the femoral vessels.

Relations.—By its *anterior surface* with the pectineus, adductor brevis, adductor longus, femoral artery and vein, and profunda artery and vein, with their branches. By its *posterior surface* with the semi-tendinosus, semi-membranosus, biceps, and gluteus maximus. By its *inner border* with the gracilis and sartorius. By its *upper border* with the obturator externus and quadratus femoris.

Nerve-supply.—Obturator nerve.

The **GRACILIS** (slender) is situated along the inner border of the thigh. It *arises* by a broad but very thin tendon, from the body of the os pubis along the edge of the symphysis; and from the margin of the ramus of the pubes and ischium; it is *inserted* by a rounded tendon into the upper part of the inner side of the tibia, nearly as far forwards as the crest, beneath the expansion of the sartorius.

Relations.—By its *inner or superficial surface* with the fascia lata, and below with the sartorius and internal saphenous nerve; the internal saphena vein crosses it, lying superficially to the fascia lata.

By its *outer* or *deep surface* with the adductor longus, brevis, and magnus, and the internal lateral ligament of the knee-joint, from which latter it is separated by a synovial bursa common to it and the tendons of the gracilis and semi-tendinosus.

Nerve-supply.—Obturator nerve.

Actions.—The iliacus, psoas, pectineus, and adductor longus muscles flex the thigh upon the pelvis, and at the same time, from the obliquity of their insertion into the lesser trochanter and linea aspera, rotate the limb outwards; the pectineus and adductors adduct the thigh powerfully, and from the manner of their insertion into the linea aspera, assist in rotating the limb outwards. The gracilis is an adductor of the thigh; but contributes to the flexion of the leg, by its attachment to the tibia.

Posterior Femoral Region.—Ham-string Muscles.

Biceps femoris, Semi-tendinosus,
Semi-membranosus.

Dissection.—Remove the integument and fascia from the posterior part of the thigh by two flaps, and turn aside the gluteus maximus from the upper part; the muscles may then be examined.

The **BICEPS FEMORIS** (flexor cruris) *arises* by two heads, one (long head) by a common tendon with the semi-tendinosus from the lower and inner part of the tuber ischii; the other (short head), muscular and much shorter, from the lower two-thirds of the external border of the linea aspera, external supracondylar ridge, and external intermuscular septum. The short head reaches as high as the insertion of the gluteus maximus. The biceps forms the outer ham-string, and is *inserted* by a strong tendon into the head of the fibula; one portion of the tendon being continued downwards into the fascia of the leg, and another being attached to the outer tuberosity of the tibia. At its insertion into the fibula the tendon divides into two portions, between which the long external lateral ligament of the knee passes, a synovial bursa being interposed.

Relations.—By its *superficial* or *posterior surface* with the gluteus maximus and fascia lata. By its *deep* or *anterior surface* with the semi-membranosus, adductor magnus, vastus externus, from which it is separated by the external intermuscular septum, great ischiatic nerve, popliteal artery and vein, and, near its insertion the external head of the gastrocnemius and plantaris. By its *inner border* with the semi-tendinosus, and in the popliteal space with the popliteal artery and vein. Its tendon of insertion has the external popliteal nerve in immediate relation with it posteriorly.

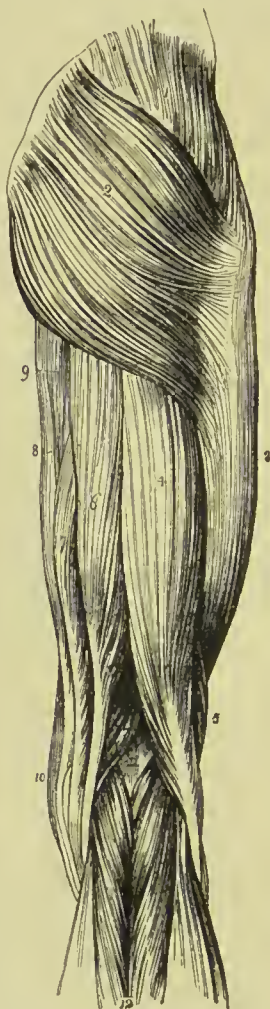
Nerve-supply.—Great sciatic nerve.

The **SEMI-TENDINOSUS**, remarkable for its long tendon, *arises* in common with the long head of the biceps, from the lower and inner part of the tuberosity of the ischium: the two muscles being closely united for several inches below their origin. It is *inserted* into the

upper part of the inner side of the tibia, nearly as far forwards as the crest, immediately below the insertion of the tendon of the gracilis, and sends an expansion to the fascia of the leg.

Relations.—By its *superficial surface* with the gluteus maximus, fascia lata, and at its insertion with the synovial bursa which separates its tendon from the expansion of the sartorius. By its *deep surface* with the semi-membranosus, adductor magnus, internal head of the gastrocnemius, and internal lateral ligament of the knee-joint,

FIG. 240. — Muscles of the posterior femoral and gluteal region. 1. Gluteus medius. 2. Gluteus maximus. 3. Vastus externus covered in by fascia lata. 4. Long head of biceps. 5. Short head. 6. Semi-tendinosus. 7, 7. Semi-membranosus. 8. Gracilis. 9. Part of the inner border of the adductor magnus. 10. Edge of sartorius. 11. Popliteal space. 12. Gastrocnemius; its two heads. The tendon of the biceps forms the outer ham-string, the sartorius with the tendons of the gracilis, semi-tendinosus and semi-membranosus, the inner ham-string.



the synovial bursa common to it and the tendon of the gracilis being interposed. By its *inner border* with the gracilis; by its *outer border* with the biceps.

Nerve-supply.—Great sciatic nerve.

These two muscles must be dissected from the tuberosity of the ischium, to bring into view the origin of the next.

The **SEMI-MEMBRANOSUS**, remarkable for the tendinous expansion upon its anterior and posterior surface, arises from the upper and outer facet on the tuberosity of the ischium, external to the common origin of the two preceding muscles. It is inserted into the posterior part of the inner tuberosity of the tibia; at its insertion the tendon splits into three portions, one of which is inserted in a groove on the inner side of the head of the tibia, beneath the internal lateral ligament. The second is continuous with an aponeurotic expansion

that binds down the popliteus muscle, the *popliteal fascia*; and the third turns upwards and outwards to the external condyle of the femur, forming the middle portion of the posterior ligament of the knee-joint (*ligamentum posticum Winslowii*).

The tendons of the semi-tendinosus, semi-membranosus, gracilis, and sartorius form the inner ham-string.

Relations.—By its *superficial surface* with the gluteus maximus, biceps, semi-tendinosus, fascia lata, and at its insertion, the tendi-

nous expansion of the sartorius. By its *deep surface* with the quadratus femoris, adductor magnus, internal head of gastrocnemius, knee-joint (from which it is separated by a synovial membrane), and the popliteal artery and vein. By its *inner border* with the gracilis. By its *outer border* with the great ischiatic nerve, and in the popliteal space the popliteal artery and vein.

Nerve-supply.—Great sciatic nerve.

If the semi-membranosus muscle be turned down from its origin, the student will bring into view the broad and radiated expanse of the adductor magnus, against which the three flexor muscles above described rest.

Actions.—The three ham-string muscles are flexors of the leg upon the thigh; and taking their fixed point from below they extend the pelvis, and balance it on the lower extremities. The biceps, from the obliquity of its direction, everts the leg when partly flexed, and the semi-tendinosus turns the leg inwards when in the same state of flexion.

Cleland has pointed out that the ham-string muscles limit flexion at the hip as long as the knee is extended; so that it is only by flexing the leg on the thigh that it is possible completely to flex the thigh on the abdomen.

Anterior Tibial Region.

Tibialis anticus,
Extensor longus digitorum,
Peroneus tertius,
Extensor proprius hallucis.

Dissection.—The dissection of the anterior tibial region is to be commenced by carrying an incision along the middle of the leg midway between the tibia and fibula, from the knee to the ankle, and bounding it inferiorly by a transverse incision extending from one malleolus to the other. To expose the tendons on the dorsum of the foot, the longitudinal incision may be carried onwards to the outer side of the base of the great toe, and terminated by another incision directed across the heads of the metatarsal bones.

The **TIBIALIS ANTICUS** arises from the outer tuberosity and upper two-thirds of the outer surface of the tibia, the interosseous membrane, intermuscular fascia, and deep fascia; its tendon passes through a distinct sheath in the anterior annular ligament close to the inner border of the tibia, and is *inserted* into the inner and under side of the internal cuneiform bone, and base of the metatarsal bone of the great toe.

Relations.—By its *anterior surface* with the deep fascia from which many of its superior fibres arise, and the anterior annular ligament. By its *posterior surface* with the interosseous membrane, tibia, ankle-joint, and bones of the tarsus. By its *internal surface* with the tibia; by its *external surface* with the extensor longus digitorum; extensor proprius hallucis, and anterior tibial vessels and nerve.

Nerve-supply.—Anterior tibial nerve.

The **EXTENSOR LONGUS DIGITORUM** (extensor communis longus) arises from the outer tuberosity of the tibia, the head and upper three-fourths of the fibula, the interosseous membrane, intermuscular fascia, and deep fascia. Near the ankle it divides into four tendons, which pass beneath the annular ligament through a proper tendinous pulley (the sling ligament of Retzius), to be inserted into the second and third phalanges of the four lesser toes. The mode of insertion

FIG. 241. — Muscles of the anterior tibial region. 1. Quadriceps extensor inserted into the patella; the figure rests on the tendon of the rectus, the vastus internus and externus are situated one at each side. 2. Subcutaneous surface of the tibia. 3. Tibialis anticus. 4. Extensor longus digitorum. 5. Extensor proprius hallucis. 6. Peroneus tertius. 7. Peroneus longus. 8. Peroneus brevis. 9, 9. Borders of the soleus muscle. 10. Part of the inner belly of the gastrocnemius. 11. Extensor brevis digitorum; the tendon in front of the number is that of the peroneus tertius; that behind it, the peroneus brevis.



of the extensor tendons is remarkable; each tendon spreads into a broad aponeurosis over the base of the first phalanx; this aponeurosis is strengthened on its borders by the tendons of the extensor brevis digitorum, lumbricales and interossei, and divides into three slips; the middle slip is inserted into the base of the second phalanx, the two lateral slips are continued onwards, to be inserted into the base of the third.

Relations.—By its anterior surface with the deep fascia of the leg and foot, and anterior annular ligament. By its posterior surface with the interosseous membrane, fibula, ankle-joint, extensor brevis digitorum (which separates its tendons from the tarsus), metatarsus, and phalanges. By its inner surface with the

tibialis anticus, extensor proprius hallucis, and anterior tibial vessels. By its outer border with the peroneus longus and brevis.

Nerve-supply.—This muscle and the next are both supplied by the anterior tibial nerve.

The **PERONEUS TERTIUS** arises from the lower fourth of the inner surface of the fibula and intermuscular fascia, and is inserted into the upper surface of the base of the metatarsal bone of the little toe. Although apparently but a mere division or continuation of

the extensor longus digitorum, this muscle may be looked upon as homologous to the flexor carpi ulnaris of the forearm. Sometimes it is wanting.

The **EXTENSOR PROPRIUS HALLUCIS** lies between the tibialis anticus and extensor longus digitorum. It *arises* from the middle three-fifths of the fibula and interosseous membrane. Its tendon passes through a distinct sheath in the annular ligament, and is *inserted* into the base of the last phalanx of the great toe, being closely connected with the first phalanx by short fibrous bands.

Relations.—By its *anterior surface* with the deep fascia of the leg and foot, and anterior annular ligament. By its *posterior surface* with the interosseous membrane, fibula, tibia, ankle-joint, extensor brevis digitorum, and

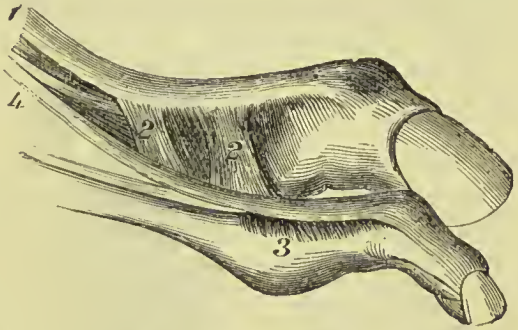


FIG. 242.—Insertion of extensors of toes. 1. Extensor proprius hallucis. 2, 2. Fibrous bands passing to first phalanx of great toe. 3. Fibrous bands from 4, Extensor longus digitorum.

bones and articulations of the great toe. It is crossed on this aspect by the anterior tibial vessels and nerve. By its *outer side* with the extensor longus digitorum, and in the foot with the dorsalis pedis artery and veins; the outer side of its tendon on the dorsum of the foot being the guide to these vessels. By its *inner side* with the tibialis anticus, and anterior tibial vessels.

Nerve-supply.—Anterior tibial nerve.

Actions.—The tibialis anticus and peroneus tertius are direct flexors of the tarsus upon the leg. The two tibial muscles acting together raise the inner border of the foot and draw it inwards. They assist also in preserving the arch of the foot during progression. The extensor longus digitorum and extensor proprius hallucis are extensors of the phalanges; and continuing their action, they assist the tibialis anticus and peroneus tertius in flexing the foot upon the leg. Taking their origin from below, they increase the stability of the ankle-joint.

Posterior Tibial Region.

Superficial Group:

Gastrocnemius,

Plantaris,

Soleus.

Dissection.—Make an incision from the middle of the popliteal space down the middle of the posterior part of the leg to the heel, bounding it inferiorly by a transverse incision passing below the two malleoli. Turn aside the flaps of integument and remove the

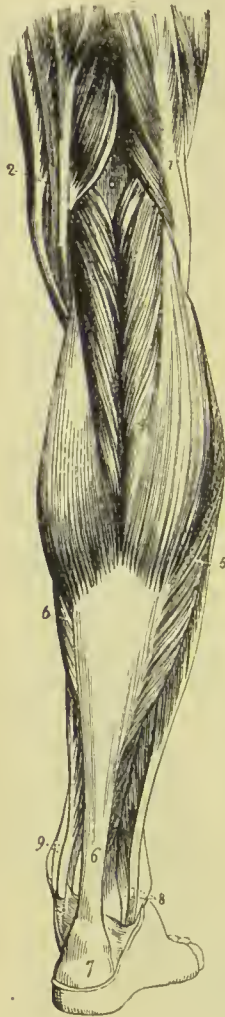fasciæ from the whole of this region ; the gastrocnemius muscle will then be exposed.

The **GASTROCNEMIUS** (*γαστροκνήμιον*, the bellied part of the leg) arises by two heads from the rough surfaces above the back part of the two condyles of the femur, the inner head being the longest. The tendons of origin are intimately connected with the posterior ligament of the knee-joint, and are lined on their anterior surface

by the synovial membrane. They unite to form the beautiful muscle so characteristic of this region of the limb. It is *inserted*, by means of the tendo-Achillis, into the lower part of the posterior tuberosity of the os calcis, a synovial bursa being placed between the tendon and the upper part of the tuberosity. The gastrocnemius must be removed from its origin, and turned down in order to expose the next muscle.

Relations. — By its *superficial surface* with the deep fascia of the leg, which separates it from the external saphena vein, and with the external saphenous nerve. By its *deep surface* with the lateral portions of the posterior ligament of the knee-joint, the popliteus, plantaris, and soleus. The internal head of the muscle rests against the posterior surface of the internal condyle of the femur, and is separated from the semi-membranosus by a synovial bursa which often communicates with the cavity of the knee-joint. The external head rests against the outer side of the external

FIG. 243.—Superficial muscles of the posterior aspect of the leg. 1. Biceps, forming the outer hamstring. 2. Tendons, forming the inner hamstring. 3. Popliteal space. 4. Gastrocnemius. 5, 5. Soleus. 6. Tendo-Achillis. 7. Posterior tuberosity of the os calcis. 8. Tendons of the peroneus longus and brevis passing behind the outer ankle. 9. Tendons of the tibialis posticus and flexor longus digitorum passing into the foot behind the inner ankle.



condyle, and often has in it a sesamoid bone or fibro-cartilage.

Nerve-supply.—Internal popliteal nerve.

The **PLANTARIS** (*planta*, the sole of the foot), an extremely diminutive muscle situated between the gastrocnemius and soleus, arises from the upper and back part of the outer condyle of the femur ; and is *inserted*, by its long and delicately slender tendon, into the inner side of the posterior tuberosity of the os calcis, having crossed obliquely between

the two muscles. It corresponds to the palmaris longus in the forearm.

Nerve-supply.—Internal popliteal nerve.

The **SOLEUS** (*solea*, a sole) is the broad muscle upon which the plantaris rests. It *arises* from the head and upper half of the fibula, from the oblique line and middle third of the inner border of the tibia, and from a tendinous arch thrown across between these two portions. Its fibres converge to the tendo-Achillis, by which it is *inserted* into the posterior tuberosity of the os calcis. The tendinous arch gives passage to the popliteal vessels and nerve in their course to the leg.

Relations.—By its *superficial surface* with the gastrocnemius and plantaris. By its *deep surface* with the intermuscular fascia, which separates it from the flexor longus digitorum, tibialis posticus, flexor longus hallucis, posterior tibial vessels and nerve, and peroneal vessels.

Nerve-supply.—Internal popliteal.

Actions.—The three muscles of the calf draw powerfully on the os calcis, and lift the heel; continuing their action they raise the entire body. This movement is attained by means of a lever of the second power, the fulcrum (the toes) being at one end, the weight (the body supported on the tibia) in the middle, and the power (these muscles) at the other extremity.

They are, therefore, the walking muscles, and perform all movements that require the support of the whole body from the ground, as dancing, leaping, &c. Taking their fixed point from below, they steady the leg upon the foot. The gastrocnemius is also a powerful flexor of the leg on the thigh.

Deep Layer.

Popliteus,	Flexor longus digitorum,
Flexor longus hallucis,	Tibialis posticus.

Dissection.—After the removal of the soleus, the deep layer will be found bound down by an intermuscular fascia which is to be dissected away; the muscles may then be examined.

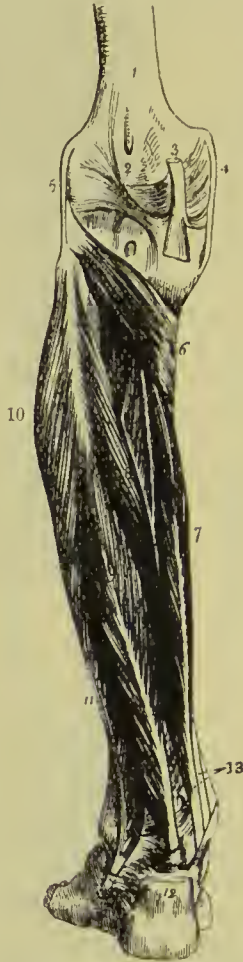The **POPLITEUS** muscle (*poples*, the ham of the leg) forms the floor of the popliteal region at its lower part, and is bound tightly down by a strong fascia derived from the middle slip of the tendon of the semi-membranosus muscle. It *arises* by a rounded tendon from a deep groove at the outer side of the external condyle of the femur, beneath the external lateral ligament and within the capsular ligament of the joint; and spreading obliquely over the head of the tibia, is *inserted* into the surface of the bone above its oblique line. This line is sometimes called, from being the limit of insertion of the popliteus muscle, the *popliteal line*. During flexion of the limb, the tendon of origin of this muscle lies in the groove on the outer side of the external condyle of the femur. It is homologous with the pronator radii teres in the forearm.

Relations.—By its *superficial surface* with a thick fascia which separates it from the gastrocnemius, plantaris, and popliteal vessels and nerve. By its *deep surface* with the synovial membrane of the knee-joint, and upper part of the tibia.

Nerve-supply.—Internal popliteal.

The **FLEXOR LONGUS HALLUCIS** is the most superficial of the next three muscles. It *arises* from the lower two-thirds of the internal surface of the fibula excepting about an inch at its lowest

FIG. 244.—Deep layer of muscles of the posterior tibial region. 1. Lower extremity of the femur. 2. Ligamentum posticum Winslowii. 3. Tendon of the semi-membranosus muscle dividing into three slips. 4. Internal lateral ligament of the knee-joint. 5. External lateral ligament. 6. Popliteus muscle. 7. Flexor longus digitorum. 8. Tibialis posticus. 9. Flexor longus hallucis. 10. Peroneus longus. 11. Peroneus brevis. 12. Tendo-Achillis divided near its insertion into the os calcis. 13. Tendons of the tibialis posticus and flexor longus digitorum, just as they are about to pass beneath the internal annular ligament of the ankle; the interval between the latter tendon and the tendon of the flexor longus hallucis is for the posterior tibial vessels and nerve.



part, and passes through a groove in the astragalus and os calcis, converted by tendinous fibres into a distinct sheath lined by synovial membrane, into the sole of the foot, to be *inserted* into the base of the last phalanx of the great toe.

Relations.—By its *superficial surface* with the intermuscular fascia, which separates it from the soleus and tendo-Achillis. By its *deep surface* with the tibialis posticus, fibula, peroneal vessels, interosseous membrane, and ankle-joint. By its *outer border* with the peroneus longus and brevis. By its *inner border* with the flexor longus digitorum. In the foot, the tendon of the flexor longus pollicis is connected with that of the flexor longus digitorum by a short tendinous slip.

Nerve-supply.—Posterior tibial nerve.

The **FLEXOR LONGUS DIGITORUM** (flexor perforans) *arises* from the posterior surface of the tibia, extending from the oblique line to within three inches of the inner ankle. Its tendon passes through a sheath, common to it and the tibialis posticus, behind the inner malleolus; it then passes through a second sheath which is connected with a groove in the astragalus and os calcis into the sole of the foot, where it divides into four tendons, which are *inserted* into the base of the last phalanx of the four lesser toes, perforating the tendons of the flexor brevis digitorum.

Relations.—By its *superficial surface* with the intermuscular fascia, which separates it from the soleus, and with the posterior tibial vessels and nerve. By its *deep surface* with the tibia and tibialis posticus. In the *sole of the foot* its tendon is in relation with the abductor hallucis and flexor brevis digitorum, which lie superficially to it, and it crosses the tendon of the flexor longus hallucis. At the point of crossing it receives a tendinous slip of communication.

Nerve-supply.—Posterior tibial.

Dissection.—The flexor longus hallucis must now be removed from its origin, and the flexor longus digitorum drawn aside, to bring into view the entire extent of the tibialis posticus.

The **TIBIALIS POSTICUS** lies upon the interosseous membrane, between the two bones of the leg. It *arises* by two heads from the adjacent sides of the tibia and fibula their whole length except about two inches at the lower end, from the interosseous membrane, and from an aponeurosis which binds it in its place. Its tendon passes inwards beneath the tendon of the flexor longus digitorum, and runs in the same sheath; it then passes through a proper sheath over the deltoid ligament, and beneath the astragalo-scaploid articulation, to be *inserted* into the tuberosity of the scaphoid and internal cuneiform bone, a process of its tendon being prolonged outwards to the external cuneiform, and other processes being connected with the middle cuneiform, the cuboid, and the bases of the second, third, and fourth metatarsal bones. While in the common sheath behind the internal malleolus, the tendon of the tibialis posticus lies internally to that of the flexor longus digitorum, from which it is separated by a thin fibrous partition. A sesamoid bone is usually met with in the tendon close to its insertion.

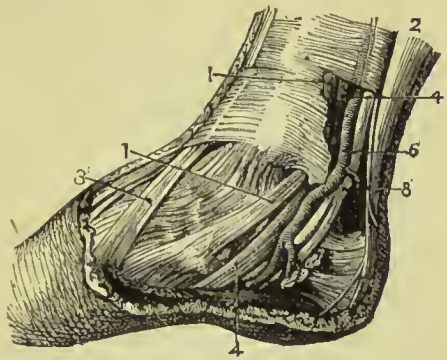


FIG. 245.—Relations of parts behind the inner malleolus. 1, 1. Tibialis posticus. 2. Tendo-Achillis. 3. Tibialis anticus. 4, 4. Flexor longus digitorum. 6. Posterior tibial artery. 8. Posterior tibial nerve. The tendon of the flexor longus hallucis is too deeply placed to be shown in this view.

Relations.—By its *superficial surface* with the intermuscular septum, flexor longus hallucis, flexor longus digitorum, posterior tibial vessels and nerve, peroneal vessels, and in the sole of the foot the abductor hallucis. By its *deep surface* with the interosseous membrane, fibula and tibia, ankle-joint and astragalus. The anterior tibial artery passes between the two heads of the muscle.

Nerve-supply.—Posterior tibial.

The student will observe that the two latter muscles change their relative position to each other in their course. Thus, in the leg, the position of the three muscles from within outwards is, flexor

longus digitorum, tibialis posticus, flexor longus hallucis. At the inner malleolus, the relation of the tendons is, tibialis posticus, flexor longus digitorum, both in the same sheath; then a broad groove, which lodges the posterior tibial artery, venæ comites, and nerve; and lastly, the flexor longus hallucis.

Actions.—The popliteus is a flexor of the tibia upon the thigh, carrying it at the same time inwards so as to invert the leg, the joint being so arranged that rotation is only possible when the leg is flexed. It is especially brought into play at the commencement of flexion of the knee, producing the inward rotation of the tibia (or outward rotation of the femur), which is essential to that action. The flexor longus hallucis and flexor longus digitorum are the long flexors of the toes; their tendons are connected in the foot by a short tendinous band, hence they necessarily act together. The tibialis posticus is an extensor of the tarsus upon the leg, and in this respect is an antagonist to the tibialis anticus. It combines with the tibialis anticus in adduction of the foot.

Fibular Region.

Peroneus longus,

Peroneus brevis.

Dissection.—These muscles are exposed by continuing the dissection of the anterior tibial region outwards beyond the fibula to the border of the posterior tibial region.

The **PERONEUS LONGUS** (*περόνη*, fibula) arises from the head and upper two-thirds of the outer side of the fibula, from the deep fascia and intermuscular septa, and terminates in a long tendon which passes behind the external malleolus, and obliquely across the sole of the foot, through the groove in the cuboid bone (converted into a canal by a fibrous band), to be inserted into the outer side of the base of the metatarsal bone of the great toe and under surface of the internal cuneiform bone. Its tendon is thickened where it glides behind the external malleolus, and a sesamoid bone is developed in that part which plays against the cuboid bone.

Relations.—By its *superficial surface* with the fascia of the leg and foot. By its *deep surface* with the fibula, peroneus brevis, os calcis, cuboid bone, and, near the head of the fibula, the external popliteal nerve. By its *anterior border* it is separated from the extensor longus digitorum by the attachment of the fascia of the leg to the fibula; and, by the *posterior border*, by the same medium from the soleus and flexor longus hallucis. The tendon of the peroneus longus is furnished with three fibrous sheaths and as many synovial membranes; the first is situated behind the external malleolus, and is common to this muscle and the peroneus brevis, the second at the outer side of the os calcis, the third on the cuboid bone.

Nerve-supply.—Musculo-cutaneous nerve, a branch of the peroneal nerve.

The **PERONEUS BREVIS** lies beneath the peroneus longus; it

arises from the lower two-thirds of the external surface of the shaft of the fibula and intermuscular septa, and terminates in a tendon which passes behind the external malleolus and through a groove in the os calcis, to be *inserted* into the outer side of the base of the metatarsal bone of the little toe.

Relations.—By its *superficial surface* with the peroneus longus and fascia of the leg and foot. By its *deep surface* with the fibula, os calcis, and cuboid bone. The lateral relations of the muscle are the same as those of the peroneus longus. The tendon of the peroneus brevis has but two tendinous sheaths and two synovial membranes, one being behind the external malleolus and common to both peronei, the other at the side of the os calcis.

Nerve-supply.—Musculo-cutaneous nerve.

Actions.—The peronei muscles are extensors of the foot, conjointly with the tibialis posticus. They antagonise the tibialis anticus and peroneus tertius, which are flexors of the foot; they also raise the outer border of the foot and draw it outwards. The whole of these muscles acting together, tend to maintain the arch of the foot, so necessary to security in walking.

FOOT.

Dorsal Region.

Extensor brevis digitorum,
Dorsal interossei.

The **EXTENSOR BREVIS DIGITORUM** muscle *arises* from the outer side of the os calcis, the external calcaneo-astragaloid ligament, and the lower part of the anterior annular ligament; it crosses the foot obliquely, and terminates in four tendons, the innermost of which is *inserted* into the base of the first phalanx of the great toe, and the other three into the outer side of the long extensor tendons of the second, third, and fourth toes.

Relations.—By its *upper surface* with the tendons of the extensor longus digitorum, peroneus brevis, and the deep fascia of the dorsum of the foot. By its *under surface* with the tarsal and metatarsal bones, and dorsal interossei muscles. Its *inner border* is in relation with the dorsalis pedis artery, the innermost tendon crossing that artery just before its division.

Nerve-supply.—Anterior tibial nerve.

The **DORSAL INTEROSSEI** muscles, four in number, are placed

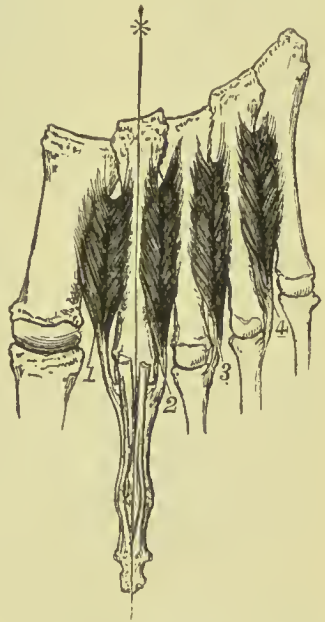


FIG. 246. —Diagram of the dorsal interosseous muscles of the foot; designed to show that they all *abduct* from the middle line of the second toe.

between the metatarsal bones ; they resemble the corresponding muscles in the hand in *arising* by two heads from the adjacent sides of the metatarsal bones ; their tendons are *inserted* into the base of the first phalanx, and the digital expansion of the tendons of the long extensor. The dorsal interossei muscles all *abduct* from the middle line of the second toe. The tendon of the first is inserted into the inner side of the base of the first phalanx of the second toe, the other tendons into the outer side of the first phalanges of the second, third, and fourth toes.

Nerve-supply.—External plantar nerve.

Relations.—By their *upper surface* with a strong fascia which separates them from the extensor tendons. By their *under surface* with the plantar interossei. Each of the muscles gives passage to a small artery (posterior perforating) which communicates with the external plantar artery ; and between the heads of the first interosseous muscle the dorsalis pedis artery takes its course.

Plantar Region.

First Layer.

Abductor hallucis, Abductor minimi digiti,
Flexor brevis digitorum.

Dissection.—The sole of the foot is best dissected by carrying an incision around the heel and along the inner and outer border of the foot, to the great and little toe. This incision should divide the integument and superficial fascia, and both together should be dissected from the deep fascia, as far forward as the base of the phalanges, where they should be removed from the foot altogether. The plantar fascia should then be raised by a transverse incision made through it at about the middle of the foot, and should be turned over towards the toes ; the first layer of muscles will thus be brought into view.

The **ABDUCTOR HALLUCIS** lies along the inner border of the foot ; it *arises* by two heads, between which the tendons of the long flexors, arteries, veins, and nerves enter the sole of the foot. One head proceeds from the inner tuberosity of the os calcis, the other from the internal annular ligament and plantar fascia ; it is *inserted* along with the inner head of the flexor brevis hallucis into the base of the first phalanx of the great toe, and into the internal sesamoid bone.

Relations.—By its *superficial surface* with the internal portion of the plantar fascia. By its *deep surface* with the flexor brevis hallucis, flexor accessorius, tendons of the flexor longus digitorum, flexor longus hallucis, tibialis anticus and posticus, plantar vessels and nerves, and tarsal bones. At its *outer border* with the flexor brevis digitorum, from which it is separated by a vertical septum of the plantar fascia.

Nerve-supply.—Internal plantar nerve.

The **ABDUCTOR MINIMI DIGITI** lies along the outer border of the sole of the foot. It arises from the outer tuberosity of the os calcis, the surface between the two tuberosities, the external intermuscular septum, and from the plantar fascia as far forward as the base of the fifth metatarsal bone; and is inserted with the flexor brevis into the base of the first phalanx of the little toe.

Relations.—By its superficial surface with the external portion of the plantar fascia. By its deep surface with the flexor accessorius, flexor brevis minimi digiti, tarsal bones, and metatarsal bone of the little toe. By its inner side with the flexor brevis digitorum, from which it is separated by the vertical septum of the plantar fascia.

Nerve-supply.—External plantar nerve.

The **FLEXOR BREVIS DIGITORUM** (*perforatus*) is placed between the two preceding muscles. It arises from the under surface of the os calcis, from the plantar fascia, and intermuscular septa; and is inserted by four tendons into the base of the second phalanx of the four lesser toes. Each tendon divides, previously to its insertion, to give passage to the tendon of the long flexor; hence its cognomen *perforatus*.

Relations.—By its superficial surface with the plantar fascia. By its deep surface with a thin layer of fascia which separates it from the flexor accessorius, tendons of the flexor longus digitorum and flexor longus hallucis, and plantar vessels and nerves. By its borders with the vertical septa of the plantar fascia which separate the muscle, on the one side from the abductor hallucis, and on the other from the abductor minimi digiti.

Nerve-supply.—Internal plantar nerve.

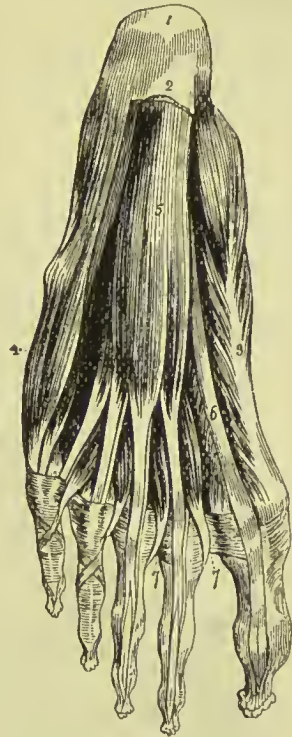


FIG. 247. — First layer of muscles of the sole of the foot; this layer is exposed by the removal of the plantar fascia. 1. Os calcis. 2. Posterior part of the plantar fascia divided transversely. 3. Abductor hallucis. 4. Abductor minimi digiti. 5. Flexor brevis digitorum. 6. Tendon of the flexor longus hallucis. 7, 7. Lumbricales. On the second and third toe, the tendons of the flexor longus digitorum are seen passing through the bifurcation of the tendons of the flexor brevis digitorum.

Second Layer.

Flexor accessorius,

Lumbricales.

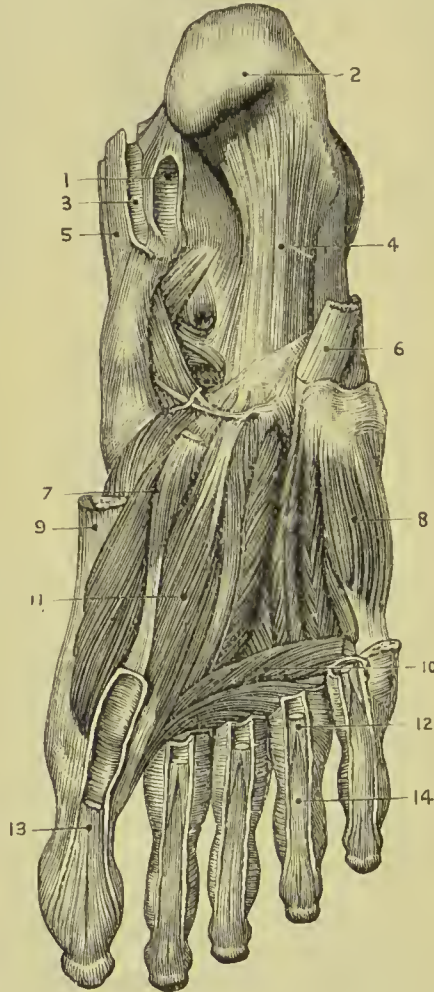Dissection.—The three preceding muscles must be divided near

their origin, and turned downwards, in order to see the muscles of this group, but they must not be entirely removed.

The **FLEXOR ACCESSORIUS** arises by two slips, the inner of which is fleshy and the outer tendinous; the former is attached to the inner surface of the os calcis, and the latter to the under surface of the same bone a little in front of the outer tuberosity, and to the long plantar ligament. It is inserted into the outer border, and upper and lower surfaces of the long flexor tendon.

FIG. 248. — Deep muscles of the sole of the foot.

1. Sheath of flexor longus hallucis.
2. Os calcis.
3. Sheath of flexor longus digitorum.
4. Long plantar ligament.
5. Sheath of tibialis posticus.
6. Tendon of peroneus longus.
7. Flexor brevis hallucis.
8. Flexor brevis minimi digiti.
9. Tendon of abductor hallucis.
10. Transversus pedis.
11. Adductor hallucis.
12. Tendon of flexor brevis digitorum to fourth toe.
13. Tendon of flexor longus hallucis.
14. Tendon of flexor longus digitorum to fourth toe.



Relations. — By its *superficial surface* with the three muscles of the superficial layer, from which it is separated by their fascial sheaths, and with the external plantar vessels and nerve. By its *deep surface* with the under part of the os calcis and long plantar ligament.

Nerve - supply. — External plantar nerve.

The **LUMBRI-CALES** (*lumbricus*, an earth-worm) are four little muscles arising from the tendons of the flexor longus digitorum at their point of bifurcation, each, with the exception of the most internal, being

attached to two tendons; they are inserted into the expansion of the extensor tendons, and the base of the first phalanx of the four lesser toes on their inner side. They pass between the digital slips of the plantar fascia to their insertion.

Nerve-supply. — The two inner by digital branches of the internal plantar nerve, the two outer by the deep branch of the external plantar.

Third Layer.

Flexor brevis hallucis,	Transversus pedis,
Adductor hallucis,	Flexor brevis minimi digiti.

Dissection.—The tendons of the long flexors and the muscles connected with them must be removed, to see clearly the attachments of the third layer.

The **FLEXOR BREVIS HALLUCIS** *arises* by a pointed tendinous process from the side of the cuboid, external cuneiform bone, and expanded tendon of the tibialis posticus; it is *inserted* by two heads into the outer and inner sides of the base of the first phalanx of the great toe. Two sesamoid bones are developed in the tendons of insertion of these two heads, and the tendon of the flexor longus hallucis lies in the groove between them.

Relations.—By its *superficial surface* with the abductor hallucis, tendon of the flexor longus hallucis, and plantar fascia. By its *deep surface* with the tarsal bones, metatarsal bone of the great toe, and insertion of the tendon of the peroneus longus. By its *inner border* with the abductor hallucis; and by its *outer border* with the adductor hallucis; with both of which muscles it is blended near its insertion.

Nerve-supply.—Internal plantar nerve.

The **ADDUCTOR HALLUCIS** *arises* from the cuboid bone, the sheath of the tendon of the peroneus longus, and the base of the third and fourth metatarsal bones. It is *inserted* into the base of the first phalanx of the great toe, in conjunction with the outer head of the flexor brevis hallucis.

Relations.—By its *superficial surface* with the tendons of the flexor longus and flexor brevis digitorum, flexor accessorius, and lumbricales. By its *deep surface* with the tarsal bones and ligaments, external plantar artery and veins, interossei muscles, tendon of the peroneus longus, and metatarsal bone of the great toe. By its *inner border* with the flexor brevis hallucis, with which its fibres are blended.

Nerve-supply.—External plantar.

The **TRANSVERSUS PEDIS** *arises* by fleshy slips from the inferior metatarso-phalangeal ligaments of the three outer toes, and from the transverse ligament. It passes transversely inwards to be *inserted* into the base of the first phalanx of the great toe, its tendon being blended with that of the adductor hallucis.

Relations.—By its *superficial surface* with the tendons of the flexor longus and flexor brevis digitorum, and lumbricales. By its *deep surface* with the interossei and ligaments of the metatarso-phalangeal articulations.

Nerve-supply.—External plantar.

The **FLEXOR BREVIS MINIMI DIGITI** *arises* from the base of the metatarsal bone of the little toe, and the sheath of the tendon of the peroneus longus. It is *inserted* into the base and external border of the first phalanx of the little toe.

Relations.—By its *superficial surface* with the tendons of the

flexor longus and flexor brevis digitorum, the fourth lumbricalis, abductor minimi digiti, and plantar fascia. By its *deep surface* with the plantar interosseous muscle of the fourth metatarsal space, and the fifth metatarsal bone.

Nerve-supply.—External plantar.

Fourth Layer.

Plantar interossei.

The **PLANTAR INTEROSSEI** muscles are three in number, and are placed *upon* rather than between the metatarsal bones. They *arise* from the base and inner side of the shaft of the metatarsal bone of the three outer toes, and are *inserted* into the inner side of the extensor tendon and base of the first phalanx of the same toes.

The plantar interosseous all draw towards the middle line of the *second* toe, the dorsal draw from that line; hence the former are *abductors*, the latter *adductors*. A like arrangement exists in the hand, with this difference, that the middle finger is the one through which the central line is drawn.

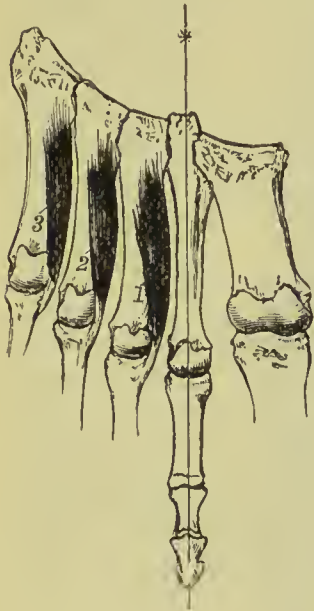


FIG. 249.—Diagram of the plantar interosseous muscles, designed to show that they are all *adductors* to the middle line of the second toe.

Actions.—The muscles of the foot correspond generally with those of the hand, and their actions are indicated by their names. It may, however, be noticed that, while the long flexor muscles are flexors of the toes, they are extensors of the foot at the ankle-joint, and in like manner the extensors of the toes are flexors of the ankle. The flexor accessorius is not represented in the hand; its use is to modify the line of action of the long flexor, so as to bring it into the direction of the middle of the foot, and of the short flexor muscle. It is probable that the adductor hallucis corresponds to the inner head of the flexor brevis pollicis of the hand, the transversus pedis being the true adductor; and the nerve-supply of these muscles furnishes confirmation of that view. The great toe has a very slight range of movement compared with the thumb, and although it has corresponding muscles, has no *opponent*

power; that is to say, it cannot be so placed as to face the other toes, as the thumb can to the fingers. The interossei and lumbricales, like those of the hand, are flexors of the first phalanges and extensors of the two last.

PART V.

ANGIOLOGY.

IN the section on Histology two sets of vessels have been described, namely, those carrying blood and those carrying lymph, and the former have further been divided into arteries, veins, and capillaries. The description of the capillaries can, however, only be satisfactorily given in connection with the organs of which they form a part, so that their arrangement and distribution will not now occupy our attention. The present section will therefore be devoted to the description of the arteries, veins, and lymphatics.

ARTERIES.

In the consideration of the arteries, the aorta will be first described, with the branches of that trunk and their subdivisions, which together constitute the efferent portion of the systemic circulation; and then the pulmonary artery as the efferent trunk of the pulmonary circulation.

AORTA.

The aorta arises from the base of the left ventricle, at the middle of the root of the heart on a level with the body of the sixth dorsal vertebra, and presents at its commencement an enlargement caused by three dilatations of the walls of the vessel, the **sinuses of Valsalva**, and corresponding with the three semilunar valves. It ascends at first forwards and to the right, then curves backwards and to the left, and descends on the left side of the vertebral column to the fourth lumbar vertebra. Hence it is divided into the arch, descending or thoracic, and abdominal aorta.

The ARCH OF THE AORTA, commencing at a point corresponding with the articulation of the cartilage of the third rib with the sternum on the left side, crosses behind and near the sternum to a point corresponding with the upper border of the articulation of the second rib with the sternum on the right side. It then curves backwards and to the left, and descends to the left side of the body

of the fifth dorsal vertebra, and at the lower border of the latter vertebra becomes the thoracic aorta.

The first or **ascending** portion of the arch, a little more than two inches in length, is almost wholly contained within the pericardium ; it extends from the third costal cartilage of the left side, to the upper border of the second cartilage of the right side, at its junction with the sternum. It has *in front* the pulmonary artery, right auricular appendix, pericardium and thymus gland ; on its *left side* the pulmonary artery ; on its *right* the right auricle and superior vena cava ; and *behind* the right pulmonary artery and veins.

The second or **transverse** portion of the arch is directed backwards and to the left, and extends from the second costal cartilage on the right side to the left side of the body of the fourth dorsal vertebra. It has *in front*, the left pleura and lung, remains of thymus gland, left phrenic nerve, left superior cardiac nerve, left inferior cardiac of the pneumogastric, left pneumogastric nerve, and left superior intercostal vein. *Behind* it is in relation with the trachea, œsophagus, thoracic duct, deep cardiac plexus, and left recurrent laryngeal nerve. *Above* it gives off the arteria innominata, left carotid and left subclavian artery, and has lying on it the left vena innominata ; and *below* is in relation with the superficial cardiac plexus, bifurcation of the pulmonary artery, cord of the ductus arteriosus, left bronchus, and left recurrent nerve.

The third or **descending** portion of the arch lies against the fifth dorsal vertebra, and is partially covered by the left pleura. It is in relation *in front* with the pleura and root of the left lung, *behind* with the body of the fifth dorsal vertebra, on the *right side* with the œsophagus and thoracic duct, and on the *left* with the pleura.

Descending Aorta.—The descending aorta is subdivided, in correspondence with the two great cavities of the trunk, into the thoracic and abdominal aorta.

Thoracic Aorta.—The thoracic aorta, commencing at the lower border and left side of the fifth dorsal vertebra, curves gently towards the right as it descends, and as it passes through the aortic opening of the diaphragm lies on the middle line of the vertebral column in front of the last dorsal vertebra.

It is in relation *behind*, with the vertebral column and lesser vena azygos ; *in front*, with the œsophagus, left pulmonary artery, left bronchus, pericardium, and right pneumogastric nerve ; to the *left side*, with the pleura, left lung, and œsophagus ; and to the *right*, with the œsophagus, vena azygos major, and thoracic duct.

Abdominal Aorta.—The aorta enters the abdomen through a special opening in the diaphragm, and, as it lies against the body of the last dorsal vertebra, receives the name of *abdominal aorta* : it passes downwards, and on the fourth lumbar vertebra, a little to the left of the middle line, divides into the two common iliac arteries. Its relations and branches will be described on a later page.

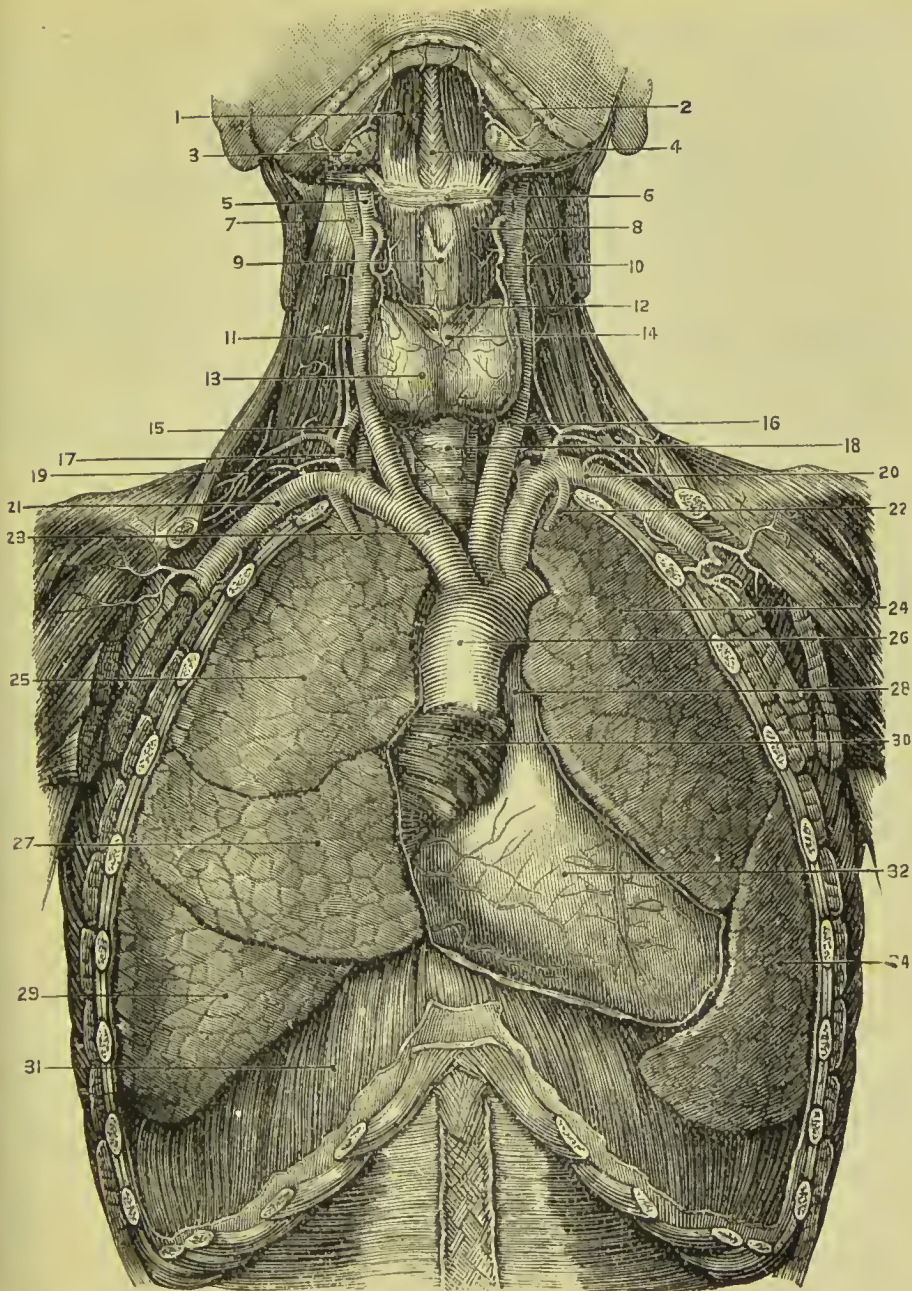


FIG. 250.—Heart and great vessels. 1. Anterior belly of digastric. 2. Submental artery. 3. Submaxillary gland. 4. Mylo-hyoid. 5. External carotid. 6. Hyoid bone. 7. Internal carotid. 8. Thyro-hyoid. 9. Thyroid cartilage. 10. Superior thyroid artery. 11. Right common carotid. 12. Crico-thyroid. 13. Thyroid body. 14. Cricoid cartilage. 15. Inferior thyroid artery. 16. Left common carotid. 17. Thyroid axis. 18. Trachea. 19. Vertebral artery. 20. Left subclavian artery. 21. Right subclavian artery. 22. Internal mammary artery. 23. Innominate artery. 24. Upper lobe of left lung. 25. Upper lobe of right lung. 26. Arch of aorta. 27. Middle lobe of right lung. 28. Pulmonary artery. 29. Lower lobe of right lung. 30. Right auricle. 31. Diaphragm. 32. Front of right ventricle. 34. Lower lobe of left lung.

Branches.—The branches of the aorta, arranged in a tabular form, are as follows :—

Arch	{	<i>ascending portion</i> , Coronary, right and left.		
	{	<i>transverse portion</i> ,	{	Innominate artery, {
				Right carotid,
				Right subclavian.
			{	
			Left carotid,	
			Left subclavian,	{
				Phrenic,
				Coeliac axis {
				Gastric,
				Hepatic,
				Splenic.
Thoracic aorta	{	Pericardiac,		
		Bronchial,		
		Oesophageal,		
		Intercostal.		
Abdominal aorta	{			Supra-renal,
				Renal,
				Superior mesenteric,
				Spermatic,
				Inferior mesenteric,
				Lumbar,
				Sacra-media,
				Common iliacs.

Varieties of the Aorta.—The aorta seldom deviates from the course and relations above described. In some few cases there is persistence of the double arch which exists in the early stages of the development of the vascular system, and in rare instances the aortic arch turns to the right side instead of the left, this being frequently accompanied by complete transposition both of the thoracic and abdominal viscera. Varieties in the primary branches of the arch are by no means uncommon. That which is by far the most frequent is the origin of the left vertebral from the arch ; next in frequency we have the origin of both carotids and the right subclavian in common from the innominate, so that the primary branches of the transverse arch are reduced to two. Occasionally there is absence of the innominate, all four branches arising directly from the arch ; in such cases the order in which the branches are generally given off is, right common carotid, left carotid, left subclavian, right subclavian, the last artery passing behind the trachea and œsophagus to reach its proper position behind the right sterno-clavicular joint.

The **CORONARY ARTERIES** arise from the two anterior of the three aortic sinuses at the commencement of the ascending portion of the arch of the aorta, immediately above the free margin of the semilunar valves.

The **left coronary** (usually the larger of the two) passes forwards, between the pulmonary artery and left auricular appendix, and divides into two branches ; one of which (posterior) winds around the base of the left ventricle in the auriculo-ventricular groove, and reaches nearly as far as the corresponding branch of the right coronary ; the other (anterior) passes along the groove of union of the two ventricles, on the anterior aspect of the heart, to its apex, giving off branches in its course to the ventricular walls. The left

coronary artery supplies the left auricle and anterior surface of both ventricles.

The **right coronary** passes forwards, between the root of the pulmonary artery and the right auricle, and runs from left to right in the auriculo-ventricular groove. It gives off a small branch which continues onwards transversely, between the left auricle and ventricle; the main trunk descends along the posterior aspect of the heart to its apex, giving off twigs which supply the posterior aspect of both ventricles.

The coronary arteries anastomose with each other on the surface of the heart, and by the branches distributed to the walls of the great vessels; but in the walls of the heart their branches are for the most part "terminal arteries," without anastomoses.

INNOMINATE ARTERY.

The innominate artery (brachio-cephalic) (Fig. 250, 23) is the first and largest artery given off by the arch of the aorta. It is an inch and a half in length, and arises from the arch behind the junction of the first and second pieces of the sternum; it ascends obliquely towards the right sterno-clavicular articulation, where it divides into the right carotid and right subclavian artery.

Plan of the **Relations** of the Innominate Artery.

In Front.

Sternum,
Sterno-hyoid muscle,
Sterno-thyroid muscle,
Remains of thymus gland,
Left brachio-cephalic vein,
Right inferior thyroid veins,
Inferior cervical cardiac branch of right vagus.

Left Side.

Remains of thymus,
Left common carotid
artery,
Left inferior thyroid
vein,
Trachea.

Right Side.

Right brachio-cephalic
vein,
Right vagus nerve,
Pleura.

Innominate Artery.

Behind.

Trachea.

The innominate artery occasionally gives off a small branch, *thyroidea ima* (lowest thyroid), which ascends along the middle of the trachea to the thyroid gland. A knowledge of its existence is important in performing the operation of tracheotomy.

COMMON CAROTID ARTERIES.

The common carotid arteries (*κάρα*, the head) arise, the *right* from the bifurcation of the innominate artery opposite the right sterno-

clavicular articulation, the *left* from the arch of the aorta. It follows, therefore, that the right carotid is shorter than the left; it is also more anterior; and, in consequence of proceeding from a branch instead of from the main trunk, is larger than its fellow.

The **right common carotid artery** (Fig. 250, 11) ascends the neck perpendicularly by the side of the trachea and larynx, from behind the right sterno-clavicular articulation to a level with the upper border of the thyroid cartilage, where it divides into the external carotid and internal carotid.

The **left common carotid** (Fig. 250, 16) passes somewhat obliquely outwards from the arch of the aorta to the side of the neck, and thence upwards by the side of the trachea and œsophagus to a level with the upper border of the thyroid cartilage, where it divides like the right common carotid into the external carotid and internal carotid.

Relations.—The common carotid artery, in the neck, is enclosed in a fibrous sheath, which also contains the internal jugular vein, lying to the outer side of the artery, and the vagus nerve, which lies between and behind both. The sheath rests on the vertebral column, having interposed the sympathetic nerve and anterior muscles of the vertebral column, and being crossed behind by the inferior thyroid artery and recurrent laryngeal nerve.

Plan of **Relations** of the Common Carotid Artery.

In Front.

Integument and fascia,
Platysma,
Superior thyroid veins,
Lingual and facial veins,
Sterno-mastoid,
Sterno-hyoid,
Sterno-thyroid,
Omo-hyoid,
Descendens cervicis nerve.

Internally.

Trachea,
Thyroid gland,
Larynx,
Pharynx,
Recurrent laryngeal nerve,
Inferior thyroid artery.

Externally.

Internal jugular vein,
Pneumogastric nerve.

Common Carotid Artery.

Behind.

Longus colli,
Rectus anticus major,
Sympathetic nerve,
Inferior thyroid artery,
Recurrent laryngeal nerve.

Additional **Relations** of the Left Common Carotid.

<i>In Front.</i>	<i>Behind.</i>	<i>Internally.</i>	<i>Externally.</i>
Left brachio-cephalic vein, Remains of thymus gland, Sternum.	Trachea, Thoracic duct.	Innominate artery, Œsophagus.	Pleura.

EXTERNAL CAROTID ARTERY.

The external carotid artery ascends nearly perpendicularly from opposite the upper border of the thyroid cartilage, to the space between the neck of the lower jaw and meatus auditorius, where it divides into two terminal branches, temporal and internal maxillary.

Plan of the **Relations** of the External Carotid Artery.*Superficial aspect.*

Integument and fascia,
Platysma,
Digastric, f. D.
Stylo-hyoid,
Hypoglossal nerve,
Facial nerve,
Temporo-maxillary vein,
Parotid gland.

**External
Carotid Artery.**

Deep aspect.

Stylo-pharyngeus,
Stylo-glossus,
Glosso-pharyngeal nerve,
Parotid gland.

Anteriorly.

Hyoid bone,
Pharynx.
Parotid gland,
Ramus of jaw.

Branches.—The branches of the external carotid, nine in number, may be arranged into three groups, anterior, posterior, and ascending. They are as follows:—

Anterior.

Superior thyroid,
Lingual,
Facial.

Posterior.

Occipital,
Posterior auricular.

Ascending and Terminal.

Ascending pharyngeal,
Parotidean,

Temporal,
Internal maxillary.

The **anterior branches** arise from the commencement of the external carotid, within a short distance of each other. The lingual and facial not unfrequently arise from a common trunk.

The **SUPERIOR THYROID ARTERY**, the first of the branches of the external carotid, arises from that trunk just below the great cornu of the hyoid bone and curves downwards to the thyroid gland. It is distributed by several large branches to the anterior part of the gland, and anastomoses with its fellow of the opposite side, and with

the inferior thyroid arteries. In its course it passes beneath the omo-hyoid, sterno-thyroid, and sterno-hyoid muscles.

Branches.—

Hyoid,
Superior laryngeal,
Sterno-mastoid.

Inferior laryngeal,
Muscular,
Glandular.

The **hyoid branch** passes forward beneath the thyro-hyoid muscle, and is distributed to the depressor muscles of the hyoid bone near their insertion. It anastomoses with its fellow of the opposite side, and with the hyoid branch of the lingual.

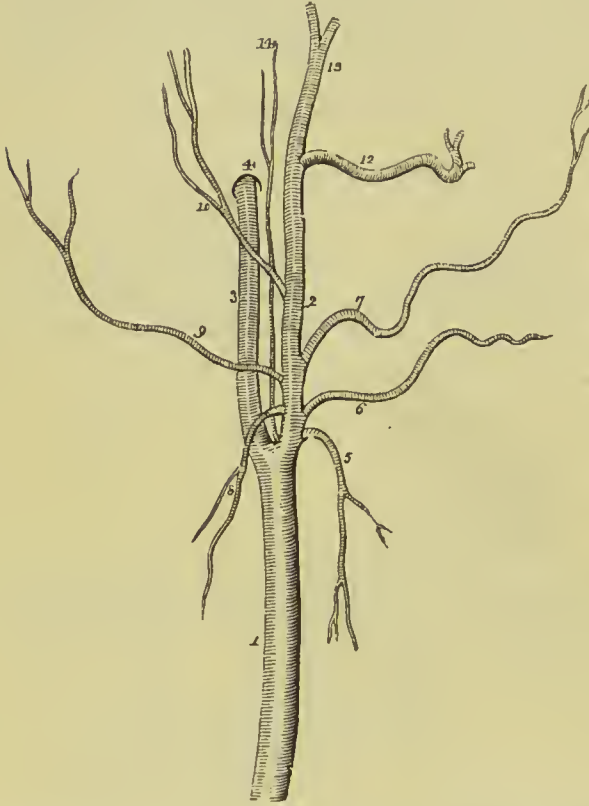

FIG. 251.—Carotid arteries with the branches of the external carotid. 1. Common carotid. 2. External carotid. 3. Internal carotid. 4. Carotid foramen in the petrous portion of the temporal bone. 5. Superior thyroid. 6. Lingual. 7. Facial. 8. Sterno-mastoid. 9. Occipital. 10. Posterior auricular. 11. Internal maxillary. 12. Temporal. 13. Ascending pharyngeal.

The **superior laryngeal** pierces the thyro-hyoid membrane, in company with the superior laryngeal nerve, and supplies the mucous membrane and muscle of the larynx, sending a branch upwards to the epiglottis.

The **sterno-mastoid** is commonly a branch of this trunk, although it sometimes comes off directly from the external carotid. It curves downwards and outwards across the carotid sheath to the anterior margin of the sterno-mastoid muscle, to which and to the neighbouring muscles and integument, it is distributed.

The **inferior laryngeal** or **crico-thyroid** is a small branch which crosses the crico-thyroid

membrane along the lower border of the thyroid cartilage. It sends branches through that membrane to supply the mucous lining of the larynx, and inosculates with its fellow of the opposite side.

The **muscular branches** are distributed to the depressor muscles of the hyoid bone and larynx.

Numerous **glandular** branches are distributed to the lateral lobe

of the thyroid gland, forming a free anastomosis in its substance with the branches of the inferior thyroid.

The **LINGUAL ARTERY** ascends obliquely from its origin; it then passes forwards parallel with the great cornu of the hyoid bone; thirdly, it ascends to the under surface of the tongue; and fourthly, runs forward in a serpentine direction to its tip, under the name of *ranine artery*, where it terminates by being distributed to the muscles and mucous membrane of the tongue.

Relations.—The *first* part of its course rests on the middle constrictor muscle of the pharynx, being covered in by the tendon of the digastric and the stylo-hyoid muscle; the *second* is situated between the middle constrictor and hyo-glossus muscle, the latter separating it from the hypoglossal nerve; in the *third* part of its course it lies between the hyo-glossus and genio-hyo-glossus; and in the fourth (*ranine*), rests on the lingualis to the tip of the tongue.

Branches.—Hyoid, Dorsalis linguæ, Sublingual, Ranine.

The **hyoid branch** runs along the upper border of the os hyoides, and is distributed to the elevator muscles of the os hyoides near

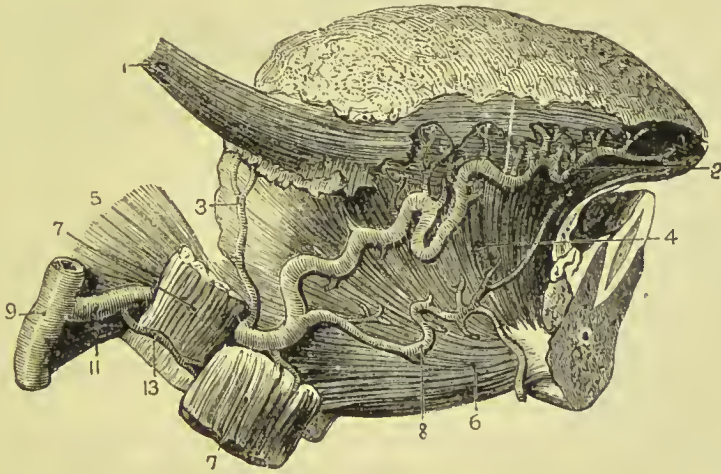


FIG. 252.—Lingual artery and branches. 1. Stylo-glossus muscle. 2. Ranine artery. 3. Dorsalis linguæ artery. 4. Genio-hyo-glossus muscle. 5. Middle constrictor. 6. Genio-hyoid muscle. 7, 7. Hyo-glossus (cut). 8. Sublingual artery. 9. External carotid artery. 11. Lingual artery. 13. Hyoid branch.

their insertion, inosculating with its fellow of the opposite side, and with the hyoid branch of the superior thyroid when that branch is present.

The **dorsalis linguæ** springs from the artery beneath the hyo-glossus; it ascends along the posterior border of the hyo-glossus muscle to the dorsum of the tongue, and is distributed to the tongue, fauces, and epiglottis; anastomosing with its fellow of the opposite side.

The **sublingual branch** runs forward on the genio-hyo-glossus muscle, and is distributed to the sublingual gland, mucous mem-

brane of the floor of the mouth, and muscles of the tongue. It is situated between the mylo-hyoid and genio-hyo-glossus, generally accompanies Wharton's duct for a part of its course, and sends a branch to the frænum linguæ. The latter branch affords the hemorrhage which sometimes follows the operation of snipping the frænum in children.

The **ranine artery** may be looked on as the true continuation of the lingual; it runs forwards beneath the tongue, resting upon the lingualis muscle, having the genio-hyo-glossus to its inner side, and is covered by mucous membrane.

It distributes numerous small branches to the substance of the tongue, but does not, as is generally stated, anastomose with its fellow of the opposite side. Hyrtle has proven by experimental injections that there is no communication between the arteries of the two sides, and this fact is substantiated by the experience of surgeons, who find that the longitudinal section of the tongue in the middle line is unaccompanied by arterial hemorrhage.

FACIAL ARTERY.—The facial artery (maxillaris externa) arises immediately above the lingual and a little above the great cornu of the hyoid bone, and passes forwards to the submaxillary gland, in which it lies embedded. It then curves around the body of the lower jaw, close to the anterior inferior angle of the masseter muscle, ascends to the angle of the mouth, and thence to the angle of the eye, where it is named *angular artery*. The facial artery is tortuous in its course over the buccinator muscle to accommodate itself to the movements of the jaw.

Relations.—Below the jaw it passes beneath the digastricus and stylo-hyoid muscles; on the body of the lower jaw it is covered by the platysma myoides, and at the angle of the mouth by the depressor anguli oris and zygomatic muscles. It rests on the submaxillary gland, lower jaw, buccinator, orbicularis oris, levator anguli oris, levator labii superioris proprius, and levator labii superioris alæque nasi.

Its *branches* may be grouped into those which are given off below the jaw, and those on the face; they may be thus arranged:—

Below the Jaw.

Ascending palatine,
Tonsillar,
Submaxillary,
Submental,
Muscular.

On the Face.

Muscular,
Buccal,
Inferior labial,
Inferior coronary,
Superior coronary,
Lateral nasal,
Angular.

The **inferior** or **ascending palatine** branch ascends between the stylo-glossus and stylo-pharyngeus muscles, to be distributed to the styloid muscles, Eustachian tube, tonsil and soft palate, and anasto-

passes with the descending palatine branch of the internal maxillary artery.

The **tonsillar** branch ascends by the side of the pharynx, and pierces the superior constrictor muscle to be distributed to the tonsil, and root of the tongue.

The **submaxillary** are four or five branches which supply the submaxillary gland.

The **submental** branch runs forward on the mylo-hyoid muscle, under cover of the body of the lower jaw, distributes branches to the submaxillary gland, and muscles attached to the lower jaw, and anastomoses with branches of the sublingual, inferior labial, and mental arteries.

The **muscular** branches beneath the jaw are distributed to the internal pterygoid, digastric, and stylo-hyoid, and those on the face to the masseter and buccinator.

The **buccal** branches, eight or ten in number, are given off upon the face, and are distributed to the buccinator, masseter, muscles of the upper lip, orbicularis palpebrarum, and integument of the cheek. They anastomose with the buccal branch of the internal maxillary, the transverse facial, and infraorbital.

The **inferior labial** branch passes forward beneath the depressor anguli oris muscle, and is distributed to the muscles of the lower lip, inosculating with the labial branch of the inferior dental, the inferior coronary, and submental. It is frequently derived from the next branch.

The **inferior coronary** branch is given off at the angle of the mouth, and passes inwards near the edge of the lower lip, lying between the orbicularis and mucous membrane: it inosculates with its fellow of the opposite side.

The **superior coronary** branch, arising close to, or in common with, the preceding, takes its course in the same manner along the upper lip, inosculating with its fellow of the opposite side. At the middle of the lip it sends a small branch upwards to the septum of the nose (arteria septi).

The **lateral nasal** branch is given off near the ala nasi, and passes beneath the levator labii superioris alæque nasi, to be distributed to the nose. It inosculates with the nasal branch of the ophthalmic artery, the infraorbital, and its fellow of the opposite side.

The **angular** is the termination of the facial artery; it inosculates at the inner side of the orbit with the nasal branch of the ophthalmic artery.

The **inosculations** of the facial artery are numerous—namely, with the sublingual branch of the lingual, ascending pharyngeal artery, descending palatine artery, inferior dental at its escape from the mental foramen, infraorbital at the infraorbital foramen, buccal branches of the internal maxillary on the surface of the buccinator, transverse facial on the side of the face, and nasal and frontal branches of the ophthalmic artery at the angle of the eye.

The facial artery is subject to variety in length: it not unfre-

quently terminates at the angle of the nose or mouth, and is rarely symmetrical on both sides of the face.

The **OCCIPITAL ARTERY**, smaller than the anterior branches, passes backwards behind the parotid gland and beneath the posterior belly of the digastric, trachelo-mastoid, and sterno-mastoid to the occipital groove in the mastoid portion of the temporal bone. It then ascends between the splenius and complexus, pierces the trapezius, and is distributed to the back of the head, anastomosing with the opposite occipital, posterior auricular, and temporal arteries. The hypoglossal nerve curves around this artery opposite the angle of the jaw and near its origin from the external carotid. The occipital artery is sometimes derived from the ascending cervical of the thyroid axis, or from the internal carotid.

Branches.—It gives off several muscular branches to the sterno-mastoid, digastric, stylo-hyoid, and deep muscles in its course, a small branch to the external ear, and two larger branches, *inferior meningeal* and *princeps cervicis*.

The **inferior meningeal** ascends by the side of the internal jugular vein, and passes through the jugular foramen, to be distributed to the dura mater.

The **arteria princeps cervicis** is a large and irregular branch. It descends the neck between the complexus and semi-spinalis colli, and inosculates with the deep cervical of the subclavian and with branches of the vertebral. This branch is the means of establishing an important collateral circulation between the branches of the carotid and subclavian, after ligature of the common carotid artery.

A small **mastoid** branch enters the skull through the mastoid foramen, and is distributed to the dura mater.

The **POSTERIOR AURICULAR ARTERY** arises from the external carotid, above the level of the digastric and stylo-hyoid muscles, and ascends by the side of the styloid process and behind the parotid gland, to the back part of the concha. It is distributed by two branches to the external ear (**auricular** branch), and side of the head (**occipital** branch), anastomosing with the occipital and temporal artery; some of its branches pass through fissures in the fibro-cartilage to reach the anterior surface of the pinna.

Branches.—The posterior auricular gives off a branch to the digastric muscle, and several branches to the parotid gland; it then gives off the **stylo-mastoid**, which enters the stylo-mastoid foramen to be distributed to the aquæductus Fallopii, labyrinth, mastoid cells, and tympanum; a twig accompanies the chorda tympani under the name of tympanica superior. One branch of the stylo-mastoid artery forms with the anterior tympanic artery an anastomotic circle round the drum of the ear.

The **ASCENDING PHARYNGEAL ARTERY**, the smallest of the branches of the external carotid, arises from that trunk near its origin (or at the point of bifurcation of the common carotid), and ascends to the base of the skull.

This artery has *behind* it, the vertebral column, rectus anticus major muscle, and superior laryngeal nerve; in *front*, the stylo-pharyngeus muscle; on the *inner side*, the pharynx; on the *outer side*, the internal carotid artery and superior cervical ganglion of the sympathetic.

Its **branches** are :—

Pharyngeal, Prevertebral, Meningeal.

The **pharyngeal** branches are distributed to the muscles and mucous membrane of the pharynx, extending upwards to the soft palate, tonsils, and Eustachian tube, and downwards nearly to the commencement of the œsophagus.

The **prevertebral** branch pierces the prevertebral fascia and is distributed to the rectus anticus muscles, superior cervical ganglion of the sympathetic, and ninth, tenth, and eleventh pairs of nerves. It anastomoses with the ascending cervical artery.

The **inferior meningeal** branches pass through the jugular foramen or anterior condylar foramen, and often through the fibrous tissue closing the middle lacerated foramen; they end in the dura mater.

The **PAROTIDEAN ARTERIES** are four or five large branches which are given off from the external carotid whilst in the parotid gland. They are distributed to the structure of the gland, their terminal branches reaching the integument of the side of the face, and masseter muscle.

The **TEMPORAL ARTERY** is one of the two terminal branches of the external carotid. It ascends over the root of the zygoma; and at about an inch and a half above the zygomatic arch, divides into an *anterior* and *posterior temporal* branch. The **anterior temporal** is distributed over the front of the temple and arch of the skull, and anastomoses with the opposite anterior temporal and with the supraorbital and frontal artery. The **posterior temporal** curves upwards and backwards, and inosculates with its fellow of the opposite side, with the posterior auricular and occipital arteries.

The trunk of the temporal artery is covered by the parotid gland and attrahens auriculam muscle, and rests on the temporal fascia.

The **branches** of the temporal artery are—some small offsets to the parotid gland and articulation of the lower jaw, and the following :—

Anterior auricular, Transverse facial,
Middle temporal.

The **anterior auricular branches**, two in number, are distributed to the anterior portion of the pinna.

The **transverse facial** arises from the temporal immediately below the zygoma, and runs transversely across the face, resting on the masseter muscle, and lying parallel with and a little above Stenson's duct. It anastomoses with the facial and infraorbital arteries.

The **middle temporal branch** passes through an opening in the temporal fascia immediately above the zygoma into the substance of the temporal muscle, and sends small branches to that muscle, inosculating with the deep temporal arteries. It gives off a small **orbital branch** which passes forward immediately above the zygoma, between the two layers of the temporal fascia, and inosculates beneath the orbicularis palpebrarum, with the lachrymal branch of the ophthalmic artery.

The **INTERNAL MAXILLARY ARTERY**, the other terminal branch of the external carotid, has next to be examined.

Dissection.—The internal maxillary artery passes inwards behind the neck of the lower jaw to the deep structures in the face; we require, therefore, to remove several parts for the purpose of seeing it completely. To obtain a good view of the vessel, the zygoma should

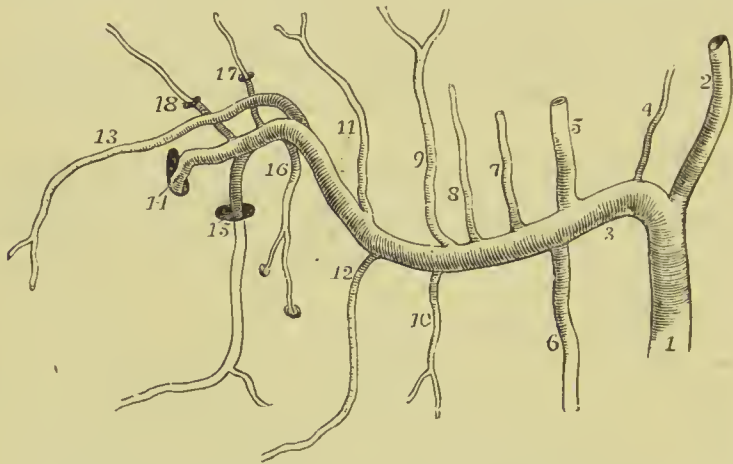


FIG. 253.—Diagram of the branches of the internal maxillary artery. 1. External carotid. 2. Superficial temporal. 3. Internal maxillary. 4. Anterior tympanic. 5. Middle meningeal. 6. Inferior dental. 7. Lesser meningeal. 8. Masseteric. 9. Posterior temporal. 10. Pterygoid. 11. Anterior temporal. 12. Buccal. 13. Infraorbital. 14. Spheno-palatine. 15. Descending palatine. 16. Superior dental. 17. Vidian. 18. Pterygo-palatine.

be sawn across in front of the external ear, and the malar bone near the orbit. Turn down the zygomatic arch with the masseter muscle. In doing this, a small artery and nerve will be seen crossing the sigmoid notch of the lower jaw to enter the masseter muscle (masseteric). Saw through the ramus of the jaw on a level with the crowns of the molar teeth, and divide the neck of the condyle with cutting forceps, then turn the coronoid process with the insertion of the temporal muscle upwards towards the skull; some vessels will be seen entering the under surface of the muscle; these are the *deep temporal*. If the artery lies beneath the external pterygoid muscle, it will be necessary to disarticulate the condyle of the jaw and turn it inwards, together with the muscle itself. The artery and the deep branches of the inferior maxillary nerve will be seen lying against the internal

pterygoid muscle. These are to be carefully freed from fat and areolar tissue, and then examined.

The internal maxillary artery commences in the substance of the parotid gland, opposite the meatus auditorius externus; it passes in the first instance horizontally forward behind the neck of the lower jaw; next, curves around the lower border of the external pterygoid muscle near its insertion, and ascends obliquely forwards upon the outer side of that muscle; it then passes inwards between the two heads of the external pterygoid, and enters the spheno-maxillary fossa. Occasionally it takes its course between the two pterygoid muscles, without appearing on the outer surface of the external pterygoid. For the purposes of description it admits of division into three portions: maxillary, pterygoid, and spheno-maxillary.

Relations.—The *maxillary* portion is situated between the neck of the jaw and the internal lateral ligament and inferior dental nerve, and lies parallel with the auriculo-temporal nerve; the *pterygoid* portion between the external pterygoid muscle, and the masseter and temporal muscle, or between the two pterygoid muscles. The *spheno-maxillary* portion lies between the two heads of the external pterygoid muscle, and, in the spheno-maxillary fossa, is in relation with Meckel's ganglion.

Branches.—*Maxillary Portion.*

Anterior tympanic,
Inferior dental,
Middle meningeal,
Lesser meningeal.

Pterygoid Portion.

Deep temporal,
Pterygoid,
Masseteric,
Buccal.

Spheno-maxillary Portion.

Superior dental,
Infra-orbital,
Pterygo-palatine,

Spheno-palatine,
Descending palatine,
Vidian.

The **anterior tympanic** branch passes into the tympanum through the fissure of Glaser, and is distributed to the cavity of the tympanum and membrana tympani; on the latter it inoscules with the stylo-mastoid branch of the posterior auricular artery, and with the Vidian artery. It gives off an auricular branch to the lining membrane of the external auditory meatus and outer surface of the drum of the ear.

The **inferior dental** descends to the dental foramen, and enters the canal of the lower jaw in company with the inferior dental nerve. Opposite the bicuspid teeth it divides into two branches, one of which is continued onwards within the bone as far as the symphysis, to supply the incisor teeth; while the other, *mental*, escapes with the nerve at the mental foramen, and anastomoses with the inferior labial and submental branches of the facial. It supplies the alveoli and teeth of the lower jaw, sending small branches along the canals in their roots. At the inferior dental foramen, it gives off a *mylo-hyoid* branch, which accompanies the mylo-hyoid nerve.

The **middle meningeal** is embraced at its origin by the two roots of the auriculo-temporal nerve; it ascends behind the temporo-maxillary articulation to the foramen spinosum in the spinous process of the sphenoid bone, and entering the cranium, divides into an anterior and a posterior branch. The *anterior branch* crosses the great ala of the sphenoid to the groove or canal in the anterior inferior angle of the parietal bone, and divides into branches which ramify on the external surface of the dura mater, and anastomose with corresponding branches from the opposite side. The *posterior branch* crosses the squamous portion of the temporal bone, to the posterior part of the dura mater and cranium.

The branches of the middle meningeal artery are distributed chiefly to the bones of the skull; in the middle fossa it sends a small petrosal branch through the hiatus Fallopii to the facial nerve, and branches to the Gasserian ganglion.

The **lesser meningeal** is a small branch which ascends to the foramen ovale, and passes into the skull to be distributed to the Gasserian ganglion and dura mater. It gives off a twig to the nasal fossæ and soft palate.

The lesser meningeal is often derived from the middle, instead of from the internal maxillary directly;—the tympanic also occasionally springs from the same trunk.

The **muscular branches** are distributed, as their names imply, to the five muscles of the maxillary region; the *deep temporal* branches are two in number, anterior and posterior; they inosculate with the middle and superficial temporal. The *pterygoid* branches are distributed to the two muscles of that name. The *masseteric* artery passes outwards, behind the tendon of the temporal muscle and over the sigmoid notch, to the masseter muscle. The *buccal* branch, arising opposite the anterior part of the pterygoid muscle, passes downwards with the buccal nerve to the buccinator muscle. It inosculates with the facial and transverse facial arteries.

The **superior dental or alveolar artery** is given off from the internal maxillary, just as that vessel is about to make its turn inwards to reach the speno-maxillary fossa. It descends on the tuberosity of the superior maxillary bone, and sends its branches through several small foramina to supply the posterior teeth of the upper jaw, and the antrum. The terminal branches are continued forwards on the alveolar process, to be distributed to the gums and sockets of the teeth.

The **infraorbital** appears, from its size, to be the proper continuation of the artery. It runs along the infraorbital canal with the superior maxillary nerve, sending branches upwards into the orbit, and downwards, through canals in the bone, to supply the mucous membrane of the antrum and the teeth of the upper jaw, and emerges on the face at the infraorbital foramen. The branch which supplies the incisor teeth is the *anterior dental artery*; on the face the infraorbital inosculates with the facial and transverse facial arteries.

The **pterygo-palatine** is a small branch which passes backwards through the pterygo-palatine canal, and supplies the mucous membrane of the posterior part of the nares, upper part of the pharynx, Eustachian tube, and sphenoidal cells.

The **spheno-palatine**, or posterior nasal, enters the superior meatus of the nose through the spheno-palatine foramen, in company with the nasal filaments of Meckel's ganglion, and divides into two branches; one branch, *arteria septi*, is distributed to the mucous membrane of the septum, and inosculates in the anterior palatine canal with the terminal branch of the descending palatine; the other supplies the mucous membrane of the lateral wall of the nares, antrum, and sphenoid and ethmoid cells.

The **descending palatine artery** descends along the posterior palatine canal, in company with the palatine branches of Meckel's ganglion, to the posterior palatine foramen; it then bends forward, lying in a groove of the bone, and is distributed to the palate. While in the posterior palatine canal it sends several twigs backwards through the small posterior palatine foramina to supply the soft palate; anteriorly it gives off a branch, **anterior palatine**, which reaches the nares through the anterior palatine canal, and inosculates with the *arteria septi*.

The **Vidian** or **pterygoid** branch passes backwards along the pterygoid canal with the nerve of the same name, and is distributed to the sheath of the nerve, the Eustachian tube, and mucous membrane of the upper part of the pharynx.

INTERNAL CAROTID ARTERY.

The internal carotid artery curves slightly outwards from the bifurcation of the common carotid, and ascends nearly perpendicularly by the side of the pharynx, to the carotid foramen in the petrous portion of the temporal bone. It next passes *inwards*, along the carotid canal, *forwards* by the side of the sella turcica, and *upwards* by the anterior clinoid process, where it pierces the dura mater, and divides into three terminal branches. The course of this artery is remarkable for the number of angular curves which it forms; one or two of these flexures are sometimes seen in the cervical portion, near the base of the skull; and, by the side of the sella turcica, it resembles the italic letter *s*, placed horizontally.

Relations.—In consideration of its connections, the artery is divisible into a cervical, petrous, cavernous, and cerebral portion.

Plan of the **Relations** of the *Cervical Portion* of the Internal Carotid Artery.

In Front.

Parotid gland,
Stylo-glossus,
Stylo-pharyngeus,
Stylo-hyoid ligament,
Glosso-pharyngeal nerve.

<i>Internally.</i> Pharynx, Superior laryngeal nerve, Tonsil, Ascending pharyngeal artery.	Internal Carotid Artery.	<i>Externally.</i> Internal jugular vein, Glosso-pharyngeal, Pneumogastric, Hypoglossal nerve.
---	-------------------------------------	--

Behind.

Pharyngeal nerve,
Superior laryngeal nerve,
Superior cervical ganglion,
Rectus anticus major.

The **PETROUS PORTION** is separated from the bony wall of the carotid canal by a periosteal lining derived from the dura mater; it is in relation with the carotid plexus, and is covered in by the Gasserian ganglion.

The **CAVERNOUS PORTION** is situated in the cavernous sinus, and is in relation by its inner side with the lining membrane of the sinus, and by its outer side with the sixth nerve.

The **CEREBRAL PORTION** of the artery is enclosed in a sheath of the arachnoid, and is in relation with the optic nerve. At its point of division it is situated in the fissure of Sylvius.

Branches.—The cervical portion of the internal carotid gives off no branches: from the other portions are derived the following:—

<i>From the Petrous portion.</i>	Tympanic.
<i>From the Cavernous portion.</i>	{ Arteriæ receptaculi, Ophthalmic.
<i>From the Cerebral portion.</i>	{ Anterior cerebral, Middle cerebral or Sylvian, Posterior communicating, Anterior choroid.

The **TYMPANIC** is a small branch given off in the carotid canal; it enters the tympanum and inosculates with the tympanic branch of the internal maxillary, and with the stylo-mastoid artery.

The **ARTERIÆ RECEPTACULI** *anterior* and *posterior* are two small branches given off in the cavernous sinus and distributed to the parts contained in the sinus, to the Gasserian ganglion, and dura mater.

The **OPHTHALMIC ARTERY** arises from the internal carotid, just as that vessel pierces the dura mater, and enters the orbit through the optic foramen, lying externally to the optic nerve. It then crosses the optic nerve to the inner wall of the orbit; and runs along the lower border of the superior oblique muscle, to the inner angle of the eye, where it divides into two terminal branches, frontal and nasal.

Branches.—The branches of the ophthalmic artery, ten in number, may be arranged into two groups: first, those distributed to the orbit and surrounding parts; and, secondly, those which supply the muscles and globe of the eye. They are:—

Orbital Group.

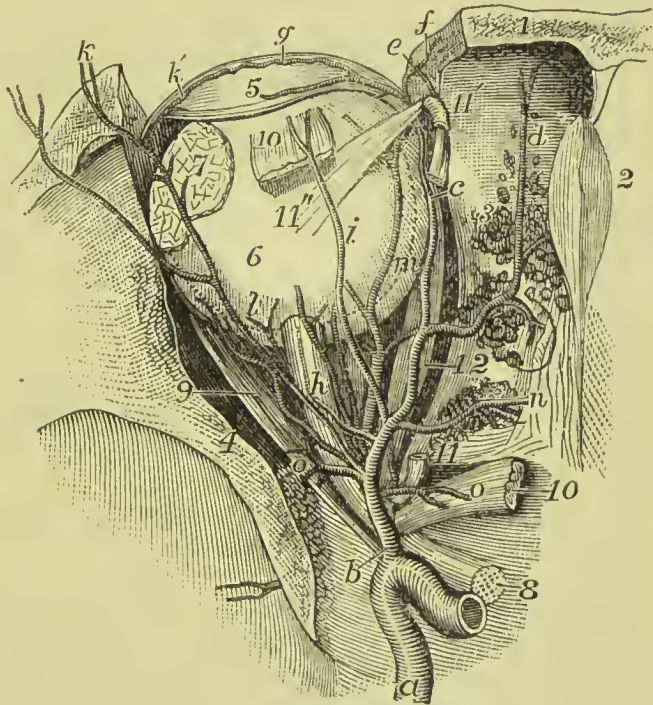
Lachrymal,
Supraorbital,
Posterior ethmoidal,
Anterior ethmoidal,
Palpebral,
Frontal,
Nasal.

Ocular Group.

Muscular,—anterior ciliary,
Ciliary, short and long,
Arteria centralis retinae.

The **lachrymal** is the first branch of the ophthalmic artery, and is usually given off immediately before that artery enters the optic foramen. It follows the course of the lachrymal nerve, above the

FIG. 254.—Distribution of the ophthalmic artery. 1. Frontal bone. 2. Crista galli. 3. Cribriform plate. 4. Lesser wing of sphenoid. 5. Upper eyelid. 6. Eyeball. 7. Lachrymal gland. 8. Optic nerve. 9. External rectus muscle. 10, 10. Cut ends of superior rectus. 11. Origin of superior oblique. 11'. Pulley for its tendon. 11''. Insertion of tendon. 12. Internal rectus. a. Internal carotid artery. b. Ophthalmic. c. Terminal branch dividing into (e) Nasal and (f) Frontal. d. Anterior ethmoidal. g. Palpebral. h. Central artery of retina. i. Supraorbital. k. Lachrymal. k'. Palpebral branch of lachrymal. l. Short ciliary. m. Long ciliary. n. Posterior ethmoidal.



upper border of the external rectus muscle, and is distributed to the lachrymal gland. The small branches which escape from the gland supply the conjunctiva and upper eyelid. The lachrymal artery gives off a *malar branch* which passes through the malar bone into the temporal fossa, and inosculates with the deep temporal arteries, while some of its branches become subcutaneous on the cheek, and anastomose with the transverse facial.

The **supraorbital artery** follows the course of the frontal nerve, resting on the levator palpebræ muscle; it passes through the supraorbital foramen, and divides into a superficial and deep branch, which are distributed to the muscles and integument of the fore-

head, and to the pericranium. At the supraorbital foramen it sends a branch inwards to the diploë.

The **ethmoidal arteries** *posterior* and *anterior* pass through the internal orbital foramina, and are distributed to the falx cerebri and to the ethmoidal cells and nasal fossæ. The latter accompanies the nasal nerve, and sends a branch to the frontal sinus. The branches distributed to the dura mater are called *anterior meningeal*.

The **palpebral arteries** *superior* and *inferior* are given off from the ophthalmic, near the inner angle of the orbit; they encircle the eyelids, forming a superior and an inferior arch near the borders of the lids, between the orbicularis palpebrarum and tarsal cartilage. At the outer angle of the eyelids, the superior palpebral inosculates with the orbital branch of the temporal artery. The inferior palpebral artery sends a branch to the caruncula lachrymalis and lachrymal sac.

The **frontal artery**, one of the terminal branches of the ophthalmic, emerges from the orbit at its inner angle, and ascends along the middle of the forehead. It is distributed to the integument, muscles, and pericranium, and anastomoses with the supraorbital artery.

The **nasal artery**, the other terminal branch of the ophthalmic, passes out of the orbit above the tendo oculi, and divides into two branches; one of which inosculates with the angular artery, while the other, *dorsalis nasi*, runs along the ridge of the nose, and is distributed to the integument of that organ. The nasal artery sends a small branch to the lachrymal sac.

The **muscular branches**, usually two in number, *superior* and *inferior*, supply the muscles of the orbit; and at the anterior part of the globe of the eye give off the *anterior ciliary* arteries, which pierce the sclerotic near its margin of connection with the cornea, and are distributed to the iris.

The **ciliary arteries** are divisible into three groups, short, long, and anterior.

The **short ciliary**, from ten to fifteen in number, pierce the sclerotic around the entrance to the optic nerve, and supply the choroid coat and ciliary processes. The *long ciliary*, two in number, pierce the sclerotic at opposite sides of the globe of the eye, and pass forwards between it and the choroid to the iris. They form an arterial circle around the circumference of the iris by inosculating with each other, and from this circle branches are given off which ramify in the substance of the iris, and form a second circle around the pupil.

The **arteria centralis retinae** pierces the optic nerve obliquely, about a quarter of an inch from the globe of the eye, and passes forwards in the centre of its cylinder to the retina, where it divides into branches, which ramify in the inner layer of that membrane. It supplies the retina and hyaloid membrane. In the fœtus a small branch of this artery is seen to run through the centre of the vitreous humour to the posterior surface of the lens; it is, however, commonly absent in the adult.

The **ANTERIOR CEREBRAL ARTERY** passes forwards in the great longitudinal fissure between the two hemispheres of the brain ; then curves backwards along the corpus callosum to its posterior extremity. Near its commencement it gives off **medullary branches** which pierce the anterior perforated space to be distributed to the anterior extremity of the caudate nucleus of the corpus striatum ; at its termination it gives off a branch to the corpus callosum. The two anterior cerebral arteries are connected soon after their origin by a short anastomosing trunk, the *anterior communicating artery*.

The **MIDDLE CEREBRAL ARTERY**, or **Sylvian artery**, larger than the preceding, passes outwards along the fissure of Sylvius, and divides into branches, which supply the anterior and middle lobes of the brain, and the island of Reil. It gives off **medullary branches** which pass through the substantia perforata to the back part of the caudate nucleus, the lenticular nucleus and neighbouring part of the thalamus opticus.

The **POSTERIOR COMMUNICATING ARTERY**, variable in size, sometimes double, and sometimes altogether wanting, passes backwards and inosculates with the posterior cerebral, a branch of the basilar artery. Occasionally it is so large as to take the place of the posterior cerebral artery.

The **ANTERIOR CHOROID** is a small branch which is given off from the internal carotid, near the origin of the posterior communicating artery, and passes beneath the edge of the middle lobe of the brain to enter the descending cornu of the lateral ventricle. It is distributed to the choroid plexus, and to the walls of the middle cornu.

A more minute description of the arteries of the brain, their communications and distribution, will be given along with the descriptive anatomy of that organ in Part VI. of this work.

SUBCLAVIAN ARTERY.

The subclavian artery on the right side arises from the innominate artery, opposite the sterno-clavicular articulation ; on the left, from the arch of the aorta. The right is consequently shorter than the left, and situated nearer the anterior wall of the chest ; it is also somewhat greater in diameter, from being a branch of a branch, in place of a division from the main trunk. On both sides the artery terminates at the lower border of the first rib, being there continued into the axillary artery.

The course of the subclavian artery is divisible, for the sake of precision and surgical observation, into three portions ; the scalenus anticus forming the means of division. The first portion of the right and left arteries differs in its course and relations in correspondence with the dissimilarity of origin above referred to. The other two portions are alike on both sides.

The *first portion*, on the *right side*, ascends obliquely outwards to the inner border of the scalenus anticus. On the *left side* it ascends

perpendicularly to the inner border of that muscle. The *second portion* curves outwards behind the scalenus anticus; the *third portion* passes downwards and outwards from the outer edge of the scalenus anticus to the lower border of the first rib, where it becomes the axillary artery.

Plan of the **Relations** of the *First Portion* of the *Right* Subclavian Artery.

In Front.

Skin, superficial fascia,
Platysma and deep fascia,
Clavicular part of sternomastoid,
Sterno-thyroid,
Sterno-hyoid,
Internal jugular vein,
Vertebral vein,
Pneumogastric nerve,
Phrenic nerve,
Cardiac nerves.

**Right
Subclavian Artery.**

Behind and Beneath.
Pleura,
Recurrent laryngeal nerve,
Sympathetic nerve,
Longus colli muscle,
Transverse process of
7th cervical vertebra.

Plan of the **Relations** of the *First Portion* of the *Left* Subclavian Artery.

In Front.

Sterno-thyroid and sterno-hyoid,
Sterno-mastoid,
Pleura,
Internal jugular and vertebral veins,
Innominate vein,
Pneumogastric nerve,
Cardiac nerves,
Phrenic nerve.

Inner Side.

Left carotid artery,
Trachea,
Œsophagus,
Thoracic duct.

**Left
Subclavian Artery.**

Outer Side.
Pleura.

Behind.

Œsophagus,
Thoracic duct,
Inferior cervical ganglion,
Longus colli,
Vertebral column.

Plan of the **Relations** of the *Second Portion* of the Subclavian Artery.

In Front.

Skin and superficial fascia,
Platysma and deep fascia,
Sterno-mastoid,
Sclenus anticus.


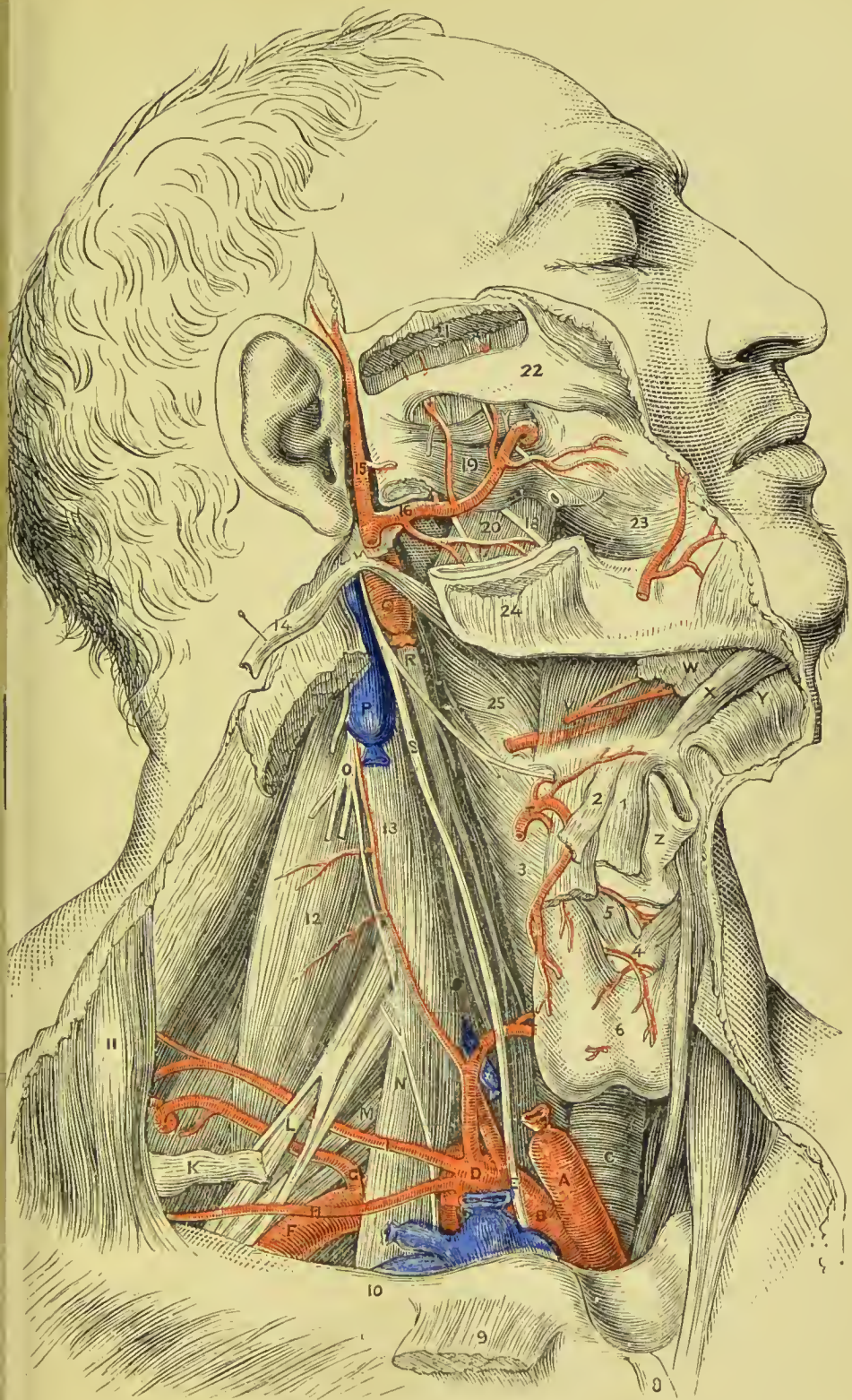



PLATE 22.

DEEP DISSECTION OF HEAD AND NECK.

- A. Right common carotid (cut).
- B. Right subclavian.
- C. Trachea.
- D. Thyroid axis.
- E. Vagus nerve, crossing subclavian artery.
- F. Subclavian artery, third part.
- G. Posterior scapular artery, arising from third part of subclavian.
- H. Supra-scapular artery.
- I. Superficialis colli artery.
- K. Posterior belly of omo-hyoid.
- L. Median nerve, branch of brachial plexus.
- M. Brachial plexus.
- N. Scalenus anticus, with phrenic nerve lying on it.
- O. Cervical plexus.
- P. Upper part of internal jugular vein.
- Q. Upper part of internal carotid artery.
- R. Superior cervical ganglion of sympathetic.
- S. Upper part of vagus nerve.
- T. Superior thyroid artery.
- V. Hyo-glossus muscle covering lingual artery.
- W. Sublingual gland.
- X. Genio-hyoid muscle.
- Y. Mylo-hyoid muscle (turned down).
- Z. Thyroid cartilage.
 1. Sterno-hyoid muscle.
 2. Omo-hyoid muscle.
 3. Inferior constrictor of pharynx.
 4. Cricoid cartilage.
 5. Crico-thyroid muscle.
 6. Thyroid body.
 7. Inferior thyroid artery.
 8. Sternal origin of sterno-mastoid.
 9. Clavicular origin of sterno-mastoid.
 10. Clavicle.
 11. Trapezius.
 12. Scalenus medius.
 13. Rectus capitis anticus major.
 14. Stylo-hyoid muscle (turned back).
 15. Temporal artery.
 16. Internal maxillary artery.
 17. Inferior dental nerve.
 18. Lingual branch of 5th nerve.
 19. External pterygoid muscle.
 20. Internal pterygoid muscle.
 21. Temporal muscle (cut).
 22. Zygomatic arch.
 23. Buccinator.
 24. Masseter.
 25. Middle constrictor of pharynx.





Above.
Brachial plexus.

Subclavian Artery.
Second Portion.

Below.
Pleura.

Behind.

Scalenus medius,
First dorsal nerve.

The *third portion* of the artery is situated in the subclavian triangle, and is more superficial than the rest.

Plan of the **Relations** of the *Third Portion* of the Subclavian Artery.

Above.

Brachial plexus,
Omo-hyoid.

In Front.

Integument and superficial fascia,
Platysma and deep fascia,
External jugular vein,
Supraclavicular nerves,
Suprascapular vessels,
Clavicle,
Subclavius.

Subclavian Artery.
Third Portion.

Behind.
Scalenus medius.

Below.

First rib,
Subclavian vein.

Branches.—The branches of the subclavian artery are four, and sometimes five, in number. Three are given off by the *first portion* of the artery; one, the superior intercostal, by the *second portion*; when a fifth artery exists, it arises from the third portion, and is the posterior scapular. So frequent is the occurrence of this variation, that many anatomists consider it to be the normal condition. In a tabular form the branches are as follows:—

Vertebral,	
Internal mammary,	
Thyroid axis,	{
	Inferior thyroid,
	Suprascapular, or transversalis humeri,
	Transversalis colli.
Superior intercostal,—Deep cervical.	

The **VERTEBRAL ARTERY**, the first and largest of the branches of the subclavian artery, arises from the posterior aspect of that trunk; it ascends through the foramina in the transverse processes of all the cervical vertebræ, excepting the last; then winds backwards around the articulating process of the atlas; and, piercing

the dura mater, enters the skull through the foramen magnum. The two arteries unite at the lower border of the pons Varolii, to form the **basilar artery**. At its origin the artery is behind the internal jugular vein, and as it ascends comes to be placed between the scalenus anticus and longus colli muscles; on the left side, it is crossed by the thoracic duct. In the foramina of the transverse processes of the vertebræ the artery lies in front of the cervical nerves, and has the vertebral vein in front of it. The sub-occipital nerve passes out beneath it where it lies on the groove of the atlas. As it enters the cranium the vertebral artery is placed between the hypoglossal nerve and the anterior root of the sub-occipital nerve, beneath the first process of the ligamentum denticulatum; it next winds round the medulla and lies between it and the basilar portion of the occipital bone. If the two arteries differ in size, the left is generally the larger.

The **basilar artery** formed by the union of the two vertebrals is so named from its position at the base of the brain; it runs forward in the groove on the midline of the pons Varolii, and at the anterior border of the pons divides into four terminal branches, two to each side.

Branches.—The branches of the **vertebral artery** are the following:—

Lateral spinal,	Anterior spinal,
Muscular, or Sub-occipital,	Posterior spinal,
Posterior meningeal,	Posterior inferior cerebellar.

The **lateral spinal branches** enter the intervertebral foramina, and taking the course of the roots of the spinal nerves, reach the spinal canals, where each divides into two branches, one to be distributed to the spinal cord, anastomosing with the other spinal arteries, and the second branch passing to the body of the vertebra.

The **muscular or sub-occipital branches** are distributed to the deep muscles of the neck, as the vertebral artery curves round the articular process of the atlas; they anastomose with the deep cervical and occipital arteries.

The **posterior meningeal** are one or two small branches which enter the cranium through the foramen magnum, to be distributed to the dura mater of the cerebellar fossæ, and to the falx cerebelli.

The **anterior spinal** is a small branch which unites with its fellow of the opposite side on the front of the medulla oblongata. The artery formed by the union of these two vessels descends along the anterior aspect of the spinal cord, to which it distributes branches; they anastomose with the other spinal arteries.

The **posterior spinal** winds around the medulla oblongata to the posterior aspect of the cord, and descends on each side to the cauda equina. It communicates very freely with the spinal branches of the intercostal and lumbar arteries, and near its origin sends a branch upwards to the fourth ventricle.

The **posterior inferior cerebellar arteries** wind around the

upper part of the medulla oblongata to the under surface of the cerebellum, to which they are distributed. They pass between the filaments of origin of the hypoglossal nerve in their course, and anastomose with the superior cerebellar arteries.

The branches of the **basilar artery** are :—

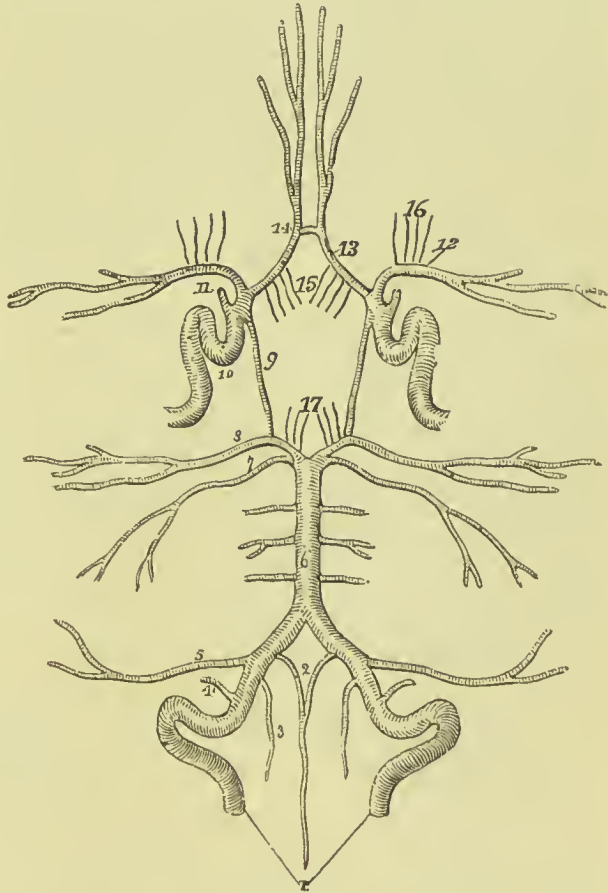
Transverse, Superior cerebellar, Posterior cerebral.

The **transverse** branches of the basilar artery supply the pons Varolii and adjacent parts of the brain. One of these branches,

FIG. 255.—Circle of Willis.

The arteries being symmetrical have references on one side only.

1. Vertebral arteries.
2. Anterior spinal branches uniting to form a single vessel.
3. Posterior spinal artery.
4. Posterior meningeal.
5. Posterior inferior cerebellar.
6. Basilar artery giving off transverse branches.
7. Superior cerebellar artery.
8. Posterior cerebral.
9. Posterior communicating branch of the internal carotid.
10. Internal carotid artery, showing its curves within the skull.
11. Ophthalmic artery divided across.
12. Middle cerebral artery.
13. Anterior cerebral arteries, connected by,
- 14, Anterior communicating artery.
15. Medullary branches of anterior cerebral.
16. Medullary branches of middle cerebral.
17. Medullary branches of posterior cerebral.



larger than the rest, receives the name of **anterior inferior cerebellar** artery ; it passes along the crus cerebelli to be distributed to the anterior border of the cerebellum, and anastomoses with the inferior cerebellar of the vertebral. Another small branch of the basilar is known as the **auditory artery** ; it accompanies the facial and auditory nerves into the meatus auditorius internus, and is distributed to the internal ear.

The **superior cerebellar** arteries, two of the terminal branches of the basilar, wind around the crus cerebri on each side, lying in relation with the fourth nerve, and are distributed to the upper surface of the cerebellum, inosculating with the inferior cerebellar.

The **posterior cerebral arteries**, the other two terminal branches of the basilar, wind around the crus cerebri at each side, and are distributed to the posterior lobes of the cerebrum. They are separated from the superior cerebellar arteries near their origin, by the third pair of nerves, and are in close relation with the fourth pair in their course around the crura cerebri. Anteriorly, near their origin, they give off a tuft of small *medullary* vessels which enter the locus perforatus to supply the optic thalamus and corpora quadrigemina. They receive the posterior communicating arteries from the internal carotid, and send a branch called *posterior choroid*, to the velum interpositum and choroid plexus.

The communications established between the anterior cerebral arteries in front, and the internal carotids and posterior cerebral arteries behind, by the communicating arteries, constitute the **circle of Willis**. This remarkable vascular communication at the base of the brain is formed by the anterior communicating branch, anterior cerebrals, and internal carotid arteries in front, and by the posterior communicating, posterior cerebrals, and basilar artery behind.

A more full description of the arteries of the brain will be found in Part VI.

The **INTERNAL MAMMARY ARTERY** arises from the under side of the subclavian, and passes down behind the subclavian vein to the cartilage of the first rib. It then descends by the side of the sternum, resting on the cartilages of the ribs, to the level of the sixth intercostal space, where it divides into two terminal branches, superior epigastric and musculo-phrenic. At its origin the artery is covered by the internal jugular and subclavian veins, and as it enters the chest it is crossed by the phrenic nerve; it then gets under cover of the pleura, and lower down lies between the triangularis sterni and internal intercostal muscles.

The **branches** of the internal mammary are—

Comes nervi phrenici,	Anterior intercostal,
Mediastinal,	Perforating,
Pericardiac,	Musculo-phrenic,
Thymic,	Superior epigastric.

The **comes nervi phrenici**, a long and slender branch given off by the artery as it enters the chest, descends with the phrenic nerve between the pleura and pericardium to the diaphragm, to which it is distributed, inosculating with the musculo-phrenic and abdominal phrenic arteries.

The **mediastinal, pericardiac, and thymic** branches are small vessels distributed to the anterior mediastinum, pericardium, and thymus gland. Some *sternal* branches are sent to supply the sternum and triangularis sterni muscle.

The **anterior intercostals** supply the intercostal muscles of the front of the chest, and inosculate with the aortic intercostals; to each space there are two arteries which either arise separately or

by common trunks and run along the borders of the rib. Besides supplying the intercostal muscles, they send branches to the pectoral muscles and mammary gland.

The **perforating arteries** pass forward to the front of the chest through the first six intercostal spaces; they then turn outwards, and after giving some branches to the front of the sternum, are distributed to the pectoral muscles and mammary gland. Those intended for the mammary gland are of larger size than the rest.

The **musculo-phrenic artery**, proceeding from the internal mammary at the interspace between the sixth and seventh ribs, passes downwards and outwards over the cartilages of the false ribs to the last intercostal space. It pierces the diaphragm at the attachment of that muscle to the eighth rib, and sends branches to its muscular structure, and others to the intercostal spaces of the false ribs which form the anterior intercostal arteries of those spaces, and are distributed in the same way as those above described.

The **superior epigastric artery** descends in the sheath of the rectus muscle, and gives off branches which are distributed to the muscles of the abdominal wall. It anastomoses with the deep epigastric, a branch of the external iliac.

The mammary arteries are remarkable for the number of their inosculation, and for the distant parts of the arterial system which they serve to connect. They anastomose with each other, and their inosculation, with the thoracic aorta, encircle the thorax. On the parietes of this cavity their branches connect the axillary and subclavian arteries: on the diaphragm they form a link in the chain of inosculation between the subclavian artery and abdominal aorta; and in the parietes of the abdomen they form an anastomosis most remarkable for the distance between those vessels which it serves to connect—namely, the arteries of the superior and inferior extremities.

The **THYROID AXIS** is a short trunk which arises from the front of the subclavian close to the inner border of the anterior scalenus, and divides almost immediately into three branches, inferior thyroid, supra-scapular, and transversalis colli.

The **INFERIOR THYROID ARTERY** ascends obliquely in a serpentine course behind the sheath of the carotid vessels, and in front of the longus colli, to the inferior and posterior part of the thyroid gland, to which it is distributed. It is in relation with the middle cervical ganglion of the sympathetic, which lies in front of it.

It gives off the following branches:—

Inferior laryngeal,
Tracheal,
Œsophageal.

Ascending cervical,
Glandular,
Muscular.

The **inferior laryngeal** accompanies the recurrent laryngeal nerve to the larynx and is distributed to the muscles and mucous membrane.

The **tracheal** and **oesophageal** branches ramify on the trachea and oesophagus.

The **ascending cervical**, a branch of the inferior thyroid, ascends upon the anterior tubercles of the transverse processes of the cervical vertebræ, lying in the groove between the scalenus anticus and rectus anticus major. It is distributed to the deep muscles and glands of the neck, and sends branches through the intervertebral foramina to supply the spinal cord and its membranes.

The **glandular** branches pass to the thyroid body and anastomose with the branches of the superior thyroid artery.

The muscular branches supply the scalenus anticus, longus colli, and depressor muscles of the hyoid bone.

The **SUPRA-SCAPULAR** or **TRANSVERSALIS HUMERI ARTERY** passes obliquely outwards behind the clavicle, and over the ligament

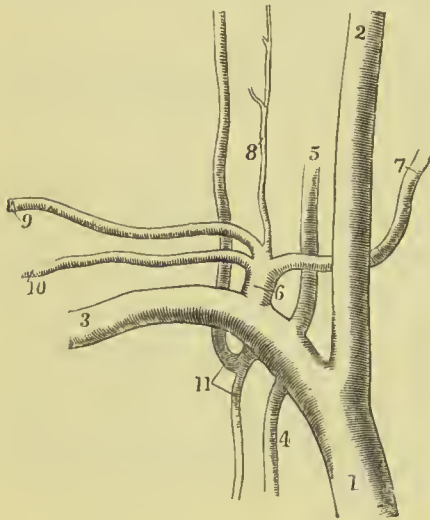


FIG. 256.—View of the branches of the right subclavian artery. 1. Innominate artery. 2. Common carotid. 3. Subclavian. 4. Internal mammary. 5. Vertebral. 6. Thyroid axis. 7. Inferior thyroid. 8. Ascending cervical. 9. Transversalis colli. 10. Supra-scapular. 11. Common trunk dividing into superior intercostal and deep cervical.

of the supra-scapular notch, to the supra-spinous fossa. It crosses in its course the scalenus anticus muscle, phrenic nerve, and subclavian artery; is distributed to the muscles of the dorsum of the scapula, and inosculates with the posterior scapular, and beneath the acromion process with the dorsal branch of the subscapular artery. At the supra-scapular notch it sends a large branch outwards, which pierces the trapezius muscle, and becomes cutaneous at the tip of the shoulder (*acromial*). It gives a number of small branches to the capsule of the shoulder-joint. The supra-scapular artery sometimes arises directly from the subclavian.

The **TRANSVERSALIS COLLI ARTERY** passes transversely across the subclavian triangle at the root of the neck, to the anterior border of the levator anguli scapulae, where it divides into two terminal branches, the *superficial cervical* and *posterior scapular*. In its course it lies above the supra-scapular artery, and crosses the scaleni muscles and brachial plexus of nerves, often passing between the latter. At its bifurcation it is covered in by the edge of the trapezius.

The **superficial cervical artery**, its ascending branch, passes upwards under cover of the anterior border of the trapezius, and is distributed to the superficial muscles of the neck and deep cervical glands.

The **posterior scapular artery**, the proper continuation of the transversalis colli, passes backwards to the superior angle of the

scapula, and then descends along the posterior border of that bone to its inferior angle, where it inosculates with the subscapular artery. In its course it lies under cover of the levator anguli scapulæ and rhomboidei muscles, distributes branches to them and neighbouring muscles, and inosculates with the arteries of the scapula and branches of the intercostal arteries.

The superficial cervical and posterior scapular artery sometimes arise separately, the former from the thyroid axis, the latter from the third portion of the subclavian. By means of its numerous inosculations the transversalis colli artery maintains an important anastomotic communication between the branches of the external carotid, subclavian, and axillary arteries.

The **SUPERIOR INTERCOSTAL ARTERY** arises from the upper and back part of the subclavian artery behind the scalenus anticus, and, descending in front of the necks of the first two ribs, sends intercostal branches to the first two intercostal spaces, and *dorsal* branches to the muscles and integument of the back. The artery lies behind the pleura, to the outer side of the sympathetic nerve, and in the second intercostal space inosculates with the first aortic intercostal. It gives off the *deep cervical artery*.

The **deep cervical (cervicalis profunda) artery** arises by a common trunk with the preceding, or, more properly, is a branch of the superior intercostal, corresponding with the posterior branch of the other intercostal arteries. It passes backwards between the transverse processes of the seventh cervical and first dorsal vertebra, and ascends the back part of the neck, between the complexus and semispinalis colli muscle. It inosculates with the princeps cervicis of the occipital artery, and with branches of the vertebral.

Varieties of the Subclavian Arteries.—Varieties in these arteries are rare; that which most frequently occurs is the origin of the right subclavian from the left extremity of the arch of the aorta, below the left subclavian artery. The vessel, in this case, curves behind the œsophagus and right carotid artery, and sometimes between the œsophagus and trachea, to the upper border of the first rib on the right side of the chest, where it assumes its ordinary course. Occasionally the left carotid and subclavian arise by a common trunk, as well as those on the right, so that there are two innominate arteries, and in rare cases the four branches all arise separately from the aorta, the right subclavian, however, retaining its normal position. Varieties in the branches of the subclavian are not unfrequent; the most interesting is the origin of the left vertebral from the arch of the aorta.

AXILLARY ARTERY.

The axillary artery passes outwards and downwards with a gentle curve through the axillary space from the lower border of the first rib to the lower border of the tendons of the latissimus dorsi and teres major, where it becomes the brachial. For convenience of

description it is divided into three parts : the *first part* extends from the lower border of the first rib to the upper border of the pectoralis minor ; the *second part* lies behind the pectoralis minor, and extends from the upper to the lower border of that muscle ; the *third part* extends from the lower border of the pectoralis minor to the lower border of the tendons of the latissimus dorsi and teres major.

Plan of the **Relations** of the *First Part* of the Axillary Artery.

In Front.

Pectoralis major,
Costo-coracoid membrane,
Acromial thoracic and cephalic veins,
Subclavius muscle.

Outer Side.
Brachial plexus.

Axillary Artery.
First Part.

Inner Side.
Axillary vein.

Behind.

First intercostal space,
Serratus magnus,
Posterior thoracic nerve.

Plan of the **Relations** of the *Second Part* of the Axillary Artery.

In Front.

Pectoralis major,
Pectoralis minor.

Outer Side.
Outer cord of plexus.

Axillary Artery.
Second Part.

Inner Side.
Inner cord of plexus,
Axillary vein.

Behind.

Subscapularis,
Posterior cord of plexus.

Plan of the **Relations** of the *Third Part* of the Axillary Artery.

In Front.

Integument and fascia,
Pectoralis major,
Inner head of median nerve.

Outer Side.
Outer head of median,
External cutaneous,
Coraco-brachialis.

Axillary Artery.
Third Part.

Inner Side.
Inner head of median,
Internal cutaneous,
Lesser internal cutaneous,
Ulnar,
Axillary vein.

Behind.

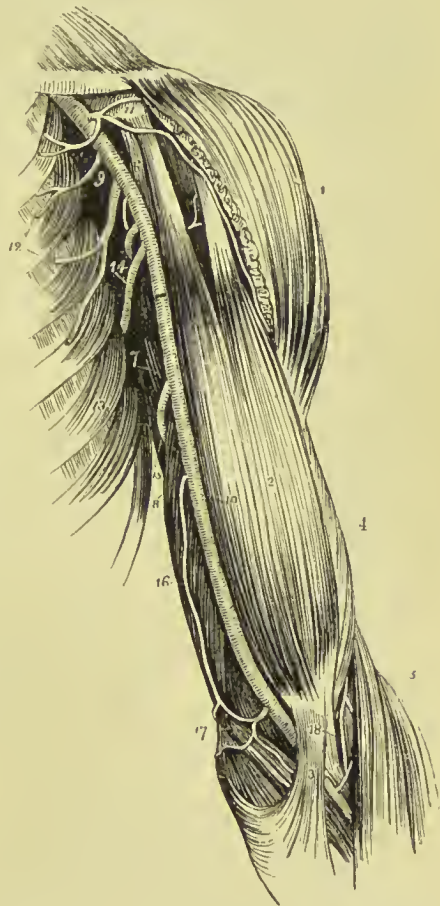Subscapularis.
Musculo-spiral nerve,
Circumflex nerve,
Tendons of latissimus and teres major.

Branches.—The branches of the axillary artery are seven in number :—

<i>From first part.</i>	}	Superior thoracic, Acromial thoracic.
<i>From second part.</i>	}	Inferior or long thoracic, Alar thoracic.
<i>From third part.</i>	}	Subscapular, Anterior circumflex, Posterior circumflex.

The superior thoracic and acromial thoracic are found in the triangular space above the pectoralis minor; the inferior thoracic

FIG. 257.—Axillary and brachial artery, with their branches. 1. Deltoid. 2. Biceps. 3. Tendinous process given off from the tendon of the biceps to the deep fascia of the forearm; this process separates the median basilic vein from the brachial artery. 4. Outer border of the brachialis anticus. 5. Supinator longus. 6. Coraco-brachialis. 7. Middle portion of the triceps. 8. Its inner head. 9. Axillary artery. 10. Brachial artery; —a dark bar marks the limit between these two vessels. 11. Acromial thoracic artery dividing into its three branches; the figure rests on the coracoid process. 12. The superior and long thoracic arteries. 13. Serratus magnus muscle. 14. Subscapular artery. The posterior circumflex and alar thoracic branches are seen in the figure between the inferior thoracic and subscapular. The anterior circumflex is observed between the two heads of the biceps, crossing the neck of the humerus. 15. Superior profunda. 16. Inferior profunda. 17. Anas-tomotica magna inosculating inferiorly with the anterior ulnar recurrent. 18. Termination of the superior profunda, inosculating with the radial recurrent in the interspace between the brachialis anticus and supinator longus.



and alar thoracic below the pectoralis minor; and the three remaining branches below the lower border of the subscapularis.

The **superior thoracic** (short thoracic), the highest of the branches of the axillary, and sometimes derived from the next, passes inwards to the chest in front of the pectoralis minor muscle, and is distri-

buted to the pectoral muscles and walls of the chest. It anastomoses with the intercostal and mammary arteries.

The **acromial thoracic** (thoracic axis) is a short trunk which proceeds from the axillary in the space above the pectoralis minor muscle, and divides into four sets of branches: *pectoral*, which are distributed to the pectoral muscles, serratus magnus, and mammary gland; *acromial*, which pass outwards to the acromion, and inosculate with branches of the supra-scapular artery; *descending* (thoracica humeraria), a single branch, which follows the interspace between the deltoid and pectoralis major muscle; and is in relation with the cephalic vein; and one or more *clavicular* branches which pass to the subclavius muscle and supply it.

The **inferior or long thoracic** (external mammary) descends along the lower border of the pectoralis minor to the side of the chest. It is distributed to the pectoralis major and minor, serratus magnus, and mammary gland; inosculating with the superior thoracic, intercostal, and mammary arteries.

The **alar thoracic** is a small branch distributed to the plexus of nerves and glands in the axilla. It is frequently wanting, its place being supplied by a branch derived from one of the other thoracic branches.

The **subscapular artery**, the largest of the branches of the axillary, runs along the lower border of the subscapular muscle, to the inferior angle of the scapula, where it inosculates with the posterior scapular, a branch from the subclavian. It supplies the muscles of the under surface and inferior border of the scapula, and the side of the chest. At about an inch and a half from the axillary, it gives off a large branch, the **dorsalis scapulæ**, which passes backwards through the triangular space bounded by the teres minor, teres major, and scapular head of the triceps, and beneath the infra-spinatus muscle to the dorsum of the scapula, where it is distributed, inosculating with the supra-scapular and posterior scapular arteries.

The **circumflex arteries** wind around the neck of the humerus. The **anterior**, very small, passes beneath the coraco-brachialis and short head of the biceps, and sends a branch upwards along the bicapital groove to supply the shoulder-joint; it then passes beneath the deltoid, and distributes branches to that muscle, which anastomose with the posterior circumflex and acromial thoracic arteries.

The **posterior circumflex**, of larger size, passes backwards through the quadrangular space bounded by the teres minor and major, the scapular head of the triceps, and humerus, and is distributed to the deltoid muscle and shoulder-joint; it anastomoses with the anterior circumflex, subscapular, acromial thoracic, and superior profunda arteries. Sometimes this artery is a branch of the superior profunda of the brachial; it then ascends behind the tendon of the teres major, and is distributed to the deltoid without passing through the quadrangular space.

Varieties of the Axillary Artery.—The most frequent peculiarity of this kind is the division of the vessel into two trunks of equal size: a muscular trunk, which gives off some of the ordinary axillary branches and supplies the upper arm, and a continued trunk which represents the brachial artery. The next most frequent variety is the high division of the radial which passes down the arm by the side of the brachial artery, and at the elbow takes its usual position, and is continued to its ordinary distribution in the hand. Sometimes there is a high division of the ulnar, that artery being given off in the axilla; at the elbow it passes superficially to the muscles attached to the internal condyle, and may in life be seen and felt pulsating immediately beneath the deep fascia.

BRACHIAL ARTERY.

The **brachial artery** passes down the inner side of the arm, from the lower border of the tendons of the latissimus dorsi and teres major, to a point opposite the neck of the radius, where it divides into the radial and ulnar artery.

Plan of the **Relations** of the Brachial Artery.

In Front.

Integument and fasciæ,
Median nerve,
Median-basilic vein,
Bicipital fascia.

Inner Side.

Internal cutaneous nerve,
Ulnar nerve,
Median nerve (below),
Basilic vein.

Brachial Artery.

Outer Side.

Median nerve (above),
Coraco-brachialis,
Biceps.

Behind.

Triceps,
Musculo-spiral nerve,
Superior profunda artery,
Coraco-brachialis,
Brachialis anticus.

The **branches** of the brachial artery are the—

Superior profunda,	Anastomotica magna,
Inferior profunda,	Muscular and nutrient.

The **superior profunda** arises opposite the lower border of the tendon of the latissimus dorsi, and winds around the humerus in the musculo-spiral groove, between the triceps and the bone, to the space between the brachialis anticus and supinator longus, where it inosculates with the radial recurrent artery. It accompanies the musculo-spiral nerve. In its course it gives off the *posterior articular* artery, which descends to the elbow-joint, and a more *superficial branch*, which descends by the side of the external intermuscular

septum and inosculates with the posterior interosseous recurrent artery. The inferior muscular branches of the superior profunda inosculate with the inferior profunda, *anastomotica magna*, and ulnar recurrent. This artery supplies the coraco-brachialis, deltoid, triceps, brachialis anticus, and the muscles attached to the external condyle and condylar ridge.

The **inferior profunda** arises from about the middle of the brachial artery, and descends with the ulnar nerve to the space between the inner condyle and olecranon, where it inosculates with the posterior ulnar recurrent. It also gives a branch to the front of the internal condyle, which anastomoses with the anterior ulnar recurrent and *anastomotica magna*. In its course it pierces the internal intermuscular septum from before backwards.

The **anastomotica magna** is given off nearly at right angles from the brachial, at about two inches above the joint. It passes directly inwards upon the brachialis anticus muscle, pierces the internal intermuscular septum, and winds around the humerus to inosculate with the superior profunda. On the brachialis anticus it divides into two branches, which inosculate with the anterior and posterior ulnar recurrent arteries, and with the inferior profunda.

The **muscular branches** are distributed to the muscles in the course of the artery, namely, coraco-brachialis, biceps, deltoid, brachialis anticus, and triceps.

The **nutrient branch** is given off at about the middle of the arm, and passes into the medullary foramen near the insertion of the coraco-brachialis muscle.

Varieties of the Brachial Artery.—The most frequent peculiarity in the distribution of branches from this artery is the high division of the radial, which arises generally from about the upper third of the brachial artery, and descends to its normal position at the bend of the elbow. The ulnar artery sometimes arises from the brachial at about two inches above the elbow, and pursues either a superficial or deep course to the wrist; and in some instances the interosseous artery arises from the brachial a little above the bend of the elbow. The two profunda arteries occasionally arise by a common trunk, or there may be two superior profundæ. Frequently a small branch is given off close to the origin of the superior profunda, or is derived from that vessel; it descends over the median nerve, supplies the biceps, and unites with the radial, or (less frequently) with the ulnar. It is called *vas aberrans*, and sometimes replaces the brachial itself.

BEND OF THE ELBOW.

At the bend of the elbow the brachial artery terminates by dividing into radial and ulnar; it here lies deeply in a triangular space which is sometimes called the *antecubital fossa*. This space is bounded *above* by an imaginary line drawn across the arm about two inches above the condyles, on the *inner side* by the pronator radii

teres, and on the *outer side* by the supinator longus; its *apex* is situated below, at the point where the pronator teres and supinator longus come in contact. The *floor* is formed by the lower part of the brachialis anticus, and the oblique fibres of the supinator brevis. The contents of the space, enumerated from within outwards, are the median nerve, brachial artery, and the tendon of the biceps. By displacing the supinator longus a little to the outer side, the musculo-spiral nerve and superior profunda artery can be brought into view; the former here divides into radial and posterior interosseous nerves, and the latter anastomoses with the radial recurrent artery, but neither the nerve nor the artery are, strictly speaking, contents of the triangle.

RADIAL ARTERY.

The radial artery, one of the divisions of the brachial, appears, from its direction, to be the continuation of that trunk. It runs along the radial side of the forearm, from the bend of the elbow to the wrist; it then turns backwards around the base of the thumb, beneath its extensor tendons, and passes between the two heads of the first dorsal interosseous muscle, into the palm of the hand. It next crosses the metacarpal bones to the ulnar side of the hand, forming the *deep palmar arch*, and terminates by inosculating with the deep branch of the ulnar artery.

Relations.—In the upper half of its course, the radial artery is situated between the supinator longus muscle, by which it is slightly overlapped, and the pronator radii teres; in the lower half between the tendons of the supinator longus and flexor carpi radialis.

Plan of the **Relations** of the Radial Artery in the Forearm.

In Front.

Integument and fasciæ,
Supinator longus.

Outer Side.

Supinator longus,
Radial nerve (middle
third).

Inner Side.

Pronator radii teres,
Flexor carpi radialis,

<p>Radial Artery.</p>

Behind.

Tendon of biceps,
Supinator brevis,
Pronator radii teres,
Flexor sublimis digitorum,
Flexor longus pollicis,
Pronator quadratus,
Radius.

At the wrist it winds round the outer side of the carpus, and lies in succession on the external lateral ligament, scaphoid, and trapezium, and is covered by the extensor tendons of the thumb, subcutaneous veins, and some twigs of the radial nerve.

In the hand it rests on the bases of the metacarpal bones and the interossei muscles, and is covered by the flexor tendons, flexor longus pollicis, lumbricales, opponens minimi digiti, flexor brevis minimi digiti, and flexor brevis pollicis. It is accompanied by the deep ulnar nerve.

The **branches** of the radial artery may be arranged into three groups, corresponding with the three regions—forearm, wrist, and hand; they are—

	<i>Forearm.</i>	
Radial recurrent,		Muscular.
	<i>Wrist.</i>	
Superficialis volæ, Anterior carpal, Posterior carpal,		Metacarpal, Dorsales pollicis, Dorsalis indicis.
	<i>Hand.</i>	
Princeps pollicis, Radialis indicis,		Interosseous, Perforating,
	Recurrent.	

The **radial recurrent branch** is given off immediately below the elbow; it ascends in the space between the supinator longus and brachialis anticus, sends branches to the muscles arising from the external condyle, and inosculates with the terminal branches of the superior profunda.

The **muscular branches** are distributed to the muscles of the radial border of the forearm.

The **superficialis volæ** is given off by the radial artery while at the wrist. It passes between the fibres of the abductor pollicis muscle, and inosculates with the termination of the ulnar artery, completing the superficial palmar arch. This artery is variable in size, being sometimes as large as the continuation of the radial, at other times a mere muscular twig, or entirely wanting; when of large size it supplies the palmar side of the thumb and radial side of the index finger.

The **anterior carpal** passes inwards along the lower border of the pronator quadratus, and forms an arch by inosculating with the anterior carpal branch of the ulnar artery. From this arch twigs are given off to supply the wrist-joint.

The **posterior carpal** arises from the radial artery beneath the extensor tendons of the thumb; it crosses the carpus transversely, and inosculates with the posterior carpal branch of the ulnar artery. Superiorly it inosculates with the termination of the anterior interosseous artery; inferiorly it gives off *dorsal interosseous branches*, which anastomose with the perforating branches of the deep palmar arch, and run forward upon the dorsal interosseous muscles of the third and fourth metacarpal spaces.

The **metacarpal or first dorsal interosseous branch** often arises in common with the posterior carpal; it runs forward to the meta-

carpal space between the index and middle finger. At the cleft of the fingers it inosculates with the palmar digital artery, and gives off dorsal collateral branches. It is joined by a perforating branch from the deep palmar arch which reaches it by passing between the heads of the second dorsal interosseous muscle.

The **dorsales pollicis** are two small branches which run along the sides of the dorsal aspect of the thumb.

The **dorsalis indicis** is a very small branch which runs along the radial border of the metacarpal bone and phalanges of the index finger.

The **princeps pollicis** (*arteria magna pollicis*), the great artery of the thumb, passes along the metacarpal bone of the thumb, between the first dorsal interosseous (*abductor indicis*) and *flexor brevis pollicis* to the base of the first phalanx; and, between the two heads of the latter muscle, in the groove of the tendon of the *flexor longus*, it divides into two collateral branches for the palmar borders of the thumb.

The **radialis indicis**, the digital branch of the radial side of the index finger, is directed inwards, between the first dorsal interosseous muscle and *flexor brevis* and *adductor pollicis*, to the side of the finger, along which it runs, forming its radial collateral artery, and anastomosing with the digital branch from the superficial arch. Near its origin it gives off a small branch (more frequently a direct branch of the radial), which inosculates with the superficial palmar arch, and often also effects a communication with the artery of the thumb.

The **palmar interosseous**, three or four in number, are branches

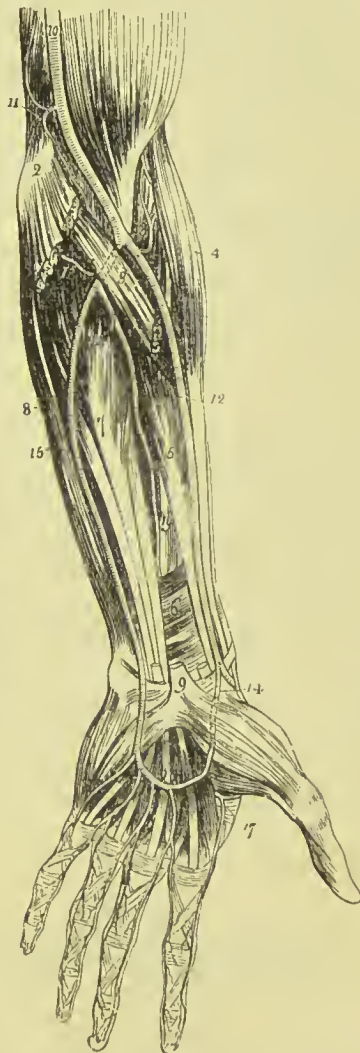


FIG. 258. — Arteries of the forearm.
 1. Biceps. 2. Inner condyle of humerus with the humeral origin of the pronator radii teres and *flexor carpi radialis* divided across. 3. Deep portion of pronator radii teres. 4. *Supinator longus*. 5. *Flexor longus pollicis*. 6. *Pronator quadratus*. 7. *Flexor profundus digitorum*. 8. *Flexor carpi ulnaris*. 9. Annular ligament with the tendons passing beneath it into the palm of the hand; the figure is placed on the tendon of the *palmaris longus*, divided close to its insertion. 10. Brachial artery. 11. *Anastomotica magna*. 12. Radial artery. 13. Radial recurrent. 14. *Superficialis volæ*. 15. Ulnar artery. 16. Superficial palmar arch. 17. *Princeps pollicis* and *radialis indicis*. 18. Posterior ulnar recurrent. 19. Anterior interosseous. 20. Posterior interosseous, passing through the interosseous membrane.

of the deep palmar arch ; they pass forward upon the interosseous muscles, and inosculate with the digital branches of the superficial arch, opposite the heads of the metacarpal bones.

The **perforating** branches, three in number, pass directly backwards between the heads of the dorsal interosseous muscles, and inosculate with the dorsal interosseous arteries.

The **recurrent** branches of the deep palmar arch pass upwards in front of the wrist-joint, and inosculate with the arterial arch formed by the anterior carpal arteries.

ULNAR ARTERY.

The ulnar artery, the other and larger division of the brachial, crosses the forearm obliquely, to the commencement of its middle third ; it then runs down the ulnar side of the forearm to the wrist, crosses the annular ligament into the hand, and forms the superficial palmar arch which terminates by inosculating with the superficialis volæ.

Relations.—In the upper or oblique portion of its course it lies upon the brachialis anticus and flexor profundus digitorum, and is covered in by the superficial layer of muscles of the forearm and median nerve. In the second part of its course, it is placed upon the flexor profundus and pronator quadratus, lying between the flexor carpi ulnaris and flexor sublimis digitorum. While crossing the annular ligament it is protected from injury by a strong tendinous arch, thrown over it from the pisiform bone ; and in the palm it rests on the origin of the muscles of the little finger, and the tendons of the flexor sublimis, being covered in by the palmaris brevis muscle and palmar fascia. It is accompanied in its course by the venæ comites, and is in relation with the ulnar nerve for the lower two-thirds of its extent, the nerve lying to its ulnar side.

Plan of the **Relations** of the Ulnar Artery.

In Front.

Superficial and deep fascia,
Superficial layer of flexor muscles,
Median nerve.

In the Hand.

Tendinous arch from the pisiform bone,
Palmaris brevis muscle,
Palmar fascia.

Inner Side.

Flexor carpi ulnaris,
Ulnar nerve (lower two-thirds).


Ulnar Artery.

Outer Side.

Flexor sublimis digitorum.

Behind.

Brachialis anticus,
Flexor profundus digitorum,
Pronator quadratus.



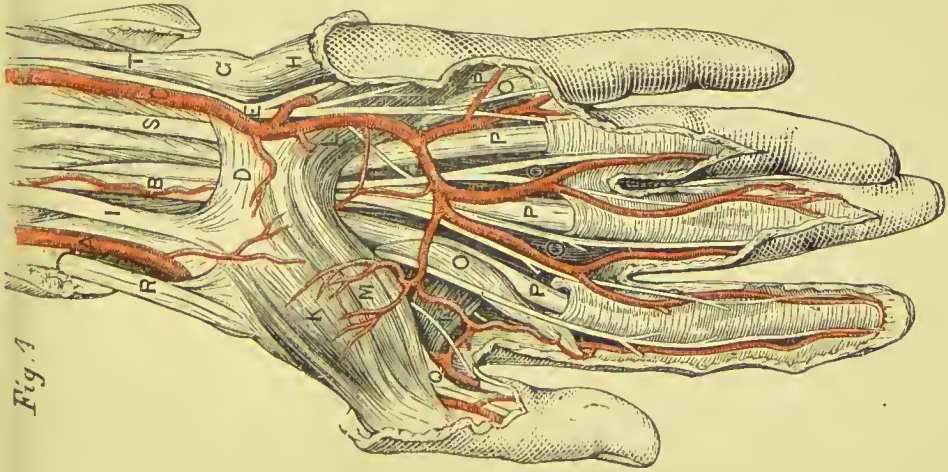
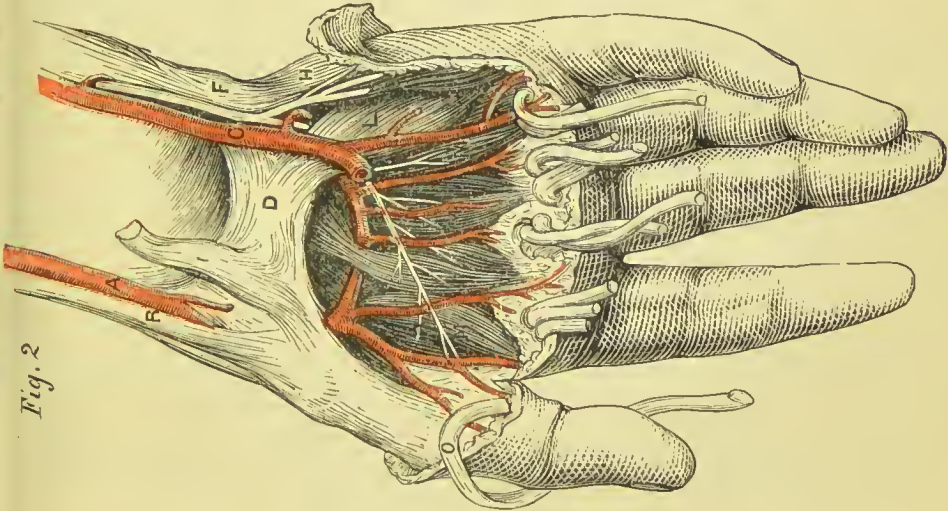
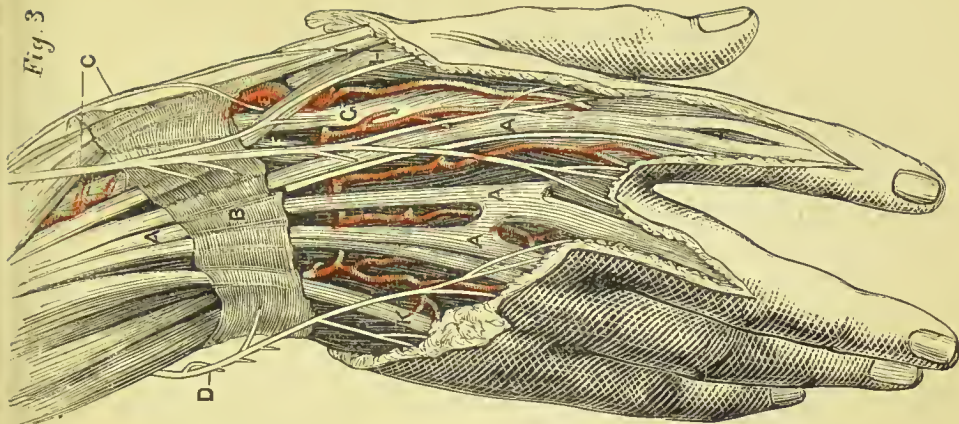
PALM AND BACK OF THE HAND.

FIGS. 1 AND 2.

- A. Radial artery.
- B. Median nerve.
- C. Ulnar artery.
- D. Annular ligament.
- E. Ulnar nerve.
- F. Insertion of flexor carpi ulnaris.
- G. Pisiform bone.
- H. Abductor minimi digiti.
- I. Tendon of flexor carpi radialis.
- K. Abductor pollicis.
- L. Flexor brevis minimi digiti.
- M. Flexor brevis pollicis.
- O. Lumbricales.
- P. Flexor tendons.
- Q. Tendon of flexor longus pollicis.
- R. Supinator longus.
- S. Flexor sublimis digitorum.
- T. Flexor carpi ulnaris.

FIG. 3.

- A. Extensor communis digitorum.
- B. Posterior annular ligament.
- C. Radial nerve.
- D. Ulnar nerve.
- E. Radial artery.
- F. Extensor carpi radialis brevis.
- G. Extensor carpi radialis longior.
- H. Extensor secundi internodii pollicis.
- I. Extensor primi internodii pollicis.
- K. Extensor minimi digiti.



In the Hand.

Annular ligament,
 Origin of muscles of little finger,
 Tendons of the flexor sublimis digitorum,
 Divisions of the median and ulnar nerves.

The **branches** of the *ulnar artery* may be arranged, like those of the radial, into three groups :—

<i>Forearm,</i>	{	Anterior ulnar recurrent,		
		Posterior ulnar recurrent,		
		Interosseous, {		Anterior interosseous,
		Posterior interosseous,		
		Muscular.		
<i>Wrist,</i>	{	Anterior carpal,		
		Posterior carpal,		
		Metacarpal.		
			<i>Hand,</i> { Communicating, Digital.	

The **anterior ulnar recurrent**, arising immediately below the elbow, ascends in front of the joint between the pronator radii teres and brachialis anticus; it distributes branches to the adjacent muscles, and inosculates with the anastomotica magna and inferior profunda. The two recurrent arteries frequently arise by a common trunk.

The **posterior ulnar recurrent**, larger than the preceding, arises immediately below the elbow-joint, and passes backwards, beneath the origin of the superficial layer of muscles; it then ascends between the two heads of the flexor carpi ulnaris, lying beneath the ulnar nerve, and inosculates with the inferior profunda, anastomotica magna, and interosseous recurrent.

The **INTEROSSEOUS ARTERY** is a short trunk which arises from the ulnar, opposite the bicipital tuberosity of the radius, and passes backwards to the interosseous membrane, where it divides into the anterior and posterior interosseous artery.

The **anterior interosseous** passes down the forearm upon the interosseous membrane, in company with the anterior interosseous nerve, between the flexor profundus digitorum and flexor longus pollicis, and behind the pronator quadratus; it then passes through an opening in the interosseous membrane to the back of the wrist, where it inosculates with the posterior carpal branches of the radial and ulnar. The anterior interosseous artery gives off several *muscular* branches; *nutrient* branches to the radius and ulna; a *companion branch* to the *median nerve* (arteria comes nervi mediani); and at the upper border of the pronator quadratus, a small branch, which descends behind that muscle to inosculate with the anterior carpal arteries. The **median artery** is sometimes of large size, and occasionally assists in forming the superficial palmar arch.

The **posterior interosseous artery** passes backwards through an opening between the upper part of the interosseous membrane and

the oblique ligament, and descends between the superficial and deep layer of muscles of the forearm to the back of the wrist, where it inosculates with the anterior interosseous and posterior carpal branches of the radial and ulnar. At its upper part it gives off a recurrent branch, **posterior interosseous recurrent**, which returns upon the elbow between the anconeus, extensor carpi ulnaris, and supinator brevis, and anastomoses with the posterior terminal branches of the superior profunda.

The **muscular branches** of the ulnar artery are distributed to the muscles of the ulnar border of the forearm.

The **anterior carpal**, a branch of small size, passes outwards upon the front of the wrist-joint, and contributes to form the *anterior carpal arch* by inosculating with the anterior carpal branch of the radial artery.

The **posterior carpal**, larger than the preceding, passes beneath the tendon of the flexor carpi ulnaris muscle to the back of the wrist-joint, where it inosculates with the posterior carpal branch of the radial artery, and forms a *posterior carpal arch*.

The **metacarpal**, often a branch of the preceding, passes along the inner border of the metacarpal bone of the little finger, and forms the dorsal collateral branch of that finger.

The **communicating or deep ulnar branch** arises close to the annular ligament, and dips between the abductor minimi digiti and flexor brevis to inosculate with the termination of the deep palmar arch. It is accompanied by the deep palmar branch of the ulnar nerve.

The **digital branches**, four in number, are given off from the convexity of the superficial palmar arch. The first and smallest is distributed to the ulnar side of the little finger. The other three are short trunks, which divide between the heads of the metacarpal bones, and form the collateral branch of the radial side of the little finger, the collateral branches of the ring and middle finger, and the collateral branch of the ulnar side of the index finger. On the last phalanx, the collateral arteries communicate and form an arch, from which numerous branches are given off to the tip of the finger.

The arteries of the hand are subject to frequent variety of distribution.

THORACIC AORTA.

The thoracic aorta commences at the lower border and left side of the fifth dorsal vertebra, passes slightly to the right as it descends, and terminates in front of the last dorsal vertebra by passing through the aortic opening of the diaphragm.

Relations.—The artery is situated in the posterior mediastinum of the thorax, and has behind it the vertebral column and vena azygos minor. The œsophagus lies first to its right side, then in front, and at the upper surface of the diaphragm is placed to the left of the artery although still in front of it.

Plan of the **Relations** of the Thoracic Aorta.*In Front.*

Left pulmonary artery,
 Left bronchus,
 Pericardium,
 Œsophagus.

Right Side.

Œsophagus (above),
 Vena azygos major,
 Thoracic duct.

Thoracic Aorta.

Left Side.

Pleura,
 Left lung,
 Œsophagus (below).

Behind.

Vertebral column,
 Vena azygos minor.

Branches.—The branches of the thoracic aorta are as follows :—

Pericardiac, Bronchial,	Œsophageal, Posterior mediastinal, Intercostal.
----------------------------	---

The **pericardiac** arteries are a few small and irregular branches distributed to the pericardium.

The **BRONCHIAL ARTERIES**, generally three in number, one for the right lung, and two for the left, vary both in size and origin; the right often proceeding from a short trunk common to it and one of the left bronchial branches, or from the first aortic intercostal. They take their course to the back of the root of the lung, and accompany the ramifications of the bronchial tubes through its substance, giving twigs also to the bronchial glands, œsophagus, and pericardium.

The **ŒSOPHAGEAL ARTERIES**, four or five in number, arise from the anterior part of the aorta, and are distributed to the œsophagus, establishing a chain of anastomoses along that tube: the superior inosculate with the bronchial arteries, and with œsophageal branches of the inferior thyroid arteries; the inferior with similar branches of the phrenic and gastric arteries.

The **posterior mediastinal** arteries are small twigs distributed to the lymphatic glands and areolar tissue of the posterior mediastinum.

The **INTERCOSTAL** arteries arise from the posterior part of the aorta; they are nine in number at each side, the upper two intercostal spaces being supplied by the superior intercostal branch of the subclavian. The right intercostals are longer than the left, on account of the position of the aorta. They ascend somewhat obliquely from their origin, and cross the vertebral column behind the thoracic duct, vena azygos major, and sympathetic nerve, to the intercostal spaces; the left passing beneath the superior intercostal vein, vena azygos minor, and sympathetic. In the intercostal space,

or rather on the external intercostal muscle, each artery gives off a *dorsal branch*, which passes back between the transverse processes of the vertebræ, lying internally to the middle costo-transverse ligament, and divides into a *spinal branch*, which supplies the spinal cord and vertebræ, and a *muscular branch*, distributed to the muscles and integument of the back. The intercostal artery then comes into relation with its vein and nerve, the former being above, the latter below, and ascends obliquely to the lower border of the rib, with which it comes into relation near the angle of the bone. It then runs along the lower border of the rib, lying between the two planes of intercostal muscles to the front of the chest, where it inosculates with the superior anterior intercostal branch of the internal mammary.

Besides the *dorsal branch* and several small muscular branches, the intercostal artery, at about the middle of its course, gives off a large *inferior branch*, which runs along the upper border of the rib below to the fore-part of the chest, and inosculates with the inferior anterior intercostal branch of the internal mammary.

While between the two planes of intercostal muscles, the intercostal artery is protected from pressure by little tendinous arches thrown across it and attached by each extremity to the bone. The upper pair of intercostal arteries inosculate with the superior intercostals of the subclavian; the lower intercostals anastomose with the lumbar and epigastric arteries in the parietes of the abdomen.

ABDOMINAL AORTA.

The abdominal aorta enters the abdomen through the aortic opening of the diaphragm, and between the two pillars of that muscle. In its course downwards, it lies on the vertebral column to the left of the middle line, and terminates on the fourth lumbar vertebra, by dividing into the two common iliac arteries. Its point of bifurcation is situated a little below and to the left of the level of the umbilicus.

Plan of the **Relations** of the Abdominal Aorta.

In Front.

Lesser omentum and stomach,
Branches of cœliac axis and solar plexus,
Splenic vein,
Pancreas,
Left renal vein,
Transverse duodenum,
Mesentery,
Aortic plexus.

Right Side.

Right crus of diaphragm,
Vena cava,
Right semilunar ganglion,
Thoracic duct,
Vena azygos major.

Abdominal Aorta.

Left Side.

Left semilunar ganglion,
Left supra-renal capsule,
Sympathetic nerve.

Behind.

Thoracic duct,
Receptaculum chyli,
Left lumbar veins,
Vertebral column.

Branches.—The branches of the abdominal aorta are the following :

Phrenic,		Inferior mesenteric,	
Cœliac axis,	{	Gastric,	Supra-renal,
		Hepatic,	Renal,
		Splenic,	Lumbar,
Superior mesenteric,		Sacra media.	
Spermatic,			

The **PHRENIC ARTERIES** are given off (frequently by a common trunk) from the anterior part of the aorta as soon as that vessel has emerged through the aortic opening. Passing obliquely outwards on the under surface of the diaphragm, each artery divides into two branches, an *internal branch*, which runs forwards and inosculates with its fellow of the opposite side in front of the œsophageal opening; and an *external branch*, which proceeds outwards towards the great circumference of the muscle, and sends branches to the supra-renal capsules. The phrenic arteries inosculate with branches of the internal mammary, intercostal, epigastric, œsophageal, gastric, hepatic, and supra-renal arteries. They are not unfrequently derived from the cœliac axis, or from one of its divisions, and sometimes they give origin to the supra-renal arteries.

The **COELIAC AXIS** is the first single trunk given off by the abdominal aorta. It arises opposite the upper border of the first lumbar vertebra, is about half an inch in length, and divides into three large branches, gastric, hepatic, and splenic.

Relations.—The trunk of the cœliac axis has in relation with it, *in front*, the lesser omentum; on the *right side*, the right semilunar ganglion and lobus Spigelii of the liver; on the *left side*, the left semilunar ganglion and cardiac portion of the stomach; and *below*, the upper border of the pancreas and lesser curve of the stomach. It is completely surrounded by the solar plexus.

The **GASTRIC ARTERY** (coronaria ventriculi), the smallest of the three branches of the cœliac axis, ascends between the two layers of the lesser omentum to the cardiac orifice of the stomach, then runs along the lesser curvature to the pylorus, and inosculates with the pyloric branch of the hepatic. It is distributed to the lower extremity of the œsophagus and lesser curve of the stomach; and anastomoses with the œsophageal arteries, vasa brevia of the splenic artery, and pyloric branch of the hepatic artery.

The **HEPATIC ARTERY** curves forward, and ascends along the right border of the lesser omentum to the liver, where it divides into two branches (right and left), which enter the transverse fissure, and are distributed along the portal canals to the right and left lobes.*

* For the mode of distribution of the hepatic artery within the liver, see the "Structural Anatomy" of that organ in the Part on Splanchnology.

It is in relation, in the right border of the lesser omentum, with the ductus communis choledochus and portal vein, lying to the left of the former structure and on a plane anterior to the latter; it is surrounded by the hepatic plexus of nerves, and numerous lymphatics. There are sometimes two hepatic arteries, in which case one is derived from the superior mesenteric.

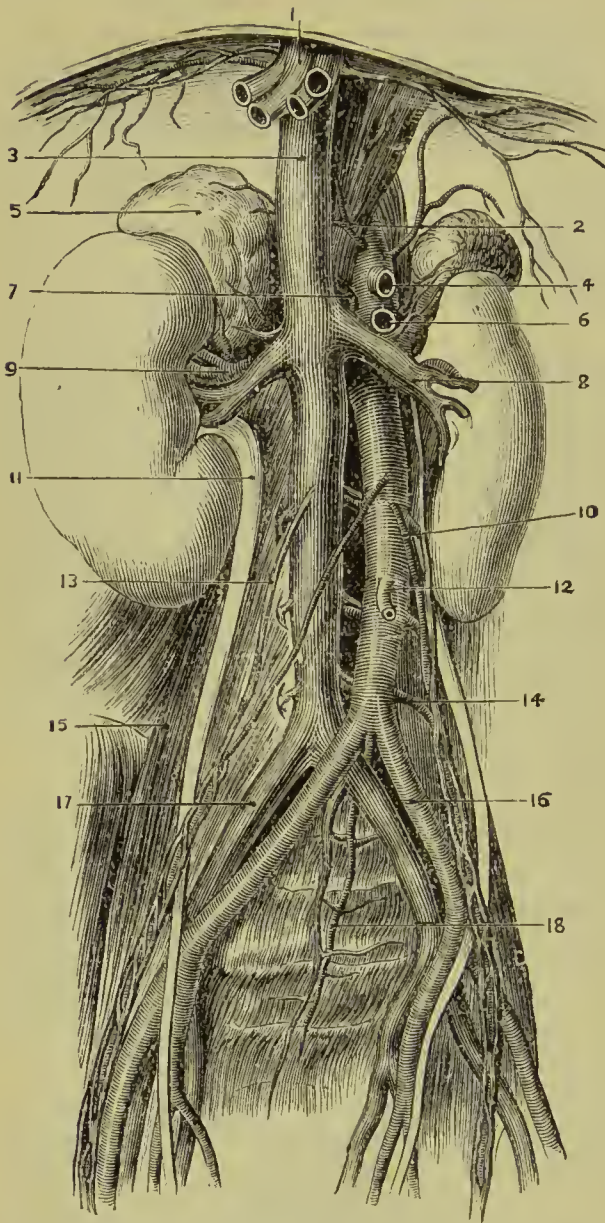


FIG. 259.—Abdominal aorta and inferior vena cava. 1. Hepatic veins (cut). 2. Phrenic arteries. 3. Vena cava. 4. Coeliac axis (cut). 5. Supra-renal capsule. 6. Superior mesenteric artery (cut). 7. Supra-renal artery. 8. Renal vein. 9. Renal artery. 10. Left spermatic vessels. 11. Right ureter. 12. Inferior mesenteric artery. 13. Right spermatic vein. 14. A lumbar artery. 15. Psoas magnus muscle. 16. Left common iliac artery. 17. Right common iliac vein. 18. Sacra media artery.

The **branches** of the hepatic artery are the—

Pyloric,
Gastro-duodenal,
Gastro-epiploica
dextra,
Pancreatico-duo-
denalis superior,
Cystic.

The **pyloric branch**, given off from the hepatic near the pylorus, runs from left to right along the lesser curve of the stomach, where it inosculates with the gastric artery, and gives branches to the coats of the stomach and to the lesser omentum.

The **gastro-duodenal artery** is a short but large trunk, which descends behind the pylorus, and divides into two branches, the gastro-

epiploica dextra, and pancreatico-duodenalis superior.

The **gastro-epiploica dextra** runs along the great curve of the stomach, lying between the two layers of the great omentum, and inosculates at about its middle with the **gastro-epiploica sinistra**, a

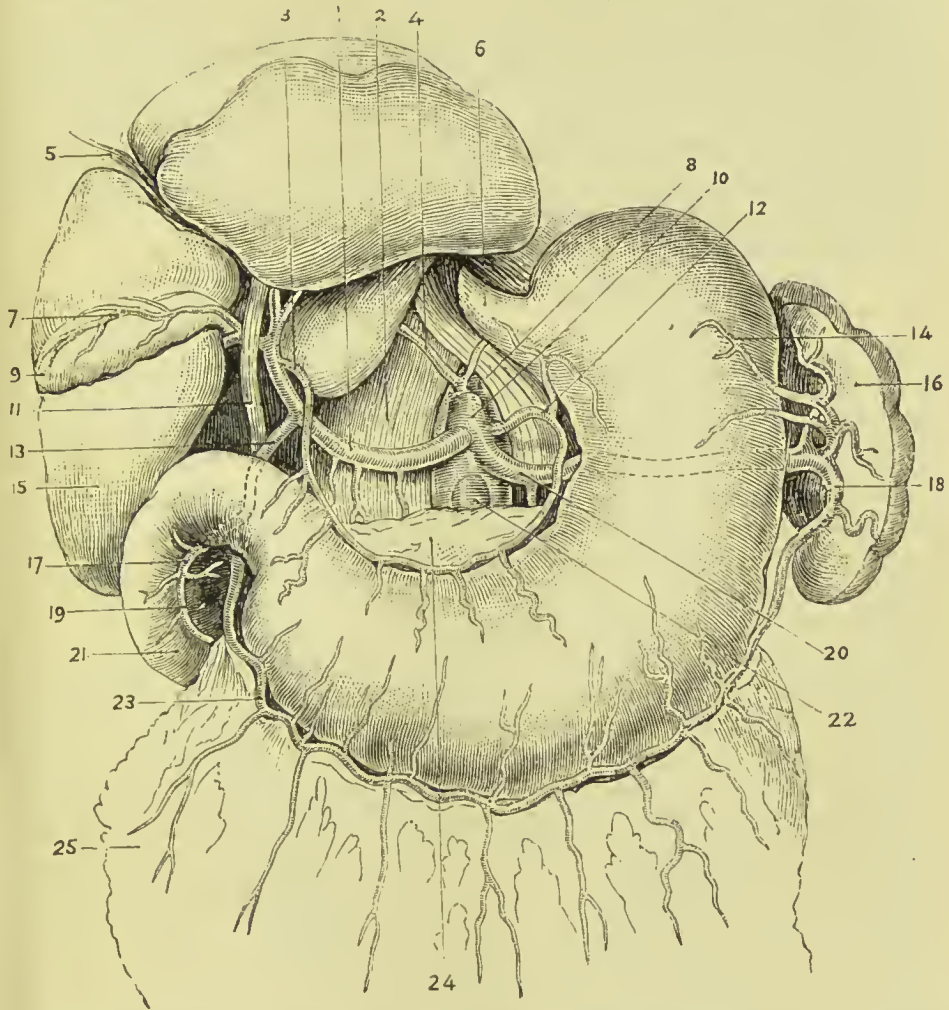


FIG. 260.—Branches of coeliac axis. 1. Hepatic artery. 2. Diaphragm. 3. Pyloric branch of the hepatic artery. 4. Right phrenic. 5. Round ligament of liver. 6. Oesophagus. 7. Cystic artery. 8. Abdominal aorta. 9. Gall-bladder. 10. Coeliac axis. 11. Common bile duct. 12. Gastric artery. 13. Gastro-duodenal artery. 14. Vasa brevia. 15. Liver. 16. Spleen. 17. Superior pancreatico-duodenal artery. 18. Gastro-epiploica sinistra. 19. Head of pancreas. 20. Splenic artery. 21. Duodenum. 22. Superior mesenteric artery. 23. Gastro-epiploica dextra. 24. Pancreas (drawn down). 25. Great omentum.

branch of the splenic artery. It supplies the greater curve of the stomach and great omentum ; hence its name.

The **pancreatico-duodenalis superior** curves along the fixed border of the duodenum, partly concealed by the attachment of the pancreas, and is distributed to the pancreas and duodenum. It inosculates inferiorly with the inferior pancreatico-duodenalis and pancreatic branches of the superior mesenteric artery.

The **cystic artery**, generally a branch of the right hepatic, is of small size, and ramifies between the coats of the gall-bladder, previously to its distribution to the mucous membrane.

The **SPLenic ARTERY**, the largest of the three branches of the cœliac axis, passes horizontally to the left along the upper border of the pancreas, and divides into five or six large branches, which enter the hilum of the spleen, and are distributed to its structure. In its course the vessel is tortuous and serpentine, frequently making a complete turn upon itself. It lies in a narrow groove in the upper border of the pancreas, and is accompanied by the splenic vein which lies beneath it, and by the splenic plexus of nerves.

The **branches** of the splenic artery are the—

Pancreaticæ parvæ,	Vasa brevia,
Pancreatica magna,	Gastro-epiploica sinistra.

The **pancreaticæ parvæ** are numerous small branches distributed to the pancreas, as the splenic artery runs along its upper border. One of these, larger than the rest, follows the course of the pancreatic duct, and is called **pancreatica magna**.

The **vasa brevia** are five or six branches of small size which pass from the extremity of the splenic artery and its terminal branches, between the layers of the gastro-splenic omentum, to the great end of the stomach, to which they are distributed, inosculating with branches of the gastric artery and gastro-epiploica sinistra.

The **gastro-epiploica sinistra** appears to be the continuation of the splenic artery; it passes forwards from left to right, along the great curve of the stomach, lying between the layers of the great omentum, and inosculates with the gastro-epiploica dextra. It is distributed to the greater curve of the stomach and great omentum.

The **SUPERIOR MESENTERIC ARTERY**, the second of the single trunks, and next in size to the cœliac axis, arises from the aorta immediately below that vessel, and behind the pancreas. It passes forwards between the pancreas and transverse duodenum, and descends within the layers of the mesentery, to the right iliac fossa, where it terminates, much reduced in size. In its course it forms a curve, the convexity being to the left, the concavity to the right; is in relation near its commencement with the portal vein, and is accompanied by the vein of the same name, which lies in front of it, and by the superior mesenteric plexus of nerves.

The **branches** of the superior mesenteric artery are—

Pancreatico-duodenalis	Ileo-colica,
inferior,	Colica dextra,
Vasa intestini tenuis,	Colica media.

The **pancreatico-duodenalis inferior** is a small branch which arises from the superior mesenteric while behind the pancreas, and curves upwards along the line of junction of the pancreas, and duodenum. It supplies both those organs, and inosculates with the pancreatico-duodenal branch of the hepatic.

The *vasa intestini tenuis* arise from the convexity of the superior mesenteric artery. They vary from fifteen to twenty in number, and are distributed to the small intestine from the duodenum to the termination of the ileum. In their course between the layers of the mesentery, they form a series of arches by the inosculation of their larger branches; from these are developed secondary arches, and from the latter a third series of arches, from which the branches

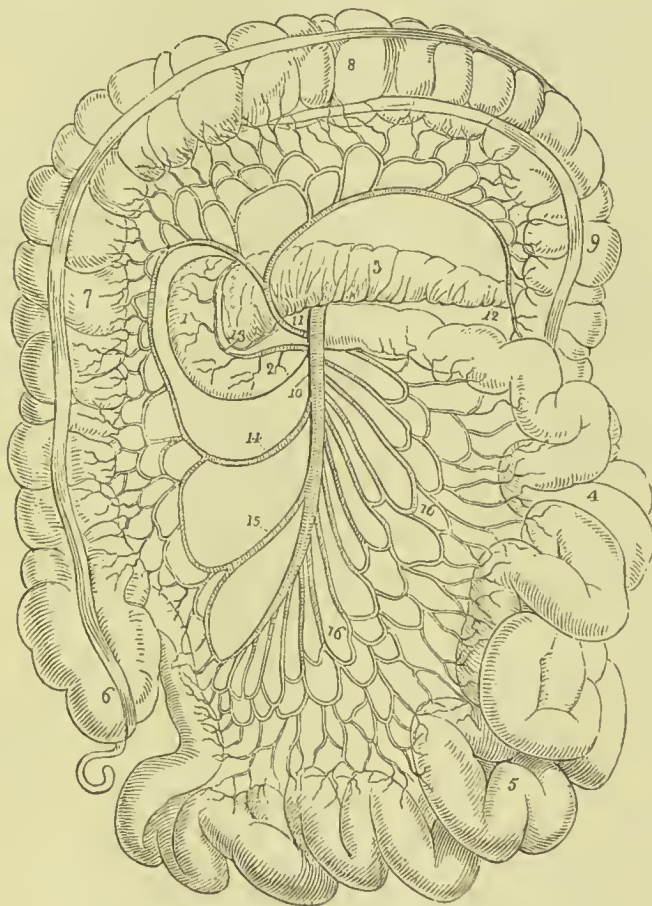


FIG. 261.—Course and distribution of the superior mesenteric artery. 1. Descending portion of the duodenum. 2. Transverse portion. 3. Pancreas. 4. Jejunum. 5. Ileum. 6. Cæcum and appendix vermiformis. 7. Ascending colon. 8. Transverse colon. 9. Descending colon. 10. Superior mesenteric artery. 11. Colica media. 12. The branch which inosculates with the colica sinistra. 13. Pancreatico-duodenalis inferior. 14. Colica dextra. 15. Ileo-colica. 16, 16'. *Vasa intestini tenuis*.

arise which are distributed to the coats of the intestine. From the middle branches a fourth and sometimes even a fifth series of arches is produced. By means of these arches a direct communication is established between all the branches given off from the convexity of the superior mesenteric artery; the upper branch inosculates with the inferior pancreatico-duodenal, the lower with the ileo-colic.

The **ileo-colic artery** is the last branch given off by the concavity

of the superior mesenteric. It descends to the right iliac fossa, and divides into branches which communicate and form arches, from which branches are distributed to the termination of the ileum, cæcum, and commencement of the colon. This artery inosculates on the one hand with the termination of the mesenteric trunk ; on the other, with the colica dextra.

The **colica dextra** arises from about the middle of the concavity of the superior mesenteric, and passing outwards behind the peritoneum, divides into branches which form arches, and are distributed to the ascending colon. Its descending branches inosculate with the ileo-colic, the ascending with the colica media.

The **colica media** arises from the upper part of the concavity of the superior mesenteric, and passes forward between the layers of the transverse mesocolon, where it forms arches, and is distributed to the transverse colon. It inosculates on the right with the colica dextra ; on the left, with the colica sinistra, a branch of the inferior mesenteric artery.

The **SPERMATIC ARTERIES** are two small vessels which arise from the front of the aorta below the superior mesenteric ; from their origin each artery passes obliquely outwards, and accompanies the corresponding ureter along the front of the psoas muscle, to the border of the pelvis, where it is in relation with the external iliac artery. It is then directed outwards to the internal abdominal ring, and follows the course of the spermatic cord, along the spermatic canal and through the scrotum to the testicle, to which it is distributed. The right spermatic artery lies in front of the vena cava, and both vessels are accompanied by veins and by the spermatic plexuses of nerves. They anastomose with the deferential arteries, branches of the superior vesical, and with the cremasteric arteries.

The **ovarian** arteries in the female correspond to the spermatic in the male. They descend into the pelvis and pass between the two layers of the broad ligaments of the uterus, to be distributed to the broad ligaments, ovaries, Fallopian tubes, and round ligaments ; along the latter they are continued to the inguinal canal and labium at each side. They inosculate with the uterine arteries.

The **INFERIOR MESENTERIC ARTERY**, smaller than the superior, arises from the abdominal aorta, about two inches below the origin of the latter vessel, and descends between the layers of the left mesocolon, to the left iliac fossa, where it divides into three *branches* :—

Colica sinistra,	Sigmoid,
Superior hæmorrhoidal.	

The **colica sinistra** is distributed to the descending colon ; it passes upwards and outwards behind the peritoneum, and divides into two branches, one of which ascends to inosculate with the colica media, while the other descends to communicate with the sigmoid branch. The inosculation of the colica sinistra with the colica media is the largest arterial anastomosis in the body.

The **sigmoid artery** passes obliquely outwards behind the peri-

toneum and divides into branches which form arches, and are distributed to the sigmoid flexure of the colon. The superior branch inosculates with the colica sinistra, the inferior with the superior hæmorrhoidal artery.

The **superior hæmorrhoidal artery** is the continuation of the

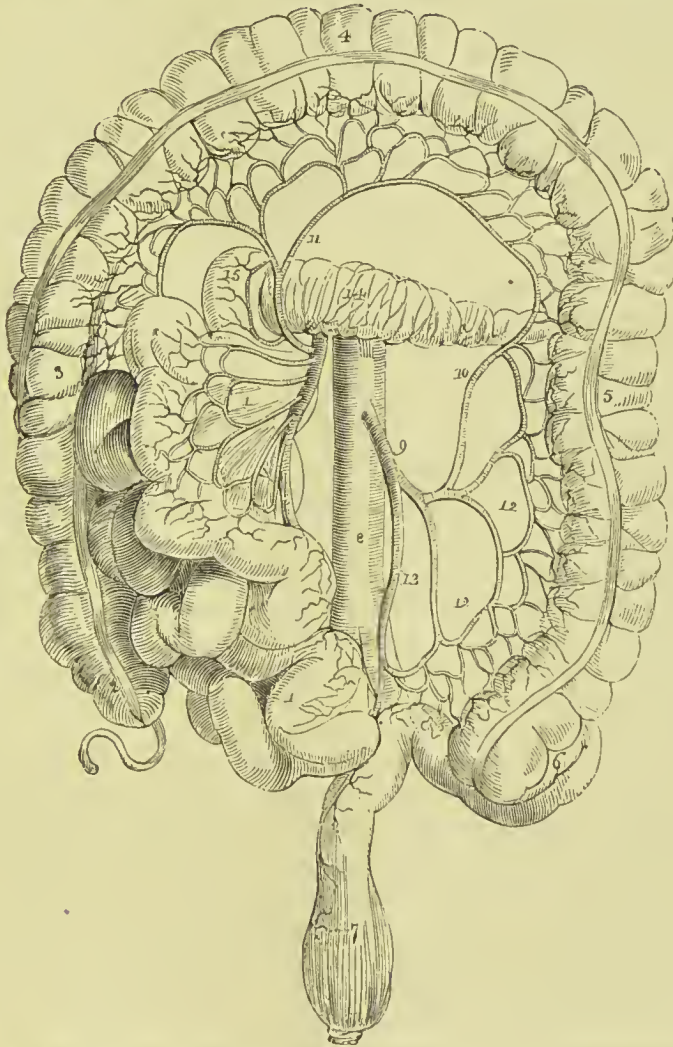


FIG. 262.—Branches of the inferior mesenteric artery. 1, 1. The superior mesenteric, and small intestines turned over to the right side. 2. Cæcum and appendix vermiformis. 3. Ascending colon. 4. Transverse colon drawn upwards. 5. Descending colon. 6. Sigmoid flexure. 7. Rectum. 8. Aorta. 9. Inferior mesenteric artery. 10. Colica sinistra, inosculating with (11) colica media. 12, 12. Sigmoid branches. 13. Superior hæmorrhoidal artery. 14. Pancreas. 15. Descending portion of the duodenum.

inferior mesenteric. It crosses the ureter and left common iliac artery, and descending between the two layers of the mesorectum, is distributed to the rectum as far as its middle, anastomosing with the middle and inferior hæmorrhoidal arteries, branches derived from the internal iliac artery.

The **SUPRA-RENAL** (capsular) are two small vessels which arise from the aorta immediately above the renal arteries, and are distributed to the supra-renal capsules. They are sometimes branches of the phrenic or of the renal arteries.

The **RENAL ARTERIES** (emulgent) are two large trunks given off from the sides of the aorta immediately below the superior mesenteric artery; the right is longer than the left, on account of the position of the aorta, and passes behind the vena cava to the kidney of that side. The left is somewhat higher than the right. They divide into several large branches previously to entering the kidney, and ramify very minutely in its vascular portion. The renal arteries supply several small branches to the supra-renal capsules, and one to the ureter. The renal arteries are subject to great variation in their number and place of origin. Frequently two or three branches arise from different parts of the aorta; in other instances a single trunk springs from the front of the aorta, and divides into two branches, one for each kidney; other cases are recorded where the renal arteries spring from the common iliac, inferior mesenteric, middle sacral, and even from the internal iliac.

The **LUMBAR ARTERIES** are four in number at each side; they correspond with the intercostals in the chest. Each artery curves around the body of the lumbar vertebra beneath the psoas muscle, and divides into two branches: one, *dorsal branch*, passes backwards between the transverse processes, and is distributed to the vertebræ and spinal cord and muscles of the back; the other, *parietal branch*, taking its course behind the quadratus lumborum, supplies the abdominal muscles, and inosculates with branches of the internal mammary and epigastric arteries in front, the terminal twigs of the intercostals above, and the ilio-lumbar and circumflex iliac below. The first lumbar artery runs along the lower border of the last rib; the last, along the crest of the ilium. In passing between the psoas muscle and the vertebræ, they are protected by a series of tendinous arches, which defend them and the communicating branches of the sympathetic nerve from pressure, during the action of the muscle.

The **SACRA MEDIA** arises from the posterior part of the aorta just above its bifurcation, and descends along the middle of the anterior surface of the sacrum to the first piece of the coccyx, where it terminates by inosculating with the lateral sacral arteries. It distributes branches to the rectum and anterior sacral nerves, and inosculates at either side with the lateral sacral arteries.

Coccygeal Gland or **Luschka's Gland**.—Lying in front of the coccyx near its tip is a small mass, connected with the extremity of the middle sacral artery, and named by Luschka, who first described it, the *coccygeal gland*. It consists of a number of small arteries with terminal dilatations like minute aneurisms, held together by fibrous tissue, which also forms a capsule for the whole mass; in the meshes of the stroma one or two ganglion cells are found, and a few small nerves derived from the sympathetic prevertebral chain. It appears to be the remains of foetal tissues.

Varieties in the Branches of the Abdominal Aorta.—The phrenic arteries are very rarely both derived from the aorta. One or both may be branches of the cœliac axis; one may proceed from the gastric artery, from the renal, or from the upper lumbar. There are occasionally three or more phrenic arteries. The cœliac axis is variable in length, and gives off its branches irregularly. There are sometimes two or even three hepatic arteries, one of which may be derived from the gastric or from the superior mesenteric. The colica media is sometimes derived from the hepatic artery. The spermatic arteries are variable both in origin and number. The right spermatic may be a branch of the renal; the left, of the inferior mesenteric. The supra-renal arteries may be derived from the phrenic or renal arteries.

COMMON ILIAC ARTERIES.

The abdominal aorta divides opposite the fourth lumbar vertebra (or the intervertebral substance between the fourth and fifth) into the two common iliac arteries. Sometimes the bifurcation takes place as high as the third, and occasionally as low as the fifth. The common iliac arteries are about two inches in length; they diverge from the termination of the aorta, and pass downwards and outwards at each side to the margin of the pelvis, opposite the sacro-iliac symphysis, where they divide into the internal and external iliac. In old persons the common iliac arteries are more or less dilated and curved in their course. The *right artery* is somewhat longer than the left, and forms a more obtuse angle with the termination of the aorta; the angle of bifurcation is greater in the female than in the male.

Relations.—The relations of the two arteries are different at the two sides of the body. The *right* common iliac is in relation in front with the peritoneum, small intestines and sympathetic nerves, and is crossed at its bifurcation by the ureter. It is in relation behind with the two common iliac veins and last lumbar vertebra, and externally with the psoas magnus, vena cava, and right common iliac vein. The *left* is in relation in front with the peritoneum and sympathetic nerves, and is crossed by the rectum and superior hæmorrhoidal artery, and, at its bifurcation, by the ureter. It is in relation behind with the left common iliac vein and last lumbar vertebra, and externally with the psoas magnus.

The **INTERNAL ILIAC ARTERY** is a short trunk, varying in length from an inch to two inches. It descends obliquely forwards to a point opposite the upper margin of the great sacro-ischiatric foramen, where it divides into an anterior and a posterior trunk. In the fœtus, the internal iliac artery, under the name of *hypogastric* or *umbilical*, is continued onwards by the side of the upper part of the bladder to near its apex, whence it ascends by the side of the linea alba and urachus to the umbilicus, where it becomes the true umbilical artery. After birth, this artery ceases to be pervious beyond

the side of the bladder, and the obliterated portion is converted into a fibrous cord. The projection of the two cords on the inner wall of the abdomen causes the depression at each side, which goes by the name of *peritoneal fossa*.

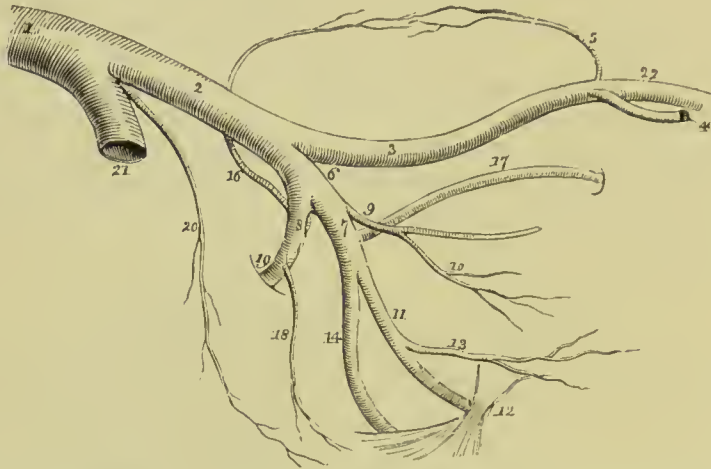


FIG. 263.—Iliac arteries. 1. Aorta. 2. Left common iliac artery. 3. External iliac. 4. Deep epigastric artery. 5. Deep circumflex iliac. 6. Internal iliac artery. 7. Its anterior trunk. 8. Its posterior trunk. 9. The pervious portion of the umbilical artery giving off (10) the superior vesical artery. 11. Internal pudic artery passing behind the spine of the ischium (12) and lesser sacro-ischiatic ligament. 13. Middle hæmorrhoidal artery. 14. Ischiatic artery, also passing behind the lesser sacro-ischiatic ligament to escape from the pelvis. 16. Ilio-lumbar ascending to inosculate with the circumflex iliac artery (5) and form an arch along the crest of the ilium. 17. Obturator artery. 18. Lateral sacral. 19. Gluteal artery passing through the upper part of the great sacro-ischiatic foramen. 20. Sacra media. 21. Right common iliac artery cut short. 22. Femoral artery.

Plan of the **Relations** of the Internal Iliac Artery.

In Front.

Peritoneum.
Ureter.

Outer Side.

Psoas magnus.

Internal Iliac.

Behind.

Internal iliac vein,
Lumbo-sacral nerve,
Pyriformis muscle.

Branches.—The branches of the anterior trunk are the :—

Superior vesical,	Vaginal (<i>in female</i>),
Inferior vesical,	Obturator,
Middle hæmorrhoidal,	Ischiatic,
Uterine (<i>in female</i>),	Internal pudic.

The branches of the posterior trunk are the :—

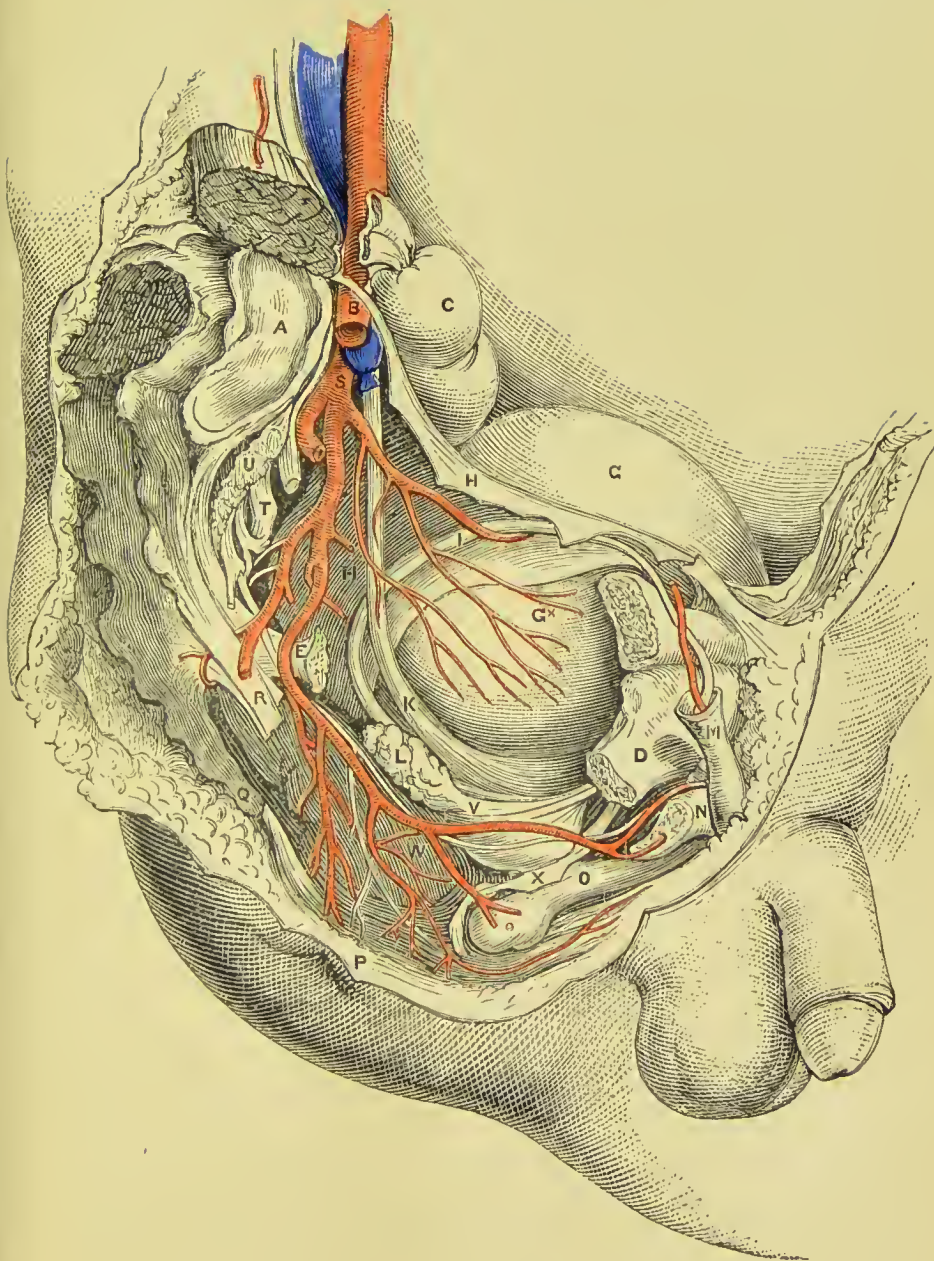
Ilio-lumbar,	Lateral sacral,
Gluteal.	

PLATE 24.

SIDE VIEW OF MALE PELVIS.

- A.** Sacrum.
- B.** External iliac artery.
- C.** Upper end of rectum.
- D.** Ramus of pubes.
- E.** Spine of ischium (cut off).
- G.** Bladder covered by peritoneum.
- G*.** Bladder, uncovered by peritoneum.
- H.** Peritoneum reflected from side of bladder.
- I.** Vas deferens.
- K.** Ureter.
- L.** Vesicula seminalis.
- M.** Spermatic cord.
- N.** Crus penis.
- O.** Urethra. **o.** Bulb.
- P.** Sphincter ani.
- Q.** Coccyx.
- R.** Great sacro-sciatic ligament.
- S.** Internal iliac artery.
- T.** Sacral nerves.
- U.** Piriformis muscle.
- V.** Internal pudic artery.
- W.** Levator ani muscle.
- X.** Triangular ligament (cut).

PLATE 24.





Branches of the Anterior Trunk.

The **superior vesical** arteries are three or four small branches, which proceed from the pervious portion of the umbilical artery. They are distributed to the upper and middle part of the bladder. From one of these there passes off a small artery, the **deferential**, which accompanies the vas deferens to the spermatic cord.

The **inferior vesical**, somewhat larger than the preceding, passes down upon the side of the bladder to its base, and is distributed to that region, the vesiculæ seminales, and prostate gland.

The **middle hæmorrhoidal artery**, frequently a branch of the preceding, passes downwards to the rectum, to which it is distributed, inosculating with the superior and inferior hæmorrhoidal arteries. In the female it distributes branches to the vagina.

The **uterine artery** passes inwards between the layers of the broad ligament to the neck of the uterus, and ascends in a tortuous course along its lateral border. It gives branches to the vagina, lower part of the bladder, Fallopian tube (*tubaria*), ovary (*ovaria*), and round ligament, and inosculates with the spermatic or ovarian artery.

The **vaginal artery** corresponds in position with the inferior vesical in the male, and is distributed to the vagina and neighbouring parts of the bladder and rectum.

The **OBTURATOR ARTERY** (arising frequently from the posterior trunk of the internal iliac) passes forwards from the anterior trunk, a little below the brim of the pelvis, to the upper border of the obturator foramen. Escaping from the pelvis through a tendinous arch formed by the obturator membrane, it divides into two branches, internal and external.

Its *branches* within the pelvis are—an *iliac* branch, which supplies the bone of the iliac fossa, and inosculates with the ilio-lumbar artery; and a *pubic* branch which is given off close to the obturator foramen, and inosculates with its fellow of the opposite side, behind the pubes, and with the pubic branch of the deep epigastric artery.

The *internal* branch curves inwards around the bony margin of the obturator foramen, and distributes twigs to the obturator and adductor muscles, inosculating with the internal circumflex artery of the femoral.

The *external* branch winds around the outer margin of the obturator

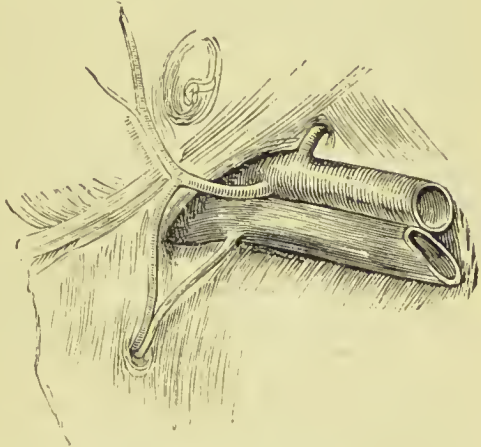


FIG. 264.—Irregular origin of obturator artery from epigastric. Second variety internal to crural ring.

foramen to the space between the gemellus inferior and quadratus femoris, where it inosculates with the ischiatic artery. In its course it inosculates also with the internal circumflex, and sends a small branch through the notch in the acetabulum to supply the ligamentum teres.

The obturator artery sometimes arises from the external iliac, but more frequently from the epigastric branch of that artery, in which case it runs down directly to the obturator foramen, either on the outer or inner side of the crural ring,—if to the inner side it is in contact with Gimbernat's ligament, and is in danger in the operation for femoral hernia; fortunately it is but rarely found in this dangerous position.

The **ISCHIATIC ARTERY** is the larger of the two terminal branches of the anterior division of the internal iliac. It passes downwards in front of the pyriformis and sacral plexus of nerves, lying internally to the pudic artery, to the lower part of the great ischiatic foramen, where it escapes from the pelvis between the inferior border of the pyriformis and coccygeus. It then descends in the space between the trochanter major and tuberosity of the ischium in company with the ischiatic nerves, and divides into several branches, the principal of which are—coccygeal, inferior gluteal, comes nervi ischiatici, and muscular.

The **coccygeal** branch pierces the great sacro-ischiatic ligament, and is distributed to the coccygeus and levator ani, and to the integument around the anus and coccyx.

The **inferior gluteal** branches, three or four in number and of large size, are distributed to the gluteus maximus muscle, anastomosing with branches of the superior gluteal artery.

The **comes nervi ischiatici** is a slender branch, which accompanies the great ischiatic nerve, extending as far as the lower part of the thigh.

The **muscular** branches supply the muscles of the posterior part of the hip and thigh, and inosculate with the internal and external circumflex arteries, obturator, and superior perforating; some branches are also sent to the hip-joint.

The **INTERNAL PUDIC ARTERY**, the other terminal branch of the anterior trunk of the internal iliac, descends externally to the ischiatic artery to the lower part of the great ischiatic foramen. It emerges from the pelvis through the great sacro-ischiatic foramen between the lower border of the pyriformis and the coccygeus, crosses the spine of the ischium, and re-enters the pelvis through the lesser sacro-ischiatic foramen; in the next place it passes forward on the internal obturator muscle, enclosed in the sheath of obturator fascia forming Alcock's canal, to the ramus of the ischium, being situated at about an inch from the margin of the tuberosity; it then ascends by the side of the ramus of the ischium and pubes, and near the symphysis pubis pierces the triangular ligament of the perineum and divides into two terminal branches, the artery of the corpus cavernosum and the artery of the dorsum of the penis.

Branches.—The branches of the internal pudic artery within the pelvis are several small twigs to the levator ani and sacral nerves ; and occasionally a branch which takes the place of the inferior vesical or middle hæmorrhoidal artery.

The *branches* given off externally to the pelvis are the—

Inferior hæmorrhoidal,	Artery of the bulb,
Superficial perineal,	Artery of the corpus cavernosum,
(Transverse perineal),	Artery of the dorsum of the penis.

The **inferior hæmorrhoidal arteries** are three or four small

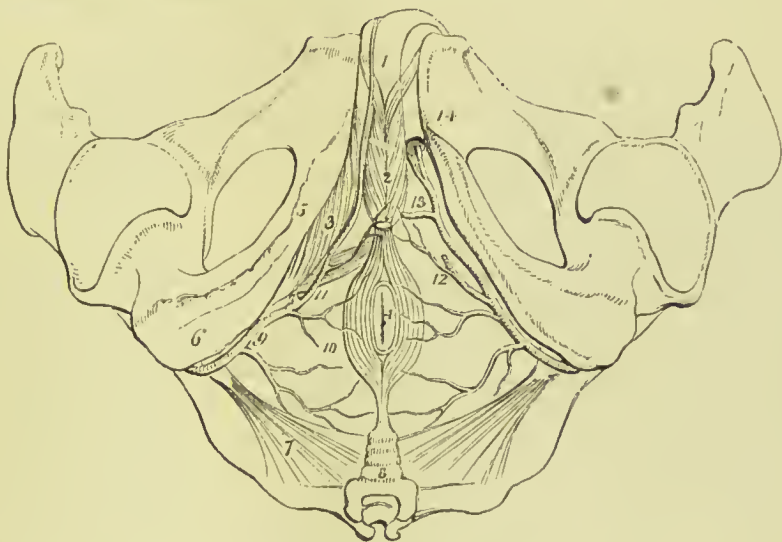

FIG. 265.—Arteries of the perineum ; on the right side the superficial arteries are seen, on the left the deep. 1. The penis ; the crus penis of the left side is cut through. 2. Bulbo-cavernosus muscles, enclosing the bulbous portion of the corpus spongiosum. 3. Ischio-cavernosus, spread out upon the crus penis of the right side. 4. Anus, surrounded by the sphincter ani. 5. Ramus of ischium and pubes. 6. Tuberosity of ischium. 7. Lesser sacro-ischiatic ligament. 8. Coccyx. 9. Internal pudic artery, crossing the spine of the ischium, and entering the perineum. 10. Inferior hæmorrhoidal branches. 11. Superficial perineal artery, giving off a small branch, transverse perineal, upon the transversus perinei muscle. 12. The same artery on the left side cut off. 13. Artery of the bulb. 14. The artery of the corpus cavernosum and artery of the dorsum of the penis.

branches, given off by the internal pudic while behind the tuberosity of the ischium. They cross the ischio-rectal fossa, and are distributed to the anus and to the muscles and integument of the anal region of the perineum, anastomosing with the branches of the middle hæmorrhoidal.

The **superficial perineal artery** is given off near the attachment of the crus penis ; it pierces the connecting layer of the perineal fascia and triangular ligament, and runs forward across the transversus perinei muscle, and along the groove between the accelerator urinæ and erector penis to the septum scroti, upon which it ramifies under the name of *arteria septi*. It distributes branches to the scrotum and perineum. One of the latter, larger than the rest,

crosses the perineum, resting on the transversus perinei muscle, and is named the *transverse perineal*. There are often two superficial perineal arteries.

The **artery of the bulb** is given off from the pudic nearly opposite the opening for the transmission of the urethra; it passes almost transversely inwards behind the triangular ligament, and pierces that ligament to enter the corpus spongiosum at its bulbous extremity. It is distributed in the corpus spongiosum and gives a small branch downwards to Cowper's gland.

The **artery of the corpus cavernosum** pierces the crus penis, and runs forward in the interior of the corpus cavernosum, by the side of the septum pectiniforme. It ramifies in the parenchyma of the venous structure of the corpus cavernosum.

The **dorsal artery of the penis** ascends between the two crura and symphysis pubis to the dorsum penis, and runs forward through the suspensory ligament, in the groove of the corpus cavernosum, to the glans, distributing branches in its course to the body of the organ and integument.

The pudic artery is sometimes small, and fails to give off some of its branches; in such cases its distribution is supplemented by a separate artery called the **accessory pudic**. This branch is generally derived from the pudic before that vessel passes through the great sacro-sciatic foramen, but it sometimes springs from the inferior vesical, the obturator, or some other branch of the internal iliac. It passes along the side of the base of the bladder, and the lateral aspect of the prostate gland, pierces the triangular ligament to reach the root of the penis, and divides into the artery of the bulb and the dorsal artery of the penis; or it may terminate in the superficial perineal artery.

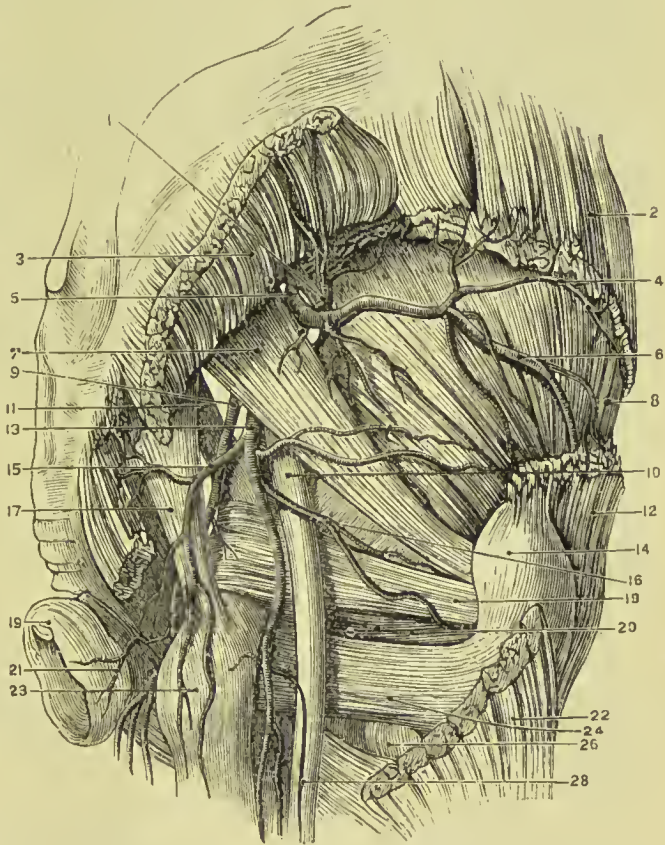
The **INTERNAL PUDIC ARTERY** in the female is smaller than in the male; its branches, with their distribution, are, in principle, the same. The superficial perineal artery supplies the homologue of the lateral half of the scrotum, namely, the greater labium. The artery of the bulb supplies the bulb of the vestibule and commencement of the vagina; the artery of the corpus cavernosum, the cavernous body of the clitoris; and the arteria dorsalis clitoridis, the dorsum of that organ.

Branches of the Posterior Trunk.

The **ILIO-LUMBAR ARTERY** passes out between the obturator nerve and lumbo-sacral cord, and ascends beneath the external iliac vessels and psoas muscle, to the posterior part of the crest of the ilium, where it divides into two branches, a *lumbar branch* which supplies the psoas and quadratus lumborum, and sends a branch through the fifth intervertebral foramen to the spinal cord and its membranes; and an *iliac branch* which crosses the iliac fossa to the crest of the ilium, and anastomoses with the lumbar arteries and deep circumflex iliac; in its course it distributes branches to the iliacus and abdominal muscles.

The **LATERAL SACRAL ARTERIES** are generally two in number on each side, superior and inferior. The *superior* passes inwards to the first sacral foramen, and is distributed to the contents of the spinal canal, from which it escapes by the posterior sacral foramen, and supplies the integument of the dorsum of the sacrum. The *inferior* passes down by the side of the anterior sacral foramina to the coccyx; it first pierces and then rests on the origin of the pyriformis, and sends twigs into the sacral canal to supply the sacral nerves. Both arteries give branches to the pyriformis and

FIG. 266.—Arteries of the buttock. 1. Superficial branch of the gluteal artery. 2. Gluteus medius (origin). 3. Gluteus maximus (origin). 4. Superior branch of deep gluteal artery. 5. Trunk of gluteal artery. 6. Inferior branch of deep gluteal artery. 7. Pyriformis. 8. Gluteus minimus. 9. Pudic artery. 10. Great sciatic nerve. 11. Lesser sacro-sciatic ligament. 12. Gluteus medius (insertion). 13. Ischiatic artery. 14. Great trochanter. 15. Coccygeal branch of ischiatic artery. 16. Anastomotic branch of ischiatic. 17. Great sacro-sciatic ligament. 18. Obturator internus and two gemelli. 19. External sphincter ani. 20. Tendon of obturator externus. 21. Inferior hæmorrhoidal artery. 22. Insertion of gluteus maximus. 23. Tuberosity of ischium. 24. Quadratus femoris. 26. Lesser trochanter. 27. Arteria comes nervi ischiatici.



coccygeus muscles, and the sacral nerves; they inosculate with each other and with the sacra media.

The **GLUTEAL ARTERY** is the continuation of the posterior trunk of the internal iliac; it passes backwards between the lumbo-sacral and first sacral nerve through the upper part of the great sacro-ischiatic foramen and above the pyriformis muscle, and divides into three branches, superficial, deep superior, and deep inferior; while within the pelvis it gives off some muscular twigs to the iliacus and pyriformis, and at its escape from the pelvis, a *nutrient* artery to the ilium.

The **superficial branch** passes backwards between the gluteus maximus and medius, and is distributed to the gluteus maximus and to the integument of the gluteal and sacral regions.

The **deep superior branch** passes forwards along the middle curved line of the ilium, between the gluteus medius and minimus to the anterior superior spinous process, where it inosculates with the superficial circumflex iliac and external circumflex of the femoral. There are frequently two arteries occupying the place of this branch.

The **deep inferior branches**, two or three in number, cross the gluteus minimus obliquely to the trochanter major, where they inosculate with branches of the external circumflex and ischiatic arteries, and send branches through the gluteus minimus to supply the capsule of the hip-joint.

The **EXTERNAL ILIAC ARTERY** of each side passes obliquely downwards along the inner border of the psoas muscle, from opposite the sacro-iliac symphysis to the femoral arch, where it becomes the femoral artery.

Plan of the **Relations** of the External Iliac Artery.

In Front.

Peritoneum, intestines, and iliac fascia,
Lymphatics,
Spermatic vessels,
Genito-crural nerve,
Circumflex iliac vein.

Inner Side.

External iliac vein,
Vas deferens.

External Iliac.

Outer Side.

Psoas magnus,
Iliac fascia.

Behind.

External iliac vein,
Psoas magnus.

Branches.—Besides several small twigs which supply the lymphatic glands and psoas muscle, the external iliac gives off two branches, the

Deep epigastric,

Deep circumflex iliac.

The **DEEP EPIGASTRIC ARTERY** arises from the front of the external iliac near Poupart's ligament; and passing inwards between the peritoneum and transversalis fascia, ascends obliquely to the sheath of the rectus. It enters that sheath near its lower third, passes upwards behind the rectus muscle, to which it is distributed, and, in the substance of that muscle, inosculates, near the ensiform cartilage, with the termination (superior epigastric) of the internal mammary artery. It lies internally to the internal abdominal ring and immediately above the femoral ring, and is crossed near its origin by the vas deferens in the male, and the round ligament in the female.

The branches of the epigastric artery are—

A **cremasteric** branch which accompanies the spermatic cord, and after supplying the cremaster muscle inosculates with the spermatic artery.

A **pubic** branch which is distributed behind the pubes, and sends a small branch of communication downwards to the obturator artery.

Muscular branches which pass outwards between the abdominal muscles, and inosculate with the circumflex iliac, lumbar, and inferior intercostal arteries.

Superficial branches which pierce the rectus muscle, and are distributed to the integument of the abdomen.

The epigastric artery forms a prominence of the peritoneum, which divides the inguinal fossa into an internal and external portion; it is from the former that direct inguinal hernia issues, and from the latter oblique inguinal hernia.

Triangle of Hesselbach.—This is a small triangular space, bounded externally by the deep epigastric artery, internally by the outer edge of the rectus abdominis, and below by Poupart's ligament and the crest of the pubes. In this space is situated the external abdominal ring, through which both direct and oblique inguinal hernia pass.

The **DEEP CIRCUMFLEX ILIAC** arises from the other side of the external iliac, a little below the epigastric artery. It ascends obliquely along Poupart's ligament, contained in a fibrous canal formed at the junction of the transversalis and iliac fasciæ, and curving around the crest of the ilium, inosculates with the ilio-lumbar and inferior lumbar arteries. It gives off muscular branches to the ilio-psoas, and upper end of the sartorius and tensor vagina femoris. Opposite the anterior superior spinous process of the ilium, it gives off a large *ascending branch*, which passes upwards between the internal oblique and transversalis, and divides into numerous branches which supply the abdominal muscles, and inosculate with the inferior intercostal and the lumbar arteries.

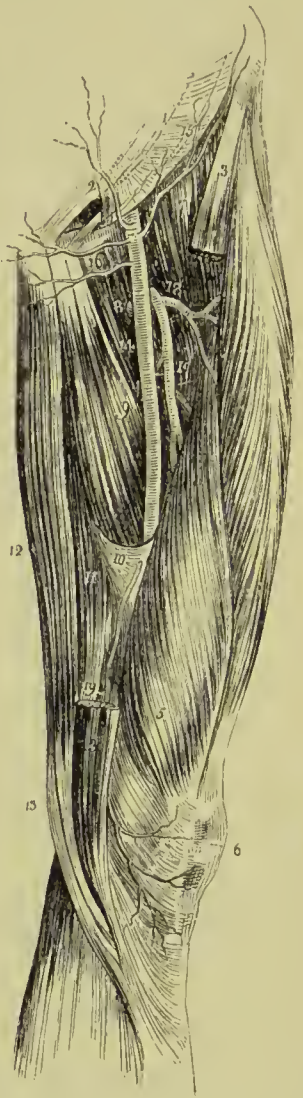
FEMORAL ARTERY.

Emerging from beneath Poupart's ligament, the external iliac artery enters the thigh and becomes the femoral. The femoral artery passes down the inner side of the thigh, from Poupart's ligament, at a point midway between the anterior superior spinous process of the ilium and the symphysis pubis, to the opening in the adductor magnus, at the junction of the middle with the inferior third of the thigh, where it becomes the popliteal artery.

The femoral artery and vein are enclosed in a strong sheath, **femoral sheath**, which is formed for the greater part of its extent by fibrous and areolar tissue, and by a process of fascia sent inwards from the fascia lata. Near Poupart's ligament this sheath is much larger than the vessels it contains, and is continuous with the trans-

versalis and iliac fascia. If the sheath be opened at this point, the artery will be seen in contact with the outer wall of the sheath. The vein lies next the artery, being separated from it by a fibrous septum,

FIG. 267. — Anterior and inner aspect of the thigh, with the femoral artery. 1. Lower part of the tendon of the external oblique muscle. 2. External abdominal ring. 3, 3. Upper and lower part of the sartorius muscle; its middle portion being removed. 4. Rectus. 5. Vastus internus. 6. Patella. 7. Iliacus and psoas. 8. Pectineus. 9. Adductor longus. 10. Hunter's canal. 11. Adductor magnus. 12. Gracilis. 13. Tendon of the semi-tendinosus. 14. Femoral artery. 15. Superficial circumflex iliac artery. 16. Superficial epigastric artery. 17. Profunda artery, giving off (18) its external circumflex branch; and lower down the three perforating. A small bend of the internal circumflex artery (8) is seen behind the inner margin of the femoral, just below the deep external pudic artery. 19. The anastomotica magna, descending to the knee, upon which it ramifies (6).



and between the vein and the inner wall of the sheath, and divided from the vein by another thin fibrous septum. is a triangular interval, **femoral or crural canal**, into which the sac is protruded in femoral hernia. This space is occupied in the normal state of the parts by loose areolar tissue, and by lymphatic vessels which pierce the inner wall of the sheath to make their way to a gland, situated in the femoral or **crural ring** (see Fig. 235).

Relations.—The upper third of the femoral artery is superficial, being covered only by the integument, inguinal glands, and superficial and deep fascia. The lower two-thirds are covered by the sartorius muscle. To its *outer*

side the artery is in relation with the psoas, and vastus internus muscles, and with the femoral vein at the upper part of the thigh. *Behind*, it rests on the inner border of the psoas; it is next separated from the pectineus by the femoral vein, profunda vein and artery, and then lies on the adductor longus to its termination; near the lower border of the adductor longus it is placed in an aponeurotic sheath or canal, called **Hunter's canal**, formed by an arch of tendinous fibres, thrown from the border of the adductor longus and the border of the opening in the adductor magnus, to the side of the vastus internus. To its *inner side* it is in relation at its

upper part with the femoral vein, and lower down with the adductor longus and sartorius.

The immediate relations of the artery are the femoral vein, long saphenous nerve, and muscular nerve to the vastus internus. The vein at Poupart's ligament lies to the inner side of the artery; but lower down gets behind it, and inclines to its outer side. The muscular nerve lies to the outer side, and somewhat upon the sheath for the lower two-thirds of its extent; and the long saphenous nerve is situated within the sheath, and in front of the artery for the same extent.

Plan of the **Relations** of the Femoral Artery.

Front.

Skin, superficial and deep fascia,
Sartorius,
Long saphenous nerve and vein,
Genito-crural nerve,
Branches of anterior crural nerve,
Aponeurotic canal.

Inner Side.

Femoral vein,
Adductor longus,
Sartorius,
Long saphenous nerve.

Femoral Artery.

Outer Side.

Long saphenous nerve,
Vastus internus,
Femoral vein.

Behind.

Psoas muscle,
Pectineus,
Nerve to pectineus,
Profunda vein,
Femoral vein,
Adductor longus,
Adductor magnus.

Branches.—The branches of the femoral artery are the—

Superficial circumflex iliac,
Superficial epigastric,
Superficial external pudic,
Deep external pudic,

Profunda, { External circumflex,
Internal circumflex,
Three perforating.
Muscular,
Anastomotica magna.

The **superficial circumflex iliac artery** arises from the femoral immediately below Poupart's ligament, and passes obliquely outwards towards the crest of the ilium, where it pierces the fascia lata. It supplies the integument of the groin, superficial fascia, and inguinal glands, and anastomoses with the deep circumflex iliac, gluteal and external circumflex arteries.

The **superficial epigastric** arises from the femoral immediately below Poupart's ligament, pierces the fascia lata, and ascends obliquely towards the umbilicus between the two layers of the superficial fascia. It distributes branches to the inguinal glands

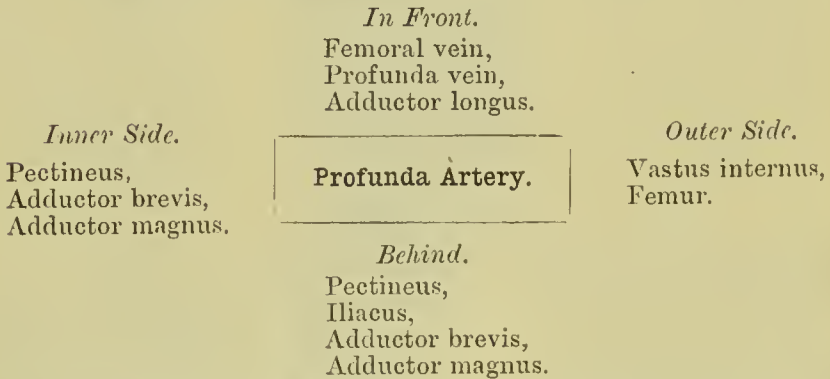
and integument, and inosculates with branches of the deep epigastric and internal mammary arteries.

The **superficial external pudic** arises near the superficial epigastric artery; it pierces the fascia lata at the saphenous opening, and passes transversely inwards, crossing the spermatic cord, to be distributed to the integument of the penis and scrotum in the male, and to the labia in the female.

The **deep external pudic** arises from the femoral a little below, and sometimes in common with, the preceding; it crosses the femoral vein immediately below the termination of the internal saphena vein, and resting on the pectineus muscle reaches the inner border of the thigh, where it pierces the fascia lata, and is distributed to the integument of the external organs of generation and perineum. Both external pudics inosculate with the internal pudic artery.

The **PROFUNDA FEMORIS** arises from the outer and posterior side of the femoral artery about one inch and a half below Poupart's ligament; it passes downwards and backwards and a little outwards, behind the adductor longus muscle, pierces the adductor magnus, and is distributed to the flexor muscles on the posterior part of the thigh. It is so large that it may be considered a *division* of the **common femoral**, in which case the continuation of the main trunk may be called **superficial**.

Plan of the **Relations** of the Profunda Artery.



Branches.—The branches of the profunda artery are the external circumflex, internal circumflex, and three perforating arteries.

The **external circumflex artery** passes outwards beneath the sartorius and rectus and in front of the crureus muscle, crossing between the divisions of the crural nerve, and divides into three sets of branches: *ascending*, which pass upwards beneath the sartorius, rectus, and tensor vaginae femoris, and inosculate with the terminal branches of the gluteal and circumflex iliac arteries; *descending*, which pass downwards beneath the rectus and along the margin of the vastus externus muscle, distributing branches to the rectus, vastus externus and crureus; some of the lower twigs can be traced as far as the knee, where they inosculate with the superior articular arteries of the popliteal; and *transverse*, which continue

the original course of the artery around the thigh, pierce the vastus externus, and anastomose with branches of the ischiatic, internal circumflex, and superior perforating arteries. The external circumflex supplies the muscles of the anterior and outer side of the thigh.

The **internal circumflex artery** winds around the inner side of the neck of the femur, passing between the pectineus and psoas, and over the upper border of the adductor brevis to the tendon of the obturator externus, which it accompanies to the space between the quadratus femoris and upper border of the adductor magnus. While on the obturator externus it gives off a branch which is distributed to that muscle, the adductor brevis, and gracilis, and anastomoses with the obturator artery. It next gives off an **articular** branch, which enters the hip-joint through the notch in the acetabulum; and terminates in several branches which inosculate with the ischiatic, external circumflex, and superior perforating arteries.

The **superior perforating artery** passes backwards near the lower border of the pectineus, pierces the adductor brevis and magnus near the femur, and is distributed to the posterior muscles of the thigh; inosculating with the circumflex, ischiatic, and middle perforating arteries.

The **middle perforating artery** pierces the tendons of the adductor brevis and magnus, and is distributed like the superior; inosculating with the superior and inferior perforating. From this branch is given off the *nutrient* artery of the femur.

The **inferior perforating artery** is given off below the adductor brevis, and pierces the tendon of the adductor magnus, supplying it and the flexor muscles, and inosculating with the middle perforating artery above, and the articular branches of the popliteal below. It is through the medium of the branches of the profunda which inosculate above with branches of the internal iliac, and below with those of the popliteal artery, that the collateral circulation is maintained in the limb after ligature of the femoral artery.

The **muscular branches** are given off by the femoral artery throughout the whole of its course. They supply the muscles in immediate proximity with the artery, particularly those of the

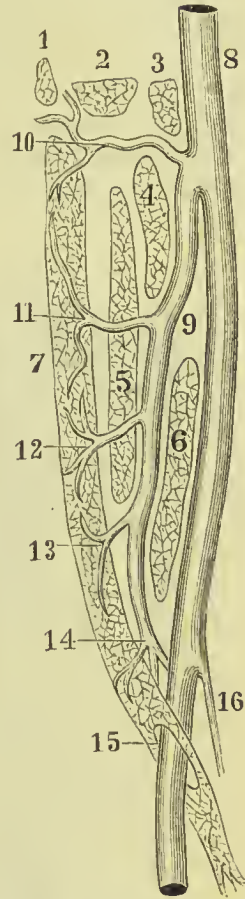


FIG. 268.—Scheme of profunda femoris artery. 1. Quadratus femoris. 2. Obturator externus. 3. Psoas. 4. Pectineus. 5. Adductor brevis. 6. Adductor longus. 7. Adductor magnus. 8. Common femoral artery. 9. Profunda femoris. 10. Internal circumflex. 11. Superior perforating. 12. Middle perforating. 13. Inferior perforating. 14. Termination of profunda. 15. Oval opening in adductor magnus. 16. Anastomotica magna.

anterior aspect of the thigh. One of these branches, larger than the rest, arises from the femoral immediately below the origin of the profunda, and passing outwards between the sartorius and rectus, divides into branches, which are distributed to all the muscles of the anterior aspect of the thigh. This may be named the *superior muscular artery*.

The **anastomotica magna** arises from the femoral near its termination at the opening in the adductor magnus, and divides into a superficial and deep branch. The *superficial branch* accompanies the

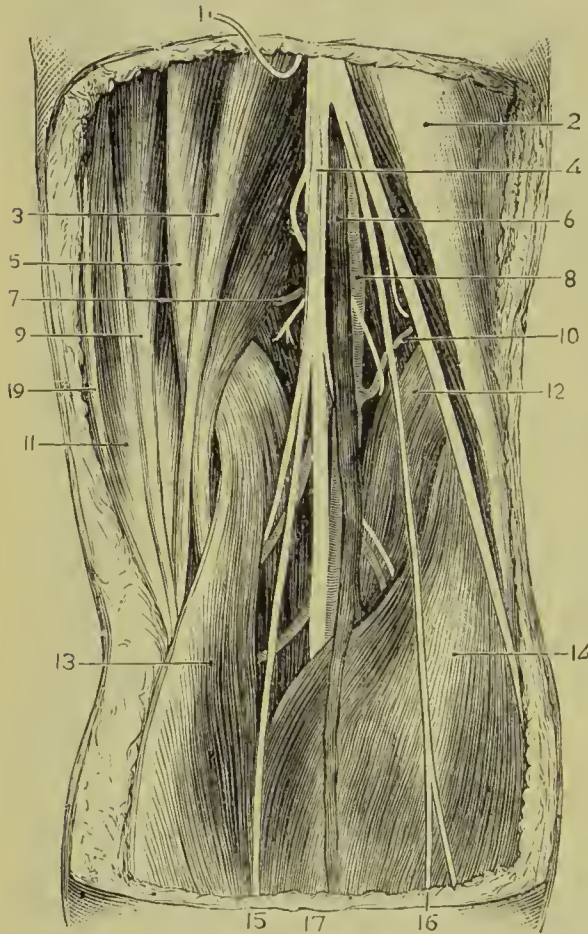


FIG. 269.—Popliteal space. 1. Branch of the small sciatic nerve (cut). 2. Biceps and external popliteal nerve. 3. Semi-tendinosus. 4. Internal popliteal nerve. 5. Semi-membranosus. 6. Popliteal vein. 7. Superior internal articular artery and nerve. 8. Popliteal artery. 9. Gracilis. 10. Superior external articular artery and nerve. 11. Sartorius. 12. Plantaris. 13. Gastrocnemius, inner head. 14. Gastrocnemius, outer head. 15. Short saphenous nerve. 16. Communicans peronei nerve. 17. External saphena vein. 19. Long saphenous nerve.

contains the popliteal vessels and their branches, the divisions of the

internal saphenous nerve to the knee, and piercing the fascia lata is distributed to the integument.

The *deep branch* passes onwards through the substance of the vastus internus muscle, resting on the tendon of the adductor magnus to the knee, where it inosculates with the internal articular branches of the popliteal, and the recurrent of the anterior tibial. It also sends a branch through the vastus internus, which supplies the synovial membrane of the joint, and inosculates with the superior external articular artery and external circumflex.

POPLITEAL SPACE.

This is a space of a diamond shape, situated at the back of the knee-joint. It is bounded below by the outer and inner heads of the gastrocnemius, above by the outer and inner hamstrings, in front by the posterior ligament of the knee-joint, and is covered in behind by the fascia lata of the thigh. It contains the popliteal vessels and their branches, the divisions of the

great sciatic nerve, termination of the external saphena vein, branches of the obturator and lesser sciatic nerves, lymphatic glands, and areolar tissue. The popliteal artery lies at the bottom of this space, immediately in contact with the ligamentum posticum Winslowii, the vein lying superficial to it, and the internal popliteal nerve superficial to both vein and artery; the external popliteal nerve (perineal) descends on the outer side of the space, in contact with the biceps tendon, and the lymphatic glands (four or five in number) surround the artery.

POPLITEAL ARTERY.

The popliteal artery (Fig. 269) commences from the termination of the femoral at the opening in the adductor magnus muscle, and passes obliquely outwards through the middle of the popliteal space to the lower border of the popliteus muscle, where it divides into the anterior and posterior tibial arteries. In structure the popliteal artery is remarkable for the thickness of its walls.

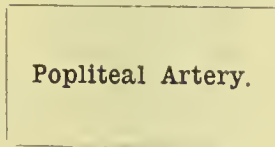
Plan of the **Relations** of the Popliteal Artery.

Superficially.

Semi-membranosus,
Popliteal nerve,
Popliteal vein,
Gastrocnemius,
Plantaris,
Soleus.

Inner Side.

Semi-membranosus,
Internal condyle,
Gastrocnemius.



Outer Side.

Biceps,
External condyle,
Gastrocnemius,
Plantaris,
Soleus.

Deeply.

Femur,
Ligamentum posticum Winslowii,
Popliteal fascia,
Popliteus.

Branches.—The branches of the popliteal artery are the—

- | | |
|------------------------------|---|
| Superior external articular, | Inferior external articular, |
| Superior internal articular, | Inferior internal articular, |
| Azygos articular, | Muscular, { Superior,
Inferior, or
Sural. |
| Cutaneous, | |

The **superior articular arteries**, *external* and *internal*, wind around the femur, immediately above the condyles, to the front of the knee-joint, anastomosing with each other, with the external circumflex, anastomotica magna, inferior articular, and recurrent of the anterior tibial. The external passes beneath the tendon of the

biceps, and the internal through an arched opening beneath the tendon of the adductor magnus. They supply the knee-joint and lower part of the femur, and give branches to the vasti muscles.

The **azygos articular artery** pierces the posterior ligament of the joint, the ligamentum posticum Winslowii, and supplies the crucial ligaments and synovial membrane. There are, frequently, several posterior articular arteries.

Cutaneous branches pass out between the two heads of the gastrocnemius and are distributed to the skin and subcutaneous fat of the calf.

The **inferior articular arteries** wind around the head of the tibia immediately below the joint, and anastomose with each other,

the superior articular arteries, and the recurrent of the anterior tibial. The external passes beneath the long external lateral ligament of the joint, the internal beneath the internal lateral ligament. They supply the knee-joint and the heads of the tibia and fibula.

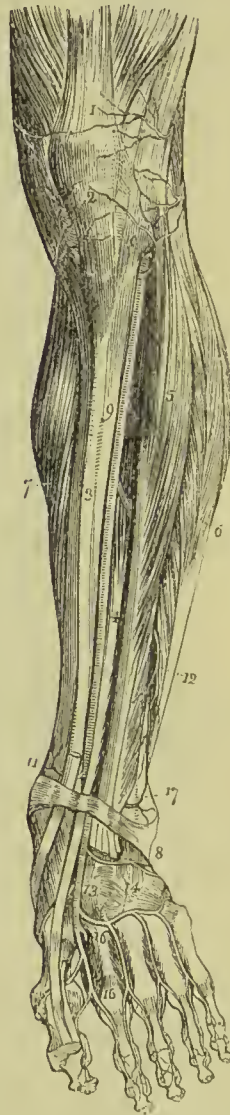
The **muscular** branches consist of a **superior** and **inferior** set: the former arise from the upper part of the artery and are distributed to the vastus externus and hamstring muscles; the latter, called also the **sural arteries**, pass to the two heads of the gastrocnemius.

ANTERIOR TIBIAL ARTERY.

The anterior tibial artery passes forwards between the two heads of the tibialis posticus muscle, and through

the opening in the upper part of the interosseous membrane, to the

FIG. 270.—Anterior aspect of the leg and foot, showing the anterior tibial and dorsalis pedis arteries; the tibialis anticus has been removed. 1. Tendon of insertion of the quadriceps extensor muscle. 2. Insertion of the ligamentum patellæ into the lower border of the patella. 3. Tibia. 4. Extensor proprius hallucis muscle. 5. Extensor longus digitorum. 6. The peronei. 7. Inner belly of the gastrocnemius and soleus. 8. Annular ligament. 9. Anterior tibial artery. 10. Its recurrent branch inosculating with (2) inferior external articular, and (1) superior external articular arteries, branches of the popliteal. 11. Internal malleolar artery. 17. External malleolar inosculating with the anterior peroneal artery (12). 13. Dorsalis pedis artery. 14. Tarsal and metatarsal branches. 15. Dorsalis hallucis artery. 16. Continuation of the dorsalis pedis into the sole of the foot.



anterior tibial region. It then runs down the anterior aspect of the leg to the ankle-joint, where it becomes the dorsalis pedis.

Relations.—In its course it rests on the interosseous membrane (to which it is connected by a little tendinous arch which is thrown across it), the lower part of the tibia, and the anterior ligament of the joint. In its upper third it is situated between the tibialis anticus and extensor longus digitorum, lower down between the tibialis anticus and extensor proprius hallucis; and just before it reaches the ankle it is crossed by the tendon of the extensor proprius hallucis, and becomes placed between that tendon and the tendons of the extensor longus digitorum. Its immediate relations are the venæ comites and anterior tibial nerve; the latter lies at first to its outer side, at about the middle of the leg it is placed superficially to the artery, and at the ankle is again at its outer side.

Plan of the **Relations** of the Anterior Tibial Artery.

Front.

Integument, superficial and deep fascia,
Tibialis anticus,
Extensor longus digitorum,
Extensor proprius hallucis,
Anterior tibial nerve.

Outer Side.

Anterior tibial nerve,
Extensor longus digitorum,
Extensor proprius hallucis,
Tendons of extensor longus digitorum.

Inner Side.

Tibialis anticus,
Tendon of extensor proprius hallucis.

Anterior Tibial Artery.

Behind.

Interosseous membrane.
Tibia (lower fourth),
Ankle-joint.

Branches.—The branches of the anterior tibial artery are the—

Recurrent,	External malleolar,
Muscular,	Internal malleolar.

The **recurrent branch** (anterior tibial recurrent) passes upwards beneath the origin of the tibialis anticus muscle to the front of the knee-joint, upon which it is distributed, anastomosing with the articular branches of the *popliteal artery*.

The **muscular branches** are numerous; they supply the muscles of the anterior tibial region. Some of them pass through the interosseous membrane to the muscles of the back of the leg and anastomose with branches of the posterior tibial and peroneal.

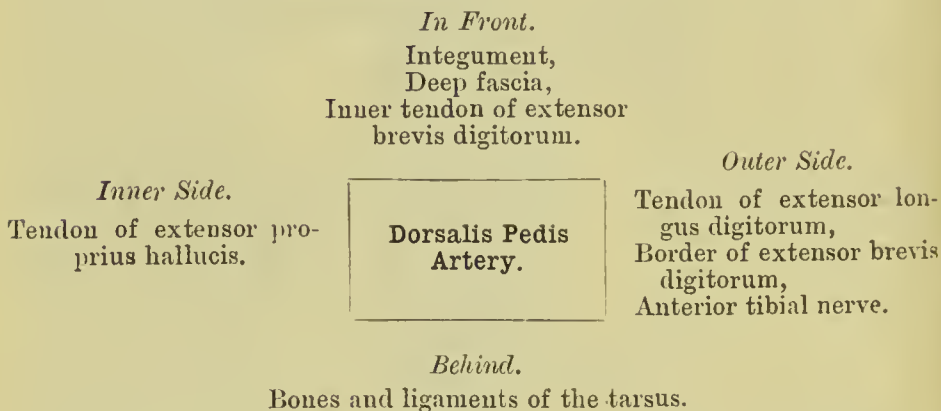
The **malleolar arteries** are distributed to the ankle-joint; the *external*, passing beneath the tendons of the extensor longus digitorum and peroneus tertius, inosculates with the anterior peroneal artery and dorsalis pedis; the *internal*, beneath the tendons of the extensor

proprius hallucis and tibialis anticus, inosculates with branches of the posterior tibial and internal plantar arteries. They supply branches to the ankle-joint.

The **DORSALIS PEDIS ARTERY** is continued forward along the tibial side of the dorsum of the foot, from the ankle to the base of the metatarsal bone of the great toe, where it divides into two branches, one of which dips between the two heads of the first dorsal interosseous muscle into the sole of the foot, and becomes continuous with the deep plantar arch; the other, called **dorsalis hallucis**, runs forward in the first interosseous space.

Relations.—It runs along the outer border of the tendon of the extensor proprius hallucis; at its fibular side is the innermost tendon of the extensor longus digitorum, and near its termination it is crossed by the inner tendon of the extensor brevis digitorum. It is accompanied by venæ comites, and has the continuation of the anterior tibial nerve to its outer side.

Plan of the **Relations** of the Dorsalis Pedis Artery.



Branches.—The branches of this artery are the—

Tarsal,	Dorsalis hallucis,
Metatarsal,	Magna hallucis.

The **tarsal** branch arches transversely across the tarsus, beneath the extensor brevis digitorum muscle, and supplies the articulations of the tarsal bones and outer side of the foot; it anastomoses with the external malleolar, peroneal arteries, and external plantar.

The **metatarsal** forms an arch across the base of the metatarsal bones, and supplies the outer side of the foot, anastomosing with the tarsal and external plantar artery. From its convex side the metatarsal gives off three branches, *dorsal interosseous*, which pass forward upon the dorsal interosseous muscles, and divide into branches (*dorsal collateral*) for the supply of the sides of the toes between which they are placed. At their commencement these interosseous branches receive the posterior perforating arteries from the plantar

arch, and opposite the heads of the metatarsal bones are joined by the anterior perforating branches from the digital arteries. The interosseous artery of the fourth interosseous space, in addition to the two dorsal collateral branches into which it bifurcates, sends a third branch to the outer side of the little toe.

The **dorsalis hallucis** runs forward upon the first dorsal interosseous muscle, and at the base of the first phalanx divides into two branches, one of which passes inwards beneath the tendon of the extensor proprius hallucis, and is distributed to the inner border of the great toe, while the other bifurcates into two *dorsal collateral digital* branches for the adjacent sides of the great and second toe.

The **arteria magna hallucis** arises from the dorsalis pedis, while in the metatarsal space and just before its inosculation with the external plantar artery. It sends a *digital* branch to the inner border of the great toe on its plantar aspect, and bifurcates to supply the *plantar collateral digital branches* of the great and second toe.

POSTERIOR TIBIAL ARTERY.

The posterior tibial artery passes obliquely downwards along the tibial side of the leg from the lower border of the popliteus muscle to the concavity of the os calcis, where it divides into the internal and external plantar artery. In its course it is accompanied by venæ comites, and by the posterior tibial nerve, which lies to its inner side at first, and to its outer side for the rest of its course.

Plan of the **Relations** of the Posterior Tibial Artery.

Superficially.

Integument and fascia,
Gastrocnemius,
Soleus,
Deep fascia,
Intermuscular fascia,
Posterior tibial nerve.

Inner Side.

Posterior tibial nerve
(upper third),
Vein.

**Posterior Tibial
Artery.**

Outer Side.

Posterior tibial nerve
(lower two-thirds),
Vein.

Deeply.

Tibialis posticus,
Flexor longus digitorum,
Tibia,
Ankle-joint.

Branches.—The branches of the posterior tibial artery are the—

Peroneal,	Internal calcanean,
Nutrient,	Internal plantar,
Muscular and cutaneous,	External plantar.
Communicating,	

The **PERONEAL ARTERY** is given off from the posterior tibial at about an inch below the lower border of the popliteus muscle; it is nearly as large as the anterior tibial artery, and passes obliquely outwards to the fibula. It then runs downwards along the inner border of the fibula to its lower third, where it divides into the anterior and posterior peroneal.

Relations.—The peroneal artery rests on the tibialis posticus muscle, and is covered in by the soleus, intermuscular fascia, and flexor longus hallucis,

having the fibula to its outer side.

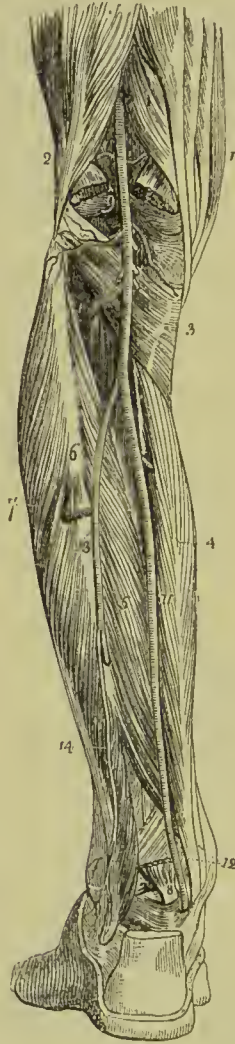
Branches.—The branches of the peroneal artery are—*muscular* to the soleus and neighbouring muscles; *nutrient* to the fibula; a *communicating* branch; and two terminal branches, *anterior* and *posterior peroneal*.

The **communicating** branch is given off near the lower end of the peroneal; it passes inwards to join a corresponding branch from the posterior tibial.

The **anterior peroneal artery** pierces the interosseous membrane at the lower third of the leg, and is distributed on the front of the outer malleolus, anastomosing with the external malleolar and tarsal arteries.

The **posterior peroneal** continues onwards along the posterior aspect of the outer malleolus to the side of the os calcis, to which, and to the muscles

FIG. 271.—Posterior view of the leg, showing the popliteal and posterior tibial arteries. 1. Tendons of the inner ham-string. 2. Tendon of the biceps, forming the outer ham-string. 3. Popliteus muscle. 4. Flexor longus digitorum. 5. Tibialis posticus. 6. The fibula; immediately below the figure is the origin of the flexor longus hallucis; the muscle has been removed in order to expose the peroneal artery. 7. Peronei muscles, longus and brevis. 8. Lower part of the flexor longus hallucis muscle with its tendon. 9. Popliteal artery giving off articular and muscular branches; the two superior articular are seen in the upper part of the popliteal space passing above the two heads of the gastrocnemius muscle, which are cut through near their origin. The two inferior are in relation with the popliteus muscle. 10. Anterior tibial artery passing through the angular interspace between the two heads of the tibialis posticus muscle. 11. Posterior tibial artery. 12. The relative position of the tendons and artery at the inner ankle from within outwards, previously to their passing beneath the internal annular ligament. 13. Peroneal artery, dividing a little below the figure, into two branches; the anterior peroneal is seen piercing the interosseous membrane. 14. Posterior peroneal.



arising from it, it distributes *external calcanean* branches. It anastomoses with the anterior peroneal, tarsal, external plantar, and posterior tibial arteries.

The **nutrient artery** of the tibia arises from the trunk of the



PLATE 25.

THE FRONT OF THE LEG AND SOLE OF THE FOOT.

FIG. 1.

- A. Tibialis anticus.
- a, a. Its tendon.
- B. Extensor longus digitorum.
- b, b. Its tendons.
- C. Extensor longus hallucis.
- c, c. Its tendon.
- F, F. Peroneus longus.
- G, G. Peroneus brevis.
- H, H. Deep fascia covering muscles and fibula.
- K. Extensor brevis digitorum.
- L. Anterior tibial artery and nerve.

FIG. 2.

- A. Calcaneum.
- B. Plantar fascia.
- C. Abductor minimi digiti.
- D. Abductor hallucis.
- E. Flexor accessorius.
- F. Flexor longus digitorum.
- G. Flexor longus hallucis.
- H. Flexor brevis hallucis.
- i. Lumbricales.
- L. External plantar artery and nerve.
- M. Internal plantar artery and nerve.

FIG. 3.

- H. Metatarsal bone of great toe.
- i. Tendon of tibialis posticus.
- K. External plantar nerve.
- L. External plantar artery.
- M. Interosseous muscles.
- O. Flexor brevis minimi digiti.
- P. Tendon of peroneus longus.

The other references are the same as in fig. 2.

Fig. 1

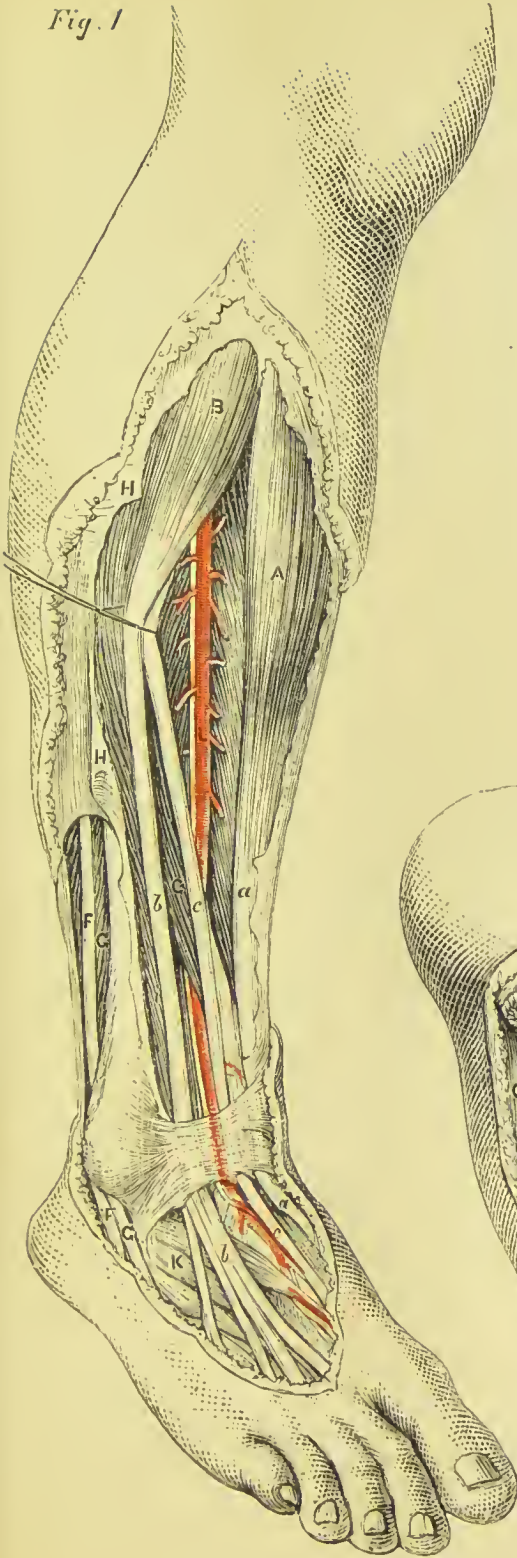


Fig. 2

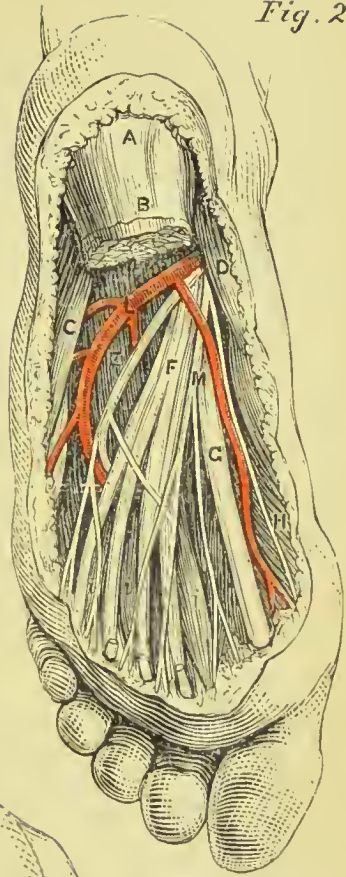
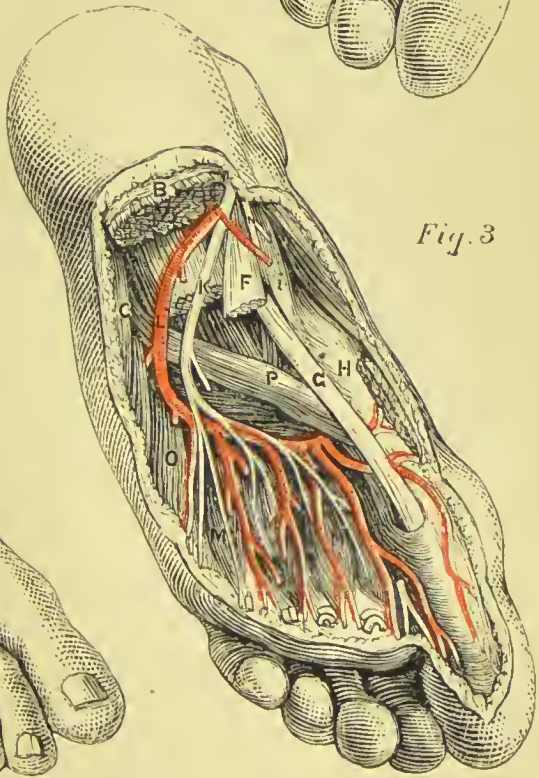


Fig. 3



posterior tibial, frequently above the origin of the peroneal, and proceeds to the nutrient canal, which it traverses obliquely from above downwards. It is the largest nutrient artery of bone in the body.

The **muscular branches** of the posterior tibial artery are distributed to the soleus and deep muscles of the posterior aspect of the leg. One of these branches is deserving of notice, a *recurrent branch*, which arises from the posterior tibial above the origin of the peroneal artery, pierces the soleus, and is distributed on the inner side of the head of the tibia, anastomosing with the inferior internal articular.

The **communicating** branch crosses the back of the tibia, about two inches above its lower end; it passes beneath the flexor longus hallucis tendon, and unites with the communicating branch of the peroneal.

The **internal calcanean branches**, three or four in number, proceed from the posterior tibial artery immediately before its division; they are distributed to the integument, to the inner side of the os calcis, and to the muscles which arise from its inner tuberosity; and anastomose with the external calcanean branches of the posterior peroneal, and with all the neighbouring arteries, forming around the heel a network of inosculations, *rete calcaneum*.

PLANTAR ARTERIES.

The **internal plantar artery** proceeds from the bifurcation of the posterior tibial at the inner malleolus, and passes along the inner border of the foot beneath the abductor hallucis, supplying the inner border of the foot and great toe, and anastomosing with the digital branches distributed to the latter.

The **external plantar artery**, much larger than the internal, passes obliquely outwards between the first and second layer of the plantar muscles to the fourth metatarsal space. It then turns transversely inwards between the second and third layer, to the first metatarsal space, where it inosculates with the dorsalis pedis. The



FIG. 272.—Arteries of the sole of the foot, the first and part of the second layer of muscles having been removed. 1. Under and posterior part of the os calcis; to which the origins of the first layer of muscles remain attached. 2. Flexor aecessorius. 3. Long flexor tendons. 4. Tendon of the peroneus longus. 5. Termination of the posterior tibial artery. 6. Internal plantar. 7. External plantar artery. 8. The plantar arch giving off four digital branches, which pass forwards on the interossei muscles. Three of these arteries are seen dividing, near the heads of the metatarsal bones, into collateral branches for adjoining toes.

transverse portion of the artery describes a slight curve, having the convexity forwards; this is the *plantar arch*.

Branches.—The branches of the external plantar artery are the—

Muscular,	Digital, { collateral,
Articular,	
	Posterior perforating.

The **muscular** and **articular branches** are distributed to the muscles of the sole of the foot and to the articulations of the tarsus.

The **digital branches** are four in number; the first is distributed to the outer side of the little toe; the three others pass forward to the cleft between the toes, and divide into *collateral branches*, which supply the adjacent sides of the three external toes, and the outer side of the second. At the bifurcation of the toes, a small branch is sent upwards from each digital artery, to inosculate with the dorsal interosseous branches of the metatarsal; these are the *anterior perforating arteries*.

The **posterior perforating** are three small branches which pass upwards between the heads of the three external dorsal interosseous muscles to inosculate with the arch formed by the metatarsal artery.

Varieties in the Arteries of the Lower Extremity.—The femoral artery occasionally divides at Poupart's ligament into two branches, and sometimes into three; the former is an instance of the high division of the profunda artery; and in the latter the branches are the profunda, superficial femoral, and internal circumflex. The point of origin of the profunda artery varies considerably in different subjects, being sometimes nearer to and sometimes farther from Poupart's ligament, but more frequently the former. The branches of the popliteal artery are very liable to variety in size; and in all these cases the compensating principle, so constant in the vascular system, is manifested. When the anterior tibial is of small size, the peroneal is large; and in place of dividing into two terminal branches at the lower third of the leg, descends to the lower part of the interosseous membrane, and emerges upon the front of the ankle, to supply the dorsum of the foot, or the posterior tibial and plantar arteries are large, and the external plantar is continued between the heads of the first dorsal interosseous muscle, to be distributed to the dorsal surface of the foot. Sometimes the posterior tibial artery is small and thread-like; and the peroneal, after descending to the ankle, curves inwards to the inner malleolus, and divides into two plantar arteries. If, in this case, the posterior tibial be sufficiently large to reach the ankle, it inosculates with the peroneal previously to the division of the latter. The internal plantar artery sometimes takes the distribution of the external plantar, which is short, and diminutive, and the latter not unfrequently replaces a deficient *dorsalis pedis*.

PULMONARY ARTERY.

The pulmonary artery has no connection with the general arterial distribution, but forms part of the lesser or pulmonary circulation. It is called an artery because it is engaged in conveying blood from the heart, but it must not be forgotten that it carries impure or venous blood from the right side of the heart to the lungs. It arises from the left side of the base of the right ventricle in front of the origin of the aorta, and ascends obliquely for the space of two inches to the under surface of the arch of the aorta, where it divides into the right and left pulmonary artery. In its course upwards and backwards it inclines to the left side, crossing the commencement of the aorta, and is connected by the root of its left branch to the under surface of the arch by a thick and impervious cord, the remains of the **ductus arteriosus** of the fœtus.

Relations.—It is enclosed for nearly the whole of its extent by the pericardium, and receives the attachment of the fibrous portion of that membrane by its upper portion. Behind, it rests against the ascending portion of the arch of the aorta and left auricle; on either side is the appendix of the corresponding auricle, and a coronary artery; and above, the superficial cardiac plexus, and the cord of the ductus arteriosus.

The **right pulmonary artery**, longer and somewhat larger than the left, passes transversely outwards behind the ascending aorta and superior vena cava to the root of the right lung, where it divides into two branches, the lower supplying the lower lobe, and the upper the other two lobes. In its course it lies parallel with and in front of the right bronchus.

The **left pulmonary artery**, shorter and smaller than the right, crosses the descending aorta and left bronchus to the root of the left lung, where it divides into two branches for the two lobes.

VEINS.

The veins are the vessels which carry the blood back from the capillaries to the heart. They are larger, more numerous, and anastomose more freely than the arteries, and form two great systems of vessels, the superficial and the deep, the former lying between the superficial and deep layers of the superficial fascia, and the latter accompanying the arteries in their distribution; the two systems have very numerous communications.

The veins will be described according to the primary division of the body, taking first, those of the head and neck; next, those of the upper extremity; then, those of the lower extremity; and lastly, the veins of the trunk.

VEINS OF THE HEAD AND NECK.

The veins of the head and neck may be arranged into three groups, namely, veins of the exterior of the head, veins of the diploë and interior of the cranium, veins of the neck.

The veins of the exterior of the head are the—

Facial,	Temporo-maxillary,
Internal maxillary,	Posterior auricular,
Temporal,	Occipital.

The **facial vein** commences on the anterior part of the head in a venous plexus, formed by the communications of the branches of the temporal, and descends along the middle line of the forehead, under the name of *frontal vein*, to the root of the nose, where it is connected with its fellow of the opposite side by a communicating trunk, the *nasal arch*. There are usually two frontal veins, which communicate by a transverse inosculation; but sometimes the vein is single and bifurcates at the root of the nose into the two angular

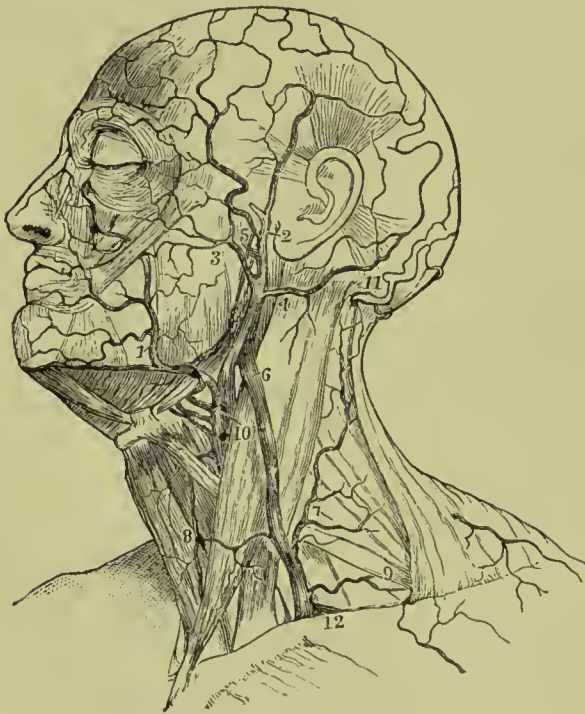


FIG. 273.—Superficial veins of the head and neck. 1. Facial. 2. Temporal. 3. Transverse facial. 4. Posterior auricular. 5. Internal maxillary. 6. External jugular. 7. Posterior external jugular. 8. Anterior jugular. 9. Posterior scapular. 10. Internal jugular. 11. Occipital. 12. Subclavian.

veins. From the nasal arch the frontal is continued downwards by the side of the root of the nose, and near the angle of the eye, under the name of *angular vein*; it then passes beneath the zygomatic muscles, becomes the facial vein, and descends along the anterior border of the masseter muscle, crossing the body of the lower jaw by the side of the facial artery, to the submaxillary gland, and from thence to the internal jugular vein, in which it terminates.

The *branches* which the facial vein receives in its course are—the *supraorbital*, which joins the frontal vein; the *dorsal veins* of the nose, which terminate

in the nasal arch; the *ophthalmic*, which communicates with the angular vein; the *palpebral* and *nasal*, which open into the angular

vein; a considerable trunk, the *deep facial*, or *anterior internal maxillary*, which returns the blood from the speno-maxillary fossa, from the infraorbital, palatine, Vidian, and speno-palatine veins, and joins the facial beneath the zygomatic process of the superior maxillary bone; and the veins corresponding with the branches of the facial artery. It receives also a *communicating* branch from the temporo-maxillary, given off from that trunk near the angle of the jaw, and often, also, the *ranine* vein.

The **internal maxillary vein** receives the veins from the zygomatic and pterygoid fossæ, which correspond generally with the branches of the internal maxillary artery; they are so numerous and communicate so freely as to constitute a *pterygoid plexus*, which is placed between the temporal and external pterygoid muscles. This plexus sends a small branch through the foramen Vesalii to join the cavernous sinus. Passing backwards behind the neck of the lower jaw, the internal maxillary joins the temporal to form the temporo-maxillary vein.

The **temporal vein** commences on the vertex of the head by a plexiform network, which is continuous with the frontal, opposite temporal, auricular, and occipital veins. The ramifications of this plexus form an anterior and posterior branch which unite immediately above the zygoma; the trunk is here joined by another large vein, the *middle temporal*, which collects the blood from the temporal muscle and outer segment of the orbit, and pierces the temporal fascia near the root of the zygoma. The temporal vein then descends in the substance of the parotid gland and a little below the neck of the lower jaw joins with the internal maxillary to form the temporo-maxillary vein. The temporal vein receives the *anterior auricular*, *masseteric*, *transverse facial*, and *parotid veins*.

The **temporo-maxillary vein**, a short trunk formed by the union of the temporal and internal maxillary, passes downwards in the substance of the parotid gland, lying in front of the external carotid artery; near the angle of the jaw it divides into two branches, one of which passes over the surface of the sterno-mastoid to form with the posterior auricular the external jugular; the other joins the facial vein, and forms with it a common trunk which ends in the internal jugular.

The **posterior auricular vein** communicates with the plexus of the vertex of the head, and descends behind the ear to join the superficial division of the temporo-maxillary and form the external jugular vein. It receives in its course the veins of the external ear and the *stylo-mastoid vein*.

The **occipital vein**, commencing posteriorly in the plexus at the vertex of the head, follows the direction of the occipital artery, and passing deeply beneath the muscles of the back part of the neck, terminates in the deep cervical vein. It communicates with the lateral sinus by means of a large branch which passes through the mastoid foramen, the *mastoid vein*.

VEINS OF THE DIPLOË.

The diploë of the bones of the head is furnished in the adult with irregular sinuses (*venæ diploeticæ*), which are formed by a continuation of the internal coat of the veins into the osseous canals in which they are lodged. At the middle period of life these sinuses are confined to separate bones; but in old age, after the ossification of the sutures, they may be traced from one bone to the next. They receive their blood from the capillaries supplying the cellular structure of the diploë, and terminate externally in the veins of the pericranium, internally in the veins and sinuses of the dura mater; they are separated from the bony walls of the canals by a thin layer of marrow.

Four of these diploetic veins can be generally distinguished, namely, frontal, anterior temporal, posterior temporal, and occipital. The *frontal*, the smallest of the four, escapes from the frontal bone at

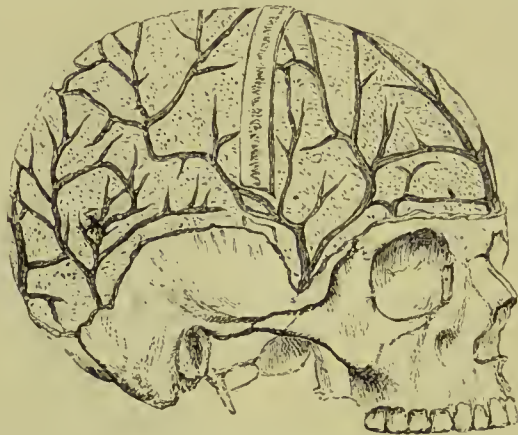

FIG. 274.—The external table of the skull removed to show the veins of the cranial diploë.

the supraorbital notch, and opens into the supraorbital vein. The *anterior temporal* also collects the blood from the frontal bone, and terminates either in the deep temporal veins or in the cavernous sinus, by passing through an opening in the great wing of the sphenoid. The *posterior temporal* commences in the parietal bone, and opens through an aperture in that bone into the lateral sinus, sometimes sending a branch outwards to the veins of the scalp. The *occipital*, the largest of the four, originates in the occipital bone, and terminates internally in the torcular Herophili or lateral sinus, or externally in the occipital vein.

Emissary Veins.—These are small veins which pass through the walls of the skull and establish communications between the sinuses and the veins on the exterior of the skull; they are large in the young child, but small and inconstant in the adult. The chief emissary vein are as follows:—(1) A *mastoid* branch, passing

through the mastoid foramen, and connecting the lateral sinus with the occipital or posterior auricular vein ; (2) a *parietal* branch (inconstant), passing through the parietal foramen and connecting the superior longitudinal sinus with the veins of the scalp ; (3) a *nasal* branch, transmitted by the foramen cæcum and connecting the nasal veins with the superior longitudinal sinus ; (4) a *condylar* branch, passing through the posterior condylar foramen and forming a communication between the lateral sinus and the veins around the cervical vertebræ (inconstant) ; (5) a small vein passing through the foramen of Vesalius and connecting the pterygoid plexus of veins with the cavernous sinus (inconstant) ; (6) an *occipital* branch traversing the external occipital protuberance, and passing from the occipital veins to the torcular Herophili (inconstant) ; (7) small veins from the pterygoid and pharyngeal plexuses passing through the foramen ovale and foramen lacerum medium to the cavernous sinus. (8) A small venous plexus accompanies the internal carotid artery through the carotid canal and opens into the internal jugular vein ; and (9) a venous ring surrounds the hypoglossal nerve in the anterior condylar foramen, and communicates between the inferior petrosal sinus and the deep veins of the neck.

CEREBRAL AND CEREBELLAR VEINS.

The cerebral veins are remarkable for the absence of valves, and for the extreme tenuity of their coats. They may be arranged into the superficial, and deep or ventricular veins.

The **superficial cerebral veins** are situated on the surface of the hemispheres lying in the sulci. They are named from the position which they occupy on the surface of the brain, either superior or inferior, internal or external, anterior or posterior.

The **superior cerebral veins**, ten to twelve in number at each side, pass obliquely forwards, and terminate in the superior longitudinal sinus, in the opposite direction to the course of the stream of blood in the sinus. In the infant the direction of these veins is nearly transverse.

The **inferior cerebral veins** pass from the lower surface of the hemispheres to the cavernous, superior petrosal and lateral sinuses. One branch, of larger size than the rest, commences on the under surface of the temporo-sphenoidal lobe, and after running for some distance in the fissure of Sylvius, empties into the cavernous sinus ; it is called the *middle cerebral vein*.

The **deep or ventricular veins** commence within the lateral ventricles by the veins of the *corpora striata* and those of the *choroid plexuses*, which unite to form the two venæ Galeni.

The **venæ Galeni** pass backwards in the structure of the velum interpositum ; and, after uniting, terminate in the straight sinus. They receive in their course small branches from the thalamus opticus and choroid plexus of the third ventricle. The *basilar vein* is the chief tributary of the vein of Galen, which it reaches by wind-

ing round the *crus cerebri*; it conveys the blood from the anterior cerebral veins, deep Sylvian vein, and inferior striate veins. The veins of Galen also receive branches from the corpora quadrigemina, pineal body and posterior cornu of the lateral ventricle.

The **cerebellar veins** are disposed, like those of the cerebrum, on the surface of the lobes of the cerebellum; they are situated, some on the superior, some on the inferior surface, while others occupy the borders of the organ. Those in the middle line of the upper surface terminate in the veins of Galen and straight sinus; those of the under surface in the lateral and occipital sinuses.

SINUSES OF THE DURA MATER.

The sinuses of the dura mater are irregular channels formed by the splitting of the layers of that membrane, and lined on their inner surface by a continuation of the internal coat of the veins. They are seventeen in number, six pairs and five single ones, and are as follows:—

Five single.	{	Superior longitudinal sinus, Inferior longitudinal sinus, Straight sinus, Circular, Transverse.
Six pairs.	{	Two occipital sinuses, Two lateral sinuses, Two cavernous, Two superior petrosal, Two inferior petrosal, Two sphenoparietal.

The **superior longitudinal sinus** is situated in the attached margin of the falx cerebri, and extends along the middle line of the arch of the skull, from the foramen cæcum in the frontal, to the inner protuberance of the occipital bone. In the young child it receives a small vein from the nose which reaches it by passing through the foramen cæcum, and not unfrequently this remains permanent in the adult. It is triangular in form, small in front, and increases gradually in size as it passes backwards; it receives the superior cerebral veins, numerous small veins from the diploë, and near the posterior extremity of the sagittal suture the *parietal veins* from the pericranium and scalp. Examined in its interior, it presents numerous transverse fibrous bands, the *chordæ Willisii*, which are stretched across its inferior angle; and some small white granular masses, the *glandulæ Pacchioni*; the oblique openings of the cerebral veins, with their valve-like margin, are also seen on the walls of the sinus.

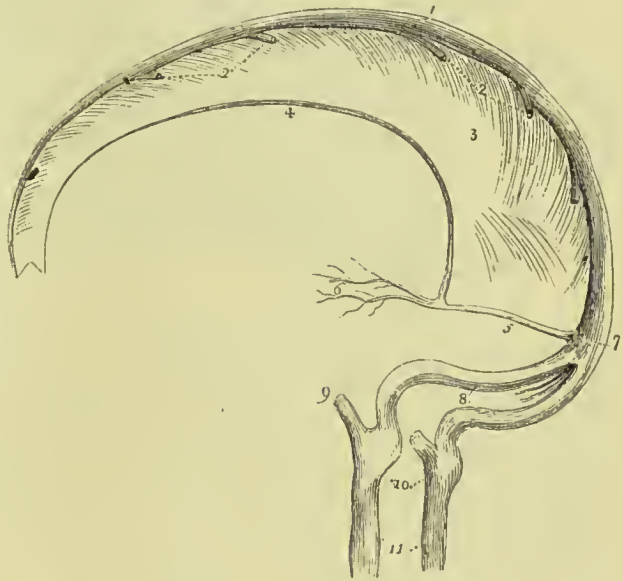The termination of the superior longitudinal sinus forms a considerable dilatation, with which the straight sinus communicates in front, the lateral sinuses on each side, and the occipital sinuses below. This dilatation is generally situated to the right of the

middle line, and is named the **torcular Herophili**. It is continuous with the lateral sinus of the same side, and communicates, by a transverse channel, with the commencement of the lateral sinus of the opposite side.

The **inferior longitudinal sinus** is situated in the free margin of the falx cerebri; it is cylindrical in form, and extends from near the crista galli to the anterior border of the tentorium, where it terminates in the straight sinus. It receives in its course several veins from the falx and sometimes one or two from the internal surface of the hemispheres.

The **straight sinus** is the sinus of the tentorium; it is situated at the line of union of the falx with the tentorium; is prismoid in form, and extends across the tentorium, terminating by bending outwards in a direction opposite to that taken by the superior

FIG. 275.—Sinuses of the upper and back part of the skull. 1. Superior longitudinal sinus. 2, 2. Superior cerebral veins opening into the sinus from behind forwards. 3. Falx cerebri. 4. Inferior longitudinal sinus. 5. Straight sinus. 6. Venæ Galeni. 7. Torcular Herophili. 8. The lateral sinuses, with the occipital sinuses between them. 9. The termination of the inferior petrosal sinus of one side. 10. Bulbs of the internal jugular veins, corresponding with the jugular fossæ. 11. Internal jugular veins.



longitudinal sinus, and forming the lateral sinus of that side. Besides the inferior longitudinal sinus it receives the venæ Galeni, the cerebral veins from the inferior part of the posterior lobes, and the superior cerebellar veins.

The **circular sinus** is situated in the sella turcica, surrounding the pituitary body; it consists of an anterior and posterior portion, the former being usually the larger. It receives veins from the pituitary body, the dura mater and the bone, and forms a communication between the two cavernous sinuses.

The **transverse** or **basilar sinus** consists of a plexus of veins lying on the basilar portion of the occipital bone. It communicates with the two inferior petrosal sinuses, and with the anterior spinal veins.

The **occipital sinuses** are two canals of small size, situated at the back of the foramen magnum; as they ascend they unite to form a

single trunk which runs in the attached border of the falx cerebelli, and terminates in the torcular Herophili. They communicate with the posterior spinal veins, and not unfrequently with the termination of the lateral sinuses.

The **lateral sinuses** are variable in their origin, but most frequently the right is formed by the superior longitudinal sinus and the left by the straight sinus. They pass outwards, in the attached margin of the tentorium, and then curve downwards and inwards along the base of the petrous portion of the temporal bone, at each side, to the posterior compartment of the jugular foramina, where they terminate in the internal jugular veins. Each sinus rests in its course on the lateral groove of the occipital bone, posterior inferior angle of the parietal, mastoid portion of the temporal, and again on the occipital bone. They receive the cerebral veins from the inferior surface of the posterior lobes, the inferior cerebellar veins, superior petrosal sinuses, mastoid and posterior condylar veins, and often the veins from the occipital diploë. These sinuses are often unequal in

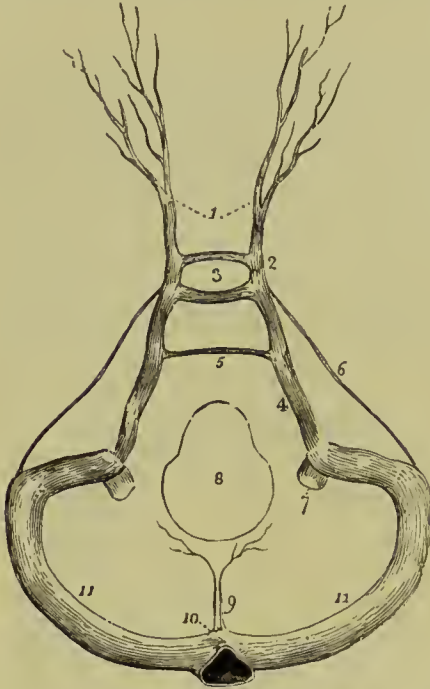
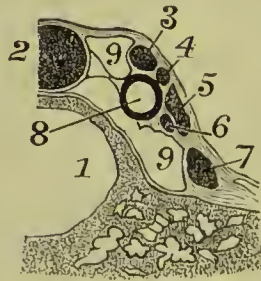


FIG. 276.—Sinuses of the base of the skull. 1. Ophthalmic veins. 2. Cavernous sinus of one side. 3. Circular sinus: the figure occupies the position of the pituitary gland in the sella turcica. 4. Inferior petrosal sinus. 5. Transverse sinus. 6. Superior petrosal sinus. 7. Internal jugular vein. 8. Foramen magnum. 9. Occipital sinuses. 10. Torcular Herophili. 11, 11. Lateral sinuses.

size, the right being larger than the left.

The **cavernous sinuses** are named from presenting in their interior a reticular structure similar to that of cavernous tissue.

FIG. 277.—Cavernous sinus. 1. Sphenoidal cells. 2. Pituitary body. 3. Third nerve. 4. Fourth nerve. 5. Ophthalmic division of fifth nerve. 6. Sixth nerve. 7. Superior maxillary division of fifth nerve. 8. Internal carotid artery. 9, 9. Cavernous sinus.



They are situated at each side of the sella turcica, receiving, anteriorly, the ophthalmic veins through the sphenoidal fissures, and the spheno-parietal sinuses, and ter-

minating posteriorly in the inferior petrosal sinuses. In the walls of the cavernous sinus are the internal carotid artery, several filaments of the carotid plexus, the third, fourth, ophthalmic division of the

fifth, and sixth nerve. The third, fourth, and ophthalmic nerves lie in the outer wall of the sinus, just beneath the dura mater; the internal carotid artery also lies on the outer wall of the sinus, but projects into its lumen. The sixth nerve winds round the outer side of the carotid artery, and is continued forwards on the floor of the sinus; the nerve and artery are separated from the cavity of the latter by its lining membrane only. As the nerves approach the sphenoidal fissure they change their position, so that at that opening the fourth nerve is highest, next, the frontal and lachrymal branches of the ophthal-

Sphenoidal Fissure.

Cavernous Sinus.




FIG. 278.—Diagram of the nerves passing through the cavernous sinus.

mic, then the upper division of the third, the nasal branch of the ophthalmic, the lower division of the third, and the sixth nerves, in the order here given. Besides the ophthalmic vein the cavernous sinus receives the cerebral veins of the under part of the anterior lobe, a vein from the posterior border of the orbit and the vein of the middle fossa of the cranium. The cavernous sinuses communicate by means of the ophthalmic with the facial veins, by the circular sinus with each other, and by the superior petrosal with the lateral sinuses.

The **inferior petrosal sinuses** are the continuations of the cavernous sinuses backwards. They run in the shallow groove formed by the lower border of the petrous portion of the temporal bone and the basilar portion of the occipital at each side of the base of the skull, to the jugular foramina, where they terminate with the lateral sinuses in the commencement of the internal jugular veins.

The **superior petrosal sinuses** pass obliquely backwards along the attached border of the tentorium, on the upper margin of the petrous portion of the temporal bone, and establish a communication between the cavernous and lateral sinus at each side. They are of very small size, and receive one or two cerebral veins from the inferior part of the middle lobes, and a cerebellar vein from the anterior border of the cerebellum. Near the extremity of the petrous bone these sinuses cross the oval aperture which transmits the fifth nerve (*Meckel's space*).

The **spheno-parietal sinuses** are two minute blood-channels which run under the border of the lesser wing of the sphenoid. They commence by small meningeal veins, and terminate in the commencement of the cavernous sinuses.

OPHTHALMIC VEINS.—The veins of each orbit are two in number, *superior* and *inferior*. The **superior ophthalmic vein**, much the larger of the two, commences near the root of the nose by communications with the angular and supra-orbital branches of the facial vein; it runs along the inner side of the orbit with the ophthalmic artery, then crosses the optic nerve from within outwards, and passing through the sphenoidal fissure joins the cavernous sinus. Its tributaries are the *anterior* and *posterior ethmoidal*, *anterior* and *posterior ciliary*, *central vein of the retina*, *muscular*, and *lacrimal veins*. The **inferior ophthalmic vein** is derived from the posterior ciliary and inferior muscular branches, it runs near the floor of the orbit, communicates through the spheno-maxillary fissure with the pterygoid plexus, and terminates in the same way as the upper branch, which it often joins.

VEINS OF THE NECK.

The veins of the neck which return the blood from the head are—

External jugular,	Internal jugular,
Anterior jugular,	Vertebral.

The **external jugular vein**, the continuation of the superficial division of the temporo-maxillary, augmented by the junction of the posterior auricular, and sometimes of the occipital, commences at the lower border of the parotid gland, in front of the sterno-mastoid muscle. It descends the neck in the direction of a line drawn from the angle of the lower jaw to the middle of the clavicle, crosses the sterno-mastoid, and terminates near the posterior and inferior attachment of that muscle, in the subclavian vein. It is provided with two pairs of valves, one situated near its entrance into the subclavian vein, and the other about the middle of the neck. In its course downwards, it lies on the anterior lamella of the deep cervical fascia, which separates it from the sterno-mastoid muscle, and is covered in by the platysma myoides and superficial fascia; at the root of the neck it pierces the deep cervical fascia. It is accompanied, for the upper half of its course, by the auricularis magnus nerve. The *branches* which it receives are the occipital cutaneous and posterior cervical cutaneous, and, near its termination, the supra-scapular and posterior scapular. Frequently a branch of considerable size, called **posterior external jugular**, collects the blood from the occipital region and muscles of the back of the neck; it runs between the splenius and trapezius, and joins the external jugular about the middle of its course.

The **anterior jugular vein** commences on the os hyoides by several small veins and by a branch from the temporo-maxillary, and passes downwards along the mid-line of the neck to the sternum ; it then turns outwards behind the lower part of the sterno-mastoid and opens into the subclavian vein, near the termination of the external jugular. The two veins communicate with each other, and with the external and internal jugular veins. The anterior jugular is very variable in size, sometimes almost or entirely replacing the external jugular, and at others being represented only by a few small branches.

The **internal jugular vein**, formed by the convergence of the lateral and inferior petrosal sinus, commences at the under surface of the jugular foramen on each side of the base of the skull, by a considerable dilatation (the *bulb* of the internal jugular vein), and descends the side of the neck, lying, in the first instance, to the outer side of the internal carotid, then on the outer side of the common carotid artery to the root of the neck, where it unites with the subclavian, and constitutes the innominate vein. At its commencement, the internal jugular vein is posterior and external to the internal carotid artery and eighth, ninth, and tenth pairs of nerves, the hypoglossal nerve being behind it ; lower down, the vein and artery are on the same plane, the glosso-pharyngeal and hypoglossal nerves passing forwards between them, the pneumogastric being between and behind in the same sheath, and the spinal accessory nerve, crossing obliquely behind or before the vein at its upper part. It is provided with a pair of valves, placed near its termination.

The **tributaries** which the internal jugular receives in its course are—*pharyngeal*, *lingual*, deep division of the *temporo-maxillary*, *facial*, *middle thyroid*, and sometimes the *occipital*.

The **vertebral vein** descends by the side of the vertebral artery, in the canal formed by the foramina in the transverse processes of the cervical vertebræ, and at the root of the neck opens into the subclavian vein close to its termination. In the lower part of the vertebral canal it frequently divides into two branches, one of which advances forwards, while the other passes through the foramen in the transverse process of the seventh cervical vertebra, before opening into the subclavian vein. On the right side it crosses the first part of the subclavian artery.

The **tributaries** which it receives in its course are the *posterior condylar* vein, *muscular* veins, *cervical meningo-rachidian* veins, and near its termination the *superficial* and *deep cervical* veins.

The **inferior thyroid veins**, two, and frequently more in number, are situated one on each side of the trachea, and receive the venous blood from the thyroid gland. They communicate with each other, and with the middle and superior thyroid veins, and form a plexus on the front of the trachea. The right vein terminates in the right innominate vein, just at its union with the superior cava ; the left in the left innominate vein.

VEINS OF THE UPPER EXTREMITY.

The veins of the upper extremity are deep and superficial. The *deep* veins accompany the branches and trunks of the arteries, and constitute their *venæ comites*. The *venæ comites* of the radial and ulnar artery are enclosed in the same sheath with those vessels, and terminate at the bend of the elbow in the brachial veins. The brachial *venæ comites* are situated one at each side of the artery, and open into the axillary vein; the axillary becomes the subclavian, and the subclavian unites with the internal jugular to form the innominate vein.

The **superficial veins** of the arm are the—

Anterior ulnar vein,	Cephalic vein,
Posterior ulnar vein,	Median vein,
Basilic vein,	Median basilic,
Radial vein,	Median cephalic.

The **anterior ulnar vein** collects the venous blood from the inner and palmar border of the hand, and ascends along the anterior aspect of the inner side of the forearm to the bend of the elbow, where it joins with the posterior ulnar to form the basilic vein.

The **posterior ulnar vein** commences on the dorsum of the hand by the ulnar termination of the *venous arch*, which receives the *digital veins* from the fingers, and, after being joined by a large vein, the *vena salvatella*, from the little finger, ascends along the posterior aspect of the forearm to the bend of the elbow, where it turns forward and terminates by joining the anterior ulnar vein.

The **basilic vein** (*βασιλικός*, royal, or principal), formed by the union of the anterior and posterior ulnar veins, ascends along the inner side of the upper arm, receives the median basilic vein, and near its middle pierces the fascia; it then passes upwards to the axilla, and being joined by the brachial *venæ comites*, becomes the axillary vein.

The **radial vein** commences on the dorsum of the hand, by the radial termination of the *venous arch*, which receives the veins of the fingers. This origin is increased by the junction of some small veins from the thumb, and a branch from the *venæ comites* of the deep palmar arch. The radial vein ascends the dorsal side of the forearm to a little below its middle, then lies on its anterior aspect to the bend of the elbow, where it unites with the median cephalic, to form the cephalic vein.

The **cephalic vein** (*κεφαλή*, the head) ascends along the outer side of the upper arm to its superior third; it then enters the groove between the pectoralis major and deltoid muscle, where it is in relation with the descending branch of the thoracico-acromialis artery, pierces the costo-coracoid membrane, and terminates beneath the clavicle in the axillary vein. A large communicating branch some-

times crosses the clavicle and connects this vein with the external jugular.

The **median vein** is intermediate in position between the anterior and radial veins; it begins at the wrist by the junction of branches from the palm of the hand, and collects the blood from the anterior aspect of the forearm, communicating with the radial and anterior ulnar. At the bend of the elbow it receives a branch from the deep veins, and divides into two branches, the median cephalic and median basilic.

The **median cephalic vein**, longer and somewhat smaller than the median basilic, passes obliquely outwards, in the groove between the biceps and supinator longus, to unite with the radial and form the cephalic vein. The branches of the external cutaneous nerve pass behind it.

The **median basilic vein**, larger than the median cephalic, passes obliquely inwards, in the groove between the biceps and pronator radii teres, and joins the basilic vein. This vein is crossed by one or two filaments of the internal cutaneous nerve, and overlies the brachial artery, from which it is separated by the semilunar fascia of the biceps.

AXILLARY VEIN.—The axillary vein is formed by the union of the venæ comites of the brachial artery with the basilic vein. It lies to the inner side of the artery, receives numerous branches from the collateral veins of the branches of the axillary artery, and at the lower border of the first rib becomes the subclavian vein. Above the pectoralis minor it receives the cephalic vein.

SUBCLAVIAN VEIN.—The subclavian vein crosses the first rib beneath the clavicle, and unites with the internal jugular vein to form the innominate vein. It lies at first in front of the subclavian artery, and then in front of the scalenus anticus, which separates it from that vessel. The phrenic and pneumogastric nerves pass between the artery and vein. The veins opening into the sub-

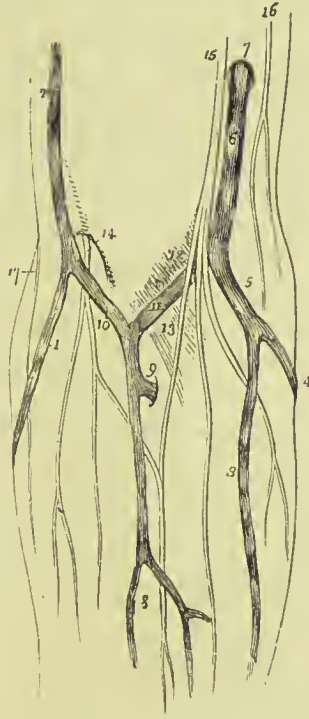
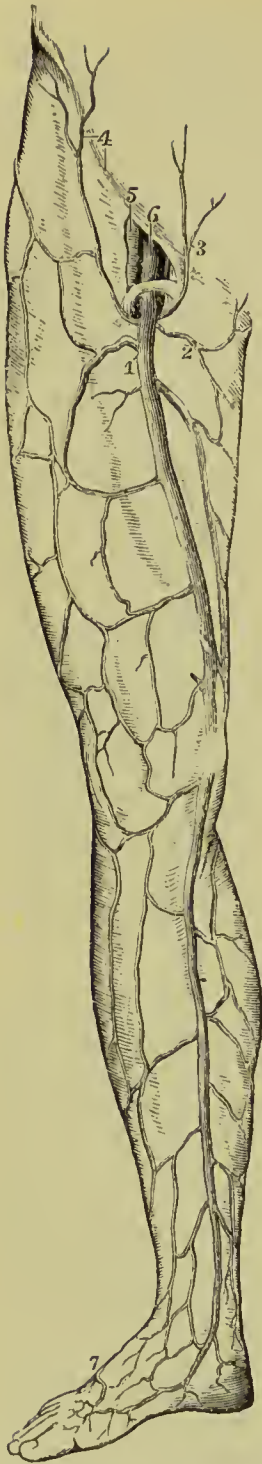


FIG. 279.—Veins of the forearm and bend of the elbow. 1. Radial vein. 2. Cephalic vein. 3. Anterior ulnar vein. 4. Posterior ulnar vein. 5. The trunk formed by their union. 6. Basilic vein, piercing the deep fascia at 7. 8. Median vein. 9. Communicating branch between the deep veins of the forearm and the upper part of the median vein. 10. Median cephalic vein. 11. Median basilic. 12. Position of the brachial artery. 13. The semilunar fascia of the biceps. 14. External cutaneous nerve. 15. Internal cutaneous nerve. 16. Intercosto-humeral nerve. 17. External cutaneous branch of the musculo-spiral nerve.



clavian are the external and anterior jugular externally to the scalenus anticus, and the vertebral internally to that muscle.

VEINS OF THE LOWER EXTREMITY.

The veins of the lower extremity are deep and superficial. The *deep veins* accompany the branches of the arteries in pairs, and form the *venæ comites* of the anterior and posterior tibial and peroneal artery. These veins unite in the popliteal region to form a single vessel of large size, the popliteal, which successively becomes in its course the femoral and the external iliac vein.

POPLITEAL VEIN.—The popliteal vein ascends through the popliteal region, lying, in the first instance, superficial to the artery, and then getting somewhat to its outer side; and, passing through the oval opening in the tendon of the adductor magnus, becomes the femoral vein. It receives several muscular and articular branches, and the external saphena vein. The valves in this vein are four or five in number.

FEMORAL VEIN.—The femoral vein, commencing at the opening in the adductor magnus muscle, ascends the thigh in the sheath of the femoral artery, and entering the pelvis beneath Poupart's ligament, becomes the external iliac vein. In the lower part of its course it is situated on the outer side of the artery; it then becomes placed behind that vessel, and at Poupart's ligament, lies to its inner side. It receives the muscular veins and profunda, and, through the saphenous opening, the internal saphena vein. The valves in this vein are four or five in number.

The **profunda vein** is formed by the convergence of the numerous small veins which accompany the branches of the artery; it is a vein, of large size, lies in front of the profunda artery, and terminates in the femoral at about two inches below Poupart's ligament.

SUPERFICIAL VEINS.—The superficial veins are the *external* or *short*, and the *internal* or *long*

FIG. 280.—Superficial veins of the front of thigh and inner side of leg. 1. Internal saphena. 2. Superficial external pudic. 3. Superficial epigastric. 4. Superficial circumflex iliac. 5. Femoral artery. 6. Femoral vein. 7. Dorsal arch connecting the short and long saphena veins.

saphena. They commence on the dorsum of the foot in a *venous arch* which lies across the metatarsus; this venous arch receives the *digital veins* by its convex side.

The **external saphena vein** commences at the outer extremity of the venous arch and on the outer border of the foot. It passes behind the outer ankle, ascends along the posterior aspect of the leg, lying in the groove between the two bellies of the gastrocnemius muscle, and pierces the deep fascia in the popliteal region to join the popliteal vein. It receives several cutaneous branches in the popliteal region previously to perforating the deep fascia, and is in relation in its course with the external saphenous nerve.

The **internal saphena vein** commences at the inner extremity of the venous arch of the dorsum and on the inner side of the foot and great toe. It ascends in front of the inner ankle and along the inner side of the leg; it then passes behind the inner condyle of the femur and along the inner side of the thigh to the saphenous opening where it pierces the sheath of the femoral vessels, and terminates in the femoral vein, at about one inch and a half below Poupart's ligament.

It receives in its course the cutaneous veins of the leg and thigh, and communicates freely with the deep veins. At the saphenous opening it is joined by the superficial epigastric and circumflex iliac vein, and by the external pudics. The situation of this vein in the thigh is not unfrequently occupied by two or even three trunks of nearly equal size. It is accompanied in its course below the knee by the long saphenous nerve.

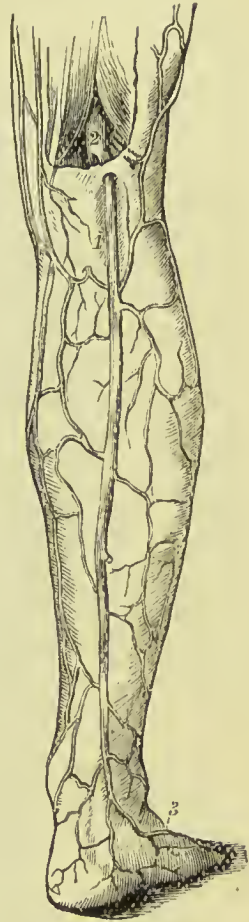


FIG. 281. — External saphena vein and its connections. 1. External saphena. 2. Popliteal. 3. Dorsal vein of the foot.

VEINS OF THE TRUNK.

The veins of the trunk may be divided into—1. The superior vena cava, with its formative branches. 2. The inferior vena cava, with its formative branches. 3. The azygos veins. 4. The vertebral and spinal veins. 5. The cardiac veins. 6. The portal vein. 7. The pulmonary veins.

SUPERIOR VENA CAVA, WITH ITS FORMATIVE BRANCHES.

The **innominate veins** are two large trunks, formed by the union of the internal jugular and subclavian vein at each side of the root of the neck.

The **right innominate** or **brachio-cephalic vein**, about an inch and a quarter in length, lies superficially and externally to the innominate artery, and descends almost vertically to unite with its fellow of the opposite side in the formation of the superior cava. It lies superficial to and on the right side of the *arteria innominata*, and has on its outer side the pleura and apex of the right lung. At the junction of the jugular and subclavian vein it receives from behind the *ductus lymphaticus dexter*, and lower down it has opening into it the *right internal mammary*, *right superior intercostal*, and *right inferior thyroid vein*.

The **left innominate** or **brachio-cephalic vein**, considerably longer than the right, extends almost horizontally across the roots of the three great arteries arising from the arch of the aorta to the right side of the mediastinum, where it unites with the right innominate vein, to constitute the superior vena cava. It is in relation in front with the left sterno-clavicular articulation, remains of the thymus gland, sterno-hyoid, and sterno-thyroid muscles, and first piece of the sternum. At its commencement it receives the thoracic duct which opens into it from behind, and in its course is joined by the *left inferior thyroid*, *left mammary*, and *left superior intercostal vein*. It also receives some small veins from the mediastinum and thymus gland. There are no valves in the innominate veins.

SUPERIOR VENA CAVA.

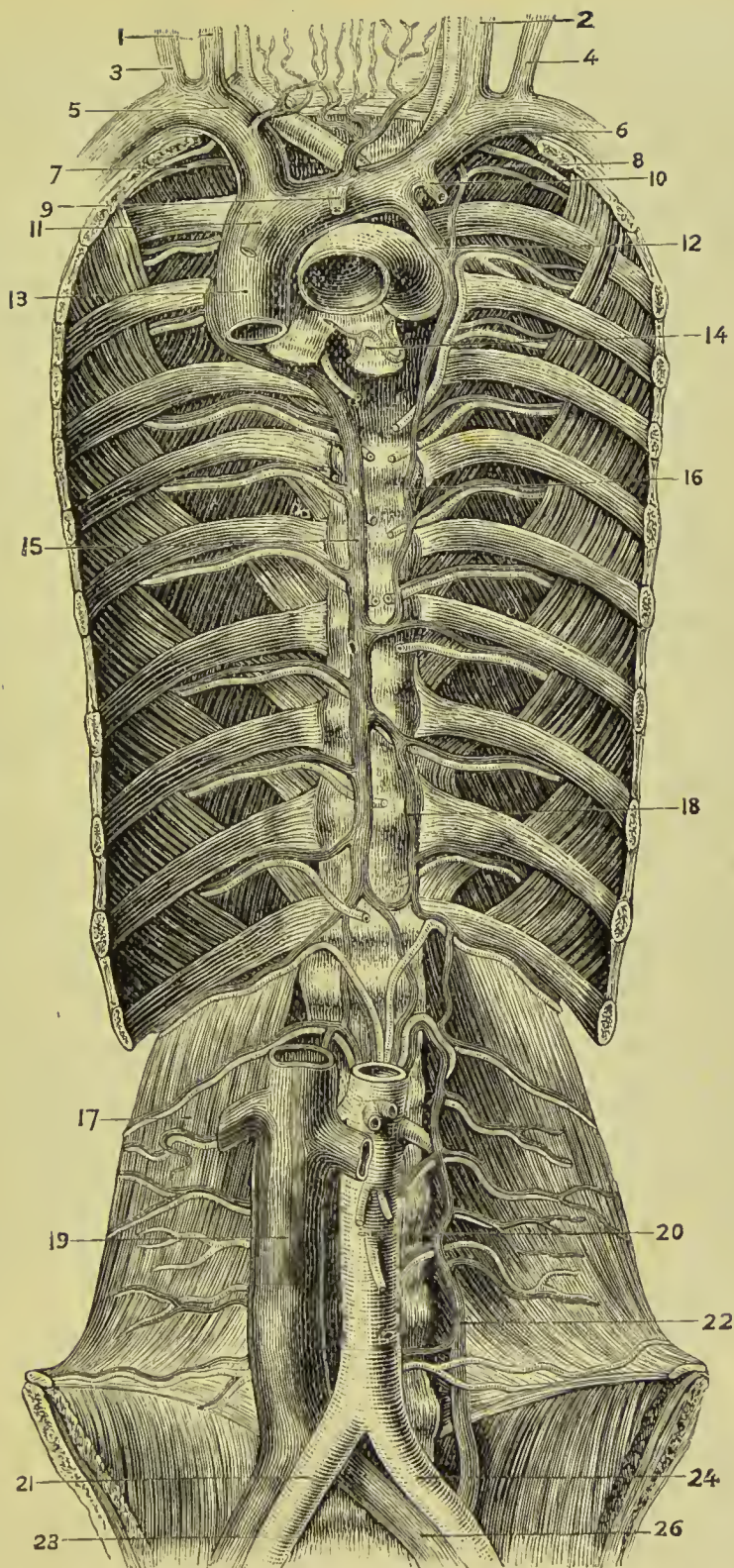
The **superior cava** is a short trunk about three inches in length, formed by the junction of the two innominate veins. It descends perpendicularly on the right side of the arch of the aorta, and entering the pericardium terminates in the upper part of the right auricle.

It is in relation *in front* with the pericardium; *behind* with the right pulmonary artery; *internally* with the ascending aorta and innominate artery; *externally* with the pleura and right phrenic nerve. It receives small mediastinal and pericardiac veins, and, immediately before entering the pericardium, is joined by the *vena azygos major*. It has no valves.

INFERIOR VENA CAVA, WITH ITS FORMATIVE BRANCHES.

The **external iliac vein** lies to the inner side of the corresponding artery at the os pubis; on the right side it gradually gets behind

FIG. 282.—Veins of the trunk. 1. Right internal jugular. 2. Left internal jugular. 3. Right external jugular. 4. Left external jugular. 5. Right innominate vein. 6. Left innominate. 7. Right superior intercostal vein. 8 and 12. Left superior intercostal veins. 9. Thymic vein. 10. Left internal mammary vein. 11. Pericardial and mediastinal veins. 13. Vena cava superior receiving vena azygos major. 14. Left bronchus. 15. Vena azygos major. 16. Superior vena azygos minor. 17. Quadratus lumborum. 18. Inferior vena azygos minor. 19. Vena cava inferior. 20. Abdominal aorta. 21. Right common iliac artery. 22. Communicating lumbar vein. 23. Right common iliac vein. 24. Left common iliac artery. 25. Left common iliac vein.



the artery as it passes upwards along the brim of the pelvis, but on the left side it lies altogether to the inner side of the artery; it terminates opposite the sacro-iliac symphysis by uniting with the internal iliac, to form the common iliac vein. Immediately above Poupart's ligament it receives the epigastric and deep circumflex iliac vein; it has no valves.

The **internal iliac vein** is formed by vessels which correspond with the branches of the internal iliac artery; it receives the returning blood from the gluteal, ischiatic, internal pudic, and obturator vein, externally to the pelvis; and from the vesical and uterine plexuses within the pelvis. The vein lies to the inner side of the internal iliac artery, and terminates by uniting with the external iliac vein, to form the common iliac; it has no valves.

The **vesical and prostatic plexus** is an important plexus of veins which surrounds the neck and base of the bladder and prostate gland, and receives its blood from the veins of the prostate, bladder, deep perineal muscles, great *dorsal vein of the penis*, and the external organs of generation. It is retained in connection with the sides of the bladder by a reflection of the pelvic fascia.

The **hæmorrhoidal plexus** consists of large veins with frequent anastomoses which surround the lower part of the rectum, beneath the mucous membrane. From the plexus proceed the superior, middle, and inferior hæmorrhoidal veins, which accompany the arteries of the same name. This plexus forms a direct communication between the portal and general venous systems.

The **uterine plexus** is situated around the vagina, and at the sides of the uterus, between the two layers of the broad ligament. The veins forming the vesical and uterine plexus are peculiarly subject to the production of calcareous concretions termed phlebolites.

The **common iliac veins** are formed by the union of the external and internal iliac vein at each side of the pelvis. The *right* common iliac, shorter than the left, ascends obliquely behind the corresponding artery; and on the intervertebral substance between the fourth and fifth lumbar vertebra, unites with the vein of the opposite side, to form the inferior cava. The *left* common iliac, longer and more oblique than the right, ascends behind and a little internally to the corresponding artery, and passes beneath the right common iliac artery, near its origin, to unite with the right vein in the formation of the inferior vena cava. Each common iliac vein receives the ilio-lumbar vein, and often the lateral sacral; the left receives in addition the vena sacra media. These veins have no valves.

INFERIOR VENA CAVA.

The inferior vena cava is formed by the union of the two common iliac veins, on the intervertebral substance between the fourth and fifth lumbar vertebra. It ascends along the front of the vertebral column, to the right of the abdominal aorta, and passing through the fissure in the posterior border of the liver and the quadrilateral

opening in the tendinous centre of the diaphragm, terminates in the inferior and posterior part of the right auricle. It has no valves.

It is in *relation* from below upwards, *in front* with the mesentery, transverse duodenum, portal vein, pancreas, and liver, which latter nearly and sometimes completely surrounds it; *behind* it rests on the vertebral column and right crus of the diaphragm, from which it is separated by the right renal artery and right lumbar arteries; to the *right* it has the peritoneum and sympathetic nerve; to the *left* the aorta.

The **tributaries** which the inferior vena cava receives in its course are the—

Lumbar,	Supra-renal,
Right spermatic,	Inferior phrenic,
Renal,	Hepatic.

The **lumbar veins**, four in number at each side, collect the venous blood from the muscles and integument of the loins, and spinal veins: the left are longer than the right on account of the position of the vena cava, and pass behind the aorta in order to reach that vessel. These veins communicate with each other by branches which pass in front of the transverse processes of the vertebræ (*ascending lumbar vein*).

The **right spermatic vein** is formed by the two veins which return the blood from the venous plexus of the spermatic cord (*spermatic* or *pampiniform plexus*). These veins follow the course of the spermatic artery, and unite to form the single trunk which opens into the inferior vena cava. The **left spermatic vein** terminates in the left renal vein.

The **ovarian veins** represent the spermatic veins of the male, and collect the venous blood from the ovaries, round ligaments, and Fallopian tubes. They communicate with the uterine sinuses, and terminate as in the male.

The **renal** or **emulgent veins** return the blood from the kidneys; their branches are situated in front of the divisions of the renal arteries, and the left opens into the vena cava somewhat higher than the right. The *left* is longer than the right in consequence of the position of the vena cava, and crosses the aorta immediately below the origin of the superior mesenteric artery. It receives the *left spermatic vein*, which terminates in it at right angles: hence the more frequent occurrence of varicocele on the left than on the right side; it also receives the *left inferior phrenic* and *left supra-renal*.

The **supra-renal veins** terminate partly in the renal veins, and partly in the inferior vena cava.

The **inferior phrenic veins** return the blood from the ramifications of the phrenic arteries; they open into the inferior vena cava.

The **hepatic veins** form two principal trunks and numerous smaller channels which open into the inferior vena cava, while that vessel is situated in the posterior border of the liver. The hepatic veins commence in the liver by minute venules, the *intra-lobular*

veins, in the centre of each lobule; these pour their blood into larger vessels, the *sublobular veins*; and the sublobular veins constitute, by their convergence and union, the hepatic trunks, which terminate in the inferior vena cava.

AZYGOS VEINS.

The azygos veins (Fig. 282) form a system of communication between the superior and inferior vena cava, and serve to return the blood from that part of the trunk of the body in which those vessels are deficient, on account of their connection with the heart. This system consists of four sets of vessels, namely—

Vena azygos major,
Vena azygos minor superior,
Vena azygos minor inferior,
Intercostal veins.

The **vena azygos major** commences in the lumbar region as a continuation of the ascending lumbar vein; sometimes it is joined by a branch directly from the inferior vena cava, or by one from the renal vein. It passes through the aortic opening of the diaphragm, lying on the right side of the thoracic duct and aorta, and ascends along the right side of the vertebral column to the third dorsal vertebra, where it arches forwards over the right bronchus, and terminates in the superior vena cava. It receives all the intercostal veins of the right side with the exception of those of the first space, the vena azygos minor superior and inferior, some œsophageal veins, and right bronchial vein.

The **vena azygos minor superior** is formed by the union of the intercostal veins of the left side from the fourth to the eighth; it communicates with the left superior intercostal vein, and crosses the body of the eighth dorsal vertebra behind the aorta to empty into the vena azygos major.

The **vena azygos minor inferior** commences in the lumbar region, on the left side, as the ascending lumbar vein, or by a communication with the renal vein. It enters the chest through the left crus of the diaphragm and ascends the left side of the vertebral column, crosses the ninth dorsal vertebra and opens into the vena azygos major. It receives the three lower intercostal veins of the left side and some branches from the mediastinum.

The azygos veins have no valves.

The **intercostal veins** vary somewhat in their arrangement, but the following seems to be the most common disposition:—On the *right side*, the vein of the first space joins the right innominate vein, or the termination of the vertebral; the veins of the second and third, or second, third, and fourth spaces, form a common trunk which terminates in the vena azygos major as it winds round the root of the lung; the veins of the remaining spaces empty directly into the vena azygos major. On the *left side*, the vein from the first space accompanies the superior intercostal artery, and empties into

the left innominate vein; the branches from the second and third spaces unite to form a common trunk which crosses the arch of the aorta to terminate in the left innominate vein; those from the fourth to the eighth spaces end in the vena azygos minor superior, and those of the remaining three spaces in the vena azygos minor inferior (B. G. Morison).

The **bronchial veins** return the blood from the structure of the lungs; the right empties into the vena azygos major near its termination, and the left in the vena azygos minor superior.

VERTEBRAL AND SPINAL VEINS.

The numerous venous plexuses of the vertebral column and spinal cord may be arranged into four groups:—

1. Those ramifying on the arches of the vertebræ externally, *dorsal-spinal*.
2. Those situated within the vertebral canal between the vertebræ

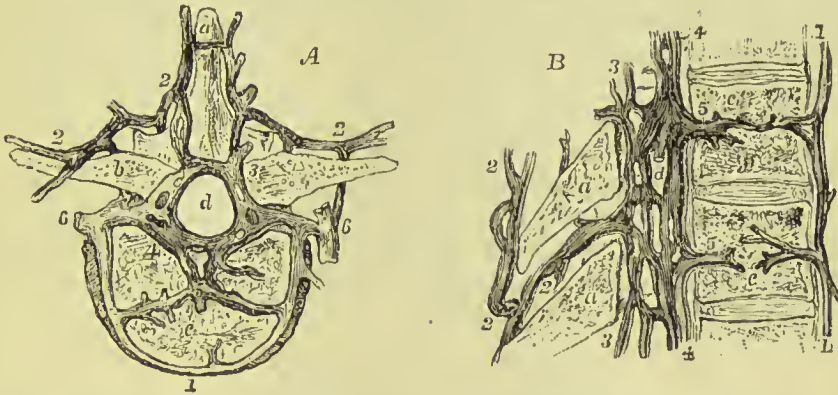


FIG. 283.—Vertebral and spinal veins. A. Horizontal view. B. Vertical view. a. Spinous process. b. Transverse process. c. Body of vertebra. d. Spinal canal. 1. Anterior external veins of body. 2. Dorsal spinal veins. 3. Posterior longitudinal spinal veins (meningo-rachidian). 4. Anterior longitudinal spinal veins (meningo-rachidian). 5. Venæ basis vertebrarum. 6. Lateral vertebral veins.

and the membranes, *meningo-rachidian*. These are further divisible into an anterior and a posterior set.

3. The veins of the bodies of the vertebræ, *venæ basis vertebrarum*.

4. The veins of the spinal cord, *medulli-spinal*.

1. The **dorsal-spinal veins** form a plexus around the spinous, transverse, and articular processes, and arches of the vertebræ. They receive the returning blood from the dorsal muscles and surrounding structures, and transmit it, in part to the veins inside the vertebral canal, by branches which perforate the ligamenta subflava, and in part to the vertebral, intercostal, lumbar, and sacral veins.

2. The **meningo-rachidian veins** are situated between the spinal dura mater and the vertebræ. They communicate freely with each

other by means of a complicated plexus. In front they form two longitudinal trunks (*anterior longitudinal spinal veins*), extending the whole length of the column on each side of the posterior common ligament, and are joined on the body of each vertebra by transverse trunks, which pass beneath the ligament, and receive the large basi-vertebral veins from the interior of each vertebra. The posterior trunks (*posterior longitudinal spinal veins*) are smaller than the anterior; they are situated one on each side between the laminae and the theca vertebralis; they communicate with each other, with the anterior trunks, and with the dorsal-spinal veins. The meningo-rachidian veins communicate superiorly through the anterior condylar foramina with the internal jugulars; in the neck they pour their blood into the vertebral veins; in the thorax, into the intercostals; and in the loins and pelvis into the lumbar and sacral veins, the communications being made through the intervertebral foramina.

3. The **venæ basis vertebrarum** pass out through the large foramina in the posterior surfaces of the bodies of the vertebræ, and empty into the transverse branches of the anterior longitudinal spinal veins. They are contained in large tortuous channels in the substance of the bones, similar to those in the diploë of the skull, and run parallel with the upper and lower surfaces of the bodies of the vertebræ. The canals become greatly developed in old age.

4. The **medulli-spinal veins** are situated between the pia mater and arachnoid; they communicate freely with each other to form plexuses, and send branches through the intervertebral foramina with each of the spinal nerves, to join the veins of the trunk. The veins of the spine have no valves.

CARDIAC VEINS.

The veins returning the blood from the substance of the heart are the—

Great cardiac vein,	Anterior cardiac veins,
Posterior cardiac vein,	Venæ Thebesii,
Right or small coronary vein,	Coronary sinus.

The **great cardiac** or **coronary vein** commences at the apex of the heart, and ascends along the anterior ventricular groove to the base of the ventricles; it then curves around the left auriculo-ventricular groove to the posterior part of the heart, where it terminates in the coronary sinus, its opening being guarded by a valve of two segments. It receives in its course the left cardiac veins from the left auricle, and branches from the anterior wall of both ventricles.

The **posterior cardiac vein** (frequently two in number) commences also at the apex of the heart, and ascends along the posterior ventricular groove, to terminate in the coronary sinus. It receives, at right angles, the veins from the posterior aspect of the two ventricles.

The **anterior cardiac veins** collect the blood from the anterior

surface of the right ventricle ; one larger than the rest runs along the right border of the heart. They join to form a small trunk, which curves around the right auriculo-ventricular groove, to open directly into the auricle.

The **venæ Thebesii** are numerous minute veins which convey the venous blood directly from the substance of the heart into the right auricle.

The **right** or **small coronary vein** runs in the right auriculo-ventricular groove, and winds around the heart, to empty into the right end of the coronary sinus.

The **coronary sinus** is a short but wide trunk which forms the true continuation of the great cardiac vein. It is situated at the back of the heart between the left auricle and ventricle, and is covered by the muscular fibres of the auricle ; it receives the great cardiac, posterior cardiac, and small coronary veins, and also a small vessel called the *oblique vein* which crosses the back of the left auricle. The coronary sinus opens into the back of the right auricle, the opening being guarded by a small fold of endocardium which receives the name of *coronary* or *Thebesian* valve. All the veins joining the sinus are guarded at their entrance by more or less complete valves, except the oblique vein.

PORTAL SYSTEM.

The **portal system of veins** includes those belonging to the spleen, stomach, large and small intestine, and pancreas. Its vessels differ from veins in general in being devoid of valves, in terminating as well as commencing in capillaries, and in the great thickness of their muscular coat. After the blood contained in the portal vein has been distributed to the liver, it is gathered up by the *hepatic veins*, and conveyed into the inferior vena cava.

The portal system is composed of four large veins which return the blood from the chylopoietic viscera ; they are the—

Inferior mesenteric vein,	Splenic vein,
Superior mesenteric vein,	Gastric veins.

The **inferior mesenteric vein** receives its blood from the rectum by means of the hæmorrhoidal veins, and from the sigmoid flexure and descending colon, and ascends behind the transverse duodenum and pancreas, to terminate in the splenic vein. Its hæmorrhoidal branches inosculate with branches of the internal iliac vein, and thus establish a communication between the portal and general venous system.

The **superior mesenteric vein** is formed by branches which collect the venous blood from the capillaries of the superior mesenteric artery ; they constitute by their junction a large trunk, which ascends by the side of the corresponding artery, crosses the transverse portion of the duodenum, and unites behind the pancreas with the splenic in the formation of the portal vein.

The **splenic vein** commences in the structure of the spleen, and quits that organ by five or six large branches, which soon unite to form a single trunk ; it is larger than the splenic artery, and perfectly straight in its course. It passes horizontally inwards behind the pancreas, and terminates near its greater end by uniting with the superior mesenteric and forming the portal vein. It receives in its course the vasa brevia, left gastro-epiploic, pancreatico-duodenal, and

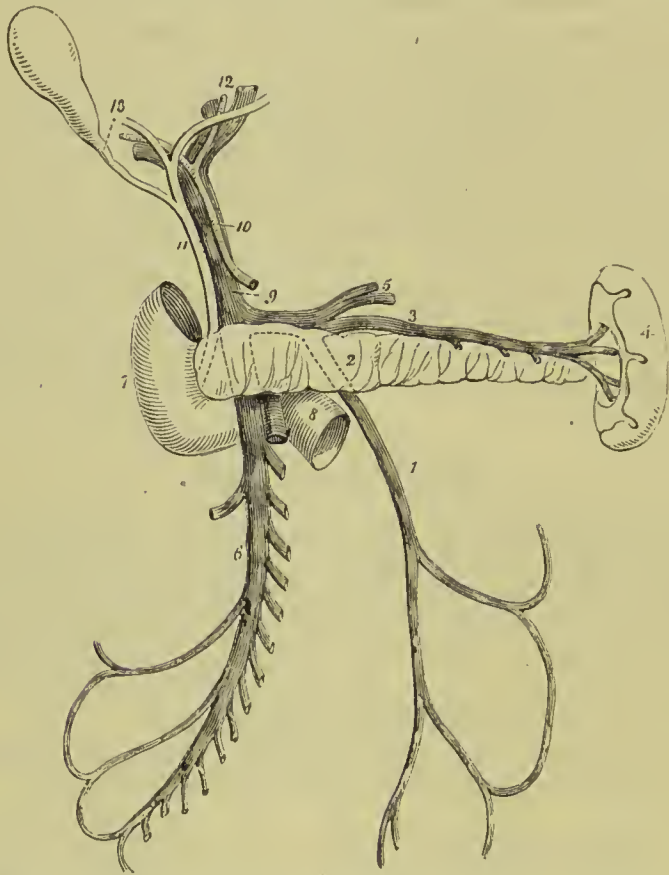


FIG. 284.—The portal vein. 1. Inferior mesenteric vein ; it is traced by means of dotted lines behind the pancreas (2) to terminate in the splenic vein (3). 4. Spleen. 5. Branches from the stomach, opening into the splenic vein. 6. Superior mesenteric vein. 7. Descending portion of the duodenum. 8. Its transverse portion, crossed by the superior mesenteric vein and part of the trunk of the superior mesenteric artery. 9. Portal vein. 10. Hepatic artery. 11. Common bile duct. 12. Division of the duct and vessels at the transverse fissure of the liver. 13. Cystic duct leading to the gall-bladder.

pancreatic veins, and near its termination the inferior mesenteric vein.

The **gastric veins** for the most part take the course of the corresponding arteries, those of the large end of the stomach terminating in the splenic vein, and the right gastro-epiploic in the superior mesenteric. Those along the lesser curvature are, however, differently arranged to the arteries ; they are two in number, and receive

the name of **coronary veins**. Of these the one placed most anteriorly is the smallest: it runs from the cardiac towards the pyloric end of the curve, receives branches from the pylorus and upper part of the duodenum, and ends in the portal vein. The posterior branch, much the largest, runs from the pyloric towards the cardiac end, and at about an inch and a half from the œsophagus winds to the posterior surface of the stomach, crosses the splenic artery, and terminates in the portal vein above the preceding.

The **PORTAL VEIN** (*vena porta*), formed by the union of the splenic and superior mesenteric veins behind the pancreas, ascends through the right border of the lesser omentum to the transverse fissure of the liver, where it divides into two branches, one for each lateral lobe. In the right border of the lesser omentum it is situated behind and between the hepatic artery and ductus communis choledochus, and is surrounded by the hepatic plexus of nerves and lymphatics. At the transverse fissure each primary branch divides into numerous secondary branches which ramify through the portal canals, and give off vaginal and interlobular veins, and the latter terminate in the lobular venous plexus of the lobules of the liver. The portal vein within the liver receives the venous blood from the capillaries of the hepatic artery.

Communications with the Systemic Veins.—The veins forming the portal system communicate with the systemic veins—(1) By the inosculation of the inferior hæmorrhoidal tributaries of the inferior mesenteric with those of the internal iliac; (2) by communications between the left renal vein and the veins of the intestines, especially those of the colon and duodenum; and (3) by the inosculation of superficial branches of the portal veins of the liver with the phrenic veins.

PULMONARY VEINS.

The pulmonary veins, four in number, return the arterial blood from the lungs to the left auricle of the heart; they differ from veins in general, in the area of their cylinders being less than that of the corresponding arteries, in carrying arterial blood, in being devoid of valves, and in accompanying singly each branch of the pulmonary artery. They commence in the capillaries upon the parietes of the alveolar passages and air-cells, and unite to form a single trunk for each lobe. The vein of the middle lobe of the right lung unites with the superior vein, so as to form the two trunks which open into the left auricle. Sometimes they remain separate, and then there are three pulmonary veins on the right side. The right pulmonary veins pass behind the right auricle to the left auricle; the left pass in front of the descending aorta; they both pierce the pericardium. Within the lung the branches of the pulmonary veins are behind the bronchial tubes, and those of the pulmonary artery in front; but at the root of the lungs the veins are in front, next the arteries, and then the bronchi.

LYMPHATICS.

Lymphatic vessels admit of a threefold division, into superficial, deep, and lacteals. The *superficial lymphatic vessels*, on the surface of the body, follow the course of the veins, and pierce the deep fascia in convenient situations, to join the deep lymphatics. On the surface of organs they converge to the nearest lymphatic trunks. The *superficial lymphatic glands* are placed in the most protected situations of the superficial fascia, as in the hollow of the ham and groin in the lower extremity; on the inner side of the arm in the upper extremity.

The *deep lymphatics*, fewer in number and somewhat larger than the superficial vessels, accompany the deeper veins; those from the lower parts of the body converging to the numerous glands seated around the iliac veins and inferior vena cava, and terminating in a large trunk situated on the vertebral column, the thoracic duct. From the upper part of the trunk of the body on the left side, and from the left side of the head and neck, they also proceed to the thoracic duct. Those on the right side of the head and neck, right upper extremity, and right side of the thorax, form a distinct duct which terminates at the point of junction of the subclavian with the internal jugular vein on the right side of the root of the neck.

The *lacteals* are the lymphatic vessels of the small intestines; they have received their distinctive appellation from conveying the milk-like product of digestion, the chyle, to the great centre of the lymphatic system, the thoracic duct. They are situated in the mesentery, and open into the numerous mesenteric glands in their course. When digestion is not proceeding they carry transparent lymph, like the other lymphatics.

The lymphatic vessels and glands will be described according to the arrangement adopted for the veins, commencing with those of the head and neck, and proceeding next to those of the upper extremity, lower extremity, and trunk.

LYMPHATICS OF THE HEAD AND NECK.

GLANDS.—The **superficial lymphatic glands of the head and face** are small, few in number, and isolated; they are—the *occipital*, which are situated near the origin of the occipito-frontalis muscle; *posterior auricular*, behind the ear; *parotid*, on the parotid gland; *zygomatic*, in the zygomatic fossa; *buccal*, on the buccinator muscle, and *submaxillary*, beneath the margin of the lower jaw. There are no deep lymphatic glands within the cranium.

The **superficial cervical lymphatic glands** are few in number and small; they are situated in the course of the external jugular vein, between the sterno-mastoid and trapezius muscle, at the root of the neck, and about the larynx.

The **deep cervical glands** (*glandulæ concatenatæ*) are numerous and of large size ; they are situated around the internal jugular vein and sheath of the carotid artery, by the side of the pharynx, œsophagus, and trachea, and extend from the base of the skull to the root of the neck, where they are in communication with the lymphatic vessels and glands of the thorax.

VESSELS.—The **superficial lymphatic vessels of the head and face** are disposed in three groups : *occipital*, which take the course of the occipital vein to the occipital and deep cervical glands ; *temporal*, which follow the branches of the temporal vein to the parotid and deep cervical glands ; and *facial*, which accompany the facial vein to the submaxillary lymphatic glands.

The **deep lymphatic vessels of the head** are the *meningeal* and *cerebral* ; the former are situated in connection with the meningeal veins, and escape through foramina at the base of the skull, to join the deep cervical glands. The chief *cerebral lymphatics* are situated on the surface of the pia mater and in the choroid plexuses of the ventricles. They pass along with the internal carotid and vertebral arteries and the internal jugular vein through the foramina at the base of the skull, to terminate in the deep cervical glands. In the substance of the brain the lymphatic capillaries form *perivascular spaces* or *canals* around all the blood-vessels even to their smallest ramifications, and are in communication with similar spaces in the pia mater, and with the sub-arachnoid space.

The **deep lymphatic vessels of the face** proceed from the nasal fossæ, mouth, orbits, temporal fossæ, and pharynx, and terminate in the submaxillary and deep cervical glands.

The **superficial and deep cervical lymphatic vessels** accompany the jugular veins, passing from gland to gland ; at the root of the neck they communicate with the thoracic lymphatic vessels, and terminate, on the right side, in the ductus lymphaticus dexter ; on the left, in the thoracic duct, near its termination.

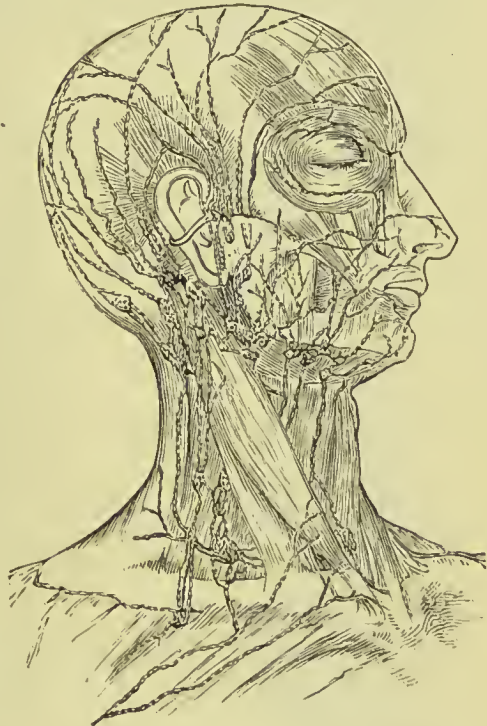

FIG. 285.—Superficial lymphatic vessels and glands of the head and neck.

LYMPHATICS OF THE UPPER EXTREMITY.

GLANDS.—The **superficial lymphatic glands** of the arm are not more than four or five in number, and of very small size. One or two are situated near the median basilic and median cephalic vein, at the bend of the elbow; and one or two near the basilic vein, on the inner side of the upper arm, immediately above the elbow.

The **deep glands** in the forearm are excessively small and infrequent; two or three may be found in the course of the radial and ulnar vessels. In the upper arm there is a chain of small glands, accompanying the brachial artery.

The **axillary glands** are numerous and of large size. Some are closely adherent to the vessels, others are dispersed in the loose areolar tissue of the axilla, and a small chain may be observed extending along the lower border of the pectoralis major to the mammary gland, receiving the lymphatics of that organ and of the front of the chest wall (*pectoral glands*). A similar chain is found along the subscapular vessels at the back of the axilla; it receives the lymphatic vessels from the integument of the back (*subscapular glands*). Two or three subclavian glands are situated beneath the clavicle, and serve as the medium of communication between the axillary and deep cervical lymphatic glands (*infra-clavicular glands*).

VESSELS.—The **superficial lymphatic vessels** of the upper extremity commence on the fingers and take their course along the forearm to the bend of the elbow. The greater part reach their destination by passing along the dorsal surface of the fingers, wrist, and forearm, and then curving around the borders of the latter; but some few are met with in the palm of the hand, which take the direction of the median vein. At the bend of the elbow the lym-

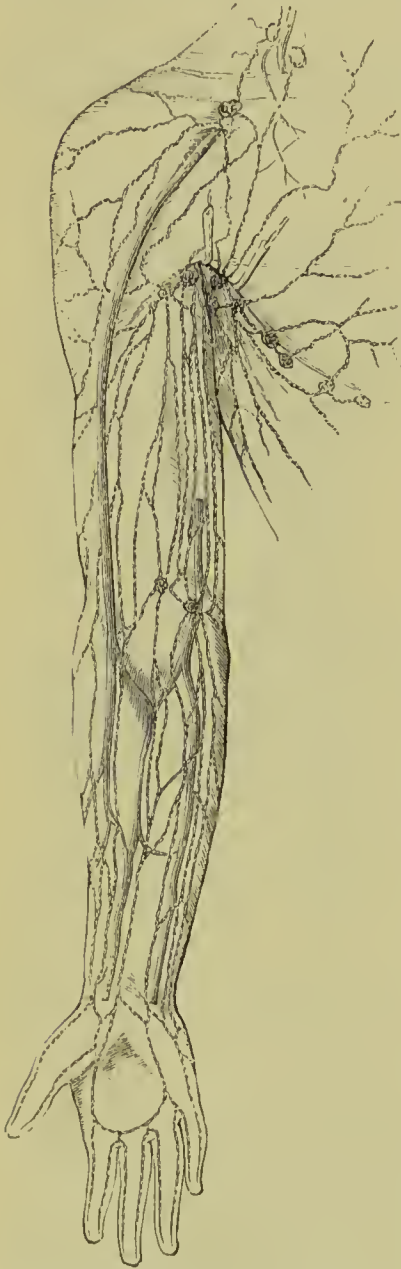

FIG. 286. — Superficial lymphatic vessels and glands of the arm and axilla.

direction of the median vein.

lymphatics arrange themselves into two groups : an internal and larger group, which communicates with a gland situated just above the inner condyle, and then accompanies the basilic vein upwards to the axilla to enter the axillary glands ; and a smaller group which follows the course of the cephalic vein. Several of the vessels of this group cross the biceps muscle at its upper part to reach the axillary glands, while the remainder, two or three in number, ascend with the cephalic vein in the interspace of the deltoid and pectoralis major ; these latter usually join a small gland in this space and then cross the pectoralis minor muscle to become continuous with the subclavian lymphatics.

Besides the lymphatic vessels of the arm, the axillary glands receive those from the integument of the chest, its anterior, posterior, and lateral aspect, and the lymphatics of the mammary gland.

The **deep lymphatics** accompany the vessels of the upper extremity, and communicate occasionally with the superficial lymphatics. They enter the axillary and subclavian glands, and, at the root of the neck, terminate on the left side in the thoracic duct, and on the right side in the ductus lymphaticus dexter.

LYMPHATICS OF THE LOWER EXTREMITY.

GLANDS.—The **superficial lymphatic glands** of the lower extremity are those of the groin, *inguinal* ; and one or two situated in the superficial fascia of the posterior aspect of the thigh, just above the popliteal region.

The **inguinal glands** are divisible into two groups : a superior group of small size, situated along the line of Poupart's ligament, and receiving the lymphatic vessels from the parietes of the abdomen, gluteal region, perineum, and genital organs ; and an inferior group, called **femoral glands**, of larger size clustered around the internal saphena vein near its termination, and receiving the superficial lymphatic vessels from the lower extremity.

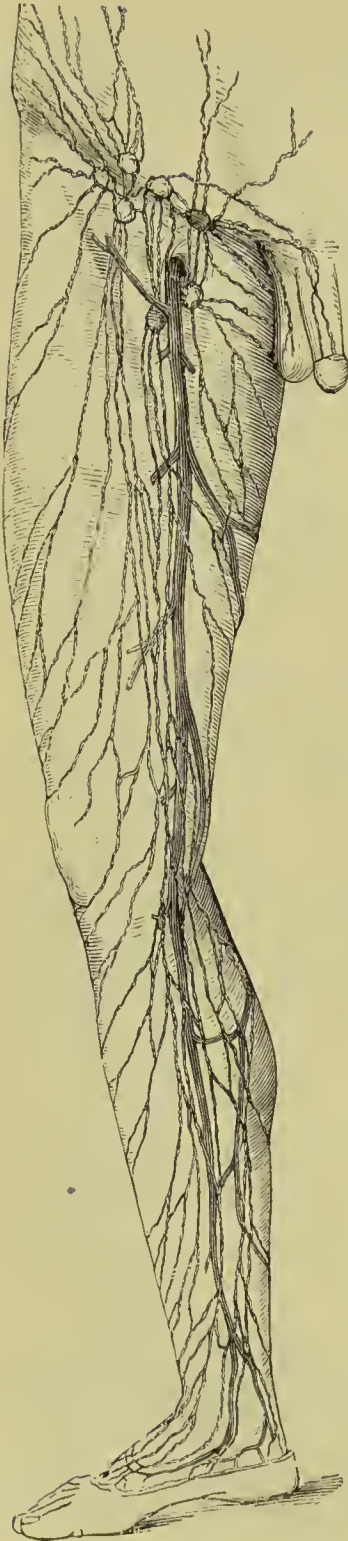The **deep lymphatic glands** are the *anterior tibial*, *popliteal*, *deep inguinal*, *gluteal*, and *ischiatric*.

The **anterior tibial** is generally a single gland, placed on the interosseous membrane, by the side of the anterior tibial artery in the upper part of its course.

The **popliteal glands**, four or five in number, and small, are embedded in the loose areolar tissue and fat of the popliteal space.

The **deep inguinal glands**, less numerous and smaller than the superficial, are situated near the femoral vessels in the groin, beneath the fascia lata ; they communicate with the superficial lymphatics through the saphenous opening.

The **gluteal** and **ischiatric glands** are placed near the vessels of that name, above and below the pyriformis muscle at the great ischiatic foramen.



VESSELS.—The **superficial lymphatic vessels** are divisible into two groups, internal and external; the *internal* and principal group, commencing on the dorsum and inner side of the foot, ascend the leg by the side of the internal saphena vein, and, passing behind the inner condyle of the femur, follow the direction of that vein to the groin, where they join the femoral group of superficial inguinal glands. The greater part of the efferent vessels from these glands pierce the cribriform fascia of the saphenous opening and the sheath of the femoral vessels, to join the lymphatic gland situated in the crural ring, which serves to establish a communication between the lymphatics of the lower extremity and those of the trunk. The other efferent vessels pierce the fascia lata to join the deep glands. The vessels which pass upwards from the outer side of the dorsum of the foot ascend along the outer side of the leg, and curve inwards across the front of the leg just below the knee, to unite with the lymphatics of the inner side of the thigh. The *external group* consists of a few lymphatic vessels which commence on the outer side of the foot and posterior part of the ankle, and accompany the external saphena vein to the popliteal region, where they enter the popliteal glands.

The **deep lymphatic vessels** accompany the deep veins, and communicate with the various glands in their course. After joining the deep inguinal glands they pass beneath Poupart's ligament, to communicate with the numerous glands situated around the iliac vessels. The deep lymphatics of the gluteal region follow the course of the branches of the gluteal and ischiatic veins. The former join the glands situated on the upper border of the pyriformis muscle, and the latter, after communicating with the lymphatics of the thigh, enter the ischiatic glands.

FIG. 287.—Superficial lymphatic vessels and glands of the front and inner side of the leg.

LYMPHATICS OF THE TRUNK.

The lymphatics of the trunk may be arranged under three heads, superficial, deep, and visceral.

The **superficial lymphatic vessels** of the upper half of the trunk pass upwards and outwards at each side, and converge, some to the axillary glands, others to the glands at the root of the neck. The lymphatics from the mammary glands follow the lower border of the pectoralis major, communicating, by means of a chain of lymphatic glands, with the axillary glands. The superficial lymphatic vessels of the lower half of the trunk, gluteal region, perineum, and external organs of generation, converge to the superior group of superficial inguinal glands. One or two small glands are situated at each side of the dorsal vein of the penis, near the suspensory ligament; from these, as from the superficial lymphatics, the efferent vessels pass into the superior group of superficial inguinal glands.

GLANDS.—The **deep lymphatic glands of the thorax** are the intercostal, anterior mediastinal, and œsophageal.

The **intercostal glands**, of small size, are situated on each side of the vertebral column, near the articulations of the heads of the ribs, and in the course of the intercostal arteries.

The **anterior mediastinal glands** are situated along the course of the internal mammary arteries; they are six or seven in number at each side, and receive the lymphatic vessels from the anterior wall of the chest, the mediastinum, thymus gland, and pericardium.

The **œsophageal** or **posterior mediastinal glands**, fifteen or twenty in number, are situated in the course of the œsophagus, and receive the lymphatics of that tube; they communicate above with the deep cervical glands, on each side with the intercostal, and below with the abdominal glands.

VESSELS.—The **deep lymphatic vessels of the thorax** are the intercostal, internal mammary, and diaphragmatic.

The **intercostal lymphatic vessels** follow the course of the veins of the same name; and reaching the vertebral column, curve downwards, to terminate in the thoracic duct.

The **internal mammary lymphatics** commence in the parietes of the abdomen communicating with the epigastric lymphatics. They ascend by the side of the internal mammary vessels, being joined in their course by the anterior intercostals, and terminate at the root of the neck, on the right side in the tributaries of the ductus lymphaticus dexter; on the left, in the thoracic duct. The *diaphragmatic* lymphatics pursue the direction of their corresponding veins, and terminate, some *in front*, in the internal mammary vessels, and some *behind* in the posterior mediastinal lymphatics.

GLANDS.—The **deep lymphatic glands of the abdomen** are the lumbar glands: they are numerous, and seated around the common iliac vessels, the aorta, and vena cava. They receive the lymphatic vessels from the lower extremities, pelvis, testicles and some of the

abdominal viscera, and their efferent vessels terminate in the receptaculum chyli.

The **deep lymphatic glands of the pelvis** are the external iliac, internal iliac, and sacral.

The **external iliac** are placed around the external iliac vessels, being in continuation, by one extremity, with the femoral lymphatics; by the other, with the lumbar glands.

The **internal iliac** glands are situated in the course of the internal iliac vessels, and the **sacral** glands rest on the concave surface of the sacrum. Both sets of glands have efferent vessels which empty into the lumbar chain of glands.

VESSELS.—The **deep lymphatic vessels** are continued upwards from the thigh beneath Poupart's ligament, and along the external iliac vessels to the lumbar glands, receiving in their course the epigastric, circumflex iliac, and ilio-lumbar lymphatic vessels. Those from the parietes of the pelvis, and from the gluteal, ischiatic, and obturator vessels, follow the course of the internal iliac veins, and unite with the lumbar lymphatics. The lumbar lymphatic vessels, after receiving all the lymphatics from the lower extremities, pelvis, and loins, terminate by several large trunks in the receptaculum chyli.

LYMPHATICS OF THE VISCERA.

LUNGS.—The **lymphatic vessels of the lungs**, of large size, are distributed over every part of the surface, and through the texture of those organs. They are divisible into a superficial set which lies immediately beneath the pleura, and a deep set which accompanies the ramifications of the bronchial tubes, and pulmonary arteries; they converge to the *bronchial glands*, ten or twelve in number, situated around the bifurcation of the trachea and roots of the lungs. Some of these glands, of small size, may be traced in connection with the bronchial tubes into the substance of the lungs. The efferent vessels from the bronchial glands unite with those from the tracheal and œsophageal glands, and terminate on the left side in the thoracic duct at the root of the neck, and on the right in the ductus lymphaticus dexter. The bronchial glands in the adult present a variable tint of brown, and in old age a deep black colour. In infancy they have none of this pigment, and are not to be distinguished from lymphatic glands in other situations.

HEART.—The **lymphatic vessels of the heart** originate in the subserous areolar tissue of the surface, and in the deeper tissues of that organ, and follow the course of the coronary vessels, principally, along the right border of the heart to the glands situated around the arch of the aorta, and to the bronchial glands, whence they proceed to the root of the neck, and terminate in the thoracic duct. The **cardiac glands** are three or four in number.

The **pericardiac** and **thymic** lymphatic vessels proceed to join the anterior mediastinal and bronchial glands.

LIVER.—The **lymphatic vessels of the liver** are divisible into deep and superficial. The former take their course through the portal canals, and through the right border of the lesser omentum, to the lymphatic glands situated in the course of the hepatic artery and along the lesser curve of the stomach. The *superficial* lymphatics are situated in the areolar structure of the proper capsule, over the whole surface of the liver. The lymphatics of the convex surface are divided into two sets:—1. Those which pass from before backwards; 2. Those which advance from behind forwards. The former unite to form trunks, which enter between the folds of the lateral ligaments at the right and left extremities of the organ, and of the coronary ligament in the middle. Some of these pierce the diaphragm and join the posterior mediastinal glands; others converge to the lymphatic glands situated around the inferior cava. Those which pass from behind forwards consist of two groups: one ascends between the folds of the broad ligament, and perforates the diaphragm, to join the anterior mediastinal glands, finally emptying their contents into the ductus lymphaticus dexter; the other curves around the anterior margin of the liver to its concave surface, and from thence to the glands in the right border of the lesser omentum. The lymphatic vessels of the concave surface are variously distributed, according to their position; those from the right lobe terminate in the lumbar glands; those from the gall-bladder, which are large, and form a remarkable plexus, enter the glands in the right border of the lesser omentum; and those from the left lobe converge to the lymphatic glands situated along the lesser curve of the stomach.

SPLEEN AND PANCREAS.—The **lymphatic glands of the spleen** are situated around its hilum, and those of the *pancreas* in the course of the splenic vein. The *lymphatic vessels* of these organs consist of two sets, superficial and deep; they pass through their respective glands, and join the aortic glands previously to terminating in the thoracic duct.

STOMACH.—The **lymphatic glands of the stomach**, of small size, are situated along the lesser and greater curve of that organ. The *lymphatic vessels*, as in other viscera, are superficial and deep, the former originating in the subserous, the latter in the submucous tissue; they pass from the stomach in four different directions: some ascend to the glands situated along the lesser curve; others descend to those occupying the greater curve; a third set pass outwards to the splenic glands, and a fourth to the glands situated near the pylorus and to the aortic glands.

INTESTINES.—The **lymphatic glands of the small intestine** are situated between the layers of the mesentery, in the meshes formed by the superior mesenteric artery, and are thence named *mesenteric glands*. These glands are most numerous and largest, superiorly, near the duodenum; and, inferiorly, near the termination of the ileum.

The **lymphatic vessels** of the small intestines are of two kinds:

those of the structure of the intestine, which run in the muscular coat between the longitudinal and circular fibres, and also beneath the peritoneum, previously to entering the mesenteric glands; and those which commence in the villi, in the substance of the mucous membrane, and are named *lacteals*.

The **lacteals** commence in the centre of each villus, as a cæcal tubulus, which opens into a fine network, situated in the submucous tissue. From this network the lacteal vessels proceed to the mesenteric glands, and from thence to the thoracic duct, in which they terminate.

The **lymphatic glands of the large intestines** are situated along the attached margin of the intestine, in the meshes formed by the colic and hæmorrhoidal arteries previously to their distribution. The *lymphatic vessels* take their course in two different directions; those of the cæcum, ascending colon, and transverse colon, after traversing their proper glands, proceed to the mesenteric glands, and those of the descending colon and rectum to the lumbar glands.

KIDNEY.—The **lymphatic vessels of the kidney** follow the direction of the blood-vessels to the lumbar glands situated around the aorta and inferior vena cava; those of the supra-renal capsules, which are very large and numerous, terminate in the renal lymphatics.

PELVIS.—The **lymphatic vessels of the bladder** are most numerous at the base and on the posterior aspect of that organ; they communicate with the lymphatics of the vesiculæ seminales and prostate, and terminate in the internal iliac glands.

The **lymphatics of the uterus** consist of a superficial and deep set; the former being placed beneath the peritoneum, and the latter in the substance of the organ. Those of the cervix and vagina join the internal iliac and sacral glands; those of the body and fundus enter the broad ligaments, and after receiving the lymphatics of the ovaries, broad ligaments, and Fallopian tubes, terminate in the lumbar glands.

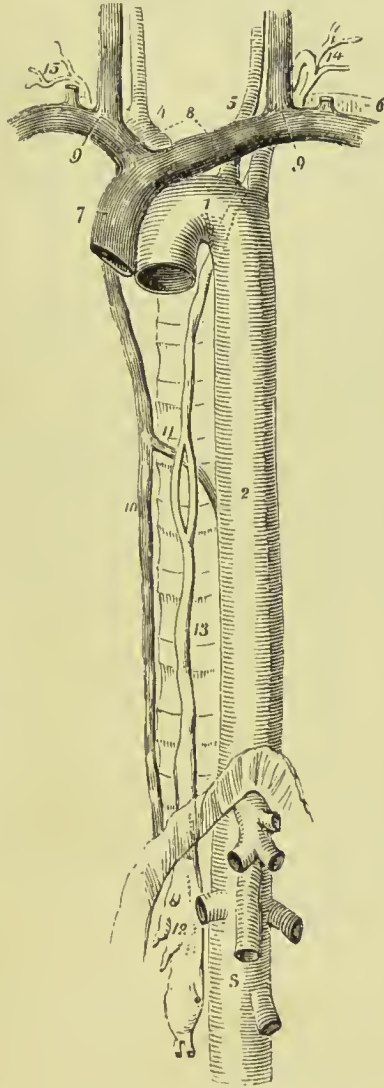
The **lymphatic vessels of the testicle** take the course of the spermatic cord, in which they are of large size; they terminate in the lumbar glands.

THORACIC DUCT.

The thoracic duct, the great trunk of the lymphatic and chylous system, commences in the abdomen by a considerable and somewhat triangular dilatation, the **receptaculum chyli**, which is situated on the front of the body of the second lumbar vertebra, behind and between the aorta and inferior vena cava, and close to the tendon of the right crus of the diaphragm. From the upper part of the receptaculum chyli the thoracic duct ascends through the aortic opening of the diaphragm, and along the front of the vertebral column, lying between the thoracic aorta and vena azygos and upon the right intercostal arteries, to the fourth dorsal vertebra. It then

inclines to the left side, passes behind the arch of the aorta, and ascends by the side of the œsophagus, and behind the perpendicular portion of the left subclavian artery to the root of the neck opposite the seventh cervical vertebra, where it makes a sudden curve forwards and downwards in front of the scalenus anticus muscle, and

FIG. 288.—The course and termination of the thoracic duct. 1. Arch of the aorta. 2. Thoracic aorta. 3. Abdominal aorta, showing its principal branches divided near their origin. 4. Arteria innominata, dividing into right carotid and right subclavian. 5. Left carotid. 6. Left subclavian. 7. Superior cava, formed by the union of (8) the two venæ innominatæ; and these by the junction (9) of the internal jugular and subclavian vein at each side. 10. Greater vena azygos. 11. Termination of the lesser in the greater vena azygos. 12. Receptaculum chyli; several lymphatic trunks are seen opening into it. 13. Thoracic duct, dividing opposite the middle of the dorsal vertebræ into two branches which reunite; the course of the duct behind the arch of the aorta and left subclavian artery is shown by a dotted line. 14. The duct making its turn at the root of the neck and receiving several lymphatic trunks previously to terminating in the posterior aspect of the junction of the internal jugular and subclavian vein. 15. Termination of the trunk of the ductus lymphaticus dexter.



terminates at the point of junction of the left subclavian with the left internal jugular vein.

The thoracic duct is about eighteen or twenty inches in length, and near its origin as large as a goose quill; as it ascends, it diminishes in size, and near its termination again becomes dilated. At the middle of the thorax it frequently divides into two branches of equal size, which reunite after a short course; and sometimes it gives off several branches, which assume a plexiform arrangement

in this situation. Occasionally the thoracic duct bifurcates at the upper part of the thorax into two branches, one of which opens into the point of junction between the right subclavian and jugular vein, while the other proceeds to the normal termination of the duct on the left side.

The thoracic duct presents fewer valves in its course than lymphatic vessels generally ; at its termination it is provided with a pair of semilunar valves, to prevent the admission of venous blood.

Branches.—The thoracic duct receives at its commencement four or five large lymphatic trunks, which unite to form the receptaculum chyli ; it next receives the trunks of the lacteal vessels. Within the thorax it is joined by the lymphatic vessels from the left half of the thoracic wall, those of the sternal and intercostal glands, those of the left lung, left side of the heart, trachea, and œsophagus, and as it curves forwards in the neck it is joined by lymphatic trunks from the left side of the head and neck, and left upper extremity.

The **ductus lymphaticus dexter** is a short trunk which receives the lymphatic vessels from the right side of the head and neck, right upper extremity, right side of the thorax, right lung, and one or two branches from the upper convex surface of the liver. It terminates at the junction of the right subclavian with the right internal jugular vein, at the point where these veins unite to form the right innominate vein ; and is provided at its termination with a pair of semilunar valves, which prevent the entrance of blood from the veins.

PART VI.

NEUROLOGY.

THE nervous system consists of large masses of nerve matter forming the cerebro-spinal axis, of lesser centres called ganglia, of the peripheral nerves, and, lastly, of certain modifications of the latter constituting the organs of sense.

THE CEREBRO-SPINAL AXIS.

The mass of nerve matter forming the cerebro-spinal axis is contained in the cavity of the cranium and vertebral canal ; it is divided into two parts—the **encephalon** or **brain** and the **spinal cord** ; each lateral half of these centres corresponds accurately with the other half, the two parts being joined together by connecting bands of nerve tissue called **commissures**. The brain, contained in the cranium, and the spinal cord occupying the vertebral canal, are protected by the osseous walls of those cavities, and are also surrounded by **meninges** or membranes which support them and convey to their substance the vessels necessary for their nutrition.

The great centres of the cerebro-spinal nervous system are most easily understood by taking them up in the following order : spinal cord, medulla oblongata, pons Varolii, cerebrum, and cerebellum.

SPINAL CORD.

The **spinal cord** of the adult, from fifteen to eighteen inches in length, extends from the foramen magnum to opposite the lower border of the body of the first or upper border of the second lumbar vertebra, where it tapers to a conical point (*conus medullaris*), from which is continued downwards a slender cord, the *filum terminale*. In the child, at birth, the cone reaches the middle of the third lumbar vertebra, and in the embryo is prolonged as far as the lower part of the sacral canal. When stripped of its membranes and nerves the cord weighs from 1 oz. to $1\frac{3}{4}$ oz. ; its proportion to the weight of the encephalon is as 1 to 33. The cord presents a difference of diameter in different parts of its extent, and has two

enlargements. The uppermost of these corresponds with the origin of the nerves destined to the upper extremities (*cervical*); and the lower enlargement (*lumbar*) is situated near the termination of the cord, and corresponds with the attachment of the nerves intended for the supply of the lower limbs. The **cervical enlargement** is widest in the transverse diameter, and extends from the third cervical vertebra to the first dorsal; corresponding, therefore, to the origin of the nerves of the brachial plexus. The **lumbar enlargement** is widest from before backwards; it corresponds to the origin of the lumbar and sacral nerves, and extends from the tenth dorsal vertebra to the upper part of the conus medullaris. The spinal cord gives off near its termination an assemblage of nerves which has received the name of *cauda equina*; the **cauda equina** is formed by the roots of the lumbar and sacral nerves elongated by the growth of the spine, the ganglia of the posterior roots being held in connection with the intervertebral foramina through which the nerves pass.

The spinal cord is held in its place by its connection above with the medulla oblongata at the foramen magnum, and below by the attachment of the filum terminale to the base of the coccyx; laterally it is secured by a membrane, the *ligamentum dentatum*, which passes from its lateral aspect to join the dura mater, and by the spinal nerves which are fixed to the membranes and bones at the intervertebral foramina. It is much smaller than the canal in which it lies, being separated from the osseous walls by its membranes, by venous plexuses and areolar tissue.

In form, the spinal cord is a flattened cylinder, and presents on its anterior surface a fissure, which extends into the cord to the depth of one-third its diameter, and is occupied by a fold of pia mater. This is the **anterior median fissure**. If the sides of this fissure be gently separated, they will be seen to be connected at the bottom by a layer of white substance, the **anterior white commissure**. In the middle line behind and corresponding with the anterior fissure is the **posterior median fissure**, which contains a few blood-vessels and a little connective tissue (*neuroglia*). It extends more deeply into the cord than the anterior fissure, and reaches the grey substance of the interior forming the **posterior grey commissure**. These two fissures divide the spinal cord into two lateral portions, which are connected to each other by the white commissure which forms the bottom of the anterior fissure, and by a mass of grey matter situated behind it. A little external to the posterior median fissure on each side is a slight line, the **posterior intermediate septum**, which marks the limits of the posterior median columns. These columns are most apparent in the cervical region, and become continuous in the medulla oblongata, with the posterior pyramids, or funiculi graciles.

On the lateral aspects of the cord two other lines are observed, the *anterior* and *posterior lateral grooves*, corresponding with the attachment of the anterior and posterior roots of the spinal nerves.

The **anterior lateral groove** is a mere trace, marked only by the attachment of the filaments of the anterior roots; the **posterior lateral groove** is somewhat more evident.

These fissures and grooves divide the cord into columns, those of the two sides accurately corresponding, and receiving the same names. The column between the anterior median fissure and anterior nerve roots is called the **anterior column**; that between the anterior and posterior nerve roots, the **lateral column**,—the two together being often spoken of as the **antero-lateral column**. Between the posterior median fissure and the posterior nerve roots is the **posterior column**, which is again divided by the posterior intermediate septum into a **postero-internal column** (*Column of Goll*) and a **postero-external** (*Column of Burdach*).

Internal Structure.—If a transverse section of the spinal cord be made, its internal structure may be seen and examined. It will

then appear to be composed of two hollow cylinders of white substance placed side by side, and connected by a narrow *white commissure*. Each cylinder is filled with grey substance, which is connected by a commissure of the same matter (*grey commissure*). The grey matter is both relatively and absolutely the greatest in quantity in the lumbar portion of the cord; the white matter is relatively the greatest in amount in the dorsal region, and absolutely greatest in the cervical region. The form of the grey substance, as observed in the section, is that of two irregularly curved or crescentic lines joined by a transverse band. The extremities of the curved lines corresponding with the sulci of origin of the anterior and posterior roots of the nerves are termed

cornua; the **anterior cornu** is short and thick; the **posterior cornu**, long and slender, reaches nearly to the surface of the posterior lateral sulcus. The back part of the posterior horn is enlarged, and is called

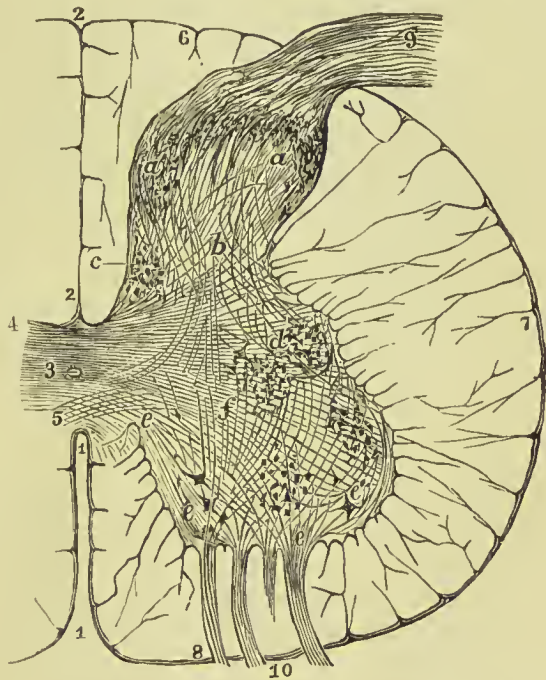


FIG. 289.—Transverse section of half the spinal cord. 1, 1. Anterior median fissure. 2, 2. Posterior median fissure. 3. Central canal. 4. Posterior commissure. 5. Anterior commissure. 6. Posterior column. 7. Lateral column. 8. Anterior column. 9. Posterior root. 10. Anterior root. a, a. Caput cornu posterioris. b. Cervix cornu. c. Cervix posterioris. d. Intermedio-lateral tract. e, e. Fibres of the anterior roots joining the anterior horn. f. Fibres running from anterior to posterior cornu.

the *caput cornu posterioris*, the constricted portion behind this being distinguished as the *cervix cornu*. At the tip of the *caput cornu* the grey matter has a semi-transparent appearance, and was called by Rolando the *substantia cinerea gelatinosa*.

Filum Terminale.—This is a fine thread which passes down from the conical end of the cord to be attached to the lower part of the sacral canal or base of the coccyx ; in its course downwards it lies in the middle of the nerves forming the cauda equina. For about half its length it contains nervous elements continued into it from the cord, contained in a sheath of pia mater, the latter forming the chief portion of the thread, and being the means by which the cord is held in place. At the lower part of the vertebral canal it is attached to the dura mater and wall of the canal.

Central Canal.—In the centre of the grey matter of the cord there is a minute canal lined by columnar epithelium, which extends upwards into the fourth ventricle, and downwards into the filum terminale. It is cylindrical or elliptical in shape in the upper part of the cord, but widens as it descends, and at the lower part is T-shaped ; it is not unusual to find it filled up with epithelial débris. The epithelium lining the canal is ciliated in the child, but there is no reason to believe that it is so in the adult.

Minute Structure of the Spinal Cord.—The pia mater closely invests the spinal cord, and sends a process into the anterior median fissure, which conveys blood-vessels for the interior of the cord. Beneath it, and not usually distinctly separable from its structure, is a covering of connective tissue, from which processes pass into the white matter of the cord so as to form partial septa between its several parts. The whole of the grey and white matter is traversed by the peculiar form of connective tissue already described under the title of **Neuroglia** (p. 37). This is especially plentiful around the central canal and in the *caput cornu posterioris* ; in the latter situation it constitutes the chief part of the *substantia gelatinosa* of Rolando. The neuroglia of the cord is composed of (1) a network of very fine fibrils resembling elastic tissue, (2) a fine granular or homogeneous matrix in which the fibres are embedded, and (3) small cells consisting of a nucleus and small cell-body, placed at the intersections of the fibres (*glia cells*, *cells of Deiters*). Neuroglia differs from all other forms of connective tissue in being of epiplastic origin, and in being composed of a peculiar material called *neuro-keratin*, which resembles horn or hair.

The **outer** or **white part of the cord** consists of medullated nerve-fibres lying in the meshes of the neuroglia ; they run, for the most part, longitudinally, and are devoid of primitive sheath and nodes of Ranvier. Sections stained with carmine show the axis-cylinder within each fibre, but seldom exactly in the centre, and the fibres are seen to vary considerably in size, the largest ones measuring $\frac{1}{150}$ inch, and the smallest $\frac{1}{1500}$ inch.

The **inner** or **grey portion of the cord** is composed of nerve-cells and grey or non-medullated nerve-fibres, supported by neuroglia.

Most of the cells are stellate or multipolar, but they vary greatly in their size and arrangement; they have no distinct sheath, possess a large nucleus and one or more nucleoli, and contain an intercellular and internuclear network. The outer edge of each grey crescent is very irregular, especially at the root of the anterior horn, where the margin is broken up by neuroglia fibres into a network, the meshes of which contain nerve-fibres; this is called the *lateral reticular formation*. In the upper dorsal region the grey matter forms a projection into the lateral white column opposite the grey commissure, sometimes described as the *lateral horn*. The nerve-cells are largest in the anterior cornu, where they are chiefly gathered into two groups, called the *antero-internal* group and the *antero-external* group. Another collection of somewhat smaller cells is found in the dorsal region of the cord in the lateral extension of the

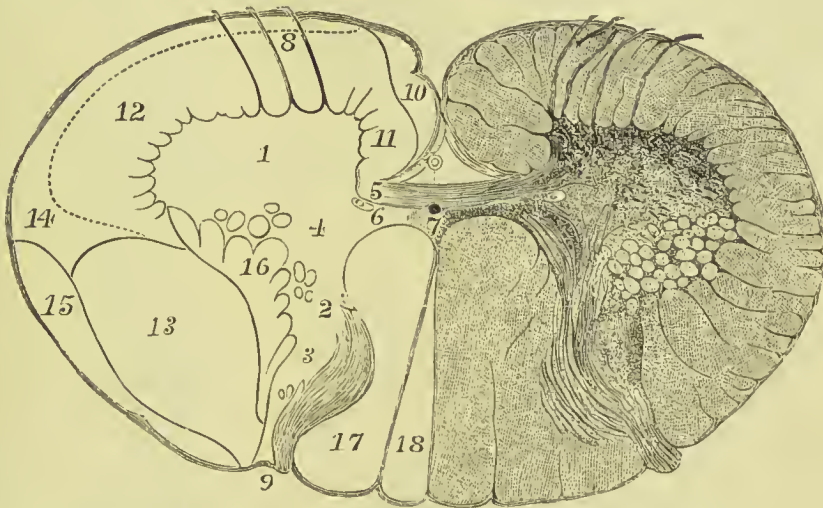


FIG. 290.—Diagram of the tracts of the spinal cord. 1. Anterior horn of grey matter. 2. Posterior horn. 3. Caput cornu posterioris. 4. Central grey matter. 5. Anterior (white) commissure. 6. Posterior (grey) commissure. 7. Central canal. 8. Anterior nerve root. 9. Posterior nerve root. 10. Direct pyramidal tract. 11. Anterior root zone. 12. Mixed zone. 13. Crossed pyramidal tract. 14. Superficial sensory tract (Gowers). 15. Direct cerebellar tract. 16. Lateral reticular formation. 17. Column of Burdach. 18. Column of Goll.

grey matter just mentioned (the lateral horn), and is called the *intermedio-lateral tract*; and another group of cells, lying in the inner part of the neck of the posterior horn, and limited to the middle region of the cord, is called the *posterior vesicular column of Clarke* (Fig. 289, c). The large multipolar cells have each one process (*axis-cylinder process*) connected with the axis-cylinder of a nerve; the other poles serve as means of communication with neighbouring cells.

Columns and Tracts in the White Matter of the Cord.—It has been noticed above that the fissures and grooves on the surface of the cord divide it into a number of columns, and these have been described as the anterior, lateral, postero-external, and postero-

internal. Experiments on animals, and observation of areas of degeneration after disease or injury in man, have, however, demonstrated that physiologically the columns or tracts are more numerous than this, and the following, briefly stated, are those generally recognised:—The inner portion of the anterior column bordering

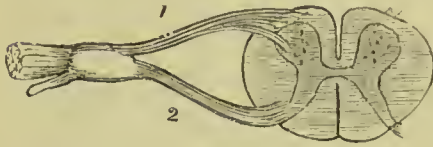


FIG. 291.—Transverse section of the spinal cord, showing the roots of the spinal nerves. 1. Anterior root. 2. Posterior root, with its ganglion.

on the anterior median fissure is known as the *direct pyramidal tract* or *column of Türck* (Fig. 290, 10); the rest of the anterior column is called the *anterior root zone* or *basis bundle* (11). On the surface of the lateral part of the cord, extending forwards from the posterior nerve roots, is a thin bundle of fibres called the *direct lateral cerebellar tract* (15), and beneath this a thicker mass of fibres, the *crossed pyramidal tract* (13), between which and the grey matter is a thin layer called the *lateral limiting layer*

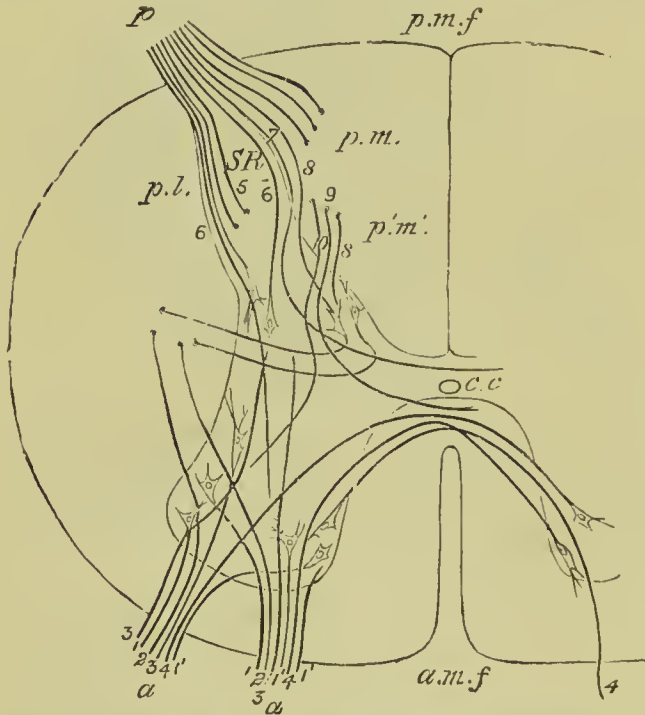


FIG. 292.—Diagram illustrating the paths probably taken by the fibres of the nerve-roots on entering the spinal cord (Schäfer). *a.m.f.* Anterior median fissure. *p.m.f.* Posterior median fissure. *c.c.* Central canal. *S.R.* Substantia gelatinosa of Rolando. *a.a.* Funiculi of anterior root of a nerve. *p.* Funiculus of posterior root of a nerve. By following the fibres 1, 2, 3, &c., their course through the grey matter of the spinal cord may be traced.

close to the lateral reticular formation (16); the rest of the lateral column is called the *mixed zone*, but this has been again divided into the deep part or *anterior ground fibres* (12); and the superficial part, the *antero-lateral sensory tract* (14). The posterior column, as already described, is divided into the *postero-external* or *column of Burdach* (17), and the *postero-internal* or *column of Goll* (18).

Origin of the Nerves.—The

spinal nerves arise by two roots, the distinctive characters of which, outside the spinal cord, will be described hereafter:

their connection with the nerve centre is here noted.

The **anterior roots** pass through the substance of the white

matter into the grey matter of the anterior cornu, which they enter in several bundles. Their fibres may be traced to (1) the antero-external group of cells, (2) the lateral white columns, (3) the posterior cornu, (4) the anterior part of the commissure, and (5) the antero-internal group of cells (J. R. Whitaker).

The **posterior roots** enter the cord in two distinct bundles—external and internal. The fibres of the *outer bundle* can be traced to (1) the nerve-cells of the posterior horn, (2) the anterior horn, and (3) the posterior part of the commissure. The fibres of the *inner bundle* do not pass directly into the grey matter, but enter the white substance of the postero-external column, and from thence pass into the grey centre; they have been traced to (1) the antero-external cells of the anterior horn, (2) the cells of the posterior vesicular column, and (3) the posterior part of the commissure (J. R. Whitaker).

THE ENCEPHALON.

The encephalon, or that part of the cerebro-spinal centre contained within the cranium, consists of the medulla oblongata, pons Varolii, cerebrum, and cerebellum. The whole mass weighs on an average about fifty ounces for the male, and forty-four and a half for the female.

MEDULLA OBLONGATA.

The medulla oblongata is the upper enlarged portion of the spinal cord. It is oblique in its position, its upper surface looking upwards and backwards, and its lower downwards and forwards; the former constitutes the lower part of the floor of the fourth ventricle, the latter lies on the basilar portion of the occipital bone. Its upper or posterior part is lodged in the vallecule of the cerebellum. It is somewhat conical in shape, and a little more than an inch in length, extending from the pons Varolii to a point corresponding with the upper border of the atlas. The *anterior* and *posterior median fissures* of the cord are continued into the medulla, and the former terminates at the lower edge of the pons in a small recess called the *foramen cecum of Vicq d'Azyr*. The *posterior fissure* expands about the middle of the medulla into a diamond-shaped cavity, the fourth ventricle, the presence of which causes the back of the medulla to be flattened. The *anterior median fissure* is interrupted at its lower part by the crossing of nerve-fibres between the two halves of the medulla, this being known as the **decussation of the pyramids**; this interchange consists in the mass of fibres from the lateral column of the one side passing to the anterior pyramid of the other side (*crossed pyramidal tract*).

The upper part of the medulla on its anterior aspect is distinguished by an oval prominence at each side called the **olivary body**; this is about half an inch in length, and extends to the inferior border of the pons.

Between the olivary body and the anterior median fissure is a pyramidal strand of white nerve matter called the **anterior pyramid**; it forms a rounded projection into which the fibres from the decussation of the pyramids pass, and is marked by a constricting groove at its connection with the pons. The outer part of each anterior pyramid is formed by fibres continued upwards from the *direct pyramidal tract* of the same side of the spinal cord; the inner and larger portion consists of the fibres of the *crossed pyramidal tract* of the opposite side of the cord, which, as already mentioned, enter it at the decussation.

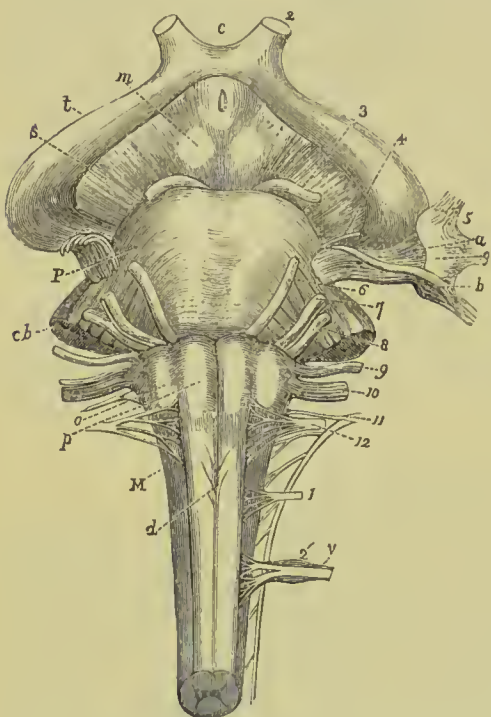


FIG. 293.—Front view of the upper part of the cranio-spinal axis, with the origins of the nerves. *M.* Medulla oblongata. *p.* Anterior pyramids. *d.* Their decussation. *o.* Olivary bodies. *p.* Pons Varolii. *c, b.* Crus cerebelli. *s.* Crus cerebri. *m.* Corpora mammillaria. *t.* Tractus opticus. *c.* Chiasma. *2.* Optic nerve. *3.* Motor oculi. *4.* Patheticus. *5.* Fifth pair. *a.* Its larger root. *b.* Its smaller root. *g.* Gasserian ganglion. *6.* Abducens. *7.* Facial. *8.* Auditory. *9.* Glosso-pharyngeal. *10.* Vagus. *11.* Spinal accessory. *12.* Hypoglossal. *1'.* First spinal nerve. *2'.* Second spinal nerve. *v.* Its ganglion.

Behind the olivary body a narrow white nerve strand will be observed,—this is the **olivary fasciculus** or **fillet**; it is derived from the mixed zone of the lateral column of the cord, and will be traced to the corpora quadrigemina and optic thalamus.

Curving round the lower end of the olive are the **external arciform** or **arcuate fibres**. They issue from the anterior median fissure, cross the anterior pyramids, skirt the lower end of the olivary body, and being joined by the lateral cerebellar tract of the cord, form the **restiform body**.

The groove between the olive and anterior pyramid is continuous with the slight marking on the cord at the origin of the anterior roots of the spinal nerves; here, however, it is a more distinct furrow, and lodges the two bundles of root fibres of the hypoglossal nerve. At the back of the olive and its fasciculus is another groove, continuous with the posterior lateral sulcus of the cord, and giving origin from above downwards to the glosso-pharyngeal, vagus, and spinal accessory nerves.

At the back part of the medulla and bordering on the posterior fissure is a narrow strand of fibres, already described in the spinal cord as the *postero-internal strand* or *column of Goll*; here it is

known as the **posterior pyramid** or **funiculus gracilis**. The upper extremity is enlarged and somewhat club-shaped, and hence is called the **clava**.

The posterior pyramid forms the lateral boundary of the lower end of the fourth ventricle; the fibres contained in it and derived from the posterior median column of the cord appear to be connected with a grey nucleus in the clava (*nucleus clavatus*).

External to the funiculus gracilis is a less-defined strand, which as it ascends also widens out, so as to become somewhat wedge-

shaped; this column is called the **funiculus cuneatus**, and its upper enlarged end is termed the **cuneate tubercle**. It is the upward extension of the *postero-external column* of the cord, or *column of Burdach*, and its tubercle contains a grey nucleus (*nucleus cuneatus*) in which many of the fibres of the column seem to terminate.

Still farther out is a longitudinal prominence, which, becoming broader as it ascends, forms a definite eminence, the **tubercle of Rolando**, the ridge itself being called the **funiculus of Rolando**. This strand is not continuous with the white matter of the cord; it consists mainly of a mass of grey matter (*nucleus of Rolando*), which is the representative in the medulla of the *caput cornu posterioris* of the cord.

Between the funiculus of Rolando and the olive we notice the *external arciform fibres* above described; they are reinforced by a band of fibres derived from the lateral column of the cord and forming the *direct cerebellar tract*. These strands unite to form the **restiform tract**, which, crossing the upper part of the funiculus of Rolando and funiculus cuneatus, in part blends with those tracts, and is thence continued upwards to the crus cerebelli, so as to form the inferior peduncle of the cerebellum (*processus ad medullam*).

Internal Structure of the Medulla Oblongata.—The internal structure is best demonstrated by cross-sections made at different levels; in such specimens the medulla is seen to be composed of

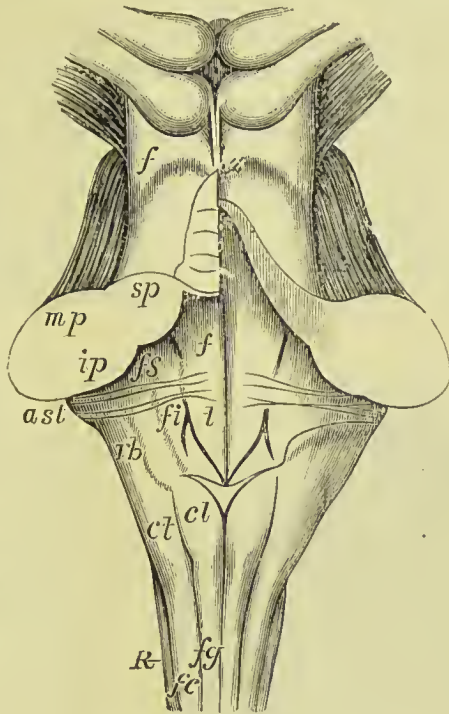


FIG. 294.—Medulla and pons from behind. *f.g.* Funiculus gracilis. *cl.* Processus clavatus. *f.c.* Funiculus cuneatus. *c.t.* Cuneate tubercle. *R.* Funiculus of Rolando. *f.i.* Inferior fovea. *f.s.* Superior fovea. *f.t.* Fasciculus teres. *a.st.* Auditory striæ. *r.b.* Restiform body. *s.p.* Superior peduncle of cerebellum. *m.p.* Middle peduncle. *i.p.* Inferior peduncle. *f.* Olfactory fillet.

longitudinal bundles of nerve-fibres, of masses of grey matter constituting nerve nuclei, and of nerve-fibres originating from them. If the section be made through the upper part of the decussation the appearance presented will be such as is shown in Fig. 295. In front and behind are the *anterior* and *posterior median fissures* (*a.m.f.* and *p.m.f.*); at the bottom of the anterior fissure is the decussation, proceeding from which a narrow band of fibres will be observed running outwards, forming the *deep arciform tract* (*f.a.¹*). Behind the decussation is the central canal surrounded by grey matter. In the front of the medulla, and bordering on the anterior fissure, is a large triangular mass of white matter, the *anterior pyramid*, on the surface of which are the *superficial arciform fibres* (*f.a.*), and near its outer border is

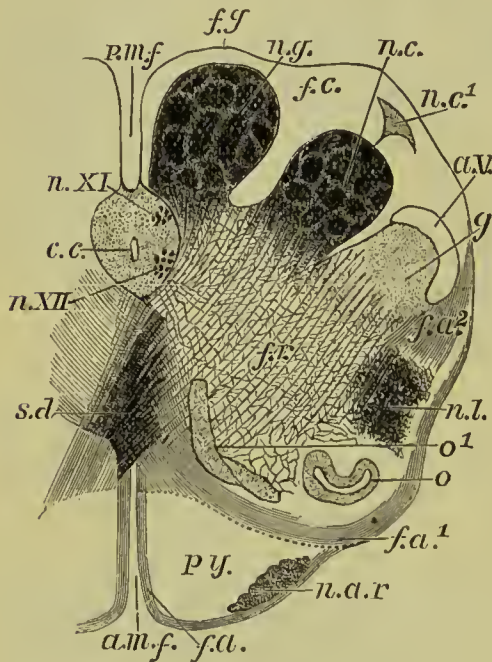


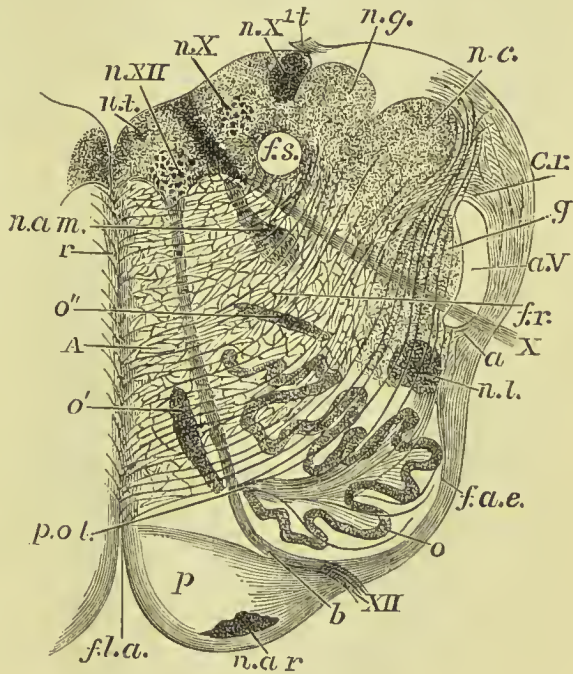
FIG. 295.—Section of the medulla at the level of the decussation of the pyramids. *a.m.f.* Anterior median fissure. *p.m.f.* Posterior median fissure. *py.* Pyramid. *n.ar.* Nucleus of the arciform fibres. *f.a.¹*. Deep arciform fibres becoming superficial. *o.* Lower end of olivary nucleus. *o¹*. Accessory olivary nucleus. *n.l.* Nucleus lateralis. *f.r.* Formatio reticularis. *f.a.²*. Arciform fibres coming from formatio reticularis. *g.* Substantia gelatinosa (Rolando). *a.v.* Ascending root of fifth nerve. *n.c.* Nucleus cuneatus. *n.c¹*. External cuneate nucleus. *f.c.* Funiculus cuneatus. *n.g.* Nucleus gracilis. *f.g.* Funiculus gracilis. *c.c.* Central canal, with grey nuclei for (*n.xi.*) spinal accessory nerve, (*n.xii.*) Hypoglossal. *s.d.* Inferior decussation.

a small grey nucleus, the *arciform nucleus*. The central part of the section is occupied by the *formatio reticularis*, a coarse network of grey matter, containing nerve-cells, intersected by bundles of white fibres; on the outer edge of this is a grey mass, the *nucleus lateralis*, which is the remains of the anterior horn of the spinal cord (*n.l.*). Between the *nucleus lateralis* and the decussation is a long grey mass, the *internal accessory olivary nucleus* (*o¹*), and outside there is an irregular nucleus (*o.*), which is the lower extremity of the *corpus dentatum* of the olive. At the back of the medulla is a large nucleus, the *nucleus gracilis* (*n.g.*), causing the projection of the clava of *funiculus gracilis* (*f.g.*), as already described; external to this another large mass, the *cuneate nucleus* (*n.c.*), lies in the deep part of the *funiculus cuneatus* (*f.c.*), a secondary smaller deposit near the surface of that column being called the *external cuneate nucleus* (*n.c¹*).

Behind the lateral nucleus is the *grey tubercle of Rolando* (*g.*), the upper expansion of the *caput cornu posterioris*, and on the surface of this a white concave band, the *ascending sensory root of the fifth nerve* (*a.v.*). In front of the latter a few fibres derived from the *formatio reticularis* will be noticed (*f.a.*²); they join the arciform fibres at the lower margin of the olive.

If we now examine a section through the middle of the olivary body we shall find that important changes have taken place in the arrangement of parts. The central canal has disappeared, and the centre of the medulla is occupied by a *raphé*, composed of non-medullated fibres and multipolar cells; it extends from the anterior median fissure to beneath the floor of the fourth ventricle. The

FIG. 296.—Section of medulla about the middle of olivary body. *f.l.a.* Anterior median fissure. *n.ar.* Arciform nucleus. *p.* Pyramid. XII. Surface origin of hypoglossal, which is seen at *b.* passing between the pyramid and olive. *o.* Dentate nucleus of olive. *o'* and *o''*. Accessory olivary nuclei. *f.a.e.* External arciform fibres. *n.l.* Nucleus lateralis. *a.* Arciform fibres passing towards restiform, partly through substantia gelatinosa, *g.* partly superficial to ascending root of fifth, *a.v.* *x.* Surface origin of vagus. *f.r.* Formatio reticularis. *c.r.* Restiform body. *n.c.* Nucleus cuneatus. *n.g.* Nucleus gracilis. *t.* Attachment of ligula. *f.s.* Funiculus solitarius. *n.x.* and *n.x*¹. Two nuclei of vagus. *n.xii.* Nucleus of hypoglossal. *n.t.* Nucleus of fasciculus teres. *n.am.* Nucleus ambiguus. *r.* Raphé. *d.* Anterior column of cord. *p.ol.* Peduncle of olive.



lateral part of the medulla is traversed by two nerve strands, in front the *hypoglossal* or *twelfth nerve* (Fig. 296, XII.), and laterally the *vagus* or *tenth nerve* (*x.*). These enclosed a wedge-shaped area which is occupied by large and irregular grey nucleus, the *corpus dentatum* of the olive (*o.*), and, behind this, a smaller deposit of grey matter, the *external accessory olivary nucleus* (*o''*). The *nucleus gracilis* and *nucleus cuneatus* have been pushed outwards by the opening up of the medulla posteriorly to form the fourth ventricle, and between them and the posterior median fissure a collection of grey matter has been interposed, which lies beneath the floor of the ventricle. In this grey matter four definite nuclei can be made out; these are, (1) near the middle line the *nucleus of the fasciculus teres* (*n.t.*), (2) beneath and external to this, the *nucleus of the hypoglossal*

nerve (*n. XII.*), and (3 and 4) the two nuclei of the *vagus* (*n. X.* and *n. X.¹*). Both the *substantia gelatinosa of Rolando* and the *nucleus lateralis* are present, but are much less distinct than in the previous section. Internal to the nucleus gracilis and a little anterior is a round bundle of white fibres, called the *funiculus solitarius* (*f. s.*); it is by some supposed to be the root of the phrenic nerve in the medulla.

The course taken by the different nerve strands in passing through the medulla will be traced after the cerebrum and cerebellum have been described.

PONS VAROLII.

The **pons Varolii** (*tuber annulare*) is a convex arch of white matter situated above the medulla, and forming on each side a slightly constricted strand where it enters each lateral half of the cerebellum, and constitutes the middle peduncle of the crus cerebelli (*processus ad pontem*). Its upper border lies across the commencement of the crura cerebri, and its lower is marked off from the medulla by a deep groove; in the middle line it has a slight depression, which lodges the basilar artery. From its lateral aspect issue the two roots of the fifth nerve. The posterior surface of the pons is ill-defined; it is flattened from before backwards, and forms the upper part of the floor of the fourth ventricle.

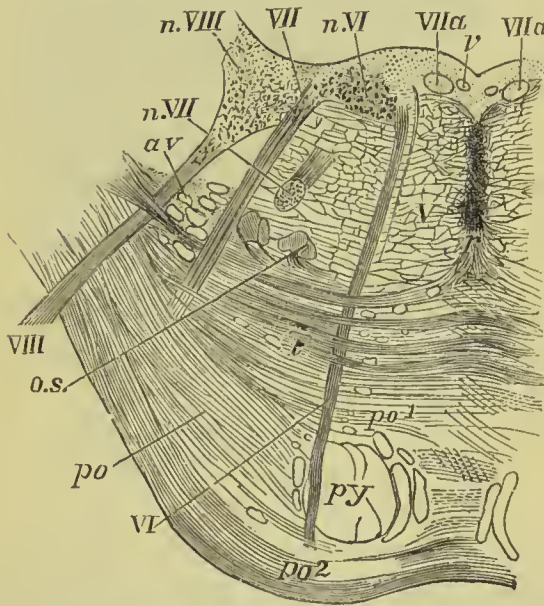


FIG. 297.—Section across pons at middle of fourth ventricle. *py.* Pyramid, continued up from medulla. *po.* Transverse fibres passing some behind (*po¹*) and some in front (*po²*) of pyramidal bundles. *t.* Deeper fibres constituting trapezium. *r.* Raphé. *o. s.* Superior olivary nucleus. *a. v.* Ascending root of fifth. *vi.* Sixth nerve. *n. vi.* Its nucleus. *vii.* The seventh nerve. *vii. a.* Intermediary nerve of Wrisberg. *n. vii.* Its nucleus. *viii.* Superior root of auditory nerve. *n. viii.* Part of the outer or superior nucleus. *v.* Section of a vein.

measure of the grey nuclei in the floor of the fourth ventricle. In order, however, fully to understand the internal structure of

the pons it is necessary to study a **transverse section**, such as that shown in Fig. 297. The *superficial transverse fibres* (*po*².) are separated from the *deep* (*po*¹.) by the mass of ascending fibres from the anterior pyramid (*py*.). Near the middle of the section is a large collection of the deep transverse fibres, called the *trapezium* (*t*.) from the fact that in certain lower animals it assumes the appearance of an irregular four-sided figure. Behind the trapezium is a continuation of the *formatio reticularis*, already described in the sections of the medulla; in the middle line is an imperfect *raphé* formed of nerve-cells and non-medullated fibres. At the back are the nuclei for the origin of the sixth, seventh, and eighth nerves (indicated in the figure by Roman numerals), and nerve strands are seen proceeding from these and traversing the pons. The ascending root of the fifth nerve is seen cut across (*a.v.*), enclosed by a continuation of the *grey substance of Rolando*; while a special nucleus (*o.s.*), called the *superior olivary nucleus*, is situated behind the lateral fibres of the trapezium. Some writers describe a small grey nucleus among the superficial transverse fibres, and name it the *nucleus of the pons*.

CEREBRUM.

The cerebrum presents on its surface a number of slightly convex elevations, the convolutions (*gyri*), which are separated from each other by *sulci* of various depth. It is divided superiorly into two hemispheres by the great longitudinal fissure, which lodges the *falx cerebri*, and marks the original development of the brain by two symmetrical halves.

Base of the Brain.

The student should first study the base of the brain; for this purpose the organ should be turned upon its upper surface. The arachnoid membrane, some parts of the *pia mater*, and the circle of Willis, must be carefully cleared away, in order to expose all the parts to be examined. These he will find to be as follows:—

Longitudinal fissure,	Infundibulum;
Corpus callosum,	Pituitary body,
Lamina cinerea,	Corpora albicantia,
Olfactory nerves,	Locus perforatus,
Fissure of Sylvius,	Crura cerebri;
Substantia perforata;	Pons Varolii,
Optic commissure,	Crura cerebelli,
Tuber cinereum,	Medulla oblongata.

The **longitudinal fissure** is the space separating the two hemispheres; it is continued downwards to the base of the brain, and divides the two anterior lobes. In this fissure the anterior cerebral arteries ascend towards the corpus callosum; and if the two lobes be slightly drawn asunder, the anterior border (*genu*) of the corpus

callosum will be seen descending to the base of the brain. Arrived at the base of the brain, the corpus callosum terminates by a concave border, which is prolonged to the commissure of the optic nerves by a thin layer of grey substance, the *lamina cinerea*. The lamina cinerea is the anterior part of the inferior boundary of the third ventricle. On each side of the lamina cinerea the corpus callosum is continued backwards and outwards as a broad white band, these being called the peduncles of the corpus callosum; they cross the

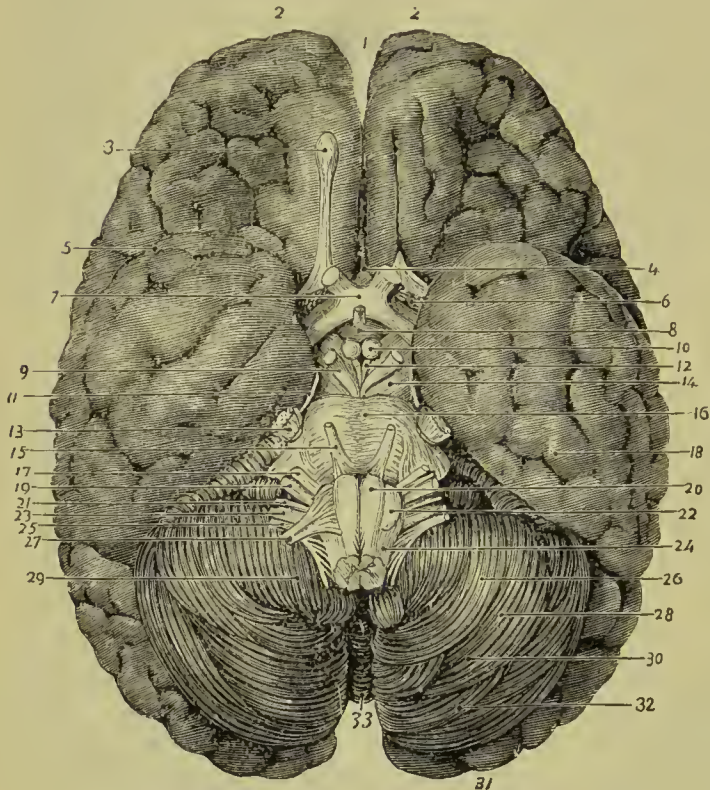


FIG. 298.—The base of the brain. 1. Longitudinal fissure. 2, 2. Frontal lobes. 3. Olfactory bulb. 4. Lamina cinerea. 5. Fissure of Sylvius. 6. Locus perforatus anticus. 7. Optic commissure. 8. Tuber cinereum and infundibulum. 9. Third nerve. 10. Corpus albicans. 11. Fourth nerve. 12. Locus perforatus posticus. 13. Fifth nerve. 14. Crus cerebri. 15. Sixth nerve. 16. Pons Varolii. 17. Seventh nerve. 18. Temporo-sphenoidal lobe. 19. Eighth nerve. 20. Anterior pyramid. 21. Glosso-pharyngeal nerve. 22. Olivary body. 23. Pneumogastric nerve. 24. Lateral tract.

25. Spinal accessory nerve. 26. Digastric lobe. 27. Hypoglossal nerve. 28. Cerebellum. 29. Amygdala. 30. Slender lobe of cerebellum. 31. Occipital lobe of cerebrum. 32. Posterior inferior lobe of cerebellum. 33. Inferior vermiform process of cerebellum.

substantia perforata and end at the commencement of the fissure of Sylvius.

On the under surface of each anterior lobe, on either side of the longitudinal fissure, is the *olfactory nerve*, with its bulb.

The **fissure of Sylvius** bounds the frontal lobe posteriorly, and separates it from the temporo-sphenoidal lobe; it lodges the middle cerebral artery.

The **substantia perforata** (locus perforatus anticus) is a triangular surface coated with grey matter, situated at the inner extremity of the fissure of Sylvius. It is named *perforata* from being pierced by a number of openings for the medullary branches of the middle

cerebral artery which enter the brain in this situation to supply the grey substance of the corpus striatum.

The **optic commissure** is situated in the middle line; it is the point of communication between the two optic nerves.

The **tuber cinereum** is an eminence of grey substance situated immediately behind the optic commissure, and in front of the corpora albicantia. From its centre there projects a small conical body of grey substance, apparently a prolongation of the tuber cinereum, the **infundibulum**. The infundibulum is hollow, enclosing a short cæcal canal, which communicates with the cavity of the third ventricle; and, below the termination of the canal, the conical process becomes connected with the pituitary body. The infundibulum and tuber cinereum form part of the floor of the third ventricle.

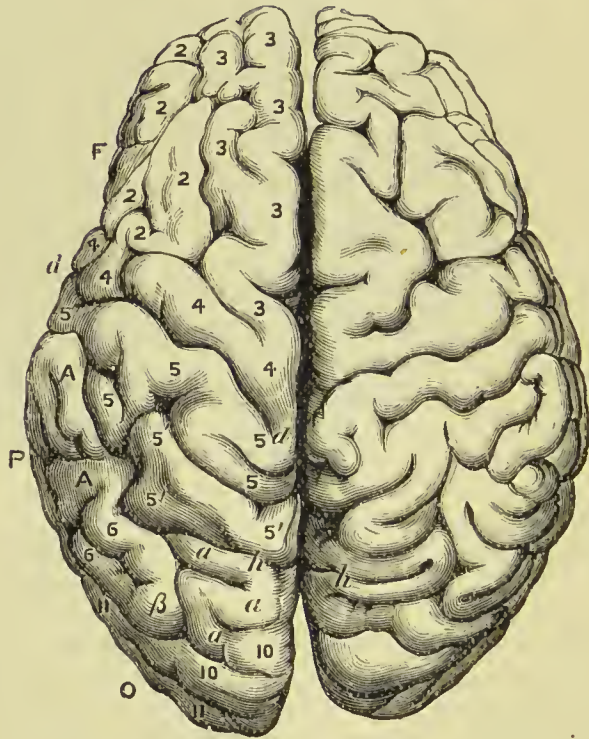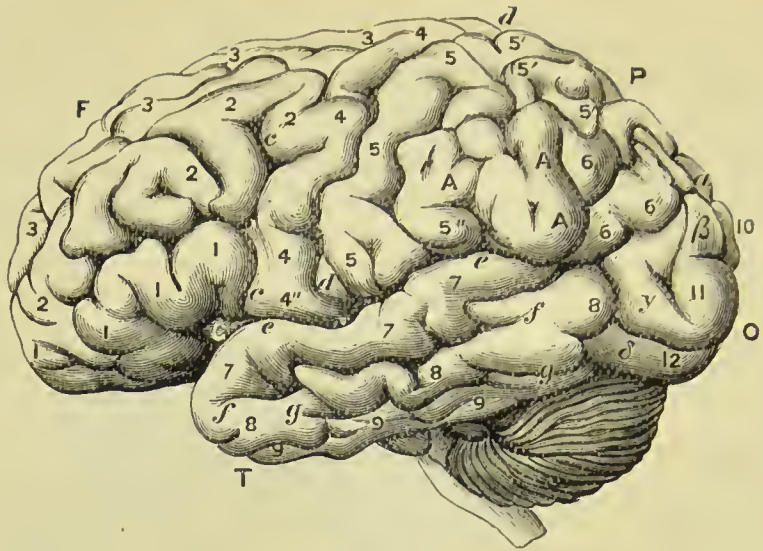The **pituitary body** (*hypophysis cerebri*) is a small, flattened reddish-grey body, situated in the sella turcica, and closely retained in that situation by the dura mater and arachnoid. It consists of two lobes, closely pressed together, the anterior lobe being the larger of the two and oblong in shape, the posterior round. Both lobes are connected with the infundibulum, but the latter is so soft in texture as to be generally torn through in the removal of the brain. Indeed, for the purposes of the student, it is better to effect this separation with the knife, and leave the pituitary body *in situ*, to be examined with the base of the cranium.

The **corpora albicantia** (*mammillaria*, *bulbi fornicis*) are two white convex bodies, having the shape and size of peas, situated behind the tuber cinereum, and between the crura cerebri. They are a part of the anterior crura of the fornix, which, after their origin from the thalami optici, descend to the base of the brain, and making a sudden curve upon themselves previously to their ascent to the lateral ventricles, constitute the corpora albicantia. When divided by section, these bodies will be found to be composed of a capsule of white substance, containing grey matter, the grey matter of the two corpora being connected by means of a commissure.

The **locus perforatus posticus** (*pons Tarini*) is a layer of whitish-grey substance, connected in front with the corpora albicantia, behind with the pons Varolii, and on each side with the crura cerebri, between which it is situated. It is perforated by several thick tufts of arteries derived from the posterior cerebral which are distributed to the thalami optici and third ventricle, of which latter it assists in forming the floor.

The **crura cerebri** (*peduncles of the cerebrum*) are two thick white cords, which issue from the anterior border of the pons Varolii, and diverge to enter the thalami optici and corpora striata. The third nerve will be observed to arise from the inner side of each crus, and the fourth nerve winds around its outer border from above.

The diverging crura cerebri behind, the temporo-sphenoidal lobes at the sides, and the end of the longitudinal fissure in front, limit



FIGS. 299, 300.—Lateral view and upper surface of the brain of a Bush-woman. *c*. Central lobe, or island of Reil. *F*. Frontal lobe. *P*. Parietal lobe. *O*. Occipital lobe. *T*. Temporo-sphenoidal lobe. The lower *c* indicates the anterior division of fissures of Sylvius, the upper *c* the precentral fissure. *d*. Fissure of Rolando. *e*. Sylvian fissure, posterior division. *f*. Parallel fissure. *g*. Inferior temporal fissure. *h*. Parieto-occipital fissure. *i*. Lower frontal convolution. *2*. Middle frontal convolution. *3*. Upper frontal convolution. *4*. Ascending frontal convolution. *4''*. Lobe of Broca. *5*. Ascending parietal convolution. *5'*. Superior parietal convolution. *5''*. Supra-marginal convolution. *A*. Inferior parietal convolution. *6*. Angular gyrus. *7*. First temporo-sphenoidal convolution. *8*. Second temporo-

sphenoidal convolution. 9. Third temporo-sphenoidal convolution. 10. First occipital convolution. 11. Second occipital convolution. 12. Third occipital convolution. *a.* First or upper external annectant convolution. *β.* Second external annectant convolution. *γ.* Third external annectant convolution. *δ.* Fourth external annectant convolution.

an irregular area, the **interpeduncular space**. The structures therein situated form the floor of the third ventricle; they are the lamina cinerea, tuber cinereum, infundibulum, corpora albicantia, and locus perforatus posticus.

The **pons Varolii** has been already described. On its lateral aspect is the thick bundle of filaments belonging to the fifth nerve; lying against its posterior border are the seventh and eighth pairs of nerves, and between it and the anterior pyramid of the medulla the sixth nerve has its origin.

The **medulla oblongata** is described at p. 491.

Convolutions and Sulci.

The cerebrum is divided into five lobes, which, although intimately connected with each other in their deeper parts, are separated on the surface by well-defined fissures or sulci; they are the **frontal, parietal, occipital, temporo-sphenoidal, and central**. The fissures which form the boundaries of these lobes are three in number—the **fissure of Sylvius, fissure of Rolando, and parieto-occipital fissure**: these will be first described, after which the different lobes and the convolutions will be studied in detail.

Fissure of Sylvius (Fig. 299, *c, e*).—This fissure has already been mentioned in connection with the structures at the base of the brain; it consists of two portions, one of which (*c*) passes almost vertically upwards into the frontal lobe; the other (*e*) is directed obliquely upwards and backwards, and serves to separate the parietal from the temporo-sphenoidal lobe.

The group of convolutions placed between the two limbs of the fissure of Sylvius were collectively named by Broca the *operculum of the insula*, but are better known as the *lobe of Broca*; on turning them aside the *central lobe* or *island of Reil* is brought into view.

Fissure of Rolando (Figs. 299 and 300, *d*).—Placed nearly in the centre of the outer surface of the cerebrum, this fissure is found to commence near the margin of the longitudinal fissure, and to run downwards and forwards, to terminate a little behind the bifurcation of the fissure of Sylvius. It divides the frontal from the parietal lobe, and is bounded throughout its entire length by two convolutions, the one in front being the ascending frontal, the one behind the ascending parietal. The chief motor areas of the cortex are situated in the convolutions bordering on this fissure.

The **parieto-occipital fissure** is less distinctly marked than the two just described; it is best seen on the inner surface of the hemisphere (Fig. 301, *p o*). It commences near the posterior extremity of the corpus callosum, where it is united with the calcarine fissure, and passing upwards and backwards appears on the margin of the

hemisphere in the longitudinal fissure ; it then runs for a short distance over the external convex surface of the cerebrum, and separates the parietal from the occipital lobe. The extent to which this fissure may be traced in the latter direction varies greatly in different brains ; sometimes the fissure is a mere notch at the upper margin of the hemisphere, at other times it extends over a considerable part of its surface. This difference depends on the presence and degree of development of the annectant convolutions.

The **frontal lobe** (Figs. 299, 300, and 301, F) forms the anterior part of the brain, its under surface resting on the orbital plate of the frontal bone ; it is separated from the parietal lobe by the fissure of Rolando, and from the temporo-sphenoidal lobe by the fissure of Sylvius. On the inner surface of the hemisphere the frontal lobe is not well defined, but is generally described as terminating at the upper limb of the callosa-marginal fissure. The frontal lobe is marked by five fissures, which are the boundaries of the convolutions of which it is composed ; two of these called *inferior* and *superior frontal sulci* divide the greater portion of the lobe into three chief convolutions, called respectively the *first*, *second*, and *third*, or *inferior*, *middle*, and *superior frontal gyri* (Fig. 299, 1, 2, 3). A third fissure called *precentral* runs in front of and nearly parallel with the fissure of Rolando ; other fissures called *olfactory* and *orbital* are found on the under surface of the frontal lobe. The *ascending frontal* convolution (4) bounds the fissure of Rolando anteriorly, and is connected at each extremity of that fissure with the *ascending parietal* convolution. The under surface of the frontal lobe rests upon the orbital plate of the frontal bone, and the convolutions are consequently named *orbital* ; there are usually three distinguishable, called from their position *inner*, *outer*, and *anterior orbital*. Two fissures are here seen, one of which is described as the *orbital* or *triradiate sulcus* ; the other lodges the olfactory tract, and hence is known as the *olfactory sulcus*. The sulci and convolutions of the inner aspect of the frontal lobe will be described when that surface of the hemisphere is considered as a whole (p. 503).

The **parietal lobe** (Figs. 299, 300, and 301, P) is separated in front from the frontal lobe by the fissure of Rolando, below it is bounded by the posterior portion of the fissure of Sylvius, and behind by the parieto-occipital fissure. At the lower and back part it is united with the temporo-sphenoidal and occipital lobes by the annectant convolutions. It is divided by a deep sulcus, which runs downwards and backwards near its centre and is called the *interparietal fissure*, into two chief convolutions, the upper called *superior* and the lower *inferior parietal* ; the latter is further divided into two parts, one running along the upper border of the posterior part of the fissure of Sylvius and called *supra-marginal convolution*, the other called *angular gyrus* forming an irregular convolution which connects the temporo-sphenoidal and parietal lobes, and winds round the posterior end of the first temporo-sphenoidal or parallel

fissure. The anterior border of the parietal lobe is formed by the *ascending parietal* convolution, which, as mentioned above, bounds the fissure of Rolando posteriorly.

The **occipital lobe** (o), of small size, forms the posterior termination of the cerebrum; it is imperfectly limited above by the parieto-occipital fissure, but laterally and below is united with the parietal and temporo-sphenoidal lobes by annectant convolutions. It contains three ill-defined convolutions placed horizontally, and named *first* (10), *second* (11), and *third* (12) occipital gyri.

The **temporo-sphenoidal** or **temporal lobe** (T) fills up the middle fossa of the skull, and is the deepest-seated portion of the cerebrum. It is separated from the frontal lobe and anterior part of the parietal lobe by the fissure of Sylvius, but is united to the occipital and parietal lobes posteriorly. It is marked by three fissures, the first of which lies immediately below the posterior part of the fissure of Sylvius, and as it runs in the same direction is named the *parallel fissure*; the other two are called the *middle* and *inferior* temporo-sphenoidal fissures. The chief convolutions are three in number, *first* (or *infra-marginal*) (7), *second* (8), and *third* (9), temporo-sphenoidal gyri. Below these, on the under surface of the brain, are two *temporo-occipital convolutions*, the outer of which, being wider in the middle than at either end, is named the *fusiform lobule*; the inner one is named the *lingual lobule*, and is continuous at its posterior part with the hippocampal convolution.

The **central lobe** or **island of Reil** (c) is situated in the fissure of Sylvius, being covered by the convolutions of the frontal, parietal, and temporo-sphenoidal lobes, more especially the lower end of ascending parietal and ascending frontal, and the posterior extremity of the inferior frontal convolution, these together constituting the *operculum*. It corresponds in position to the outer surface of the corpus striatum, as may be well seen in a vertical transverse section of the brain (see Fig. 314). It is divided into four or five small convolutions (*gyri operati*) which radiate from the centre of its posterior border, the sulci between which lodge the divisions of the middle cerebral artery. The sulci which separate the central lobe from the rest of the hemisphere are known as the *anterior*, *posterior*, and *external fissures of Reil*.

The **annectant convolutions** are four in number; the *first* (a) joins the parietal to the upper part of the occipital lobe, the *second* (β) connects the angular gyrus of the parietal with the first convolution of the occipital lobe, and the *third* (γ) and *fourth* (δ) connect the second and third temporal convolutions with the occipital lobe.

The Inner Surface of the Hemisphere.

By slicing off one hemisphere to the level of the corpus callosum, a side view of the opposite hemisphere will be obtained, but to complete the study of the inner surface of the hemisphere a complete vertical section of a hardened brain should be referred to.

The *inner surface of the hemisphere* (Fig. 301) at its anterior part presents two large convolutions, the upper, the *marginal convolution* (1) (convolution of longitudinal fissure), and the lower, the *convolution of the corpus callosum* (2) or *gyrus fornicatus*, separated by the *calloso-marginal fissure* (CM) which reaches the margin of the hemisphere, a little posterior to the position of the fissure of Rolando, and bounds the marginal convolution behind.

The **marginal convolution** (1) commences in front of the anterior perforated spot, and runs along the edge of the longitudinal fissure to the point where the calloso-marginal fissure turns up to the edge of the hemisphere. It is continuous over the edge of the longitudinal fissure with the inner orbital, superior frontal, ascending frontal, and ascending parietal convolutions.

The **gyrus fornicatus** (2) is a well-marked convolution which begins at the anterior perforated space in the base of the brain, and

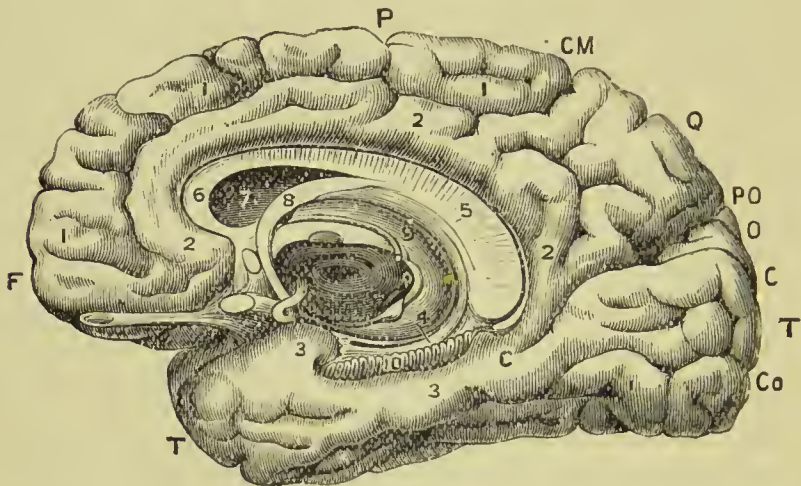


FIG. 301.—The inner and under surfaces of the brain to show the convolutions. F. Frontal lobe. P. Parietal lobe. Q. Quadrangle lobe. O. Cuneus lobe. T, T. Temporal lobe. CM. Calloso-marginal fissure. PO. Parieto-occipital fissure. CC. Calcarine fissure. Co. Collateral fissure. 1, 1. Marginal convolution. 2, 2. Gyri fornicatus. 3, 3. Uncinate gyri. 4. Dentate convolution. 5. United corpus callosum and fornix. 6. Genu of corpus callosum. 7. Cavity of lateral ventricle. 8. Fornix. 9. Thalamus with corpora geniculata. 10. Fascia dentata in dentate fissure.

winds round the corpus callosum to the posterior part, where it becomes continuous with the upper internal temporal convolution or uncinate gyrus. It becomes connected in its course with the frontal convolutions, the quadrangle lobe, the cuneus, and the lingual lobule. As it winds round the splenium of the corpus callosum it bounds the *fissure of the hippocampus* which forms the hippocampus major; hence this portion of the gyrus receives the name of *gyrus hippocampi*.

Posterior to the marginal convolution and continuous below with the *gyrus fornicatus* is the *quadrangle lobe* (*precuneus*) (Q), which is separated from the *cuneus lobe* (O) by the *parieto-occipital fissure* (PO), a continuation of the fissure of the same name seen externally.

The **quadrate lobe** or **precuneus** (Q), the inner portion of the parietal lobe, is bounded in front by the calloso-marginal fissure, and behind by the parieto-occipital fissure; below it is continuous with the gyrus fornicatus, and above with the superior parietal convolution.

The **cuneus lobe** (o) is triangular in shape, and is placed between the parieto-occipital and the calcarine fissure (c); the latter separates it from the internal convolutions of the temporal lobe (T).

The **calcarine fissure** (c) of Huxley runs below the cuneus lobe to the extremity of the gyrus fornicatus, being joined midway by the parieto-occipital fissure. It is an important fissure, since it corresponds to the projection called the *hippocampus minor* in the posterior cornu of the lateral ventricle.

The **internal temporal convolutions** form the lower part of the inner wall of the hemisphere, and are continuous with those of the temporal lobe externally. The most important is the *uncinate gyrus* (3), which is immediately below the calcarine fissure and runs horizontally forward, becoming united with the gyrus fornicatus and passing in front of the fascia dentata. It then makes a sudden bend backward for half an inch, this hook-like process from which it derives its name becoming united with the *tænia hippocampi*.

The **collateral fissure** (Co) separates this last convolution from the inferior temporal convolutions, which are very irregular. It causes the prominence in the descending cornu of the lateral ventricle known as the *eminentia collateralis*.

The **dentate fissure** (IO) is that immediately above the uncinatè gyrus which lodges the *fascia dentata*, and corresponds to the *hippocampus major* in the descending cornu of the lateral ventricle. Immediately above this is a small *dentate convolution* (4), united with the *tænia hippocampi*, and continuous below with the uncinatè gyrus.

Structure of the Convolution.

The convolutions are composed internally of white nerve matter continuous with that which forms the great bulk of the interior of the brain; externally they are covered by several superimposed layers of grey matter, each layer having certain characteristics which serve to distinguish it from its fellows. The layers vary in their number and depth in different brains and in different parts of the same brain, but in the parietal lobe it is easy with the microscope to distinguish that they are five in number.

The *first* or *external* layer forms about one-tenth of the thickness of the cortex. It is pale in colour, and consists chiefly of neuroglia, in which a few scattered stellate nerve-cells are found, and near the surface numerous fine varicose medullated nerve-fibres, crossing each other in all directions.

The *second* layer, of about the same width, is made up of closely set small pyramidal nerve-cells with branching processes, the apex

of the pyramid being a little drawn out, and in every instance directed towards the surface of the convolution.

The *third* layer is wider and paler than the second; it consists of large pyramidal cells separated into groups by the radiating fibres of the hemisphere.

The *fourth* layer is composed of small, closely set, angular corpuscles, placed irregularly, and imperfectly separated into groups.

The *fifth* is a layer of fusiform corpuscles which are placed vertically to the summit of a gyrus, but parallel to the surface of a sulcus.

With the unaided eye it is easy to note the alternation of whitish with reddish-grey layers, but it is at all times difficult, even with the microscope, to ascertain the number of layers, or to define accurately the limits of each.



FIG. 302.—Section of grey cortex of a convolution. 1, 2, 3, 4, 5. The five layers described in the next. *m*. The white centre of the brain.

The Interior of the Cerebrum.

If the brain be placed upon its base, and the upper part of one hemisphere, at about one-third from its summit, be removed with a scalpel, a centre of white substance will be observed, surrounded by a narrow border of grey, which follows the line of the sulci and convolutions, and presents a zigzag form. This section is called *centrum ovale minus*; it is spotted by numerous small red points (*puncta vasculosa*), which are produced by the escape of blood from the cut ends of minute arteries and veins.

Separate carefully the two hemispheres of the cerebrum, and a broad band of white substance (*corpus callosum*) will be seen to connect them; it will be seen also that the surface of the hemisphere, where it comes in contact with the *corpus callosum*, is bounded by the *gyrus fornicatus*. The sulcus between this convolution and the *corpus callosum* has been termed the “ventricle of the *corpus callosum*.” If the upper part of each hemisphere be removed to a level with the *corpus callosum*, a large expanse of medullary matter, surrounded by a zigzag line of grey substance corresponding with the convolutions and sulci of the two hemispheres, will be seen; this is the *centrum ovale majus* of Vieussens.

The **corpus callosum** is a thick layer of fibres passing transversely between the two hemispheres, and constituting their *great*

commissure. It is situated in the middle line of the centrum ovale majus, but nearer the anterior than the posterior part of the brain, and ends anteriorly in a rounded border, *genu*, which may be traced downwards to the base of the brain in front of the commissure of the optic nerves; it here gives off two narrow white bands called *peduncles*, which diverge from each other and pass backwards across the substantia perforata

to the fissure of Sylvius, where they terminate. Posteriorly it forms a thick rounded fold, *splenium*, which is connected on its under surface with the fornix; throughout the rest of its extent the corpus callosum is connected on its under surface with the septum lucidum. The length of the corpus callosum is about four inches. Along the middle line is the *raphé*, a linear depression between two slightly elevated longitudinal bands (*chordæ longitudinales Lancisii*); and, on each side of the *raphé*, may be seen the *linæ transversæ*, which mark the direction of the fibres of which the corpus callosum is composed. These fibres may be traced into the hemispheres on each side, and they will be seen to be crossed at about an inch from the *raphé*, by lateral longitudinal fibres, *striæ longitudinales laterales*. Anteriorly and posteriorly the fibres of the corpus callosum curve forwards and backwards into their corresponding lobes.

Beneath the posterior rounded border of the corpus callosum is the *transverse fissure* of the cerebrum, which extends between the hemispheres and crura cerebri from near the fissure of Sylvius on one side, to the same point on the opposite side of the brain. It is through this fissure that the pia mater communicates with the velum interpositum.

If a superficial incision be made through the corpus callosum on each side of the *raphé*, two irregular cavities will be opened, which extend from one extremity of the hemispheres to the other; these

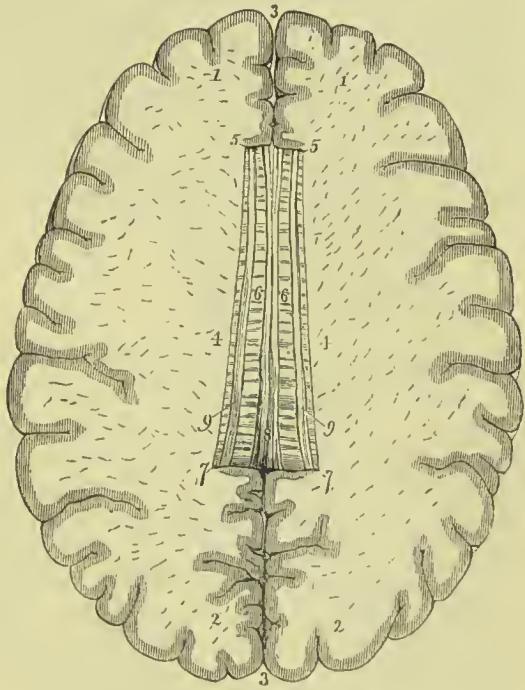


FIG. 303.—Section of the brain showing the centrum ovale majus and corpus callosum. 1, 1. Frontal lobes of the brain. 2, 2. Occipital lobes. 3, 3. Longitudinal fissure for the reception of the falx cerebri. 4, 4. Roof of the lateral ventricles. 5, 5. Genu of the corpus callosum. 6. Its body, upon which the *linæ transversæ* are seen. 7, 7. Splenium. 8. Raphé. 9, 9. Stria longitudinales laterales.

are the **lateral ventricles**. To expose them completely, their upper boundary should be removed with the scissors. In making this dissection the thin and diaphanous lining membrane of the ventricles may frequently be seen.

LATERAL VENTRICLES.—Each lateral ventricle is divided into a *central cavity* and three smaller cavities called *cornua*. The **anterior cornu** curves forwards and outwards in the anterior lobe; the **middle cornu** descends into the middle lobe; and the **posterior cornu** passes backwards in the posterior lobe, converging towards its fellow of the opposite side. The central cavity is triangular in form, being bounded above (*roof*) by the corpus callosum; internally by the septum lucidum, which separates it from the opposite ventricle; and below (*floor*) by the following parts, taken in their order of position from before backwards:—

Corpus striatum,	Choroid plexus,
Tenia semicircularis,	Corpus fimbriatum,
Thalamus opticus,	Fornix.

The **corpus striatum** is named from the striated lines of white and grey matter which are seen upon cutting into its substance. The portion of it which is seen in the lateral ventricle is the *intra-ventricular nucleus* or *nucleus caudatus*. Its anterior extremity forms a rounded projection in the anterior cornu; from whence it may be traced outwards and backwards, along the outer border of the optic thalamus, and separated from it by the stria terminalis. It becomes much narrower as we trace it backwards (the appearance thus produced giving rise to the name of nucleus caudatus), and its extremity will be found in the roof of the middle or descending horn. The other parts of the corpus striatum will be described when the structures seen in a transverse section of the brain are under consideration.

The **tænia semicircularis** or **stria terminalis** is a narrow whitish band, extending along the posterior border of the corpus striatum, and serving as a bond of connection between that body and the thalamus opticus. It joins the anterior pillar of the fornix and is continued with it to the corpora albicantia. The tenia is partly concealed by a large vein (*vena corporis striati*), which receives numerous small veins from the corpus striatum and thalamus opticus, and terminates in the vena Galeni of its own side.

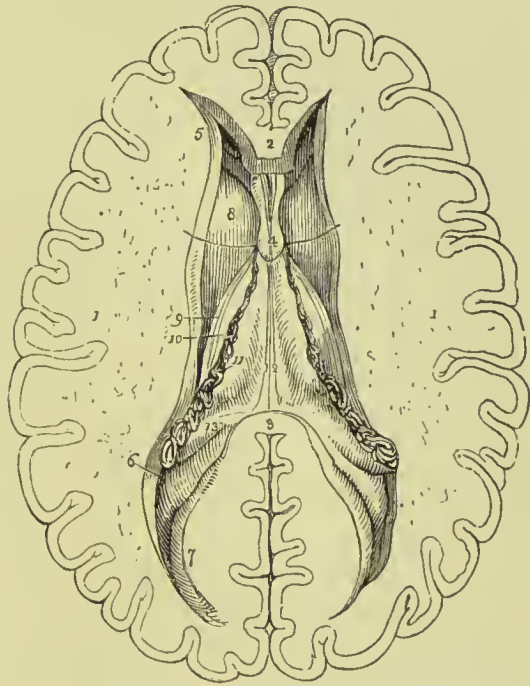The **thalamus opticus** (*thalamus*, a bed) is an oblong body, having a thin coating of white substance on its surface; and has received its name from having the optic tract lying against its under surface. It is the inferior ganglion of the cerebrum. Part only of the thalamus is seen in the floor of the lateral ventricle; we must, therefore, defer its further description until we can examine it in its entire extent.

The **choroid plexus** (*χόριον*, *εἶδος*, resembling the chorion) is a vascular fringe extending obliquely across the floor of the lateral ventricle, and sinking into the middle cornu. Anteriorly, it is

small and tapering, and communicates with the choroid plexus of the opposite ventricle, through a large oval opening, the *foramen of Monro*, or foramen commune anterius. This foramen may be seen by pulling slightly on the plexus, and pressing aside the septum lucidum with the handle of the knife. It is situated between the under surface of the fornix and the anterior extremities of the thalami optici, and forms a communication transversely between the lateral ventricles, and perpendicularly with the third ventricle.

The choroid plexus presents on its surface a number of minute vascular processes, which are termed *villi*. They are covered by an epithelium consisting of a single layer of nucleated polygonal

FIG. 304.—Lateral ventricles of the cerebrum. 1, 1. The two hemispheres cut down to a level with the corpus callosum so as to constitute the centrum ovale majus. 2. Genu of the corpus callosum. 3. Splenium; the intermediate portion forming the roof of the lateral ventricles has been removed. 4. Part of the septum lucidum, showing an interspace between its layers, the fifth ventricle. 5. Anterior cornu of one side. 6. Commencement of the middle cornu. 7. Posterior cornu. 8. Inter-ventricular nucleus of corpus striatum. 9. Tenia semicircularis. 10. Thalamus opticus. 11. Choroid plexus. This plexus communicates with that of the opposite ventricle through the foramen of Monro; a bristle is passed through this opening (under figure 4), and its extremities are seen resting on the corpus striatum at each side. The figure 11 rests on



the edge of the fornix, on that part of it which is called corpus fimbriatum. 12. Fornix. 13. Commencement of the hippocampus major. The rounded oblong body, directly behind figure 13, is the pes accessorius, and farther back, immediately under figure 7, the hippocampus minor.

cells, which are ciliated in the embryo, but the cilia are absent in the adult. Besides the nucleus the cells contain numerous yellow granules and one or two dark oil-drops; and, according to Henle, give off from their angles spine-like processes, which are connected with the bed of homogeneous areolar tissue on which they rest. The chief arteries of the choroid plexuses enter at the lower extremity of the middle horn of the lateral ventricle; others enter it from behind by passing beneath the splenium of the corpus callosum; the veins terminate in the veins of Galen.

The **corpus fimbriatum** is a narrow white band, situated internally to the choroid plexus, and extending with it into the descending cornu of the lateral ventricle. It is, in fact, the lateral thin

edge of the fornix, and being attached to the hippocampus major in the descending horn of the lateral ventricle, is also termed *tania hippocampi*.

The **fornix** is a white layer of medullary substance, of which a portion only is seen in this view of the ventricle.

The **anterior cornu** is triangular in form, sweeping outwards and terminating by a point in the anterior lobe of the brain, at a short distance from its surface. It has projecting into its cavity the nucleus caudatus of the corpus striatum.

The **posterior cornu** curves inwards, as it extends back into the posterior lobe of the brain and likewise terminates near the surface. An elevation corresponding with the calcarine fissure on the inner surface of the hemisphere, projects into the area of this cornu, and is called the *hippocampus minor* or *calcar avis*.

The **middle** or **descending cornu**, in descending into the middle lobe of the brain, forms a very considerable curve, and alters its direction several times as it proceeds. Hence it is described as passing backwards and outwards and downwards, and then turning forwards and inwards. This complex expression of a very simple curve has given origin to a symbol, formed of the primary letters of the term, by which the student is enabled to recollect more easily the course of the cornu, **BODFI**. It is the largest of the three cornua, and terminates close to the fissure of Sylvius, after having curved around the crus cerebri.

The middle cornu should now be laid open by inserting the little finger into its cavity, and making it serve as a director for the scalpel in cutting away the side of the hemisphere, so as to expose it completely.

The *superior boundary* of the middle cornu is formed by the fibres of the corpus callosum, as they arch downwards to reach the temporo-sphenoidal lobe; with these the tail of the nucleus caudatus and the fibres of the tania semicircularis are united. The *inferior wall* presents for examination the following parts:—

Hippocampus major,	Corpus fimbriatum,
Pes hippocampi,	Choroid plexus,
Pes accessorius,	Fascia dentata,
Transverse fissure.	

The **hippocampus major** or **cornu ammonis** is a considerable projection from the inferior wall, and extends the whole length of the middle cornu. Its extremity is likened to the foot of an animal, from its presenting a number of knuckle-like elevations on the surface, and is named *pes hippocampi*. The hippocampus major corresponds to the sulcus on the inner side of the gyrus fornicatus, as that convolution winds round beneath the splenium of the corpus callosum to end in the uncinatè gyrus. If the hippocampus be cut across, the section will be seen to resemble the extremity of a convoluted scroll, consisting of alternate layers of white and grey substance.

The **pes accessorius** (*eminentia collateralis*) is a swelling somewhat resembling the hippocampus major, but smaller in size, and situated in the angular interval between it and the hippocampus minor. It is formed by the protrusion of the sulcus described above as the *collateral fissure*.

The **corpus fimbriatum** (*tænia hippocampi*) is the thinned and flattened posterior pillar of the fornix, which is prolonged from the central cavity of the ventricle, and is attached along the inner border of the hippocampus major. It is lost inferiorly in the hippocampus.

Fascia Dentata.—If the corpus fimbriatum be carefully raised, a narrow serrated band of grey substance, the margin of the grey substance of the middle lobe, will be seen beneath it; this is the fascia dentata. It is so called from presenting an appearance resembling a regular row of teeth.

Transverse Fissure.—Beneath the corpus fimbriatum will be seen the *transverse fissure* of the brain, which extends from near the fissure of Sylvius on one side, across to the same point on the opposite side. It is through this fissure that the pia mater communicates with the *choroid plexus*, and the latter obtains its supply of blood. The fissure is bounded above by the corpus callosum and fornix in the middle, and on each side by a free margin of the hemisphere formed by the fascia dentata and corpus fimbriatum; inferiorly, it is bounded near the middle line by the corpus quadrigemina, and on each side by the back part of the optic thalamus. In its central part it lodges the *velum interpositum*.

Septum Lucidum.—The internal boundary of the lateral ventricle is the *septum lucidum*. This septum is thin, semi-transparent, and consists of two laminae of cerebral substance attached above to the under surface of the corpus callosum at its anterior part, and below to the fornix. Each of these laminae consists of white and grey matter, the white being situated on the surface looking towards the lateral ventricle, the grey matter nearer the middle line of the brain. Between the two layers is a narrow space, the **fifth ventricle**, which is lined by a proper membrane. The *fifth ventricle* may be shown by snipping through the septum lucidum transversely with the scissors.

The corpus callosum should now be cut across towards its anterior extremity, and the two ends carefully dissected away. The anterior portion will be retained only by the septum lucidum, but

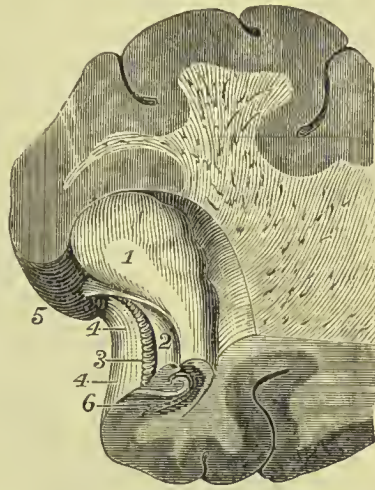

FIG. 305.—Section through the hippocampus major, showing fascia dentata. 1. Pes hippocampi. 2. Corpus fimbriatum. 3. Fascia dentata. 4, 4. Hippocampal gyri. 5. Uncinate gyrus. 6. Section through the hippocampus.

the posterior will be found incorporated with the white layer beneath, which is the fornix.

Fornix.—The fornix (arch) is an arched band of white substance, placed in the floor of the lateral ventricle, and intimately connected posteriorly with the under surface of the corpus callosum. It consists of two lateral halves which unite in the middle of the lateral ventricle forming the *body*, but diverge from each other posteriorly as the *posterior pillars* or *crura*, and anteriorly as the *anterior pillars* or *crura*. The two anterior crura descend in a curved direction to the base of the brain, embedded in the anterior part of the

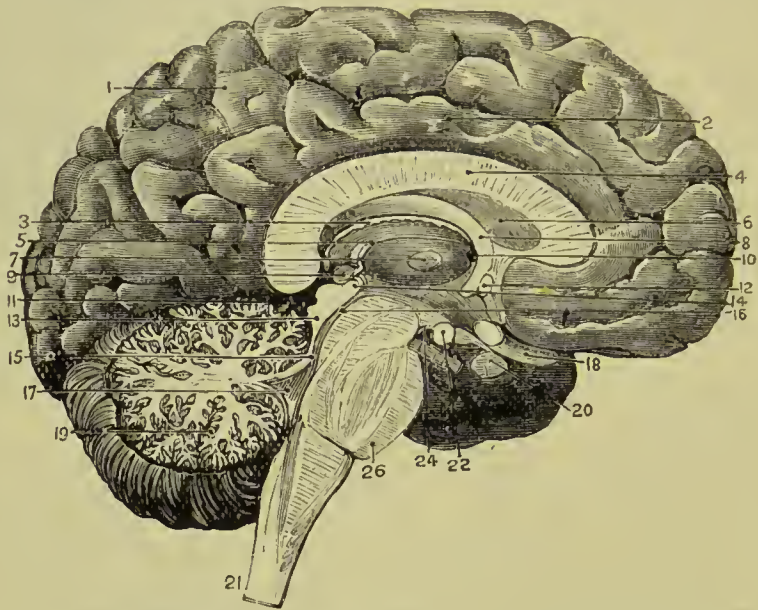

FIG. 306.—Vertical longitudinal section of the brain. 1. Marginal convolution. 2. Gyrus fornicatus. 3. Velum interpositum. 4. Corpus callosum. 5. Peduncle of pineal gland on the margin of optic thalamus. 6. Septum lucidum. 7. Middle commissure of third ventricle. 8. Fornix. 9. Pineal body. 10. Foramen of Monro. 11. Transverse fissure. 12. Anterior commissure. 13. Corpora quadrigemina. 14. Posterior commissure. 15. Valve of Vieussens. 16. Aqueduct of Sylvius. 17. Fourth ventricle. 18. Optic nerve. 19. Arbor vitæ cerebelli. 20. Pituitary body and infundibulum. 21. Section of medulla. 22. Corpus albicans. 24. Locus perforatus posticus. 26. Section of pons.

septum lucidum, and lying directly behind the anterior commissure. At the base of the brain they make a sudden curve upon themselves and constitute the *corpora albicantia*, from which they may be traced upwards to the thalami optici. Opening transversely beneath these two crura, just as they are about to arch downwards, is the foramen of communication between the lateral and the third ventricle, the *foramen of Monro*; or *foramen commune anterius*. The choroid plexuses and the veins of the corpora striata pass through this opening.

The lateral thin edges of the fornix are continuous *posteriorly* with the concave border of the hippocampus major at each side

and form the narrow white band called *corpus fimbriatum* or *tænia hippocampi*. In the middle line the fornix lies in contact by its upper surface with the corpus callosum, and by its under surface with the velum interpositum.

The fornix may now be removed by dividing it across anteriorly, and turning it backwards, at the same time separating its lateral connections with the hippocampi. On examining its under surface it will be noticed that where the posterior pillars diverge from each other they expose the fibres of the corpus callosum, and that these are for the most part transverse. The appearance presented by the lateral bars formed by the fornix and the transverse lines of the corpus callosum, has been named the *lyra* from a fancied resemblance to a harp.

Velum Interpositum.—Beneath the fornix is the *velum interpositum* (tela choroidea), a fold of pia mater introduced into the interior of the brain through the transverse fissure. It extends from the foramen of Monro in front to the back part of the splenium of the corpus callosum behind; laterally, it passes beneath the edge of the fornix and reaches the floor of the lateral ventricles, where it is connected with the choroid plexuses of those cavities. In this way it gives to the edge of the fornix that fringed appearance from which its name of *corpus fimbriatum* has been derived. On its under surface the velum forms the roof of the third ventricle, having attached to it the choroid plexuses of the latter cavity; and at the back part it is intimately connected with the pineal body. In the centre of its upper aspect run two veins, the veins of Galen, which receive blood from the interior of the ventricles, and empty it into the straight sinus. The velum interpositum is coated with an epithelium identical with that of the choroid plexuses; and around the pineal body the areolar tissue is abundant and strong.

If the velum interpositum be raised and turned back, an operation to be conducted with care, particularly at its posterior part, where it invests the pineal body, the thalami optici and the cavity of the third ventricle will be brought into view.

Thalami Optici.—The thalami optici are two oval bodies, of a white colour superficially, inserted between the two diverging portions of the corpora striata, and resting upon the upper surface of the crura cerebri. In the middle line a fissure exists between them which is called the *third ventricle*. The anterior part forms a rounded prominence immediately behind the *tænia semicircularis*, and is called the *anterior tubercle*; the posterior extremity forms a free rounded border, projecting into the transverse fissure of the brain, the *posterior tubercle* or *pulvinar*. Beneath the latter lie two small rounded elevations, the *external* and *internal geniculate bodies*, separated from each other by one of the roots of the optic nerve. The *corpus geniculatum externum*, the larger of the two, and of a greyish colour, is the principal origin of the optic nerve. The upper surface of the optic thalamus is marked by a shallow groove, which distinguishes the limit of the floor of the lateral ventricle; and

at the junction of the internal and upper surfaces a band of white fibres will be noticed constituting the *peduncle of the pineal body*. Between the upper edge of the pulvinar and the peduncle of the pineal body is a triangular depression called *trigonum habenulae*. Anteriorly, the thalami are connected with the corpora albicantia by means of two white bands, which are the terminations of the crura of the fornix. Externally, they are in relation with the corpora striata and hemispheres. In their interior the thalami are chiefly composed of grey matter arranged in three masses, the *anterior, external, and internal nuclei*.

Third Ventricle.—The third ventricle is the fissure between the two thalami optici, and is the remains of the anterior cerebral vesicle. It is bounded above by the under surface of the velum interpositum, from which are suspended the choroid plexuses of the third ventricle, and is separated by the velum from the body of the fornix. Its *floor* is formed by the lamina cinerea, the tuber cinereum, infundibulum, corpora albicantia, and locus perforatus posticus. *Laterally*, it is bounded by the thalami optici and peduncles of the pineal body; *anteriorly*, by the anterior commissure and anterior crura of the fornix; and *posteriorly*, by the posterior commissure and the aqueduct of Sylvius. The third ventricle is crossed by three commissures, anterior, middle, and posterior; and communicates by two openings, called foramen of Monro and aqueduct of Sylvius, with the lateral and fourth ventricles.

The **anterior commissure** is a small rounded white cord, which connects the corpora striata of the two sides, and reaches the substance of the hemispheres; it lies immediately in front of the crura of the fornix, and is united by its anterior margin with the septum lucidum. The **middle** or **soft commissure** consists of grey substance, which is continuous with the grey lining of the ventricle; it connects the adjacent sides of the thalami optici. The **posterior commissure**, smaller than the anterior, is a flattened white cord, connecting the two thalami optici posteriorly; it is placed beneath the peduncles of the pineal body near their origin, and has beneath it the aqueduct of Sylvius.

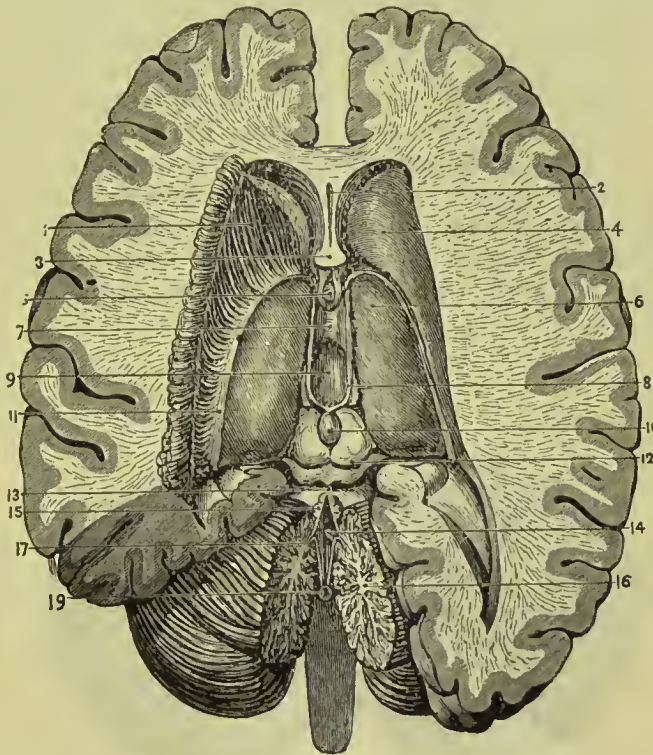
The **foramen of Monro** is the medium of communication between the two lateral and third ventricles, and transmits superiorly the choroid plexus and veins of the corpus striatum.

The **aqueduct of Sylvius**, or *iter a tertio ad quartum ventriculum*, leads backwards beneath the posterior commissure and through the base of the corpora quadrigemina to the upper part of the fourth ventricle.

Corpora Quadrigemina.—The corpora quadrigemina, or optic lobes, are situated immediately behind the third ventricle and posterior commissure, and beneath the posterior border of the corpus callosum. They form, indeed, at this point, the inferior boundary of the transverse fissure of the hemispheres. The anterior pair of these bodies, grey in colour, are named *nates*; the posterior pair, white and much smaller than the anterior, are termed *testes*. From

the nates on each side may be traced a rounded process (brachium superior) which passes obliquely outwards into the thalamus opticus; and from the testis a similar but smaller process (brachium inferior) which has the same destination. The internal geniculate body lies in the interval of these two processes where they enter the thalamus, and behind the inferior brachium is a prominent band which marks the course of the superior division of the olivary fasciculus. The corpora quadrigemina are perforated longitudinally through their base by the aqueduct of Sylvius; they are covered in partly by the pia mater and partly by the velum interpositum, and the nates support the pineal body. Two large white bands pass

FIG. 307.—Third ventricle of brain. 1. Corpus striatum dissected. 2. Fifth ventricle. 3. Anterior crura of fornix (cut). 4. Corpus striatum. 5. Anterior commissure of third ventricle. 6. Optic thalamus. 7. Middle or soft commissure. 8. Peduncles of pineal body. 9. Third ventricle. 10. Pineal body. 11. Tania semicircularis. 12. Corpora quadrigemina. 13. Valve of Vicussens. 14. Fourth ventricle. 15. Anterior extremity of superior vermiform process. 16. Arbor vite cerebelli. 17. Anterior extremity of inferior vermiform process (nodulus). 19. Communication of fourth ventricle with sub-arachnoid space.



down from them to the cerebellum, forming the *processus e cerebello ad testes*, the great bond of connection between the great and little brain.

Pineal Body.—The pineal body (epiphysis cerebri) is a small reddish-grey body of a conical form (hence its synonym *conarium*), situated on the anterior part of the nates, and invested by a duplication of pia mater derived from the under part of the velum interpositum. It is connected to the brain by means of two cords of white matter called *peduncles*, which may be traced along the upper and inner margin of the thalami optici to the crura of the fornix with which they become blended. From the close connection subsisting between the pia mater and the pineal body, and the softness of texture of the latter, it is liable to be torn away in the removal of the pia mater.

CEREBELLUM.

The cerebellum, less than one-eighth the weight of the cerebrum, is situated beneath the occipital lobes, being lodged in the posterior fossa of the base of the cranium, and protected from the superincumbent pressure of the cerebrum by the tentorium cerebelli. Like the cerebrum, it is composed of grey and white substance, the former occupying the surface, the latter the interior, and its surface is formed of parallel lamellæ separated by sulci, and here and there by deeper sulci. In form, the cerebellum is oblong and flattened, its greater diameter being from side to side, its two surfaces looking upwards and downwards, and its borders being anterior, posterior, and lateral. In consideration of its shape the cerebellum admits of a division into two hemispheres, into certain prominences termed processes and lobules, and into certain divisions of its substance called lobes, formed upon the hemispheres by the deeper sulci above referred to. On the anterior border of the organ there is a semilunar notch, *ineisura cerebelli anterior*, which embraces the corpora quadrigemina. On the posterior border there is another notch, *ineisura cerebelli posterior*, which receives the upper part of the falx cerebelli; and on the under surface of the cerebellum is a deep fissure corre-

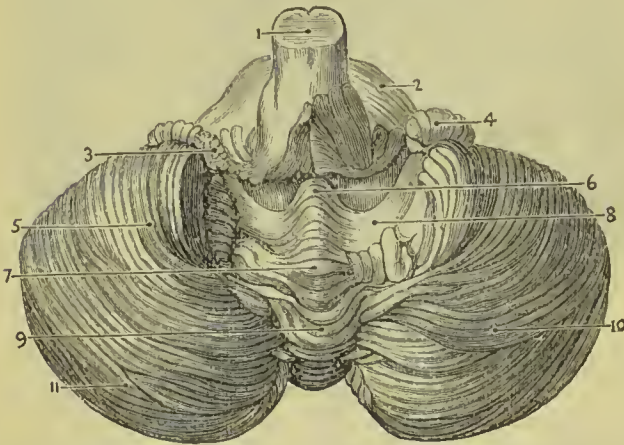


FIG. 308.—Under surface of cerebellum, the amygdalæ having been removed. 1. Medulla oblongata. 2. Pons Varoli. 3. Choroid plexus of the fourth ventricle. 4. Flocculus. 5. Biventral lobe of cerebellum. 6. Nodulus of inferior vermiform process. 7. Uvula. 8. Posterior medullary velum. 9. Pyramid. 10. Slender lobe. 11. Posterior inferior lobe.

sponding with the medulla oblongata, and termed the *vallecula* (valley). Each hemisphere of the cerebellum is divided by means of a fissure which runs along its free border into an upper and a lower portion, and upon each of these portions certain lobes are marked out. Thus on the upper portion there are two such lobes, the *anterior superior* or *quadrate lobe*, and the *posterior superior lobe*. On the under portion of the hemisphere there are three such lobes, namely, the *posterior inferior lobe*, the *slender* (*gracilis*) *lobe*, and the *biventral lobe*; and two smaller ones, the *tonsil* (*amygdala*), situated at the side of the vallecula, and the *flocculus* (*pneumogastric lobe*), placed behind and below the middle peduncle of the cerebellum.

The central mass connecting the two hemispheres is called the *worm* (*vermis*); its upper aspect projects above the general level of

the cerebellum, and is called the superior vermiform process; the lower part is lodged within the vallecule, and is named the inferior vermiform process. The *superior vermiform process* is very indistinctly demarcated from the upper surface of the hemispheres, the folia of the latter being continued into it; at its anterior border, about eight folia form the *central lobe*, a portion of which is continued upwards on to the superior medullary velum or valve of Vieussens, and is termed, from its shape, the *lingula*. The posterior superior lobe is only represented in the superior vermiform process by a single well-marked lamina, the *folia cacuminis*. The *inferior vermiform process* is divisible into four lobes, namely: (1) the *tuber valle* situated in the incisura posterior, and connecting the postero-inferior and slender lobes of the two sides; (2) in front of this the *pyramid*, a small, obtusely pointed eminence connecting the biventral lobes; (3) the *uvula*, placed between the two tonsils; and (4) the *nodule* or *laminated tubercle*, forming a free pointed anterior termination to the process. Connecting the uvula on each side with the tonsil is a ridge of grey matter, the *furrowed band*. On each side of the nodule is a thin layer of white matter, the *posterior medullary velum*; it has a membranous texture, and terminates anteriorly in a crescentic border; laterally, each process can be traced into the flocculus. Between the posterior velum and the nodule and uvula is a deep fossa which is known as the *swallow's nest* (*nidus hirundinis*). The *anterior medullary velum* is the valve of Vieussens, which will be described in connection with the fourth ventricle.

The cerebellum is connected with the rest of the encephalon by means of three pairs of rounded cords or peduncles, superior, middle, and inferior. The *superior peduncle* (*processus cerebelli ad testes*) forms the superior lateral boundary of the fourth ventricle, and is continued upwards and forwards upon the upper surface of the crus cerebri to the corpora quadrigemina, beneath which its fibres decussate with those of the corresponding process of the opposite side; higher up they may be traced into the white centre of the hemisphere. The *middle peduncle* (*processus ad pontem*) connects the two hemispheres of the cerebellum, and is constituted by the transverse fibres of the pons. The *inferior peduncle* (*processus ad medullam*) is the connection of the cerebellum with the medulla and spinal cord, and has been already described under the title of *restiform body* or *tract*. The three peduncles together form the **crus cerebelli** of each side.

Structure of the Cerebellum.—A horizontal section of the cerebellum shows it to be composed, like the cerebrum, of an internal white mass, and of grey cortical matter; but the grey matter greatly preponderates, so that the white centre is relatively small. The white substance resembles the trunk of a tree, from which branches are given off, and from the branches, branchlets and leaves the two latter being coated by a moderately thick and uniform layer of grey substance. The appearance thus produced has received the name of *arbor vitæ cerebellæ*. In each lateral half of the white

centre will be seen an irregular mass of grey matter, forming a wavy line, and enclosing white matter; this is the *corpus dentatum*. It exists as a grey capsule or pouch, which, however, is defective at

its inner part. If the section be made rather nearer to the under surface of the cerebellum than its centre, other nuclei will be displayed in the white centre. These are three in number on each side, and are named the nucleus fastigii, nucleus globosus, and nucleus emboliformis (Fig. 309). The *nucleus fastigii* is situated near the middle line; it is rounded in front, but behind becomes forked. The *nuclei globosi* generally consists of two or three round grey spots a little external to the preceding. The *nucleus emboliformis* is a club-shaped mass of grey matter running antero-posteriorly close to the inner side of the corpus dentatum.

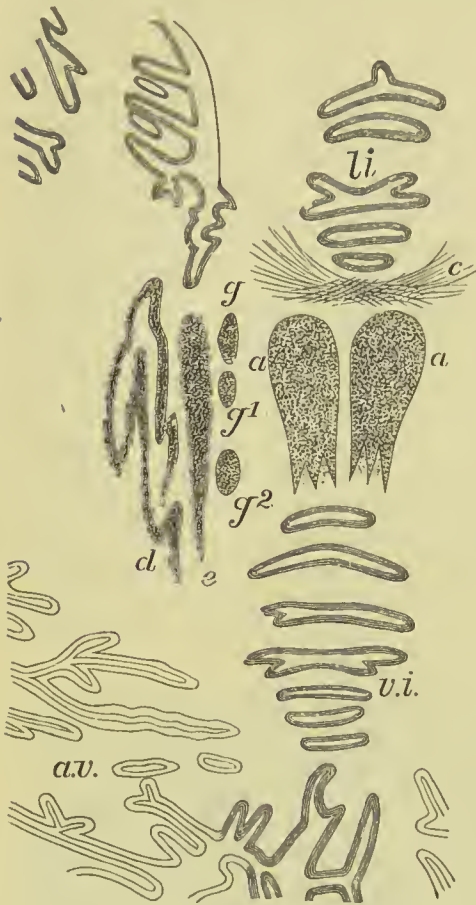

FIG. 309.—Part of the white centre of the cerebellum, showing the nuclear masses. *li.* Lingula. *c.* Commissural fibres. *a.* Nucleus fastigii. *g, g¹, and g².* Nuclei globosi. *e.* Nucleus emboliformis. *d.* Corpus dentatum. *v.i.* Inferior vermiciform process. *a.v.* Arbor vitæ cerebelli.

Minute Structure.—The *grey cortex* is divisible into two layers, the outer being of a clear grey colour, and the inner rust-coloured and granular in appearance. The external layer consists of a delicate neuroglia supporting nerve-fibres and nerve-cells; the fibres run for the most part at right angles to the surface of the cerebellum, and many of them

are connected with the processes of the cells below; the cells are very small, and have the appearance of granules. The inner layer is formed also of granule-like cells very closely aggregated, and embedded in a gelatinous matrix. Between the inner and outer layers is a single layer of peculiar cells called *cells of Purkinje*; they are chiefly flask-shaped, and give off from their deep aspect a single process which becomes connected with the axis-cylinder of a nerve in the white centre; from its superficial surface each cell gives off two processes which branch very freely in an antler-like manner, some of their finer processes becoming connected with the round cells of the outer layer. The

white centre is composed of medullated nerve-fibres, some of which are (1) commissural between the two hemispheres of the cerebellum, others (2) are association fibres between different folia, and (3) other fibres spring from the central nuclei above described.

Fourth Ventricle.

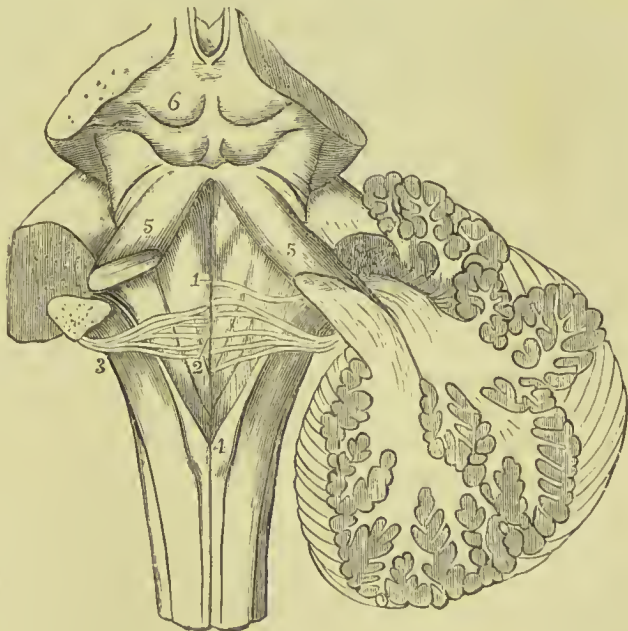
Dissection.—An oblique incision must be made through each half of the cerebellum, and the wedge-shaped intervening mass removed; the membranes covering the back part of the medulla and pons must be carefully cleared away, when the fourth ventricle will be displayed.

The fourth ventricle is the remains of the posterior cerebral vesicle of the embryo, and is situated between the cerebellum and the posterior surface of the medulla and pons; it is diamond-shaped, with narrow angles directed upwards and downwards, and wider angles passing towards each crus cerebelli (*lateral recesses*). The lower angle is called the *calamus scriptorius*, from a fancied resemblance to



FIG. 310.—1a. External and, 1b, Internal portions of the outer grey layer. 2. Layer of cells of Purkinje. 3. Inner layer. m. Medullary layer.

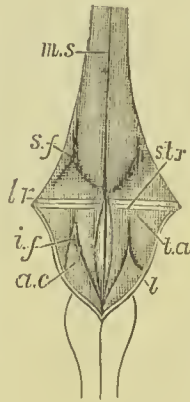
FIG. 311.—1. Median groove of the fourth ventricle, with the fasciculi teretes, one on each side. 2. The striæ acusticæ and origin of the auditory nerve. 3. The restiform body. 4. The posterior pyramid; the figure is placed on the right *clava*. 5. The processus cerebelli ad testes. 6. The corpora quadrigemina.



the nib of a pen; it is marked by a slight pit, the *ventricle of Aranzi*, which communicates with the central canal of the spinal

cord. The *upper angle* has opening into it the aqueduct of Sylvius, by which the fourth ventricle communicates with the third. The *roof* is tent-shaped, and is formed by a thin layer of grey matter connecting the upper part of the two *processus cerebelli ad testes*, called the *valve of Vieussens* (*velum medullare anterius*), by the anterior medullary velum, the nodule of the inferior vermiciform process, and the pia mater passing from the latter to the medulla. A thickening of the epithelium on the under surface of the pia mater at the lower angle of the cavity gives rise to a process called the *obex*, and a similar thickening running along the side wall from the obex to the lateral recess is called the *ligula* (Fig. 312, *l.*). The *floor* has running down its centre a slight groove continuous with

FIG. 312. — Diagrammatic view of the floor of the fourth ventricle. *m.s.* Mesial sulcus. *s.f.* Superior fovea. *l.r.* Lateral recess. *str.* Striæ acusticæ. *i.f.* Inferior fovea. *t.a.* Tuberculum acusticum. *a.c.* Ala cinerea. *l.* Ligula. (*E. A. Schäfer.*)



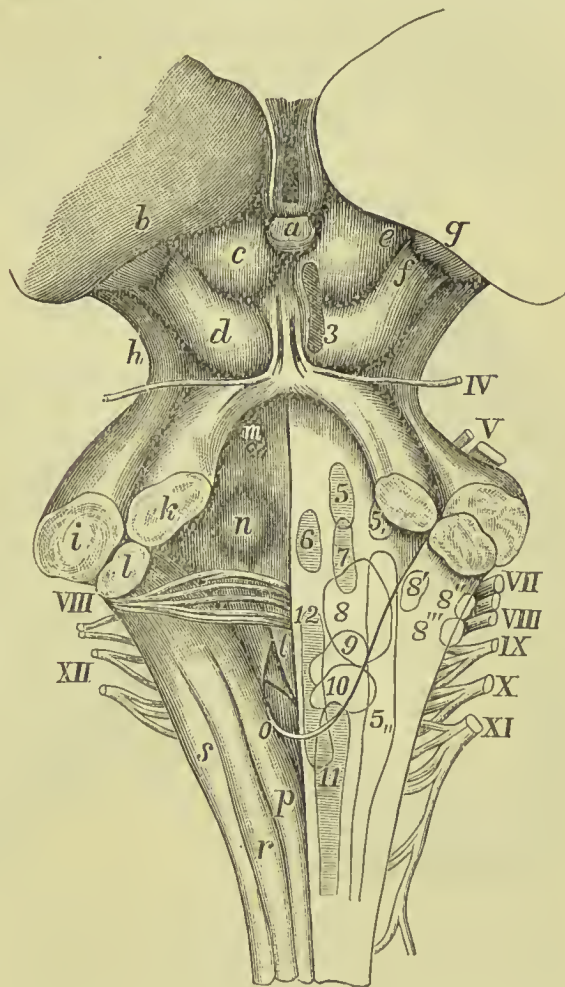
the posterior median fissure of the cord, and, crossing its middle, some transverse lines, the *striæ acusticæ*. These lines mark the superior limit of the medulla; they also serve to divide the floor of the ventricle into two triangles, the upper belonging to the medulla, and the lower to the pons. These are again divided vertically by the median fissure, and each of the four divisions so formed is marked by a triangular depression or *fovea*. The division formed by the medulla may be defined as consisting of (1) the depression of the *inferior fovea*; (2) a ridge between it and the median fissure, the *fasciculus teres*; (3) a prominence between the fovea and the lateral wall, the *tuberculum acusticum*; and (4) a grey mass between the fovea and the inferior angle, the *ala cinerea*. In like manner the area belonging to the pons consists of: (1) the *superior fovea*, (2) the upper part of the *fasciculus teres*, and (3) a pigmented area between the superior fovea and the lateral wall, the *locus ceruleus*. The *lateral boundaries* of the ventricle are: in the *upper part*, the two *processus cerebelli ad testes*; in the *lower*, the *funiculi graciles* with their *clavæ*; above these the *funiculi cuneati*, and still higher up the *restiform bodies*.

The roof of the fourth ventricle has been already described as partly formed by pia mater covered by epithelium. In the part so formed there is a small opening, the *foramen of Magendie*, placed a little above the *calamus scriptorius*, by means of which the cavity of the ventricle communicates with the posterior sub-arachnoid space; other openings also exist in each lateral recess.

In the floor of the fourth ventricle are placed the nuclei of origin of the chief cranial nerves, as well as the vaso-motor, cardiac, and respiratory centres. The nucleus of the hypoglossal nerve lies beneath the *fasciculus teres*. In the lower part of the *ala cinerea* is situated the nucleus of the spinal accessory nerve; in its upper part the nuclei of the vagus and glosso-pharyngeal nerves, the latter being

placed above the former. Close to the lateral recesses in the upper portion of the floor are the sensory (outer) and motor (inner) nuclei of the fifth nerve; higher up and nearer the middle line is the nucleus of the sixth nerve; deeper down, between the fifth and sixth is the centre for the seventh nerve. The nuclei of the

FIG. 313.—Floor of fourth ventricle, showing nuclei of origin of cranial nerves. *a.* Pineal body. *b.* Pulvinar of optic thalamus. *c.* Anterior corpus quadrigeminus (nates). *d.* Posterior corpus quadrigeminus (testes). *e.* Anterior brachium. *f.* Posterior brachium. *g.* Internal geniculate body. *h.* Crus cerebri. *i.* Middle peduncle of crus cerebelli. *k.* Superior peduncle (processus e cerebello ad testes). *l.* Inferior peduncle (restiform). *m.* Locus ceruleus. *n.* Eminentia teres. *o.* Obex. *p.* Funiculus gracilis. *r.* Funiculus cuneatus. *s.* Funiculus of Rolando. *t.* Fasciculus teres. The nuclei of the cranial nerves are indicated by italic figures, the nerve trunks by Roman numerals.



eighth or auditory nerve are covered by the tuberculum acusticum and transverse striæ. The position of these nuclei will be best understood by reference to Fig. 313.

Transverse Section of the Cerebrum.

Transverse vertical sections of the cerebrum at different levels are useful for the purpose of ascertaining the relative position of the structures in the interior, and more especially for determining the relation which the two great basal ganglia, the thalamus opticus and corpus striatum, bear to each other and to surrounding parts. The figure here given (Fig. 314) is taken from a recent section of the

brain, which has been made immediately behind the corpora albicantia; it passes through the lateral and third ventricles, the middle horn of the lateral ventricles, island of Reil, thalamus opticus, fornix, and corpus striatum. The latter is now seen to be a composite body made up of several independent nuclei; its full description is as follows.

The **corpora striata** are two pyriform bodies placed with their broad ends forwards and their narrow ends backwards. They are throughout the greater part of their extent embedded in the sub-

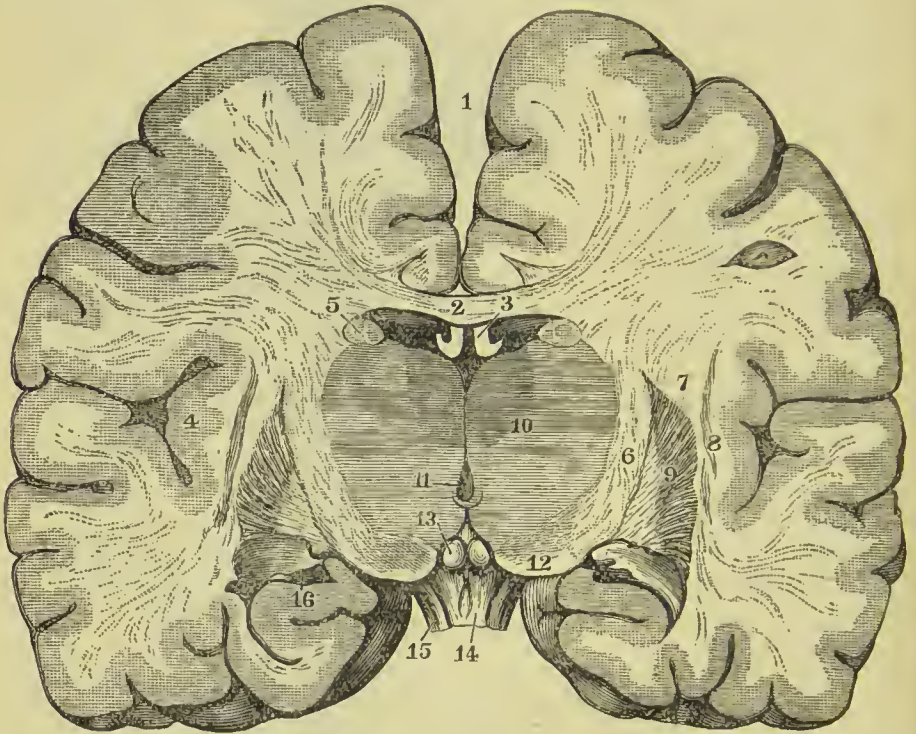


FIG. 314.—Transverse vertical section of the cerebrum made immediately behind the corpora albicantia. 1. Longitudinal fissure. 2. Corpus callosum. 3. Fornix. 4. Island of Reil. 5. Nucleus caudatus. 6. Internal capsule. 7. External capsule. 8. Tenuiform nucleus or claustrum. 9. Lenticular nucleus. 5, 6, 7, 8, and 9 together constitute the corpus striatum. 10. Thalamus opticus. 11. Third ventricle. 12. Crus cerebri. 13. Corpora albicantia. 14. Tuber cinereum and commencement of infundibulum. 15. Optic tract. 16. Extremity of middle horn of lateral ventricle.

stance of the hemispheres, but their anterior extremities come to the surface in the body and anterior horn of the lateral ventricles; they are thus divisible into an *intraventricular* and an *extraventricular* portion. The intraventricular portion is named *nucleus caudatus*; its large end, or head, is directed forwards and projects into the anterior cornu of the lateral ventricle; its smaller end or tail runs on the outer side of the thalamus, and narrowing as it proceeds backwards, terminates by a pointed end in the roof of the descending horn. The extraventricular portion lies to the outer side of the optic thalamus, and between it and the island of Reil;

it is chiefly formed by a large nucleus, which on horizontal section presents the appearance of a biconvex lens ; hence it has been named the *lenticular nucleus*. In a transverse vertical section this nucleus appears triangular, with the base directed outwards and the apex inwards ; the grey matter which forms its bulk is streaked by numerous white fibres which radiate as they pass through it into the convolutions. On the inner side the lenticular nucleus is separated from the nucleus caudatus and thalamus opticus by a strand of white matter called the *internal capsule*, and on the outer side a similar but less-marked band called *external capsule* lies between it and the island of Reil ; a grey streak in the middle of the latter has been named the *teniaform nucleus* or *claustrum*.

Transverse Section of the Crura Cerebri.

The **crura cerebri** or **cerebral peduncles** are two rounded white masses which proceed from the upper margin of the pons, and, diverging from each other, enter the under aspect of the hemispheres in the region of the basal ganglia. In front of the diverging crura is the posterior perforated space and corpora albicantia, while the third nerve issues from the inner side of each crus, and the fourth nerve from the outer side ; on their upper aspect they are inseparable from the corpora quadrigemina. A transverse section (Fig. 315) shows the crura to be divisible into two parts, an upper, called the *tegmentum*, and a lower, the *crusta* ; separated by a transverse band of pigmented grey matter, the *locus niger*. The **tegmentum** is traversed in

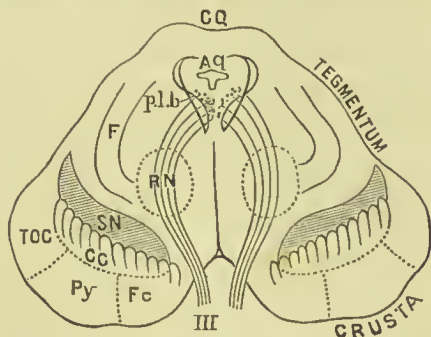


FIG. 315.—Transverse section of crura cerebri. CQ. Corpora quadrigemina. Aq. Aqueduct of Sylvius. p.l.b. Posterior longitudinal bundle. F. Olivary fillet. RN. Red nucleus. SN. Substantia nigra. TOC. Fibres passing between cerebellum and temporal sphenoid convolutions. Py. Pyramidal tract. Fc. Fibres passing to frontal convolutions from cerebellum. III. Origin of the third nerve.

the middle line near its upper part by the aqueduct of Sylvius, which in cross-section is triangular or T-shaped ; and beneath the floor of this canal is a small grey nucleus on each side which gives origin to the third nerves. Beneath the nucleus of the third, a bundle of longitudinal nerve fibres is seen, constituting the *posterior longitudinal bundle* (p.l.b.), and about the middle of the peduncle there is a spheroidal mass of nuclear matter, named from its colour the *red nucleus* ; it is traversed by the fibres of the third nerve. The bulk of the tegmentum is formed by a continuation upwards of the formatio reticularis of the pons, which is in its turn continued into a reticular layer beneath the thalamus. Towards the outer side, however, is a band of white fibres called the *fillet* ; it lies

immediately above the locus niger, and reaching the surface of the tegmentum, forms a white band round its outer surface, below the corpora quadrigemina. The **crusta** is composed entirely of longitudinal nerve bundles communicating between the cerebrum and medulla, and the cerebrum and cerebellum. The middle band is the largest, and consists of the fibres of the pyramidal tract; the band on the outer side contains fibres passing to the temporo-occipital convolutions; and that on the inner side, fibres connecting the frontal lobes and cerebellum. The two crusta are completely separate; the tegmenta are united, but their line of fusion is marked by an incomplete septum. The **locus niger** (*substantia nigra*) is composed of deeply pigmented nerve-cells with many branching processes; nothing is known of the connections or uses of this large mass of grey matter.

Lining Membrane of the Ventricles.

The lining membrane of the ventricles, *ependyma ventriculorum*, is a serous layer distinct from the arachnoid; it lines the whole of the interior of the lateral ventricles, and is connected with the attached border of the choroid plexus, so as to exclude direct communication between the lateral ventricles and the exterior of the brain. From the lateral ventricles it is reflected through the foramen of Monro on each side into the third ventricle, which it invests throughout. From the third it is conducted into the fourth ventricle, through the iter a tertio ad quartum ventriculum, and after lining its interior becomes continuous inferiorly with the sub-arachnoid tissue of the spinal cord. The lining membrane of the ventricles is provided with an epithelium which is ciliated in patches and is the source of the secretion which moistens and lubricates their interior. The fifth ventricle has a separate lining membrane.

The epithelium of the *ependyma ventriculorum* is supported by a delicate layer of modified connective tissue, similar to that described in the spinal cord under the name of neuroglia.

White Matter of the Cerebrum.

The white matter of the cerebrum consists of medullated nerve-fibres, varying in size in different parts, but generally smaller than those of the spinal cord and medulla. They may be conveniently arranged into three sets, viz., (1) *ascending* or *peduncular*, (2) *transverse* or *commissural*, and (3) *longitudinal* or *collateral*.

The **peduncular fibres** may again be divided into (a) *those ascending in the crusta of the crura*, and (b) *those reaching the cerebrum through the tegmentum*. The fibres derived from the **crusta** pass chiefly in the inner capsule of the corpus striatum, and from thence into the white centre of the hemispheres, where they spread out in a fan-like arrangement, forming the *corona radiata*, and ultimately reach the

grey cortex of the convolutions. The most definite band of these fibres is continued upwards from the pyramidal tract of the medulla, and passes to the convolutions bordering on the fissure of Rolando (*motor area of the cortex*). Another set of these fibres passes from the lateral part of the crusta to the occipital lobe of the cerebrum (*direct sensory tract*). The innermost fibres of the crusta may be traced beneath the thalamus to terminate in the under part of the lenticular nucleus (*ansa lenticularis*). The **fibres of the tegmentum** consist of the bundles traversing the *formatio reticularis*; they are joined by those passing from the cerebellum in the *processus e cerebello ad testes*, and probably some strands from the *corpora quadrigemina* and other nuclei. Passing beneath the thalamus they enter that nuclear mass, but some run on the outer side thereof, to join the *corona radiata*, and pass from thence to the cortex of the temporo-sphenoidal and occipital lobes.

The **transverse** or **commissural fibres** include (1) the anterior commissure of the third ventricle, (2) the posterior commissure, and (3) the transverse fibres of the *corpus callosum*.

The **longitudinal** or **collateral fibres** include the following: viz., (1) the *forix*, (2) *tænia semicircularis*, (3) *striæ longitudinales* of the *corpus callosum*, (4) fibres of the *gyrus fornicatus* (*superior longitudinal commissure*), (5) a white bundle of fibres at the bottom of the fissure of Sylvius, connecting the frontal with the temporo-sphenoidal lobe and called the *uncinate fasciculus*, (6) a bundle of fibres lying in the outer wall of the posterior and middle horns of the lateral ventricles, connecting the occipital and temporo-sphenoidal lobes, and named the *inferior longitudinal fasciculus*, and (7) *association fibres* passing between the several convolutions, and between different parts of the same convolution (A. Campbell Clark).

The connection of the fibres in the cerebrum with those in the medulla and spinal cord will be best understood from the table given on page 526, and derived chiefly from J. Rylands Whitaker.

Arteries of the Brain.

The arteries of the brain present certain peculiarities which render it necessary that they should be studied apart from the general arterial system, and along with the organ to which they are distributed. The important anastomotic connection at the base of the brain called the *circle of Willis* has been described on a previous page (402), and it is only necessary here to recall the fact that from that circle three main trunks, called *anterior*, *middle*, and *posterior cerebral* arteries, are given off on each side to the anterior, middle, and posterior regions of the brain. The branches derived from these trunks are of two kinds: *medullary*, which pass to the basal ganglia and neighbouring parts; and *cortical*, which are distributed to the convolutions of the five lobes into which the cerebrum is divided. These two systems of arteries are almost entirely independent of each other, what communications exist between them being very few

TABLE SHOWING THE COURSE OF THE FIBRES IN THE SPINAL CORD, MEDULLA, CRUS
CEREBRI AND CEREBRUM.

	CORD.	MEDULLA.	CRUS.	CEREBRUM.			
Anterior Column.	{ 1. Direct pyramidal tract. { 2. Anterior root zone.	{ Outer part of anterior pyramid of the same side. { Posterior longitudinal bundle. { Olivary peduncle and fillet. { Formatio reticularis.	{ Lower part of crusta. { Tegmentum.	{ Through internal capsule to corona radiata, thence to convolutions bordering on fissure of Rolando. { Corpora quadrigemina. { Optic thalamus.			
Lateral Column.	{ 1. Crossed pyramidal tract. { 2. Direct lateral cerebellar tract. { 3. Mixed zone.	{ Inner part of anterior pyramid of opposite side. { Restiform body. { Olivary fillet. { Formatio reticularis. { Fasciculus teres.	{ Lower part of crusta. { Tegmentum.	{ Internal capsule. { Corona radiata. { Motor convolutions. { Cerebellum. { Corpora quadrigemina. { Optic thalamus. { Sensory convolutions.			
Posterior Column.	{ 1. Postero-internal. { 2. Postero-external.	{ Funiculus gracilis. { Funiculus cuneatus. { Formatio reticularis.	{ Tegmentum. { Tegmentum.	{ Probably the thalamus and corpora quadrigemina. { Probably the lenticular nucleus and inner capsule.			

in number, and of capillary minuteness; the individual branches also of each system are distributed to independent areas, and only communicate with their fellows at the margins of those areas, by few and small communications; hence they are distinguished as *end arteries*. As a necessary result of this arrangement, one artery cannot take the place or perform the work of another, as we so often find to be the case in other parts of the body, but if an artery becomes plugged, the area to which it is distributed becomes deprived of nourishment and rapidly undergoes degeneration. The following is a brief description of the chief branches of the three arteries mentioned above.

Anterior Cerebral.—The *medullary* branches of this trunk are few in number; they are given off close to its origin from the internal carotid, pass through the anterior part of the substantia perforata, and are distributed to the front of the corpus striatum, and genu of the corpus callosum. The *cortical* branches are four in number. The first of these is distributed to the internal orbital convolutions; the second to the anterior part of the marginal convolution, the anterior part of the middle frontal convolution, and the superior frontal convolution; the third to the inner surface of the hemisphere as far back as the ascending portion of the callosomarginal fissure. The fourth supplies the quadrate lobe, and gives off a branch which enters the corpus callosum and supplies its structure.

Middle Cerebral.—This is the largest artery of the three, and from its position is frequently named the **Sylvian artery**; it is distributed chiefly to the motor convolutions of the brain. The *medullary* branches are numerous; they enter the openings in the substantia perforata, and passing directly upwards are distributed to the extraventricular nuclei of the corpus striatum, and the back part of the nucleus caudatus. The main trunk of the middle cerebral passes upwards in the fissure of Sylvius, and as it lies against the island of Reil divides into four *cortical* branches. The first of these is distributed to the outer part of the orbital surface and inferior frontal convolution; the second to the posterior part of the middle frontal and three-fourths of the ascending frontal convolution; the third to the rest of the ascending frontal, ascending parietal, and anterior part of the superior parietal, and the fourth to the inferior parietal (supra-marginal) and superior temporo-sphenoidal convolution.

Posterior Cerebral.—Most of the *medullary* branches of this artery enter the locus perforatus posticus, but a few are given off on the outer side of the crus cerebri; both sets are distributed to the thalamus opticus, crus cerebri, and corpora quadrigemina. The *cortical* branches are three in number; the first passes to the anterior part of the uncinat gyrus, the second to the back part of the same convolution and the lower part of the temporo-sphenoidal lobe, and the third to the occipital lobe. The convolutions to which this artery is distributed are for the most part sensory in function.

Relations of the Chief Sulci and Convolutions to the Exterior of the Skull.

The relations of the sulci and convolutions of the cerebrum to the exterior of the skull are of great importance, in consequence of the increasing frequency with which operations are now performed for the removal of tumours and other morbid products from the con-

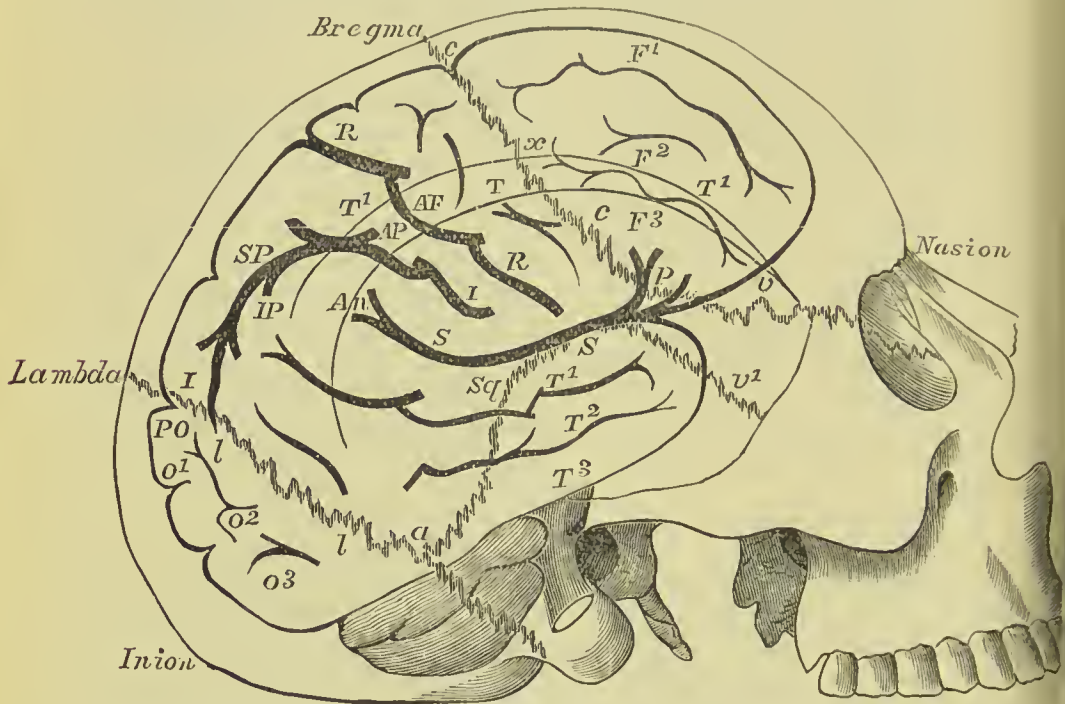


FIG. 316.—Relations of the brain to the exterior of the skull. *c.c.* Coronal suture. *Sq.* Squamous suture. *v.* Back part of transverse suture. *v1.* Squamo-sphenoidal suture. *l.l.* Lambdoidal suture. *T.* Inferior temporal ridge. *T1.* Superior temporal ridge. *x.* Stephanion. *p.* Pterion. *a.* Asterion. *F1, F2, and F3.* First, second, and third frontal convolutions. *A.F.* Ascending frontal convolution. *R.* Fissure of Rolando. *A.P.* Ascending parietal convolution. *S.* Fissure of Sylvius; at *p.* its ascending portion is seen. *I.I.* Inter-parietal fissure. *S.P.* Superior parietal gyrus. *I.P.* Inferior parietal gyrus. *An.* Angular gyrus. *P.O.* Parieto-occipital fissure. *O1, O2, and O3.* First, second, and third occipital gyri. *T1, T2, and T3.* First, second, and third temporal gyri.

volutions. Our space will only permit of a brief notice of the chief “landmarks” useful in such operations.

The **longitudinal fissure** corresponds to a line drawn from the root of the nose (*nasion*) to the external occipital protuberance (*inion*).

Fissure of Sylvius.—The bifurcation of this fissure corresponds to a point an inch and a quarter behind the external angular process of the frontal and about a quarter of an inch above its lower extremity. From this point the vertical portion passes directly upwards for about three-quarters of an inch, running parallel to and imme-

diately behind the coronal suture. The horizontal limb of this fissure corresponds to a line drawn from a point an inch and an eighth behind the external angular process to a little below the most prominent part of the parietal eminence; it is covered for the middle three-fifths of its course by the upper part of the squamous suture.

Fissure of Rolando.—The upper end of this fissure is situated at a point on the line from the nasion to the inion measuring 55.6 per cent. of the whole line, starting from the front (*Hare's line*). It runs downwards and forwards for about $3\frac{3}{4}$ inches, forming an angle of 67° with the line of the sagittal suture (middle line). Its lower end is situated about half an inch behind the bifurcation of the fissure of Sylvius and close to the horizontal limb. Reid, in order to define the position of the fissure of Rolando more accurately, takes a base line from the lowest part of the infra-orbital margin, through the external auditory meatus to the back of the head; he next marks out the course of the fissure of Sylvius according to the above rules; two vertical lines are then drawn, reaching from the base line to the line of the sagittal suture, one passing through the depression in front of the auditory meatus, and the other through the posterior border of the mastoid process. A line drawn from the upper end of the posterior line to the point where the anterior one crosses the fissure of Sylvius, marks out the course of the fissure of Rolando.

The **parieto-occipital fissure** runs horizontally outwards from the longitudinal fissure, at a point about one-fifth of an inch in front of the *lambda*. If the line marking the horizontal part of the fissure of Sylvius is continued backwards till it reaches the sagittal suture, the posterior inch of its course will mark the parieto-occipital fissure.

Membranes of the Brain.

Dissection.—To examine the brain with its membranes, the upper part of the skull must be removed, by sawing through the external table and breaking the internal table with the chisel and hammer. After the calvarium has been loosened all round, it will require a considerable degree of force to tear the bone away from the dura mater. This adhesion is particularly firm at the sutures, where the dura mater is continuous with a membranous layer interposed between the edges of the bones; in other situations the connection results from numerous vessels which permeate the inner table of the skull. The adhesion subsisting between the dura mater and bone is greater in the young subject and in old persons than in the adult. On being torn away, the internal table will present numerous deeply grooved and ramified channels, corresponding with the branches of the meningeal arteries. Along the middle line will be seen a groove corresponding with the superior longitudinal sinus, and on either side may be frequently observed some small fossæ, corresponding with the Pacchionian bodies.

The membranes of the brain and spinal cord are—the *dura mater*, *arachnoid membrane*, and *pia mater*.

The **dura mater** is the firm whitish or greyish layer which is brought into view when the calvarium is removed. It is a strong fibrous membrane, somewhat laminated in texture, and composed of white fibrous tissue. Lining the interior of the cranium, it serves as the internal periosteum of that cavity; it is prolonged also into the spinal column, but is not adherent to the bones in that canal as in the cranium. It is very firmly attached to the margin of the foramen magnum, and to the foramina of exit of the cranial nerves. From the internal surface of the dura mater, processes are directed inwards for the support and protection of parts of the brain; while from its exterior, other processes are prolonged outwards to form sheaths for the nerves as they quit the skull. Its external surface is rough and fibrous, and corresponds with the internal table of the skull. The internal surface is smooth, and lined by endothelium; it was formerly regarded as a reflected layer of the arachnoid membrane.

On the external surface of the dura mater the branches of the middle meningeal artery may be seen ramifying; and in the middle line is a depressed groove, formed by the subsidence of the upper wall of the superior longitudinal sinus.

The **Pacchionian bodies** (*glandulae Pacchioni*) are small, round, whitish granulations, occurring singly or in clusters, and forming small groups of various sizes along the margin of the longitudinal fissure of the cerebrum, and more particularly near the summit of the latter. They are absent in infancy, increase in numbers in adult life, and are abundant in the aged. They are simply enlarged villi of the arachnoid, and consist of a spongy tissue continuous with the sub-arachnoid tissue and of the same composition, covered by a layer of epithelial cells. When of large size they cause absorption of the bone, and so come to be lodged in depressions or pits in the interior of the vertex of the skull.

If the student cut through one side of the dura mater, in the direction of his incision through the skull, and turn it upwards towards the middle line, he will observe the smooth internal surface of this membrane. He will perceive also the large veins of the hemispheres passing from behind forwards to open into the superior longitudinal sinns. If he introduce the handle of his scalpel between the dura mater and arachnoid, he will see a vertical layer of the former descending between the hemispheres; and if he draw one side of the brain a little outwards, he will be enabled to perceive the extent of the process of membrane which is called the falx cerebri.

The processes of dura mater which are sent inwards towards the interior of the skull are the *falx cerebri*, *tentorium cerebelli*, and *falx cerebelli*.

The **falx cerebri** (*falx*, a sickle, so named from its sickle-like appearance), narrow in front, broad behind, and forming a sharp curved edge below, is attached in front to the crista galli process of the ethmoid bone, and behind to the tentorium cerebelli; between these points it is connected with the inner surface of the cranium in the middle line. Along the attached border runs the superior

longitudinal sinus, and along the free edge the inferior longitudinal sinus, these vessels being situated between the two layers of which the membrane is composed.

The **tentorium cerebelli** (*tentorium*, a tent) is a roof of dura mater (raised in the centre and sloping down at the sides) thrown across the cerebellum and attached at each side to the margin of the petrous portion of the temporal bone; behind, to the transverse ridge of the occipital bone which lodges the lateral sinuses; and in front to the upper border of the petrous portion of the temporal bone and to the anterior and posterior clinoid processes. It supports

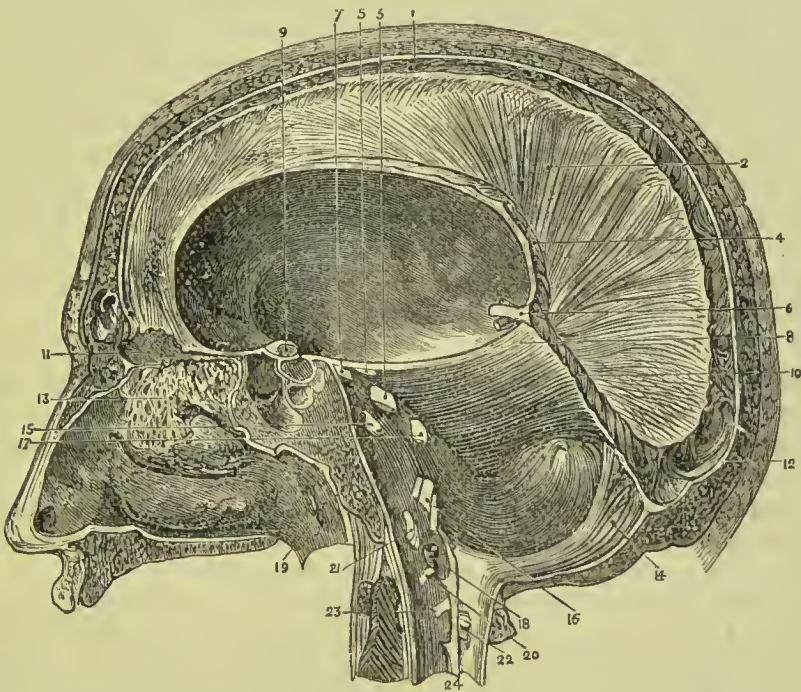


FIG. 317.—Sinuses and membranes of the brain (side view). 1. Superior longitudinal sinus. 2. Falx cerebri. 3. Fifth nerve. 4. Inferior longitudinal sinus. 5. Fourth nerve. 6. Venæ Galeni. 7. Third nerve. 8. Tentorium cerebelli. 9. Second nerve. 10. Straight sinus. 11. Crista galli of ethmoid. 12. Torcular Herophili. 13. First nerve. 14. Falx cerebelli. 15. Sixth nerve. 16. Eighth, ninth, and tenth nerves. 17. Seventh and eighth nerves. 18. Vertebral artery. 19. Eustachian tube. 20. First cervical nerve. 21. Twelfth nerve. 22. Posterior root of second cervical nerve. 23. Anterior root of second cervical nerve. 24. Ligamentum denticulatum.

the posterior lobes of the cerebrum and prevents their pressure on the cerebellum, leaving a small opening anteriorly (*superior occipital foramen*), for the transmission of the crura cerebri. Its attached border contains the lateral and superior petrosal sinuses, and the junction between it and the falx cerebri is channelled by the straight sinus.

The **falx cerebelli** is a small process, generally double, attached to the vertical ridge of the occipital bone beneath the lateral sinus, and to the tentorium. It lodges the occipital sinuses and is received into the indentation between the two hemispheres of the cerebellum.

Removal of the Brain.—The tentorium and falx cerebelli cannot

be seen until the brain is removed; but the attachments of the former should be studied on the dried skull, for it will have to be incised in the removal of the brain. That operation should now be performed, for which purpose divide the dura mater all round, on a level with the section through the skull, and carry the scissors deeply between the hemispheres of the brain in front, to cut through the anterior part of the falx; then draw the dura mater backwards, and leave it hanging by its attachment to the tentorium. Raise the anterior lobes of the brain carefully with the hand, and lift the olfactory bulbs from the cribriform fossæ with the handle of the scalpel. Then cut across the two optic nerves and internal carotid arteries. Next divide the infundibulum and third nerves, and carry the knife along the margin of the petrous bone at each side, so as to divide the tentorium near its attachment. Cut across in succession the other pairs of cranial nerves with a sharp knife, and pass the scalpel as far down as possible into the vertebral canal, to sever the spinal cord, cutting first to one side, and then to the other, in order to divide the vertebral arteries and spinal accessory nerves. Then press the cerebellum gently upwards with the fingers of the right hand, the hemispheres being supported with the left, and the brain will roll into the hand.

The **arteries** of the dura mater are—the *anterior meningeal* from the ethmoidal, ophthalmic, and internal carotid; the *middle meningeal* and *lesser meningeal* from the internal maxillary; the *inferior meningeal* from the ascending pharyngeal and occipital arteries; and the *posterior meningeal* from the vertebral.

Its **nerves** are derived from the nervi molles and superior cervical ganglion of the sympathetic, from the Gasserian ganglion, the ophthalmic nerve, and from the fourth and hypoglossal.

The dura mater is composed of two lamellæ, *endosteal* and *proper meningeal*; the former adheres to the bones, the latter forms the internal processes, whilst the sinuses result from the separation of the two. It consists of interwoven bands of white fibrous tissue, with some admixture of elastic fibres; its inner surface is lined with flattened nucleated endothelial cells.

The space between the dura mater and arachnoid is called the *subdural space*; it was formerly known as the cavity of the arachnoid.

The **arachnoid** (ἀράχνη εἶδος, like a spider's web) is a delicate membrane which invests the brain externally to the pia mater. On the upper surface of the hemispheres it is transparent, but may be demonstrated as it passes across the sulci from one convolution to another by injecting with a blow-pipe a stream of air beneath it. At the base of the brain the membrane is opalescent and thicker than in other situations, and more easily demonstrable from the circumstance of stretching across the interval between the temporal lobes of the hemispheres. The space which is included between this layer of membrane and those parts of the base of the brain which are bounded by the optic commissure and fissures of Sylvius in front, and the pons Varolii behind, is termed the *anterior sub-*

arachnoid space. Another space formed in a similar manner between the under part of the cerebellum and the medulla oblongata, is the *posterior sub-arachnoid space*; and a third space, situated over the corpora quadrigemina and corpus callosum, may be termed the *superior sub-arachnoid space*. These spaces communicate freely with each other, the anterior and posterior across the crura cerebelli, the anterior and the superior around the crura cerebri, and the latter and the posterior across the cerebellum in the course of the vermiform processes. The posterior space communicates by means of an opening called the *foramen of Magendie* with the cavity of the fourth ventricle; and the anterior space has two small openings in its wall behind the roots of the glosso-pharyngeal nerves, which communicate with a pouch-like prolongation of the arachnoid beneath the flocculus. They communicate also with a still larger space formed by the loose disposition of the arachnoid around the spinal cord, the *spinal sub-arachnoid space*. The whole of these spaces, with the lesser spaces between the convolutions of the hemispheres, constitute one large and continuous cavity which is filled with a limpid serous secretion, the *sub-arachnoid* or *cerebro-spinal fluid*, a fluid which is necessary for the regulation of pressure, and protection of the cerebro-spinal mass. The arachnoid is connected to the pia mater by a delicate areolar tissue, which in the sub-arachnoid space is loose and filamentous. The serous secretion of the sub-dural space is very small in quantity as compared with the sub-arachnoid fluid.

The arachnoid does not enter into the ventricles of the brain, but is reflected inwards upon the venæ Galeni for a short distance only, and returns upon those vessels to the dura mater of the tentorium. It surrounds the nerves as they originate from the brain, and forms a sheath around them to their point of exit from the skull.

Vessels of considerable size, but few in number, and branches of cranial **nerves**, are found in the arachnoid.

Structure.—The arachnoid consists of interlacing bundles of fine fibrous tissue, the interstices of which are occupied by spread-out cells. Its outer surface is covered by a layer of endothelium. On its inner surface it gives off numerous bundles of fibres which form trabeculæ and traverse the sub-arachnoid spaces; both the surface of the membrane and the trabeculæ are covered by endothelial cells.

Cerebro-Spinal Fluid.—This is a limpid fluid, slightly alkaline in reaction, containing albumen, a trace of grape sugar, and the salts of the blood.

The **pia mater** is an areolo-vascular membrane composed of innumerable vessels held together by fine bundles of connective tissue. It invests the whole surface of the brain, dipping into the sulci between the convolutions, and forming a fold in its interior called *velum interpositum*. It also forms folds in other situations, as in the third and fourth ventricles, and in the anterior fissure of the spinal cord.

This membrane differs in structure in different parts of the cerebro-spinal axis. Thus, on the surface of the cerebrum, in contact with the soft grey matter of the brain, it is extremely vas-

ular, forming remarkable loops of anastomosis in the interspaces of the convolutions, and distributing multitudes of minute straight vessels to the grey substance. In the *substantia perforata*, again, and *locus perforatus*, it gives off tufts of small arteries, which pierce the white matter to reach the grey substance in the interior. But upon the *crura cerebri*, *pons Varolii*, and spinal cord, its vascular character seems almost lost. It has become a *dense fibrous membrane*, difficult to tear off, and forming the proper sheath of the spinal cord.

The *pia mater* is the nutrient membrane of the brain, and derives its blood from the internal carotid and vertebral arteries. Lymphatics have also been described as entering into its structure.

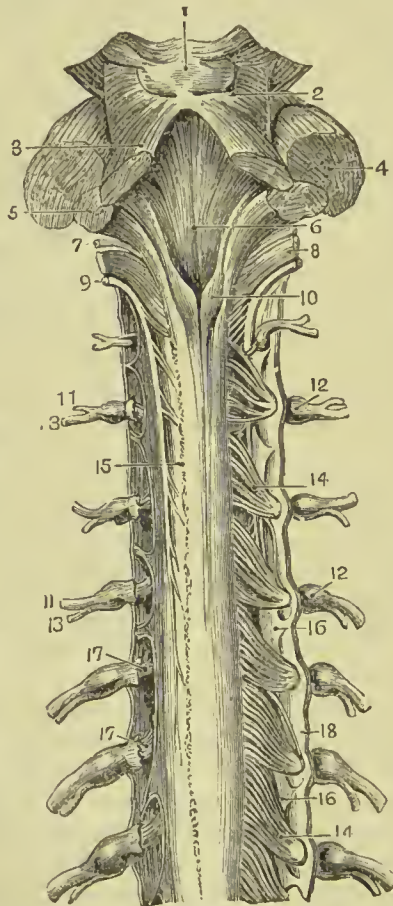
Its **nerves** are the minute filaments of the sympathetic, and filaments from the sensory cranial nerves; they accompany the branches of the arteries.

MEMBRANES OF THE SPINAL CORD.

The **dura mater spinalis** is a cylindrical sheath of fibrous membrane, identical in structure with the *dura mater* of the skull, and continuous with that membrane.

At the margin of the occipital foramen it is closely adherent to the bone; by its anterior surface it is attached to the posterior common ligament, and below, by means of its pointed extremity, to the coccyx. In the rest of its extent it is comparatively free, being separated from the vertebræ by loose areolar tissue and a plexus of veins. On either side and below, the *dura mater* forms a sheath for each of the spinal nerves, to which it is closely adherent.

FIG. 318.—Fourth ventricle and upper part of spinal cord and membranes. The posterior roots of the nerves are removed on the left side. 1. Corpora quadrigemina. 2. Fillet of the olivary body. 3. Proecessus e cerebello ad testes. 4. Proecessus e cerebello ad pontem. 5. Proecessus e cerebello ad medullam. 6. Floor of fourth ventricle. 7. Glosso-pharyngeal nerve. 8. Pneumogastrie nerve. 9. Spinal accessory nerve. 10. Posterior pyramids of medulla. 11, 11. Anterior divisions of spinal nerves. 12, 12. Ganglia of nerves. 13, 13. Posterior divisions of spinal nerves. 14, 14. Posterior roots of spinal nerves. 15. Line of origin of posterior roots of left side. 16, 16. Ligamentum denticulatum. 17, 17. Anterior root of spinal nerves. 18. Dura mater.



Upon its inner surface it is smooth, and on its sides may be seen double openings for the two roots of each of the spinal nerves.

The **arachnoid** of the spinal cord is a continuation of that of the brain. It encloses the cord very loosely, being connected to it only by long slender filaments of areolar tissue, and by a longitudinal lamella which is attached to the posterior aspect of the cord (*septum posticum*). The areolar tissue is most abundant in the cervical region, and diminishes in quantity from above downwards; and the *septum posticum* is complete only in the dorsal region. The arachnoid passes off from the cord on either side with the spinal nerves, to which it forms a sheath. The space between the arachnoid and the pia mater is identical with that already described as existing between the same parts in the brain, the *sub-arachnoid space*. It is occupied by cerebro-spinal fluid, sufficient in quantity to expand the arachnoid, and fill completely the cavity of the dura mater. The *sub-arachnoid* or *cerebro-spinal fluid* keeps up a constant and gentle pressure on the entire surface of the brain and spinal cord, and yields with the greatest facility to the various movements of the cord.

The **pia mater** is the immediate investment of the cord, and, like the other membranes, is continuous with that of the brain. It is not, however, like the pia mater cerebri, a vascular membrane, but is dense and fibrous in structure, and contains but few vessels. It invests the cord closely, and sends a fold into the anterior median fissure; it is intimately connected with the neuroglia of the cord and with that occupying the posterior median fissure. It forms a sheath for each of the funiculi of the nerves, and for the nerves themselves; and, inferiorly, at the conical termination of the cord, is prolonged downwards as a slender ligament (*filum terminale*), which descends through the centre of the cauda equina, and is attached to the dura mater lining the canal of the coccyx. This attachment is a rudiment of the original extension of the spinal cord into the canal of the sacrum and coccyx. A longitudinal band of white fibres runs down the centre of the anterior aspect of the cord, and was called by Haller the *linea splendens*. The pia mater has, distributed to it, a number of nervous plexuses.

The **ligamentum denticulatum** (*ligamentum dentatum*) is a thin process of pia mater sent off from each side of the cord throughout its entire length, and separating the anterior from the posterior roots of the spinal nerves. At its inner edge it is attached to the lateral aspect of the cord, and at its outer edge forms numerous saw-like processes or denticulations, the points of which are connected with the inner surface of the dura mater. The number of serrations on each side is about twenty, the first being situated on a level with the occipital foramen, and having the vertebral artery and hypoglossal

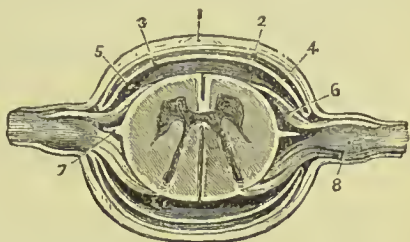


FIG. 319.—Transverse section of the spinal cord and its membranes. 1. Dura mater. 2. Inner lining of dura mater. 3. Arachnoid. 4. Sub-dural space. 5. Sub-arachnoid space. 6. Anterior root of nerve. 7. Ligamentum denticulatum. 8. Ganglion on posterior root of nerve.

nerve passing in front and the spinal accessory nerve behind it, and the last opposite the first or second lumbar vertebra. Below this point the ligamentum denticulatum is lost in the filum terminale of the pia mater. The denticulations do not pierce the arachnoid, but are covered by funnel-like prolongations of that membrane. The use of this membrane is to maintain the position of the spinal cord in the midst of the fluid by which it is surrounded.

CRANIAL NERVES.

The PAIRS of cranial nerves are *nine* or *twelve* in number, according as the arrangement of Willis or Soemmering is adopted. The following table shows their numbering according to both systems, and also gives the names by which the several nerves are known:—

Willis.	Soemmering.	Name.
First.	First.	Olfactory.
Second.	Second.	Optic.
Third.	Third.	Oculo-motor.
Fourth.	Fourth.	Pathetic or trochlear.
Fifth.	Fifth.	Trifacial or trigeminal.
Sixth.	Sixth.	Abducens.
Seventh	Seventh.	Facial.
{ portio dura.	Eighth.	Auditory.
{ portio mollis.	Ninth.	Glosso-pharyngeal.
Eighth.	Tenth.	Vagus.
	Eleventh.	Spinal accessory.
Ninth.	Twelfth.	Hypoglossal.

In the following description we shall follow the arrangement of Soemmering, as being that most commonly adopted by anatomists at the present time.

FIRST PAIR.—OLFACTORY.

The **olfactory tract** is more truly a lobe or offshoot of the brain than a cranial nerve; it *arises* by three roots: an *inner* or *short root* from the inner and posterior part of the anterior lobe close to the substantia perforata; a *middle root* from a papilla of grey matter (*tuber olfactorium*), embedded in the under surface of the frontal lobe, and an *external* or *long root*, which may be traced as a white streak along the fissure of Sylvius into the temporo-sphenoidal lobe. The nervous cord formed by the union of the three roots is soft in texture, prismoid in shape, and embedded in the olfactory sinus on the under surface of each anterior lobe of the brain, lying between the pia mater and arachnoid. As it passes forward it increases in breadth, and swells at its extremity into an oblong mass of grey and

white substance, the **olfactory bulb**, which rests on the cribriform plate of the ethmoid bone. From the under surface of the olfactory bulb are given off the nerves which pass through the cribriform foramina, and supply the mucous membrane of the nares; they are arranged into three groups: an inner group, which spread out upon the septum narium; an outer group, which descend through bony canals in the outer wall of the nares, and are distributed on the superior and middle turbinated bones; and a middle group, which supply the mucous membrane of the roof of the nasal fossæ. Each

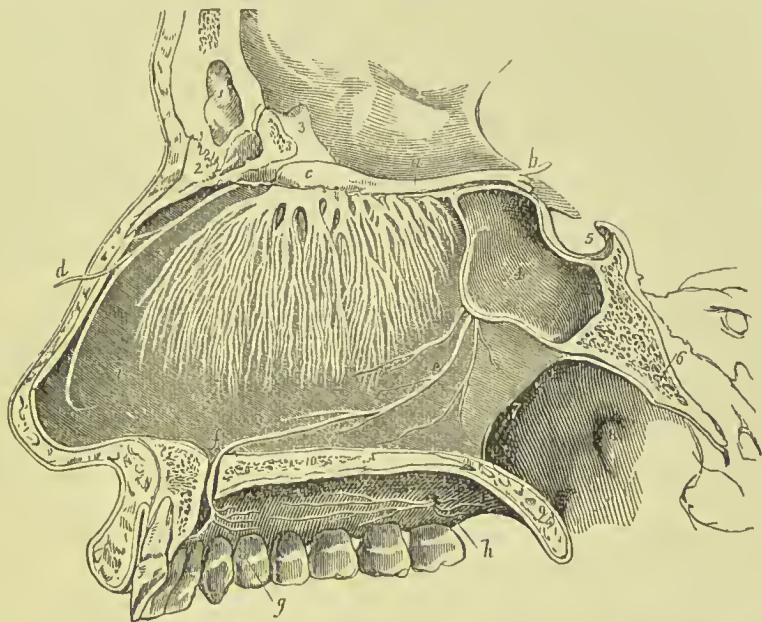


FIG. 320.—Olfactory nerves, with their distribution on the septum nasi. The nares have been divided by a longitudinal section made immediately to the left of the septum, the right naris being preserved entire. 1. Frontal sinus. 2. Nasal bone. 3. Crista galli. 4. Sphenoidal sinus of left side. 5. Sella turcica. 6. Basilar process of sphenoid and occipital bone. 7. Posterior opening of the right naris. 8. Opening of the Eustachian tube. 9. Soft palate. 10. Cut surface of the hard palate. *a.* Olfactory tract. *b.* Its three roots of origin. *c.* Its bulb, from which the filaments are seen to proceed which spread out in the substance of the pituitary membrane. *d.* Nasal branch of the ophthalmic nerve. *e.* Naso-palatine nerve, distributing twigs to the mucous membrane of the septum nasi in its course to (*f.*) the anterior palatine foramen. *g.* Branches of the naso-palatine nerve to the palate. *h.* Anterior and posterior palatine nerves. *i.* Septum nasi.

nerve is enclosed in a tabular prolongation of the dura mater and pia mater. The nerves are devoid of medullary sheath, and form frequent anastomoses with each other.

SECOND PAIR.—OPTIC.

This nerve consists of three parts: the *optic tract*, the *optic chiasma*, and the *nerve* proper. The first portion *arises* from the corpora geniculata on the posterior and inferior aspect of the thalamus opticus, from the thalamus itself, and from the nates. Pro-

ceeding from this origin it winds around the crus cerebri as a flattened band, and joins with its fellow in front of the tuber cinereum to form the *optic commissure* (chiasma). The optic tract is united with the crus cerebri and tuber cinereum, and is covered by the pia mater; the commissure is also connected with the tuber cinereum, from which it receives fibres, and the nerve beyond the commissure diverges from its fellow, becomes rounded in form, and is enclosed in a sheath derived from the arachnoid, which is continued upon it to the eyeball. In passing through the optic foramen the optic nerve receives a sheath from the dura mater, which splits at this point into two layers: one, which becomes the periosteum of the orbit; the other, the one in question, which forms a sheath for the nerve, and is lost in the sclerotic coat of the eyeball. After a short course within the orbit the optic nerve pierces the sclerotic and choroid coats, and expands into the nervous membrane of the eyeball, the retina. Near the globe the nerve is pierced by a small artery, *arteria centralis retinae*, which runs through the central axis of the nerve and reaches the inner layers of the retina, to which it distributes branches.

The **optic commissure** lies in a groove in front of the olivary body of the sphenoid bone; is bounded by the lamina cinerea in front, by the substantia perforata at each side, and by the tuber cinereum behind. Within the commissure the innermost fibres of each optic nerve cross each other to pass to the eye of the opposite side; the outer fibres continue their course uninterruptedly to the eye of the corresponding side. Some fibres pass in an arched direction from one nerve to the other behind, and others, taking a similar course in front, connect the two retinae.

THIRD PAIR.—MOTORES OCULORUM.

The motor oculi, a nerve of moderate size, *arises* from the inner side of the crus cerebri, close to the pons Varolii, and passes forward between the posterior cerebral and superior cerebellar arteries. Its deep origin has been traced through the locus niger, to a grey nucleus beneath the floor of the aqueduct of Sylvius and beneath the corpora quadrigemina. It pierces the dura mater immediately in front of the posterior clinoid process; descends obliquely in the external wall of the cavernous sinus; and divides into two branches which enter the orbit through the sphenoidal fissure and between the two heads of the external rectus muscle. The *superior* branch ascends, and supplies the superior rectus and levator palpebrae. The *inferior* sends a branch beneath the optic nerve to the internal rectus, another to the inferior rectus, and a long branch to the inferior oblique muscle. From the latter a short thick branch is given to the ophthalmic ganglion, forming its inferior root. The branches of the third nerve enter the muscles on their ocular side.

In the cavernous sinus it receives one or two filaments from the carotid plexus, and one from the ophthalmic nerve.

FOURTH PAIR.—PATHETICI (trochlearis).

The fourth is the smallest cerebral nerve ; it *arises* from a nucleus beneath that of the third nerve in the floor of the aqueduct of Sylvius ; it passes across the outer border of the valve of Vieussens, and winding around the crus cerebri to the extremity of the petrous portion of the temporal bone, pierces the dura mater below the third nerve, and passes forward in the outer wall of the cavernous sinus to the sphenoidal fissure. In its course in the outer wall of the sinus it is situated at first below the motor oculi, but afterwards ascends and becomes the highest of the nerves entering the orbit by the sphenoidal fissure. On entering the orbit the nerve crosses the levator palpebræ muscle near its origin, and is distributed on the orbital surface of the superior oblique or trochlearis muscle ; hence its synonym *trochlearis*.

The fibres of origin of the two nerves communicate with each other, forming a kind of commissure, on the upper surface of the valve of Vieussens.

Branches.—While in the cavernous sinus the fourth nerve gives off a recurrent branch, and sends a branch of communication to the ophthalmic nerve ; the *recurrent branch*, consisting of sympathetic filaments derived from the carotid plexus, passes backwards between the layers of the tentorium, and divides into two or three filaments, which are distributed to the lining membrane of the lateral sinus.

FIFTH PAIR.—TRIFACIAL (trigeminus).

The fifth nerve, the great sensitive nerve of the head and face, and the largest cranial nerve, is analogous to the spinal nerves in its origin by two roots from the anterior and posterior columns of the spinal cord, and in the existence of a ganglion on the posterior root. It *arises*, or rather makes its appearance at the surface of the brain, on the anterior part of the lateral and constricted portion of the pons Varolii, and consists of a large and small fasciculus, separated by a narrow interspace, the larger fasciculus being the posterior or sensory root ; the smaller one, the anterior or motor root. The sensory root is composed of from seventy to a hundred filaments each enclosed in a sheath of pia mater, and the entire bundle is bound together into a single nerve and connected with the motor root by a sheath of arachnoid membrane. The nerve then passes through an oval opening in the border of the tentorium, near the extremity of the petrous bone, and spreads out into a large semilunar ganglion, the **Gasserian**. If the ganglion be turned over, it will be seen that the anterior root lies against its under surface without having any connection with it, and may be followed onwards to the inferior maxillary nerve. The Gasserian ganglion divides into three branches—ophthalmic, superior maxillary, and inferior maxillary.

Deep Origin.—The motor root arises (1) from a nucleus in the

floor of the fourth ventricle, immediately below the lateral recess, and (2) from grey matter in the sides of the Sylvian aqueduct (*descending root*). The sensory root springs (1) from a long nucleus placed beneath the floor of the fourth ventricle and extending into the medulla in the region of the funiculus cuneatus (*ascending root*), and (2) from the nerve cells of the formatio reticularis in the medulla and pons.

The **OPHTHALMIC NERVE** is the nerve of sensation of the eyeball, lachrymal gland, mucous membrane of the eye and nose, integument of the forehead and nose, and muscles of the eyebrow and forehead. It arises from the upper part of the Gasserian ganglion by a short trunk, about three-quarters of an inch in length; passes forwards in the outer wall of the cavernous sinus, lying externally to the other nerves, and divides into three branches. Previously to its division it receives several filaments from the carotid plexus, and gives off a small *recurrent nerve*, which passes backwards with the recurrent

branch of the fourth nerve between the two layers of the tentorium to the lining membrane of lateral sinus.

The **branches** of the ophthalmic nerve are the—

Frontal,
Lachrymal,
Nasal.

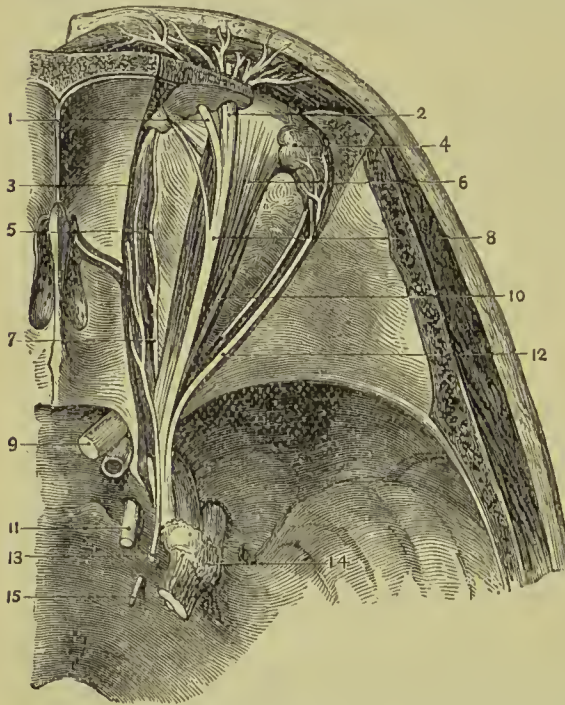


FIG. 321.—Superficial dissection of the nerves of the orbit. 1. Supra-trochlear nerve. 2. Supra-orbital nerve. 3. Obliquus superior. 4. Lachrymal gland. 5. Infra-trochlear nerve. 6. Levator palpebrae superioris. 7. Nasal nerve (fifth). 8. Frontal nerve (fifth). 9. Optic nerve. 10. Rectus superior. 11. Third nerve. 12. Lachrymal nerve. 13. Fourth nerve. 14. Gasserian ganglion of fifth. 15. Sixth nerve.

branch of the fourth nerve between the two layers of the tentorium to the lining membrane of lateral sinus. The **branches** of the ophthalmic nerve are the—
Frontal,
Lachrymal,
Nasal.
The **frontal nerve** enters the orbit immediately to the outer side of the fourth nerve, and passing forwards, for some distance, upon the levator palpebrae muscle, divides into a supra-orbital and supra-trochlear branch. The *supra-orbital* branch, the proper continuation of the nerve, passes out of the orbit through the supra-orbital notch, in company with the supra-orbital artery, and after giving filaments to the upper eyelid, muscles of the forehead and pericranium, divides into two cutaneous branches, internal and external. The *internal branch* pierces the occipito-frontalis and is distributed to the integument as

far as the summit of the head. The *external branch* of larger size communicates with the facial nerve, and piercing the occipito-frontalis supplies the integument as far back as the occiput.

The *supra-trochlear* branch passes inwards to the angle of the orbit, above the superior oblique muscle and close to the pulley, and is distributed to the inner angle of the eye, root of the nose, and in-

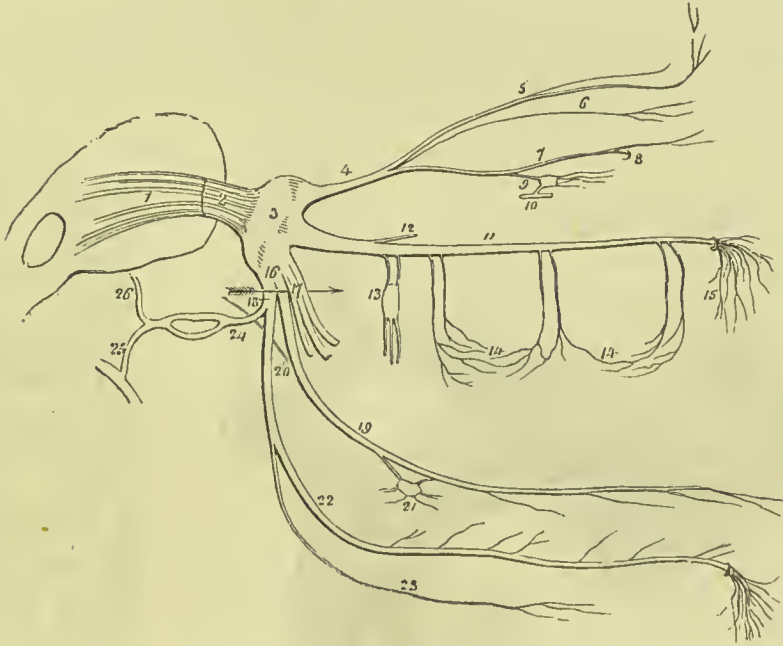


FIG. 322.—Diagram showing the fifth pair of nerves with its branches. 1. Origin of the nerve by two roots. 2. The nerve escaping from the pons Varolii. 3. Gasserian ganglion. 4. Ophthalmic nerve. 5. Frontal nerve giving off the supra-trochlear branch. 6. Lachrymal nerve. 7. Nasal nerve passing at 8 through the anterior internal orbital foramen, and giving off the infra-trochlear branch. 9. Superior root of the ophthalmic ganglion given off from nasal nerve. 10. Inferior or motor root, derived from third nerve; the ganglion gives off the ciliary nerves from its anterior aspect. 11. Superior maxillary nerve. 12. Orbital branch. 13. Spheno-palatine nerves communicating with Meckel's ganglion; the three branches from the lower part of the ganglion are the palatine nerves. 14, 14. Superior dental nerves, posterior, middle, and anterior. 15. Infra-orbital branches. 16. Inferior maxillary nerve. 17. Its anterior or muscular trunk. 18. The posterior trunk; the two divisions are separated by an arrow. 19. Lingual nerve. 20. Chorda tympani joining it at an acute angle. 21. Submaxillary ganglion. 22. Inferior dental nerve. 23. Mylo-hyoid branch. 24. Auriculo-temporal nerve, dividing behind the articulation of the lower jaw, to reunite and form a single trunk. 25. Its branch of communication with the facial nerve. 26. Continuation of its trunk to the temple.

tegument of the middle line of the forehead. It communicates with the infra-trochlear branch of the nasal nerve.

The **lachrymal nerve**, the smallest of the three branches of the ophthalmic, enters the orbit on the outer side of the frontal, but enclosed in a separate sheath of dura mater; and passes forward, above the upper border of the external rectus muscle, and in company with the lachrymal artery to the lachrymal gland, where it divides into two branches, superior and inferior. The *superior*

branch passes over the gland which it supplies on the upper surface. The *inferior branch* supplies the under surface of the gland, upper lid, and outer angle of the eye. It gives off a branch which passes downwards to join the orbital branch of the superior maxillary, and from the connection between these two nerves, temporo-malar filaments are derived which pass through foramina in the malar bone to be distributed to the outer part of the face and the temple, communicating with branches of the facial and auriculo-temporal nerves.

The **nasal nerve** enters the orbit between the two heads of the external rectus and between the two branches of the third nerve. It

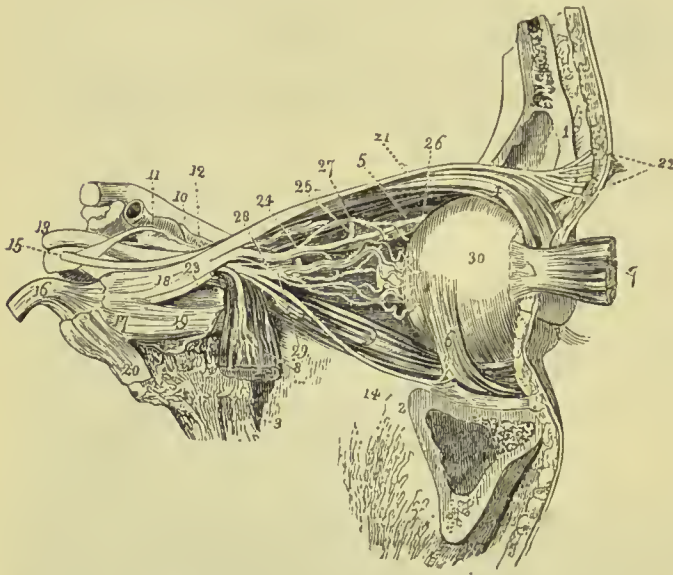


FIG. 323.—Nerves of the orbit seen from the outer side. 1. Section of frontal bone. 2. Superior maxillary bone. 3. Part of sphenoid bone. 4. Levator palpebræ and superior rectus muscles. 5. Superior oblique muscle. 6. Inferior oblique. 7. Ocular half of the external rectus drawn forwards. 8. Orbital half of the external rectus turned downwards. On this muscle the sixth nerve is seen dividing into branches. 9. Inferior rectus. 10. Optic nerve. 11. Internal carotid artery emerg-

ing from the cavernous sinus. 12. Ophthalmic artery. 13. Third nerve. 14. Branch of the third nerve to the inferior oblique muscle. Between this and the sixth nerve (8) is seen the branch which supplies the inferior rectus; its branch to the ophthalmic ganglion is seen proceeding from the upper side of the trunk of the nerve, at the bottom of the orbit. 15. Fourth nerve. 16. Trunk of the fifth nerve. 17. Gasserian ganglion. 18. Ophthalmic nerve. 19. Superior maxillary nerve. 20. Inferior maxillary nerve. 21. Frontal nerve. 22. Supra-orbital nerve. 23. Lachrymal nerve. 24. Nasal nerve; the small nerve seen between the nasal and frontal, is one of the branches of the upper division of the third nerve. 25. Nasal nerve passing over the internal rectus muscle to the anterior internal orbital foramen. 26. Infra-trochlear nerve. 27. A long ciliary branch of the nasal; another long ciliary branch is seen proceeding from the lower aspect of the nerve. 28. Long root of the ophthalmic ganglion, proceeding from the nasal nerve, and receiving the sympathetic root which joins it at an acute angle. 29. Ophthalmic ganglion, giving off from its fore-part the short ciliary nerves. 30. Globe of the eye.

crosses the optic nerve in company with the ophthalmic artery, and, passing over the internal rectus, enters the anterior internal orbital foramen, by which it is conducted to the cribriform plate of the ethmoid bone. It then passes through the slit-like opening by the side of the crista galli, and descends into the nose, where it divides into an internal and external branch. The *internal branch* is distributed to the mucous membrane; the *external branch*, passing

outwards between the nasal bone and cartilage, supplies the integument of the exterior of the nose as far as its tip.

The **branches** of the nasal nerve are—*ganglionic*, *ciliary*, and *infra-trochlear*.

The **ganglionic branch**, about half an inch in length and of small size, enters the upper angle of the ophthalmic ganglion, and constitutes its superior or long root. It is often joined by the sympathetic root of the ganglion derived from the cavernous plexus.

The **long ciliary branches** are two or three filaments given off from the nerve as it crosses the optic nerve. They pierce the sclerotic coat near the short ciliary nerves, and passing through the globe of the eye between the sclerotic and choroid, are distributed to the iris.

The **infra-trochlear branch** is given off close to the anterior internal orbital foramen. It passes forward along the upper border of the internal rectus to the inner angle of the eye, where it communicates with the supra-trochlear nerve, and is distributed to the lachrymal sac and inner angle of the orbit.

The **SUPERIOR MAXILLARY NERVE**, larger than the preceding, is the nerve of sensation of the teeth of the upper jaw, the hard and soft palate, tonsils, antrum maxillare, and muscles and integument of the lower eyelid, cheek, and upper lip. Proceeding from the middle of the Gasserian ganglion, it passes forward through the foramen rotundum, crosses the speno-maxillary fossa, and enters the canal in the floor of the orbit, along which it runs to the infra-orbital foramen. Emerging on the face, beneath the levator labii superioris muscle, it becomes the *infra-orbital nerve*, and divides into palpebral, nasal, and labial branches, which form a plexus with the facial nerve.

The **branches** of the superior maxillary nerve are divisible into three groups: namely, those given off in the speno-maxillary fossa; those given off in the infra-orbital canal; and those given off on the face. They may be thus arranged:—

Speno-maxillary fossa	}	Orbital, or temporo-malar,
		Speno-palatine,
		Posterior dental.
Infra-orbital canal	}	Middle dental,
		Anterior dental.
On the face	}	Palpebral,
		Nasal,
		Labial.

The **orbital branch** enters the orbit through the speno-maxillary fissure, and divides into two branches, temporal and malar; the *temporal branch* ascends along the outer wall of the orbit, and after receiving a branch from the lachrymal nerve, passes through a canal in the malar bone, and enters the temporal fossa; it then pierces the temporal muscle and fascia, and is distributed to the integument of the temple and side of the forehead, communicating with the

facial and auriculo-temporal nerves. In the temporal fossa it communicates with the deep temporal nerves. The *malar*, or inferior branch (subcutaneous malæ) takes its course along the lower angle of the outer wall of the orbit, and emerges on the cheek through an opening in the malar bone, passing between the fibres of the orbicularis palpebrarum muscle. It communicates with branches of the infra-orbital and facial nerve.

The **spheno-palatine branches**, two in number, pass downwards to the spheno-palatine or Meckel's ganglion.

The **posterior dental branches**, two in number, pass downwards upon the tuberosity of the superior maxillary bone, where *one* enters

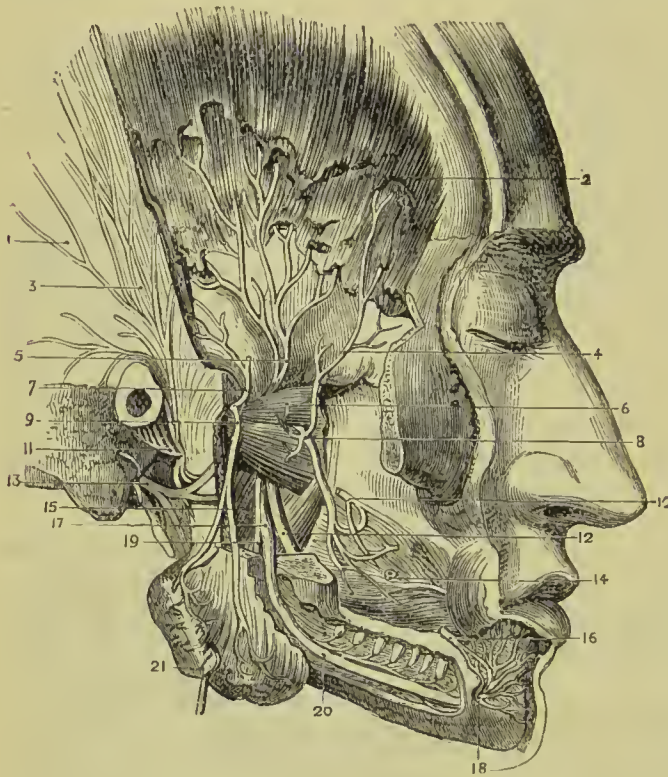


FIG. 324. — Pterygo-maxillary region and fifth nerve. 1. Temporal fascia. 2. Temporal muscle. 3. Temporal branches of auriculo-temporal nerve. 4. Anterior deep temporal nerve. 5. Posterior deep temporal nerve. 6. External pterygoid muscle. 7. Deep temporal branch of masseteric nerve (inconstant). 8. Buccal nerve. 9. Masseteric nerve. 10. Buccal branch of seventh. 11. Auriculo-temporal nerve. 12. Lingual nerve. 13. Facial nerve at stylo-mastoid foramen. 14. Buccinator muscle. 15. Internal pterygoid. 16. Supra-maxillary branch of seventh. 17. Inferior dental nerve. 18. Its mental branches. 19. Its mylo-hyoid branch. 20. Inferior dental canal opened. 21. Masseter (turned down).

a canal in the bone, and is distributed to the molar teeth and lining membrane of the antrum, and communicates with the anterior dental nerve; while the *other*, lying externally to the bone, is distributed to the gums and buccinator muscle.

The **middle** and **anterior dental branches** descend to the corresponding teeth and gums; the former beneath the lining membrane of the antrum, the latter through distinct canals in the walls of the bone. Previously to their distribution, the dental nerves form a plexus in the outer wall of the superior maxillary bone immediately above the alveolus. From this plexus filaments are given off which supply the pulps of the teeth, gums, mucous membrane of the floor

of the nares, and palate. Small ganglia have been described in connection with this plexus, one being placed over the canine, another over the second molar tooth; the former has been named the *ganglion of Bochdalek*.

The **palpebral branches** are given off from the infra-orbital as it issues from the infra-orbital foramen; they turn upwards to the eyelid and are distributed to the skin, conjunctiva, and orbicularis palpebrarum (sensory supply).

The **nasal branches** pass inwards between the fibres of the levator labii superioris alæque nasi to be distributed to the skin of the side of the nose and the extrinsic and intrinsic muscles (sensory supply).

The **labial branch** lies on the levator anguli oris, and divides into branches for the skin of the cheek, mucous membrane of the upper lip, and muscles of the upper lip (sensory supply).

The **INFERIOR MAXILLARY NERVE** is a nerve both of sensation and motion, and is distributed to the teeth and gums of the lower jaw, to the tip and sides of the tongue, to the integument of the temple, external ear, lower part of the face and lower lip, and to the muscles of mastication. Its sensory root proceeds from the inferior angle of the Gasserian ganglion, is the largest of the three sensory divisions of the fifth nerve, and is increased in size by the anterior or motor root, which, passing behind the ganglion, unites with it as it escapes through the foramen ovale. Emerging at the foramen ovale the nerve divides into two trunks, anterior and posterior, separated from each other by the external pterygoid muscle; the anterior division is almost entirely motor, but its buccal branch is believed to be in chief part sensory; the posterior division is sensory, but the mylo-hyoid branch of the inferior dental is motor.

The **anterior division**, into which may be traced nearly the whole of the motor root, immediately separates into five or six branches, distributed to the muscles of the temporo-maxillary region; they are—masseteric, temporal, buccal, internal pterygoid, and external pterygoid.

The **masseteric branch** passing over the external pterygoid muscle, and behind the tendon of the temporal, crosses the sigmoid notch with the masseteric artery to the masseter muscle. It sends a filament to the temporo-maxillary articulation, and frequently a small branch to the temporal muscle.

The **deep temporal branches**, two in number, **anterior** and **posterior**, pass between the upper border of the external pterygoid muscle and the temporal bone to the temporal muscle. Two or three filaments from these nerves pierce the temporal fascia, and communicate with the lachrymal, subcutaneous malæ, superficial temporal and facial nerves.

The **buccal branch** is of large size, and pierces the lower fibres of the external pterygoid muscle at its anterior part; it runs downwards and forwards in close contact with the inner surface of the tendon of the temporal muscle and accompanied by the bucca

branch of the internal maxillary artery. It sends a branch to the external pterygoid muscle, and is distributed to the buccinator and mucous membrane and integument of the cheek, communicating with the facial nerve.

The **internal pterygoid branch** is a long and slender nerve which passes inwards to the internal pterygoid muscle, and enters it on its deep surface. This nerve is remarkable for its connection with the otic ganglion, to which it is closely adherent.

The **external pterygoid branch** is commonly derived from the buccal nerve.

The **posterior division** of the inferior maxillary nerve splits into three branches—

Auriculo-temporal, Inferior dental, Lingual.

The **AURICULO-TEMPORAL NERVE** originates by two roots, between which the middle meningeal artery takes its course, and passes directly backwards behind the articulation of the lower jaw. It then ascends between that articulation and the meatus auris, and, escaping from beneath the parotid gland, divides into two temporal branches. While behind the temporo-maxillary articulation, it forms a kind of plexus, and sends off several branches.

Its **branches** are—a small branch to the temporo-maxillary articulation; two or three to the parotid gland; two to the meatus auris, which enter the canal between the fibro-cartilage and processus auditorius; two auricular branches to the pinna; a communicating branch to the otic ganglion; two communicating branches to the facial nerve, and the temporal branches.

The **auricular branches, superior and inferior**, are distributed to the pinna above and below the meatus. The inferior branch communicates with the sympathetic.

The branches which communicate with the facial nerve embrace the external carotid artery in their course.

The **temporal** branches are anterior and posterior: the **anterior** accompanies the anterior temporal artery, and supplies the integument of the temporal region, communicating with branches of the facial, supra-orbital, subcutaneus malæ, and lachrymal nerves; the **posterior** is distributed to the upper part of the pinna, attrahens auriculam muscle, and integument of the posterior part of the temple.

The **INFERIOR DENTAL NERVE**, the largest of the three branches of the posterior division of the inferior maxillary, passes downwards with the inferior dental artery, at first between the two pterygoid muscles, then between the internal lateral ligament and ramus of the lower jaw to the dental foramen, next it runs along the canal in the inferior maxillary bone, distributing branches to the teeth and gums, and divides into two terminal branches, incisive and mental.

The **branches** of the inferior dental nerve, besides those given to the teeth, are the mylo-hyoid and the two terminal branches.

The **mylo-hyoid branch** leaves the nerve just as it is about to

enter the dental foramen ; it then pierces the insertion of the internal lateral ligament, and descends along a groove in the bone to the inferior surface of the mylo-hyoid muscle, to which, and to the anterior belly of the digastricus, it furnishes the motor supply.

The **incisive branch** is continued forward to the symphysis of the jaw, to supply the incisor teeth.

The **mental or labial branch** emerges from the jaw at the mental foramen, beneath the depressor anguli oris, and divides into branches which supply the muscles (sensory supply) and integument of the lower lip and chin, and communicate with the facial nerve.

The **LINGUAL NERVE** (*gustatory*) descends between the two pterygoid muscles, and makes a gentle curve forwards to the side of the tongue, along which it takes its course to the tip. On the side of the tongue it is flattened, and gives off numerous branches, which are distributed to the mucous membrane and papillæ.

In the upper part of its course the lingual nerve lies between the external pterygoid muscle and the pharynx, next between the two pterygoid muscles, then between the internal pterygoid and ramus of the jaw, crosses the upper border of the superior constrictor of the pharynx, and runs between the stylo-glossus muscle and the submaxillary gland ; lastly, it runs along the side of the tongue, resting against the hyo-glossus muscle and crossing the duct of the submaxillary gland, and lies between the mylo-hyoid muscle and the mucous membrane of the floor of the mouth.

The lingual nerve, while between the pterygoid muscles, often receives a communicating branch from the inferior dental ; lower down it is joined at an acute angle by the chorda tympani, a small nerve, which, arising from the facial in the aqueductus Fallopii, crosses the tympanum, and escapes from that cavity through the canal of Huguier at the inner end of the fissure of Glaser. Having joined the lingual nerve, the chorda tympani is continued downwards in its sheath to the submaxillary ganglion and tongue.

One or two **branches** are given by the lingual nerve to the submaxillary ganglion.

On the hyo-glossus muscle several **branches** of communication join with branches of the hypoglossal nerve, and others are sent to the sublingual gland, Wharton's duct, and mucous membrane of the mouth and gums.

SIXTH PAIR.—ABDUCENTES.

The abducens nerve, about half the size of the motor oculi, *arises* by several filaments from the groove between the anterior pyramid and the pons Varolii. Proceeding forwards from this origin, it lies parallel with the basilar artery, and, piercing the dura mater low down on the side of the basilar process of the sphenoid bone, ascends between the two layers of that membrane to the cavernous sinus. It then runs forward on the outer wall of the sinus, below the level of the other nerves and resting against the internal carotid artery, to the sphenoidal fissure. Entering the orbit through the

sphenoidal fissure it passes between the two heads of the external rectus, and is distributed to that muscle. At the sphenoidal fissure it lies upon the ophthalmic vein, from which it is separated by a lamina of dura mater; and in the cavernous sinus is joined by several filaments from the carotid plexus.

Deep Origin.—Underneath the fasciculus teres in the floor of the fourth ventricle, immediately above the striæ acusticæ.

SEVENTH PAIR.

The seventh and eighth pairs of nerves consist of two nervous cords which lie side by side on the posterior border of the crus cerebelli in the groove between the olivary and restiform bodies. The smaller and most internal of these, and at the same time the most dense in texture, is the seventh (*facial nerve* or *portio dura*). The external nerve, which is soft and pulpy, and often grooved by contact with the preceding, is the eighth or auditory nerve (*portio mollis*). A third nerve of small size, *portio intermedia* of Wrisberg, is brought into view by separating these two cords. It arises from the same nucleus as the auditory nerve, and generally joins the facial nerve where the two lie together in the internal auditory meatus. Some observers state that it is continued into the chorda tympani nerve beyond the gangliform enlargement of the facial.

FACIAL OR SEVENTH NERVE (portio dura).—The facial nerve, the motor nerve of the face, *arises* from the upper part of the groove between the olivary and restiform bodies, close to the lower edge of the pons Varolii; its **deep origin** being traced to the formatio reticularis of the pons, beneath the floor of the fourth ventricle. The nerve passes forward, resting on the crus cerebelli, and comes into relation with the auditory nerve, with which it enters the meatus auditorius internus, lying at first to the inner side of, and then upon that nerve. At the bottom of the meatus, the facial nerve enters the aqueductus Fallopii, and takes its course forwards to the hiatus Fallopii, in the anterior wall of the petrous bone, where it forms a gangliform swelling (**intumescencia gangliformis, geniculate ganglion**), and receives the petrosal branch of the Vidian nerve. It then runs along the inner wall of the tympanum, and descends behind the pyramid and tympanic cavity to the stylo-mastoid foramen. Emerging at the stylo-mastoid foramen, it passes forwards within the parotid gland, crossing the external carotid artery, to the ramus of the lower jaw, where it splits into two trunks, **temporo-facial** and **cervico-facial**. These trunks divide into numerous branches, which escape from the anterior border of the parotid gland, and are distributed in a radiated manner over the side of the face, from the temple to below the lower jaw; on the masseter muscle the branches communicate and form loops, and the whole arrangement over the side of the face has been termed **pes anserinus**.

Communications.—In the meatus auditorius, the facial nerve communicates with the auditory nerve by one or two filaments; the intumescentia gangliformis is connected with the greater and lesser petrosal nerves, and sends a twig back to the auditory nerve; at the back of the tympanum, the nerve receives one or two twigs from the auricular branch of the pneumogastric; at its exit from the stylo-mastoid foramen it receives a twig from the glosso-pharyngeal, and in the parotid gland one or two large branches from the auriculo-temporal nerve. Besides these, the facial nerve has numerous peripheral communications, with the branches of the fifth nerve on the face, with the cervical nerves in the parotid gland and on the neck, and with the sympathetic.

The **branches** of the facial nerve are—

Within the aqueductus Fallopii	{ Tympanic, Chorda tympani.
After emerging at the stylo-mastoid foramen	{ Posterior auricular, Stylo-hyoid, Digastric.
On the face	{ Temporo-facial, Cervico-facial.

The **tympanic branch** is a small filament given off by the facial while in the petrous bone, and distributed to the stapedius muscle.

The **chorda tympani** quits the facial immediately above the stylo-mastoid foramen, and ascends by a distinct canal to the upper part of the posterior wall of the tympanum, where it enters that cavity through an opening situated between the base of the pyramid and the attachment of the membrana tympani, and becomes invested by mucous membrane. It then crosses the tympanum between the handle of the malleus and long process of the incus to its anterior inferior angle, and escapes through an opening at the inner end of the fissure of Glaser (canal of Huguier), to join the lingual branch of the fifth at an acute angle between the two pterygoid muscles. Enclosed in the sheath of the lingual nerve, it descends to the submaxillary gland, where part of it ends in the submaxillary ganglion; the rest is continued onwards with the filaments of the lingual, to be distributed to the tongue.

The origin of the chorda tympani has long been a subject of discussion, some observers regarding it as derived from the intermediary nerve of Wrisberg, others considering it as traceable through the greater and lesser petrosal nerves to the spheno-palatine and otic ganglia; latterly, there has been a growing opinion in favour of its origin from the communicating branch of the glosso-pharyngeal, which joins the facial nerve at the stylo-mastoid foramen.

The **posterior auricular branch** ascends behind the ear, between the meatus and mastoid process, and divides into an anterior or auricular, and a posterior or occipital branch. The *auricular* branch receives a filament of communication from the auricular branch of the pneumogastric nerve, and distributes filaments to the

retrahens auriculam muscle and pinna. The *occipital* branch communicates with the auricularis magnus and occipitalis minor, and is distributed to the occipital portion of the occipito-frontalis.

The **stylo-hyoid branch** is distributed to the stylo-hyoid muscle, and communicates with the sympathetic plexus on the external carotid artery.

The **digastric branch** supplies the posterior belly of the digastric muscle, and communicates with the glosso-pharyngeal and

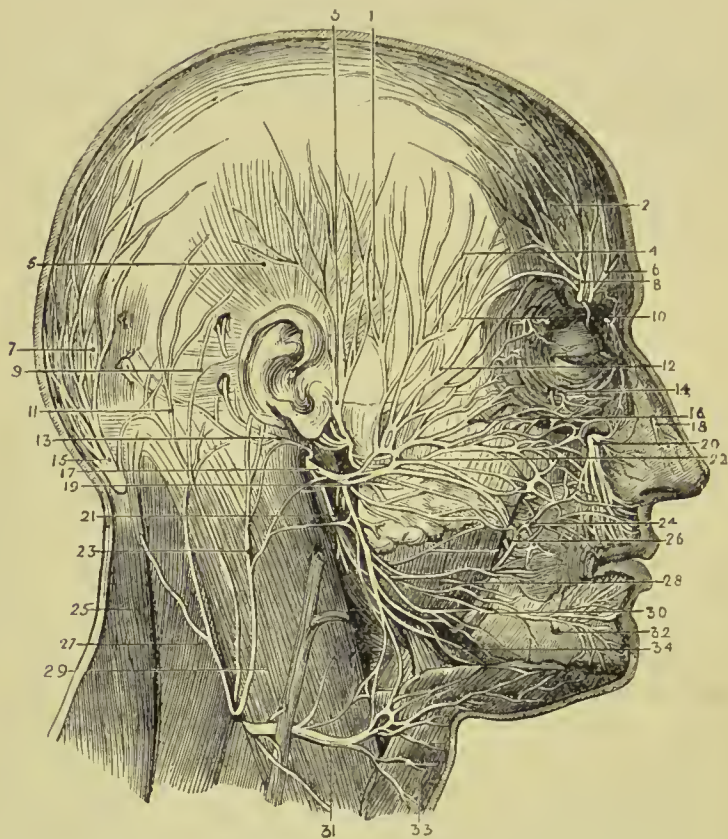


FIG. 325.—Nerves of the face and scalp. 1. Attrahens auriculam muscle. 2. Anterior belly of occipito-frontalis. 3. Auriculo-temporal nerve. 4. Temporal branches of facial nerve. 5. Attollens auriculam muscle. 6. Supra-trochlear nerve. 7. Posterior belly of occipito-frontalis. 8. Supra-orbital nerve. 9. Retrahens auriculam muscle. 10. Temporal branch of orbital nerve (superior maxillary). 11. Occipitalis minor nerve. 12. Malar branches of facial. 13. Posterior auricular. 14. Malar branch of temporo-malar. 15. Great occipital. 16. Infra-orbital branches of facial. 17. Facial. 18. Nasal branch of ophthalmic. 19. Cervico-facial division of facial. 20. Infra-orbital branch of fifth. 21. Branches of facial to digastric and stylo-hyoid. 22. Temporo-facial division of facial. 23. Great auricular. 24. Buccal branches of facial. 25. Trapezius muscle.

pneumogastric nerves. This nerve and the preceding often arise from the facial by a common trunk.

The **TEMPORO-FACIAL DIVISION**, while in the parotid gland, sends a branch of communication along the carotid artery to the

auriculo-temporal nerve, and divides into temporal, malar, and infra-orbital branches.

The **temporal branches** ascending upon the temporal region supply the *atrahens auriculam*, *occipito-frontalis*, and *orbicularis palpebrarum*; and communicate with the supra-orbital nerve and temporal branch of the superior maxillary.

The **malar branches** cross the malar bone to the outer angle of the eye, and supply the *orbicularis palpebrarum*, *corrugator supercilii*, and eyelids. They communicate with the subcutaneous malar branch of the superior maxillary nerve, and with branches of the ophthalmic nerve in the eyelids.

The **infra-orbital branches** cross the masseter muscle, and are distributed to the buccinator, elevator muscles of the upper lip, and *orbicularis oris*. They communicate with the terminal branches of the infra-orbital nerve, infra-trochlear, and nasal nerve. Two or more of these branches are found by the side of Stenson's duct.

The **CERVICO-FACIAL DIVISION**, smaller than the temporo-facial, communicates in the parotid gland with the *auricularis magnus* nerve, and divides into branches which admit of arrangement into three sets: buccal, supra-maxillary, and infra-maxillary.

The **buccal branches** pass forward across the masseter muscle towards the mouth, and distribute branches to the *orbicularis oris* and buccinator. They communicate with branches of the temporo-facial, and with the buccal branch of the inferior maxillary nerve.

The **supra-maxillary branches** are destined to the muscles of the lower lip, and take their course along the body of the lower jaw. Beneath the *depressor anguli oris*, they have a plexiform communication with the inferior dental nerve.

The **infra-maxillary branches** take their course below the lower jaw, pierce the deep cervical fascia, and are distributed to the *platysma*, communicating with the *superficialis colli* nerve.

EIGHTH NERVE.

Auditory Nerve (portio mollis).—The auditory nerve takes its origin in the floor of the fourth ventricle from two nuclei—one in the *tuberculum acusticum* at the outer side of the inferior fovea, the other in the lateral recess. It winds around the restiform body, from which it receives fibres, to the posterior border of the *crus cerebelli*. It then passes forward on the *crus cerebelli* in company with the facial nerve, which lies in a groove on its superior surface, enters the *meatus auditorius internus*, and at the bottom of the *meatus* divides into two branches, *cochlear* and *vestibular*. The distribution of these branches will be found described with the anatomy of the internal ear. The auditory nerve is soft and pulpy in texture, and receives in the *meatus auditorius* several filaments from the facial nerve.

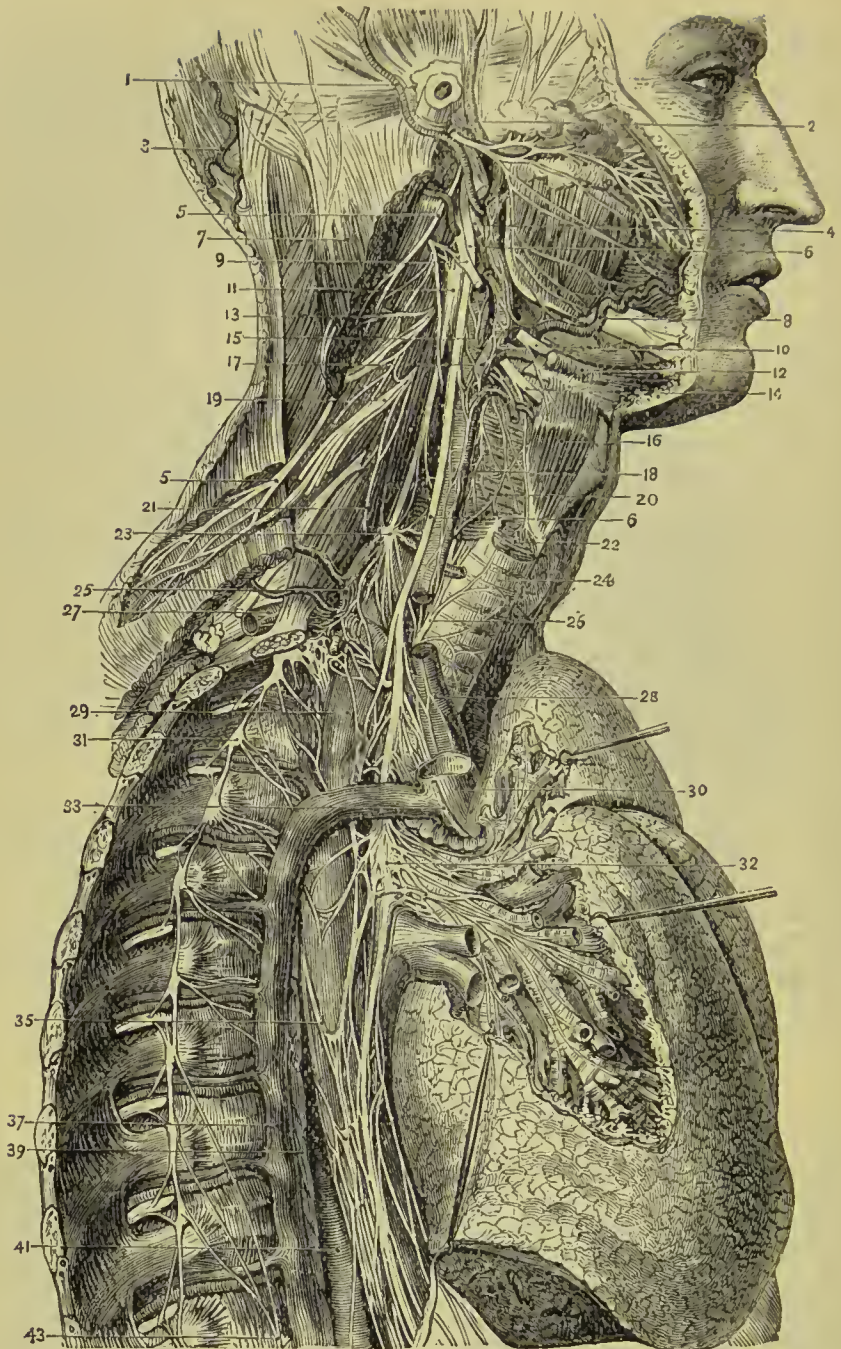


FIG. 326.—1. Posterior auricular artery. 2. Temporal artery. 3. Occipital artery. 4. Glosso-pharyngeal nerve. 5, 5. Spinal accessory nerve. 6, 6. Pneumogastric nerve. 7. Sterno-mastoid (cut). 8. Facial artery. 9. Hypoglossal nerve, with communication from second cervical nerve. 10. Lower end of ditto. 11. Superior cervical ganglion. 12. Digastricus. 13. Third cervical nerve. 14. Superior laryngeal nerve. 15. Internal carotid. 16. Thyro-hyoid muscle. 17. External carotid. 18. Common carotid. 19. Fourth cervical nerve. 20. Inferior constrictor of pharynx. 21. Phrenic nerve. 22. Crico-thyroid. 23. Middle cervical ganglion.

24. Trachea. 25. Thyroid axis. 26. Recurrent laryngeal nerve. 27. Subclavian artery. 28. Innominate artery. 29. Œsophagus. 30. Vena cava superior (cut). 31. Gangliated cord of sympathetic. 32. Posterior pulmonary plexus. 33. Phrenic nerve (cut). 35. Œsophageal plexus. 37. Vena azygos major. 39. Thoracic duct. 41. Thoracic aorta. 43. Great splanchnic nerve.

NINTH NERVE.

The **glosso-pharyngeal nerve**, as its name implies, is the nerve of sensation of the mucous membrane of the tongue and pharynx, but it also gives branches to some of the muscles of these organs. It *arises* by five or six filaments from the groove between the olivary and restiform bodies, and escapes from the skull at the innermost extremity of the jugular foramen through a distinct opening in the dura mater, lying anteriorly to the sheath of the pneumogastric and spinal accessory nerves, and internally to the jugular vein. It then passes forward between the jugular vein and internal carotid artery, and crosses the artery to reach the posterior border of the stylo-pharyngeus. Following the posterior border of this muscle for a short distance, it next passes across it and the middle constrictor and behind the hyo-glossus muscle, to be distributed to the mucous membrane of the tongue, pharynx, and tonsil.

Deep Origin.—Beneath the floor of the fourth ventricle, above the nucleus of the vagus and below that of the auditory nerve.

While in the jugular fossa, it presents two gangliform swellings: one *superior*, the **jugular ganglion**, of small size, and involving only the posterior fibres of the nerve; the other *inferior*, nearly half an inch below the preceding, of larger size, and occupying the whole diameter of the nerve, the **petrous ganglion** or **ganglion of Andersch**.

The **branches** of the glosso-pharyngeal nerve are branches of communication and branches of distribution.

The **branches of communication** proceed chiefly from the ganglion of Andersch; they are—one to join the auricular branch of the pneumogastric; one to the ganglion of the root of the pneumogastric; one to the superior cervical ganglion of the sympathetic; and one, which arises below the ganglion and pierces the posterior belly of the digastricus muscle, to join the facial nerve.

The **branches of distribution** are—

Tympanic,	Pharyngeal,
Carotid,	Tonsillitic,
Muscular,	Lingual.

The **tympanic branch** (Jacobson's nerve) proceeds from the ganglion of Andersch, or from the trunk of the nerve immediately above the ganglion; it enters a small bony canal between the jugular fossa and carotid foramen (p. 99), and divides into six branches, which are distributed on the inner wall of the tympanum, and establish a plexiform communication (tympanic plexus) with the sympathetic and fifth pair of nerves. The *branches* of distribution supply the fenestra rotunda, fenestra ovalis, and Eustachian

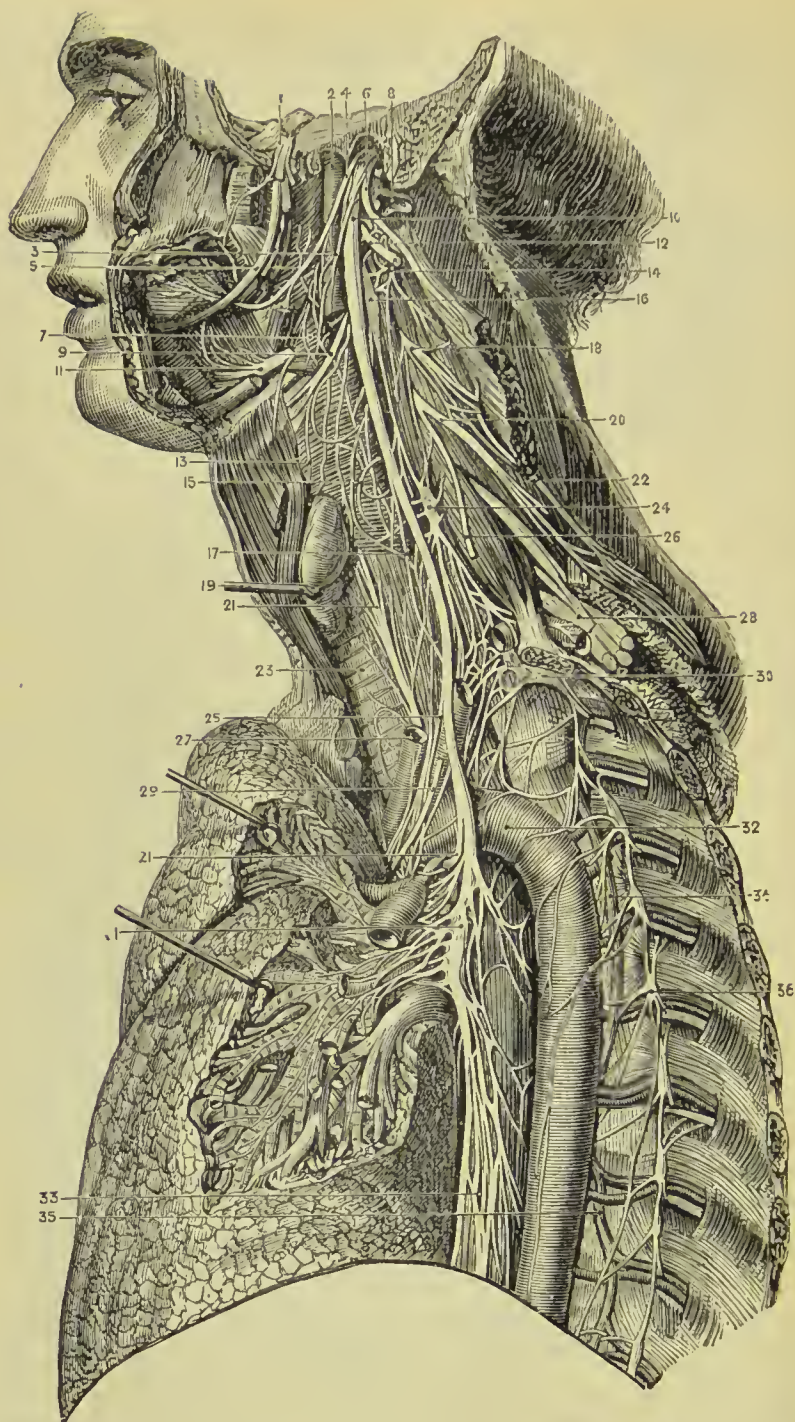


FIG. 327.—1. Gasserian ganglion of fifth nerve. 2. Internal carotid artery. 3. Pharyngeal branch of pneumogastric. 4. Glossopharyngeal nerve. 5. Lingual nerve (fifth). 6. Spinal accessory nerve. 7. Middle constrictor of pharynx. 8. Internal jugular vein (cut). 9. Superior laryngeal nerve. 10. Ganglion of trunk of pneumogastric nerve. 11. Hypoglossal nerve on hyoglossus. 12. Ditto communicating with vagus and first cervical nerve. 13. External laryngeal nerve. 14.

Second cervical nerve looping with first. 15. Pharyngeal plexus on inferior constrictor. 16. Superior cervical ganglion of sympathetic. 17. Superior cardiac nerve of pneumogastric. 18. Third cervical nerve. 19. Thyroid body. 20. Fourth cervical nerve. 21, 21. Left recurrent laryngeal nerve. 22. Spinal accessory communicating with cervical nerves. 23. Trachea. 24. Middle cervical ganglion of sympathetic. 25. Middle cardiac nerve of pneumogastric. 26. Phrenic nerve (cut). 27. Left carotid artery. 28. Brachial plexus. 29. Phrenic nerve (cut). 30. Inferior cervical ganglion of sympathetic. 31. Pulmonary plexus of pneumogastric. 32. Thoracic aorta. 33. Oesophageal plexus. 34. Vena azygos minor superior. 35. Vena azygos minor inferior. 36. Gangliated cord of sympathetic.

tube : those of communication join the carotid plexus in the carotid canal, the petrosal branch of the Vidian nerve (great petrosal nerve), and lesser petrosal nerve.

The **carotid branches** are several filaments which follow the trunk of the internal carotid artery, and communicate with the *nervi molles* of the sympathetic and pharyngeal branch of the pneumogastric.

The **muscular branch** divides into filaments, which are distributed to the stylo-pharyngeus, and constrictor muscles. *The N. laryng. is connected with the Com. with VII*

The **pharyngeal branches** are two or three filaments which are distributed to the pharynx and unite with the pharyngeal branches of the pneumogastric, external laryngeal, and sympathetic nerves to form the *pharyngeal plexus*.

The **tonsillitic branches** proceed from the glosso-pharyngeal nerve, near its termination; they form a plexus (*circulus tonsillaris*) around the base of the tonsil, from which numerous filaments are given off to the mucous membrane of the fauces and soft palate. These filaments communicate with the descending palatine branches of Meckel's ganglion.

The **lingual branches** enter the substance of the tongue beneath the hyo-glossus and stylo-glossus muscle, and are distributed to the mucous membrane of the side and base of the tongue, and to the epiglottis and fauces.

TENTH NERVE.

The **pneumogastric** or **vagus nerve** is the nerve of the respiratory organs and upper part of the alimentary canal, supplying branches to the larynx, trachea, lungs, pharynx, oesophagus, and stomach, and also giving branches to the heart. It *arises* by ten or fifteen filaments from the groove between the olivary and restiform bodies, immediately below the glosso-pharyngeal, and passes out of the skull through the inner extremity of the jugular foramen, enclosed in a sheath of dura mater common to it and the spinal accessory. The nerve then takes its course down the side of the neck, lying at first between the internal jugular vein and internal carotid artery, and lower down behind and between that vein and the common carotid artery and enclosed in the same sheath. At the root of the neck the course of the nerve on the two sides is different. The *right nerve* enters the chest by passing between the subclavian artery and vein, and descends by the side of the trachea to the posterior part of the root of the right lung; it then proceeds as a double cord along the posterior aspect of the oesophagus to the corresponding

side of the stomach ; the two cords reuniting at the lower part of the œsophagus. The *left nerve* enters the chest between the left common carotid and subclavian artery lying behind the left vena innominata ; it then crosses the arch of the aorta, and reaches the posterior part of the root of the left lung, whence it descends, by one or two cords, along the anterior aspect of the œsophagus to the front part of the stomach.

In the jugular foramen, the pneumogastric nerve presents a small round ganglion, the **superior ganglion** or **ganglion of the root** ; and immediately after its exit a gangliform swelling, nearly an inch in length, the **inferior ganglion** or **ganglion of the trunk**.

Deep Origin.—The fibres of origin of the pneumogastric nerve may be traced to a mass of nerve cells placed beneath the floor of the fourth ventricle, below the nucleus of the glosso-pharyngeal, and extending down to the calamus scriptorius.

The **branches** of the pneumogastric nerve are branches of communication and branches of distribution.

The **branches of communication** proceed from the ganglia ; from the superior ganglion one or two branches pass to the spinal accessory ; one or two to the superior ganglion of the sympathetic ; and one to the inferior ganglion of the glosso-pharyngeal. From the inferior ganglion there pass off branches to the hypoglossal, branches to the superior cervical ganglion of the sympathetic, and branches to the loop between the first and second cervical nerve.

The **branches of distribution** are—

Meningeal,	Anterior pulmonary,
Auricular,	Posterior pulmonary,
Pharyngeal,	Œsophageal,
Superior laryngeal,	Gastric.
Cardiac,	
Inferior or recurrent laryngeal.	

The **meningeal** or **recurrent** is a small branch given off from the ganglion of the root ; it passes backwards to be distributed to the dura mater of the posterior fossa of the skull.

The **auricular branch** (Arnold's nerve) is given off from the lower part of the ganglion of the root, or from the trunk of the nerve immediately below it, and receives immediately after its origin a small branch of communication from the petrous ganglion of the glosso-pharyngeal. It then passes outwards behind the jugular vein, and at the outer side of that vessel enters a small canal (p. 99) in the jugular fossa of the temporal bone. Guided by that canal it reaches the descending part of the aqueductus Fallopii and communicates with the facial nerve ; it then passes outwards through a small fissure situated between the mastoid process and external auditory process (auditory fissure), and reaching the surface of the bone communicates with the posterior auricular nerve and is distributed to the back part of the pinna and auditory canal.

The **pharyngeal** nerve arises from the upper part of the ganglion

of the trunk, and crosses behind the internal carotid artery to the upper border of the middle constrictor, upon which it forms the *pharyngeal plexus* assisted by branches from the glosso-pharyngeal, superior laryngeal, and sympathetic. One small branch, called, the *lingual branch of the vagus*, is derived from the pharyngeal branches of this nerve and the glosso-pharyngeal; it joins the hypoglossal nerve, as that trunk winds round the occipital artery, and is distributed with it. The pharyngeal plexus is distributed to the muscles and mucous membrane of the pharynx.

The **superior laryngeal** nerve arises from the ganglion of the trunk, and descends behind the internal carotid artery to the opening in the thyrohyoid membrane, through which it passes with the superior laryngeal artery, and is distributed to the mucous membrane of the larynx, communicating with the inferior laryngeal nerve. Behind the internal carotid it gives off the **external laryngeal branch**, which sends a twig to the pharyngeal plexus, and then descends to supply the inferior constrictor, crico-thyroid muscle and thyroid gland. This branch communicates inferiorly with the superior cardiac nerve and superior cervical ganglion of the sympathetic.

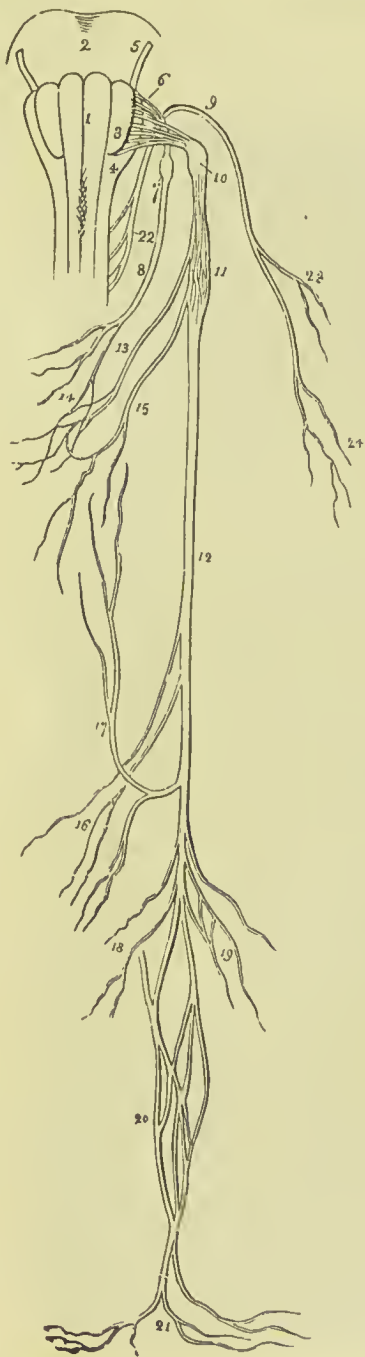

FIG. 328. — Origin and distribution of the glosso-pharyngeal, pneumogastric, and spinal accessory nerves. 1, 3, 4. Medulla oblongata. 1. Anterior pyramid. 2. Pons Varolii. 3. Olivary body. 4. Restiform body. 5. Facial nerve. 6. Origin of the glosso-pharyngeal. 7. Ganglion of Andersch. 8. Trunk of the nerve. 9. Spinal accessory nerve. 10. Ganglion of the root of the pneumogastric. 11. Ganglion of the trunk. 12. Trunk. 13. Pharyngeal branch forming the pharyngeal plexus (14) assisted by a branch from the glosso-pharyngeal (8), and one from the superior laryngeal nerve (15). 16. Cardiac branches. 17. Recurrent laryngeal branch. 18. Anterior pulmonary and cardiac branches. 19. Posterior pulmonary branches. 20. Esophageal plexus. 21. Gastric branches. 22. Origin of the spinal accessory nerve. 23. Branch to the sterno-mastoid muscle. 24. Branches to the trapezius.

The **cervical cardiac branches**, two or three in number, arise from the upper and lower part of the cervical portion of the nerve. Those from above communicate with cardiac branches of the sympathetic. One large branch (*inferior cardiac*) is given off just before the nerve enters the chest; on the *right* this branch descends by the side of the arteria innominata to the deep cardiac plexus; on the *left* it passes in front of the arch of the aorta to the superficial cardiac plexus. One or two cardiac branches also proceed from the thoracic portion of the right pneumogastric nerve and end in the deep cardiac plexus.

The **inferior, or recurrent laryngeal nerve**, curves around the subclavian artery on the right, and the arch of the aorta on the left side. It ascends in the groove between the trachea and œsophagus, and piercing the lower fibres of the inferior constrictor muscle enters the larynx close to the articulation of the inferior cornu of the thyroid with the cricoid cartilage. It is distributed to all the muscles of the larynx, with the exception of the crico-thyroid, and communicates with the superior laryngeal nerve. As it curves around the subclavian artery and aorta it gives branches (cardiac) to the deep cardiac plexus and root of the lungs; and as it ascends the neck it distributes filaments to the œsophagus and trachea, and communicates with the external laryngeal nerve and sympathetic.

The **anterior pulmonary branches**, two or three in number, are distributed upon the anterior aspect of the root of the lungs, forming, with branches from the cardiac plexuses, the *anterior pulmonary plexus*.

The **posterior pulmonary branches**, more numerous and larger than the anterior, are distributed on the posterior aspect of the root of the lungs; they are joined by filaments from the third and fourth thoracic ganglia of the sympathetic, and form the *posterior pulmonary plexus*.

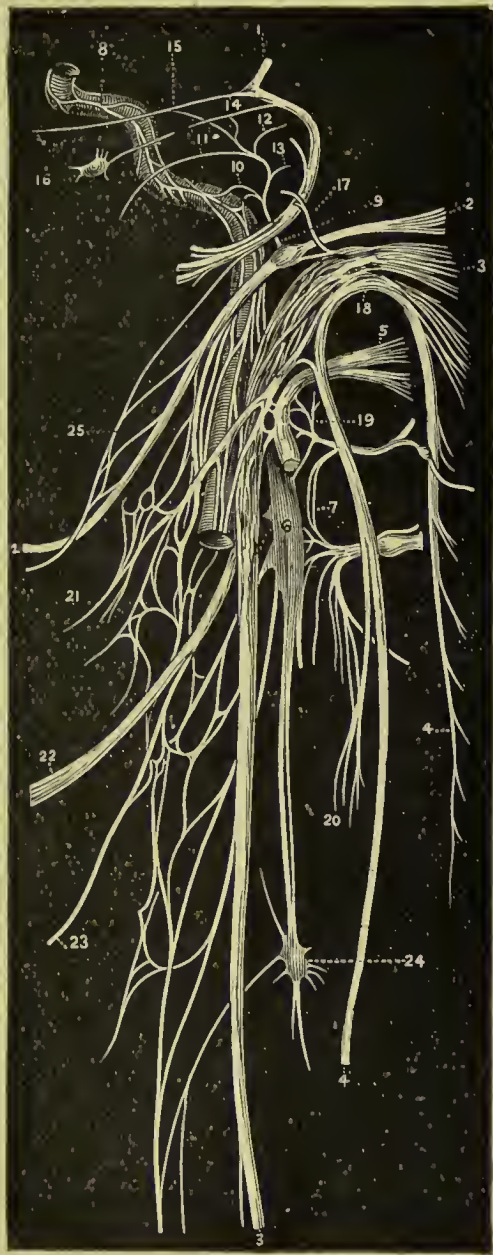Œsophageal branches are given off by the pneumogastric nerves above the root of the lungs; below that point, the trunks of the nerves, divided into several cords, form a plexus around the œsophagus, the right and left nerves communicating with each other. This plexus accompanies the œsophagus to the stomach, and is the *œsophageal plexus* (plexus gulæ).

The **gastric branches** are the terminal filaments of the pneumogastric nerves; they are spread out upon the anterior and posterior surface of the stomach, and are likewise distributed to the omentum, spleen, pancreas, liver, and gall-bladder. The branches of the anterior aspect of the stomach proceed from the left nerve and communicate with the hepatic plexus in the lesser omentum; those of the posterior aspect are derived from the right nerve and communicate with the solar plexus.

ELEVENTH NERVE.

SPINAL ACCESSORY NERVE.—The spinal accessory consists of a *spinal* and an *accessory* portion; the former *arises* by several filaments from the side of the spinal cord as low down as the fifth or sixth

FIG. 329. — Diagram of the ninth, tenth, eleventh, twelfth, and sympathetic nerves. 1. Facial nerve. 2. Glosso-pharyngeal nerve, with its petrous ganglion. 3. Pneumogastric nerve. 4. Spinal accessory nerve. 5. Hypoglossal nerve. 6. Superior cervical ganglion of sympathetic. 7. Loop between first and second cervical nerves. 8. Carotid branch of sympathetic. 9. Tympanic nerve (Jacobson). 10. Its branch to carotid plexus. 11. Its branch to Eustachian tube. 12. Its branch to fenestra ovalis. 13. Its branch to fenestra rotunda. 14. Its union with small superficial petrosal nerve. 15. Its union with large superficial petrosal nerve. 16. Otic ganglion. 17. Auricular branch of pneumogastric (Arnold's nerve). 18. Junction of pneumogastric with spinal accessory. 19. Junction of hypoglossal and first cervical nerve. 20. Junction of mastoid branch of spinal accessory and second cervical nerve. 21. Pharyngeal plexus. 22. Superior laryngeal nerve. 23. External laryngeal nerve. 24. Middle cervical ganglion of sympathetic. 25. Junction of digastric nerve (seventh) with glosso-pharyngeal.



cervical nerve, and ascends behind the ligamentum denticulatum, and between the anterior and posterior roots of the spinal nerves,

to the foramen lacerum posterius. It communicates in its course with the posterior root of the first cervical nerve, and entering the skull by the foramen magnum, leaves it again by the jugular foramen, and becomes applied against the posterior aspect of the ganglion of the trunk of the pneumogastric, being contained in the same sheath of dura mater. The accessory portion arises from the lateral aspect of the medulla, immediately below the vagus; its fibres being traceable through the medulla to a grey nucleus in the lower part of the floor of the fourth ventricle.

The two portions lie together, in the same compartment of the jugular foramen as the vagus, and often become intimately united so as to form a short trunk. Immediately after leaving the foramen the accessory portion of the nerve joins the ganglion of the trunk of the vagus, and probably endows that nerve with motor power. The spinal portion is continued downwards behind, but sometimes in front of, the internal jugular vein, to the upper and deep part of the sterno-mastoid, pierces that muscle obliquely, and descends across the posterior triangle of the neck to the deep surface of the trapezius, to which it is distributed, its branches being continued downwards to near the lower border of the muscle.

In the substance of the sterno-mastoid it communicates with branches of the cervical plexus, and in the posterior triangular space with the third and fourth cervical nerves.

TWELFTH NERVE.

HYPOGLOSSAL NERVE.—The hypoglossal is a nerve of motion, distributed to all the extrinsic muscles of the tongue, the genio-hyoid and the thyro-hyoid. It *arises* from the groove between the anterior pyramid and olivary body by ten or fifteen filaments, which are collected into two bundles, and escape from the cranium through the anterior condylar foramen. At its exit from the cranium, the nerve lies behind the internal carotid artery and internal jugular vein, then passing forward between the artery and vein it descends to a point parallel with the angle of the lower jaw. It next curves forward around the occipital artery, with which it forms a loop, and crossing the external carotid and lower part of the hyo-glossus muscle to the genio-hyo-glossus, sends filaments onwards with the anterior fibres of that muscle as far as the tip of the tongue. While resting on the hyo-glossus muscle it is flattened, and beneath the mylo-hyoid communicates with the lingual branch of the fifth nerve.

At its origin, the hypoglossal nerve sometimes communicates with the posterior root of the first cervical nerve. Its *deep origin* may be traced to one of the nuclei of grey substance, in the floor of the fourth ventricle, where it decussates with its fellow of the opposite side.

The **branches** of the hypoglossal nerve are—branches of communication and branches of distribution.

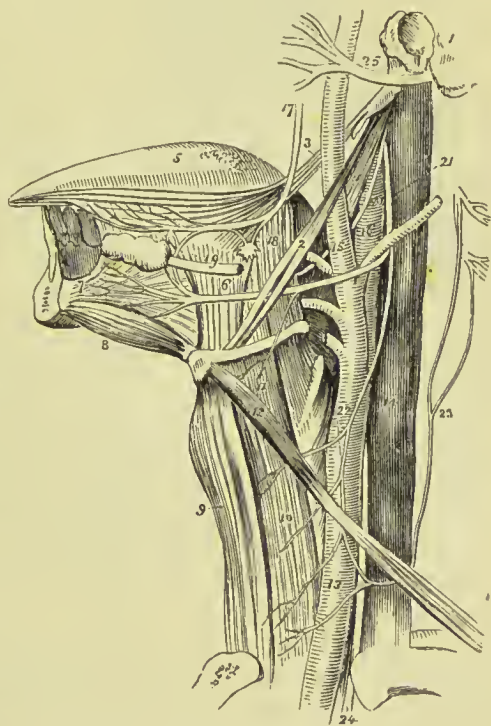
The **branches of communication** of the hypoglossal nerve are—several to the pneumogastric, with which nerve it is closely united; one or two with the superior cervical ganglion of the sympathetic; and one or two with the loop between the first and second cervical nerves.

The **branches of distribution** are—

Descendens cervicis, Thyro-hyoid, Muscular.

The **descendens cervicis** (*descendens noni*) is a long and slender nerve, which quits the hypoglossal just as it is about to form its arch around the occipital artery, and descends on the sheath of the carotid vessels. Just below the middle of the neck it forms a loop (*ansa hypoglossi*) with the communicans cervicis, derived from the second and third cervical nerves. From the convexity of this loop branches are sent to the sterno-hyoid, sterno-thyroid, and both

FIG. 330.—Anatomy of the side of the neck, showing the nerves of the tongue. 1. Temporal bone. 2. Stylo-hyoid muscle. 3. Stylo-glossus. 4. Stylo-pharyngeus. 5. Tongue. 6, 18. Hyo-glossus muscle. 7. Genio-hyo-glossus. 8. Genio-hyoid. 9. Sterno-hyoid muscle. 10. Sterno-thyroid. 11. Thyro-hyoid, upon which the thyro-hyoid branch of the hypoglossal nerve is seen ramifying. 12. Omo-hyoid crossing the common carotid artery (13) and internal jugular vein (14). 15. External carotid giving off its branches. 16. Internal carotid. 17. Lingual branch of fifth giving a twig to the submaxillary ganglion (18), and communicating a little farther on with the hypoglossal nerve. 19. Submaxillary, or Wharton's duct, passing forwards to the sublingual gland. The submaxillary ganglion is the small round body between figures 18 and 19. 20. Glosso-pharyngeal nerve. 21. Hypoglossal nerve curving around the occipital artery. 22. Descendens cervicis nerve, forming a loop with (23) the communicans cervicis, which is seen arising by filaments from the upper cervical nerves. 24. Pneumogastric nerve. 25. Facial nerve.



bellies of the omo-hyoid; sometimes also a twig is given off to the cardiac plexus, and occasionally one to the phrenic nerve.

The descendens cervicis probably arises from the upper cervical nerves, and is only temporarily associated with the hypoglossal (Luschka); this view receives confirmation from the fact that in

some instances it accompanies the vagus instead of the hypoglossal, and in others is absent, the entire distribution taking place through the communicans cervicis. In yet another set of cases, the descendens supplies the place of the communicans, which is otherwise unrepresented.

The **thyro-hyoid** nerve is a small branch distributed to the thyro-hyoid muscle. It is given off by the trunk of the hypoglossal near the posterior border of the hyo-glossus, and descends obliquely over the great cornu of the os hyoides. According to Holl, this nerve is really derived from the upper cervical nerves.

The **muscular branches** are given off where the nerve is covered by the mylo-hyoid muscle, and rests on the hyo-glossus; several large branches take their course across the fibres of the genio-hyo-glossus to reach the substance of the tongue. They are distributed to the hyo-glossus, genio-hyoid, genio-hyo-glossus, and stylo-glossus muscles. On the hyo-glossus muscle, the branches of the hypoglossal nerve communicate with those of the lingual branch of the fifth nerve.

SPINAL NERVES.

There are thirty-one pairs of spinal nerves, each arising by two roots, an anterior or motor root, and a posterior or sensory root.

The **anterior roots** proceed from the anterior lateral sulcus, which marks the division of the anterior from the posterior part of the antero-lateral column of the spinal cord, and gradually approach towards the anterior median fissure as they descend.

The **posterior roots**, more regular than the anterior, proceed from the posterior lateral sulcus; they are larger, and the filaments of origin more numerous than those of the anterior roots; and in the intervertebral foramina there is a ganglion on each of their roots. The first cervical nerve forms an exception to these characters; its posterior root is smaller than the anterior; it often joins, in whole or in part, the spinal accessory nerve, and sometimes the hypoglossal; it has frequently no ganglion, and when the ganglion exists, it is often situated within the dura mater, the latter being the usual position also of the ganglia of the last two pairs of spinal nerves.

After the formation of a ganglion, the two roots unite, and constitute a spinal nerve, which escapes through the intervertebral foramen, and separates into an **anterior division** for the supply of the front aspect of the body, and a **posterior division** for the posterior aspect. In the first cervical, last sacral, and coccygeal nerve this division takes place within the dura mater; and in the upper four sacral nerves, externally to that cavity, but within the sacral canal. The anterior cords, with the exception of the first two cervical nerves, are larger than the posterior; an arrangement which is proportioned to the larger extent of surface they are required to supply.

Both divisions are compound—that is to say, they contain both motor and sensory filaments.

The SPINAL NERVES are classed as follows :—

Cervical	8 pairs
Dorsal	12 „
Lumbar	5 „
Sacral	5 „
Coccygeal	1 „

The cervical nerves pass off transversely from the spinal cord ; the dorsal are oblique in direction ; the lumbar and sacral, vertical ;

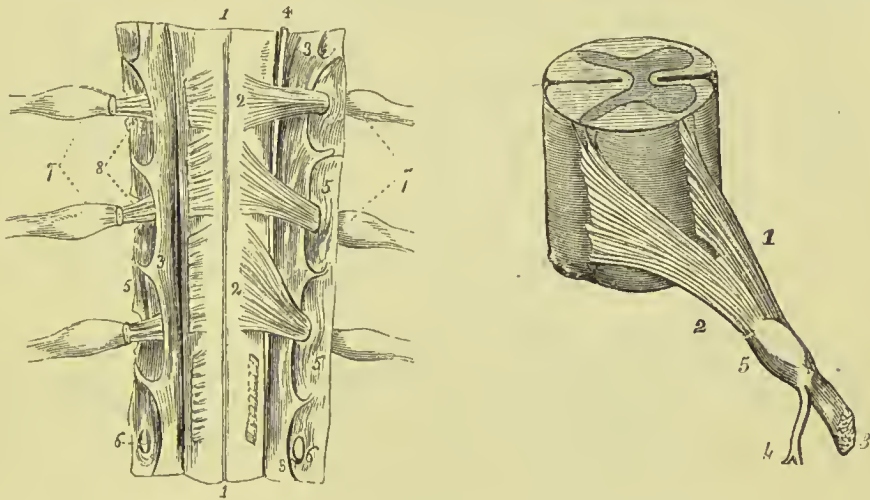


FIG. 331.—Part of the cervical portion of the spinal cord, viewed on its posterior aspect; showing its membranes and the roots of the spinal nerves. 1, 1. Posterior median fissure. 2, 2. Posterior roots of the cervical nerves; on the opposite side the corresponding roots are cut through near their origin. 3, 3. Ligamentum denticulatum. 4. Spinal accessory nerve, ascending between the posterior roots and ligamentum denticulatum. 5, 5. Dura mater. 6, 6. Openings in the dura mater for the passage of the roots of the nerve. 7, 7. Ganglia on the posterior roots. 8. Anterior roots. The posterior roots have been cut away in order to show each anterior root proceeding to join the nerve beyond the ganglion.

FIG. 332.—Roots of the spinal nerves. 1. Anterior root. 2. Posterior root. 3. Anterior division. 4. Posterior division. 5. Ganglion on the posterior root.

the latter form the large assemblage of nerves, at the termination of the cord, called **cauda equina**. The cauda equina occupies the lower third of the spinal canal.

Point of Exit of the Spinal Nerves.—The roots of the spinal nerves run obliquely downwards from the part of the cord from which each springs to the intervertebral foramen by which it emerges from the canal. The degree of obliquity varies in different regions, being greatest in the lumbar and sacral nerves, and least in the dorsal. The following table from A. Macalister's *Text-Book of*

Anatomy gives the relation of the point of origin of each nerve to the bodies and tips of the spinous processes of the vertebræ :—

Level of Body of	No. of Nerve.	Level of Tip of Spine of	Level of Body of	No. of Nerve.	Level of Tip of Spine of	
C 1	C 1	...	D 8	9	7 d	
2 }	2	...	9	10	8 d	
3 }	3	1 c	10	11	9 d	
4 }	4	2 c	...	12	10 d	
5 }	5	3 c	11	L 1	11 d	
6 }	6	4 c	...	2	...	
7 }	7	5 c	12	3	} 12 d	
D 1	D 1	7 c	...	4		
2	2	1 d	L 1	5	} ...	
3	3	...		S 1		2
4	4	2 d		3		} 1 l
5	5	3 d		4		
6	6	4 d	...	5	}	
7	7	5 d	...	C 1		
	8	6 d	L 2	

CERVICAL NERVES.

The cervical nerves increase in size from the first to the fifth, and then remain the same size to the eighth. The first (*suboccipital*) passes out of the spinal canal between the occipital bone and atlas; the second between the posterior ring of the atlas and the lamina of the axis; and the last between the last cervical and first dorsal vertebra. Each nerve, at its escape from the intervertebral foramen, divides into an anterior and a posterior division. The anterior divisions of the four upper cervical nerves form the *cervical plexus*; the posterior divisions, the *posterior cervical plexus*. The anterior divisions of the four inferior cervical together with the first dorsal form the *brachial plexus*.

ANTERIOR CERVICAL NERVES.—The anterior division of the **first cervical** or **suboccipital nerve** escapes from the spinal canal through the groove on the posterior arch of the atlas, which supports the vertebral artery, lying beneath that vessel. It descends in front of the transverse process of the atlas, sends twigs to the occipito-atlantal joint, rectus lateralis and rectus anticus minor, and forms an anastomotic loop by communicating with an ascending branch of the second nerve. Branches from this loop communicate with the pneumogastric nerve, hypoglossal nerve, and superior cervical ganglion of the sympathetic.

The anterior cord of the **second cervical nerve**, at its exit from the intervertebral foramen between the atlas and axis, gives twigs to the rectus anticus major, scalenus medius, and levator anguli scapulæ, and divides into three branches: *ascending* branch, which

completes the arch of communication with the first nerve ; and two *descending* branches, which form loops with corresponding branches of the third nerve.

The anterior cord of the **third cervical nerve**, double the size of the preceding, divides at its exit from the vertebral foramen into several branches, some of which are distributed to the rectus major, longus colli, and scalenus medius, while others communicate and form loops with the second and fourth nerves.

The anterior cord of the **fourth cervical nerve**, equal in size with the preceding, sends twigs to the rectus major, longus colli, and levator anguli scapulae, communicates with the third, and sends a small branch downwards to the fifth nerve. Its principal branches pass downwards and outwards across the posterior triangle of the neck, towards the clavicle and acromion.

The anterior cords of the **fifth, sixth, seventh, and eighth** cervical nerves will be described with the brachial plexus, of which they form a part.

CERVICAL PLEXUS.—The cervical plexus is constituted by loops of communication between the anterior divisions of the first four cervical nerves. The plexus rests on the levator anguli scapulae, posterior and middle scalenus, and splenius colli muscle, and is covered by the sterno-mastoid and platysma.

The **branches** of the cervical plexus may be arranged into superficial and deep :—

Superficial	{	<i>Ascending,</i>	{	Superficialis colli, Auricularis magnus, Occipitalis minor.
		<i>Descending,</i>	{	Acromial, Clavicular, Sternal.
Deep	{	Communicating branches, Communicans cervicis, Muscular, Phrenic.		

The **superficialis colli** is formed by communicating branches from the second and third cervical nerves ; it curves around the posterior border of the sterno-mastoid, and crosses obliquely behind the external jugular vein to the anterior border of that muscle, where it pierces the deep cervical fascia and divides into an ascending and a descending branch.

The *ascending branch* passes upwards to the submaxillary region, and divides into four or five filaments, some of which pierce the platysma myoides, and supply the integument as high as the chin and lower part of the face ; while others form a plexus with the inframaxillary branches of the facial nerve beneath the platysma. One or two filaments from this branch accompany the external jugular vein.

The *descending branch* pierces the platysma, and is distributed to

the integument of the front of the neck as far downwards as the sternum.

The **auricularis magnus**, the largest of the three ascending branches of the cervical plexus, also proceeds from the second and third cervical nerves; it curves around the posterior border of the sterno-mastoid, and ascends upon that muscle, lying parallel with the external jugular vein, to the parotid gland, where it divides into an anterior and a posterior branch.

The *anterior branch* is distributed to the integument over the parotid gland, and to the gland itself, communicating with the facial nerve.

The *posterior branch* ascends behind the ear, where it divides into *auricular branches*, supplying the pinna; and a *mastoid branch* which communicates with the posterior auricular branch of the facial and is distributed to the integument behind the ear. The auricular branches communicate with the auricular offsets of the facial nerve, pneumogastric nerve, and occipitalis minor.

The **occipitalis minor** arises from the second cervical nerve; it curves around the posterior border of the sterno-mastoid above the preceding, and ascends upon that muscle, parallel with its posterior border, to the lateral and posterior aspect of the cranium. It is distributed to the integument, to the occipital portion of the occipito-frontalis and attollens auriculam, and communicates with the occipitalis major, auricularis magnus, and posterior auricular branch of the facial.

Superficial Descending Branches.—The *acromial* and *clavicular* are two or three large nerves which proceed from the fourth cervical nerve, and pass downwards in the posterior triangle of the neck; they pierce the deep fascia, and crossing the clavicle are distributed to the integument of the front of the chest as low down as the nipple line, from the sternum to the acromion; hence their designation, *clavicular* and *acromial*. The most anterior of the branches is named *sternal*, from its destination, and the outermost branch passes over the clavicular attachment of the trapezius, to reach the shoulder.

Deep Branches.—The *communicating branches* are filaments which arise from the loop between the first and second cervical nerves, and pass inwards to communicate with the sympathetic, pneumogastric, and hypoglossal nerves. The first three cervical nerves send branches to the first cervical ganglion; the fourth sends a branch to the trunk of the sympathetic, or to the middle cervical ganglion. From the second cervical nerve a large branch is given off, which joins the spinal accessory nerve.

The **communicans cervicis** (*communicans noni*) is a long and slender branch of communication between the cervical plexus and descendens cervicis; it is formed by filaments from the second and third cervical nerves, descends at the outer side of the internal jugular vein, and forms a loop with the descendens cervicis over the sheath of the carotid vessels.

The **muscular branches** of the cervical plexus are distributed

to the muscles of the front of the vertebral column and side of the neck. From the loop, between the first and second nerve, branches are given to the anterior recti; from the *second* cervical nerve a branch proceeds to the sterno-mastoid; from the *third* and *fourth* nerve branches are distributed to the trapezius, levator anguli scapulæ, scalenus medius, and scalenus posticus. The branch to the trapezius communicates with the spinal accessory nerve.

The **phrenic nerve** (internal respiratory of Bell) is formed by the union of filaments from the fourth and fifth cervical nerves, and is joined by a communication from the combined cord of the fifth and sixth and a filament from the sympathetic. It descends to the root of the neck, resting on the scalenus anticus muscle, crosses the first portion of the subclavian artery, and enters the chest between it and the subclavian vein, passing over the commencement of the internal mammary artery. Within the chest it passes downwards through the middle mediastinum, lying between the pleura and pericardium, and in front of the root of the lung, to the diaphragm; near the diaphragm it divides into branches which pierce that muscle, and are distributed on its under surface. Some of its filaments reach the abdomen through the openings for the œsophagus and vena cava, and communicate with the phrenic and solar plexus, and on the right side with the hepatic plexus. The *left phrenic nerve* is longer than the right, from the inclination of the heart to the left side, and crosses the arch of the aorta. The *right nerve* is situated more deeply in the upper part of the chest than the left, and lies in contact with the right innominate vein and superior vena cava; at its termination it forms a plexus with branches derived from the solar plexus, and in this there is usually a small ganglion (*phrenic ganglion*). Each nerve is accompanied by the *arteria comes nervi phrenici*, a branch of the internal mammary, and by two veins.

POSTERIOR CERVICAL NERVES.—The posterior divisions of the *cervical nerves* issue from between the transverse processes, and divide into an internal and external branch. The *internal* branch is directed inwards towards the middle of the spine, and, becoming cutaneous near the spinous processes of the vertebræ, is then reflected outwards to supply the integument. The *external* branch, smaller than the internal, is distributed to the muscles of the outer portion of the vertebral groove.

The posterior division of the **first cervical nerve** (suboccipital), larger than the anterior, escapes from the spinal canal through the opening for the vertebral artery, lying posteriorly to that vessel, and emerges in the suboccipital triangle. It is distributed to the recti, obliqui, and complexus, and sends a branch downwards to communicate with the second cervical nerve; it has no external branch.

The posterior cord of the **second cervical nerve** is three or four times larger than its anterior cord, and exceeds in size the other posterior cervical nerves. Its *internal branch* is the **occipitalis major nerve**.

The posterior cord of the **third cervical nerve** is smaller than the second, but larger than the fourth; its *internal branch* gives off a cutaneous branch to the back of the cranium.

The posterior cords of the remaining cervical nerves go on progressively decreasing in size to the seventh.

The **internal branches** of the **second, third, fourth, and fifth** nerves lie on the semispinalis colli muscle, and are closely connected with a fascia which separates that muscle from the complexus. The second and third, with a branch from the first, constitute the **posterior cervical plexus**; and all the branches in their course to the surface pierce the complexus and trapezius, and some the splenius.

The **internal branches** of the **sixth, seventh, and eighth** nerves pass beneath the semispinalis colli, which they supply, as they also do the interspinales, multifidus spinæ, and complexus; finally they send twigs through the latter muscle to supply the skin over the spinous processes of the lower cervical vertebræ.

The **occipitalis major nerve**, the internal branch of the posterior cord of the second cervical nerve, ascends obliquely inwards between the obliquus inferior and complexus, pierces the complexus and trapezius after passing for a short distance between them, and ascends the posterior aspect of the head in company with the occipital artery. Soon after its escape from the trapezius, it receives a branch from the third cervical, and divides into numerous branches, which are distributed to the occipitalis muscle and to the integument as far as the summit of the head. It communicates with the occipitalis minor nerve, and sends an *auricular* branch to the back of the ear.

BRACHIAL PLEXUS.

The brachial or axillary plexus of nerves is formed by communications between the anterior divisions of the four lower cervical nerves and first dorsal. These nerves are alike in size, and their mode of disposition in the formation of the plexus is as follows: the fifth and sixth unite to form a common trunk, the eighth and first dorsal unite in like manner, the seventh runs alone; each of these three trunks then divides into an anterior and posterior branch. The anterior branch of the trunk derived from the fifth and sixth receives the anterior branch of the seventh, and these together form the **outer cord**. The anterior branch of the trunk formed by the eighth and first dorsal constitutes the **inner cord**. The three posterior branches unite to form the **posterior cord**.

The plexus is broad in the neck, narrows as it descends into the axilla, and again enlarges at its lower part, where it divides into its terminal branches.

The brachial plexus communicates with the cervical plexus by means of a branch from the fourth to the fifth nerve, and receives branches from the two inferior cervical ganglia of the sympathetic.

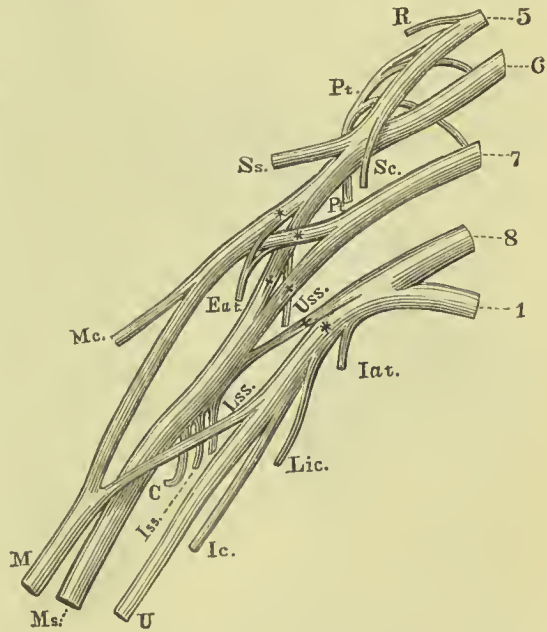
The plexus is in relation in the neck with the scaleni muscles;

lower down it is placed between the clavicle and subclavius muscle above, and the first rib and first serration of the serratus magnus muscle below. In the axilla, it is situated at first to the outer side of and then behind the axillary artery, resting by its outer border against the tendon of the subscapularis muscle. Lower down it completely surrounds the artery.

The **branches** of the brachial plexus are: from the **outer cord**, one of the anterior thoracic nerves, the musculo-cutaneous nerve, and the outer head of the median; from the **inner cord**, the other anterior thoracic nerve, inner head of the median, internal cutaneous, lesser internal cutaneous of Wrisberg, and ulnar; from the **posterior cord**, the subscapular nerves, circumflex, and musculo-spiral.

Besides these, the brachial plexus, while in the neck, gives off several *superior muscular branches*: one to the subclavius muscle,

FIG. 333.—Nerves forming the brachial plexus. The numerals 5, 6, 7, 8, and 1, refer to the four lower cervical and first dorsal nerves. *R.* Nerve to the rhomboid muscles. *Pt.* Posterior or long thoracic. *Ss.* Supra-scapular. *Sc.* Nerve to the subclavius. *Uss.* Upper subscapular. *Lss.* Long subscapular. *Iss.* Inferior subscapular. *Eat.* External anterior thoracic. *Iat.* Internal anterior thoracic. *Mc.* Musculo-cutaneous. *M.* Median. *Ms.* Musculo-spiral. *U.* Ulnar. *Ic.* Internal cutaneous. *Lic.* Lesser internal cutaneous. *** Anterior and (††) posterior branches of the three primary trunks. *C.* Circumflex.



one to the rhomboid muscles and levator anguli scapulæ; one of large size, the *suprascapular*; and a long and slender nerve which passes down the thoracic wall of the axilla, the *posterior thoracic* or external respiratory nerve of Bell.

The spinal nerves with which each of the nerves of the brachial plexus is connected are shown in the subjoined table; the higher numbers refer to the cervical nerves, the unit to the dorsal nerve:—

Subscapular	} from 5, 6, 7, 8.	Ulnar	8, 1, or 7, 8, 1.
Circumflex		Internal cutaneous	} 8, 1.
Musculo-spiral		Lesser internal cutaneous	
External cutaneous	5, 6, 7,	Anterior thoracic	{ Outer 5, 6, 7.
Median	5, 6, 7, 8, 1.		{ Inner 8, 1.

The **anterior thoracic nerves**, two in number, proceed, one from the external cord of the plexus, the other from the internal cord. The former, the *external* or superficial branch, crosses the axillary artery in the space above the pectoralis minor to the front of the chest, and is distributed to the pectoralis major muscle. The

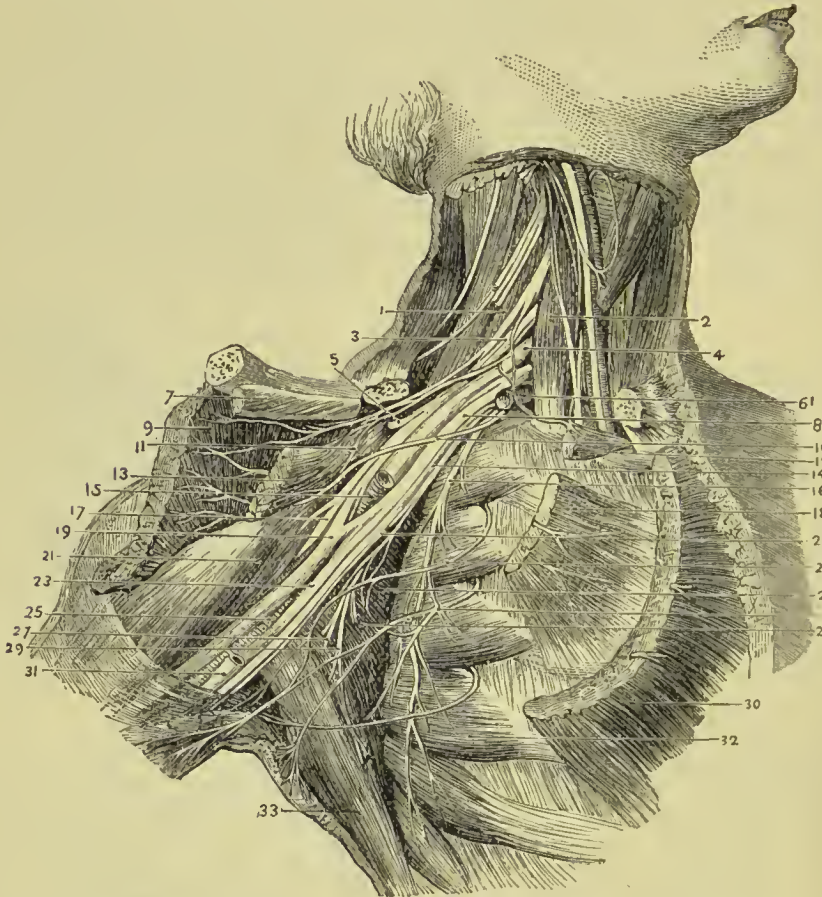


FIG. 334.—The nerves of the axilla. 1. Scalenus medius. 2. Scalenus anticus. 3. Cord formed by fifth and sixth cervical nerves. 4. Seventh cervical nerve. 5. Suprascapular nerve. 6. Subclavian artery (cut). 7. Insertion of subclavius. 8. Cord formed by eighth cervical and first dorsal nerves. 9. Pectoralis major (reflected). 10. Internal anterior thoracic nerve. 11. External anterior thoracic nerve. 12. Origin of subclavius. 13. Pectoralis minor (reflected). 14. Internal cutaneous nerve. 15. Axillary artery (cut). 16. Posterior thoracic nerve (Bcll). 17. Musculo-cutaneous nerve. 18. Origin of pectoralis minor. 19. Median nerve. 20. Nerve of Wrisberg. 21. Coraco-brachialis. 22. Intercosto-humeral nerve. 23. Ulnar nerve. 24. Subscapularis. 25. Brachial artery. 26. Lateral cutaneous branch of third intercostal nerve. 27. Middle subscapular nerve. 28. Short subscapular nerve. 29. Long subscapular nerve. 30. Pectoralis major (cut). 31. Basilic vein. 32. Serratus magnus. 33. Latissimus dorsi.

internal or deeper branch issues from between the axillary artery and vein, and after forming a loop of communication with the preceding is distributed to the under surface of the pectoralis minor and major, generally piercing the former to reach the latter.

The **posterior thoracic**, or external respiratory of Bell, is formed by the junction of two offsets, one from the fifth, the other from the sixth cervical nerve ; it crosses behind the brachial plexus to reach the side of the chest, and descends on the serratus magnus to the lower part of that muscle, to which it is distributed.

The **superior muscular nerves** are small branches to the longus colli and scilicet, and branches to the rhomboidei and subclavius.

The **rhomboid branch** proceeds from the fifth cervical nerve, and passing backwards through the fibres of the scalenus medius, and beneath the levator anguli scapulæ, is distributed to the under surface of the rhomboid muscles. In its course it sometimes gives a branch to the levator anguli scapulæ.

The **subclavian branch**, proceeding from the cord formed by the fifth and sixth nerve, descends in front of the subclavian artery, to the subclavius muscle. This nerve usually communicates with the phrenic at its entrance into the chest.

The **suprascapular nerve** arises from the trunk formed by the union of fifth and sixth cervical nerves and proceeds obliquely outwards, along with the artery of the same name, to the suprascapular notch ; it passes through the notch, crosses the supra-spinous fossa beneath the supra-spinatus muscle, and running in front of the concave margin of the spine of the scapula enters the infra-spinous fossa, to be distributed to the supra-spinatus and infra-spinatus muscles, and sends two or three filaments to the shoulder-joint.

The **subscapular nerves** are three in number ; one arises from the brachial plexus above the clavicle, the others from the posterior cord of the plexus within the axilla. The first or smallest supplies the upper part of the subscapularis muscle ; the second and largest (*long subscapular*) follows the course of the subscapular artery, and is distributed to the latissimus dorsi ; the third supplies the lower part of the subscapularis muscle and teres major.

BRACHIAL NERVES.—The brachial branches of the plexus are arranged in the following order : musculo-cutaneous, and one head of the median to the outer side of the artery ; the other head of the median, internal cutaneous, lesser internal cutaneous, and ulnar, to its inner side ; the circumflex and musculo-spiral behind.

The **MUSCULO-CUTANEOUS NERVE** (external cutaneous, perforans Casserii) arises from the brachial plexus in common with the external head of the median ; pierces the coraco-brachialis muscle, and passes between the biceps and brachialis anticus to the outer side of the bend of the elbow, where it perforates the deep fascia, and divides into an anterior and posterior branch. These branches pass behind the median cephalic vein ; the *anterior*, the larger of the two, runs along the radial border of the forearm and communicates with the radial nerve on the back of the hand ; the *posterior* and smaller is distributed to the back of the forearm, communicating with the internal cutaneous, and distributes filaments to the synovial membranes of the wrist-joint.

The musculo-cutaneous nerve supplies the coraco-brachialis, biceps,

and brachialis anticus in the upper arm, and the integument of the outer side of the forearm as far as the wrist and hand. It also gives a branch to the elbow-joint, and another which accompanies the nutrient artery to the interior of the humerus.

The **INTERNAL CUTANEOUS NERVE**, one of the internal and smaller branches of the brachial plexus, arises from the plexus in common with the ulnar and internal head of the median, and passes down the inner side of the arm in company with the basilic vein, giving off several cutaneous filaments in its course. At about the middle of the upper arm it pierces the deep fascia by the side of the basilic vein and divides into two branches, anterior and posterior. The *anterior branch*, the larger of the two, divides into several branches which pass in front of, and sometimes behind the median basilic vein at the bend of the elbow, and descend in the course of the palmaris longus muscle to the wrist, distributing filaments to the integument in their course and communicating with the anterior branch of the musculo-cutaneous on the outer side, and its own internal branch on the inner side of the forearm. The *posterior branch* sends off several twigs to the integument over the inner condyle and olecranon, passes behind the inner condyle, and descends the forearm in the course of the ulnar vein as far as the wrist, supplying the integument of the inner side of the forearm, and communicating with the external branch of the same nerve in front, and the dorsal branch of the ulnar nerve at the wrist.

The **LESSER INTERNAL CUTANEOUS NERVE**, or **nerve of Wrisberg**, the smallest of the brachial nerves, arises with the preceding from the inner cord of the plexus, and issuing from beneath the axillary vein descends the inner side of the arm, to the middle of its posterior aspect, where it pierces the fascia and is distributed to the integument of the lower third of the upper arm as far as the olecranon. While in the axilla, the nerve of Wrisberg communicates with the intercosto-humeral nerve, and sometimes its place is taken by the latter. It also communicates with the posterior branch of the internal cutaneous nerve.

The **MEDIAN NERVE**, named from its median position in the arm and forearm, arises by two heads which proceed from the outer and inner cord of the plexus and embrace the axillary artery. The nerve lies at first to the outer side of the brachial artery, but crosses it in the middle, sometimes in front and sometimes behind, and getting to its inner side descends to the bend of the elbow. It next passes between the two heads of the pronator radii teres and beneath the flexor sublimis digitorum, and runs down the middle of the forearm, lying between the latter muscle and the flexor profundus to the wrist. It then dips beneath the annular ligament and enters the palm of the hand. Just above the wrist it is superficial, lying between the tendons of the flexor carpi radialis and flexor sublimis digitorum. In the forearm the nerve is accompanied by a small branch of the anterior interosseous artery.

The **branches** of the median nerve are—

Muscular,
Anterior interosseous,

Superficial palmar,
Digital.

The **muscular branches** are given off by the nerve at the bend of the elbow; they are distributed to all the muscles of the anterior aspect of the forearm, with the exception of the flexor carpi ulnaris, and ulnar half of the flexor profundus. The branch to the pronator radii teres sends off reflected filaments to the elbow-joint.

The **anterior interosseous** is a large branch accompanying the anterior interosseous artery, and supplying the deep layer of muscles and the bones of the forearm, being lost inferiorly in the pronator quadratus. From its lower end a small twig is given off to the front of the wrist-joint.

The **superficial palmar branch** arises from the median at about the lower fourth of the forearm; it crosses the annular ligament, and is distributed to the integument of the palm of the hand, and ball of the thumb.

The median nerve as it enters the palm of the hand is of a

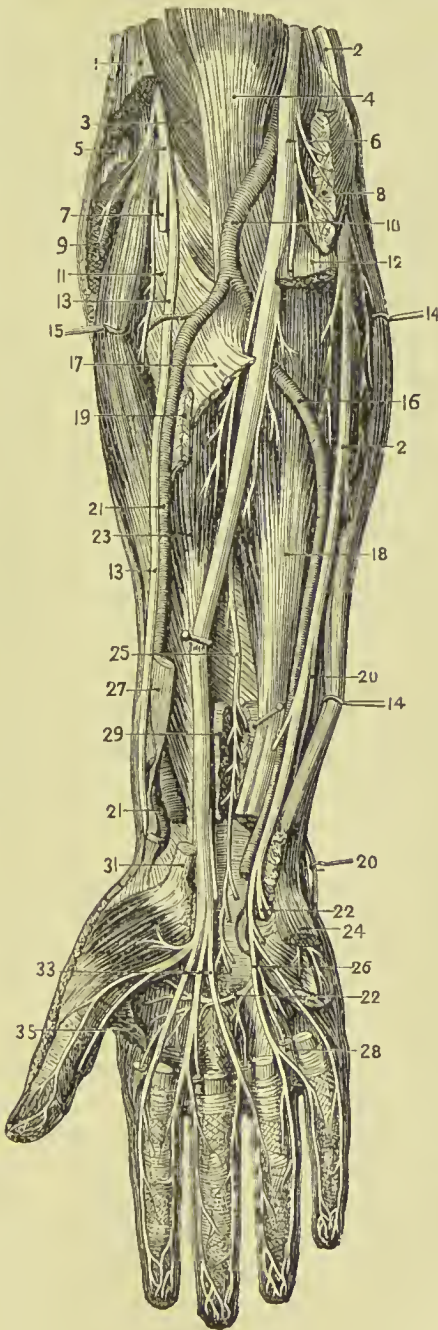


FIG. 335.—Deep dissection of the front of the forearm and hand. 1. Supinator longus (cut). 2, 2. Ulnar nerve. 3. Brachialis anticus. 4. Biceps. 5. Musculo-spiral nerve. 6. Median nerve. 7. Posterior interosseous nerve. 8. Pronator teres and flexor carpi radialis (cut). 9. Extensor carpi radialis longior (cut). 10. Brachial artery. 11. Supinator brevis. 12. Flexor sublimis digitorum (cut). 13, 13. Radial nerve. 14, 14. Flexor carpi ulnaris. 15. Extensor carpi radialis brevis. 16. Ulnar artery. 17. Radial origin of flexor sublimis digitorum (cut). 18. Flexor profundus digitorum. 19. Tendon of pronator teres. 20, 20. Dorsal branch of ulnar nerve. 21, 21. Radial artery. 22, 22. Deep branch of ulnar nerve. 23. Flexor longus pollicis. 24. Abductor minimi digiti. 25. Anterior interosseous nerve. 26. Digital branches of ulnar nerve. 27. Tendon of supinator longus. 28. One of the lumbricalis muscles. 29. Pronator quadratus. 31. Tendon of flexor carpi radialis. 33. Digital branches of median nerve. 35. Adductor pollicis.

reddish colour and is spread out and flattened ; it divides into six branches, one muscular and five digital.

The **muscular branch** is distributed to the abductor pollicis, flexor ossis metacarpi pollicis, and radial half of the flexor brevis pollicis.

The **digital branches** are arranged as follows : *two* pass outwards to the thumb and supply its borders ; the *third* runs along the radial side of the index finger, sending a twig to the first lumbricalis in its course ; the *fourth* subdivides for the supply of the adjacent sides of the index and middle finger, and gives a twig to the second lumbricalis ; the *fifth* receives a filament of communication from the ulnar nerve, and supplies the collateral branches of the middle and ring fingers.

Opposite the base of the first phalanx, each nerve gives off a *dorsal branch* which runs along the border of the dorsum of the finger. Near its extremity the nerve divides into a *palmar* and a *dorsal* branch ; the former supplying the sentient extremity of the finger, the latter the structures around and beneath the nail. The digital nerves in their course along the fingers lie to the inner side of and superficially to the arteries ; and the nerve of one side of a finger has no communication with that of the opposite side.

It will be observed that the median nerve supplies all the muscles of the front of the forearm except the flexor carpi ulnaris and half the flexor profundus digitorum. In the hand it gives branches to those muscles of the thumb which lie to the radial side of the tendon of the flexor longus pollicis, and the two outer lumbricales ; the latter muscles are supplied by this nerve because they are connected with the tendons of that portion of the flexor profundus which derives its nerve supply from the median. The digital branches are distributed to the palmar aspect of the thumb, index, middle, and half the ring fingers.

The **ULNAR NERVE** is somewhat smaller than the median, behind which it lies, gradually diverging from it in its course. It arises from the inner cord of the brachial plexus in common with the internal head of the median and internal cutaneous nerve, and runs down the inner side of the arm, piercing the internal intermuscular septum from before backwards, to the groove between the internal condyle and olecranon, resting on the internal head of the triceps, and accompanied by the inferior profunda artery. At the elbow it is superficial, and supported by the inner condyle, against which it may be compressed, giving rise to the thrilling sensation along the inner side of the forearm and little finger, popularly ascribed to striking the "funny bone." It then passes between the two heads of the flexor carpi ulnaris, and descends along the inner side of the forearm, crosses the annular ligament with the ulnar artery, and divides into two branches, superficial and deep palmar. At the commencement of the middle third of the forearm it comes into relation with the artery, and lies to the ulnar side of that vessel, as far as the hand.

The **branches** of the ulnar nerve are—

Articular,	Dorsal branch,
Muscular,	Superficial palmar,
Cutaneous,	Deep palmar.

The **articular branches** are several filaments to the elbow-joint, given off from the nerve while lying in the groove between the inner condyle and olecranon.

The **muscular branches** are distributed to the flexor carpi ulnaris and ulnar half of the flexor profundus digitorum.

The **cutaneous branch** proceeds from about the middle of the nerve, and descends upon the ulnar artery to the hand, giving twigs to the integument in its course. One branch from its upper part, sometimes a separate offset from the nerve and sometimes absent, pierces the fascia, and communicates with the internal cutaneous nerve.

The **dorsal branch** passes backwards beneath the tendon of the flexor carpi ulnaris, at the lower fourth of the forearm, and divides into branches which supply the integument and two fingers and a half on the posterior aspect of the hand, communicating with the radial nerve, with which it forms an arch.

The **superficial palmar branch**, after giving some twigs to the palmaris brevis and inner border of the hand, divides into three filaments, two of which are distributed, *one* to the ulnar side of the little finger, and *one* to the adjoining borders of the little and ring fingers, while the third, a *communicating branch*, joins the median nerve.

The **deep palmar branch** passes between the abductor and flexor minimi digiti, to the deep palmar arch, supplying the muscles of the little finger, interossei, two ulnar lumbricales, adductor pollicis, and inner head of the flexor brevis pollicis.

The ulnar nerve supplies in the forearm the flexor carpi ulnaris and half the flexor profundus digitorum; in the hand it supplies all the muscles of the palm which lie to the ulnar side of the tendon of the long flexor of the thumb except the two radial lumbricales. Its cutaneous branches are distributed to one and a half fingers on the front and two and a half on the back of the hand.

The **MUSCULO-SPIRAL NERVE**, the largest branch of the brachial plexus, arises from its posterior trunk in common with the circumflex, and, descending behind the axillary and brachial artery, winds around the humerus between the triceps and the bone, and in company with the superior profunda artery, pierces the external intermuscular septum from behind forwards to reach the space between the brachialis anticus and supinator longus, and runs thence onwards to the bend of the elbow, where it divides into two branches, radial and posterior interosseous.

The **branches** of the musculo-spiral nerve are—

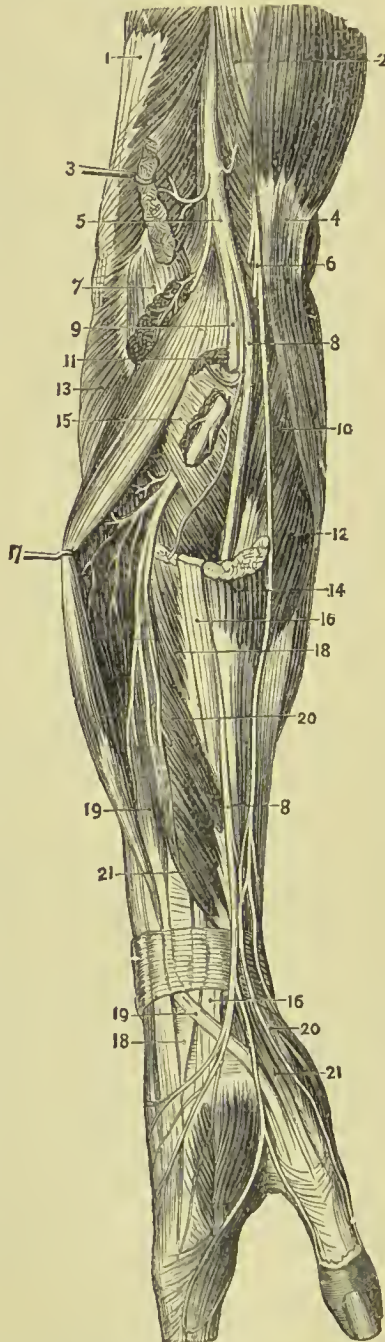
Muscular,	Radial,
Cutaneous,	Posterior interosseous.

The **muscular branches** are distributed to the triceps, anconeus, brachialis anticus, supinator longus, and extensor carpi radialis longior.

The **cutaneous branches** are three in number, internal and two external. The *internal branch* arises from the nerve in the axilla, and piercing the deep fascia in the upper third of the arm on its posterior aspect, communicates with the intercosto-humeral nerve, and is distributed to the integument of the posterior aspect of the upper arm, as far as the olecranon.

FIG. 336. — Dissection of the musculo-spiral nerve and its branches.

1. Triceps.
2. Brachialis anticus.
3. Supinator longus.
4. Biceps.
5. Musculo-spiral nerve.
6. Musculo-cutaneous nerve.
7. Origin of extensor carpi radialis longior.
- 8, 8. Radial nerve.
9. Posterior interosseous nerve.
10. Pronator radii tercis.
11. Origin of extensor carpi radialis brevior.
12. Flexor carpi radialis.
13. Anconeus.
14. Tendon of supinator longus.
15. Supinator brevis.
- 16, 16. Tendon of extensor carpi radialis longior.
17. Extensor communis digitorum.
- 18, 18. Tendon of extensor carpi radialis brevior.
- 19, 19. Extensor secundi internodii pollicis.
- 20, 20. Extensor ossis metacarpi pollicis.
- 21, 21. Extensor primi internodii pollicis.



The *external cutaneous branches* pass through the substance of the external head of the triceps, and pierce the deep fascia; one, *upper*, near the insertion of the deltoid, the other, *lower*, at about the middle of the upper arm. The *upper branch* follows the course of the cephalic vein, supplying the integument of the outer and fore-part of the upper arm as far as the bend of the elbow. The *lower branch* passes down the outer side of the forearm, reaches the posterior aspect at about its middle, and is continued on-

wards to the wrist, where it communicates with the posterior branch of the musculo-cutaneous.

wards to the wrist, where it communicates with the posterior branch of the musculo-cutaneous.

The **radial nerve** runs along the radial side of the forearm to the commencement of its lower third ; it there passes beneath the tendon of the supinator longus, and, at about two inches above the wrist-joint, pierces the deep fascia and divides into an external and internal branch.

The *external branch*, the smaller of the two, is distributed to the outer border of the thumb, and communicates with the posterior branch of the musculo-cutaneous nerve. The *internal branch* crosses the direction of the extensor tendons of the thumb, and divides into several filaments for the supply of the ulnar border of the thumb, radial border of the index finger, and adjacent borders of the index and middle fingers. It communicates above the wrist with the posterior branch of the musculo-cutaneous nerve, and on the back of the hand forms an arch by joining with the dorsal branch of the ulnar nerve. On the backs of the fingers the digital branches communicate with those of the median nerve.

In the upper third of the forearm the radial nerve lies beneath the border of the supinator longus muscle ; in the middle third it is in relation with the radial artery, lying to its outer side ; and in the lower third it quits the artery, and passes beneath the tendon of the supinator longus to reach the back of the hand.

The radial nerve is purely cutaneous in its distribution, giving no branches to muscles.

The **posterior interosseous nerve**, somewhat larger than the radial, separates from the latter at the bend of the elbow, pierces the supinator brevis muscle and emerges from its lower border on the posterior aspect of the forearm, where it divides into branches which supply all the muscles of the posterior aspect of the forearm, with the exception of the anconeus, supinator longus, and extensor carpi radialis longior. In passing from the front to the back of the forearm it winds round the outer side of the radius, and does not pass between the two bones as the posterior interosseous artery does. One branch, longer than the rest, descends upon the interosseous membrane to the posterior part of the wrist, and forms a gangliform swelling (a common character of nerves which supply joints), from which numerous filaments are distributed to the wrist-joint and to the metacarpo-phalangeal articulations.

The **CIRCUMFLEX NERVE** arises from the posterior cord of the brachial plexus in common with the musculo-spiral. It passes downwards over the border of the subscapularis muscle, winds around the neck of the humerus with the posterior circumflex artery, and splits into an upper and lower division ; the upper division is continued onwards beneath the deltoid, and distributed to the anterior part of that muscle, some of its branches piercing the muscular fibres and becoming cutaneous. The lower division sends a branch (remarkable for a gangliform swelling) to the teres minor, several branches to the posterior part of the deltoid, and mounting upon the border of that muscle becomes *cutaneous*, supplying the integument over its lower half by means of several filaments. Besides its

muscular and cutaneous branches, the trunk of the nerve gives off an *articular* branch, which enters the shoulder-joint at its posterior and under part.

DORSAL NERVES.

The dorsal nerves are twelve in number at each side, the first appearing between the first and second dorsal vertebra, the last between the twelfth dorsal and first lumbar. They are smaller than the lower cervical nerves, diminish gradually in size from the first to the tenth, and then increase to the twelfth. Each nerve, as soon as it has escaped from the intervertebral foramen, separates into an anterior and posterior division; the anterior divisions being the intercostal nerves, the posterior the dorsal branches of the dorsal nerves.

The **dorsal branches** pass directly backwards between the transverse processes of the vertebræ, lying internally to the anterior costo-transverse ligament, and each nerve divides into an *internal* and *external* branch. The *internal branches* diminish in size from the first to the last. The six upper branches pass inwards between the semi-spinalis dorsi and multifidus spinæ, and, piercing the rhomboid, trapezius, and latissimus dorsi, become cutaneous close to the spinous processes, and are then reflected outwards to supply the integument. The six lower branches are lost in the muscles of the spine.

The *external branches* increase in size from above downwards, and make their appearance in the line of separation between the longissimus dorsi and sacro-lumbalis. The six upper branches are distributed to those muscles and the levatores costarum. The six lower, after supplying the same muscles, pierce the serratus posticus inferior and latissimus dorsi in a line with the angles of the ribs, and becoming *cutaneous*, are directed downwards and forwards over the side of the trunk.

INTERCOSTAL NERVES.—The *anterior cords* of the dorsal nerves, twelve in number at each side, are the **intercostal nerves**. Each intercostal nerve passes outwards in the intercostal space in company with the intercostal vessels, below which it lies; at the commencement of its course it rests on the external intercostal muscle; farther outwards it is placed between the two planes of intercostal muscles; beyond the middle of the rib it enters the substance of the internal intercostal and reaches its inner surface, being in contact with the pleura; finally, at the anterior extremity of the intercostal space, it crosses in front of the triangularis sterni and internal mammary vessels, and piercing the internal intercostal muscle and pectoralis major, is distributed to the integument of the front of the chest and mammary gland, under the name of **anterior cutaneous**. The intercostal nerve, near its origin, sends one or two filaments to the neighbouring dorsal ganglion of the sympathetic, and midway between the vertebral column and sternum, while situated between the intercostal muscles, gives off a **lateral**

cutaneous branch which pierces the external intercostal muscle and divides into an anterior and posterior twig for the supply of the integument of the side of the thorax.

Abdominal Intercostals.—This description applies in full only to the six upper intercostal nerves; the six lower, with the exception of the last, cross the cartilages of the ribs where the thorax is deficient and take their course between the internal oblique and transversalis muscles to the sheath of the rectus, and, after supplying that muscle, to the linea alba, by the side of which they reach the integument constituting the **anterior cutaneous nerves** of the abdomen.

The first and the last intercostal nerves are exceptions to this general scheme of distribution. The *first* ascends over the first rib to join the brachial plexus, and gives off only a small branch, to take the usual course of the other intercostal nerves. The *last* or *twelfth nerve* lies below the last rib, and after crossing the quadratus lumborum takes its course between the internal oblique and transversalis muscle like the other inferior intercostals. Near its origin it sends a branch, the *dorsi-lumbar*, downwards to join the first lumbar nerve.

The **branches** of the intercostal nerves are—muscular, lateral cutaneous, and anterior cutaneous.

The **muscular branches** are small twigs distributed to the intercostal and neighbouring muscles.

The **lateral cutaneous nerves**, given off from the intercostals at about the middle of the lateral half of the thorax, pierce the external intercostal muscle and pass between the fibres of the serratus magnus above and the obliquus externus below to reach the surface. The lateral cutaneous nerve then divides into an anterior and posterior branch. The *anterior branches* are directed forwards to supply the integument of the antero-lateral aspect of the trunk, some of the superior branches turning around the inferior border of the pectoralis major to the mammary gland. The *posterior branches* take their course backwards to supply the integument of the posterolateral aspect of the trunk, some of the superior turning around the posterior border of the axilla to reach the integument over the lower part of the scapula and latissimus dorsi; and that from the third intercostal being distributed to the integument of the axilla and neighbouring part of the arm.

The first intercostal gives off no lateral cutaneous nerve; the lateral cutaneous branch of the second intercostal nerve will be presently described, under the name of *intercosto-humeral nerve*. The lateral cutaneous branch of the last intercostal nerve pierces the internal and external oblique muscle, crosses the crest of the ilium just behind the tensor vaginæ femoris, and is distributed to the integument of the anterior part of the gluteal region as low down as the trochanter major.

The **anterior cutaneous nerves** are divided according to their position into those of the thorax and those of the abdomen. Having

reached the surface they are reflected outwards to supply the integument of the front of the trunk. The anterior cutaneous branches of

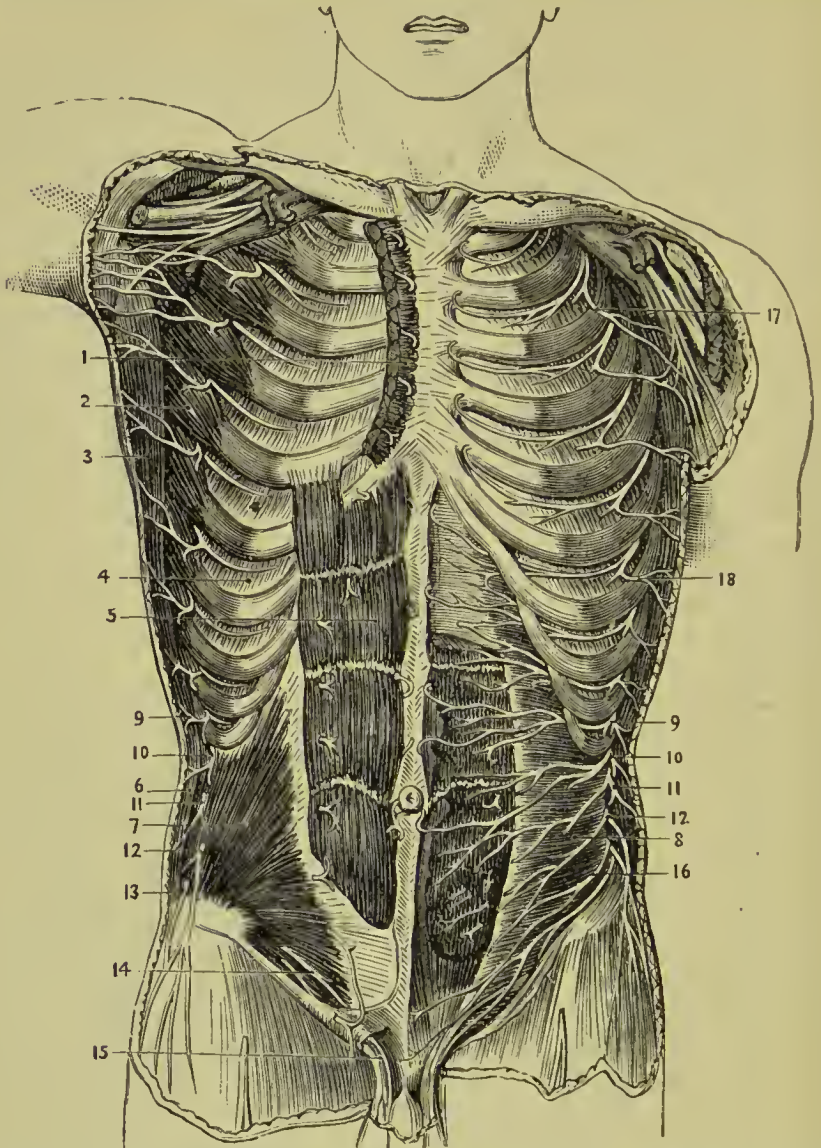


FIG. 337.—The nerves of the abdominal wall. 1. Pectoralis major (cut). 2. Serratus magnus. 3. Latissimus dorsi. 4. Intercostal muscles. 5. Rectus abdominis. 6. Section of obliquus externus. 7. Obliquus internus. 8. Transversalis abdominis. 9, 9. Ninth dorsal nerve. 10, 10. Tenth dorsal nerve. 11, 11. Eleventh dorsal nerve. 12, 12. Twelfth dorsal nerve. 13. Iliac branch of ilio-hypogastric. 14. Hypogastric branch of ilio-hypogastric. 15. Inguinal branch of ilio-inguinal. 16. Ilio-hypogastric and ilio-inguinal nerves. 17. Intercosto-humeral nerve. 18. Lateral cutaneous branch of intercostal nerve.

the third and fourth intercostal nerves are distributed to the mammary gland.

The **intercosto-humeral nerve** is the posterior division of the

lateral cutaneous branch of the second intercostal nerve ; after piercing the external intercostal muscle, it passes downwards into the axilla and communicates with a branch of the lesser internal cutaneous nerve of Wrisberg. It then perforates the deep fascia, and is distributed to the integument of the inner and back part of the arm to about the middle, and to the integument covering the lower part of the scapula. On the back of the arm it communicates with the internal cutaneous branch of the musculo-spiral nerve. This nerve sometimes takes the place of the nerve of Wrisberg.

LUMBAR NERVES.

There are five pairs of lumbar nerves, of which the first makes its appearance between the first and second lumbar vertebra ; the last between the fifth lumbar and the base of the sacrum. The **anterior divisions** increase in size from above downwards. They communicate at their origin with the lumbar ganglia of the sympathetic, and pass obliquely outwards behind the psoas magnus, or between its fasciculi, sending twigs to that muscle and to the quadratus lumborum. In this situation each nerve divides into two branches, a superior branch which ascends to form a loop of communication with the nerve above ; and an inferior branch which descends to join in like manner the nerve below. The communications which are thus established constitute the **lumbar plexus**.

The **posterior divisions** diminish in size from above downwards ; they pass backwards between the transverse processes of the corresponding vertebræ, and each nerve divides into an internal and external branch. The *internal branch*, the smaller of the two, passes inwards to be distributed to the multifidus spinæ and inter-spinales. The *external branches* communicate with each other by several loops, and, after supplying the deeper muscles, pierce the sacro-lumbalis to reach the integument, to which they are distributed. The external branches of the three upper lumbar nerves descend over the posterior part of the crest of the ilium, and are distributed to the integument of the gluteal region.

LUMBAR PLEXUS.—The lumbar plexus is formed by the communications and anastomoses which take place between the anterior divisions of the four upper lumbar nerves, and between the latter and the last dorsal. It is narrow above, increases in breadth inferiorly, and is situated between the transverse processes of the lumbar vertebræ and quadratus lumborum behind, and the psoas magnus muscle in front.

The **branches** of the lumbar plexus are the—

Ilio-hypogastric,
Ilio-inguinal,
Genito-crural,

External cutaneous,
Obturator,
Anterior crural.

The **ILIO-HYPOGASTRIC NERVE** proceeds from the first lumbar

nerve, and passes obliquely outwards between the fibres of the psoas magnus and across the quadratus lumborum to about the middle of the crest of the ilium. It then pierces the transversalis muscle, and between it and the internal oblique divides into its two terminal branches, iliac and hypogastric.

The **iliac branch** pierces the internal and external oblique muscles close to their attachment, and a little behind the middle of the crest of the ilium; it is distributed to the integument of the gluteal region as far down as the upper part of the hip.

The **hypogastric branch** continues its course onwards, piercing

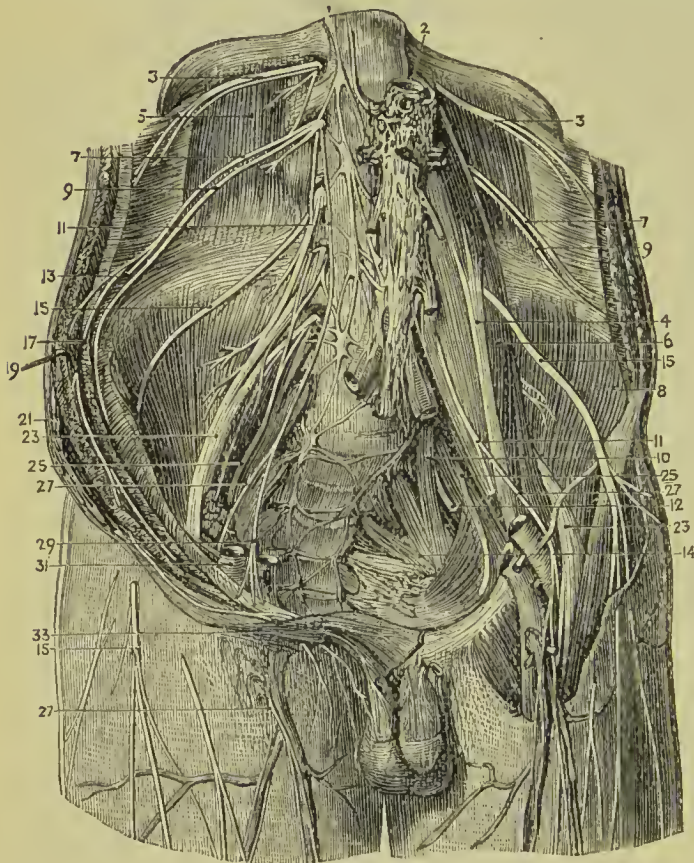


FIG. 338. — Lumbar plexus. 1. Right gangliated cord of sympathetic. 2. Abdominal aorta. 3, 3. Last dorsal nerves. 4. Psoas parvus. 5. Quadratus lumborum. 6. Psoas magnus. 7, 7. Ilio-hypogastric nerves. 8. Iliacus internus. 9, 9. Ilio-inguinal nerve. 10. Lumbo-sacral nerve. 11, 11. Genito-erural nerves. 12. Gluteal nerve. 13. Iliac branch of ilio-hypogastric nerve. 14. Sacral plexus. 15, 15. External cutaneous nerves. 17. Transversalis abdominis. 19. Obliquus internus. 21. Obliquus externus. 23, 23. Anterior erural nerves. 25, 25. Obturator nerves. 27, 27. Crural branch of genito-erural nerve. 29. Genital branch of genito-crural nerve. 31. External iliac artery. 33. External abdominal ring.

first the internal oblique, and just above the external abdominal ring the aponeurosis of the external oblique. It is distributed to the integument of the hypogastric region and mons pubis.

The **ILIO-INGUINAL NERVE**, smaller than the preceding, also arises from the first lumbar nerve. It passes obliquely downwards and outwards below the ilio-hypogastric nerve, and crosses the quadratus lumborum and iliacus muscles to the anterior part of the crest of the ilium; it then pierces the transversalis muscle, and between that muscle and the obliquus internus communicates with the ilio-hypogastric nerve. It next pierces the obliquus internus, and enters

the inguinal canal, which it traverses, lying in front of the spermatic cord, and escapes at the external abdominal ring to be distributed to the scrotum and to the integument of the upper part of the thigh, internally to the saphenous opening; and in the female to that of the pudendum.

The **GENITO-CRURAL NERVE** proceeds from the second lumbar and by a few filaments from the loop between it and the first. It traverses the *psoas magnus* from behind forwards, and runs down the anterior surface of that muscle, lying beneath its fascia, to near Poupart's ligament, where it divides into a genital and a crural branch.

The **genital branch** crosses the external iliac artery to the internal abdominal ring, and descends along the spermatic canal, lying behind the cord, to the scrotum, where it distributes twigs to the spermatic cord and cremaster muscle. In the female it gives twigs to the round ligament and external labium. At the internal abdominal ring this nerve sends off a branch, which, after supplying the lower border of the internal oblique and transversalis, is lost in the integument of the groin.

The **crural branch**, the most external of the two, descends along the outer border of the external iliac artery, and, crossing the origin of the deep circumflex iliac artery, enters the sheath of the femoral vessels in front of the femoral artery. It pierces the sheath below Poupart's ligament, and is distributed to the integument of the anterior aspect of the thigh as far as its middle. This nerve communicates with the middle cutaneous branch of the anterior crural nerve, and is often very small.

The **EXTERNAL CUTANEOUS NERVE** proceeds from the second lumbar, and from the loop between it and the third. It pierces the posterior fibres of the *psoas* muscle and crossing the *iliacus* on the iliac fascia, to the anterior superior spinous process of the ilium, passes into the thigh, beneath Poupart's ligament, where it divides into two branches, anterior and posterior.

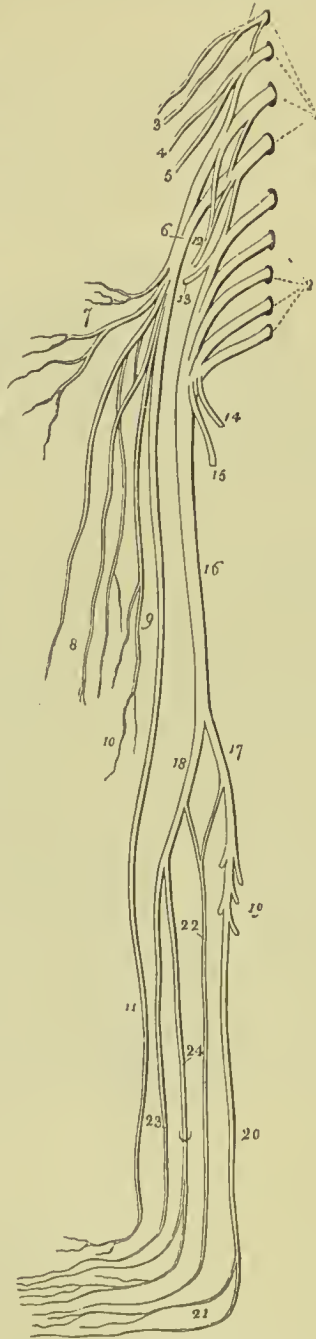
The **posterior branch** crosses the *tensor vaginae femoris* muscle to the outer and posterior aspect of the thigh, and supplies the skin as far as its middle.

The **anterior nerve**, after passing for three or four inches down the thigh in a sheath formed by the *fascia lata*, becomes superficial, and divides into two branches, which are distributed to the integument of the outer border of the thigh, and to the articulation of the knee. Its branches assist in the formation of the *plexus patellæ*.

The **OBTURATOR NERVE** is formed by a branch from the third, and another from the fourth lumbar nerve, and is distributed to the *obturator externus* and *adductor* muscles of the thigh, the hip and knee joint, the femoral and popliteal artery, and sometimes to the integument of the upper and inner part of the leg. From its origin it takes its course among the fibres of the *psoas* muscle, through the angle of bifurcation of the common iliac vessels, and along the inner

border of the brim of the pelvis, to the obturator foramen, where it joins the obturator artery. Having escaped from the pelvis, it divides

FIG. 339. — Lumbar and sacral plexuses, with the nerves of the lower extremity. 1. The first four lumbar nerves; which, with a branch from the last dorsal, constitute the lumbar plexus. 2. The four upper sacral nerves; which, with the last lumbar, form the sacral plexus. 3. The ilio-hypogastric and ilio-inguinal nerves. 4. Genito-crural nerve. 5. External cutaneous nerve. 6. Anterior crural nerve. 7. Its muscular branches. 8. Middle cutaneous branches. 9, 10. Internal cutaneous branches. 11. The long or internal saphenous. 12. Obturator nerve. 13. Gluteal nerve, a branch of the lumbosacral. 14. Internal pudic nerve. 15. Lesser ischiatic nerve. 16. Greater ischiatic nerve. 17. Internal popliteal nerve. 18. External popliteal nerve. 19. Muscular branches. 20. Posterior tibial nerve, dividing at 21 into the two plantar nerves. 22. External saphenous nerve. 23. Anterior tibial nerve. 24. Musculo-cutaneous nerve, piercing the deep fascia, and dividing into two cutaneous branches for the supply of the dorsum of the foot.



into an anterior and posterior branch.

The **anterior branch** passes downwards in front of the adductor brevis, supplies that muscle together with the pectineus, gracilis, and adductor longus, and at the lower border of the latter unites with the internal cutaneous and long saphenous nerve, to form a plexus. It then passes onwards to the femoral artery, to which it distributes filaments. In its course this nerve gives off an *articular* branch to the hip-joint; and a *cutaneous* branch, which pierces the fascia lata at the knee, communicates with the long saphenous nerve, and is distributed to the integument of the inner side of the leg as far as its middle. The cutaneous branch is often wanting, its place being supplied by the internal cutaneous nerve, and sometimes by the accessory obturator.

The **posterior branch** pierces the obturator externus muscle, to which and to the adductor magnus it distributes branches; it also gives off an *articular* branch which pierces the ad-

ductor magnus muscle, and accompanies the popliteal artery to the knee-joint.

The **accessory obturator nerve**, small and inconstant, is a high

division of the obturator, being sometimes derived from it near its origin, and sometimes by separate filaments from the third and fourth lumbar nerves. It passes down the inner border of the psoas muscle, crosses the os pubis, and dips beneath the pectineus, where it divides into branches. One of its branches is distributed to the pectineus, another supplies the hip-joint, while a third communicates with the anterior branch of the obturator nerve, and when of large size constitutes its *cutaneous* branch. As already stated, the existence of the accessory obturator nerve is uncertain.

The **ANTERIOR CRURAL** is the largest of the divisions of the lumbar plexus; it is formed by the union of branches from the second, third, and fourth lumbar nerves, and is distributed to the integument of the front and inner side of the thigh, leg, and foot, to all the muscles of the front of the thigh (excepting one), to the iliacus, pectineus, femoral artery, and knee-joint. Emerging from beneath the psoas, the nerve passes downwards in the groove between that muscle and the iliacus, and beneath Poupart's ligament into the thigh, where it spreads out and divides into numerous branches. At Poupart's ligament it is separated from the femoral artery by the breadth of the psoas muscle, which at this point is scarcely more than half an inch in diameter, and by the iliac fascia, beneath which it lies.

Branches.—Within the pelvis, the anterior crural nerve gives off three or four twigs to the iliacus muscle, and a *branch to the femoral artery*. The latter divides into filaments which entwine about the artery, and follow its course downwards in the thigh. Below Poupart's ligament the crural nerve becomes flattened out, and divides into numerous branches, which may be arranged into two principal groups, superficial and deep. The separate branches of these groups are as follows:—

Superficial.

Middle cutaneous,
Internal cutaneous.

Deep.

Muscular,
Articular,
Long or internal saphenous.

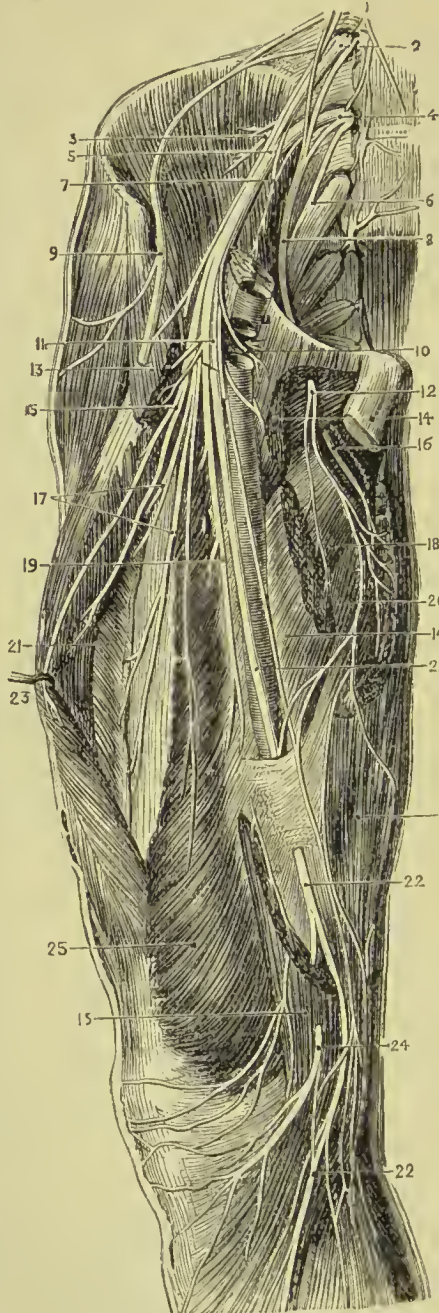
The superficial branches are mainly cutaneous, but they supply motor filaments to two muscles, namely, pectineus and sartorius; the deep branches are all motor, with the exception of the long saphenous, which is purely sensory.

The **middle cutaneous nerve** pierces the fascia lata at about three inches below Poupart's ligament, and divides into two branches, which pass down the inner and front part of the thigh, and are distributed to the integument as low as the knee-joint. At its upper part the external branch communicates with the crural branch of the genito-crural nerve; and below, the internal branch communicates with the internal cutaneous. One or both of these branches sometimes pierce the sartorius muscle.

The **internal cutaneous nerve** passes inwards in front of the

sheath of the femoral artery, and divides into an *anterior* and an *inner* branch. Previously to its division it gives off three cutaneous filaments, which pierce the fascia near the internal saphena vein,

FIG. 340.—Nerves of the thigh. 1. Gangliated cord of sympathetic. 2. Third lumbar nerve. 3. Branches to iliacus internus. 4. Fourth lumbar nerve. 5. Anterior crural nerve. 6. Lumbo - sacral nerve. 7. Branch to psoas. 8. Obturator nerve. 9. External cutaneous nerve (cut). 10. Nerve to pectineus. 11. Superficial division of anterior crural nerve (cut). 12. Superficial division of obturator nerve. 13, 13. Sartorius muscle. 14, 14. Adductor longus. 15. Branch to rectus. 16. Deep division of obturator nerve. 17. Branches to vastus internus and crureus. 18. Adductor brevis. 19. Branch to vastus internus. 20. Adductor magnus. 21. Vastus externus. 22, 22. Internal saphenous nerve. 23. Rectus femoris. 24. Patellar branch of saphenous nerve. 25. Vastus internus. 26. Gracilis.



and following the course of that vessel, are distributed to the integument of the inner side of the thigh as low down as the knee. The uppermost of these filaments passes through the saphenous opening, the middle becomes subcutaneous at about the middle of the thigh, and the lowest pierces the fascia at its lower third.

The *anterior* branch passes down the inner side of the thigh, and pierces the fascia at its lower third, near the internal saphena vein. It then divides into two twigs, one of which continues onwards to the inner side of the knee; while the other curves outwards to its outer side, communicating in its course with a branch of the long saphenous nerve.

The *inner* branch descends along the inner and posterior border of the sartorius muscle to the knee, where it pierces the fascia lata, and gives off several cutaneous twigs. It then sends a small branch of communication to the long saphenous nerve, and passes down-

wards along the inner side of the leg, to which it is distributed. While beneath the fascia lata it aids in the formation of a plexus by uniting with branches of the long saphenous nerve and descending branch of the obturator. When the latter is large the inner branch of the internal cutaneous nerve is small, and may terminate in the plexus, or merely give off a few cutaneous filaments.

The **long or internal saphenous nerve** inclines inwards to the sheath of the femoral vessels, and passes downwards in front of the sheath and beneath the aponeurotic expansion which covers the sheath, to the opening in the adductor magnus. It then quits the femoral vessels, and continuing to descend, passes between the tendons of the sartorius and gracilis, and reaches the internal saphena vein. By the side of the latter it passes down the inner side of the leg, in front of the inner ankle, and along the inner side of the foot as far as the great toe, being distributed to the integument in its course.

The branches of the long saphenous nerve in the thigh are—one or two to join the plexus formed by the obturator and internal cutaneous nerves; and a large branch, the *cutaneus patellæ*, which pierces the sartorius and fascia lata at the inner side of the knee, and divides into many twigs, which are distributed to the integument of the front of the knee. Above the patella this branch communicates with the anterior branch of the internal cutaneous nerve, and with the terminal twigs of the middle, and external cutaneous. Below the patella it communicates with other branches of the long saphenous; the whole of these communications constituting a kind of plexus (plexus patellæ).

The branches of the long saphenous nerve below the knee are distributed to the integument of the front and inner side of the leg. By one of these branches it communicates with the cutaneous branch of the obturator nerve.

The **muscular branches** of the anterior crural nerve supply all the muscles of the front of the thigh (with the exception of the tensor vaginæ femoris, which obtains its nerve from the superior gluteal) and the pectineus. The branch to the *pectineus* passes behind the sheath of the femoral vessels; the branches to the *sartorius*, three or four in number, arise with the cutaneous nerves, and sometimes are supplied by the latter. The branch to the *rectus* enters the deep surface of that muscle. The branch to the *vastus externus* follows the course of the descending branch of the external circumflex artery; the branch to the *crureus* passes directly to that muscle; and the branch to the *vastus internus*, remarkable for its length, descends by the side of the sheath of the femoral vessels.

The **articular branches** are distributed to the knee-joint; one enters the joint at its outer side, being derived from the nerve of the vastus externus; the other, proceeding from the nerve of the vastus internus, descends with the anastomotica magna to a level with the joint, and then pierces the capsular ligament.

The **LUMBO-SACRAL NERVE**.—The anterior division of the fifth

lumbar nerve, conjoined with a branch from the fourth, constitutes the lumbosacral nerve, which descends over the base of the sacrum into the pelvis, and assists in forming the sacral plexus. Immediately before it joins the first sacral, it gives off the superior gluteal nerve, but this nerve is, notwithstanding, usually described as a branch of the sacral plexus.

The connection of the nerves of the plexus with the anterior divisions of the lumbar nerves, may be most simply expressed in a tabular form, as follows:—

Ilio-hypogastric	1.
Ilio-inguinal	1.
Genito-crural	1, 2.
External cutaneous	2, 3.
Anterior crural	2, 3, 4.
Obturator	3, 4.
Lumbo-sacral	4, 5.

SACRAL NERVES.

There are five pairs of sacral nerves; the first four escape from the vertebral canal through the sacral foramina, the last between the sacrum and coccyx. The **posterior sacral nerves** are small, and diminish in size from above downwards; they communicate with each other by means of anastomosing loops immediately after their escape from the posterior sacral foramina, and divide like the other spinal nerves into external and internal branches. The external branches pierce the gluteus maximus, to which they give filaments, and are distributed to the integument of the posterior part of the gluteal region. The internal branches supply the multifidus spinæ muscle and the integument over the sacrum and coccyx.

The **anterior sacral nerves** diminish in size from above downwards; the *first* is large, and unites with the lumbosacral nerve; the *second*, of equal size, unites with the first; and the *third*, scarcely one-fourth so large as the second, joins with the two preceding nerves in the formation of the sacral plexus.

The **fourth sacral nerve** divides into two branches, one of which assists in forming the sacral plexus; the other separates into three branches: a *communicating branch*, to unite with the fifth sacral nerve; a *visceral branch*, to join with the hypogastric plexus and supply the bladder and prostate gland, and in the female the vagina; and a *muscular branch*, which sends filaments to the levator ani and coccygeus, and a *hæmorrhoidal branch* to the sphincter ani and integument behind the anus.

The **fifth sacral nerve**, issuing from between the sacrum and coccyx, pierces the coccygeus muscle, and receives the communicating branch from the fourth; it then communicates with the coccygeal nerve, and piercing the coccygeus a second time, is distributed to the integument over the dorsal surface of the coccyx.

The **coccygeal nerve** pierces the coccygeus muscle, and unites with the fifth sacral nerve, in which it is lost. The connection between the fourth and fifth sacral nerves and the coccygeal is sometimes described as the *coccygeal plexus*.

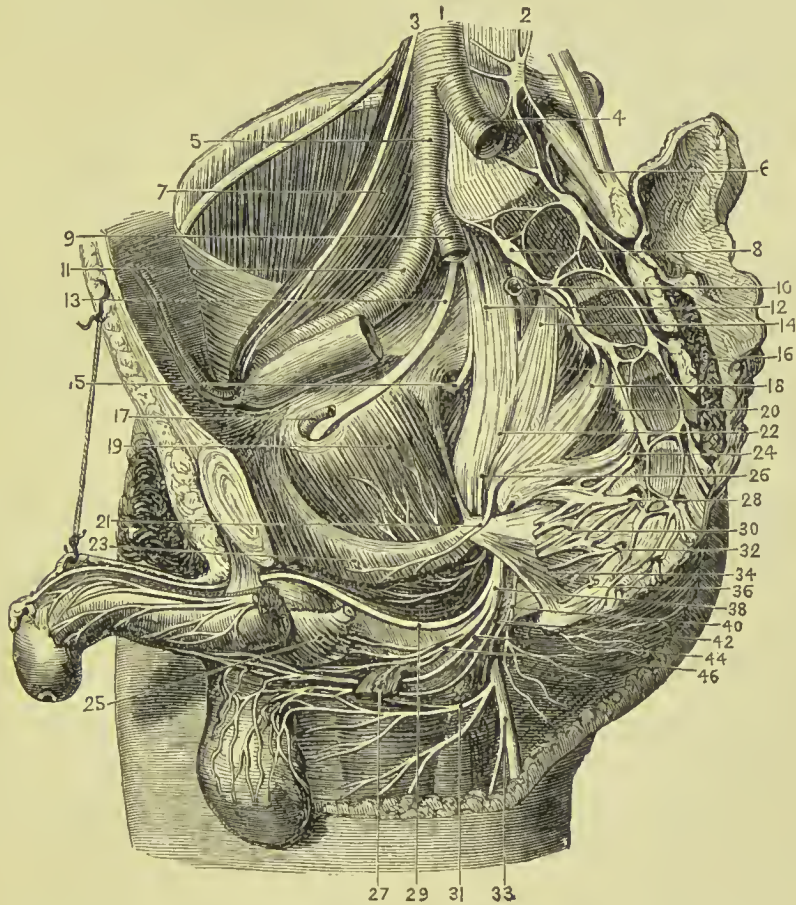


FIG. 341.—Side view of the nerves of the pelvis, the viscera having been removed. 1. Abdominal aorta. 2. Gangliated cord of sympathetic (left side). 3. Genito-crural nerve. 4. Left common iliac artery. 5. Right common iliac artery. 6. Left lumbo-sacral cord. 7. Psoas muscle. 8. Gangliated cord of sympathetic (right side). 9. Internal iliac artery (cut). 10. Gluteal artery (cut). 11. Right external iliac artery. 12. Right lumbo-sacral nerve. 13. Obturator nerve. 14. First sacral nerve. 15. Gluteal nerve. 16. Piriformis of left side (cut). 17. Obturator artery. 18. Second sacral nerve. 19. Obturator internus. 20. Piriformis of right side. 21. Nerve to levator ani. 22. Sacral plexus. 23. Levator ani (cut). 24. Third sacral nerve. 25. Bulb of urethra covered by accelerator urinæ. 26. Nerve to obturator internus. 27. Transversus perinæi (cut). 28. Fourth sacral nerve. 29. Dorsal nerve of penis. 30. Visceral branches (cut). 31. Inferior pudendal nerve. 32. Fifth sacral nerve. 33. Small sciatic nerve. 34. Coccygeus muscle. 36. Sixth or coccygeal nerve. 38. Internal pudic nerve. 40. Inferior hæmorrhoidal nerve. 42. Posterior superficial perineal nerve. 44. Anterior superficial perineal nerve. 46. Deep perineal nerves to bulb and muscles.

Each of the anterior divisions of the sacral nerves communicates with the sympathetic at its point of escape from the sacral canal.

SACRAL PLEXUS.—The sacral plexus is formed by the union of the lumbo-sacral and the anterior divisions of the three upper sacral

nerves and one-half the fourth. The plexus is triangular in form, its base corresponding with the whole length of the sacrum, and its apex with the lower part of the great sacro-ischiatic foramen. It is in relation behind with the pyriformis muscle, and in front with the pelvic fascia, which separates it from the internal iliac vessels and the viscera of the pelvis.

The **branches** of the sacral plexus are—

Visceral,	Pudic,
Muscular,	Lesser ischiatic,
Superior gluteal,	Greater ischiatic.
Inferior gluteal,	

The **visceral nerves** are three or four large branches derived from the fourth and fifth sacral nerves : they ascend by the side of the rectum and bladder ; in the female by the side of the rectum, vagina, uterus, and bladder ; and interlace with branches of the hypogastric plexus, sending in their course numerous filaments to the pelvic viscera.

The **muscular branches** are one or two twigs to the *levator ani*; an *obturator branch*, which curves around the spine of the ischium along with the pudic vessels and nerve, to reach the internal surface of the obturator internus muscle ; two twigs to the *pyriformis*; a branch to the *gemellus superior* ; and a branch of moderate size, which descends between the gemelli muscles and the ischium, and is distributed to the *gemellus inferior*, *quadratus femoris*, and capsule of the *hip-joint*.

The **SUPERIOR GLUTEAL NERVE** arises from the lumbo-sacral near its junction with the first sacral nerve ; it passes out of the pelvis with the gluteal artery, through the great sacro-ischiatic foramen above the pyriformis muscle, and divides into a superior and an inferior branch.

The **superior branch** follows the direction of the middle curved line of the ilium, accompanying the deep superior branch of the gluteal artery, and sends filaments to the gluteus medius and minimus.

The **inferior branch** passes obliquely downwards and forwards between the gluteus medius and minimus, distributing numerous filaments to both, and terminates in the tensor vaginae femoris muscle.

The superior gluteal nerve should, properly, be described with the lumbar plexus, as its fibres are entirely derived therefrom, the sacral plexus contributing nothing to its formation ; its description with the latter is, however, so thoroughly sanctioned by usage that we hesitate to make a change.

The **INFERIOR GLUTEAL NERVE** is often described as a branch of the lesser ischiatic, with which it is intimately connected. It arises from the lumbo-sacral cord and first and second sacral nerves, escapes from the pelvis through the greater sacro-sciatic foramen,

below the pyriformis muscle, and enters the deep aspect of the gluteus maximus, to which it is distributed.

The **PUDIC NERVE** arises from the lowest part of the sacral plexus and passes out of the pelvis through the great sacro-ischiatic foramen below the pyriformis muscle. It crosses the spine of the ischium, and re-entering the pelvis through the lesser sacro-ischiatic foramen, accompanies the internal pudic artery through Alcock's canal, lying inferiorly to the artery and enclosed in the same sheath. Near its origin it gives off the *inferior hæmorrhoidal* nerve, and in the outer wall of the ischio-rectal fossa divides into a superior and inferior branch.

The **inferior hæmorrhoidal nerve**, often a branch of the sacral plexus, crosses the ischio-rectal fossa with the vessels of the same name, and descends to the termination of the rectum to be distributed to the sphincter ani and integument.

The **dorsalis penis nerve**, the superior division of the internal pudic, ascends along the posterior surface of the ramus of the ischium, pierces the triangular ligament, and accompanies the arteria dorsalis penis to the glans, to which it is distributed. At the root of the penis the nerve gives off a cutaneous branch which runs along the side of the organ, gives filaments to the corpus cavernosum, and with its fellow of the opposite side supplies the integument of the upper two-thirds of the penis.

The **perineal nerve** or inferior terminal branch, larger than the preceding, pursues the course of the superficial perineal artery in the perineum and divides into cutaneous and muscular branches.

The **cutaneous branches** (superficial perineal), two in number, *posterior* and *anterior*, enter the ischio-rectal fossa and pass forward with the superficial perineal artery to be distributed to the integument of the perineum, scrotum, and under part of the penis. The *posterior* superficial perineal nerve sends a few filaments to the integument of the anus and sphincter ani; while the *anterior* gives off one or two twigs to the levator ani.

The **muscular branches** proceed from a single trunk, which passes inwards behind the transversus perinei muscle; they are distributed to the transversus perinei, accelerator urinæ, and erector penis. The perineal nerve also sends two or three filaments to the *corpus spongiosum*.

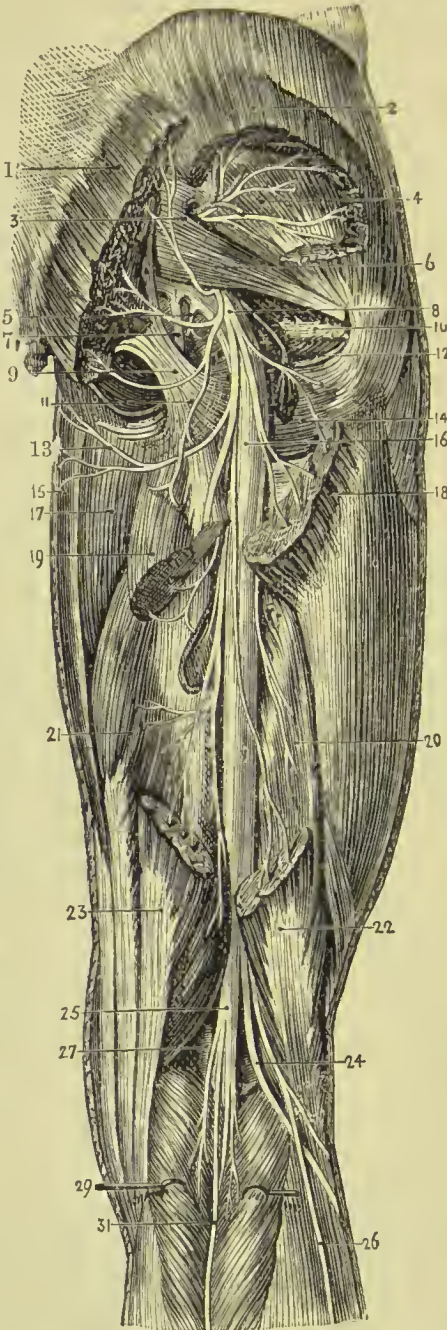In the female the pudic nerve is distributed to the parts analogous to those of the male. The *superior branch* supplies the clitoris; the *inferior* the vulva and perineum.

The **LESSER ISCHIATIC NERVE** arises from the second and third sacral nerves; it passes out of the pelvis through the great sacro-ischiatic foramen below the pyriformis muscle, and continues its course downwards through the thigh to the lower part of the popliteal region, where it pierces the fascia and becomes subcutaneous. It then accompanies the external saphena vein to the lower part of the leg, and communicates with the external saphenous nerve.

The branches of the lesser ischiatic nerve are all cutaneous; they

are divisible into external, internal, and middle. The *external cutaneous branches* are several filaments which turn around the lower border of the gluteus maximus, and are distributed to the integument over the hip and outer side of the thigh.

FIG. 342. — Dissection of the buttock and back of the thigh. 1. Gluteus maximus. 2. Gluteus medius. 3. Gluteal artery and nerve. 4. Gluteus minimus. 5. Nerve to obturator internus. 6. Piriformis. 7. Pudic nerve. 8. Small sciatic nerve. 9. Great sacro-sciatic ligament. 10. Obturator internus and gemelli. 11. Inferior gluteal nerve. 12. Tendon of obturator externus. 13. Inferior pudendal nerve. 14. Quadratus femoris. 15. Gracilis. 16. Great sciatic nerve. 17. Adductor magnus. 18. Insertion of gluteus maximus. 19. United origins of semitendinosus and biceps. 20. Short head of biceps. 21. Semi-membranosus. 22. Tendon of biceps. 23. Tendon of semitendinosus. 24. External popliteal nerve. 25. Internal popliteal nerve. 26. Communicans peronei nerve. 27. Popliteal artery. 29. Gastrocnemius. 31. Communicans poplitei nerve.



The *internal cutaneous branches* are distributed to the integument of the upper and inner part of the thigh. One of these, larger than the rest, **inferior pudendal**, curves around the tuberosity of the ischium, pierces the fascia lata near the ramus of that bone, and, after communicating with one of the superficial perineal nerves, is distributed to the integument of the scrotum and penis. The *middle cutaneous branches*, two or three in number, are derived from the lesser ischiatic in its course down the thigh, and are distributed to the integument.

The **GREAT ISCHIATIC NERVE** is the largest nervous cord in the body; it is formed by the sacral plexus, or rather is a pro-

longation of the plexus, and at its exit from the great sacro-ischiatic foramen beneath the piriformis muscle measures three-quarters of an inch in breadth. It descends through the middle of the space be-

tween the trochanter major and tuberosity of the ischium, and along the posterior part of the thigh to its lower third, where it divides into two large terminal branches, internal and external popliteal. This division sometimes takes place at the plexus, and the two nerves descend side by side; occasionally they are separated at their commencement by a part or by the whole of the pyriformis muscle. The nerve in its course down the thigh rests on the gemellus superior, tendon of the obturator internus, gemellus inferior, quadratus femoris, and adductor magnus, and is covered by the gluteus maximus and biceps.

The **branches** of the great ischiatic nerve, previously to its division, are, muscular and articular.

The **muscular branches** are given off from the upper part of the nerve and supply both heads of the biceps, the semi-tendinosus, semi-membranosus, and adductor magnus.

The **articular branch** descends to the upper part of the external condyle of the femur, and divides into filaments, which are distributed to the fibrous capsule and synovial membrane of the knee-joint.

The **INTERNAL POPLITEAL NERVE** passes through the middle of the popliteal space, from the division of the great ischiatic nerve to the lower border of the popliteus muscle, accompanies the artery beneath the arch of the soleus, and becomes the posterior tibial nerve. It is superficial in the whole of its course, and lies externally to the vein and artery.

The **branches** of the internal popliteal nerve are—muscular or sural, articular, and a cutaneous branch, the external saphenous.

The **muscular branches**, of considerable size, and four or five in number, are distributed to the two heads of the gastrocnemius, to the soleus, plantaris, and popliteus.

The **articular branches**, two or three in number, supply the knee-joint, two of the twigs accompanying the internal articular arteries.

The **external** or **short saphenous nerve** (communicans poplitei, vel tibialis) proceeds from the middle of the internal popliteal, and descends in the groove between the two bellies of the gastrocnemius muscle to the middle of the leg; it then pierces the fascia, and, after receiving the communicans peronei, comes into relation with the external saphena vein, and follows the course of that vein to the outer ankle, to which, and to the integument of the heel and outer side of the foot (cutaneus dorsi pedis externus), it distributes branches.

The **POSTERIOR TIBIAL NERVE** is continued along the posterior aspect of the leg from the lower border of the popliteus muscle to the posterior part of the inner ankle, where it divides into the internal and external plantar nerve. In the upper part of its course it lies to the inner side of the posterior tibial artery; it then becomes placed superficially to that vessel, and at the ankle is situ-

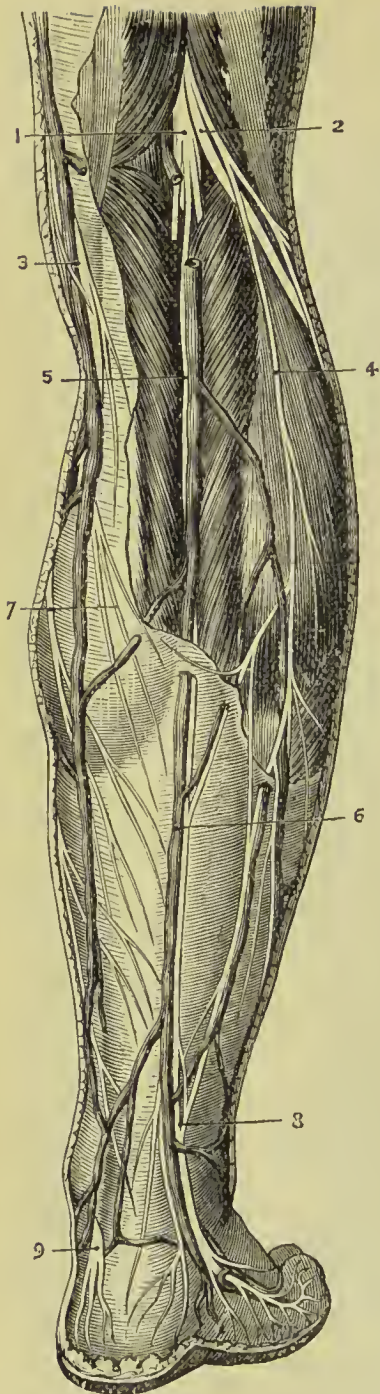


FIG. 343.—Superficial nerves of the back of the leg. 1. Internal popliteal nerve. 2. External popliteal nerve. 3. Internal saphena vein. 4. Nervus communicans peronei. 5. Upper part of short saphenous nerve. 6. External saphena vein. 7. Internal saphenous nerve. 8. Lower part of short or external saphenous nerve. 9. Posterior tibial nerve.

ated to its outer side ; in the lower third of the leg it lies parallel with the inner border of the tendo-Achillis.

The **branches** of the posterior tibial nerve are—three or four *muscular* twigs to the deep muscles of the posterior aspect of the leg, the branch to the flexor longus hallucis accompanies the nutrient artery of the fibula ; one or two filaments which entwine around the artery and then terminate in the integument ; and a *plantar cutaneous branch* which pierces the internal annular ligament, and is distributed to the integument of the heel and inner border of the sole of the foot.

The **INTERNAL PLANTAR NERVE**, larger than the external, crosses the posterior tibial vessels to enter the sole of the foot, and becomes placed between the abductor hallucis and flexor brevis digitorum ; it then enters the sheath of the latter muscle, and divides opposite the base of the metatarsal bones into three digital branches ; *one* to supply the adjacent sides of the great and second toe ; the *second*, the adjacent sides of the second and third toe ; the *third*, the corresponding sides of the third and fourth toe.

In its course the internal plantar nerve gives off *cutaneous branches* to the integument of the inner side and sole of the foot ; *muscular branches* to the muscles forming the inner and middle group of the sole ; a *digital branch* to the inner border of the great toe ; and *articular branches* to the articulations of the tarsal and metatarsal bones.

The **EXTERNAL PLANTAR NERVE**, the smaller of the two, follows the course of the external plantar artery to the outer border of the musculus

accessorius, beneath which it sends several deep branches to supply the adductor hallucis, interossei, transversus pedis, and the articulations of the tarsal and metatarsal bones. It then gives branches to the integument of the outer border and sole of the foot, and sends forward two digital branches to supply the little toe and half the next.

Comparison of the Nerves of the Sole of the Foot with those of the Palm of the Hand.—The cutaneous distribution of the internal plantar nerve corresponds to that of the median nerve,

and that of the external plantar to the ulnar. The flexor brevis digitorum is supplied by the internal plantar and probably corresponds to the flexor sublimis in the hand, supplied by the corresponding nerve, the median; the abductor hallucis and two inner lumbricales of the foot are also supplied by the same nerve, and agree in all respects with those occupying the same position in the hand. The flexor accessorius, adductor hallucis, two outer lumbricales, dorsal and palmar interossei, transversus pedis, and muscles of the little toe

are supplied by the external plantar nerve, a distribution corresponding very closely to that of the ulnar nerve in the hand. The flexor brevis hallucis differs from the flexor brevis pollicis in obtaining nerve supply for both heads from the same nerve, namely, the internal plantar.

The **EXTERNAL POPLITEAL NERVE** (*peroneal nerve*), one-half smaller than the internal, passes downwards by the side of the tendon of the biceps, and crosses the outer head of the gastrocnemius

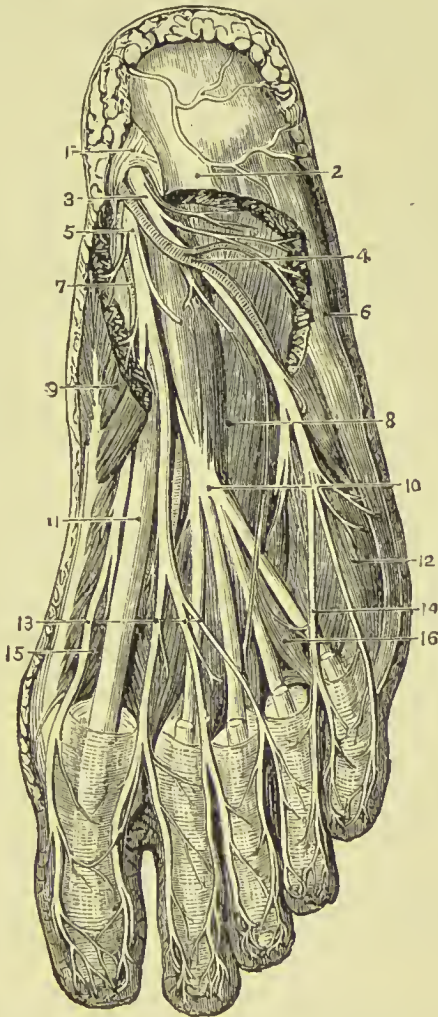


FIG. 344.—Second stage of dissection of sole of foot. 1. Internal annular ligament. 2. Flexor brevis digitorum (cut). 3. External plantar nerve. 4. External plantar artery. 5. Internal plantar nerve. 6. Abductor minimi digiti. 7. Internal plantar artery. 8. Accessorius muscle. 9. Abductor hallucis. 10. Flexor longus digitorum. 11. Flexor longus hallucis. 12. Flexor brevis minimi digiti. 13. Digital branches of internal plantar nerve. 14. Digital branches of external plantar nerve. 15. Flexor brevis hallucis. 16. One of the lumbricales.

and the head of the soleus, to the neck of the fibula ; it then pierces the peroneus longus muscle, and divides into two branches, anterior tibial and musculo-cutaneous.

The **branches** of the external popliteal nerve are—*communicans peronei*, cutaneous, and articular.

The **communicans peronei**, proceeding from the external popliteal near the head of the fibula, crosses the external origin of the gastrocnemius muscle, and, piercing the deep fascia, descends to the middle of the leg, where it joins the external saphenous nerve. It gives off one or two cutaneous filaments in its course.

The **cutaneous** branch passes down the back part and outer side of the leg, supplying the integument.

The **articular** branches follow the external articular arteries to the knee-joint.

The **ANTERIOR TIBIAL NERVE** commences at the bifurcation of the external popliteal on the neck of the fibula, and passes beneath the upper part of the extensor longus digitorum, to reach the outer side of the anterior tibial artery, just as that vessel has emerged through the opening in the interosseous membrane. It descends the leg with the artery, lying at first to its outer side, then in front of it, and near the ankle becoming again placed to its outer side. Reaching the ankle it passes beneath the annular ligament, accompanies the dorsalis pedis artery, supplies the adjacent sides of the great and second toe, and communicates with the internal division of the musculo-cutaneous nerve.

The **branches** given off by the anterior tibial nerve are—*muscular* to the muscles in its course ; and at the ankle a *tarsal* branch which may be considered as one of the terminal divisions of the nerve. This branch passes outwards upon the dorsum of the foot, becomes ganglionic like the posterior interosseous nerve at the wrist, and supplies the extensor brevis digitorum muscle and the articulations of the tarsus and metatarsus.

The **MUSCULO-CUTANEOUS NERVE** passes downwards along the fibula, in the substance of the peroneus longus ; it then gets between the peroneus longus and brevis, next between the peronei and extensor longus digitorum, and at the lower third of the leg pierces the deep fascia, and divides into the internal and external cutaneous nerves of the foot. In its course it gives off several branches to the peronei muscles and cutaneous branches to the skin of the lower part of the leg.

The **internal branch**, the smaller of the two, is distributed to the inner side of the foot and great toe, and the adjoining sides of the second and third toes communicating with the anterior tibial and internal saphenous. The **external**, or larger branch, supplies the adjacent sides of the third and fourth, and fourth and fifth toes, and communicates with the external saphenous.

SYMPATHETIC NERVES.

The *sympathetic* consists of a vertebral and prevertebral portion. The *vertebral portion* is composed of a series of ganglia united by a longitudinal cord; it descends along each side of the vertebral column from the head to the coccyx, communicates with the cranial and spinal nerves, and distributes branches to the internal organs and viscera. The *prevertebral portion* is that part of the sympathetic which appertains to the viscera, comprising the numerous ganglia and plexuses of the head, chest, abdomen, and pelvis.

The sympathetic nerve communicates with the cerebro-spinal nerves immediately at their exit from the cranium and vertebral canal. With the fourth and sixth nerve, however, it unites in the cavernous sinus; with the olfactory in the nose; and with the auditory in the meatus auditorius internus.

The branches of distribution accompany the arteries which supply the different organs, and form communications around them which are called *plexuses*, and take the name of the artery with which they are associated; thus we have the mesenteric plexus, hepatic plexus, and splenic plexus.

The chief ganglia in the head are four in number; namely, the ophthalmic or lenticular, the spheno-palatine or Meckel's, the otic or Arnold's, and the submaxillary; three in the neck, superior, middle, and inferior cervical; twelve in the dorsal region; four in the lumbar region; and four or five in the sacral region.

Each ganglion may be considered as a *distinct centre*, receiving and giving branches in four different directions, viz., *superior* or *ascending*, to communicate with the ganglion above; *inferior* or *descending*, to communicate with the ganglion below; *external*, to communicate with the spinal nerves; and *internal*, to communicate with the sympathetic filaments of the opposite side, and be distributed to the viscera.

As regards the spinal nerves it receives as well as gives, the white fibres of the sympathetic being derived from the cerebro-spinal nerves.

CRANIAL PORTION OF THE SYMPATHETIC NERVE.

Cranial Ganglia.

Ophthalmic, or lenticular ganglion,
Spheno-palatine, or Meckel's ganglion,
Otic, or Arnold's ganglion,
Submaxillary ganglion.

The **OPHTHALMIC GANGLION** (*ciliary; lenticular*) is a small quadrangular and flattened ganglion situated within the orbit, between the optic nerve and external rectus muscle; it is in close relation with the optic nerve and generally with the ophthalmic

artery ; and is surrounded by adipose tissue, which renders its dissection somewhat difficult. It is of a reddish-grey colour, like other sympathetic ganglia.

Its **branches of distribution** are the *short ciliary* nerves, which arise from its anterior angles in two groups ; the upper group consisting of about four filaments ; the lower, of five or six. They accompany the ciliary arteries in a waving course, and divide into filaments which pierce the sclerotic around the optic nerve to supply

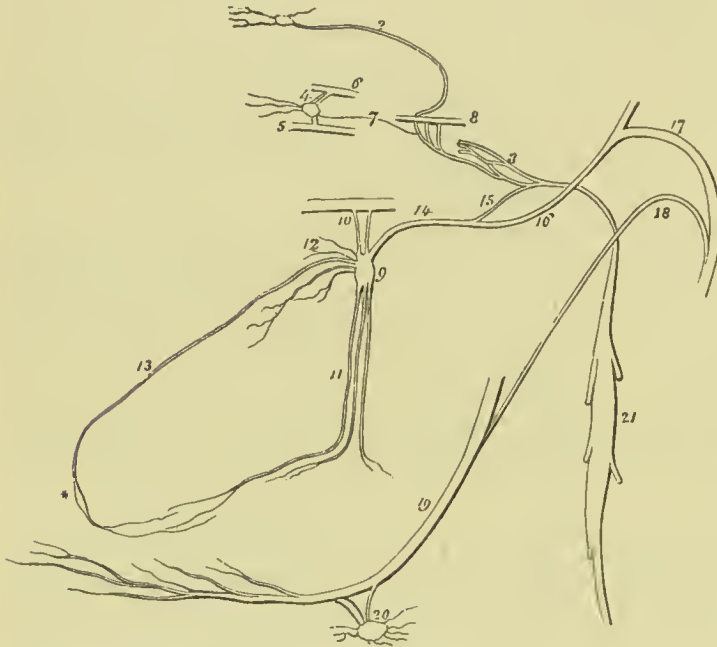


FIG. 345.—Cranial ganglia of the sympathetic nerve. 1. Ganglion of Ribes. 2. Filament by which it communicates with the carotid plexus (3). 4. Ophthalmic or lenticular ganglion, giving off ciliary branches. 5. Part of the inferior division of the third nerve communicating with the ganglion by means of a short thick branch (short root). 6. Part of the nasal nerve, connected with the ganglion by means of a longer branch (long root). 7. A slender filament

(the sympathetic root) from the carotid plexus. 8. Part of the sixth nerve in the cavernous sinus, receiving two branches from the carotid plexus. 9. Meckel's ganglion (spheno-palatine). 10. Spheno-palatine nerves. 11. Descending palatine branches. 12. Its internal or nasal branches. 13. Naso-palatine branch, one of the nasal branches. 14. Posterior branch of the ganglion, the Vidian nerve. 15. Its carotid branch, communicating with the carotid plexus. 16. Its petrosal branch, joining the intumescencia gangliiformis of the facial nerve. 17. Facial nerve. 18. Chorda tympani nerve, descending to join the lingual nerve. 19. Lingual nerve. 20. Submaxillary ganglion, receiving filaments from the chorda tympani and lingual. 21. Superior cervical ganglion of the sympathetic. * Naso-palatine ganglion of Cloquet.

the tunics of the eyeball, the greater number of them being traceable to the iris and ciliary processes.

Its **branches of communication** are three : one, the *long root*, proceeds from the *nasal* branch of the ophthalmic nerve and joins its superior angle ; a short and thick branch, the *short root*, from the inferior division of the third nerve to its inferior angle ; and a slender filament, the *sympathetic root*, from the cavernous plexus, which accompanies the long root to the ganglion. Occasionally the ophthalmic ganglion receives also a filament of communication from the sphenopalatine ganglion ; and sometimes from the abducens nerve.

The **SPHENO-PALATINE GANGLION** (Meckel's), the largest of the cranial ganglia of the sympathetic, is situated in the sphenomaxillary fossa, a little below the superior maxillary nerve. It is of small size, of a reddish-grey colour, and triangular in shape; and is placed on the posterior part of the sphenopalatine nerves which it only partially involves. Its branches are divisible into four groups: ascending, descending, internal, and posterior.

The **ascending** branches are three or four small filaments which are distributed to the periosteum of the orbit. One of these branches sometimes joins the ophthalmic ganglion, one the sixth nerve, and two the optic nerve.

The **descending** branches are the three palatine nerves—anterior, middle, and posterior.

The **anterior** or **large palatine nerve** descends from the ganglion through the descending palatine canal, and emerges at the posterior palatine foramen. It then passes forward in a groove in the hard palate, to the mucous membrane of which it is distributed, and reaches the incisive foramen, where it communicates with the nasopalatine nerve. While in the descending palatine canal, this nerve gives off several branches (*inferior nasal*), which enter the nose through openings in the palate bone, and are distributed to the middle and inferior meatus, inferior spongy bone, and antrum.

The **middle** or **external palatine nerve** descends externally to the preceding to the posterior palatine foramen, and distributes branches to the tonsil, soft palate, and uvula.

The **posterior** or **small palatine nerve** quits the other nerves to enter a distinct canal, from which it emerges by a separate opening behind the posterior palatine foramen. It is distributed to the hard palate and gums near the point of its emergence, and also to the tonsil, soft palate, and uvula. The middle and posterior palatine nerves join with the branches of the glosso-pharyngeal in the formation of a plexus around the tonsil.

The **internal branches** are the superior nasal and nasopalatine. The **superior nasal nerves**, four or five in number, enter the nasal fossa through the sphenopalatine foramen, and are distributed to the mucous membrane of the superior meatus, and superior and middle spongy bone. They are formed almost entirely by filaments derived from the superior maxillary nerve, which do not pass through Meckel's ganglion.

The **nasopalatine nerve** (Scarpa) enters the nasal fossa through the sphenopalatine foramen, and crosses the roof of the nares to reach the septum, to which it gives filaments. It then curves downwards and forwards along the vomer, to the nasopalatine canal, and passes through that canal to the palate, to which and to the papilla behind the incisor teeth it is distributed. The two nerves are contained in canals situated at the junction of the two superior maxillary bones, termed the canals of Scarpa; the right nerve is placed behind, the left in front. This nerve was described by Cloquet as uniting with its fellow in the nasopalatine canal and

constituting the *naso-palatine ganglion*. The existence of this ganglion is disputed. The naso-palatine nerves are directly continuous with the sphenopalatine, derived from the superior maxillary, and are unconnected with the nerve cells of the ganglion.

The **posterior branches** are the Vidian or pterygoid nerve, and the pterygo-palatine.

The **Vidian nerve**, connected with the back part of the ganglion, passes directly backwards through the pterygoid or Vidian canal to the foramen lacerum basis cranii, where it divides into two branches, *carotid* and *petrosal*. The **carotid branch** crosses the foramen lacerum, surrounded by the cartilaginous substance which closes that opening, and enters the carotid canal to join the carotid plexus. The **petrosal branch** enters the cranium through the foramen lacerum basis cranii, piercing the cartilaginous substance, and passes backwards beneath the Gasserian ganglion and dura mater, embedded in a groove on the anterior surface of the petrous bone to the hiatus Fallopii. In the hiatus Fallopii it receives a branch from Jacobson's nerve, and terminates in the intumescentia gangliformis of the facial nerve.

The Vidian nerve contains both the motor and sympathetic roots of Meckel's ganglion, and most observers agree in regarding the motor power as derived from the facial nerve; others, however, consider it to come from the spinal accessory or the glosso-pharyngeal.

The **pterygo-palatine** nerve is a small branch which passes backwards through the pterygo-palatine canal with the pterygo-palatine artery, to be distributed to the mucous membrane of the Eustachian tube and neighbouring part of the pharynx.

Roots.—The sphenopalatine ganglion gets its *motor root* from the facial, spinal accessory, or glosso-pharyngeal, through the Vidian nerve, its *sensory roots* are the sphenopalatine branches of the superior maxillary, and its *sympathetic root* is derived from the carotid plexus through the Vidian nerve.

The **OTIC GANGLION** (Arnold's) is a small oval-shaped and flattened ganglion, lying against the inner surface of the inferior maxillary nerve, close to the foramen ovale; it is in *relation, externally*, with the trunk of that nerve, just at the point of union of the motor root; *internally* it rests against the cartilage of the Eustachian tube and tensor palati muscle; and *posteriorly* is in contact with the arteria meningea media. It is closely adherent to the internal pterygoid nerve, and appears like a swelling on that nerve.

The branches of the otic ganglion are six in number; two of distribution and four of communication.

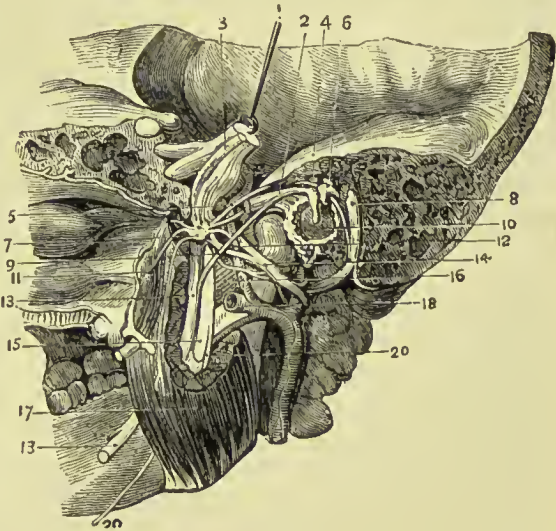
The **branches of distribution** are—a small filament to the tensor tympani muscle, and one or two to the tensor palati.

The **branches of communication** are—one or two filaments from the inferior maxillary nerve; one or two filaments to the auriculo-temporal nerve, distributed with it to the parotid gland; filaments from the nervi molles of the arteria meningea media, and the

lesser petrosal nerve. The latter nerve arises from the tympanic plexus in the middle ear, communicates with the gangliform enlargement on the facial nerve, traverses the petrous bone to emerge on its anterior surface through a minute opening external to the hiatus Fallopii; it crosses the middle fossa of the skull, and passes through the foramen ovale (or a special foramen) to join the otic ganglion. It conveys nerve filaments from the facial nerve and glosso-pharyngeal nerve, those from the former constituting the *motor root*, and those from the latter the *sensory root* of the ganglion; the *sympathetic root* coming from the *nervi molles* on the middle meningeal artery.

The **SUBMAXILLARY GANGLION** (Wharton's) is a small round or triangular ganglion situated on the deep portion of the sub-

FIG. 346. — Dissection showing inferior maxillary nerve and otic ganglion. 1. Sensory portion of fifth nerve, with Gasserian ganglion. 2. Tensor tympani. 3. Motor portion of fifth, passing beneath ganglion. 4. Malleus. 5. Small superficial petrosal nerve. 6. Incus. 7. Otic ganglion. 8. Facial nerve. 9. Chorda tympani. 10. Membrana tympani. 11. Tensor palati. 12. Middle meningeal artery. 13, 13. Lingual nerve. 14. Auriculo-temporal nerve. 15. Inferior dental nerve. 16. External pterygoid. 17. Internal pterygoid. 18. Internal maxillary artery. 20, 20. Mylo-hyoid nerve.



maxillary gland, in close relation with the lingual nerve, and near the posterior border of the mylo-hyoid muscle.

Its **branches of distribution**, six or eight in number, divide into many filaments, which supply the side of the tongue, the submaxillary gland, sublingual gland, and Wharton's duct.

Its **branches of communication** are two or three from and to the lingual nerve; one from the chorda tympani; two or three which form a plexus with branches of the hypoglossal nerve; and one or two filaments which pass to the facial artery, and communicate with the *nervi molles* from the cervical portion of the sympathetic.

Roots.—The *motor root* of the submaxillary ganglion is derived from the hypoglossal; the *sensory root* from the lingual branch of the inferior maxillary, and the *sympathetic root* from the filaments which accompany the facial artery (*nervi molles*).

CAROTID PLEXUS.—The ascending branch of the superior cervical ganglion enters the carotid canal with the internal carotid artery, and divides into two branches, which form several loops of com-

munication with each other around the artery. These branches, together with those derived from the carotid branch of the Vidian, constitute the **carotid plexus**, situated for the most part on the outer side of the artery. The continuation of the carotid plexus onwards with the artery by the side of the sella turcica, is the **cavernous plexus**.

The **carotid plexus** is the centre of communication between all the cranial ganglia and the sympathetic in the neck; it also communicates with most of the cerebral nerves, and distributes filaments with each of the branches of the internal carotid, to accompany those branches to their ultimate ramifications. The branches which accompany the anterior cerebral artery at each side, unite upon the anterior communicating artery, and according to Ribes form a small ganglion, the *ganglion of Ribes*. The existence of this ganglion is disputed.

The *ophthalmic ganglion* communicates with the plexus by means of the long branch which reaches it from the cavernous plexus, often in connection with the nasal nerve, but sometimes with the third. The *spheno-palatine* communicates with the plexus by means of the carotid branch of the Vidian. The *otic ganglion* is brought into connection with the plexus by means of the communication between the lesser petrosal nerve and tympanic plexus.

The carotid plexus communicates with the third nerve in the cavernous sinus, and through the ophthalmic ganglion; frequently with the fourth in the formation of the nerve of the tentorium; with the Gasserian ganglion; with the *ophthalmic* division of the fifth in the cavernous sinus, and by means of the ophthalmic ganglion; with the superior maxillary, through the spheno-palatine ganglion; and with the inferior maxillary, through the otic ganglion. It sends two branches directly to the sixth nerve, which unite with it as it crosses the cavernous sinus; it communicates with the facial and auditory nerves, through the medium of the petrosal branch of the Vidian; and with the glosso-pharyngeal by means of two filaments to the tympanic nerve.

CERVICAL PORTION OF THE SYMPATHETIC NERVE.

The **superior cervical ganglion** is long and fusiform, of a reddish-grey colour, smooth, and of considerable thickness, extending from within an inch of the carotid foramen in the petrous bone to opposite the lower border of the third cervical vertebra. It is in relation, in front, with the sheath of the internal carotid artery and internal jugular vein; and, behind, with the rectus anticus major muscle.

Its **branches** are divisible into *superior, inferior, external, and internal*; to which may be added, as proper to this ganglion, *anterior*.

The **superior** (carotid nerve) is a single branch which ascends by

the side of the internal carotid, and divides into two branches ; one lying to the outer, the other to the inner side of that vessel. The two branches enter the carotid canal, and, by their communications with each other and with the carotid branch of the Vidian, constitute the *carotid plexus*.

The **inferior** or descending branch, sometimes two, is the cord of communication with the middle cervical ganglion.

The **external branches** are numerous, and may be divided into two sets : those which communicate with the glosso-pharyngeal, pneumogastric, and hypoglossal nerve, and those which communicate with the first four cervical nerves.

The **internal branches** are three in number : **pharyngeal**, to assist in forming the pharyngeal plexus ; **laryngeal**, to join the superior laryngeal nerve, and its branches ; and **superior cardiac nerve**, or *nervus superficialis cordis*.

The **anterior branches** accompany the external carotid artery with its branches, around which they form plexuses, and here and there small ganglia ; they are named, from the softness of their texture, **nervi molles**, and from their reddish hue, *nervi subrufti*. The branches accompanying the facial artery are conducted by that vessel to the submaxillary ganglion, and those which accompany the internal maxillary artery reach the otic ganglion through the medium of the middle meningeal artery.

Small ganglia are found on these plexuses, and are named from the arteries on which they are situated. The largest of these is placed between the external and internal carotid arteries in the angle of bifurcation of the common carotid ; it is named the *inter-carotid ganglion* or *gland*, and has been described by Luschka as not truly ganglionic, but similar in structure to the coccygeal gland.

The **middle cervical ganglion** (thyroid ganglion) is small, and sometimes wanting. It is situated opposite the fifth cervical vertebra, and rests against the inferior thyroid artery.

Its **superior branch**, or branches, ascend to communicate with the superior cervical ganglion.

Its **inferior branches** descend to join the inferior cervical ganglion ; one of these frequently passes in front of the subclavian artery, the other behind it.

Its **external branches** communicate with the fifth and sixth cervical nerves.

Its **internal branches** are filaments which accompany the inferior thyroid artery, **inferior thyroid plexus** ; and the **middle cardiac nerve**, *nervus cardiacus magnus*.

The **inferior cervical ganglion** (vertebral ganglion) is much larger than the preceding, and constant in its existence. It is of a semilunar form, and situated on the base of the transverse process of the seventh cervical vertebra, immediately behind the vertebral artery ; hence its designation, "*vertebral ganglion*."

Its **superior branches** communicate with the middle cervical ganglion.

The **inferior branches** pass some before and some behind the subclavian artery, to join the first thoracic ganglion.

The **external branches** consist of two sets; one which communicates with the sixth, seventh, and eighth cervical, and first dorsal nerves, and one which accompanies the vertebral artery along the vertebral canal, forming the **vertebral plexus**. The plexus sends filaments to all the branches given off by that artery, and communicates in the cranium with the filaments of the carotid plexus accompanying the branches of the internal carotid artery.

The **internal branch** is the **inferior cardiac nerve**, *nervus cardiacus minor*.

CARDIAC NERVES.—The cardiac nerves are three in number at each side—namely, superior, middle, and inferior.

The **superior cardiac nerve** (*nervus superficialis cordis*) proceeds from the lower part of the superior cervical ganglion; it descends the neck behind the common carotid artery and parallel with the trachea, crosses the inferior thyroid artery, and running by the side of the recurrent laryngeal nerve, enters the chest. The nerve of the right side passes either in front of or behind the subclavian artery and along the posterior aspect of the *arteria innominata* to the deep cardiac plexus. The left superior cardiac nerve runs by the side of the left carotid artery, and crosses the arch of the aorta to the superficial cardiac plexus.

In its course it receives branches from the pneumogastric nerve and its external laryngeal branch, and sends filaments to the thyroid gland and trachea.

The **middle cardiac nerve** (*nervus cardiacus magnus*) proceeds from the middle cervical ganglion, or in its absence, from the cord of communication between the superior and inferior ganglion. It is the largest of the three nerves, and lies parallel with the recurrent laryngeal. At the root of the neck it divides into several branches, which pass some before and some behind the subclavian artery, communicates with the superior and inferior cardiac, pneumogastric, and recurrent nerves, and descends to the bifurcation of the trachea, to join the *deep cardiac plexus*. On the left side this nerve passes between the left carotid and subclavian arteries to reach the chest, and terminates in the left side of the deep cardiac plexus.

The **inferior cardiac nerve** (*nervus cardiacus minor*) arises from the inferior cervical ganglion, communicates with the recurrent laryngeal and middle cardiac nerves, passes behind the subclavian artery and descends to the front of the bifurcation of the trachea, to the *deep cardiac plexus*. The nerve of the left side often unites with the middle cardiac nerve, either before or immediately after they enter the thorax, the combined cord joining the deep cardiac plexus.

The **SUPERFICIAL CARDIAC PLEXUS** is situated immediately beneath the arch of the aorta and in front of the right pulmonary artery. It receives the superior cardiac nerve of the *left* side and the inferior cardiac branch of the *left* pneumogastric nerve, both

of which cross the arch of the aorta between the left phrenic and pneumogastric nerve. It receives besides several filaments from the

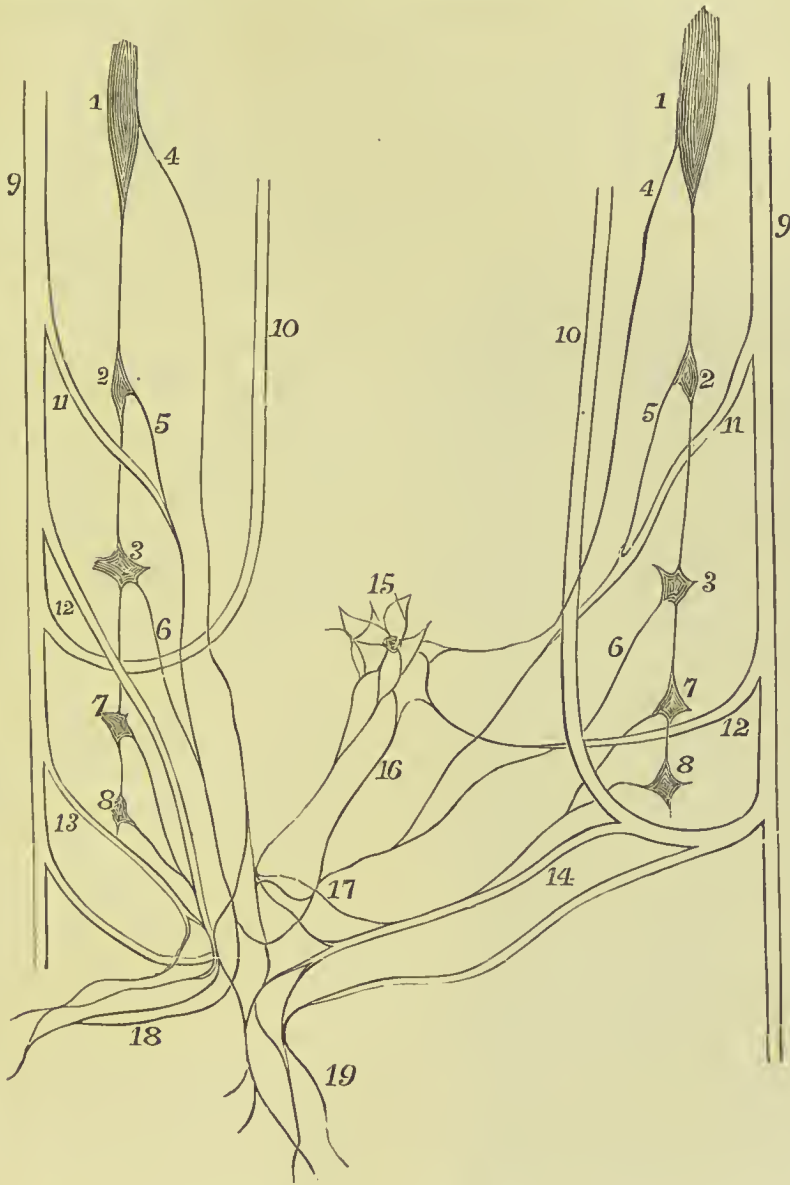


FIG. 347.—Scheme of the formation of the deep and superficial cardiac plexuses. 1. Superior cervical ganglion of the sympathetic. 2. Middle ganglion. 3. Inferior ganglion. 4. Superior cervical sympathetic cardiac branch. 5. Middle cardiac. 6. Inferior cardiac. 7. First dorsal sympathetic ganglion. 8. Second dorsal ganglion. 9. Vagus. 10. Recurrent laryngeal. 11. Superior cervical cardiac branch of vagus. 12. Inferior cardiac branch of vagus. 13. Thoracic cardiac branches of vagus. 14. Cardiac branches of left recurrent nerve. 15. Superficial cardiac plexus and ganglion. 16. Communicating branches between deep and superficial plexus. 17. Deep cardiac plexus. 18. Right and, 19. Left coronary plexuses.

deep cardiac plexus, and sometimes a cardiac branch from the right pneumogastric nerve. Connected with the plexus is a small ganglion

(sometimes wanting), the **cardiac ganglion of Wrisberg**, which lies close to the right side of the fibrous cord of the ductus arteriosus. The superficial cardiac plexus gives off filaments which pass along the front of the left pulmonary artery to the root of the left lung, where they communicate with the anterior pulmonary plexus; while the principal part of the plexus descends in the groove between the pulmonary artery and aorta to the anterior longitudinal *sulcus* of the heart, where it comes into relation with the anterior coronary artery, and becomes the *anterior coronary plexus*. At the base of the heart, the anterior coronary plexus receives several filaments from the deep cardiac plexus. Its branches are distributed to the substance of the heart in the course of the left or anterior coronary artery.

The **DEEP** or **GREAT CARDIAC PLEXUS** is situated on the bifurcation of the trachea, above the right pulmonary artery and behind the transverse portion of the arch of the aorta. It receives on the *right* side the three cardiac nerves of the sympathetic of the same side, and the cardiac branches of the right pneumogastric and right recurrent nerve. On the *left* side it receives the middle and inferior cardiac nerves of the sympathetic of the left side; the cardiac branches of the left pneumogastric (excepting the inferior), and several cardiac branches from the left recurrent nerve. Filaments also pass to this plexus from the first and second thoracic ganglia of both sides.

It will be noted that the deep cardiac plexus receives all the cardiac filaments of the sympathetic, pneumogastric, and recurrent nerves, with the exception of the left superior cardiac of the sympathetic (*nervus superficialis cordis*) and the inferior cervical cardiac of the left pneumogastric, these two nerves being destined to the superficial cardiac plexus.

The **branches** of the deep cardiac plexus, proceeding from its right and left division, pass downwards to join the coronary arteries, and outwards to the pulmonary plexuses.

From the **right division** of the plexus the branches proceed before and behind the right pulmonary artery. Those which pass in front descend upon the trunk of the pulmonary artery to the left coronary artery, and help to form the *anterior coronary plexus*; those which pass behind the right pulmonary artery are distributed to the right auricle; a third set of filaments, proceeding from the right division of the deep cardiac plexus, follow the course of the right pulmonary artery to the anterior pulmonary plexus.

From the **left division** of the plexus branches proceed beneath the arch of the aorta immediately to the right of the ligament of the ductus arteriosus to join the superficial cardiac plexus; others pass outwards with the pulmonary artery to the pulmonary plexus; a few descend to the left auricle; but the chief bulk pass on to the right coronary artery and form the *posterior coronary plexus*.

The **anterior coronary plexus** proceeds from the superficial cardiac plexus, and receives other filaments from the deep cardiac

plexus. It is distributed with the branches of the coronary artery on the anterior aspect of the heart.

The **posterior coronary plexus** proceeds from the deep cardiac plexus, and principally from its left division. It follows the course of the arteries distributed to the posterior aspect of the heart.

THORACIC PORTION OF THE SYMPATHETIC NERVE.

The thoracic portion of the sympathetic nerve is the trunk of the sympathetic in its course through the cavity of the thorax. It lies by the side of the vertebral column on the heads of the ribs and intercostal spaces, but at its lowest part comes into relation with the sides of the bodies of the two last dorsal vertebrae.

The **THORACIC GANGLIA** (Fig. 348) are twelve in number at each side. They are flattened and triangular, or irregular in form, and present the peculiar reddish-grey colour and pearly lustre of sympathetic ganglia in general; they rest against the heads of the ribs, and are covered by the pleura costalis. The first two ganglia and the last are usually the largest; the latter being situated on the side of the body of the last dorsal vertebra.

Their **branches** are branches of communication and branches of distribution. Some ascending filaments from the first ganglion assist in the formation of the vertebral plexus.

The **external or communicating branches**, usually two in number for each ganglion, communicate with the intercostal nerves; of these, one is greyish in colour, and is believed to pass from the ganglion to the spinal nerve; the other, of a white colour, probably is spinal in its origin, and is distributed with the sympathetic nerves.

The **internal or visceral branches** proceeding from the five or six upper ganglia, are of small size, and distributed to the aorta, heart, œsophagus, vertebral column, and lungs. The branches to

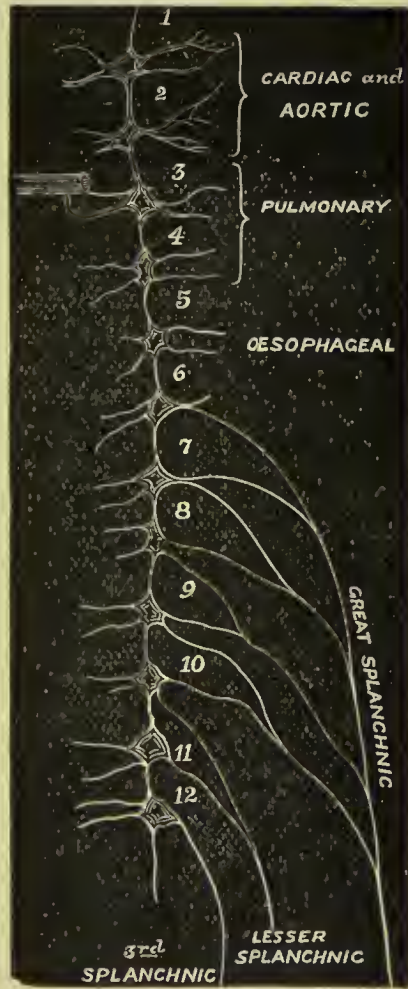

FIG. 348.—Diagram of the thoracic sympathetic chain, and the branches given off from it. Opposite 3, the communications with one of the dorsal nerves are shown.

the lungs proceed from the third and fourth ganglia, and go to join the posterior pulmonary plexus. The visceral branches of the six lower ganglia unite to form the three splanchnic nerves.

The **great splanchnic nerve** proceeds from the sixth dorsal ganglion, and receiving the branches of the seventh, eighth, ninth, and tenth, passes downwards along the front of the vertebral column, and, piercing the crus of the diaphragm, terminates in the semilunar ganglion.

The **lesser splanchnic nerve** is formed by filaments which issue from the tenth and eleventh ganglia; it pierces the crus of the diaphragm, and joins the solar plexus near the middle line, frequently distributing branches also to the renal plexus.

The **third or renal splanchnic nerve** proceeds from the last thoracic ganglion, and, piercing the diaphragm, terminates in the renal plexus. When absent, the place of this nerve is supplied by the lesser splanchnic.

The **semilunar ganglion** is a large, irregular, gangliform body, pierced by numerous openings, and appearing like the aggregation of a number of smaller ganglia, having spaces between them. By its upper and posterior extremity each ganglion receives the corresponding great splanchnic nerve. It is situated by the side of the celiac axis and root of the superior mesenteric artery, and extends outwards to the supra-renal capsule. The ganglia communicate both above and below the celiac axis and form a gangliform circle, from which branches pass off in all directions, like rays from a centre. Hence the entire circle has been named the *solar plexus*.

The **solar or epigastric plexus** receives the great and lesser splanchnic nerves, the termination of the right pneumogastric nerve, some filaments from the right phrenic nerve, and sometimes one or two from the left. It sends forth numerous filaments which accompany, under the name of **plexuses**, all the branches given off by the abdominal aorta. Thus we have derived from the solar plexus the—

Phrenic, or diaphragmatic plexuses,	Renal plexuses,
Gastric plexus,	Superior mesenteric plexus,
Hepatic plexus,	Aortic plexus,
Splenic plexus,	Spermatic plexuses,
Supra-renal plexuses,	Inferior mesenteric plexus.

In connection with the **phrenic plexus** of the right side, there is described a small **ganglion diaphragmaticum**, which is situated near the supra-renal capsule. In this ganglion branches of the right phrenic nerve communicate with those of the sympathetic.

The **supra-renal plexuses** are remarkable for their large size, and for a ganglion, which has received the name of *ganglion supra-renalé*.

The **renal plexuses** are large, and receive the third splanchnic nerve. They are joined by filaments from the aortic plexus and

lesser splanchnic nerve. The nerves passing to the kidney from each plexus are about fifteen or twenty in number ; they accompany the branches of the renal artery and have numerous small ganglia upon them. Branches are given off from the renal plexuses to the inferior vena cava and spermatic plexuses.

The **superior mesenteric plexus** has several small ganglia at the root of the artery ; and its nerves, which are whiter than those of the other plexuses, form a kind of nervous sheath to the artery and its branches.

The **aortic plexus** is a continuation of the solar plexus downwards on the aorta, for the supply of the inferior branches of that trunk ; it receives also branches from the renal plexuses and lumbar ganglia. It is the source of origin of the inferior mesenteric plexus and part of the spermatic plexus, and terminates below in the hypogastric plexus. It likewise distributes branches on the inferior vena cava.

The **spermatic plexus** is derived from the renal plexus, but receives filaments from the aortic plexus.

The **inferior mesenteric plexus** is derived chiefly from the aortic plexus.

LUMBAR PORTION OF THE SYMPATHETIC NERVE.

The lumbar portion of the trunk of the sympathetic is situated on the vertebral column, close to the anterior border of the psoas magnus muscle. It is continuous above, under the edge of the diaphragm, with the thoracic portion of the nerve, and below it descends upon the sacrum, in front of the anterior sacral foramina, to the coccyx. It presents four small ganglia and an intermediate cord.

The **lumbar ganglia**, four in number at each side, of a pearly-grey colour and fusiform shape, are situated on the anterior part of the bodies of the lumbar vertebræ.

The **branches** of the lumbar ganglia are branches of communication and branches of distribution.

The **external** or **communicating branches**, two or three in number from each ganglion, and longer than in the other regions, communicate with the lumbar nerves.

The **internal** or **visceral branches** consist of two sets : the upper pass inwards in front of the abdominal aorta, and join the **aortic plexus** ; the lower cross the common iliac arteries, and unite over the promontory of the sacrum to form the hypogastric plexus.

The **hypogastric plexus** is formed by the termination of the aortic plexus, and by the union of branches from the lower lumbar ganglia. It is situated over the promontory of the sacrum, between the two common iliac arteries, and bifurcates inferiorly into two lateral portions, **inferior hypogastric** or **pelvic plexuses**.

PELVIC PLEXUSES.

The **inferior hypogastric** or **pelvic plexus** on each side is placed in the lower part of the pelvic cavity, at the side of the rectum and bladder, extending in the female to the side of the vagina also. The nerve filaments are derived from the hypogastric plexus; they form frequent communications, and small ganglia are situated at the points of intersection; additional filaments are derived from the second, third, and fourth sacral nerves, and from the two upper sacral sympathetic ganglia. The plexus gives off branches to all the pelvic viscera, which follow the distribution of the internal iliac artery, and receive the same names as the branches of that vessel which they accompany. The nerves distributed to the bladder and vagina contain more nerve filaments derived from spinal nerves than the other branches of the plexus.

The **hæmorrhoidal plexus** arises from the back of the pelvic plexus, and passes to the rectum, where it communicates with the superior hæmorrhoidal branches of the inferior mesenteric plexus.

The **vesical plexus** comes from the front of the pelvic plexus. The nerves at first accompany the vesical arteries, but afterwards leave them, and penetrate the muscular coat to reach the mucous membrane. They are chiefly distributed to the base and sides of the bladder, and form secondary plexuses on the vasa deferentia and vesiculæ seminales.

The **prostatic plexus** is given off by the lower part of the pelvic plexus. It consists of nerves of considerable size, which are distributed to the prostate gland, vesiculæ seminales, and penis; those passing to the latter organ are named *cavernous nerves*, being distributed to the corpus cavernosum.

The **vaginal plexus**, derived from the lower part of the pelvic plexus, is distributed to the mucous membrane and erectile tissue of the vagina.

The **uterine plexus**, given off by the upper part of the pelvic plexus, accompanies the branches of the uterine artery, between the layers of the broad ligament, to the side of the uterus. The nerves are for the most part distributed to the mucous membrane of the lower part of the body and cervix, several large ganglia being found in the plexus by the side of the cervix; other branches pass to the muscular coat, penetrating as far as the fundus.

SACRAL PORTION OF THE SYMPATHETIC NERVE.

The **sacral ganglia** are four or five in number at each side. They are situated on the sacrum, close to the anterior sacral foramina, and resemble the lumbar ganglia in form and mode of connection, although much smaller in size.

The **external** or **communicating branches** are two from each ganglion, which pass outwards to communicate with the anterior sacral nerves and with the coccygeal nerve.

The **internal** or **visceral branches** communicate very freely with the inferior hypogastric plexuses, and are distributed to the pelvic viscera. The last pair of sacral ganglia give off branches which join a small ganglion, situated on the first bone of the coccyx, called the *ganglion impar*, or *azygos*. This ganglion serves to connect the extremities of the two sympathetic nerves. It gives off a few small branches to the coccyx and rectum, and communicates with the coccygeal nerve.

COCCYGEAL GLAND.

Numerous branches from the ganglion impar are given off to a peculiar reddish body situated on the anterior aspect of the tip of the coccyx, and called by Luschka, by whom it was first described, the *coccygeal gland*. It consists of an aggregation of little lobules or granules, and has been shown by Arnold to be formed by a number of dilated and tortuous arteries connected with the middle sacral artery. In the stroma of the organ scattered nerve cells are found.

ORGANS OF SENSE.

The organs of sense, the instruments by which the animal frame is brought into relation with surrounding nature, are five in number. Four of these organs are situated within the head; viz., the apparatus of smell, sight, hearing, and taste; the remaining organ, that of touch, is resident in the skin, and distributed over the surface of the body. The latter was described in the section on Histology, p. 63.

THE NOSE AND NASAL FOSSÆ.

The organ of smell consists essentially of two parts: one external, the **nose**; the other internal, the **nasal fossæ**.

The nose is the triangular pyramid which projects from the centre of the face, immediately above the upper lip. Superiorly it is connected with the forehead by means of a narrow bridge; inferiorly, it presents two openings, the **nostrils**, which overhang the mouth, and are so constructed that the odour of all substances must be received by the nose before they can be introduced within the lips. The septum between the openings of the nostrils is called the **columna**. Their entrance is guarded by a number of stiff hairs (*vibrissæ*) which project across the openings, and act as a filter in preventing the introduction of foreign substances, such as dust or insects, with the current of air intended for respiration.

The anatomical elements of which the nose is composed are:
1. Integument. 2. Muscles. 3. Bones. 4. Cartilages. 5. Mucous membrane. 6. Vessels and nerves.

1. The **integument** forming the tip (*lobulus*) and wings (*alæ*) of the nose is extremely thick and dense, so as to be with difficulty separated from the cartilages. It is furnished with an abun-

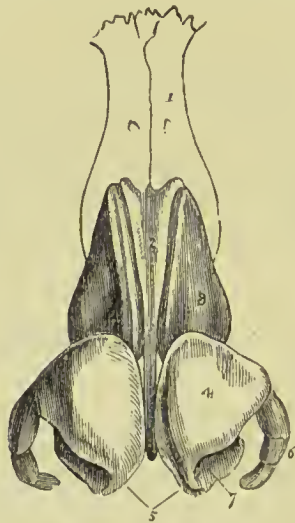
dance of *sebaceous glands*, which, by their oily secretion, protect the extremity of the nose under alternations of temperature. The sebaceous matter of these glands becomes of a dark colour near the surface, from altered secretion, and also from attraction of the carbonaceous matter floating in the atmosphere; hence the spotted appearance which the tip of the nose presents in large cities. When the integument is firmly compressed, the inspissated sebaceous secretion is squeezed out, and taking the cylindrical form of the excretory ducts of the glands, has the appearance of small white maggots (grubs; comedones) with black heads.

2. The **muscles** are brought into view by reflecting the integument; they are the *pyramidalis nasi*, *compressor nasi*, *dilatator naris*, *levator labii superioris aëque nasi*, and *depressor aë nasi*. They have been already described with the muscles of the face.

3. The **bones** of the nose are—the nasal, and nasal processes of the superior maxillary.

4. The **cartilages** give form and stability to the nose, providing, at the same time, by their elasticity, against injuries. They are five in number, namely, the—

FIG. 349. — The cartilages of the nose. 1. One of the nasal bones. 2. Cartilage of the septum. 3. Lateral cartilage. 4. Alar cartilage. 5. Central portions of the alar cartilages which constitute the *columna*. 6. Sesamoid cartilages. 7. The nostril.



Cartilage of the septum,
Two lateral cartilages,
Two alar cartilages.

The **cartilage of the septum**, somewhat triangular in form, divides the nose into its two nostrils. It is connected above with the nasal bones and lateral cartilages; behind, with the ethmoidal septum and vomer; and below, with the palate processes of the superior maxillary bones. The alar cartilages and *columna* move freely on the

cartilage of the septum, being but loosely connected with it by perichondrium.

The **lateral cartilages** are also triangular; they are connected, *in front*, with the cartilage of the septum; *above*, with the nasal bones; *behind*, with the nasal processes of the superior maxillary bones; and *below*, with the alar cartilages.

Alar Cartilages (lower lateral cartilages).—Each of these cartilages is curved so as to correspond with the walls of the nostril, to which it forms a kind of rim. The inner portion is loosely connected with the same part of the opposite cartilage, to form the *columna*. It is expanded and thickened at the point of the nose, to constitute the *lobe*; and on the side makes a curve corresponding with that of the ala. This curve is prolonged backwards and downwards in the direction of the posterior border of the ala by three or

four small cartilaginous plates (**sesamoid cartilages**), which are appendages of the alar cartilage.

The whole of the cartilages are connected with each other, and to the bones, by perichondrium, which, from its membranous structure, permits of the freedom of motion existing between them.

The lower margin and back part of the ala of the nose is devoid of cartilage, and is composed of areolar and elastic tissue to which the skin is closely adherent; it resembles the lobule of the ear.

5. The **mucous membrane**, lining the interior of the nose, is continuous with the skin externally, and with the pituitary membrane of the nasal fossæ within. Around the entrance of the nostrils it is provided with the *vibrissæ*.

6. **Vessels and Nerves**.—The *arteries* of the nose are—the lateral nasal from the facial, the artery of the septum from the superior coronary, the nasal branch of the ophthalmic and the infra-orbital.

Its *nerves* are—the facial, infra-orbital, infra-trochlear, and nasal branch of the ophthalmic.

NASAL FOSSÆ.

To obtain a good view of the *nasal fossæ*, the face must be divided through the nose by a vertical incision, a little to one side of the middle line.

The **nasal fossæ** are two irregular, compressed cavities, extending backwards from the nose to the pharynx. They are bounded *superiorly* by the lateral cartilages of the nose, and by the nasal bones, ethmoid, and sphenoid; *inferiorly* by the hard palate; and, in the *middle* line, they are separated by a bony and cartilaginous septum. A plan of the boundaries of the nasal fossæ will be found at p. 129.

On the outer wall of each fossa, in the dried skull, are three projecting processes, termed spongy bones. The two superior belong to the ethmoid, the inferior is a separate bone. In the fresh fossæ these are covered with mucous membrane, and serve to increase the surface of that membrane by their prominence and convoluted form. The space intervening between the superior and middle spongy bone is the **superior meatus**; the space between the middle and inferior,

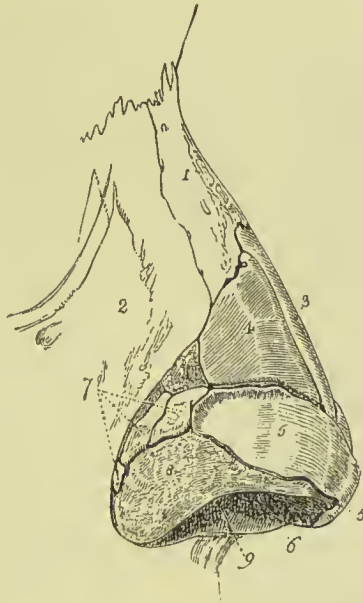

FIG. 350. — The cartilages and bones of the nose viewed from the side. 1. Nasal bone. 2. Nasal process of the superior maxillary bone. 3. Cartilage of the septum. 4. Lateral cartilage. 5, 5. Alar cartilage. 6. Inner portion of the alar cartilage. 7. Sesamoid cartilages. 8. Areolar tissue of the ala nasi. 9. Aperture of the nostril.

the **middle meatus**; and that between the inferior and the floor of the fossa, the **inferior meatus**.

The openings into these spaces have been described along with the bones of the skull, p. 129. It should, however, be noted that two of the openings there mentioned, namely, the sphenopalatine and anterior palatine foramina, are not seen in the recent state, being covered by the mucous membrane. In the position of the anterior palatine canal there is, not unfrequently, a small cæcal tube, the remains of a structure present in the man during embryonic life, and called the *organ of Jacobson*. This organ is present in mammals generally in adult life, and appears as a double tube in the nasal septum, supported by a plate of cartilage, the *cartilage of Jacobson*.

The **mucous membrane** of the nasal fossæ is called *pituitary*, or *Schneiderian*; the former name being derived from the nature of

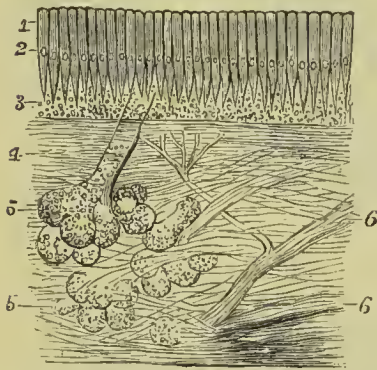


FIG. 351.—A section of the mucous membrane in the olfactory region. 1. Coloured part of the epithelium. 2. Nucleus. 3. Deeper part, containing olfactory cells and filaments. 4. Connective tissue. 5, 5. Mucous glands. 6, 6. Nerve twigs giving off terminal branches.

its secretion, the latter from Schneider, who was the first to show that the secretion of the nose proceeded from the mucous membrane, and not from the brain, as was previously imagined. It is closely adherent to the periosteum, constituting what is called a fibromucous membrane, and is continuous with the general gastro-pulmonary mucous membrane. From the nasal fossæ it may be traced through the openings in the meatuses, into the sphenoidal and ethmoidal cells; into the frontal sinuses; into the antrum maxillare; through the nasal duct to the surface of the eye, where it is continuous with the conjunctiva; along the Eustachian tubes into the tympanum and mastoid cells, to which it

forms the lining membrane; and through the posterior nares into the pharynx and mouth, and thence through the lungs and alimentary canal. Bigelow has pointed out that the mucous membrane covering the middle and inferior turbinated bones contains a true cavernous structure, similar to that of the corpus cavernosum penis. The cavernous spaces are irregular in shape and variable in size; they approach quite near to the surface of the mucous membrane and the bone, and they communicate freely with each other.

The surface of the membrane is furnished with laminated squamous epithelium near the aperture of the nares, and with ciliated columnar epithelium in the respiratory tract; in the latter it is also furnished with mucous glands, which are especially numerous on the septum at its posterior part. The mucous membrane which covers the upper and middle turbinated bones and the upper part of the septum (the olfactory tract) is of a darker colour, softer and more pulpy, its epithelium is columnar and non-ciliated, and the

epithelial processes are prolonged at their deep extremities into threads which appear to join the connective tissue corpuscles. It also contains numerous glands, but these are more simple than the glands of the respiratory tract. Mingled with the cells of the columnar epithelium are certain peculiar rod-like bodies, each of which is connected with or grows out from a nucleated cell (*olfactory cell*), while from the deeper surface of the same cell proceeds a fine thread, which is supposed to be continuous with a filament of the olfactory nerve. They bear a striking resemblance to the retinal rods and cones.

Vessels and Nerves. — The *arteries* of the nasal fossæ are the anterior and posterior ethmoidal, from the ophthalmic; and sphenopalatine and pterygo-palatine from the internal maxillary.

The *nerves* are — olfactory, sphenopalatine and naso-palatine from Meckel's ganglion, and nasal branch of the ophthalmic.

The filaments of the olfactory nerves differ from those of the cerebral and spinal nerves generally, in being devoid of the medullary sheath; they form a fine anastomotic network, and probably terminate in the olfactory cells above described. In the frog the olfactory fibres have been observed breaking up into a bundle of fine, pale, varicose fibrils which perforate the mucous membrane, and each of these appears then to join an olfactory cell (Schultze and Kölliker).

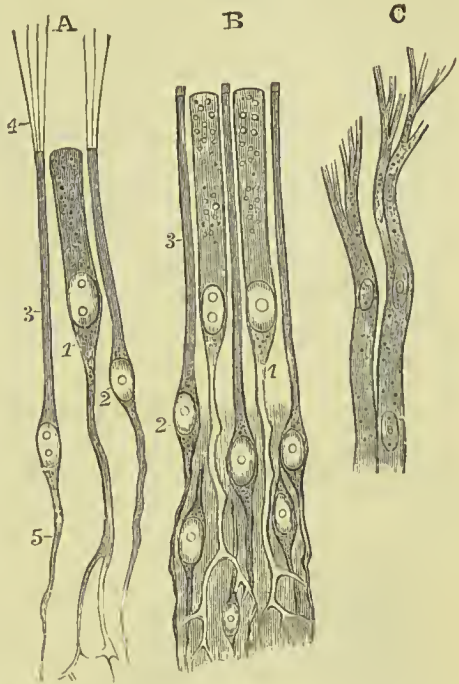


FIG. 352.—Olfactory cells and nerve terminations. A. Olfactory cells from frog. B. From man. C. Filaments of olfactory nerve from dog. 1. Epithelial cells, extending deeply into ramified processes. 2. Olfactory cells. 3. The rod-like processes of olfactory cells. 4. Their ciliated extremities. 5. Their central filaments.

ORGAN OF VISION.

The organ of vision consists of the two eyes and their connections with the brain.

The eyes are situated in the orbital fossæ, on each side of the upper part of the face; they are freely movable in consequence of being surrounded by fat and contained in a smooth fibrous capsule (*capsule of Tenon*), and have numerous muscles to perform their movements. They are protected from external violence by being situated in cavities with osseous walls, and have in front both

cleansing and protective apparatus against the intrusion of foreign bodies. The fossæ in which the eyes are situated have their axes directed outwards, but the eyes themselves are directed much more forwards, varying, however, in their direction with the distance or nearness of the object looked at, their axes being parallel in looking at distant objects, but converging slightly when near objects are viewed. The optic nerves follow the direction of the orbits, and therefore enter the eyeballs on their nasal side.

We shall in the first place give a short account of those structures which, although not essential to vision, are provided for the protection of the anterior part of the eye.

These appendages of the eye (*tutamina oculi*) are—the eyebrows, eyelids, eyelashes, conjunctiva, caruncula lachrymalis, and lachrymal apparatus.

APPENDAGES OF THE EYE.

The **eyebrows** (*supercilia*) are two prominent arches of integument which overlie the superciliary ridges of the frontal bone.

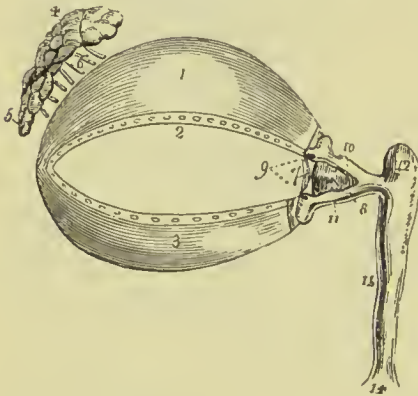


FIG. 353.—Appendages of the eye. 1. Superior tarsal plate. 2. Lower border of the plate on which are seen the openings of the Meibomian glands. 3. Inferior tarsal plate; along the upper border of this plate the openings of the Meibomian glands are likewise seen. 4. Lachrymal gland, its superior or orbital portion. 5. Inferior or palpebral portion. 6. Lachrymal ducts. 7. Plica semilunaris. 8. Caruncula lachrymalis. 9. Puncta lachrymalia. 10. Superior lachrymal canaliculus. 11. Inferior lachrymal canaliculus. 12. Lachrymal sac. 14. Dilatation of the nasal duct, where it opens into the inferior meatus of the nose. 15. Nasal duct.

They are covered with short, stiff hairs directed obliquely upwards and outwards, and are connected beneath with the orbicularis palpebrarum, occipito-frontalis, and corrugator supercillii muscles, by which they are moved. They serve to shade the eyes from too vivid light, to protect them from the entrance of dust from above, and to carry the moisture from the forehead on to the temple and lateral parts of the face, and so prevent its entering the eyes.

The **eyelids** (*palpebræ*) are two movable folds, which serve by their closure to protect the anterior part of the eye from injury, or to exclude the light, as during sleep. When open they have an elliptical fissure between them (*rima palpebrarum*), and it is upon the size of this that the apparent size of the eye depends. The angles of junction of the two lids are called **canthi**. The **outer canthus** is acute, so that but a small space is left between the lids; the **inner canthus** is prolonged for a short distance towards the nose, and a triangular space called **lacus lachrymalis** is left between

the lids in this situation. At the commencement of this space, upon the edge of each of the lids, is a small angular projection, the **lachrymal papilla**; and at the apex of each papilla is a small orifice, **punctum lachrymale**, the commencement of the lachrymal canaliculus.

The eyelids have entering into their structure, *integument, orbicularis palpebrarum muscle, tarsal plates, palpebral ligament, Meibomian glands, and conjunctiva.*

The **areolar tissue** of the skin of the eyelids is remarkable for its looseness, and the absence of adipose substance; it is particularly liable to serous infiltration.

The **fibres of the orbicularis** are for the most part thin and pale, but a thicker band of fibres has been found internal to the eyelashes, constituting the *ciliary muscle* of Riolan.

The **tarsal plates** are two thin plates of dense connective tissue, about an inch in length, which give form and support to the eyelids. The *upper* plate is of a semilunar form, thicker in the middle than at its extremities; its lower border is broad and flat, its upper thin, and gives attachment to the levator palpebræ muscle and the palpebral ligament. The *lower* plate, narrower than the upper, is situated in the substance of the lower lid. Its upper border is flat, and corresponds with the flat edge of the upper plate; the lower border is attached to the palpebral ligament.

Near the inner canthus, the tarsal plates terminate at the commencement of the lacus lachrymalis, and are attached to the margin of the orbit by the tendo oculi. At their outer extremity they terminate at a short distance from the canthus, and are retained in position by a fibrous band which is part of the palpebral ligament, and is called the *external tarsal ligament*.

The **palpebral ligament** (*broad tarsal ligament*) is a fibrous membrane which is firmly attached to the periosteum around the margin of the orbit, and to the internal free edges of the tarsal plates. It is thick and dense for the outer half of the orbit, but becomes thin to its inner side. Its use is to retain the tarsal plates in their place, and give support to the lids.

The **Meibomian glands** are embedded in grooves on the under surface of each tarsal plate, and are distinctly seen on examining the inner aspect of the lids. They have the appearance of parallel strings of pearls, about thirty in

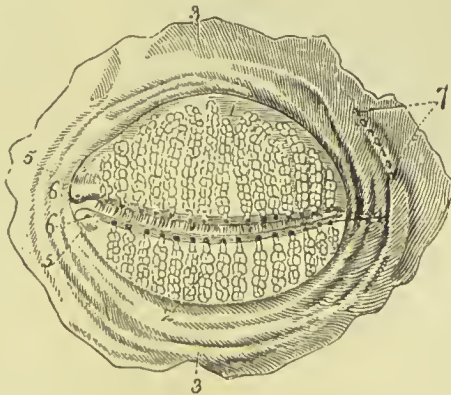


FIG. 354.—Meibomian glands, as seen upon the inner side of the eyelids. 1. Upper lid. 2. Lower lid. 3, 3. Conjunctiva. 4. Apertures of the Meibomian glands, forming a row along the free border of each eyelid. 5, 5. Papillæ lachrymales. 6, 6. Puncta lachrymalia. 7. Apertures of the efferent ducts of the lachrymal gland.

number in the upper plate, and somewhat fewer in the lower; they open by minute foramina on the edges of the lids. They correspond

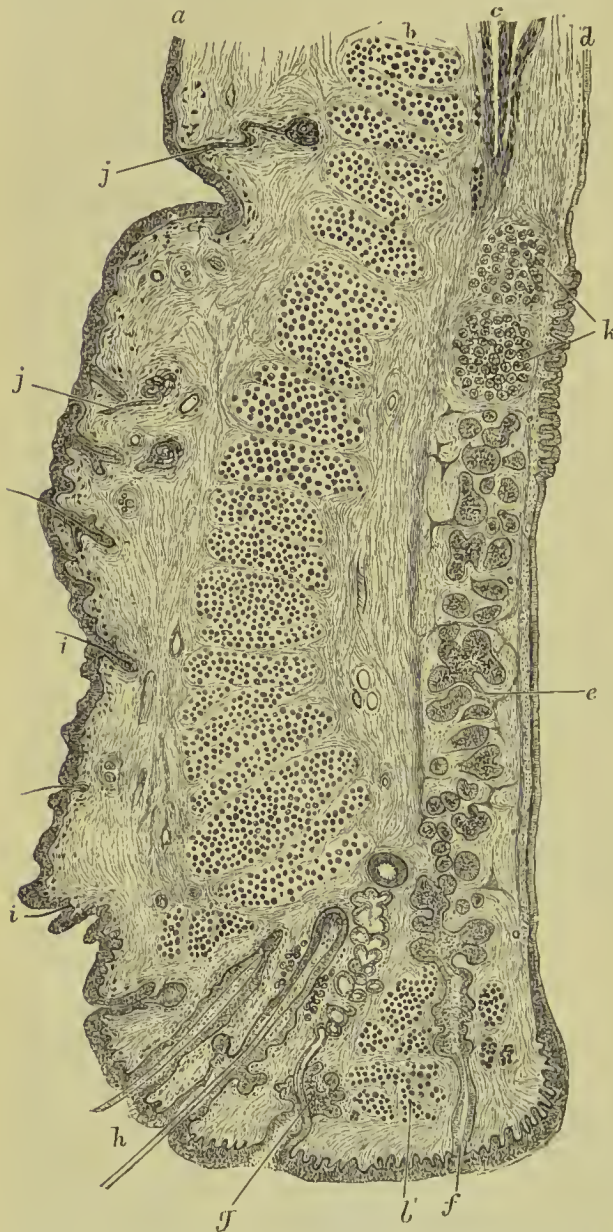


FIG. 355.—Vertical antero-posterior section of upper eyelid. *a*. Skin. *b*. Orbicularis palpebrarum. *b'*. Ciliary muscle of Riolan. *c*. Levator palpebrae. *d*. Conjunctiva. *e*. Meibomian gland, with (*f*) its duct. *g*. Gland of Moll. *h*. Eyelashes. *i, i*. Hair follicles containing hairs. *j, j*. Sweat glands. *k*. Racemose glands of conjunctiva.

in length with the breadth of the plate, and are consequently longer in the upper than in the lower lid. Each gland consists of a single lengthened follicle or tube, into which a number of small clusters of glandular vesicles open; the latter are so numerous as almost to conceal the tube by which the secretion is poured out on the edges of the lids. Occasionally an arch is formed between two of the follicles, producing a graceful appearance. The tubes are lined by a stratified epithelium, and the gland vesicles by cubical cells; the lumen of the gland is usually filled up with the fatty secretion and partly disintegrated epithelial cells.

The edges of the eyelids are furnished with strong, short, curved hairs, called **eyelashes** (*cilia*), arranged in two to four rows; those of the upper lid curving upwards, and those of the lower downwards, so as not to interlace with each other in the closure of the lids, and prove an impediment to the opening of the eyes. Near the point of emergence of the eyelashes are the openings of the *glands of Moll*, arranged in

the opening of the eyes. Near the point of emergence of the eyelashes are the openings of the *glands of Moll*, arranged in

several rows ; the glands themselves are situated near the roots of the hairs, and between the fibres of the mass of the orbicularis and the ciliary muscle of Riolan. In structure they resemble sweat ducts, being composed of a bent tube, lined with cubical epithelial cells.

The **conjunctiva** is the mucous membrane of the eye. It covers the whole of its anterior surface, and is reflected on the lids so as to form their internal layer. It is continuous with the general gastro-pulmonary mucous membrane, and sympathises in its affections, as may be observed in various diseases. From the surface of the eye it may be traced through the lachrymal ducts into the lachrymal gland, along the edges of the lids it is continuous with the mucous lining of the Meibomian glands, and at the inner angle of the eye it may be followed through the lachrymal canaliculi into the lachrymal sac, and thence downwards through the nasal duct into the inferior meatus of the nose. Where it covers the cornea the conjunctiva is thin, transparent, and inseparable from the corneal substance ; it consists of stratified epithelial cells alone. In the conjunctiva at the circumference of the cornea a plexus of vessels is found, but this never extends entirely across the latter. The conjunctiva over the sclerotic is also thin and transparent, but is loosely applied and glides freely over the surface of the eyeball ; it is freely supplied with blood by an irregularly disposed plexus of vessels. These vessels are readily distinguished from those of the sub-conjunctival tissue, as the latter radiate in nearly straight lines from the circumference of the cornea, and do not glide over the surface of the sclerotic on pressure. The sclerotic conjunctiva consists of stratified epithelium supported by a sub-epithelial layer, composed of white fibrous and elastic tissue, in the meshes of which numerous lymph corpuscles are seen.

The palpebral conjunctiva is thick, opaque, and red ; it presents papillæ on its surface, and very closely resembles ordinary mucous membrane in structure, but the papillæ are limited to the part below the level of the tarsal plate. It consists of a stratified epithelium, supported by an elastic submucous tissue ; in the latter, numerous simple follicles are found, and near the reflected portion, certain racemose glands, similar in structure to the lachrymal gland. Bruch has described masses of lymphoid tissue as occupying the conjunctiva of the fornix conjunctivæ, and Henle has named these masses *trachoma glands* ; it appears doubtful, however, if they are present in normal conditions of the conjunctiva.

Between the eyelids and ball of the eye the conjunctiva forms an upper and lower fold, which are called the **superior** and **inferior palpebral folds** (*retro-tarsal folds*), the upper being the larger ; they are now frequently spoken of as the **upper** and **lower fornix conjunctivæ**.

The **caruncula lachrymalis** is the small reddish body which occupies the lacus lachrymalis at the inner canthus of the eye. In health it presents a bright pink tint ; in sickness it loses its colour

and becomes pale. It is studded with fine hairs, and consists of a dozen racemose sebaceous glands, with some few fat cells intermingled, a few fibres of unstripped muscle, and a covering of mucous membrane.

Immediately to the outer side of the caruncula is a slight duplicature of the conjunctiva, called **plica semilunaris**; it is simply a fold of conjunctiva, and is the rudiment of the third lid or *membrana nictitans* of birds.

Vessels and Nerves.—The eyelids and other appendages of the eye are supplied with blood by the nasal, palpebral, and lachrymal branches of the ophthalmic, and the angular branch of the facial artery. The nerves are derived from the facial and fifth nerves.

LACHRYMAL APPARATUS.

The lachrymal apparatus consists of the lachrymal gland with its excretory ducts; the puncta lachrymalia and lachrymal canaliculi; the lachrymal sac and nasal duct.

The **lachrymal gland** is situated at the upper end and outer part of the orbit, in a depression of the orbital plate of the frontal bone, with the periosteum of which bone it is connected by fibrous bands; by its under surface it is in relation with the globe of the eye, and the superior and external rectus muscles. It is oval in shape, about three-quarters of an inch long, convex on its upper and concave on its under surface. The anterior portion is frequently separated from the rest by a slight depression, and is then described as the *palpebral portion* (*accessory gland of Rosenmüller*); it is situated in the upper eyelid, and extends downwards to the superior margin of the tarsal cartilage. The gland consists of a number of aggregated racemose glands similar in structure to the salivary and mucous glands. The secretion is conveyed away by from eight to twelve small ducts which run for a short distance beneath the conjunctiva, and open on its surface by separate orifices, about a twentieth of an inch apart, the greater number in the fold above the outer canthus, and two of them in the fold below.

The **lachrymal canaliculi** commence at the minute openings, puncta lachrymalia, seen on the lachrymal papillæ of the lids at the outer extremity of the lacus lachrymalis, and proceed inwards to the lachrymal sac, where they terminate beneath a valvular semilunar fold of mucous membrane (*valve of Huschke*). The *superior* duct is the narrower and longer of the two; it at first ascends and then suddenly turns inwards towards the sac, forming an abrupt angle. The *inferior* duct forms the same kind of angle by descending at first and then turning abruptly inwards. Both canals are dilated where they are bent. A valve-like projection (*valve of Foltz*) has been described as projecting from the side into the interior of the vertical portion of each canaliculus near the punctum lachrymale; it seems to be sufficient to close the tube completely when it is flattened by the orbicularis and tensor tarsi muscles. It no doubt

prevents the tears being driven back when such pressure is applied, as in winking; and as a consequence they are then driven forward into the lachrymal sac. The two fasciculi of the tensor tarsi muscle are inserted into the canaliculi, and serve to draw them inwards and compress them.

The **lachrymal sac** is the dilated upper extremity of the nasal duct. It is lodged in the groove of the lachrymal bone, and is often distinguished internally from the nasal duct by a semilunar or circular valve. The sac consists of mucous membrane, but is covered in and retained in place by a fibrous expansion, derived from the tendon of the orbicularis, which is inserted into the ridge on the lachrymal bone; it is also covered by the tensor tarsi muscle, which arises from the same ridge, and when in action makes pressure on the lachrymal sac.

The **nasal duct** is a short canal, about three-quarters of an inch in length, directed downwards, backwards, and a little outwards to the inferior meatus of the nose, into which it opens. It is lined by mucous membrane, which is continuous with the conjunctiva above, and with the pituitary membrane of the nose below; it frequently forms an imperfect valve (*valve of Hasner*) at the lower opening of the duct.

The mucous membrane of the canaliculi is covered by a stratified scaly epithelium, and that of the lachrymal sac and nasal duct by columnar ciliated cells.

Vessels and Nerves.—The lachrymal gland is supplied with blood by the lachrymal branch of the ophthalmic artery, with nerves by the lachrymal branch of the ophthalmic, and the orbital branch of the superior maxillary.

GLOBE OF THE EYE.

The globe or ball of the eye is irregularly spheroidal in form, having the segment of a smaller sphere (the cornea) projecting from it anteriorly, and being slightly flattened behind. Its transverse diameter is about 24 mm., the horizontal 23.5 mm., and the vertical 23.1 mm. Around the eyeball is a layer of fascia which separates it from the fat of the orbit, and enables it to move smoothly; this is the so-called *tunica vaginalis oculi*, or *capsule of Tenon*; it is pierced by the tendons of the straight and oblique muscles, and is connected with the sclerotic by means of delicate fibrous threads.

The globe of the eye is composed of a strong external fibrous coat, called the *sclerotic*, with its clear anterior portion, the *cornea*; a middle vascular and pigmentary covering, the *choroid*, which is also continued forwards to form a partition, the *iris*; and an internal nervous tunic, the *retina*. It encloses certain refracting media, for the purpose of bringing rays of light to a focus on the retina; these are the *vitreous* and *aqueous humour*, and the *crystalline lens*.

EXTERNAL TUNIC.—**Sclerotic.**—The sclerotic (*σκληρός*, hard) forms the outer covering of the posterior four-fifths of the globe of the

eye. It is continuous posteriorly with the outer sheath of the optic nerve derived from the dura mater, and is pierced by the ciliary nerves and arteries. Anteriorly its fibres are continuous with the transparent ones of the cornea. It is thickest behind, but is strengthened in front by an expansion of the recti tendons, forming the **tunica albuginea**; this is covered for the greater part of its extent by the conjunctiva, and by reason of its brilliant whiteness gives occasion to the common expression, "the white of the eye." In structure the sclerotic is found to consist of white fibrous tissue, with some few elastic fibres and a great number of stellar nucleated cells; the fibres are arranged in bundles which run both longitudinally and transversely, the superficial layers being chiefly longitudinal. The inner surface of the sclerotic is in contact with the choroid, and is connected to it by means of numerous threads of

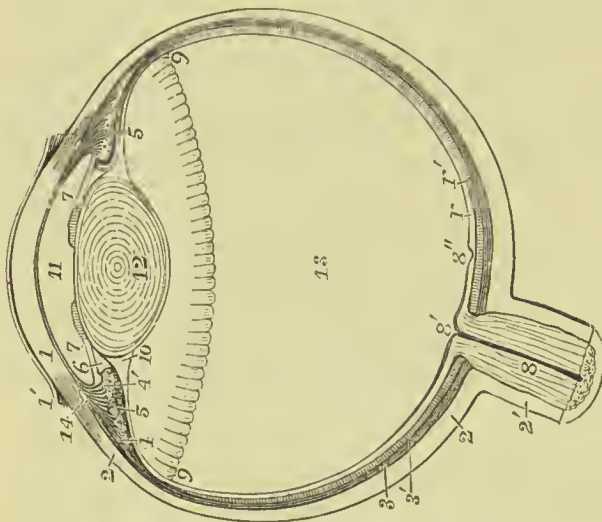


FIG. 356.—General diagram of the eye. 1. Cornea. 1'. Corneal conjunctiva. 2. Sclerotic. 2'. Outer sheath of the optic nerve, which is seen to be continuous with the sclerotic. 3. Vascular layers of the choroid. 3'. Pigmentary layer. 4. Radiating portion of the ciliary muscle. 4'. Cut fibres of circular portion, or *muscle of Müller*. 5, 5. Ciliary processes. 6. Posterior chamber of the aqueous humour. 7, 7. Iris. 8. Optic nerve. 8'. Optic cumulus. 8". Yellow spot. 9. Ora serrata. 10. Canal of Hannover. 11. Anterior chamber of the aqueous humour. 12. Crystalline lens. 13. Chamber of the vitreous humour. 14. Canal of Schlemm. 14'. Bacillary and molecular layers of the retina.

fibrous tissue and by small vessels; these being tinged with the pigmentary matter of the choroid have a brown appearance, and hence the term **lamina fusca** is applied. The lamina fusca is lined by a layer of endothelial cells and forms the outer wall of the perichoroidal lymph space. At the entrance of the optic nerve a thin cribriform lamella, **lamina cribrosa**,* takes the place of the sclerotic; it is pierced by a number of minute openings for the passage of the nervous filaments, and in the centre by a larger opening called **porus opticus**, for the entrance to the eyeball of the *arteria centralis retinae*.

The **cornea** (*corneus*, horny) is the transparent prominent layer which constitutes the anterior fifth of the globe of the eye. When

* The lamina cribrosa is generally described as the continuation of the sclerotic, but it seems more probable (as Dr. T. Reid suggests) that it is continuous with the choroid; indeed, in an inflamed eyeball the fibres of the lamina have been distinctly traced into the choroid.

examined from the exterior, its vertical diameter is seen to be about one-sixteenth shorter than its transverse, in consequence of the overlapping above and below of the margin of the sclerotic; on the interior its outline is circular. It is continuous with the sclerotic, and is connected with the iris, choroid, and ciliary processes. The thickness of the cornea is about one millimetre; it is generally the same throughout, except at the periphery, where it becomes a little thinner.

Structure.—The cornea is divisible into four layers; these are, 1. Conjunctival epithelium; 2. Anterior limiting layer; 3. Cornea propria; and 4. Membrane of Descemet or Demours.

The first of these has been already described. The **anterior limiting layer** (*anterior elastic lamina of Bowman*) is a transparent and apparently structureless layer, having an average thickness of from $\frac{1}{2000}$ to $\frac{1}{1200}$ of an inch; it is devoid of laminae and corneal corpuscles, but otherwise is indistinguishable from the next layer, with which it is connected by fine threads running into the substance of the latter. The **cornea propria** forms the bulk of the cornea. It consists of numerous layers of delicate transparent fibres, continuous externally with those of the opaque sclerotic; the fibres are collected into bundles, separated from each other by a ground substance similar to that in other connective tissues. Between the strata nucleated cells are found, which freely anastomose with each other, and appear to be stellate in sections made parallel to the surface of the cornea. The cells lie in spaces in the ground substance, which correspond to them accurately in size and shape. The spaces can be easily made out by painting the tissue with nitrate of silver; they are generally held to be lymph channels. The

membrane of Descemet or Demours forms the posterior layer of the cornea, and lines the chamber of the aqueous humour; it consists of an elastic and an epithelial layer. The elastic layer (*posterior elastic lamina of Bowman*) is about .006 mm. in thickness; it is highly elastic, and when partially detached tends to curl up. The epithelium consists of a single layer of irregularly shaped nucleated cells. At the edges, the membrane of Descemet breaks up into threads, some of which are continued on to the iris to form the **ligamentum pectinatum**, others terminate in the inner wall of the canal of Schlemm, and some few are connected with the ciliary muscle. The processes which pass to the iris are covered by a single layer of cells of the same kind as those lining the membrane of Descemet, but, as the cells do not pass over the intervals between



FIG. 357.—A vertical section of the cornea of an adult, showing the layers of which it is composed.

of Descemet, but, as the cells do not pass over the intervals between

the strands, small apertures are left, called the **spaces of Fontana**, through which the anterior chamber communicates with the canal of Schlemm.

MIDDLE TUNIC.—The second or middle tunic of the eyeball is formed by the *choroid*, *ciliary muscle*, and *iris*, the *ciliary processes* being appendages developed from its inner surface.

The **choroid** ($\chi\acute{o}\rho\iota\omicron\nu\ \epsilon\acute{\iota}\delta\omicron\varsigma$, like the chorion, that is to say, “vascular”) is of a rich chocolate-brown colour on its external surface, and of a darker tint within. It is connected to the sclerotic by means of the fine areolar tissue called *lamina fusca*, by vessels and nerves. Internally, it is in simple contact with the retina. It is pierced posteriorly for the passage of the optic nerve, and is connected anteriorly with the iris, ciliary processes, and the line of junction of the cornea and sclerotic.

The choroid is composed of three layers. The **external layer** is composed of fine elastic fibres arranged in lamellæ, and lined

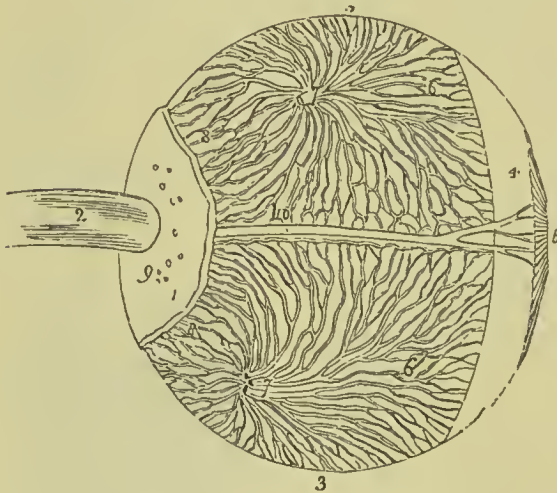


FIG. 358.—Dissection of the eyeball, showing its second tunic, and the mode of distribution of the venae vorticosae of the choroid. 1. Part of the sclerotic coat. 2. Optic nerve. 3, 3. Choroid coat. 4. Ciliary ligament. 5. Iris. 6, 6. Venae vorticosae. 7, 7. Trunks of the venae vorticosae at the point where they have pierced the sclerotic. 8, 8. Posterior ciliary veins, which enter the eyeball in company with the posterior ciliary arteries, by piercing the sclerotic at 9. 10. One of the long ciliary nerves, accompanied by a long ciliary vein.

with endothelium ; it forms lymph spaces, which are connected with the cavity of Tenon's capsule. This layer is called the **lamina supra-choroidea**. The **middle** or **venous** layer consists principally of veins, the smaller branches of which are arranged in whorls (*vasa vorticosae*) round the chief trunks, four or five in number. Between the meshes of the veins are stellate pigmentary cells, which are connected together so as to form a fine web. The **inner** or **arterial** layer of the choroid or **chorio-capillaris** (*tunica Ruyschiana*) is formed principally of the ramifications of minute arteries, which form a complete network with very fine meshes. It is reflected inwards so as to form the ciliary processes.

A structureless transparent membrane (*membrane of Bruch*) has been described as lying between the chorio-capillaris and the pigmentary layer of the retina.

At the junction of the sclerotic and cornea with the choroid and iris, a small venous canal is found, called the **canal of Schlemm**

(sinus circularis iridis); it communicates with the venous trunks of the choroid, and by the spaces of Fontana with the anterior chamber of the aqueous. This canal seems to be more constant in the lower animals than in man, and has been observed to be very large in the negro; its place is frequently taken by several small veins.

The **iris** (*iris*; a rainbow) is so named from its variety of colours in different individuals; it consists of muscular and fibrous tissue with pigmentary cells, the latter being interspersed throughout the tissues, as well as forming a distinct posterior layer. The colour of the iris depends on the quantity and arrangement of the pigment cells; when the cells are in small quantity they are chiefly confined to the posterior layers, and the iris as seen from the front has a blue colour; but when in greater quantity, they are also dispersed through the tissues, and a grey or brown colour is the result. By its outer edge the iris is connected with the choroid and sclerotic; by its inner it forms the boundary of a circular opening called the *pupil*; its anterior surface looks towards the cornea and is free; its posterior, looking towards the ciliary processes and lens, is in contact with them throughout greater part of its extent. The stroma of the iris consists of fibres of connective tissue intermixed with cells, the former being arranged radially towards the pupil and circularly near the outer margin. The cells are very numerous, and for the most part much branched; many of them contain pigment, both in the body of the cell and in the processes.

The muscular tissue is of the unstriped variety. It consists of two sets of fibres, one of which is disposed circularly round the aperture of the pupil, so as to form a sphincter, the contraction of which will diminish the size of the opening; the other set is gathered into numerous bands which radiate from the pupillary margin to the circumference, and serve by their contraction to dilate the pupil.

The pigmentary layer, situated on the posterior surface of the iris, is of a deep purple tint, and hence has received the name of **uvea** (like a grape); it is continuous with the inner layer of the choroid. It consists of deeply pigmented polygonal cells, and is

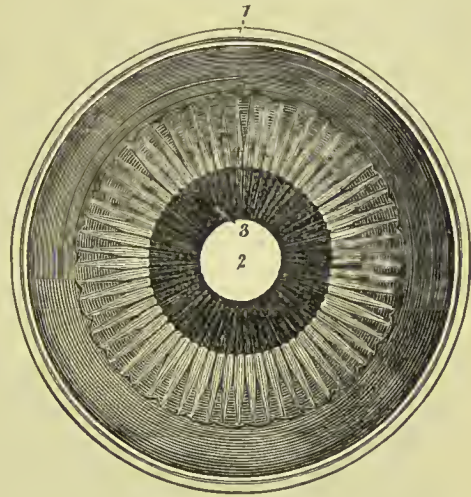


FIG. 359.—Anterior segment of a transverse section of the globe of the eye, seen from within. 1. Divided edge of the three tunics: sclerotic, choroid (the dark layer), and retina. 2. Pupil. 3. Iris, the surface presented to view in this section being the uvea. 4. Ciliary processes. 5. The scalloped anterior border of the retina.

generally thrown into folds or ridges when the pupil is moderately dilated.

On its anterior surface the fibres of the iris have mingled with them some elastic fibres continuous with those of the membrane of Descemet, and are so arranged as to produce a festooned appearance. These festoons are very distinct in the eye of the ox and sheep; they form the **ligamentum pectinatum**. The epithelial cells of the membrane of Descemet are continued over the anterior surface of the iris.

The *blood-vessels of the iris* are numerous, and their outer coat is intimately connected with the fibrous stroma; the arteries are derived from the long and anterior ciliary arteries, and from the *circulus iridis major* of the ciliary processes.

In the foetus a delicate vascular membrane closes in the pupil (*membrana pupillaris*); it disappears about the seventh or eighth month.

The *nerves* come from the ciliary branches of the lenticular ganglion, and from the long ciliary branch of the nasal. After

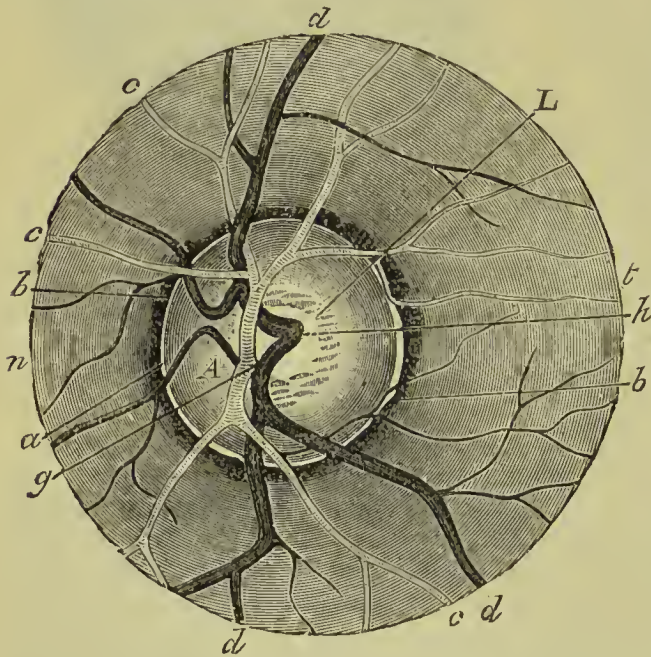


FIG. 360.—Ophthalmoscopic view of the fundus of the eye.
A, Optic disc. *b, b*, Choroidal ring. *c, c*, Retinal arteries.
d, d, Retinal veins. *g*, Arteria centralis retinae dividing.
h, Venous radicles uniting to form a trunk. *n*, Inner side.
t, Outer side. *L*, Physiological eup and lamina cribrosa.

forming a plexus near the ciliary margin of the iris, they divide into twigs which are distributed to the muscular fibres and anterior surface.

The **ciliary processes** are formed by the plication of the anterior part of the ciliary region of the choroid. They may be seen in two ways, either by removing the iris from its attachment to the choroid, when a front view of the processes will be obtained, or by making a transverse section through the globe

of the eye, when they may be examined from behind, as in Fig. 359. They consist of about eighty triangular folds, about one-third of which are smaller than the rest, and are interspersed at irregular intervals. The summits of the larger processes have upon them smaller, secondary processes, varying greatly in their number, size,

and shape. They have much the same structure as the choroid, and are composed of a vascular network and an internal pigmentary layer. Their periphery is connected with the ciliary muscle; the central border is free, and nearly reaches the circumference of the lens; the anterior surface is continuous with the uvea: the posterior surface receives the folds of the suspensory ligament of the lens. Each of the larger folds measures about $\frac{1}{10}$ of an inch in length, and $\frac{1}{10}$ of an inch in depth.

The **ciliary muscle** (formerly described as the *ciliary ligament*) is situated internally to the canal of Schlemm. It forms a greyish-white ring round the anterior part of the choroid, and is found to consist of unstriated muscular tissue, the fibres of which are connected in front with the inner surface of the sclerotic, and the fibres of the membrane of Descemet; they pass inwards and backwards, and are attached to the choroid opposite and beyond the ciliary processes. Besides these fibres there are others, situated more inter-

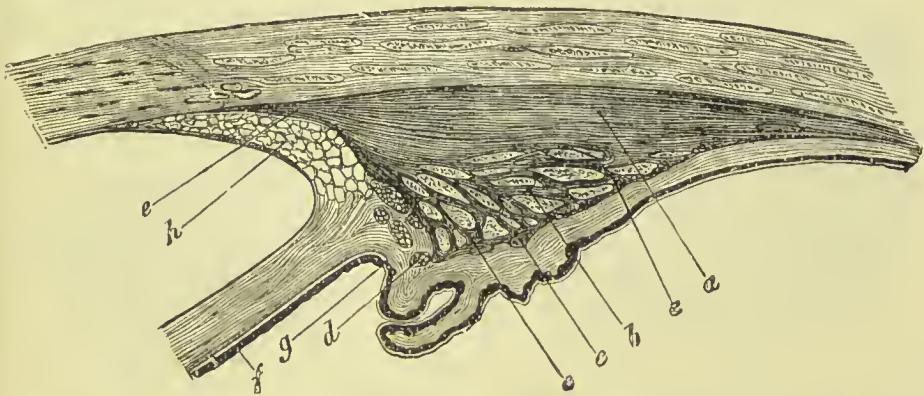


FIG. 361.—Section through the ciliary processes and periphery of the iris. *a.* Radiating fibres of the ciliary muscle. *b.* Circular fibres or muscle of Müller. *c.* Circular fibres surrounded by radiating fibres. *d.* Circular fibres by themselves. *e.* Muscular fibres shown in their connection with the corneo-sclerotic junction. *f.* Iris. *g.* Uveal tract. *h.* Ligamentum pectinatum.

nally, at the base of the ciliary processes; these are disposed circularly, and constitute the **circular muscle of Müller** (sphincter ciliaris). The circular fibres are most developed in hypermetropic eyes, and are very scanty or altogether absent in those which are myopic (Iwanoff).

INTERNAL TUNIC.—This consists of the *retina*, with its continuation forwards, called the *pars ciliaris retinae*.

The **retina** is the inner nervous tunic of the eye, and that on which the images of external objects are produced. It is in contact by its external surface with the choroid, and by its internal surface with the hyaloid membrane of the vitreous humour. It is firmly attached to the back part of the eye by means of the retinal artery and fibres of the optic nerve which enter it, but is loosely applied to the inside of the choroid throughout the rest of its extent. It terminates anteriorly, a little behind the ciliary processes, in a festooned edge, the *ora serrata*; but from this edge there are

continued forwards over the ciliary processes to the base of the iris, some peculiar, elongated, nucleated cells, constituting the *pars ciliaris retinae*.




FIG. 362.—Cells of the *pars ciliaris retinae*.

In the fresh eye the retina is of a pale pink colour, and is translucent, but it soon becomes opaque and yellowish, especially when in contact with fluids. At the back part of the retina, nearly in the axis of the eye, is a spot of a golden-yellow colour—*macula lutea* (called by Soemmering *limbus luteus*); it is elliptical in form, with a long diameter of about $\frac{1}{12}$ of an inch, and short diameter $\frac{1}{30}$ of an inch. In the

middle of this is a depression, *fovea centralis*, where, the retina being thinned, the pigmentary matter of the choroid is seen through;

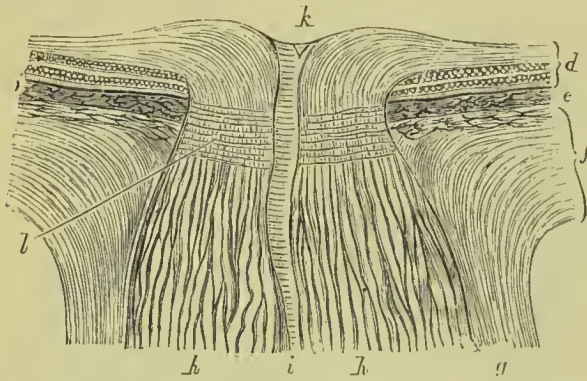


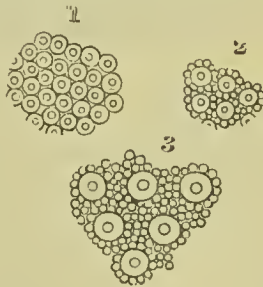
FIG. 363.—Vertical section of the coats of the eye at the point of entrance of the optic nerve. *d*. Retina. *e*. Choroid. *f*. Sclerotic. *g*. Outer sheath of the optic nerve. *h*. Fibres of the optic nerve. *i*. Central artery of the retina. *k*. Its point of subdivision. *l*. Lamina cribrosa.

hence it has the appearance of being a foramen, and was so described by Soemmering. This is the most sensitive spot of the retina, and being placed nearly in the axis of the eye, receives the image of that part of an object to which the eye is directed, and of which the most vivid impression is obtained.

About $\frac{1}{10}$ of an inch to the inner side of the macula is the entrance of the optic nerve.

Here there is a slight elevation (*colliculus nervi optici*), with a cupped centre, perforated by the *arteria centralis retinae*; the

FIG. 364.—Bacillary layer of the retina, seen from the outer surface. 1. In the yellow spot. 2. In the neighbourhood of the yellow spot. 3. Near the ora serrata.



artery upon entering immediately breaking up into branches. This is the only part of the retina from which the power of vision is absent. The retina is thickest posteriorly, in the immediate vicinity of the optic nerve, where it has a thickness of $\frac{1}{100}$ of an inch, but it thins

as it passes forwards, and near the ora serrata measures only $\frac{1}{250}$ of an inch.

Structure.—On the outer surface, the retina is formed by a single layer of hexagonal cells loaded with pigment, and constituting the

pigmentary layer, formerly described as forming part of the choroid coat. In some animals this is replaced by a layer of considerable extent and of metallic brilliance, called *tapetum*; it appears to consist chiefly of connective tissue. The next layer of the retina (*bacillary layer*) was formerly called *Jacob's membrane*, from its having been described by Dr. Jacob; it consists of a number of peculiar rod-like bodies, with which are mingled others with bulbous inner extremities, called *cones*. The relative proportion of **rods** and **cones** differs in different parts of the retina—thus, in the yellow spot the rods are absent, and the cones are attenuated, elongated, and crowded; in the neighbourhood of the ora serrata, on the other hand, the rods are the most numerous, and the cones are interspersed at considerable intervals (Fig. 364).

The middle layers consist of several strata of corpuscles and molecules, which, upon minute examination, are found to be divisible into—(1) an outer stratum, consisting of oval corpuscles of small size, many of which are nucleated (*outer granular layer*); they have been divided into *cone granules* and *rod granules*, according as they

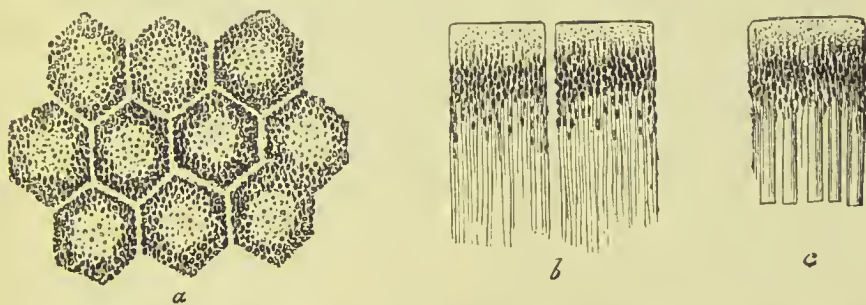


FIG. 365.—Pigmentary cells of retina. *a*. Seen from the surface. *b*. Seen from the side. *c*. Relation of retinal rods to the pigment.

are connected with one or other of the elements of the bacillary layer; the former are larger than the latter, and are closely connected to the bases of the cones, while the rod granules are small, transversely striated, and distinct from the bases of the rods; (2) next to this a very narrow band of fine molecules (*outer molecular layer*); and (3) internal to this a layer of larger corpuscles, all of which seem to be nucleated (*inner granular layer*). The granules of the third layer are of two kinds, namely, (α) large cells with two processes or poles; and (β) pale-edged oval nuclei, which are less numerous, and clearly belong to the connective-tissue stroma.

The inner layers of the retina consist in part of the expanded fibres of the optic nerve, and in part of superadded molecules and nerve cells. Immediately in contact with the inner granular layer above described is a stratum of fine molecules (*inner molecular layer*), and next to this one or two rows of multipolar nerve cells, while, most internally, the fibres of the optic nerve form a thin layer.

These structures are supported by a network of connective tissue, which is condensed so as to form a limiting membrane on the inside

of the nerve fibres, and, externally, at the base of the bacillary layer. This stromal tissue also contains a large number of fibres which run

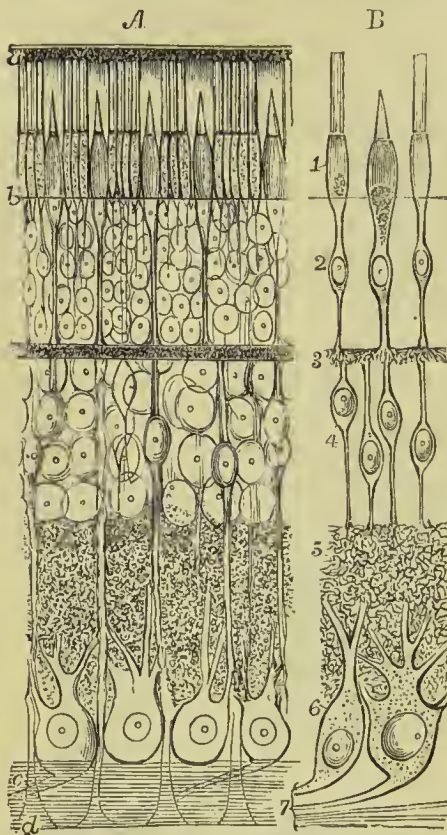


FIG. 366.—Diagram of the structures composing the retina. *A.* The structures viewed *in situ*. *B.* Shows the supposed connection between the components of the several layers. 1. Bacillary layer (rods and cones). 2. Outer granular layer. 3. Outer molecular layer. 4. Inner granular layer. 5. Inner molecular layer. 6. Layer of nerve cells. 7. Layer of nerve fibres. *a.* Pigmentary layer. *b.* External limiting membrane. *c.* Connecting trabeculae (rods of Müller). *d.* Internal limiting membrane.

vertically to the surface of the retina, and have been named the **rods of Müller**. These appear to be connected externally with rods and cones; some few have been observed to join the cells of the granular layers, and some have been traced into the internal limiting membrane. It is supposed that these elements connect the rods and cones with the fibres of the optic nerve, being connected intermediately with the cells of the granular layers and the multipolar cells above described; hitherto, however, this complete chain has not been satisfactorily demonstrated.

At the **yellow spot** the retina becomes very much thinned, and the layers of which it is composed are one by one suppressed, until in the centre of the spot only a crowded layer of attenuated cones, a few cells of the outer granular layer, and a few nerve cells arranged like pavement epithelium, remain. At the entrance of the optic nerve, on the other hand, the bacillary and granular layers are absent, and the layer of nerve cells exists only at the border of the colliculus; the nerve fibres are, however, numerous, and form a very thick layer.

Vessels.—The arteries of the retina are chiefly derived from the *arteria centralis retinae*, which enters the eye in the centre of the optic nerve, and breaks up immediately into branches, ramifying for the most part in the inner or nervous layers of the retina, the outer layers being entirely devoid of blood-vessels. The veins have a similar distribution, and terminate in the ophthalmic vein. The optic nerve and its termination, the optic disc, receive only a few very fine branches from the *arteria centralis*, being chiefly supplied by vessels running inside the sheath and derived from the short ciliary arteries.

The **refracting media** of the eye are the *aqueous* and *vitreous humours*, and the *lens*; but in conjunction with these we shall also describe the *suspensory ligament* and *capsule of the lens*.

The **aqueous humour** fills up the space between the cornea and the capsule of the lens with its suspensory ligament; it is a weakly albuminous fluid, with an alkaline reaction, and a specific gravity very little greater than that of water. The *anterior chamber* is the space intervening between the cornea in front, and the iris and pupil behind. The *posterior chamber* was formerly described as the space between the posterior surface of the iris and pupil in front, and the ciliary processes, suspensory ligament, and lens behind,—but it is now known that the iris at the edge of the pupil is in absolute

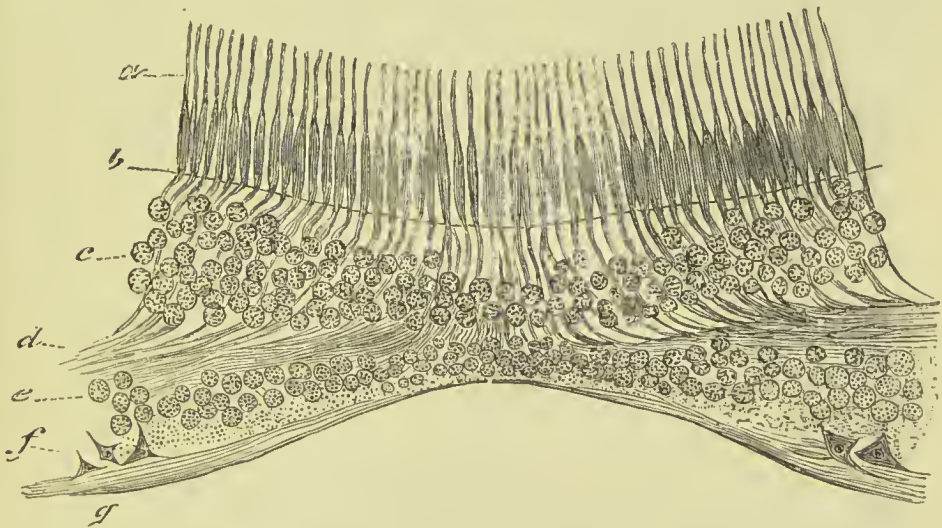


FIG. 367.—Section through yellow spot of the retina. *a*, Layer of modified cones. *b*, External limiting layer. *c*, Outer granular layer. *d*, Outer molecular layer. *e*, Inner granular layer. *f*, Layer of nerve cells. *g*, Layer of nerve fibres, and internal limiting layer.

contact with the capsule of the lens, so that the term must be restricted to the triangular interval existing between the ciliary processes, suspensory ligament, and iris, at the attached margin of the latter.

The **vitreous humour** forms the principal bulk of the globe of the eye, and supports the delicate retina internally. It is a transparent and highly albuminous substance, enclosed in a delicate homogeneous membrane, the **hyaloid membrane**. Hannover supposed that septa of the hyaloid membrane also formed cavities for the contained fluid, but microscopic examination has shown that such is not the case in the adult, though there undoubtedly are fibres in the centre of the vitreous in the fœtus. Scattered through its substance are a number of corpuscles of various shapes and sizes, many exhibiting amoeboid movements, and near the periphery stellate and spindle-shaped cells have been described. The centre of the vitreous is traversed by a minute canal (*canal of Stilling*) extending from

the optic-nerve entrance to the back of the lens; it is filled with clear fluid. Anteriorly the hyaloid is connected with the posterior part of the capsule of the lens, while a thickened prolongation of it forms the suspensory ligament of the lens.

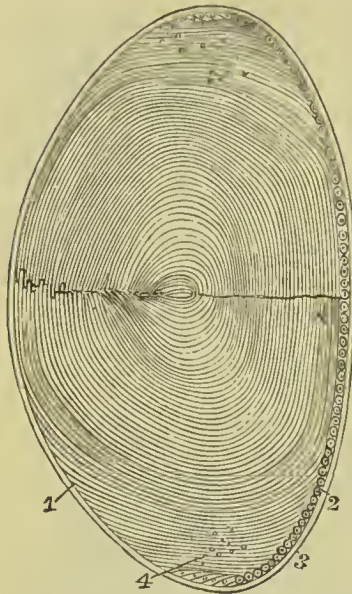


FIG. 368.—The crystalline lens.
1. The laminae of which the lens is composed. 2. The cells contained between the capsule and front of the lens. 3. Capsule of the lens. 4. Nuclear zone.

The **crystalline lens** is situated immediately behind the pupil, and surrounded by the ciliary processes, which nearly reach its margin. It is more convex on its posterior than its anterior surface, and is embedded in the anterior part of the vitreous humour, from which it is separated by the hyaloid membrane. It is invested by a peculiar transparent and elastic membrane, the *capsule of the lens*, which is thicker in front than behind, in consequence of the suspensory ligament joining it on that aspect. The capsule is connected with the lens in front by means of a single layer of "granular and nucleated polygonal cells," which, at its edge, become continuous with the nucleated fibres of the lens itself (Fig. 368). The lens is retained in its place by means of the suspensory ligament, to be presently described.

Structure.—The lens consists of concentric layers, of which the external are soft, the next firmer, and the central form a hardened nucleus. They are best demonstrated by boiling or by immersion in alcohol, when they are easily separated from each other. Another division of the lens takes place at the same time: it splits into three triangular segments, having the sharp edge directed towards the centre, and the base towards the circumference. The concentric laminae are composed of minute hexagonal fibres, united with each other by means of irregularly serrated edges, the serrations of which accurately fit into each other. Some of the superficial fibres possess nuclei, which are usually arranged in regular zones, and are continuous in series with the nuclei of the cells between the capsule and lens anteriorly (Babuchin).

The **suspensory ligament of the lens**—Retzius (Zonule of Zinn, Zonula ciliaris)—is a firm, transparent membrane, passing from the fore-part of the circumference of the lens to join the hyaloid membrane nearly opposite the ora serrata. It is gathered up into numerous pleats which fit into the depressions between the ciliary processes, and when withdrawn carry with them some of the pigment which covers those processes. Structurally, it is found to consist of pale longitudinal parallel fibres, resembling those of

elastic tissue. These fibres spread out upon the margin of the lens, both on its anterior and posterior aspect ; it is, however, possible to inflate spaces between them, and this fact led to the description of a space round the margin of the lens under the name of *canal of Petit* (canal of Hannover).

VESSELS AND NERVES OF THE GLOBE OF THE EYE.

The *vessels* of the globe of the eye are the long, short, and anterior ciliary arteries, and the *arteria centralis retinae*.

The **long ciliary arteries**, two in number, pierce the posterior part of the sclerotic, and pass forwards on each side, between that membrane and the choroid, to the base of the ciliary processes, where each divides into two branches, which form an elaborate network in the substance of the ciliary processes and iris. The **short ciliary arteries** pierce the posterior part of the sclerotic coat, and are distributed to the middle layer of the choroid membrane (chorio-capillaris).

The **anterior ciliary** are branches of the muscular arteries ; they enter the eye just behind the junction of the cornea and sclerotic, and join the anastomotic circle of the iris. It is the congestion of these latter arteries, in iritis, that gives rise to the peculiar red zone round the circumference of the cornea. The distribution of the **arteria centralis retinae** has been already described.

The **nerves** of the eyeball are—the optic, two ciliary nerves from the nasal branch of the ophthalmic, and the ciliary nerves from the ophthalmic ganglion. The optic nerve has an outer sheath continuous with the sclerotic and derived from the dura mater, and an inner sheath which it receives from the arachnoid. Between these is the *subvaginal space*, continuous with the subdural space of the cranial cavity.

ORGAN OF HEARING.

The apparatus of hearing is composed of three parts : external ear, middle ear or tympanum, and internal ear or labyrinth.

EXTERNAL EAR.

The external ear consists of two portions, the **pinna** or **auricle** and **meatus** ; the former representing a kind of funnel which collects the vibrations of the atmosphere producing sounds, and the latter a tube which conveys the vibrations to the tympanum.

The **PINNA** presents a number of folds and hollows on its surface, which have different names assigned to them. Thus, the external folded margin is the **helix** (ἑλιξ, a fold). The elevation parallel with and in front of the helix, is the **antihelix** (ἀντι, oppo-

site). The pointed process, projecting like a valve over the opening of the ear, from the face, is the **tragus** (*ζράγος*, a goat), probably from being sometimes covered with bristly hair like that of a goat; and a tubercle opposite this is the **antitragus**. The lower dependent and fleshy portion of the pinna is the **lobule**. The space between the helix and antihelix is named the **fossa of the helix** (*scaphoid or innominate fossa*). Another depression at the upper extremity of the antihelix, produced by a bifurcation of that ridge,

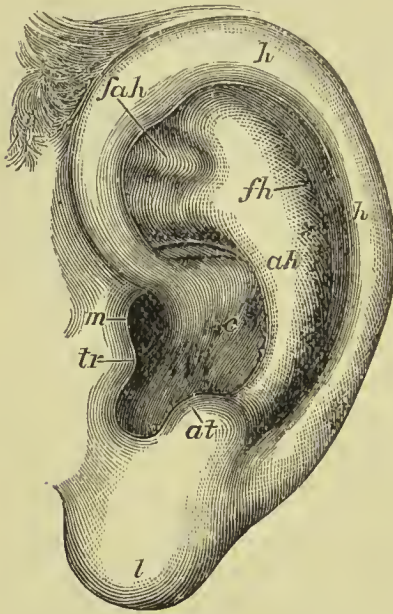


FIG. 369.—External ear. *h.* Helix. *ah.* Antihelix. *fh.* Fossa of the helix. *fah.* Fossa of the antihelix. *tr.* Tragus. *at.* Antitragus. *m.* External meatus. *c.* Concha. *l.* Lobule.

is the **fossa of the antihelix** (*oval or triangular fossa*); and the large central space, to which all the channels converge, the **concha**, which opens directly into the **meatus**.

The pinna is composed of *integument, fibro-cartilage, ligaments, and muscles*.

The **integument** is thin, contains an abundance of sebaceous glands, and is closely connected with the fibro-cartilage.

The **fibro-cartilage** gives form to the pinna, and is folded so as to produce the various convexities and grooves which have been described on its surface. The **helix** begins in the concha, and partially divides that cavity into two parts; on its anterior border, where it commences its curve upwards, is a tubercle or spine, and a little above this a small vertical fissure, the **fissure of the helix**. The termination of the helix and antihelix forms a lengthened

process, the **processus caudatus**, which is separated from the concha by an extensive fissure. On the anterior surface of the tragus is another fissure, the **fissure of the tragus**; and, in the lobule, the fibro-cartilage is wanting. The fibro-cartilage of the meatus is divided from the concha by several fissures (fissures of Santorini), and at the upper and anterior part of the cylinder is a considerable space, which is closed by muscular and ligamentous fibres; it is firmly attached at its termination to the **processus auditorius**. The fibro-cartilage of the pinna and meatus is of the yellow variety.

The **ligaments** of the external ear are those which attach the pinna to the side of the head—viz., anterior, posterior, and ligament of the tragus; and those of the fibro-cartilage, which serve to preserve its folds and connect the opposite margins of the fissures. The latter are two in number, the ligament between the concha and **processus caudatus**, and the broad ligament which extends from the

upper margin of the fibro-cartilage of the tragus to the helix, and completes the meatus.

The proper **muscles** of the pinna are the—

Major helicis,
Minor helicis,
Tragicus,

Antitragicus.
Transversus auriculæ,
Obliquus auris.

The **major helicis** is a narrow band of muscular fibres situated on the anterior border of the helix. It arises from the spine of the helix, and is inserted into the anterior border of that fold.

The **minor helicis** is placed upon the anterior extremity (crus) of the helix, at its commencement in the fossa of the concha.

The **tragicus** is a thin quadrilateral layer of muscular fibres, situated on the tragus, and having a vertical direction.

The **antitragicus** arises from the antitragus, and is inserted into the posterior surface of the processus caudatus of the helix.

The **transversus auriculæ**, partly tendinous and partly muscular, extends transversely from the convexity of the concha to that of the helix, on the posterior surface of the pinna.

The **obliquus auris** (Tod) is a small band of fibres passing between the upper part of the convexity of the concha and the convexity immediately above it.

Dissection.—In the recent temporal bone the external auditory meatus may be examined by cutting away with the saw the squamous portion of the bone in front of the fissure of Glaser, and then removing with bone forceps the anterior wall of the meatus, excepting the portion which supports the membrana tympani.

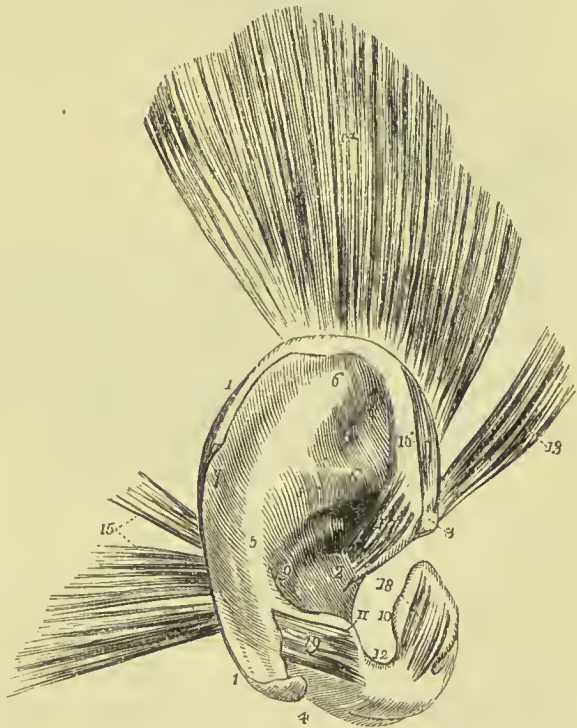


FIG. 370.—The pinna and its muscles. 1, 1. Helix. 2. Crus helicis. 3. Spina helicis. 4. Processus caudatus helicis. 5. Antihelix. 6, 6. Crura antihelicis. 7. Fossa of the helix (scaphoid fossa). 8. Fossa of the antihelix (triangular fossa). 9. Concha. 10. Tragus. 11. Antitragus. 12. Incisura intertragica. 13. Attrahens auriculam. 14. Attollens auriculam. 15. Retrahens auriculam. 16. Major helicis muscle. 17. Minor helicis. 18. Tragicus. 19. Antitragicus.

The **MEATUS AUDITORIUS** is a canal, partly cartilaginous and partly osseous, about an inch in length, which extends inwards and a little forwards from the concha to the tympanum. It is narrower

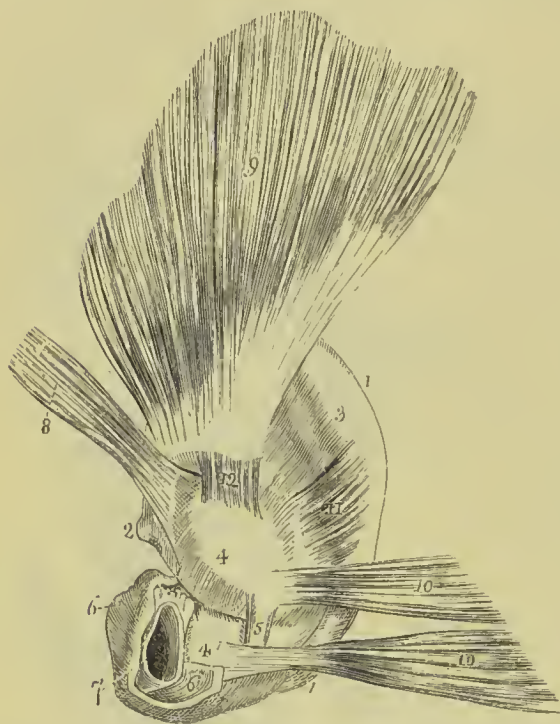


FIG. 371.—The pinna and its muscles, as seen from behind. 1, 1. Border of the helix. 2. Spine of the helix. 3. Convexity corresponding with the fossa of the helix. 4, 4. Convexity of the concha; the fissure between the numbers corresponds with the crus helicis. 5. Ponticulus conchæ. 6, 6. Cartilage of the meatus. 7. Aperture of the meatus. 8. *Attrahens auriculam*. 9. *Attollens auriculam*. 10. *Retrahens auriculam*. 11. *Transversus auriculæ*. 12. *Obliquus auris*.

in the middle than at each extremity, forms an oval cylinder, the long diameter being vertical, is directed a little forwards, and is slightly curved on itself, the concavity looking downwards. In consequence of the obliquity of the *membrana tympani*, the floor of the canal is a little longer than its roof.

The cartilaginous portion of the tube forms a little less than half the passage. The osseous portion is longer and slightly narrower than the cartilaginous. At its inner end is an oblique groove for the *membrana tympani*; the groove is defective at the upper part, where there is a small irregular excavation, the *Rivian recess*. The skin of the meatus is very thin, especially towards the bottom of the passage;

after maceration in water, the epithelial lining frequently comes away as a complete and very delicate pouch. Some stiff short hairs are also found in its interior, which stretch across the tube, and prevent the ingress of insects and dust. In the substance of its lining membrane are a number of *ceruminous glands*, which secrete the wax of the ear.

Vessels and Nerves.—The pinna is plentifully supplied with *arteries*; by the anterior auricular from the temporal, by the posterior auricular from the external carotid, and by a branch from the occipital artery.

Its **nerves** are derived from the auriculo-temporal of the fifth, the posterior auricular of the facial, and the *auricularis magnus* of the cervical plexus.

MIDDLE EAR OR TYMPANUM.

Dissection.—In a fresh specimen in which the meatus has been displayed in the manner above described, it is only necessary to remove with bone forceps the roof of the tympanum, taking care to avoid injuring the membrana tympani, chorda tympani nerve, and chain of small bones.

The **tympanum** is an irregular cavity hollowed out in the base of the petrous bone, and placed between the membrana tympani externally and the labyrinth within. It is narrow below and in front, and wider above and behind, and communicates behind with the mastoid cells, internally with the vestibule and scala tympani, and in front by means of the Eustachian tube with the pharynx.

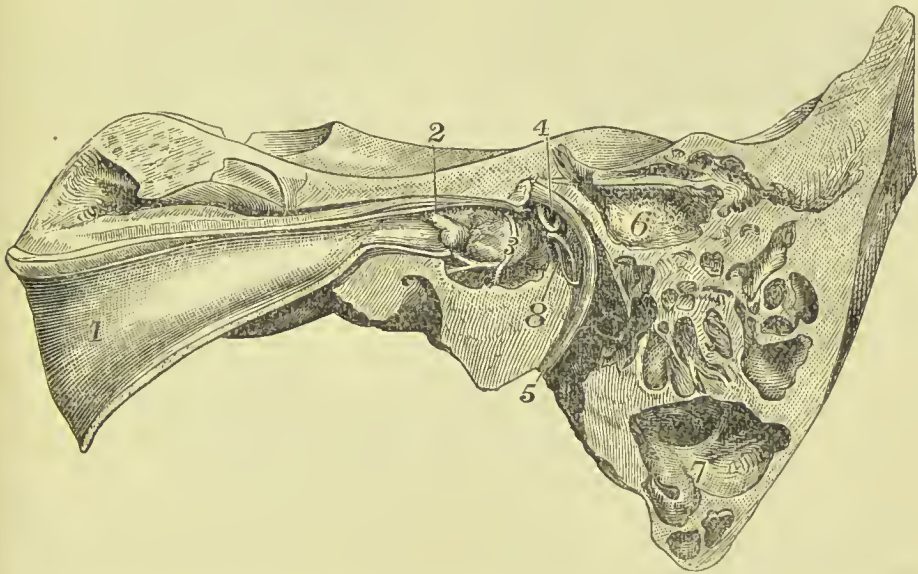


FIG. 372.—View of the middle ear. 1. Eustachian tube. 2. Tensor tympani muscle. 3. Promontory, with tympanic plexus of nerves. 4. Stapes, in fenestra ovalis. 5. Facial nerve in aqueduct of Fallopius. 6. Mastoid antrum. 7. Large diploetic mastoid cells. 8. Pyramid, with stapedius muscle escaping from its apex.

It is described as having a *roof* (*tegmen tympani*) and a *floor*, the former consisting of a thin plate of bone separating the cavity from the middle fossa of the skull, and the latter being formed by the roof of the jugular fossa. The *outer wall* corresponds throughout greater part of its extent to the membrana tympani and the ring of bone surrounding it; in front of the latter is the irregular slit called *fissure of Glaser*, which gives passage to the anterior tympanic artery, and in infancy lodges the long process of the malleus (*processus gracilis*); at the inner extremity of this fissure is a small canal (*canal of Huguier*) which gives passage to the chorda tympani nerve. The *inner wall* separates the cavity of the tympanum from the internal ear; it is rough and irregular, and is more extensive than the outer wall. It is marked at its upper part by a

ridge formed by the aquæductus Fallopii; beneath this is an oval opening, *fenestra ovalis*, which lodges the foot of the stapes; next a rounded prominence due to the projection of the first turn of the cochlea, and called the *promontory*; and below this, near the floor of the cavity, a circular opening, *fenestra rotunda*, which communicates with the scala tympani of the cochlea. At the back part of this wall, behind the fenestra ovalis, is a conical projection named the *pyramid*; it contains the stapedius muscle, the tendon of which escapes through a small opening near its summit. The *posterior wall* is irregular, and has several small openings which communicate with the mastoid cells. The *anterior extremity* is narrow, and has opening into it two canals separated by a lamella of bone (processus cochleariformis), the lower and larger being the commencement of the Eustachian tube, and the upper and smaller containing the tensor tympani muscle.

The cavity of the tympanum is lined by mucous membrane continuous with that of the Eustachian tube and pharynx: it covers the walls of the cavity including the membrana tympani, is reflected over the ossicles and chorda tympani nerve, and is continued into the mastoid cells to form their lining membrane. The epithelium is for the most part columnar and ciliated, but the roof, promontory, ossicles, and membrana tympani are covered by flattened non-ciliated cells.

The **membrana tympani** is a thin and semi-transparent membrane of an oval shape, its long diameter being vertical. It is inserted into a groove situated around the circumference of the meatus, near its termination, and is placed obliquely across the area of that tube, the direction of the obliquity being downwards and inwards. As seen from the outer surface it presents a depressed centre, or *umbo*, corresponding to the line of its attachment to the handle of the malleus; from this depression its fibres radiate, but run in curved lines, so as to cause the membrane to bulge outwards between the umbo and periphery. At the site of the Rivinian recess the membrane is thin and lax, and is formed by loose connective tissue; it was specially described by Shrapnell under the name of *membrana flaccida* (*Shrapnell's membrane*).

The membrana tympani is composed of *three layers*: *external*, or epithelial, continuous with the integument of the meatus; *middle*, fibrous, the fibres of which, for the most part, radiate from the handle of the malleus, but are strengthened at the periphery by a strong band of circular fibres; and *internal*, mucous, derived from the mucous lining of the tympanum.

The tympanum contains three small bones, **ossicula auditûs**—viz., the malleus, incus, and stapes.

The **malleus** (*hammer*) consists of a head, neck, handle (*manubrium*), and two processes, *long* (*processus gracilis*), and *short* (*processus brevis*). The manubrium is connected with the membrana tympani by its whole length, extending below the central point of that membrane. The long process descends in the young child to the fissure of Glaser; in the adult it is in great measure converted into

ligamentous tissue; hence it no longer deserves the title of *processus gracilis*, and Helmholtz proposes to call it *processus Foliauus*. The short process is a conical elevation at the junction of the manubrium with the rest of the bone; into it is inserted the tendon of the tensor tympani. The articular surface consists of an oval depressed area, surrounded by prominent ridges; the former corre-

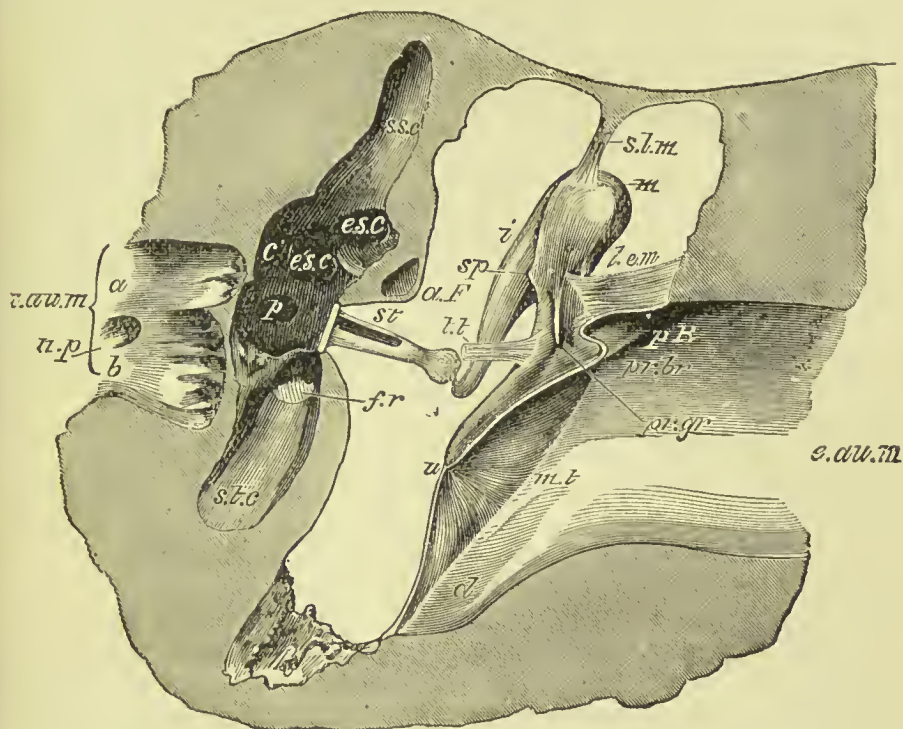


FIG. 373.—Profile view of left tympanic cavity, membrane and ossicles (E. A. Schäfer).
m. Head of the malleus. *sp.* Spur-like projection of lower border of articular surface. *pr.br.* Processus brevis. *pr.gr.* Processus gracilis. *s.l.m.* Suspensory ligament of malleus. *l.e.m.* External ligament. *t.t.* Tensor tympani (cut). *i.* Incus (long process). *st.* Stapes in fenestra ovalis. *e.au.m.* External meatus. *p.R.* Rivinian recess. *m.t.* Membrana tympani. *u.* Umbo. *d.* Declivity at inner end of external meatus. *i.au.m.* Internal meatus. *a* and *b.* Its upper and lower divisions. *n.p.* Canal for nerve to ampulla of posterior semicircular canal. *s.s.c.* Ampulla of superior semicircular canal. *p.* Ampullary opening of posterior canal. *c.* Common aperture of superior and posterior canals. *e.s.c.* Ampullary—and *è.s.c.* non-ampullary end of external canal. *s.t.c.* Scala tympani of cochlea. *f.r.* Fenestra rotunda. *a.f.* Aquæductus Fallopii.

sponds to the articular surface on the incus, and the latter serve to limit the movements of the malleo-incudal joint.

The **incus** (*anvil*) is named from an imagined resemblance to an anvil. It has also been likened to a bicuspid tooth, having one root longer than, and widely separated from, the other. It consists of two processes, united nearly at right angles, and at their junction forming a flattened body, which articulates with the head of the malleus. The *short process* is attached to the margin of the opening

of the mastoid cells by means of a ligament ; the *long process descends* nearly parallel with the handle of the malleus, and curves inwards near its termination. At its extremity is a small globular projection, the **os orbiculare**, which in the fœtus is a separate piece, but becomes ankylosed to the long process of the incus in the adult ; this process articulates with the head of the stapes.

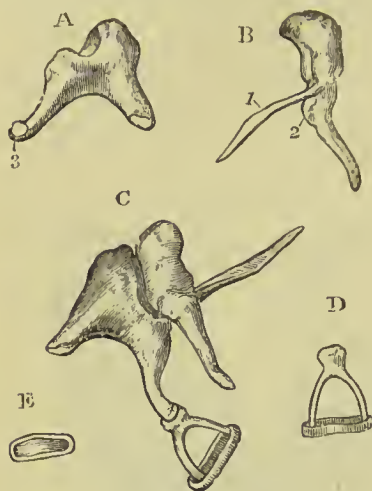


FIG. 374.—Small bones of the tympanum. A. Incus. B. Malleus. C. The three bones articulated. D. Stapes. E. The foot of the stapes. 1. Processus gracilis of the malleus. 2. Processus brevis. 3. Os orbiculare.

The **stapes** is shaped like a stirrup, to which it bears a close resemblance. Its head articulates with the os orbiculare, and the two branches (crura) are connected by their extremities with a flat, oval-shaped plate, representing the foot of the stirrup. The foot of the stirrup is received into the fenestra ovalis, to the margin of which it is connected by means of a ligament ; it is in contact, by its surface, with the membrana vestibuli, and is covered in by the mucous lining of the tympanum. The neck of the stapes gives attachment to the stapedius muscle.

The ossicula auditûs are retained in position and moved upon themselves by means of ligaments and muscles.

The **ligaments** are five in number : the *suspensory ligament of the malleus* (Fig. 373, *s.l.m.*), which is attached by one extremity to the upper wall of the tympanum, and by the other to the head of the malleus ; the *anterior ligament of the malleus* (formerly described as the *laxator tympani muscle*), a broad and strong band which connects the anterior wall of the tympanum with the malleus, in a line extending from the base of the processus Folianus to the head ; the *external ligament of the malleus* (Fig. 373, *l.c.m.*), a fan-shaped band of fibres radiating from the processus brevis to the sides of the Rivinian recess ; the *posterior ligament of the incus*, a short and thick band, which serves to attach the extremity of the short process of that bone to the margin of the opening of the mastoid cells ; and the *annular ligament*, which connects the margin of the foot of the stapes with the circumference of the fenestra ovalis ; it is continuous with the periosteum of the vestibular wall and with that covering the foot of the stapes.

Between the head of the malleus and the incus, and between the incus and stapes, there are distinct joints ; the bones being united by ligaments, the osseous surfaces coated with cartilage, and the joints lined by complete synovial membranes.

The **muscles of the tympanum** are two in number, the—

Tensor tympani,

Stapedius.

The **tensor tympani** *arises* from the spinous process of the sphenoid, the petrous portion of the temporal bone and the Eustachian tube, and passes forwards in a distinct canal, separated from the tube by the *processus cochleariformis*. It bends nearly at a right angle over the end of that process, and passes, to be *inserted* into the inner part of the handle of the malleus near its base. It is supplied by a branch from the otic ganglion.

The **stapedius** *arises* from the interior of the pyramid and descending part of the aquæductus Fallopii, it becomes tendinous, and escapes from the summit of the pyramid to be *inserted* into the neck of the stapes, posteriorly. It is supplied by the tympanic branch of the facial nerve.

Actions.—The action of the tensor muscle is sufficiently indicated by its name, but that of the stapedius is more difficult to understand. It seems, however, evident that by its contraction it will tend to pull the foot of the stapes out of the fenestra ovalis, and thus prevent too forcible excitation of the delicate internal ear.

Foramina.—The openings in the tympanum are nine in number, *five large* and *four small*; they are—

Large Openings.

Meatus auditorius,
Fenestra ovalis,
Fenestra rotunda,
Mastoid cells,
Eustachian tube.

Small Openings.

Entrance of chorda tympani,
Exit of chorda tympani,
For the tensor tympani,
For the stapedius.

The opening of the **meatus auditorius** has been already described.

The **fenestra ovalis** (*fenestra vestibuli*) is a reniform opening, situated at the bottom of a small oval fossa in the upper part of the inner wall of the tympanum, directly opposite the meatus. The long diameter of the fenestra is horizontal, and its convex border directed upwards. It is the opening of communication between the tympanum and vestibule, and is closed by the foot of the stapes and by the lining membrane of both cavities.

The **fenestra rotunda** (*fenestra cochleæ*) is somewhat triangular in form, and situated in the inner wall of the tympanum, below and rather posteriorly to the fenestra ovalis, from which it is separated by a bony elevation, called the **promontory**; it lies at the bottom of a funnel-shaped depression, and serves to establish a communication between the tympanum and cochlea. In the fresh subject it is closed by a proper membrane (*m. tympani secundaria*) as well as by the lining of both cavities.

The **mastoid cells** are the cavities contained in the interior of the mastoid portion of the temporal bone. In the majority of cases, the lower and posterior cells are *diplœtic*, contain marrow, and do not communicate with the cavity of the tympanum; and the upper ones are *pneumatic*, and in communication with the tympanic cavity.

Sometimes the whole of the cells contain air, while in other specimens the mastoid process is sclerosed and there is no general excavation. In all cases, however, a cavity is found at the upper and anterior part of the mastoid which communicates with the tympanic cavity, and is called the *mastoid antrum*; it is present even in infancy, and corresponds in position to the triangular area bounded above by the superior root of the zygoma, below by the edge of the external auditory meatus, and behind by the commencement of the rough surface of the mastoid.

The **Eustachian tube** is a short canal about an inch and three-quarters in length, extending obliquely between the pharynx and the anterior edge of the tympanic membrane. It is directed downwards, forwards, and inwards, and opens anteriorly, behind the inferior meatus of the nose, into the pharynx. It consists of an osseous and a fibro-cartilaginous portion, the former of which has been already described in connection with the temporal bone. The cartilage of the Eustachian tube is of a triangular form, having its inferior angles rolled up towards each other, but leaving between them a gap on the under side, which is filled up with fibrous tissue. On its anterior aspect is a muscular band, continuous with the tensor palati, and named by Rüdinger *dilatator tubæ*. The tube is narrow where it opens into the tympanum, but expands anteriorly, so as to become wide and trumpet-shaped.

The **smaller openings** serve for the transmission of the chorda tympani nerve, and the two muscles of the tympanum.

The *opening* by which the *chorda tympani* enters the tympanum is at about the middle of its *posterior wall*, and near the root of the pyramid. The *opening of exit* for the chorda tympani is at the inner end of the fissure of Glaser in the *outer wall* of the tympanum. The nerve is usually contained in a canal (called the *canal of Huguier*) distinct from the fissure of Glaser.

The *opening* for the *tensor tympani* muscle is in the *anterior wall*, immediately above the opening of the Eustachian tube. The *opening* for the *stapedius* muscle is at the apex of a conical bony eminence, the pyramid, which is situated at the back part of the *inner wall* of the tympanum, immediately behind the fenestra ovalis.

Directly *above* the fenestra ovalis is a *rounded ridge* formed by projection of the *aqueductus Fallopii*. *Beneath* the fenestra ovalis and separating it from the fenestra rotunda is the *promontory*, a rounded prominence formed by the projection of the first turn of the cochlea. It is channelled on its surface by three small grooves which lodge the three tympanic branches of Jacobson's nerve.

The **foramina and processes of the tympanum** may be arranged, according to their situation, into four groups:—

- I. In the **external wall**, from above downwards, are the—
 Meatus auditorius, closed by the membrana tympani,
 Fissure of Glaser,
 Canal of Huguier.

2. In the **inner wall** are the—
 Ridge of the aquæductus Fallopii,
 Fenestra ovalis,
 Pyramid,
 Promontory, with the grooves for nerves,
 Fenestra rotunda.
3. In the **posterior wall** are the—
 Opening of the mastoid cells,
 Opening for Jacobson's nerve,
 Opening of entrance of chorda tympani.
4. In the **anterior wall** are the—
 Canal for tensor tympani muscle,
 Eustachian tube.

Vessels and Nerves.—The *arteries* of the tympanum are the anterior tympanic from the internal maxillary, the tympanic from the internal carotid, the stylo-mastoid from the posterior auricular, and the petrosal from the middle meningeal; occasionally there is also a small branch of the ascending pharyngeal, which ascends by the side of the Eustachian tube to reach the tympanum. The *veins* terminate in the middle meningeal and pharyngeal veins, which form a plexus near the articulation of the lower jaw, and empty into the internal jugular vein.

The *nerves* are—1. Minute branches of the facial distributed to the stapedius muscle. 2. The *chorda tympani* nerve, which leaves the facial nerve near the stylo-mastoid foramen, and arches upwards to enter the tympanum at the root of the pyramid; it then passes forwards between the handle of the malleus and long process of the incus to reach the canal of Huguier, through which it escapes. 3. The *tympanic plexus*, formed by the tympanic branch of the glossopharyngeal (Jacobson's nerve), filaments from the carotid plexus, the lesser petrosal nerve from the otic ganglion, and a branch from the greater petrosal nerve. The branches of the plexus lie in shallow grooves on the surface of the promontory, and contain numerous ganglion cells, both in the course of the filaments and at the points where they unite; they are distributed to the mucous membrane of the tympanum, Eustachian tube, and mastoid cells. 4. A filament from the otic ganglion to the tensor tympani muscle.

INTERNAL EAR.

The internal ear is called the **labyrinth**, from its complexity; it consists of an osseous cavity and certain membranous structures contained therein, the latter constituting the membranous labyrinth.

The **OSSEOUS LABYRINTH** presents a series of cavities, which

are channelled in the substance of the petrous portion of the temporal bone, and is situated between the cavity of the tympanum and the meatus auditorius internus. It is divided into three unequal portions; these are the—

Vestibule, Semicircular canals, Cochlea.

The **vestibule** is the central part of the osseous labyrinth; it is irregularly ovoid in shape, and a little flattened from without inwards. In front it communicates with the cochlea, and behind with the semicircular canals; its outer wall separates it from the cavity of the tympanum, and its inner wall corresponds to the bottom of the meatus auditorius internus.

In the outer wall there is seen the reniform opening of the fenestra ovalis, the margin of which presents a prominent ring towards the vestibule; it is closed in the recent state by the foot of the stapes and its annular ligament, as well as by the lining membrane of the labyrinth and a special membrane (*membrana secundaria*).

In the anterior part of the inner wall is a circular depression which corresponds to the posterior segment of the cul-de-sac of the internal meatus; it is called *fovea hemispherica*, and is pierced by a cluster of openings (*macula cribrosa*) through which pass filaments of the vestibular branch of the auditory nerve, and twigs of the auditory artery. Behind this is a small ridge (*crista vestibuli*), and the commencement of a small canal called the *aquæductus vestibuli*, containing a tubular membranous sheath and a small vein.

In the roof is another depression of oval form called *fovea hemielliptica*; it is separated from the fovea hemispherica by a slight ridge.

Posteriorly, the five openings of the three semicircular canals are observed, the oblique and perpendicular canals joining by one extremity and so entering by a common opening.

In front the vestibule opens into the cochlea by means of a wide, funnel-shaped opening, called *apertura scalæ vestibulæ*.

The openings of the vestibule may be arranged, like those of the tympanum, into *large* and *small*.

The large openings are seven in number :—

Fenestra ovalis,
Apertura scalæ vestibuli,
Five openings of the semicircular canals.

The small openings are three :—

Aquæductus vestibuli,
Openings for small arteries,
Openings for filaments of the auditory nerve.

The **SEMICIRCULAR CANALS** are three bony passages communicating with the vestibule, into which they open by both their

extremities. Near one extremity of each of the canals is a dilatation of its cavity which is called *ampulla*.

1. The **superior** or **perpendicular** canal is directed transversely across the petrous bone, and forms that prominence on its anterior surface which we have already described. It commences by means of an ampulla in the upper part of the vestibule, and terminates posteriorly by joining with the oblique canal, and forming a common canal which opens into the back part of the vestibule.

2. The **posterior** or **oblique** canal corresponds with the posterior part of the petrous bone; it commences by an ampullary dilatation in the posterior part of the vestibule, and curves nearly perpendicularly upwards to terminate in the common canal. In the ampulla of this canal are numerous openings for nervous filaments.

3. The **external** or **horizontal** canal is directed outwards towards the base of the petrous bone, and is shorter than the two preceding. It commences by an ampullary dilatation above the fenestra ovalis, and terminates near to the common canal.

The **COCHLEA** (so called from its resemblance to a snail's shell) is the most anterior part of the labyrinth, corresponding by its apex with the anterior wall of the petrous bone, and by its base with the anterior depression at the bottom of the cul-de-sac of the meatus auditorius internus. Its apex is arched so as to form a sort of dome, which is called the *cupola*.

It consists of a gradually tapering canal, about one inch and a half in length, which makes two turns and a half around a central axis called the *modiolus*.

The first coil projects into the tympanum, forming that rounded elevation which has already been described as the *promontory*.

The **central axis** or **modiolus** is large near its base, where it corresponds to the first turn of the cochlea, but diminishes as it proceeds towards the apex. Its external surface is composed of dense tissue, but its interior is spongy, and is pierced by numerous canals, which run spirally in its length, transmitting the filaments of the cochlear nerve. The central canal is usually larger than the others; it transmits the artery of the modiolus as well as a nerve, and is called *tubulus centralis modioli*.

The interior of the canal of the cochlea is partially divided into two passages or *scalæ* by means of a thin and porous lamina of bone, the **lamina spiralis ossea**, which is wound spirally round the modiolus in the direction of the canal. It extends about two-thirds

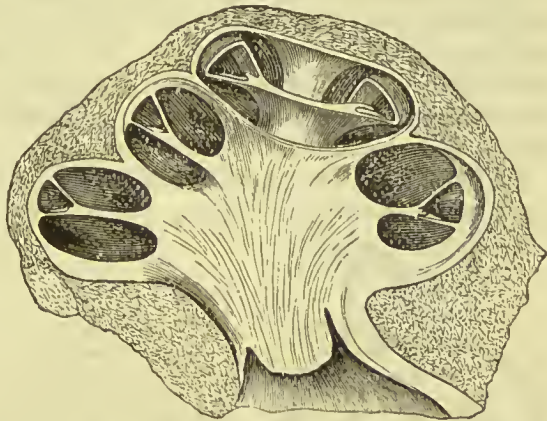


FIG. 375.—Vertical section of the cochlea of a calf, showing the modiolus and scalæ.

across the diameter of the canal, and consists of two thin lamellæ, between which, and through the perforations on their surfaces, the filaments of the cochlear nerve reach the membranous portion of the cochlea. The upper of the two passages thus separated is called the **scala vestibuli**, the lower the **scala tympani**.

At the apex of the cochlea the osseous lamina terminates by a hook-shaped process (*hamulus laminae spiralis*); and here also the scalæ communicate by means of a small opening called the **helicotrema**. Inferiorly, one of the two scalæ, the scala vestibuli, terminates by an oval aperture in the anterior part of the vestibule; while the other, the scala tympani, becomes somewhat expanded, and opens into the tympanum through the fenestra rotunda.

The internal surface of the osseous labyrinth is lined by a thin layer of periosteum which is separated from the membranous structures contained in its cavities by a limpid fluid called the **perilymph** (liquor Cotunnii). In the cochlea the periosteum invests the two surfaces of the bony lamina spiralis. The fenestra ovalis and fenestra rotunda are closed by an extension of this membrane across them, assisted by the membrane of the cavity of the tympanum, and a proper intermediate layer (*membrana secundaria*). Besides lining the interior of the osseous cavity, the periosteum sends two delicate processes along the aqueducts of the vestibule and cochlea, to the dura mater, with which they are continuous. These processes are the remains of a communication originally existing between the dura mater and the cavity of the labyrinth.

MEMBRANOUS LABYRINTH.—This consists of certain membranous bags contained within the osseous cavity of the vestibule and semicircular canals, and of the structures which serve to complete the spiral lamina of the cochlea.

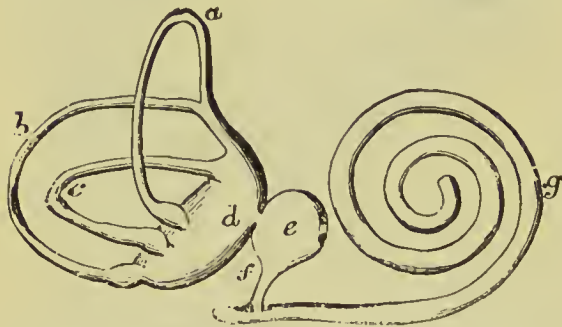


FIG. 376.—Membranous labyrinth. *a*. Superior semicircular canal. *b*. Posterior semicircular canal. *c*. External semicircular canal. *d*. Utricle. *e*. Saccule. *f*. Canalis reuniens. *g*. Membranous cochlea.

floats in the perilymph, and is held in position by numerous nerve filaments derived chiefly from the vestibular wall, and by fine fibrous bands derived from the periosteum of the osseous labyrinth. It contains in its interior a fluid similar to the perilymph, which is called **endolymph**, and is secreted by its lining membrane.

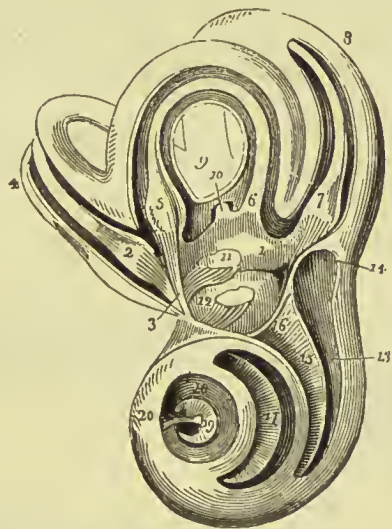
Structure.—In structure this part of the membranous labyrinth consists of three layers—an *outer*, fibrous; a *middle*, homogeneous (tunica propria); and an *inner*, epithelial. The *fibrous* layer consists

of connective tissue containing some scattered pigment cells ; it is connected with the periosteum by well-marked fibrous bands along which blood-vessels run. The *tunica propria* is transparent and apparently structureless, and is thinnest where the membranous tube is in contact with the osseous wall ; it presents towards the cavity of the tube a number of papillary projections covered by the cells of the inner coat. The *epithelial* layer is formed throughout of a single layer of flattened cells.

The **membranous vestibule** consists of two sacs, a greater and a lesser. The greater sac, called the **utricle** (*sacculus communis*), rests in the depression called *fovea hemi-elliptica*, in the upper and back part of the vestibule ; it is oblong and slightly flattened from within outwards. Its inner wall is thickened, where it receives numerous

FIG. 377.—Labyrinth of the left ear showing

its cavities and the membranous labyrinth :
 1. Cavity of the vestibule ; the figure rests on the utricle. 2. Ampulla of the perpendicular semicircular canal, receiving a fasciculus from the superior branch of the vestibular nerve (3). 4. Perpendicular canal with its contained membranous canal. 5. Ampulla of the horizontal semicircular canal, receiving a fasciculus from the superior branch of the vestibular nerve. 6. Termination of the membranous canal of the horizontal semicircular canal, in the utricle. 7. Ampulla of the oblique semicircular canal, receiving a fasciculus from the inferior branch of the vestibular nerve. 8. Oblique semicircular canal. 9. The common canal, resulting from the union of the perpendicular with the oblique semicircular canal. 10. Membranous common canal terminating in the utricle. 11. The otolith of the utricle seen through the membranous parietes. A fasciculus from the inferior branch of the vestibular nerve distributed to the utricle near the otolith. 12. Sacculc ; its otolith is seen through its membranous parietes, and a fasciculus derived from the middle branch of the vestibular nerve is distributed to it. 13. First turn of the cochlea ; the figure points to the *scala tympani*. 14. Extremity of the *scala tympani*, the *fenestra rotunda*. 15. *Lamina spiralis* : the figure is situated in the *scala vestibuli*. 16. Opening of the *scala vestibuli* into the vestibule. 17. Second turn of the cochlea ; the figure is placed on the *lamina spiralis*, and therefore in the *scala vestibuli*, the *scala tympani* being beneath the *lamina*. 18. Remaining half-turn of the cochlea ; the figure is placed in the *scala tympani*. 19. *Lamina spiralis* terminating in its falciform extremity. The dark space included within the falciform curve of the extremity of the *lamina spiralis* is the *helicotrema*. 20. *Infundibulum*.



branches of the vestibular nerve (*macula acustica*). Firmly attached to the wall of the utricle, is a small aggregation of crystals of carbonate of lime ; these are irregular in shape, and are called *otoliths* (ear-stones), or *otoconia* (ear-dust). The cavity of the utricle is continuous with that of the membranous semicircular canals, but is distinct from that of the saccule.

The lesser sac, called the **sacculc** (*sacculus proprius*), is spherical in shape, and is situated in the lower and anterior part of the vestibule, lying in the depression of the *fovea hemispherica*. It

receives nerves through the lamina cribrosa, and contains otoliths similar to those of the utricle. It is connected by means of a minute passage (*canalis reuniens*) with a small canal, which is contained within the membranous part of the cochlea, and is called *scala media*; it also sends a small canal along the aquæductus vestibuli, which ends blindly at the surface of the petrous bone.

The **membranous semicircular canals** are about one-third the size of the osseous canals which lodge them; they open into the utricle. They have dilatations which correspond to the ampullæ, but the dilatation of the membranous canals is proportionally greater than that of the osseous ones, so that at these places they nearly fill the osseous cavities in which they lie. Here also the wall is much thickened, and on it branches of the vestibular nerve are thickly distributed. In the ampullæ the tunica propria is very thick, and causes the wall to project into the cavity in the form of a transverse partition (*septum transversum*); on this septum the epithelial cells are columnar, and surmounted by fine

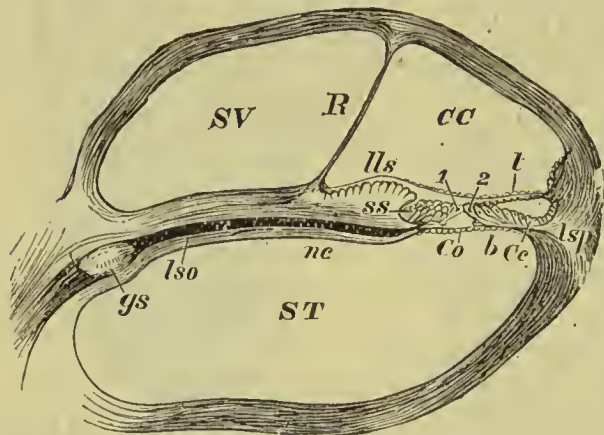


FIG. 378.—Section through one of the coils of the Cochlea. *st*, scala tympani; *sv*, scala vestibuli; *cc*, canalis cochlæ or scala media; *R*, membrane of Reissner; *lls* to *lsp*, lamina spiralis membranacea; *lls*, limbus laminae spiralis; *ss*, sulcus spiralis; *gs*, ganglion spirale seated on *ne*, the nervus cochlearis, indicated by the black line; *lso*, lamina spiralis ossea; *t*, membrana tectoria; *b*, membrana basilaris; *Co*, organ of Corti; *lsp*, ligamentum spirale; *Cc*, cells of Claudius. 1. Inner rod of Corti. 2. Outer rod of Corti.

but stiff hair-like processes (*fila acustica*). These canals contain endolymph, and have some few otoliths distributed over their epithelial lining.

The **membranous part of the cochlea*** not only completes the lamina spiralis, but also encloses a tube called the **canalis membranacea** or **scala media**, within which is a very complicated structure called the **organ of Corti**.

The description of the membranous cochlea, therefore, resolves itself into a description of this canal, its boundaries, and the parts contained in it.

Scala Media.—This canal is triangular in cross section, and is bounded externally by the osseous wall of the labyrinth, lined by its proper membrane. Internally it is bounded by a thin sheet

* To understand the description of the membranous cochlea, it is necessary that the student should constantly refer to Fig. 378.

called the **membrane of Reissner**, which separates it from the scala vestibuli. Its floor is formed by a membrane, which is stretched across from the lower edge of the osseous lamina spiralis to the cochlear wall, and is called the **membrana basilaris**.

The scala media accompanies the lamina spiralis throughout, and terminates superiorly in a cul-de-sac near the helicotrema; below, it also ends in a blind extremity, but from its inner side a small canal (*canalis reuniens*) passes to join the sacculæ, as already mentioned.

On the upper* surface of the osseous lamina spiralis, near to its outer edge, there is a thick prominence, called *limbus lamina spiralis*, which is firmly connected with the periosteum of the lamina. Its surface is irregular, being marked by certain fungiform prominences; these are not all of the same length, the internal ones being short, while the external are long, and hang over towards the basilar membrane, so as to form a groove beneath them, which is called the *sulcus spiralis*. Covering in the limbus, and stretching across from its outer edge to the outer wall of the scala, is an elastic membrane called *membrana tectoria* (membrane of Corti). It is nearly parallel with the basilar membrane, and thus divides the scala media into two parts, the inferior of which is the smallest, and contains the organ of Corti.

The **basilar membrane** is stretched across from the free edge of the osseous lamina to the outer wall of the spiral canal; it is on the same plane as the lamina itself, and is firmly attached at its outer extremity by means of a thick ligament (spiral ligament) to the cochlear wall.

The **membrane of Reissner** arises from the base of the limbus (or on its inner side), and extends across to the upper and outer part of the cochlear wall. It is directed somewhat obliquely, and separates the scala vestibuli from the scala media. It is composed of very delicate connective tissue, covered on the vestibular side by an epithelioid layer of flattened connective tissue corpuscles, and on the side towards the scala media by simple pavement epithelium.

The **organ of Corti** consists of those structures which are contained between the membrana tectoria above and the basilar membrane below. Its central and most important part is formed of rod-like bodies, which are fixed firmly below to the basilar membrane, but above, their enlarged ends meet together like the beams of a roof, so as to enclose a triangular space. The inner rods overlap the outer, and the latter have a process bent back towards the outer side of the canal. On each side of these central bodies are others which appear to recline on the larger ones just described; they consist of an inner and an outer set.

The inner cells (*inner hair cells*) form a single layer, each cell terminating in fine, stiff, hair-like processes. Those on the outer

* For convenience of description we speak as if the base of the cochlea was directed downwards and its apex upwards; it must, however, be kept in mind that this is not their position when *in situ*. In like manner, it is convenient to speak of the wall nearest the modiolus as *inner*, and that at the periphery of the cochlea as *outer*.

side of the rods of Corti are more numerous and longer; they commonly form four or five rows, which incline towards the outer

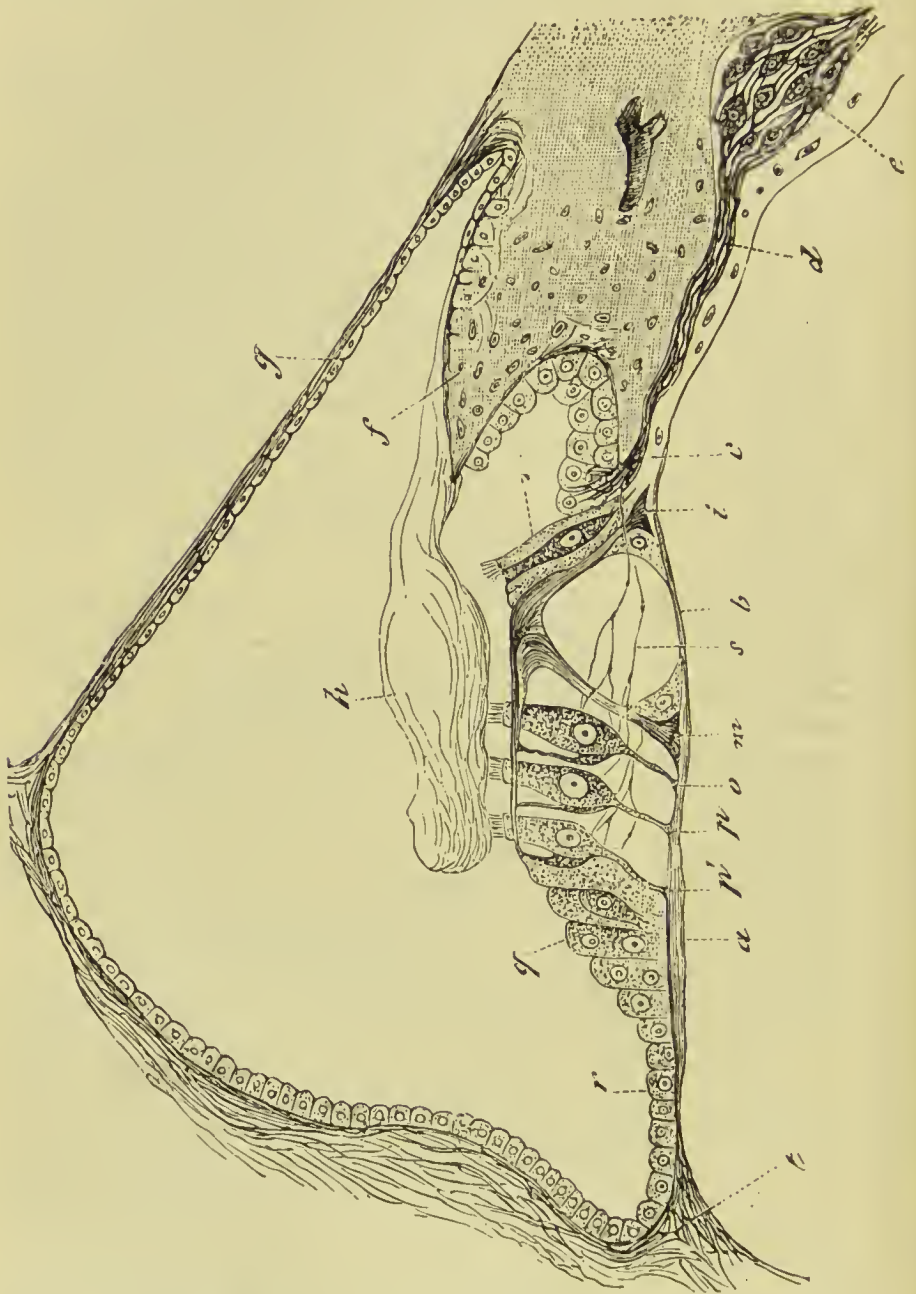


FIG. 379.—Transverse section through the membranous canal of the cochlea. *a*. Striated zone of basilar membrane. *b*. Pectinate zone of the basilar membrane. *c*. Perforated zone of basilar membrane through which the nerves pass. *d*. Nerve fibres from spiral ganglion. *e*. Spiral ganglion. *f*. Limbus. *g*. Reissner's membrane. *h*. Tectorial membrane. *i*. Internal rod of Corti. *m*. External rod of Corti. *o*, *p*, *p'*. Special cells receiving nerve terminals. *q*. Epithelial cells covering the basilar membrane. *s*. Nerve fibres. *t*. Spiral ligament.

rod, and also terminate in bunches of stiff hairs (*outer hair cells*). The hairs of the outer series project through ring-like processes which surmount the top of the cells, these processes presenting the appearance of a wire net, and forming what has been named the *reticular lamina*. On each side of the hair cells the epithelium becomes shorter and shorter, until at length it forms merely a cubical layer, which on the inner side partly fills up the sulcus spiralis, and on the outer side forms a covering for the basilar membrane.

VESSELS AND NERVES OF THE INTERNAL EAR.

Vessels.—The arteries of the labyrinth are derived from the internal auditory branch of the basilar artery, and from the stylo-mastoid branch of the posterior auricular. The auditory artery at the bottom of the meatus internus divides into cochlear and vestibular branches, which accompany the branches of the auditory nerve to the vestibule and cochlea.

The veins of the vestibule unite with those of the cochlea, and empty themselves into the superior petrosal sinus, or into the commencement of the internal jugular vein.

Nerves.—In order that the student may fully understand the distribution of the nerves of the internal ear, it is necessary, in the first place, that he should know something of the anatomy of the interior of the meatus auditorius internus.

The **meatus** pursues a course directly outwards; it is about one-third of an inch in length, and terminates in two deep depressions, separated by a sharp horizontal ridge. The *superior depression*, the smaller of the two, is divided by a vertical ridge into an anterior portion, forming the commencement of the aquæductus Fallopii, and a posterior portion, which corresponds with the upper part of the inner wall of the vestibule, and is pierced by numerous small foramina. The *inferior depression* presents posteriorly an oval pit, pierced by numerous foramina, opening into the vestibule; near its anterior extremity, it is marked by a spiral groove pierced by minute openings for the passage of filaments of the cochlear nerve; this is called *tractus spiralis foraminulentus*. In the centre of the small piece of bone which this groove isolates, is one foramen larger than the rest, which leads into the central canal of the modiolus, *tubulus centralis modioli*. Upon the posterior wall of the lower depression, and opposite to the spiral groove, is a longitudinal groove leading to a foramen, for the transmission of a considerable branch of the vestibular nerve.

The auditory and facial nerves enter the meatus internus together, accompanied by the auditory branch of the basilar artery. At the bottom of the meatus the facial enters the aqueduct of Fallopius, and is conducted along it to the stylo-mastoid foramen, as already described.

The **auditory** nerve divides into two branches at the bottom of

the meatus, a vestibular nerve and a cochlear nerve, the latter lying anterior to the former, and a little below the facial nerve.

The **vestibular** nerve separates into three branches, superior, middle, and inferior. The *superior* vestibular branch gives off a number of filaments, which pass through the foramina in the posterior part of the superior depression; they enter the vestibule beside the crista vestibuli, and are distributed to the utricle, and the ampulla of the superior and external semicircular canals. The *middle* vestibular branch sends off numerous filaments which pass through the foramina in the lower depression, enter the vestibule through the fovea hemispherica, and are distributed to the saccule. The *inferior* and smallest branch passes along the groove and through the foramen at the back part of the meatus; it is distributed to the ampulla of the posterior canal. The filaments which pass to the canals bifurcate at their extremities, and are applied against the flattened side of each membranous ampulla; they then pass into the membranous wall, and into the partial septum, which has been already described as projecting into the ampulla (*crista acustica*).

The **cochlear** nerve divides into numerous filaments, which enter the foramina of the tractus spiralis in the base of the cochlea, pass upwards in the canals of the modiolus, and, bending outwards at right angles, pass between the two layers of the osseous lamina spiralis. Here the nerve filaments form a network, in the midst of which numerous small ganglia have been observed. From this plexus branches are given off externally, which perforate the bottom of the sulcus spiralis, and, it is supposed, terminate by becoming attached to the rods of Corti; and the cells which adjoin them on each side. The central portion of the cochlear nerve passes through the tubulus centralis modioli, and supplies the apical portion of the lamina spiralis, and the adjoining structures.

ORGAN OF TASTE.

The **tongue** is composed of muscular fibres, which are distributed in layers arranged in various directions: thus, some are disposed *longitudinally* (lingualis superficialis); others *transversely* (lingualis transversus); others, again, *obliquely* and *vertically*. The arrangement of the different bundles forming the intrinsic muscles of the tongue has been described on a previous page (p. 257). Between the muscular fibres is a considerable quantity of adipose substance, and in the middle of the organ a vertical septum of fibrous tissue.

The tongue is *connected*, posteriorly, with the os hyoides by muscular attachment; and to the epiglottis by mucous membrane, which forms the three *glosso-epiglottic folds*. At either side it is held in connection with the lower jaw by mucous membrane; and in front, a fold of that membrane, which is named *frænum lingue*, is formed

beneath its under surface. It is also connected with the soft palate by means of the anterior pillars of the fauces.

The upper surface of the tongue is covered by a dense layer of

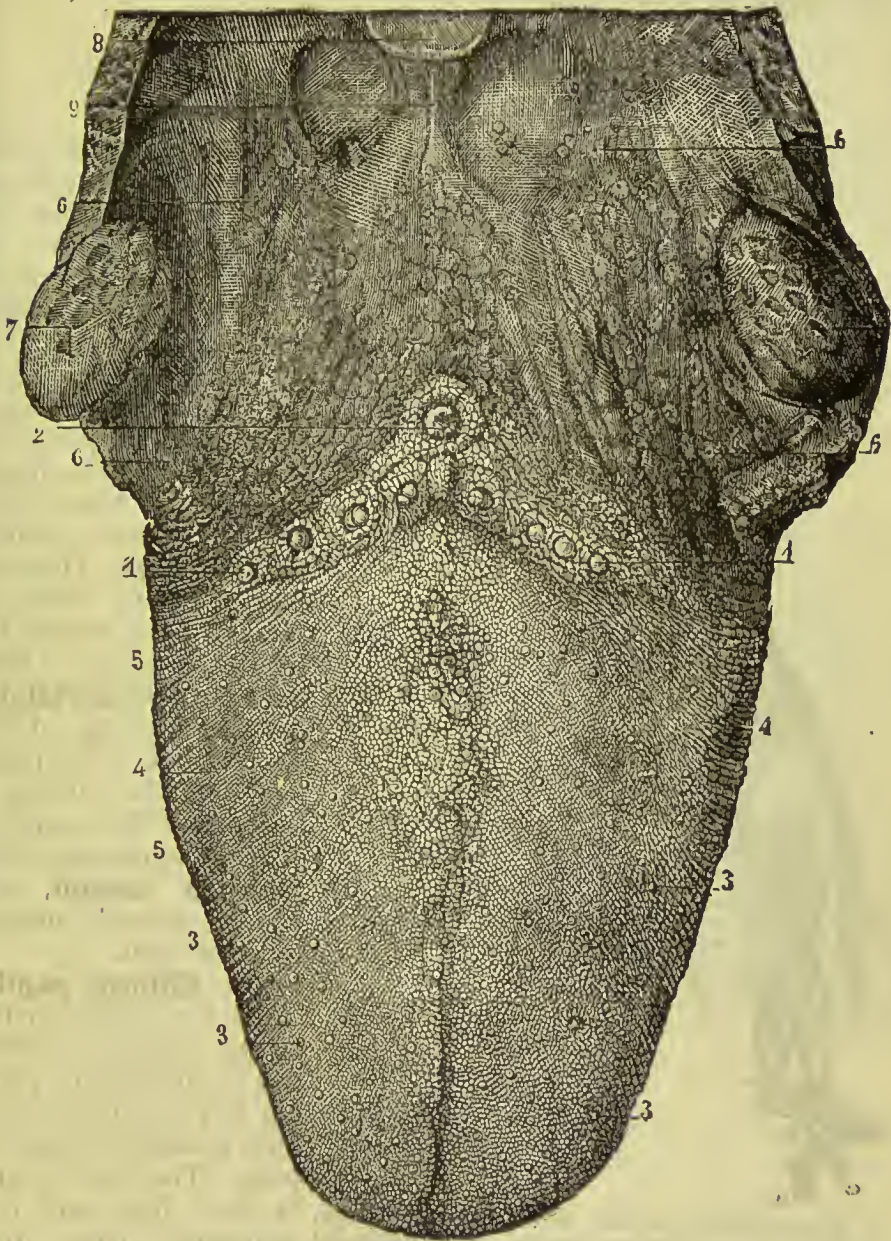


FIG. 380.—Tongue and tonsils. 1, 1. Circumvallate papillæ. 2. Foramen cæcum. 3, 3, 3, 3. Fungiform papillæ. 4, 4. Filiform papillæ. 5, 5. Lateral rows of filiform papillæ. 6, 6, 6, 6. Glands at the base of the tongue. 7. Tonsil. 8. Epiglottis. 9. Middle glos-o-epiglottic fold.

mucoſ membrane, ſtudded over in its anterior three-fourths by prominent papillæ, and preſenting an irregular ſurface in its poſte-

rior fourth due to the projection of thickly crowded mucous glands. A raphé marks the middle line of the organ, and divides it into symmetrical halves.

The **papillæ** of the tongue are the—

Circumvallate papillæ,
Filiform papillæ,
Fungiform papillæ.

The **circumvallate papillæ** (p. lenticulares) are of large size, and from fifteen to twenty in number. They are situated on the dorsum

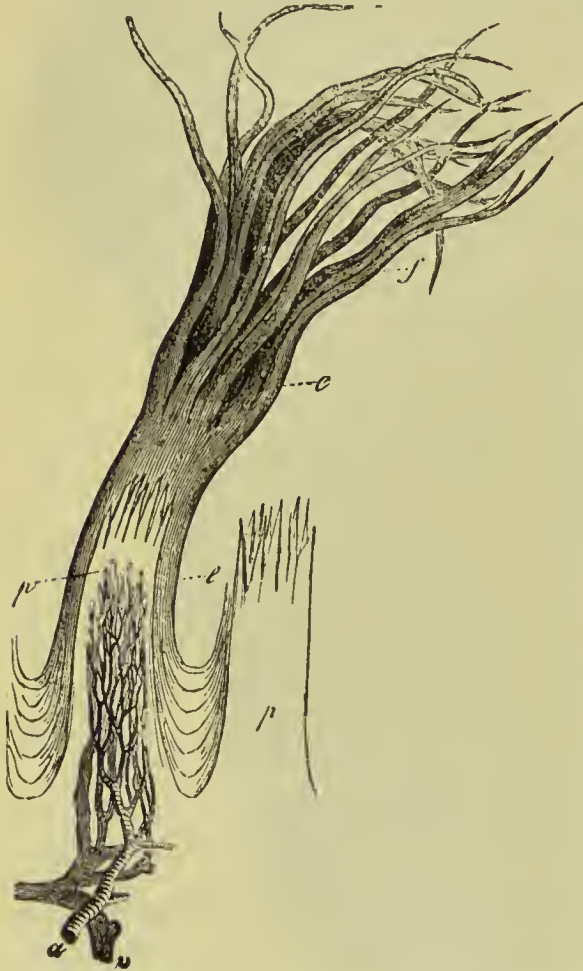

FIG. 381.—Filiform papillæ of tongue. *a*. Artery.
v. Vein. *p*, *p*. Primary papillæ. *e*, *e*. Epithelial
covering ending in the tufted processes, *f*.

of the tongue, near its root, and form a row at each side, which meets its fellow at the middle line, like the two branches of the letter A. Each papilla resembles a cone, attached by its apex to the bottom of a cup-shaped depression; hence they are also named **papillæ calyciformes**. This cup-shaped cavity forms a kind of fossa around the papilla, whence their name **circumvallatæ**. At the meeting of the two rows of these papillæ upon the middle of the root of the tongue, is a deep depression called **foramen cæcum**, into which several mucous follicles open.

The **filiform papillæ** cover the whole surface of the tongue in front of the circumvallate papillæ, but are most abundant towards its anterior part. They are conical at their base, and have projecting from their apices filiform processes,

which are found to be products of the epithelium. They are arranged in rows, which at the back part of the tongue are nearly parallel with the circumvallate papillæ, but get more longitudinal in their direction as we proceed forwards, so that at the tip of the tongue they get to be nearly parallel with the raphé.

The **fungiform papillæ** are irregularly dispersed over the dorsum of the tongue, and are easily recognised among the other papillæ by their rounded heads, larger size, and red colour. A number of these papillæ will generally be observed at the tip of the tongue.

All these papillæ have minute secondary papillæ projecting from their surfaces, and these are coated with a very dense epithelial layer, which is generally flat over the circumvallate and fungiform papillæ, but in the others forms hair-like processes, which vary greatly in their size and shape.

The circumvallate and fungiform papillæ appear alone to possess the special sense of taste, the filiform being much too dense at their apices for the apprehension of delicate sensation, and hitherto no nerve filaments have been traced into the secondary papillæ which surmount them. The filiform, however, are probably endowed with common sensation, and it is manifest that they perform important service in assisting mastication.

Behind the papillæ circumvallatæ, at the root of the tongue, are a number of mucous glands (*lingual*), which open on the surface. There is also a small cluster beneath the tip of the tongue.

Taste-buds.—These are believed to be the special organs of taste; they are found on the sides of the circumvallate papillæ embedded in the sub-

stance of the mucous membrane, one end being in contact with the corium, the other opening by minute pores on to the surface. They consist of numerous aggregated epithelial cells, the central ones being spindle-shaped, the peripheral ones flattened, with tapering ends. The free end

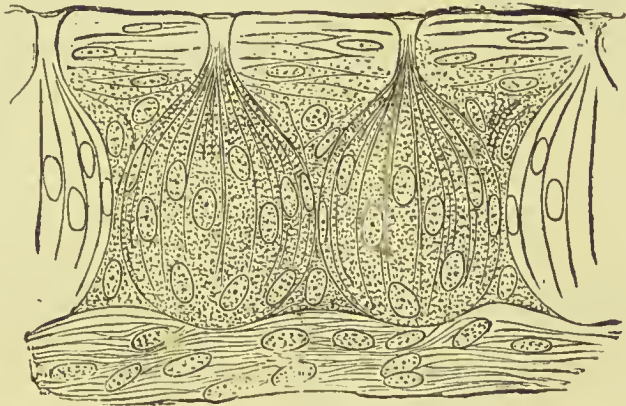


FIG. 382.—Taste-buds from the lateral gustatory organ of a rabbit.

of each cell is sharp and pointed, and projects through the pore; the deep extremity is branched and connected with a plexus of nerve fibres.

Vessels and Nerves.—The tongue is abundantly supplied with blood by the lingual arteries.

The **nerves** are three in number, and of large size; the *gustatory* or *lingual* branch of the inferior maxillary is distributed to the papillæ and mucous membrane generally of the fore-part and sides of the tongue; it is the nerve of common sensation to those parts. With it are distributed filaments of the chorda tympani; these seem to go chiefly to the papillæ, and experiments tend to show that the sense of taste in the front and sides of the tongue is due to these, and not to the lingual filaments, as was formerly sup-

posed. Many observers believe that the chorda tympani filaments are really derived from the glosso-pharyngeal nerve; that they join the facial nerve at the stylo-mastoid foramen, and ascend through the lower part of the aqueduct of Fallopius to the iter chordæ posterioris. Traversing the tympanum in the manner already described, and leaving the cavity through the canal of Huguier, the chorda joins the lingual branch of the fifth in the pterygoid region, and with it is distributed to the tongue.

The **glosso-pharyngeal** nerve is distributed to the back part of the tongue, and more especially to the circumvallate papillæ; it endows those parts with the sense of taste. The **hypoglossal** nerve is the motor nerve distributed to the extrinsic muscles of the tongue, and to most of the intrinsic fibres. A branch of the facial nerve, however, is transmitted along the glosso-pharyngeal nerve, and in part supplies the intrinsic muscles (Hirschfeld).

The terminal filaments of the sensory nerves are supposed in some cases to become attached to the inner ends of the epithelial cells, especially those forming the taste-buds; the connection bearing a close resemblance to that observed in the retina, the cochlea, and the nasal mucous membrane.

The **mucous membrane** which invests the tongue is continuous with the derma along the margin of the lips. On either side of the frænum linguæ it may be traced through the sublingual ducts into the sublingual glands, and along Wharton's ducts into the submaxillary glands; from the sides of the cheeks it passes through the opening of Stenson's ducts to the parotid glands; in the fauces, it forms the assemblage of mucous crypts called tonsils, and may thence be traced downwards into the larynx and pharynx, where it is continuous with the general gastro-pulmonary mucous membrane.

Beneath the mucous membrane of the mouth are a number of small *glands*, which pour their secretion upon the surface. A considerable number of these bodies are situated within the lips, in the palate, and in the floor of the mouth. They are named according to their position—*labial glands*, *palatal glands*, and *buccal glands*.

PART VII.

SPLANCHNOLOGY.

THAT part of the science of anatomy which treats of the viscera is named splanchnology, from the Greek words *σπλάγχνον*, viscus, and *λόγος*. The viscera of the human body are situated in the three great internal cavities: cranio-spinal, thorax, and abdomen. The viscera of the cranio-spinal cavity, namely, the brain and spinal cord, with the principal organs of sense, have been already described, in conjunction with the nervous system. The viscera of the chest are: the central organ of circulation, the heart; the organs of respiration, the lungs; and the thymus gland. The abdominal viscera admit of a subdivision into those which properly belong to that cavity—viz., the alimentary canal, liver, pancreas, spleen, kidneys, and supra-renal capsules; and those of the pelvis: the bladder and internal organs of generation.

THORAX.

The thorax is the conical cavity situated at the upper part of the trunk of the body; it is narrow above and broad below, and is bounded, in *front*, by the sternum, six superior costal cartilages, ribs, and intercostal muscles; *laterally*, by the ribs and intercostal muscles; and, *behind*, by the ribs, intercostal muscles, and vertebral column, as low down as the upper border of the last rib and first lumbar vertebra; *superiorly*, by the first rib at each side, the upper part of the sternum in front and the body of the second dorsal vertebra behind; and, *inferiorly*, by the diaphragm. The superior opening of the thorax gives passage to the following parts, namely, the sterno-hyoid, sterno-thyroid, and longus colli muscles; the remains of the thymus gland; the trachea, œsophagus, and thoracic duct; left carotid, left subclavian, innominate, superior intercostal, and internal mammary arteries; the right and left innominate and inferior thyroid veins; the pneumogastric, cardiac, left recurrent laryngeal, phrenic, and sympathetic nerves; the anterior division of the first dorsal nerve; and the upper part of the lungs and pleuræ. The cavity of the thorax is much deeper on the posterior than on the anterior wall, in consequence of the obliquity of the diaphragm, and contains the heart enclosed in its pericardium, with the great

vessels; the lungs, with their serous coverings, the pleuræ; the œsophagus; some important nerves; and, in the foetus, the thymus gland.

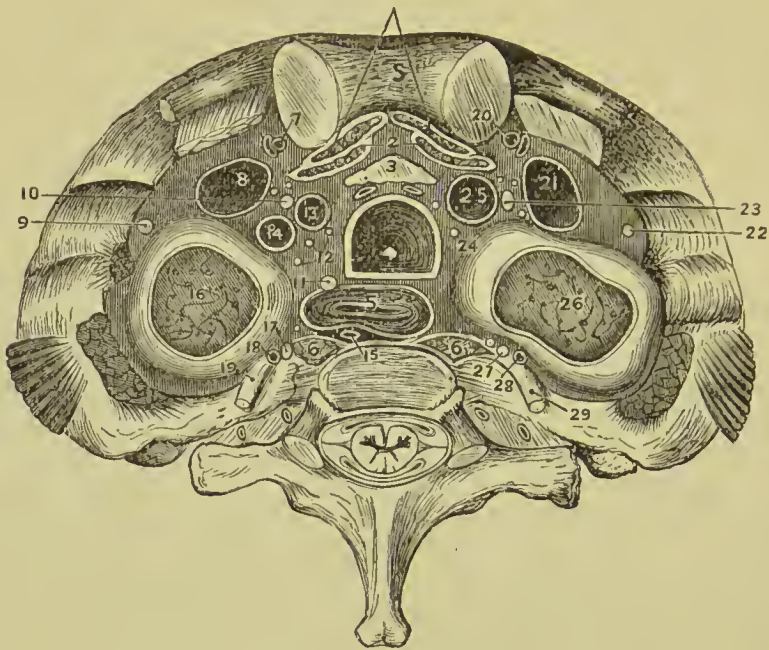

FIG. 383.—Upper opening of the thorax. *Median line.* 1. Sterno-hyoid. 2. Sterno-thyroid. 3. Remains of thymus gland. 4. Trachea. 5. Œsophagus. 6. Longus colli muscles. *Left side.* 7. Internal mammary artery. 8. Innominate vein. 9. Phrenic nerve. 10. Pneumogastric nerve. 11. Recurrent laryngeal nerve. 12. Cardiac nerves. 13. Left carotid artery. 14. Left subclavian artery. 15. Thoracic duct. 16. Apex of lung and pleura. 17. Sympathetic nerve. 18. Superior intercostal artery. 19. First dorsal nerve. *Right side.* 20. Internal mammary artery. 21. Innominate vein. 22. Phrenic nerve. 23. Pneumogastric nerve. 24. Cardiac nerves. 25. Innominate artery. 26. Apex of lung and pleura. 27. Sympathetic nerve. 28. Superior intercostal artery. 29. First dorsal nerve.

PERICARDIUM.

The central organ of circulation, the heart, is situated between the two layers of pleura which constitute the mediastinum, and is enclosed in a proper membrane, the pericardium.

The pericardium is a fibro-serous membrane, its serous layer being reflected from the serous membrane of the viscus which it encloses. In shape it is like a truncated cone, the base being downward, the truncated apex upward, surrounding the aorta. It consists of two layers, external, fibrous; and internal, serous. The *fibrous* layer is attached above to the great vessels proceeding from the heart, on which it is continuous with the deep cervical fascia; and below, to the tendinous portion of the diaphragm. Where it encloses the great vessels it is prolonged on them for some distance

in a tubular form, and at length becomes lost in their outer coat. The vessels which are partly covered by it are eight in number, namely, the aorta, superior vena cava, four pulmonary veins, and right and left divisions of the pulmonary artery. The *serous* membrane invests the heart with the commencement of its great vessels as high as the arch of the aorta, and is then reflected upon the internal surface of the fibrous layer. The aorta and pulmonary artery are contained in the same tube of pericardium, having been formed by the division of the primitive aorta; it will consequently be found impossible to pass anything between them. Where the serous layer is reflected from the heart on to the bloodvessels, it forms a series of pouches, the largest of which, called the *great oblique sinus*, is situated between the inferior cava on the right and the left inferior pulmonary vein. Another, but narrower, pouch runs between the aorta and pulmonary artery above, and the superior cava and superior pulmonary vein below, and is called the *transverse sinus*. A crescentic fold of pericardium is found lying across the front of the upper left pulmonary vein; it is called the *vestigial fold*, and contains the remains of the left superior vena cava.

In intimate structure the fibrous layer is composed of strong interlacing fibres, the serous layer consisting of a thin stratum of elastic tissue disposed in a network, adherent by one surface to the fibrous layer, and smooth on the free surface, where it gives support to a single or double lamina of tessellated endothelium. The bag of the pericardium has few vessels and nerves, the latter being derived from the phrenic and recurrent branch of the right pneumogastric.

The pericardium is connected with the sternum by two weak fibrous bands, the *superior* and *inferior sterno-pericardiac ligaments*; it is further steadied and fixed by its connection with the central tendon of the diaphragm below, and the thoracic and deep cervical fasciæ above.

HEART.

The heart is placed obliquely in the chest, the *base* being directed upwards and backwards towards the right shoulder, and corresponding to the interval between the fifth and eighth dorsal vertebræ; the *apex* forwards and to the left, pointing to the space between the fifth and sixth rib, at about two and a half inches from the sternum. Its *posterior* or *under side* is flattened, and rests on the tendinous portion of the diaphragm; its *anterior side* is rounded and convex; the *lower* or *right border* is thin (*margo acutus*) and longer than the left border; the latter is formed by the left ventricle, and is thick and rounded (*margo obtusus*). The heart is divided by a deep transverse groove, *auriculo-ventricular groove*, into an upper or auricular, and a lower or ventricular portion; in the latter, a less distinct and shallower groove, runs from base to apex, both on the front and back, *interventricular groove*, and marks out the right from the left ventricular cavity. In the auriculo-

ventricular and interventricular grooves lie the arteries, veins, nerve plexuses, and lymphatics of the organ. The front of the heart is chiefly formed of the wall of the right ventricle; the left border and apex by the left ventricle; the extreme right edge by the right auricle; and the posterior surface mainly by the left ventricle, with a small part of the right ventricle and left auricle. At the base, above the auriculo-ventricular groove, are the auricles, surmounted by their *auricular appendages*; these are lappet-like processes which overlap the root of the pulmonary artery. The lungs extend on to the margins of the heart, especially during inspiration, so that when they are fully inflated only a small triangular part not more than two inches in extent is left uncovered. The pulmonary artery is the large anterior vessel at the root of the heart; it crosses obliquely the commencement of the aorta. The right is the venous side of the heart; it receives into its auricle the venous blood from every part of the body, by the superior and inferior cava and coronary sinus. From the auricle the blood passes into the ventricle, and from the ventricle through the pulmonary artery to the capillaries of the lungs. From these it is returned as arterial blood to the left auricle; from the left auricle it passes into the left ventricle, and from the left ventricle is carried through the aorta, to be distributed to every part of the body and again returned to the heart by the veins. This constitutes the course of the adult circulation.

The heart is best studied *in situ*. If, however, it be removed from the body, it should be placed in the position indicated by the above description of its situation. An incision should be made from the superior to the inferior cava, and joined by one at right angles to it, passing into the auricular appendage. The blood must then be removed.

The **RIGHT AURICLE** is larger than the left, and consists of a principal cavity and an auricular appendix; the former is the part into which the great veins empty their blood, and it hence receives the name of **sinus venosus** or **atrium**. The interior of the auricle presents for examination five openings, two valves, two relics of foetal structure, and two peculiarities in the proper structure of the auricle. To facilitate remembrance they may be thus arranged:—

Openings	{	Superior cava,	Relics of foetal structure	{	Annulus ovalis,
		Inferior cava,			Fossa ovalis.
Valves	{	Coronary sinus,	Structure of the auricle	{	Tubercle of
		Foramina Thebesii, Auriculo-ventricular.			Lower, Musculi pectinati.
		Eustachian valve,			
		Coronary valve.			

The **superior vena cava** returns the blood from the upper half of the body, and opens into the upper and back part of the auricle.

The **inferior vena cava** returns the blood from the lower half of the body, and opens through the lower and posterior wall, close to the partition between the auricles (*septum auricularum*). The

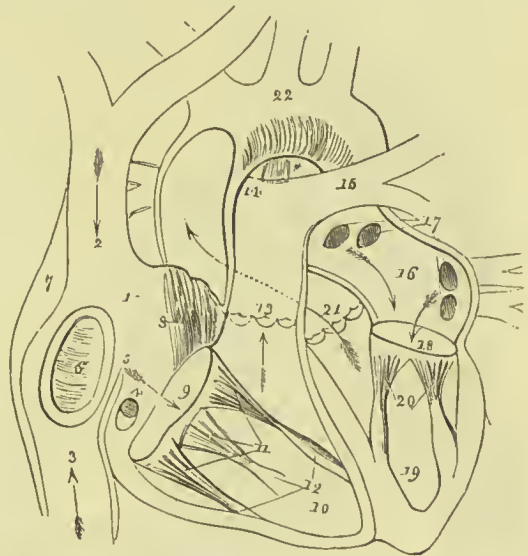
direction of these two vessels is such, that a stream forced through the superior cava would rush towards the auriculo-ventricular opening. In like manner, a jet issuing from the inferior cava would dash its stream against the septum auricularum; this is the proper direction of the two currents during foetal life.

The **coronary sinus** returns the venous blood from the substance of the heart; it opens into the auricle between the inferior cava and auriculo-ventricular opening, under cover of the coronary valve.

The **foramina Thebesii** are minute pore-like openings of small veins which issue directly from the muscular structure of the heart,

FIG. 384.—Anatomy of the heart.

1. Right auricle. 2. Entrance of the superior vena cava. 3. Entrance of the inferior cava. 4. Opening of the coronary sinus, half closed by the coronary valve. 5. Eustachian valve. 6. Fossa ovalis, surrounded by the annulus ovalis. 7. Tubercle of Lower. 8. Musculi pectinati of the appendix auriculæ. 9. Auriculo-ventricular opening. 10. Cavity of the right ventricle. 11. Tricuspid valve, attached by the chordæ tendinæ to the columnæ carneæ (12). 13. Pulmonary artery, guarded at its commencement by three semilunar valves. 14. Right pulmonary artery, passing beneath the arch and behind the ascending aorta. 15. Left pulmonary artery, crossing in front of the descending aorta. * Remains of the ductus arteriosus, acting



as a ligament between the pulmonary artery and arch of the aorta. The arrows mark the course of the venous blood through the right side of the heart. Entering the auricle by the superior and inferior cavæ, it passes through the auriculo-ventricular opening into the ventricle, and thence through the pulmonary artery to the lungs. 16. Left auricle. 17. Openings of the four pulmonary veins. 18. Auriculo-ventricular opening. 19. Left ventricle. 20. Mitral valve, attached by its chordæ tendinæ to two large columnæ carneæ, which project from the walls of the ventricle. 21. Commencement and course of the ascending aorta behind the pulmonary artery, marked by an arrow. The entrance of the vessel is guarded by three semilunar valves. 22. Arch of the aorta. The comparative thickness of the two ventricles is shown in the diagram. The course of the pure blood through the left side of the heart is marked by arrows. The blood is brought from the lungs by the four pulmonary veins into the left auricle, and passes through the auriculo-ventricular opening into the left ventricle, whence it is conveyed by the aorta to every part of the body.

without entering the venous current. Similar openings are also found in the left auricle, and in the right and left ventricles, but, in the latter, they are commonly not the termination of vessels but mere caecal depressions.

The **auriculo-ventricular opening** is the large opening of communication between the auricle and ventricle. It is oval in form, and admits three fingers easily.

The **Eustachian valve** is a part of the apparatus of foetal circulation, and serves to direct the placental blood from the inferior

cava, through the foramen ovale into the left auricle. In the adult it is a mere vestige and imperfect, being often cribriform, though sometimes it remains of large size. It is formed by a fold of the lining membrane of the auricle, containing some muscular fibres, is situated between the aperture of the inferior cava and the auriculo-ventricular opening, and is continued into the anterior part of the annulus ovalis.

The **coronary** or **Thebesian valve** is a semilunar fold of the lining membrane, stretching across the mouth of the coronary sinus, and preventing the reflux of blood in the vein during contraction of the auricle. It is insufficient to close the opening when the walls of

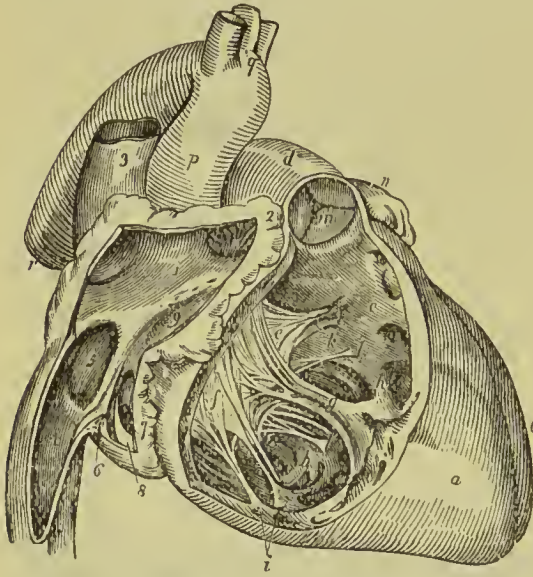


FIG. 385.—Anatomy of the heart: right side. 1. Cavity of right auricle. 2. Appendix auriculæ; in its cavity are seen the muscoli pectinati. 3. Superior vena cava, opening into the upper part of right auricle. 4. Inferior vena cava. 5. Fossa ovalis; the prominent ridge surrounding it is the annulus ovalis. 6. Eustachian valve. 7. Opening of the coronary sinus. 8. Coronary valve. 9. Entrance of the auriculo-ventricular opening. Between the figures 1 and 9, two or three foramina Thebesii are seen. *a*. Right ventricle. *b*, *c*. Cavity of right ventricle, on the walls of which the columnæ carneæ are seen; *c* is placed in the channel leading upwards to the pulmonary artery, *d*. *e*, *f*. Tricuspid valve; *e* is placed on the anterior curtain, *f* on the right curtain. *g*. Musculus papillaris, to the apex of which the anterior and right curtain are connected

by chordæ tendineæ. *h*. The "long moderator band." *i*. The two columnæ carneæ of the right curtain. *k*. Attachment by chordæ tendineæ of the left limb of the anterior curtain. *l*, *l*. Chordæ tendineæ of the "fixed curtain" of the valve. *m*. Valve of the pulmonary artery. The letter of reference is placed on one of the posterior semilunar segments. *n*. Apex of left appendix auriculæ. *o*. Left ventricle. *p*. Ascending aorta. *q*. Its transverse portion, with the three arterial trunks which arise from the arch. *r*. Descending aorta.

the heart are relaxed, but is quite competent during their contraction, as the opening then becomes narrowed.

The **annulus ovalis** is situated on the septum auricularum, opposite the termination of the inferior cava. In the fœtus it formed the margin of an oval opening (**foramen ovale**) by which the two auricles communicated. In the adult the annulus is commonly incomplete below.

The **fossa ovalis** is an oval depression corresponding with the foramen ovale of the fœtus. This opening is closed at birth by a thin valvular layer, which is continuous with the left margin of the annulus, and is frequently imperfect at its upper part. The depression or fossa in the right auricle results from this arrangement. There is no fossa ovalis in the left auricle.

The **tubercle of Lower** is the portion of auricle intervening between the openings of the superior and inferior cava. Being thicker than the walls of the veins, it forms a projection, which was supposed by Lower to direct the blood from the superior cava into the auriculo-ventricular opening. It is better marked in the lower animals than in man.

The **musculi pectinati** are small muscular columns situated in the auricular appendix. They are numerous, and arranged parallel with each other; hence their cognomen *pectinati*, like the teeth of a comb. They terminate posteriorly on a vertical ridge, the *crista terminalis* of His.

The **RIGHT** or **ANTERIOR VENTRICLE** is triangular in form. Its walls form the chief part of the anterior surface and lower border of the heart, and a small portion of the posterior surface. The posterior side, which is also inferior, is flat, and rests on the diaphragm; the inner side corresponds with the partition between the two ventricles, septum ventriculorum; the anterior side is convex. Superiorly where the pulmonary artery arises, there is a dilatation of the ventricle, termed the **infundibulum**, or **conus arteriosus**. The ventricular septum bulges towards the right, so that in cross sections of the heart, the cavity of the right ventricle is crescentic.

Dissection.—The right ventricle is to be laid open by grasping the wall with the left hand, transfixing it with the scalpel about half-way down, and carrying the incision onwards to the apex of the heart.

It contains, to be examined, two openings, the auriculo-ventricular and that of the pulmonary artery; two apparatus of valves, tricuspid and semilunar; and a muscular and tendinous apparatus belonging to the tricuspid valves. They may be thus arranged:—

Auriculo-ventricular opening,	Tricuspid valve,
Opening of the pulmonary artery,	Semilunar valves.
Chordæ tendineæ,	
Columnæ carneæ.	

The **auriculo-ventricular opening** is surrounded by a fibrous ring, covered by the lining membrane (endocardium) of the heart. It is the opening of communication between the right auricle and ventricle.

The **opening of the pulmonary artery** is situated at the summit of the conus arteriosus, close to the septum ventriculorum, on the left side of the right ventricle, and upon the anterior aspect of the heart.

The **tricuspid valve** is formed by three triangular folds of the lining membrane, strengthened by a thin layer of fibrous tissue. They are connected by their base around the auriculo-ventricular opening; and by their sides and apices which are thickened, they give attachment to a number of slender tendinous cords, called chordæ tendineæ. The **chordæ tendineæ** are the tendons of the thick muscular column (*columnæ carneæ*) which stand out from the

walls of the ventricle and serve as muscles to the valves. A number of these tendinous cords converge to a single muscular attachment. Of the three segments of which the valve is composed one is placed anteriorly, and is connected with the anterior wall, a second is placed against the posterior wall, while the third lies between the auriculo-ventricular opening and the commencement of the pulmonary artery; the first of these (*anterior*) is attached by means of chordæ tendineæ to a papillary muscle springing from the anterior free wall of the cavity, the second (*left or infundibular*) is attached in like manner to a papillary muscle on the posterior wall, while the third is connected directly by its chordæ to the ventricular septum (*posterior or septal*). Between the bases of these three flaps

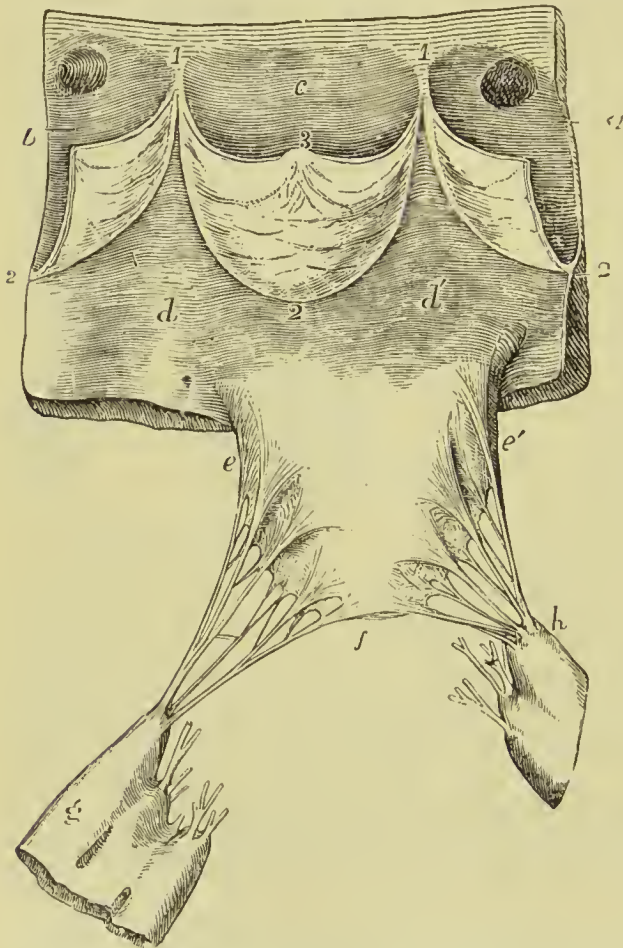


FIG. 386.—Portion of the wall of the ventricle *d, d'*, and aorta, *a, b, c*, showing attachments of one flap of the mitral and the aortic valves. *h* and *g*. Musculi papillares. *e, f, f*. Attachment of the chordæ tendineæ.

small intermediate folds are usually found. The chordæ tendineæ are attached not only to the margins of the valve segments, but also to the base and outer or ventricular surface; there are none, however, attached to the inner surface, over which the blood passes in its course from the auricle to the ventricle, so that this surface is smooth throughout, and friction is thus lessened. The tricuspid valves prevent the regurgitation of blood into the auricle during the contraction of the ventricle, and they are prevented from being themselves driven back by the chordæ tendineæ and their muscular attachments.

The *columnæ carneæ* (fleshy columns) is a name expressive

of the appearance of the internal walls of the ventricles, which, with the exception of the infundibulum, seem formed of muscula

columns interlacing in almost every direction. They are divided, according to the manner of their connection, into three sets. 1. The great number are attached by the whole of one side, and merely form convexities into the cavity of the ventricle. 2. Others are connected by both extremities, being free in the middle. 3. Two of larger size called **musculi papillares**, are attached by one extremity to the walls of the heart, and by the other give insertion to the chordæ tendineæ. One of these is connected with the anterior and the other with the posterior wall of the ventricle. At the base of the anterior one a transverse fleshy band stretches across to the ventricular septum; it is called the *moderator band*, and is believed to strengthen the thin anterior wall by binding it to the firmer septum.

The **semilunar or sigmoid valves**, three in number, are situated around the commencement of the pulmonary artery, being formed by a folding of its lining membrane, strengthened by a thin layer of fibrous tissue. They are attached by their convex borders, and free by the concave, which are directed upwards in the course of the vessel, so that, during the current of the blood along the artery, they are pressed against the sides of the cylinder; but if regurgitation ensue, they are immediately expanded, and effectually close the entrance of the tube. The margins of the valves are thicker than the rest of their extent, and each valve presents in the centre of this margin a small fibrous thickening, called **corpus Arantii**, which locks in with the other two during the closure of the valves, and secures the triangular space which would otherwise be left by the approximation of three semilunar folds. On each side of the nodule, the edge of the valve is folded and thin, and to this part the term *lunula* has been applied. When the valves are closed, the lunulæ are brought in contact with each other by their surfaces.

Between the semilunar valves and the cylinder of the artery are three pouches called the **pulmonary sinuses** (sinuses of Valsalva). Similar sinuses are situated behind the valves at the commencement of the aorta, and are larger and more capacious than those of the pulmonary artery.

The **pulmonary artery** commences by a scalloped border, corresponding with the three valves which are attached along its edge. It is connected to the ventricle by muscular fibres, and by the lining membrane of the heart.

The **LEFT or POSTERIOR AURICLE** is thicker than the right, and situated more posteriorly. The *auricular appendix* is constricted at its junction with the auricle, and has a foliated appearance; it is directed forwards towards the root of the pulmonary artery, to which the auriculæ of both sides appear to converge.

Dissection.—The left auricle is to be laid open by one incision, running vertically downwards in front of the pulmonary veins, and a second at right angles to this, into the auricular appendix. It presents for examination five openings, and the muscular structure of the appendix: the fossa ovalis, as previously observed, is not to

be seen on the left side of the septum auricularum. The parts to be examined are—

Four pulmonary veins,
Auriculo-ventricular opening,
Musculi pectinati.

The **pulmonary veins**, two from the right and two from the left lung, open into the back part of the auricle. The two left pulmonary veins terminate frequently by a common opening.

The **auriculo-ventricular opening** is the aperture of communication between the auricle and ventricle; it is oval in shape and is a little smaller than the corresponding opening on the right side.

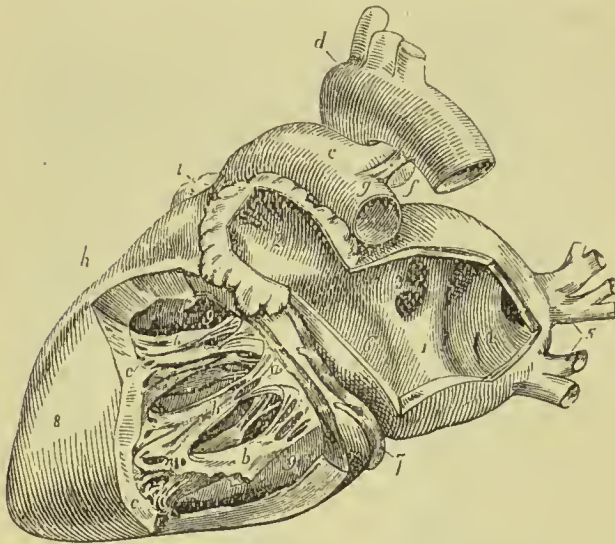


FIG. 387.—Anatomy of the heart: left side. 1. Cavity of left auricle. The figure is placed on that portion of the septum auricularum corresponding with the centre of the fossa ovalis. 2. Cavity of the auricular appendix, near the apex of which are seen musculi pectinati. 3. Opening of the two right pulmonary veins. 4. The sinus, into which the left pulmonary veins open. 5. Left pulmonary veins. 6. Auriculo-ventricular opening. 7. Coronary vein, lying in the auriculo-ventricular groove. 8. Left ventricle. 9, 9. Cavity of the left ventricle; the figures rest on the septum. *a*. Mitral valve; its flaps are

connected by chordæ tendineæ to *b, b*, Columnæ carneæ. *c, c*. Fixed columnæ carneæ, forming part of the internal surface of the ventricle. *d*. Arch of the aorta, from the summit of which the three arterial trunks of the head and upper extremities are seen arising. *e*. Pulmonary artery. *f*. Obliterated ductus arteriosus; the letter is placed in the cleft formed by the bifurcation of the pulmonary artery. *g*. Left pulmonary artery. *h*. Right ventricle. *i*. Point of the appendix of right auricle.

The **musculi pectinati** are fewer in number than in the right auricle, and are situated only in the appendix auriculæ.

LEFT VENTRICLE.—The left ventricle is to be opened in the same manner as the right by transfixing its anterior wall close to the septum, and cutting downwards to the apex.

The left ventricle is conical in external figure; it forms the apex of the heart, by projecting beyond the right ventricle, while the latter has the advantage in length towards the base. Its walls are about seven lines in thickness, those of the right ventricle being about two lines and a half. In cross section its cavity is oval in shape, from the septum bulging towards the right side.

It presents for examination, in its interior, two openings, two

valves, and the tendinous cords and muscular columns; they may be thus arranged:—

Aniculo-ventricular opening,	Mitral valve,
Aortic opening,	Semilunar valves.
Chordæ tendineæ,	
Columnæ carneæ.	

The **auriculo-ventricular opening** is a dense fibrous ring covered by the endocardium, but smaller in size than that of the right side. Its fibrous structure is closely connected with that of the right auriculo-ventricular and aortic rings; at the junction of the three there is a fibro-cartilaginous mass, and in some animals (as the ox) a partial ring of bone called *os cordis*.

The **mitral valve** is attached around the auriculo-ventricular opening, as is the tricuspid in the right ventricle. It is thicker than the tricuspid, and consists of two segments, of which the *anterior* is the largest and is placed between the auriculo-ventricular opening and the commencement of the aorta. The *posterior* is placed behind and to the left of the auriculo-ventricular opening. The difference in size of the two valves, both being triangular, and the space between them, has given rise to the idea of a bishop's mitre, after which they are named. Two small secondary flaps are placed between the two larger ones. These valves, like the tricuspid, are furnished with an apparatus of tendinous chords, *chordæ tendineæ*, which are attached to two very large muscoli papillares.

The **columnæ carneæ** are smaller than those of the right ventricle, but are more numerous and more closely reticulated; they admit of the same arrangement into three kinds as on the right side. Those which are free

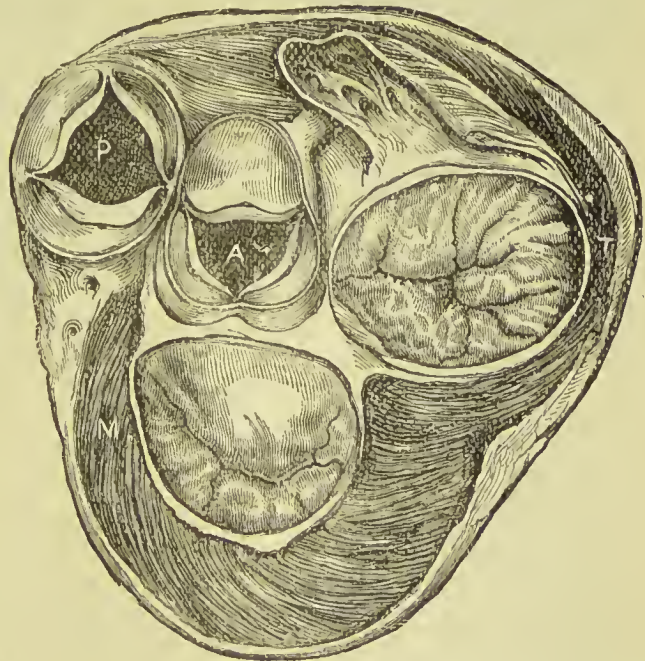


FIG. 388.—Section of heart at level of valves, as seen from above. Tricuspid and mitral valves closed; aortic and pulmonary partly open. P. Pulmonary artery. A. Aorta. M. Mitral valve. T. Tricuspid valve.

by one extremity, the muscoli papillares, are two in number; and larger than those on the opposite side, one being placed on the left

wall of the ventricle, the other at the junction of the septum ventriculorum with the posterior wall.

The **semilunar valves** are placed around the commencement of the aorta, like those of the pulmonary artery; they are similar in structure, and are attached to the scalloped border by which the aorta is connected with the ventricle. The nodule in the centre of each fold is larger than those of the pulmonary valves, and it was these that Aranzi particularly described; but the term **corpora Arantii** is now applied indiscriminately to both. The fossæ between the semilunar valves and the cylinder of the artery are larger than those of the pulmonary artery, and are called the **sinus aortici** (sinuses of Valsalva).

The part of the ventricle which leads upwards to the aorta is sometimes described as the **aortic vestibule** or **conus arteriosus**; its surface is smooth from the absence of *columnæ carneæ*, and from its walls containing a large amount of fibrous tissue it does not collapse when the heart empties.

The **interventricular septum** is of about the same thickness as the wall of the left ventricle; it is thickest below and gradually thins as it ascends. At its upper and anterior part there is a small area where the muscular fibres are entirely absent, and the septal wall consists only of fibrous tissue between two layers of endocardium; this is called the *undefended space* or *membranous part of the septum*. It is situated between the aortic and left auriculo-ventricular openings.

Position of the Heart in Relation to the Chest Wall.

Two-thirds of the heart lie to the left of the middle line, only the right auricle lying to the right of it; its extreme limit to the right is about one inch from the border of the sternum, and to the left two and a half inches from the edge of that bone. The upper margin of the auricles corresponds to a line drawn from the second right to the first left intercostal space. The *right auricle* lies behind the lower part of the sternum, its outer edge being situated at about an inch to the outer side of the right border of the bone. The *left auricle* lies on the left of the sternum, in a line running from the second left intercostal space to the upper border of the fourth left cartilage. The *right ventricle* extends from the third to the sixth cartilage of the left side near the sternum, the part nearest the surface being the *conus arteriosus*. The *left border*, formed by the left ventricle, may be defined by a line curved to the left, and extending from the edge of the sternum in the third left intercostal space, to the fifth space at about three and a half inches from the middle line. The *apex* of the heart, also formed by the left ventricle, is situated behind the fifth intercostal space, about two inches below the nipple, and half an inch to its inner side. The *right auriculo-ventricular opening* (tricuspid valve) corresponds to the middle of the sternum, on a line with the fourth costal cartilages. The *left auriculo-ventricular opening* (mitral valve) lies behind the third intercostal space of the

left side at about an inch from the sternum. The *pulmonary opening* (pulmonary semilunar valves) is placed to the left of the sternum, on a level with the articulation of the third cartilage. The *aortic opening* (aortic semilunar valves) is placed lower than the pulmonary, and corresponds to the upper edge of the third intercostal space close to the sternum. The valves are so situated that the mouth of a stethoscope placed over the inner end of the third intercostal space of the left

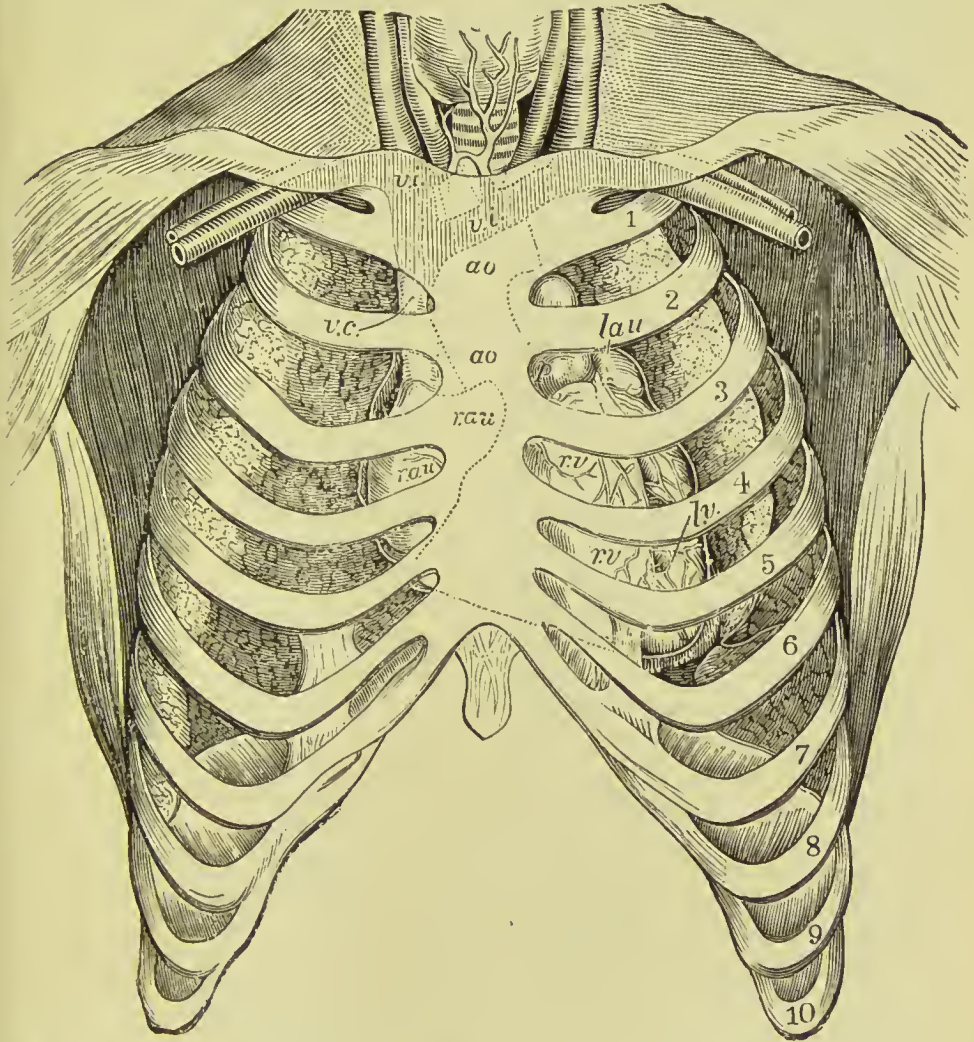


FIG. 389.—Position of the heart in relation to the chest wall. *v. i.* Innominate veins. *a. o.* Aorta. *v. c.* Vena cava superior. *r. au.* Right auricle. *l. au.* Left auricle. *r. v.* Right ventricle. *l. v.* Left ventricle.

side will cover a portion of them all (Holden). A needle introduced into the second right intercostal space close to the sternum, will pierce first the pleura and lung, then the pericardium, and next the ascending aorta; introduced into the third, fourth, or fifth space of the right side, it will, after piercing the pleura and lung, enter the right auricle of the heart.

STRUCTURE OF THE HEART.

The heart is covered externally by a delicate serous membrane, the *pericardium*, and is lined within by another serous membrane, the *endocardium*; its walls consist for the most part of muscular fibres, forming the *myocardium*, with a considerable amount of fat, especially in the grooves on the surface, and beneath the pericardium. The large openings are surrounded by rings of fibrous tissue, and these are intimately connected with a fibro-cartilaginous mass situated in the angle between the aortic and two auriculo-ventricular openings.

Muscular Structure.

The muscular fibres of the heart have been already described in the section on Histology (p. 31); but their arrangement in the auricular and ventricular walls has still to be studied.

Ventricles.—The fibres of the ventricles have a very intricate arrangement. They may be divided into seven layers, the fibres of which differ in direction. The fibres of the first layer run spirally downwards from left to right, but nearly vertically; those of the second layer take the same general direction, but are more inclined to the horizontal; those of the third layer are still more transverse, and the fourth layer is quite transverse. Passing the fourth layer, which occupies a central position in the ventricular walls and forms the boundary between the external and internal layers, the order of arrangement is reversed and the fibres of the remaining layers, viz., five, six, and seven, gradually return in an opposite direction and in an inverse order to the same relation to the vertical as that maintained by the first external layer. The fibres composing corresponding external and internal layers, such as layers one and seven, two and six, &c., are continuous in the left ventricle at the apex, and in the right ventricle in the track for the anterior coronary artery, the fibres of both ventricles being for the most part continuous likewise at the base. The fibres of the right and left ventricles anteriorly and septally are to a certain extent independent of each other; whereas posteriorly many of them are common to both ventricles; *i.e.*, the fibres pass from one ventricle to the other. At the apex the fibres are twisted round like a scroll or whorl, and then the external fibres enter into the interior of the ventricle, and some of them are continuous with those of the *musculi papillares*, others with the innermost layer of spiral fibres. The fibres from the back and front of the ventricle enter the apex in two different bundles, so that the whorl is composed of a double set of fibres twisted round each other something like the fingers of the two hands when they are folded over each other and closed.

Auricles.—The muscular fibres of the auricles are disposed in three sets—transverse, spiral, and circular. The transverse are most external; they extend over both cavities and enter the septum. The spiral are attached at each extremity to the auriculo-ventricular

rings ; they are looped and irregular in their arrangement, and are common to both auricles. The circular begin at the apex of the appendix and are continued on to the body of the auricle ; they have on their interior a number of fibres which are arranged longitudinally. The circular fibres belonging to each auricle are distinct from those of its fellow. Other fibres surround the entrance of the venæ cavæ and pulmonary veins and are continued for some distance along these vessels.

Minute Structure.

The **cardiac pericardium** (*epicardium*), is a thin layer, composed of sub-serous areolar tissue formed by a network of fine elastic fibres, adherent by the deep surface to the muscular structure of the heart ; this supports on its free surface a single layer of polygonal endothelial cells, in the midst of which stomata are found, communicating with the sub-pericardial lymphatics. Beneath the pericardium, especially in the grooves of the heart, is more or less adipose tissue, which is sometimes distributed more extensively over the surface of the organ.

The **endocardium**, or lining membrane of the heart, is also thin, but thicker in the auricles than in the ventricles, and especially in the left auricle. It consists of three layers—namely, (1) a thin stratum of white fibrous areolar tissue, which connects it to the muscular structure ; (2) a middle layer, composed of elastic tissue, which is so abundant in the auricles as to constitute a fenestrated membrane ; and (3) a layer of polygonal endothelial cells. Muscular fibres similar to those of the wall of the heart are also found in certain parts. In the ventricles the endocardium is transparent ; in the auricles, particularly the left, it is opaque and white ; it is continuous with the lining membrane of the vessels which open into the heart.

Beneath the endocardium of the ventricles in some animals, as the horse and sheep, peculiar beaded, reticulating fibres are found, and have been named the *fibres of Purkinje*. They are formed of large clear nucleated cells joined end to end, surrounded by granular material ; the outer part of the cells shows evidences of transverse striation. They are believed to represent a stage in the development of the heart muscle, and are not present in the adult human heart.

The **auriculo-ventricular valves** are composed of two layers of endocardium, connected in the body of the valve by areolo-fibrous tissue, mingled with a network of elastic fibres ; towards the edges of the valve, the two layers become blended with each other, and form a single membrane. Occasionally the muscular fibres of the heart wall are continued into these valves. The *chordæ tendineæ*

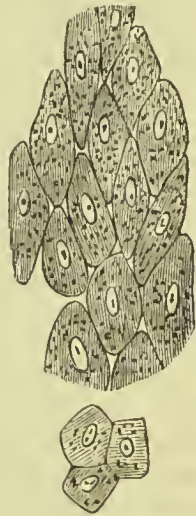


FIG. 390.—Endothelium of the endocardium.

consist of a fasciculus of tendinous fibres invested by a thin layer of endocardium. The **semilunar valves** are composed of a thin stratum of elastic and areolar tissue, the elastic tissue forming a fine network in the substance of the latter, and the free surface being invested by a single or double layer of endothelium.

Vessels and Nerves.—The *arteries* of the heart are derived from the left and right coronary; the *capillaries* form a fine network around the muscular fasciculi as in other muscles; the *veins* accompany the arteries, and empty themselves by the common coronary vein into the right auricle; the Thebesian and right cardiac veins discharging their blood directly into the auricle. The valves of the heart are non-vascular, with the exception of the auriculo-ventricular valves when they contain muscular fibre. *Lymphatic vessels* are scanty in the bag of the pericardium, but numerous beneath the visceral layer; they follow the grooves of the heart, and terminate in the glands situated beneath the arch of the aorta, and upon the bifurcation of the trachea.

The *nerves* of the heart are numerous, and derived from the cardiac plexuses, which are formed by filaments from the sympathetic and pneumogastric nerve, and reach the substance of the organ by means of the anterior and posterior coronary plexus. The nervous filaments partly accompany the vessels, partly cross their course, anastomose with each other at acute angles, and pierce the surface of the heart to reach its substance and the endocardium. The nerves are grey, being composed of fine pale fibres, a few only of the larger nerves containing in addition an admixture of medullated fibres. Where the nerve filaments intersect each other there are minute ganglionic enlargements, which receive the name of *ganglia of Remak*.

Size and Weight of the Heart.—Roughly stated, the heart is about equal in size to the closed fist of the individual; it measures about five inches in length, three and a half in greatest width, and two and a half in greatest thickness. The average weight of the heart in the male is eleven ounces, and in the female about nine ounces.

Fœtal Heart and Fœtal Circulation.

Fœtal Heart.—At the time of birth the heart is large in proportion to the size of the body; the walls of the two ventricles are of nearly equal thickness, and are relatively thicker than in adult life; the right and left auricles communicate by an oval opening, **foramen ovale** (Foramen of Botal). Both ventricles pour their blood into the aorta, this being accomplished in the case of the right ventricle by means of a trunk connecting the pulmonary artery with the junction of the transverse and descending parts of the arch. **ductus arteriosus**; the Eustachian valve is large, and serves to prevent the blood from the inferior cava passing into the auriculo-ventricular opening, directing it into the foramen ovale.

Fœtal Circulation.—The pure blood is brought from the placenta

by the **umbilical vein**. The umbilical vein passes through the umbilicus and enters the liver, where it divides into several branches ; two or three of these branches are distributed to the left lobe, one branch communicates with the portal vein in the transverse fissure and supplies the right lobe, and a large branch, the **ductus venosus**, passes directly backwards and joins the inferior vena cava. In the inferior vena cava the pure blood becomes mixed with that which is returning from the lower extremities and abdominal viscera, and is carried through the right auricle (guided by the Eustachian valve) and through the **foramen ovale** into the left auricle. From the left auricle it passes into the left ventricle, and from the left ventricle into the aorta, whence it is distributed by means of the carotid and subclavian arteries, principally to the head and upper extremities. From the head and upper extremities the impure blood is returned by the superior vena cava to the right auricle ; from the right auricle it is propelled into the right ventricle, and from the right ventricle into the pulmonary artery. In the adult, the blood would now be circulated through the lungs and oxygenated, but in the fœtus the lungs are solid and almost impervious. Only a small quantity of blood passes therefore into the lungs, the greater part courses through the **ductus arteriosus** into the commencement of the descending aorta, where it becomes mingled with a very small portion of the pure blood derived from the left ventricle.

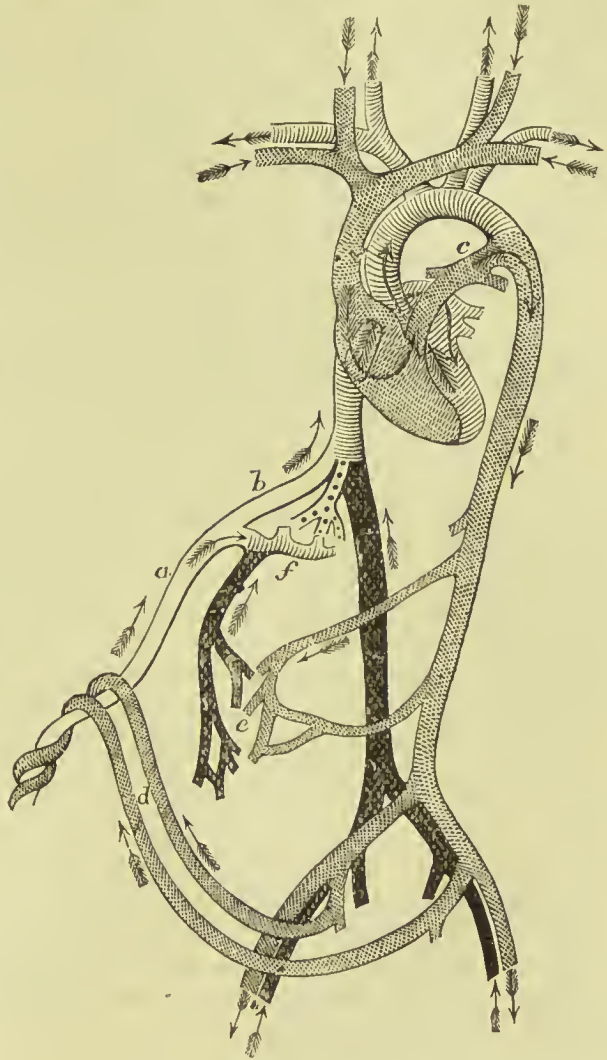

FIG. 391.—Fœtal circulation. *a.* Umbilical vein. *b.* Ductus venosus. *c.* Ductus arteriosus. *d.* Hypogastric arteries. *e.* Termination of visceral arteries and commencement of portal system. *f.* Portal vein. The arrows show the course of the blood current.

Passing along the aorta, a small quantity of this mixed blood is distributed by the external iliac arteries to the lower extremities ; the greater portion is conveyed by the hypogastric branches of the internal iliac arteries to the placenta ; the hypogastric arteries pass forwards by the side of the fundus of the bladder, and upwards along the anterior wall of the abdomen to the umbilicus, where they become the umbilical arteries.

From a careful consideration of this circulation, we perceive—1st. That the pure blood from the placenta is distributed in considerable quantity to the liver, before entering the general circulation. Hence arises the abundant nutrition of that organ, and its enormous size in comparison with other viscera.

2dly. That the right auricle is the scene of meeting of a double current ; the one coming from the inferior cava, the other from the superior, and that they must cross each other in their respective courses. The inferior cava opens almost directly into the left auricle ; and, by the aid of the Eustachian valve, the current in the cava is almost entirely excluded from the right auricle.

3dly. That the blood which circulates through the arch of the aorta comes directly from the placenta ; and although mixed with the impure blood of the inferior cava, yet is propelled in such abundance to the head and upper extremities, as to provide for the increased nutrition of those parts, and prepare them, by their greater size and development, for the functions which they are required to perform at the instant of birth.

4thly. That the blood circulating in the descending aorta is very impure, being obtained principally from the returning current in the superior cava ; a small quantity only being derived from the left ventricle. Yet it is from this impure blood that the nutrition of the lower extremities is provided ; hence we are not surprised at their insignificant development at birth.

5thly. That there are three places where a certain admixture of impure with purer blood occurs, viz., (1) at the junction of the ductus venosus and inferior cava, (2) in the right auricle, and (3) at the junction of the ductus arteriosus and aorta ; the first of these is the only important mixture.

After birth, the *foramen ovale* becomes gradually closed by a membranous layer, which is developed from the margin of the opening on the left side and from below upwards, and completely separates the two auricles. The situation of the foramen is seen in the adult heart, on the septum auricularum, and is called the *fossa ovalis* ; the prominent margin of this opening is the *annulus ovalis*.

As soon as the lungs have become inflated by the first act of inspiration, the blood of the pulmonary artery courses through its right and left branches into the lungs, to be returned to the left auricle by the pulmonary veins. Thus the pulmonary circulation is established. Then the *ductus arteriosus* contracts and degenerates into an impervious fibrous cord, serving in after-life simply as a

bond of union between the left pulmonary artery and the concavity of the arch of the aorta.

The current through the umbilical cord being arrested, the *hypogastric arteries* likewise contract and become impervious. The *umbilical vein* and *ductus venosus*, also deprived of their circulating current, become reduced to fibrous cords, the former being the *round ligament* of the liver, and the latter a fibrous band which may be traced along the fissure of the ductus venosus to the inferior vena cava.

ORGANS OF RESPIRATION AND VOICE.

The organs of respiration are the two lungs, with their air-tube, the trachea, to the upper part of which is adapted an apparatus of cartilages, constituting the organ of voice, or larynx.

THE LARYNX.

The larynx is situated at the fore-part of the neck, between the trachea and base of the tongue. It is a short tube, of an hour-glass form, and is composed of *cartilages, ligaments, muscles, vessels, nerves,* and *mucous membrane.*

The **cartilages** are nine in number, three of which are single and placed in the middle line; the other six are arranged in three pairs placed symmetrically on each side. They are the—

Thyroid,	Two cornicula laryngis,
Cricoid,	Two cuneiform,
Two arytenoid,	Epiglottis.

The **thyroid** (*θυρεὸς εἶδος*, like a shield) is the largest cartilage of the larynx: it consists of two lateral portions, or **alæ**, which meet at an angle in front, and form the projection which is known by the name of **pomum Adami**. In the male, after puberty, the angle of union of the two alæ is acute; in the female, and before puberty in the male, it is obtuse. When the pomum Adami is prominent, a bursa mucosa is often found between it and the skin.

Each ala is quadrilateral in shape, and forms a rounded border posteriorly, which terminates above, in the **superior cornu**, and below, in the **inferior cornu**; the former pass upwards and slightly backwards, and are connected by means of the thyro-hyoid ligaments with the extremities of the greater cornua of the os hyoides; the latter curve downwards and inwards, and terminate by a smooth facet, by means of which they articulate with the lateral aspect of the cricoid cartilage. On the side of the ala is an **oblique line**, or **ridge**, directed downwards and forwards, and bounded at each extremity by a tubercle. Into this line the sterno-thyroid muscle is inserted, and from it the thyro-hyoid takes origin; the triangular area behind it gives attachment to the inferior constrictor of the

pharynx. In the *receding angle*, formed by the meeting of the two alæ, on the inner side of the cartilage, and near its lower border,

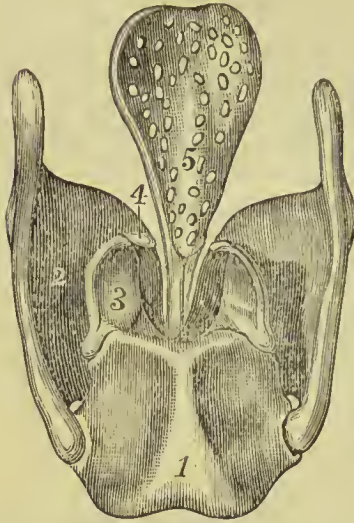


FIG. 392.—Cartilages of the larynx. 1. Cricoid. 2. Thyroid. 3. Arytenoid cartilage. 4. Corniculum laryngis. 5. Epiglottis.

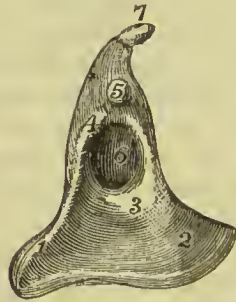
are attached the epiglottis, vocal cords, thyro-arytenoid and thyro-epiglottidean muscles. By its upper border the thyroid cartilage is connected with the hyoid bone by means of the thyro-hyoid membrane, its lower border being in like manner connected with the cricoid cartilage by the crico-thyroid membrane. The posterior border of each ala has attached to it the thyro-hyoid and palato-pharyngeus muscles.

The **cricoid** (*κρίκος εἶδος*, like a ring) is a ring of cartilage, narrow in front, and broad behind, where it is surmounted by *two rounded surfaces*, which articulate with the arytenoid cartilages. At the middle line, posteriorly, is a *vertical ridge* giving attachment to the œsophagus, and at each side of the ridge are the depressions which lodge the crico-arytenoidei postici muscles.

On either side of the ring is a *glenoid cavity*, which articulates with the inferior cornu of the thyroid cartilage. Its upper border gives attachment to the lateral crico-arytenoideus muscle and the crico-thyroid membrane, and its lower border is connected with the upper ring of the trachea by fibrous membrane.

The **arytenoid cartilages** (*ἀρταινα*,* a pitcher), two in number, are triangular and prismatic in form. They are broad and thick

FIG. 393.—Right arytenoid, viewed from the outer side (twice the normal size). 1. Muscular angle. 2. Vocal angle. 3. Transverse ridge. 4. Upper ridge, bordering fossa. 5. Tubercle. 6. Fossa. 7. Corniculum laryngis.



below where they articulate with the upper border of the cricoid cartilage; pointed above, and prolonged by two small pyriform fibro-cartilages, **cornicula laryngis** (*capitula Santorini*), which are curved inwards and backwards, and they each present three surfaces, posterior, internal, and anterior.

The *posterior surface* is concave, and lodges part of the arytenoideus muscle; the *internal surface* is smooth, and forms part of the lateral wall of the glottis; the *anterior or external surface* is rough and uneven, and gives attachment to the vocal cord, thyro-arytenoideus, crico-arytenoideus lateralis

* This derivation has reference to the appearance of both cartilages taken together and covered by mucous membrane. In animals, which were the principal subjects of dissection among the ancients, the opening of the larynx, with the arytenoid cartilages, bears a curious resemblance to the mouth of a pitcher with a large spout.

and posticus. The *outer angle* is a stout prominent process, which gives attachment to the crico-arytenoideus posticus and crico-arytenoideus lateralis muscles, and hence has been named the *processus muscularis*; the *anterior angle* is a sharp and pointed process directed forwards; it gives attachment to the inferior thyro-arytenoid ligament or true vocal cord, and has been named the *processus vocalis*.

The **cuneiform cartilages** (cartilages of Wrisberg) are two small cylinders of yellow fibro-cartilage, about seven lines in length, and enlarged at each extremity. They lie in the aryteno-epiglottidean folds of mucous membrane.

In the male, the cartilages of the larynx are more or less ossified, particularly in old age.

The **epiglottis** (*ἐπιγλωττίς*, upon the tongue) is a fibro-cartilage of a yellowish colour, studded with a number of small mucous glands, lodged in shallow pits on its surface. It is shaped like an obcordate leaf, and placed immediately in front of the opening of the larynx, which it partly closes when the larynx is drawn up beneath the base of the tongue. It is attached by its point to the *receding angle* of the thyroid cartilage by means of fibrous tissue forming the *thyro-epiglottic ligament*, and to the inner surface of the body of the hyoid bone by the *hyo-epiglottic ligament*; with the base of the tongue it is connected by folds of mucous membrane forming the *frenula*, or *glosso-epiglottidean* folds, and with the summit of the arytenoid cartilages by the *aryteno-epiglottidean folds*. Its laryngeal surface is concavo-convex from above downwards, and concave from side to side; the convex portion projects into the anterior part of the upper opening of the larynx, and forms the **cushion of the epiglottis**.

Ligaments.—The *ligaments* of the larynx are numerous, and may be arranged into four groups: 1. Those which articulate the thyroid with the os hyoides. 2. Those which connect it with the cricoid. 3. Ligaments of the arytenoid cartilages. 4. Ligaments of the epiglottis.

1. The ligaments which connect the thyroid cartilage with the os hyoides are three in number.

Two **thyro-hyoid ligaments** pass between the superior cornua of the thyroid and the extremities of the greater cornua of the os hyoides; they are composed of yellow fibrous tissue, and often contain a sesamoid bone or cartilage (*cartilago triticea*).

The **thyro-hyoid membrane** is a broad membranous layer, occupying the entire space between the upper border of the thyroid cartilage and the upper and inner border of the os hyoides. It is pierced by the superior laryngeal nerve and artery.

2. The ligaments connecting the thyroid to the cricoid cartilage are also three in number:—

Two **capsular ligaments**, with their synovial membranes, which form the articulation between the inferior cornua of the thyroid and the sides of the cricoid; and the crico-thyroid membrane.

The **crico-thyroid membrane** is a fan-shaped layer of yellow

elastic tissue, thick in front (middle crico-thyroid ligament) and thinner at each side (lateral crico-thyroid ligament). It is attached by its apex to the lower border and receding angle of the thyroid cartilage, and by its expanded margin to the upper border of the cricoid and base of the arytenoid cartilages. Superiorly it is continuous with the inferior margin of the vocal cords. The front of the crico-thyroid membrane is crossed by a small artery, the inferior laryngeal, and is the spot selected for the operation of laryngotomy. Laterally it is covered in by the crico-thyroid and lateral crico-arytenoid muscles.

3. The ligaments of the arytenoid cartilages are eight in number:—

Two **capsular ligaments**, with synovial membranes, which articulate the arytenoid cartilages with the cricoid, strengthened behind

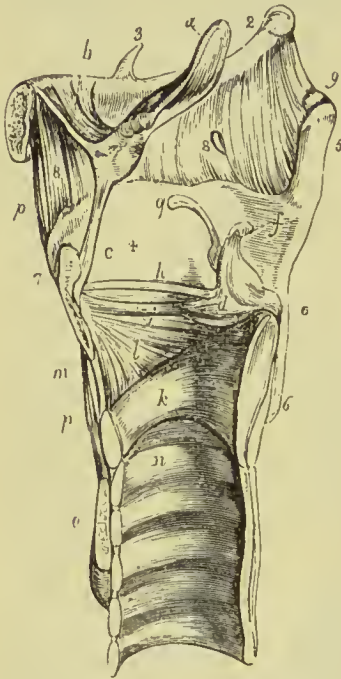


FIG. 394.—Vertical section of the larynx, showing its ligaments. 1. Body of os hyoides. 2. Its great cornu. 3. Lesser cornu. 4. Ala of the thyroid cartilage. 5. Superior cornu. 6. Inferior cornu. 7. Pomum Adami. 8, 8. Thyro-hyoid membrane; the opening in the membrane immediately above the posterior figure is for the passage of the superior laryngeal nerve and artery. 9. Thyro-hyoid ligament; the figure is placed immediately above the sesamoid cartilage. *a*. Epiglottis. *b*. Hyo-epiglottic ligament. *c*. Thyro-epiglottic ligament. *d*. Arytenoid cartilage; inner surface. *e*. Outer angle of base of arytenoid cartilage. *f*. Corniculum laryngis. *g*. Cuneiform cartilage. *h*. Superior thyro-arytenoid ligament. *i*. Inferior thyro-arytenoid ligament, or true vocal cord; the elliptical space between the two thyro-arytenoid ligaments is the ventricle of the larynx. *k*. Cricoid cartilage. *l*. Lateral portion of the crico-thyroid membrane. *m*. Central portion of the same membrane. *n*. Upper ring of trachea. *o*. Section of isthmus of thyroid body. *p, p*. Levator glandulæ thyroideæ.

by two **posterior crico-arytenoid bands** or ligaments; and the superior and inferior thyro-arytenoid ligaments.

The **superior thyro-arytenoid ligaments** are two scattered bands of fibres attached in front to the receding angle of the thyroid cartilage, and behind to a tubercle on the anterior surface of each arytenoid cartilage, and contained in the folds of mucous membrane constituting the false vocal cords. The lower border of this ligament forms the upper boundary of the ventricle of the larynx.

The **inferior thyro-arytenoid ligaments**, or true **vocal cords**, are thicker than the superior, and are composed of yellow elastic tissue. Each ligament is attached in front to the receding angle of the thyroid cartilage, and behind to the anterior angle of the base of

the arytenoid. The inferior border of the vocal cord is continuous with the lateral expansion of the crico-thyroid ligament. The superior border forms the lower boundary of the ventricle of the larynx. The space between the two true vocal cords is the **glottis** or **rima glottidis**.

4. The ligaments of the epiglottis are five in number—namely, three glosso-epiglottic, hyo-epiglottic, and thyro-epiglottic.

The **glosso-epiglottic** ligaments are three folds of mucous membrane, which connect the anterior surface of the epiglottis with the root of the tongue. The **hyo-epiglottic** ligament is a band of yellow elastic tissue passing between the anterior aspect of the epiglottis near its apex, and the upper margin of the body of the os hyoides. The **thyro-epiglottic** ligament is a long and slender fasciculus of yellow elastic tissue, which embraces the apex of the epiglottis, and is inserted into the receding angle of the thyroid cartilage immediately below the anterior fissure and above the attachment of the vocal cords.

Muscles.—The intrinsic muscles of the larynx are nine in number; five of which are the muscles of the vocal cords and rima glottidis, and four are muscles of the epiglottis.

The five muscles of the vocal cords and rima glottidis are—

Crico-thyroid,	Thyro-arytenoideus,
Crico-arytenoideus posticus,	Arytenoideus.
Crico-arytenoideus lateralis,	

The **crico-thyroid** muscle *arises* from the anterior surface of the cricoid cartilage, and passes obliquely outwards and backwards to be *inserted* into the lower and inner border of the ala of the thyroid from its tubercle as far back as the inferior cornu. Some of its fibres are continuous with those of the inferior constrictor of the pharynx, and others with those of the crico-arytenoideus lateralis.

The **crico-arytenoideus posticus** *arises* from the depression on the posterior surface of the cricoid cartilage, and passes upwards and outwards to be *inserted* into the muscular angle of the arytenoid. Its upper fibres are continuous with the lower fibres of the arytenoideus.

The **crico-arytenoideus lateralis** *arises* from the upper border of the side of the cricoid, and passes upwards and backwards to be *inserted* into the muscular angle of the base of the arytenoid cartilage.

The **thyro-arytenoideus** is situated above the preceding muscle; it *arises* from the receding angle of the thyroid cartilage, close to the outer side of the true vocal cord, and passes backwards parallel with the cord, to be *inserted* into the base and outer and anterior surfaces of the arytenoid cartilage. Some observers describe the fibres of this muscle as being attached to the true vocal cord, spreading along its outer border; this, however, is much disputed, and must be regarded at present as not definitely proved.

The **arytenoideus** muscle occupies the posterior concave surface of the arytenoid cartilages, between which it is stretched. It

consists of deep fibres arranged transversely, and passing between the arytenoid cartilages, and of two oblique bands crossing each other and continuous by their outer ends with the thyro-arytenoideus. The uppermost fibres run to the cartilages of Santorini, and the lower ones blend with those of the thyro-arytenoideus, and crico-arytenoideus lateralis (Kanthack).

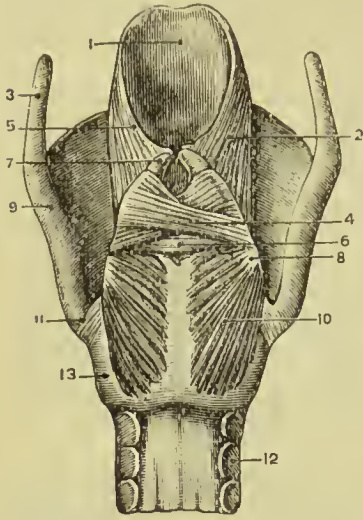


FIG. 395.—Posterior view of the larynx. 1. Epiglottis. 2. Aryteno-epiglottideus. 3. Superior cornu of thyroid. 4. Oblique fibres of arytenoideus. 5. Aryteno-epiglottidean fold. 6. Deep fibres of arytenoideus. 7. Corniculum laryngis. 8. Muscular angle of arytenoid. 9. Thyroid cartilage. 10. Crico-arytenoideus posticus. 11. Articulation of cricoid with thyroid. 12. Trachea. 13. Cricoid cartilage.

The four muscles of the epiglottis are—

Thyro-epiglottideus,
Aryteno-epiglottideus superior,
Aryteno-epiglottideus inferior,
Hyo-epiglottideus.

The **thyro-epiglottideus** appears to be formed by the upper fibres of the thyro-arytenoideus muscle; they spread out on the external surface of the sacculus laryngis, and in the aryteno-epiglottidean fold of mucous membrane, on which they are lost; a few of the anterior fibres being continued onwards to the side of the epiglottis (depressor epiglottidis).

The **aryteno-epiglottideus superior** consists of a few scattered muscular fibres, which pass forward in the fold of mucous membrane forming the lateral boundary of the entrance into the larynx, from the apex of the

arytenoid cartilage to the side of the epiglottis.

The **aryteno-epiglottideus inferior**, closely connected with the sacculus laryngis, may be seen by raising the mucous membrane immediately above the ventricle of the larynx. It *arises* by a narrow and fibrous origin from the arytenoid cartilage, just above the attachment of the vocal cord; and passing forwards and a little upwards expands over the upper half or two-thirds of the sacculus laryngis; it is *inserted* by a broad attachment into the side of the epiglottis.

The **hyo-epiglottideus** has not hitherto been described as a normal muscle of the human larynx. From the investigations, however, of Dr. John Macintyre in the dissecting-room of St. Mungo's College, it would appear that it is invariably present, although varying much in the degree of its development. It generally consists of three muscular slips lying beneath the glosso-epiglottidean folds, and passing from the hyoid bone to the front of the epiglottis.

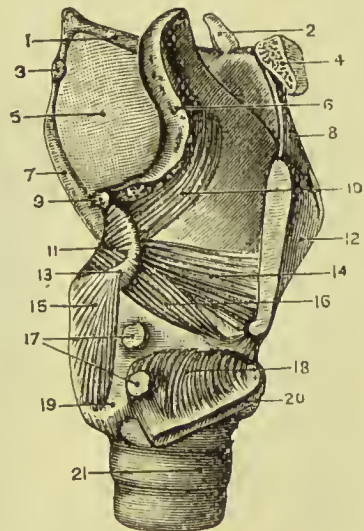
The muscles of the larynx are so intimately connected with each other, that the separation into those above named and described is

in the main, artificial. The most distinct muscle is the crico-thyroid, and next to this the crico-arytenoideus posticus; the others are so united as to form a complete sphincter muscle, **sphincter laryngis**, which encloses the cavity of the glottis, and spreads out over the vocal cords and arytenoid cartilages, some of the fibres even reaching to the cornicula laryngis.

Actions.—The crico-arytenoidei postici open the glottis while all the rest close it. The arytenoideus approximates the arytenoid cartilages posteriorly, and the crico-arytenoidei laterales and thyro-arytenoidei anteriorly; the latter, moreover, close the glottis mesially. The crico-thyroidei are tensors of the vocal cords, and these muscles, together with the thyro-arytenoidei, regulate the tension, position, and vibrating length of the vocal cords.

The crico-thyroid muscles effect the tension of the vocal cords by rotating the inferior cornua of the thyroid on the cricoid; by this

FIG. 396.—Side view of larynx, one ala of thyroid cut through and turned down. 1. Great cornu of hyoid. 2. Lesser cornu. 3. Cartilago triticea in thyro-hyoid ligament. 4. Body of hyoid. 5. Thyro-hyoid membrane. 6. Epiglottis. 7. Superior cornu of thyroid. 8. Front of thyro-hyoid membrane. 9. Corniculum laryngis. 10. Aryteno-epiglottideus. 11. Arytenoideus. 12. Thyroid. 13. Muscular angle of arytenoid. 14. Thyro-arytenoideus. 15. Crico-arytenoideus posticus. 16. Crico-arytenoideus lateralis. 17. Articulation between inferior cornu of thyroid and cricoid (laid open). 18. Crico-thyroid (turned down). 19. Cricoid. 20. Lower part of right ala of thyroid (turned down). 21. Trachea.



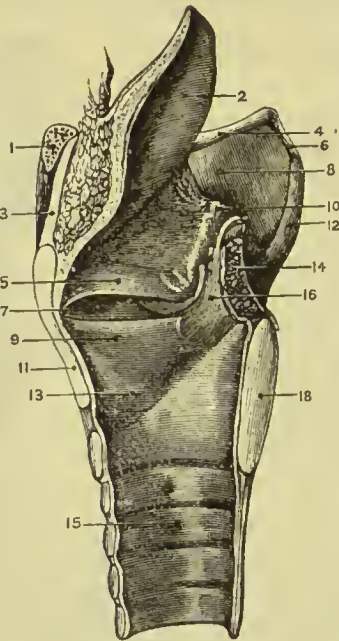
action the anterior portion of the thyroid is drawn downwards, and made to approximate the upper edge of the cricoid, thus separating it further from the arytenoid to which the vocal cords are fixed. The crico-arytenoidei postici separate the vocal cords by drawing the outer angles of the arytenoid cartilages outwards and downwards. The crico-arytenoidei laterales, by drawing the outer angles of the arytenoid cartilages forwards, approximate the anterior angles to which the vocal cords are attached. The thyro-arytenoidei draw the arytenoid cartilages forwards, and, by their connection with the vocal cords, make the whole length or any segment of the cords tense.

The thyro-epiglottideus acts principally by compressing the glands of the sacculus laryngis and the sac itself: by its attachment to the epiglottis it would act feebly upon that valve. The aryteno-epiglottideus superior serves to keep the mucous membrane of the sides of the opening of the glottis tense, when the larynx is drawn

upwards and the opening closed by the epiglottis. Of the aryteno-epiglottideus inferior, the functions appear to be, to compress the subjacent glands which open into the pouch; to diminish the capacity of that cavity, and change its form; and to approximate the epiglottis and the arytenoid cartilage.

Mucous Membrane.—The aperture of the larynx is a triangular or cordiform opening, broad in front and narrow behind; bounded anteriorly by the epiglottis, posteriorly by the arytenoidens muscle, and on either side by a fold of mucous membrane stretched between the side of the epiglottis and the apex of the arytenoid cartilage. On the margin of this **aryteno-epiglottidean** fold the cuneiform cartilage forms a prominence more or less distinct. Between these folds and the ala of the thyroid, on each side, is a large fossa lined by mucous membrane, and named the **hyoid** or **innominate fossa**; be-

FIG. 397.—Vertical section of larynx, showing its ligaments. 1. Hyoid. 2. Epiglottis. 3 and 8. Thyro-hyoid membrane. 4. Great cornu of hyoid. 5. False vocal cord. 6. Thyro-hyoid ligament. 7. Ventricle of larynx. 9. True vocal cord. 10. Aryteno-epiglottidean fold and cartilage of Wrisberg. 11. Thyroid. 12. Superior cornu. 13. Crico-thyroid membrane. 14. Arytenoideus. 15. Trachea. 16. Arytenoid cartilage. 18. Cricoid.



neath its mucous lining the superior and inferior laryngeal nerves communicate, and the branches of the superior and inferior thyroid arteries anastomose. The cavity of the larynx is divided into two parts by an oblong constriction produced by the prominence of the vocal cords. That portion of the cavity which lies above the constriction is broad and triangular above, and narrow below; that which is below it, is narrow above

and broad and cylindrical below, the circumference of the cylinder corresponding with the ring of the cricoid; while the space included by the constriction is a narrow, triangular fissure, the **glottis** or **rima glottidis**. The form of the glottis is that of an isosceles triangle, bounded on the sides by the vocal cords and inner surface of the arytenoid cartilages, and behind by the arytenoideus muscle; the part of the chink of the glottis which lies between the vocal cords is often described as the *vocalising area*, and the smaller posterior portion as the *respiratory area*. Its length is greater in the male than in the female, and in the former measures somewhat less than an inch. Immediately above the prominence caused by the vocal cord, and extending nearly its entire length on each side of the cavity of the larynx, is an elliptical fossa,

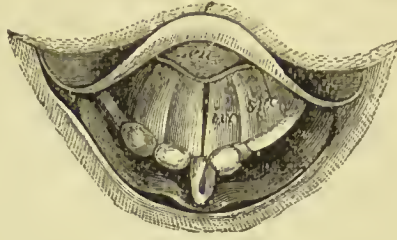
the **ventricle of the larynx**. This fossa is bounded below by the true vocal cord, which it serves to isolate, and above by a border of mucous membrane folded upon the lower edge of the superior thyro-arytenoid ligament (superior or false vocal cord). The whole of the cavity of the larynx, with its prominences and depressions, is lined by mucous membrane, continuous superiorly with that of the mouth and pharynx, and prolonged inferiorly through the trachea and bronchial tubes into the lungs. In the ventricles of the larynx the mucous membrane forms a cæcal pouch of variable size, termed the **sacculus laryngis**. The sacculus laryngis is directed upwards, sometimes extending as high as the upper border of the thyroid cartilage, and occasionally above that border. When dissected from the interior of the larynx it is found covered by the aryteno-epiglottideus muscle and a fibrous membrane, which latter is attached to the superior thyro-arytenoid ligament below; to the epiglottis in front; and to the upper border of the thyroid cartilage above. If examined from the exterior of the larynx, it will be seen to be covered by the thyro-epiglottideus muscle. On the surface of its mucous membrane are the openings of sixty or seventy small racemose glands, which are situated in the sub-mucous tissue, and give to its external surface a rough and ill-dissected appearance. The secretion from these glands is intended for the lubrication of the vocal cords, and is directed upon them by two small valvular folds of mucous membrane, which are situated at the entrance of the sacculus. The mucous membrane is closely connected to the epiglottis and to the vocal cords, on the latter being remarkable for its thinness. It is invested by a columnar ciliated epithelium as high up as the superior folds of the ventricle of the larynx and lower half of the epiglottis, but on the true vocal cords the epithelium is squamous and non-ciliated.

Glands.—The mucous membrane of the larynx is furnished with an abundance of mucous glands; many of these are situated on the epiglottis, in the sacculus laryngis, and in the aryteno-epiglottidean folds, where they are termed *arytenoid*. The body known as the epiglottic gland is merely a mass of areolar and adipose tissue, situated in the triangular space between the front surface of the apex of the epiglottis, the hyo-epiglottic ligament, and the thyrohyoid ligament.

Laryngoscopic Appearance.—When examined by means of the laryngoscope, the upper opening of the larynx presents the appearance of a space of almost semilunar form, bounded in front by the base of the tongue and behind by the wall of the pharynx. In the anterior part of this space the curved free extremity of the epiglottis (Fig. 398, *e*) is seen, and projecting into the space from before, in the middle line, the cushion of the epiglottis (*cu*). In the middle line behind is a narrow slit, which is the space between the two arytenoid cartilages, and on each side of this a rounded tubercle, the tip of each corniculum laryngis; a little externally to these, two other tubercles will be noticed, due to the presence of the cuneiform

cartilages, and running from them outwards to the edges of the epiglottis, two crescentic folds of mucous membrane, the aryteno-epiglottidean folds. In the middle of the space, four flattened

FIG. 398.—Laryngoscopic view of the glottis during the emission of a high note. *e.* Epiglottis. *cu.* Cushion of the epiglottis. *ivc.* True vocal cord. *svc.* False vocal cord.



bands will be seen, two on each side; these are the true (*ivc*) and false (*svc*) vocal cords; between the former lies the narrow chink or fissure of the glottis.

Vessels and Nerves.—The *arteries* of the larynx are derived from the superior and inferior thyroid. The *nerves* are the superior laryngeal and recurrent laryngeal; both branches of the pneumogastric. The two nerves communicate with each other, but the superior laryngeal is distributed principally to the mucous membrane at the entrance of the larynx; the recurrent to the muscles.

THE TRACHEA.

The trachea or wind-pipe is cylindrical for about two-thirds of its circumference, and flattened on the posterior third, where it rests on the œsophagus; it extends from opposite the upper border of the sixth cervical vertebra to opposite the fourth dorsal, where it divides into the two bronchi. The length of the trachea is about four inches (11 cm.), and its diameter from side to side nearly an inch (21 mm.); it is somewhat larger in the male than in the female. The **right bronchus**, larger than the left, passes off nearly at *right angles*, to the upper part of the corresponding lung. The **left** descends *obliquely*, and passes beneath the arch of the aorta, to reach the left lung.

The trachea is composed of cartilaginous rings, fibrous membrane, muscular fibres, elastic tissue, and is lined by mucous membrane.

The **cartilaginous rings** are from fifteen to twenty in number, and extend for two-thirds around its cylinder, being deficient at the posterior part. The first ring is received within the lower margin of the cricoid cartilage, and is broader than the rest; the last is broad at the middle in consequence of the prolongation of the lower border into a triangular process which curves backwards at the point of bifurcation. The posterior extremities of the rings are rounded, and occasionally one or two rings will be found to bifurcate. The outer surface of each ring is flat, the inner is convex from above downwards.

The **fibrous membrane** connects the rings and forms a thin covering to them on the outer surface. Internally it does not reach the surface, and the rings have in consequence on that aspect an appearance of greater prominence. It also stretches across between the rings on the posterior part of the trachea.

The **muscular fibres** are disposed transversely across the space,

between the extremities of the rings behind. They are placed internally to the fibrous membrane. Outside the circular fibres are a few running longitudinally; they are connected with the inner surface of the ends of the rings, and with the external fibrous membrane.

The **elastic tissue** forms the **submucous tissue**, and is disposed in longitudinal bundles within the rings, and internally to the muscular layer behind. It is most developed opposite the bifurcation of the trachea.

The **mucous membrane**, which is pale, forms the internal lining of the tube, and has opening upon its surface the excretory tubes of numerous mucous glands, the glands themselves lying external to the muscular coat; it is furnished with a ciliated columnar epithelium, continuous with that of the larynx above and the bronchial tubes below. Beneath the columnar cells and surrounding their bases is a collection of small irregular cells (*Debove's layer*), many of which become distended with mucus and form goblet cells. The mucous membrane contains a large amount of lymphoid tissue.

The **mucous glands** are small ovoid bodies situated between the fibrous membrane and the muscular layer behind, and in the substance of the fibrous membrane between the rings. Their ducts open upon the mucous membrane.

Nerves.—The nerves of the trachea are derived from the vagus and its recurrent branch; they form a fine gangliated plexus on the outside of the muscular coat, the nerve filaments becoming non-medullated.

The **bronchi** correspond very closely in structure with the trachea; the cartilaginous rings are deficient behind, as in that tube; there are usually six to eight rings in the right bronchus and ten to twelve in the left.

The right bronchus is the more horizontal of the two, but it is shorter than the left; it is larger, and is more directly continuous with the trachea, so that foreign bodies getting into the windpipe commonly pass into the right bronchus. The right gives off a branch above the pulmonary artery (*eparterial bronchus*) as well as branches below (*hyparterial*); the left gives off the latter only.

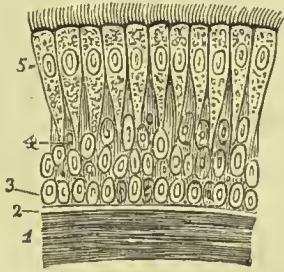


FIG. 399.—Ciliated epithelium from the trachea. 1. External layer of longitudinal elastic fibres. 2. Basement membrane. 3. Round cells. 4. Oval and oblong cells. 5. Ciliated cells.

THYROID BODY.

The thyroid body consists of two lobes, placed one on each side of the trachea, and connected with each other by means of an **isthmus**, which crosses its upper rings, usually the third and fourth; but in this respect there is some variety, a point necessary to be remembered

in operations on the trachea. The lobes are somewhat conical in shape, being larger below than above, and the smaller end is continued upwards to the side of the thyroid cartilage. The isthmus is connected with the lower third of the two lobes, and often gives origin to a process of variable length and size, called the **pyramid** or third lobe. The pyramid is generally situated on the left side of the isthmus, and is often derived from the left lobe; it is frequently connected with the hyoid bone by a muscular band, which receives the name of *levator glandulæ thyroideæ*. The left lobe is somewhat smaller than the right, the weight of the entire body being about one ounce and a half. It is, however, larger in young persons and females than in adult males, and undergoes a slight increase during menstruation. Its permanent enlargement constitutes bronchocele, goitre, or the Derbyshire neck.

Structure.—The structure of the thyroid is of a brownish-red colour, and is composed of a dense aggregation of minute and independent

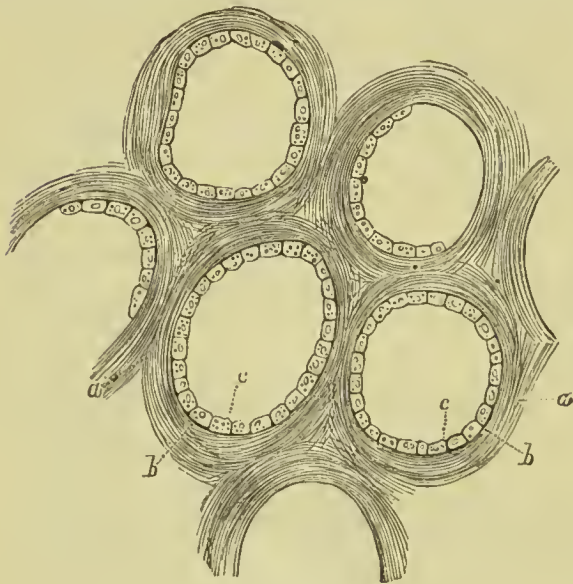


FIG. 400.—Structure of the thyroid body. *a.* Connective-tissue stroma. *b.* Basement membrane. *c.* Epithelial cells.

membranous cavities or vesicles enclosed by a plexus of capillary vessels, and connected together by areolar tissue. The vesicles are composed of a *basement membrane* lined by a *columnar epithelium* of nucleated cells, and contain a clear yellowish fluid, in which are found cells; the latter measuring $\frac{1}{1400}$ of an inch in diameter.

Vessels and Nerves.—It is abundantly supplied with blood by the superior and inferior thyroid arteries. Sometimes an additional artery is derived from the *arteria innominata*, and ascends upon the front of the trachea to be distributed to the gland. The *nerves* are derived from the superior laryngeal and from the middle and inferior cervical ganglia of the sympathetic. The *lymphatics* are very numerous, and originate for the most part in the connective tissue forming the stroma of the organ.

THE LUNGS.

The lungs are two conical organs, situated one at each side of the chest, embracing the heart, and separated from each other by that organ and by an interspace, the mediastinum. On the external or

thoracic side they are convex, and correspond with the form of the cavity of the chest; internally they are concave, to receive the convexity of the heart. Superiorly they terminate in a tapering cone, which extends above the level of the first rib into the root of the neck, and inferiorly they are broad and concave, and rest on the convex surface of the diaphragm. Their posterior border is rounded, broad, and long; the anterior, sharp, short, and marked by one or two deep fissures; and the inferior border which surrounds the base is also sharp. The colour of the lungs is pinkish-grey, mottled, and variously marked with black. The surface is figured with irregularly polyhedral outlines, which represent the lobules of the organ, and the area of each of these polyhedral spaces is crossed by lighter lines representing smaller lobules. The weight of the lungs is about forty-two ounces, the right lung being twenty-two ounces and the left twenty; the ratio to the weight of the body is as 1 to 37 in the male and 1 to 42 in the female.

Each lung is divided into two lobes by a long and deep fissure, called the **great fissure**, which extends from the posterior surface of the upper part of the organ downwards, and forwards to near the anterior angle of its base. In the right lung the upper lobe is subdivided by a second fissure, which extends obliquely forward from the middle of the preceding to the anterior border of the organ, and marks off a small triangular lobe. The left lung presents a deep notch in its anterior border, at a point corresponding with the apex of the heart.

The right lung is larger than the left, in consequence of the inclination of the heart to the left side. It is also shorter, from the great convexity of the liver, which presses the diaphragm upwards on the right side of the chest, considerably above the level of the left, and it has three lobes. The left lung is smaller, has only two lobes, but is longer than the right.

The healthy lung is free at all parts of its surface, excepting along the lower two-thirds of the middle of its inner surface, where it is fixed, above by the *root* and below by a double layer of pleura called *ligamentum latum pulmonis*. The **root** is formed by the pulmonary artery, pulmonary veins, and divisions of the bronchus, together with the bronchial vessels, lymphatic vessels and glands, and pulmonary plexuses of nerves. The groove on the surface of the lung where the vessels enter its substance is the **hilum pulmonis**, and the position of the large vessels in the root of the lung, as follows: from before, backwards, they are placed in a similar order on both sides, viz. :—

Pulmonary veins,
Pulmonary artery,
Bronchus.

From above, downwards, the relative position of these structures is essentially the same on both sides, but on the right side there is an additional bronchus (*eparterial*), which is placed above the

pulmonary artery, consequently the arrangement on the two sides is as follows :—

Right,	{	Eparterial bronchus, Artery, Hyparterial bronchus, Veins.	Left,	{	Artery, Hyparterial bronchus, Veins.
---------------	---	--	--------------	---	--

Relations of the Roots of the Lung.—1. **Both lungs.** *In front,* phrenic nerve and companion vessels, anterior pulmonary plexus. *Behind,* vagus nerve and posterior pulmonary plexus. *Below,* ligamentum latum pulmonis. 2. **Right lung alone.** *Above,* vena azygos major. *In front,* superior vena cava. 3. **Left lung alone.** *Above,* arch of aorta. *Behind,* descending aorta.

Structure of the Lungs.

The lung is of a soft spongy texture, and, from its containing air, crepitates when squeezed between the fingers. Its specific gravity varies from .345 to .746. When cut, there exudes a frothy fluid consisting of mucus and blood intimately mixed with air. In the young child the lung is of a rose-pink colour, but in the adult it is much darker from the presence of pigment; in both, the surface is mottled, from the area over the centre of each lobule being lighter than that over the periphery. The surface is marked out into small polyhedral divisions, which are the outlines of the **lobules**. The lobules have their apices directed towards the centre of the lung, and their bases towards the surface; they are largest at the surface of the lung, and smallest near its centre; they are connected with each other at their apices by the smallest bronchial tubes. Each lobule is a miniature lung, and consists of bronchial tube, pulmonary artery and vein, air cells supported by an elastic stroma, lymphatic vessels, and nerves. It is isolated from surrounding lobules by areolar tissue derived from the subserous layer; the entire lung is an assemblage of these lobules, so separated and so connected, held together by the pleura.

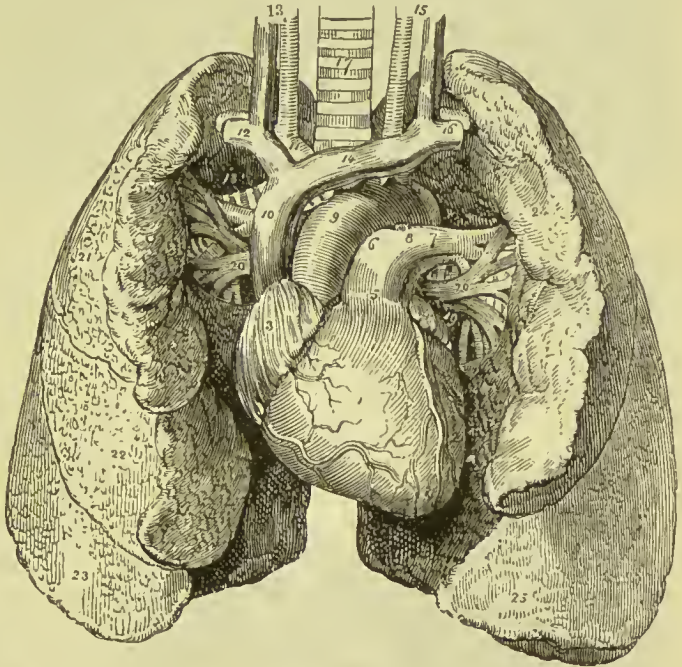
The serous investing membrane of the lungs or pleura is connected with the surface of the lobules by means of a *subserous areolar tissue*, which forms a distinct layer, and being prolonged between the lobules, serves to unite them. This layer contains elastic tissue, and is a chief source of the elasticity of the lungs; in it a close plexus of capillary vessels is found, and numerous lymphatics, which communicate with the surface of the pleura by minute stomata.

Bronchial Tubes.—The two bronchi proceed from the bifurcation of the trachea opposite the fourth dorsal vertebra to their corresponding lungs. The right, about an inch long, takes its course nearly at right angles with the trachea, passes behind the superior vena cava, and gives off a branch above the pulmonary artery (*eparterial branch*) to the upper lobe of the right lung: it then passes behind the artery

and gives off two other branches below its level (*hyperarterial branches*), which pass to the middle and lower lobes. The left, two inches in length, and smaller than the right, passes obliquely beneath the arch of the aorta, and divides into two branches, both of which are placed below the pulmonary artery (*hyperarterial branches*), and pass to the two lobes of the left lung. From this arrangement of the bronchi it seems probable that the two lower lobes of the right lung correspond to the whole of the left, and that the upper lobe of the right is entirely additional. Upon entering the lungs the bronchi divide into branches, and each of these divides and subdivides dichotomously to their ultimate termination in the intercellular passages and air-cells.

FIG. 401.—Heart and lungs.

1. Right ventricle, the vessels to the left of the figure are the right coronary artery and veins; those to its right, the left coronary artery and veins. 2. Left ventricle. 3. Right auricle. 4. Left auricle. 5. Pulmonary artery. 6. Right pulmonary artery. 7. Left pulmonary artery. 8. Ligamentum arteriosum. 9. Arch of the aorta. 10. Superior vena cava. 11. Innominate artery, and in front of it the right innominate vein. 12. Right subclavian vein, and, behind it, its corresponding artery. 13. Right common carotid artery and internal jugular vein. 14. Left innominate vein. 15. Left carotid artery and jugular vein. 16. Left subclavian vein and artery. 17. Trachea. 18. Right bronchus. 19. Left bronchus. 20, 20. Pulmonary veins; 18, 20, form the root of the right lung; and 7, 19, 20, the root of the left. 21. Superior lobe of the right lung. 22. Middle lobe. 23. Inferior lobe. 24. Superior lobe of the left lung. 25. Inferior lobe.



tomously to their ultimate termination in the intercellular passages and air-cells.

The **bronchial tubes** or **bronchioles** are cylindrical tubes which differ from the bronchi in not being flattened posteriorly, and in having the cartilaginous and muscular layers distributed throughout their entire calibre. The cartilages cease to be regular rings and become irregular plates, which are most developed at the points of division of the bronchioles, where they form a concave ridge projecting into the tube; they disappear altogether when the tube is reduced to one millimetre in diameter. Connecting the cartilages and arranged outside them is a layer of fibrous tissue forming the *fibrous coat*; in the smallest tubes it is found devoid of cartilage, and becoming thinner is at length continued into the areolar stroma

of the lobules. In this coat are numerous mucous glands, which send their ducts to open on the surface of the mucous membrane.

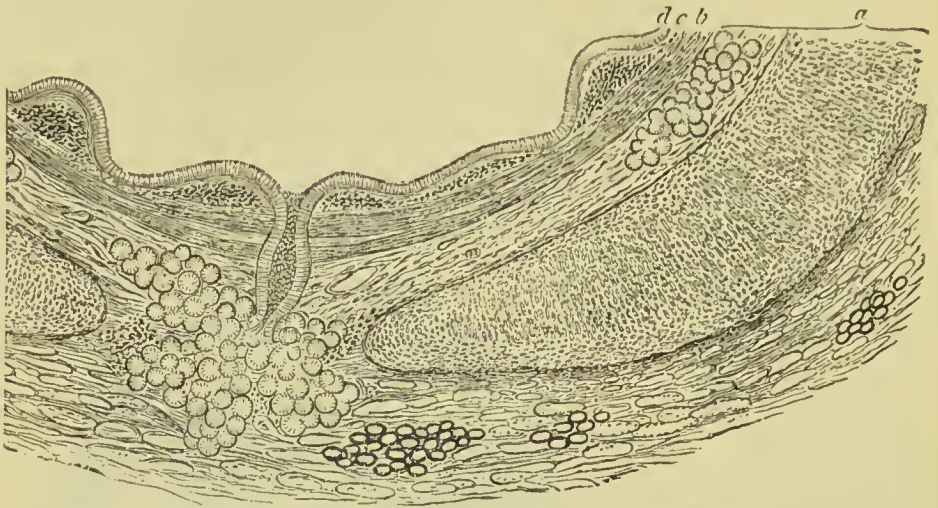

FIG. 402.—Transverse section of the wall of a medium-sized bronchial tube. *a*. Fibrous layer containing plates of cartilage, mucous glands, &c. *b*. Muscular layer. *c*. Elastic sub-endothelial layer. *d*. Columnar ciliated epithelium.

The bronchial tubes continue to diminish in size until they attain a diameter of one millimetre, when they become changed in structure, and are continued onwards in the midst of air-cells, under the name of **alveolar passages**. These passages divide into smaller ones, which terminate by somewhat dilated extremities, called **infundibula**, the walls of which are everywhere crowded by hemispherical saccules called *alveoli* or *air cells*.

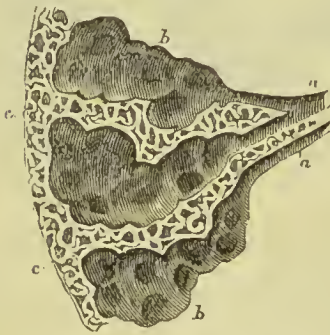


FIG. 403.—A diagram showing the dilatation of the ultimate bronchial tubes into alveolar passages, and the enlargement of the latter near the surface of the lung. *a*, *a*. Bronchial tubes. *b*, *b*. Infundibula, on the walls of which are seen opening the air-cells. *c*, *c*. Air-cells near the surface of the lung.

The **muscular fibres** of the bronchioles are non-striated; they are arranged in rings around the tube, and form a muscular coat which is placed internally to the cartilaginous plates and is continued as far as the plates themselves. The **elastic fibres**, arranged in longitudinal fasciculi, form a thin stratum next the mucous lining; this elastic coat is prolonged to the ends of the tubes, and scattered fibres are found around the alveolar passages and air-cells. The **mucous membrane**, lining the bronchial tubes, is provided with a ciliated columnar epithelium as far as their termination; but in the alveolar passages and air-cells it is altered in its characters, is thin and transparent and coated with a squamous epithelium.

The **air-cells** are polygonal in form, and vary in diameter from .15 mm. to .35 mm.; they are smallest in the centre of the lung, and largest along the thin edges. Near the apex of the lobule the cells open singly into the alveolar passage, but at the base they are clustered, and several cells communicate with each other before opening into the infundibulum. The wall of the air-cells is composed of the stromal tissue of the lung, formed in large part of yellow elastic tissue, with areolar tissue and a few muscular fibres mixed. The white fibres are distinguished by numerous corpuscles scattered throughout them. The air-cells are lined by a single layer of epithelial cells, most of which are large flat cell-plates without a nucleus, but there are others which are small, polygonal, and nucleated, and these are placed in groups of two or three cells over the interstices of the capillary plexus.

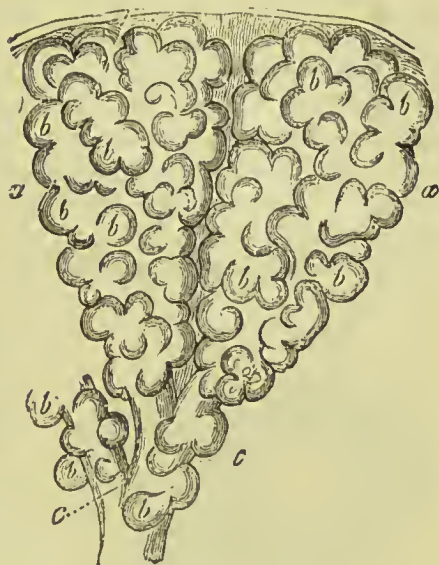

FIG. 404.—Two primary lobuli or infundibula. *a, a.* Exterior of lobules. *b, b.* Pulmonary vesicles. *c, c.* Smallest bronchia.

The **capillaries of the lungs** form plexuses which occupy the walls and septa of the air-cells and the walls of the alveolar passages, but are not continued into the bronchial tubes. The capillary plexus in the wall of each air cell consists of a single layer of vessels, which is so disposed that it is exposed to the air contained in two contiguous air-cells. The air-cells of the central part of the lung are most vascular, and at the same time smallest, whilst those of the periphery are less vascular and larger.

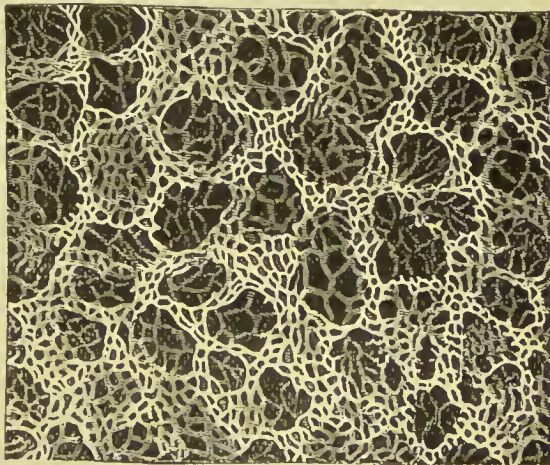


FIG. 405.—Arrangement of the capillaries of the human lung.

The pigmentary matter of the lungs is contained in the walls of the air-cells, as well as in the areolar tissue of the inter-lobular spaces and blood-vessels; it is composed chiefly of carbon.

The **pulmonary artery**, conveying the dark and impure venous

blood to the lungs, accompanies the bronchial tubes to the lung, and divides as the tubes divide. The branches terminate in capillary vessels, which form a dense network in the parietes of the alveolar passages and air-cells, and then converge to form the **pulmonary veins**, by which the arterial blood, purified in its passage through the capillaries, is returned to the left auricle of the heart. In their course through the lung, the artery is commonly found above and behind the bronchial tube, while the vein is below and in front.

The **bronchial arteries**, branches of the thoracic aorta, ramify on the parietes of the bronchial tubes, and terminate partly in bronchial veins which convey the venous blood to the vena azygos on the right side, and superior intercostal vein on the left; and partly in the pulmonary capillaries.

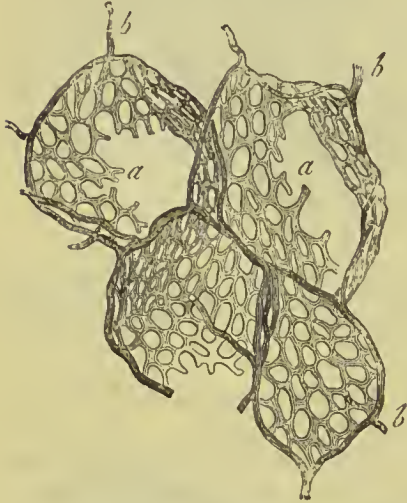


FIG. 406.—Capillary network of an air cell. *a.* Capillary network. *b.* Terminal branch of the pulmonary artery encircling the cell.

The **lymphatics** on the surface of the lung form a fine sub-pleural plexus, communicating by means of stomata with the pleural cavity. Those in the substance of the lung consist of two sets, one of which forms an elaborate plexus beneath the mucous membrane of the bronchial tubes, and the other originates in capillaries between the air-cells and alveolar passages. They all terminate in the bronchial glands at the root of the lung. These glands, very numerous and often of large

size, are placed at the roots of the lungs, around the bronchi, and at the bifurcation of the trachea. In early life they resemble lymphatic glands in other situations; but in old age, and often in the adult, are black, and filled with carbonaceous matter, and occasionally with calcareous deposits.

The **nerves** are derived from the pneumogastric and sympathetic. They form two plexuses: **anterior pulmonary plexus**, situated upon the front of the root of the lungs, and composed chiefly of filaments from the deep cardiac plexus; and **posterior pulmonary plexus**, on the posterior aspect of the root of the lungs, composed principally of branches from the pneumogastric. The branches from these plexuses follow the course of the bronchial tubes, and are distributed to the intercellular passages and air-cells.

PLEURÆ.

Each lung is enclosed and its structure supported by a serous membrane, the pleura, which invests it as far as the root, and is then reflected on the parietes of the chest. That portion of the membrane which is in relation with the lung is called *pleura pulmonalis*, and that in contact with the parietes, *pleura costalis*. The pulmonary pleura is very thin, is elastic, and inseparably connected with the structure of the lung; the costal pleura is thick and strong, has very little elasticity, and can be readily stripped off the ribs and intercostal muscles which it covers. The latter, besides forming the internal lining to the ribs and intercostal muscles, also covers the diaphragm and thoracic surface of the vessels at the root of the neck, extending for somewhat more than an inch above the margin of the first rib. At the lower border of the root of the lung is a fold of the pleura, which extends down by the side of the posterior mediastinum to the diaphragm, and serves to retain the lower part of the lung in position. This fold is the broad ligament of the lung, *ligamentum latum pulmonis*.

At the right side, where the diaphragm is pressed upwards by the liver, the cavity of the pleura is shorter than on the left; while the left pleural cavity, in consequence of the encroachment of the heart on the left side of the chest, is narrower than the right. The right pleura extends at its anterior limit to the lower border of the seventh rib, in the axillary line to the ninth rib, and behind to the eleventh rib. The left pleura reaches to a lower level all round than the right; in the axillary line it touches the lower border of the tenth rib.

MEDIASTINUM.

The two pleural sacs do not communicate with each other, but have between them a space which contains all the viscera of the chest with the exception of the lungs. This is called the **interpleural space** or **mediastinum**. The mediastinum is divided into an *anterior, middle, posterior, and superior* portion.

The **anterior mediastinum** is a triangular space, bounded *in front* by the sternum, *triangularis sterni*, sterno-hyoid, and sterno-thyroid muscles; *behind* by the pericardium and the remains of the thymus gland, and *at each side* by the pleura. It contains a quantity of loose areolar tissue, in which are found some lymphatic vessels passing upwards from the liver, and mediastinal lymphatic glands.

Dissection of the anterior mediastinum.—This space is best displayed by (1) dividing the sternum transversely on a level with the lower border of the first costal cartilages; (2) dividing the same bone transversely between the fifth and sixth costal cartilages; (3) cutting the sternum obliquely, commencing near the right end of the first cut, and terminating at the left end of the second. The two halves of the sternum can now be separated and the anterior mediastinum exposed. (Turner.)

The **middle mediastinum** contains the heart enclosed in its pericardium, the ascending aorta, superior vena cava, pulmonary arteries and veins, bifurcation of the trachea, and phrenic nerves with their accompanying vessels. With the exception of the trachea and phrenic nerves, the whole of the contents of this space lie within the pericardium.

The **posterior mediastinum** is bounded behind by the vertebral column, in front by the pericardium, and at each side by the pleura. It contains the thoracic aorta, the greater and lesser azygos veins, and superior intercostal veins, the thoracic duct, œsophagus, and pneumogastric nerves, the great splanchnic nerves, and some lymphatic glands.

The **superior mediastinum** is the part of the interpleural space which lies above the pericardium, and is bounded *in front* by the

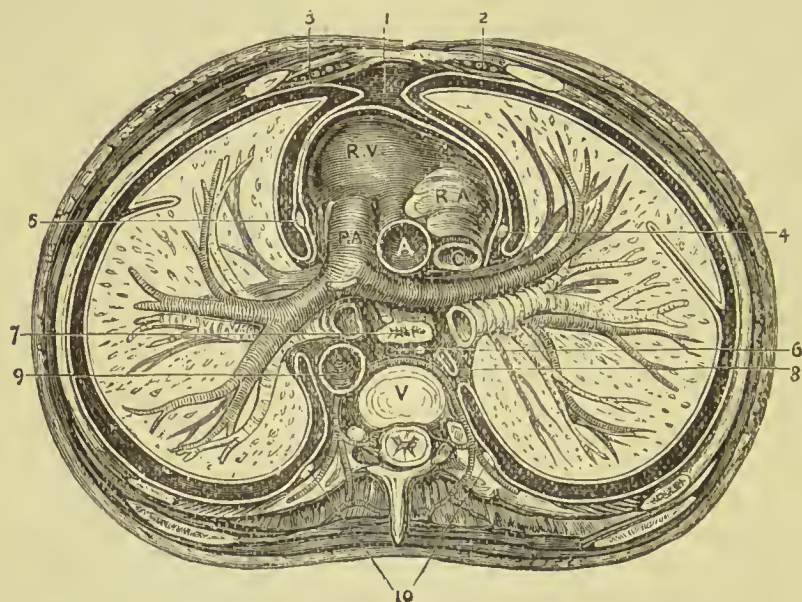


FIG. 407.—Transverse section of the thorax. 1. Anterior mediastinum. 2. Internal mammary vessels. 3. Triangularis sterni muscle. 4. Right phrenic nerve. 5. Left phrenic nerve. 6. Thoracic duct in posterior mediastinum. 7. Œsophagus with left vagus in front and right behind. 8. Vena azygos major. 9. Thoracic aorta giving off intercostal branches. 10. Gangliated cord of sympathetic. R.V. Right ventricle. R.A. Right auricle. P.A. Pulmonary artery. A. Aorta. c. Vena cava superior. v. Dorsal vertebra.

sternum, and the origin of the sterno-hyoid and sterno-thyroid muscles, *behind* by the four upper dorsal vertebræ and longus colli muscle, and *on each side* by the pleura. It is bounded *below* by a plane passing from the junction of the first and second pieces of the sternum to the lower edge of the body of the fourth dorsal vertebra. It contains the remains of the thymus gland, the pneumogastric, cardiac, phrenic, and left recurrent laryngeal nerves; the trachea, œsophagus, and thoracic duct; the transverse portion of the arch of the aorta, and its three great branches; the superior intercostal veins;

the two innominate veins, commencement of the superior vena cava, and termination of the vena azygos major.

THYMUS BODY.

The thymus is a temporary organ, which is of large size in the young child, but in the adult is reduced so as to become a mere vestige; it occupies the anterior mediastinum, and lies in relation with the pleuræ and pericardium.

In its mature state it consists of a thoracic and a cervical portion on each side. The former is situated in the anterior mediastinum, and the latter is placed in the neck just above the first bone of the sternum and behind the sterno-hyoid and sterno-thyroid muscles. It extends upwards from the fourth rib as high as the thyroid gland, resting against the pericardium, separated from the arch of the aorta and great vessels by fâscia, and lying at each side of the trachea in the neck.

Although described usually as a single mass, it consists actually of two lateral, almost symmetrical lobes, connected with each other by areolar tissue only, and having no structural communication; they may therefore be properly called a right and left thymus body.

The thymus is perceptible as early as the seventh week of embryonic existence, and continues gradually increasing with the growth of the fœtus until the seventh month. At the eighth month it is large; during the ninth it undergoes a sudden change, assumes a greatly increased size, and at birth weighs 240 grains. After birth it continues to enlarge until the expiration of the second year, when it ceases to grow, and begins to diminish between the eighth and twelfth year, being often well developed at the age of twenty, and only disappearing entirely before forty.

The two lateral lobes of which it consists, are of an elongated pyramidal form, with their bases resting on the pericardium, and their apices reaching to the thyroid body. Each lobe consists of a number of polyhedral lobules, held together by connective tissue, and enclosed in a fibrous capsule.

The **lobules**, somewhat more than a quarter of an inch in diameter, are composed of smaller lobules, and the *smaller lobules* are made up of small round or polygonal solid masses, the **nodules** or **follicles**. These are in every respect similar in structure to the lymphoid masses found in other parts of the body, as, for instance, in the tonsils, and the solitary and agminate glands of the intestine. They consist of retiform tissue, the meshes of which are crowded with lymph corpuscles; at the circumference of each nodule the retiform tissue is closer so as to form a sort of capsule. Scattered throughout the retiform tissue are peculiar, highly refracting corpuscles, which present an appearance of concentric striation, and have been named the *concentric corpuscles of Hassall*.

The **arteries** of the thymus gland are derived from the internal

mammary, superior thyroid, and inferior thyroid. The **veins** terminate in the left innominate vein, and some small branches in the thyroid veins. The **nerves** are minute, and derived chiefly, through the internal mammary plexus, from the superior thoracic ganglion of the sympathetic. Other branches reach the gland from the phrenic, pneumogastric, and descendens cervicis nerves.

The **lymphatics** accompany the blood-vessels in the interior of the gland, terminate in the general union of the lymphatic vessels at the junction of the internal jugular and subclavian veins.

ABDOMEN.

The abdomen is the inferior cavity of the trunk of the body ; it is bounded *in front*, and *at the sides*, by the lower ribs and abdominal muscles ; *behind*, by the vertebral column and abdominal muscles ;

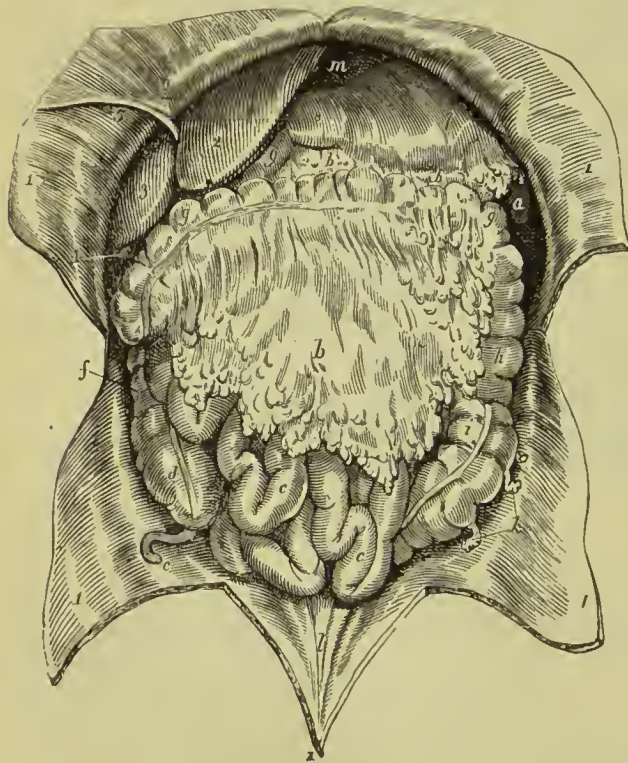


FIG. 408.—Viscera of the abdomen *in situ*. 1, 1. Flaps of the abdominal parietes turned aside. 2. Liver, its left lobe. 3. Right lobe. 4. Fundus of the gall-bladder. 5. Round ligament of the liver, issuing from the cleft of the longitudinal fissure, and passing along the parietes of the abdomen to the umbilicus. 6. Part of the broad ligament of the liver. 7. Stomach. 8. Its pyloric end. 9. Commencement of the duodenum. a. Lower extremity of spleen. b, b. Greater omentum. c, c. Small intestines. d. Cæcum. e. Vermiform appendix. f. Ascending colon. g, g. Transverse colon. h. Descending colon. i. Sigmoid flexure of colon. k. Appendices epiploicæ connected with the sigmoid flexure. l. Three ridges representing the cords of the urachus and hypogastric arteries ascending to the umbilicus. m. Diaphragm.

above, by the diaphragm ; and *below*, by the pelvis ; and contains the alimentary canal, the liver, pancreas, spleen, kidneys, and suprarenal capsules.

Regions.—For convenience of description of the viscera, and of reference to the morbid affections of this cavity, the abdomen is

divided into certain districts or regions. Thus, if two transverse lines be carried around the body, the one parallel with the cartilages of the ninth ribs, the other with the highest point of the crests of the ilia, the abdomen will be divided into three zones. Again, if a perpendicular line be drawn, at each side, from the cartilage of the eighth rib to the middle of Poupart's ligament, the three primary zones will each be subdivided into three compartments or regions, middle and two lateral.

The middle region of the upper zone being immediately over the small end of the stomach, is called **epigastric** (ἐπὶ γαστήρ, over the stomach). The two lateral regions being under the cartilages of the ribs, are called right and left **hypochondriac** (ὑπὸ χόνδροι, under the cartilages). The middle region of the middle zone is the **umbilical**; the two lateral, the **lumbar**. The middle region of the inferior zone is the **hypogastric** (ὑπὸ γαστήρ, below the stomach); and the two lateral, the **iliac**. In addition to these divisions, we employ the term **inguinal region**, in reference to the vicinity of Poupart's ligament.

Position of the Viscera.—The position of the viscera which occupy these several regions may be best understood and remembered, by arranging them in a tabular form, as follows:—

Right Hypochondriac.	Epigastric.	Left Hypochondriac.
Right lobe of liver, Hepatic flexure of colon, Upper end of kidney, Supra-renal capsule.	Left lobe of liver, Part of right lobe, Gall-bladder, First and second parts of duodenum, Stomach, Pancreas, Part of spleen, Parts of both kidneys and supra-renal capsules.	Great end of stomach, Spleen, Tail of pancreas, Splenic flexure of colon, Upper end of kidney, Supra-renal capsule.
Right lumbar.	Umbilical.	Left Lumbar.
Ascending colon, Lower part of kidney, Jejunum.	Great omentum, Mesentery, Transverse colon, Transverse duodenum, Small intestines, Part of both kidneys.	Descending colon, Lower part of kidney, Jejunum.
Right Iliac.	Hypogastric.	Left Iliac.
Cæcum, Vermiform appendix, Ilium, Ureter.	Ilium, (Bladder and uterus when enlarged.)	Sigmoid flexure, Small intestines, Ureter.

PERITONEUM.

The *peritoneum* (περιτείνειν, to extend around) forms a completely shut sac, excepting in the female, where the peritoneum is perforated by the open extremities of the Fallopian tubes, and is continuous with their mucous lining.

The simplest idea that can be given of a serous membrane is, that it invests the viscus or viscera, and is then reflected on the parietes of the containing cavity. If the cavity contain only a single viscus, the consideration of the serous membrane is extremely simple. But in the abdomen, where there are a number of viscera, the serous membrane passes from one to the other until it has invested the

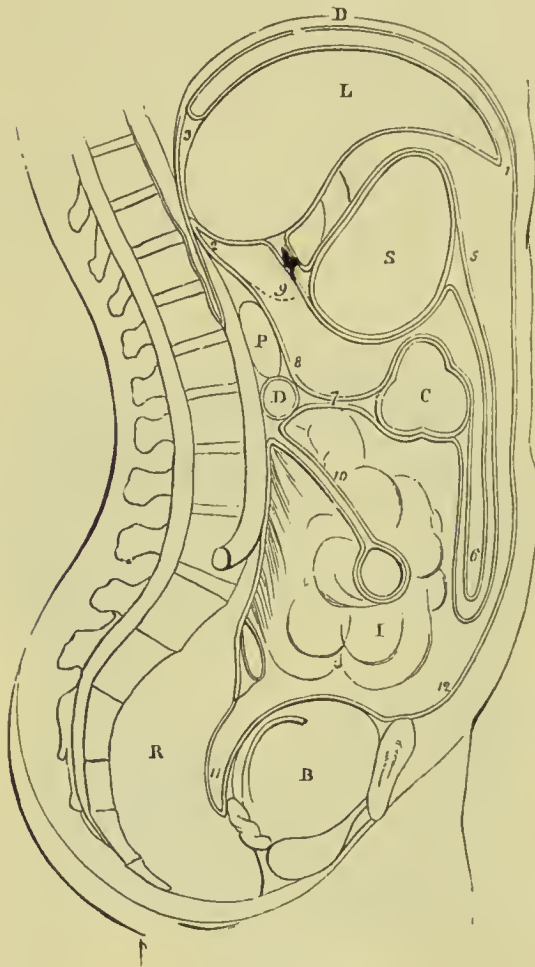


FIG. 409.—Reflections of the peritoneum. D. Diaphragm. L. Liver. S. Stomach. C. Transverse colon. D. Transverse duodenum. P. Pancreas. I. Small intestines. R. Rectum. B. Urinary bladder. 1. Anterior layer of peritoneum, lining the under surface of the diaphragm. 2. Posterior layer. 3. Coronary ligament, formed by the passage of these two layers to the posterior border of the liver. 4. Lesser omentum; the two layers passing from the under surface of the liver to the lesser curve of the stomach. 5. The two layers meeting at the greater curve, then passing downwards and returning upon themselves, forming (6) the greater omentum. 7. Transverse meso-colon. 8. Posterior layer traced upwards in front of D, transverse duodenum, and P, pancreas, to become continuous with the posterior layer (2). 9. Foramen of Winslow: the dotted line bounding this foramen inferiorly marks the course of the hepatic artery forwards, to enter between the layers of the lesser omentum. 10. Mesentery encircling the small intestines. 11. Rectovesical fold, formed by the descending anterior layer. 12. Anterior layer traced upwards on the inner surface of the abdominal parietes to the layer (1), with which the examination commenced.

whole, before it is reflected on the parietes. Hence its reflections are a little more complicated.

In tracing the reflections of the peritoneum, in the middle line, we commence with the diaphragm, which is lined by two layers, one from the parietes in front, *anterior*, and one from the parietes behind, *posterior*. These two layers of the same membrane, at the posterior part of the diaphragm, descend to the upper surface of the liver, forming the **coronary** and **lateral ligaments** of the liver. They then surround the liver, one going in front, the other behind that viscus, and meeting at its under surface, pass to the stomach,

forming the **lesser omentum**. They then, in the same manner, surround the stomach, and meeting at its lower border, descend for some distance in front of the intestines, and return to the transverse colon, forming the **great omentum**; they then surround the transverse colon, and pass directly backwards to the vertebral column, forming the transverse **meso-colon**. Here the two layers separate; the *posterior* ascends in front of the pancreas and aorta, and returns to the posterior part of the diaphragm, where it becomes the posterior layer with which we commenced. The *anterior* descends, invests all the small intestines, and returning to the vertebral column, forms the **mesentery**. It then descends into the pelvis in front of the rectum, which it holds in its place by means of a fold called **meso-rectum**, forms a pouch, the **recto-vesical fold**, between the rectum and the bladder, ascends upon the posterior surface of the bladder, forming its false ligaments, and returns upon the anterior parietes of the abdomen to the diaphragm, whence we first traced it.

In the female, after descending into the pelvis in front of the rectum, it is reflected upon the posterior surface of the vagina and uterus. It then descends on the anterior surface of the uterus, and forms at either side the broad ligaments of that organ. From the uterus it ascends upon the posterior surface of the bladder, and anterior parietes of the abdomen, and is continued, as in the male, to the diaphragm.

In like manner the peritoneum can be traced as a continuous sheet from one side to the other side of the abdomen. Thus, if

we commence at the middle line in front and follow it across the abdomen below the level of the transverse colon, we shall find that it passes from the abdominal wall to the right iliac fossa where it covers in the cæcum and ascending colon, forming the meso-cæcum and ascending meso-colon; it

then passes inwards and forms the mesentery which attaches the small intestines to the vertebral column, and may be traced from thence to the left iliac

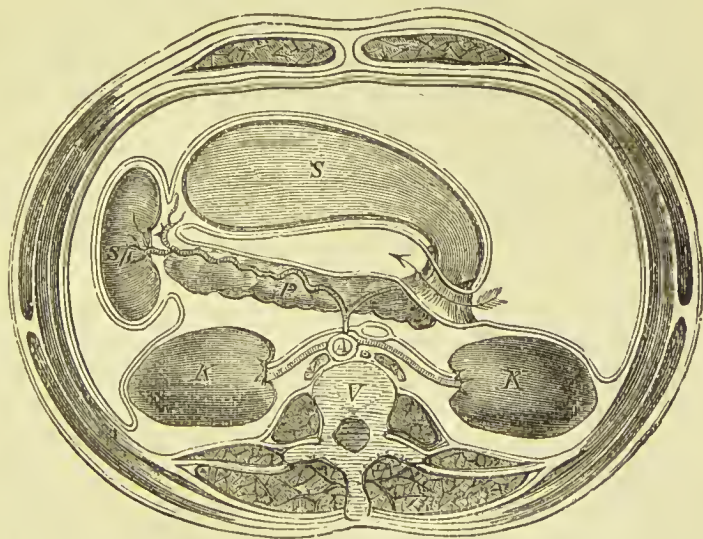


FIG. 410.—Transverse section of the abdomen at the level of the foramen of Winslow. The arrow passes from the greater to the lesser cavity of the peritoneum through the foramen of Winslow which is shown in section. S. Stomach. P. Pancreas. Sp. Spleen. K. Kidney. V. Vertebra. A. Aorta.

fossa where it covers the sigmoid flexure (sigmoid meso-colon) ; it is then continued on to the abdominal wall, terminating at the point whence we set out. Above the transverse colon the arrangement is more complicated, in consequence of the existence of two cavities, a greater and a lesser. Beginning at the middle line we may trace the peritoneum over the right kidney into the right hypochondrium ; it then passes across the body in front of the pancreas, and returns from left to right along the posterior surface of the stomach, so as to reach the **foramen of Winslow**, where it forms the posterior layer of the lesser omentum. It now becomes reflected on itself round the structures (hepatic artery, portal vein, and common bile duct) forming the pillar of the foramen of Winslow, and constitutes the anterior layer of the lesser omentum. Passing over the anterior surface of the stomach, it is continued on the spleen, which it encloses (forming the **gastro-splenic omentum**), and so passes to the left hypochondrium, and from thence to the anterior wall of the abdomen.

Processes of Peritoneum.—The folds of peritoneum serve the purpose of connecting the viscera with the abdominal wall or with each other, and thus limiting their movement. Those attached to the stomach are called **omenta** (*greater, lesser, and gastro-splenic*) ; those attaching the hollow viscera to the wall have the prefix **meso-**, as mesentery, meso-colon, meso-cæcum, meso-sigmoid, &c. ; other folds more limited in extent receive the name of **ligaments**, such as those of the liver, stomach, urinary bladder, and uterus. The following is a brief description of these processes :—

The **lesser omentum** (gastro-hepatic) is the duplicature which passes between the liver and the upper border of the stomach. It is extremely thin, excepting at its right border, where it is free, and contains between its layers the—

Hepatic artery, Common bile duct, Hepatic plexus of nerves.	Portal vein, Lymphatics,
---	-----------------------------

These structures are enclosed in a loose areolar tissue called *Glisson's capsule*. The relative position of the three vessels is, the artery to the left, the duct to the right, the vein between and behind.

If the finger be introduced behind the right border of the lesser omentum, it will be situated in an opening called the **foramen of Winslow**. In *front* of the finger will lie the right border of the lesser omentum, containing the hepatic artery, portal vein, and hepatic duct ; *behind* it, the right ends of the diaphragm and inferior vena cava covered by the ascending or posterior layer of the peritoneum ; *below*, the hepatic artery, curving forward from the celiac axis, and the ascending portion of the duodenum ; and *above*, the lobus Spigelii. These, therefore, are the *boundaries of the foramen of Winslow*, which is nothing more than a constriction of the general cavity of the peritoneum at this point, arising out of the

necessity for the hepatic and gastric arteries to pass forwards from the celiac axis to reach their respective viscera.

If air be blown through the foramen of Winslow, it will descend behind the lesser omentum and stomach to the space between the descending and ascending pair of layers, forming the great omentum. This is sometimes called the **lesser cavity of the peritoneum**, and that external to the foramen the **greater cavity**; in which case the foramen is considered as the means of communication between the two. It may be objected to this division that it tends to lead the inexperienced to believe that there are two cavities, while, in reality, there is but one, the foramen of Winslow being merely a constriction of that one, to facilitate the communication between the nutrient arteries and the viscera of the upper part of the abdomen.

The **great omentum** (gastro-colic) consists of *four layers of peritoneum*, the two which descend from the stomach, and the same two, returning upon themselves to the transverse colon. A quantity of adipose substance is deposited around the vessels which ramify through its structure. In the fœtus and young child, and occasionally in the adult, it is possible to separate the ascending layers of the great omentum from the transverse colon, and to trace them to the vertebral column on the upper surface of the transverse mesocolon, with which, however, they are only loosely connected. Under these circumstances the latter fold is formed by a separate duplicature of the peritoneum, and is not the direct continuation of the omentum, as in the description above given.

The **transverse meso-colon** (*μέσος*, middle, being attached to the middle of the cylinder of the intestine) is the medium of connection between the transverse colon and the posterior wall of the abdomen. It affords to the nutrient arteries a passage to reach the intestine, and also forms a transverse septum across the abdominal cavity. On reaching the posterior wall of the abdomen, its two layers separate from each other on the anterior aspect of the transverse duodenum, the one ascending to cover in the pancreas, kidneys, and supra-renal capsules, and to pass from thence to the under surface of the diaphragm, the other descending to form the mesentery, and then passing into the pelvis.

The **mesentery** (*μέσον έντερον*, connected to the middle of the cylinder of the small intestine) is the medium of connection between the small intestines and the posterior wall of the abdomen. It is very narrow at its vertebral edge, measuring usually about six inches, while on its visceral border it measures from fifteen to eighteen feet; it thus presents the appearance of a gigantic fan folded on itself. It is oblique in direction, being attached to the posterior wall, from the left side of the second lumbar vertebra to the right iliac fossa; retains the small intestines in their place, and contains between its folds the mesenteric arteries, veins, nerves, lymphatic glands, and lacteal vessels.

The **meso-rectum**, in like manner, retains the rectum in con-

nection with the front of the sacrum. Besides this, there are some minor folds in the pelvis, as the **recto-vesical** fold, the **false ligaments of the bladder**, and the **broad ligaments of the uterus**.

The ligaments of the liver, uterus, and urinary bladder will be fully discussed in the description of those organs.

The **appendices epiploicæ** are small irregular pouches of the peritoneum, filled with fat, and attached like fringes to the colon, and upper part of the rectum.

Three other duplicatures of the peritoneum are situated in the sides of the abdomen; they are the **gastro-phrenic** ligament, the **gastro-splenic** omentum, the **ascending** and **descending meso-colon**, and the **costo-colic** ligament. The **gastro-phrenic ligament** is a small duplicature of the peritoneum, which descends from the diaphragm to the extremity of the œsophagus, and lesser curve of the stomach. The **gastro-splenic omentum** (ligamentum gastro-lienale) is the duplicature which connects the spleen to the stomach. The **ascending meso-colon** is the fold which connects the upper part of the ascending colon with the posterior wall of the abdomen; and the **descending meso-colon**, that which retains the sigmoid flexure in connection with the abdominal wall. The **costo-colic ligament** (sustentaculum lienis) is a fold of peritoneum which stretches from the diaphragm about the level of the tenth or eleventh rib on the left side, to the splenic flexure of the colon; it supports the spleen.

Review of the Relations of the Peritoneum to the Abdominal Viscera.—The liver is entirely covered by peritoneum, excepting a triangular area on its upper surface, where the coronary and falciform ligaments meet, and its posterior border, including the lobus Spigelii. The stomach may be considered as practically entirely covered by peritoneum, but Cathcart has pointed out that there is a triangular area at the back where it rests against the left crus of the diaphragm which is uncovered. The spleen is entirely covered. The ascending duodenum and the whole of the jejunum and ileum are entirely enveloped; the descending and transverse parts of the duodenum are covered only in front. The transverse colon has peritoneum all round it. The ascending and descending portions vary in their arrangement; the cæcum is usually completely covered so that there is a meso-cæcum, and the same thing is true of the sigmoid flexure, a meso-sigmoid being generally present. The ascending and descending parts of the large bowel are commonly covered only in front, but in many cases the descending colon has a meso-colon and is thus completely covered, and in less frequent examples the ascending colon is in the same condition. The upper part of the rectum has a meso-rectum; the part below this is covered only on the front and sides; the next part has peritoneum only in front, and the last has no relation to that membrane. The pancreas, kidneys, and supra-renal capsules are covered only in front. The relation of the peritoneum to the pelvic organs will be considered when the organs themselves are described.

ALIMENTARY CANAL.

The alimentary canal is a musculo-membranous tube, extending from the mouth to the anus. It is variously named in the different parts of its course, and is divided into the—

	Mouth, Pharynx, Œsophagus, Stomach,	
Small intestine	{ Duodenum, Jejunum, Ileum,	Large intestine { Cæcum, Colon, Rectum.

The **mouth** is the irregular cavity which contains the organ of taste and the principal instruments of mastication. It is bounded *in front* by the lips; on each *side* by the internal surface of the cheeks; *above*, by the hard palate and teeth of the upper jaw; *below*, by the tongue, the mucous membrane stretched between the arch of the lower jaw and the under surface of the tongue, and by the teeth of the inferior maxilla; and *behind* by the soft palate and fauces.

The **lips** are two fleshy folds formed externally by integument and internally by mucous membrane, and containing between these two layers, muscles, a quantity of fat, and numerous small *labial glands*. They are attached to the surface of the upper and lower jaw, and each lip is connected to the gum in the middle line by a fold of mucous membrane, the *frena* or *frenula*.

The **cheeks** are continuous with the lips, and form the sides of the face; they are composed of integument, a large quantity of fat, muscles, mucous membrane, and *buccal glands*.

The mucous membrane lining the cheeks is reflected above and below on the sides of the jaws, and is attached posteriorly to the anterior margin of the ramus of the lower jaw. At about its middle, opposite the second molar tooth of the upper jaw, is a papilla, on which may be observed a small opening, the aperture of the duct of the parotid gland (Stenson's duct).

The **hard palate** is a dense structure, composed of mucous membrane, *palatine glands*, areolar tissue, vessels, and nerves, and firmly connected to the palate processes of the superior maxillary and palate bones. It is bounded in front and at each side by the alveolar processes and gums, and is continuous behind with the soft palate. Along the middle line it is marked by an elevated raphé, and presents at each side of the raphé a number of transverse ridges and grooves. Near its anterior extremity, and immediately behind the middle incisor teeth, is a papilla which corresponds with the termination of the anterior palatine canal, and receives the naso-palatine nerves.

The **gums** are composed of a thick and dense mucous membrane, which is closely adherent to the periosteum of the alveolar processes,

and embraces the necks of the teeth. They are remarkable for their hardness and insensibility, and for their close contact, without adhesion, to the surface of the tooth. From the neck of the tooth they are reflected into the alveolus and become continuous with the periosteal membrane of that cavity (alveolo-dental membrane).

The **tongue** has been already described as an organ of sense; it is invested by mucous membrane, which is reflected from its under

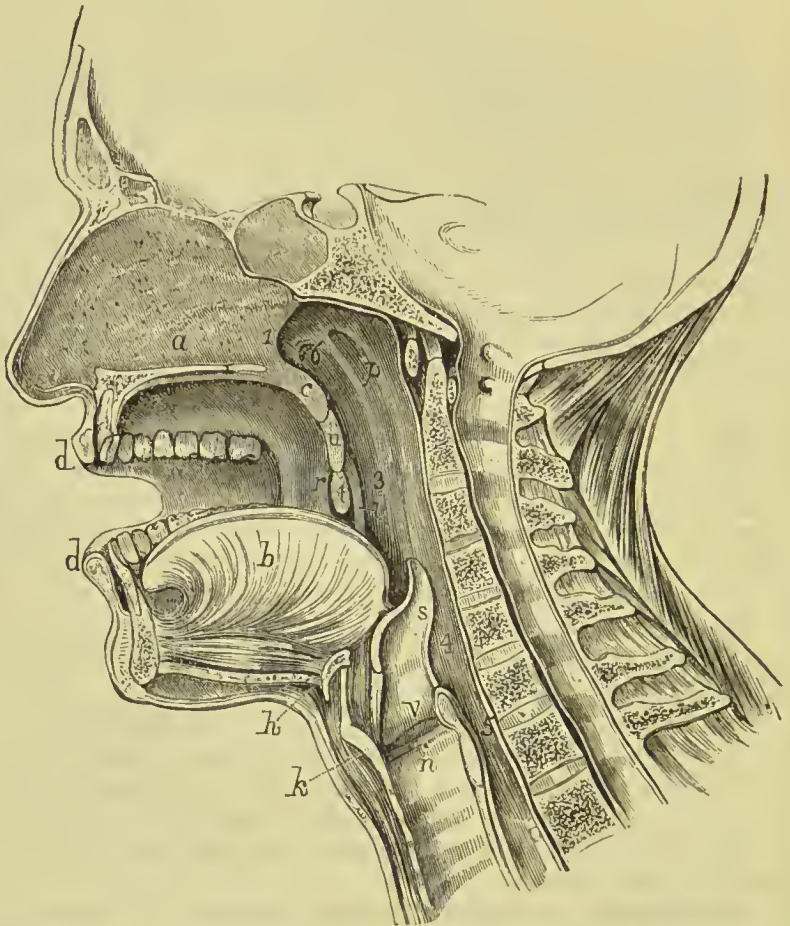


FIG. 411.—Median section of mouth, nose, pharynx, and larynx. *a*. Septum of nose; below it, section of hard palate. *b*. Tongue. *c*. Section of velum pendulum palati. *d, d*. Lips. *u*. Uvula. *r*. Anterior pillar of fauces. *i*. Posterior pillar. *t*. Tonsil. *p*. Pharynx. *h*. Hyoid bone. *k*. Thyroid cartilage. *n*. Cricoid cartilage. *s*. Epiglottis. *1*. Posterior opening of nares. *3*. Isthmus faucium. *4*. Upper opening of larynx. *5*. Œsophagus. *6*. Eustachian tube.

part upon the inner surface of the lower jaw, and constitutes, with the muscles beneath, the floor of the mouth. On the under surface of the tongue, near its anterior part, the mucous membrane forms a considerable fold, which is called the **frænum linguæ**, and on each side of the frænum is a large papilla, *caruncula sublingualis*, the termination of the duct (Wharton's duct) of the submaxillary gland. Running back from this papilla is a ridge occasioned by the

prominence of the sublingual gland, and opening along the summit of this ridge a number of small openings, the apertures of the excretory ducts (ducts of Rivinus) of the gland. Posteriorly the tongue is connected with the os hyoides by muscle, and to the epiglottis by three folds of mucous membrane, the **glosso-epiglottic folds**.

The **soft palate** (*velum pendulum palati*) is a fold of mucous membrane situated at the posterior part of the mouth. It is continuous, superiorly, with the hard palate, and is composed of a double fold of mucous membrane, containing muscles, glands, and blood-vessels; it is concave towards the mouth and convex towards the pharynx, and presents a free festooned edge inferiorly. The structures forming the soft palate may be briefly summed up as follows:—
Muscles: Two levatores palati, two tensores palati, two palati glossi, two palati pharyngei, azygos uvulæ. *Palatine aponeurosis*. *Palatine glands*. *Arteries*: Ascending palatine, descending palatine, palatine branch of ascending pharyngeal. *Nerves*: Descending palatine and external palatine from spheno-palatine ganglion. The mucous membrane is continuous with that of the hard palate, but is thinner and darker, and is covered by stratified squamous epithelium, excepting at the extreme upper part of its posterior surface, near the opening of the Eustachian tube, where it is columnar and ciliated. The **palatine glands** are most numerous on the posterior surface of the velum and covering the uvula; they are small compound racemose glands. Hanging from the middle of the inferior border of the soft palate is a small rounded process, the **uvula**, and passing outwards from the uvula at each side are two curved folds of the mucous membrane, the arches or pillars of the fauces. The **anterior pillar** is continued downwards to the side of the base of the tongue, and is formed by the prominence of the palato-glossus muscle. The **posterior pillar** is prolonged downwards and backwards into the pharynx, being formed by the convexity of the palato-pharyngeus muscle. These two pillars, closely united above, are separated below by a triangular interval or niche, in which the tonsil is lodged.

The space included between the soft palate and the root of the tongue is the **isthmus of the fauces**. It is bounded *above* by the soft palate, on each *side* by the pillars of the soft palate and tonsil, and *below* by the root of the tongue. It is the opening between the mouth and pharynx.

The **tonsils** (*amygdalæ*) are two glandular organs, about half an inch in length, shaped like almonds, and situated between the anterior and posterior pillar of the soft palate, at each side of the fauces. Externally, they are invested by the pharyngeal fascia, which separates them from the superior constrictor muscle and internal carotid artery, and prevents an abscess from opening in that direction; they correspond in position to the angles of the lower jaw, behind which they may be felt when enlarged. They present on their surface the openings of twelve to fifteen mucous crypts, similar to those at the root of the tongue and described below under

the name of lingual glands. The substance of the tonsil is formed of a great number of lymphoid nodules, with some looser reticular tissue between them.

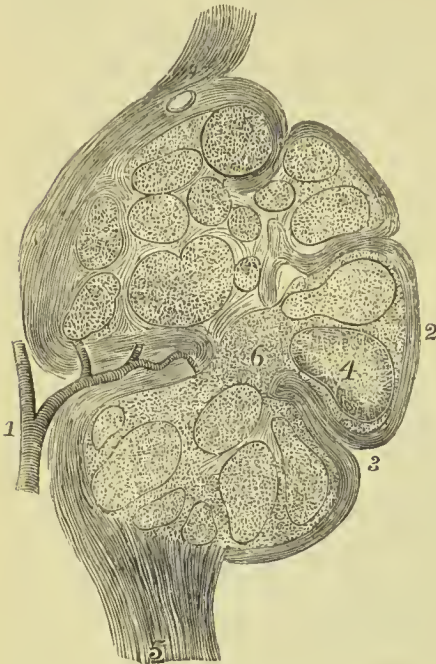
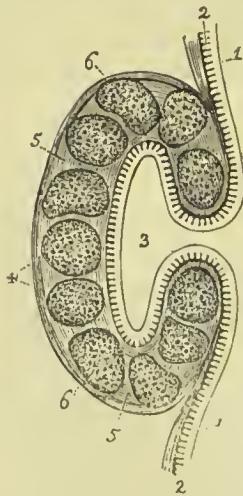


FIG. 412.—Vertical section of the tonsil. 1. Hilus with vessel entering it. 2. Epithelial external layer. 3. Mucous crypt. 4. Lymphoid nodule. 5. Submucous tissue of the fauces terminating in the tonsil. 6. Interstitial connective tissue.

lingual glands form a thick stratum in the submucous tissue beneath

FIG. 413.—Mucous crypt from the root of the tongue. 1, 1. Epithelium. 2, 2. Papillæ of the mucous membrane. 3. Cavity of the crypt. 4. Investing coat of the gland, composed of areolar tissue. 5, 5. Fibro-vascular matrix, forming the parenchyma of the crypt; and containing, 6, 6, Lymphoid nodules surrounding the crypt.



the mucous crypts at the root of the tongue; the layer of glands extends completely across the tongue, and their ducts, several lines in length, open by infundibuliform expansions, some into the mucous crypts, others into the foramen cæcum, others into the fossæ of the papillæ circumvallatæ, and others between the papillæ. They are surrounded by a large quantity of lymphoid tissue which is here and there collected into round masses called lymphoid nodules, many of these being grouped around the cavities of the mucous crypts. Mucous glands are also dispersed on other parts of the tongue, but are smaller and few in number: a small group is found between the vertical folds on the sides of the

The **mucous glands** of the mouth are racemose glands; they are yellowish or whitish in colour, rounded in form, and situated in the submucous areolar tissue. The **labial glands** vary in size from half a line to one line and a half in diameter, and form an almost continuous layer around the mouth. The **buccal glands** are numerous, but smaller than the labial; a few of larger size being located near the aperture of Stenson's duct. The **molar glands** are placed between the masseter and buccinator, and pierce the latter with their ducts opposite the molar teeth. The **palatine glands** are situated in the posterior half of the hard palate and in the soft palate; in the latter forming a layer several lines in breadth. They are also numerous but small on the posterior part of the soft palate. The

tongue, and a considerable group on its under surface near the tip and on either side of the frænum linguæ.

SALIVARY GLANDS.

Communicating with the mouth are the excretory ducts of three pairs of salivary glands—the parotid, submaxillary, and sublingual.

The **PAROTID GLAND** (*παρά*, near ; *ὄς*, *ὄτος*, the ear), the largest of the three, is situated immediately in front of the external ear, and extends superficially for a short distance over the masseter muscle ; on its deep aspect it is projected inwards by two processes, one of which lies between the styloid and mastoid processes, and fills up the back part of the glenoid cavity (*glenoid lobe*) ; the other passes in front of the styloid process (*pterygoid lobe*). It reaches inferiorly to below the level of the angle of the jaw, and posteriorly to the mastoid process, slightly overlapping the insertion of the sterno-mastoid muscle. It is separated from the submaxillary gland by the stylo-maxillary ligament. Embedded in its substance are—the external carotid artery, temporo-maxillary vein, and facial nerve ; emerging from its anterior border, the transverse facial artery and branches of the facial nerve, and above, the temporal artery and auriculo-temporal nerve. On its posterior border lies the great auricular nerve, from which it receives branches.

The **duct of the parotid gland (Stenson's duct)**, about two inches in length, and about the diameter of a crow's quill, issues from the anterior part of the gland, just below the zygoma, and crosses the masseter muscle ; it then curves inwards over the anterior border of the muscle, and pierces the buccinator opposite the second molar tooth of the upper jaw ; its course through the mucous membrane of the cheek is very oblique, so that the posterior border of its opening forms a valvular fold, which prevents fluid from passing from the mouth into the duct. The course taken by the duct may be roughly indicated by a line drawn from the bottom of the lobule of the ear to a point midway between the mouth and nose. The duct is dense in structure, and its walls of considerable thickness in proportion to the area of the tube, which is remarkably small.

A small glandular appendage, the *socia parotidis*, is connected with the upper part of the duct on the masseter muscle ; and opens into it by one or several small ducts.

The **SUBMAXILLARY GLAND**, rounded in its form, is situated in the posterior part of the submaxillary triangle of the neck. It rests on the hyo-glossus, stylo-glossus, and mylo-hyoid muscles, and is covered in by the body of the lower jaw and the deep cervical fascia. It is separated from the parotid gland by the stylo-maxillary ligament, and from the sublingual gland by the mylo-hyoid muscle. Embedded among its lobules are the facial artery and submaxillary ganglion.

Its excretory duct, **Wharton's duct**, about two inches in length, issues from the middle of the gland, and passes between the mylo-

hyoid and hyo-glossus to the frænum linguæ, by the side of which it terminates at the apex of a papilla, *caruncula sublingualis*. A process

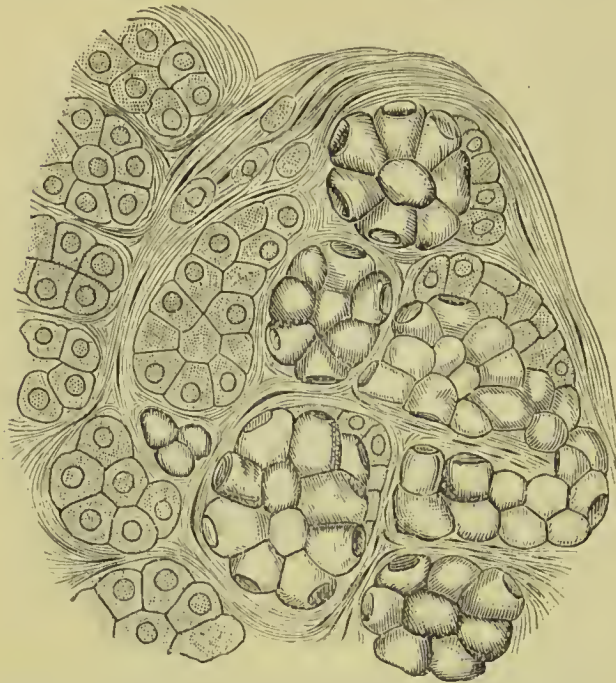


FIG. 414.—Section of part of the human submaxillary gland. To the right of the figure is a group of mucous alveoli, to the left a group of serous alveoli; in the former the marginal cells are seen, forming the *lunula of Gianuzzi*.

in relation also with the duct of the submaxillary gland and the hypoglossal nerve.

Its secretion is poured into the mouth by from seven to twenty short ducts, **ducts of Rivinus**, which open on the ridge made by the gland in the floor of the mouth; the larger openings being situated by the side of the frænum linguæ. One of the ducts longer than the rest, and opening close to Wharton's duct, has been named *ductus Bartholini*.

Structure.—The salivary glands are of the racemose kind, consisting of lobes which are made up of polyhedral lobules; and these of smaller lobules; in minute structure they correspond with the racemose glands described on p. 62.

Two kinds of alveoli are, however, to be distinguished, namely, those secreting a thick, ropy fluid containing mucin, and hence called *mucous alveoli*; and those secreting a more watery fluid often containing serum-albumin, and named *serous alveoli*. The parotid is composed of serous alveoli, the sublingual of mucous alveoli, but the submaxillary is mixed in character, containing both kinds.

The **mucous alveoli** are distinguished by possessing two sets of cells, namely, large, clear, almost spheroidal *mucigenous cells*, with a flat nucleus near the basement membrane; and densely clustered smaller cells with oval nuclei, lying near the periphery of the alveolus

of the gland is prolonged with the duct for a short distance above the mylo-hyoid.

The **SUBLINGUAL** is a long and flattened gland, situated beneath the mucous membrane of the floor of the mouth, at the side of the frænum linguæ. It is in relation with its fellow of the opposite side, and in the rest of its course lies between the lower jaw and genio-hyo-glossus, being bounded below by the mylo-hyoid. It is in

and flattened by pressure between the basement membrane and mucigenous cells ; these are called *marginal cells* (*lunula of Gianuzzi*). In **serous alveoli** the gland cells almost completely fill the alveolus, and when the gland is at rest they are packed with distinct granules which obscure the nucleus ; during secretion the granules decrease in number and are limited to the periphery of the cell, so that the nucleus becomes distinct.

The **ducts of the salivary glands** consist of a strong fibrous outer coat, beneath which are longitudinal and circular elastic layers, mixed with a few fibres of unstriped muscle ; the lining membrane is formed by a basement membrane supporting columnar epithelial cells. The epithelium is remarkable for its vertical striation at the part resting on the basement membrane, probably due to the presence of rod-like bodies in the protoplasm.

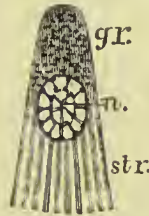

FIG. 415.—Striated epithelial cell from the duct of a salivary gland (semi-diagrammatic). *gr.* Granular protoplasm. *str.* Striæ. *n.* Nucleus. (E. A. Schäfer).

Vessels and Nerves.—The parotid gland is abundantly supplied with *arteries* by the external carotid ; the submaxillary by the facial and lingual ; and the sublingual by the sublingual and submental branches of the lingual artery. The capillaries form a network around and in contact with the glandular vesicles.

The **nerves** of the parotid gland are derived from the auriculo-temporal branch of the inferior maxillary, from the auricularis magnus, and from the nervi molles accompanying the external carotid artery. In some animals the parotid also receives filaments from the glosso-pharyngeal nerve, through the lesser petrosal nerve and otic ganglion, but this distribution has not been proved to obtain in the human subject. The submaxillary gland is supplied by the branches of the submaxillary ganglion, chorda tympani, sympathetic, lingual branch of the fifth, and sometimes filaments from the mylo-hyoid nerve ; and the sublingual by filaments from the submaxillary ganglion and lingual branch of the fifth nerve. Each salivary gland has three nerves distributed to it : (1) *secretory filaments* ending in the gland epithelium ; (2) *afferent branches*, passing from the mucous surface on which the gland duct opens to the salivary centre ; and (3) *vaso-dilator twigs* to the blood-vessels supplying the gland.

TEETH.

Man is provided with two sets of teeth, which appear the one in succession to the other ; the first are the teeth of childhood—they are called temporary, deciduous, or milk-teeth ; the second continue until old age, and are named permanent.

The **permanent teeth** are thirty-two in number, sixteen in each jaw ; they are divisible into four classes : *incisors*, of which there are four in each jaw, two central and two lateral ; *canine*, two above and two below ; *bicuspid* or *premolar*, four above and four below ; and *molars*, six above and six below.

The **temporary teeth** are twenty in number : eight incisors, four canines, and eight molars. There are no bicuspidis in the temporary set, but the eight deciduous molars are succeeded by the permanent bicuspidis.

The following table shows the position of the teeth relative to each other, in each set, and the relation of those of the temporary to those of the permanent series :—

		Mo.	Ca.	In.	Ca.	Mo.			
Temporary teeth.	}	Upper	2	1	4	1	2	= 10	
		Lower	2	1	4	1	2	= 10	
							= 20		
		Mo.	Pm.	Ca.	In.	Ca.	Pm.	Mo.	
Permanent teeth.	}	Upper	3	2	1	4	1	2	3 = 16
		Lower	3	2	1	4	1	2	3 = 16
								= 32	

Every tooth is divisible into a *crown*, which is the part above the gum ; a constricted portion around the base of the crown, the *neck* ; and a *root* or *fang*, which is contained within the alveolus. The root is invested by periosteum, which is a bond of connection between it and the alveolus.

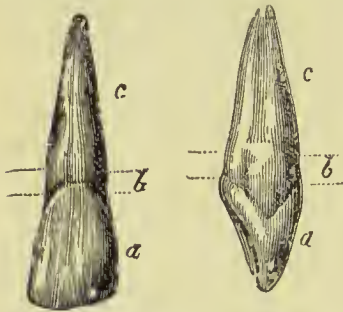


FIG. 416.—Front and side view of a left upper central incisor. a. Crown. b. Neck. c. Fang.

Characters of the Permanent Teeth.—The **incisors** (cutting teeth) are named from presenting a sharp and cutting edge, formed at the expense of the posterior surface. The crown is flattened from before backwards, being somewhat convex in front and concave behind ; the neck is much constricted, and the root compressed from side to side ; at its apex is a small opening for the passage of the nerve and artery of the tooth. The upper incisors are directed a little forwards ; they are larger than the lower, and slightly overlap them. The upper central incisors are much larger than the laterals ; their inner border is a little longer than their outer, and by this character we can distinguish the side to which a particular specimen belongs. In the lower jaw the central incisors are smaller than the lateral, and have their fangs much flattened from side to side. The fangs of the lateral incisors are also flattened, but are longer than those of the central teeth.



FIG. 417.—Lingual, labial, and distal surfaces of an upper canine.

The **canine** teeth (*enspidati*) follow the incisors in order from before backwards ; two are situated in the upper jaw, one at each side, and two in the lower. The crown is larger than that of the in-

cisors, convex before, concave behind, and tapering to a blunted point or cusp. The root is longer than that of all the other teeth, compressed at each side, and marked by a slight groove. The upper canine teeth (called eye-teeth) are longer and larger than the lower, and are situated a little behind and external to them.

The **bicuspid** or **premolar** teeth, two at each side in each jaw, follow the canine, and are intermediate in size between them and the molars. The crown is compressed from before backwards, and surmounted by two tubercles, one internal, the other external, the latter being the largest. The neck is oval; the root is compressed, marked on each side by a deep groove, and bifid near its apex. The teeth of the upper jaw have a greater tendency to the division of their roots than those of the lower, and the posterior than the anterior pair. The lower bicuspids are smaller than the upper; their outer cusp is long and prominent, and is bent inwards; the inner cusp is smaller, and is connected with the outer by a slight ridge.

The **molar** teeth (grinders), three at each side in each jaw, are the largest of the permanent set. The first molar is the largest and



FIG. 418.—Grinding surface of an upper bicuspid.

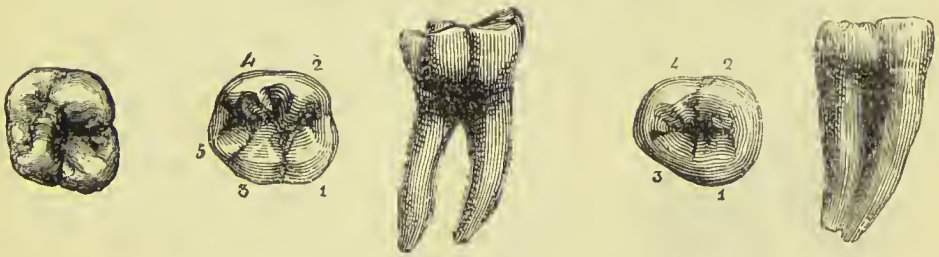

FIG. 419.—Masticating surface of a first upper molar of the left side.

FIG. 420.—Masticating surface and side view of first lower molar of right side. The small figures indicate the five cusps.

FIG. 421.—Masticating surface and side view of second lower molar of right side. The small figures indicate the four cusps.

broadest, and the third is the smallest, so that there is a gradation of size of these teeth. The crown is quadrilateral, and is surmounted by four or five tubercles (four in the upper, five in the lower molars); the neck is large and round, and the root divided into several fangs. In the upper jaw the first and second molar teeth have three roots (sometimes four), more or less widely separated from each other, two of the roots being external, the other internal. In the lower there are but two roots, anterior and posterior, flattened from behind forwards, and grooved so as to mark a tendency to division. The first lower molar has five cusps (Fig. 420), three outer and two inner, the fifth cusp being postero-external; its anterior fang has two pulp cavities. The third molars, or *wisdom-teeth* (*dentes sapientiae*), are smaller than the other two; they present three tubercles on the surface of the crown, and the root is single and grooved, appearing to be made up of four or five fangs compressed together, or partially divided. In the lower jaw the fangs

are frequently separated to some distance from each other, and curved backwards so as to offer considerable resistance in the operation of extraction.

The range of teeth in each jaw forms a pretty uniform curve, without any break or *diastema*, such as occurs to some extent in the *Quadrumana*, and more markedly in the *Rodents* and *Ruminants*.

Characters of the Temporary Teeth.—In general form these resemble the teeth of the permanent set, but they are smaller. The enamel which covers the crown terminates in a more distinct edge than in the permanent teeth, so that the neck is more evidently constricted. The canines are relatively shorter, and their crowns broader than those which succeed them. The second molar is the largest, being, indeed, larger than the second permanent bicuspid which succeeds it. The first upper molar has only three cusps, the second has four; the first lower molar has four and the second five cusps. The fangs are like those of the permanent set, but are smaller and more divergent.

Structure of the Teeth.

If a vertical section be made through a tooth, it will be found to be hollowed out in its interior into a small cavity, the *pulp cavity*, which has a general resemblance in its form to the external configuration of the tooth. It extends upwards a little into the cusps, and is prolonged downwards into the fangs, terminating at the extremity of each of the latter in a small opening which transmits the vessels and nerves. This cavity is filled with a soft, highly vascular, and sensitive substance, called the *dental pulp*, which is continuous through the apertures at the extremity of the fangs with the periosteum on the outside of the tooth.

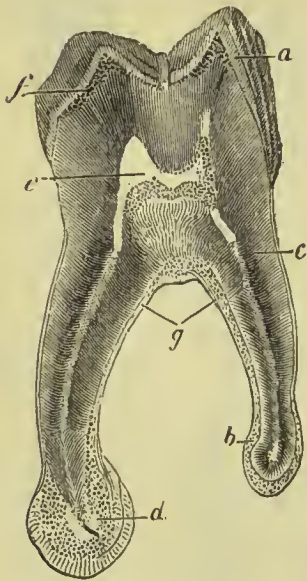


FIG. 422.—Vertical section of molar tooth. *a*. Enamel. *b*, *g*. Cementum. *c*. Dentine. *d*. Osseous excrescence at end of fang. *e*. Pulp cavity. *f*. Lacunar spaces at outer part of dentine.

The solid portion of the tooth is composed of three distinct structures:—(1) The **dentine** or **ivory**, which forms the bulk of the tooth; (2) the **enamel**, which forms a thick covering to the crown; and (3) the **cement**, which covers the fang externally.

The **dentine** (ivory or tooth bone) is a hard substance having some resemblance to bone, but on microscopic examination it appears to consist of very minute, tapering, and branching tubules, embedded in a dense, homogeneous intertubular matrix. These tubules commence by their larger ends in the wall of the pulp cavity, and pursue a radiating and serpentine course towards the periphery of the tooth; they give

off minute branches from their sides, and divide dichotomously as they proceed, so that when they reach the outer layers of

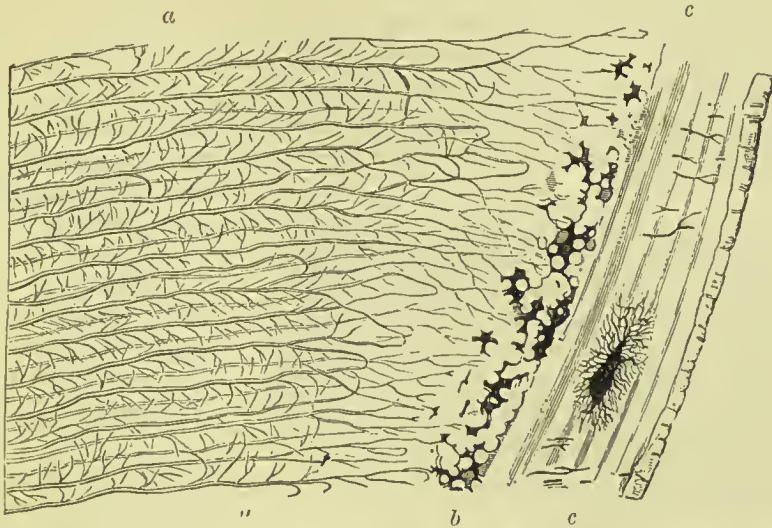


FIG. 423.—Section of dentine in the direction of the tubules. *a.* Dentinal tubules. *b.* Nodular layer. *c.* Cement.

the dentine they have become very numerous and minute. Upon cross section the dentinal tubules appear each to be surrounded

by an annulus of considerable thickness (Fig. 424); but it is probable that this appearance results from the obliquity of the section, by which a certain length of the tubes is seen as well as their extremities. The true wall of the canal can only be seen as a faint yellow ring (*dentinal sheath of Neumann*), and even this is not always

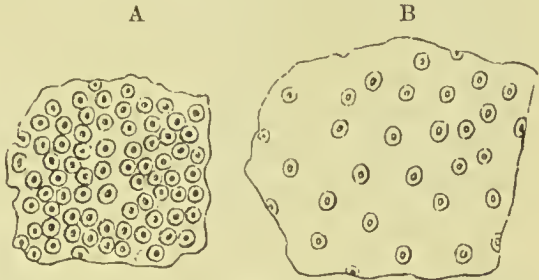


FIG. 424.—Transverse section of dentine, showing the tubules cut across. *A.* in the crown; *B.* in the fang.

manifest. In the recent state the tubules are occupied by a protoplasmic substance (*dentinal fibre of Tomes*), which is continuous with the nucleated cells of the dental pulp, and serves to convey nutritive material to the dentine; it appears also to confer on the latter a certain amount of sensibility. The tubules are most numerous in the crown (Fig. 424, *A*), where they are closely crowded together, while in the fang they are much more scattered, so that here the matrix forms the largest element (Fig. 424, *B*). The matrix of the dentine appears to be perfectly homogeneous, without trace of fibres or granules; when softened by reagents it has a tendency to split up into laminae, but no such lamination is observable in hard sections. The surface of the dentine which is in contact with the enamel is marked by hexagonal depressions, corresponding

to the ends of the enamel fibres. In the fang the outer portion of the dentine—namely, that next the cement—has often a peculiar nodular appearance (Fig. 423, *b*), which results from the incomplete fusion of the calcareous masses when they are deposited. Frequently also we find in this situation irregular lucunar spaces, which are filled with the same protoplasmic material as the dentinal tubules. Similar imperfect calcifications lead to the production of lamination in the dentine above the pulp cavity, and of consequent parallel curved lines in the crown of the tooth called *incremental lines*.

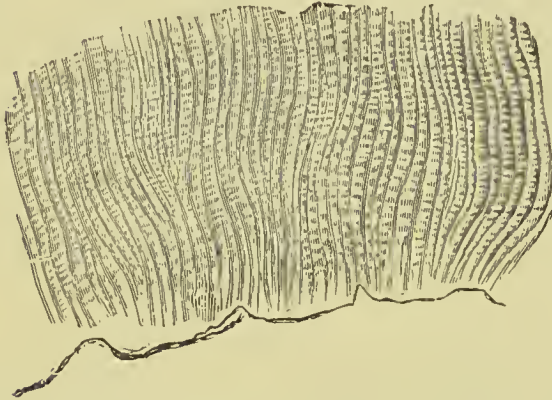

FIG. 425.—Longitudinal section of the enamel, showing the wavy arrangement of the fibres, and the faint transverse striations.

substance in the body ; it contains only about $3\frac{1}{2}$ per cent. of animal matter.

The enamel is composed of minute fibres $\frac{1}{5000}$ th of an inch in diameter, which run in a wavy course from the dentine to the free surface of the crown, and which on cross section are seen to be hexagonal (Fig. 426, A). By their attached

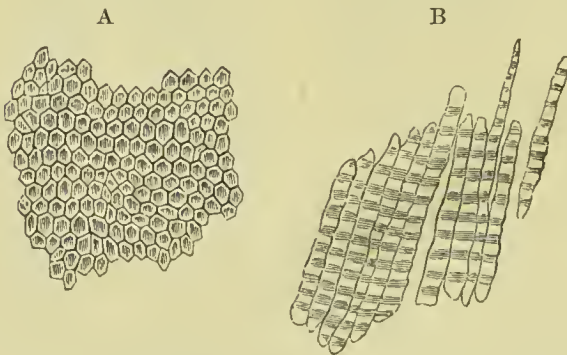


FIG. 426.—A. Transverse section of the enamel, showing the fibres to be irregularly hexagonal. B. Detached enamel fibres, more highly magnified than in Fig. 425.

running in opposite directions. The enamel is covered by a thin membrane (composed of non-nucleated horny scales), which separates from it on the application of hydrochloric acid—this is called the *cuticle of the enamel*, or *Nasmyth's membrane*.

The **enamel** forms a crust over the whole exposed surface of the crown of the tooth to the commencement of its root ; it is thickest on the summit of the tooth, and becomes gradually thinner as it approaches the neck. It is translucent and bluish in thin sections, and is the hardest and most brittle

as existing on the surface of the dentine. The enamel fibres are marked at irregular intervals by transverse lines (Fig. 426, B), which possibly may indicate their formation from aggregated cells, although this is denied by many histologists, who consider them to result from the fibres of superimposed layers

The cortical substance, or **cement**, forms a thin coating over the root of the tooth, from the termination of the enamel to the opening in the apex of the fang. In structure it differs little from true bone, being characterised by the presence of lacunæ and canaliculi (Fig. 423, *c*); but it generally has no Haversian canals, although these also may appear in the cement in old age. It increases in thickness as age advances, and gives rise to those exostosed appearances occasionally seen on the teeth of very old persons, or in those who have taken much mercury. In old age the pulp cavity is often filled up and obliterated by osseous substance analogous to the cement, but bearing also some resemblance to dentine. This is called *osteodentine*; it is traversed by canals which are surrounded by concentric laminae, like the Haversian canals of bone.

The **tooth pulp**, as stated above, is continuous with the periosteum of the alveolus or *alveolo-dental membrane*. On its surface is a layer of fine columnar cells which are in close contact externally with the inner surface of the dentine, and contain oval nuclei at their bases; as they were supposed to be instrumental in the formation of that tissue, they have received the name of "odontoblasts." Some authors state that they give off processes which pass into the dentinal tubules and become continuous with the fibres therein contained. Beneath these, numerous fusiform or pyramidal cells are found, many of which wedge themselves in between the odontoblasts, while others are continuous with the ramified cells of the reticulum to be presently mentioned. Klein believes that it is this deeper cell stratum and not the layer of odontoblasts which sends processes into the dentinal tubules. The cells of the pulp, as well as the blood-vessels and nerves, are supported by a fine reticulum formed by ramified nucleated cells. Numerous non-medullated nerve fibres run through the pulp, some of which have been traced to the layer of odontoblasts, and it is probable that they also pass into the dentine. A dense network of capillaries occupies the outer part of the pulp.

Development of the Teeth.

At the time when the germs of the teeth first make their appearance the lower jaw consists of embryonic tissue, composed chiefly of branched cells, in which a cartilaginous rod, the *cartilage of Meckel*, is embedded. At this period the superior maxillary processes, formed also of embryonic tissue, have just met and united with the pre-maxillary or inter-maxillary processes. In the position of the future alveolar border an upgrowth of epithelial cells produces two narrow ridges arranged in a horse-shoe form; the groove between these ridges (formerly described as the *primitive dental groove*) is almost entirely filled up with cells which are actively growing and rapidly increasing in number. This growth of cells takes a downward as well as an upward course so as to invade the tissue occupying the position of the future jaw, but instead of passing vertically downwards becomes inclined inwards at its lower extremity (see Fig.

427, 1); in cross section this inflection of cells closely resembles a tubular gland. At their deepest point the cells increase in number more rapidly than elsewhere so as to result in the production of expansions taking somewhat the form of Florence flasks; and it is noticeable that while the inflection of cells takes place along the whole

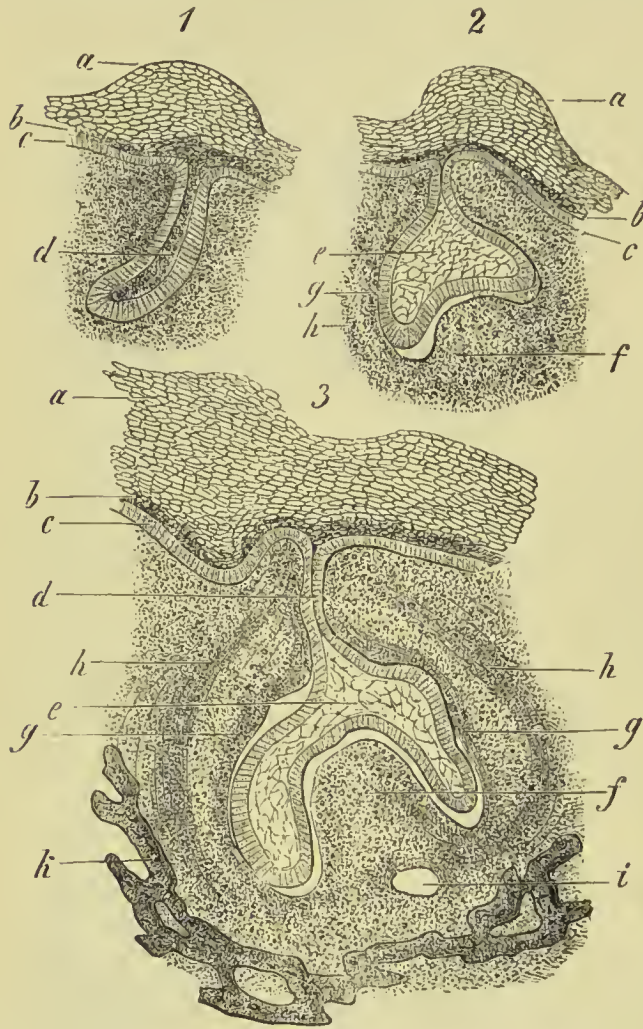

FIG. 427.—Three stages in the development of a mammalian tooth germ. *a*. Oral epithelium heaped up over germ. *b*. Younger epithelial cells. *c*. Deep layer of cells. *d*. Inflection of epithelium for enamel germ. *e*. Stellate reticulum. *f*. Dentine germ. *g*. Inner portion of future tooth sac. *h*. Outer portion of future tooth sac. *i*. Vessels cut across. *k*. Bone of jaw.

lie on its cupped or concave surface become greatly elongated, and their nuclei recede to their bases; the central cells become chiefly converted into a stellate reticulum, the processes of the cells communicating freely with each other, but those which lie in contact with the columnar cells next the dental papilla remain unchanged and form a

circumference of the jaw, the expansions are only produced at those points where teeth are to be developed. The cells of the surface of the enlargements are columnar, those of the interior are polygonal or stellate. By a more rapid downward growth at the sides than in the centre, these processes assume a cupped or bellshape with the concavity directed downwards, and into this concavity the dentinal papilla is received. The expansions have long received the name of *enamel germs*, or *enamel organs*, although much difference of opinion exists as to the part played by them in the production of enamel. The outer cells of the enamel organ either remain unchanged or become slightly atrophied; those which

stratum intermedium. During these changes, and for long after, the epithelium constituting the enamel organ remains connected with that on the surface of the jaw by a narrow process or neck.

The *dentinal papillæ* are first observed as slightly opaque spots at some little distance from the surface and at points corresponding to the flask-like expansions above described; they are almost as early in making their appearance as the latter, but are at first much slower in development, so that the enamel organ is for some time very large in proportion to the dentinal papilla. Not only does the dentinal papilla grow upwards into the cupped cavity formed by the lower part of the enamel germ, but it also gives off lateral processes which pass to the sides of that organ, and by a continuous upward growth come later to enclose it and form the dental sac. At first the dentinal papilla only differs from the rest of the substance of the jaw in being more vascular and containing more cells, but it soon assumes the form of the future tooth, becoming simply conical for a canine, having two cusps for a bicuspid, and four or five for a molar. The cells on the surface of it become distinguished from the rest by their columnar form and close aggregation, so that they form a compact layer, which, from the part it plays in the formation of the dentine, has been named the *membrana eboris*, the individual cells being called *odontoblasts*. These cells are furnished with processes by means of which they communicate with each other, or with the cells deeper in the pulp; some of the processes also pass into the dentine when it is formed, and become continuous with the protoplasm contained in the dentinal tubules.

The enamel germ for the permanent tooth is produced by an outgrowth of epithelial cells from the side of the neck of the enamel organ of the temporary tooth; this passes to the back and inner side of the latter, and undergoes the same changes in shape and composition as have been described above to take place in the germ of the

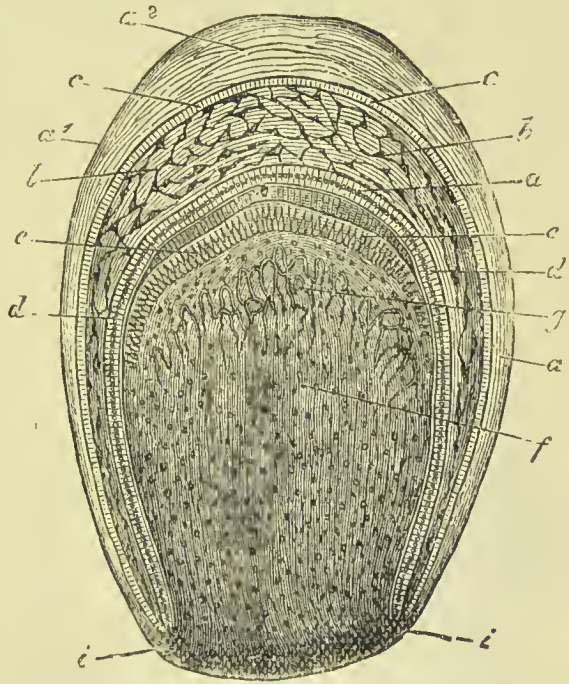


FIG. 428.—Dental sac of a tolerably mature human fetus, partly diagrammatic. *a*¹. Outer layer, and *a*² deeper layer of fibrous wall of sac. *b, b*. Stellate reticulum of enamel organ. *c, c*. Outer cells, and *d, d*, inner cells of enamel organ. *f*. Dental papilla with its capillaries, *g*. *i, i*. Continuation of connective tissue of the parietes of the sac into the dental papilla.

temporary tooth. The dentinal papilla also of the permanent tooth grows up beneath its enamel germ, and, assuming the characteristic shape of the tooth to be formed, has its superficial cells elongated and aggregated so as to form a *membrana eboris*, exactly in the same way as we have traced it in the case of the temporary tooth. The germ of the first permanent molar is formed about the sixteenth week by a down-growth of the epithelium from the surface of the jaw, in the same way as the germ for the temporary teeth originated; the second permanent molar has its germ formed from the neck of the enamel organ of the first molar about the third month after birth. The germ for the wisdom-tooth is formed from the neck of the enamel germ of the second permanent molar about the third year.

Formation of the Hard Tissues.

Enamel.—We have seen that the deeper cells of the enamel organ (those, namely, which are next to the dentinal papilla) become elongated; they also, by their mutual pressure, come to assume the form of elongated hexagonal prisms, and receive the distinctive title of *enamel cells*. A deposition of calcareous salts takes place in these cells, commencing at the end nearest to the papilla, and proceeding towards the centre of the enamel organ. As the process advances, the cells of the *stratum intermedium* assume the same form as the deeper cells, and in process of time become also calcified; the stellate reticulum which forms the great part of the enamel organ seems to take no active part in the formation of the enamel, but, as the latter is formed, becomes progressively reduced in quantity until at length the outer or superficial cells (still epithelial in character, and become flattened) are in contact with the enamel cells. As the latter are hexagonal in form (from mutual compression), the fibres which result from their calcification are necessarily hexagonal prisms. The outer part of the cell is first calcified, the centre later, so that the outer

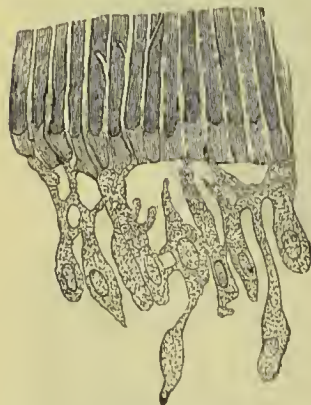


FIG. 429. — Odontoblasts *in situ*.

part of the prismatic fibre is the hardest; and when fracture of the enamel takes place it usually follows the line of the centre of the fibre, this being less perfectly calcified than the periphery.

Dentine.—The cells which form a compact layer on the surface of the dentinal papilla, and are called odontoblasts, become calcified in the same manner as the enamel cells. The calcareous deposit takes place first at the surface nearest to the enamel and passes inwards along the elongated cell; while the outer part of the cell is thus converted into dentine, the inner end continues to grow towards the papilla, and thus each dentinal tubule and its surrounding matrix is formed by the calcification of a single cell, and not, as was formerly supposed, by the union

of several. Most observers agree in stating that the dentinal matrix, dentinal sheaths, and the fibres contained in the tubules, represent three stages of calcification, the matrix exhibiting the completion of the process, the sheaths of Neumann an imperfect calcification, and the fibres being the unchanged protoplasm of the original cell. Klein is, however, of opinion that the fibres contained in the tubules are derived from the processes of the deeper layers of cells, and are not the product of the odontoblasts. The part of the dentinal papilla which is not converted into dentine, remains throughout life as the pulp of the tooth.

Cement.—This is produced by the tissue of the tooth sac, the process being precisely the same as the production of bone beneath periosteum, described on a previous page.

Eruption of Teeth.

When the crown of the tooth has been formed and coated with enamel, and the fang has grown to the bottom of its socket by the progressive lengthening of the pulp, the formation of the dentine, and the adhesion of the latter to the contiguous portion of the sac, the pressure of the socket causes the reflected part of the sac and the edge of the tooth to approach, and the latter to pass through the gum.

The opened sac now begins to shorten more rapidly than the fang lengthens, and the tooth is quickly drawn upwards by the contraction, leaving a space between the extremity of the unfinished root and the bottom of the socket, in which the growth and completion of the fang are effected.

During the changes above described as taking place among the dental sacs contained within the jaws, the septa between the sacs, at first consisting of spongy tissue, gradually become fibrous, and subsequently osseous, the bone being developed from the surface and proceeding by degrees more deeply into the jaws to constitute the alveoli. The necks of the sacs of the permanent teeth, by which they originally communicated with the mucous surface of the gum,

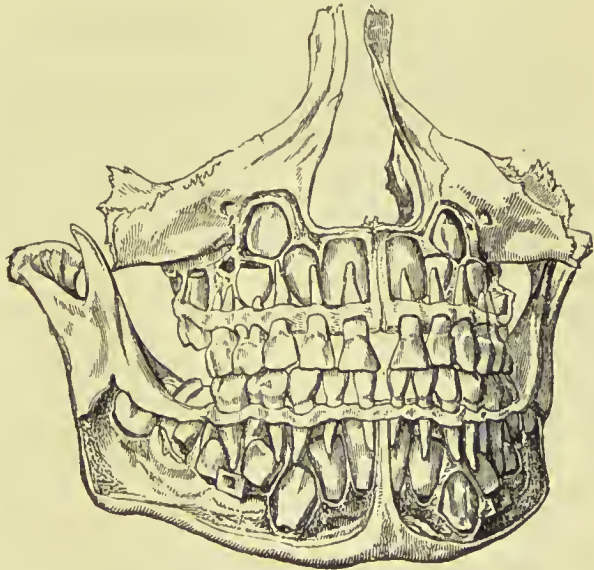


FIG. 430.—Normal well-formed jaws from which the alveolar plate has been removed, so as to expose the developing permanent teeth in their crypts in the jaws.

still exist, in the form of cords, separated from the deciduous teeth

by their alveolus, but communicating through minute osseous canals with the mucous membrane of the mouth immediately behind the corresponding deciduous teeth.

The periods of appearance of the teeth are very irregular; it is necessary, therefore, to have recourse to an average, which may be stated in a tabular form as follows, the teeth of the lower jaw preceding those of the upper by a short interval.

SUCCESSION OF TEETH.

1. *Temporary Teeth.*

	Molar 2	Molar 1	Canine	Incisors	Canine	Molar 1	Molar 2
Months.	24	12	18	9.7.7.9	18	12	24

2. *Permanent Teeth.*

	Molar 3	Molar 2	Molar 1	Premolar 2	Premolar 1	Canine	Incisors	Canine	Premolar 1	Premolar 2	Molar 1	Molar 2	Molar 3
Years.	17-21	12-13	6	10	9	11-12	8.7.7.8	11-12	9	10	6	12-13	17-21

PHARYNX.

The pharynx (*φάρυγξ*, the throat) is a musculo-membranous sac, about four and a half inches in length, situated on the cervical portion of the vertebral column, and extending from the base of the skull to a point corresponding with the cricoid cartilage in front and the upper border of the sixth cervical vertebra behind. It is widest opposite the hyoid bone, and narrowest where it terminates in the œsophagus. It is composed of mucous membrane, muscles, and a strong aponeurosis; and communicates in front with the cavity of the nose, mouth, and larynx. Above, it is attached partly by muscle, but chiefly by aponeurosis, to the basilar process of the occipital bone and petrous portion of the temporal bone; and below, it is continuous with the œsophagus. It is loosely connected by areolar tissue with the prevertebral fascia behind, and with the styloid process and muscles and the carotid sheath on each side. Its central attachment above is by means of a strong band having its origin from the pharyngeal tubercle on the occipital bone, and passing down between the recti antici muscles to terminate in the pharyngeal aponeurosis; this band has been termed by Cleland the *cranio-pharyngeal ligament*.

The **pharyngeal aponeurosis** is a strong sheet of fascia placed between the mucous membrane and muscles of the pharynx; it is

strong and thick above, but thins as it passes downwards, and at the lower part of the pharynx is distinguishable only as a layer of diffuse areolar tissue.

The **mucous membrane** varies greatly in its character in different parts of the pharynx; it is thick where it clothes the base of the skull, but thinner in the neighbourhood of the Eustachian tube, and near the posterior nares; in the latter situations numerous racemose glands are seated in the submucous tissue, and pour

their secretion on to the surface of the membrane. Lymphoid tissue is everywhere abundant, and at the back part of the pharynx, forms a glandular mass stretching across between the openings of the two Eustachian tubes, which receives the name of the *pharyngeal tonsil*. In the middle line, near the base of the skull, there is in the young child a small recess in the mucous membrane, called the *bursa pharyngea*; it sometimes remains permanent throughout adult life.

At its anterior part the pharynx has opening into it seven foramina, viz:—

Posterior nares, two,
Eustachian tubes, two,
Mouth,

Larynx.
Œsophagus.

The **posterior nares** are the two large openings at the upper and front part of the pharynx. On each side of these openings, and parallel with the posterior termination of the inferior turbinated bone, is the depression in the mucous membrane, marking the aperture of the **Eustachian tube**. It is bounded above and internally by a prominent ridge, formed by the margin of the cartilage, covered by thick mucous membrane. Between the opening of the Eustachian tube and the back of the pharynx is a somewhat triangular depression, which has been named the *fossa of Rosenmüller*. Beneath the posterior nares is the isthmus faucium, the large opening into the **mouth**, partly veiled by the soft palate; and beneath the root of the tongue, the cordiform opening of the **larynx**. The **œsophageal** opening is the lower constricted portion of the pharynx.

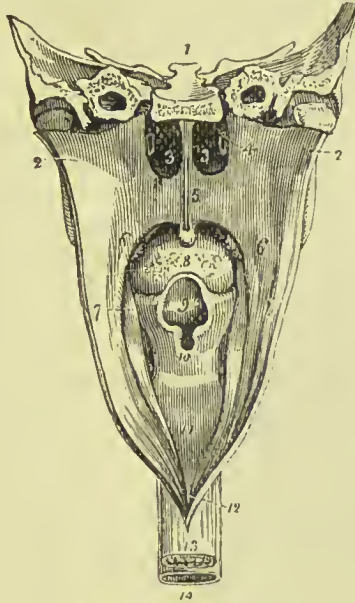


FIG. 431.—Pharynx laid open from behind. 1. Section carried transversely through the base of the skull. 2, 2. Walls of the pharynx drawn aside. 3, 3. Posterior nares, separated by the vomer. 4. Extremity of one Eustachian tube. 5. Soft palate. 6. Posterior pillar of the soft palate. 7. Anterior pillar; the tonsil is seen in the niche between the two pillars. 8. Root of the tongue, partly concealed by the uvula. 9. Epiglottis, overhanging (10) the cordiform opening of the larynx. 11. Posterior part of the larynx. 12. Opening of the œsophagus. 13. Œsophagus. 14. Trachea.

ŒSOPHAGUS.

The œsophagus (*οἴσω*, to bear ; *φάγω*, to eat) is a slightly flexuous canal, inclining to the left in the neck, to the right in the upper part of the thorax, and again to the left in its course through the posterior mediastinum ; it commences at the termination of the pharynx, opposite the lower border of the cricoid cartilage and upper border of the sixth cervical vertebra, and descends the neck, behind and rather to the left of the trachea. It then passes behind the arch of the aorta and left bronchus, and along the posterior mediastinum, lying in front of the thoracic aorta ; at the lower part of

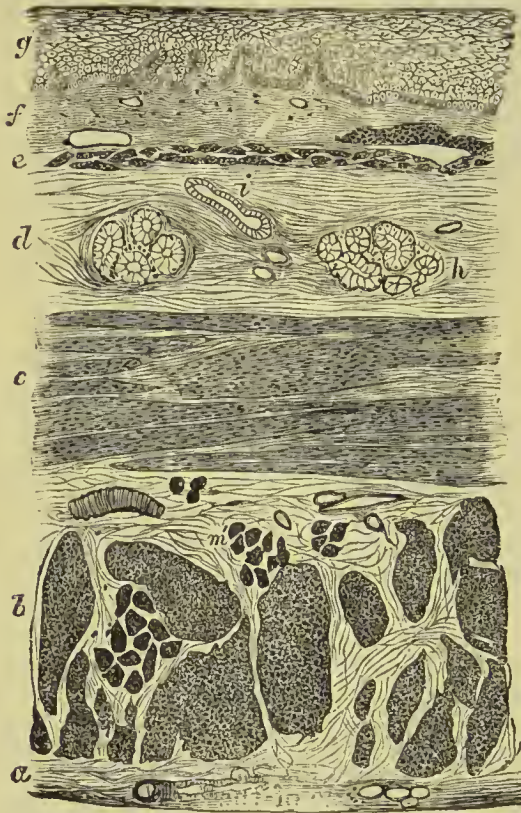


FIG. 432.—Transverse section of œsophagus. *a.* Outer fibrous covering. *b.* Longitudinal muscular fibres. *c.* Circular muscular fibres. *d.* Submucous coat. *e.* Muscularis mucosæ. *f.* Mucous membrane. *g.* Stratified epithelium. *h.* Racemose gland. *i.* Section of an artery.

the thorax it lies slightly to the left of the aorta, and passing through the œsophageal opening in the diaphragm enters the abdomen, and terminates at the cardiac orifice of the stomach opposite the lower border of the tenth dorsal vertebra. As it follows the curves of the vertebral column, it presents in its upper part an antero-posterior flexure. It is about nine or ten inches in length, is narrowest at its commencement, and is also slightly constricted where it passes through the diaphragm. In the relaxed condition its mucous membrane assumes the condition of longitudinal folds, which lie in contact with each other ; when distended the folds disappear.

Relations.—*Behind*, it lies upon the longus colli muscles and vertebral column, in the middle of the thorax upon the thoracic duct, and at the lower part upon the thoracic aorta. *In front*, it has the trachea, left bronchus, and pericardium. *At the sides*, the recurrent laryngeal nerves, carotid sheaths, thyroid body, and pleural sacs. As it deviates to the left in the lower part of the neck, it has more intimate relation with the left carotid sheath than with the right. The vagus nerves lie at first on each side of the œsophagus, but they form a plexus around it (*plexus gulæ*), and the left nerve

gradually passes round to the front and the right to the back. The vena azygos major is in relation with its right side in the thorax.

Structure.—The œsophagus is formed of three coats—an *outer*, muscular; a *middle*, submucous or areolar; and an *inner*, mucous. External to the muscular coat there is, however, a layer of areolar tissue, containing many elastic fibres. The **muscular coat** consists in its upper part of striped fibres, but these gradually pass, about its middle, into the unstriped variety, and in its lower part the latter form only is found. The fibres are arranged in an outer *longitudinal*, and an inner *circular* layer; the *longitudinal fibres* are in the upper part of the tube disposed in three fasciculi, two lateral, which are continuous with those of the inferior constrictor, and one anterior which is attached to the vertical ridge of the cricoid cartilage. The *circular fibres* are attached superiorly to the cricoid cartilage; they are transverse in their arrangement, above and below, but spiral in the middle of the œsophagus. Below, both sets of fibres are continuous with those of the stomach. A band of unstriped muscle is frequently found passing from the left pleura to the œsophagus, and occasionally a similar band from the left bronchus. The **submucous coat** loosely connects the mucous and muscular coats; it is thicker than the latter, is composed of areolar tissue containing many elastic fibres, and has embedded in it the glands which open on to the surface of the mucous membrane. The **mucous membrane** is pale in colour, but of firm texture. It is studded over with a number of very fine papillæ, and is covered by a stratified epithelium. A number of racemose glands situated in the submucous tissue, open by short ducts on to its surface. Between it and the submucous layer is a thin stratum of unstriped muscle, the fibres of which are for the most part longitudinally disposed, and have been named the *muscularis mucosæ*.

THE STOMACH.

The stomach is an expansion of the alimentary canal, situated in the left hypochondriac and epigastric regions. The hypochondriac part forms fully three-fourths of the organ; it is vertical in direction, and the fundus extends to the highest limit of the region. The epigastric part is transverse in direction, and lies about three fingers' breadth below the ensiform cartilage (Cunningham). On account of the peculiarity of its form, it is divided into a middle part or *body*, a *greater* or *splenic*, and a *lesser* or *pyloric end*; a *lesser curvature* above, and a *greater curvature* below; an *anterior* and a *posterior surface*; a *cardiac orifice*, and a *pyloric orifice*. The great end (fundus) is not only of large size, but expands beyond the point of entrance of the œsophagus, and is embraced by the concave surface of the spleen; it presents superiorly a funnel-shaped expansion, leading to the cardiac orifice. The pylorus (janitor) is the small and contracted extremity of the organ; it is situated on a plane anterior and inferior to the cardiac orifice, and lies in contact with the under surface of the

liver, often reaching to the gall-bladder. It would be pierced, when the stomach is empty, by a needle passing through the abdominal wall five cm. below the junction of the seventh right costal cartilage with the sternum (A. M'Alister). Near the lesser end is a dilatation, the *antrum of the pylorus*. The two curvatures give attachment to the peritoneum; the upper curve to the lesser omentum, the lower to the great omentum. The anterior surface looks upward and forward, and is in relation with the diaphragm (which separates it from the viscera of the thorax and six lower ribs), with the left lobe of the liver, and in the epigastric region with the abdominal parietes. The posterior surface looks downwards and backwards, and is in relation with the diaphragm, pancreas, third portion of the duodenum, transverse meso-colon, left kidney, and left supra-renal body; this

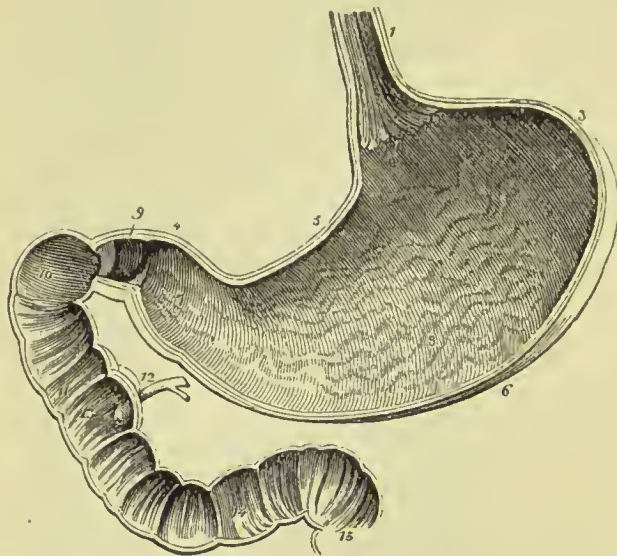


FIG. 433.—Vertical and longitudinal section of the stomach and duodenum, made so as to include the two orifices of the stomach. 1. Œsophagus; on its internal surface the plicated arrangement of the mucous membrane is shown. 2. Cardiac orifice of the stomach, around which the serrated border of the epithelium is seen. 3. Great end of the stomach. 4. Lesser or pyloric end. 5. Lesser curve. 6. Greater curve. 7. Antrum of the pylorus. 8. Rugæ formed by the mucous membrane. 9. Pylorus. 10. Ascending portion of the duodenum. 11. Descending

portion. 12. Pancreatic duct and common bile duct close to their termination. 13. Papilla upon which the ducts open. 14. Transverse portion of duodenum. 15. Commencement of jejunum. In the interior of the duodenum and jejunum, the *valvula conniventes* are seen.

surface forms the anterior boundary of that cul-de-sac of the peritoneum which is situated behind the lesser omentum and extends into the great omentum. In a state of distension, as after a meal, the anterior surface becomes superior, and the greater curvature is directed forwards against the abdominal parietes. The stomach is a little larger in the male than in the female, and in the former measures about twelve inches in length, and four or five inches in width at its broadest part. When moderately full it is capable of holding from five to ten pints of fluid.

Connections.—By its *upper border* it is connected with the liver by the lesser omentum, and with the diaphragm by the gastro-phrenic ligament; by its *lower border* it is connected with the transverse colon by the great omentum. The *great end* is in close connection

with the spleen, the bond of union being the gastro-splenic omentum, and its *posterior surface* is connected with the left crus of the diaphragm by means of peritoneum. It is fixed at the cardiac end by the union of the œsophagus with the diaphragm, while at the pyloric end the limitation of its movement depends on the fixation of the descending portion of the duodenum.

Structure of the Stomach.—The stomach has four coats—viz., serous, muscular, submucous, and mucous.

The **serous** coat is derived from the peritoneum and completely invests it, except at the upper and lower borders, where the anterior and posterior layers are separated by a very small interval, in which run the gastric and gastro-epiploic arteries, and at the back part where it lies upon the left crus of the diaphragm.

The **muscular** coat consists of unstriped fibres arranged in three layers. The most external are *longitudinal*, and extend from the œsophageal to the pyloric orifice. They are continuous with the longitudinal fibres of the œsophagus, and are scattered over the back and front of the organ, but collected into strong bundles along the two borders. The middle layer is disposed in *circles*, which commence at the left extremity, and continue along the whole body of the stomach to the pylorus, where they are gathered into a muscular ring, which forms the contractile part of that outlet. They are very thin at the great end of the stomach, but get thicker and more distinct as they approach the pylorus. Some *oblique* fibres, continued from the circular fibres of the œsophagus, form a partial layer within the two former. They are continued from the circular fibres at the cardiac orifice, and spread out on the left of it; some of them having nearly the same direction as the circular fibres, with which, indeed, many become continuous.

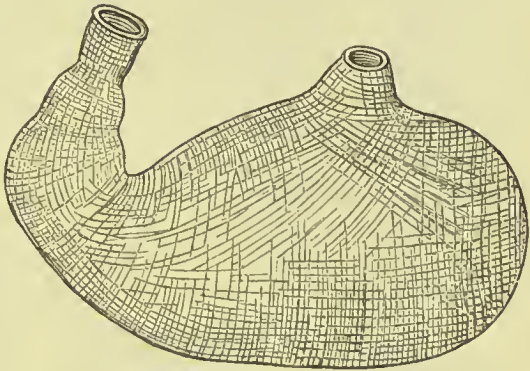


FIG. 434.—Diagram of the muscular coat of the stomach, showing the circular, oblique, and longitudinal fibres.

The **submucous** areolar tissue forms a third coat. It is loose and filamentous in structure, so that the next coat is comparatively feebly attached to the muscular coat. In it the blood-vessels, nerves, and lymphatics are distributed.

The **mucous membrane** of the stomach is soft and loose, thinner at the cardiac than at the pyloric end, and of a greyish or pinkish-grey colour. It is redder in infancy than in the adult. It is so loosely connected to the muscular coat that when the stomach is distended it has a smooth, even, mucous lining; but when contracted the membrane is thrown into folds, or **rugæ**. These folds, though not permanent, always when present assume one direction, that next

the pylorus being disposed circularly, those over the rest of the interior longitudinally. The circular fold at the pylorus along with the muscular ring, constitutes the **pyloric valve**.

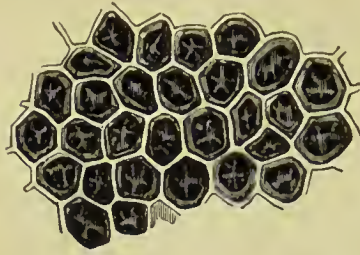


FIG. 435.—Portion of the mucous membrane of the stomach, showing the polygonal alveoli, and at the bottom of these the openings of the gastric follicles.

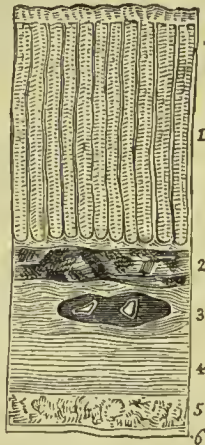
The surface of the mucous membrane is covered with small depressions called **alveoli**, of a polygonal form, averaging $\frac{1}{150}$ of an inch in diameter. They are deeper, more marked, and more numerous near the pylorus. In the bottom of each alveolus, and in the mucous membrane between them, are to be seen minute circular orifices of tubular glands. Four or five open into each alveolus. The **gastric follicles**,

as they are called, are small tubes arranged perpendicularly to the mucous surface, their closed extremities resting against the submucous tissue.

They are more numerous and longer at the pyloric than at the cardiac end of the stomach, and in the former situation are frequently divided at their deep extremities so as to form compound follicles. They vary in length from $\frac{1}{80}$ to $\frac{1}{50}$ of an inch, and in width from $\frac{1}{500}$ to $\frac{1}{360}$ of an inch. Two kinds of glands may be distinguished ; the first (which, it is believed, simply secrete mucus) are called

mucous glands ; they are most numerous near the pylorus, and are therefore sometimes termed **pyloric glands**. The second kind are named **cardiac glands**, from the part of the stomach where they are most found ; as they are supposed to be specially engaged in the secretion of the gastric juice, they have also been named **peptic glands**. In both there is a basement membrane formed by flattened cells joined edge to edge, and from

FIG. 436.—Perpendicular section of the stomach in the pyloric region, showing its coats and the gastric glands ; from the fig. 1. Gastric glands. 2. Muscularis mucosæ. 3. Submucous coat, in which a vessel has been divided. 4. Transverse fibres of the muscular coat. 5. Longitudinal fibres of the muscular coat. 6. Serous coat.



which processes spring, some to join the cells of the retiform tissue of the mucous membrane, and others to penetrate between the epithelial cells which line the glands. The lining cells differ in their character and arrangement in the two kinds of glands ; in the mucous glands they are throughout of the columnar variety, similar to those covering the surface of the mucous membrane, the only change observable in them being that in the deeper part of the gland they become cubical in form instead of elongated. In the cardiac glands the columnar epithelium is found only in the upper part (neck) of the gland, the deeper cells being spher-

roidal or oval, and coarsely granular (*parietal or oxyntic cells*); towards the bottom of the gland, however, the parietal cells do not form a continuous layer, but only occur here and there, the intervals between them being filled up with polyhedral, finely granular cells (*central cells*). Between the glands the mucous membrane consists of connective tissue with a considerable amount of lymphoid tissue.

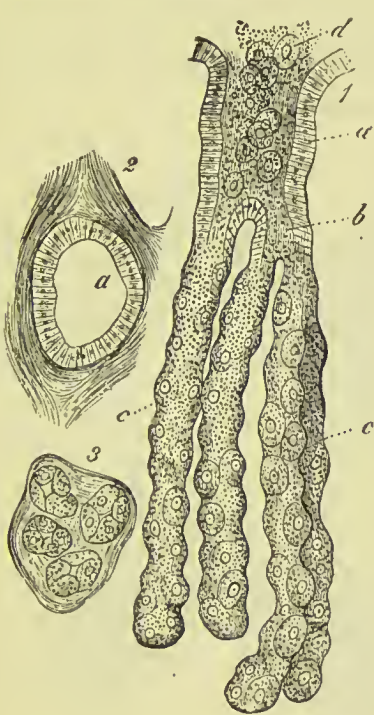


FIG. 437.—A compound peptic gland. 1, *a*. Wide entrance lined with columnar epithelium. *b*. Division. *c, c*. Tubules lined with peptic cells. *d*. Contents of peptic gland in process of being thrown out. 2. The opening *a* seen in transverse section. 3. Transverse section through the deep part of the glands.

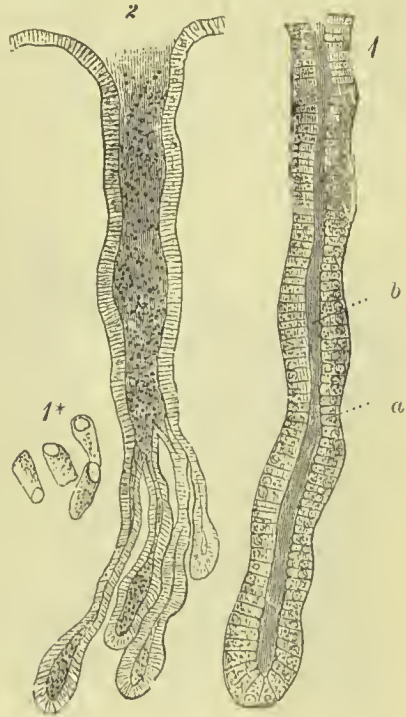

FIG. 438.—Gastric mucous glands. 1. Single mucous gland, lined by columnar cells, *a*. *b*. Lumen of gland. 1*. Columnar epithelium. 2. A compound mucous gland.

Between the mucous membrane and submucous tissue a small quantity of mstriped muscular fibre is found, forming the *muscularis mucosæ*.

The **nerves** of the stomach are derived from the vagus nerves and the solar plexus; small ganglia are found in their course, and they form a plexus in the muscular coat (*plexus myentericus*), and a second one in the submucous coat.

SMALL INTESTINES.

The small intestine, *intestinum tenue*, is about twenty to twenty-five feet in length, and is divisible into three portions, *duodenum*, *jejunum*, and *ileum*.

The **duodenum** (called δωδεκάδακτυλον by Herophilus), larger and more deeply seated than the rest of the small intestine, has received its name from being about equal in length to the breadth of twelve fingers (eight or ten inches). In its course it presents a horse-shoe curve; commencing at the pylorus, it ascends *obliquely* backwards to the under surface of the liver; it next descends *perpendicularly* in front of the right kidney as low as the fourth lumbar vertebra, and then passes nearly *transversely* across the third lumbar vertebra; terminating in the jejunum at the left side of the second lumbar vertebra, where it is crossed by the superior mesenteric artery and

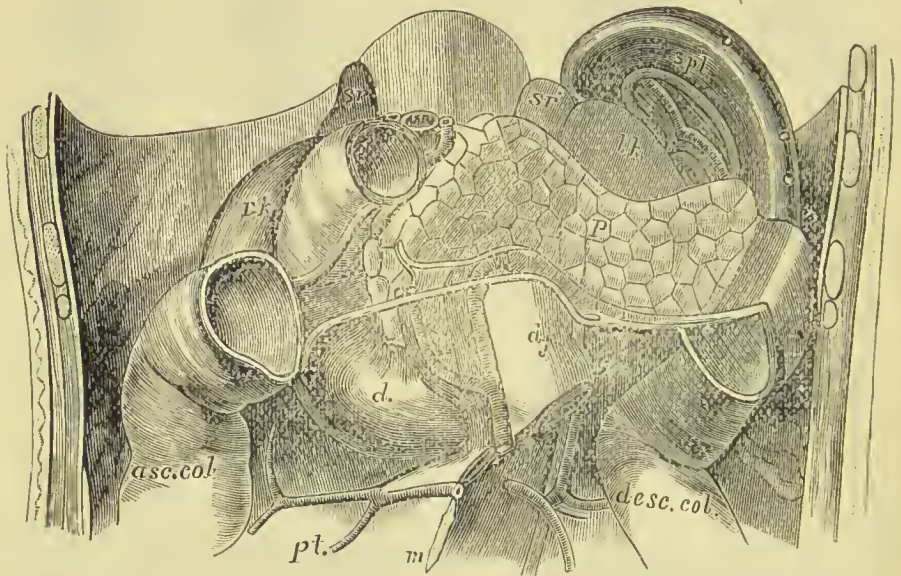


FIG. 439.—View of part of the abdominal viscera, showing the relations of the pancreas and duodenum. *p.* Pancreas. *d.* Duodenum, *d.j.* Duodenum becoming jejunum. *asc. col.* Ascending colon. *desc. col.* Descending colon. *m.* Mesentery. *spl.* Spleen. *sr.* Right, and *sr.* left suprarenal body. *r.k.* Right kidney. *l.k.* Left kidney. *pt.* Formation of portal vein.

vein. The part of the duodenum which joins the jejunum is sometimes described as the second ascending portion (J. Yule Mackay). The duodenum is the most fixed portion of the small intestine.

The **first** or **ascending portion** of its course, between two and three inches in length, is completely enclosed by the peritoneum: it is in relation, *above* with the liver and neck of the gall-bladder; *in front* with the great omentum and abdominal parietes; and *behind* with the right border of the lesser omentum and its vessels.

The **second** or **descending portion** is situated altogether behind the peritoneum: it is in relation by its *anterior surface* with the commencement of the arch of the colon; by its *posterior surface* with the concave margin of the right kidney, the inferior vena cava, and common bile duct; by its *right border* with the ascending colon; and by its *left border* with the pancreas. The common bile duct

and pancreatic duct open into the internal and posterior side of the perpendicular portion, a little below its middle.

The **third or transverse portion** of the duodenum, the longest and narrowest of the three, lies behind the diverging layers of the transverse meso-colon, with which and with the stomach it is in relation *in front*; *above*, it is in contact with the lower border of the pancreas, the superior mesenteric artery and vein being interposed; and, *behind*, it rests on the inferior vena cava, left renal vein, the two crura of the diaphragm, and aorta.

The extremity of the duodenum is held in place by a band of non-striated muscle and connective tissue, which descends to it from the cœliac axis and left crus of the diaphragm, and is named the *musculus suspensorius duodeni*.

The **jejunum** (*jejunus*, empty) is named from being generally found empty. It forms the upper two-fifths of the small intestine; commencing at the bend of the duodenum, on the left side of the second lumbar vertebra, and terminating in the ileum. It is wider and thicker than the rest of the intestine, has a pinkish tinge from containing more mucous membrane than the ileum, and is situated in the umbilical and left iliac regions.

The **ileum** (*εἰλεον*, to twist, to convolute) includes the remaining three-fifths of the small intestine. It is somewhat smaller in calibre, thinner in texture, and paler than the jejunum; but there is no mark by which to distinguish the termination of the one or the commencement of the other. It is situated in the umbilical and hypogastric regions and pelvic cavity, and terminates in the right iliac fossa, by opening at an obtuse angle into the commencement of the colon.

The jejunum and ileum are surrounded, above and at the sides, by the colon; in front they are in relation with the omentum and abdominal parietes; they are retained in position by the mesentery, which connects them with the posterior wall of the abdomen; and below they descend into the cavity of the pelvis. At about the lower third of the ileum a pouch-like process or diverticulum of the intestine is occasionally seen. This is a vestige of embryonic structure, and results from the obliteration of the omphalo-mesenteric or vitelline duct at a short distance from the cylinder of the intestine.

Structure of the Intestinal Canal.

The intestinal canal, like the stomach, has four coats—*serous*, *muscular*, *submucous*, and *mucous*.

SEROUS COAT.—The serous layer of the small intestine is formed by the peritoneum.

The **first or ascending portion of the duodenum** is completely covered by the serous membrane, with the exception of the points of attachment of the omenta. The **descending portion** has only a partial covering on its anterior surface, derived from the right meso-

colon. The **transverse portion** is also behind the peritoneum, being situated behind the two layers of the transverse meso-colon. The rest of the **small intestine** is completely invested by it, excepting along the concave border, to which the mesentery is attached.

MUSCULAR COAT.—The muscular coat of the small intestine is composed of two planes of unstriped muscular fibres, external or *longitudinal*, and internal or *circular*.

The muscular coat is thicker in the duodenum and jejunum than in the ileum; the *longitudinal fibres* are most numerous along the free border of the intestine; and the *circular fibres* are more or less oblique in direction. At the termination of the ileum the circular fibres are continued into the two folds of the ileo-cæcal valve, while the longitudinal fibres pass onwards to the large intestine.

SUBMUCOUS COAT.—The *submucous* or *areolar coat* is a moderately thick stratum of areolar tissue which sustains the vessels, nerves, and glands of the mucous membrane, and connects it to the muscular coat; it is thin and dense in the œsophagus; thicker and more distinct in the stomach; and thicker than the other coats in the small intestine, where it is loose in texture, devoid of fat, and easily distended with air, excepting at Peyer's glands, where it is closely adherent. It is also thicker in the upper part of the small intestine than below, and is one cause of the greater thickness of the duodenum and jejunum; moreover, it enters into the structure of the *valvulæ conniventes*.

MUCOUS COAT.—In the small intestine the mucous membrane is thinner than in the stomach; it is smooth in the upper fourth of the *duodenum*, but raised into crescentic folds, **valvulæ conniventes** (valves of Kerkring), in its lower three-fourths; the *valvulæ conniventes* being continued throughout the jejunum, and extending



Fig. 440.—Valvulæ conniventes of the jejunum.

as far as the middle of the ileum. On the posterior and inner side of the descending portion of the duodenum is a longitudinal ridge or crest, *plica longitudinalis*, about an inch in length, caused by the oblique passage, through the walls of the intestine, of the common bile duct; and at the lower and most prominent part of this crest is the aperture of termination of that duct and the pancreatic duct. The *valvulæ conniventes* are narrow at their commencement, but quickly become larger; and at the lower part of the duodenum and upper part of the jejunum, where they are largest, have a breadth of several lines. In the lower part of the jejunum and upper

part of the ileum they become narrower and more scanty, and are finally lost altogether at about the middle of the latter. Each fold or valve extends for about one-half or three-fourths around the cylinder of the intestine; and as they spring from all sides of its circumference, they have the appearance of circular septa. The jejunum owes its considerable thickness to these valves; and as they are small in the upper half of the ileum and wanting in its lower half, the thinness of the latter is due to their absence. The *valvulae conniventes* differ from the *rugae* described as present in the stomach, in that they are not obliterated when the wall of the canal is put on the stretch.

The mucous membrane of the small intestine is lined on its inner surface by a single layer of columnar epithelial cells; on its deep aspect it is bounded by a layer of unstriped muscular fibre forming the *muscularis mucosæ*.

Villi and Glands.—Besides the larger folds on the mucous membrane, there are certain more minute structures, which can

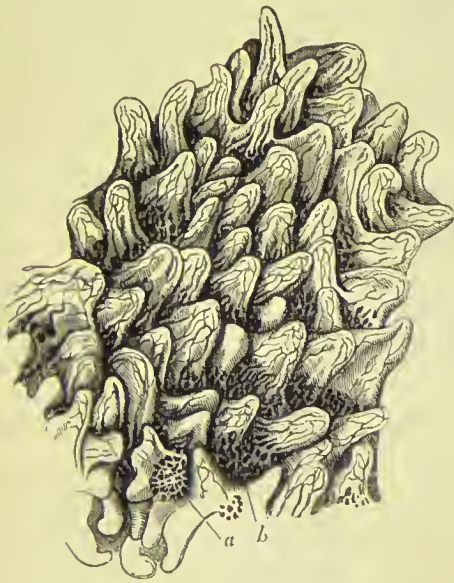

FIG. 441.—Mucous membrane of the small intestine, showing villi. In the hollows between the villi are seen the apertures of Lieberkühn's follicles (*b*); and near the bottom of the figure is a zone of follicles (*a*), surrounding a solitary gland.

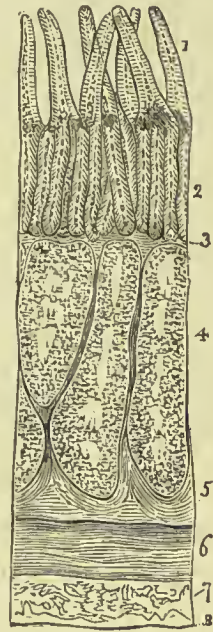


FIG. 442.—Section of the lower part of the ileum of the calf, through a Peyer's patch. 1. Villi. 2. Lieberkühn's follicles. 3. Muscularis mucosæ. 4. Peyer's patch. 5. Deep portion of the submucous coat. 6. Circular layer of the muscular coat. 7. Longitudinal layer of the muscular coat. 8. Serous coat.

only be well studied by microscopic observation. They are the intestinal villi, Lieberkühn's follicles, Brunner's glands, the solitary glands, and Peyer's patches.

The **villi** are little conical or club-shaped projections, about one-fourth of a line in length. They are confined to the small intestine, and are so thickly set, especially at the upper part of the tube, that they resemble the nap of velvet, and give rise to the villous or velvety appearance presented by a well-washed piece of intestine suspended in water. They are largest and most numerous in the duodenum and jejunum, and number from 10 to 18 to the square millimetre; they are fewer and less numerous in the ileum, being only 8 to 14 to the millimetre. In structure each villus consists of a process of the basement membrane, which is covered with a layer of columnar epithelial cells. In its interior are contained a network

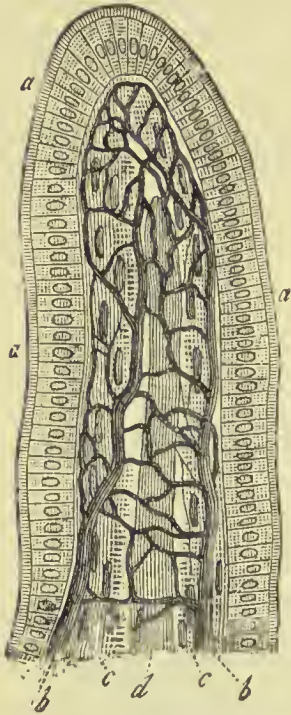


FIG. 443. — An intestinal villus. *a, a, a.* Columnar epithelium. *b, b.* Capillary network. *c, c.* Longitudinal muscular bundles. *d.* Lymphatic capillary.

of capillaries, lymphoid tissue, connective tissue, and a small lacteal vessel, the latter being the agent for the selective absorption of nutriment. The lacteal lies in the centre, and has connected with it the cells of the lymphoid tissue, which again lie in contact with the basement membrane, through which they are in immediate relation with the epithelial cells. Through this channel the nutritive materials taken up by the epithelial cells are transmitted to the lacteal, though in what precise method has not yet been determined. Each villus contains some fibres of unstripped muscle prolonged into it from the muscularis mucosæ.

Lieberkühn's follicles are minute tubules about $\frac{1}{20}$ of a line in length, somewhat like the gastric follicles, but smaller. They are found all over the surface of the small intestine, between the villi, and forming circles round the nodules of Peyer's patches. They are composed of an involution of the basement membrane, and their epithelium is columnar.

Brunner's Glands. — These **racemose** or **lobulated glands** are small yellowish and flattened glands, each surrounded by a small capsule of areolar tissue, and situated in the submucous coat of the alimentary canal. They are identical in structure with the racemose glands of the mouth, and open on the surface of the mucous membrane by means of an excretory duct. They are confined to the **duodenum**, extending from the pylorus, where they are most abundant, to the entrance of the ductus communis choledochus. Von Brunn compared them to a second pancreas, and after him they have been named *Brunner's glands* or *duodenal glands*. Their average size is a quarter to half a line, and they secrete a clear alkaline

mucus, in which no formed elements, such as cells or nuclei, are present.

Solitary Glands.

—These glands (*glandulæ solitariae*) are called also, from the shape of their sac, *lenticular* and *vesicular*. In structure they consist of spheroidal masses of retiform or lymphoid tissue, the interstices of which are crowded with lymph cells; each mass is surrounded by a very fine capillary plexus. The sacculi are embedded in the substance of the mucous membrane, by which they are surrounded on all sides, and they form a prominence on the surface, which in the small intestine is studded with villi.

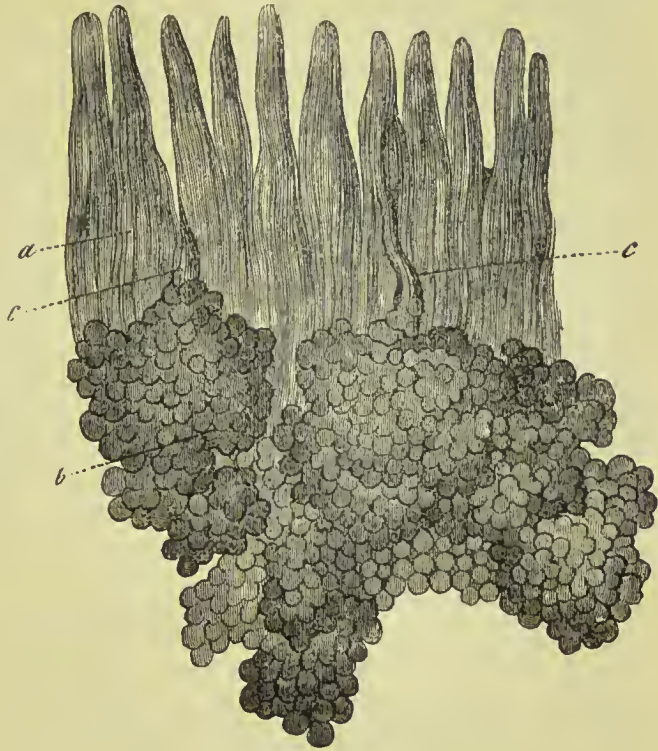


FIG. 444.—Brunner's glands from the duodenum. *a*, Villi. *b*, Bodies of the glands. *c*, *c*, Excretory ducts opening between the villi.

The solitary glands are met with in every part of the cylinder of

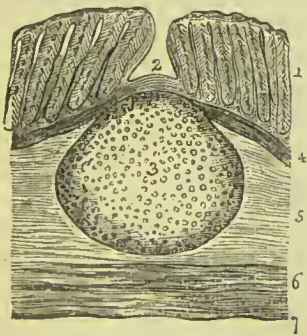


FIG. 445.—Solitary gland from the colon of a child, as shown in a section of the intestine. 1. Lieberkühn's glands. 2. Depression on the surface of the membrane corresponding with the central prominence of the gland. 3. The gland. 4. Muscular layer of the mucous coat. 5. Submucous coat. 6. Muscular coat. 7. Serous coat.

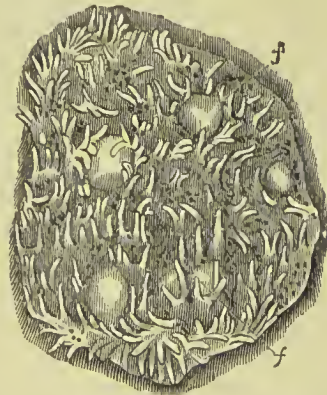


FIG. 446.—Surface aspect of a portion of the intestinal mucous membrane, showing the solitary glands, *f*, *f*, and the villi.

the bowel, sometimes singly and sometimes in groups, and more

numerously in the jejunum than in the ileum. They are also found in the large intestine.

Peyer's Glands or **patches** (*glandulæ agminatæ*) are confined to the jejunum and ileum, being larger and more numerous in the lower part of the latter. To the naked eye they appear as oval patches on the mucous membrane, of about from one to three inches in length, and about an inch in breadth. They are paler in colour than the surrounding membrane, and are somewhat raised above the general level. They run in the direction of the length of the intestine, and are generally found on the side opposite to the attached border. On more close inspection they are found to be formed of a

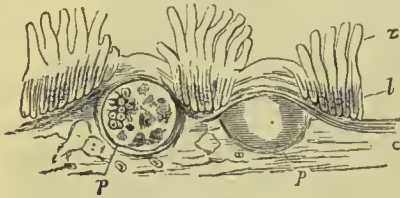


FIG. 447.—Vertical section of the intestinal mucous membrane, bringing into view two Peyerian bodies. *z*. Villi. *l*. Follicles of Lieberkühn. *c*. Submucous coat. *p*, *p*. Peyerian nodules, one of them shown in section, the other not cut open.

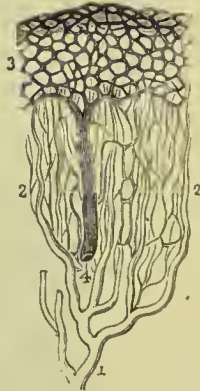
collection of solitary glands in close proximity to each other; hence their name, "aggregate glands." The surface mucous membrane in which they are embedded is free from villi, and the Lieberkühn follicles are arranged in circles around each nodule. The patches vary from twenty to forty in number.

Vessels of the Mucous Coat.—

The distribution of the finer arterial vessels and capillaries in the mucous membrane of the intestinal canal, in relation to the glands, is worthy of attention. The small arteries divide into fine capillaries in the

submucous coat; these fine capillaries enter the spaces between the tubular glands, and form by their communications a plexus around the glands, in their course to the surface. Having reached the surface of the mucous membrane, the capillaries become increased in size, and form a horizontal plexus around the apertures of the glands, and these larger capillaries, taking a retrograde course, unite to form small venous trunks, by which the

FIG. 448.—Circulation in the mucous membrane of the intestine. *1*. Artery. *2*. Fine capillary network, proceeding from the artery and surrounding the tubular glands. *3*. Superficial capillary network around the mouths of the tubular glands. *4*. Vein formed by the union of capillaries returning the blood of the superficial capillary network.



blood is returned to the venous circulation. Hence the glands are provided for their secreting function with fine capillaries, while the capillaries which contribute to the nutrition and secretion of the surface of the mucous membrane are of a coarser kind.

Vessels and Nerves of the Alimentary Canal.—The *arteries* of the alimentary canal, as they supply the tube from above downwards, are—the pterygo-palatine, ascending pharyngeal, superior thyroid, and inferior thyroid, in the neck; œsophageal in the thorax; gastric, hepatic, splenic, superior and inferior mesenteric, in the abdomen; and inferior mesenteric, internal iliac, and internal

pubic, in the pelvis. The *veins* from the abdominal alimentary canal unite to form the vena portæ. The *lymphatics* and *lacteals* open into the thoracic duct.

The *nerves* of the pharynx and œsophagus are derived from the glosso-pharyngeal, pneumogastric, and sympathetic. The nerves of the stomach are the pneumogastric, and sympathetic branches from the solar plexus; and those of the intestinal canal are the superior and inferior mesenteric and hypogastric plexuses. The extremity of the rectum is supplied by the inferior sacral nerves from the spinal cord.

The nerves distributed to the small intestine form two plexuses, one between the longitudinal and circular muscular fibres, and the other in the submucous tissue: the former is described as **Auerbach's plexus** (plexus myentericus); it gives off a number of minute filaments which ramify in the midst of the muscular fibres and are distributed to them: the latter is named **Meissner's plexus**; it consists of fibres which are much finer than those of the intermuscular plexus, and pass to the mucous membrane. Both plexuses are remarkable for the large number of minute ganglia which they contain.

LARGE INTESTINE.

The large intestine, five or six feet and sometimes more in length, sacculated and thicker than the small intestine, tapers gradually from above downwards, and is divided into *cæcum*, *colon*, and *rectum*. It is distinguished from the small intestine by four characters, namely, its size, sacculation, the existence of three longitudinal bands, and the presence in connection with it of little fringes of fat called *appendices epiploicæ*.

The **cæcum** (caput coli) is the blind pouch, or cul-de-sac, about two inches and a half in length, situated at the commencement of the large intestine. It is lodged in the right iliac fossa, and retained in its place by the peritoneum which passes round it and forms posteriorly a short meso-cæcum. Attached to its extremity is the **appendix vermiformis**, a long worm-shaped tube, the rudiment of the lengthened cæcum found in all mammiferous animals except man, the higher quadrumana, and the wombat. The appendix varies in length from one to five or six inches; it is about equal in diameter to a goose-quill, and is connected with the posterior and left aspect of the cæcum near the extremity of the ileum. It is usually more or less coiled upon itself, and retained in that coil by a falciform duplicature of peritoneum. Its canal is extremely small, and the orifice by which it opens into the cæcum not unfrequently provided with an incomplete valve. The cæcum is the most dilated portion of the large intestine, and is distinguished from the colon externally by the constriction corresponding with the entrance of the ileum, and internally by the ileo-cæcal or ileo-colic valve.

The **colon** is divided into *ascending*, *transverse*, and *descending*. The **ascending colon** passes upwards from the right iliac fossa,

through the right lumbar region to the under surface of the liver. It then bends inwards and crosses the upper part of the umbilical region under the name of **transverse colon**; and on the left side

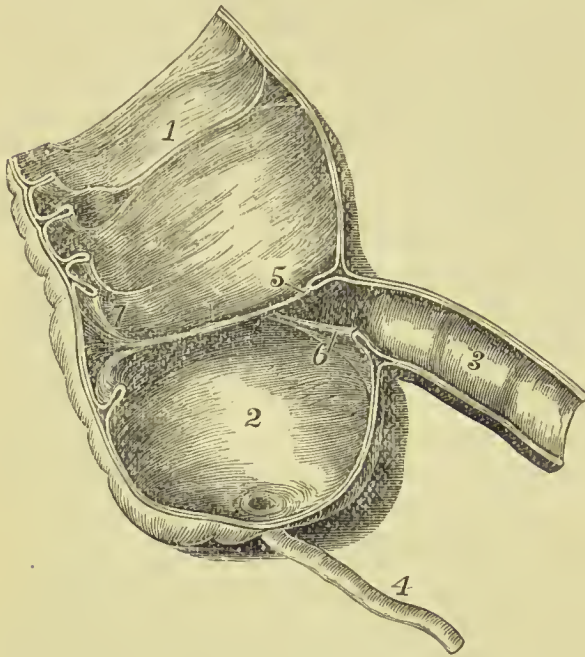


FIG. 449.—Cæcum and ileo-cæcal valve. 1. Ascending colon. 2. Cæcum. 3. Ilium. 4. Vermiform appendix. 5. Ilio-colic fold. 6. Ilio-cæcal fold. 7. Frænula.

descends, **descending colon**, through the left lumbar region to the left iliac fossa, where it makes a remarkable curve upon itself, which is called the **sigmoid flexure**.

The **ascending colon**, the most dilated portion of the large intestine, next the cæcum, is retained in position in the abdomen either by the peritoneum passing simply in front of it or by a narrow meso-colon. It is in relation *in front* with the small intestine and abdominal parietes; *behind* with the quadratus lumborum muscle and right kidney; *internally* with

the small intestine and descending portion of the duodenum; and by its *upper extremity* with the under surface of the liver and gall-bladder (*hepatic flexure*).

The **transverse colon**, the longest portion of the large intestine, forms a curve across the cavity of the abdomen, the convexity of the curve looking forwards and sometimes downwards. It is in relation, by its *upper surface*, with the liver, gall-bladder, stomach, and lower extremity of the spleen; by its *lower surface*, with the small intestine; by its *anterior surface*, with the anterior layers of the great omentum and abdominal parietes; and, by its *posterior surface*, with the transverse meso-colon which connects it with the pancreas and duodenum. As it bends downwards to become descending colon it lies in contact with the lower end of the spleen (*splenic flexure*), and is connected with the inner surface of the ribs and diaphragm by a peritoneal band (*phreno-colic ligament*). The transverse colon is the most movable part of the large intestine.

The **descending colon** is smaller in calibre, and situated more deeply than the ascending colon. It is generally covered by peritoneum only in front, but in fully a third of the specimens examined there will be found a complete envelopment by peritoneum and consequent *descending meso-colon*. It is in relation in front with the

small intestines and great omentum, and behind with the quadratus lumborum, left kidney and left crus of the diaphragm.

The **sigmoid flexure**, the narrowest part of the colon, curves upwards and to the right, then downwards and to the left, and is retained in its place by a *sigmoid meso-colon*. It is in relation, *in front*, with the small intestine and abdominal parietes; and *behind* with the iliac fossa. Including the upper part of the rectum as far as the third sacral vertebra, it has been described by F. Treves as forming a large loop somewhat resembling the Greek letter Ω , and he proposes the substitution of the title *Omega loop* for *sigmoid flexure*.

The **rectum**, the termination of the large intestine, seven or eight inches in length, has received its name, not so much from the direction of its course, as from the straightness of its form in comparison with the colon. It descends from opposite the left sacro-iliac symphysis, in front of the sacrum, forming a gentle curve to the right side, and then returning to the middle line; opposite the extremity of the coccyx it curves backwards to terminate in the anus at about an inch in front of the apex of that bone. The rectum, therefore, forms a double flexure in its course, the one being directed from side to side, the other from before backwards. It is smaller in calibre at its upper part than the sigmoid flexure, but becomes gradually larger as it descends, and its lower extremity, previously to its termination at the anus, forms a dilatation of considerable but variable magnitude. It is not sacculated like the colon, and has no separate longitudinal bands on it.

With reference to its relations, the rectum is divided into three portions; the *first*, including half its length, extends to about the middle of the sacrum, is completely surrounded by peritoneum, and connected to the sacrum by means of the *meso-rectum*. This portion is in relation above with the left sacro-iliac symphysis; and below, with the branches of the internal iliac artery, sacral plexus of nerves and left ureter; one or two convolutions of the small intestine are interposed between the front of the rectum and the bladder in the male; and between the rectum and the uterus with its appendages in the female. The *second portion*, about three inches in length, is closely attached to the surface of the sacrum, and is at first covered by peritoneum on the front and sides, but lower down has that membrane only in front; it is in relation by its lower part with the base of the bladder, vesiculæ seminales, and prostate gland; and in the female with the vagina. The *third portion* curves backwards from opposite the prostate gland and tip of the coccyx to terminate in the anus; it is embraced by the levatores ani, and is about one inch and a half in length. It has no peritoneal covering, and is separated by the recto-vesical fascia from the prostate gland, vasa deferentia, vesiculæ seminales and trigone of the bladder. This portion is separated from the membranous part of the urethra by a triangular space; in the female the triangular space intervenes between the vagina and rectum, and constitutes by its base the perineal body. Immediately above its

termination the rectum undergoes considerable enlargement, and bulges forwards, so as to give the anus the appearance of being bent backwards; this dilatation is called the *sinus analis*.

The **anus** is situated at a little more than an inch in front of the extremity of the coccyx. The integument around it is covered with hairs, and is thrown into numerous radiated folds, which are obliterated during the passage of fæces. The *anal passage* or *canal* is described by Symington as connecting the anal aperture with the rectum; it is from half an inch to an inch in length, and when closed has its lateral walls in contact with each other, so that the lumen has the form of a median slit. The margin of the anus is provided with an abundance of sebaceous glands, and the epidermis may be seen terminating by a fringed and scalloped border, at a few lines above the extremity of the opening.

Structure of the Large Intestine.

The large bowel has the same coats as the small, namely, *serous*, *muscular*, *submucous* and *mucous*.

SEROUS COAT.—The peritoneum forms the serous coat; its arrangement in relation to the several parts of the colon has been described on a previous page (p. 702).

MUSCULAR COAT.—This consists, as in the small intestine, of longitudinal and circular fibres. The *longitudinal fibres* commence at the appendix vermiformis, and are collected into three bands— anterior, broad; and two narrower bands, one placed posteriorly and the other laterally. The anterior band corresponds in the transverse colon to the line of attachment of the great omentum; the posterior band is at the attached border of the colon; and the lateral one lies on the inner aspect of the ascending and descending colon, and under surface of the transverse colon. These bands, the *ligamenta coli*, are nearly one-half shorter than the intestine, and serve to maintain the sacculated structure of the cæcum and colon. In the *descending colon* the posterior bands usually unite and form a single band. In addition to these bands, the longitudinal fibres are also sparsely distributed over the surface of the sacculi. In the lower part of the sigmoid flexure, the muscular fibres of the longitudinal bands begin to spread out, and in the rectum the fibres are regularly distributed throughout the entire calibre of the bowel. The *circular fibres* are distributed over the whole surface of the colon, but are thickest in the sulci between the sacculi. In the cæcum and colon they are very thin; in the rectum they are thicker, and near its lower extremity are aggregated into the thick muscular band which is known as the internal sphincter ani.

SUBMUCOUS COAT.—This coat in all respects corresponds to that in the small intestine.

MUCOUS COAT.—In the **cæcum** and **colon** the mucous membrane is smooth, and lines the surfaces of the folds which form the boundaries

of the sacculi of the large intestine. In the **rectum** it forms three valvular folds (*valves of Houston*), one of which is situated near the commencement of that part of the intestine; the second, extending from the side of the tube, is placed opposite the middle of the sacrum; and the third, which is the largest and most constant, projects from the anterior wall of the bowel opposite the prostate gland. Besides these folds, the membrane in the empty state of the intestine is thrown into longitudinal pleats somewhat similar to those of the œsophagus; these have been named the *columns* of the rectum (*columnæ recti of Morgagni*). The mucous membrane of the rectum is connected to the muscular coat by a loose areolar tissue, as in the œsophagus.

One character serves infallibly to distinguish the mucous membrane of the small intestine from that of the large, namely, that the former is studded over throughout by minute conical processes called **villi**, which are entirely absent from the latter.

The mucous membrane of the large intestine is furnished with Lieberkühn's follicles, resembling those of the small intestine; they are, however, more numerous, are much longer, and contain a larger number of mucous-cells. The lymphoid tissue of the large bowel forms spherical masses, like those described in the structure of the small bowel under the name of solitary glands, but they are smaller and less prominent. They are especially numerous in the cæcum and vermiform appendix. The epithelium on the surface of the large intestine is columnar, and the mucous membrane has on its deep aspect a definite muscularis mucosæ.

Ilio-cæcal Valve.—At the termination of the ileum in the large intestine, the mucous membrane forms two semilunar folds, strengthened by the muscular coat. The termination of the ileum is oblique and flattened, and constitutes the division between the cæcum and colon, the two folds of mucous membrane being the *ileo-cæcal* or *ileo-colic valve* (valve of Baulin or valve of Tulpius). The position of these folds is such that one belongs to the cæcum, the other to the colon, the opening between them being oblong and oval, and not inaptly compared to a button-hole; moreover, the colic flap somewhat overlaps the cæcal flap, and is so disposed in relation to the entrance of the ileum that the contents of the small bowel are necessarily discharged into the cæcum. The upper or ileo-colic fold is horizontal in its direction, the lower or ileo-cæcal is nearly vertical; both folds are prolonged on each side for some distance beyond the ends of the opening, these prolongations being called *frenula* or *retinacula*. The opening from the ileum to the cæcum is rounded and wide at its anterior and left end, narrow and pointed at the posterior.

The description of the **vessels** and **nerves** distributed to the alimentary canal has been given with the anatomy of the small intestine.

THE LIVER.

The liver is the largest gland in the body, weighing about four pounds, and measuring through its longest diameter about twelve inches; its breadth is commonly about six to seven inches, and its greatest thickness three and a half inches. It is situated in the right hypochondriac region, and extends across the epigastrium into the left hypochondrium, frequently reaching, by its left extremity, the upper end of the spleen. It is placed obliquely in the abdomen; its convex surface looking upwards and forwards, the concave downwards and backwards. The anterior border is sharp and free, and marked by a deep notch, and the posterior rounded and broad. His has pointed out that the liver when in the body has three surfaces, and not two, as usually described. The additional

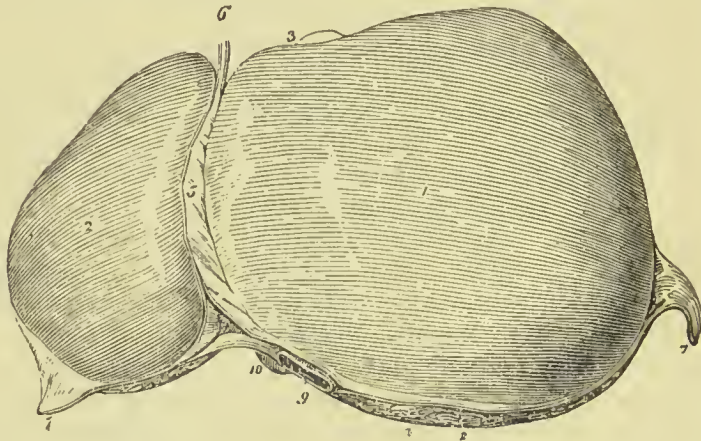


FIG. 450.—Upper surface of the liver. 1. Right lobe. 2. Left lobe. 3. Anterior or free border. 4. Posterior or rounded border. 5. Falciform ligament. 6. Round ligament. 7, 7. The two lateral ligaments. 8. The space left uncovered by the peritoneum, and surrounded by the coronary ligament. 9. Inferior vena cava. 10. Point of the lobus Spigelii. 11. Fundus of the gall-bladder seen projecting beyond the anterior border of the right lobe.

surface looks altogether backwards, and may hence be named the posterior surface; it includes the posterior border, the whole of the Spigelian lobe, and a strip of the left lobe. The liver is in relation, superiorly and posteriorly, with the diaphragm; inferiorly with the stomach, ascending portion of the duodenum, transverse colon, right supra-renal body, and right kidney; and corresponds, by its free border, with the lower margin of the ribs.

Ligaments.—The liver is retained in its place by five ligaments, four of which are duplicatures of the peritoneum, situated on the convex surface of the organ; the fifth is a fibrous cord which passes through a fossa in its under surface, from the umbilicus to the inferior vena cava. They are the—

Falciform,
Coronary,

Two lateral,
Round.

The **falciform ligament** (broad or suspensory) is an antero-posterior fold of peritoneum, extending from the notch in the anterior margin of the liver to its posterior border. Between its two layers, in the anterior and free margin, is the round ligament. It divides the upper surface of the liver into the right and left lobes.

The **coronary ligament** is formed by the separation of the two layers of peritoneum which pass from the diaphragm to the liver. The posterior layer is continued unbroken from one lateral ligament to the other; but the anterior quits the posterior at each side, and is continuous with the corresponding layer of the falciform ligament. In this way a large oval surface on the posterior border of the liver is left uncovered by peritoneum, and is connected to the diaphragm by areolar tissue. This space is formed principally by the right lateral ligament, and is pierced near its left extremity by the inferior vena cava, previously to the passage of that vessel through the tendinous opening in the diaphragm.

The **lateral ligaments** are formed by the two layers of peritoneum which pass from the under surface of the diaphragm to the posterior border of the liver; they are lateral extensions of the coronary ligament.

The **round ligament** is a fibrous cord resulting from the obliteration of the umbilical vein, and situated between the two layers of peritoneum in the anterior border of the falciform ligament. It may be traced from the umbilicus through the longitudinal fossa of the under surface of the liver to the inferior vena cava, with which it is connected.

Fissures.—The under surface of the liver is marked by five fissures, which divide its surface into five compartments or lobes, two principal and three minor lobes; they are the—

Fissures.

Longitudinal fissure,
Fissure for the ductus venosus,
Transverse fissure,
Fissure for the gall-bladder,
Fissure for the vena cava.

Lobes.

Right lobe, .
Left lobe,
Lobus quadratus,
Lobus Spigelii,
Lobus caudatus.

The **longitudinal fissure** is a deep groove running from the notch, *umbilical fissure*, in the anterior margin of the liver, to the posterior border of the organ. At about one-third from its posterior extremity it is joined by a short but deep fissure, the transverse, which meets it transversely from the under part of the right lobe. In front of this junction it lodges the fibrous cord of the umbilical vein, and is generally crossed by a band of hepatic substance called the *pons hepatis*.

The **fissure for the ductus venosus** is the shorter portion of the longitudinal fissure, extending from the junctional termination of the transverse fissure to the posterior border of the liver, and con-

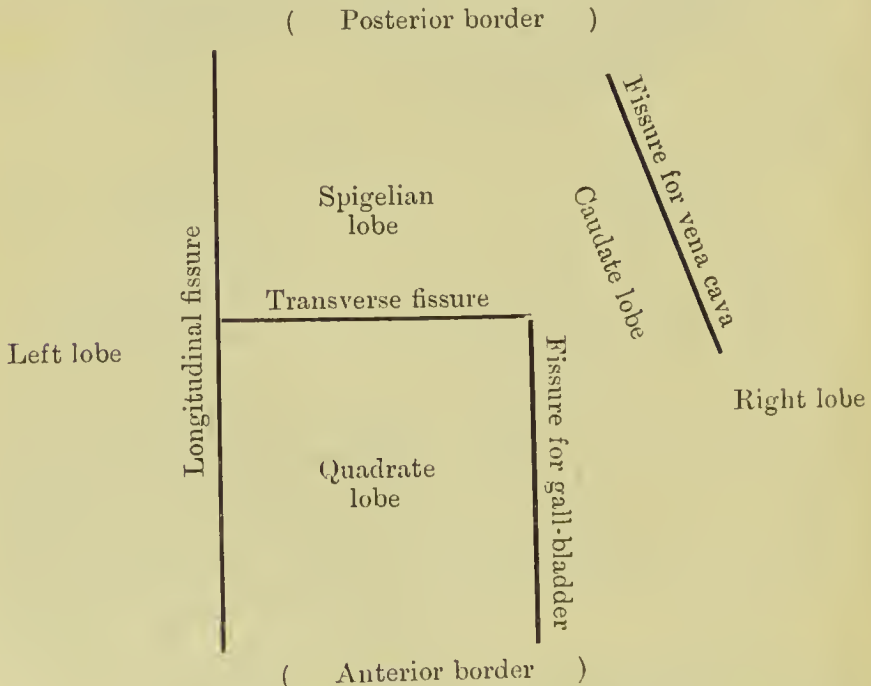
taining a small fibrous cord, the remains of the ductus venosus. This fissure is therefore but a part of the longitudinal fissure.

The **transverse** or **portal fissure** is the short and deep fissure, about two inches in length, through which the hepatic ducts quit and the hepatic artery and portal vein enter the liver. Hence this fissure was considered by the older anatomists as the gate of the liver, *porta hepatis*; and the large vein entering the organ at this point, was named the portal vein. At their entrance into the transverse fissure the branches of the hepatic duct are the most anterior, next those of the artery, and most posteriorly the portal vein. Besides these three structures, the nerves and lymphatics also enter the liver through this fissure.

The **fissure for the gall-bladder** is a shallow depression extending forwards, parallel with the longitudinal fissure, from the right extremity of the transverse fissure to the free border of the liver, where it frequently forms a notch, *incisura vesicalis*.

The **fissure for the vena cava** is a deep and short fissure, occasionally a circular tunnel, which proceeds from a little behind the right extremity of the transverse fissure to the posterior border of the liver, and lodges the inferior vena cava. It lies between the Spigelian lobe and the right lobe, and has opening into it the hepatic veins, by which the blood leaves the liver.

The relative position of these fissures, and the lobes which they limit, will be best understood from the subjoined scheme, for which we are indebted to Prof. D. J. Cunningham:—

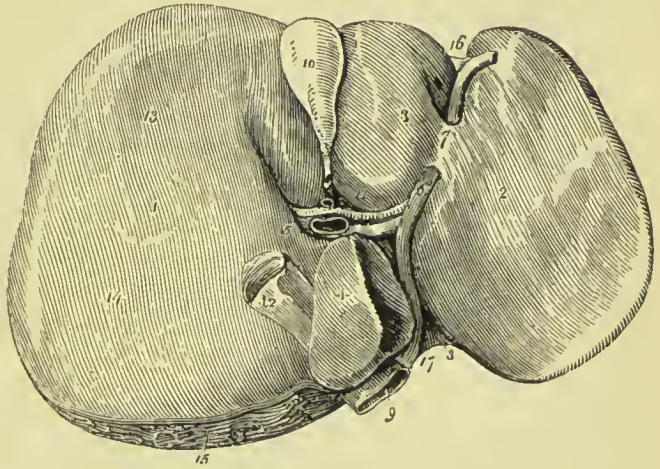


Lobes.—The **right lobe** is four or six times larger than the left,

from which it is separated, on the concave surface, by the longitudinal fissure, and on the convex, by the falciform ligament. It is marked on its under surface by the transverse fissure, and by the fissures for the gall-bladder and vena cava; and presents three depressions, one in front (*impressio colica*) for the curve of the ascending colon, and one behind (*impressio renalis*) for the right supra-renal capsule and kidney. On the inner edge of the renal impression, a narrow and indistinct marking is generally present, being the part against which the ascending duodenum lies (*impressio duodenalis*).

The **left lobe** is small and flattened, convex on its upper surface and concave below, where it lies in contact with the anterior surface of the stomach. It is sometimes in contact by its extremity

FIG. 451.—Under surface of the liver. 1. Right lobe. 2. Left lobe. 3. Lobus quadratus. 4. Lobus Spigelii. 5. Lobus caudatus. 6. Longitudinal fissure; the figure is placed on the rounded cord, the remains of the umbilical vein. 7. Pons hepatis. 8. Fissure of the ductus venosus; the obliterated cord of the ductus is seen passing backwards to be attached to the coats of the inferior vena cava (9). 10. Gall-bladder lodged in its fissure. 11. Transverse fissure, containing, from before backwards, hepatic duct, hepatic artery, and portal vein. 12. Vena cava. 13. Depression corresponding with the curve of the colon. 14. Depression produced by the right kidney. 15. Rough surface on the posterior border of the liver left uncovered by peritoneum; the cut edge of the peritoneum surrounding this surface forms part of the coronary ligament. 16. Notch on the anterior border separating the two lobes. 17. Notch on the posterior border corresponding with the vertebral column.



with the upper end of the spleen, and is in relation, by its posterior border, with the cardiac orifice of the stomach and left pneumogastric nerve.

The **lobus quadratus** is a quadrilateral lobe situated on the under surface of the right lobe: it is bounded, *in front*, by the free border of the liver; *behind*, by the transverse fissure; to the *right*, by the gall-bladder; and to the *left*, by the longitudinal fissure.

The **lobus Spigelii** is a small triangular lobe, also situated on the under surface of the right lobe: it is bounded, *in front*, by the transverse fissure; and, *on the sides*, by the fissures for the ductus venosus and vena cava.

The **lobus caudatus** is a small tail-like appendage of the lobus Spigelii, from which it runs outwards like a crest into the right lobe, and serves to separate the right extremity of the transverse fissure

from the commencement of the fissure for the vena cava. In some persons this lobe is well marked, in others it is small and ill-defined.

Position of the Liver in relation to the Abdominal and Thoracic Wall.—The upper convex surface reaches as high as the level of the fifth right chondro-sternal articulation; the lower border corresponds pretty accurately to the inferior margin of the cartilages of the 6th, 7th, 8th, and 9th ribs on the right side. The left lobe extends to about an inch to the left of the middle line, and lies against the anterior wall of the abdomen, its lower border being indicated by a line drawn from the ninth right to the eighth left costal cartilage. The gall-bladder has its fundus at the outer border of the rectus muscle, under the ninth right costal cartilage.

Vessels and Nerves.—The vessels entering into the structure of the liver are also *five* in number; they are the—

Hepatic artery,	Hepatic veins,	Lymphatics.
Portal vein,	Hepatic ducts,	

The **hepatic artery, portal vein, and hepatic duct** enter the liver together at the transverse fissure, and ramify through portal canals to every part of the organ; so that their general direction is from below upwards, and from the centre towards the circumference.

The **hepatic veins** commence at the circumference, and proceed from before backwards, to open into the vena cava at the posterior border of the liver.

The portal vein, hepatic artery, and hepatic duct are enveloped in a loose areolar tissue, the capsule of Glisson, which permits them to contract upon themselves when emptied of their contents; the hepatic veins, on the contrary, are closely adherent by their walls to the substance of the liver in which they run, and are unable to contract. The former will consequently be found in any section more or less collapsed, and always accompanied by an artery and duct, and the latter widely open and solitary.

The **lymphatics** of the liver are described in the section dedicated to those vessels.

The **nerves** of the liver are derived from the spinal and sympathetic system; the former proceed from the right phrenic and right pneumogastric nerve, the latter from the hepatic plexus.

Minute Anatomy of the Liver.

The liver is composed of *lobules*, of *areolar tissue* which connects them together, of the ramifications of the *portal vein, hepatic duct, hepatic artery, hepatic veins, lymphatics, and nerves*, and is enclosed and retained in its situation by the peritoneum.

The **serous coat**, formed by the peritoneum, covers the whole surface of the liver, excepting a triangular area situated near the posterior border of the organ, at the meeting of the coronary and falciform ligaments. This coat is inseparable from the fibrous coat, or Glisson's capsule.

The **lobules** are small granular bodies which vary in size from

$\frac{3}{4}$ th to $\frac{1}{2}$ th of an inch. When divided longitudinally, they have a foliated appearance, and transversely, a polygonal outline, with sharp or rounded angles, according to the smaller or greater quantity of areolar tissue contained in the liver. Each lobule is divided on its exterior into a base and a peripheral surface. The *base* corresponds with one extremity of the lobule, is flattened, and rests on an hepatic vein, which is thence named **sublobular**. The *peripheral surface* includes the rest of the surface of the lobule. In the centre of each lobule is a small vein, the **intralobular**, which is formed by the convergence of six or eight minute venules from the lobule. The intralobular vein thus constituted takes its course through the centre of the longitudinal axis of the lobule, pierces the middle of its base, and opens into the sublobular vein. The periphery of the lobule, with the exception of its base, which is always closely attached to a sublobular vein, is connected by means of its areolar tissue, with

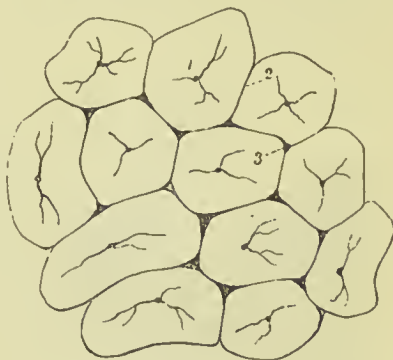
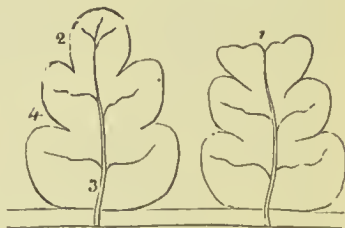

FIG. 452.—Lobules of the liver. The lobules as they are seen on the surface of the liver, or when divided transversely. 1. Intralobular vein in the centre of each lobule. 2. Interlobular fissure. 3. Interlobular space.

FIG. 453.—Longitudinal section of two lobules. 1. A superficial lobule, terminating abruptly, and resembling a section at its extremity. 2. A deep lobule, showing the foliated appearance of its section. 3. Intralobular vein, with its converging venules; the vein terminates in a sublobular vein. 4. External surface of the lobule.



the surfaces of surrounding lobules. The interval between the lobules is the **interlobular fissure**, and the angular interstices formed by the apposition of several lobules are the **interlobular spaces**.

In **ultimate structure** the lobule is composed of **hepatic cells**, of a **vascular plexus** which receives its blood exteriorly from an interlobular branch of the portal vein and transmits it internally to the intralobular vein, the radicle of the hepatic vein, of stromal supporting tissue, and of the ultimate ramifications of the **biliary ducts**.

The **hepatic cells** are nucleolo-nucleated cells, of a polyhedral figure, measuring about $\frac{1}{1000}$ of an inch in diameter, and of a pale amber colour. They have no distinct cell-wall, and when isolated possess the power of amoeboid motion; their contents are granular and often fatty vesicles of various sizes may be observed in their interior. The cells are arranged in a network corresponding with

the vascular plexus, the columns or solid portions of the network constituting the secretory portion of the gland; the vessels are not in absolute contact with the hepatic cells, but are separated from them by a membrane formed of flattened cells, the space left between this membrane and the capillary wall forming a lymph channel.

In order to understand the relations which the cells bear to the vessels and ducts, it will be necessary to trace the two latter from

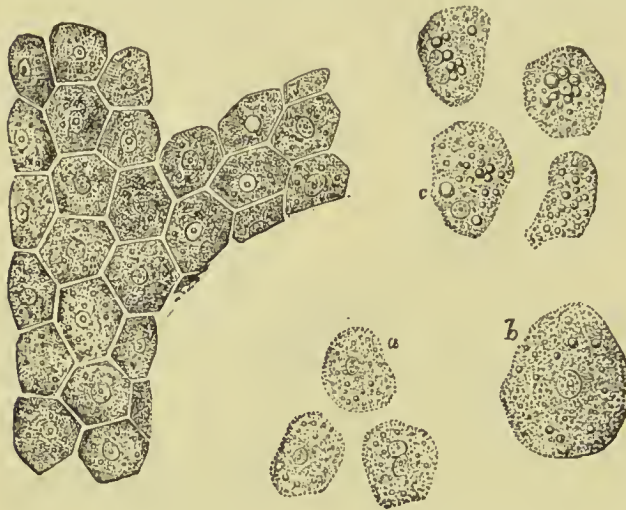


FIG. 454.—Cells of the liver. One large mass shows the shape they assume, by mutual pressure. (a) The same free, when they become spheroidal. (b) More magnified. (c) During active digestion containing refracting globules like fat.

the transverse fissure to the interior of the liver, and to note their arrangement in the portal canals, around the lobules, and in the substance of the lobules.

The portal vein, hepatic artery, and hepatic duct run together in the interior of the liver, being contained in channels formed by a layer of connective tissue called *Glisson's capsule*, the channels receiving the name of **portal canals**; the hepatic veins run a

totally independent course, and terminate in the inferior vena cava, where it lies against the under and posterior part of the liver.

Glisson's capsule is the areolar tissue which envelops the hepatic artery, portal vein, and hepatic duct, during their passage through the transverse fissure, and which continues to surround them in the interlobular fissures. It also constitutes the proper capsule of the entire organ. Hence arises a division of the capsule into two portions, *vaginal* and *investing*.

The vaginal portion is that which invests the hepatic artery, hepatic duct, and portal vein, in the portal canals; in the large canals it completely surrounds these vessels, but in the smaller is situated only on that side which is occupied by the artery and duct. The investing portion is that which covers the exterior of the organ.

The **portal vein** enters the liver at the transverse fissure, and ramifies throughout its structure in the portal canals; in the smaller canals Glisson's capsule only envelops the artery and duct, so that the portal vein is in direct contact with the lobules.

The branches of the portal vein are—vaginal, interlobular, and lobular. The **vaginal branches** are those which, being given off in the portal canals, have to pass through the sheath (*vagina*) of Glisson's capsule, previously to entering the interlobular spaces. In

this course they form an intricate plexus, **vaginal plexus**, in the capsule of Glisson, and this plexus surrounds the vessels as does the capsule in the larger canals, and occupies the capsular side only in the smaller canals. The **interlobular branches** are given off from

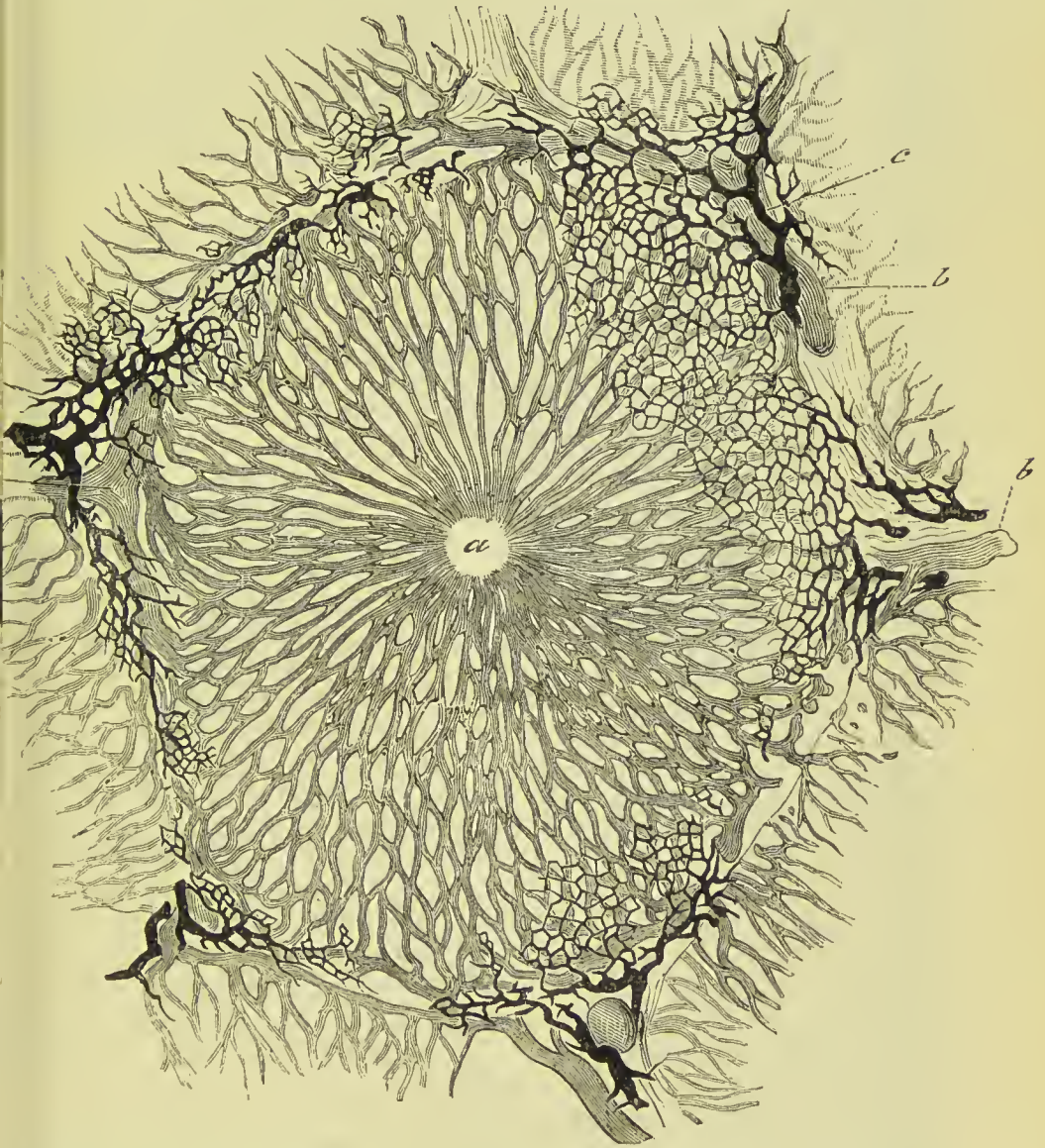


FIG. 455.—Section of lobule of the liver of a rabbit, in which the blood and bile capillaries have been injected. *a*. Intralobular vein. *b*. Interlobular veins. *c*. Biliary canals beginning in fine capillaries.

the vaginal portal plexus where it exists, and directly from the portal veins, in that part of the smaller canals where the coats of the vein are in contact with the walls of the canal. They then enter the interlobular spaces and divide into branches, which cover with their ramifications every part of the surface of the lobules, with the

exception of their bases and those extremities of the superficial lobules which appear on the surfaces of the liver. The **lobular branches** are derived from the interlobular veins; they form a plexus within each lobule, and converge from the circumference towards the centre, where they terminate in the minute radicles of the intralobular vein. This plexus, interposed between the interlobular portal veins and the intralobular hepatic vein, constitutes the venous part of the lobule, and is called the **lobular venous plexus**. The regular islets of the substance of the lobules, seen between the meshes of this plexus by means of the microscope, are the network of hepatic cells.

The portal vein returns the venous blood from the chylipoietic viscera, to be circulated through the lobules; it also receives the blood which results from the distribution of the hepatic artery.

The **hepatic artery** enters the liver with the portal vein and hepatic duct, and ramifies with those vessels through the portal canals. Its branches are—vaginal, interlobular, and capsular. The **vaginal branches**, like those of the portal vein and hepatic duct, form a **vaginal plexus**, which exists throughout the whole extent of the portal canals, with the exception of that side of the smaller canals which corresponds with the artery. The **interlobular branches**, arising from the vaginal plexus and from the parietal side of the artery (in the smaller canals), ramify through the interlobular fissures, and are principally distributed to the coats of the interlobular ducts. The **capsular branches** ramify within the capsule, accompanied by small veins.

The **hepatic veins** commence in the substance of each lobule by minute venules, which receive the blood from the lobular venous plexus, and converge to form the intralobular vein. The **intralobular vein** passes through the central axis of the lobule, and through the middle of its base, to terminate in a **sublobular vein**; and the union of the sublobular veins constitutes the hepatic trunks, which open into the inferior vena cava. The **hepatic trunks** are formed by the union of the sublobular veins; they have very thin walls and are in almost immediate contact with the lobules, even the larger veins being only separated by a small quantity of areolar tissue. They proceed from before backwards, and terminate, by two large openings (corresponding with the right and left lobe of the liver) and several smaller apertures, in the inferior vena cava.

Biliary Capillaries and Ducts.—The biliary capillaries begin as minute passages between the sides of contiguous bile-cells, in which no definite wall has hitherto been demonstrated. They appear to communicate by minute channels with vacuoles in the cells themselves. The bile capillaries form a fine plexus throughout the whole of the lobule, **lobular plexus of ducts**, and on reaching the circumference thereof, form a second plexus on its exterior, the **interlobular plexus of ducts**. From this plexus ducts are derived which run in the portal canals, being placed in each case on the same side as the hepatic artery, and surrounded

by Glisson's capsule; they form fine plexuses in the portal canals, **vaginal plexuses**, and terminate by uniting to form the **hepatic duct** at the transverse fissure. The ducts in the interlobular plexus have definite walls formed by a basement membrane, lined by a single layer of flattened or cubical epithelial cells: the larger ducts have their mucous membrane supplied with a large number of tubular or flask-shaped mucous recesses, having much the appearance of mucous glands; these are arranged in two rows, one on each side of the vessel. The largest ducts have an outer coat of areolar and elastic tissue, a middle coat of longitudinal and circular

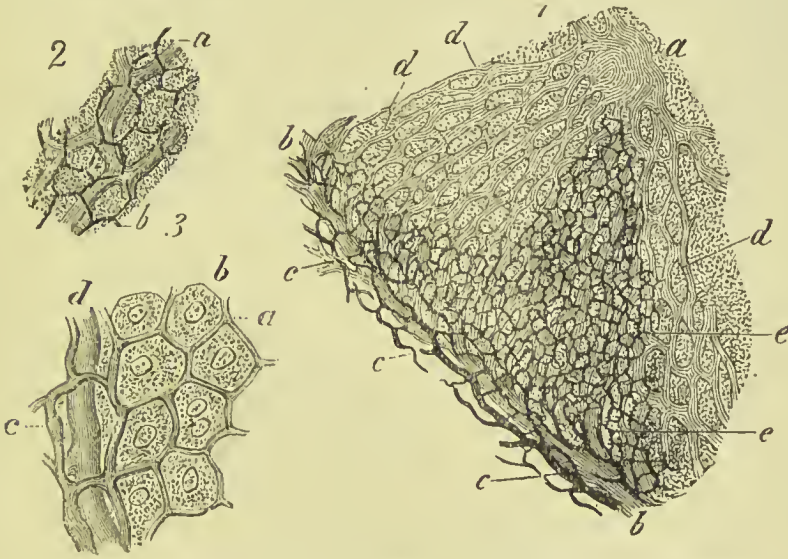


FIG. 456.—Biliary capillaries from the rabbit's liver. 1. Part of a lobule. *a*, Intra-lobular vein. *b*, *b*, Interlobular vein. *c*, *c*, *c*, Biliary ducts. *d*, *d*, *d*, Lobular venous plexus. *e*, *e*, *e*, Biliary capillaries. 2. Biliary capillaries (*b*) in their relation to the capillaries of the vascular system (*a*). 3. Biliary capillaries in their relation to the hepatic cells. *a*, Biliary capillaries. *b*, Hepatic cells. *c*, Biliary ducts. *d*, Capillaries of the blood-vessels.

muscular fibres, and a mucous membrane lined with columnar epithelium, and possessing true, lobulated, mucous glands.

The **right and left hepatic ducts** unite to form the **common hepatic duct**, and this in turn is joined by a duct from the gall-bladder, the two together forming the **common bile duct** (*ductus communis choledochus*). The common bile duct runs in the free border of the lesser omentum, being placed to the right of the hepatic artery and in front of the portal vein. It passes behind the descending portion of the duodenum to the inner side of that intestine, where it terminates by passing obliquely between the muscular and mucous coat, and opening on the summit of a papilla which is common to it and the pancreatic duct. The papilla is situated near the lower part of the descending portion of the duodenum at its inner side; and the duct is constricted in size during its passage between the coats of the intestine.

Lymphatics and Nerves.—The *lymphatic* vessels accompany the

portal vein through the portal canals and into the interlobular fissures; they originate in the spaces described above as separating the capillaries from the biliary cells. There are also superficial lymphatic plexuses beneath the peritoneum, those on the upper convex surface communicating with the lymphatics of the diaphragm and thorax. The *nerves* form the hepatic plexus, and are derived from the solar plexus and the left pneumogastric and right phrenic nerves. The branches entering the liver are very small; they run with the arteries and ducts in the portal canals, those on the former having minute ganglia in their course. Some of the branches form an interlobular plexus, which gives twigs to the surface of the hepatic cells.

Fœtal Liver.—The liver is one of the first formed abdominal organs in the embryo, consisting primarily of two small masses of hypo-blastic origin, which grow out from the duodenum just beyond the stomach, and penetrate the meso-blastic mass between those organs and the abdominal wall. The cells rapidly increase in number, those of hypo-blastic origin forming solid cylinders which ramify and anastomose with each other, and finally constitute the secretory portion of the gland; the meso-blastic cells included within the network of the former constituting the areolar and vascular structure of the organ. Subsequently the solid cylinders are hollowed in their interior and form the biliary ducts. At the sixth week the liver fills the whole abdomen, and is one-half the weight of the entire embryo. At the fourth month the liver is of immense size in proportion to the bulk of the fœtus. At birth it is of very large size, and occupies the whole upper part of the abdomen. The left lobe is as large as the right, and the falciform ligament corresponds with the middle line of the body. The liver diminishes rapidly after birth, probably from obliteration of the umbilical vein.

GALL-BLADDER.

The gall-bladder (Fig. 457) is the reservoir of the bile; it is a pyriform sac, situated in a fossa on the under surface of the right lobe of the liver, and extending from the right extremity of the transverse fissure to the free margin. It is divided into a body, fundus, and neck; the fundus or broad extremity in the natural position of the liver is placed downwards, and frequently projects beyond the free margin of the liver, while the neck, small and constricted, is directed upwards. The fundus comes in contact with the abdominal wall opposite the ninth costal cartilage of the right side. The gall-bladder is composed of three coats, serous, fibrous, and mucous. The **serous coat** is partial, is derived from the peritoneum, and covers that side only which is unattached to the liver. The **middle** or **fibrous coat** is a thin but strong fibrous layer, composed of dense areolar tissue, and connected on the one side with the liver, on the other with the peritoneum. There also exists in this layer a stratum of unstriped muscular fibres, which are longitudinal and

circular in direction. The **internal** or **mucous coat** is but loosely attached to the fibrous layer; it is everywhere raised into minute rugæ, which give it a beautifully reticulated appearance. It is continuous through the hepatic duct with the mucous membrane lining the ducts of the liver, and through the common bile duct, with the mucous membrane of the alimentary canal. It is coated on its surface with a columnar epithelium.

At the neck the gall-bladder becomes narrowed, much bent on itself, forming an S-like curve, and passes into the cystic duct; in the interior the reticular folds become modified so as to form seven or eight oblique ridges, having much the appearance of a spiral valve, so as to check the outflow of the bile. These folds are called *valves of Heister*.

The **cystic duct**, about an inch and a half in length, runs downwards and backwards to join the hepatic duct and form the common bile duct.

Vessels and Nerves.—The gall-bladder is supplied with blood by the cystic artery, a branch of the hepatic. Its veins return their blood into the portal vein. The nerves are derived from the hepatic plexus.

THE PANCREAS.

The pancreas is a long, flattened, conglomerate gland, analogous to the salivary glands. It is about six inches in length, and between three and four ounces in weight; is situated transversely across the posterior wall of the abdomen, behind the stomach, and rests on the aorta, portal vein, inferior vena cava, the origin of the superior mesenteric artery, and the left kidney and supra-renal body, opposite the first lumbar vertebra. After the abdominal cavity has been laid open, the pancreas may be displayed in one of three ways:—(1) By cutting through the lesser omentum and drawing the stomach downwards; (2) by cutting through the great omentum and displacing the stomach upwards; and (3) by cutting through the transverse meso-colon. A glance at the diagram of the reflections of peritoneum (Fig. 409) will enable the student to understand how the pancreas is reached by each of these incisions.

The pancreas is divided into a body, a greater and a smaller extremity; the great end or head is placed towards the right, and surrounded by the curve of the duodenum; the lesser end or tail extends to the left as far as the spleen. The anterior surface of the body of the pancreas is covered by the ascending posterior layer of peritoneum, and is in relation with the stomach, the first portion of the duodenum, and the commencement of the transverse arch of the

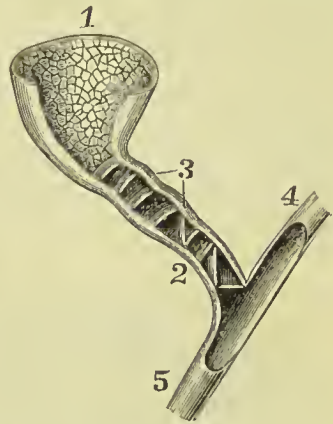


FIG. 457.—Gall-bladder and biliary ducts. 1. Gall-bladder. 2. Cystic duct. 3. Valves of Heister. 4. Hepatic duct. 5. Common bile duct.

colon. The posterior surface is grooved for the splenic vein, and tunnelled by a complete canal for the superior mesenteric and portal veins, and superior mesenteric artery; it is also in relation with the termination of the inferior mesenteric vein, left crus of the diaphragm, and left supra-renal body. The upper border presents a deep groove, sometimes a canal, for the splenic artery and vein, and is in relation with the oblique portion of the duodenum, lobus Spigelii, and celiac axis; and the lower border is separated from the transverse portion of the duodenum by the superior mesenteric artery and vein. On the posterior part of the head of the pancreas is a lobular fold of the gland which completes the canal of the superior mesenteric

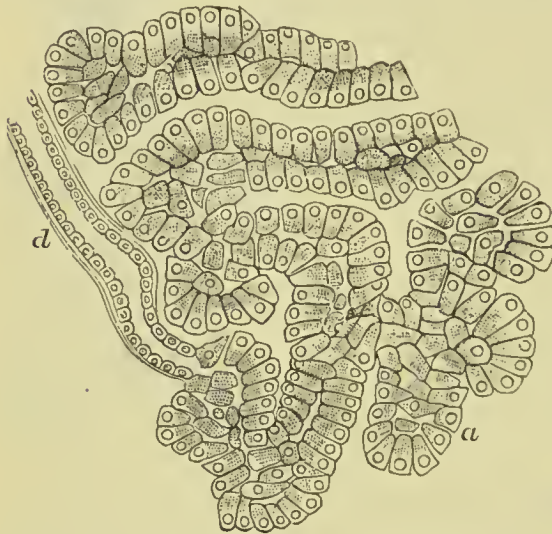

FIG. 458.—Section of the pancreas of a dog, showing the inner granular zone and outer clear, striated zone. *d*. Termination of a duct in the tubular alveoli, *a*.

branches which open into it on all sides from the lobules of the gland, and at its termination is slightly dilated and passes obliquely between the muscular and mucous coat of the intestine to reach the papilla. The duct which receives the secretion from the lesser pancreas is called the *ductus pancreaticus minor*; it opens into the principal duct near the duodenum, and sometimes passes separately into that intestine.

In **structure** the pancreas presents the ordinary composition of an *acino-tubular gland*, being made up of lobes, and these of reddish-yellow polyhedral lobules, which latter consist of smaller lobules, and the smallest lobules of the ramifications of minute ducts, terminating in *tubular alveoli*. The alveoli are distinctly tubular, and sometimes are convoluted; the cells lining them are columnar, and when the gland is at rest they completely fill the cavity and leave scarcely any lumen. They display an inner granular and an outer striated zone. In many parts the middle of the alveolus is occupied by spindle-shaped cells (centro-acinar cells). Intercellular passages

vessels, and is called the *lesser pancreas*. The tail lies on the left kidney, and its extremity is in contact with the spleen.

The **pancreatic duct** (duct of Wirsung) commences at the small extremity of the organ by the union of the ducts from the lobules; it is continued onwards from left to right, gradually increasing in size, to the lower part of the descending duodenum, where it terminates on the papilla of mucous membrane, common to it and the common bile duct. The duct receives numerous

have been described as running between the gland cells. The *ducts* are composed of areolar and elastic tissue, and lined by a *columnar epithelium*. In the walls of the ducts are numerous small racemose mucous glands like those in the hepatic ducts. The secretion of the pancreas is a clear fluid containing few cells.

Vessels and Nerves.—The arteries of the pancreas are branches of the splenic, hepatic, and superior mesenteric; the *veins* open into the splenic and superior mesenteric veins; the *lymphatics* terminate in the lumbar glands. The *nerves* are filaments of the solar plexus.

THE SPLEEN.

The spleen is an oblong flattened organ, of a dark bluish-red colour, situated in the left hypochondriac region. It is very variable in size and weight, but on an average is about five inches in length, and weighs six ounces; it is spongy and vascular in texture, and

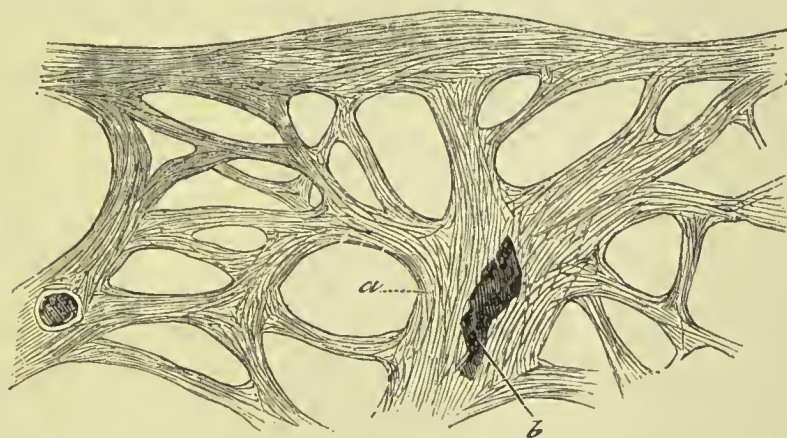


FIG. 459.—*a*. Trabeculae of Spleen. *b*. An artery cut obliquely.

exceedingly friable. The external surface is convex, the internal slightly concave, indented along the middle line, and pierced by several large and irregular openings for the entrance and exit of vessels; this is the *hilum lienis*. The upper extremity is somewhat larger than the lower, and rounded; the inferior is flattened; the posterior border is obtuse, the anterior sharp, and marked by several notches. The spleen is in relation by its external or *convex* surface with the diaphragm, which separates it from the ninth, tenth, and eleventh ribs; by its *concave* surface, with the great end of the stomach, small extremity of the pancreas, gastro-splenic omentum with its vessels, left kidney and supra-renal body, and left crus of the diaphragm; by its *upper end* with the diaphragm, and sometimes with the extremity of the left lobe of the liver; and, by its *lower end*, with the left extremity of the transverse arch of the colon. It is connected to the stomach by the gastro-splenic omentum, and is supported by a fold of peritoneum passing from the diaphragm to the splenic flexure of the colon, and called the *phreno-colic ligament* or *suspensory ligament of the spleen*.

A second spleen (*lien succenturiatus*) is sometimes found appended to one of the branches of the splenic artery, near the great end of the stomach; when it exists, it is round and of small size, rarely larger than a hazel-nut. There are sometimes two, and even three, of these bodies.

Structure.—The spleen is closely invested by the peritoneum, excepting where that membrane is reflected on to the stomach and diaphragm, and at the hilus where the vessels and nerves enter it; this forms its outer or **serous coat**. Beneath this is the proper capsule or **tunica propria**; it is thicker than the serous coat, whitish in appearance, and very elastic. At the hilus the capsule is reflected into the interior of the organ along with the vessels, forming strong bands or **trabeculæ** which radiate from the centre to the circumference, and communicate with each other so

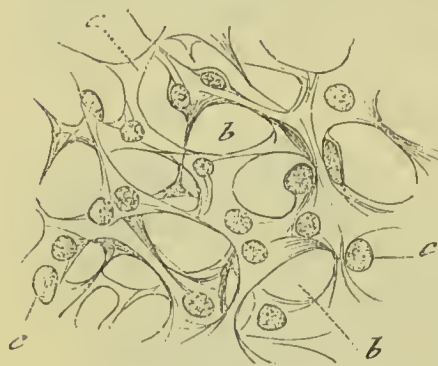

FIG. 460.—Reticulum of the splenic pulp.
a. Meshes covered with endothelium.
b. Lacunar spaces. c. Nuclei.

as to form a mesh-work enclosing irregular spaces or **areolæ**; the fine external strands of the trabeculæ become connected with the interior of the capsule, binding it firmly and inseparably to the internal structure of the organ. Besides fibrous and elastic tissue these bands contain a few unstriped muscular fibres irregularly distributed. The interspaces or areolæ thus formed are filled by a soft material of a reddish-brown colour, called the **splenic pulp**; it consists of a fine reticulum of ramified connective-tissue corpuscles (*supporting cells of the pulp*), the interstices of which are occupied by blood, containing more than the usual proportion of white corpuscles. The cells of the reticulum contain many pigment granules of a yellow or reddish colour; these are probably derived from disintegrated red blood corpuscles, and, indeed, it is not uncommon to find corpuscles in various stages of change in the protoplasm of the supporting cells. Scattered throughout the spleen numerous light-coloured spots are observed, which, when of large size, present the appearance of sago grains; they are the **Malpighian corpuscles** of the spleen. They are closely

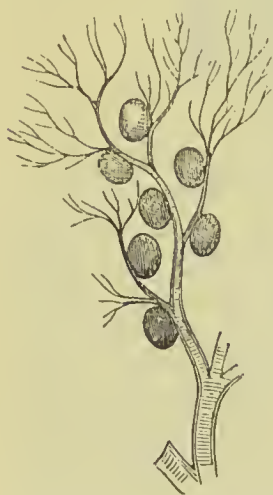

FIG. 461.—Arterial twig of the splenic artery, showing the connection of the splenic corpuscles with the small vessels. From the spleen of a dog.

connected with the outer coat of the small arterial twigs, sometimes being situated only on one side of the vessel (as shown in Fig. 461), but more commonly in the human subject completely surrounding

it. In structure they correspond closely to the lymphoid masses described as forming the tonsils, the solitary and agminate glands of the intestine, and the lymph nodules of the lymphatic glands, being composed of retiform tissue supporting innumerable round lymphoid cells. The cells of the retiform tissue are intimately connected with the supporting cells of the pulp. The outer coat of the smaller arteries is, throughout the whole of their ramifications in the spleen, converted into lymphoid tissue, so that the Malpighian corpuscles are but thicker aggregations of this tissue at certain parts of the course of the vessel.

Arrangement of the Vessels of the Spleen.—The *splenic artery* is of very large size in proportion to the bulk of the spleen; it is a division of the cœliac axis. The branches which enter the spleen are distributed to distinct sections of the organ, and anastomose very sparingly with each other; they terminate in elegant bundles or *pencil* of minute straight arteries, which end in capillaries. The latter, after running for a short distance, lose their tubular character, and the cells which form their walls become branched and communicate freely with the branched cells of the supporting reticulum of the pulp; the contained blood comes thus to flow directly into the interstices of the latter. The *veins* commence in like manner by capillaries, the cells forming the walls of which are continuous with those of the pulp; as we trace them outwards they assume the tubular character and anastomose freely with each other in the meshes of the trabeculæ, thus differing from the arteries between which, in the substance of the spleen, the anastomoses are few. From this description it will be seen that the arteries terminate and the veins commence in capillaries which are in direct communication with the pulp, so that the blood, in order to pass from the one to the other, has to traverse it. There are, however, a few arterial capillaries in the trabeculæ and capsule of the spleen which terminate in the veins in the usual manner.

The **lymphatics** of the spleen are in two sets—*trabecular* and *perivascular*; the former run in the trabeculæ and communicate

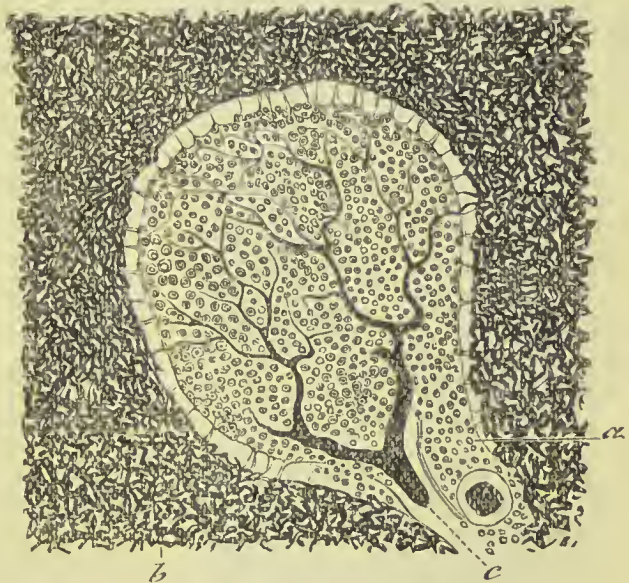

FIG. 452.—Section of spleen, showing *a* Malpighian body. *b*. Injected capillaries. *c*. Artery entering the lymphoid tissue of the Malpighian body.

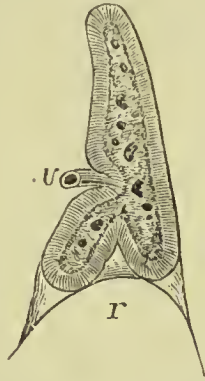
with a superficial set in the capsule; the latter commence in the lymphoid tissue around the arteries, and in the Malpighian corpuscles.

The **nerves** form the splenic plexus and are derived from the solar plexus.

THE SUPRA-RENAL BODIES.

The supra-renal bodies or *supra-renal capsules* are two small yellowish and flattened bodies surmounting the kidneys, and inclining inwards towards the vertebral column. The right is somewhat three-cornered in shape, the left semilunar; they are connected to the kidneys by the common investing areolar tissue, and each capsule is marked on its anterior surface by a fissure or *hilum* which appears to divide it into two lobes. The right supra-renal body is closely

FIG. 463.—Section of the supra-renal body of a fœtus, showing the lower notch by which it rests on the summit of the kidney *r*, and the anterior notch by which the veins issue *v*. It also shows the distinction between the cortical and medullary substance.



adherent to the posterior and under surface of the liver, the left lies in contact with the pancreas and spleen. Both bodies rest against the crura of the diaphragm on a level with the tenth dorsal vertebra, and by their inner border are in relation with the great splanchnic nerve and semilunar ganglion. They are larger in the fœtus than in the adult, and appear to be more active during embryonic life. Each body is about one

and three-quarter inches in height, an inch and a quarter in width, and from two to three lines in thickness; they weigh from one to two drachms.

Structure.—A section of a supra-renal body shows that it has externally a fibrous investment or capsule, and internally is divisible into two portions, that nearest the surface and forming the great bulk of the organ being firm, striated, and of a brownish-yellow colour; this is the *cortical portion*. The central or *medullary portion* is of a brownish-black colour, and so soft that many anatomists have erroneously supposed a cavity to exist in it. The **cortical portion** consists of a stroma supporting cells, the cells being arranged in groups, the largest and most important of which assume the appearance of columns. Arnold has divided the cortical portion into three layers. The outer he calls the *zona glomerulosa*; in it the cell groups are round or oval in shape. The next layer he names the *zona fasciculata*; it is much the thickest of the three layers, and forms the bulk of the organ; in it the cells are arranged in columns placed at right angles to the surface of the organ. The third layer of the cortex is a very narrow one called *zona reticularis*; here the stroma is equally distributed, and the cells are consequently not arranged in groups. The cells of the cortex are polyhedral in shape, and consist of granular protoplasm containing oil globules; each

cell has a clear spheroidal nucleus. The **medullary portion** is separated from the cortical by loose areolar tissue ; it is traversed by large veins, and is composed of a reticular stroma enclosing groups of cells which differ from those of the cortex in being coarsely granular, devoid of oil globules, and many of them branched. The medulla is rich in nerves, and some observers have supposed the branched cells of this portion of the organ to be nerve cells, Luschka even stating that he has traced nerve fibres in connection with them ; this statement is not confirmed by other observers.

The **blood-vessels** of the supra-renal bodies are very numerous. The *arteries*, about twenty in number, proceed from the aorta, phrenic, cœliac, and renal trunks ; they enter the cortical substance at every point of its surface, the greater number dividing into minute twigs and forming a plexus in the cortical layer ; while others continue onwards to the medullary substance, and either terminate in the medullary plexus or cross the medullary substance to re-enter the cortical layer and contribute to the formation of its capillary plexus. The *veins* take their origin from the capillary plexus by minute venules, which unite to form the supra-renal vein. The *supra-renal vein* runs through the centre of the medullary substance, and issues from the supra-renal body at the *hilum* on its anterior surface, to terminate on the right side in the inferior vena cava, on the left in the renal vein. The *lymphatic vessels* are numerous, and belong to the exterior of the organ ; they terminate in the lumbar glands.

The *nerves* are very numerous, and derived from the renal and phrenic plexus, some filaments being received from the phrenic and vagus nerves ; Kölliker counted as many as thirty-three trunks, composed of dark-bordered nerve-fibres and provided with isolated

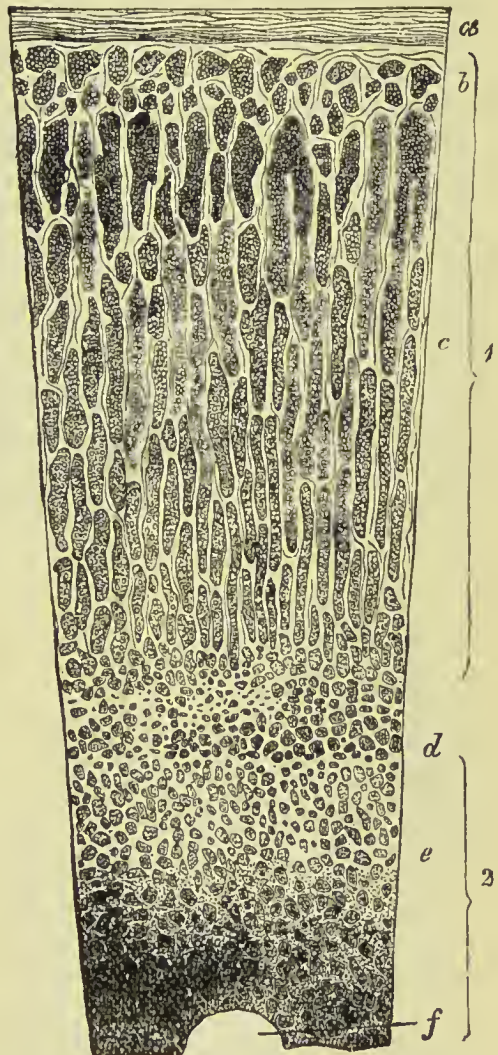


FIG. 464.—Vertical section of supra-renal body. 1. Cortex. 2. Medulla. a. Capsule. b. Zona glomerulosa. c. Zona fasciculata. d. Zona reticularis. e. Medullary substance. f. Section of a vein.

ganglia. They are distributed to the medullary substance only, in which they form a rich nervous plexus.

THE KIDNEYS.

The kidneys, the secreting organs of the urine, are situated in the lumbar regions, behind the peritonæum, and at each side of the vertebral column, corresponding to the bodies of the last dorsal and two upper lumbar vertebræ, and extending from the eleventh rib to near the crest of the ilium; they approach the vertebral column by their upper end. Each kidney is between four and five inches in length, about two inches and a half in breadth, somewhat more than one inch in thickness, and weighs about $4\frac{1}{2}$ oz. in the male and rather less in the female. The kidneys are usually surrounded by fat; they rest on the crura of the diaphragm, on the anterior lamella of the aponeurosis of the transversalis muscle, which separates them from the quadratus lumborum, and on the psoas magnus. The **right kidney** is somewhat lower than the left, from the position of the liver; it is in relation, by its anterior surface, with the liver and descending portion of the duodenum, which rests against it; and is covered in by the ascending colon. The **left kidney**, higher than the right, is covered, in front, by the great end of the stomach, the spleen, tail of the pancreas, and descending colon. The anterior surface of the kidney is convex, the posterior is flat; the superior extremity is larger than the inferior, and is in relation with the supra-renal capsule; the convex border is turned outwards towards the parietes of the abdomen; the concave border looks inwards towards the vertebral column, and presents a deep notch (*hilum renale*), which leads to a cavity, or *sinus*, within the organ. In the *sinus renalis* are situated the vessels and nerves of the kidney and the expansion of the excretory duct called the **pelvis** of the kidney. At the hilum these vessels are so placed that the renal vein is in front of the artery, and the pelvis and ureter behind.

The kidney is surrounded by a thick layer of fat, contained in the meshes of a loose areolar tissue, forming the **adipose capsule**, and separating the kidney at the back from the diaphragm, anterior layer of the fascia lumborum, and ilio-hypogastric nerve; and internally from the edge of the psoas. Within this, the organ is enclosed in a **fibrous capsule**, which is thin, firm, and whitish, and composed of dense areolar tissue intermingled with elastic fibres, and beneath this an incomplete layer of unstriped muscle. The capsule is connected by its inner surface with the substance of the gland by fine areolar tissue, but so loosely as to be easily separable. The substance of the kidney is dense and fragile, and when divided by a longitudinal incision, exhibits two structures, different in colour and texture—an external *vascular* or *cortical portion*, and an internal *tubular* or *medullary portion*. The **medullary portion** consists of from eight to fifteen dark red conical masses, having their apices or **papillæ** directed towards the pelvis, and their bases

to the cortical substance; these conical masses are the **pyramids of Malpighi**. By their bases they are inseparably connected with the cortex; their apices, or papillæ (of a paler colour than the rest of the pyramids) project like little teats into the sinus of the kidney, being received into cavities lined with mucous membrane and called **calices**, which are subdivisions of the renal pelvis. The pyramids are composed of an assemblage of **straight tubules**, the *tubuli recti*, which open into a shallow depression on the summit of the papilla, and divide into branches at acute angles as they proceed from the apex to the base of the pyramid; these cause the radiate striation observable on a vertical section of the pyramids. The **cortical portion**, distinguished by its bright red colour, granular appearance, and softer texture, forms the surface of the organ, surrounding the base of each pyramid and penetrating between them to the sinus renalis. It therefore forms septa between the pyramids (*septa vel columnæ Bertini*), and marks the original composition of the kidney of separate lobes. It is composed of blood-vessels, with the cortical fasciculi and ultimate terminations of the tubuli uriniferi, held together by a delicate stroma of areolar tissue.

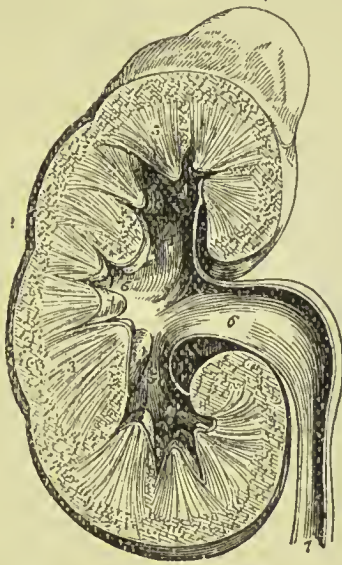


FIG. 465.—Section of the kidney, surmounted by the supra-renal body; the swellings on the surface mark the original constitution of the organ of lobes. 1. Supra-renal body. 2. Cortical portion of the kidney. 3, 3. Medullary portion, consisting of cones. 4, 4. Two of the papillæ projecting into their corresponding calices. 5, 5, 5. The three infundibula; the middle 5 is situated in the mouth of a calyx. 6. Pelvis. 7. Urter.

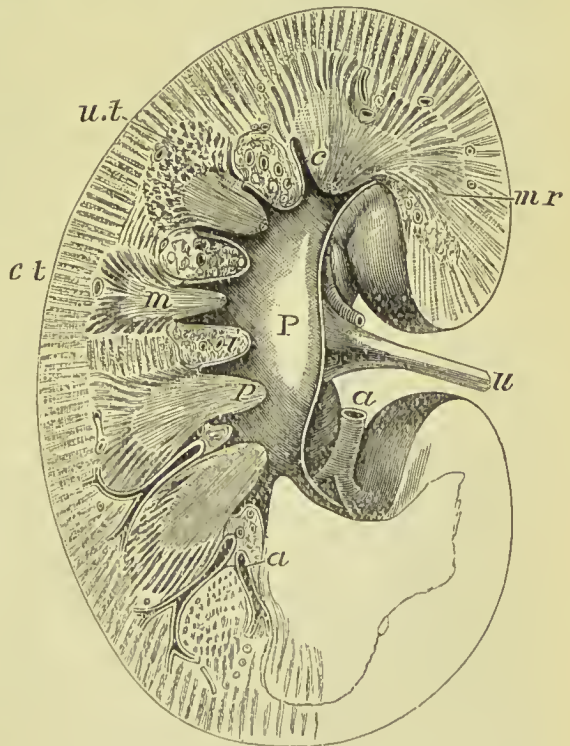


FIG. 466.—Vertical section of kidney. u. Ureter. P. Pelvis. a, a. Renal arteries. ct. Cortex. m. Pyramid of Malpighi. c. Calix. u.t. Cut uriniferous tubules. p. Papilla. i. Intertubular stroma. mr. Medullary rays.

Uriniferous tubules.—The kidney is a compound tubular gland, its secreting structure being formed by the uriniferous tubules. These commence by spherical dilatations, the **Malpighian capsules**, in the labyrinth of the cortex, each capsule enclosing a tuft of blood-

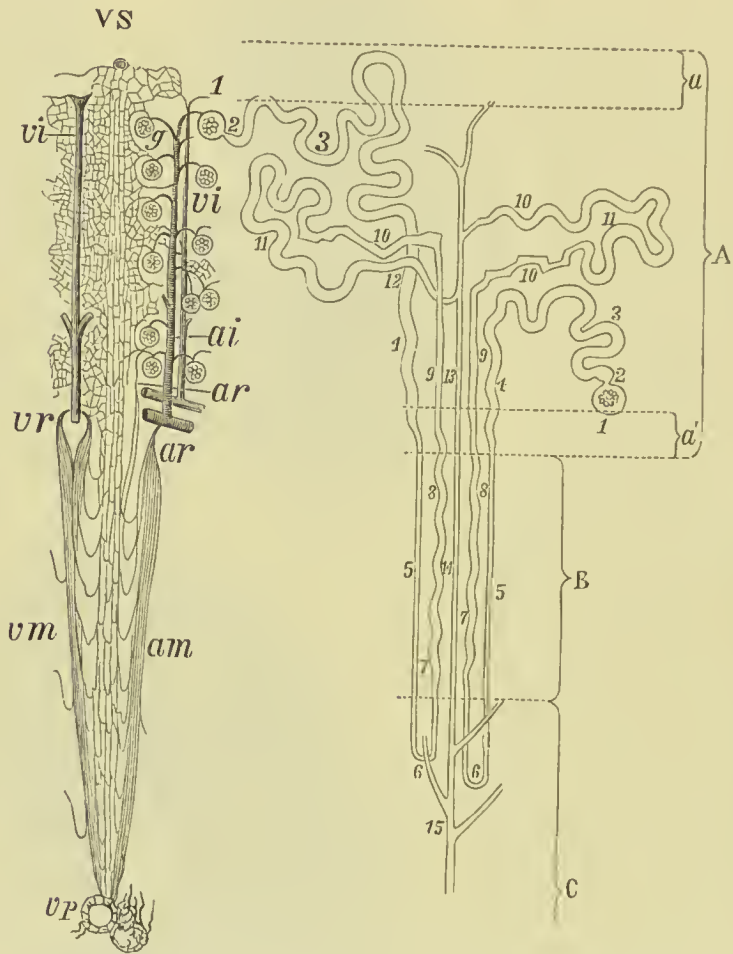


FIG. 467.—On the left of the figure the arrangement of the blood-vessels of the kidney is shown, on the right the course of the uriniferous tubules. *vs.* Vena stellulae. *vi.* Interlobular veins. *vr.* Vena rectae. *vm.* Veins of medullary part. *vp.* Veins of papillae. *ai.* Interlobular artery. *g.* Glomerulus. *ar.* Arteriae rectae. *am.* Arteries of medullary part. A. Cortex. B. Boundary zone. C. Papillary zone of medulla. *a, a'.* Superficial and deep layers of cortex, free of glomeruli. 1. Malpighian capsule. 2. Neck. 3. First convoluted tubule. 4. Spiral tubule of Schachowia. 5. Descending limb of looped tubule of Henle. 6. Bend. 7, 8, 9. Ascending limb. 10. Irregular tubule. 11. Second convoluted tubule. 12. Junctional tubule. 13, 14. Collecting tubule. 15. Excretory tubule.

vessels, the **Malpighian tuft** or **glomerulus**; the capsule and tuft together constituting the **Malpighian body**. The tubule, on issuing from the capsule, is constricted by a narrow **neck**, then widens out and becomes convoluted, forming the **first convoluted tubule**; next it passes towards one of the pyramids of the medulla, becoming

spiral as it descends—the **spiral tubule of Schachowa**. Entering the pyramid, the tubule becomes much narrower, and after a shorter or longer course bends on itself and again runs towards the cortex, becoming larger as it ascends, these two parts form the *descending* and *ascending limb* of the **looped-tubule of Henle**. On again entering the cortex, the uriniferous tubule becomes extremely irregular in outline, and is distinguished as the **irregular tubule**, and then again becoming convoluted forms the **second convoluted tubule**. The latter passes into a small **junctional tubule**, by which it is connected with one of the tubules in the Malpighian pyramids, called **collecting tubules**—these last uniting to form the **excretory tubules** already described as opening on to the apex of the papilla.

The part of the pyramids near the cortex is called the **boundary zone**; in it the tubules are collected into bundles, separated from each other by groups of small blood-vessels; and these, as they radiate from the pyramids into the cortex, form the **medullary rays**; the cortical substance between and around their ends is called, on account of its intricacy, the **labyrinth of the cortex**. The Malpighian body, first convoluted tubule, irregular tubule, and second convoluted tubule, are in the labyrinth; the spiral and junctional tubule are in the medullary rays; the descending and ascending limbs of the looped tubule of Henle, and the collecting tubules are in the boundary zone.

The tubules are formed by a basement membrane supporting epithelium; they vary considerably in width in different parts of their course. Near the apex of the papilla the excreting tube measures from $\frac{1}{240}$ to $\frac{1}{430}$ of an inch; the straight or collecting tubules are smaller, averaging $\frac{1}{800}$ of an inch; the junctional and convoluted portions are about the same size as the straight tubules; the looped tubules of Henle vary from $\frac{1}{1000}$ to $\frac{1}{1200}$ of an inch; and the Malpighian capsules are from $\frac{1}{120}$ to $\frac{1}{250}$ of an inch in width.

Epithelium of the tubules.—The epithelium of the excretory tubes is columnar, and the lumen is large in proportion to the depth of the cells; that in the collecting tubules is cubical, but the cells vary considerably as regards regularity and thickness. In the junctional tubules the epithelium is cubical but somewhat flattened, and the lumen is relatively large.

The second convoluted tubule (*intercalary tubule*) has an epithelium the cells of which are rather long, have a highly refractive protoplasm and a large nucleus, and possess at their bases lateral projections which dovetail into those of neighbouring cells. The irregular tubule is distinguished by the fact that, notwithstanding its irregularities in size and shape, the lumen is nearly the same throughout, this being brought about by the inequalities in the size of the cells; their protoplasm appears to be made up of a series of minute rods, placed vertically to the surface of the basement membrane. A difference exists in the appearance presented by the ascending and descending limb of the looped tubules of Henle; in

the latter the lumen is distinct, and the cells form a flattened layer thickened here and there by the presence of nuclei; in the former

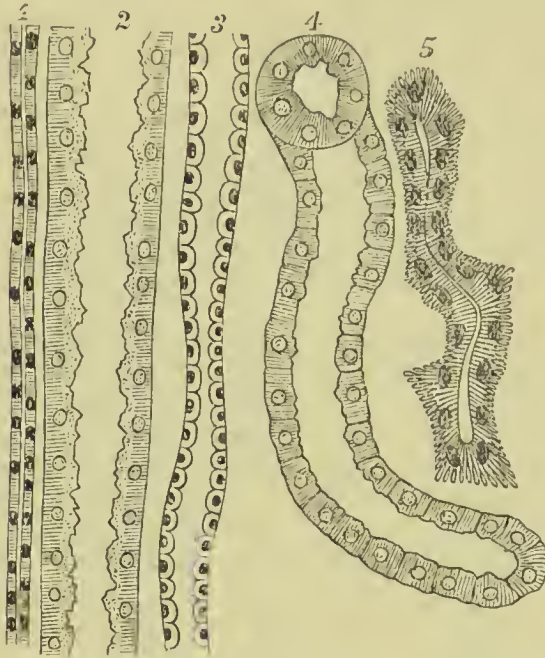


FIG. 468.—Epithelium of the uriniferous tubules.
 1. From ascending limb of looped tubule of Henle.
 2. From spiral tubule. 3. From collecting tubule.
 4. From convoluted tubule. 5. From irregular tubule.

the cells approximate in character to those of the convoluted tubes, and although the whole tube is wider than the descending limb the lumen is much narrower. In the spiral tube of Schachowa the lining cells are columnar, are firmly united by interlocking processes, and have the part next the basement membrane apparently composed of vertical rods; towards its termination, however, the cells become shorter, less fibrillated, and split into ridges with furrows between. The first convoluted tube has an epithelium which corresponds in all essentials with that of the spiral tube. The neck of the

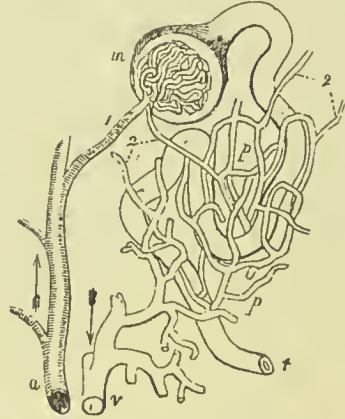Malpighian capsule is lined with cubical epithelium, and in many animals this is furnished with cilia; but in the human kidney they have not up to the present been demonstrated.

The **Malpighian bodies** are found only in the cortical substance of the kidney, and form the most distinctive feature of the structure of the organ. Two vessels are connected with each Malpighian body, one entering it, **afferent vessel**, and the other leaving it, **efferent vessel**; the glomerulus and its vessels resemble in appearance fruit supported on its stalk. The capsule is lined by a flattened epithelium, which may also be traced on to the surface of the glomerulus, being most distinct in the latter situation where the capsule opens into the first convoluted tube. The epithelial cells in the capsule are supported by a basement membrane formed of flattened epithelial cells.

Blood-vessels.—The **renal artery**, derived from the aorta, enters the kidney between the vein and ureter, and divides into four or five large trunks which pass between the papillæ to enter that portion of the cortical substance placed between the pyramids of the medulla: here they divide and subdivide, and give off small branches, which communicate across the bases of the pyramids so as to form imperfect arches between the cortical and medullary substance. From

these arches are given off **interlobular arteries**, placed between the medullary rays, and giving off afferent vessels on each side to the Malpighian bodies. In the Malpighian body the afferent artery divides into from five to eight branches, and each of these branches into a bundle of capillaries; they form a spherical vascular tuft, the **glomerulus**, and are again gathered up into a single branch, the *effluent vessel*. The *effluent vessel* is smaller than the afferent; it quits the

FIG. 469.—Plan of the renal circulation. *a*. Interlobular branch of the renal artery giving off several afferent vessels. 1. An afferent twig to the capillary tuft contained in the Malpighian body, *m*; from the Malpighian body the uriniferous tube is seen taking its tortuous course to *t*. 2, 2. Effluent vessels; that which proceeds from the Malpighian body is smaller than the corresponding afferent branch. *p, p*. The capillary plexus, ramifying on the uriniferous tube. This plexus receives its blood from the afferent vessels, 2, 2; and transmits it to the branch of the renal vein, *v*.



Malpighian body by the side of the latter and divides into capillary vessels, which form a rich plexus around the uriniferous tubules of the labyrinth, and eventually terminate in the renal veins. Those efferent vessels which are nearest to the base of the pyramids take a straight course (*arteriola rectæ*) between the straight tubules, and giving off but few branches in their course, also pass into a capillary plexus which surrounds the tubules and terminates in the *venulæ rectæ*. The renal artery also gives off branches to the capsule of the kidney which anastomose freely with branches of the lumbar arteries.

The **veins** of the kidney commence at the surface by minute converging venules, the **stellated vessels**, in the cortical substance where they form the **interlobular veins**, and in the pyramids of Malpighi, where they constitute the **venulæ rectæ**; proceeding from these three sources, they unite to form the branches of the renal vein, which terminates in the vena cava by a single large trunk at each side; the left renal vein receiving the left spermatic vein. The renal veins are less capacious than the renal arteries, they have no

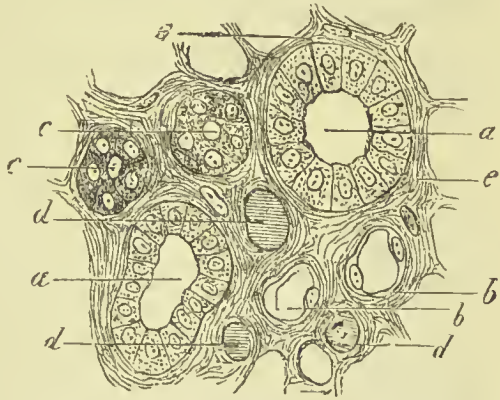


FIG. 470.—Transverse section through a Malpighian pyramid. *a, a*. Collecting tubule with columnar epithelium. *b, b*. Descending limb of looped tubule of Henle, lined by flat cells. *c, c*. Ascending limb with thick granular cells. *d, d*. Transverse section of vessels. *e, e*. Intertubular stroma.

valves, and carry blood distinctly purer than that brought to the kidneys by the arteries. The **lymphatic vessels** consist of a superficial set placed beneath the capsule, and of a deep set which accompanies the deep blood-vessels; both sets terminate in the lumbar glands.

The **nerves** are derived from the renal plexus, which is formed partly by the solar plexus, and partly by the third splanchnic nerve. The renal plexus gives branches to the spermatic plexus, and branches which accompany the ureters.

Intertubular Stroma.—The tubules and vessels of the kidney are held together and supported by very fine connective tissue, that in the neighbourhood of the vessels and around the Malpighian bodies being fibrous in its character. The stroma is more abundant in the cortical than in the medullary portion, and is there chiefly formed of connective-tissue corpuscles.

The **cavity of the kidney** is occupied by a membranous bag,

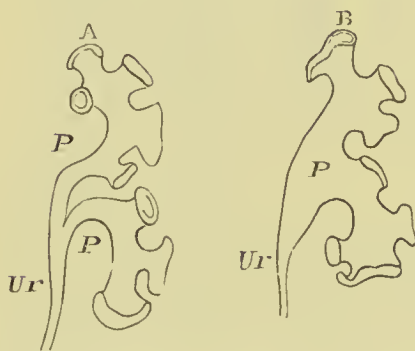


FIG. 471.—Two varieties in the arrangement of the pelvis and infundibula of the kidney.

the **pelvis renalis**, which gives off three processes, the **infundibula**, one for each extremity, and one for the middle of the organ; and the infundibula give off smaller processes termed **calices**, which embrace the papillæ and form a separate pouch around each; the calyx being firmly attached to the base of the papilla and continuous with the fibrous capsule. Externally the sac of the pelvis renalis contracts into its excretory duct, the ureter. Sometimes there is no true pelvis, the

calices uniting to form two or more infundibula which join to constitute the ureter.

Ureter.

The ureter (*οὐρέω*, I pass water) is a membranous tube of about the diameter of a goose-quill, and nearly eighteen inches in length, continuous superiorly with the pelvis of the kidney, and constricted inferiorly, where it lies in an oblique direction between the muscular and mucous coat of the base of the bladder, and opens on its mucous surface. Lying along the posterior wall of the abdomen, it is situated behind the peritoneum, and is crossed by the spermatic vessels; in its course downwards it rests against the anterior surface of the psoas, and crosses the common iliac artery and vein, and then the external iliac vessels. Within the pelvis it crosses the hypogastric cord and vas deferens in the male; and runs by the side of the cervix uteri and upper part of the vagina in the female. There are sometimes two ureters to one kidney.

The ureter, the pelvis, the infundibula, and the calices are composed of three coats, external or fibrous, middle or muscular, and

internal or mucous. The **fibrous coat** consists of condensed areolar tissue, intermingled with fine elastic fibres. The **muscular coat** is made up of muscular fibres of the smooth kind, disposed in three layers, external and internal longitudinal, and a circular layer between. The muscular coat is thick in the ureter and pelvis renalis, thin on the calices, and ceases altogether at the attachment of the latter to the papillæ. The **mucous coat** is thin, vascular, and without villi; on the papillæ it is connected with the substance of the pyramids, and is continuous with the uriniferous tubules, while inferiorly it becomes blended with the mucous membrane of the bladder. The *epithelium* of the mucous coat is thick, and composed of several layers of nucleated cells, which are small and round next the membrane; of larger size and cylindrical or pear-shaped in the middle; and large and cubical at the surface, sometimes measuring $\frac{1}{600}$ of an inch in breadth, and not unfrequently containing two nuclei. Many of the superficial cubical cells are excavated on their under surface into little depressions, into which the heads of the pear-shaped cells of the middle layer fit.

PELVIS.

The cavity of the pelvis is that portion of the great abdominal cavity which is included within the bones of the pelvis, below the level of the pectineal line and promontory of the sacrum. It is bounded by the cavity of the abdomen above, and by the perineum below; its internal parietes are formed in front, below, and at the sides, by the peritoneum, pelvic fascia, levatores ani, and obturator internus muscles; and behind, by the coccygei muscles, sacro-ischiatic ligaments, pyriformes muscles, sacral plexus of nerves, sacrum, and coccyx.

The **viscera of the pelvis** in the male are—the urinary bladder, prostate gland, vesiculæ seminales, and rectum.

URINARY BLADDER.

The bladder is a hollow membranous viscus, triangular and flattened against the pubes when empty, ovoid when distended, situated behind the pubes and in front of and upon the rectum. It is larger in its vertical diameter than from side to side; and its long axis is directed from above, obliquely downwards and backwards. Braune has shown that in the erect posture the neck of the bladder is the lowest part of the viscus. It is divided into body, fundus, base, and neck. The **body** comprehends the middle zone of the organ; the **summit** or **superior fundus**, its upper segment; the **base** or **inferior fundus**, the lower broad extremity which rests on the rectum; and the **neck**, the narrow constricted portion which is applied against the prostate gland.

Relations.—When moderately distended the bladder is in relation, *in front*, with the pubes (some retro-pubic fat intervening), and

the anterior true ligaments; *behind*, with the small intestines occupying the recto-vesical pouch; *below*, with the rectum, vesiculæ seminales, vasa deferentia, ureters, and recto-vesical fascia, and at *each side* by the vas deferens, lateral true ligament, ureter and obliterated hypo-gastric artery. The *summit* is connected with the abdominal wall by means of the urachus, and the *neck* is surrounded by the prostate gland.

It is retained in position by ligaments which are divisible into true and false: the **true ligaments** are five in number, two anterior, two lateral, and the cord of the urachus; the **false ligaments** are folds of the peritoneum, and are also five in number, two posterior, two lateral, and one superior.

The **anterior ligaments** (*pubo-prostatic*) are formed by the visceral layer of the pelvic fascia, in its passage from the inner surface of the pubes at each side of the symphysis to the neck of the bladder and prostate gland. Between the two ligaments the dorsal vein of the penis runs.

The **lateral ligaments** are also formed by the visceral layer of the pelvic fascia, in its passage from the white line to the sides of the prostate gland and bladder.

The **ligament of the urachus** is a fibrous cord resulting from the obliteration of the allantoic canal in the embryo. It proceeds from the summit of the bladder, and ascends along the linea alba to the umbilicus.

The **posterior false ligaments** are the folds of peritoneum passing from the rectum and sides of the sacrum to the bladder; they contain the ureters, and the vessels and nerves of the bladder.

The **lateral false ligaments** are formed by the passage of the peritoneum from the side of the pelvis to the bladder; they cover the upper and posterior half of its lateral wall. The obliterated hypogastric artery lies along the line of reflection of the membrane.

The **superior or suspensory false ligament** is the fold of peritoneum caused by the prominence of the cord of the urachus and the cords of the obliterated hypogastric arteries.

Structure.—The bladder is composed of four coats, external or serous, muscular, areolar, and mucous.

The **serous or peritoneal coat** covers the whole posterior surface of the bladder, and the under surface as far forwards as the entrance of the ureters, where it is attached to the back part of the recto-vesical fascia. At the sides it is limited by the obliterated hypogastric arteries, and consequently only invests the upper and posterior part; on the anterior surface it is entirely absent; above, it covers the part behind the urachus.

The **muscular coat** consists of three layers of unstriped muscular fibre; external or longitudinal, middle or circular, and internal, which is also longitudinal. The **external layer, or detrusor urinæ**, consists of parallel longitudinal fasciculi which take their origin from the anterior ligaments of the bladder, thence named tendons of the detrusor urinæ; they spread out upon the upper surface of the

prostate gland and ascend upon the anterior surface of the bladder to the fundus, where they are inserted into the subserous tissue, some being continuous with the longitudinal fibres of the posterior surface of the organ, and others prolonged upon the urachus. The longitudinal fasciculi of the posterior surface and sides of the bladder, attached superiorly to the subserous tissue, and partly continuous with those of the opposite aspect, while some are prolonged upon the urachus, are attached inferiorly to the prostate gland, those in the middle line being lost in the deep muscular layer of the neck of the bladder. The **middle layer** consists of circular fibres which are most numerous at the cervix, where they form a moderately thick stratum, the **sphincter vesicæ**, and are then continued onwards around the prostatic urethra. The **internal layer** (submucous layer; Ellis), thinner than the preceding, is composed of fibres which are oblique and scattered in the fundus and body of the bladder, but become longitudinal in its lower part and base, and are continued into the urethra. At the base of the bladder this layer is strengthened by the longitudinal fibres of the ureters. The three muscular layers communicate with each other by means of a frequent interchange of fasciculi.

The **areolar** or **submucous coat** is the thick layer of areolar tissue interposed between the mucous and muscular coat, and forming the bond of union between them.

The **mucous coat** is thick and smooth, of a pale-rose colour, and exactly moulded on the muscular coat, to which it is loosely connected by the submucous coat. When the bladder is empty it is thrown into folds or *rugæ*, excepting in the triangular area at the neck called the *trigone*. The mucous membrane is continuous through the ureters with the lining membrane of the pelvis of the kidney, and through the urethra with that of the seminiferous ducts, prostate gland, and Cowper's glands. It is provided with a stratified epithelium similar to that of the ureters, the deeper cells of which are conical or fusiform; the intermediate pyriform, and the superficial spheroidal or flattened, and of unequal size. It has a thin layer of *mucularis mucosæ* on its outer surface. The mucous membrane is rich in vessels, which are most abundant, as are the nerves, in the cervix and fundus; the nerves are not numerous.

On the internal surface of the base of the bladder is a triangular smooth plane, the **trigonum vesicæ** or vesical trigone (Fig. 474), on which the mucous membrane is paler and thinner than the rest, and is not thrown into folds when the viscus is empty. Calculi resting on this part give rise to much suffering on account of the greater number of nerves distributed to the cervix vesicæ. The trigone is bounded at each side by the raised ridge, corresponding with the muscles of the ureters, at each posterior angle by the openings of the ureters, and, in front, by a slight elevation of the mucous membrane at the entrance of the urethra, called *uvula vesicæ*.

The external surface of the base of the bladder corresponding with the trigone is also triangular, and separated from the rectum

by the recto-vesical layer of pelvic fascia. It is bounded behind by the recto-vesical fold of peritoneum and at each side by the vasa deferentia, which converge almost to a point at the base of the prostate gland. It is uncovered by peritoneum, and for this reason it is through this space that the opening is made in the recto-vesical operation for puncture of the bladder.

Vessels and Nerves.—The *arteries* of the urinary bladder are the *superior vesical*, three or four small branches which proceed from

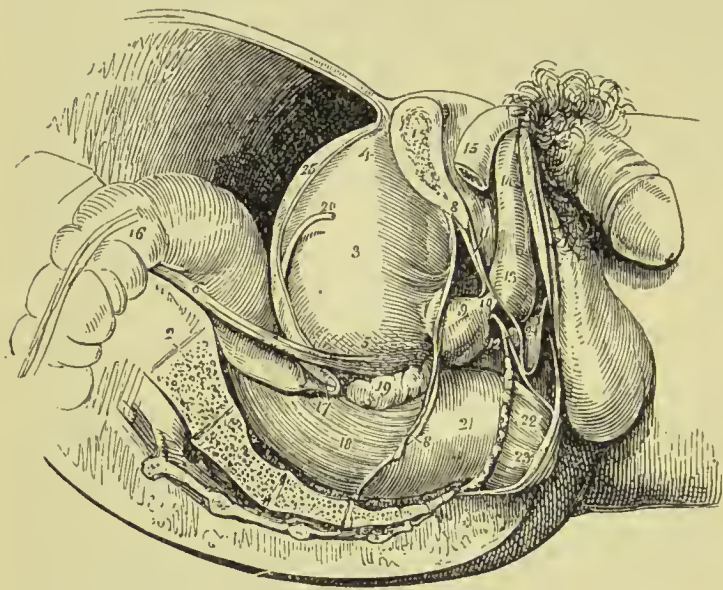


FIG. 472. — Side view of the viscera of the male pelvis, *in situ*. The right side of the pelvis has been removed by a vertical section made through the os pubis near the symphysis; and another through the middle of the sacrum. 1. Divided surface of the os pubis. 2. Divided surface of the sacrum. 3. Body of the bladder. 4. Its superior fundus; from the apex is seen passing upwards the urachus. 5. Base of the bladder.

6. Ureter. 7. Neck of the bladder. 8, 8. Pelvic fascia; the fibres immediately above 7, are given off from the pelvic fascia, and represent the anterior ligaments of the bladder. 9. Prostate gland. 10. Membranous portion of the urethra. 11. Triangular ligament. 12. One of Cowper's glands lying beneath the membranous portion of the urethra. 13. Bulb of corpus spongiosum. 14. Body of corpus spongiosum. 15. Right crus penis. 16. Upper part of first portion of the rectum. 17. Recto-vesical fold of peritoneum. 18. Second portion of rectum. 19. Right vesicula seminalis. 20. Vas deferens. 21. The rectum covered by the descending layer of the pelvic fascia, just as it is making its bend backwards to constitute the third portion. 22. Part of the levator ani muscle investing the lower part of the rectum. 23. External sphincter ani. 24. Interval between Colles' fascia and the anterior layer of the triangular ligament; they are seen to be continuous beneath the figure.

the commencement of the hypogastric artery, previously to its complete obliteration; an *inferior vesical*, from the internal iliac. The latter is distributed to the base of the bladder, vesiculæ seminales, and prostate gland. The *veins* are numerous and of large size, and form a plexus around the neck and at the base of the bladder; the plexus communicates with the prostatic plexus and hæmorrhoidal veins. The *nerves* of the bladder are derived from the inferior hypogastric plexuses and their communications with the third and fourth sacral nerves. They form a gangliated plexus on the blood-vessels, and also form a network under the epithelium.

PLATE 26.

THE MALE PERINEUM.

FIG. 1.—THE BULBO-CAVERNOSUS REMOVED TO SHOW THE BULB OF THE URETHRA, AND THE TRIANGULAR LIGAMENT PARTIALLY REMOVED TO SHOW COWPER'S GLANDS.

FIG. 2.—THE LEVATOR ANI REMOVED, AND RECTUM TURNED DOWN TO SHOW THE PROSTATE AND NECK OF BLADDER.

- A. Urethra.
B. Bulb.
C. Prostate.
D. Crus penis with ischio-cavernosus.
E. Triangular ligament (cut to show Cowper's glands).
F. Anus.
G. Tuber ischii.
H. Coccyx.

- I. Gluteus maximus.
K. Levator ani (cut).
L. Pudic artery.
M. Membranous urethra.
N. Vesicula seminalis.
O. Great sacro-sciatic ligament.
P. Base of bladder.
Q. Vas deferens.

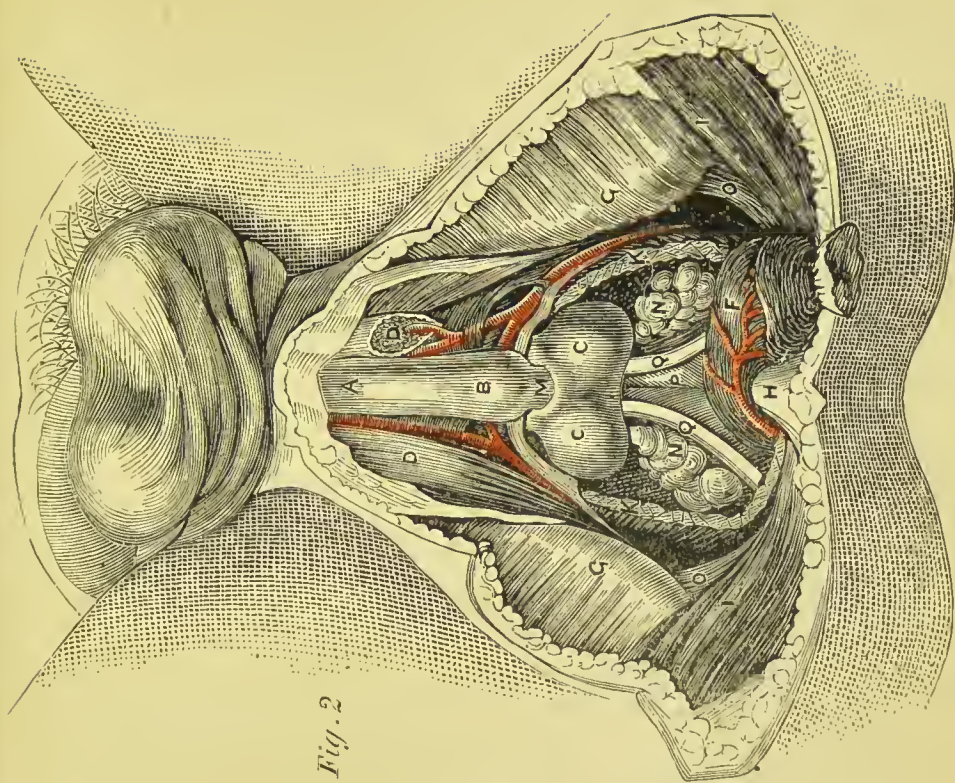


Fig. 2

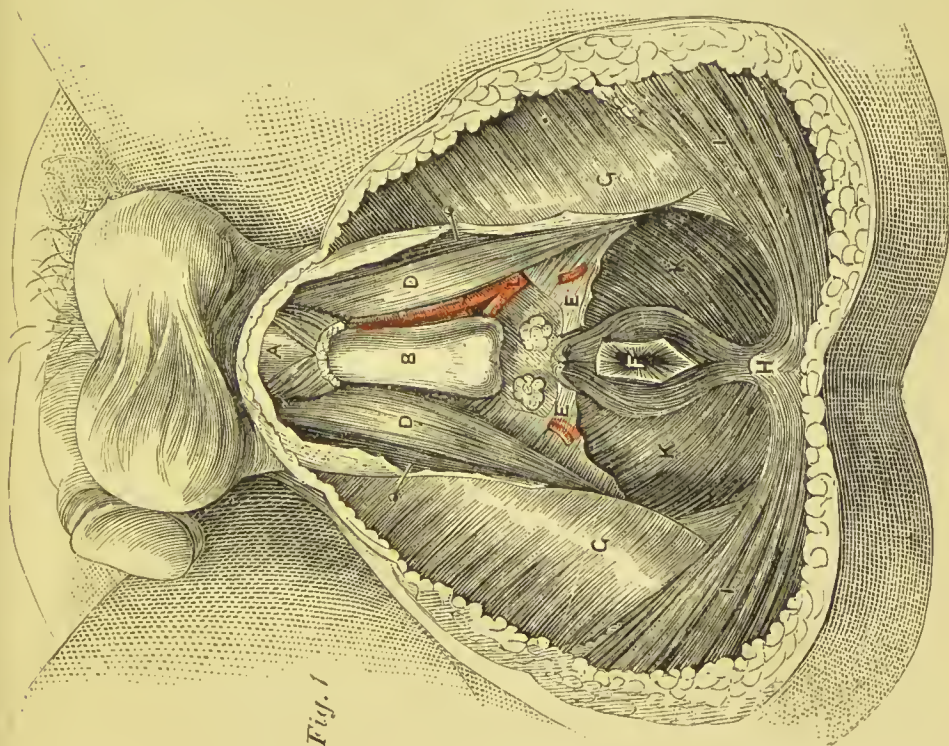


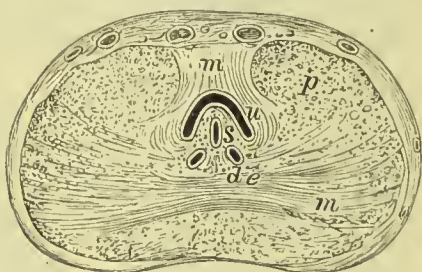
Fig. 1



PROSTATE GLAND.

The prostate gland (*προίστημι*, to stand in front of) is situated in front of the neck of the bladder, behind the triangular ligament and pelvic fascia, and upon the rectum, through which latter it may be felt with the finger. It measures about one and a half inches across at its base, is about an inch and a quarter from base to apex, and its depth is nearly an inch; it weighs from six drachms to an ounce. It surrounds the commencement of the urethra for a little more than an inch of its extent, and resembles a Spanish chestnut both in size and form; the base being directed backwards towards the neck of the bladder, the apex forwards, and the flattened side towards the rectum. It is retained firmly in position by the anterior and lateral ligaments of the bladder, and by a process of the pelvic fascia, which forms a sheath around it. It consists of three imperfectly defined lobes, two lateral and a middle lobe or isthmus; the lateral lobes are distinguished by an indentation at the base of the gland, and a slight furrow on its upper and lower surface. The third lobe (*prometria*) is a small mass which passes between the two lateral

FIG. 473.—Transverse section through the middle of the prostate gland. *u.* The urethra, encroached on below by the caput gallinaginis. *s.* Sinus pocularis. *de.* Ejaculatory ducts. The upper *m* shows the deep sphincter muscular fibres, the lower *m* the muscular bands penetrating into the lateral lobes. *p.* Glandular substance.



lobes at the back part of the under surface of the organ; it is generally imperfectly marked in the normal state of the gland, but becomes evident when enlarged; when prominent it corresponds to the elevation at the neck of the bladder called the *uvula*.

Structure.—It is covered by a thick and strong fibrous capsule, derived from the recto-vesical fascia behind and deep layer of the triangular ligament in front, and divisible into two layers, between which the prostatic plexus of veins is placed. Its proper structure is composed of smooth muscle and glandular tissue, the latter being not more than one-third or one-fourth of the whole, and consisting of from thirty to fifty compound racemose glands, of a pyriform shape. Its secretion is poured into the prostatic portion of the urethra by fifteen or twenty excretory ducts. The ducts of the lateral lobes open into the urethra at each side of the vern montanum; those of the third lobe open upon and behind the vern. The greater part of the prostate is formed of unstriped muscle mixed with white and yellow fibrous tissue; the muscle fibres are many of them arranged circularly around the urethra, and are continuous with those of the sphincter vesicæ; others pass transversely across

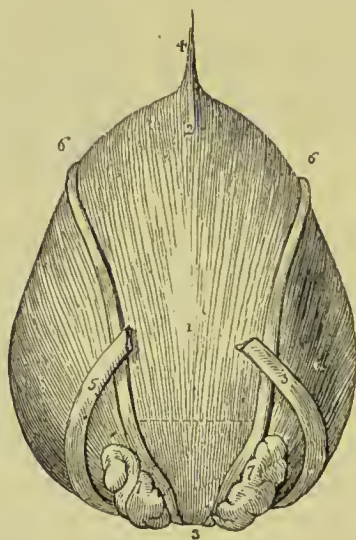
in front and behind the urethra, and radiate into the lateral lobes. The urethra, in passing through the prostate, lies one-third nearer its upper, than its lower, surface.

The **arteries** of the prostate are small, and derived from the inferior vesical and middle hæmorrhoidal; they distribute numerous capillaries to the glandular structure of the organ. The **veins** form a rich plexus in the submucous tissue of the urethra, and another of larger vessels on the exterior of the gland; the latter receives from the front the veins of the penis, and terminates in the vesical plexus. **Lymphatics** are distributed with the veins between the two layers of the capsule.

VESICULÆ SEMINALES.

On the under surface of the base of the bladder, and converging towards the base of the prostate gland, are two lobulated and somewhat pyriform bodies, about two inches in length, the vesiculæ seminales. Their upper surface is in contact with the base of the bladder; the under side rests on the rectum, separated only by the recto-vesical fascia; the larger extremities are directed backwards and outwards, and the smaller ends almost meet at the base of the prostate. They enclose between them a triangular space, which is

FIG. 474.—Posterior aspect of the male bladder; the serous covering is removed in order to show the muscular coat. 1. Body of the bladder. 2. Superior fundus. 3. Inferior fundus or base. 4. Urachus. 5, 5. Ureters. 6, 6. Vasa deferentia. 7, 7. Vesiculæ seminales. The triangular area, bounded by the vasa deferentia and vesiculæ seminales at either side, a dotted line above, and the figure 3 below, is the space corresponding with the trigonum vesicæ. The dotted line, forming the base of this triangular area, marks the limit of the recto-vesical fold of peritoneum.



bounded posteriorly by the recto-vesical fold of peritoneum, and corresponds with the trigonum vesicæ on the interior of the bladder. Each vesicula is formed by the convolutions of a single tube, which gives off several irregular cæcal sacculi and branches. It is enclosed in a thin fibrous membrane, and is constricted beneath the isthmus of the prostate gland,

where it terminates in the ejaculatory duct. The **vas deferens**, somewhat enlarged and sacculated, lies along the inner border of each vesicula, and is included in its fibrous investment; it unites with the vesicula beneath the isthmus of the prostate, in the formation of the ejaculatory duct.

The **ejaculatory duct** is about three-quarters of an inch in length, and running forwards, first between the base of the prostate and the isthmus, and then through the tissue of the veru montanum,

opens on the mucous membrane of the urethra, by the side of or within the aperture of the sinus pocularis.

The vesiculæ seminales and vasa deferentia are partly covered by a muscular layer, *compressor vesiculæ et ductus seminalis* (Ellis); which is brought into view on raising the recto-vesical fascia. This muscular layer consists of transverse and longitudinal fibres, the *transverse fibres* being the most superficial, and continuous with the posterior border of the prostate gland; the *longitudinal fibres* lying in contact with the vesiculæ and vasa deferentia.

In **structure** the vesiculæ seminales are composed of three coats: *external*, a thin **fibrous** membrane, made up of condensed areolar tissue; *middle*, a **muscular** coat, consisting of smooth muscular fibres arranged in two layers, longitudinal and circular; and *internal*, a thin **mucous** membrane, vascular, marked by a delicate reticulation of ridges and alveoli, and coated with a squamous epithelium of cells containing yellowish pigment granules. Opening on to the surface of the mucous membrane are a large number of tubular glands, which give to its surface a brownish-yellow colour. The vesiculæ are covered externally and their convolutions held together by a thin membrane of areolar tissue, and they are further invested by the recto-vesical fascia, and the muscular stratum already described.

MALE ORGANS OF GENERATION.

The organs of generation in the male are—the penis and testicles, with their appendages.

PENIS.

The penis is divisible into a body, root, and extremity. The **body** is surrounded by a thin integument, which is remarkable for the looseness of its connection with the deeper parts of the organ, and for containing no adipose tissue. The **root** is broad, and firmly adherent to the rami of the pubes and ischium by means of two strong processes, the **crura**, and connected to the symphysis pubis by an elastic fibrous membrane, the **suspensory ligament**. The *extremity* or **glans penis** resembles an obtuse cone, somewhat compressed from above downwards, and of a deeper red colour than the surrounding skin. At its apex is a small vertical slit, the **meatus urinarius**, which is bounded by two, more or less protuberant, labia; and, extending backwards from the meatus, a grooved raphé, to which a loose fold of mucous membrane, the **frænum præputii**, is attached. Over the surface of the glans the integument takes on the characters of mucous membrane; it is very intimately adherent to the tissue beneath it, is very vascular, and is covered with large papillæ, some of which contain vascular tufts and others nerve endings. The base of the glans is marked by a projecting collar, the **corona glandis**, in the groove beneath which (*fossa glandis*) are placed the openings of numerous glands, the **glandulæ odoriferæ**

Tysoni. The integument around the base of the glans forms a loose fold, the **prepuce**, which, in the collapsed state of the organ, may be drawn over the glans, but, in its distended state, is obliterated, and serves to facilitate its enlargement. The internal surface of the prepuce is lined by mucous membrane, which, as above described, is reflected over the glans, and, at the meatus urinarius, is continuous with the mucous lining of the urethra.

The **superficial fascia** of the penis is thin, and its areolar structure free from fat; it is continuous with the superficial fascia of the abdomen above, and with the dartos and superficial fascia of the perineum below.

The **suspensory ligament** of the penis is an elastic fibrous membrane of triangular form, attached by its apex to the symphysis pubis; and by its base, to the body of the penis. Near the latter attachment it separates into two layers, to give passage to the dorsal vessels and nerves of the penis.

The penis is composed of the *corpus cavernosum* and *corpus spongiosum*, and contains in its interior the longest portion of the urethra.

The **corpus cavernosum** is distinguished into two lateral portions (corpora cavernosa) by an imperfect septum and a superior and inferior groove, and is divided posteriorly into two crura. It is firmly adherent, by means of its crura, to the rami of the pubes and ischium; and each crus, previously to its junction with its fellow, presents a slight enlargement, which was named by Kobelt, the **bulb**. The corpus cavernosum forms, anteriorly, a single rounded extremity, which is received into a fossa in the base of the glans; the superior groove lodges the dorsal vessels of the penis, and the inferior receives the corpus spongiosum. Its fibrous tunic is thick, elastic, and extremely firm, and sends a number of fibrous bands and cords (trabeculae) inwards from the inferior groove, which cross the interior in a radiating direction, and are inserted into the inner walls of the tunic. These trabeculae are most abundant at the middle line, where they are

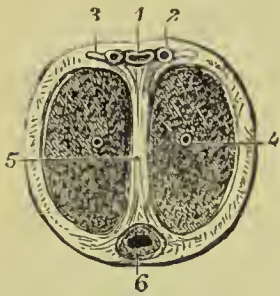

FIG. 475.—Transverse section of the penis. 1. Dorsal vein. 2. Dorsal artery. 3. Dorsal nerve. 4. Artery of corpus cavernosum. 5. Septum pectiniforme. 6. Urethra, surrounded by corpus spongiosum.

ranged vertically, side by side, somewhat like the teeth of a comb, and constitute the imperfect partition of the corpus cavernosum, called **septum pectiniforme**. The septum is more complete at its posterior than towards its anterior part.

The tunic of the corpus cavernosum consists of two layers of fibrous fasciculi. The *external* is longitudinal and forms a kind of close net by the frequent interchange of fibrous bundles; it is common to the two corpora cavernosa. The *internal*, less thick, forms a circle around each lateral mass, and also constitutes the septum pectiniforme. From its anterior extremity it gives off small fibrous bands,

which are prolonged into the substance of the glans penis. The fibres of the fibrous coat penetrate into the interior, and there form the *trabeculae* of the cavernous erectile tissue.

The **corpus spongiosum** is situated along the under surface of the corpus cavernosum, in its inferior groove. It commences by its posterior extremity between and beneath the crura penis, where it forms an enlargement, the **bulb**, and terminates anteriorly by another expansion, the **glans penis**. Its middle portion, or body, is nearly cylindrical, and tapers gradually from the posterior to the anterior extremity. The bulb is adherent to the triangular ligament by means of a prolongation of fibrous membrane; in the rest of its extent the corpus spongiosum is attached to the corpus cavernosum by areolar tissue, and by veins which pass upwards to reach the dorsal vein. It is composed of erectile tissue, enclosed in a dense fibrous layer much thinner than that of the corpus cavernosum, and contains the spongy portion of the urethra, which lies nearer its upper than its lower wall. The bulb shows a tendency to division into two lobes, an appearance which is due to the existence of a thin longitudinal septum in its interior.

The fibrous tunic of the corpus spongiosum, unlike that of the corpus cavernosum, consists only of circular fibres which are reflected inwards along the middle line, forming a septum which is complete only in the bulb; the reflected fibres of this septum embrace the urethra through its entire length, and exclude the latter from the proper structure of the corpus spongiosum.

Erectile tissue is a peculiar cellulo-vascular structure, entering in considerable quantity into the composition of the organs of generation. It consists of bands of fibrous and elastic tissue (with a few muscular fibres) which pass from the capsule of the organ into its interior, and there divide and unite in such a manner as to produce a system of cavities communicating freely with each other. The cavities are smaller in the glans penis, corpus spongiosum, and circumference of the corpus cavernosum than in the central part of the latter, where they are large and dilated; they are lined by a layer of flattened endothelial cells, continuous with those lining the arteries and veins. The cavernous spaces are at all times filled with blood, but become overcharged and distended during erection of the organ, in consequence of pressure upon its large veins retarding the venous flow. The arteries are convoluted in the passive state of the penis, but straightened in its distended condition; they terminate in large capillaries, which do not form a plexus, as in other situations, but open directly into the cavernous spaces. Some of the finer twigs of the arteries have a peculiar, twisted, and dilated or tendril-like appearance, first described by Müller under the name of *arteriæ helicinae*. The helicine arteries are somewhat dilated where they lie in the trabeculae, and are bound down by small fibrous bands, possibly for the purpose of limiting their distension. The venous plexus conveys the blood into the efferent veins of the penis, by which it is returned to the general circulation.

Vessels and Nerves.—The arteries of the penis are derived from the internal pudic; they are—the arteries of the bulb, arteries of the corpus cavernosum, and dorsum of the penis.

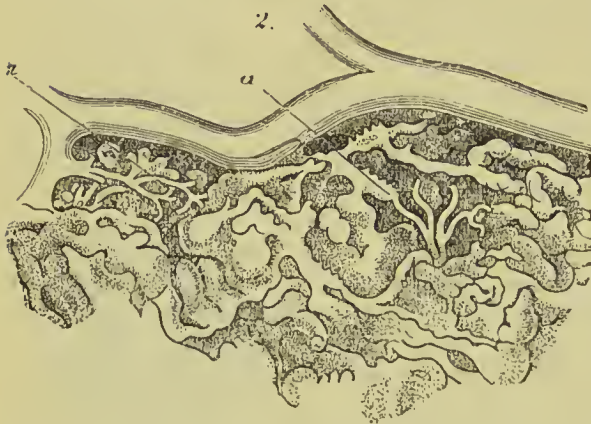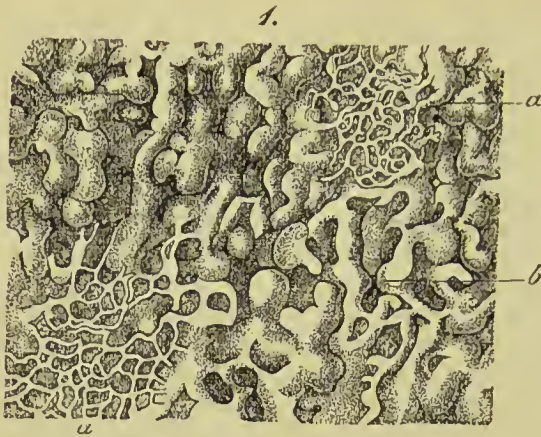


FIG. 476.—Structure of the peripheral portion of the corpus cavernosum penis. 1, *a, a*. Superficial network. *b*. Deep network. 2. Connection of the arterial twigs (*a, a*) with the canals of the deeper cortical network.

pelvic glands. The *nerves* are derived from the pudic nerve, sacral plexus, and hypogastric plexus.

Its *veins* are superficial and deep. The deep veins run by the side of the deep arteries, and terminate in the internal pudic veins. The superficial veins escape in considerable number from the base of the glans, and converge on the dorsum penis, to form a large dorsal vein, which receives other veins from the corpus cavernosum and spongiosum in its course, and passes backwards between two layers of the ligamentum suspensorium, and through the triangular ligament beneath the arch of the pubes, to terminate in the prostatic plexus.

The **lymphatics** terminate in the upper group of inguinal glands, while some of the deeper lymphatics take the course of the urethra and end in the

URETHRA.

The urethra is the membranous canal extending from the neck of the bladder to the meatus urinarius. It is curved in its course, and composed of three layers, a mucous coat, submucous coat, and muscular coat. The **mucous coat** is thin and smooth; it is continuous internally with the mucous membrane of the bladder; externally, with the investing membrane of the glans; and at certain points of its extent, with the lining membrane of the numerous ducts which open into the urethra, namely, those of

Cowper's glands, prostate gland, vasa deferentia, and vesiculae seminales. It is provided with a stratified squamous epithelium corresponding with that of the bladder, and has opening on to its surface numerous mucous recesses or crypts, and the ducts of the glands lying in the submucous tissue. The **submucous coat** is loose, and contains a convoluted vascular structure resembling erectile tissue ; it also contains numerous racemose mucous glands, which

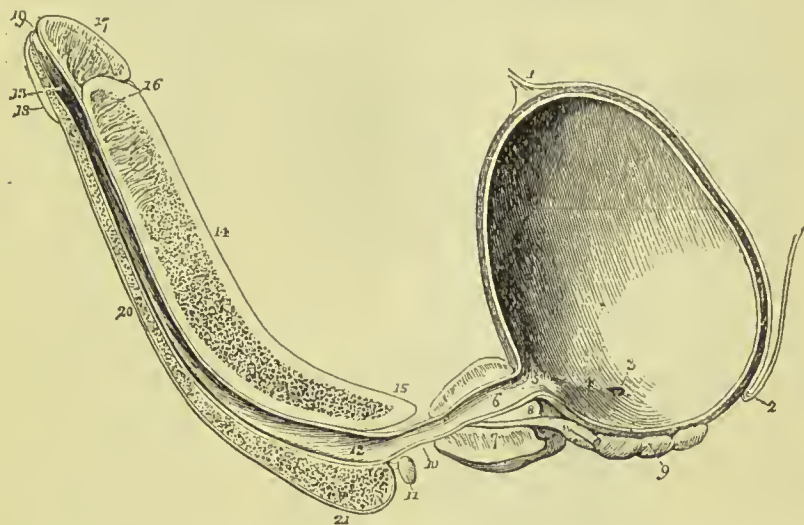


FIG. 477.—Longitudinal section of the bladder, prostate gland, and penis, showing the urethra. 1. Urachus. 2. Recto-vesical fold of peritoneum. 3. Opening of the right ureter. 4. A slight ridge, formed by the muscle of the ureter, and extending from the termination of the ureter to the commencement of the urethra. This ridge forms the lateral boundary of the trigonum vesicæ. 5. Commencement of the urethra ; the elevation of mucous membrane immediately below the figure is the uvula vesicæ. The constriction of the bladder at this point is the neck of the bladder. 6. Prostatic portion of the urethra. 7. Prostate gland ; the difference of thickness of the gland above and below the urethra is shown. 8. Isthmus, or third lobe of the prostate, immediately beneath which the ejaculatory duct is seen passing. 9. Right vesicula seminalis ; the vas deferens is seen to be cut short off, close to its junction with the ejaculatory duct. 10. Membranous portion of the urethra. 11. Cowper's gland of the right side, with its duct. 12. Bulbous portion of the urethra ; throughout the whole length of the urethra of the corpus spongiosum numerous lacunæ are seen. 13. Fossa navicularis. 14. Corpus cavernosum, cut somewhat obliquely to the right side, near its lower part. 15. Right crus penis. 16. Near the upper part of the corpus cavernosum, the section has fallen a little to the left of the middle line ; a portion of the septum pectiniforme is consequently seen. This figure also indicates the thickness of the fibrous investment of the corpus cavernosum, and its abrupt termination at the base of (17) the glans penis. 18. Lower segment of the glans. 19. Meatus urinarius. 20. Corpus spongiosum. 21. Bulb of the corpus spongiosum.

open on the surface of the mucous membrane (*glands of Littre*). The glands are most abundant along the floor of the urethra, especially in the bulbous portion. The **muscular coat** consists of unstripped muscular fibres, the outer layer of which is arranged circularly and is continuous with the circular muscular layer of the bladder ; the inner layer is longitudinal.

The urethra is about eight inches in length, and divided into a *prostatic, membranous, and spongy portion*.

The **prostatic portion**, about one and a quarter inches in length, is situated in the prostate gland, about one-third nearer its upper than its lower surface, and extending from its base to its apex. It is the widest part of the urethral canal; and measures about one-third of an inch at the neck of the bladder, and nearly half an inch in the middle of the prostate; it then narrows to about one quarter inch as it passes into the membranous portion. On its floor is a longitudinal ridge, the **veru montanum**, or **caput gallinaginis**; and at

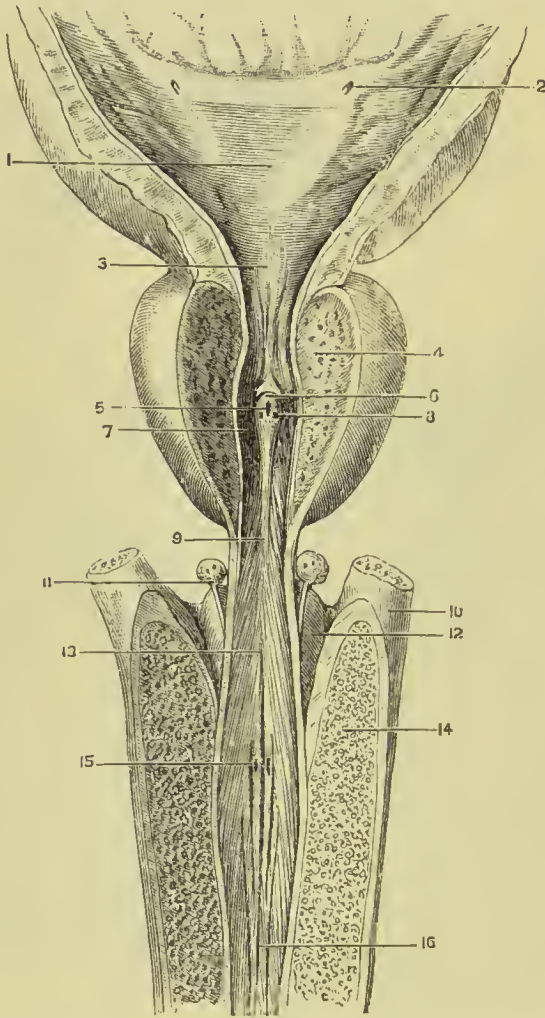


FIG. 478.—The bulbous, membranous, and prostatic urethra, with part of the bladder, laid open from above. 1. Trigone. 2. Opening of ureter. 3. Uvula vesicæ. 4. Lateral lobe of prostate. 5. Opening of sinus pocularis. 6. Veru montanum. 7. Prostatic sinus and opening of prostatic ducts. 8. Aperture of ejaculatory duct. 9. Membranous part of urethra. 10. Crus penis. 11. Cowper's gland, and commencement of its duct. 12. Upper surface of bulb. 13. Commencement of bulbous portion of urethra. 14. Section of crus penis. 15. Entrance of duct of Cowper's gland. 16. Spongy part of urethra.

each side of the veru, a shallow fossa, the **prostatic sinus**, in which are seen the numerous openings (15 to 20) of the prostatic ducts.

The veru montanum is most prominent in the centre; and immediately in front of the prominent part is the opening of a small caecal sac, the **sinus pocularis**, or **vesicula prostatica** (*uterus masculinus*). This sac is the homologue of the uterus; it is nearly half an inch in length, extends back beneath the third lobe of the prostate, and by its approach to the surface contributes to the prominence

of the veru montanum. Its walls, of a yellowish-white colour, are composed of areolar and elastic tissue, mingled towards its fundus with unstriped muscular fibre, and it is lined within by a laminated epithelium, the surface layer being formed of flattened cells. The **ejaculatory ducts** take their course forward in the walls of the sinus pocularis, and terminate close to its aperture by slit-like openings. The veru montanum contains erectile and muscular tissue, and it is believed that its distension may prevent the semen passing back into the bladder during emission.

The **membranous portion** is the narrowest and most fixed part of the canal; it measures about one-fifth of an inch in diameter, and is about three-quarters of an inch in length along its lower wall, and half an inch on its upper. It extends from the apex of the prostate gland to the bulb of the corpus spongiosum, and passes through the triangular ligament. Its coats are—the mucous membrane, circular muscular coat, and compressor urethræ muscle. The submucous tissue is richly supplied with vessels, and much resembles erectile tissue.

The **spongy portion**, about six inches in length, forms the rest of the extent of the canal, and is lodged in the corpus spongiosum from its commencement at the triangular ligament to the meatus urinarius. It is narrowest in the body, and dilated at each extremity, posteriorly in the bulb, where it is named the **bulbous portion**, and anteriorly in the glans penis, where it forms the **fossa navicularis**. The meatus urinarius is the most constricted part of the canal; so that a catheter, which will enter that opening, may be passed freely through the whole extent of a normal urethra. Opening into the bulbous portion are two small excretory ducts about an inch in length, which may be traced backwards, between the coats of the urethra and the bulb, to the under part of the membranous portion behind the triangular ligament, where they originate in two small, lobulated, and somewhat compressed glands, of about the size of peas, **Cowper's glands**. These glands are enclosed in a thin capsule, their glandular structure being held together by areolar tissue and smooth muscular fibre; smooth muscular fibre is also found as a longitudinal layer, around their excretory ducts. They are situated immediately beneath the membranous portion of the urethra, and are enclosed by the lower segment of the compressor urethræ muscle, so as to be subject to muscular compression. On the whole internal surface of the spongy portion of the urethra, and especially along its lower surface, are numerous small openings of lacunæ, and the apertures of mucous glands situated in the submucous areolar tissue (*glands of Littré*). The openings of the lacunæ are directed forwards, and are liable occasionally to intercept the point of a small catheter in its passage to the bladder. At about an inch and a half from the opening of the meatus, in the upper wall of the urethra, one of the lacunæ is generally found much larger than the rest, and is named the **lacuna magna**.

The urethral canal is closed, except during the passage of urine or semen, the closure resulting in the mucous membrane being thrown into longitudinal folds; the lumen in this condition forms a transverse slit, but at the meatus the slit is vertical.

TESTICLES.

The testicles are two small glandular organs suspended from the abdomen by the spermatic cords, and enclosed in an external tegumentary covering, the scrotum.

The **SCROTUM** is distinguished into two lateral halves or hemispheres by a **raphé**, which is continued anteriorly along the under surface of the penis, and posteriorly along the middle line of the perineum to the anus. Of these two lateral portions the left is somewhat longer than the right, and corresponds with the greater length of the spermatic cord on the left side.

The scrotum is composed of two layers, integument, and a proper covering, the dartos: the integument is thin, devoid of fat, semi-transparent, possesses numerous large sebaceous and sudoriparous glands, is beset with hairs which issue obliquely from the skin, and have prominent roots, and has usually a dark colour from the presence of pigment in the epidermis. The **tunica dartos** is a thin reddish layer composed of unstriped muscular tissue; it forms the proper tunic of the scrotum, and sends inwards a septum, *septum scroti*, which divides the cavity into two sacs for the two testicles. The dartos is continuous around the base of the scrotum with the common superficial fascia of the abdomen and perineum, and in an attenuated form is prolonged upon the penis to the prepuce.

The **SPERMATIC CORD** is the medium of communication between the testicle and the interior of the abdomen; and is composed of arteries, veins, lymphatics, nerves, the excretory duct of the testicle, and investing tunics. It commences at the internal abdominal ring, where the vessels of which it is composed converge, and passes obliquely along the spermatic canal; the cord then escapes at the external abdominal ring, and descends through the scrotum to the posterior border of the testicle. The left cord is somewhat longer than the right, and permits the left testicle to reach a lower level than its fellow.

The **arteries** of the spermatic cord are—the spermatic artery from the aorta; the deferential artery, accompanying the vas deferens, from the superior vesical; and the cremasteric, from the epigastric artery. The **spermatic veins** form a plexus which constitutes the chief bulk of the cord; they are provided with valves at short intervals, and the smaller veins have a peculiar tendril-like arrangement, which has obtained for them the name of *pampiniform plexus* (*spermatic plexus*). The **lymphatics** are of large size, and terminate in the lumbar glands. The **nerves** are the spermatic plexus of the sympathetic, which is derived from the aortic and renal plexus, the

genital branch of the genito-crural nerve, and the inguinal branch of the ilio-inguinal.

The **vas deferens**, the excretory duct of the testicle, is situated along the posterior border of the cord, where it may be distinguished by the hard and cordy sensation which it communicates to the fingers. It is about a line or a line and a half in thickness; its parietes are thick and tough, and its canal from one-fourth to one-third the diameter of the entire duct. In **structure** it is composed of three coats—an **external** or **fibrous coat**, which is thin; a **middle** or **muscular coat**, which is remarkable for its thickness, and consists of three layers of smooth muscular fibre, namely, external longitudinal, middle circular, and internal longitudinal; and an **internal** or **mucous coat**, the mucous membrane being pale in colour, disposed in longitudinal pleats, and coated with a columnar epithelium, composed of cells containing yellowish pigment granules. In the dilated portion, near its termination (ampulla), it presents a reticular appearance, like that of the vesiculæ seminales.

The **coverings of the spermatic cord** are—the spermatic fascia, cremaster muscle, and fascia propria. The spermatic fascia is a prolongation of the intercolumnar fascia, derived from the borders of the external abdominal ring during the descent of the testicle in the fœtus. The cremasteric covering, *erythroid*, is the thin muscular expansion formed by the spreading out of the fibres of the cremaster, which is likewise carried down by the testicle during its descent. The fascia propria is a continuation of the infundibuliform process from the transversalis fascia, which immediately invests the vessels of the cord, and is also obtained during the descent of the testicle.

The **TESTICLE** is a small oblong and rounded gland, about an inch and a half in length, somewhat compressed at the sides and behind, and suspended in the cavity of the scrotum by the spermatic cord.

Its position in the scrotum is oblique, so that the upper extremity is directed upwards and forwards, and a little outwards; the lower, downwards and backwards, and a little inwards; the convex border looks forwards and downwards, and the flattened border to which the cord is attached, backwards and upwards. Lying against its outer and posterior border is a flattened body which follows the course of the testicle, and extends from its upper to its lower extremity; this body is named, from its relation to the testis, **epididymis** (ἐπί, upon; δίδυμος, the testicle); it is divided into a central part or **body**, an upper extremity, **head** or **globus major**, and a lower extremity, **tail** or **globus minor**. The globus major is situated against the upper end of the testicle, to which it is closely adherent; the globus minor is placed at its lower end, is attached to the testicle by areolar tissue, and curves upwards, to become continuous with the vas deferens.

The testicle is invested by three tunics—tunica vaginalis, tunica albuginea, and tunica vasculosa, and is connected to the inner surface of the dartos by a large quantity of extremely loose areolar tissue,

in which fat is never deposited, but which is very susceptible of serous infiltration.

The **tunica vaginalis** is a pouch of serous membrane derived from the peritoneum in the descent of the testicle, and afterwards obliterated from the abdomen to within a short distance of the gland. It is a shut sac, investing the organ, *visceral portion*, and then reflected so as to form a bag around its circumference, *parietal portion*. On the outer side it forms a shallow pouch called *digital fossa*, between the testicle and the body of the epididymis. The visceral portion, *tunica vaginalis propria*, covers the surface of the *tunica albuginea*, and surrounds the epididymis, connecting it to the testicle by means of a duplicature. The parietal portion, *tunica vaginalis communis*, is attached by its external surface, through the medium of a quantity of loose areolar tissue, to the inner surface of

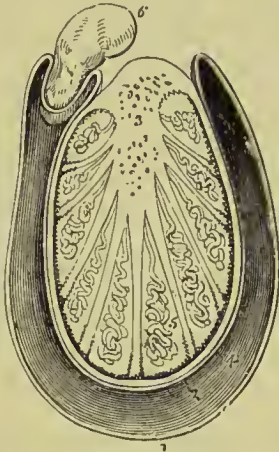


FIG. 479.—Transverse section of the testicle. 1. Cavity of the tunica vaginalis; the most external layer is the parietal layer; and that in contact with the organ, the visceral layer. 2. Tunica albuginea. 3. Mediastinum testis giving off numerous fibrous cords in a radiated direction to the internal surface of the tunica albuginea. The cut extremities of the vessels below the figure belong to the rete testis; and those above to the arteries and veins of the organ. 4. Tunica vasculosa. 5. One of the lobules, consisting of the convolutions of the tubuli seminiferi, and terminating by a single duct, the vas rectum. Corresponding lobules are seen between the other fibrous cords of the mediastinum. 6. Section of the epididymis.

the dartos. Between the two layers is the smooth surface of the shut sac, moistened by its secretion.

At the upper part of the testicle and in front of the globus major of the epididymis one or two small pedunculated bodies are commonly observed; they are described as the **hydatids of Morgagni**, and are composed of connective tissue and blood-vessels with a covering of tunica vaginalis. The largest of these is regarded as the remains of a foetal structure called the duct of Müller.

The **tunica albuginea** is a thick areolo-fibrous membrane, of a bluish-white colour, and the proper tunic of the testicle. It is adherent externally to the tunica vaginalis propria, and, from the union of a serous with a fibrous membrane, is regarded as a fibro-serous membrane, like the dura mater and pericardium. After surrounding the testicle, the tunica albuginea is reflected from its posterior border into the interior of the gland, and forms a projecting longitudinal ridge, the **mediastinum testis** (corpus Highmorianum), from which numerous fibrous cords (trabeculae, septula) are given off, to be inserted into the inner surface of the tunic. The mediastinum contains the blood-vessels and ducts in their passage

into the substance of the organ. If a transverse section of the testicle be made, and the surface of the mediastinum examined, it will be observed that the blood-vessels of the substance of the organ are situated near the posterior border of the mediastinum, while the divided ducts of the rete testis occupy a place nearer the anterior margin. The whole internal surface of the tunica albuginea is covered by a plexus of minute blood-vessels, which also extends on to the septa derived from the mediastinum ; this layer is sometimes described as the **tunica vasculosa**.

The substance of the testicle consists of numerous conical flattened **lobules**, the bases being directed towards the surface of the organ, and the apices towards the mediastinum. Krause found between four and five hundred of these lobules in a single testicle. Each lobule is invested by a distinct sheath formed of two layers, one being derived from the tunica vasculosa, the other from the tunica albuginea. The lobule is

composed of from one to three minute tubuli, **tubuli seminiferi**,* exceedingly convoluted, anastomosing frequently with each other near their extremities, terminating in loops or in free cæcal ends, and of the same diameter, $\frac{1}{170}$ of an inch (Lauth), throughout. The tubuli seminiferi become less convoluted in the apices of the lobules, and terminate by forming between twenty and thirty small straight ducts of about twice the diameter of the tubuli seminiferi, the **vasa recta**. The vasa recta enter the substance of the mediastinum, and terminate in from seven to thirteen ducts,

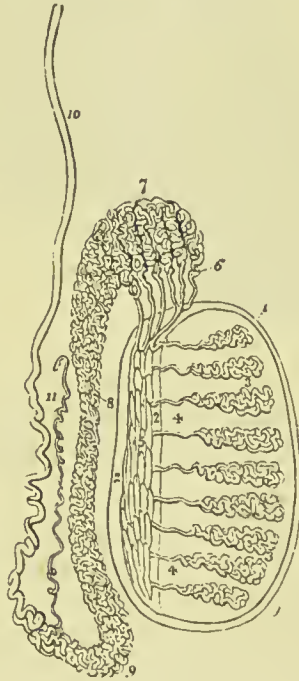


FIG. 480. — Anatomy of the testicle. 1, 1. Tunica albuginea. 2, 2. Mediastinum testis. 3, 3. Lobuli testis. 4, 4. Vasa recta. 5. Rete testis. 6. Vasa efferentia, of which six only are represented in this diagram. 7. Coni vasculosi, constituting the globus major epididymis. 8. Body of the epididymis. 9. Globus minor epididymis. 10. Vas deferens. 11. Vasculum aberrans.

smaller in diameter than the vasa recta. These ducts pursue a waving course from below upwards through the fibrous tissue of the mediastinum ; they communicate freely with each other, and constitute the **rete testis**. At the upper extremity of the mediastinum, the ducts of the rete testis terminate in from nine to thirty small ducts, the **vasa efferentia**,† which form by their convolutions a series of conical masses, the *coni vasculosi* ; from the bases

* Lauth estimates the whole number of tubuli seminiferi in each testicle at 840, and their average length at 2 feet 3 inches. According to this calculation, the entire length of the tubuli seminiferi would be 1890 feet.

† Each vas efferens with its cone measures, according to Lauth, about 8 inches. The entire length of the tubes composing the epididymis, according to the same authority, is about 21 feet.

of these cones tubes of larger size proceed, which constitute, by their complex convolutions, the body of the epididymis. The tubes become gradually larger towards the lower end of the epididymis, and terminate in a single large and convoluted duct, the vas deferens.

The walls of the seminal tubules are formed of a basement membrane, consisting of several layers of flattened epithelial cells. The tubes are occupied by cells, which are in some places situated at the

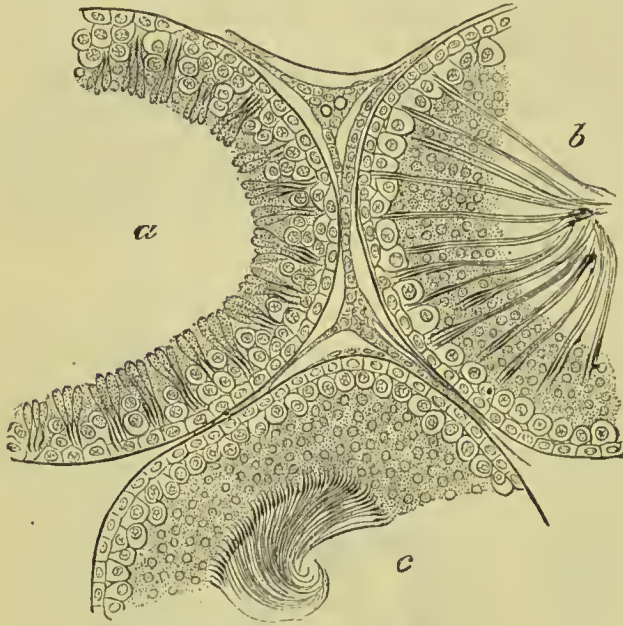


FIG. 481.—Section of the tubuli seminiferi of a rat. *a.* Tubuli in which the spermatozoa are commencing to form. *b.* Spermatozoa more fully developed. *c.* Spermatozoa fully developed. (*E. A. Schäfer.*)

circumference only, a small lumen or cavity being left in the centre; but in the adult testicle they generally form a confused mass filling up the entire tube. In many cases there is a pretty definite layer of cubical or flattened cells next the basement membrane, and these have been named the *outer* or *lining cells*. The cells placed internally to these are large and clear; the appearance of their nuclei indicates that they are proliferating, and they have accordingly been named the *intermediate* or *proliferating cells*. Within these, again, the cells are united to form an almost indistinguishable mass, in which the heads of the spermatazoa are imbedded, the tails being free in the lumen of the tube (*innermost* or *nutritive cells*).

Between the tubes the blood-vessels, lymphatics, and nerves ramify; they are supported by a peculiar tissue containing a large quantity of nuclear and molecular elements, and in which there are lacunar spaces lined by a flattened epithelium, these spaces being the radicles of the lymphatics.

The **epididymis** is formed by the convolutions of the excretory seminal ducts, externally to the testis, and previously to their termination in the vas deferens. The more numerous convolutions and the aggregation of the *coni vasculosi* at the upper end of the organ constitute the **globus major**; the continuation of the convolutions downwards is the **body**; and the smaller number of convolutions of the single tube at the lower extremity, the **globus minor**. The tubuli are connected together by filamentous areolar tissue, and bands of fibrous tissue.

A small convoluted duct, of variable length, is generally connected with the duct of the epididymis, just at the commencement of the vas deferens. This is the **vasculum aberrans** of Haller; it is attached to the epididymis by the areolar tissue in which that body is enveloped. Sometimes it becomes dilated towards its extremity, but more frequently retains the same diameter throughout.

The rete testis is lined by a single layer of squamous cells. The lining cells of the vasa efferentia and upper part of the epididymis are columnar or prismatic in form, and are ciliated; in the lower part of the epididymis the cilia disappear. The walls of these canals are of considerable thickness, and contain unstriped muscular fibre arranged for the most part in a circular manner.

In front of the spermatic cord, and in contact with the globus major of the epididymis, is a minute irregular structure, which, on microscopic examination, is found to be tubular. It is the remains of the Wolffian body, and is called the **parepididymis** or **organ of Giraldès**.

The **vas deferens** may be traced upwards, from the globus minor of the epididymis along the posterior part of the spermatic cord, and along the spermatic canal to the internal abdominal ring. From the ring it is reflected inwards to the side of the fundus of the bladder, and descends along its posterior surface, crossing the ureter, to the inner border of the vesicula seminalis. In the latter situation it becomes somewhat larger in size and sacculated (forming an *ampulla*), and terminates at the base of the prostate gland, by uniting with the duct of the vesicula seminalis, and constituting the ejaculatory duct. The **ejaculatory duct**, which is thus formed by the junction of the duct of the vesicula seminalis with the vas deferens, passes forwards in the outer wall of the sinus pocularis, and terminates by a slit-like opening by the side of the aperture of the sinus.

The **TESTICLES IN THE EMBRYO** are situated in the lumbar regions, immediately in front of and somewhat below the kidneys. They have, connected with them inferiorly, a peculiar structure, which assists in their descent, and is called the gubernaculum testis.

The **gubernaculum** is a soft and conical cord, composed of areolar tissue, containing in its areolæ a gelatiniform fluid. In the abdomen it lies in front of the psoas muscle, and passes along the spermatic canal, which it serves to distend for the passage of the testis. It is attached by its superior and larger extremity to the lower end of the testis and epididymis, and by the inferior extremity to the bottom of the scrotum. The gubernaculum is surrounded by a thin layer of muscular fibres, the **cremaster**, which passes upwards upon this body to be attached to the testis. Inferiorly the muscular fibres divide into three processes, which are thus attached: the external and broadest is connected to Poupart's ligament in the inguinal canal; the middle forms a lengthened band, which escapes at the external abdominal ring, and descends to the bottom of the

scrotum, where it joins the dartos; the internal passes in the direction inwards, and has a firm attachment to the os pubis and sheath of the rectus muscle. Besides these a number of muscular fibres are reflected from the internal oblique on the front of the gubernaculum.

The descent of the testicle is gradual and progressive. Between the fifth and sixth month it has reached the lower part of the psoas muscle, and, during the seventh, makes its way through the spermatic canal, and descends into the scrotum.

While situated in the lumbar region, the testicle and gubernaculum are placed behind the peritoneum by which they are invested upon their anterior surface and sides, forming a *mesorchium*. As they de-

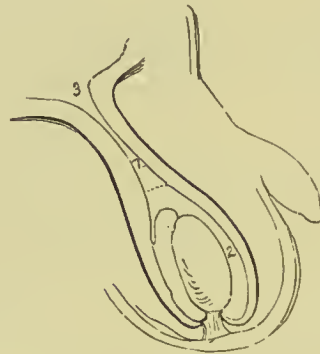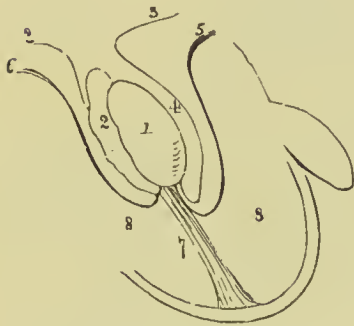


FIG. 482.—Diagram illustrating the descent of the testicle. 1. Testicle. 2. Epididymis. 3. Peritoneum. 4. Pouch formed around the testicle by the peritoneum, the future cavity of the tunica vaginalis. 5. Pubic portion of the cremaster attached to the lower part of the testicle. 6. Portion of the cremaster attached

to Poupart's ligament. The mode of eversion of the cremaster is shown by these lines. 7. Gubernaculum attached to the bottom of the scrotum. 8, 8. Cavity of the scrotum.

FIG. 483.—In this figure the testicle has completed its descent. The gubernaculum is shortened to its utmost, and the cremaster completely everted. The pouch of peritoneum above the testicle is compressed so as to form a tubular canal, z. A dotted line marks the point at which the tunica vaginalis will terminate superiorly; and the figure 2 its cavity. 3. Peritoneal cavity.

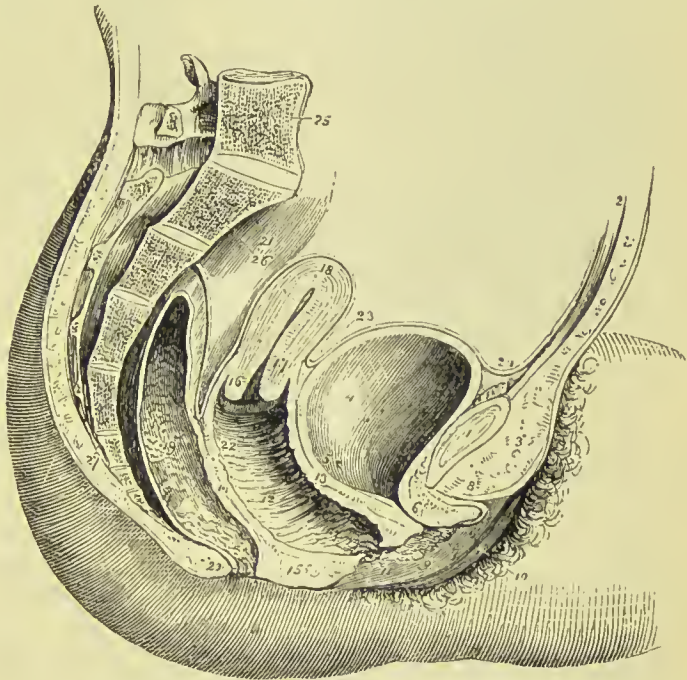
scend, the investing peritoneum is carried downwards with the testicle into the scrotum, forming a lengthened pouch, which by its upper extremity opens into the cavity of the peritoneum. The upper part of this pouch, being compressed by the spermatic canal, is gradually obliterated, the obliteration extending downwards along the spermatic cord nearly to the testicle. That portion of the peritoneum immediately surrounding the testicle is, by the above process, cut off from its continuity with the peritoneum, and is termed the *tunica vaginalis*. In its descent the testicle receives certain structures from the different layers of the abdominal wall; these have been enumerated in connection with the description of inguinal hernia (p. 296), the coverings being exactly the same as those of the oblique form of that affection.

FEMALE PELVIS.

The peculiarities in form of the female pelvis have already been examined with the anatomy of the bones (p. 160). Its lining boundaries are the same as those of the male. The contents are the bladder, vagina, uterus with its appendages, and rectum. Some portion of the small intestine also occupies the upper part of its cavity.

The **bladder** is in relation with the pubes in front, with the

FIG. 484.—Side view of the viscera of the female pelvis. 1. Symphysis pubis. 2. Abdominal parietes. 3. Collection of fat, forming the mons Veneris. 4. Urinary bladder. 5. Entrance of left ureter. 6. Urethra. 7. Meatus urinarius. 8. Clitoris, with its prepuce divided through the middle. 9. Left nymphæ. 10. Left labium majus. 11. Meatus of the vagina, narrowed by the contraction of its sphincter. 12, 22. Canal of the vagina, on which the transverse rugæ are apparent. 13. Vesico-vaginal wall. 14. Recto-vaginal wall. 15. Perineal body.



16. Os uteri. 17. Cervix. 18. Fundus uteri. The cavity of the uterus is seen along the centre of the organ. 19. Rectum, showing the disposition of its mucous membrane. 20. Anus. 21. Upper part of rectum, invested by peritoneum. 23. Utero-vesical fold of peritoneum. The recto-vaginal fold is seen between the rectum and posterior wall of the vagina. 24. Reflection of peritoneum, from the apex of the bladder upon the urachus to the internal surface of the abdominal parietes. 25. Last lumbar vertebra. 26. Sacrum. 27. Coccyx. This view is diagrammatic, the vagina being shown dilated; in the normal state the walls are in loose contact, excepting at the upper part, where the canal has the os uteri projecting into it.

uterus behind, from which it is usually separated by a convolution of small intestine, and with the neck of the uterus and vagina beneath. The form of the female bladder corresponds with that of the pelvis, being broad from side to side, and often bulging more on one side than on the other. This is particularly evident after parturition. The *coats* of the bladder are the same as those of the male.

The **urethra**, about an inch and a half in length, is lodged in the upper and anterior wall of the vagina, in its course downwards and forwards, beneath the arch of the pubes, to the meatus urinarius. Skene has discovered in each lateral urethral wall a minute tubule about $\frac{3}{8}$ to $\frac{1}{4}$ of an inch in length, passing beneath the mucous membrane in the muscular wall of the urethra; these canals have been

named in honour of their discoverer *Skene's tubules*. The urethra is composed of three coats, mucous, submucous, and muscular; the **mucous coat** is vascular, and disposed in longitudinal folds, and is continuous internally with the mucous membrane of the bladder and externally with that of the vulva. It is provided with a squamous epithelium, having a deep stratum of elongated cells, like the mucous membrane of the bladder, and near its extremity has, opening on its surface, the ducts of numerous racemose mucous glands, the glands of Littré. The **submucous coat** is loose, and provided with a considerable plexus of veins, and in its areolar tissue are situated the racemose mucous glands, which open into the urethra near its termination. The **muscular coat** consists of two layers, which are continuous with the muscular structure of the bladder, the internal layer being longitudinal, and mingled with areolar and elastic tissue; the external circular, and continuous with the middle layer of the muscular coat. The female urethra is remarkable for its distensibility, which is only restricted at the meatus by a ring of dense areolar tissue; hence, in distending the urethra for surgical purposes, it is often necessary to divide the margin of the meatus with the knife.

VAGINA.

The vagina is a membranous canal, leading from the vulva to the uterus, and corresponding in direction with the axis of the outlet of the pelvis. It is constricted at its commencement, but near the uterus becomes dilated, and is closed by the contact of the anterior with the posterior wall, so as to appear in sections as a mere longitudinal or transverse slit. Its length is variable; but it is always longer on the posterior than on the anterior wall, the former being usually about five or six inches in length, the latter about four. It is attached to the cervix of the uterus, which latter projects into the upper extremity of the canal. Its upper fourth is covered posteriorly by the peritoneum, while anteriorly the peritoneum is reflected from the cervix uteri without reaching so low as the vagina; it is firmly connected to the bladder in front, and loosely to the rectum behind; at the sides it receives the attachment of the posterior layer of the broad ligaments above, and that of the pelvic fascia and levatores ani below. Its close connection with the bladder occasions the prolapsus of that organ in cases of prolapsus uteri, while its looser connection with the rectum preserves the latter from a similar accident.

Structure.—The vagina, about one line in thickness, is composed of three coats: external, fibrous; middle, muscular; and internal, mucous. The **external** or **fibrous coat** is thin and white, and consists of condensed areolar tissue, with an admixture of elastic fibres. It is firm around the upper part of the tube, and lax inferiorly, and contains in its tissue, especially below, an abundant venous plexus. By its inner surface it is blended with the muscular coat without any distinct separation. The **middle** or **muscular coat** is composed of smooth muscular fibre, arranged in longitudinal and

circular bundles, and intermingled with areolar tissue and a considerable plexus of veins. The **internal** or **mucous coat** is of a pale red colour, and disposed in numerous pleats or folds, **columnæ rugarum**; which diverge transversely from a middle line, or raphé, situated on the anterior and posterior wall of the vagina; the rugæ are most strongly developed on the anterior wall, and near the entrance of the vagina, and are termed **columns of the vagina**. In intimate structure the mucous membrane consists of areolar and elastic tissue, to which its firmness and elasticity are due, and presents numerous conical papillæ embedded in a squamous epithelium. The **epithelium** is thick and laminated, resembling that of the œsophagus, its upper scales measuring about $\frac{1}{1000}$ of an inch in diameter; it is continuous externally with the epithelium of the vulva, and terminates internally at about the middle of the cervix uteri. Opening on to the surface of the mucous membrane are numerous mucous follicles and glands; they are especially plentiful in the upper smooth portion of the vagina and around the cervix uteri.

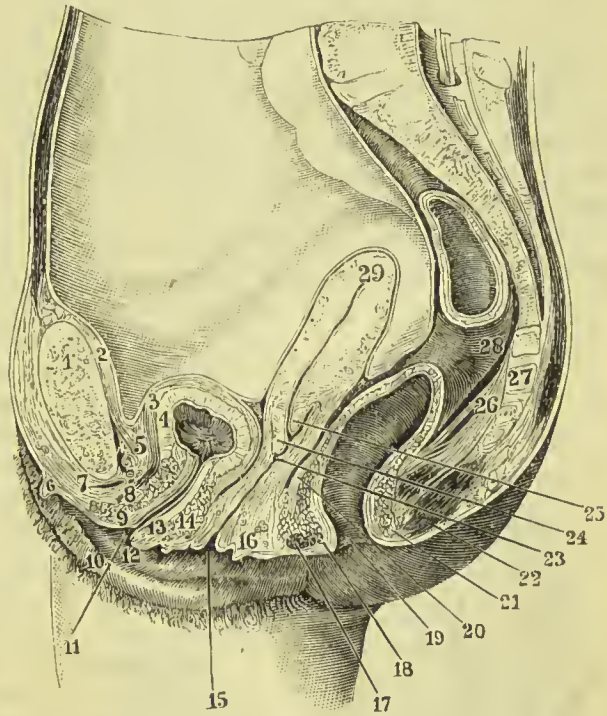


FIG. 485.—Vertical mesial section of a nulliparous female, showing the normal position and relations of the pelvic organs. 1. Pubic symphysis. 2. Peritoneum. 3. Outer layer of bladder wall. 4. Inner layer. 5. Retro-pubic fat. 6. Clitoris. 7. Vena dorsalis clitoridis. 8. Transversus perinei muscle. 9. Circular muscular fibres of urethra. 10. Labium major. 11. Urethral orifice. 12. Nympha. 13. Longitudinal muscular fibres of urethra. 14. Deep circular fibres. 15. Orifice of vagina. 16. Perineal body. 17. External sphincter ani. 18. Internal sphincter. 19. Anus. 20. Recto-vaginal fold of peritoneum. 21. Posterior part of internal sphincter ani. 22. External sphincter. 23. Vagina. 24. Anterior lip of os uteri. 25. Posterior lip of os. 26. Levator ani. 27. Sacrum. 28. Rectum. 29. Uterus.

UTERUS.

The uterus or womb is a flattened organ of a pyriform shape, having the base directed upwards and forwards, and the apex downwards and backwards, in the line of the axis of the inlet of the pelvis, and forming a considerable angle with the course of the

vagina. Its position, however, varies very greatly with the varying conditions of the bladder and rectum; when the bladder is empty the body of the uterus may be horizontal. It is convex on its posterior surface, and somewhat flattened in front; in the unimpregnated state it is about three inches in length, two in breadth across its broadest part, and one in thickness; and is divisible into fundus, body, cervix, and os uteri. At the period of puberty the uterus weighs about one ounce and a half; after parturition from two to three ounces; and at the ninth month of utero-gestation from two to four pounds.

The **fundus** and **body** are enclosed in a duplicature of peritoneum, which is connected with the sides of the pelvis, and forms a transverse septum between the bladder and rectum. The folds formed by this duplicature of peritoneum at each side of the organ are the **broad ligaments**. The **cervix** is the lowest portion of the uterus; it is distinguished from the body by a well-marked constriction; around its circumference is attached the upper end of the vagina, and at its extremity is an opening which is nearly round in the virgin, and transverse after parturition, the **os uteri** (*os tinæ*), bounded before and behind by two labia; the posterior labium being somewhat longer than the anterior, and somewhat less thick. The opening of the os uteri is of considerable size, and is named the **os uteri externum**; the canal then becomes narrowed, and at the upper end of the cervix is constricted into a smaller opening, the **os internum**. Beyond this point the canal of the cervix expands into the shallow triangular cavity of the uterus, the inferior angle corresponding with the os internum, and the two superior angles, which are funnel-shaped and represent the original bicornute condition of the organ, with the commencement of the Fallopian tubes.

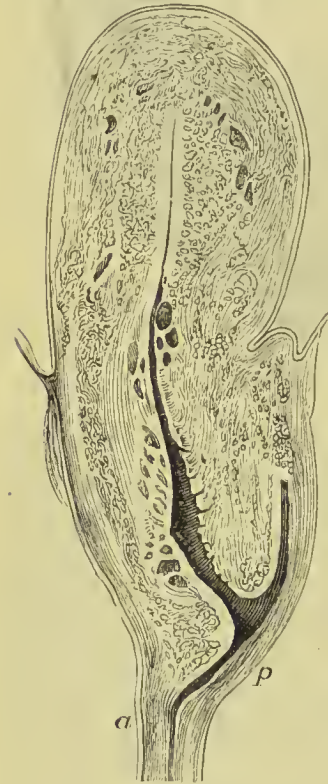

FIG. 486.—Median vertical section through uterus and upper part of vagina. *a.* Anterior wall of vagina. *p.* Posterior wall.

Structure.—The uterus is composed of three tunics: of an *external* or *serous coat*, derived from the peritoneum, which constitutes the duplicatures at each side of the organ called the broad ligaments; of a *middle* or *muscular coat*, and of an *internal*, or *mucous membrane*, which lines its interior, and is continuous on the one hand with the mucous lining of the Fallopian tubes, and on the other with that of the vagina.

The **peritoneum** forms only a partial covering to the front of the

uterus, extending from the fundus to about the lower third, where it is reflected on to the bladder, forming the *recto-vesical fold*. On the posterior aspect it not only covers the whole surface of the uterus, but passes on to the posterior vaginal wall for rather more than an inch, and from thence is continued to the rectum, forming the *recto-vaginal pouch* or *space of Douglas*.

In the unimpregnated state the **muscular coat** is exceedingly dense in texture, offers resistance to section with the scalpel, and appears to be composed of whitish fibres inextricably interlaced and mingled with blood-vessels. In the impregnated uterus the fibres are of large size, distinct, and separable into three layers: *external*, which are longitudinal and transverse, the former constituting a thin plane on the anterior and posterior surface and fundus of the organ, the latter being prolonged outwards on the Fallopian tubes, and into the round and ovarian ligaments; *middle*, a thick layer

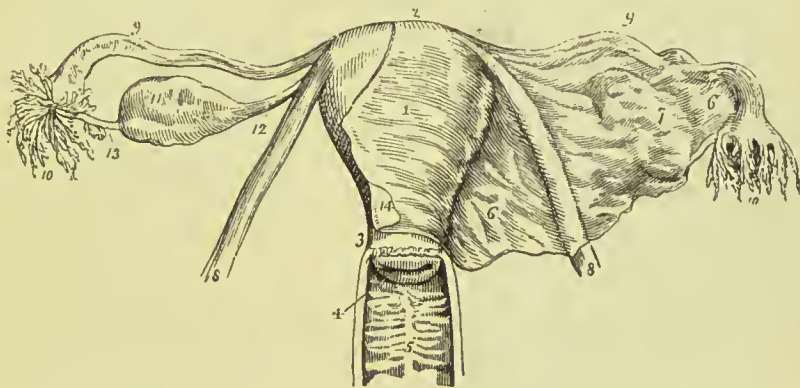


FIG. 487.—Uterus with its appendages viewed from the front. 1. Body of the uterus. 2. Fundus. 3. Cervix. 4. Os uteri. 5. Vagina; the figure is placed on the posterior raphe or column, from which the transverse rugæ are seen passing off at each side. 6, 6. Broad ligament of the uterus. 7. Convexity of the broad ligament formed by the ovary. 8, 8. Round ligaments of the uterus. 9, 9. Fallopian tubes. 10, 10. Fimbriated extremities of the Fallopian tubes; on the left side the mouth of the tube is turned forwards in order to show its ostium abdominale. 11. Ovary. 12. Utero-ovarian ligament. 13. Tubo-ovarian ligament, on which some small fimbriæ are continued for a short distance. 14. Peritoneum of anterior surface of uterus. This membrane is removed at the left side, but on the right is continuous with the anterior layer of the broad ligament.

consisting of flat bundles of transverse, longitudinal, and oblique fibres, complexly interlaced, and traversed by a plexus of large veins, which give this portion of the substance of the uterus a spongy appearance: and an *internal* layer of longitudinal fibres, which is thin and slender, and is disposed chiefly on the back of the fundus. The muscular tissue of the uterus is of the unstriped variety, and consists of long, nucleated, fibre cells, mixed with a considerable quantity of areolar tissue in which are many nucleated cells.

The **mucous membrane**, of a whitish or pale red colour, is closely connected, or more correctly, is blended with the muscular coat; it is characterised by possessing a very thick layer of muscularis mucosæ, a ciliated epithelium, and a number of tubular glands.

The *muscularis mucosæ* forms the greater part of the thickness of the uterine wall; the fibres form concentric rings in the fundus, round the openings of the Fallopian tubes, and in the cervix form the sphincters of the external and internal os uteri. In the cervix uteri the mucous membrane is somewhat thicker than in the fundus, and on the anterior and posterior surface of its canal is disposed in folds, **plicæ palmatæ**, which have received the name of **arbor vitæ uterina**. In the lower part of the cervix, moreover, are found filiform papillæ, invested by a ciliated epithelium.

The **mucous glands** of the uterus, or *uterine glands*, are minute follicles corresponding in length with the thickness of the mucous membrane, very numerous, sometimes simple, sometimes bifid, and sometimes spirally twisted. Their structure resembles other mucous glands, namely, a basement membrane, an epithelium of prismatic cells, with their broad bases and nuclei towards the basement membrane, and their narrow ends towards the lumen of the gland. The cells near the mouth of the follicle are surmounted by cilia, the deeper ones being devoid of them. The glands become much enlarged during pregnancy. In the cervix uteri, between the plicæ palmatæ, are found other *mucous* follicles which secrete the peculiar transparent mucus of that region. It is these follicles in an imperforate state which constitute the small transparent vesicles termed **ovula Nabothi**, seen in the canal of the cervix around the os uteri, and sometimes in its cavity.

Vessels and Nerves.—The *arteries* of the uterus are—the uterine from the internal iliac, and the ovarian from the aorta; they ramify through the muscular and mucous coat, forming a plexus of larger vessels in the deep portion of the latter, and of smaller vessels in its superficial portion; from the smaller vessels are given off the capillaries, which constitute a fine plexus around the glands and a coarse plexus at the surface, the blood from the latter passing into the veins. The *veins* take the course of the arteries, and terminate in the venous plexus situated on each side of the body of the uterus. In the impregnated womb, the veins are so much dilated as to deserve the name of *sinuses*; they are thin in structure, and devoid of valves, and their great number in the muscular coat gives a spongy appearance to the walls of the pregnant uterus. The *lymphatics* are numerous, the deep commencing in the mucous membrane, the superficial taking their course in the subserous tissue; they follow the direction of the blood-vessels, and terminate in the pelvic and lumbar glands.

The **nerves** of the uterus are derived from the hypogastric and spermatic plexuses, and from the sacral plexus. They form a very elaborate plexus, in the midst of which numerous ganglia are found. Of these latter the chief are—one, called the *hypogastric* or *cervical ganglion*, which is situated at the side of the cervix just behind the ureter; another, *spermatic ganglion*, which supplies the fundus uteri; and a number of smaller ones, called posterior and anterior *subperitoneal*, *vesical*, and *vaginal ganglia*.

The nerves of the uterus all increase in size during pregnancy, and again decrease after parturition.

Appendages of the Uterus.

The appendages of the uterus are enclosed by the lateral duplicatures of peritoneum called the broad ligaments. They are the *Fallopian tubes* and *ovaries*.

The **FALLOPIAN TUBES**, or **oviducts**, are situated in the upper border of the broad ligaments, and are connected with the superior angles of the uterus. They are somewhat trumpet-shaped, being smaller at the uterine than at the free extremity. The narrow inner extremity has been named by Henle the *isthmus*, and the wider outer half the *ampulla*. Each tube is about four inches in length, and more or less flexuous in its course. The canal of the Fallopian tube is exceedingly minute; its inner extremity opens by means of the **ostium uterinum** into the upper angle of the cavity of the uterus, and the opposite end into the cavity of the peritoneum. The free or expanded extremity of the Fallopian tube presents a double and sometimes a triple series of small processes or fringes which surround the margin of the trumpet or funnel-shaped opening, the **ostium abdominale**. This fringe-like appendage to the end of the tube has gained for it the appellation of the **fimbriated extremity** (*morsus diaboli*). A short ligamentous cord proceeds from the fimbriated extremity to be attached to the distal end of the ovary.

Structure.—The Fallopian tube is composed of three tunics—an **external** and **serous** investment derived from the peritoneum; a **middle** or **muscular coat**, consisting of circular (internal) and longitudinal (external) fibres, continuous with those of the uterus; and an **internal** or lining **mucous membrane**, which is continuous on the one hand with the mucous membrane of the uterus, and at the opposite extremity with the peritoneum.

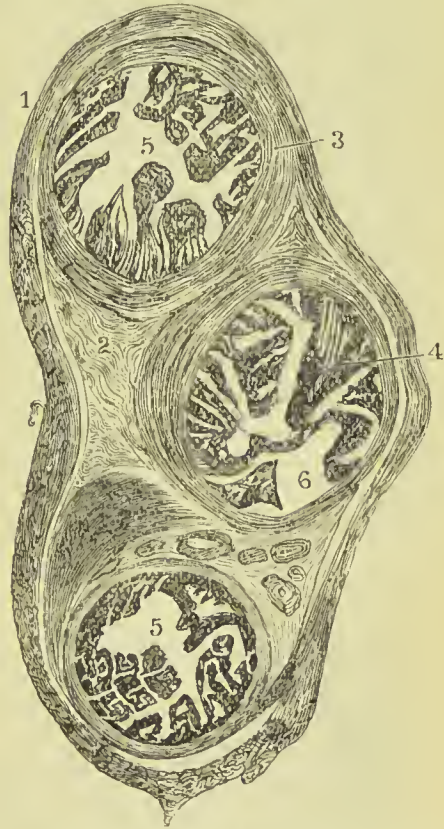


FIG. 488.—Transverse section of Fallopian tube of a nulliparous female, showing three tubes separated by intertubular tissue. 1. Serous outer coat. 2. Interstitial connective tissue. 3. Muscular coat, consisting chiefly of circular fibres. 4. Mucous membrane thrown into irregular folds. 5, 5. Lumen of tubes. At 6 the mucous membrane has been stripped off in making the section.—From a preparation by Dr. Milroy of Kilwinning.

The fibres of smooth muscle are mingled, as in the uterus, with immature nucleated areolar tissue. The mucous membrane is thin, pale, and soft, without villi or glands, and disposed in longitudinal pleats. It is invested by an **epithelium** consisting of a single layer of conical or filiform ciliated cells, the direction of the vibrations of the cilia being towards the cavity of the uterus. The inner surface of the fimbria is covered with ciliated epithelium, and this is continued for a short distance on to the outer surface, but soon passes into the squamous form, similar in character to the cells covering the peritoneum. In some instances there are two or more canals, as shown in Fig. 488; as they are surrounded by a common investment, it is not probable that this appearance is produced by great convolution of the tube, and the consequent appearance of several parts of the tube in the same section.

If the broad ligament of the uterus be held up to the light, a few scattered tubules will be seen between the ovary and Fallopian tube. These constitute the **par ovarium** or **organ of Rosenmüller**. They are lined with epithelium, and are closed at their ovarian extremity, but communicate at the other end with an imperfect duct, which in the sow and some other animals forms the **duct of Gaertner**. The par ovarium is developed along with the Wolffian body, and seems to be the representative in the female of the *coni vasculosi* of the testicle of the male.

The **OVARIES** (*testis muliebres*) are two oblong, flattened, and oval bodies, of a whitish colour and uneven surface, dependent from the posterior layer of peritoneum of the broad ligaments. They are connected to the upper angles of the uterus at each side by means of

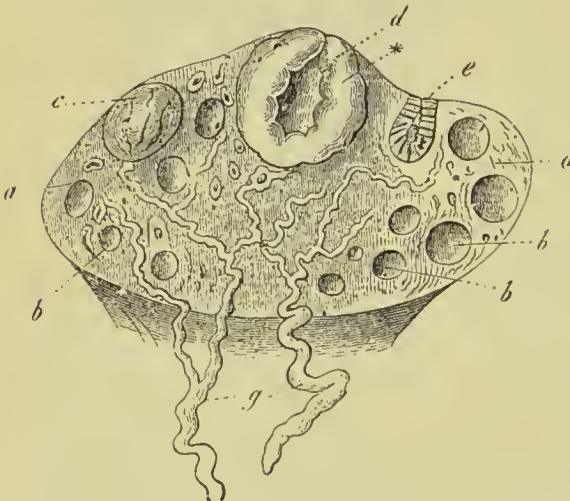


FIG. 489.—The ovary. *a, a*. Stroma. *b, b, b*. Small Graafian vesicles. *c*. A mature vesicle. *d*. A fresh corpus luteum, with thick lining*. *e*. An old corpus luteum. *g*. Veins.

a rounded cord, consisting of fibrous tissue, and a few muscular fibres derived from the uterus, the **ligament of the ovary**. By the opposite extremity they are connected by another and a shorter ligament to the fimbriated aperture of the Fallopian tube, **tubo-ovarian ligament**.

Structure.—The ovary is composed of a spongy fibrous stroma of a greyish-red colour, containing a number of small cells traversed by blood-vessels, and

is covered by a serous membrane which in the early history of the organ was evidently a continuation of the peritoneum. The

cells of this outer membrane differ from those of the peritoneum in being columnar or prismatic, and in their giving to the surface a dull appearance instead of the smooth glistening character usually distinguishing serous membranes; the cells have received the name of **germ epithelium** because they originate the ova. Beneath this membrane is a layer of condensed stroma, having a white appearance, and called from its supposed resemblance to one of the coats of the testicle the *tunica albuginea*. The deep part of the stroma is formed of fibrous tissue containing a large number of nuclei and some elastic tissue; the fibres radiate from the attached border or *hilus* towards the circumference in small bundles. Underneath the capsule, the tissue of the organ is crowded with closely set vesicles, forming an early condition of the characteristic structures of the ovary, the Graafian vesicles; deeper in, the vesicles are less numerous but much larger.

The **ovisac** or **Graafian vesicle** is a vesicle consisting of an external membrane and fluid contents. The membrane is composed of an outer coat formed by the condensation of the stroma, and sometimes named the **tunica fibrosa**, a basement membrane and an internal lining or **epithelium**. The epithelium consists of round or polygonal cells with large nuclei, and a greater or less number

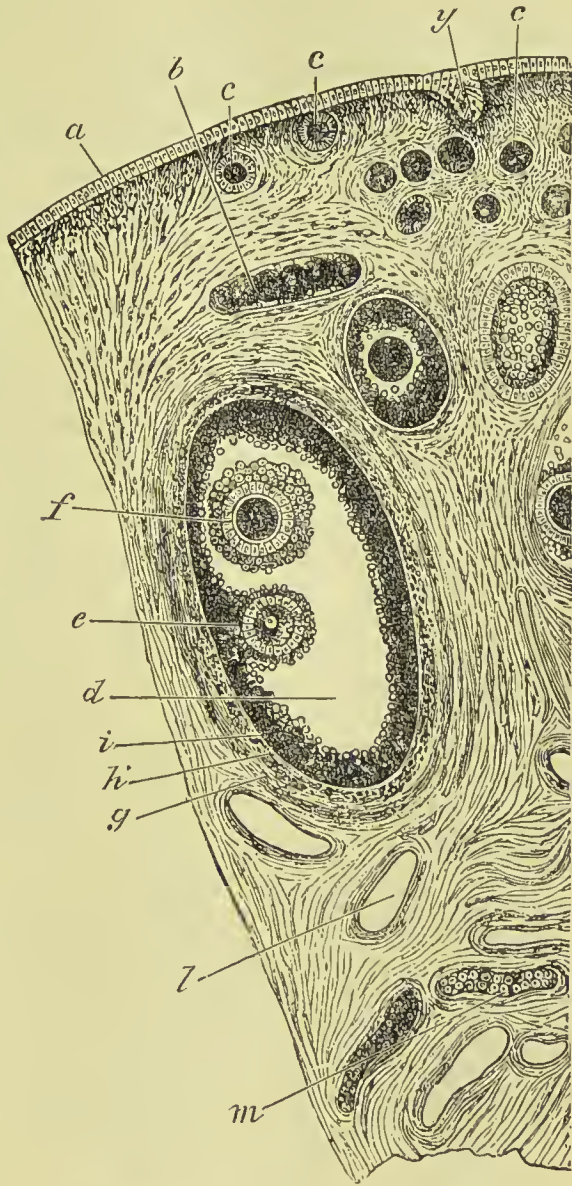


FIG. 490.—Section of ovary. *a*. Germ epithelium. *b*. Ovarian tube, or string of ovigerms. *c, c, c*. Early vesicles. *d*. A more mature vesicle. *e*. Ovum and discus proligerus. *f*. A second ovum in the same vesicle. *g*. Tunica fibrosa of vesicle. *h*. Inner coat of the vesicle. *i*. Epithelial lining (tunica granulosa). *l*. Blood-vessel, cut across. *m*. Section of tubes of par ovarium. *y*. Involved portion of germ epithelium of surface.

of fatty granules; the cells quickly lose their definition after death, and then the epithelium assumes the appearance which has gained for it the name of **membrana granulosa**, namely, a granular layer with numerous nuclei. The *membrana granulosa* forms a uniform lining to the ovisac, excepting on the side nearest the surface of the ovary, where the cells are accumulated into a small eminence, termed **discus proligerus** or **germinal eminence**. This germinal eminence contains a minute globular nucleated vesicle, the **ovum**. The fluid contents of the ovisac, *liquor folliculi*, are a clear yellowish fluid, and a few free albuminous cells detached from the *membrana granulosa*. The Graafian vesicles are very small in the outer part of the ovary, but are there so numerous as to give a granular character distinct from that of the rest of the organ; hence it is defined as the *cortical portion*. In the deeper portions they are less numerous but larger and more mature, and as they increase in size they displace the cells of the cortical portion in order to reach the surface of the organ.

Ovum.—The ovum, measuring in its mature state about $\frac{1}{125}$ of an inch in diameter, is a globular vesicle consisting of a cell membrane, the **vitelline membrane**, a **yelk** or **vitellus**, and a vesicular nucleated nucleus, the vesicular nucleus being the **germinal vesicle**, and the nucleolus the **germinal spot**. The cell membrane is clear and transparent, and has received the name of **zona pellucida**; with high magnifying powers, it is, however, possible to make out fine striæ passing radially through the membrane, and it is for this reason named the **zona striata** or **striate membrane**. The **yelk**, yellowish and viscid, consists of protoplasm filled with granules and nuclei, and traversed by an extremely fine reticulum. The **germinal vesicle** measures about $\frac{1}{500}$ inch, and consists of a nuclear network supporting nucleoplasm.

As the ovisac attains maturity, it approaches nearer and nearer the capsule of the ovary, and pressing against the capsule renders it so thin that moderate pressure, such as that made by the fibriated extremity of the Fallopian tube, causes the protrusion and rupture both of the ovisac and the capsule of the ovary. By this rupture the ovum is expelled, carrying with it the germinal eminence and part of the *membrana granulosa*, which in its new relation is termed the *germinal disc*, **discus proligerus**. The ovisac, now emptied of its contents, is quickly filled with a sanguineous fluid, resulting from the tearing of its vessels, the internal portion of the tunica fibrosa becomes thickened and plicated, and converted into a yellow vascular tissue, while the external layer of the tunic retains its character of a white fibrous membrane. This is the **corpus luteum**, a yellowish mass with fast-diminishing cavity, plicated structure, vascular, and enclosed in a thin fibrous layer. It retains these characters up to the second or third month of pregnancy, and then slowly diminishes in size, being gradually lost some months after parturition is complete, or reduced to a small whitish or dark coloured mass. The corpora lutea, which are independent of preg-

nancy, **false corpora lutea**, disappear in the course of one or two months, and leave behind them a scarcely perceptible trace of their existence.

Formation of Ova.—The ova are formed from the germ epithelium on the surface of the ovary, the cells becoming enlarged and penetrating into the substance of the ovum as shown at *y*, Fig. 490. After passing downwards for a short distance they lose their surface connection, and become enveloped by layers of condensed stroma constituting the walls of the Graafian vesicles; the germ cell thus comes to form the ovum, its nucleus the germinal vesicle, and a nucleolus which soon appears in the centre of the nucleus the germinal spot. The cells of the membrana granulosa are the product of the nuclei of the fibro-nuclear tissue forming the stroma.

Vessels and Nerves.—The *arteries* of the ovaries are branches of the uterine and ovarian. The arteries enter the ovary along its inferior border by numerous minute trunks, which pass in a serpentine course through its stroma, to be distributed chiefly to the walls of the ovisacs, forming an exterior coarse and interior fine capillary plexus. The *veins* constitute an ovarian plexus, which terminates in the uterine plexus. The *lymphatics*, few in number, terminate in the pelvic and lumbar glands. The *nerves* are derived from the spermatic plexus, and take the course of the arteries.

The **ROUND LIGAMENTS** are two musculo-fibrous cords between four and five inches long, situated within the layers of the broad ligaments, and extending from the upper angles of the uterus and along the inguinal canals to the mons Veneris, in which they are lost. They are composed of smooth muscular fibre and areolar tissue, but towards the internal abdominal rings, have also numerous fasciculi of striated muscular fibres. The round ligaments are accompanied by a small artery, by several filaments of the spermatic plexus of nerves, by a plexus of veins, and by a process of the peritoneum which represents the serous membrane investing the spermatic cord in the male. In the young subject, this process extends for a short distance along the spermatic canal, and is denominated the **canal of Nuck**: it is sometimes pervious in the adult. The round ligaments serve to retain the uterus in position in the pelvis, and, during utero-gestation, to draw the anterior surface of the organ against the abdominal parietes.

EXTERNAL ORGANS OF GENERATION.

The female organs of generation are divisible into internal and external; the internal are contained within the pelvis, and have been already described; they are—the vagina, uterus, ovaries, and Fallopian tubes. The external organs are the mons Veneris, labia majora, labia minora, clitoris, meatus urinarius, and opening of the vagina.

The **mons Veneris** is the eminence of integument, situated on

the front of the pubes. Its areolar tissue is loaded with adipose substance, and the surface covered with hairs.

The **labia majora** are two large longitudinal folds of integument containing areolar tissue, fat, and a tissue resembling the dartos. They enclose an elliptical fissure, the common urino-sexual opening or **vulva**. The vulva receives the inferior opening of the urethra and vagina, and is bounded anteriorly by the *anterior commissure*, and posteriorly by the *posterior commissure*. Stretching across the posterior commissure is a small transverse fold, the *frænulum labiorum* or **fourchette**, which is ruptured during parturition; and immediately within this fold a small cavity, the **fossa navicularis**. The external surface of the labia is covered with hairs; the inner surface is smooth, and lined by mucous membrane, which contains a number of large sebaceous glands, and is covered by a thin cuticular epithelium. The mass of tissue intervening between the posterior commissure and anus is known as the **perineal body**; superficially it is covered by skin, and is generally spoken of by the accoucheur as "*the perineum*." In median sections of the pelvic viscera it is seen to be of triangular form (Fig. 485) with its base directed outwards and its apex inwards and backwards; it is formed of the interwoven fibres of the sphincter ani and sphincter vaginae, with a large quantity of fat, and fibrous tissue and elastic tissue.

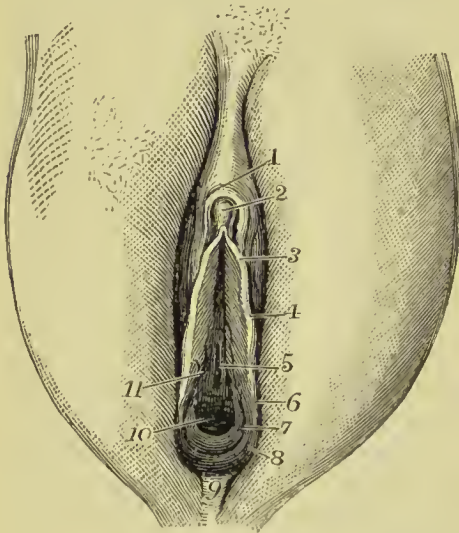


FIG. 491.—External organs of generation of the female. 1. Præputium clitoridis. 2. Clitoris. 3. Frenulum clitoridis. 4. Labium minor (Nympha). 5. Meatus urinarius. 6. Opening of Duvernay's gland. 7. Hymen. 8. Fourchette. 9. Posterior commissure. 10. Orifice of vagina. 11. Skene's tubule opening into meatus.

The **labia minora**, or **nymphæ**, are two smaller folds, situated within the labia majora. Superiorly they are divided into two processes, which surround the glans clitoridis, the superior fold forming the **præputium clitoridis**, the inferior its **frænulum**. Inferiorly, they diminish gradually in size, and are lost on the sides of the opening of the vagina. The nymphæ consist of mucous membrane, covered by a thin cuticular epithelium. They are provided with a number of sebaceous glands, and contain, in their interior, a plexus of blood-vessels.

The **clitoris** is a small elongated organ situated in front of the pubes, and supported by a suspensory ligament. It is formed by a small body, analogous to the corpus cavernosum penis, and, like it, arises from the ramus of the os pubis and ischium at each side by two **crura**. At the extremity of the clitoris is a small accumulation of erectile tissue which is highly sensitive, and is termed the **glans**.

The corpus cavernosum clitoridis, like that of the penis, is composed of erectile tissue enclosed in a dense layer of fibrous membrane, and is susceptible of erection. Like the penis, also, it is provided with two small muscles, the **erectores clitoridis**.

At about an inch behind the clitoris, is the **entrance of the vagina**, an elliptical opening, marked by a prominent margin. The entrance to the vagina is closed in the virgin by a duplicature of mucous membrane of a semilunar form, which is stretched across the opening; this is the **hymen**. Sometimes the membrane forms a complete septum, and gives rise to inconvenience by preventing the escape of the menstrual effusion. It is then called an *imperforate hymen*. The *hymen* must not be considered a necessary accompaniment of virginity, for its existence is uncertain. When present, it assumes a variety of appearances; it may be a membranous fringe, with round opening in the centre; or a semilunar fold, leaving an opening in front; or a transverse septum, having an opening both in front and behind; or a vertical band with an opening at each side.

The rupture of the hymen, or its rudimentary existence, gives rise to the appearance of a fringe of papillæ around the opening of the vagina; these are called **carunculæ myrtiformes**.

The triangular smooth surface between the clitoris and the entrance of the vagina, which is bounded at each side by the upper portions of the nymphæ, is the **vestibule**.

At the posterior part of the vestibule and near the margin of the vagina is the opening of the urethra, the **meatus urinarius**; and around the meatus an elevation of the mucous membrane formed by the aggregation of numerous mucous glands. This prominence serves as a guide to finding the meatus in the operation of introducing the female catheter. Beneath the vestibule at each side, and extending from the clitoris to the side of the vagina, are two oblong or pyriform bodies, consisting of erectile tissue enclosed in a thin layer of fibrous membrane. These bodies are narrow above, broad and rounded below, and are termed by Kobelt, who considers them analogous to the bulb of the male urethra, the **bulbi vestibuli**. Behind these bodies and lying against the outer wall of the vagina are two small glands, analogous to Cowper's glands in the male subject; they are the **glands of Bartholin** or **Duvernay**. Each gland opens by means of a long excretory duct on the inner side of the corresponding nympha. In front of the masses of erectile tissue forming the bulb of the vestibule is a smaller plexus of vessels continuous with those of that body behind and with the erectile tissue of the glans clitoridis in front; it has been named by Kobelt the *pars intermedia*, and is supposed to correspond with that part of the corpus spongiosum penis lying in front of the bulb of the urethra in the male.

The **mucous membrane** of the external organs, about a quarter of a line in thickness, is composed of areolar and elastic tissue, without fat, and rich in capillary vessels. It is furnished with

numerous papillæ, which are large on the labia minora, smaller on the clitoris, and is invested by a squamous epithelium. On the internal surface of the labia majora, on the labia minora, and occasionally around the meatus urinarius and entrance of the vagina, there exist **sebaceous glands**; while on the vestibule, around the meatus urinarius and around the entrance of the vagina, there is an abundance of **racemose mucous glands**, opening on the surface of the membrane by shorter and longer ducts.

Vessels and Nerves.—The external organs of generation are abundantly supplied with *arteries*, chiefly by the internal pudic; they terminate in a deep and superficial capillary plexus, as in other mucous membranes. Valentin has described helicine arteries in the clitoris. The *veins* returning the blood from the capillaries form a rich plexus, which is especially abundant in the bulbi vestibuli of Kobelt. The *lymphatics* are numerous, and communicate partly with the inguinal and partly with the pelvic glands. The *nerves* are derived partly from the hypogastric plexus and partly from the sacral plexus.

MAMMARY GLANDS.

The **mammæ** are situated in the pectoral region, and are separated from the pectoralis major muscle by a thin layer of superficial fascia. Their base is somewhat elliptical, the long diameter corresponding with the direction of the fibres of the pectoralis major muscle; and the left mamma is generally a little larger than the right.

Near the centre of the convexity of each mamma is a small prominence of the integument, called the **nipple** (mammilla), which is surrounded by an **areola** having a coloured tint. In females of fair complexion before impregnation, the colour of the areola is a delicate pink; after impregnation, it enlarges and assumes a brownish hue, which deepens in colour as pregnancy advances; and after the birth of a child, the brownish tint continues through life.

The areola is furnished with a number of **sebaceous glands**, which secrete a peculiar fatty substance for the protection of the delicate integument around the nipple. During suckling these glands increase in size, and have the appearance of small pimples, projecting from the skin. At this period they serve by their secretion to defend the nipple and areola from the excoriating action of the mouth of the infant.

In *structure*, the mamma is a compound racemose or conglomerate gland, consisting of **lobes**, **lobules**, and **gland-vesicles**. The lobes, from 15 to 25 in number, have each a separate system of lobules and gland-vesicles, and a distinct excretory duct; hence, the mamma may be regarded as being composed of a number of separate glands, their excretory ducts converging to the nipple, and terminating at its extremity by distinct apertures. The lobes are irregular in size and form, flattened, and bounded by rounded angles; they are made

up of smaller lobes or lobules, and the lobules of other lobules still more diminutive, the smallest lobules consisting of round or pyriform *gland-vesicles* or *alveoli*.

The **gland-vesicles** or **alveoli**, about $\frac{1}{200}$ of an inch in diameter, are composed of a basement membrane, lined with an *epithelium*, which changes in character with the varying conditions of the organ. When the gland is inactive, the alveoli are very small, and the lining cells are small and granular. When active secretion is going on, the alveoli are large and distended with fluid, the epithelial cells are flattened out against the mucous membrane and contain fat globules. The alveoli communicate with an excretory duct, and the excretory ducts of all the lobules unite to form a common excretory duct or canal for each lobe, **galactophorus duct**. The duct, taking its course beneath the areola, dilates into an elongated sac or **ampulla**, and reaching the base of the mammilla, contracts in size and bends outwards into that process to terminate at its extremity by a small aperture. There are from 15 to 25 ducts in the nipple, a number corresponding with the number of lobes composing the gland.

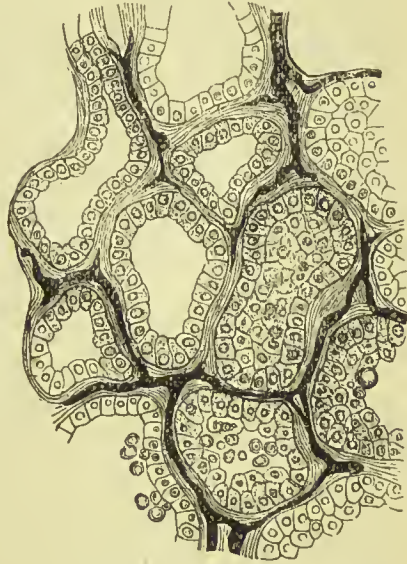


FIG. 492.—Gland-vesicles of the mammary gland during lactation, showing the lining cells and capillary vessels.

The gland-vesicles are held together by a dense white areolar tissue, which unites the lobules into lobes, and connects the different lobes with each other, forming a covering for the whole, and being itself surrounded with adipose tissue. The galactophorus ducts are composed of areolar tissue, with longitudinal and circular elastic fibres, and, according to Henle, there is an indication of longitudinal smooth muscular fibre; they are lined by columnar epithelium, passing into the squamous form near the openings on the nipple.

The **mammilla** or **nipple** is covered by a thin epidermis, presenting more or less pigment in its rete mucosum; it possesses at the extremity a number of papillæ, between which are the lactiferous openings, and it is composed internally of the ducts, united together and surrounded by areolar and smooth muscular tissue, the latter giving the nipple the faculty of erection and retraction. The integument of the **areola**, besides possessing a coloured epidermis with numerous large sudoriparous and sebaceous glands, the latter associated with fine hairs, is also provided with a layer of smooth muscular fibre, which gives it a power of contraction.

The **secretion of milk** is effected by the formation of oil-globules in the epithelial cells of the gland-vesicles; the epithelial cells being perfected, are pushed outwards and displaced by a new layer of similar cells which form beneath them; they are thus carried forward into the lacteal ducts, where the cell bursts and gives exit to its oil-globules, now become *milk-globules*; and the cell-membrane and nucleus are lost. These milk-globules suspended in a fluid, the *milk-plasma*, constitute the *milk*. Previously to conception, the mammæ only secrete a yellowish viscid mucus, and at the commencement of lactation the milk is imperfect and termed *colostrum*, having entering into its composition a number of cells filled with yellow fat globules, named *colostrum corpuscles*.

The **mammary gland of the male** is rudimentary; it varies in size from a quarter of an inch to two inches in breadth, by one to three lines in thickness. It is firm in texture, presents no division into lobes, and its ducts are small without dilatations, and terminate in gland-vesicles larger than those of the female.

At birth the mammary gland measures between two and four lines in breadth, and presents from twelve to fifteen lobular divisions, and then goes on gradually, but very slowly, increasing in bulk. True gland-vesicles do not make their appearance until the period of menstruation, and are not fully developed throughout the entire gland until the first pregnancy. After the period of child-bearing, the gland generally degenerates, the gland-vesicles disappear, and in old age the organ passes into a state of atrophy, the ducts, with their epithelium in a state of fatty degeneration, alone remaining, surrounded by a cushion of fat which takes the place of the glandular tissue.

Vessels and Nerves.—The mammæ are supplied with *arteries* from the thoracic branches of the axillary, the intercostals, and internal mammary; having entered the substance of the gland they divide into capillaries, which constitute a close network around the gland-vesicles. The *veins* form an incomplete circle around the base of the nipple, *circulus venosus Halleri*, from which larger veins conduct the blood to the circumference of the gland, and by these communications form a plexus on its surface. They terminate in the axillary vein, internal mammary, intercostals, and jugular veins.

The *lymphatics* are abundant in the integument covering the mammæ. In the gland itself the lymphatic capillaries commence in the fibrous connective tissue between the gland vesicles, and the vessels formed therefrom accompany the veins and milk-ducts. The main lymphatic trunks run for the most part along the edge of the pectoralis major muscle to end in the axillary glands, but others pass through the intercostal spaces to reach the anterior mediastinal glands.

The *nerves* of the mammary gland are derived from the anterior cutaneous branches of the second, third, and fourth intercostal nerves, and from the lateral cutaneous branches of the same nerves.

GLOSSARY OF ANATOMICAL TERMS.

- ABDOMEN** (Lat. *abdo*, I conceal). The inferior cavity of the trunk, containing the stomach, intestines, liver, &c.
- ABDUCTOR** (Lat. *abduco*, I draw from). A muscle which carries the limb *away from* the middle line of the body, or the digits from the middle line of the hand or foot.
- ACCESSORIUS** (Lat. *accedere*, to be added to). Muscles or nerves which assist others in their action are thus named.
- ACERVULUS** (dim. of Lat. *acervus*, a heap). Applied to the mass of gritty particles contained in the pineal body.
- ACETABULUM** (Lat. *acetabulum*, a vessel for holding vinegar). The cup-shaped cavity of the innominate bone which receives the head of the femur.
- ACHROMATIN** (Gk. *a*, not, and *χρῶμα*, colour). The part of a nucleus which does not readily absorb staining fluids.
- ACINI** (Lat. *acinus*, a berry). The small vesicles which form conglomerate glands.
- ACROMION** (Gk. *ἄκρον*, the extremity, and *ῶμος*, the shoulder). The part of the scapula forming the tip of the shoulder.
- ADENOID** (*αδην*, a gland, and *εἶδος*, like). Tissue like that of the lymphatic glands.
- ADIPOSE** (Lat. *adeps*, fat). Fatty.
- ADDUCTOR** (Lat. *adduco*, I draw to). A muscle which carries the limb *towards* the middle line of the body, or the digits towards the middle line of the hand or foot.
- ADVENTITIA** (Lat. *adventitus*, foreign). The outer coat of arteries and veins.
- AFFERENT** (Lat. *ad*, to, and *fero*, I convey). Vessels or nerves which convey the contents or impulses from the periphery to the centre.
- ALA** (Lat. *ala*, a wing). Term applied to the lateral lobe of the nose, the expanded part of the external ear, and to certain processes of the sphenoid bone.
- ALVEOLI** (Lat. *alveus*, a cavity). The name given to the sockets of the teeth and the air-cells of the lung.
- AMEBOID** (Gk. *αμειβω*, I change, and *εἶδος*, like). Movement like that of the *Amœba*, a single-celled organism living in the sea and fresh waters.
- AMPHIARTHROSIS** (Gk. *ἀμφί*, both, and *ἄρθρον*, a joint). An articulation by means of some intervening substance, as that between the bodies of the vertebræ.
- AMPULLA** (Lat. *ampulla*, a wine-jug). The dilated end of a canal; chiefly used for the semicircular canals of the ear.

- AMYGDALÆ (Gk. ἀμυγδάλη, an almond). The tonsils are so called from their resemblance to almonds.
- ANASTOMOSIS (Gk. ἀνα, by, and στομά, a mouth). The intercommunication of vessels.
- ANATOMY (Gk. ἀνα, through, and τέμνω, I cut). The Greek equivalent of "Dissection."
- ANCHYLOSIS (Gk. ἀγκυλος, crooked). An unnatural union between bones.
- ANCONÆUS (Gk. ἀγκων, the elbow). A muscle situated near the elbow.
- ANNULUS (Lat. *annulus*, a ring). A circle or ring.
- ANTI—as in *anti-tragus*, *anti-helix*, &c. (Gk. ἀντί, against). Opposite, or opposed to.
- ANTRUM (Lat. *antrum*, a cave). The name given to a cavity in the superior maxillary bone, and a much smaller one in the mastoid.
- ANUS (Lat. *anus*, an opening). The termination of the rectum which serves as an outlet for the fæces.
- AORTA (Gk. ἀορτήρ, a belt or strap to hang anything to). The main artery of the body is probably so called because it apparently suspends the heart.
- APONEUROSIS (Gk. ἀπό, from, and νεῦρον, a nerve). A tendinous expansion, so called because the early anatomists did not distinguish between tendons and nerves.
- APOPHYSIS (Gk. ἀπό, from, and φύω, I grow). A projection from the surface of a bone.
- APPENDICES EPIPLOICÆ (Lat.). Small fringes of fat attached to the large intestine.
- ARACHNOID (Gk. ἀράχνη, a spider's web, and εἶδος, like). The middle membrane of the brain.
- ARCUATUM (Lat. *arcuatus*, bow-shaped). Name given, from their shape, to tendinous bands connecting the diaphragm with the last rib and first lumbar vertebra.
- AREOLA (Lat. diminutive of *area*, a void space). Term applied to interspaces in fibrous tissue.
- ARTERY (Gk. ἀήρ, air or spirit, and τηρέω, I keep). A vessel carrying blood from the heart. The ancients supposed the arteries contained the vital spirit or soul, and hence the name.
- ARTHRODIA (Gk. ἄρθρον, a joint). An articulation admitting of a gliding movement.
- ARTHOLOGY (Gk. ἄρθρον, a joint, and λόγος, a discourse). A treatise on joints.
- ARTICULATION (Lat. *articulus*, a joint). The means by which the bones of the skeleton are connected.
- ARYTENOID (Gk. ἀρύταινα, a pitcher, and εἶδος, like). The two pyramidal cartilages of the larynx, so called from the supposed resemblance of the two together to the mouth of a pitcher.
- ASTERION (Gk. ἀστήρ, a star). The point of junction of the occipital, parietal, and temporal bones.
- ASTRAGALUS (Gk. ἀστράγαλος, a die). One of the bones of the tarsus.
- ATLAS (Gk. τλάω, I sustain). The vertebra which supports the head.
- ATTOLLENS (Lat. *attollo*, I raise up). Raising. The attollens auricular muscle raises the pinna.
- ATTRAHENS (Lat. *ad*, to, and *trahō*, I draw). Drawing towards. The anterior extrinsic muscle of the ear is so called because it draws the ear forwards.

- AUDITORY** (Lat. *audio*, I hear). Belonging to the ear.
- AURICLE** (Lat. *auricula*, diminutive of *auris*, a little ear). The two superior cavities of the heart are so called because of their appendices which look like ears.
- AZYGOS** (Gk. *α*, without, and *ζυγός*, a yoke). Without fellow. The term is applied to parts which are not in pairs.
- BACILLARY** (Lat. *bacillum*, a little rod). The layer of rods and cones of the retina is sometimes called the bacillary layer.
- BASILAR** (Lat. *basis*, a base). Belonging to the base of the brain or skull.
- BASILIC** (Gk. *βασιλικός*, royal). A term generally of eminence, and hence applied to a large vein of the arm.
- BICEPS** (Lat. *bis*, twice, and *caput*, a head). Muscles having two heads receive this name.
- BICIPITAL**. Adjective from the preceding.
- BICUSPID** (Lat. *bis*, twice, and *cuspis*, a spear). Having two tubercles or points.
- BIPENNIFORM** (Lat. *bis*, twice, and *penna*, a feather). Applied to muscles having their fibres arranged on each side of a central tendon, like the barbs of a feather.
- BRACHIA** (Lat. *brachium*, an arm). Two arms of nerve matter in the interior of the brain.
- BRACHIAL** (Lat. *brachium*, an arm). Belonging to the arm.
- BREGMA** (Gk. *βρέχω*, I moisten). The anterior fontanelle.
- BRONCHI** (Gk. *βρόγχος*, the windpipe). The tubes which convey the air from the trachea to the lungs.
- BRONCHOCELE** (Gk. *βρόγχος*, the windpipe, and *κήλη*, a tumour). A permanent enlargement of the thyroid gland.
- BUCCINATOR** (Lat. *buccina*, a trumpet). A muscle of the cheek, so called from its use in blowing.
- BULBUS** (Lat. *bulbus*, an expanded underground stem). Applied to several rounded structures in the body, as the *bulbus olfactorius* and *bulbus urethrae*.
- BURSA** (Lat. *bursa*, a sac). A closed sac containing fluid, and intended to modify pressure.
- CÆCUM** (Lat. *cæcus*, blind). Any *cul-de-sac* is called cæcum, but the term is especially applied to the expanded commencement of the large intestine.
- CALAMUS SCRIPTORIUS** (Lat. a writing pen). A groove upon the floor of the fourth ventricle.
- CALCANEUM** (Lat. *calx*, the heel). The heel bone.
- CALICES** (Gk. *καλύξ*, a cup). The cup-like commencement of the ureters, which receive the apices of the pyramids of the kidney.
- CALX** (Lat. *calx*, *calcis*, the heel). *Os calcis*, the bone of the heel.
- CANALICULUS** (Lat. diminutive of *canalis*, a canal). A small canal. The term is applied to the minute canals of bone, and to the passages which carry away the tears.
- CANCELLI** (Lat. *cancelli*, lattices). Term used to denote the spongy structure of bone.
- CANINE** (Lat. *canis*, a dog). The so-called canine teeth are largely developed in the dog.

- CANTHI (Gk. *κανθός*, the angle of the eye). The angles formed by the junction of the eyelids.
- CAPILLARIES (Lat. *capillus*, a hair). The minute vascular tubes in the tissues.
- CAPITULUM (Lat. *capitulum*, a little head). Certain small rounded prominences receive this title, as the projection on the lower end of the humerus which articulates with the radius, and the lower extremity of the ulna (*capitulum ulnæ*).
- CAPSULE (Lat. *capsula*, diminutive of *capsa*, a box). A bag enclosing any part or organ, as the capsule of the kidney.
- CARDIAC (Gk. *καρδία*, the heart). Belonging to the heart.
- CAROTID (Gk. *καρόω*, I induce sleep). The carotid arteries are so named because pressure on them is supposed to induce sleep.
- CARPUS (Gk. *καρπός*, the wrist). The bones of the wrist.
- CARUNCULA (Lat. diminutive of *caro*, flesh). A small flesh-like body.
- CAUDA EQUINA (Lat. a horse's tail). The lumbar and sacral nerves, as they spring from the lower end of the spinal cord.
- CAVERNOUS (Lat. *cavus*, hollow). Hollow channels or cavities are called cavernous.
- CEMENTUM (Lat. *cementum*, a rough stone). The substance which forms the exterior of the fang of a tooth.
- CENTRUM (Lat. the centre). The body of a vertebra.
- CERPHALIC (Gk. *κεφαλή*, the head). Belonging to the head.
- CEREBELLUM (Lat. diminutive of *cerebrum*). The lesser brain.
- CEREBRUM (Lat. the brain). The term applied to the greater brain or that part occupying the upper portion of the skull.
- CERVIX (Lat. *cervix*, gen. *cervicis*, the neck).
- CERUMINOUS (Lat. *cera*, wax). Glands secreting the ear wax.
- CHIASMA (Gk. *χιάζω*, I mark with the letter X; crossing or decussation). The commissure of the optic nerves.
- CHOLEDOCHUS (Gk. *χολή*, bile, and *δέχομαι*, I receive). Conveying bile.
- CHORDA (Lat. a cord). A cord, tendon, or nerve filament. Ex. Chorda tympani nerve.
- CHORION (Gk. *χόριον*, skin or leather). One of the membranes of the embryo.
- CHOROID (Gk. *χόριον*, the chorion, and *είδος*, like). Term applied to the middle coat of the eye from its vascularity.
- CHROMATIN (Gk. *χρῶμα*, colour). The part of the nucleus which has an affinity for staining fluids.
- CHROMOPLASM (Gk. *χρῶμα*, colour, and *πλάσμα*, substance). The amorphous part of a nucleus; so called from its affinity for staining fluids.
- CHROMOSOMES (Gk. *χρῶμα*, colour, and *σῶμα*, a body). The nuclear threads after their division, in indirect cell-division.
- CHYLE (Gk. *χῦλος*, juice). The fluid absorbed from the intestines by the lymphatics in digestion.
- CHYLO-POIETIC (Gk. *χυλός*, juice, that is to say, chyle, and *ποιέω*, I make). Chyle-producing. Term applied to the viscera connected with the formation of chyle.
- CILIA (Lat. *cilium*, an eyelash). The eyelashes.
- CILIARY (Lat. *cilium*, a hair). Belonging to the eyelashes. Also, by extension, to the structures connected with the power of accommodation in the eye.

- CIRCUMDUCTION** (Lat. *circum*, around, and *duco*, I lead). The slight degree of motion which takes place between the head of a bone and the socket, while the extremity of the limb is made to describe a large circle.
- CIRCUMVALLATE** (Lat. *circumvallatus*, trenched about).
- CLAUSTRUM** (Lat. *claudio*, I shut). A layer of grey matter in the outer capsule of the corpus striatum.
- CLAVICLE** (Lat. *clavis*, a key). The collar bone.
- CLEIDO-MASTOID** (Gk. κλείς, a key, μαστός, a nipple, and εἶδος, like). Connected with the clavicle and mastoid process.
- CLINOID** (Gk. κλίνη, a bed, and εἶδος, like). The processes which border the sella turcica are so called because they bear some resemblance to the posts of a bedstead.
- CLITORIS** (Gk. κλεινω, I shut up). The homologue in the female of the penis of the male.
- COAPTATION** (Lat. *con*, together, and *apto*, I fit). The bringing successive articular areas into relation with another articular surface.
- COCCYX** (Gk. κόκκυξ, a cuckoo). The last bone of the vertebral column in man. It is supposed to resemble a cuckoo's beak.
- COCHLEA** (Gk. κόχλος, a shell-fish). A spiral cavity in the internal ear.
- CÆLIAC** (Gk. κοιλία, the belly). Belonging to the belly.
- COLON** (Gk. κῶλον, the colon). The large intestine.
- COMMISSURE** (Lat. *committere*, to unite). A joining together.
- COMPLEXUS** (Lat. *complecti*, to comprise). A muscle at the back of the neck, so called because of the intricate mixture of its muscular and tendinous parts.
- CONCHA** (Gk. κόγχη, a shell). The central part of the external ear.
- CONDYLE** (Gk. κόνδυλος, a knuckle). Term applied to certain articular osseous processes.
- CONJUNCTIVA** (Lat. *con*, together, and *jungo*, I join). The mucous membrane of the front of the eye, which connects the lids with the eyeball.
- CONOID** (Gk. κώνος, a cone, and εἶδος, like). A cone-shaped portion of the coraco-clavicular ligament is so called.
- CONSTRICTOR** (Lat. *constringere*, to bind tightly together). A muscle which constricts or closes any opening of the body.
- CORACOID** (Gk. κόραξ, a raven, and εἶδος, like). A process of the scapula supposed to resemble a raven's beak.
- CORIUM** (Gk. χόριον, leather). The deep layer of the skin.
- CORNEA** (Lat. *corneus*, horny). The anterior transparent part of the eye.
- CORNUA** (Lat. *cornu*, a horn). Processes which project like horns.
- CORONA** (Lat. *corona*, a crown). Forming a circlet like a crown.
- CORPUS** (Lat. *corpus*, a body, pl. *corpōra*). A body. Hence we have the following:—
- Corpora albicantia** (Lat. *albico*, I become white). Two whitish masses of nerve substance at the base of the brain.
- „ **Arantii**. Fibrous nodules in the semilunar valves of the heart, so named after the anatomist, Aranzi of Bologna.
- „ **cavernosa** (Lat. *caverna*, a cavern). Two elongated bodies, formed of erectile tissue, and forming the chief bulk of the penis and clitoris.
- „ **geniculata** (Lat. *geniculum*, a knot). Two small prominences of nerve matter situated at the back part of each thalamus opticus.

- Corpora quadrigemina** (Lat. *quadrigeminus*, four placed in two pairs). The masses of nerve matter with which the optic tracts are especially connected. They are also called *optic lobes*.
- „ **striata** (Lat. *stria*, a streak). The great motor ganglia of the cerebrum; their streaked appearance is due to the presence of grey nuclei enclosed in white matter.
- Corpus callosum** (Lat. *callus*, hard). The great transverse commissure of the brain.
- „ **dentatum** (Lat. *dentatus*, toothed). A small mass of grey matter having an irregular outline, and situated in the centre of the cerebellum and in the olivary body.
- „ **fimbriatum** (Lat. *fimbria*, a fringe). The fringed edge of the fornix as seen in the lateral ventricle.
- „ **Highmorianum**. The central fibrous portion of the testicle, named after Highmore of Oxford.
- „ **luteum** (Lat. *luteus*, pale yellow). The cicatrix left in the ovary from the bursting of a Graafian vesicle.
- „ **spongiosum** (Lat. *spongia*, a sponge). The part of the penis which encloses the urethra.
- CORPUSCLE** (Lat. *corpuseulum*, diminutive of *corpus*, a body). A small body.
- CORRUGATOR** (Lat. *corrugare*, to wrinkle). A muscle which contracts the brow and produces wrinkles.
- COSTAL** (Lat. *costa*, a rib). Pertaining to the ribs.
- COTYLOID** (Gk. *κοτύλη*, a cup, and *εἶδος*, like). The cup-shaped cavity which receives the head of the femur.
- CRANIUM** (Gk. *κράνιον*, the skull). The skull.
- CREMASTER** (Gk. *κρεμάω*, I suspend). The suspensory muscle of the testicle.
- CRIBRIFORM** (Lat. *cribrum*, a sieve, and *forma*, likeness). Sieve-like.
- CRICOID** (Gk. *κρίκος*, a ring, and *εἶδος*, like). One of the cartilages of the larynx.
- CRISTA GALLI** (Lat. a cock's comb). A comb-like process of the ethmoid bone.
- CRUS** (Lat. *crus*, a leg). A process or peduncle of the brain. *Crural—erurus*. Belonging to the leg.
- CRUSTA** (Lat. *crusta*, the rind or crust). The lower part of the crus cerebri.
- CUBOID** (Gk. *κύβος*, a cube, and *εἶδος*, like). A cube-shaped bone.
- CUNEIFORM** (Lat. *euneus*, a wedge, and *forma*, likeness). Wedge-shaped.
- CUNEUS** (Lat. *euneus*, a wedge). A wedge-shaped lobe of the brain.
- CUTICLE** (Lat. *cuticula*, diminutive of *cutis*, the skin). The superficial layer of the skin. Called also *epidermis*, and *scarf-skin*.
- CYSTIC** (Gk. *κύστις*, a bladder or bag). Belonging to the urinary or gall bladder.
- DARTOS** (Gk. *δαρτός*, flayed). The subcutaneous layer of the scrotum.
- DEGLUTITION** (Lat. *deglutire*, to swallow). The act of swallowing.
- DELTOID** (Gk. Δ, and *εἶδος*, like). The muscle and ligament thus named resemble in shape the Greek letter D.
- DENTES SAPIENTIE** (Lat. *dens*, a tooth, and *sapientia*, wisdom). Wisdom teeth.

- DENTINE (Lat. *dens*, a tooth). The tissue forming the body of the tooth.
- DERMA (Gk. *δέρμα*, the skin). The deeper layer of the skin ; called also *true skin*.
- DIAPHRAGM (Gk. *διάφραγμα*, a partition wall). The muscle which separates the cavity of the abdomen from that of the thorax.
- DIAPHYSIS (Gk. *διά*, through, and *φύω*, I grow). A term applied to the shaft of a long bone.
- DIARTHROSIS (Gk. *διά*, through, and *ἄρθρον*, a joint). A joint which is freely movable.
- DIASTER (Gk. *δίσ*, twice, and *αστηρ*, a star). A stage of nuclear division.
- DICHOTOMOUSLY (Gk. *δίχα*, double, and *τέμνω*, I cut). Dividing into pairs.
- DIGASTRIC (Gk. *δίσ*, twice, and *γαστήρ*, a belly). Two-bellied.
- DIGITAL FOSSA (Lat. *digitus*, a finger, and *fossa*, a ditch). A depression such as might be produced by the tip of the finger.
- DIPLOË (Gk. *διπλῶς*, double). The osseous tissue between the two tables of the skull.
- DISC (Lat. *discus*, a flat plate).
- DISSECT (Lat. *disseco*, I cut to pieces).
- DUODENUM (Lat. *duodeni*, twelve). The first portion of the small bowel was thus named by Herophilus, because it is twelve fingers' breadth in length.
- DURA MATER (Lat. *dura*, hard, and *mater*, mother). The outer membrane of the brain.
- ELEIDIN (Gk. *ἦλος*, a nail, and *εἶδος*, form). A peculiar organic principle found in the *stratum granulosum* of skin, and in nails.
- EMBRYO (Gk. *έν*, in, and *βρύω*, I bud forth). The foetus in utero.
- EMULGENT (Lat. *emulgeo*, I milk or drain out). Term applied to the renal arteries.
- ENAMEL (Gk. *έν*, in, and Fr. *émail*). The hard substance covering the crown of a tooth.
- ENARTHROSIS (Gk. *έν*, in, and *ἄρθρον*, a joint). A ball-and-socket joint, in which the rounded head of one bone is received into the cup-shaped socket of another.
- ENCEPHALON (Gk. *έν*, in, and *κεφαλή*, the head). The brain.
- ENDOCARDIUM (Gk. *ένδον*, within, and *καρδία*, the heart). The membrane lining the cavities of the heart.
- ENDOMYSIUM (Gk. *ένδον*, within, and *μῦς*, muscle). The membrane lying between the fibres of muscle.
- ENDOTHELIUM (Gk. *ένδον*, within, and *θηλή*, papilla). Cells derived from the mesoblast, and lining serous surfaces.
- ENSIFORM (Lat. *ensis*, a sword, and *forma*, shape). The terminal piece of the sternum.
- EPHIPPIUM (Gk. *ἐπίππιον*, a saddle). The ridge forming the back of the sella turcica is called *dorsum ephippii*.
- EPICRANIUM (Gk. *ἐπί*, upon, and *κράνιον*, the skull). The periosteum of the skull.
- EPIDERMIS (Gk. *ἐπί*, upon, and *δέρμα*, skin). The superficial layer of the skin.
- EPIDIDYMIS (Gk. *ἐπί*, upon, and *δίδυμος*, the testicle). A small lobule connected with the testicle.
- EPIGASTRIUM (Gk. *ἐπί*, upon, and *γαστήρ*, stomach). The region of the abdomen in which part of the stomach lies.

- EPIGLOTTIS** (Gk. *ἐπί*, upon, and *γλωττίς*, the glottis). The cartilage which covers the opening of the glottis in deglutition.
- EPINEURIUM** (Gk. *ἐπί*, upon, and *νεῦρον*, nerve). The nerve sheath.
- EPIPHYSIS** (Gk. *ἐπί*, upon, and *φύω*, I grow). The portions of long bones which grow by centres distinct from that of the shaft.
- EPIPLOIC** (Gk. *ἐπί*, upon, and *πλέω*, I sail). Belonging to the omentum, this being called *epiploon*.
- EPITHELIUM** (Gk. *ἐπί*, upon, and *θηλή*, papilla). So called because it generally forms the superficial layers of tissues.
- ERECTOR** (Lat. *erigere*, to raise).
- ERYTHROID** (Gk. *ερυθρος*, red, and *εἶδος*, like). Reddish. A term applied to the cremaster muscle where it covers the spermatic cord.
- ETHMOID** (Gk. *ἤθμός*, a sieve, and *εἶδος*, like). A bone so called from the perforations in its horizontal plate.
- EXTENSOR** (Lat. *extendere*, to stretch out). A muscle which extends a part.
- FACET** (Fr. *facette*, a little face). A small plane surface.
- FALCIFORM** (Lat. *falx*, a sickle, and *forma*, like). Sickle-like.
- FALLOPIAN TUBES**. The ducts for the passage of the ovum from the ovary to the uterus; so called after Gabriel Fallopius, the anatomist who first described them.
- FALX CEREBRI** (Lat. *falx*, a sickle, and *cerebrum*, the brain). A sickle-like process of the dura mater separating the two hemispheres of the brain.
- FASCIA** (Lat. *fascia*, a bundle). A sheet composed of bundles of fibrous tissue.
- FASCICULUS** (Lat. diminutive of *fascia*, a bundle). A small bundle of muscular or nerve fibres.
- FAUCES** (Lat. plural of *fauz*, the throat). The opening between the mouth and pharynx.
- FEMUR** (Lat. *femur*, the thigh). The thigh bone.
- FENESTRA** (Lat. *fenestra*, a window). Term applied to the openings between the middle and internal ear.
- FIBRIL** (Lat. *fibril*, a fibre). A small filament or fibre.
- FIBRILLÆ** (Lat. diminutive of *fibril*). The ultimate fibres of muscle.
- FIBULA** (Lat. *fibula*, a clasp). The lesser bone of the leg.
- FILIFORM** (Lat. *filum*, a thread, and *forma*, like). Thread-like.
- FILUM TERMINALE**. The thread by which the spinal cord is fixed at its lower extremity.
- FIMBRIÆ** (Lat. *fimbriae*, fringes). The fringes of the Fallopiian tube.
- FLEXOR** (Lat. *flectere*, to bend). A muscle which bends the limb.
- FLOCCULUS** (Lat. diminutive of *floccus*, a lock of wool). The part of the cerebellum on which the pneumogastric nerve lies.
- FŒTUS** (Lat. *fœtus*, the young of any creature). The child in utero after the fourth month.
- FOLLICLE** (Lat. diminutive of *follis*, a bag). A small cavity with open mouth.
- FONTANELLES** (Lat. diminutive of *fons*, a fountain). The spaces between the cranial bones in the fœtus.
- FORAMEN** (Lat. *foramen*, a hole). A passage or opening.
- FORNIX** (Lat. *fornix*, an arch or vault). An arched commissure of the brain.
- FOURCHETTE** (Fr. *fourchette*, a fork). The thin fold which connects the labia majora posteriorly.

FOVEA (Lat. *fovea*, a pit). A shallow depression.

FRÆNUM (Lat. *frænum*, a curb or bridle). Any part which performs the office of a check or curb; more especially applied to a band of mucous membrane.

FUNDUS (Lat. *fundus*, the bottom). The base of an organ.

FUNGIFORM (Lat. *fungus*, and *forma*, shape). Shaped like a mushroom.

FUSIFORM (Lat. *fuscus*, a spindle). Spindle-shaped.

GALACTOPHORUS (Gk. γάλα, milk, and φέρω, I carry). Term applied to the ducts of the mammary glands.

GANGLION (Gk. γάγγλιον, a tumour or enlargement). A nerve centre.

GASTRIC (Gk. γαστήρ, the belly). Pertaining to the stomach.

GASTROCNEMIUS (Gk. γαστήρ, the belly, and κνήμη, the leg). The muscle which forms the bulk of the bellied part of the leg.

GEMELLUS (Lat. dim. of *geminus*, double). Twin muscles.

GENIAL (Gk. γένειον, the chin). Belonging to the chin.

GENICULATE (Lat. *geniculum*, a little knee). A ganglionic swelling on a bend of the facial nerve is called *geniculate*.

GENIO-HYO-GLOSSUS (Gk. γένειον, the chin, and γλῶσσα, the tongue). A muscle attached to the chin, hyoid bone, and tongue.

GENIO-HYOID. A muscle attached to the chin and hyoid bone.

GENU (Lat. *genu*, the knee). The anterior bent portion of the corpus callosum.

GINGLYMUS (Gk. γιγγλυμός, a hinge). A hinge-joint.

GLANS (Lat. *glans*, an acorn). The extremity of the penis or clitoris.

GLENOID (Gk. γλήνη, a socket, and εἶδος, likeness). The name of a part having a shallow cavity, as the shoulder-joint, and a fossa in the temporal bone.

GLOBUS (Lat. *globus*, a ball). Term applied to part of the epididymis.

GLOMERULUS (Lat. dim. of *glomus*, a ball of thread). The vascular tufts of the kidneys.

GLOSSO—(Gk. γλῶσσα, the tongue). Terms compounded of this word belong to nerves or muscles connected with the tongue.

GLOTTIS (Gk. γλωττις). The opening of the larynx.

GLUTEUS (Gk. γλουτός, the buttock). The name given to the chief muscles of the buttock.

GOMPHOSIS (Gk. γόμφος, a nail). A nail-like articulation, as that of the teeth with the jaws.

GRACILIS (Lat. *gracilis*, slender). A long, thin muscle of the thigh.

GUBERNACULUM (Lat. *gubernare*, I steer or guide). The cord which guides the testicle in its descent.

GUSTATORY (Lat. *gusto*, I taste). Connected with taste.

GYRUS (Gk. γύρος, a ring). A convolution.

HABENULA (Lat. *habena*, a rein). A ribbon-like band. Especially applied to a part of the optic thalamus.

HÆMATOBLASTS (Gk. αἷμα, blood, and βλάστος, a cell). Minute plate-like elements in the blood.

HÆMORRHOIDAL (Gk. αἷμα, blood, and ῥέω, I flow). A term applied to those vessels which bleed in piles.

HAMULAR (Lat. *hamus*, a hook). Hook-shaped.

HARMONIA (Gk. ἄρμοζω, I fit together). An articulation in which the

- bones are joined together without serration of the edges, or the intervention of cartilage.
- HAVERSIAN.** A term given from the name of their discoverer, Havers, to a very complicated system of minute canals found in the substance of bone.
- HELICO-TREMA** (Gk. ἑλιξ, a spiral, and τρήμα, a hole). The hole between the two scalæ of the cochlea.
- HELIX** (Gk. ἑλιξ, a spiral). Having a spiral form. *Helicine*.
- HEPATIC** (Gk. ἥπατικός, of the liver). Relating to the liver.
- HIATUS** (Lat. *hius*, I open). An irregular opening.
- HILUM** (Lat. *hilum*, a very little thing). A slight groove or fissure.
- HIPPOCAMPUS** (Gk. ἵπποκάμπος, a sea-horse). Convulsions of the brain supposed to resemble a sea-horse.
- HISTOLOGY** (Gk. ἵστος, a web, and λόγος, a discourse). The study of the minute structure of the tissues.
- HOMOLOGY** (Gk. ὁμος, like, and λόγος, a discourse). The morphological identity of parts or organs in different animals, or of the several parts of the same animal (*Serial Homology*).
- HYALINE** (Gk. ὑαλος, glass). Transparent and apparently structureless.
- HYALOPASM** (Gk. ὑαλος, glass, and πλάσμα, substance). The fluid part of cell protoplasm.
- HYOID** (Gk. υ, the letter upsilon, and εἶδος, likeness). The hyoid bone, so named from its shape.
- HYDROCEPHALIC** (Gk. ὕδωρ, water, and κεφαλή, the head). Relating to water in the head.
- HYO-EPIGLOTTIC.** Connecting the hyoid bone and epiglottis.
- HYPOCHONDRIUM** (Gk. ὑπό, under, χόνδρος, cartilage). The upper lateral region of the abdomen, situated under the cartilages of the false ribs.
- HYPOGASTRIC** (Gk. ὑπό, under, and γαστήρ, the stomach). Beneath the stomach.
- HYPOGLOSSAL** (Gk. ὑπό, under, and γλῶσσα, the tongue). Beneath the tongue.
- HYPOPHYSIS** (Gk. ὑπό, under, and φύσις, from φύω, I grow). The pituitary body is called *hypophysis cerebri*, because it is connected with the under surface of the anterior part of the brain.
- HYPOTHENAR** (Gk. ὑπό, under, and θέναρ, the palm of the hand).
- ILEUM** (Gk. εἰλέω, I roll up). The lower three-fifths of the small intestine : so called from its convolution.
- ILIAC** (Lat. *ilia*, the flanks). Belonging to the ilia or flanks.
- IMPAR** (Lat. *in*, not, and *par*, equal). Odd or unequal. *Ganglion impar*.
- INFRAORBITAL** (Lat. *infra*, beneath, and *orbs*, a circle). Beneath the circle of the eye.
- INFUNDIBULUM** (Lat. *infundibulum*, a funnel or tunnel). A funnel-shaped opening or canal.
- INGUINAL** (Lat. *inguin*, the groin). Belonging to the groin.
- INION** (Gk. ἰμιον, the occiput). The external occipital protuberance.
- INOSCULATION** (Lat. *in*, in, and *osculum*, a little mouth). The union of vessels, or anastomosis.
- INTEGUMENT** (Lat. *in*, in, and *tego*, I cover). The skin.
- INTERCALARY** (Lat. *inter*, between, and *calo*, I insert). Placed or inserted between.

- INTERNODIA** (Lat. *internodium*, the space between two knots). The interspaces between the joints of the fingers.
- INTEROSSEOUS** (Lat. *inter*, between, and *os*, a bone). Between the bones.
- IRIS** (Gk. *iris*, the rainbow). The iris is so called from its bright colours.
- ISCHIUM** (Gk. *ischion*, the hip). The hip bone.
- JEJUNUM** (Lat. *jejunos*, empty). The upper two-fifths of the small intestine, so named from this portion being generally found empty after death.
- JUGULAR** (Lat. *jugulum*, the throat). Veins of the throat are so named.
- KARYOKINESIS** (Gk. *κάρνον*, a kernel, and *κίνησις*, movement). Cell-division preceded by certain peculiar changes in the nucleus. Mitosis.
- KARYOSTENOSIS** (Gk. *κάρνον*, a kernel, and *στενωω*, I contract). Cell-division without precedent nuclear elaboration.
- LABIA** (Lat. pl. of *labium*, a lip). The lips. *Labia majora*, the two large folds forming the external orifice of the pudendum, and the *labia minora*, the two smaller folds situated within them.
- LABYRINTH** (Gk. *λαβύρινθος*, a maze). The internal ear.
- LACERUM** (Lat. *lacerum*, a torn opening). A term applied to irregular openings seen in the base of the skull.
- LACHRYMAL** (Lat. *lachryma*, a tear). Pertaining to the tears.
- LACUNE** (Lat. *lacus*, a lake). Small cavities.
- LAMBDA** (Gk. letter Λ). The point of junction of the lambdoidal and sagittal sutures.
- LAMBDOIDAL** (Gk. letter Λ , lambda, and *ειδος*, likeness). Formed like the Greek letter Λ .
- LARYNX** (Gk. *λάρυξ*, the larynx). The upper part of the windpipe.
- LATISSIMUS DORSI** (Lat. *latissimus*, broadest, and *dorsum*, the back). The broadest muscle of the back.
- LENTICULAR** (Lat. *lens*, *lentis*, a lentil). Lens-shaped.
- LEVATOR** (Lat. *levare*, to lift up). A muscle which raises any part.
- LIGAMENT** (Lat. *ligare*, to bind). A membrane which connects the articular surface of bones and cartilages, and sometimes protects the joint by a capsular envelope.
- LINEA ASPERA** (Lat. *linea*, a line, and *asper*, rough).
- LINGUAL** (Lat. *lingua*, a tongue). Relating to the tongue.
- LINGULA** (Lat. dim. of *lingua*, a tongue). A thin layer of bone, or of nerve matter of the brain.
- LOCUS PERFORATUS** (Lat. *locus*, a place, and *perforatus*, bored). A perforated space.
- LUMBRICALES** (Lat. *lumbricus*, an earth-worm). The name of certain muscles of the hand and foot, so called from their resemblance to the earth-worm.
- LUNULA** (Lat. *lunula*, dim. of *luna*, the moon). The small white portions at the root of the nails.
- LYMPH** (Lat. *lymp̄ha*, water). A colourless liquid of an alkaline character which fills the lymphatic vessels.
- LYMPHATICS** (from preceding). The term applied to vessels containing lymph.

- LYRA (Lat. *lyra*, a lyre). The name given to that part of the fornix which presents the appearance of some white lines somewhat resembling the strings of a lyre.
- MACERATION (Lat. *macerare*, to make soft by steeping). The steeping of a body for some time in water, spirit, ether, wine, or vinegar, for purposes of softening.
- MALAR (Lat. *mala*, the cheek). Belonging to the cheek.
- MALLEOLAR (Lat. *malleolus*, dim. of *malleus*, a hammer). A term applied to two projections of bone which overhang the ankle-joint.
- MALLEUS (Lat. *malleus*, a hammer). The hammer bone, one of the small bones of the ear.
- MASSETER (Gk. *μασσάομαι*, I chew). One of the chief muscles of mastication.
- MASTOID (Gk. *μαστός*, a breast, and *είδος*, like). A prominence which resembles the nipple of the breast.
- MAXILLARY (Lat. *maxilla*, the cheek bone). Belonging to the jaws.
- MEATUS (Lat. *meatus*, a passage). A passage.
- MEDIASTINUM (Lat. *medius*, middle, and *sto*, I stand). The space left between the two pleural sacs in the cavity of the thorax.
- MEDULLA (Lat. *medius*, middle). Marrow, situated in the middle of the bones.
- MEMBRANE (Lat. *membrana*, the skin of an animal). A thin substance lining a cavity.
- MENINGES (Gk. *μήνιγξ*, a membrane). The membranes of the brain.
- MENSTRUATION (Lat. *menstrua*, pl. of *menstruus*, a monthly allowance). The periodical discharge from the female generative organs of a bloody fluid poured out by the inner surface of the uterus.
- MENTAL (Lat. *mentum*, the chin). Belonging to the chin.
- MESENTERY (Gk. *μέσος*, middle, and *έντερον*, an intestine). The membrane which suspends the small intestines from the posterior wall of the abdomen; a reflection of the peritoneum.
- MESIAL (Gk. *μέσος*, middle). In the middle line.
- MESO- (Gk. *μέσος*, middle). A term compounded with other words to attach the meaning of middle to these words.
- META- (Gk. *μετά*, beyond). A Greek preposition prefixed to anatomical terms to convey the idea of farther distance, as in metacarpus, beyond the carpus.
- MITOSIS (Gk. *μίτρος*, a thread). Cell-division preceded by peculiar changes in the nucleus. The same as karyokinesis.
- MODIOLUS (Lat. *modiolus*, the nave of a wheel). The central osseous column of the cochlea.
- MOLAR (Lat. *mola*, a millstone). Grinding teeth.
- MONS PUBIS (Lat. *mons*, a mountain, and *pubes*, one of the bones of the pelvis). The pad over the pubes in the female.
- MUCIPAROUS (Gk. *μύξα*, the mucus of the nostrils, and *παίρειν*, to produce). Producing mucus.
- MUCUS (Gk. *μύξα*, the mucus of the nostrils). The liquid secreted by mucous membrane.
- MYLO-HYOID (Gk. *μύλη*, a millstone). Attached to the lower jaw (part of the mill), and the hyoid bone.
- MYOLEMMA (Gk. *μύς*, a muscle, and *λεμμα*, a membrane). A delicate sheath investing the ultimate fibrils of muscular tissue.

- MYOLINE** (Gk. *μῦς*, a muscle). A transparent substance contained in the ultimate fibrils of muscular tissue.
- MYOIDES** (Gk. *μῦς*, a muscle, and *εἶδος*, like). *Platysma myoides*.
- MYRTIFORM** (Gk. *μύρτος*, a myrtle berry, and Lat. *forma*, likeness). A fossa on the superior maxillary bone is so called on account of its shape.
- NARES** (Lat. *nares*, the nostrils). The cavities of the nose.
- NASAL** (Lat. *nasus*, the nose). Belonging to the nose.
- NASION** (Lat. *nasus*, the nose). The depression at the junction of the nose with the forehead.
- NAVEL** (Sax. *nafela*, from *nafa*, nave). The vernacular name for the depression in the middle of the abdomen, being the scar left by the detachment of the umbilical cord after parturition.
- NAVICULAR** (Lat. *navicula*, a small ship). Term applied to the boat-like or scaphoid bone of the wrist.
- NECROSIS** (Gk. *νεκρω*, I mortify). Term used to denote death of the bone.
- NERVES** (Lat. *nervus*, a string or cord). White cords arising from the brain, or the spinal marrow, and distributed over every part of the system.
- NEUROGLIA** (Gk. *νεῦρον*, nerve, and *γλία*, glue). The connective elements of nerve tissues.
- NEUROLEMMMA** (Gk. *νεῦρον*, nerve, and *λέμμα*, a skin). The primitive sheath of nerve fibre.
- NOTOCHORD** (Gk. *νωτον*, the back, and *χορδη*, a cord). The primitive vertebral column.
- NUCLEUS** (Lat. *nuclcus*, a kernel). A body usually found in the centre of a cell.
- NYMPHÆ** (Gk. *Νυμφαι*, Nymphs). Two folds of mucous membrane situated within the labia majora of the pudendum, so called because they direct the course of the urine.
- OBELION** (Gk. *οβελος*, a mark). The slightly flattened area of the skull, near the parietal foramina.
- OBTURATOR** (Lat. *obturo*, I stop up). An aperture in the innominate bone which in the recent state is nearly closed by a membrane.
- OCCIPUT** (Lat. *ob*, *caput*, against the head). The back part of the head; the part opposite to the front or *sinciput*.
- ODONTOID** (Gk. *ὀδούς*, a tooth, and *εἶδος*, like). Resembling a tooth.
- (EDEMA** (Gk. *οίδημα*, from *οιδεω*, I swell). An infiltration of the subcutaneous areolar tissue.
- (ESOPHAGUS** (Gk. *οἶω*, *οἶσω*, I carry, and *φάγειν*, to eat). The gullet.
- OLECRANON** (Gk. *ὠλένη*, the elbow, and *κρᾶνον*, the head). The tip of the elbow.
- OLFACTORY** (Lat. *olfacere*, to smell). Belonging to the sense of smelling; the name of the first pair of cerebral nerves.
- OLIVARY** (Lat. *oliva*, an olive). The olivary bodies are two olive-shaped eminences of the *medulla oblongata*.
- OMENTUM** (Lat. *omentum*, the caul whercin the bowels are wrapped—Ainsworth).
- OMO-HYOID** (Gk. *ὤμος*, the shoulder). Attached to the shoulder and the hyoid bone.

- OPHTHALMIC (Gk. *ὀφθαλμῖς*, the eye). Belonging to the eye.
- OPPONENS (Lat. *opponens*, opposing). A term applied to a muscle which brings the thumb inwards, so as to oppose the fingers.
- OPTIC (Gk. *ὀπτομαι*, to see). Belonging to the sight.
- ORBICULAR (Lat. *orbiculus*, a little orb). Having a spherical or circular form; a name given to several muscles and to one of the ossicles of the ear.
- OS (ORIS) (Lat. *os*, *oris*, the mouth). A mouth; a passage or entrance into any place.
- OS (OSSIS) (Lat. *os*, *ossis*, a bone). A bone.
- OS CALCIS (Lat. *os*, a bone, and *calx*, the heel). The bone of the heel.
- OSSA TRIQUETRA (Lat. *os*, a bone, and *triquetrus*, having three corners). Small triangular bones sometimes found in the lambdoidal suture.
- OSSEOUS (Lat. *os*, a bone). Bony, formed of bone.
- OSSICULA (Lat. *ossiculum*, a little bone). Little bones.
- OSSIFICATION (Lat. *os*, a bone, and *facio*, I make). The act of the formation of bone.
- OSTEODENTINE (Lat. *os*, a bone, and *dens*, a tooth). A peculiar form of dentine, approaching closely to bone in its structure.
- OSTEOBLASTS (Gk. *ὀστέον*, bone, and *βλάστος*, a gerin). The formative cells of bone.
- OSTEOCLASTS (Gk. *ὀστέον*, bone, and *κλάω*, I break). The destructive cells of bone.
- OSTEOGENESIS (Gk. *ὀστέον*, a bone, and *γένεσις*, formation). The development of bone.
- OSTEOLOGY (Gk. *ὀστέον*, a bone, and *λόγος*, a discourse). A description of bones.
- OSTIUM (Lat. *ostium*, a mouth). The door or mouth of a tubular passage.
- OTIC GANGLION (Gk. *οἶς*, an ear, and *γάγγλιον*, a tumour). A small ganglion near the ear.
- OTOCONIA (Gk. *οἶς*, the ear, *κόμης*, dust). Minute particles of calcareous sand found in the membranous labyrinth of the ear.
- OTOLITHS (Gk. *οἶς*, the ear, and *λίθος*, a stone). Synonymous with otoconia.
- OVARIAN (Lat. *ovum*, an egg). Pertaining to the ovary.
- OVUM (Lat. *ovum*, an egg).
- OXYNTIC (Gk. *οξύς*, acid). Name given to certain cells of the stomach, from the supposition that they form the acid of the gastric juice.
- PACCHIONIAN BODIES. Small round whitish granulations found in connection with the membranes of the brain and called after Pacchioni.
- PACINIAN. Pacinian corpuscles are found on the peripheral extremities of the nerve fibres, chiefly in the palm of the hand and the sole of the foot, and are named after Pacini, an Italian anatomist.
- PALPEBRÆ (Lat. *palpebræ*, to wink). The eyelids.
- PAMPINIFORM (Lat. *pampinus*, a tendril, and *forma*, likeness). Plexus of veins of the testicle.
- PANCREAS (Gk. *πᾶν*, all, and *κρέας*, flesh). A conglomerate gland situated transversely across the posterior wall of the abdomen. It is also called sweet-bread.
- PANNICULUS (Lat. dim. of *pannus*, a piece of cloth). A membrane.
- PAPILLE (Lat. *papilla*, teats). The small conical eminences situated on the tongue and the deep layer of the skin.

- PARIETAL (Lat. *paries*, the wall of a house). The term applied to two of the bones of the cranium.
- PAROTID (Gk. *παρά*, near, and *οἶς*, the ear). The salivary gland situated just in front of the ear.
- PATELLA (Lat. *patella*, a small pan). The knee-pan, or cap of the knee.
- PECTINEAL (Lat. *pecten*, the pubic bone). The term applied to prominences of the pubic bone.
- PECTORALIS (Lat. *pectus*, the breast). The term applied to two muscles of the breast.
- PELVIS (Lat. *pelvis*, a basin). The osseous girdle which contains the internal organs of generation.
- PENIS (Lat. *penis*, a tail). The male organ of generation.
- PENNIFORM (Lat. *penna*, a feather, and *forma*, likeness). Feather-shaped; a term applied to those muscles that have their fibres arranged on one side of a long tendon.
- PEPTIC (Lat. *pepticus*, digestive). Pertaining to digestion.
- PERFORANS (Lat. *perforare*, to pierce through). A designation of the *flexor profundus digitorum* from its perforating the tendon of the flexor sublimis.
- PERICARDIUM (Gk. *περί*, around, and *καρδία*, the heart). The membrane which surrounds the heart.
- PERICHONDRIUM (Gk. *περί*, around, and *χόνδρος*, cartilage). The membrane that covers the free surface of cartilage.
- PERICRANIUM (Gk. *περί*, around, and *κράνιον*, the cranium). The periosteum of the cranium.
- PERIMYSIUM (Gk. *περί*, around, and *μυς*, muscle). The areolar sheath surrounding muscular fibre.
- PERINEUM (Gk. *περί*, around, and *ναίω*, I am situated). The space between the anus and the scrotum, or anus and vagina.
- PERINEURIUM (Gk. *περί*, around, and *νευρον*, a nerve). The sheath which encloses the funiculi of a nerve.
- PERIOSTEUM (Gk. *περί*, around, and *ὀστέον*, a bone). The membrane which covers the outside of a bone.
- PERIOTIC (Gk. *περί*, around, and *οὖς*, the ear). The petrous and mastoid portions of the temporal bone.
- PERITONEUM (Gk. *περί*, about, and *τείνω*, I stretch). The serous membrane which lines the abdominal and pelvic cavities.
- PERONEAL (Gk. *περόνη*, the pin of a buckle). Belonging to the fibula.
- PES (Lat. *pes*, the foot). A term applied to parts resembling a foot.
- PES ANSERINUS (Lat. *pes*, a foot, and *anserinus*, belonging to a goose). The goose's foot. The name of a plexus of nerves formed by the facial, or portio dura of the seventh pair, on the side of the face.
- PES ACCESSORIUS (Lat. *pes*, a foot, and *accessio*, I add to). A swelling at the junction of the posterior and middle horns of the lateral ventricles.
- PES HIPPOCAMPI (Lat. *pes*, a foot, and *hippocampus*). The termination or foot of the hippocampus major.
- PETROUS (Gk. *πέτρα*, a rock). The term applied to the hardest portion of the temporal bone. *Petrosal*.
- PEYER'S PATCHES. The groups of lymphoid nodules in the small intestine.
- PHALANX (Gk. *φάλαγξ*, a rank of soldiers). A term applied to the bones of the fingers and toes, from their regularity.

- PHARYNX (Gk. *φάρυγξ*, the throat). The upper part of the food passage.
- PHRENIC (Gk. *φρήν*, the mind). Belonging to the diaphragm. The ancients supposed the diaphragm to be the seat of the mind, and hence they called it *phrenes*.
- PIA MATER (Lat. *piā*, tender, and *mater*, mother). The innermost membrane of the brain.
- PINEAL (Lat. *pinus*, a pine). A small body, situated in the interior of the brain, is called the *pineal body*.
- PINNA (Lat. *pinna*, a feather). The expanded part of the external ear.
- PISIFORM (Lat. *pisum*, a pea). A bone of the wrist, shaped like a pea.
- PITUITARY (Lat. *pituita*, the secretion of the nostrils). The body thus named was so called because it was erroneously supposed to be the source of the nasal mucus.
- PLACENTA (Lat. *placenta*, a cake). The after-birth.
- PLANTARIS (Lat. *planta*, the sole of the foot). A muscle which in the plantigrade animals makes tense the fascia of the sole of the foot.
- PLATYSMA (Gk. *πλάτυσμα*, a flat piece). See MYOIDES.
- PLEURA (Gk. *πλευρά*, side). A membrane which covers the inside of the ribs, and the outside of the lungs.
- PNEUMOGASTRIC (Gk. *πνεύμων*, the lung, and *γαστήρ*, the stomach). The great nerve distributed to the larynx, lungs, heart, and stomach.
- POMUM ADAMI (Lat. *pomum*, an apple). Adam's apple. The anterior prominence of the thyroid cartilage.
- POPLITEAL (Lat. *poples*, the ham). The space behind the knee is so called, and certain nerves and vessels in it receive the same name.
- PORTAL (Lat. *porta*, a gate). The great vein which enters the liver through the transverse fissure ("gate of the liver") is so named.
- PORTIO DURA (Lat. *portio*, a part, and *dura*, hard). The facial nerve.
- POUPART'S LIGAMENT. The lower border of the aponeurosis of the external oblique muscle of the abdomen, attached to the anterior superior spine of the ilium and spine of the pubes.
- PREPUCE (Lat. *preputium*.) The foreskin.
- PROFUNDUS (Lat. *profundus*, deep). Deep-seated.
- PRONATOR (Lat. *pronus*, face downwards). Muscles bringing the hand to the *prone* position are thus named.
- PROSTATE (Gk. *πρό*, before, and *ἵστημι*, I stand). A glandular body which stands in front of the bladder.
- PROTOPLASM (Gk. *πρώτος*, first, and *πλάσσω*, I form). The material of which all cells are originally formed.
- PSEUDOPODIA (Gk. *ψευδής*, false, and *πούς*, a foot). Processes put out by free protoplasm.
- PSEUDO-STOMATA (Gk. *ψευδής*, false, and *στόμα*, a mouth). Minute intercellular patches in serous membranes, which resemble openings but are not.
- PSOAS (Gk. *ψόα*, the loin). A muscle of the loin.
- PTERION (Gk. *πτερυξ*, a wing). The tip of the great wing of the sphenoid.
- PTERYGOID (Gk. *πτέρυξ*, a wing, and *εἶδος*, like). Wing-like processes.
- PUBES (Lat. *pubescens*, covered with hair).
- PUDIC (Lat. *pudeo*, I am ashamed). The arteries and nerves going to the perineum and external organs of generation are thus named.
- PULMONARY (Lat. *pulmo*, the lung). Belonging to the lungs.
- PUNCTUM (Lat. *punctum*, a point).

- PYLORUS (Gk. *πυλωρός*, a gate-keeper). The lower opening of the stomach.
- PYRIFORMIS (Lat. *pyrus*, a pear, and *forma*, shape). A pear-shaped muscle.
- QUADRATUS (Lat. *quadratus*, square). The name of several muscles having a square form.
- QUADRICEPS (Lat.). Having four heads.
- QUADRIGEMINA (Lat. *quadrigeminus*, four arranged in two pairs). Name given to the optic lobes of the brain, from their division into four.
- RACEMOSE (Lat. *racemus*, a cluster of grapes). Clustered.
- RACHIDIAN (Gk. *ράχης*, the spine). Belonging to the spinal column.
- RADIUS (Lat. *radius*, a ray, or spoke of a wheel). One of the bones of the forearm.
- RAMUS (Lat. *ramus*, a branch).
- RANINE (Lat. *rana*, a frog). This word seems to be derived from *ranula*, an affection which is supposed to resemble a frog.
- RAPHÉ (Gk. *ράφή*, a seam). The line of junction of two lateral parts.
- RECTUS, RECTUM (Lat. *rectus*, straight). A straight muscle or tube.
- RENAL (Lat. *ren*, the kidney). Belonging to the kidney.
- RESTIFORM (Lat. *restis*, a cord). A cord-like band.
- RETINA (Lat. *rete*, a net). The nervous net-work of the eye. From the same root we have *rete mucosum*, *rete testis*, and others.
- RETINACULA (Lat. *retinere*, to hold back). Fibrous bands on the back of the neck of the femur.
- RISORIOUS (Lat. *rideo*, I laugh). The *risorius Santorini* is the muscle which produces the sardonic smile.
- ROTULA (Lat. dim. of *rota*, a wheel). The patella.
- RUGÆ (Lat. *ruga*, a wrinkle). Term applied to certain folds of mucous membrane.
- SACCULUS (Lat. dim. of *saccus*, a bag). A membranous bag in the internal ear.
- SACRUM (Lat. *sacris*, sacred). The sacrum was offered as a sacrifice by the ancients.
- SAGITTAL (Lat. *sagitta*, an arrow). Term applied to the straight suture between the parietal bones.
- SALPINGO-PHARYNGEUS (Gk. *σάλπιγξ*, a trumpet). Name given to a muscle which passes from the Eustachian tube to the pharynx.
- SAPHENOUS (Gk. *σαφηνής*, manifest). Name given to the superficial veins of the leg, because they are usually prominent.
- SARCOLEMMMA (Gk. *σάρξ*, flesh, and *λέμμα*, a covering). The covering of the muscular fibres.
- SARTORIUS (Lat. *sartor*, a tailor). The muscle thus named is used in crossing the legs.
- SCALA (Lat. *scala*, a stair). Three spiral passages in the cochlea are so called.
- SCALENUS (Gk. *σκαλήνος*, a geometrical figure having three unequal sides). The name of several muscles of the neck which are triangular in shape.
- SCAPHOID (Gk. *σκαφή*, a boat, and *εἶδος*, like). Anything having a boat-shape.

- SCAPULA (probably from Gk. *σκαπάνη*, a spade). The shoulder-blade.
- SCHINDYLESIS (Gk. *σχινδύλεω*, I cleave). An articulation in which the prominent spine of one bone is placed between two laminæ of the other, like a wedge into the wood it splits. The best example of this is the articulation of the rostrum of the sphenoid with the vomer.
- SCIATIC. *See* ISCHIATIC.
- SCLEROTIC (Gk. *σκληρός*, hard). The dense outer tunic of the eye.
- SCROTUM (Lat. *scrotum*, a leather bag). The pouch which contains the testicles.
- SEBACEOUS (Lat. *sebum*, suet). The glands which lubricate the hairs are thus named.
- SELLA TURCICA (Turkish saddle). The hollow on the upper surface of the sphenoid is so called from its supposed resemblance to a Turkish saddle.
- SEPTUM (Lat. *sepio*, I hedge in). A partition.
- SERRATUS (Lat. *serra*, a saw). The muscles which bear this name are so called from the resemblance of their costal attachments to the teeth of a saw.
- SESAMOID (Gk. *σησάμον*, sesame, and *εἶδος*, like). Bones contained in tendons of muscles.
- SIGMOID (Gk. *ς*, form of sigma, and *εἶδος*, like). Cavities which resemble in shape the old Greek letter *sigma*.
- SINUS (Lat. *sinus*, a hollow). A cavity or cell; also a venous channel, as those in the dura mater and heart.
- SKELETON (Gk. *σκέλλω*, I dry). The dry bones of any animal.
- SOLEUS (Lat. *solea*, a sandal; also a sole fish). A muscle which bears some resemblance to a sole fish.
- SPERMATOZOA (Gk. *σπέρμα*, seed, and *ζῶον*, an animal). The generative cells of the male. *Spermatic*.
- SPHENOID (Gk. *σφήν*, a wedge, and *εἶδος*, like). The bone so named wedges in the other bones of the base of the skull.
- SPHINCTER (Gk. *σφίγγω*, I contract). A term applied to those muscles which close an aperture.
- SPIREM (Gk. *σπίραμα*, a twisted cord). A stage of nuclear division.
- SPLANCHNIC (Gk. *σπλάγχνον*, a viscus or intestine). Nerves which go chiefly to the intestines.
- SPLEEN (Gk. *σπλήν*, the spleen). The spleen.
- SPLENIUS (Lat. *splenium*, a pad). A muscle of the neck.
- SQUAMOUS (Lat. *squama*, a scale). A scale-like piece of bone.
- STAPEDIUS (Lat. *stapes*, a stirrup). The muscle of the stirrup bone of the ear.
- STEPHANION (Gk. *στέφανος*, a crown or coronet). The point where the coronal suture crosses the upper temporal crest.
- STERNUM (Gk. *στέρνον*, the breast or chest). The breast bone.
- STOMATA (Gk. *στόμα*, a mouth). Openings communicating between the surface of serous membranes and the lymphatic capillaries.
- STROMA (Gk. *στρώμα*, a bed). The tissue forming the framework of an organ.
- STYLOID (Gk. *στύλος*, a style or pen, and *εἶδος*, like). An osseous process which resembles an ancient *stylus*.
- SUBLIMIS (Lat. *sublimis*, high). Superficial.
- SUDORIFEROUS (Lat. *sudor*, sweat, and *fero*, I bear). Term applied to the sweat glands and their ducts.

- SULCUS (Lat. *suleus*, a hollow). A hollow between convolutions of the brain.
- SUPINATOR (Lat. *supinus*, lying face upwards). Muscles which bring the arm to such a position that the palm of hand looks upwards are called supinators.
- SURAL (Lat. *sura*, the calf of the leg). Belonging to the calf.
- SUSPENSORIUM (Lat. *sub*, under, and *pendo*, I hang). That which slings up or supports.
- SUSTENTACULUM (Lat. *sustento*, I support). Supporting.
- SUTURE (Lat. *sutura*, a seam). The union of two bones by rough edges.
- SYMPHYSIS (Gk. *σύν*, together, and *φύω*, I grow). "An articulation in which there is no manifest motion" (Hoblyn).
- SYNARTHROSIS (Gk. *σύν*, together, and *αρθρόν*, a joint). An articulation in which there is complete fixture.
- SYNCHONDROSIS (Gk. *σύν*, together, and *χόνδρος*, cartilage). An articulation partly cartilaginous and partly fibrous.
- TENIA (Gk. *ταινία*, a band). The term is applied to certain bands of nerve matter in the brain.
- TARSUS (Gk. *ταρσός*, the upper surface of the foot). The bones of the posterior part of the foot.
- TEGMENTUM (Lat. *tegere*, to cover). Term applied to the upper strand of the crus cerebri.
- TELA (Lat. *tela*, a web). A term applied to web-like tissues.
- TEMPORAL (Lat. *tempora*, the temples, from *tempus*, time). Belonging to the temples.
- TENDON (Lat. *tendere*, to stretch). The fibrous extremity of a muscle, by which it is attached to bone.
- TENSOR (Lat. *tendere*, to stretch). A term conventionally applied to a muscle which stretches any part.
- TENTORIUM (Lat. *tentorium*, a tent). A process of the dura mater.
- TERES (Lat. *teres*, round).
- THALAMUS (Gk. *θάλαμος*, a bed). The part of the brain against which the optic nerves rest at their commencement is called *thalamus opticus*.
- THECA (Gk. *θήκη*, a case). The sheaths of the tendons of the fingers are called *thece*.
- THENAR (Gk. *θέναρ*, the palm of the hand). The mass of muscles forming the ball of the thumb is called the *thenar prominenee*.
- THORAX (Gk. *θώραξ*, a breastplate). The chest.
- THYMUS (Lat. *thymus*, thyme). A gland found in the upper part of the chest of young animals.
- THYROID (Gk. *θυρεός*, a shield, and *είδος*, like). Shield-shaped.
- TIBIA (Lat. *tibia*, a pipe or flute). The large bone of the leg.
- TORCULAR HEROPHILI (Lat. *torcular*, a wine-press). The meeting of the sinuses of the brain on the occipital bone. Literally it means the "wine-press of Herophilus."
- TRABECULÆ (Lat. dim. of *trabs*, a beam). Fibrous bands in the interior of such organs as the spleen, lymphatic glands, and penis.
- TRACHEA (Gk. *τράχυς*, rough). The wind-pipe. It was formerly called *arteria trachea*, the "rough air-passage;" rough from its cartilages.
- TRACHELO—(Gk. *τράχηλος*, the neck). Connected with the neck.

- TRAGUS (Gk. *τράγος*, a goat). A process of the external ear.
- TRAPEZIUM, TRAPEZIUS (Gr. *τραπέζα*, a table). Having a tabular form.
- TRICEPS (Lat. *tres*, three, and *caput*, a head). Having three heads.
- TRICUSPID (Lat. *tres*, three, and *cuspis*, a point). Name given to the right auriculo-ventricular valve from its being composed of three flaps.
- TRIGONE (Gk. *τρεῖς*, three, and *γωνία*, an angle). A triangle at the base of the bladder.
- TRIQUETRA. See OSSA TRIQUETRA.
- TROCHANTER (Gk. *τροχάω*, I roll or turn). Two prominences of the femur are so named.
- TROCHLEA (Gk. *τροχός*, a wheel). A kind of pulley.
- TURBINATED (Lat. *turbo*, a top). The term is applied to certain coiled bones in the nasal cavities.
- TYMPANIC (Lat. *tympanum*, the drum of the ear). Belonging to the cavity of the middle ear, or to the drum.
- TYSON'S GLANDS. Sebaceous glands situated around the *corona* of the penis, and named after Tyson, who first described them.
- ULNA (Gk. *ώλένη*, the elbow). One of the bones of the forearm.
- UMBILICUS (Lat. *umbilicus*). The navel.
- UNCINATE (Lat. *uncus*, a hook). Hooked.
- UNGUAL (Lat. *unguis*, a nail). Belonging to the nail.
- URACHUS (Gk. *οὔρον*, urine, and *ἔχω*, I hold). A cord which forms one of the ligaments of the bladder. It is the remains of the allantois of the embryo.
- URETER (Gk. *οὐρέω*, I pass water). The tube which conveys the urine from the kidney to the bladder.
- URETHRA (Gk. *οὔρον*, urine). The tube which conveys the urine from the bladder.
- UTERUS (Lat. *uterus*, the womb).
- UVEA (Lat. *uva*, grape). The posterior layer of the iris, named from its resemblance in colour to a grape.
- UVULA (Lat. dim. of *uva*, a grape). The small tongue which depends from the centre of the soft palate.
- VAGINA (Lat. *vagina*, a sheath). The term is generally restricted to the vulvo-uterine canal.
- VAGUS (Lat. *vago*, I wander). The pneumo-gastric nerve.
- VELUM (Lat. *velum*, a veil). A thin membranous layer which covers any part.
- VENTER (Lat. *venter*, the belly).
- VERMIFORM (Lat. *vermis*, a worm, and *forma*, shape). Having a shape like a worm.
- VERTEBRÆ (Lat. *vertere*, to turn). The segments of the spinal column. So called because they turn on each other.
- VESICAL (Lat. *vesica*, a bladder). Pertaining to the bladder.
- VILLI (Lat. *villus*, shaggy hair). Small processes on the mucous membrane of the small intestine.
- VINCULA (Lat. *vincula*, a small chain). Accessory bands found in the sheaths of the tendons of the fingers.
- VISCERA (Lat. *viscus*, pl. *viscera*, one of the internal organs of the body). The internal organs.

- VITREOUS (Lat. *vitrum*, glass). The transparent mass which occupies the posterior part of the globe of the eye.
- VOLAR (Lat. *vola*, the palm of the hand). Belonging to the palm.
- VOMER (Lat. *vomer*, a ploughshare). The central bone of the nose.
- VULVA (Lat. *volvere*, to roll). The genital opening of the female, enclosed by the labia majora.
- WORMIAN. The ossa triquetra are sometimes called Wormian bones from Olaus Wormius, who first described them.
- XIPHOID (Gk. *ξίφος*, a sword, and *εἶδος*, like). The lower piece of the sternum.
- ZYGOMA (Gk. *ζυγός*, a yoke). Joining together the bones of the side of the head and face.

INDEX.

	PAGE		PAGE
Abdomen	696	Arch, femoral	346
Abdominal regions	697	of aorta	377
ring	288, 295	palmar, superficial	416
Acetabulum	156	plantar	448
Achromatic spindle	3	Arciform fibres	492
Achromatin	3	nucleus	494
Acini	62	Areola of nipple	798
Acromion	139	Arcolæ, primary	25
Adenoid tissue	16	secondary	26
Adipose tissue	13	Areolar tissue	11
Air-cells	691	ARTERIES :	
Ala cinerea	520	general anatomy	43
Alcock's canal	313	structure	44
Alimentary canal	703	acromial-thoracic	408
Alveoli	54, 690	alar-thoracic	408
Amæboid motion	2	anastomotic of arm	410
Amphi-arthritis	179	leg	440
Ampulla	645	angular	387
Amygdalæ of the cerebellum	516	aorta	377
fauces	705	articular of knee	441
Anastomosis	43	auditory	401
Angular processes	92	auricular anterior	389
Angiology	377	posterior	388
Annulus membranæ tympani	99	axillary	405
ovalis	662	basilar	400
Antihelix	633	brachial	409
Antitragus	634	bronchial	417, 692
Antrum of Highmore	109	buccal	392
pylorus	724	bulbo-urethral	432
Anus	738	calcanean	447
Aorta	377	capsular	426
abdominal	418	cardiac	380, 672
thoracic	416	carotid, common	381
Aortic sinuses	377, 668	external	383
vestibule	668	internal	393
Aponurosis	227	carpal, radial	412
Apparatus ligamentosus colli	186	ulnar	416
Appendices epiploicæ	702	cavernosal	432
Appendix auriculæ	660, 665	central of retina	396
vermiformis	735	cerebellar	400, 401
Aquæductus cochleæ	97	cerebral	397, 525
vestibuli	97, 644	cervicalis ascendens	404
Aqueduct of Fallopius	651	profunda	405
Sylvius	514	superficialis	404
Aqueous humour	631	choroid	397
Arachnoid membrane	532, 535	ciliary	396
Aranzi, ventricle of	519	circumflex femoris	438
Arbor vitæ of cerebellum	517	humcri	408
uterns	790	ili	435, 437
Arch, crural	295	coccygeal	430

ARTERIES— <i>continued.</i>	PAGE
cœliac	419
colic	424
comes nervi ischiatici	430
mediani	415
phrenici	402
communicans cerebri	397
coronary of heart	380
lips	387
stomach	419
corporis cavernosi	432
cremasteric	435
crico-thyroid	384
cystic	422
deferential	429
dental	391
diaphragmatic	419
digital of hand	416
foot	448
dorsales pollicis	413
dorsalis hallucis	445
indicis	413
linguæ	385
pedis	444
penis	432
scapulæ	408
emulgent	426
epigastric	403, 434
superficial	437
ethmoidal	396
facial	386
facial, transverse	389
femoral	435
frontal	396
gastric	419
gastro-duodenal	420
gastro-epiploica dextra	421
sinistra	422
gluteal	433
hæmorrhoidal	425, 429, 431
helicine	773
hepatic	419, 748
hyoid	384, 385
hypogastric	427
ileo-colic	423
iliac, common	427
external	434
internal	427
ilio-lumbar	432
infra-orbital	392
innominate	381
intercostal	417
anterior	402
superior	405
interosseous	415
intestini tenuis	423
ischiatric	430
labial	387
lachrymal	395
laryngeal	384
lateral nasal	387
sacral	433
lingual	385
lumbar	426
magna pollicis	413
mallcolar	443
mammary	408
internal	402

ARTERIES— <i>continued.</i>	PAGE
mastoid	388
maxillary, internal	390
mediastinal	402
meningeal, anterior	396
inferior	389
lesser	392
middle	392
posterior	400
mesenteric, inferior	424
superior	422
metacarpal	412, 416
metatarsal	444
musculo-phrenic	403
mylo-hyoid	391
nasal	387, 396
nutrient of humerus	410
tibia	446
obturator	429
occipital	388
oesophageal	417
ophthalmic	394
orbital	390
ovarian	424, 795
palatine, anterior	393
ascending	386
descending	393
palpebral	396
pancreatica magna	422
pancreaticæ parvæ	422
pancreatico-duodenal	421, 422
parotidean	389
perforating, femoral	439
palmar	414
plantar	448
pericardiac	402
perineal, superficial	431
peroneal	446
pharyngeal, ascending	388
phrenic	419
plantar	447
popliteal	441
princeps cervicis	388
pollicis	413
profunda cervicis	405
femoris	438
inferior	410
superior	409
prostatic	770
pterygoid	393
pterygo-palatine	393
pubic	429, 435
external	438
internal	430, 432
pulmonary	449, 665
pyloric	420
radial	411
radialis indicis	413
ranine	386
receptacular	394
recurrent, interosseous	416
radial	412
tibial	443
ulnar	415
renal	426, 762
sacral, lateral	433
middle	426
scapular, posterior	404

ARTERIES— <i>continued.</i>	PAGE		PAGE
sigmoid	424	Bicuspid teeth	711
spermatic	424, 778	Biliary ducts	748
spheno-palatine	393	Bladder	765
spinal	400	Blood	4
splenic	422, 755	clot	4
sterno-mastoid	384	corpuscles	5
stylo-mastoid	388	platelets	6
subclavian	397	Blood-vessels, structure of	42
sublingual	385	Bochdalek, ganglion of	545
submaxillary	387	Body, pineal	515
submental	387	Bodies, supra-renal	756
subscapular	408	BONES :	
superficialis volæ	412	chemical composition	20
supra-orbital	395	development	24
supra-renal	426, 757	minute structure	21
supra-scapular	404	number of	73
sural	442	structure	20
Sylvian	397, 527	astragalus	167
tarsal	444	atlas	76
temporal, deep	392	axis	77
superficial	389	calcis	168
thoracic	407, 408	carpus	146
thymic	402	clavicle	136
thyroidea ima	381	coccyx	86
thyroid, inferior	403	coxæ	153
lowest	381	cuboid	171
superior	383	cuneiform, of carpus	148
tibial, anterior	442	external of tarsus	171
posterior	445	internal	169
tonsillar	387	middle	170
transversalis colli	404	ethmoid	105
humeri	404	femur	160
perinei	432	fibula	166
tympanic	391, 394	frontal	92
ulnar	414	humerus	140
umbilical	427, 674	hyoid	131
uterine	429, 790	ilium	154
vaginal	429	incus	639
vasa brevia	422	innominate	153
intestini tenuis	423	ischium	155
of vas-deferens	429	jugal	112
vertebral	399	lachrymal	111
vesical	429, 768	lingual	131
Vidian	393	magnum	150
Arthrodia	179	malar	112
Arthrology	175	malleus	638
Articulations	175, 178	maxillary, lower	117
Arytenoid cartilages	676	upper	107
glands	683	metacarpus	151
Asterion	528	metatarsus	172
Aster stage	4	nasal	107
Atrium	660	occipital	87
Auerbach, plexus of	735	orbicular	640
Auricles of the heart	660, 665	palate	113
Auriculo-ventricular openings	663, 667	parietal	90
Axis, cœliac	419	patella	163
thoracic	408	pelvis	153, 158
thyroid	403	phalanges of hand	153
Axis cylinder	34	foot	173
Bartholin's duct	708	pisiform	148
glands	797	pubes	156
Base of the brain	497	pyramidal	148
Basement membrane	16	radius	145
Bauhin, valve of	739	ribs	133
Bertin, bones of	102	sacrum	84
Bertini, columns of	759	scaphoid of carpus	147
		tarsus	169

BONES— <i>continued.</i>	PAGE	CARTILAGE— <i>continued.</i>	PAGE
scapula	137	fibro	19
semi-lunar	147	hyaline	17
sesamoid of hand	174	interarticular of clavicle	198
foot	174	jaw	189
sphenoid	100	wrist	205
spongy	102	of Meckel	119
stapes	640	permanent	18
sternum	131	reticular	18
tarsus	167	semi-lunar	216
temporal	94	temporary	18
tibia	164	xiphoid	132
trapezium	149	Cartilages, arytenoid	676
trapezoid	150	bronchial	689
triquetra	120	costal	135
turbinated, inferior	115	of larynx	675
superior	106	Santorini	676
tympenic	99	trachea	684
ulna	143	Caruncula lachrymalis	619
unciform	151	mamillaria	499
vertebra prominens	78	sublingualis	704
vertebræ, cervical	75	Caruncula myrtiformes	797
dorsal	78	Cauda equina	486
lumbar	80	Cava, vena	464
vomere	116	Cells	1
Wormiana	120	epithelial	7
Botal, foramen of	672	ethmoidal	106
Bowman's discs	29	hepatic	745
Brachia cerebri	515	Cell division	3
Brain	497	direct	3
Bregma	528	indirect	3
Bronchi	684, 688	Cement	715
Bronchial tubes	688	Centrum ovale	506
Bronchocele	686	Cerebellum	516
Bruch, membrane of	624	structure of	517
Brunner's glands	732	Cerebro-spinal axis	485
Bulb of corpus spongiosum	773	fluid	533, 535
olfactory	537	Cerebrum	497
Bulbous part of the urethra	777	transverse section of	521
Bulbs of fornix	499	Ceruminous glands	72, 636
Bursæ mucosæ	58, 177	Cervical ganglia	602
Cæcum	735	Chambers of the eye	631
Calamus scriptorius	519	Cheeks	703
Calcarine fissure	505	Chiasma of optic nerves	538
Calices	759	Chondrin	19
Canal of Alcock	313	Chordæ longitudinales	507
Hannover	633	tendinæ	663, 667
Huguier	98	Chordæ vocales	678
Hunter	436	Willisii	454
Nuck	795	Chorio-capillaris	624
Petit	633	Choroid coat	624
Schlemm	624	plexus	508
Stilling	631	Chromatin	3
Canaliculi of bone	22	Chromoplasm	3
lachrymal	620	Chyle	7
Canals of Havers	21	Cilia	618
Cancelli of bone	20	Ciliated epithelium	10
Canine teeth	710	Ciliary ligament	627
Canthi	616	processes	626
Capillaries	47	Circle of Willis	402
Capsule of Glisson	746	Circulation, adult	660
Tenon	236, 615, 621	fœtal	672
Caput coli	735	Circulus tonsillaribus	555
gallinaginis	776	venosus Halleri	800
Carpus	146	Willisii	402
Cartilage, articular	18	Clastrum	523
elastic	18	Clava	493
		Clitoris	796

	PAGE		PAGE
Clivus Blumenbachii	101	Crura cerebelli	517
Clot, blood	4	cerebri	499
Cochlea	645	of diaphragm	299
Coceygeal gland	611	penis	771
Cœliac axis	419	Crural arch	295
Cohnheim, polygonal areas of	30	canal	345
Colon	735	ring	345
Colostrum	800	Crystalline lens	632
Column of Burdach	487	Cuneiform cartilages	677
Goll	487	Cuneate tubercle	493
Columna of nose	611	Cuneus lobe	505
Columnæ carneæ	664, 667	Cupola	645
Columnar epithelium	8	Cuticle	64
Commissures	514	Cutis	63
Commissure, great	506	Cylinder epithelium	8
Concha	634	Cystic duct	751
Condylarthritis	180		
Cones of retina	629	Dartos	778
Congenital hernia	297	Decussation of pyramids	491
Coni vasculosi	781	Deglutition, mechanism of	265
Conjunctiva	619	Deiters, cells of	488
Connective tissue	11	Demours, membrane of	623
Conus arteriosus	668	Dentine	712
medullaris	485	Derbyshire neck	686
Convolutions	501	Derma	63
structure of	505	Descemet, membrane of	623
Coracoid process	139	Descent of testicle	784
Corium	59, 63	Detrusor urinæ	766
Cornæ	622	Development of bone	24
Cornicula laryngis	676	intracartilaginous	25
Cornu Ammonis	510	intramembranous	24
Cornua of the ventricles	510	Diaphragm	299
Corona glandis	771	Diaphysis	27
Coronary valve	662	Diarthrosis	179
Corpora albicantia	499	Diaster stage	4
Arantii	665, 668	Digital fossa	160
cavernosa	000	Diploë	20
geniculata	513	Dobie's line	29
Malpighiana	754, 760	Dorsi-spinal veins	469
mammaria	499	Douglas, fold of	293
olivaria	491	Duct of Gaertner	792
quadrigemina	514	nasal	621
restiformia	493	Wharton's	707
striata	522	Wirsung, of	752
Corpus callosum	506	Ductus arteriosus	672
cavernosum	772	Bartholini	708
dentatum	495, 518	communis choledochus	749
fimbriatum	509, 511	cysticus	751
geniculatum	513	ejaculatorius	783
Highmorianum	780	galactophorus	799
lutenm	794	hepaticus	749
spungiosum	773	lymphaticus dexter	484
striatum	508, 522	pancreaticus	752
Corpuscles of blood	5	prostaticus	769
Pacinian	39	Rivini	708
Corpuscula tactus	67	Stenson's	707
Corti, organ of	649	thoracicus	482
Costal cartilages	135	venosus	673
Costo-coracoid membrane	318	Duodenum	728
Cotunnus, liquor of	646	Dura mater	530, 534
Cotyloid cavity	156		
Cowper's glands	777	Ear	633
Cranial nerves	536	Ejaculatory duct	783
Cranium	121	Elastic tissue	14
Cribriform fascia	345	Elbow, bend of	410
Cricoid cartilage	676	Eminentia collateralis	511
Crico-thyroid membrane	677		

	PAGE	FASCIA— <i>continued.</i>	PAGE
Enamel	714	palmar	317
Enarthrosis	180	parotideo-masseteric	248
Encephalon	491	pelvic	311
End bulbs	41	perineal	303
Endocardium	671	plantar	348
Endolymph	646	popliteal	347
Endomysium	28	recto-vesical	314
Endoneurium	38	spermatic	288
Endothelium	11	supra-hyoidean	254
Engelmann, discs of	29	temporal	244
Ensiform cartilage	132	transversalis	294
Ependyma ventriculorum	524	Fasciculi teretes	520
Epidermis	64	of muscle	28
Epididymis	779	Fauces	705
Epigastric region	697	Femoral arch	346
Epiglottic gland	683	canal	345
Epiglottis	677	hernia	346
Epineurium	38	ring	345
Epiphysis	27	Fenestra ovalis	638
cerebri	515	rotunda	638
Epithelium	7	Fenestrated membrane	15, 45
ciliated	10	Fibres, arciform	492
columnar	8	of heart	670
cylinder	8	Fibrils of muscle	29
glandular	9	Fibrin	6
goblet	9	Fibrin-factors	6
non-stratified	7	Fibrin-ferment	6
scaly	8	Fibrinogen	6
spheroidal	9	Fibrinoplastin	6
squamous	8	Fibro-cartilage	19
stratified	7	interarticular of the	
tesselated	8	clavicle	198
transitional	9	jaw	189
Erectile tissue	773	knee	216
Eruption of teeth	719	wrist	205
Eustachian tube	642	Fibrous tissue	13
valve	661	Filum terminale	488
Eye	621	Fimbriae, Fallopian	791
Eyebrows	616	Fissure calcarine	505
Eyelashes	618	collateral	505
Eyelids	616	dentate	505
Eye-teeth	710	Glaser, of	98
		longitudinal	497
		Rolando, of	501
		Sylvius, of	498, 501
		transverse	507, 511
Falciform border	344	Fissures of the spinal cord	486
Fallopian tubes	791	Fissures of the liver	741
Fallopian, aqueduct of	642	Santorini	634
hiatus of	97	Flocculus	516
Falx cerebelli	531	Flood, ligament of	201
cerebri	530	Fœtal circulation	672
FASCIA :		Folia cacuminis	517
arrangement of	228	Foltz, valve of	620
abdominal	294	Follicles, gastric	726
anal	315	of Lieberkühn	732
axillary	315	Fontana, spaces of	624
brachial	315	Foramen, Botal, of	672
cervical	248	cœcum	93, 491, 654
Colles, of	303	communis antcrius	509
cribriform	345	Magendie, of	520
dentata	511	Munro, of	509, 514
dorsal of hand	316	obturator	157
iliac	344	ovale	157, 662, 672
infundibuliform	295	Soemmering, of	628
intercolumnar	288	thyroid	157
lata	343	Vesalius, of	103
lumbar	291		
obturator	313		

	PAGE		PAGE
Foramen, Winslow, of	700	Gastro-phrenic ligament	702
Foramina, Scarpa, of	111	Gastro-splenic omentum	702
Stenson, of	111	Genu corporis callosi	507
Thebesii	661	Germinal eminence	794
Fornix	512	spot	794
Fossa, hyoid	682	vesicle	794
innominata	634	Giant-cells	24, 27
ischio-rectal	303	Gimbernat's ligament	288
navicularis urethræ	777	Ginglymus	179
pudendi	796	Giraldès, organ of	783
ovalis	662	Gland, epiglottic	683
of Rosenmüller	721	prostate	769
scaphoid	634	thymus	605
Fovea hemielliptica	644	thyroid	685
hemispherica	644	Glands, absorbent	53
Foveæ of fourth ventricle	520	arytenoid	683
Fourchette	796	axillary	476
Fræna epiglottidis	677	Bartholin's	797
Frænulum clitoridis	796	bronchial	480, 602
Frænulum labiæ	703	Brunner's	732
linguæ	652, 704	ceruminous	72, 636
præputii	771	concatenate	475
Frommann's lines	34	Cowper's	000
Funiculus cuneatus	493	duodenal	732
gracilis	493	femoral	477
of Rolando	493	follicular	61
solitarius	496	gastric	726
Gaertner, duct of	792	inguinal	477
Galactophorus ducts	799	lachrymal	620
Gall-bladder	750	lenticular	733
Ganglia, cervical	602	Lieberkühn's	732
lumbar	609	lingual	655, 706
sacral	610	Littre, of	775
semilunar	608	lymphatic	53
structure of	37	mammary	798
thoracic	607	Meibomian	617
Ganglion, Andersch, of	553	mesenteric	481
Arnold's	600	odorifera	771
azygos	611	Pacchionian	454
Bochdalek, of	545	parotid	707
cardiac	606	Peyer's	731
carotid	603	racemose	61
ciliary	597	saccular	61
Cloquet's	599	salivary	707
diaphragmatic	608	sebaceous	70
Gasserian	539	secreting	60
geniculate	548	solitary	733
hypogastric	790	sublingual	708
impar	611	submaxillary	707
jugular	553	sudoriferous	71
lenticular	597	tracheal	685
Meckel's	599	Glands, tubular	61
naso-palatine	600	Tyson, of	771
ophthalmic	597	uterine	790
otic	600	Glandulæ odorifera	771
petrous	553	Pacchioni	454
Ribes, of	602	Tysoni	771
semilunar	608	Glans clitoridis	796
spheno-palatine	599	penis	770
submaxillary	601	Glenoid cavity	138
thyroid	603	Glisson's capsule	746
vertebral	603	Globus major epididymis	782
Wrisberg, of	606	minor epididymis	782
Ganglion cells	37	Glomerulus	760
Gastro-colic omentum	701	Glossary of terms	801
Gastro-hepatic omentum	700	Glottis	682
		Goblet cells	9

	PAGE		PAGE
Goitre	686	Incisura cerebelli	516
Gomphosis	179	Infundibula	764
Graafian vesicles	793	Infundibulum	499
Ground substance	12	Inguinal canal	295
Gubernaculum testis	783	region	697
Gums	703	Inion	528
Gyri, annectant	503	Inosculation	43
frontal	502	Inscriptiones tendinæ	292
operti	503	Interarticular cartilages of the	
temporo-sphenoidal	503	clavicle	198
Gyrus fornicatus	504	jaw	189
		knee	216
Hair	68	wrist	205
Hannover, canal of	633	Intercolumnar fibres	288
Hasner, valve of	621	Intermaxillary bone	110
Hamulus of cochlea	646	Intervertebral substance	183
Harmonia	178	Intestinal canal	727
Haversian canals	21	Intra-cartilaginous ossification	25
lamellæ	21	Intra-membranous ossification	24
systems	21	Intumescencia gangliiformis	548
Heart	659	Intussusception, movement of	3
fœtal	672	Involuntary muscle	31
in relation to chest wall	658	Iris	625
muscle of	31	Island of Reil	503
size of	672	Isthmus of the fauces	705
weight of	672	Iter ad quartum ventriculum	514
Helicine arteries	773	Jacobson, cartilage of	614
Helico-trema	646	nerve of	553, 643
Helix	633	organ of	614
Hemispheres, cerebral	497	Jejunum	729
Hensen, disc of	29	Joint, ankle	220
Hepatic cells	745	elbow	202
duct	748	hip	210
Hernia, congenital	297	lower jaw	188
diaphragmatic	299	knee	213
direct	297	shoulder	201
encysted	297	wrist	205
femoral	346	Karyokinesis	3
infantile	297	Karyostenosis	3
inguinal	296	Kerkring, valves of	730
scrotal	298	Kidneys	758
Hesselbach, triangle of	435	Krause, end bulbs of	41
Hiatus Fallopii	97	membrane of	29
Hilton's law	177	Labia majora	796
Hilum lienis	753	minora	796
renale	758	Labyrinth	643, 646
Hippocampus major	510	Lachrymal canaliculi	620
minor	510	gland	620
Histology	1	papillæ	617, 620
Horner's muscle	232	puncta	617, 620
Hugnier, canal of	98, 637	sac	621
Humours of the eye	631	Lacteals	482
Hunter's canal	436	Lacunæ of bone	22
Huschke, valve of	620	Lacus lachrymalis	616
Hyaloid membrane	631	Lambda	528
Hyaloplasm	2	Lamellæ of bone	22
Hydatids of Morgagni	780	Laminated tubercle	517
Hymen	797	Lamina cinerea	498
Hypochondriac regions	697	cribrosa	622
Hypogastric region	697	fnsca	622
Hypophysis cerebri	499	spiralis	645
		Laryngotomy	678
Ileo-cæcal valve	739	Larynx	675
Ileo-colic valve	739	Lateral ventricles	508
Ileum	729	Lens	632
Iliac regions	697		
Incus	639		

	PAGE	LIGAMENTS— <i>continued.</i>	PAGE
Lenticular ganglion	597	carpal	207
Levers	323, 367	peroneo-tibial	219
Lieberkühn's follicles	732	radio-ulnar	204
Ligament	176	interspinous	184
LIGAMENTS	175	inter-transverse	184
accessory	192	intervertebral	183
aeromio-clavicular	199	jaw, of the	182
alar	217	knee, of the	213
ankle, of the	220	larynx, of the	677
annular, ankle, of the	347	lateral, of the ankle	220
radius	204	elbow	203
wrist, anterior	207, 316	jaw	188
posterior	207, 316	knee	214
areuatum externum	301	phalanges, foot	226
internum	300	hand	210
astragalo-calcaneal	222	wrist	206
scaphoid	222	liver, of the	698, 740
atlanto-axial	187	longum plantæ	223
bladder, of the	766	malleus, of	640
breve plantæ	223	metacarpal	209
calcaneo-euboid	223	metatarsal	225
scaphoid	222	mucosum	216
capsular, hip, of the	211	nuchæ	271
jaw	189	oblique	204
rib	191	obturator	197
shoulder	201	occipito-atlantal	185
thumb	209	axial	186
carpal	207	odontoid	186
carpo-metacarpal	208	orbicular	204
chondro-sternal	192	palpebral	617
xyphoid	192	patellæ	213
common, anterior	182	phalanges of the foot	226
posterior	182	hand	210
conoid	200	plantar, long	223
coracoid	200	short	223
coraeo-aeromial	200	posticum Winslowii	213
clavicular	199	Poupart's	288
humeral	201	pterygo-maxillary	245
coronary	204	pubic	196
of the knee	215	radio-ulnar	205
corroseantia	192	rhomboïd	198
costo-clavicular	198	round of uterus	795
coracoid	318	liver	741
transverse	191	sacro-coecygean	196
vertebral	190	sacro-iliae	194
cotyloid	212	sacro-ischiatic	195
cranio-pharyngeal	259	sacro-lumbar	193
crico-thyroid	677	sacro-vertebral	193
crucial	215	spheno-maxillary	188
cruciform	187, 347	stellate	190
deltoid	220	sternal	193
dentatum	535	sterno-clavicular	197
elbow, of the	202	sterno-xyphoid	193
Gimbernat's	288	stylo-maxillary	190, 249
glenoid	201	sub-flava	183
gleno-humeral	201	sub-pubic	197
glosso-epiglottic	679	supra-scapular	200
hip-joint, of the	210	supra-spinous	184
hyo-epiglottic	679	suspensorium dentis	180
ilio-femoral	211	hepatis	741
ilio-lumbar	193	penis	771
inens, of	640	tarsal	222
interarticular of ribs	191	tarsometatarsal	225
inter-clavicular	198	teres	211
interosseular	315	thyro-arytenoid	678
interosseous		thyro-epiglottic	679
astragalo-calcaneal	223	thyro-hyoid	677

LIGAMENTS— <i>continued</i>	PAGE	LYMPHATICS— <i>continued.</i>	PAGE
tibio-fibular	219	intestines	481
transverse		kidneys	482, 764
of the acetabulum	212	lacteals	51, 482
ankle	219	liver	481
atlas	187	lower extremity	477
knee	215	lungs	692
metacarpus	209	mammary	479, 800
metatarsus	225	mediastinal	479
scapula	200	mesenteric	481
semilunar cartilages	216	pancreas	481
trapezoid	200	pelvic viscera	482
triangular	304	popliteal	478
tympanum, of the	640	spleen	481, 755
uterus, of the	795	stomach	481
vertebral	182	testicle	482
wrist, of the	205	thymic	696
Zinn, of	234	trunk	479
Ligamentum denticulatum	535	upper extremity	476
nuchæ	271	uterus, of the	482, 790
pectinatum	623	viscera	480
Ligula	520	Lymphoid tissue	16
Liugula	517	Lyra	513
Limbus luteus	628	Macula acustica	647
Linea alba	287	cribrosa	644
Lineæ semilunares	287	lutea	628
transversæ	287, 507	Magendic, foramen of	520
Lips	703	Malleus	638
Liquor Cotinnii	646	Malpighian corpuscles	762
sanguinis	4	glomeruli	760
Littre, glands of	775	pyramids	759
Liver	740	Mammæ	798
Lobule of ear	634	Mammary gland	798
pneumo-gastric	516	Marrow of bones	23
Lobules of the liver	744	Mastoid cells	641
testicle	781	Matrix	68
Lobus caudatus	743	Maxillo-pharyngeal space	261
quadratus	743	Meatus auditorius	96, 641, 651
Spigelii	743	urinarius, female	797
Lobe, central	503	male	771
cuneus	505	Meatuses of the nose	130
frontal	502	Meckel's ganglion	599
occipital	503	Median disc of Hensen	29
parietal	502	Mediastinum	693
quadrate	505	testis	780
temporal	503	Medulla, course of fibres in	526
temporo-sphenoidal	503	of bones	23
Lobes of brain	501	oblongata	491
cerebellum	516	Medullary sheath	33
Locus niger	524	Medullary velum, anterior	520
perforatus	498, 499	posterior	517
Lumbar fascia	291	Meibomian glands	617
regions	697	Meissner, plexus of	735
Lungs	686	Membrana basilaris	649
Lunula	68	eboris	717
Lymph	6	flaccida	638
Lymph corpuscles	7	fusca	622
Lymph sinus	54	interosseous	204, 219
Lymphatic glands and vessels	51, 53	nictitans	620
axillary	476	pupilaris	626
bronchial	480, 692	sacciformis	208
cardiac	480	tectoria	649
cervical	474	tympani	638
concatenate	475	Membrane, Bruch, of	624
head and neck	474	choroid	624
heart	480	Corti, of	649
iliac	480	costo-coracoid	318
inguinal	477		

	PAGE	MUSCLES— <i>continued.</i>	PAGE
Membrane, Demour, of ; Descemet,		adductor hallucis	375
of	623	pollicis	339
hyaloid	631	anconeus	335
Jacob's	629	anomalous	239
Nasmyth's	714	anti-tragicus	635
Reissner, of	649	arytenoides	679
Schneiderian	614	aryteno-epiglottideus	680
Shrapnell, of	638	attollens auriculam	233
ventricles, of the	524	attrahens auriculam	233
Membranous labyriuth	646	auricularis	334
urethra	777	azygos uvulae	264
Mesenteric glands	481	back, of the	269
Mesentery	701	basio-glossus	257
Meso-colou	701	biceps flexor cruris	361
Meso-rectum	701	cubiti	325
Mesosternum	132	biventer cervicis	277
Metacarpus	151	brachialis anticus	325
Metasternum	132	buccinator	245
Metatarsus	172	bulbo-cavernosus	305
Milk, secretion of	799	cerato-glossus	257
Mitosis	3	cervicalis ascendens	275
Mitral valve	667	descendens	275
Modiolus	645	chondro-glossus	257
Moll, glands of	618	ciliary of eye-ball	627
Monro, foramen of	509, 514	orbicularis palpebrarum	231
Mons Veneris	795	Riolan, of	231, 617
Morgani, sinus of	261	circular, of Müller	627
Morsus diaboli	791	circumflexus palati	264
Motorial end plates	41	cleido-occipital	249
Mouth	703	cleido-mastoid	249
Movements of ankle-joint	221	coccygeus	306, 310
atlas	188	complexus	276
axis	188	compressor nasi	239
clavicle	198	urethrae	306, 310
elbow-joint	204	vesiculae seminalis	771
hip-joint	212	constrictor isthmi faucium	264
joints	180	of pharynx, inferior	260
knee-joint	217	middle	260
lower jaw	190	superior	261
occipital bone	188	coraco-brachialis	324
phalanges of hand	210	corrugator supercilii	232
radius and ulna	205	cremaster	289
ribs	192	crico-arytenoides lateralis	679
scapula	200	posticus	679
shoulder-joint	202	crico-thyroid	679
spine	184	crureus	356
wrist-joint	208	cucullaris	269
Mucous membrane, structure	59	deltoid	323
tissuc	15	depressor alae nasi	239
Multipolar cells	35	anguli oris	242
MUSCLES :		labii inferioris	242
arrangement of	227	detrusor urinae	766
non-striated	31	diaphragm	299
striated	28	digastricus	254
structure of	28	dilatator naris	239
abdomen, of the	284	tubae	642
abductor indicis	342	erector clitoridis	309
minimi digiti	339, 373	penis	305
hallucis	372	spinæ	275
pollicis	338	erectores pili	70
accelerator urinae	305	extensor carpi radialis	333
accessorii	240	ulnaris	335
accessorius	275, 374	coccygis	279
adductor brevis	360	digiti minimi	334
longus	359	digitorum brevis	371
maguus	360	digitorum communis	334
minimi digiti	342	digitorum longus	364

MUSCLES— <i>continued.</i>	PAGE	MUSCLES— <i>continued.</i>	PAGE
extensor indicis	337	obliquus abdominis	288, 289
ossis metacarpi pollicis	330	auris	635
pollicis internodii	336	capitis	278
hallucis proprius	365	oculi	235
face, of the	229	obturator	350, 351
flexor accessorius	374	occipito-frontalis	229
brevis digiti minimi	340, 375	omo-hyoid	253
carpi radialis	328	opponens digiti minimi	340
ulnaris	330	pollicis	338
digitorum brevis	373	orbicularis oris	240
profundus	330	palpebrarum	231
sublimis	329	palato-glossus	258, 264
longus digitorum pedis	368	palato-pharyngens	262, 264
longus pollicis	331	palmaris brevis	339
ossis metacarpi min. dig.	340	longus	328
metacarpi pollicis	338	patientia	272
pollicis brevis	338	pectineus	359
hallucis longus	368	pectoralis major	317
gastrocnemius	366	minor	318
gemellus	350, 351	perineum, of the	302
genio-hyo-glossus	256	peroneus brevis	370
genio-hyoid	255	longus	370
gluteus maximus	349	tertius	364
medius	349	plantaris	366
minimus	350	platysma myoides	247
gracilis	360	popliteus	367
helicis major	635	pronator quadratus	332
minor	635	radii teres	327
head, of the	229	psoas magnus	358
Horner's	232	parvus	298
hyo-epiglottideus	680	pterygoideus	245
hyo-glossus	256	pyramidalis abdominis	292
iliacus interuus	357	nasi	238
ilio-costalis	275	pyriformis	350
indicator	337	quadratus femoris	352
infra-spinatus	321	lumborum	298
intercostals	281	lumbi	242
interossei	341, 371, 376	quadriceps extensor	357
interspinales	279	rectus abdominis	292
intertransversales	279	capitis anticus	266
ischio-cavernosus	305	lateralis	278
larynx, of the	679	posticus	277
latissimus dorsi	271	femoris	354
levator alæ nasi	239	oculi externus	235
anguli oris	241	inferior	234
scapulæ	272	internus	235
ani	308, 310	superior	234
glandulæ thyroideæ	686	retrahens auriculam	233
labii inferioris	243	rhomboideus major et minor	272
superioris	241	risorius Santorini	242
menti	243	rotatores spinæ	279
palati	263	sacro-coccygeus posticus	279
palpebræ superioris	234	lumbalis	275
prostatii	308	salpingo-pharyngeus	262
levatores costarum	283	sartorius	353
lingualis	257	scalenus anticus	267
longissimus dorsi	275	medius	267
longus colli	268	posticus	268
lower extremity	343	semi-spinalis dorsi et colli	277
lumbricales	341, 374	semi-membranosus	362
masseter	243	semi-tendinosus	361
motor uvulæ	264	serratus magnus	319
multifidus spiniæ	279	posticus	273
mylo-hyoid	254	soleus	367
naso-labialis	240	sphincter ani	307, 310
neck, of the	247	vaginæ	309
nutator capitis	250	vesicæ	767

MUSCLES— <i>continued.</i>	PAGE		PAGE
spinalis dorsi	275	Nasion	528
splenius	274	Nasmyth, membrane of	714
stapedius	641	Nates cerebri	514
sterno-hyoid	252	Nerve endings, motor	41
mastoid	249	sensory	39
occipital	249	Nerve cells	35
thyroid	252	fibres	33
stylo-glossus	258	terminations	39
hyoid	254	NERVES :	
pharyngeus	262	general anatomy	32, 38
subanconeus	327	abducentes	547
subclavius	319	accessorius	559
subcostals	282	acromial	565
sub-crurens	357	Arnold's	556
subscapularis	320	auditory	551, 651
supinator brevis	335	auricularis inferior	546
longus	333	magnus	566
supra-spinatus	320	posterior	549
temporal	244	superior	546
tensor palati	264	vagi	556
tarsi	232	auriculo-temporal	546
tympani	641	brachial	568
vaginae femoris	353	buccal	545, 551
teres major	321	cardiac	558, 604, 672
minor	321	carotid	555
thorax, of the	281	cervical	564
thyro-arytenoideus	680	cervico-facial	551
thyro-epiglottoides	680	chorda tympani	549, 643
hyoid	253	ciliary	543, 626
tibialis anticus	363	circumflex	577
posticus	369	clavicular	566
trachelo-mastoid	276	coceygeal	589
tragicus	635	cochlear	551, 652
transversalis abdominis	291	communicans cervicis	566
cervicis	276	peronei	596
transversus auriculæ	635	poplitei	593
pedis	375	tibialis	593
perinei	306, 309	cranial	536
trapezius	269	crural	585
triangularis oris	242	cutaneus externus, brachialis	571
sterni	282	femoris	596
triceps brachii	326	internus, brachialis	572
extensor femoris	357	femoris	585
cubiti	326	medius, femoris	585
trochlearis	235	lateralis	579
upper extremity, of the	315	patellæ	587
ureters, of the	729	spiralis	576
vastus externus	355	dental	544, 546
internus	355	descendens cervicis	561
Wilson's	307	digastric	550
zygomatic	241	dorsal	578
Muscle	27	dorsalis penis	591
striated	28	eighth pair	551
non-striated	31	eleventh pair	559
of heart	31	facial	548
rods	29	fifth pair	539
Musculi papillares	665, 667	first pair	536
pectinati	663, 666	fourth pair	539
Myeloplaxes	24	frontal	540
Myolemma	28	gastric	727
Myology	227	genito-crural	583
Naboth, ovula of	790	glosso-pharyngeal	553, 656
Nails	68	gluteal	590
Nares	130	inferior	590
Nasal duct	621	gustatory	547, 655
fosse	129, 613	hemorrhoidal	591
		hypoglossal	560, 656

	PAGE		PAGE
Nucleus, fastigii	518	Penis	771
globosus	518	Perforating fibres of bone	21
lenticularis	523	Pericardium	658, 671
of cells	3	Perichondrium	19
olivary	495	Perilymph	646
teniaformis	523	Perimysium	28
Nymphæ	796	Perineurium	38
Obex	520	Perincum, muscles of	302, 308
Obturator foramen	157	Periosteum	21
Odontoblasts	718	Peritonæum	697
Œsophagus	722	Perspiratory ducts	72
Olivary body	491	Pes accessorius	511
fasciculus	492	anserinus	548
nucleus	494	hippocampi	511
Omentum, gastro-colic	701	Petit, canal of	633
gastro-hepatic	700	Peyer's glands	734
gastro-splenic	702	Phalanges	153
great	701	Pharynx	720
lesser	700	Pia mater	533, 535
Operculum	501, 503	Pigment	16
Optic commissure	538	Pillars of the abdominal ring	288
thalami	508, 513	diaphragm	292
Ora serrata	627	palate	705
Orbicular, os	640	Pineal body	515
Orbits	127	Pinna	633
Organ of Corti	649	Pituitary body	499
Giraldès	783	membrane	614
Rosenmüller	792	Plasma	6
Os tincæ	788	Pleura	693
Ossicula auditus	638	Plexus, Auerbach, of	735
Ossification	24	general anatomy	39
Osteoblasts	21, 24	aortic	600
Osteoclasts	27	axillary	568
Osteodentine	715	brachial	568
Osteology	73	cardiac	604
Ostium abdominale	791	carotid	602
uterinum	791	cavernous	602
Otoconia	647	cervical	565
Otoliths	647	choroid	508
Ovaries	792	coronary	606
Oviducts	791	diaphragmatic	608
Ovisacs	793	epigastric	608
Ovula of Naboth	790	gastric	608
Ovum	794	gulae	558
Pacchionian bodies	454, 530	hæmorrhoidal	610
Pacinian corpuscles	39	hepatic	608
Palate	703	hypogastric	609
Palmar arch	416	lumbar	581
Palpebræ	616	maxillary	544, 546
Palpebral ligament	617	Meissner, of	735
Pancreas	751	mesenteric	609
Papillæ of the nail	68	myenteric	735
skin	64	œsophageal	558
tongue	654	patellar	587
calyciformes	654	pharyngeal	555, 557
circumvallatæ	654	phrenic	608
filiform	654	prostatic	466, 610
fungiform	655	pterygoid	451
Paraglobulin	6	pulmonary	558
Parepididymis	783	renal	608
Par ovarium	792	sacral	589
Parotid gland	707	solar	608
Pedunculi cerebri	499	spermatic	609
Pelvis	158, 765	splenic	608
viscera of	765	supra-renal	608, 757
		tonsillitic	555
		tympanic	553, 643

	PAGE		PAGE
Plexus, uterine	466, 610	Ring, internal abdominal	295
vaginal	610	Rivinian ducts	708
vertebral	604	recess	636
vesical	466, 610, 768	Rods of Corti	649
Plicæ palmatæ	790	retina	629
Pneumo-gastric lobule	516	Rolando, fissure of	501, 529
Pomum Adami	675	funiculus of	493
Pons Tarini	499	tubercle of	493
Varolii	496	Roots of spinal nerves	490
Pores	67	Rosenmüller, accessory gland of	620
Portal vein	473, 746	organ of	792
Portio dura	548	fossa of	721
mollis	548	Rugæ	725
Porus opticus	622	Ruysch, tunic of	624
Poupart's ligament	288		
Prepuce	772	Sacculus communis	647
Presternum	132	laryngis	683
Prickle cells	8	proprius	647
Processus e cerebello ad testes	520	Salivary glands	707
vermiformis	517	Saphenous opening	344
Promontory	638	Saphena veins	463
Prostate gland	769	Sarcolemma	28
Prostatic urethra	776	Sarcous elements	29
Protoplasm	1	Scala tympani	646
Primitive sheath	33	vestibuli	646
Pseudo-podia	2	Scarf-skin	64
Pseudo-stomata	57	Scarpa, space of	354
Pulmonary artery	449, 665	Schindylæsis	179
plexuses	558, 692	Schneiderian membrane	614
sinuses	665	Schwann, white matter of	33
veins	473, 666	Sclerotic coat	621
Pulvinar	513	Scrotum	778
Puncta lachrymalia	617, 620	Sebaceous glands	70
vasculosa	506	Semicircular canals	644
Pupil	625	Semilunar fibro-cartilages	216
Purkinje, cells of	518	valves	665, 668
Pylorus	723	Sense, organs of	611
Pyramid	517, 638	Septum crurale	346
Pyramids, anterior	491	lucidum	511
decussation of	491	interventricular	668
Malpighi, of	759	pectiniforme	772
posterior	493	posticum	535
		scroti	778
Quadrante lobe	505, 707	Serous membrane, structure	56
		Serum	6
Ranvier, nodes of	34	Sesamoid bones	174
Raphé corporis callosi	507	Sheath of arteries	47
Receptaculum chyli	482	rectus	293
Rectum	737	Shrapnell, membrane of	638
Red corpuscles	5	Sigmoid valves	665, 668
Regions, abdominal	697	Sinus pocularis	776
Reil, island of	503	venosus	660
fissures of	503	Sinuses, structure	51
Reissner, membrane of	649	aortic	377, 668
Remak, fibres of	34	basilar	455
Respiratory muscles	283	cavernous	456
Restiform bodies	492	circular	455
Reticular tissue	16	coronary	471
Rete mucosum	65	lateral	456
testis	781	longitudinal, inferior	455
Retina	627	superior	454
Ribes, ganglion of	602	occipital	455
Ribs	133	petrosal, inferior	457
Rima glottidis	682	superior	457
Ring, external abdominal	288	pulmonary	665
femoral	345	spheno-parietal	458

	PAGE		PAGE
Sinuses, straight	455	Temporal fossa	122
transverse	455	Tendo-Achillis	366
uterine	790	oculi	231
Valsalva, of	377, 665, 668	Tendon	14
Skein	3	Tenon, capsule of	236, 615, 621
Skeleton	73	Tenia hippocampi	511
Skene, tubules of	786	semicircularis	508
Skin	63	Tentorium cerebelli	531
Skull	87	Tessclated epithelium	8
Socia parotidis	707	Testes cerebri	514
Soft palate	705	Testicles	778
Spaces of Fontana	624	descent	784
Spermatic canal	295	Thalami optiei	508, 513
cord	778	Thebesian valve	662
Spheno-maxillary fossa	128	Thecæ	329
Spheno-palatine ganglion	599	Thoracic duct	482
Spheroidal epithelium	9	Thorax	136, 657
Spigelius, lobule of	743	Thymus body	695
Spinal cord	485	Thyro-hyoid membrane	677
nerves	490, 562	Thyroid axis	403
veins	469	cartilage	675
Spleen	753	foramen	157
Splenium corporis callosi	507	body	685
Spongio-plasm	2	Tissue, yellow fibrous	14
Spongy part of the urethra	777	elastic	14
Squamous epithelium	8	Tongue	652, 704
Stapes	640	Tonsils	705
Stenson's duct	707	of cerebellum	516
Stephanion	528	Torcular Herophili	455
Stilling, canal of	631	Trachea	684
Stomach	723	Tractus opticus	537
Stomata	11	spiralis	651
Stratum Malpighi	65	Tragus	634
Stria terminalis	508	Transitional epithelium	9
Striæ acusticæ	520	Triangle of Hesselbach	435
longitudinales	507	Triangles of the neck	251
muscular	28	Triangular ligament	304
Sub-arachnoid fluid	533, 535	Tricuspid valve	663
space	533, 535	Trigonum vesicæ	767
Sublingual gland	708	habenulæ	514
Submaxillary gland	707	Trochanter major et minor	160, 161
Substantia cinerea	488	Trochoides	180
perforata	498	Trochlea	142
Sudoriferous ducts	72	Trochlearis	235
glands	71	Tuber cinereum	499
Sulci of the brain	501	Tuberculum acusticum	520
Supercilia	616	Tuber valla	517
Superficial fascia	228	Tubercle of Lower	663
Supra-renal bodies	756	Tubuli seminiferi	781
Suspensory ligament, liver	741	uriniferi	760
penis	775	Tulpius, valve of	739
Sutures	120	Tunica albuginea oculi	235
Sylvius, aqueduct of	514	testis	780
fissure of	501	erythroides	779
Sympathetic ganglia	37	Ruyshiana	624
nerve	41	vaginalis	780
system	41, 597	oculi	236, 615, 621
Symphysis	179	vasculosa testis	781
Synarthrosis	175, 178	Tutamina oculi	616
Synovial membranes	57	Tympanic bone	99
Tactile corpuscles	67	Tympanum	637
Tapetum	629	Tyson's glands	771
Tarsal plates	617	Umbo	638
Tarsus	167	Umbilical region	697
Tecth	709	Urachus	766
Tela choroidea	513	Ureter	764

	PAGE
Urethra, female	785
male	774
Uterus	787
Utricle	647
Uvea	625
Uvula cerebelli	517
palati	705
vesicæ	767
Vagina	786
Vallecula	516
Valsalva, sinuses of	377, 665, 668
Valve, Bauhin, of	739
coronary	662
Eustachian	661
Foltz, of	620
Hasner, of	621
Huschke, of	620
ileo-cæcal	739
mitral	667
pyloric	726
rectum, of the	739
semi-lunar	665, 668
tricuspid	663
Tulpius	739
Vieussens, of	520
Valves of Kerkring	730
veins	50
Valvulæ conniventes	730
Vasa afferentia	53, 763
efferentia	53, 763, 781
pampiniformia	778
recta	781
vasorum	47
vorticosa	624
Vasculum aberrans	783
Vas deferens	783
Vater, corpuscles of	39
VEINS :	49
structure	50
angular	450
auricular	451
axillary	461
azygos	468
basilar	453
basilic	460
basis vertebrarum	470
brachio-cephalic	464
bronchial	469
cardiac	470
cava, inferior	464
superior	463
cephalic	460
cerebellar	454
cerebral	453
comites	49, 460, 462
coronary	471
corporis striati	453, 508
diploë	452
dorsal of penis	466
dorsi-spinal	469
emissary	452
emulgent	467
facial	450
femoral	462
frontal	450
Galenii	453, 513

VEINS—continued.	PAGE
gastric	472
hæmorrhoidal	466
hepatic	467, 748
iliac	466
innominate	464
intercostal	468
jugular	458
lumbar	467
mammary	464
mastoid	452
maxillary internal	451
median	461
basilic	461
cephalic	461
medulli-spinal	470
meningo-rachidian	469
mesenteric	471
occipital	451
ophthalmic	458
ovarian	467
parietal	454
phrenic	467
popliteal	462
portal	473, 746
profunda femoris	462
prostatic	466
pulmonary	473
radial	460
renal	467, 763
salvatella	460
saphena	463
spermatic	467
spinal	469
splenic	472
subclavian	461
supra-renal	467
temporal	451
temporo-maxillary	451
Thebesii	471
thymic	696
thyroid	459
ulnar	460
umbilical	673
uterine	466
vena cava	463
vertebral	459, 469
vesical	466, 768
Velum interpositum	513
medullare	517
pendulum palati	705
Venæ comites	49, 460, 462
Galenii	453, 513
Thebesii	471
vorticose	624
Ventricles of the brain—fifth	511
fourth	519
lateral	508
third	514
corpus callosum	506
heart	663, 666
larynx	683
Vermiform process	735
Vermis of cerebellum	517
Vertebra, characters of	75
Vertebral column	74
Veru montanum	776
Vesiculæ seminales	770

	PAGE		PAGE
Vestibule	644	Wormian bones	120
Vestibulum vaginae	797	Wrisberg, nerve of	572
Vibrissæ	611	Xiphoid process	132
Vieussens, valve of	520	Y-shaped ligament	211
Villi	732	Yellow fibrous tissue	14
Vinula accessoria	329	spot	630
Vitreous humor	631	Zona fasciculata	756
Voluntary muscle	28	glomerulosa	756
Vulva	796	pellucida	794
Wander cells	2	reticularis	756
Wharton's duct	704	Zonula ciliaris	632
White corpuscles	5	of Zinn	632
Willis, circle of	402	Zygoma	95
Wilson's muscles	307	Zygomatic fossa	122
Winslow, foramen of	700		
Wirsung, duct of	752		
Worm of cerebellum	516		



THE END.

J. & A. CHURCHILL'S
MEDICAL CLASS BOOKS.

ANATOMY.

BRAUNE.—An Atlas of Topographical Anatomy, after Plane Sections of Frozen Bodies. By WILHELM BRAUNE, Professor of Anatomy in the University of Leipzig. Translated by EDWARD BELLAMY, F.R.C.S., late Surgeon to Charing Cross Hospital, and Lecturer on Surgery in its School. With 34 Photo-lithographic Plates and 46 Woodcuts. Large Imp. 8vo, 40s.

FLOWER.—Diagrams of the Nerves of the Human Body, exhibiting their Origin, Divisions and Connexions, with their Distribution to the various Regions of the Cutaneous Surface, and to all the Muscles. By WILLIAM H. FLOWER, K.C.B., F.R.C.S., F.R.S. Third Edition, containing 6 Plates. Royal 4to, 12s.

GODLEE.—An Atlas of Human Anatomy: illustrating most of the ordinary Dissections and many not usually practised by the Student. By RICKMAN J. GODLEE, M.S., F.R.C.S., Surgeon to University College Hospital; Teacher of Operative Surgery, and Assistant Professor of Clinical Surgery in University College; With 48 Imp. 4to Coloured Plates, containing 112 Figures, and a Volume of Explanatory Text, with many Engravings. 8vo, £4 14s. 6d.

HEATH.—Practical Anatomy: a Manual of Dissections. By CHRISTOPHER HEATH, F.R.C.S., Holme Professor of Clinical Surgery in University College and Surgeon to the Hospital. Seventh Edition, revised by RICKMAN J. GODLEE, M.S. Lond., F.R.C.S., Teacher of Operative Surgery, and Assistant Professor of Clinical Surgery in University College, and Surgeon to the Hospital. With 24 Coloured Plates and 278 Engravings. Crown 8vo, 15s.

ANATOMY—*continued.*

HOLDEN.—**A Manual of the Dissection of the Human Body.** By LUTHER HOLDEN, F.R.C.S. Fifth Edition, by JOHN LANGTON, F.R.C.S. and Member of the Court of Examiners; Surgeon to St. Bartholomew's Hospital. With 208 Engravings. 8vo, 20s.

By the same Author.

Human Osteology: comprising a Description of the Bones, with Delinuations of the Attachments of the Muscles, the General and Microscopical Structure of Bone and its Development. Seventh Edition, by CHARLES STEWART, Conservator of the Museum, R.C.S., and R. W. REID, M.D., Professor of Anatomy in the University of Aberdeen. With 59 Plates and 75 Wood Engravings. Royal 8vo, 16s.

ALSO,

Landmarks, Medical and Surgical. Fourth Edition. 8vo, 3s. 6d.

MORRIS.—**The Anatomy of the Joints of Man.**

By HENRY MORRIS, M.A., F.R.C.S., Surgeon to, and Lecturer on Anatomy and Practical Surgery at, the Middlesex Hospital. With 44 Plates (19 Coloured) and Engravings. 8vo, 16s.

TOOTH.—**An Atlas of the Central Nervous**

System and Cranial Nerves, from the larger work of HIRSCHFELD and LÉVEILLÉ. Edited by HOWARD H. TOOTH, M.D., F.R.C.P., Assistant Physician to the National Hospital for the Paralysed and Epileptic. 37 Coloured Plates. Imp. 8vo, 40s.

WAGSTAFFE.—**The Student's Guide to Human**

Osteology. By WM. WARWICK WAGSTAFFE, F.R.C.S., late Assistant-Surgeon to, and Lecturer on Anatomy at, St. Thomas's Hospital. With 23 Plates and 66 Engravings. Fcap. 8vo, 10s. 6d.

WILSON AND CLARK.—**Wilson's Anatomist's**

Vade-Mecum: a System of Human Anatomy. Eleventh Edition, by HENRY E. CLARK, M.R.C.S. Eng., F.F.P.S. Glasgow, Professor of Anatomy in St. Mungo's College, Glasgow. With 492 Engravings and 26 Coloured Plates. Crown 8vo, 18s.

11, NEW BURLINGTON STREET

BOTANY.

BENTLEY AND TRIMEN.—**Medicinal Plants:** being descriptions, with original Figures, of the Principal Plants employed in Medicine, and an account of their Properties and Uses. By ROBERT BENTLEY, F.L.S., and HENRY TRIMEN, M.B., F.R.S., F.L.S. In 4 Vols., large 8vo, with 306 Coloured Plates, bound in half morocco, gilt edges, £11 11s.

BENTLEY.—**A Manual of Botany.** By Robert BENTLEY, Emeritus Professor of Botany in King's College and to the Pharmaceutical Society. With 1178 Engravings. Fifth Edition. Crown 8vo, 15s.

By the same Author.

Structural, Morphological, and Physiological Botany. With 660 Engravings. Fcap. 8vo, 7s. 6d.

ALSO,

Systematic Botany, including the Classification of Plants and Descriptive Botany. With 357 Engravings. Fcap. 8vo, 3s. 6d.

SHORE.—**Elementary Practical Biology. Vegetable.** By THOMAS W. SHORE, M.D., B.Sc. Lond., Lecturer on Comparative Anatomy at St. Bartholomew's Hospital. 8vo, 6s.

CHEMISTRY.

BERNAYS.—**Notes on Analytical Chemistry for Students in Medicine.** By ALBERT J. BERNAYS, Ph.D., F.C.S., F.I.C., late Professor of Chemistry, &c., at St. Thomas's Hospital Medical School. Third Edition. Crown 8vo, 4s. 6d.

BLOXAM.—**Chemistry, Inorganic and Organic; with Experiments.** By CHARLES L. BLOXAM. Seventh Edition, by JOHN MILLAR THOMSON, Professor of Chemistry, King's College, London, and ARTHUR G. BLOXAM, Demonstrator of Chemistry, Royal Agricultural College, Cirencester. With 282 Illustrations. 8vo, 18s.

By the same Author.

Laboratory Teaching; or, Progressive Exercises in Practical Chemistry. Fifth Edition. With 89 Engravings. Crown 8vo, 5s. 6d.

BOWMAN AND BLOXAM.—**Practical Chemistry, including Analysis.** By JOHN E. BOWMAN, and CHARLES L. BLOXAM late Professor of Chemistry in King's College. Eighth Edition. With 90 Engravings. Fcap. 8vo, 5s. 6d.

CHEMISTRY—*continued.*

CLOWES.—**Practical Chemistry and Qualitative Analysis.** Adapted for use in the Laboratories of Colleges and Schools. By FRANK CLOWES, D.Sc. Lond., Professor of Chemistry in the University College, Nottingham. Fifth Edition. With 57 Engravings and Frontispiece. Post 8vo, 7s. 6d.

CLOWES AND COLEMAN.—**Quantitative Chemical Analysis.** Adapted for use in the Laboratories of Colleges and Schools. By FRANK CLOWES, D.Sc. Lond., Professor of Chemistry in the University College, Nottingham, and J. BERNARD COLEMAN, Assoc. R.C.Sci. Dublin, Senior Demonstrator of Chemistry in the University College, Nottingham. With 83 Engravings. Post 8vo, 7s. 6d.

FOWNES.—**Manual of Chemistry.**—*See WATTS.*

FRANKLAND AND JAPP.—**Inorganic Chemistry.**
By EDWARD FRANKLAND, Ph.D., D.C.L., F.R.S., and F. R. JAPP, M.A., Ph.D., F.R.S., Professor of Chemistry in the University of Aberdeen. With Lithographic Plates and Wood Engravings. 8vo, 24s.

MORLEY.—**Outlines of Organic Chemistry.** By H. FORSTER MORLEY, M.A., D.Sc., Joint Editor of "Watts' Dictionary of Chemistry." Crown 8vo, 7s. 6d.

RAMSAY.—**Elementary Systematic Chemistry.**
For Use of Schools and Colleges. By WILLIAM RAMSAY, Ph.D., F.R.S., Professor of Chemistry in University College, London. With Engravings, 4s. 6d. (or Interleaved, 5s. 6d.).

By the same Author.

A System of Inorganic Chemistry. With Engravings. 8vo, 15s.

VALENTIN.—**Chemical Tables for the Lecture-room and Laboratory.** By WILLIAM G. VALENTIN, F.C.S. In Five large Sheets, 5s. 6d.

VALENTIN AND HODGKINSON.—**A Course of Qualitative Chemical Analysis.** By the late W. G. VALENTIN F.C.S. Seventh Edition, by Dr. W. R. HODGKINSON, F.R.S.E., Professor of Chemistry and Physics in the Royal Artillery College, and Royal Military Academy, Woolwich; assisted by H. CHAPMAN-JONES, F.C.S., Demonstrator in the Royal School of Mines, and F. E. MATTHEWS, Ph.D., of Cooper's Hill College. With Engravings and Map of Spectra. 8vo, 8s. 6d. [The Tables separately, 2s. 6d.]

CHEMISTRY—continued.

WATTS.—Manual of Chemistry, Theoretical and Practical. (Based on Fownes' Manual.) BY HENRY WATTS, B.A., F.R.S.

VOL. I.—Physical and Inorganic Chemistry. Second Edition (Fourteenth of Fownes'). By WILLIAM A. TILDEN, D.Sc., F.R.S., Professor of Chemistry in the Mason College, Birmingham. With 122 Wood Engravings, and Coloured Plate of Spectra. Crown 8vo, 8s. 6d.

VOL. II.—Chemistry of Carbon-Compounds, or Organic Chemistry. Second Edition (Thirteenth of Fownes'). Edited by WM. A. TILDEN, D.Sc., F.R.S. With Engravings. Crown 8vo, 10s.

CHILDREN, DISEASES OF.

DAY.—A Manual of the Diseases of Children. By WILLIAM H. DAY, M.D., Physician to the Samaritan Hospital for Women and Children. Second Edition. Crown 8vo, 12s. 6d.

ELLIS.—A Practical Manual of the Diseases of Children. By EDWARD ELLIS, M.D., late Senior Physician to the Victoria Hospital for Sick Children. With a Formulary. Fifth Edition. Crown 8vo, 10s.

GOODHART.—The Student's Guide to Diseases of Children. By JAMES FREDERIC GOODHART, M.D., F.R.C.P., Physician to Guy's Hospital and Lecturer on Pathology in its Medical School. Fourth Edition. Fcap. 8vo, 10s. 6d.

SMITH.—A Practical Treatise on Disease in Children. By EUSTACE SMITH, M.D., F.R.C.P., Physician to H.M. the King of the Belgians, and to the East London Hospital for Children. Second Edition. 8vo, 22s.

By the same Author.

Clinical Studies of Disease in Children. Second Edition. Post 8vo, 7s. 6d.

Also,

On the Wasting Diseases of Infants and Children. Fifth Edition. Post 8vo, 8s. 6d.

STEINER.—Compendium of Children's Diseases; a Handbook for Practitioners and Students. By JOHANN STEINER, M.D. Translated by LAWSON TAIT, F.R.C.S., Surgeon to the Birmingham Hospital for Women, &c. 8vo, 12s. 6d.

DENTISTRY.

GORGAS. — **Dental Medicine: a Manual of**
Dental Materia Medica and Therapeutics. By FERDINAND J. S. GORGAS,
A.M., M.D., D.D.S., Professor of Dental Surgery and Science, &c., in
the University of Maryland. Third Edition. 8vo, 16s.

HARRIS. — **The Principles and Practice of**
Dentistry; including Anatomy, Physiology, Pathology, Therapeutics,
Dental Surgery, and Mechanism. By CHAPIN A. HARRIS, M.D., D.D.S.
Twelfth Edition, revised and edited by FERDINAND J. S. GORGAS,
A.M., M.D., D.D.S. With over 1,000 Illustrations. 8vo, 33s.

STOCKEN. — **Elements of Dental Materia Medica**
and Therapeutics, with Pharmacopœia. By JAMES STOCKEN, L.D.S.R.C.S.,
late Lecturer on Dental Materia Medica and Therapeutics and Dental
Surgeon to the National Dental Hospital; assisted by THOMAS GADDES,
L.D.S. Eng. and Edin. Third Edition. Fcap. 8vo, 7s. 6d.

TOMES (C. S.). — **Manual of Dental Anatomy,**
Human and Comparative. By CHARLES S. TOMES, M.A., F.R.S.
Third Edition. With 212 Engravings. Crown 8vo, 12s. 6d.

TOMES (J. and C. S.). — **A System of Dental**
Surgery. By Sir JOHN TOMES, F.R.S., and CHARLES S. TOMES, M.A.,
M.R.C.S., F.R.S. Third Edition. With 292 Engravings. Crown
8vo, 15s.

EAR, DISEASES OF.

BURNETT. — **The Ear: its Anatomy, Physio-**
logy, and Diseases. A Practical Treatise for the Use of Medical
Students and Practitioners. By CHARLES H. BURNETT, M.D., Aural
Surgeon to the Presbyterian Hospital, Philadelphia. Second Edition.
With 107 Engravings. 8vo, 18s.

DALBY. — **On Diseases and Injuries of the Ear.**
By SIR WILLIAM B. DALBY, F.R.C.S., Consulting Aural Surgeon to,
and Lecturer on Aural Surgery at, St. George's Hospital. Fourth
Edition. With Woodcuts and Coloured Plates. Crown 8vo.

11, NEW BURLINGTON STREET.

FORENSIC MEDICINE.

ABERCROMBIE.—The Student's Guide to Medical Jurisprudence. By JOHN ABERCROMBIE, M.D., F.R.C.P., Physician to Charing Cross Hospital. Fcap. 8vo, 7s. 6d.

OGSTON.—Lectures on Medical Jurisprudence. By FRANCIS OGSTON, M.D., late Professor of Medical Jurisprudence and Medical Logic in the University of Aberdeen Edited by FRANCIS OGSTON, Jun., M.D. With 12 Plates. 8vo, 18s.

TAYLOR.—The Principles and Practice of Medical Jurisprudence. By ALFRED S. TAYLOR, M.D., F.R.S. Third Edition, revised by THOMAS STEVENSON, M.D., F.R.C.P., Lecturer on Chemistry and Medical Jurisprudence at Guy's Hospital; Examiner in Chemistry at the Royal College of Physicians; Official Analyst to the Home Office. With 188 Engravings. 2 Vols. 8vo, 31s. 6d.

By the same Author.

A Manual of Medical Jurisprudence.
Twelfth Edition, revised by THOMAS STEVENSON, M.D., F.R.C.P.
With 56 Engravings. Crown 8vo, 14s.

ALSO,

On Poisons, in relation to Medical Jurisprudence and Medicine. Third Edition. With 104 Engravings. Crown 8vo, 16s.

TIDY AND WOODMAN.—A Handy-Book of Forensic Medicine and Toxicology. By C. MEYMOTT TIDY, M.B.; and W. BATHURST WOODMAN, M.D., F.R.C.P. With 8 Lithographic Plates and 116 Wood Engravings. 8vo, 31s. 6d.

HYGIENE.

PARKES.—A Manual of Practical Hygiene. By the late EDMUND A. PARKES, M.D., F.R.S. Eighth Edition, by J. LANE NOTTER, M.D., Professor of Military Hygiene in the Army Medical School. With 10 Plates and 103 Wood Engravings. 8vo, 18s.

WILSON.—A Handbook of Hygiene and Sanitary Science. By GEORGE WILSON, M.A., M.D., F.R.S.E., D.P.H. (Camb., Medical Officer of Health for Mid Warwickshire. Seventh Edition. With Engravings. Crown 8vo, 12s. 6d.

MATERIA MEDICA AND THERAPEUTICS.

LESCHER.—Recent *Materia Medica*. Notes on their Origin and Therapeutics. By F. HARWOOD LESCHER, F.C.S., Pereira Medallist. Fourth Edition. 8vo, 2s. 6d.

OWEN.—A *Manual of Materia Medica*; incorporating the Author's "Tables of *Materia Medica*." By ISAMBARD OWEN, M.D., F.R.C.P., Lecturer on *Materia Medica* and Therapeutics to St. George's Hospital. Second Edition. Crown 8vo, 6s. 6d.

ROYLE AND HARLEY.—A *Manual of Materia Medica* and Therapeutics. By J. FORBES ROYLE, M.D., F.R.S., and JOHN HARLEY, M.D., F.R.C.P., Physician to, and Joint Lecturer on Clinical Medicine at, St. Thomas's Hospital. Sixth Edition, including addition and alterations in the B.P. 1885. With 139 Engravings. Crown 8vo, 15s.

SOUTHALL.—The *Organic Materia Medica* of the British Pharmacopœia, Systematically Arranged. By W. SOUTHALL, F.L.S. Fourth Edition. Crown 8vo 5s.

THOROWGOOD.—The *Student's Guide to Materia Medica* and Therapeutics. By JOHN C. THOROWGOOD M.D., F.R.C.P. Second Edition. With Engravings. Fcap. 8vo, 7s.

WARING.—A *Manual of Practical Therapeutics*. By EDWARD J. WARING, C.I.E., M.D., F.R.C.P. Fourth Edition, revised by the Author and DUDLEY W. BUXTON, M.D., F.R.C.P. Crown 8vo, 14s.

WHITE.—*Materia Medica, Pharmacy, Pharmacology, and Therapeutics*. By W. HALE WHITE, M.D., F.R.C.P., Physician to, and Lecturer on *Materia Medica* and Therapeutics at Guy's Hospital; Examiner in *Materia Medica* to the Conjoin Board of England. Fcap. 8vo, 7s. 6d.

MEDICINE.

CHARTERIS.—The *Student's Guide to the Practice of Medicine*. By M. CHARTERIS, M.D., Professor of Therapeutics and *Materia Medica*, University of Glasgow. With Engravings on Copper and Wood. Sixth Edition. Fcap. 8vo, 9s.

11, *NEW BURLINGTON STREET.*

MEDICINE—*continued.*

FAGGE AND PYE-SMITH.—**The Principles and Practice of Medicine.** By the late C. HILTON FAGGE, M.D., F.R.C.P., and PHILIP H. PYE-SMITH, M.D., F.R.S., F.R.C.P., Physician to, and Lecturer on Medicine in, Guy's Hospital. Third Edition. 2 Vols. 8vo. Cloth, 40s., leather, 46s.

FENWICK.—**The Student's Guide to Medical Diagnosis.** By SAMUEL FENWICK, M.D., F.R.C.P., Physician to the London Hospital. Seventh Edition. With 117 Engravings. Fcap. 8vo, 7s.

By the same Author.

Outlines of Medical Treatment, including Foreign as well as English Methods. Third Edition. Crown 8vo, 10s.

FOWLER.—**A Dictionary of Practical Medicine.** By Various Writers. Edited by JAMES KINGSTON FOWLER, M.A., M.D., F.R.C.P., Physician to Middlesex Hospital and the Hospital for Consumption, Brompton. 8vo., cloth, 21s. ; half-calf, 25s

HARRIS.—**The Student's Guide to Diseases of the Chest.** By VINCENT D. HARRIS, M.D., F.R.C.P., Physician to the Victoria Park Hospital for Diseases of the Chest. With 55 Engravings, plain and Coloured. Fcap. 8vo, 7s. 6d.

NIXON.—**Handbook of Hospital Practice and Physical Diagnosis.** By CHRISTOPHER J. NIXON, M.D., LL.D. Professor of Medicine in the Catholic University, Dublin; Examiner in Medicine, R.C.P.I., and for the Conjoint Examinations of R.C.P. and S. Irel. With Plates and Engravings. 8vo, 9s.

ORMEROD.—**Diseases of the Nervous System (Student's Guide Series).** By J. A. ORMEROD, M.D., F.R.C.P., Physician to the National Hospital for the Paralysed and Epileptic. With 66 Illustrations. Fcap. 8vo, 8s. 6d.

TAYLOR.—**A Manual of the Practice of Medicine.** By FREDERICK TAYLOR, M.D., F.R.C.P., Physician to, and Lecturer on Medicine at, Guy's Hospital. Second Edition. With 24 Illustrations. Crown 8vo, 15s.

WEST.—**How to Examine the Chest: a Practical Guide for the Use of Students** By SAMUEL WEST, M.D., F.R.C.P., Assistant Physician and Medical Tutor to St. Bartholomew's Hospital. Second Edition. With 46 Engravings. Fcap. 8vo, 5s.

MIDWIFERY.

- BARNES.**—Lectures on Obstetric Operations, including the Treatment of Hæmorrhage, and forming a Guide to the Management of Difficult Labour. By ROBERT BARNES, M.D., F.R.C.P., Consulting Obstetric Physician to St. George's Hospital. Fourth Edition. With 121 Engravings. 8vo, 12s. 6d.
- BURTON.**—Handbook of Midwifery for Midwives. By JOHN E. BURTON, M.R.C.S., L.R.C.P., Surgeon to the Liverpool Hospital for Women. Second Edition. With Engravings. Fcap 8vo, 6s.
- GALABIN.**—A Manual of Midwifery. By Alfred LEWIS GALABIN, M.A., M.D., F.R.C.P., Obstetric Physician and Lecturer on Midwifery, &c., to Guy's Hospital, Examiner in Midwifery to the Conjoint Examining Board for England. Second Edition. With 249 Engravings. Crown 8vo, 15s.
- REYNOLDS.**—Notes on Midwifery: specially designed to assist the Student in preparing for Examination. By J. J. REYNOLDS, L.R.C.P., M.R.C.S. Second Edition. With 15 Engravings. Fcap. 8vo, 4s.
- ROBERTS.**—The Student's Guide to the Practice of Midwifery. By D. LLOYD ROBERTS, M.D., F.R.C.P., Lecturer on Clinical Midwifery and Diseases of Women at Owen's College, Physician to St. Mary's Hospital, Manchester. Third Edition. With 2 Coloured Plates and 127 Engravings. Fcap. 8vo, 7s. 6d.
- SWAYNE.**—Obstetric Aphorisms for the Use of Students commencing Midwifery Practice. By JOSEPH G. SWAYNE, M.D., Lecturer on Obstetric Medicine at the Bristol Medical School. Ninth Edition. With 17 Engravings. Fcap. 8vo, 3s. 6d.

MICROSCOPY.

- CARPENTER.**—The Microscope and its Revelations. By WILLIAM B. CARPENTER, C.B., M.D., F.R.S. Seventh Edition. Edited by Rev. Dr. DALLINGER, F.R.S. With 21 Plates and 800 Woodcuts. 8vo, 26s.
- LEE.**—The Microtomist's Vade-Mecum; a Handbook of the Methods of Microscopic Anatomy. By ARTHUR BOLLES LEE, Assistant in the Russian Laboratory of Zoology at Villefranche-sur-Mer (Nice). Second Edition. 8vo, 12s. 6d.

11, NEW BURLINGTON STREET.

OPHTHALMOLOGY.

GOWERS.—A Manual and Atlas of Medical Ophthalmoscopy. By W. R. GOWERS, M.D., F.R.S., F.R.C.P., Physician to the National Hospital for the Paralysed and Epileptic. Third Edition. Edited with the assistance of MARCUS GUNN, M.B., F.R.C.S., Surgeon to the Royal London Ophthalmic Hospital; Ophthalmic Surgeon to the National Hospital for the Paralysed and Epileptic. With 12 Autotype Plates and 83 Engravings. 8vo, 16s.

HARTRIDGE.—The Refraction of the Eye. By GUSTAVUS HARTRIDGE, F.R.C.S., Surgeon to the Royal Westminster Ophthalmic Hospital. Sixth Edition. With 98 Illustrations, Test Types, &c. Crown 8vo, 6s.

By the same Author.

The Ophthalmoscope: A Manual for Students. With 2 Coloured Plates and 63 Engravings. Post 8vo 4s.

HIGGENS.—Hints on Ophthalmic Out-Patient Practice. By CHARLES HIGGENS, F.R.C.S., Ophthalmic Surgeon to, and Lecturer on Ophthalmology at, Guy's Hospital. Third Edition. Fcap. 8vo, 3s.

MACNAMARA.—Diseases and Refraction of the Eye. By CHARLES MACNAMARA, F.R.C.S., and GUSTAVUS HARTRIDGE, F.R.C.S., Surgeons to the Royal Westminster Ophthalmic Hospital. Fifth Edition. With 156 Engravings. Crown 8vo, 10s. 6d.

NETTLESHIP.—The Student's Guide to Diseases of the Eye. By EDWARD NETTLESHIP, F.R.C.S., Ophthalmic Surgeon to St. Thomas's Hospital, Surgeon to the Royal London Ophthalmic Hospital. Fifth Edition. With 164 Engravings, and a Coloured Plate illustrating Colour-blindness. Fcap. 8vo, 7s. 6d.

POLLOCK.—The Normal and Pathological Histology of the Human Eye and Eyelids. By C. FRED. POLLOCK, M.D., F.R.C.S.E., and F.R.S.E., Surgeon for Diseases of the Eye, Anderson's College Dispensary, Glasgow. With 100 Plates, containing 230 Original Drawings by the Author, Lithographed in black and colours. Crown 8vo, 15s.

WOLFE.—On Diseases and Injuries of the Eye: a Course of Systematic and Clinical Lectures to Students and Medical Practitioners. By J. R. WOLFE, M.D., F.R.C.S.E., Senior Surgeon to the Glasgow Ophthalmic Institution, Lecturer on Ophthalmic Medicine and Surgery in Anderson's College. With 10 Coloured Plates, and 120 Wood Engravings, 8vo, 21s.

PATHOLOGY.

BOWLBY.—*The Student's Guide to Surgical Pathology and Morbid Anatomy.* By ANTHONY A. BOWLBY, F.R.C.S., Assistant Surgeon to, and Demonstrator of Practical Surgery and Surgical Pathology at, St. Bartholomew's Hospital. Second Edition. With 158 Engravings. Fcap. 8vo, 9s.

JONES AND SIEVEKING.—*A Manual of Pathological Anatomy.* By C. HANDFIELD JONES, M.B., F.R.S., and SIR EDWARD H. SIEVEKING, M.D., F.R.C.P. Second Edition. Edited, with considerable enlargement, by J. F. PAYNE, M.B., Physician to St. Thomas's Hospital. With 195 Engravings. Crown 8vo, 16s.

LANCEREAUX.—*Atlas of Pathological Anatomy.* By Dr. LANCEREAUX. Translated by W. S. GREENFIELD, M.D., Professor of Pathology in the University of Edinburgh. With 70 Coloured Plates. Imperial 8vo, £5 5s.

MOORE.—*Pathological Anatomy of Diseases,* arranged according to the Nomenclature of Diseases of the R.C.P. Lond. By NORMAN MOORE, M.D., Assistant Physician and Lecturer on Pathological Anatomy to St. Bartholomew's Hospital. With 110 Illustrations. Fcap. 8vo, 8s. 6d.

SUTTON.—*Lectures on Pathology delivered at the London Hospital.* By the late HENRY GAWEN SUTTON, M.B., F.R.C.P., Physician and Lecturer on Pathology at the London Hospital, &c. Edited by MAURICE EDEN PAUL, M.D., and Revised by SAMUEL WILKS, M.D., LL.D., F.R.S. 8vo, 15s.

SUTTON. — *An Introduction to General Pathology.* By JOHN BLAND SUTTON, F.R.C.S., Sir E. WILSON Lecturer on Pathology, R.C.S.; Assistant Surgeon to, and Lecturer on Anatomy at, Middlesex Hospital. With 149 Engravings. 8vo, 14s.

WYNTER AND WETHERED.—*A Manual of Clinical and Practical Pathology.* By W. ESSEX WYNTER, M.D., Medical Registrar and late Demonstrator of Anatomy and Chemistry at the Middlesex Hospital; and FRANK J. WETHERED, M.D., Assistant Physician to the City of London Hospital for Diseases of the Chest. With 4 Coloured Plates and 67 other Illustrations, 8vo, 12s. 6d.

11, *NEW BURLINGTON STREET.*

PHYSIOLOGY.

CARPENTER.—**Principles of Human Physiology.** By WILLIAM B. CARPENTER, C.B., M.D., F.R.S. Ninth Edition. Edited by Henry Power, M.B., F.R.C.S. With 3 Steel Plates and 377 Wood Engravings. 8vo, 31s. 6d.

DALTON.—**A Treatise on Human Physiology :** designed for the use of Students and Practitioners of Medicine. By JOHN C. DALTON, M.D., Professor of Physiology and Hygiene in the College of Physicians and Surgeons, New York. Seventh Edition. With 252 Engravings. Royal 8vo, 20s.

FREY.—**The Histology and Histo-Chemistry of Man.** A Treatise on the Elements of Composition and Structure of the Human Body. By HEINRICH FREY, Professor of Medicine in Zurich. Translated by ARTHUR E. BARKER, Surgeon to the University College Hospital. With 608 Engravings. 8vo, 21s.

SANDERSON.—**Handbook for the Physiological Laboratory :** containing an Exposition of the fundamental facts of the Science, with explicit Directions for their demonstration. By J. BURDON SANDERSON, M.D., F.R.S.; E. KLEIN, M.D., F.R.S.; MICHAEL FOSTER, M.D., F.R.S., and T. LAUDER BRUNTON, M.D., F.R.S. 2 Vols., with 123 Plates. 8vo, 24s.

STARLING.—**Elements of Human Physiology.** By ERNEST H. STARLING, M.D., M.R.C.P., Joint Lecturer on Physiology at Guy's Hospital. With 94 Engravings. Fcap. 8vo, 6s. 6d.

YEO.—**A Manual of Physiology for the Use of Junior Students of Medicine.** By GERALD F. YEO, M.D., F.R.C.S., F.R.S., late Professor of Physiology in King's College, London. Second Edition. With 318 Engravings (many figures). Crown 8vo, 14s.

PSYCHOLOGY.

BUCKNILL AND TUKE.—**A Manual of Psychological Medicine :** containing the Lunacy Laws, Nosology, Ætiology, Statistics, Description, Diagnosis, Pathology, and Treatment of Insanity, with an Appendix of Cases. By JOHN C. BUCKNILL, M.D. F.R.S., and D. HACK TUKE, M.D., F.R.C.P. Fourth Edition, with 12 Plates (30 Figures). 8vo, 25s.

CLOUSTON.—**Clinical Lectures on Mental Diseases.** By THOMAS S. CLOUSTON, M.D., and F.R.C.P. Edin.; Lecturer on Mental Diseases in the University of Edinburgh. Third Edition. With 13 Plates. Crown 8vo, 14s.

SURGERY.

BELLAMY.—The Student's Guide to Surgical Anatomy; an Introduction to Operative Surgery. By EDWARD BELLAMY, F.R.C.S., late Surgeon to, and Lecturer on Surgery at, Charing Cross Hospital. Third Edition. With 80 Engravings. Fcap. 8vo, 7s. 6d.

BRYANT.—A Manual for the Practice of Surgery. By THOMAS BRYANT, F.R.C.S., Consulting Surgeon to Guy's Hospital. Fourth Edition. With 750 Illustrations (many being coloured), and including 6 Chromo-Lithographic Plates. 2 Vols. Crown 8vo, 32s.

DRUITT AND BOYD.—Druitt's Surgeon's Vade-Mecum; a Manual of Modern Surgery. Edited by STANLEY BOYD, M.B., B.S. Lond., F.R.C.S., Assistant Surgeon and Pathologist to the Charing Cross Hospital. Twelfth Edition. With 373 Engravings. Crown 8vo, 16s.

HEATH.—A Manual of Minor Surgery and Bandaging. By CHRISTOPHER HEATH, F.R.C.S., Holme Professor of Clinical Surgery in University College and Surgeon to the Hospital. Ninth Edition. With 146 Engravings. Fcap. 8vo, 6s.

By the same Author.

A Course of Operative Surgery: with
Twenty Plates (containing many figures) drawn from Nature by
M. LÉVEILLÉ, and Coloured. Second Edition. Large 8vo, 30s.

ALSO,

The Student's Guide to Surgical Diag-
nosis. Second Edition. Fcap. 8vo, 6s. 6d.

JACOBSON.—The Operations of Surgery: intended especially for the use of those recently appointed on a Hospital Staff, and for those preparing for the Higher Examinations. By W. H. A. JACOBSON, M.A., M.B., M.Ch. Oxon., F.R.C.S. Assistant Surgeon to Guy's Hospital, and Lecturer on Anatomy in the Medical School. Second Edition. With 235 Engravings. 8vo, 30s.

11, NEW BURLINGTON STREET.

SURGERY—*continued.*

MOULLIN.—Surgery. By C. W. Mansell

Moullin, M.A., M.D.Oxon., F.R.C.S., Surgeon to, and Lecturer on Physiology at, the London Hospital; formerly Radcliffe Travelling Fellow and Fellow of Pembroke College, Oxford. With 497 Illustrations. 8vo, 34s.

WALSHAM.—Surgery: its Theory and Practice

(Student's Guide Series). By WILLIAM J. WALSHAM, F.R.C.S., M.B., and C.M. Aberd., Senior Assistant Surgeon to, and Lecturer on Anatomy at, St. Bartholomew's Hospital. Fourth Edition. With 335 Engravings. Fcap. 8vo, 12s.

TERMINOLOGY.

MAXWELL.—Terminologia Medica Polyglotta :

a Concise International Dictionary of Medical Terms (French, Latin, English, German, Italian, Spanish, and Russian). By THEODORE MAXWELL, M.D., B.Sc. Lond., F.R.C.S. Edin. Roy. 8vo, 16s.

MAYNE.—A Medical Vocabulary: being an

Explanation of all Terms and Phrases used in the various Departments of Medical Science and Practice, giving their Derivation, Meaning, Application, and Pronunciation. By R. G. MAYNE, M.D., LL.D. Sixth Edition, by W. W. WAGSTAFFE, B.A., F.R.C.S. Crown 8vo, 10s. 6d.

A Short Dictionary of Medical Terms, 2s. 6d.

TREVES AND LANG.—A German-English Dic-

tionary of Medical Terms. By FREDERICK TREVES, F.R.C.S., Surgeon to the London Hospital, and HUGO LANG, B.A. Half-bound in calf, 12s.

WOMEN, DISEASES OF.

BARNES.—A Clinical History of the Medical

and Surgical Diseases of Women. By ROBERT BARNES, M.D., F.R.C.P., Obstetric Physician to, and Lecturer on Diseases of Women, &c., at St George's Hospital. Second Edition. With 181 Engravings. 8vo, 28s.

DUNCAN.—Clinical Lectures on the Diseases

of Women. By J. MATTHEWS DUNCAN, A.M., M.D., LL.D., F.R.C.P., F.R.S., late Physician Accoucheur to, and Lecturer on Midwifery at St. Bartholomew's Hospital. Fourth Edition. 8vo, 16s.

WOMEN, DISEASES OF—*continued.*

GALABIN.—The Student's Guide to the Diseases of Women. By ALFRED L. GALABIN, M.D., F.R.C.P., Obstetric Physician to Guy's Hospital, Examiner in Obstetric Medicine to the University of Cambridge, and to the R. C. P. Lond. Fifth Edition. With Engravings. Fcap. 8vo.

REYNOLDS.—Notes on Diseases of Women. Specially designed to assist the Student in preparing for Examination. By J. J. REYNOLDS, L.R.C.P., M.R.C.S. Third Edition. Fcap. 8vo, 2s. 6d.

SAVAGE.—The Surgery of the Female Pelvic Organs. By HENRY SAVAGE, M.D., Lond., F.R.C.S., one of the Consulting Medical Officers of the Samaritan Hospital for Women. Fifth Edition. With 17 Lithographic Plates and 52 Woodcuts. Royal 4to, Coloured Plates, 35s.; Uncoloured, 15s.

WEST AND DUNCAN.—Lectures on the Diseases of Women. By CHARLES WEST, M.D., F.R.C.P. Fourth Edition. Revised and in part re-written by the Author, with numerous additions by J. MATTHEWS DUNCAN, M.D., F.R.C.P., F.R.S., late Obstetric Physician to St. Bartholomew's Hospital. 8vo, 16s.

ZOOLOGY.

CHAUVEAU AND FLEMING.—The Comparative Anatomy of the Domesticated Animals. By A. CHAUVEAU, Professor at the Lyons Veterinary School; and GEORGE FLEMING, C.B., late Principal Veterinary Surgeon of the Army. Second Edition. With 585 Engravings. 3ls. 6d.

HUXLEY.—Manual of the Anatomy of Invertebrated Animals. By THOMAS H. HUXLEY, LL.D., F.R.S. With 156 Engravings. Post 8vo, 16s.

By the same Author.

Manual of the Anatomy of Vertebrated Animals. With 110 Engravings. Post 8vo, 12s.

WILSON.—The Student's Guide to Zoology: a Manual of the Principles of Zoological Science. By ANDREW WILSON, Lecturer on Natural History, Edinburgh. With Engravings. Fcap. 8vo, 6s. 6d.

11, NEW BURLINGTON STREET.

